

A practical treatise on fractures and dislocations / by Frank Hastings Hamilton.

Contributors

Hamilton, Frank Hastings, 1813-1886.
Smith, Stephen, 1823-1922
Francis A. Countway Library of Medicine

Publication/Creation

Philadelphia : Lea Brothers, 1891.

Persistent URL

<https://wellcomecollection.org/works/h748e5e3>


License and attribution

This material has been provided by This material has been provided by the Francis A. Countway Library of Medicine, through the Medical Heritage Library. The original may be consulted at the Francis A. Countway Library of Medicine, Harvard Medical School. where the originals may be consulted. This work has been identified as being free of known restrictions under copyright law, including all related and neighbouring rights and is being made available under the Creative Commons, Public Domain Mark.


You can copy, modify, distribute and perform the work, even for commercial purposes, without asking permission.





Wellcome Collection
183 Euston Road
London NW1 2BE UK
T +44 (0)20 7611 8722
E library@wellcomecollection.org
<https://wellcomecollection.org>




23. 6. 71.









Digitized by the Internet Archive
in 2011 with funding from
Open Knowledge Commons and Harvard Medical School

A

PRACTICAL TREATISE

ON

FRACTURES AND DISLOCATIONS.

BY


FRANK HASTINGS HAMILTON, A.B., A.M., M.D.; LL.D.,
LATE PROFESSOR OF SURGERY IN BELLEVUE HOSPITAL MEDICAL COLLEGE, AND SURGEON TO
BELLEVUE HOSPITAL, NEW YORK; CONSULTING SURGEON TO HOSPITAL FOR RUPTURED
AND CRIPPLED, TO ST. ELIZABETH'S HOSPITAL, ETC.; AUTHOR OF A TREATISE
ON MILITARY SURGERY AND HYGIENE, A TREATISE ON THE
PRINCIPLES AND PRACTICE OF SURGERY, ETC.

EIGHTH EDITION,

REVISED AND EDITED BY

STEPHEN SMITH, A.M., M.D.,
PROFESSOR OF CLINICAL SURGERY IN THE UNIVERSITY OF THE CITY OF NEW YORK, AND
SURGEON TO BELLEVUE AND ST. VINCENT'S HOSPITALS, NEW YORK.


ILLUSTRATED WITH FIVE HUNDRED AND SEVEN WOODCUTS.



PHILADELPHIA:
LEA BROTHERS & CO.
1891.

8415

Entered according to the Act of Congress, in the year 1891, by
LEA BROTHERS & CO.,
in the Office of the Librarian of Congress. All rights reserved.



PREFACE BY THE EDITOR.

THE preparation of this edition for the press has been a grateful service to the Editor. He was a pupil of the Author at the time of the conception of the work, and during the period of the collection and arrangement of the greater part of the materials for the first edition. Subsequently he was associated with the Author, for many years, in the same school and hospital. These intimate relations gave to the Editor direct familiarity with much of the original clinical matter which enriches the volume. He was also personally cognizant of the vast amount of labor bestowed on the work by the Author in his efforts to perfect the several editions, and his conscientious regard for truth and accuracy of detail, so noticeable on every page. It is doubtful if any surgical work has appeared during the last half century which more completely filled the place for which it was designed. Its great merits appear most conspicuously in its clear, concise, and yet comprehensive statement of principles, which renders it an admirable text-book for teacher and pupil, and in its wealth of clinical materials, which adapts it to the daily necessities of the practitioner. The efforts of the Editor have been in the direction of rendering the text more compact, of eliminating matter now irrelevant, of using a subordinate type for clinical cases, of illustrating the various subjects more fully by selected cuts, and of adding such new facts, cases, and opinions as were deemed necessary to render the work a correct exponent of the present state of knowledge in this department of practice. He trusts that these changes and additions to the last edition will prove to have, in some degree, enhanced the practical value and usefulness of the work.

The new illustrations, amounting to one hundred and five, have been selected chiefly from such well-known works as Erichsen, Bryant, Stimson, Pick, Pye, etc.

STEPHEN SMITH.

NEW YORK, JANUARY, 1891.

AUTHOR'S PREFACE TO SEVENTH AMERICAN EDITION.

SOME apology or explanation may be due to many of the writers on these subjects who have been occupied, especially of late, in experiments upon the cadaver, for the purpose of determining the nature, causes, mechanism, and treatment of fractures in the vicinity of joints, and of dislocations, in that the Author has not, generally, attached to them the same degree of importance which the experimenters seem to have claimed for them.

There can be no doubt that most of these experiments furnish valuable information, which it would be unwise to reject; but it is equally beyond doubt that the results thus obtained cannot be accepted as illustrating precisely what usually occurs in traumatisms inflicted upon the living body, while the muscles retain their normal activity. In the case of fractures, the rigidity of the muscles is always a factor of great importance in determining the seat and character of the lesion, and in some cases it is the sole factor. In the case of dislocations the same is true, only in a much greater degree. A large proportion of traumatic dislocations are determined in their nature, direction, and extent by the violent, and often spasmodic, action of the muscles acting in connection with the direction and force of the external violence. Some are dependent solely upon the action of the muscles. It is also the sole determining cause in all idiopathic, spontaneous, or pathological dislocations. In neither fractures nor dislocations made upon the cadaver can this action be imitated or supplemented.

On the other hand, clinical observations alone cannot always be relied upon to settle a disputed point in the mechanism and nature of a traumatism belonging to the classes of which we are speaking, and especially when the question relates to a lesion involving a joint; and this partly because of the difficulty of making a diagnosis while the seat

of lesion is covered with soft and sensitive tissues, partly because of the fallibility of the testimony furnished by the patients themselves, and partly because of the fact that the reliability of the surgeon as an expert who has reported the case is not always established, and the report has not, therefore, any more value than common "hearsay."

Finally, nothing is more unreliable than the testimony furnished by cabinet specimens whose clinical history is wholly unknown; and in reference to which, in many cases, it is impossible to say whether their present condition was due to traumatism before or after death, or, indeed, whether it was not due to some long preëxisting pathological cause. The fact that by different students these specimens are often interpreted differently, is sufficient to justify the statement we have made as to their occasional worthlessness as testimony.

From the beginning of his studies, the Author has found one of his most difficult labors in attempting to eliminate from the branch of science which he has undertaken to teach, the numerous "false facts," or unreliable statements derived from these several sources; and this must be accepted as his apology for his repeated expressions of scepticism in reference to testimony, some of which has been accepted, as is believed without sufficient examination, by writers whose opinions might be regarded as of more value than his own.

FRANK H. HAMILTON.

43 W. 32D STREET, NEW YORK,

May 1, 1884.

CONTENTS.

PART I.

FRACTURES.

CHAPTER I.

	PAGE
GENERAL DIVISION OF FRACTURES	35

CHAPTER II.

GENERAL ETIOLOGY OF FRACTURES	37
---	----

CHAPTER III.

GENERAL SEMEIOLOGY AND DIAGNOSIS OF FRACTURES	41
---	----

CHAPTER IV.

REPAIR OF FRACTURES	46
-------------------------------	----

CHAPTER V.

GENERAL PROGNOSIS OF FRACTURES	51
--	----

CHAPTER VI.

GENERAL TREATMENT OF FRACTURES	55
--	----

CHAPTER VII.

DELAYED UNION, FIBROUS UNION, AND NON-UNION OF FRACTURES	74
--	----

CHAPTER VIII.

BENDING, PARTIAL FRACTURES, AND FISSURES OF THE LONG BONES	83
§ 1. Bending of the Long Bones	83
§ 2. Partial Fractures of the Long Bones	86
§ 3. Fissures	93

CHAPTER IX.

FRACTURES OF THE NOSE	96
§ 1. Fractures of the Ossa Nasi	96
§ 2. Fractures and Displacements of the Septum Narium	100

CHAPTER X.

	PAGE
FRACTURES OF THE MALAR BONE	102

CHAPTER XI.

FRACTURES OF THE UPPER MAXILLARY BONES	104
--	-----

CHAPTER XII.

FRACTURES OF THE ZYGOMATIC ARCH	109
---	-----

CHAPTER XIII.

FRACTURES OF THE LOWER JAW	111
--------------------------------------	-----

CHAPTER XIV.

FRACTURES OF THE HYOID BONE	131
---------------------------------------	-----

CHAPTER XV.

FRACTURES OF THE CARTILAGES OF THE LARYNX	135
§ 1. Fractures of the Thyroid Cartilage	138
§ 2. Fractures of the Thyroid and Cricoid Cartilages	139
§ 3. Fractures of the Cricoid Cartilage	140
§ 4. Fracture of the Condyle of the Occiput	140

CHAPTER XVI.

FRACTURES OF THE VERTEBRÆ	140
§ 1. Fractures of the Spinous Processes	140
§ 2. Fractures of the Transverse Process	142
§ 3. Fractures of the Vertebral Arches	143
§ 4. Fractures of the Bodies of the Vertebrae	147
1. Fractures of the Bodies of the Lumbar Vertebrae	149
2. Fractures of the Bodies of the Dorsal Vertebrae	151
3. Fractures of the Bodies of the Five Lower Cervical Vertebrae	151
4. Treatment of Fractures of the Bodies of the Vertebrae	153
§ 5. Fractures of the Axis and Odontoid Process	156
§ 6. Fractures of the Atlas	159
§ 7. Fractures of the First Two Cervical Vertebrae (Atlas and Axis) at the same time	160

CHAPTER XVII.

FRACTURES OF THE STERNUM	161
------------------------------------	-----

CHAPTER XVIII.

FRACTURES OF THE RIBS AND THEIR CARTILAGES	167
§ 1. Fractures of the Ribs	167
§ 2. Fractures of the Cartilages of the Ribs	171

CHAPTER XIX.

FRACTURES OF THE CLAVICLE	173
-------------------------------------	-----

CHAPTER XX.

	PAGE
FRACTURES OF THE SCAPULA	194
§ 1. Fractures of the Body of the Scapula	194
§ 2. Fractures of the Neck of the Scapula	198
§ 3. Fractures of the Acromion Process	199
§ 4. Fractures of the Coracoid Process	203

CHAPTER XXI.

FRACTURES OF THE HUMERUS	205
§ 1. Fractures of the Head and Anatomical Neck	206
§ 2. Fractures through the Tubercles	211
§ 3. Longitudinal Fractures of the Head and Neck, or Splitting off of the Greater Tubercle	212
§ 4. Fractures through the Surgical Neck (including Separations at the Upper Epiphysis)	213
§ 5. Fractures of the Shaft below the Surgical Neck, and above the Base of the Condyles	227
§ 6. Fractures at the Base of the Condyles (including Separations of the Lower Epiphysis)	237
§ 7. Fractures at the Base of the Condyles, complicated with Fracture between the Condyles, extending into the Joint	244
§ 8. Fractures of the Internal Epicondyle	247
§ 9. Fracture or Diastasis of the External Epicondyle	254
§ 10. Fractures of the Internal Condyle	255
§ 11. Fractures of the External Condyle	259
§ 12. Fractures of the Articular Processes of the Humerus (wholly within the Capsule)	262

CHAPTER XXII.

FRACTURES OF THE RADIUS	263
-----------------------------------	-----

CHAPTER XXIII.

FRACTURES OF THE ULNA	302
§ 1. Fractures of the Olecranon Process	302
§ 2. Fractures of the Coronoid Process	310
§ 3. Fractures of the Shaft	317
§ 4. Fractures of the Styloid Process	321

CHAPTER XXIV.

FRACTURES OF THE RADIUS AND ULNA	321
--	-----

CHAPTER XXV.

FRACTURES OF THE CARPAL BONES	329
---	-----

CHAPTER XXVI.

FRACTURES OF THE METACARPAL BONES	329
---	-----

CHAPTER XXVII.

	PAGE
FRACTURES OF THE FINGERS	332

CHAPTER XXVIII.

FRACTURES OF THE PELVIS, AND TRAUMATIC SEPARATIONS AT ITS SYM-	
PHYSES	335
§ 1. Fractures of the Pubes	336
(a) Separations at the Symphysis Pubis	336
(b) True Fractures of the Pubes	337
§ 2. Fractures of the Ischium	339
§ 3. Fractures of the Ilium	340
§ 4. Fractures of the Acetabulum	343
(a) Fractures of the Base	344
(b) Fractures of the Rim	346
§ 5. Fractures of the Sacrum	349
§ 6. Fractures of the Coccyx	351

CHAPTER XXIX.

FRACTURES OF THE FEMUR	352
§ 1. Fractures of the Neck of the Femur	353
(a) Neck of the Femur within the Capsule	354
(b) Neck of the Femur without the Capsule	370
(c) Neck of the Femur partly within and partly without the Capsule	377
§ 2. Fractures through the Trochanter Major and Base of the Neck of the Femur	379
(a) Fractures through the Process	379
(b) Fractures of the Process	380
(c) Fractures of the Epiphysis of the Trochanter Major	381
§ 3. Fractures of the Shaft of the Femur	382
§ 4. Fractures at or near the Base of the Condyle	419
§ 5. Fractures of the Condyles	422
(a) Fractures of the External Condyle	422
(b) Fractures of the Internal Condyle	424
(c) Fractures between the Condyles and across the Base	425
(d) Separation of the Lower Epiphysis	427
§ 6. Non-union and Delayed Union of Fractures of Shaft of Femur	428

CHAPTER XXX.

FRACTURES OF THE PATELLA	429
------------------------------------	-----

CHAPTER XXXI.

FRACTURES OF THE TIBIA	457
----------------------------------	-----

CHAPTER XXXII.

FRACTURES OF THE FIBULA	462
-----------------------------------	-----

CHAPTER XXXIII.

	PAGE
FRACTURES OF THE TIBIA AND FIBULA	470

CHAPTER XXXIV.

FRACTURES OF THE TARSAL BONES	491
---	-----

CHAPTER XXXV.

FRACTURES OF THE METATARSAL BONES	496
---	-----

CHAPTER XXXVI.

FRACTURES OF THE PHALANGES OF THE TOES	498
--	-----

CHAPTER XXXVII.

GUNSHOT FRACTURES	498
-----------------------------	-----

PART II.

DISLOCATIONS.

CHAPTER I.

GENERAL CONSIDERATIONS	511
§ 1. Division and Nomenclature	511
§ 2. Predisposing Causes	512
§ 3. Direct or Exciting Causes	513
§ 4. Symptoms	513
§ 5. Pathology	515
§ 6. Prognosis	516
§ 7. Treatment	516

CHAPTER II.

DISLOCATIONS OF THE LOWER JAW	519
§ 1. Double or Bilateral Dislocations	519
§ 2. Single or Unilateral Dislocations	524
§ 3. Dislocations Outward, with Fracture	524
§ 4. Dislocations Backward, with Fracture	525
§ 5. Conditions of the Jaw Simulating Dislocation	526

CHAPTER III.

DISLOCATIONS OF THE HYOID BONE	527
--	-----

CHAPTER IV.

DISLOCATIONS OF THE SPINE	528
§ 1. Dislocations of the Lumbar Vertebrae	529

	PAGE
§ 2. Dislocations of the Dorsal Vertebrae	530
§ 3. Dislocations of the Six Lower Cervical Vertebrae	532
§ 4. Dislocations of the Atlas	538
§ 5. Dislocations of the Head upon the Atlas, or Occipito-atloidean Dislocations	540

CHAPTER V.

DISLOCATIONS OF THE RIBS	541
§ 1. Dislocatione of the Ribs from the Vertebrae	541
§ 2. Dislocations of the Ribs from the Sternum	542
§ 3. Dislocations of One Cartilage upon Another	543

CHAPTER VI.

DISLOCATIONS OF THE CLAVICLE	544
§ 1. Sterno-clavicular	544
(a) Dislocations of the Sternal End of the Clavicle Forward	544
(b) Dislocations of the Sternal End of the Clavicle Upward	548
(c) Dislocations of the Sternal End of the Clavicle Backward	550
§ 2. Acromio-clavicular	552
(a) Dislocations of the Acromial End of the Clavicle Upward	552
(b) Dislocations of the Acromial End of the Clavicle Down- ward	559
(c) Dislocations of the Acromial End of the Clavicle under the Coracoid Process	560
(d) Dislocations of the Clavicle at both ends, simultaneously	561

CHAPTER VII.

DISLOCATIONS OF THE SHOULDER (SCAPULO-HUMERAL)	563
§ 1. Dislocations of the Shoulder Downward (Subglenoid)	564
Dislocations, with Fracture of the Humerus near its Upper End	592
§ 2. Dislocations of the Humerus Forward (Subcoracoid and Subcla- vicular)	594
§ 3. Dislocations of the Humerus Backward (Subspinous)	601
§ 4. Dislocations of the Humerus Upward	606
§ 5. Partial Dislocations of the Humerus	612

CHAPTER VIII.

DISLOCATIONS OF THE HEAD OF THE RADIUS (HUMERO-RADIAL)	616
§ 1. Dislocations of the Head of the Radius Forward	615
§ 2. Dislocations of the Head of the Radius Backward	621
§ 3. Dislocations of the Head of the Radius Outward	624
§ 4. Dislocations of the Head of the Radius Downward	626

CHAPTER IX.

DISLOCATIONS OF THE UPPER END OF THE ULNA (HUMERO-ULNAR)	629
§ 1. Dislocations of the Upper End of the Ulna Backward	629
§ 2. Dislocations of the Upper End of the Ulna Inward	631

CHAPTER X.

	PAGE
DISLOCATIONS OF THE RADIUS AND ULNA (FOREARM) AT THE ELBOW-JOINT	631
§ 1. Dislocations of the Radius and Ulna Backward	631
§ 2. Dislocations of the Radius and Ulna Outward (to the Radial Side)	640
(a) Complete Outward Dislocations	640
(b) Incomplete Outward Dislocations	642
§ 3. Dislocations of the Radius and Ulna Inward (to the Ulnar Side)	646
§ 4. Dislocations of the Radius and Ulna Forward	649
§ 5. Diverging Dislocations of the Radius and Ulna	651
(a) Dislocations of the Radius Forward and Ulna Backward .	651
(b) Transverse, Ulna Inward, and Radius Outward	652
(c) Oblique, Ulna Backward, and Radius Outward	652
(d) Oblique, Ulna Forward, and Radius Outward	652

CHAPTER XI.

DISLOCATIONS OF THE WRIST (RADIO-CARPAL)	652
§ 1. Dislocations of the Carpal Bones Backward	655
§ 2. Dislocations of the Carpal Bones Forward	657

CHAPTER XII.

DISLOCATIONS OF THE LOWER END OF THE ULNA (INFERIOR RADIO-ULNAR)	658
§ 1. Dislocations of the Lower End of the Ulna Backward	659
§ 2. Dislocations of the Lower End of the Ulna Forward	660

CHAPTER XIII.

DISLOCATIONS OF THE CARPAL BONES (AMONG THEMSELVES)	661
---	-----

CHAPTER XIV.

DISLOCATIONS OF THE METACARPAL BONES (AT THE CARPO-METACARPAL ARTICULATIONS)	663
§ 1. Dislocations of the Metacarpal Bone of the Thumb Backward .	663
§ 2. Dislocations of the Metacarpal Bone of the Thumb Forward .	665
§ 3. Dislocations of the Metacarpal Bone of the Fingers	665

CHAPTER XV.

DISLOCATIONS OF THE FIRST PHALANGES OF THE THUMB AND FINGERS (METACARPO-PHALANGEAL)	667
(a) Dislocations of the First Phalanx of the Thumb Backward . .	667
(b) Dislocations of the First Phalanx of the Thumb Forward . . .	674
(c) Lateral Dislocation of the last Phalanx	675
(d) Dislocations of the First Phalanx of the Fingers	675

CHAPTER XVI.

DISLOCATIONS OF THE SECOND AND THIRD PHALANGES OF THE THUMB AND FINGERS (PHALANGEAL)	676
--	-----

CHAPTER XVII.

	PAGE
DISLOCATIONS OF THE THIGH (COXO-FEMORAL)	678
§ 1. Dislocations Upward and Backward on the Dorsum Ilii	681
§ 2. Dislocations Upward and Backward into the Great Ischiatic Notch	706
§ 3. Dislocations Downward and Forward into the Foramen Thyroideum	713
§ 4. Dislocations upward and Forward upon the Pubes	720
§ 5. Anomalous Dislocations, or Dislocations which do not properly belong to either of the four principal divisions before described	726
1. Dislocations directly Upward above the Margin of the Acetabulum, and Below the Anterior Inferior Spinous Process	726
2. Dislocations directly Upward, between the Anterior Inferior and Anterior Superior Spinous Processes	729
3. Dislocations Upward upon the Dorsum Ilii, and near its Anterior Margin	731
4. Dislocations Downward and Backward upon the Posterior Part of the Body of the Ischium, between its Tuberosity and its Spine	732
5. Dislocations Downward and Backward into the Lesser or Lower Ischiatic Notch	732
6. Dislocations directly Downward	733
7. Dislocations Forward into the Perineum	734
§ 6. Ancient Dislocations of the Femur	735
§ 7. Partial Dislocations of the Femur	740
§ 8. Coxo-Femoral Dislocations, complicated with Fracture of the Femur	741
§ 9. Voluntary or Spontaneous Dislocations of the Femur	743

CHAPTER XVIII.

DISLOCATIONS OF THE PATELLA	751
§ 1. Dislocations of the Patella Outward	751
§ 2. Dislocations of the Patella Inward	755
§ 3. Dislocations of the Patella upon its Axis	755
(a) Vertical	755
(b) Complete Version	758
§ 4. Dislocations of the Patella Upward	759

CHAPTER XIX.

DISLOCATIONS OF THE HEAD OF THE TIBIA (FEMORO-TIBIAL)	760
§ 1. Dislocations of the Head of the Tibia Backward	761
§ 2. Dislocations of the Head of the Tibia Forward	762
§ 3. Dislocations of the Head of the Tibia Outward	764
§ 4. Dislocations of the Head of the Tibia Inward	765
§ 5. Dislocations of the Head of the Tibia Backward and Outward	766
§ 6. Dislocations of the Head of the Tibia Forward and Outward	767
§ 7. Dislocations of the Head of the Tibia Forward and Inward	767

	PAGE
‡ 8. Dislocations of the Head of the Tibia by Rotation	768
‡ 9. Internal Derangement of the Knee-Joint	768

CHAPTER XX.

DISLOCATIONS OF THE LOWER END OF THE TIBIA (TIBIO-TARSAL)	770
‡ 1. Dislocations of the Lower End of the Tibia Inward	771
‡ 2. Dislocations of the Lower End of the Tibia Outward	775
‡ 3. Dislocations of the Lower End of the Tibia Forward	776
‡ 4. Dislocations of the Lower End of the Tibia Backward	779

CHAPTER XXI.

DISLOCATIONS OF THE UPPER END OF THE FIBULA	781
‡ 1. Dislocations of the Upper End of the Fibula Forward	781
‡ 2. Dislocations of the Upper End of the Fibula Backward	782
‡ 3. Displacement of the Head of the Fibula with Fracture	783

CHAPTER XXII.

DISLOCATIONS OF THE LOWER END OF THE FIBULA	784
---	-----

CHAPTER XXIII.

TARSAL DISLOCATIONS	784
‡ 1. Dislocations of the Astragalus	784
‡ 2. Astragalo-calcaneo-scaphoid Dislocations	794
‡ 3. Dislocations of the Calcaneum	795
‡ 4. Middle Tarsal Dislocations	796
‡ 5. Dislocations of the Cuboid Bone	797
‡ 6. Dislocations of the Scaphoid Bone	797
‡ 7. Dislocations of the Cuneiform Bones	798

CHAPTER XXIV.

DISLOCATIONS OF THE METATARSAL BONES	800
--	-----

CHAPTER XXV.

DISLOCATIONS OF THE PHALANGES OF THE TOES	802
---	-----

CHAPTER XXVI.

COMPOUND DISLOCATIONS OF THE LONG BONES	803
---	-----

CHAPTER XXVII.

CONGENITAL DISLOCATIONS	807
Etiology	818
‡ 1. Congenital Dislocations of the Inferior Maxilla	820
‡ 2. Congenital Dislocations of the Spine	823
‡ 3. Congenital Dislocations of the Pelvic Bones	824
‡ 4. Congenital Dislocations of the Sternum	824
‡ 5. Congenital Dislocations of the Clavicle	825
‡ 6. Congenital Dislocations of the Shoulder (Upper End of the Humerus)	825

	PAGE
§ 7. Congenital Dislocations of the Radius and Ulna Backward	829
§ 8. Congenital Dislocations of the Head of the Radius	830
§ 9. Congenital Dislocations of the Wrist	830
§ 10. Congenital Dislocations of the Fingers	831
§ 11. Congenital Dislocations of the Hip	831
§ 12. Congenital Dislocations of the Patella	837
§ 13. Congenital Dislocations of the Knee	838
§ 14. Congenital Dislocations of the Tarsal Bones	841
§ 15. Congenital Dislocations of the Toes	841

PART I.

FRACTURES.



FRACTURES.

CHAPTER I.

GENERAL DIVISION OF FRACTURES.

A Complete fracture is one in which the line of division completely traverses the bone.

An Incomplete fracture is a partial separation of the bone: under which name are included Bending, Partial fractures, Fissures, Indented fractures, and Punctured or Perforating fractures, the last of which is almost peculiar to gunshot injuries.

A Simple fracture is one in which the bone is broken at only one point. The term has no reference to the question of complications, but in its technical meaning, as employed by both English and American surgeons, it has reference only to the number of fragments into which the bone is broken.

It would be more correct, perhaps, to substitute the word "single" for "simple," as has been done by Malgaigne and some other French writers, but I fear that to American surgeons the substitution would be rather a source of confusion than otherwise.

A Comminuted fracture, called by Malgaigne "multiple," is a fracture in which the bone is broken at more than one point, and in which, consequently, the bone is divided into more than two fragments. It is used in a technical sense, and by no means implies minute division or comminution of the fragments.

A Compound fracture is technically one in which there exists also an external wound communicating with the bone at the point of fracture. It may be either partial or complete, simple or comminuted, or even complicated, while at the same time it is also compound.

Complicated fractures are such as present additional complications, or complications for which no other specific term has been invented, as, with the lesion of an important bloodvessel or nerve, or with great contusion or laceration of the soft parts, with a dislocation, or with fractures of other bones, or even with some constitutional fault.

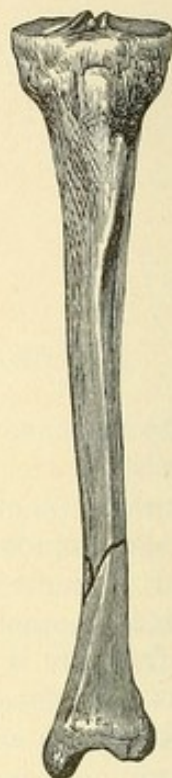A Transverse fracture exists whenever the obliquity is only moderate, or when, in the examination of a limb, although we are unable to detect the precise line of the fracture, we ascertain that, without being impacted or serrated, the ends of the bones continue to rest upon each other, or, being replaced, do not spontaneously become displaced.

A **Longitudinal fracture** occurs generally in connection with an oblique or transverse fracture; as when the lower end of the femur is

FIG. 1.



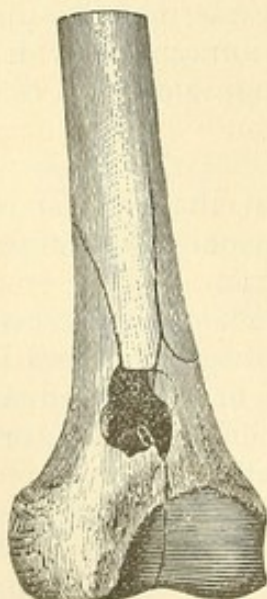
Transverse, serrated (denticulated) fracture.



Oblique fracture. Called also V-shaped.
From author's collection.

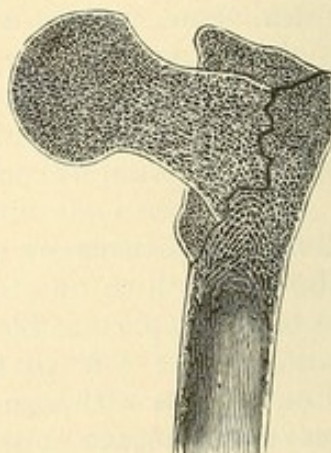
split vertically into the joint, and the shaft of the bone is traversed horizontally by a fracture which intercepts the vertical or longitudinal fracture.

FIG. 2.



Perforating and longitudinal fracture.

FIG. 3.



Impacted, extracapsular fracture of neck of femur. Vertical section.

A fracture of a condyle, or of any projection from the body of the bone, is called longitudinal if the direction of the line of fracture is parallel, or nearly so, to the axis of the shaft.

A Serrated or Denticulated fracture is one in which the opposite surfaces denticulate, the elevations upon one fragment being reflected by corresponding depressions upon the other.

Impacted fractures are those in which the fragments are driven into each other, the lamellated structure of one fragment penetrating the cancellous structure of the other.

We speak also of fractures by avulsion, or *arrachement*, which are due in most cases to the action of the ligaments, but occasionally to the action of the tendons. They occur mostly in the vicinity of the joints, and consist in the separation of minute fragments or scales of bone, or of tubercles and tuberosities to which ligaments or muscles are attached, and occasionally of considerable portions of the articular ends of bones.

Epiphyseal separations we class with fractures, and submit them to the same rules of nomenclature. These accidents rarely occur after the twentieth year of life; since after this period, and in the case of some bones, at a much earlier period, the epiphyses are usually united to the diaphyses by bone.

A large proportion of these accidents seem to be due to *arrachement*, the epiphyses being torn off by the action of the ligaments or of the muscles. Suppuration and necrosis are more frequent sequences than in the case of true fractures.

CHAPTER II.

GENERAL ETIOLOGY OF FRACTURES.

Predisposing Causes.—Partial fractures, with bending of the bones, are most frequent in infancy and childhood; but complete fractures occur most often during manhood; and if they are again less frequent in old age, it is because the exciting causes are less operative, since the fragility of the bones, as a general rule, increases with age.

The influence of age as a predisposing cause of fractures consists in the changes which the bones undergo in advancing years by interstitial absorption, known as "senile atrophy." The interior or cancellated tissue is especially liable to this change; the cavities of the cylindrical bones becoming increased in size and filled with fat. It will be noticed, also, that somewhat in proportion as the bone is more brittle, its fracture will be more nearly transverse, so that very old persons have occasionally what has been not inaptly termed the "pipe-stem fracture;" but we must except from this rule fractures occurring in children, which are also sometimes transverse, often denticulated or splintered, and but rarely oblique. In all of the intermediate periods of life, oblique fractures are by far the most common.

Females are less liable to fractures than males, except in old age, when the law seems, in general, to be reversed. It has been generally observed by surgical writers that fractures are more frequent in winter than in

summer, and an explanation has been sought for in the greater rigidity of the muscles during the cold weather, and the greater liability to falls upon the ice and frozen ground.

It is a question whether fractures are actually more frequent in the winter than in the summer. If, on the one hand, the rigidity of the muscles and falls upon slippery walks are active causes in the production of fractures in the one season; on the other hand, falls from buildings and accidents from a great variety of similar causes are equally active agents in the other.

Mollities ossium, rickets, cancer, tertiary lues, scrofula, gout, scurvy, mercurialization, and, in short, all diseases dependent upon cachexiæ, are believed more or less to predispose to the occurrence of fractures.

[Gurlt thinks, however, there is no evidence that scrofula or gout predisposes to fracture, and that syphilis is not a very frequent cause.]

Inflammation of the periosteum also, or of the bone itself, may predispose to fracture. It is said, moreover, that the bones of persons who have lain a long time in bed break easily. The liability to fracture is also sometimes *hereditary*, when there exists no recognized cachexia.

[Goddard knew a boy who had fourteen fractures; his mother had six fractures; his brother had thirteen fractures.]

We may suppose that the proportion of the earthy salts in the bones is increased.

Trophic changes consequent upon disease of the nerve-centres may give rise to a fragility of the bones. It has been observed in lunatics, the paralytic, and in persons affected with locomotor ataxia.¹

Remarkable examples of fragility of the bones have been from time to time recorded. Gibson relates the case of a man who, at the age of nineteen, had suffered twenty-four fractures. Arnott speaks of a girl who, at the age of fourteen, had suffered thirty-one fractures. Esquirol had in his possession the skeleton of a woman in which were found traces of more than two hundred fractures. And we have had, at the Charity Hospital, a man aged fifty-three, who had suffered eleven fractures and two dislocations, in whose case the susceptibility both to fractures and to dislocations appeared to be hereditary.² In most of these cases, so far as is known, union occurred rapidly.

Exciting Causes.—The exciting, determining, or immediate causes of fractures are of two kinds: mechanical violence and muscular action. Of these two, mechanical or external violence is much the more frequent cause; and this violence may operate in two ways: by acting directly upon the bone at the point at which it separates, and then we say the fracture is “direct,” or from “direct violence;” or by acting upon some point remote from the seat of fracture, and then we say the fracture is “indirect,” or from a “counter-stroke.”

When a person falls from a height, alighting upon his feet, and the leg or thigh is broken, the fracture is indirect; so also if the bone is broken by flexion or torsion. Even direct pressure upon one side of a long bone in a child may produce a partial fracture upon the opposite side, which is properly an indirect fracture; or a direct blow upon the trochanter major may occasion a counter-fracture through the neck of the femur.

¹ Weir Mitchell, Amer. Journ. Med. Sci., July, 1873, p. 113.

² The Physician and Pharmaceutist, Feb. 1870. Report by Armenag Assadoorian.

Fractures from muscular action occur most often in the patella, calcaneum, humerus, femur, tibia, and olecranon process of the ulna. These accidents may imply some condition of the bones themselves which predisposes them to fracture.

I have seen one example of a fracture of the shaft of the femur in a large and perfectly healthy man, occasioned by a twist of the leg in rolling tenpins. I have also quite often known the tibia to break from natural muscular action in persons of uncommon vigor; and there is reason to believe that the patella is broken more often from muscular action than from direct force. Fractures sometimes occur in the violent contractions of the muscles during convulsions, and where no abnormal condition of the bones could be assumed to exist. Parker, of New York, relates a case of fracture of the humerus in a negro preacher, which occurred in the act of gesticulation; also, a fracture of the clavicle occasioned by striking a dog with a whip; in another case the humerus was broken in attempting to throw a peach; but the most singular case of all was a fracture of the humerus caused by an effort to extract a tooth.¹ I have seen the clavicle broken in the case of a man who was reaching back to lift the top of his carriage; and another in which the humerus was broken in a contest to determine the power of the rotator muscles of the forearm. Lente has seen both femurs broken in epileptic convulsions, in a child twelve years of age. The left femur was broken at the junction of the upper with the middle third, and the right femur was broken at the same point eight months after, and about six weeks later he died. The first fracture united with considerable bowing and shortening. The second did not unite at all. He had been subject to epilepsy since he was fifteen months old.²

Nearly all of the cases of fractures occasioned by muscular contraction seen by me were transverse, or nearly so, and most of those occurring in the long bones have been unattended with shortening, the ends of the bones not becoming completely displaced from each other. Intra-uterine fractures are not yet fully explained, but it is probable that they, like extra-uterine fractures, may be ascribed sometimes to external violence, and at other times to simple muscular contraction, both perhaps acting upon bones already somewhat predisposed by a peculiar constitutional cachexy.

A child was brought to me having a fracture of the left clavicle, which had united with considerable deformity, the point of fracture being at the junction of the middle and outer thirds. The mother said that she fell upon her belly about two weeks before the birth of the child, striking upon a tub; delivery occurred at the full period, in the hands of an uneducated female accoucheur. Four weeks later (when I was consulted) union was complete.

Proudfoot, of New York, has related a case of compound fracture *in utero*, which was apparently caused by external violence. Mrs. F., during the sixth month of gestation, while attempting to pass through a very narrow passage, was severely pressed upon the abdomen, and immediately experienced a severe pain in that region, accompanied with nausea and faintness. The following day, uterine hemorrhage, with pain, commenced; and these symptoms continued at intervals, in a form more or less severe, up to the period of her delivery, which occurred at full time, and was perfectly natural. At birth, the right foot of the child, a female, was found to be much distorted, and in a condition of valgus with equinus, the outer side of the foot being laid against the side of the leg above the external malleolus. The tibia, also, of the same limb, near its middle, seemed to have been the seat of a compound fracture; the two ends of the bone having united at an angle slightly salient anteriorly, and the skin presenting over the point of fracture an old cicatrix.³ Dr. Rodrigue, of

¹ Parker, New York Journ. Med., July, 1852, p. 95.

² Amer. Med. Times, July 21, 1860, p. 41.

³ Proudfoot, New York Journ. Med., Sept. 1846, p. 199.

Hollidaysburg, Pa., has communicated a case of fracture with dislocation. The woman, when about four months with child, fell on her left side, striking upon a board, and hurting herself severely. At the full period she was delivered of a well-grown male child. Its left humerus was found to be dislocated into the axilla, and both the radius and ulna of the same limb had been broken through their lower thirds, but were now united by bony callus at an angle of about 45° , and slightly overlapped.¹ Devergie has given an account of a woman who, when seven months with child, struck her abdomen against the corner of a table. Intense pain followed, lasting some time. She went her full period, and the child was then found to have a fracture of the left clavicle, the fragments being overlapped somewhat, and united in this position by a firm and large callus.² A woman also six months gone met with a similar accident, and at the full time she gave birth to a feeble child, having in one leg a separation of the shaft of the tibia from its lower epiphysis. The end of the shaft was necrosed, and projected through a wound in the integument. This child died on the thirteenth day.³ Schubert reports the case of a female delivered before her term, of twins, one of whom was born with a fracture of the left thigh, which had occurred *in utero*; the fractured bone had pierced the flesh, through which it projected more than an inch, and it was carious. The mother stated that about six weeks before the accouchement, during a movement of the fœtus, she had heard a noise like that produced by breaking a stick, and from that moment she had felt pricking pains in her belly.⁴ Similar cases have been recorded by Ploucquet, Kopp, Carus, Sachse, Moffat, and Brodhurst.⁵

In many other examples upon record⁶ the explanation is plainly enough to be sought for in the abnormal or rachitic condition of the bones. Monteggia saw, in a newly born infant, twelve united fractures. Chaussier, who has published a memoir upon this subject, mentions two very extraordinary cases, in one of which the child presented forty-three fractures, and in the other one hundred and twelve.⁷ I saw an infant only four days old, who was born at the full time, of a healthy mother, in whom nearly all of the long bones were separated and movable at their epiphyses, the motion being generally accompanied with a distinct crepitus. The bones were also much enlarged in their circumference; the bones of the forearm and the femur were greatly curved; the fontanelles unusually open, and the clavicles were entirely wanting. The child was of full size, but looked feeble. It died in a condition of marasmus six months after birth, at which time some degree of union had taken place at several of the points of separation, the limbs having been supported constantly with pasteboard splints and rollers.

Fractures occurring from violence inflicted upon the child by the accoucheur, or from contractions of the neck of the womb while the child is *in transitu*, are more common occurrences, and do not require a separate consideration.

¹ Rodrigue, Amer. Journ. Med. Sci., Jan. 1854, p. 272.

² Devergie, Rev. Méd., 1825.

³ Malgaigne, from Archiv. Gén. de Méd., t. xvi. p. 288.

⁴ Amer. Journ. Med. Sci., May, 1828, p. 223; from Zeitsch. für Staatsarz. von Henke, 7e Erg. Heft., p. 311. Holmes's Surgery, vol. iv. p. 826.

⁵ Holmes's Surgery, vol. iv. 827, from Med.-Chir. Trans., vol. xliii., 1860.

⁶ Lond. Med. Times and Gaz., April 7, 1860. New Orleans Med. Journ., Nov. 1860.

⁷ Chaussier, Bullet. de la Faculté de Méd. de Paris, 1813, p. 301.

CHAPTER III.

GENERAL SEMEIOLOGY AND DIAGNOSIS.

FRACTURES are liable to be confounded with contusions, and with various other local injuries, but most often with dislocations, and especially when the fracture has taken place near one of the articulations is the differential diagnosis sometimes rendered exceedingly difficult. The most important general or common signs of fracture are *crepitus*, *mobility*, and *an inability on the part of the fragments to maintain their positions when reduced*.

Dislocations are almost as uniformly characterized by the absence of crepitus, by preternatural immobility, and by the fact that, when reduced, the bones do not usually require support to retain them in place, or indeed, we may say, by the fact that they are generally reducible.

Crepitus, occasioned by the chafing of the broken surfaces upon each other, when actually present, is almost positive evidence of the existence of a fracture. It is possible, however, to confound the chafing of engorged tendinous sheaths, or of inflamed joints upon which fibrinous effusions have occurred, or of emphysema even, for the true crepitus of a fracture; but to the experienced ear and well-practised touch these sensations are seldom a source of error. The one is rough, crackling, even clicking sometimes; while the other is more subdued, and imparts a more uniform sensation to the hand, and but rarely conveys an actual sound, unless the ear is directly applied or the stethoscope is employed. It is only when the crepitus is transmitted obscurely through a great mass of soft tissues, or sufficient time has elapsed for the ends of the fragments to become softened by inflammation and partially covered with a plastic material, or when, indeed, a dislocation is actually coincident with the fracture, that the surgeon is left in doubt. Occasionally, also, the existence of caries or of necrosis, in connection with a dislocation, might lead to the supposition of a fracture; but the history of the case, aside from the remaining common signs, and the special symptoms hereafter to be enumerated, would prevent any possibility of error. In a few cases the diagnosis may be facilitated by the application of the ear or of the stethoscope. A fracture at one point may transmit the sensation of crepitus distinctly enough, but in such a direction, owing to the relations of other bones to the one broken, as to mislead the surgeon, and induce him to locate the fracture in the wrong bone.

Valuable and important as is crepitus in its relations to differential diagnosis, unfortunately it is not always present, and for reasons which must be plainly stated. First. We cannot, in a pretty large proportion of cases, bring the broken ends again into apposition. Whatever mere theorists may say to the contrary, and notwithstanding surgeons up to this time have rarely ventured to allude to this subject, the fact is that we do not usually "set" broken bones. We do not, even at the first,

bring them into complete apposition, unless it is as the exception. I speak of the bones once completely displaced by overlapping, and these constitute the majority of examples which come under the surgeon's observation. Second. In transverse fractures of the patella, and in fractures of the olecranon process of the ulna, of the acromion process of the scapula, and in all similar detachments of processes and apophyses, the action of the muscles, by displacing the fragments, may prevent crepitus from being readily produced. Third. In a few cases, such as certain fractures of the neck of the femur, of the neck and head of the humerus, in a Colles fracture, etc., the broken ends may be impacted, or so driven into each other as to forbid the production of motion and crepitus; or they may be simply denticulated, and the consequences, so far as crepitus is concerned, will be the same.

Finally, in very many incomplete fractures, crepitus does not exist; and even when it is present, the sensation is feeble, or very much modified, sometimes giving only a faint and single click. Under the head of crepitus we may properly include the sharp crack sometimes felt, or even heard, by the patient at the moment of fracture.

Preternatural mobility, less valuable as a means of diagnosis than crepitus, is, nevertheless, more constantly present, being never absent, in some degree, in all complete, non-impacted, and non-denticulated fractures; but its presence does not, like crepitus, render the existence of a fracture quite certain. Whenever the bony lesion takes place in the vicinity of a joint, it may be difficult or impossible to determine whether the mobility of the limb is due to motion in the joint or to motion at the supposed seat of fracture; while, on the other hand, the preternatural immobility so generally observed in dislocations may give place to preternatural mobility, as when the ligaments and tendons surrounding the joint are extensively torn, or the system itself is laboring under the shock of the accident, or when from any other cause there exists great general prostration.

Broken bones do not generally support themselves, but demand for this purpose, in most cases, the interposition of splints, bandages, and even of extending and counter-extending forces. This fact rests upon the same evidence as does the assertion already made, that bones once separated entirely, cannot generally be "set"—that is, placed again end to end in such a manner as to be made effectually to support each other. If we find it possible to bring the broken surfaces sufficiently into contact to develop crepitus, they may still be unable to maintain themselves in this position, owing to the obliquity of the line of fracture.

The other common signs of fracture may be briefly stated. *Pain at the seat of fracture; swelling; ecchymosis; and deformity*, produced by either an angular, transverse, or rotary displacement of the fragments, and which is quite as often due to the direction and force of the impulse which occasioned the fracture as to the action of the muscles; separation of the fragments, as in fractures of the patella and olecranon process; and inability to move the limb, a phenomenon due in part to the breaking of the bony lever upon which the muscles acted, and in part to the intense pain caused by any such attempts. This latter symptom is, however, often entirely absent. It is not generally present in impacted fractures, in serrated and partial fractures, or in many other fractures in which the periosteum has not yet completely given way.

The cause of this fracture exercises an important influence. Fractures of long bones, caused by muscular action, generally occur near the middle of the shaft, and they are usually transverse. Direct fractures are also more nearly transverse than indirect fractures, but less so than those caused by muscular action; while those indirect fractures which are caused by a force applied in the direction of the axis of the bone are, in general, very oblique. But what is of more importance in connection with diagnosis is, that in this latter class of cases the fracture usually takes place near the point upon which the force of the blow is received.

Thus, a fall upon the hand generally causes a fracture of the lower end of the radius—a Colles fracture—or if both bones break, it is generally below the middle, and very seldom indeed in the upper third. A fracture of the shaft of the humerus near the condyles is a frequent result of a fall upon the elbow. The classical fracture of the clavicle, at the junction of the middle and outer thirds, is usually caused by a fall upon the shoulder. A fall upon the foot causes a fracture, in most cases, near the lower end of the tibia, and the same is true, quite often, of the lower end of the femur. Exceptions to the rule above stated are most commonly met with in advanced life, when falls upon the elbow occasion fractures at the surgical neck of the humerus, and falls upon the shoulder sometimes cause fractures near the sternal end of the clavicle. Similar accidents, in old people, also sometimes break the tibia near its upper extremity, and the femur within its capsule.

Care and gentleness, as well as skill, in the examination of broken limbs, are of the greatest importance in diagnosis. Nothing, in my opinion, betrays a lack of judgment as well as of common humanity on the part of the surgeon, so much as a rude and reckless handling of a limb already pricked and goaded into spasms by the sharp points of a broken bone. It is not enough to say that such rough manipulation is generally unnecessary, it is positively mischievous; provoking the muscles to more violent contractions, increasing the displacement which already exists, and sometimes producing a complete separation of the impacted, denticulated, transverse, or partial fractures, which can never afterward be wholly remedied; augmenting the pain and inflammation, and not unfrequently, I have no doubt, determining the occurrence of suppuration, gangrene, and death.

In proceeding to establish the diagnosis in any case, the surgeon should sit down quietly and patiently by the sufferer, so as to inspire in him from the first a confidence that he is not to be hurt, at least unnecessarily. He ought then to inquire of him minutely as to all the circumstances immediately relating to the accident, in order that he may determine as nearly as possible its cause, which alone, to the experienced surgeon, often affords presumptive, if not conclusive, evidence as to the nature and precise point of the injury. From this, he should proceed to examine the disabled limb; removing the clothes with the utmost care by cutting them away rather than by pulling; and when completely exposed, he should notice with his eye its position, its contour, the points of abrasion, discoloration, or of swelling; and not until he has exhausted all these sources of information ought the surgeon to resort to the harsher means of touch and manipulation. Nor will his sensations guide him to the point of fracture by any other method so accurately as when,

the patient being composed and his muscles at rest, he moves his fingers lightly along the surface of the limb, pressing here and there a little more firmly, according as a trifling indentation or elevation may lead him to suspect this or that to be the point of fracture. The limb, in case of a supposed fracture of a long bone, may now be measured with a tape-line, and compared with the opposite limb, having first marked with a soft pencil or with ink the several points from which the measurements are to be made.

Finally, if any doubt remains, the limb must be firmly but steadily held while the necessary manipulations are performed, for the purpose of ascertaining the existence of mobility and of crepitus. Mobility is most easily determined by giving to the limb a lateral motion, but in general, crepitus is most effectually developed by gentle rotation. If the place of fracture is already pretty well declared by the previous examinations, the surgeon should place one finger over the suspected point, during this manipulation, by which means the crepitus will be more certainly recognized.

Anæsthetics for the purpose of insuring quietude and annihilating pain in making these examinations are not often necessary. If the examination is not satisfactory, and the diagnosis is important, do not hesitate to render the patient completely insensible, after which the questions in doubt may be more thoroughly investigated and perhaps definitely settled. Do not forget, however, that while the patient is under the influence of an anæsthetic, violent manipulations are no less liable to rupture bloodvessels, and to lacerate other tissues, than if employed when the patient is conscious.

Surgeons have not seemed always to understand this, and the result has been that in too many instances they have inflicted serious and irreparable injury; in one instance which came under my notice, the injury thus inflicted caused tetanus and death.

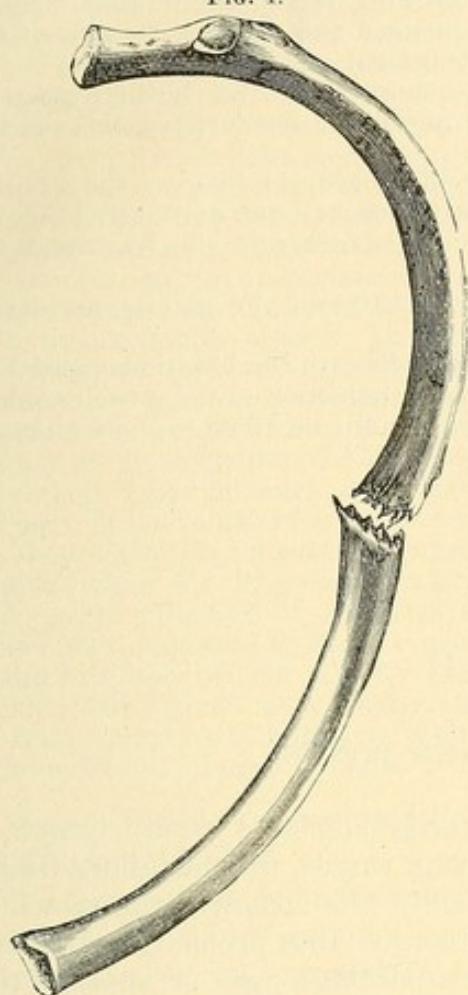
The period of examination is important. The earlier the examination is entered upon, the more readily will the diagnosis be made out; and if, unfortunately, some time has already elapsed before the patient is seen by the surgeon, and much swelling has taken place, the examination is still not to be omitted; and whatever doubts remain we must endeavor to remove by repeated examinations, made from day to day, until the subsidence of the tumefaction has brought the surfaces of the bone again within the reach of our observation.

[Varieties of Displacement.]—An important feature in the diagnosis is to determine the peculiar form of displacement of the fragments which may exist. Without that knowledge the surgeon may mistake the direction which should be given to the forces which he employs to secure the proper apposition of the extremities of the bones. Malgaigne has given a very practical classification of these displacements, which may be usefully studied.

1. *Transverse or lateral displacement* exists when the fragments pass each other in the transverse diameter of the bone, whether laterally or antero-posteriorly. This displacement occurs in transverse or denticulate fractures.

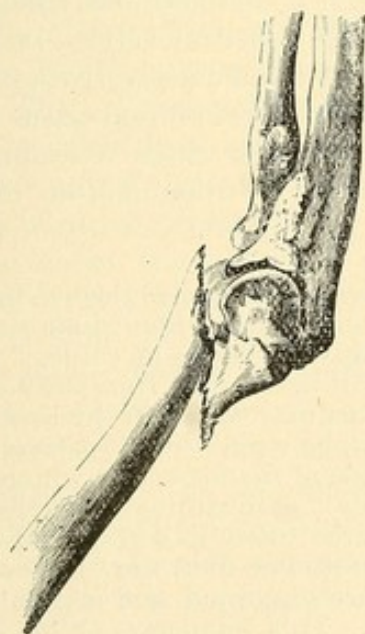
2. *Angular displacement* occurs when the bones are placed at an angle with each other (Figs. 4, 5, and 6). This angle may be slight or obtuse.

FIG. 4.



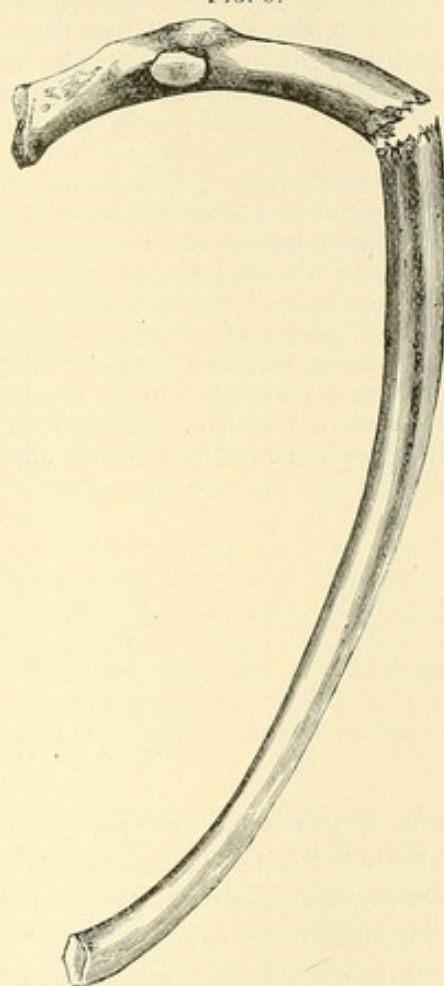
Angular displacement inward.

FIG. 6.



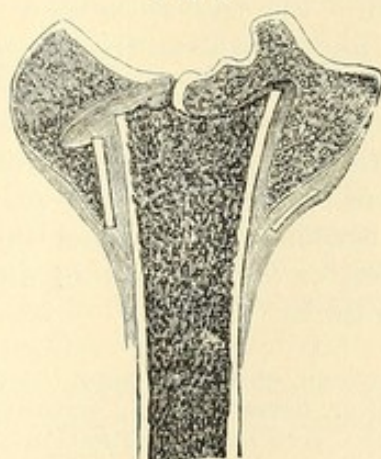
Over-riding of fracture.

FIG. 5.



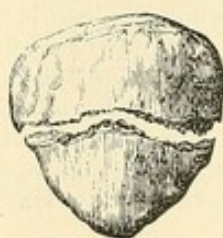Angular displacement outward.

FIG. 7.



Presentation of fragments.

FIG. 8.



Longitudinal displacement.

3. *Rotatory displacement* is a change in the long axis of the fragments, as in fractures of the femur, when the foot falls outward and changes the axis of the lower fragment in its relation to the upper fragment.

4. *Overriding* is the most frequent displacement, and is due to the passage of one fragment over the others. It is found in oblique fractures of the shaft of long bones (Fig. 6).

5. *Penetration* of the fragment, impaction, may occur in long or short bones. In the long bones the shaft usually penetrates the cancellated extremity (Fig. 7); in the short bones the injury is of a crushing nature, and the fragments are driven into the cancellated tissue.

6. *Longitudinal displacement* is found in fractures of the patella, and occasionally in the shaft of long bones (Fig. 8).

In addition to these forms of displacement, there are combinations caused by the violence which produced the fracture, or by the action of the muscles subsequent to the fracture. Too careful attention cannot be given to these changed positions when the limb is first examined.]

CHAPTER IV.

REPAIR OF BROKEN BONES.

THE reparative material, consisting originally of a plastic lymph, is poured out from the vessels of the Haversian canals, the medullary tissue, the periosteum, and more or less from all of the lacerated tissues which are immediately adjacent to the seat of fracture; but probably in greatest abundance from the periosteum. After a period, longer or shorter, this lymph becomes organized, and begins to receive from the same sources particles of bony matter, through which the consolidation is finally effected. The transition from the original plastic material to bone is in adults almost constantly through the interposition of connective tissue, rarely, unless in the case of children, through a cartilaginous tissue, and sometimes through both consentaneously or consecutively. In a few fortunate examples bones unite directly or immediately, without the intervention of a reparative material. Finally, granulation-tissue sometimes becomes transformed into bone, in certain cases of compound fractures, or of fractures in which the process of inflammation exceeds certain limits.

Dupuytren, enlarging upon the doctrines taught by Galen, Duhamel, Camper, and Haller, declared that "nature never accomplishes the immediate union of a fracture save by the formation of two successive deposits of callus;" one of which is derived from the periosteum, the adjacent tissues, and from the medulla; while the other, derived, perhaps, from the broken extremities of the bone itself, is found at a later period directly interposed between these surfaces. The material or callus derived from the tissues outside of the bone, and which Galen compared to a ferrule, but which Mr. Paget calls "ensheathing," together with the material derived from the medulla, compared often to a plug, and by Mr. Paget named "interior" callus, is by Dupuytren spoken of as the "provisional" or temporary callus, by which the fragments are supported, and maintained in contact until the permanent callus is formed. This temporary splint is completed or has arrived at the condition of bone in a spongy form, at periods varying from twenty to sixty days; but it does not assume the character of

compact bone until a period varying from fifty days to six months has elapsed; after which it is gradually removed by absorption. The second process, by which the ends of the bone are definitely or permanently united, commences when the provisional callus has arrived at the stage of spongy bones, and is not completed usually within less than eight, ten, or twelve months, "when," says Dupuytren, "it acquires a solidity greater than the original bone."

While it is certain that this eminent surgeon and most accurate observer has described faithfully the various phenomena which usually accompany the repair of bones in those animals which were the subjects of his experiments, and that his conclusions have a certain degree of application to the human species, it is equally certain that he erred in assuming that in man simple fractures always unite by this double process; yet, such is the power of authority, these doctrines were accepted from the first without hesitation or debate, and for nearly half a century they have occupied the minds of surgeons, to the almost complete exclusion of every other theory. Mr. Stanley was among the first to question the solidity of the doctrines of Dupuytren, but it remained for Mr. Paget to expose fully their many fallacies; nor has Malgaigne, although not strictly a disciple of Paget, failed to detect certain of these errors.

I should also do injustice to myself were I not to mention that at the very moment when Mr. Paget was making his observations upon the specimens in "the large collection of fractures in the museum of University College," I myself was employed in similar researches both among cabinet specimens and in the hospitals of this country and of Europe; and that the conclusions to which I had arrived were nearly identical with, although the inferences were far from being so complete in their detail as those to which this distinguished pathologist was himself brought.¹

It may now be fairly stated that fractures may unite by either one of the following modes:

1. Immediately, or in the same manner that the soft tissues sometimes unite, by the direct reunion of the broken surfaces, and without the interposition of any reparative material. This happens probably sometimes in the spongy bones, and in the extremities or spongy portions of the long bones, especially when one portion of bone is driven into another and becomes impacted; as, for example, in some extracapsular impacted fractures of the neck of the femur, in certain impacted fractures of the head or neck of the humerus, of the lower end of the radius, etc.

2. By interposition of a reparative material between the broken ends; as when the fragments remain in exact apposition, but immediate union fails. This is especially apt to occur in superficial bones, such as the tibia; or upon those sides of the bone which are most superficial. It is not an unusual circumstance to find the shaft of the tibia during the process of union presenting no exterior callus upon its anterior and inner surface, whilst the posterior and outer section of its circumference is covered with an abundant deposit. In other cases, however, of fractures of the shaft as well as of the epiphyses, the intermediate callus secures a prompt union, but no ensheathing callus is ever formed.

3. Bones broken and not separated, unite occasionally by the process described by Dupuytren, namely, by the formation, first, of an ensheathing callus, whilst at the same moment the cylindrical cavity becomes closed by a spongy plug, or its canal is merely interrupted by a compact septum of bone; and, second, by definitive callus deposited between the broken ends. It is probable that this happens generally in children, or

¹ Paper on "Provisional Callus," by Frank H. Hamilton. Buffalo Medical Journal, Feb. 1853.

during the periods of the greatest activity in the development of bones; and it is a common mode of union in the ribs, which bones, during the whole progress of the union, are necessarily kept in motion. My cabinet furnishes many illustrations of ensheathing callus in ribs; and also a few in fractures of the tibia and fibula.

4. Under similar circumstances, where no displacement exists, the fracture may unite by ensheathing and interior callus alone, no intermediate callus ever being formed between the broken ends; in which case it may be probably said that the bone itself has never united, and the ensheathing callus, instead of being provisional, is permanent or definitive.

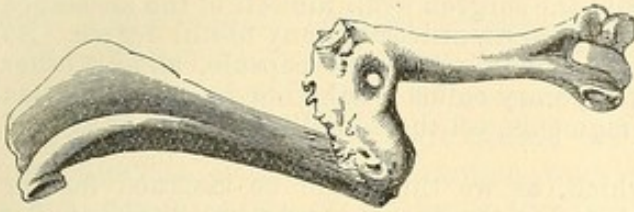
This was essentially the doctrine of Galen, Haller, and Duhamel before Dupuytren added his "fifth period," or the formation of definitive callus; and by these older surgeons it was held to be of universal application, except, perhaps, in the case of children. To this doctrine also Malgaigne has returned; at least to the question, "Is there always a definitive callus, or complete union of the fragments?" he has made this laconic reply: "Galen admitted its occurrence, but only in young subjects; it has been obtained in animals, where there had been no displacement. I would willingly believe that such is sometimes the case in human adults; but I must confess I have seen only the instance above recited, which might just as well be used to prove the compact ossification of the provisional callus." He accepts, therefore, the doctrine of Galen as having not merely an occasional application, but as explaining the process of union in the large majority of cases; and in support of this extreme view he finds that the exterior callus, which Dupuytren called provisional or temporary, is actually permanent, unless removed by the absorption consequent upon pressure. To all of which we can only say that an examination of five or six specimens in our own cabinet, after having carefully divided them with a saw, has furnished only one illustration of union by ensheathing and interior callus alone. In each of the other specimens the union was completed by definitive or intermediate callus. We cannot, therefore, avoid the conclusion that Malgaigne has been deceived as to the relative frequency of these different modes of union, and that union without intermediate callus is exceptional.

5. When the bones are broken and overlap, they may unite by the interposition of a callus between the opposing surfaces—that is, by an intermediate callus, but which will differ from that described as the second method, inasmuch as the new material will be deposited upon the sides of the fragments and not upon their extremities. The limb being kept perfectly at rest, and all other circumstances proving favorable, this union may take place without any excess or irregularity in the deposit. The surfaces will unite firmly where they are in actual contact; and smooth and well-formed buttresses will fill up all the spaces between the bones where they are not in actual contact, sufficient generally to give the requisite strength to this new bond of union. This mode of union will be completed sometimes when the two ends of the bones are separated laterally an inch or more from each other.

I have in my collection the bone of a turkey's thigh (Fig. 9) thus united by a transverse bony shaft, although separated more than one inch; and, what is less common, I possess also a specimen of the adult human thigh (Fig. 10), in which an oblique shaft of solid callus has, after many months, and while no splints were employed, bound together firmly the two opposite extremities of the broken bone.

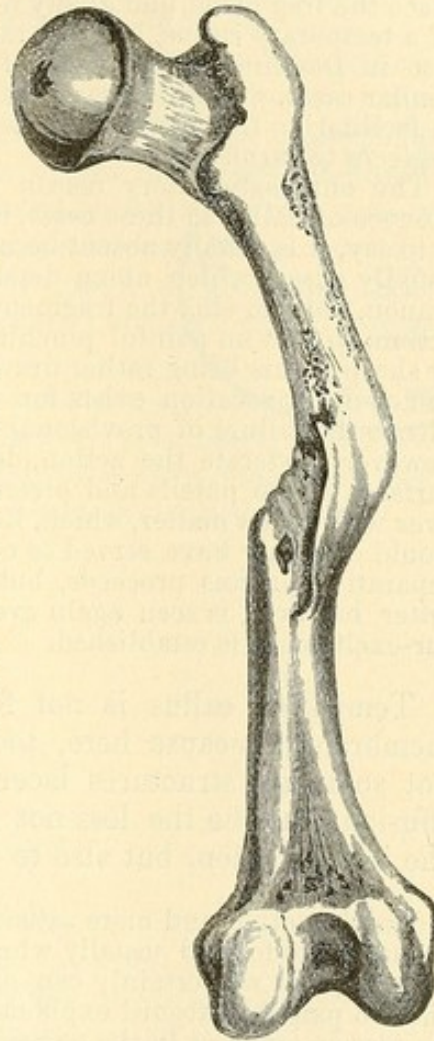
6. The fragments being overlapped more or less, and suffering unusual disturbance, or the adjacent tissues having been much torn, or

FIG. 9.



Fracture of the humerus of a turkey; united with the fragments widely separated. From a specimen in the author's cabinet.

FIG. 10.



Fracture of the shaft of the femur; united with an oblique callus. From a specimen in the author's cabinet.

much blood being effused, so that considerable inflammation is caused, the amount of callus will exceed what is necessary for the complete union of the bones; and this redundancy may be deposited around and upon the broken ends of the bones, or anywhere in their immediate vicinity, in layers, or in masses of irregular shape and size. Even the bones which are not broken, but which are near, as in the case of the fibula after a fracture of the tibia, may become inflamed, or their coverings may inflame, and they may also contribute to the general mass of bony callus.

Compound fractures, or rather, fractures accompanied with granulations and supuration, obey no uniform law of repair, so far as the manner and position of the deposit are concerned; but they come together finally with more or less irregular distributions of ossified matter, according to the varying circumstances of imperfect coaptation, mobility, etc., in which they may chance to be placed. Occasionally the amount of callus is less than occurs in simple fractures, and at other times the excess is very great.

That was, no doubt, a beautiful thought, which ascribed the formation of provisional callus to an intelligent efficient cause, which in this manner sought to support the fragments until a reunion of their divided ends was accomplished. But the beauty of a conception supplies no evidence of its truth; and we have grave doubts whether Nature ever allows any interference with her laws even in an exigency, unless by the substitution of a miracle. Provisional callus is, in our opinion, just as much the necessary result of natural laws, as is definitive. It is formed because in that condition of the parts and of the general life its formation was inevitable. Whether useful for the purposes of repair or not, it will, under certain circumstances, exist. In the repair of certain fractures, provisional callus, it is conceded, seldom occurs. Thus it is with the cranium, the acromion, coracoid and olecranon processes, the patella, and with all those portions of bones which are immediately invested with a synovial capsule. Will it

be affirmed that in the examples just named this callus is not formed because it is not required? To us it seems that nowhere could it prove more useful, since, with the single exception of the cranium, it is in these very cases that the obstacles to a reunion are the most serious. In fractures of the patella, olecranon, etc., the action of the muscles tends constantly and powerfully to displace the fragments, and gladly would the surgeon avail himself of the assistance of a temporary callus, but it is rarely present, at least in any useful degree. So also in fractures of the neck of the femur within the capsule, and in other similar cases, we cannot say that temporary callus would not be advantageous in facilitating the retention of the fragments, yet the "intelligent efficient agent" neglects to furnish it.

The only satisfactory reason which, as we think, can be assigned for the absence of callus in these cases, is found in the doctrines we now advocate; that is to say, it is usually absent because that amount of excitement and irritation is usually absent which alone determines its formation. In the case of the olecranon, patella, etc., the fragments being separated from each other by muscular action, so that no painful pinchings or chafings occur, and their rough surfaces or sharp points being rather drawn away from than protruded into the flesh, no sufficient provocation exists for the production of inflammation and effusion. Hence the failure of provisional callus; but wherever the fracture occurs, and however moderate the action, definitive callus does not fail; still the broken surfaces of the patella and olecranon are softened, and smoothed, and covered over with a new matter, which, if contact could have been secured and preserved, would certainly have served to consolidate and repair the breach. The natural reparative process proceeds, but only the accidental process is omitted. The latter, however, is seen again even here, when from other and unusual causes a sur-excitement is established.

Temporary callus is not formed upon bones invested with synovial membranes, because here, too—as in the neck of the femur—there are not so many structures lacerated and irritated, and the supply of this effusion must be the less not only in proportion to the less intensity of the inflammation, but also to the less amount of structures implicated.

Possibly other and more satisfactory reasons may be assigned why provisional callus is not formed usually when the neck of the femur is broken within the capsule; but we certainly can never admit the common, and, as here applied, the too palpably absurd explanation, that it is not wanted. It is wanted, and in no case so much as in the one now supposed.

Provisional callus has, therefore, no final purpose, but it is the unavoidable result of certain abnormal conditions. It still occurs everywhere when against and in the vicinity of the bone there are the requisite lesion and action, and it will occur as certainly when there is no fracture at all, but only a caries, a necrosis, or a simple bony or periosteal inflammation; and whilst it is doubtless true that in fractures it sometimes renders valuable aid to the surgeon, it is equally true that it often proves a source of hindrance.

Dupuytren, in determining the limits of his "third" period, or of that in which a provisional callus is formed of sufficient strength to support the fragments, has given what has been usually quoted as the natural period within which bones may be said to be united—that is, "from the twentieth or twenty-fifth day, to the thirtieth, fortieth, or sixtieth." But this depends so much upon the age of the patient, his general condition of health, the condition and position of the broken ends, as well as upon the bone itself, and the point at which it is broken, with many other circumstances, that it would be unsafe to establish any absolute laws in reference to this point.

In very early infancy, union is accomplished in half the time required in adult life, and it is generally thought to be still more retarded in advanced age, but Malgaigne has not found this latter observation confirmed by his own experience; nor have I observed any marked difference, in this respect, between persons of middle and old age.

Various constitutional causes retard bony union. Motion, also, sometimes delays consolidation; fragments which are overlapped do not unite as speedily as those which are placed end to end; and other complications interfere in a similar manner, such as lesions of nerves, of blood-vessels, comminution of the bone, the interposition between the ends of the fragments of a blood-clot, a portion of muscular, tendinous, or other tissue, etc. In general, the bones of the lower extremities, independently of their size, unite more slowly than the bones of the upper extremities.

Epiphyses, when separated, unite by the same process as fractures of the bone. It is observed, however, that when certain epiphyses unite with much displacement, the shafts from which they have been separated cease to grow, or grow more slowly, and the limbs become atrophied.

CHAPTER V.

GENERAL PROGNOSIS.

THE prognosis in fractures must vary greatly according to the place, character, and complications of the accident; and for this reason it is impossible to give anything beyond a few general maxims at this time, leaving the more precise and detailed statements until we come to consider each individual fracture.

In general it may be said that simple, oblique fractures occurring in the shafts of long bones unite with some shortening. Indeed, this rule presents but few exceptions. This is due to the overlapping or to the impaction, both of which we are in most cases unable completely to overcome. It is scarcely necessary to say that the inevitable result of such overlapping is a more or less manifest irregularity, or deformity at the seat of fracture. In general, however, the natural line of the axis of the limb may be preserved. Simple transverse fractures of the shafts of long bones, which are of rare occurrence, when completely displaced and made to slide past each other, are seldom effectually replaced, and are, like oblique fractures of the same class, apt to result in shortening and some deformity.

All compound, comminuted, and complicated fractures, which in their very nature present additional obstacles in the way of complete adjustment and of proper support, are likely to entail deformity. Contrary, however, to what is generally supposed, certain compound fractures of the shaft of the femur, caused by thrusting a sharp fragment through the

flesh and skin, if promptly reduced, unite as speedily and with as little deformity as simple fractures.

Gunshot fractures, which are necessarily in most cases compound and comminuted, are in a much less degree amenable to treatment with adjusting and supporting apparatus than are most other fractures, and they necessarily entail greater deformity, both in the matter of shortening and lateral deviation. A certain proportion of these, as well as of other compound and comminuted and complicated fractures, demand, for the purpose of obtaining the best possible results, a course of treatment having in view the control of the inflammatory action as the primary consideration, and the relief of the deformity by lateral supports and by extension as the secondary consideration; although perhaps in most cases both are to be regarded as necessary indications of treatment. We do not of course include in this statement those cases which demand immediate amputation.

Simple greenstick fractures, denticulated fractures, and most transverse fractures do not become displaced in the direction of the axes of the bones in which they occur, and may generally be made to unite without shortening or deformity. They unite also very speedily.

Fractures occurring in infancy and childhood unite more quickly than fractures occurring in adult life; more speedily in the robust than in the feeble; and there are certain special conditions, as we have already stated in the chapter on delayed union, which tend to retard bony union.

Fractures of the upper extremities unite in general more speedily than fractures of the lower extremities. The smaller bones unite more rapidly than the larger bones. In the case of the bones of the face and jaws, and of the clavicle, union is especially rapid. This is probably true also of the ribs; and this notwithstanding the fact that in the case of most of these bones we encounter peculiar and often insurmountable difficulty in securing absolute quiet during the treatment.

Fractures at or near the extremities of certain long bones are less liable to displacement, and therefore unite with less shortening and deformity than most fractures of the shaft. They unite also more quickly. This is true especially of fractures of the surgical neck of the humerus, when the fragments remain in place, of fractures of the lower end of the radius, of extracapsular fractures of the neck of the femur, of fractures of the lower end of the femur and of the upper end of the tibia. But some of these fractures are liable to be complicated with injuries to the joints, and either to endanger life or entail a partial or permanent ankylosis. Ankylosis is less liable to result, however, in fractures of the neck of the humerus, and in extracapsular fractures of the neck of the femur, than in fractures of the lower end of the femur, of the lower end of the tibia, and of the lower end of the humerus and of the radius.

Fractures which actually involve the joints are in general much more dangerous to life than other fractures. This statement, however, does not include intracapsular fractures of the neck of the femur, and is most especially applicable to fractures involving the knee-joint. If old people pretty often die not long after receiving intracapsular fractures of the neck of the femur, the death is seldom due to the fracture, but rather to the shock received and the prolonged confinement and recumbency which

are perhaps necessitated. In this last-named fracture, the union, if it takes place at all, is almost invariably fibrous, and the limb usually shortens very much.

When the patella, or the acromion process, or the olecranon process, is broken, the bond of union is generally fibrous; but if the bond is short, this does not materially affect the future usefulness of the limb. In the case of the patella, when the fracture is caused by muscular action, as it generally is, and it is a simple transverse fracture, the new bond of union is almost invariably fibrous.

Ankylosis, more or less complete, is the result of nearly all fractures. This may be temporary or permanent. Temporary ankylosis is due, first, to disuse and atrophy of the muscles, and to passive contraction of the ligaments about the joints. Second, to inflammatory effusions and adhesions among the muscular fibres; between adjacent tendons and in the sheaths of tendons; in the capsules of the joints and among the ligaments.

All of the forms of ankylosis above described may, but do not often, become permanent. Usually the products of inflammation are removed by the natural action of the absorbents in the course of a few months, and especially when the natural efforts are aided by friction, passive or active motion, or by other appropriate means. Passive contraction of ligaments and atrophy of muscles are never overcome except by motion, either passive or active. If they are not overcome in some degree within a year, they are likely to be permanent, or to require for their relief active surgical interference, such as *brisement forcé*, or some of the graver surgical operations.

Permanent ankylosis, sometimes the result of what ought to have been only temporary ankylosis, is more often due to the presence of cicatricial tissue resulting from lesions of the muscles, to actual lesions of tendons or of ligaments, to firm intracapsular adhesions, and finally to bony deposits in or about the joints, to bony consolidation of the adjacent bones, to malposition of fragments, to encroachment of fragments upon the joints, and to hypertrophy of fragments.

Pain, tenderness, and more or less loss of strength in the limbs, lasting for months or years, are common as sequelæ of these accidents; but which phenomena have in general little or no direct relation to the previous existence of a fracture, unless they are present as the natural results of the deformity which remains. They are quite as likely to be entailed upon severe injuries where no fracture has occurred.

After the removal of the splints and bandages the limb is apt to become œdematous; a condition which in old and feeble persons may continue many months, and the existence of which has been lately ascribed to the temporary obliteration of the deeper veins in the region of the fracture. This will no doubt furnish a sufficient explanation in a certain proportion of cases, and perhaps a partial explanation in all cases; but the partial paralysis or loss of tone in the superficial veins, and in all the superficial tissues, due to the long-continued pressure of the bandages, is probably quite as responsible for these results as the deeper seated changes due to the injuries arising directly from the fracture. It is generally found to exist in a pretty exact ratio with the long continuance and tightness of the bandages.

A certain amount of asymmetry in all the long bones of the extremities is the rule and not the exception.

The observations which led to these conclusions were first made upon the lower extremities by Dr. W. C. Cox, of Philadelphia, while he was a student of the Pennsylvania Hospital. They were subsequently confirmed, and the examination then extended to the upper extremities, by Dr. Wm. Hunt, of Philadelphia, by Prof. J. S. Wight, of Brooklyn, by myself and others, Prof. Wight having especially studied the whole subject.¹ In 1879, Dr. J. Garson,² of London, published the results of the measurement of seventy skeletons, and in a later reference to these observations he says: "The lower limbs were equal in length in only seven instances, or in 10 per cent; in twenty-five instances, or 35.8 per cent., the *right* limb was longer than the left, while in thirty-eight instances, or 54.3 per cent., the *left* limb was longer than the right. The left leg I found not only to be more frequently longer than the right, but the difference in length between the two limbs is greater on an average when the left is the longer. Inequality in length is not confined to any particular age, sex, or race, but seems to be universal in all respects. My observations corroborated those of several American surgeons made on the living subject." Measurements of fifty skeletons showed a like asymmetry in all the long bones, but in the case of the arms the right is more often the longer. The conclusions reached by all have been nearly identical, namely, that throughout the long bones of both extremities there existed usually a certain amount of asymmetry in regard to length. Ordinarily the difference is inconsiderable, ranging from one-eighth of an inch to one-half, but sometimes much exceeding this without having been noticed by the patient or by his friends. In the case of the lower extremities the left is more often longer than the right.

These conclusions by no means render the measurements of limbs valueless, although they place a serious obstacle in the way of our attaining that precision which is desirable when we seek to determine the relative value of different plans of treatment in preventing shortening. Unfortunately, I may say, we have not yet devised a method of extension so effective that our ignorance of the original normal differences causes any embarrassment. The fact is, and always has been, that measurement of the limb in which a long adult bone has been broken obliquely and has united, shows, in a large majority of cases, that it is shorter than the other; and the frequency of this occurrence is evidence that in many cases it becomes the shorter limb, although it was originally the longer, and it leaves a possible question whether those few cases which we have regarded as perfect results, because the opposite limbs were after consolidation of the same length, were not then symmetrical solely in consequence of the shortening; and we may consider it probable that in other cases the actual shortening is much more than is indicated by the measurements. Nevertheless the unpleasant fact remains, and is rendered only the more conspicuous, that oblique fractures of the long bones in the adult generally shorten, inasmuch as we find in nearly all cases the broken limb the shorter. When we have found an apparatus or a mode of dressing which will make a broken limb as long as or longer than the other as often as it is found to be normally, then we may lay aside the tape and line, for it will be of no further use; practically, also, our labors will be ended, for shortenings no greater

¹ Philadelphia Medical Times, Jan. 16, 1875. Amer. Journ. Med. Sci., April, 1875. Archives of Clinical Surgery, Feb. 1877. Hospital Gazette, April 12, 1879.

² Garson, Journal of Anatomy and Physiology, vol. xiii, p. 502, 1879. Nature, Jan. 26, 1884.

than normal deviations occasion no maiming or halting, and are of no consequence.

I think it proper to mention venous and fatty embolisms in connection with prognosis in fractures, since modern pathological investigations have established their occasional connection as sequences, if not as consequences.

Virchow, in 1846, was the first to call attention to an example of pulmonary embolism due to the presence of a venous clot and consequent upon a fracture. Since then, similar examples have been reported by other surgeons; the accidents having taken place usually at periods varying from two to six or seven weeks after the fracture occurred, and being due, as is believed, to the displacement of a clot from a vein in the vicinity of the fracture, whose channel had been temporarily closed by inflammation and pressure.

The presence of a pulmonary venous embolism in the lungs may be recognized by the sudden occurrence of pain, cough, and dyspnoea, accompanied, perhaps, with bloody expectoration, and the usual physical signs of localized congestion or consolidation. In some cases, the symptoms are more urgent, and the patient dies in a few minutes.

In 1864, Flournoy reported a death from fatty embolism, consequent upon a fracture of the leg, death having occurred thirty-six hours after. Since then, Busch, Wagner, Czerny, and others have reported similar examples. The accident is supposed to be due to the absorption into the venous and capillary circulation of the crushed fat globules contained in the marrow at or near the point of fracture. The symptoms are said to resemble those of shock and of traumatic and alcoholic delirium; but an interval always exists between the occurrence of the accident and the accession of the symptomatic phenomena, which latter are by no means uniform, the most reliable signs being referable to pulmonary and cardiac obstructions. The breathing becomes suddenly difficult or labored; the pulse becomes feeble and rapid, the countenance pale or cyanosed, and delirium, followed by coma, terminates speedily in death. It is affirmed also, that in other cases, where the fatty embolisms are less extensively distributed, the symptoms, although presenting the same general type, are less urgent, and may terminate in recovery.

It is gratifying to know that both of these forms of embolism, as sequences of a fracture, are probably exceedingly rare, and that some excellent pathologists have even denied that any relation whatever has been shown to exist between the presence of the oil-cells in the bloodvessels and capillaries and the symptoms which have been attributed to them.

CHAPTER VI.

GENERAL TREATMENT OF FRACTURES.

ALL that has been said in relation to the propriety of handling a broken limb gently, when the surgeon is examining the position and character of the fracture, is equally applicable to the lifting and transporting of the patient to his bed, to the removal of the clothing, and to the general management of the limb before it is dressed. Rude or

awkward manipulations, by which needless pain is inflicted, are not simply acts of wanton cruelty, but they are sources, and I think I may say frequent sources, of inflammation, suppuration, and gangrene. Here, as in all the subsequent handlings, everything should be done slowly, thoroughly, and systematically. Yet it is difficult to state the precise manner in which the surgeon ought to proceed. Much will depend upon the circumstances of the case, something upon one's natural tact, and upon the amount of experience, but more, I think, upon natural kindness of heart and social education. The man of refinement and sensibility will know instinctively how to proceed, and needs no instruction. They who lack these qualities can never learn, and it would be quite useless to undertake to teach them.

[§ 1. The Immediate Care and Dressing of Fractures.

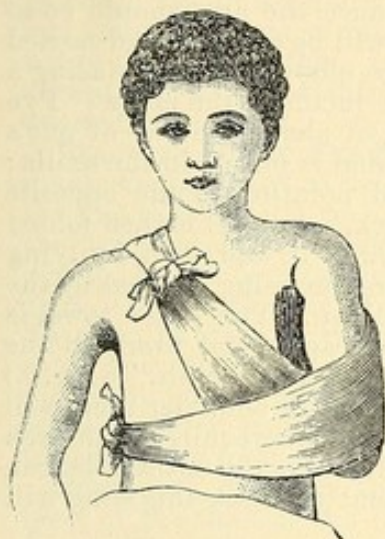While it is desirable to reduce a fracture at the earliest possible moment after the accident and retain the bones in apposition by retentive dressings, it rarely happens that this can be effected at once without an amount of pain and inconvenience that is very disturbing to the patient, and may prove injurious to the parts involved in the injury. There is, therefore, a period in the history of nearly every fracture when temporary dressings are required. This is especially true of fractures that occur when the patient is absent from home, and he must be immediately subjected to transportation. It is with reference to this latter class that the following remarks are principally made. It may be stated that, as a rule, fractures occur under circumstances which necessitate the removal of the patient to his home. In this removal the limb, or part injured, is liable to be subjected to such rude handling that the local injuries are greatly aggravated, and the discomfort and sufferings of the patient are immensely increased. Fractures that would be attended with little pain and very moderate swelling, if properly treated where the accident occurred, may, by the first manipulations of the surgeon in preparing the patient for removal, or by the rough handling of inexperienced persons in his transportation, be rendered serious, or even be changed from a simple to a compound fracture. It is of the utmost importance, therefore, that from the occurrence of the fracture to the final removal of all dressings, intelligent care and adequate skill should be exercised.

Removal of the clothes of a patient who is to be transported some distance is usually unnecessary, and should be delayed until he is placed on his bed. The exceptions to this rule are cases of compound fracture with hemorrhage, and crushed fractures, which require special care and dressing. Splints can be applied to the part outside of the clothes in such manner as to steady the fractured bone, and prevent the fragments from further lacerating the parts. It is not necessary to reduce the displacement except so far as to make the patient comfortable. These dressings must not be too tight. Arrived at the bed the patient should be placed upon it in a comfortable position, and the clothes removed, chiefly by cutting them away. While they are being removed an assistant may be able so to support the part as to prevent all movement of the fragments.

The Materials.—The materials for these temporary dressings must be such appliances at hand as will prevent further injury to the parts while the patient is being removed to his home and bed. Thin pieces of board or sides of cigar boxes, with pads of cotton wadding or folds of cloth next to the limb make very serviceable splints for the arms and legs. Pasteboard and book covers may be of service, especially for the arms and elbows. Towels or sheets may be used for slings or bandages, and even a well-folded newspaper may sustain the parts sufficiently. An umbrella, a cane, a broom handle, a crotched stick are a few of the common materials which have served a good purpose in cases of great emergency. Success in the selection and employment of such materials for dressings will depend much upon the skill and ingenuity of the surgeon. (Fig. 12.)

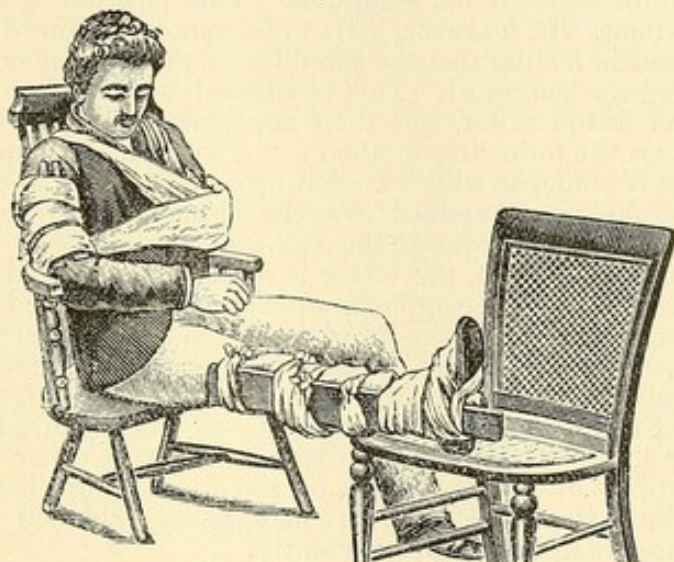
Fractures of the Spine.—The immediate care of a person suffering from a fracture of the spine must be most judicious. A slight force improperly applied may result in such displacements of the fragments as will result in paralysis, or even in death. The danger of doing great harm to the patient by moving him is greater when the fracture is in the cervical region, and is greatest when it is in the upper part of this region. The movements which are more likely to displace the bones are those of rotation or flexion of the spine. The position which

FIG. 11.



Treatment of fractures of clavicle with two towels, or triangular bandage. (PYE.)

FIG. 12.



Improvised splinting. (PYE.)

most directly relieves local pressure is the recumbent, on a smooth, firm surface. And the force applied to the spine which is least liable to cause injury is gentle traction. From these facts it is apparent that the patient should at once be placed in a recumbent position on a smooth surface, as a stretcher, a board, a shutter, or similar support for transportation. In raising the patient from his position to the stretcher no movement should be made which bends or rotates the spine, and slight traction of the trunk should be constantly maintained during the change of position. In transportation the patient should not be subjected to any jarring or jolting, as in a common wagon on a rough road. When the patient reaches his destination he should be removed to his bed with the same care and the same attention to minute details. Finally, the removal of his clothes must be effected without any disturbance of the spine. In general those fitting tightly, as shirts, should be cut with shears.

Fracture of the Ribs.—These fractures are attended with acute lancinating pains in the chest wall, which recur on, and are greatly aggravated by, forced respirations, coughing, or jarring of the body. The patient involuntarily protects himself by short respirations, avoiding coughing and jarring, and by pressure over the injured ribs to prevent the movements of the fragments. Persons suffering from fractured ribs can usually be removed without material injury. They can walk cautiously without great inconvenience and by pressure of the hand or arm upon the side can relieve in a great measure their sufferings. The best dressing is a firm bandage, four to six inches in width, as a towel, pinned tightly about the entire chest.

Fractures of the Pelvis.—These fractures are more difficult of diagnosis, and can only be conjectured on first examination. They may be inferred from the nature of the injury, as the passage of a heavy wheel over the pelvis. Nothing can be recommended that will prove more serviceable in the first care of such a patient than has been given in connection with fractures of the spine.

Fractured Lower Jaw.—The first treatment of this fracture should be to support the jaw in contact with the other by a bandage around the chin and

over the head. The patient should not be allowed to talk nor to take solid food. As a temporary dressing until the final apparatus is applied cardboard may be shaped so as to make a complete splint for the jaw and chin by moulding it when softened in water, the splint being retained by a split bandage; the centre being applied to the chin, the two lower tails being tied over the vertex, and two upper behind the head.

Fractured Clavicle.—The displacement in this fracture is most readily and completely overcome by placing the patient on a firm bed on his back with a pillow between his shoulders. This position is also most comfortable to the patient. If, however, he is to be removed some distance the arm should be so fixed in a sling that the shoulder of the injured side will be elevated and carried slightly backward. This is effected by bringing the elbow forward, placing a pad in the axilla, and then applying a sling which includes the elbow. Pye gives the following method: "A soft, but firm pad, of about the size of one's fist is made, as with a cricketer's cap or a newspaper, and is placed in the axilla; the forearm is crossed over the chest with the hand pointing to the opposite shoulder, the point of the elbow being held well back. A towel is then folded as a broad scarf, the elbow is settled into the middle of it, and then, by tying the ends over the opposite shoulder, the hand and forearm being covered by the scarf, the arm on the injured side can be pushed well up. The other towel is then brought round so as to fasten the arm, forearm and hand firmly to the trunk and the ends are knotted or pinned beneath the opposite armpit." (Fig. 9.)

Fractures of the Humerus.—If the fracture is near the shoulder there will be slight tendency to displacement, and no other dressing is required than such support of the arm as may be given by a sling which includes the entire forearm, elbow, wrist and hand. If moderately tightened about the neck this sling will support the fracture sufficiently.

Owing to the great leverages of the arm and the hinge-like action of the elbow, fractures of the shaft of the humerus are readily displaced by the movements of patients. Whatever position the patient may take, whether recumbent, sitting, or walking, the proper apposition of the fragments will not be retained without the careful application of splints. It is important, first, that the forearm be flexed and fixed to the body. By this means the action of the elbow is very completely controlled. Without removing the clothes a pad should be prepared, which may consist of several folds of cloth, and placed along the inside of the arm, from the axilla to the elbow, as a support to the shaft. The arm being then placed upon the chest, with the fingers pointing to the opposite shoulder, a bandage should be passed around the body and across the elbow, fixing the elbow in this position. A sling, consisting of a handkerchief or strip of cloth around the wrist, is used to support the hand. If the elbow is not thus supported against the body four short splints of light wood or cardboard, padded, should be applied to the arm and fixed by tapes, while the hand is supported in a sling about the wrist.

Fractures Near and at the Elbows.—The mobility of the elbow-joint must be fixed, and the position must be flexion at right angles. Common cardboard or thin sole leather, shaped to the bend of the elbow, is a convenient and admirable dressing. The splint should extend from the middle of the forearm to the middle of the arm and be made much larger than the elbow. It should now be placed in hot water, and when soft and yielding moulded to the parts. It should next be well protected by cotton wadding, the cotton being in excess about the prominent parts of the joint. The splint is best retained by a bandage extending its entire length. The hand should be supported by a sling around the wrist.

Fractures of the Forearm.—Fractures occurring at any point of the forearm are best supported by two broad splints applied, one to the anterior and the other to the posterior surface. They should extend from the elbow to the hand, the anterior reaching to the middle of the hand to prevent pronation. The sides of cigar boxes answer a good purpose. They should be wider than the arm and well padded. When applied the forearm should be held so as to make the bones parallel, the thumb being upward. The splints may be held in place by tapes, care being taken not to make them too tight. The forearm should be supported by a sling.

Fracture of the Neck of the Femur.—The most important fact to be borne in mind in the care of this injury is this, the fracture may be partial or impacted. If it is partial or impacted it is in the best possible condition for rapid union. But by rude handling, as in lifting the patient, the partial or impacted fracture may be made complete, and thus in a moment irreparable injury is done to the patient. It is well to assume, in all cases, that the fracture is not complete, for if that fact is prominently in the mind of the surgeon who prepares his patient for transportation, he will exercise that degree of care which is essential in all cases. A well-padded, long splint should be applied, extending from the foot to the axilla, and be retained by a broad towel around the hips and stout bandages at other points. This dressing should be adjusted without removal of the clothes, and with as little movement of the limb as possible, except that the foot should be placed in its proper position if it is too much everted or inverted.

Fracture of the Shaft of the Femur.—In this fracture there is usually much displacement at first. A long splint should be applied externally from the foot to the axilla, as in the preceding case, and a short splint internally from the foot to the groin. Before they are fastened to the limb, the leg should be gently but firmly extended and the eversion of the foot corrected. Plaster-of-Paris, if at hand, may be used with great advantage in the form of a splint. This can be made of two layers of woollen blanketing, cut of the length of the thigh and sufficiently wide to surround the limb. The blanket is soaked in the dissolved plaster and quickly applied, and retained by bandages. In a few minutes it will be firm. This dressing is to be preferred if the patient is to be transported a long distance.

Fractures Near or Into the Knee-joint.—The same dressings as in fractures of the shaft of the femur are generally best adapted to secure the limb from further injury when the fracture is near or into the joint. It may happen that the slightly flexed position is most comfortable. In that case the knee may be bent over a firm pillow or other support.

Fractures of the Patella.—The important point to be made in this fracture is that the leg must not be flexed, but rather must be maintained in a state of extreme extension. For this purpose a firm splint must be applied on the posterior part of the limb, extending from the middle of the thigh to the middle of the leg, and be firmly retained by a bandage or broad tapes.

Fractures of the Leg.—The plaster-of-Paris splint above described makes the best dressing for these cases and is most readily applied. The blanket must be cut in such manner as to form a good covering of the foot. Another dressing, which may be readily extemporized, is a thin pillow, of hair, straw, or even feathers. The leg is placed in the middle and the sides of the pillows are folded up over it; then several tapes are firmly tied at different points around the whole. The same dressings are most useful when the fracture involves the parts entering into the ankle-joint.]

§ 2. General Treatment of Fractures.

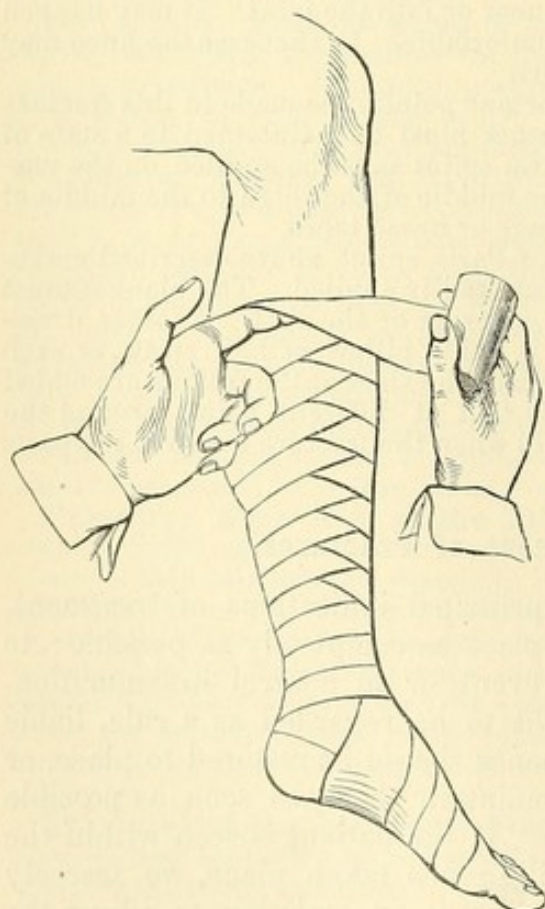
Nearly all fractures present three principal indications of treatment, namely: to restore the fragments to place as completely as possible; to maintain them in place; and to prevent or to control inflammation, spasms, and other accidents. It ought to be regarded as a rule, liable only to rare exceptions, that broken bones should be restored to place, or to the position in which we hope to maintain them, as soon as possible after the occurrence of the accident. If the patient is seen within the first few hours, or before much swelling has taken place, we scarcely know the circumstances which would warrant an omission to adjust the fragments either end to end or side by side, as the one or the other might be found to be practicable.

We have before sufficiently explained the general impossibility of again restoring to place, end to end, and fibre to fibre, fragments which have been

made to override. We are therefore in no danger of being understood to say that bones should in all cases be immediately "set," in the popular sense of this term. They ought to be "set," no doubt, if this can be accomplished through the application of a prudent amount of force; but if they cannot be thus placed end to end, they may at least be laid in such a manner side by side as to restore, in some measure, the natural axis of the limb, and prevent the points of the bone from pressing unnecessarily into the flesh.

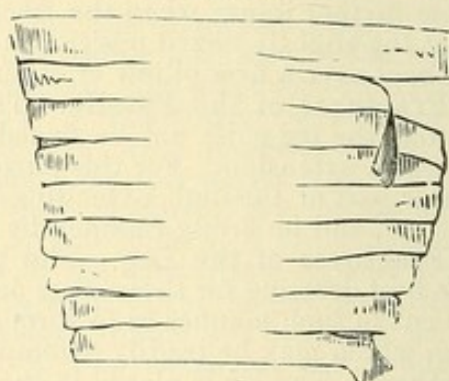
Experience has, indeed, furnished us with four or five very good reasons why broken bones should be reduced as soon as possible. When the injury is recent, the muscles offer less resistance; their resistance being increased after a time not only by the reaction which ensues upon the shock, but also by actual adhesion between their fibres; effusions distend both the muscles and the skin, and compel the limb to shorten; the constant goading of the flesh by the sharp points of the broken bones increases the muscular contractions; the patient will submit readily to manipulation and extension at first, but after the lapse of a few days it is very seldom that he will permit the limb to be in any manner disturbed, even if he is assured that his refusal entails upon him a great deformity. If it is true that no callus or bony structure is deposited earlier than the seventh or tenth day, it is also true that the renewed attempt to adjust the bones at this period, by chafing and tearing again

FIG. 13.



Application of the "roller" by circular and reversed turns.

FIG. 14.



Many-tailed bandage.

the tissues, reduces the fracture, in some degree, to the same condition in which it was at first, and, consequently, the time which has elapsed, or, at least, a portion of it, may be regarded as lost.

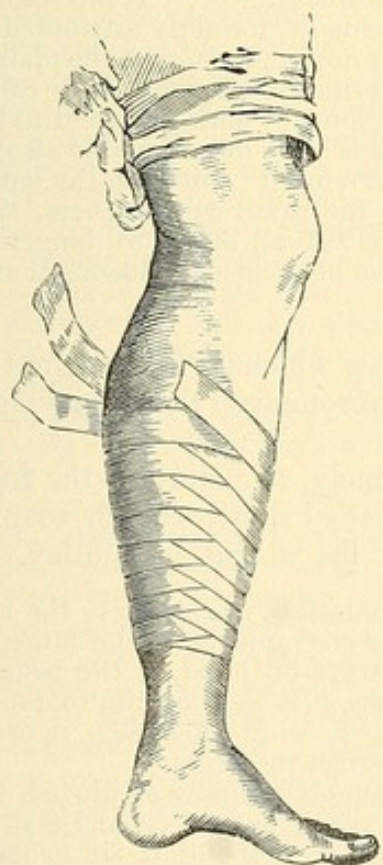
We cannot, therefore, understand the argument by which Bromfield, South, and a few other surgeons have persuaded themselves, that reduction should never be attempted before the third or fourth day; nor, indeed, do we fully appreciate the refinement which Malgaigne has given to this question, in itself so simple. To affirm that we ought not to reduce the bones

to their original positions during the period of intense inflammation, or of great swelling, or while the muscles are acting spasmodically, is only to affirm that we

may not do what is impossible; and the attempt to do which, therefore, can only be mischievous; but to authorize their restoration to a better position, by such manipulation, extension, and lateral support as they may comfortably bear, is warrantable under any circumstances. The practice is not only defensible, but imperative, and we do not think any really sound and practical surgeon ever intended to teach the contrary. We say still, if bones can be easily reduced, or the position of the fragments improved at any moment, or under any circumstances, it ought to be done; and if we fail in accomplishing all that we wish to do in the first instance, we must remain incessantly watchful to seize the earliest opportunity which presents, to complete the adjustment. No doubt our efforts will prove fruitless very much in proportion to the amount of swelling, inflammation, or muscular spasm which exists, and also in proportion to the time which has elapsed; but this will not excuse us for omitting to do all which the circumstances permit.

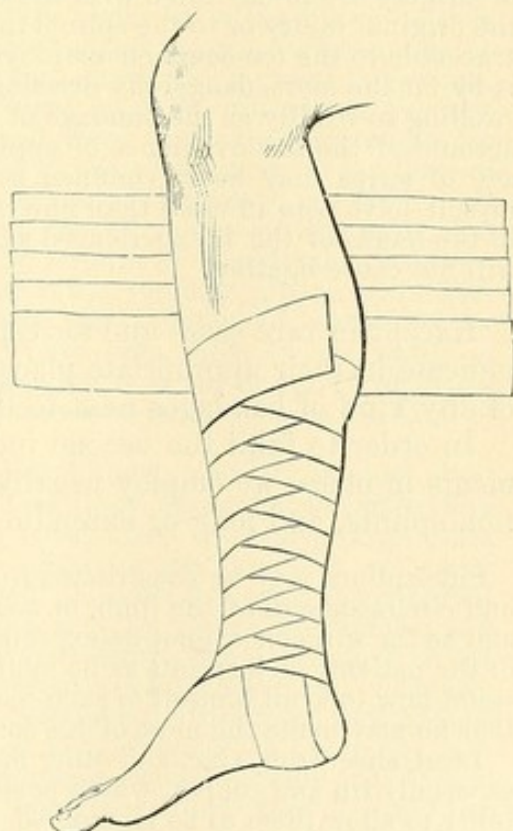
Of the primary dressings there are two principal varieties: first, the "roller" or simple bandage, applied to the limb in circular and reversed turns; and second, the "many-tailed bandage," consisting of a piece of muslin, or other cloth torn down from each side into a suitable number of strips, leaving the centre, which is to be applied to the back of the limb, entire.

FIG. 15.



Application of the many-tailed bandage.

FIG. 16.



Bandage of Scultetus.

A modification of this latter bandage consists of a number of separate strips, so laid upon one another, commencing from above, that each strip shall overlap the other by one-third or one-half of its breadth. This is called the bandage of Scultetus, and it possesses one advantage over the many-tailed bandage just described, especially in the case of compound fractures, in the facility with which each separate piece may be removed and another substituted. Some surgeons prefer to form the bandage of separate strips, and having overlaid them

in the manner directed, to unite them again into one by running a thread through the whole mass along the centre. Whichever of these several varieties of strips are employed, the mode of applying them is the same. They are folded alternately around the limb, being made to overlap and cross upon each other in front, and only the last strip or two is fastened with a pin.

The object proposed in the use of the roller or of the many-tailed bandage is two-fold; first, to compress and support the muscles, by which their tendency to contraction is in some measure controlled; and second, to protect the limb against the direct pressure of the side-splints.

A moment's consideration will convince us that the first of these objects is in most cases fully attained by the lateral splints themselves, and by the bandages by which they are retained in place; and that the second can be as well accomplished by a single fold of cloth, or by the compresses, which ought generally, even when the roller is used, to underlie the splints. Nevertheless, we should hardly feel authorized to reject these primary dressings solely because the splints and compresses furnish a convenient substitute, especially since we are compelled to admit that they are occasionally useful, unless objections of a more serious nature could be brought against them. Unfortunately, this latter supposition is actually true. By ligating the limb completely, leaving no point of the tegumentary surface to which the pressure is not applied, they too often occasion congestion, inflammation, and gangrene. It is not until lately that the attention of surgeons has been sufficiently called to this subject; but the records of surgery are to-day filled with these terrible accidents, formerly attributed to the original injury or to the splints themselves, but now understood to be plainly traceable to the too common employment of the primary bandage. The roller is by far the more dangerous dressing of the two, since it does not yield to the swelling so readily as the bandage of strips, and it is more objectionable also on account of the inconvenience of applying and removing it; but even the bandage of strips may be so confined as to produce the same consequences, as I myself have seen in more than one instance. It is also all the more dangerous in the hands of the inexperienced surgeon, because he feels a confidence that it will not cause ligation.

Except in rare cases and for especial reasons, which I shall attempt to indicate in their appropriate places, I cannot recommend the employment of any kind of bandages next to the skin.

In order to fulfil the second indication, namely, to maintain the fragments in place, we employ usually what are called short, side, or coaptation splints, and long or extending splints, or the weight and pulley.

Side-splints may be constructed from various materials, according to the size and circumstances of the limb, or according to the convenience of the surgeon; and as the surgeon cannot be expected to have always on hand, at the bedside of the patient, such splints as he might prefer to use, it is well for him to understand how to avail himself of such materials as may be within his reach, in order that he may make the most of his sometimes imperfect resources.

Lead, sheet-iron, zinc, and other metals have been occasionally employed, but especially tin and copper, which possess all of the requisite firmness and malleability to allow them to be hammered, and thus moulded to the limb. In general, however, they are unnecessarily heavy, and demand too much labor to be wrought into shape. I have sometimes employed tin splints perforated with large fenestræ to diminish their weight and increase their flexibility, and found them to answer, in certain emergencies, an excellent purpose. The light perforated zinc splints, introduced into the U. S. Army during the civil war of 1861-65, by the Sanitary Commission, were found exceedingly useful for field service.

Iron-wire splints, made from wire-cloth or coarse gauze, were first publicly mentioned, so far as I can learn, in a communication to the *Memphis Medical Recorder*, made by Dr. J. C. Nott, of Mobile; but they have been brought more

particularly into notice, and their construction perfected, by Louis Bauer.¹ These splints, as modified by Bauer, are moulded upon "gypsum or wooden casts," of different sizes, and surrounded with a stout iron-wire frame, in order to give them the requisite degree of firmness, and to preserve their forms; after which they are tinned by galvanism, and varnished, to prevent them from becoming rusted. When applied, Dr. Bauer recommends that they shall be filled with loose cotton, and that they shall be held in place by rollers. It is claimed for these splints that they are light, flexible, permeable to air and to the perspiration, and that they permit the application of cooling lotions without impairing their firmness; the last of which is a quality of questionable value, since lotions applied to permanent dressings of any kind are only warm fomentations, and do not, therefore, in this respect serve the purpose for which they are intended. They render the skin tender and disposed to vesicate, and they also give rise to a sensation of scalding, which is sometimes almost intolerable. The water soaks into the bed, and in many other ways renders the patients uncomfortable. Lotions are only applicable where the dressings are open, loose, and temporary.

According to Poincet (note to French edition of this work), the wire-gauze splint has been used in the Hospital of St. Andrew, Bordeaux, since 1868; a strip of leather being substituted for the stout wire frame of Bauer.

The same objections hold, also, to this as to all other forms of moulded metallic or carved wooded splints, namely, that they seldom exactly fit the limb, even when the supply of assorted sizes is complete, and that they are not sufficiently flexible to adapt themselves to anything but the slightest irregularity of surface. They are not, however, without merit, and they deserve at least a qualified commendation in many cases.

Horn and whalebone may be employed in thin plates, or in the form of narrow strips quilted into cloth; but they are expensive, and possess no special value except in an emergency. Reeds, the coarse rank grass which grows in swamps, flags, willow branches, and unbroken wheat straw, may be quilted between two thicknesses of cloth in the same manner, and form very excellent temporary splints. I have especially found it convenient to use wheat straw in the form of junks. Gathering up a bundle of unbroken straws of the size of my arm, I roll them snugly in a broad piece of cotton cloth, cut off the projecting ends, and then stitch up the cloth neatly. We have thus a splint of considerable firmness, and one which is cool and especially adapted to the summer, allowing the perspiration to evaporate freely. Straw splints were employed sometimes by Ambroise Paré, by J. L. Petit, Larrey, and I have seen them in the wards of certain European hospitals, although I am unable now to say under whose direction. Mr. Tuffnell, of Dublin, has especially recommended them in the form of junks.²

Wooden splints, made of pine, willow, white or linden wood, or of some other light and easily wrought timber, are probably of more general application, and possess greater intrinsic value than splints constructed from any other solid material; but I wish at once, and for all, to disclaim any intention of giving even a qualified approval of any of those carved, polished, and generally patented wooden splints, which are manufactured and sold by clever mechanics, and which one may see suspended in almost every doctor's office, whether in the city or in the country. Constructed with grooves and ridges, and variously inclined planes, for the avowed purpose of meeting a multitude of indications, such as to protect a condyle, to press between parallel bones, to follow the subsidence of a muscular swelling, etc., they never meet exactly a single one of these indications, whilst they seldom fail to defeat some other indication of equal importance. They deceive especially the inexperienced surgeon into the belief that he has in the splint itself a provision for all these wants, and consequently lead him to neglect those useful precautions which he would otherwise have adopted.

If carved wooden splints are employed, they ought to be made especially for the case under treatment. But this requires time and some more mechanical

¹ Nott and Bauer, Buffalo Med. Journ., vol. xii., April, 1857.

² Tuffnell, New York Journ. Med., March, 1847, p. 264.

skill than can always be commanded; and when accurately fitted, it is quite probable that the subsidence or increase of the swelling will, within the next forty-eight hours, render some change in the form of the splint necessary, or compel the surgeon to throw it aside.

I much prefer to use plain, straight strips of wood, of the requisite width and length, which may be cut at any moment from a pine shingle or a thin piece of board; but in order that these splints may adapt themselves to the inequalities of the limb, and properly support the fragments, they ought to be covered with a muslin sack, open at both ends; into which, and on the side of the splint which is to be placed against the limb, bran, wool, oakum, curled hair, or cotton batting may be pressed, until it is made to fit accurately. I generally prefer cotton batting. Bran is liable to get displaced, and curled hair does not pack firmly enough. When the sack is sufficiently filled, the two ends must be stitched up. This mode of constructing the splint is simple and easy of accomplishment; the splint can be fitted very accurately; the padding never becomes displaced; and when the bandages are applied, they may be pinned or sewed to the cover in such a way that they shall not slide or loosen.

If pads are employed separate from the splint—and for this purpose, also, I generally prefer the cotton batting—they ought to be made and fitted with the same care, and neatly stitched together at their ends, rather than pinned. Cotton batting laid loosely next to the skin, or underneath the splints at any point, will not keep its place so well as when it is inclosed in covers—it is more liable to get into knots, and it has altogether a slovenly appearance. The pads may be stitched to the roller, and in this way secured effectually in place, but loose cotton is subject to no control.

When I speak of pads, it must not be understood that I intend to recommend them for compresses, or for the purpose of pressing fragments into place. Nothing could be a greater source of mischief in the dressing of a broken limb. I have only directed their employment as a means of adaptation, and to protect the skin against the direct pressure of the splint.

Dr. Jacobs, of Dublin, says that he has seen an excellent splint made from the "fresh bark of a tree, taken off while the sap is rising. "It fits admirably," says Dr. Jacobs, "just like pasteboard soaked in water."¹ Dr. C. C. Jewett, of the 20th Mass. Vols., recommends for the same purpose the bark of the liriodendron, or tulip tree.

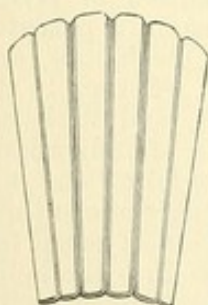
Hemlock-tanned, undressed sole leather, cut into shape and soaked a few minutes in water, adapts itself easily to the limb, and is sufficiently firm. It is especially applicable to fractures of the larger limbs. At Bellevue Hospital it has for several years taken the place of almost all other materials, for the construction of movable splints. Oak-tanned leather is less flexible than the hemlock-tanned, and does not make so good a splint. The specimens selected should be of medium thickness. Before applying the splint the edges should be bevelled

on the inner side, and the corners rounded, and a piece of woollen cloth should be interposed between the splint and the skin. The leather will become hard within twenty-four hours, and at the next dressing it may be removed, covered with a sack made of woollen or cotton cloth, and replaced. Dr. Vance prefers what is known as "bridle leather," which is more plastic than sole leather, hardens as quickly, and becomes as firm. It can be made very hard by substituting hot water for cool in soaking the leather.

A splint is also occasionally made of thin calfskin, veneered with some light timber, such as linden or white wood, the latter being subsequently split into strips of from half an inch to one inch in width, so as to combine a certain degree of flexibility with the requisite firmness.

The Turks use, according to Sedillot, in a similar manner, the "nervures" of palm, laid upon sheep-skin, and fastened with wooden thongs;² and Packard mentions that he has seen narrow slips of some light wood glued in the same way upon soft pieces of buckskin

FIG. 17.



Wood and leather
splint.

¹ Jacobs, New York Journ. Med., March, 1847, p. 265, from Dublin Med. Press.

² Amer. Journ. Med. Sci., vol. xxiii., Feb. 1839, p. 481.

and then fastened together with two strips of buckskin, which were also glued to the splints.¹

Common, unpolished pasteboard, cardboard, and the stout millboard used by bookbinders, constitute the valuable domestic resorts, since they can generally be found in the house of the patient; and, if in no other way, pasteboard may generally be had at the expense of some paper box or of the loose cover of some old book. For small bones, the thinner sheets afford a sufficient support; but for large bones the thick binder's board is necessary. In preparing the latter for use, it ought to be moistened with water; but if soaked too much it will separate and fall into pieces, or lose its firmness when dry, in consequence of having parted with some of its paste. This splint may be applied to the limb without the interposition of anything but a few folds of muslin cloth or a piece of flannel; or we may use instead a single sheet of cotton-wadding. It must be bound to the limb by the roller whilst it is moist; and, as it dries speedily, it forms a smooth, firm, and reliable splint.

Felt, made of wool saturated with gum shellac, and pressed into sheets, makes an excellent moulding tablet for splints. This may be obtained at any hat manufactory. A much cheaper material, and which has nearly all the qualities of the real felt, may be made from old pieces of broadcloth, or from any similar closely woven texture, by saturating it thoroughly with gum shellac, the gum being dissolved in alcohol in the proportion of one pound of the former to two quarts of the latter. Thus prepared, it is to be spread upon both surfaces of the cloth with a common paint-brush. When this first coat is well dried by suspending the cloth where the air will have free access to both surfaces, a second must be spread upon one of the surfaces; and then a third; the cloth being allowed to dry after each successive coat. Finally, the sheet is to be folded upon itself, so as to bring the most thickly covered surfaces together, and pressed with a hot flatiron. If it is necessary to have greater strength, more gum may be laid upon the cloth, and it may be again folded and pressed. When used, it is to be dipped into boiling water, or held near the fire until it becomes flexible. Shellac cloth hardens very rapidly in cooling, and demands, therefore, some quickness in its application; but once applied and fitted, it forms a hard but smooth splint, well adapted to all the purposes for which it is designed. It is well to mention, if one wishes to keep any portion of the solution which is not used, that, in order to prevent evaporation, the vessel in which it is contained must be closely covered. Boiling water deprives it of a portion of its shellac, and it is better to soften it by holding it to the fire.

Recently, I have found an article which is better for general use than woollen cloth treated with gum shellac. The fabric is lighter, cheaper, and more flexible. It is made of from four to six layers of cotton cloth, saturated with gum shellac and smoothly pressed, and is sold by the manufacturer at the rate of about two dollars per yard. At the present time it is used more often by myself than any other material for the ordinary purposes of a movable plastic splint, and I think is preferred by most of our surgeons. It is light, and, if dipped in hot or boiling water for a few moments, it becomes sufficiently flexible to adapt itself readily to almost any inequality of surface. Before being cut, a paper model should be made from the limb to serve as a pattern. It hardens quickly, but not too quickly for accurate adjustment.

The principal objection to all of those forms of splints which contain gum shellac is, they harden so rapidly after being made flexible by exposure to heat, that it is often found difficult to give them an accurate mould to the limb. It has been objected to the felt splint occasionally, that it is impervious to air and moisture, and that it confines the insensible perspiration; but, as I never use splints of any kind without underlaying them with compresses, or woollen cloth, which act sufficiently as absorbents, I have never been aware of any inconvenience from this source.

Dr. R. O. Cowling, of Louisville, Ky., has called attention to the value of Manilla paper in the construction of splints.² A limited use of this material satisfies me that it possesses most of the qualities of a good splint. It is cut into

¹ Packard's edition of Malgaigne, vol. i. p. 173.

² American Practitioner, Jan. 1871.

strips, stiffened with starch, and applied longitudinally or spirally, as may be necessary to cover the limb completely and smoothly. For the lower extremities six to eight layers are required. The material may be obtained at most large paper stores.

The employment of gutta-percha as a coaptation splint was first suggested and practised by Oxley, of Singapore. For fracture of the thigh, and for the large bones generally, I prefer a thickness of about one-sixth or one-fifth of an inch; but for the fingers or toes it need not be more than one-sixteenth of an inch in thickness. In its natural state, and at the ordinary temperature of the body, it is nearly as hard and as inflexible as bone; but when immersed in hot water it almost immediately softens, and would become too soft to be conveniently handled unless soon removed. It can therefore be adapted to any surface, however irregular, and its form may be changed as often as may be necessary. It does not harden as rapidly as felt, and it possesses, therefore, in this respect, an advantage, since it allows the surgeon more time for adjustment; whilst, on the other hand, it hardens much more rapidly than either starch, paste, or dextrine. Ten or twenty minutes is all the time usually required for gutta-percha to acquire that degree of firmness which will prevent it from yielding under the pressure of a bandage. To use gutta-percha skilfully requires some experience, and I have known surgeons to reject it after a single trial; but by those who have acquired the necessary skill it is generally regarded as an invaluable resource. When constructing from this material a thigh-splint, we should order a very large tin pan, or some open, flat tray, in which we may lay the splint at full length. If the splint is required to be twelve inches long and six inches wide, we must cut it about fourteen inches long by seven wide, so as to allow for the contraction which always takes place more or less when the hot water is applied. It is then to be laid upon a sheet of cotton-cloth of more than twice the width of the splint, in order that the cloth may envelop it completely when it is folded upon it; and the cloth should be enough longer than the splint, to enable us to handle and lift it by the two ends without immersing our fingers in the hot water. If the gum is not thus covered and supported, it will adhere to the vessel, to the fingers, to the surface of the limb, and indeed to whatever else it comes in contact with; it may even fall to pieces, or become very much stretched and distorted by its own weight. The cloth cover will generally adhere to the splint, and may be permitted to remain upon it permanently. Place the splint, thus covered, in the basin, and pour on the water slowly. As soon as it is sufficiently softened, lay it over the limb, moulding it carefully with the hands, or by pressing it against the limb with a pillow. If it does not harden rapidly enough, this process may be hastened by sponging the outer surface with cold water; and as soon as it has acquired sufficient firmness to support itself, it may be removed and immersed in a pail of cold water or placed under a hydrant; after this, it is to be neatly trimmed and wiped dry, when it is ready for use. When gutta-percha remains a long time exposed to the air, it gradually oxidizes, its color becomes darker, it loses its tenacity and flexibility. This may be prevented by keeping it constantly immersed in cold water. It may be sufficient to place it in a damp cellar.

The same objection has been made to gutta-percha which is occasionally made to felt, namely, that it confines the perspiration, but to this I have already sufficiently replied. There is scarcely any fracture demanding the use of a splint in which I have not demonstrated its utility, but it is especially valuable, as I shall have occasion to mention again, as an interdental splint in fractures of the jaw, and as a moulding tablet in all fractures occurring in the vicinity of joints.

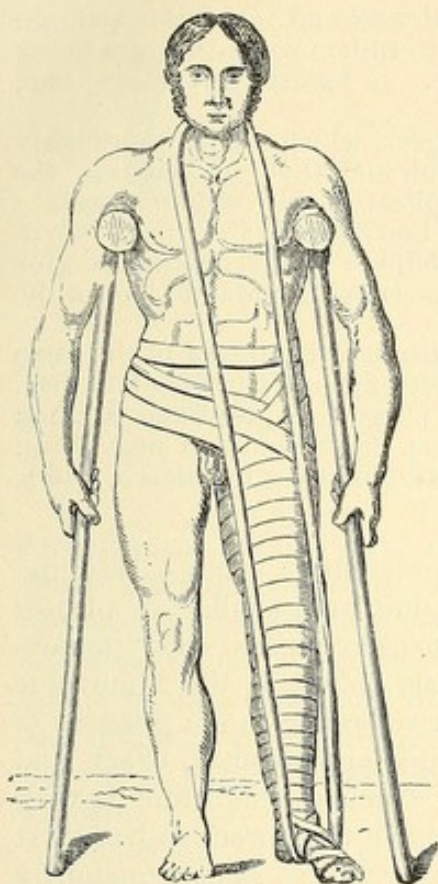
Immovable or Permanent Dressings.—This class of dressings have now a most important place in the treatment of fractures, and deserve careful study.

In 1834, Seutin, of Brussels, introduced the use of *starch* as a means of hardening the bandages; his method of using which is essentially as follows: A dry roller is first applied to the skin, and then smeared with starch; all of the bony prominences and irregularities of the limb are filled up, or covered with cotton batting, charpie, down, etc.; strips of pasteboard, or of binders' board moistened and covered also with starch, are now laid alongside the limb, over which again are turned in succession, one, two, or three layers of the starched roller; the number of rollers, and the thickness of the pasteboard being proportioned

to the size of the limb or to the required strength of the splint. The whole is completed by starching the outside of the last bandage.

This dressing will generally become dry within from thirty to forty hours; which process may be expedited by exposing its sides as much as possible to the

FIG. 18.

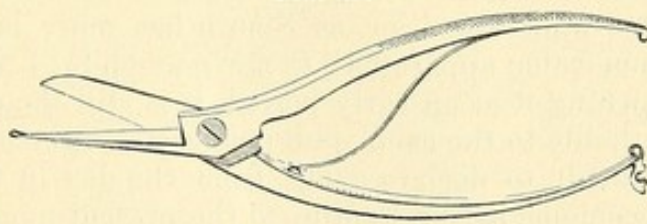


Starch bandages applied for a broken thigh.

air, or by the application of artificial heat with bags of dry sand, or with hot bricks. As a temporary support until the drying is completed, some surgeons lay upon each side of the limb additional splints, securing them in place with tapes. As soon as the bandages are dry, they are to be cut along the front to a sufficient extent to permit of an examination of the limb, and then closed with an additional roller. For the purpose of opening the bandages, both at this period and subsequently, Seutin uses a pair of strong scissors or pliers, such as are represented in Fig. 19. On the third or fourth day, or as soon as the subsidence of the swelling may render it necessary, the bandages should be cut open through their whole extent, the edges pared off and brought together again snugly with an additional roller.

In 1837, Velpeau substituted *dextrine* ("British gum"); a kind of glue or jelly obtained by the continued action of diluted sulphuric acid upon starch at the boiling-point. It is pre-

FIG. 19.



Seutin's pliers.

pared for use by dissolving it in alcohol or tincture of camphor, or camphorated brandy, until it has acquired about the consistence of honey; at this point hot water should be added, reducing its consistence to that of thin treacle, when, after one or two minutes' shaking, it is ready for application. According to F. d'Arcet, the proportions most favorable to the drying and solidifying of the apparatus are, one hundred parts of dextrine, sixty of camphorated brandy, and fifty of water. Malgaigne, to whom I am indebted for this observation of d'Arcet, says, also, in a note, "As regards dextrine, an important point was recently brought practically under my notice, viz., that, as sold in the shops, it is often unfit for making an agglutinative mixture; it forms lumps with alcohol, as starch does with cold water, without cohering; and twice in succession I have been obliged to change the supply at the Hôpital Saint Antoine. The dextrine thus deteriorated is whiter and less saccharine; it crepitates more in the fingers; and on pouring a few drops of tincture of iodine into the solution there is produced a violet tint, indicating the presence of fecula; while true dextrine, treated with iodine, gives a vinous red, or the color of onion-peel." The addition of one part of common glue to six of dextrine renders the splint more tough. Velpeau soaked his bandages with the dextrine before applying them, but, like Seutin, he applied his first roller dry. He used but one bandage, which he carried first from below upward, and then from above downward; and he rarely thought it necessary to employ the pasteboard as a collateral support.

Tripolith was first introduced by Skenk as a substitute for plaster in the preparation of bandages. It is a gray powder, composed of lime, silice, and oxide of iron. Lately Langenbeck and other German surgeons, and some of the French

surgeons, including M. Poincot, have spoken of it quite enthusiastically. It hardens much more quickly than plaster, and is much lighter, in both of which qualities it resembles dextrine.¹ But Dr. N. S. Nelson, in his inaugural thesis at Harvard, declares that he has experimented with it, and that it hardens too quickly; that it is not, as claimed by Langenbeck, impervious to water; that it is expensive, and as a splint "untrustworthy."²

A mixture composed of equal parts of *precipitated chalk* and *gum arabic*, reduced to a proper consistence by boiling water, applied to rollers while they are being applied to the limb, forms a firm and light splint. It has the advantage, also, of hardening quickly.

Startin and Tait, of London, recommend *paraffine*, which, being thoroughly melted, is cooled a little, to render it more viscid, and then rubbed into the meshes of the bandage, during the process of application with a paint-brush.

Morgan, of the Middlesex Hospital, uses the best *French glue*, dissolved in water, with a little alcohol; while Levis, of Philadelphia, has recommended glue mixed with a small amount of oxide of zinc, the latter being added to hasten the process of hardening.

Silicate of soda, of *potassa*, or of *magnesia*, have also been employed in the same manner. Of these, the silicate of soda is the least expensive and equally firm, but does not harden as quickly as the silicate of potash. A saturated solution is prepared, and applied with a brush. It forms a light, firm, and neat spint, Wheat-flour paste, if properly made, dries about as quickly as the starch, and is equally firm.

Whatever material is used—whether starch, flour paste, dextrine, paraffine, tripolith, solutions of the silicates, glue, gum shellac, or plaster of Paris—in the construction of what is now usually termed the "immovable apparatus," or, as Seutin has more lately called it, the "movable immovable apparatus" ("movo-amobile"), in reference to his practice of opening it at an early period, it is still the same apparatus in effect, and is liable to the same judgment—a judgment which we shall find it very difficult to declare, since from the day in which this practice was first recommended by Seutin, to the present moment, it has been constantly experiencing the most extraordinary vicissitudes in the public favor; at one time, and by the most experienced surgeons, extolled as a method unequalled in its simplicity, efficacy, and safety; and at another, and by surgeons of equal experience, denounced as eminently lacking in all the true essentials of an apparatus for broken limbs. These conflicting opinions, which it is impossible to reconcile, have nevertheless some foundation in truth. The immovable apparatus, of whatever materials constructed, is under some circumstances a very simple, safe, and efficient dressing, while under other circumstances it is, as we think, eminently unsafe and inefficient. Thus, in all of those fractures which are accompanied with such injury to the soft parts as to render subsequent inflammation inevitable or probable, this form of dressing exposes to congestion, strangulation, and gangrene. Whatever its advocates may say to the contrary, the simple fact is before us that the number of accidents resulting from this practice is out of all proportion with any other yet introduced. I myself have met with them in all parts of my own country, and the journals abound with records of disasters from this source.³

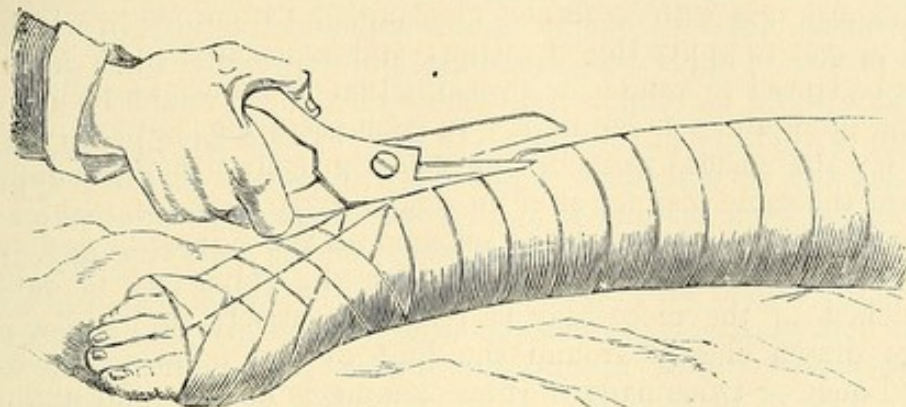
¹ Berliner klinische Wochenschrift, 1880.

² Nelson, Annals of Anatomy and Surgery, April, 1882.

³ Amer. Journ. Med. Sci., vol. xxv. p. 460, Feb. 1840; also vol. xxxi. p. 212. Med. Record, Nov. 1, 1873. New York Med. Journ., Aug. 1874, Oct. 1874.

Nor is it a sufficient reply to this statement that with proper care and prudence such accidents may be avoided. We think they could not always be avoided. But admitting that they could, it is still undeniable that in certain cases the immovable apparatus demands extraordinary attention;

FIG. 20.



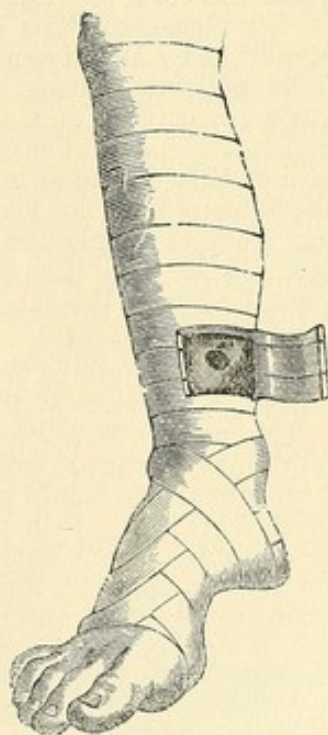
Opening of the apparatus with Seutin's pliers.

and what is the need of multiplying our cares when already they are more than sufficient? Many circumstances, over which he has no control, may prevent the surgeon from giving to the limb the full amount of attention which is required; and for this reason that apparatus is the best which, whilst it answers the indications equally well, exacts the least amount of skill and attention on the part of the surgeon.

Immovable dressings are not only liable to become too tight as the swelling augments, but, on the other hand, the surgeon may omit to notice that as the swelling has subsided it has become loose. Portions of the limb may vesiccate, ulcerate, or even slough, without the knowledge of the surgeon. If, however, the bandages are frequently opened, and all the proper precautions are taken, it is possible that these accidents may also be avoided; but unfortunately experience has shown that they have not been avoided in too many instances.

The cases, then, to which this apparatus seems to be especially adapted, are a few examples of transverse or serrated fractures in which the bones have not become displaced, and in which little or no swelling is anticipated; and certain fractures which were originally more complicated, but in which a partial union, and the subsidence of the inflammation, have reduced them to a more simple condition; and especially is it adapted to cases of delayed union. If now the dressings are applied carefully, the bandage being only moderately tight; and a portion of the extremity of the limb is left

FIG. 21.



"Apparatus immobile"
applied over a compound
fracture.

uncovered so that we may observe constantly its condition, and at proper intervals the apparatus is opened completely, in order that we may subject the whole limb to a thorough examination; in such cases as I have now indicated, and with such precautions, I admit that the "apparatus immobile" constitutes an invaluable surgical appliance, and one of which no surgeon can well afford to be deprived.

I have also met with examples of compound fractures in which it has seemed proper to apply this dressing; and especially when a sufficient time had elapsed to render it probable that there would be no sudden accession of swelling in the limb. In such cases I have preferred generally to lay the several turns of the roller directly over the suppurating wound in the same manner as if no wound existed, and to make a valvular opening, or window, with the scissors, on the following day, in order to allow the matter to escape, after which the valve may be laid down and stitched, or the piece may be removed entirely, and a new piece of bandage drawn closely around the limb at this point. This may be repeated once or twice daily. If an opening is left by the roller, and no additional bandage or compress is laid over it, the margins of the wound soon became œdematous and protrude, making an ugly-looking and ill-conditioned sore.

Plaster of Paris has, however, been from a later period employed in another form, as an "immovable" dressing. I allude to the so-called "plaster-of-Paris bandages," which were first introduced to notice by Mathiesen, of Holland, in 1852. In 1854, Pirogoff, surgeon in chief of the Russian armies, called attention to the plaster-of-Paris dressing, but in a form differing somewhat from that employed by Mathiesen.

At Bellevue, during six or seven years, Paris-of-Paris bandages were used quite extensively, and, after a careful observation of the results in my own wards, and in the wards of my colleagues, I find no occasion to recall anything I have said of this, as one form of the immovable apparatus, in the preceding pages; the dangers have not been over-estimated, yet I must say that in fractures of the leg, whether simple or compound, when great care is exercised in the management of the case, it is, in some respects, superior to any other form of dressing. I shall describe the cases to which it is applicable, more particular, when speaking of these fractures. At the present moment the use of plaster of Paris as a dressing for fractures is very little in favor with most of the Bellevue surgeons, except in fractures of the tibia and fibula.¹

The manner of using gypsum bandages, generally preferred at Bellevue Hospital, may be thus briefly described. Thin, rather coarse, unglazed cotton cloth, torn into strips, is laid upon a table and the dry plaster rubbed into it until its meshes are full. It is then rolled, and made ready for use by immersing it a few minutes in hot water. The limb, being held in a proper position, is first inclosed in soft, dry flannel cloth, and the rollers are then applied. In most cases two or three thicknesses of bandage are found to be sufficient. A more full description of this method, known generally as Mathiesen's, will be found in the chapter devoted to the consideration of fractures of the femur.

Another method of using the gypsum bandages, not generally practised at Bellevue, is as follows: A dry roller is first applied to the limb, or it may be covered with a single piece of cloth of any kind, and the irregularities are filled up and protected with cotton-wool, the same as we have directed when

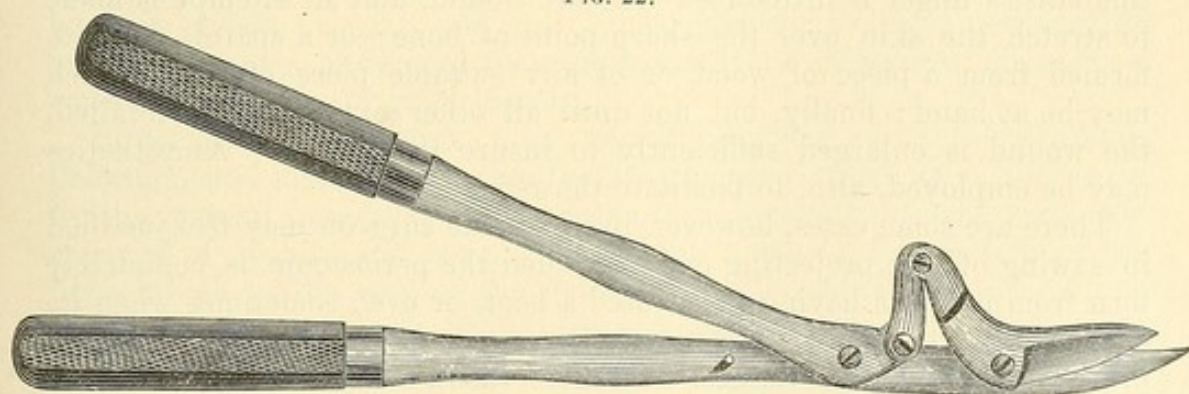
¹ Treatment of Fractures of the Femur by the Immovable Apparatus, by the author. New York Med. Journ., Aug. 1874. A comparison of the results of treatment of 308 fractures of the thigh at Bellevue Hospital, by Frederick E. Hyde, M.D., New York Journ. Med., Oct. 1874.

about to apply the starch bandage. The remaining dressings being now at hand and ready for use, we proceed to mix the plaster. For this purpose we must select the fine, fresh, well-dried, white powder. The gray does not solidify well, nor that which has been a long time ground, or is moist. The proportions of water and plaster usually required are about equal parts by weight. For the thigh it may require, perhaps, seven or eight pounds of plaster, and for the leg or arm much less. It is probably a better rule to direct the gypsum to be added to the water until it is of about the consistence of cream. The water should be cold and the gypsum thrown in not too rapidly, at least not more rapidly than it can be thoroughly mixed, otherwise we shall not be able to determine precisely its consistence. If, while applying the paste, it begins to harden in the bowl, we must not add more water, as this will again interfere with its final solidification upon the limb. It must be thrown away and some fresh immediately prepared; or the crystallization may be retarded by throwing in a few drops of carpenter's glue, or a little starch, dextrine, or glycerin. The solidification may be hastened by adding a little salt to the water. When the plaster is good, and it is properly mixed, we may allow ourselves from five to eight minutes in the application. A large paint-brush is the most convenient thing for spreading it, but the hands will do very well in an emergency.

Everything being ready, the limb is to be seized by assistants at both of its extremities and held in a position of steady extension until the dressing is completed, and for several minutes longer, or until the plaster is hard. The surgeon then proceeds to lay a long piece of linen—old sack will answer as well as any—folded three or four times, and saturated with the paste, parallel to the two sides of the limb, around which are to be immediately placed, horizontally and at several points, short and wide strips of the same material. These latter are intended to increase the strength of the apparatus, and to bind on the side strips. Finally, the whole may be painted with the solution. It is very well, however, not to cover the front of the limb, or a narrow strip somewhere in the line of the axis of the limb, with the plaster, as this will not diminish materially its strength, and it will enable the surgeon to open it more easily with the scissors. Pirogoff accomplishes the same purpose by laying a piece of narrow tape, soaked in oil, along the line through which he wishes to make the section of the splint.¹

Little, of New York, makes his plaster splints of two or three thicknesses of muslin, or of canton flannel, which being saturated with fluid plaster, are laid upon the limb previously shaven and oiled, and secured in place with a roller. He advises that the roller shall be removed as soon as the plaster is set and a fresh one applied, which can afterward be easily removed.²

FIG. 22.



Von Brun's plaster cutter.

In removing the plaster we generally employ a shoemaker's knife, softening the plaster as we proceed with a sponge dipped in hot water. As cutting pliers

¹ Weber on Plaster-of-Paris Bandage, New York Journ. Med., May, 1856, p. 341.

² On the Use of Plaster of Paris in the Treatment of Fractures, by James L. Little, Surgeon to St. Luke's Hospital, etc., Med. Record, Nov. 1, 1873.

for this purpose, no instrument has been found sufficiently powerful except that introduced by Dr. Victor von Brun, of Tübingen.

Professor B. W. Dudley, of Lexington, Ky., one of the most successful surgeons in this country, but especially distinguished as a lithotomist, for many years employed in the treatment of fractures nothing but a roller, regarding both side-splints and extending apparatus as not only useless, but absolutely pernicious.¹ This practice, which seems to have originated with Radley, of England, has not found, hitherto, in this country or elsewhere, many imitators.

Still more unscientific and irrational was the practice of Jobert, of Paris, who employed neither side-splints nor bandages, but only extension, in the treatment of all, or of nearly all fractures of the long bones. The side or coaptation splints bring the fragments into more complete apposition, and secure a more prompt and certain union. They ought, therefore, never be omitted, unless the condition of the limb precludes their application.

As to the question of permanent extension in fractures, and the means by which it may be most effectually accomplished, nothing need be said at this time, inasmuch as it relates only to the fractures of certain bones, and to certain forms of fractures; we must therefore refer its consideration to those chapters which treat of individual bones.

In the treatment of *comminuted* fractures, no pains ought to be spared to bring the fragments as nearly as possible into apposition; and if there exists at the same time an external wound, and the fragments are small and loose, they ought to be removed carefully. Nor, indeed, should we be deterred from the attempt to remove them by finding that they are somewhat adherent, if still they are very easily moved about with the finger.

In *compound* fractures, not unfrequently the end of one of the fragments protrudes from the wound, and its reduction may be attended with considerable difficulty. My practice is usually in such cases to attempt the reduction first, by simple extension and counter-extension; but if this fails, a finger is introduced into the wound, and an attempt is made to stretch the skin over the sharp point of bone; or a spatula is used, formed from a piece of wood, or of any suitable piece of metal which may be at hand; finally, but not until all other expedients have failed, the wound is enlarged sufficiently to insure its return. Anæsthetics may be employed, also, to facilitate the reduction.

There are some cases, however, in which the surgeon may feel justified in sawing off the projecting end; as when the periosteum is completely torn from it by its having penetrated a boot, or even sometimes when its extremity is very sharp, and there is reason to suppose that it would prick and irritate the tissues. In these cases, also, surgeons have proposed to secure the fragments in apposition by metallic ligatures or sutures. In a few instances the practice has been attended with success, but in most cases the wires have failed utterly of their purpose, and have only proved sources of additional irritation.

¹ Dudley, Trans. Amer. Med. Assoc., vol. iii., 1850, p. 349.

Ruptured arteries, if within reach, ought always to be tied; and if arteries situated remote from the surface bleed freely and for a long time, we may make some effort to find the open mouths in the wound; but in this we rarely succeed, nor is it safe generally to trust to a ligature of the main branch which supplies the limb. Fortunately, this bleeding, although at first profuse, generally ceases in a few hours under the steady employment of cold lotions, moderate compression, and rest. If it does not, the chances are that the case will call for amputation.

To ligate the main arterial trunk which supplies the injured limb, as suggested by Poincot, would, in my opinion, expose the life of the patient to greater dangers than to amputate the limb. Under such circumstances, with the limb bruised and infiltrated with blood, to cut off its main arterial supply would render the occurrence of gangrene almost inevitable. Compression at the point of lesion and upon the main artery, at the same time, as suggested also by Poincot, would insure the same result.¹

Bones Badly United.—Bones which have united with serious deformity are occasionally refractured for the purpose of securing a more comely or a more serviceable limb. This may be done when the union is recent and the callus and adjacent tissues are vascular, with almost an assurance of a prompt union. Indeed, if the bone be refractured within four or eight weeks after the occurrence of the original fracture, it will in general unite more speedily than at first; and this is especially true in the case of children; but if the refracture be delayed much beyond the latter period, the chances of prompt reunion become lessened, and after the lapse of several months or years the danger that a refracture will result in only a fibrous union is considerable. In the case of an old fracture it becomes therefore a question, whether the deformity and maiming are sufficient to warrant the surgeon in assuming the risk that it may not unite at all, or that it may result in a fibrous union. The cause of this delay and uncertainty in the proper union after refracture of bones which have been long united, is probably the fact that the bond of union becomes at length harder than the original bone, and although it may break as easily as, or even in most cases more easily than, the natural bone, it is less vascular, and the tissues adjacent are also perhaps less vascular, having undergone certain textural or cicatricial changes in consequence of the original lesion.

In deciding this question, then, we will be governed by the degree of deformity and maiming, by the time which has elapsed since the union, by the general condition of the patient as to constitutional vigor and capacity of repair, and especially by the bone, or the portion of the bone, which is the seat of the deformity. Refractures of the shafts of the humerus and of the femur are less likely to unite by bony callus, than refractures of the forearm or leg. If only one bone is broken in the forearm or leg, the danger of non-union after refracture is lessened, and especially if the lower end of the radius is the part involved.

There is one popular error in reference to refracture, and indeed the error is by no means confined to the laity, namely, that by a refracture at any period after four or six weeks we can materially add to the length of the limb. The

¹ Poincot, French edition of this work, p. 55.

permanent contraction of the muscles which by this time has taken place, the presence at an early stage of inflammatory effusions, and at a later stage of adhesions, will in most cases effectually prevent any considerable elongation of the limb. It may be lengthened by being rendered more straight, and in a small degree perhaps by actual stretching of the soft tissues, but this is all that can be reasonably promised or expected, in a large majority of cases.

In general, no fear need be entertained that the refracture will endanger the life of the patient, unless the fracture involves a joint. No doubt death may have been caused in this way, but a scientifically conducted refracture is vastly less likely to cause death than the original accident. Nor need we generally fear that the bone will break at any other point than at the place of the old fracture, provided at least we take proper care to make the pressure at the right point.

CHAPTER VII.

DELAYED UNION, FIBROUS UNION, AND NON-UNION OF BROKEN BONES.¹

MUHLENBERG, of Philadelphia, has made a very valuable contribution to this subject in a collection of cases drawn from the medical journals, and published in a tabular form by Dr. Agnew in his treatise on surgery. In a summary of the whole number, 656 cases, it is stated that 565 were males and 91 females. The youngest was 13 years old and the oldest 70, the largest number being within 28 and 40 years. In 61 the fractures had existed less than three months; the shortest period being three weeks, and the longest ten years. The whole number cured by the various plans of treatment was 385; of the remaining 271, 43 were relieved—that is, the amount of motion between the fragments was lessened—in 204 no benefit was derived from the operation, 19 proved fatal, and in 5 the result is not known.

Causes and Varieties.—Most surgical writers concur in the statement that non-union of broken bones is an uncommon event.

Walker, of Oxford, affirms that of not less than one thousand fractures which have come under his treatment at some period of the repair, he does not recollect more than six or eight instances. According to Lonsdale, not more than five or six cases of false joint, excepting those within a capsule, have occurred out of nearly four thousand fractures treated at the Middlesex Hospital. In a table of 367 cases, collected and arranged by W. W. Morland, from the books of the Massachusetts General Hospital, extending through a period of nineteen years, only one example of false joint is recorded; but as only seventy-four days had elapsed when this patient was discharged, it is doubtful whether this might not have proved to be a case of delayed union simply.² In 946 cases of recent

¹ I shall in this chapter avail myself freely of the labors of George W. Norris, of Philadelphia, whose paper, entitled "On the Occurrence of Non-union after Fractures, its Causes and Treatment," published in the *American Journal of the Medical Sciences* for Jan. 1842, constitutes one of the most complete and reliable monographs upon this subject contained in any language.

² Address on Fractures, by A. L. Pierson, read before the Massachusetts Med. Soc., May 27, 1840.

fracture treated in the Pennsylvania Hospital, between the years 1830 and 1840, there was no instance of false union.¹ Sir Stephen Hammick, Mr. Liston, and Malgaigne affirm also the infrequency of these accidents in the cases which have come under their personal treatment. I myself have seen a large number of examples of non-union, but in not one of my own patients, whether in hospital or private practice, except in cases involving joints, has the bone refused finally to unite; and my opinion is that, in proportion to the number of fractures everywhere, these cases are very rare, perhaps not in a larger proportion than one in five hundred.

The humerus and femur would appear to be the bones most liable to non-union, as shown by Norris's statistics; in which forty-eight belonged to the humerus, forty-eight to the femur, thirty-three to the leg, nineteen to the forearm, and two to the jaw. I have found the humerus ununited more often than the femur.

Bérard has shown that in the growth of the long bones the period at which the epiphyses are united to the diaphyses depends upon the direction of the nutritive artery; for example, "It is found that in the humerus, where the direction of this vessel is from above downward, consolidation takes place soonest at its inferior extremity. In the forearm the course of the nutrient vessels is from below upward, and here consolidation of the epiphyses is found to occur at the elbow sooner than at the wrist. In the inferior members, on the contrary, the epiphyses composing the knee are the last which become firm, because in the femur the nutritious artery runs upward, and in the bones of the leg it courses from above downward." A knowledge of these facts led Guéretin to inquire into the influence of these arteries upon the consolidation of fractures; and the cases collected by him did indeed seem to show a positive relation between the direction of the artery and the union of the bone: that is to say, the examples of non-union were chiefly found where the fracture had taken place on that side of the nutritious foramen from which the artery entered, as if to imply that the non-union was in some measure due to the imperfect nutrition of this extremity of the bone. In thirty-five cases of non-union analyzed by Guéretin, ten belonged to that portion of the bone which was traversed by the artery, and twenty-five to the other portion. But an analysis of forty-one cases, made by Norris, does not seem to confirm this observation of Guéretin, since twenty-seven were in the direction of the nutritious arteries, and only fourteen in the opposite portion, or in that which is supposed to be less nourished.

Another observation, made by Curling, that in fractures of the long bones the portion below the entrance of the nutrient artery, or on that side of the nutrient foramen toward which the blood flows, being defrauded of its proper supply, is subjected to a species of atrophy, presenting a larger medullary canal, with thinner walls, and a spongy tissue less dense, also needs confirmation. Malgaigne has not noticed this fact in any of the specimens contained in the public museums of Paris.

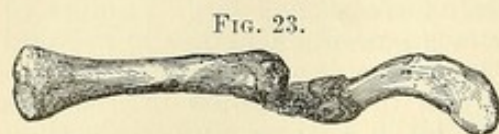
According to Norris, there are four principal kinds of *false joint*:

In the *first*, the bones are united and completely enveloped in a cartilaginous mass or callous tumor, but, in consequence of some retardation in the process, bony matter is not deposited, and, as a consequence, it wants solidity, the part continuing easily movable. This may be regarded as a proper example of delayed union, as distinguished from complete non-union, or false joint.

In the *second*, there is entire want of union of any sort between the fragments, the ends of which seem to be diminished in size and extremely movable beneath the integuments. The limb in these cases is found wasted and powerless.

¹ Norris, loc. cit.

In the *third* and most common class, the medullary canal is obliterated in both fragments, and the ends are more or less absorbed, rounded, and



Clavicle united by ligamentous bands.

covered, in part or in whole, with a dense tissue resembling the periosteum. A connection also exists between the opposing fragments in the form of strong ligamentous or fibro-ligamentous bands, which, if of any length,

are quite flexible, and allow of considerable motion at the seat of fracture.

In the *fourth*, "a dense capsule without opening of any kind, containing a fluid similar to synovia, and resembling closely the complete ligaments, is found." In these cases the points of the bony fragments corresponding to each other are rounded, smooth, and polished, in some instances eburnated, and in others covered with points or even thin plates of cartilage, and a membrane closely resembling the synovial of the natural articulation. It is in this kind of cases, Norris remarks, that the member affected may still be of use to the patient, the fragments being so firmly held together as to be displaced only upon the application of considerable force.

The existence of the newly formed joints, or true diarthroses, has been called in question by Boyer, Hewson, Chelius,¹ and others; but the observations of Sylvestre, Brodie, Beclard, Home, Howship, Otto, Kuhnholz, Houston, Cooper, Langenbeck, Féraud, and Breschet prove that such examples are occasionally found.² I myself have met with several examples.

The causes of delayed union and of non-union are either constitutional or local.

The *constitutional causes* are chiefly those conditions of the general system which manifest themselves by anæmia, debility, or some peculiar dyscrasy.

Syphilis in the system has seemed to prevent the formation of callus. Such is the opinion of Sansom, Beulac, Condie,³ and many others.

Lagneau and Oppenheim⁴ incline to the opinion that syphilis exerts in this respect but little influence; and even Bérard, who admits the pertinence of one case observed by Nicod, concludes, after numerous researches, that it has been very rarely shown to affect the formation of callus.⁵

Pregnancy and *lactation* have been known to interfere with the union of bones.

¹ Malad. Chirurg., t. iii. p. 103, Paris, 1831; North Amer. Med. and Surg. Journ., No. ix. p. 7, 1828; Trait. de Chir., trad. par Pigné, p. 150, 1836. (Norris, loc. cit.)

² Nouvelles de la Répub. des Lettres de Bayle, p. 718, 1685; Lond. Med. Gaz., xiii. p. 57, 1833; Beclard, Gen. Anat., trans. by Hayward, pp. 149, 248; Transac. Med.-Chir. Soc. of Edinburgh, i. p. 233, 1793; Med.-Chir. Trans., viii. p. 517, 1817; Otto's Path. Anat., trans. by South, i. p. 138; Journ. Complément, iii. p. 291; Dub. Med. Journ., viii. p. 493; Cooper on Frac. and Disloc., fourth London ed., p. 508; Recherch. sur les Formation du Cal, 1819, p. 34. (Norris, loc. cit.)

³ Dict. de Méd. et Chir. Prat., iii. p. 492; Journ. de Méd. Chir. et Pharm., t. xxv. p. 216. (Norris, loc. cit.)

⁴ Exposé des symp. de la mal. Vén., p. 525; Oppenheim on False Joints, 1837. (Norris, loc. cit.)

⁵ Op. cit., p. 21.

Werner, Hildanus, Wilson, Hertodius, Alanson, Bard, of New York, and Condie, of Philadelphia,¹ have all reported examples, in some of which the process of union was resumed and brought to a rapid completion as soon as the period of pregnancy was closed, or when lactation ceased; but three cases reported by Sir Stephen Love Hammick would seem to show, what, indeed, other evidences render probable, that the delay was less due to the fact of the pregnancy and the lactation than to the debility occasionally consequent upon these conditions.²

As to the question whether *cancer* ever causes a delay in the union of bones, it may be said that where the fracture arises in consequence of a true cancerous deposit around or in the interior of the bones, producing absorption of their tissue, no union takes place; but that the mere presence of the cancerous cachexy does not usually prevent the formation of callus.

Scurvy, *fevers* of a low type, and, on the other hand, fevers of a highly inflammatory character, profuse uterine and vaginal discharges, and rhachitis, conduce to the same result.

The withdrawal of an *habitual stimulus*, and especially a change from a good to a low diet, or copious bleedings, may either of them delay the deposit of ossific matter, or prevent it altogether.³

Bonn has furnished two cases in which *advanced age* seemed to have retarded the formation of callus, but Horner saw a fracture of the humerus in a woman ninety years old unite in five weeks.⁴ I myself have noticed a good many similar examples in advanced life, and it is now rendered quite probable that surgeons have generally over-estimated the influence of old age upon the formation of callus.

The *local causes* are, arrest of the arterial circulation by bandages; arrest of the venous circulation by pressure, by rupture of veins, or by the formation of venous clots;⁵ paralysis or impairment of the nervous circulation; the occurrence of the fracture within a capsule; obliquity of the fracture; overlapping of the fragments; interposition of a piece of bone, of a tendon, muscle, or of a clot of blood, or separation of the fragments from any cause whatever; erysipelas; acute phlegmonous inflammation; suppuration; necrosis; too much motion; exclusion of light and air inducing local scurvy; wet, and especially cold and moist dressings; too early use of the limb, etc.

Treatment.—In order to hasten the consolidation when it is simply delayed, we resort to all of those expedients which are calculated to invigorate the general system; and for this purpose the employment of a nutritious diet and the use of mineral or vegetable tonics may not be properly omitted; but in our experience nothing has proved so efficient as encouraging the patient to leave his bed and get out into the open air; for which purpose, if the fracture is in the lower extremities, crutches will be necessary.

As local means, we may enumerate first the removal of those local

¹ Cooper's Diet., ed. 1838, p. 546; Opera Hild., 1681; Wilson on the Human Skeleton, p. 214; Bib. Choise de Méd., xxiv. p. 595; Med. Obs. and Inquiries, 4, 1772.

² Practical Remarks on Amputations, Fractures, etc., p. 121. (Norris, loc. cit.)

³ Norris, loc. cit.

⁴ Ibid., p. 29.

⁵ George W. Callender, Brit. Med. Journ., Nov. 30, 1872.

causes which seem to have interfered with the consolidation or with the union. If the fragments have been officiously disturbed, it may be sufficient to impose upon the limb absolute rest for a certain length of time; and the fragments may be more closely pressed against each other; in other cases it will be found necessary to remove the bandages, expose the limb freely to the light and air at least once or twice daily, and to rub it gently with the dry hand or with some moderately stimulating oil, so as to induce a more healthy condition of the soft parts, and encourage the natural circulation. Moving the fragments freely upon each other, sufficient to determine a degree of excitement in the adjacent tissues, and upon the opposing surfaces of the bones, and then confining them during one or two weeks in firm and well-fitting splints, will sometimes succeed when other means have failed.

Indeed, I may say that by one or another of the simple methods now enumerated I have never failed, sooner or later, to effect consolidation in recent fractures; and it has only been in fractures of at least four, six, or eight months' standing that I have been compelled to resort to more extreme measures. As a means of combining immobility with compression and healthful exercise, the *apparatus immobile* in many of its forms, is peculiarly adapted. White, of Manchester, employed a firm leather sheath for the thigh. H. H. Smith, of Philadelphia,¹ recommends a more complex artificial support, upon which the limb may be allowed to rest while in the act of progression. With some surgeons, the object of allowing the patient to walk, in fractures of the thigh or leg, is chiefly to excite in the tissues adjacent to the seat of fracture some degree of inflammatory action; but which, as the result in one of White's patients has sufficiently shown, may be carried too far, and even determine suppuration.

Dr. E. D. Hudson, artificial limb maker, of New York, has applied in similar cases, which have come under my observation, an apparatus of his own construction, made of willow, and secured in place by leather straps. In case the purpose of the apparatus is to encourage bony union, no motion is allowed at the knee-joint.

Recently, also, Tiemann and Stollman have adapted to one of my patients successfully an apparatus of their own construction. This was a case of ununited fracture of the femur, of long standing, and in which I had succeeded by the use of Brainard's drills, the gimlet, and other operative procedures, in securing a very close and firm fibrous union. The fibrous band became finally converted into bone, after the lapse of a few months, while walking with crutches, the limb being supported by Mr. Tiemann's very ingenious apparatus.

Blisters, mustard cataplasms, the tincture of iodine,² caustics,³ etc., applied externally over the seat of fracture, can have no other effect than to increase moderately the congestion of the tissues, and in so far they may aid in the accomplishment of the bony union; but in this respect they are inferior to the violent twistings, flexions, and rubbings of the broken ends of which we have already spoken.

Electricity was first employed by Mr. Birch, of London, but Dr. Valentine Mott obtained no effect from it in two cases in which he seems to have given it a fair trial.⁴ Lente, of the New York Hospital, has furnished an account of three cases treated in that institution by electricity in connection with acupuncture; the mode of using which was to pass a needle down to the periosteum on each side of the bone, and to attach the poles of the battery to these opposite points. Lente thinks that electricity employed in this way is much more efficient than when the poles are merely applied to the surface. He informs us,

¹ H. H. Smith, Amer. Journ. Med. Sci., Jan. 1855, Jan. 1876.

² Hartshorne, Eclectic Rep., vol. iii. p. 114, 1813.

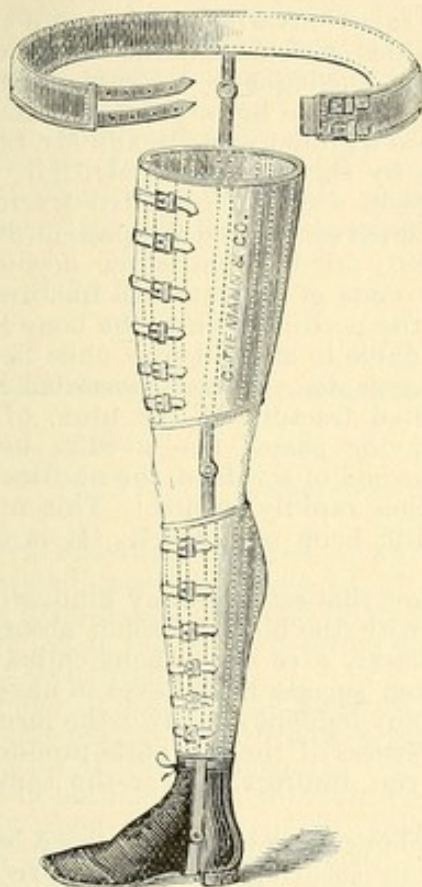
³ Willoughby, Amer. Journ. Med. Sci., Aug. 1834, p. 444.

⁴ Mott, Med. and Surg. Rep., pp. 21, 375.

also, that other cases than these now reported have been treated successfully in this hospital by means of electricity.¹

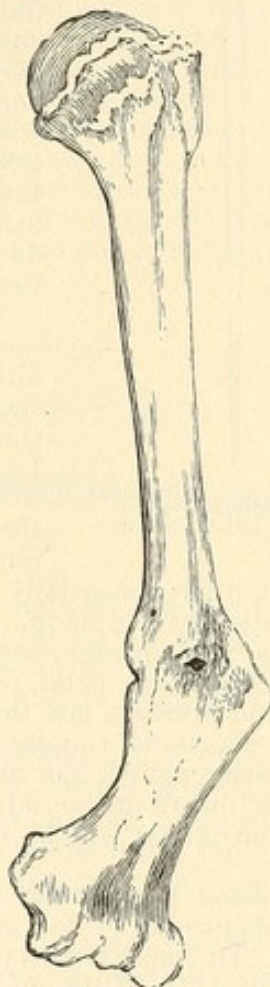Mercury will no doubt prove serviceable occasionally by virtue of its powers as an anti-syphilitic, but its beneficial influence in other cases is far from having been established.

FIG. 24.



Tiemann & Co.'s apparatus for ununited fracture of the femur.

FIG. 25.



Physick's first case, after 28 years.
(From Amer. Journ. Med. Sci.)

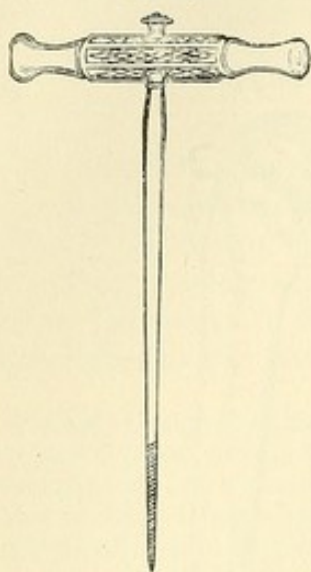
The *seton* is said to have been first suggested by Winslow, in 1787; but, what is of much more consequence, the credit of its first successful application and its general introduction into practice is due to Dr. Philip Syng Physick, of Philadelphia, by whom it was employed in 1802.² Physick used for his seton, generally, silk ribbon or French tape; and this he introduced, by means of a long seton needle, between the ends of the fragments. He recommended that the seton should remain in place four or five months, and longer if necessary, and it was his opinion that the failures were generally due to its being removed too early. At the present day, however, surgeons who employ the seton think it serves its purpose better when it remains in place but a few days, not longer, perhaps, than ten or fifteen, always taking care that it is removed before excessive suppuration is induced. It has been found especially valuable in fractures of the inferior maxilla, clavicle, and of the upper extremities; but in the case of the femur it has so frequently failed, that Dr. Physick himself did not recommend its use.

¹ Lente, New York Journ. Med., Nov. 1850, p. 317.

² Physick, Med. Repository of New York, vol. i., 1804.

In case the seton cannot be passed directly between the opposing fragments, as recommended by Physick, we may adopt the practice suggested by Oppenheim, and carry two setons, one on each side, close to the bone.

FIG. 26.



Dieffenbach's drill for ununited fracture.

Sommé, of Antwerp, preferred a loop of wire to the silk seton employed by Physick.¹ Seerig passed a ligature around the ligamentous mass connecting the two fragments, and then proceeded to tighten the ligature until it fell off.² Dr. Hulse, of the U. S. Navy, employed stimulating injections with success in a case of non-union, accompanied with an external and fistulous opening.³ In 1848, Dieffenbach recommended that *ivory pegs* be introduced into holes previously made in the bone⁴ by means of a gimlet or drill, and Mr. Stanley has succeeded once by this method.⁵ Mr. Hill introduced the ivory pegs in a case of ununited fracture of the femur, pyæmia supervened, and the patient died.⁶

Malgaigne, in 1837, tried to introduce *acupuncture needles* between the ends of an ununited fracture, but, although he thrust the needle down to the bone thirty-six times, he was unable to make it pass once between the ends of the fragments. Wiesel succeeded better. In a case of ununited fracture of the ulna, of nine weeks' standing, having passed two needles between the fragments, at the end of six days, the needles being removed, consolidation rapidly ensued.⁷ This practice

does not differ essentially from the metallic hoop of Sommé. It is only a modification of the seton.

Brainard, of Chicago, has attempted to show that setons of any kind, whether of wood, ivory, or metal, placed in contact with the bone, occasion absorption, caries, and necrosis, but that they never directly give rise to bony callus; and that the occasional success of the seton, which success he believes to have been greatly exaggerated, has not resulted from any tendency to favor the formation of callus, but from the induration and tenderness of the soft parts produced by it; circumstances which, by conducing to rest, indirectly favor the consolidation.⁸

[The seton, as a remedy for non-union of bones, has been superseded by anti-septic operations of far greater certainty in securing union, and free from danger. The most important of these operations is the wiring of the fragments.]

In May, 1848, Miller, of Edinburgh, reported five cases treated successfully by *subcutaneous puncture*. The operation consisted in passing the point of a needle or small tenotomy bistoury down upon the ends of the bone, and freely irritating the surfaces at several points.⁹ George F. Sanford, of Davenport, Iowa, has successfully imitated this practice in two cases.¹⁰

In 1850 Dr. William Detmold, of New York, performed the operation of *drilling* or perforating the fragments in a case of ununited fracture of the tibia, employing for this purpose a large gimlet. He first bored two holes between the opposing fragments, and then, introducing the gimlet one and a half inch below the fracture, he penetrated the tibia upward and inward until he had traversed, also, the upper fragment to the extent of an inch. In three weeks the bone appeared firm, but from this time the patient was not seen.¹¹

¹ Amer. Journ. Med. Sci., vol. vii. p. 497.

² Norris, loc. cit., p. 46.

³ Hulse, Amer. Journ. Med. Sci., vol. xiii. p. 374.

⁴ Malgaigne, trans. by Packard, op. cit., p. 258, note.

⁵ Stanley, New York Journ. Med., Nov. 1854, p. 441, from Dublin Press.

⁶ New York Med. Gaz., July 4, 1868, from the London Lancet.

⁷ Wiesel, Amer. Journ. Med. Sci., vol. xxxiv. p. 254, July, 1844.

⁸ Brainard, Trans. Amer. Med. Assoc., vol. vii., 1854; Prize Essay. Report on Surgery to Illinois State Med. Soc., May, 1860.

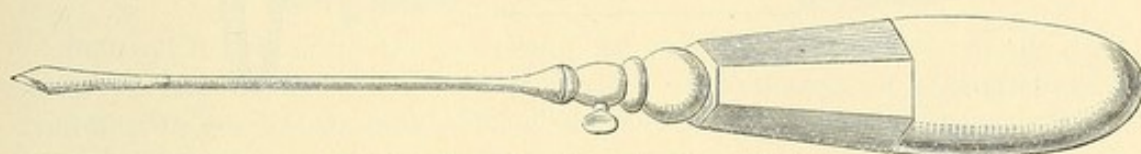
⁹ Miller, New York Journ. Med., July, 1848, p. 134.

¹⁰ Sanford, Trans. Amer. Med. Assoc., vol. iii. p. 355, 1850.

¹¹ New York Med. Gazette, Oct. 12, 1850.

Brainard employs for this same purpose a strong metallic perforator, consisting of a handle, into which points of different sizes may be inserted, and which have been hardened so as to penetrate the hardest bone or even ivory in every direction easily. The points are "somewhat awl-shaped; but more pointed in the middle rather than like a drill, which leaves chips." His manner of using this instrument is as follows: "In case of an oblique fracture, or one with overlapping, the skin is perforated with the instrument at such a point as to enable it to be carried through the ends of the fragments, to wound their surfaces, and to transfix whatever tissue may be placed between them. After having transfixed them in one direction, it is withdrawn from the bone, but not from the skin, its direction changed, and another perforation made, and this operation is repeated as often as may be desired." Dr. Brainard, who succeeded by this procedure in a number of cases of ununited fracture, thinks it better to commence in most cases with not more than two or three perforations, in order that the effect produced shall not be too severe. It is scarcely necessary to add that, after the punctures have been made, the limb should be put completely at rest in appropriate splints, or in apparatus of some kind.

FIG. 27.



Brainard's perforator, reduced one-half.

I have recently employed, as an addition to the surgical procedures above enumerated, *common shawl-pins*, of steel, about four or six inches in length, having glass heads. Several of these are thrust between the ends of the bone, and are left in place seven or ten days; to be inserted again from time to time as may seem desirable.

Scraping or rasping the ends of the bones is a practice which dates from a very early period. Mr. Brodie scraped the ends of the bones, and then interposed a bit of lint.¹ Mayor, in 1828, contrived to introduce an iron, previously heated in boiling water, through a canula, and thus brought the heat to bear directly upon the ends of the fragments; and, by repeating the application several times, a cure was effected.²

Resection of the ends of the bones, first brought into notice by White, of Manchester, in 1760,³ and opposed by Brodie⁴ as dangerous, and by Malgaigne regarded as generally useless or unnecessary, has still been practised a great number of times, with more or less success. It is especially applicable to superficial bones, and in cases where the bones overlap. Its value is now sufficiently demonstrated, except, perhaps, in the case of the femur. Roux practised resection in one instance, and then managed to engage the point of one of the fragments in the medullary canal of the other. I have succeeded in doing the same.

White, of Manchester, Henry Cline, of London, Hewson, Barton, and Norris,⁵ of Philadelphia, have applied *caustics* directly to the ends of the fragments, after having exposed them by a free incision.⁶ Petit applied the actual cautery.⁷

Tying the fragments together by means of *metallic ligatures* after a recent fracture is as old as the days of Hippocrates; but in 1805 Horeau adopted the same procedure in a case of ununited fracture;⁸ since which date it has been practised successfully by many surgeons. My own experience confirms the value of the method, especially when the fragments overlap.

E. S. Gaillard, of Louisville, Ky., proposes to secure the fragments in place by means of a *metallic pin*. The instrument which he employs is composed of a

¹ Brodie, Lond. Med. Gaz., July, 1834.

² Dict. de Méd., vol. xxiii. p. 503.

³ Brodie, New York Journ., vol. viii. 1st ser., p. 133.

⁴ Norris, loc. cit., p. 49.

⁵ Norris, loc. cit., p. 49.

⁶ Norris, loc. cit., p. 48.

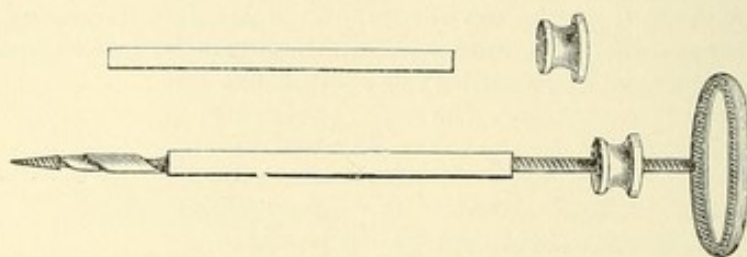
⁷ Ibid.

⁸ Ibid.

steel shaft with a handle, a silver sheath, and a brass nut. For a broken femur the shaft is six inches long, its lower extremity being constructed like a gimlet, while two and a half inches of its upper extremity are cut for a male screw, being intended to carry the brass nut. The sheath is three inches long. Through an incision made over the seat of fracture, the sheath, detached from the shaft, is carried down to the bone. The shaft is then passed through the sheath, and made to penetrate and transfix the two fragments; as soon as this is accomplished, the nut is turned down firmly upon the top of the sheath, and apposition of the fragments is thus secured. The whole instrument is permitted to remain until bony union is effected.¹

Fitzgerald, of Melbourne, has practised successfully the injection of five to ten

FIG. 28.



Gaillard's instrument for ununited fractures.

minims of *glacial acetic acid* between the fragments. It causes at first a sharp pain, and he thinks it accomplishes its beneficial results by causing a resolution and absorption of the interposed fibrinous, cartilaginous materials and encouraging the substitution of bone.²

Finally, having thus brought rapidly before us all of the various modes of treatment which have been suggested and practised for non-union of broken bones, we are prepared to affirm the following conclusions, or summary of what has been our own practice, and of what we believe ought to be the general course of procedure in these cases:

1. Improve the condition of the general system.
2. Remove as far as possible the local impediments, such as a separation of the fragments, local paralysis, local scurvy resulting from long exclusion from light and air, congestions, etc.
3. Increase the action of the tissues immediately adjacent to the fracture, upon which tissues, rather than upon the bone, the formation of callus depends. This may be accomplished by frictions, and violent flexions of the limb at the seat of fracture: possibly in some measure by the application of vesicants or of other stimulants to the skin itself.
4. Employ again compression and rest for a period of from two to four or eight weeks.
5. Resort to the method recommended by Brainard, or to some of its modifications, to interfragmentary injections, etc.
6. If in the lower extremity, allow the patient to walk about with the fragments well supported.
- [7. If simple measures fail, resort to the operation of wiring the fragments, with antiseptic precautions.]

Where these measures have failed, after a fair trial, we should cease to hope for success from operative measures, and subsequently rely only

¹ E. S. Gaillard, New York Journ. Med., Nov. 1865.

² Boston Med. and Surg. Journ., Aug. 15, 1878, from Medical Press and Circular.

upon retentive apparatus, under the continued use of which consolidation is sometimes effected.

More precise rules of procedure will be given hereafter in connection with the various fractures.

CHAPTER VIII.

INCOMPLETE FRACTURES.

BENDING, PARTIAL FRACTURES, AND FISSURES OF THE LONG BONES.

§ 1. Bending of the Long Bones.

STRICTLY speaking, no bone can be much bent without being also more or less broken, and that whether it immediately or spontaneously resumes its position or not; for, if the bending and straightening of the bone be repeated a sufficient number of times, the yielding of the fibres will become apparent, and at length the separation will be complete. The first of this series of flexions was quite as much responsible for this result as the last, and, no doubt, performed its share in the production of the complete fracture. There could be no impropriety, therefore, in speaking of a bending of the bones as a variety of incomplete fractures. They have been called, not inappropriately, *interperiosteal fractures*, since in these cases the periosteum is not broken.

M. Blandin thinks that the outer and semicartilaginous laminæ of the bone also do not break, while the deeper laminæ suffer an actual disruption.¹ But it is quite as probable that in a majority of cases the true pathological condition is a compression of the bony fibres upon one side, and a corresponding expansion upon the opposite side, with only a slight interstitial fracture, too trivial to be easily recognized even in the dissection. Sometimes, as I have several times observed in my experiments on the bones of chickens, when the bones are small, and the bending is near the centre of the shaft, the whole of the laminæ on the side of the retiring angle produced by the bending are doubled in, or indented toward the hollow of the bone, so that the fibres on the side of the salient angle are not even stretched, and much less broken. In such cases the interstitial disruption, if it exist at all—and I think it does—first takes place in the deeper layers of the retiring angle. I might, therefore, feel justified in continuing to call these cases partial fractures, or, perhaps, interstitial fractures; but I believe that the whole subject will be rendered more intelligible if I call them simply bending of the bones, as distinguished from those other and more palpably partial fractures of which I shall speak presently.

Bending, with an Immediate and Spontaneous Restoration of the Bone to its Original Form.

The possibility of this accident, to which, however, surgical writers have hitherto made no distinct allusion, is rendered certain by the following experiments:

¹ Markham's Obs. on the Surg. Practice of Paris, London Med.-Chir. Rev., vol. xxxiv. p. 473, 1841.

EXPERIMENT I.—July 16, 1857. I bent the tibia of a Shanghai chicken, four weeks old, at about the middle of the bone. It was bent to an angle of quite twenty-five degrees, but it was not felt or heard to break. It immediately and spontaneously resumed the straight position. July 18, two days after the bending, I dissected the limb, and found no trace of the injury, either within or without the bone, unless I except a very minute blood-clot in the centre of the shaft.

EXPERIMENT II.—I bent the leg of a chicken, four weeks old, at the same point and to the same degree. It immediately resumed the straight position. *Dissection after two days:* Nothing abnormal except a small blood-clot in the centre of the bone, and a slight disorganization of the medulla.

EXPERIMENTS III. AND IV.—Bent both legs of a chicken, four weeks old, at the same point and in the same manner. They immediately resumed their positions. *Dissection after two days:* No lesions or morbid appearances which I could detect.

EXPERIMENTS V. AND VI.—Bent both wings of a chicken four weeks old, bent the right wing to an angle of thirty-five degrees. I did not feel them break. Both resumed their positions spontaneously. *Dissection after two days:* No lesions or other morbid appearances.

EXPERIMENT VII.—July 16, 1857, I bent the leg of a Shanghai chicken, five weeks old, below the knee and about the middle of the bone. It was bent to an angle of about twenty-five degrees, but the bone was not felt or heard to break. It immediately and spontaneously resumed the straight position. July 20, four days after the bending, I dissected the leg, but could not discover any trace of the injury, except that there was a very minute ossific deposit in the centre of the bone at the point at which I suppose it to have been bent.

EXPERIMENT VIII.—July 16, 1857, I bent the right leg of a Shanghai chicken, five weeks old, at the same point as in the first experiment, and to the same extent. The bone did not seem to break, but it immediately and spontaneously resumed the straight position. *Dissection after four days:* Nothing appeared to indicate the seat of the bending, except a small clot of blood in the centre of the shaft.

EXPERIMENT IX.—Bent the leg of a chicken, six weeks old, in the same manner and to the same degree as in the other examples. It resumed its position spontaneously. *Dissection after ten days:* No evidence of injury of any kind; the bone being sound and straight.

These experiments were made in connection with others to which more especial reference will hereafter be made. They are selected, and constitute the whole number of those in which I did not feel the bone break or crack under my fingers. In every instance the bone sprung back immediately and spontaneously to its natural form. In no instance could I afterward discover any trace of lesion or sign indicating the point at which the bone had been bent before dissection, nor did dissection itself disclose anything but the most inconsiderable marks, and that in but three examples.

I infer, therefore, not forgetting the caution with which the conclusions from all such experiments ought to be applied to similar accidents upon the human skeleton, that whenever the bones of healthy infants have been slightly bent and not broken, they will, probably, in most cases, unless prevented by causes foreign to the bones themselves, spontaneously and immediately resume their position, and that no sign will remain to indicate that a bending has occurred. The accident will not be recognized, and, as a further inference, this bending does not belong to that class of cases of which I shall next speak.

Bending, without Immediate and Spontaneous Restoration of the Bone to its Original Form.

“Dethleef, believing that he had broken the two bones of the legs of a dog, found the fibula bent without a fracture. Similar results were

obtained by Duhamel upon a lamb; by Troja upon a pigeon; and I have myself twice succeeded in bending the fibula while breaking the tibia. The possibility of simple curvature is then not contestable" (the writer means to say that the possibility of a simple curvature *remaining permanently* bent is not contestable), "but we must observe that they have never been obtained except upon young animals, and that they have been unable to maintain themselves permanently except through the aid of a fracture and displacement of a neighboring bone; and there is a wide difference between these and those pretended curvatures which some believe they have seen in man, in which the curved bone maintains itself, and resists perfect reduction until the fracture is complete."¹

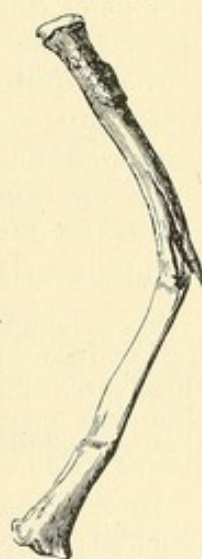
In this single paragraph Malgaigne seems to have given a fair summary of the testimony upon this point. With the exception of these and a few other similar examples, some of which I think I have observed myself, where one of the bones of the forearm has been broken and the other bent, I know of no well-attested cases of a permanent bending; using the term bending in a sense distinguished from a partial fracture.

If, in numerous cases mentioned by surgical writers, there has seemed to be probable evidence that the permanent bending was unaccompanied with fracture, there has always been wanting, so far as I know, the positive evidence of dissection. The example of partial fracture mentioned by Fergusson, and represented by a drawing, is described as having also, "toward the lower extremity, a slight indentation and curve."² This was the radius of a child; but how long the child survived the accident, and what was the condition of the ulna, we are not informed. The observations made by Jurine, of Geneva, in Switzerland,³ by Barton⁴ and Norris,⁵ of Philadelphia, all fail to furnish any such conclusive evidence of the correctness of their own views. Norris says that "Thierry, of Bordeaux, Martin, and Chevalier, had all met with and published cases of this kind prior to the appearance of Jurine's paper (in 1810), the former of whom asserts that Haller, in experimenting upon the subject, had been able satisfactorily to produce the same accident in young animals." For myself, I cannot say how much confidence we ought to place in these assertions of Thierry, Martin, and Chevalier, having never seen the papers referred to; but since Dr. Norris has neglected to inform us whether any dissections were ever made, we shall not be expected to regard their testimony as conclusive.

With the qualifications now made, Gibson was more nearly right when he said, "Dupuytren and Dr. John Rhea Barton have each furnished accounts of *bent* bones. There are no such injuries, however, in my opinion; such cases being, in reality, *partial* fractures from which deformities result, upon the same principle that a piece of tough wood, like oak or hickory, if broken half through, may be inclined to one side and shortened, although still held together by interlocking of fibres. Many specimens in my cabinet, and in the Wistar Museum, attest the accuracy of this assertion."

In my own experiments upon the chicken, the bones uniformly resumed their original position as soon as the restraining force was

FIG. 29.

Case mentioned
by Fergusson.

¹ Traité des Frac., etc., par L. F. Malgaigne, tom. i. p. 48.

² Practical Surgery, by William Fergusson, 4th Am. ed., p. 208.

³ Journ. de Corvisart et Boyer, tom. xx. p. 278. etc.

⁴ Phila. Med. Recorder, 1821.

⁵ Phila. Med. Journ., vol. xxix. p. 233, 1842.

removed, unless a fracture occurred, and this notwithstanding the bones were bent quite abruptly and to an angle of twenty-five degrees. Certainly, if the bones of children may be bent during life and be made to retain this position without a fracture, then the same thing might be done upon the bones of children recently dead, and, by successful experiments, this long-agitated question might be easily and forever put to rest.

It will be understood that our observations are confined to the long bones. That the flat bones, and especially the bones of the cranium, in childhood, may be indented by blows, and remain in this condition, is undeniable. Scultetus says he had seen "the skull pressed down in children, without a fracture, so that those who touch or look upon it can perceive a small pit," and it has been mentioned by many writers since, and perhaps before his day. I have myself published two examples.

§ 2. Partial Fracture of the Long Bones.

Partial Fracture with Immediate and Spontaneous Restoration of the Bone to its Original Form.

I have not noticed this variety of accident in any other bone except the clavicle, yet it is not improbable that it happens occasionally, and perhaps quite as often, in other long bones, but that its existence is not elsewhere so easily recognized. According to Poinso, M. Demons has seen a similar case in the humerus of a newly born infant.

Of one hundred and fifty-seven fractures of the clavicle recorded by me, thirty-four were partial fractures; and of these at least eleven were spontaneously and immediately restored to their natural axes.

In explanation of the fact that hospital surgeons have not observed so large a proportion of partial fractures of the clavicle, it must be stated that most of these cases of partial fracture were drawn from private practice. Accidents of this class may be often met with in private practice and in dispensaries, but they are seldom found in hospitals.

In fourteen experiments which I have made upon the bones of chickens, a partial fracture, with immediate and spontaneous restoration, has occurred but once. In nine of these cases the bones were only bent, and in five they were partially broken; an immediate restoration has occurred, therefore, in one case out of five of partial fractures; while in my recorded examples of partial fracture of the clavicle it has been noticed about once in every four or five cases. The following is the experiment to which I have referred:

I produced a partial fracture of the tibia in a chicken six weeks old. The fracture was near the middle of the bone. It was felt to break under my finger; but, on removing the pressure, it immediately and spontaneously resumed the straight position. The limb was dissected on the tenth day. The line of the axis of the bone was perfect, but on the fractured side was a node-like enlargement, sufficient to be distinctly felt and seen before the soft parts were removed.

Pathology.—In no case, except in my single experiment upon the bone of a chicken, has the actual condition been determined by dissection, and if any question has existed heretofore as to the possibility of an immediate and spontaneous restoration after a partial fracture, this experiment ought to decide it in the affirmative; but then the first nine experiments already quoted have shown that a mere bending with immediate restoration leaves no such traces or signs as have been described as following these accidents. We have, therefore, the negative argument that, since a bending with restoration leaves no signs, the examples, reported by myself and others as having occurred, and as having been followed by a node-like swelling, etc., must have been partial fractures. Moreover, in one of the cases of immediate restoration reported by Blandin, there was a feeble crepitus; and in another, the subsequent displacement proved the correctness of his diagnosis. The same has been noticed by myself in several examples.

No writer seems to have given any special attention to the form of fracture now under consideration, although its existence appears to have been occasionally recognized. In the case reported by Camper, in 1765, of a partial fracture of the tibia, the bone had regained its natural form, but whether immediately after the accident occurred, or at a later period, I am not able to learn.¹ Jurine, Gulliver, and others, have noticed a gradual straightening of the bone after a partial fracture, so that its complete restoration has been accomplished after several weeks or months; but this, although partly due to the same cause which produces occasionally an immediate restoration, namely, its elasticity, is in part also due to other causes, and will be more properly considered under the next division of partial fractures.

Says Malgaigne: "Finally, at other times the fracture takes place without opening and without curvature; the only sign which one can recognize is a yielding of the bone under the pressure of the finger at the point of fracture; yet upon the living subject we may see the same symptom pertain to complete and simple fractures without displacement."²

In the following report of one of M. Blandin's clinics the accident is described a little more distinctly: "In some cases of fracture of the clavicle occurring about the middle of the bone in young subjects, displacement of the fragments does not immediately take place, thus giving rise to a risk of an error in diagnosis, by which the ultimate probability of a cure is diminished. A lad, seventeen years of age, was recently admitted into the Hôtel Dieu, under the care of M. Blandin, having, a few days previously, fallen upon one of his comrades while playing with him, when he instantly experienced pain and a cracking sensation about the middle of the left clavicle, where there soon formed a tumor, which, increasing, induced him to enter the hospital. On examination, the swelling was found to occupy the middle of the clavicle; it was about as large as half a hen's-egg, ovoid in shape, well circumscribed, colorless, and hard, but sensible to pressure. There was not any deformity of the shoulders, nor any abnormal modification of the axis of the bone, to indicate the existence of a fracture; and although the different movements of the arm caused pain in the shoulder, yet they could be made without much difficulty.

"The symptoms in this case would lead to the belief that it was a case of simple periostitis, caused by external violence; but M. Blandin at once decided that there existed a fracture of the bone, having seen a similar case previously at the Hôpital Beaujon, where the tumor was treated as traumatic periostitis, the patient merely carrying his arm in a sling, until, by a sudden movement of the limb, displacement of the fragments was produced, and clearly demonstrated the existence of a fracture. A second case occurring soon afterward, M. Blandin profited by the experience gained from the preceding, and by moving the frag-

¹ Essays and Obs. Phys. and Lit. of Soc. of Edinburgh, vol. iii. p. 527.

² Op. cit., tom. i. p. 70.

ments of the broken clavicle on each other, obtained motion and crepitus. Still these indications were not so clear that M. Marjolin could diagnosticate a fracture; he was of opinion that the case was one of exostosis, probably syphilitic, and the crepitus, he believed, depended on an erosion of the osseous surface. In consequence, the patient was left to himself, until a movement of the arm gave proof of the fracture by the displacement of the broken portions of the bones.

"Two other cases occurring in young subjects have been admitted since in the Hôtel Dieu, under the care of M. Blandin, one of whom was purposely left without surgical assistance, while Desault's bandage was applied to the other. The former soon showed evidence of consecutive displacement; the latter was cured without any deformity following. The surgeon may diagnosticate a fracture without displacement of the middle portion of the clavicle, when a circumscribed tumor forms in that part of young subjects, consecutive on a fall on the shoulder, and motion of the fragments, with crepitus, can be detected, there not being any syphilitic taint in the constitution."¹

The following examples, which have come under my own observation, will illustrate more completely the usual history and symptoms of these cases:

A. B., aged three years, fell from a sofa upon the floor, striking, it is thought, on her right shoulder. Two days after this, she fell again, and then, for the first time, Mr. B. noticed the deformity. She was brought to me three days after the second fall. There existed, then, a round, smooth projection at the outer end of the middle third of the clavicle. It felt hard, like bone. The line of the clavicle was not changed. I advised a handkerchief sling, simply to steady and support the arm. Seven months after the accident, she fell sick and died. The projection continued at the time of death, only slightly diminished.

H. S., aged six years, was thrown from a horse, partially breaking his left clavicle, near its middle. The projection in front was for several days very apparent. The bone did not seem to be out of line. Five years after the accident, I examined the lad, and could not find any trace of the original injury.

Mrs. T. C. brought to me her infant child, then but two weeks old. Upon the left clavicle, at a point a little nearer the acromion process than the sternum, was an oblong swelling, three-quarters of an inch in length, smooth and hard like callus; the skin was not reddened, nor tender. There was no motion or crepitus, and the line of the axis of the bone was perfect. The mother, who had been put to bed by a midwife, thinks the injury occurred in the act of birth, although she did not notice the swelling until a week after. Nearly one month later, I found no change in the condition of the bone; the hard lump remained, but it was still entirely free from tenderness.

An infant boy, three years old, fell from the hands of the nurse. The child cried, but the point of injury was not detected until the third or fourth day, although the mother examined the shoulders and neck carefully at the time. She is quite certain that if any swelling or discoloration had been present, she would have seen it then, or on the subsequent days, while washing and dressing the child. When first seen it was very distinct, but not so large as at present. Seven days later the child was brought to me. A little to the sternal side of the middle of the right clavicle there was an oblong node-like swelling, of the size of the half of a pigeon's egg, hard, smooth, and feeling like bone; there was no discoloration or swelling of the integuments; no crepitus or motion; the line of the clavicle seemed nearly or quite unchanged.

Diagnosis.—The diagnosis will depend somewhat upon the history of the accident as well as upon the present symptoms. In no instance, where I could ascertain the cause, have I known an incomplete fracture of this variety produced by any other than an indirect blow; and where the clavicle has been the seat of the fracture, the counter-blow has been received upon the end of the shoulder. The fact possesses, therefore,

¹ Amer. Journ. Med. Sci., vol. xxxi. p. 473, from Journ. de Méd. et Chirurg. Prat. July, 1842.

equal significance in its relation to either of the varieties of partial fracture; but in the case of a partial fracture with a permanent curvature, the diagnosis would be complete without the history, while in this case it might not be, and a knowledge of the manner in which the accident occurred would, therefore, be of great importance. The signs, then, after a knowledge of the fact that a blow has been received upon the shoulder, are a node-like swelling upon the anterior or upper face of the clavicle, generally in its middle third, this swelling being hard, smooth, oblong; the skin only slightly or not at all swollen or tender, and in no way discolored, as it would have been had the swelling upon the bone been the result of a direct blow; and the line of the axis of the bone being unchanged.

I have occasionally detected motion and crepitus at the point of injury, and we have seen that Blandin was able to detect both in one instance; but it has never occurred to me to see the swelling upon the bone until two or three days after the injury was received. We are not very likely, therefore, to recognize this accident immediately after its occurrence.

Treatment.—In the case of the clavicle, neither bandages, slings, compresses, nor lotions can be of much service. Yet no harm can arise from employing a simple sling and roller to confine the arm; and it is always proper to enjoin some degree of care in using the arm of the injured side. The consolidation will be speedily accomplished, and after a time the ensheathing callus will wholly disappear. If a similar accident should occur in any other of the long bones, as retentive and precautionary means, splints ought to be applied, at least for a few days.

Partial Fracture, without Immediate and Spontaneous Restoration of the Bone to its Natural Form.

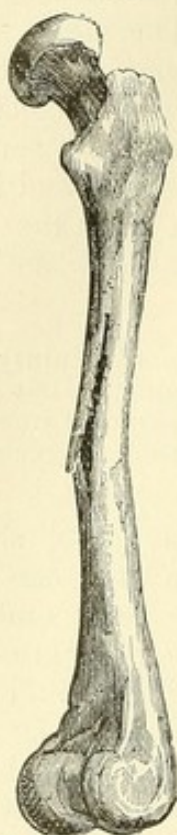
The causes of this accident are the same as those which produce simple bending, or partial fracture with immediate and spontaneous restoration, from which latter they differ probably in the greater extent of the bony lesion. Perhaps, also, they differ sometimes in the peculiar form and degree of the denticulation at the seat of the fracture; in consequence of which an antagonism of the fibres takes place, preventing a restoration of the bone to its original form.

Very few surgeons have spoken of partial fracture in the clavicle, while Jurine, Syme, Liston, Miller, Norris, and many others, have declared that it is much more frequent in the bones of the forearm than elsewhere. This does not agree with my experience, according to which it occurs oftener in the clavicle than in the forearm; a discrepancy which I cannot very well explain, except by supposing that in the case of the clavicle the accident has either been overlooked entirely or misapprehended. Blandin, who, we have seen, has reported five cases of partial fracture of the clavicle with immediate restoration, states distinctly that in two of these cases distinguished surgeons of the Hôpital Beaujon and Hôtel Dieu failed to recognize it.

Says Turner: "The next I shall descend to is that of the clavicle or collar-bone, which I have found the most frequently overlooked, I think, of any other, till it has been sometimes too late to remedy, especially among the children of poor people; for, though they find these little ones to wince, scream, or cry, upon the taking off or putting on their clothes, yet, seeing that they suffer the handling of their wrists and arms, though it be with pain, they suspect only

some sprain or wrench, that will go away of itself, without regarding anything further or looking out for help; whereas, this fracture discovers itself as easily

FIG. 30.



Partial fracture without restoration of the bone to its natural form.

FIG. 31.



Partial fracture of the clavicle without spontaneous restoration. From nature; taken three weeks after the accident.

as most others. For not only the eye, in examining or taking a view of the part, may plainly perceive a bunching out or protuberance of the bones when the neck is bared for that purpose, with a sinking down in the middle or on one side thereof, which will be still more obvious on comparing it with its fellow on the other side; but when it is more obscure, and the bone, as it were, cracked only—a *semi-fracture*, as we say—yet, by pressing hard upon the part, from one extremity to the other, you will find your patient crying out when you come upon the place; and by your fingers, so examining, sometimes perceive a sinking further down, with a crackling of the bone itself.”¹

Erichsen, who regards all of these cases as mere bendings of the bones, remarks that it “most commonly occurs in the long bones, especially the clavicle, the radius, and the femur.”² He says, moreover, “Fracture of the clavicle in infants not unfrequently occurs, and is apt to be overlooked. The child cries and suffers pain whenever the arm is moved. On examination, an irregularity, with some protuberance, will be felt about the centre of the bone.”³ The reader will not fail to recognize in these symptoms the incomplete fracture of which we are now speaking, although Erichsen evidently believes them to be examples of complete fracture.

Pathology.—The following experiment will assist in the elucidation of this part of our subject :

EXPERIMENT.—I bent the leg of a chicken five weeks old. It cracked under my fingers, and remained bent. Having waited a few seconds, and finding that it was not restored to position, I pressed upon it and made it straight. The chicken walked off without any limp. On the fourth day, before dissection, the bone looked as if it was still bent; but, on removing the soft parts, the line of the axis of the bone was found to be straight. The areolar tissue under the

¹ Art of Surgery, by Daniel Turner, London, 1742, vol. ii. p. 255.

² Science and Art of Surgery, Phila. ed., 1854, p. 180.

³ Op. cit., p. 205.

skin was infiltrated with lymph, which was most abundant near the fracture, and gradually diminished toward each extremity of the limb. This effusion was confined almost entirely to the front of the limb, or to that side which had been broken, and constituted the greater part of the enlargement, which I had noticed before the dissection was commenced, and which then felt like bone. On the front of the bone, also, underneath the periosteum, there was a loose, honeycomb deposit of ensheathing callus, about one line in thickness, and extending upward and downward about half an inch. This callus surrounded the bone in three-fourths of its circumference; but there was no callus on its posterior surface. It was also deficient exactly along the line of fracture, in front and on the sides, in consequence of which an oblique groove remained, indicating the seat of the fracture.

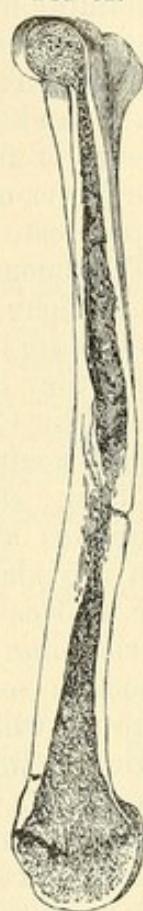In three other experiments, the particulars of which are detailed in the earlier editions of this book, similar results were obtained.

So early as the year 1673, a dissection made by Glaser demonstrated incontestably the existence of partial fractures in the shaft, and in the direction of the diameter of long bones.¹ Camper, in 1765, again described a specimen which he had seen;² and Bonn, in 1783, added a third positive observation.³

M. Gimele is, therefore, in error when he ascribes to Campagnac the credit of having first proved by dissection their existence, in a paper communicated to the Academy of Medicine at Paris, in 1826. Campagnac, however, seems to have been the first who described very particularly the condition of this fracture. He has recorded the history and dissection of two cases, one of which occurred in the fibula, and one in the tibia. The first of these cases was a girl twelve years old, who survived the accident just eight weeks. The fracture had occurred near the middle of the bone, and upon the interior and internal side; in which direction, resting against the tibia, the bone was found inclined. "The bony fibres had been broken at different lengths, almost exactly like what takes place in the branch of a tree which has been partially broken; and, as we see sometimes in this latter case, the bundles of splintered bony fibres abutted upon themselves, and did not take their places when we endeavored to restore them; so the abnormal angle which the fibula represented could not be effaced, the ends of the divided fasciculi not restoring themselves to their respective places. This disposition might be especially seen toward the anterior part of the internal face, where a packet of fibres, coming from below, was braced against the upper lip of the division, which it thus held open. This opening at first made me think that the fragments could not have been well consolidated, but I assured myself that it was, and the fact was subsequently confirmed by the Academy of Medicine; all the points which were in contact were found intimately united."⁴

Diagnosis.—The diagnosis is not difficult. The distortion indicates sufficiently the existence of a fracture, while the complete absence of crepitus in nearly all cases, and of either overlapping or lateral displacement, must generally, especially where the accident has occurred in a child, sufficiently indicate that the fracture is incomplete. It will assist

FIG. 32.



Partial fracture
after union is consummated.

¹ Malgaigne, op. cit., p. 44, from Th. Boneti Sepulchretum, 1700, tom. iii. p. 424.

² Essays and Obs. Phys. and Lit. of Soc. of Edinburgh, 1771, vol. iii. p. 537.

³ Malgaigne, op. cit., p. 44, from Descript. Thes. Ossium. Morb. Hoviani, 1783.

⁴ Des Fractures Incompletes et des Fractures Longitudinales des Os des Membres; par J. A. J. Campagnac. Paris, 1829, pp. 9, 10.

the diagnosis, also, to notice that these accidents are almost confined to the middle third of the long bones; and they are produced usually by a bending of the bones, the forces operating upon the extremities, and not directly upon the point which is broken. In complete fractures the preternatural mobility is so constant a sign as to be regarded as diagnostic where there is almost always a great degree of immobility at the seat of fracture. The angle made by the projecting extremities is usually rather gentle and smooth; at other times it is abrupt, indicating a greater amount of fracture, or that the outer fibres are broken more irregularly. The power of using the limb is generally sensibly impaired, but not completely lost.

Treatment.—Jurine, Murat, Campaignac, Gulliver, Malgaigne, with some others, have noticed the fact that it is often difficult, and sometimes quite impossible, to restore these bones to position; a circumstance which they have justly ascribed to that condition of the fragments described by Campaignac. The broken extremities of the fasciculi become braced against each other, and effectually resist all efforts to straighten the bone; unless, indeed, so much force is used as to render the fracture complete; a result which, if it should chance to happen, need not occasion any alarm, since, while it enables us at once to restore the bone to line, it does not much increase the danger of lateral displacement and overlapping. That the fracture has become complete we may know by a sudden sensation of cracking, by the increased mobility, and by the crepitus, which is now easily developed.

But we need not, on the other hand, be over-anxious to straighten the bone completely, since experience has shown that after the lapse of a few weeks or months the natural form is usually restored spontaneously. I am not now speaking of those cases in which the restoration occurs immediately, in which it is probable that the splintered fibres offer no resistance to the restoration; but only of those in which the bone straightens so gradually as to induce a belief that the broken ends are the cause of the resistance. In a case mentioned by Gulliver, it required about four weeks' time to render the bones of the forearm perfectly straight; and in one case mentioned by Jurine, at the end of six months it was "difficult to say which arm had been broken, and at the end of one year it was impossible."

Jurine attributes this restoration to "muscular action, or more especially to the reaction of the compressed bony plates;" but while it is easy to understand how the reaction of the compressed fibres may accomplish the gradual restoration, I am unable to understand in what manner muscular action contributes to this result, since most of the muscles attached to the long bones operate so much more energetically in the direction of their axes than in the direction of their diameters. Indeed, we have often seen these bones bent after complete fractures, and before the union was consummated, by muscular action alone.

I repeat, then, that the gradual restoration of these bones is due to the same circumstance which produces at other times an immediate restoration, namely, the elasticity of the unbroken fibres, but which elasticity, in this latter instance, is, for a time, effectually resisted by the bracing of the broken fibres. At length, however, in consequence of the gradual absorption of the broken ends, the resistance is removed, and the bone

becomes straight. If this absorption refuses to take place, and the fibres continue pressed forcibly against each other, as in the case described by Campagnac, then the bone remains permanently bent.

Having straightened the bone as far as is practicable, it only remains to secure the fragments in place by suitable bandages or splints. If the restoration is incomplete, these means may assist the efforts of nature in accomplishing a gradual restoration. It is scarcely necessary to say that extension and counter-extension avail nothing in partial fractures.

§ 3. Fissures.

The fissures constitute the second principal form of incomplete fractures, or those in which the fracture is accompanied with no appreciable bending, which occur almost exclusively in inflexible bones, such as the compact bones of adults, and more often in the direction of their axes than of their diameters. They are complete so far as they extend, but they do not completely sever the bone so as to form two distinct fragments. They have been most frequently observed in the flat bones, such as the bones of the skull, and in the upper bones of the face; occasionally in the long bones, both in their diaphyses and epiphyses, and rarely in the short bones.

M. Gariel has reported, in the *Bulletins de la Société Anat.*, for 1835, a case of fissure of the inferior maxilla, occurring in a lad sixteen or eighteen years old. Palletta found a fissure extending partly through the third dorsal vertebra, in a man who had fallen upon his back eleven days before; and M. Lisfranc has mentioned a remarkable case of fissure and partial fracture, with bending of five ribs in the same person.¹ In the skeleton of an Indian the scapula was found broken nearly transversely, the fracture commencing upon the posterior margin at a point about three-quarters of an inch below the spine, and extending across the body of the bone one inch and three-quarters, in a direction inclining a little upward, being irregularly denticulate and without comminution. The fragments were in exact apposition, and, throughout most of their extent, in immediate contact. They were, however, not consolidated at any point, but upon either side of the fissure there was a ridge of ensheathing callus, of from one to three or four lines in breadth, and of half a line or less in thickness along the broken margin, from which point it subsided gradually to the level of the sound bone.

M. Voillemier found the head of the humerus penetrated by two or three fissures;² and M. Campagnac reports the case of a lad ten or twelve years old in whom the humerus was found, after amputation, fissured from the insertion of the deltoid to near the condyles, extending through the entire thickness of the bone, and the edges of the fissure so much separated toward its lower extremity as to admit the blade of a knife.³ Chaussier has related a case in which a criminal, who died soon after having submitted to the torture, was found to have a nearly longitudinal fissure of the radius in its upper fourth, and which penetrated half-way through the thickness of the bone.⁴ Gulliver saw a fissure in the pelvis of an infant.⁵ Malgaigne has seen two specimens of this fracture in the iliac bones, both of which belonged, as he thinks, to adults; in one, the fissure was limited to the internal table;⁶ and in the case of the lad reported by Gariel, as having a fissure of the inferior maxilla, there was also found a fissure of the left ilium, but which was limited to the outer table.⁷ M. J. Cloquet has

¹ Des Fract. Incomplet. et des Fissures, par J. A. J. Campagnac, 1829, p. 20.

² Malgaigne, op. cit., p. 35.

³ Campagnac, Des Fract. Incomplet., etc., p. 24.

⁴ Méd. Légale, p. 447 et seq.

⁵ Malgaigne, op. cit., p. 34.

⁶ Gazette Méd., p. 1835, p. 472.

⁷ Bulletins de la Soc. Anat., 1835, p. 24.

mentioned a case of fissure of the shaft of the femur passing through the condyles and extending upward to near the middle of the bone, produced by a bullet, which had completely traversed the bone from behind forward, a little above the condyles.¹

A fissure of the neck of the femur is reported by Dr. Jackson, of Boston. The fracture commences anteriorly just above, but very near to the insertion of the capsular ligament, runs along the insertion for about an inch, and then extends directly upward to the margin of the head of the bone; from this last point it crosses the upper surface of the neck almost in a straight line, and at a little distance from the margin of the head, but afterward approaches very closely to this margin posteriorly; it then turns downward and obliquely forward, and stops at a point about half-way between the small trochanter and the head of the femur, and two-thirds of an inch or more anteriorly to the line of this trochanter. The fracture then involves about three-fourths of the neck of the bone; the inner anterior portion only being spared. There is considerable motion between the neck and the shaft, and the fracture could undoubtedly be completed without the application of any extraordinary force. There was, also, a transverse fracture of the same femur midway, with a split extending upward nearly to the neck of the bone. The femur is perfectly healthy in structure, and no changes are observable in the bone about the fracture."² In Dr. Mütter's collection is a specimen of fissure of the trochanter major. There is an example of a fissure in a patella belonging to the museum of the Edinburgh College of Surgeons, the fissure traversing its articular face only.³

The first example of a fissure of the tibia is recorded by Corn. Stalpart Vander-Wiel, in 1867; and indeed this is, according to Campaignac, the first exact observation of this species of fracture which our science possesses, although its existence had been recognized by the most ancient authors. A servant had been kicked by a horse, and after a time, pain continuing in the limb, his surgeon, Dufoix, suspected a fissure of the tibia, and having cut down to the bone, a cure was soon effected.⁴

In the Dupuytren Museum, at Paris, there are two tibiæ with linear fractures, one without history, and the other presented by MM. Marjolin and Rullier, "and which had been broken by a ball."⁵ In the example related by Campaignac, a woman, having leaped from a second-story window, died immediately, and upon examination she was found to have three fissures in the upper portion of the left tibia, of which only one entered the articulation.⁶

Duverney saw a priest who had fallen and bruised the middle of his left leg, the swelling and pain consequent upon which were subdued after a few days. The patient believed himself cured, and acted accordingly. Suddenly, in the night, he was seized with an acute pain in the limb; and on cutting down to the bone a bloody serum escaped from between it and the periosteum, and the bone was discovered to be fissured longitudinally. Subsequently the tibia was trephined, but the fissure did not reach the marrow. He recovered completely in less than two months. The same writer mentions another case, in which a soldier received the kick of a horse in the middle of his left leg, which was followed immediately by great pain, and subsequently by much inflammation, and even gangrene of the skin. The wound, however, cicatrized kindly, but after three months he was seized suddenly with a severe pain in the limb, and after the trial of many remedies, resort was finally had to the knife, when the tibia was seen to be discolored and cracked longitudinally. On the following day, the bone was opened over the course of the fissure with a chisel and mallet, and the patient was at once relieved by the escape of a yellowish and very offensive matter. At the next dressing the bone was opened more freely by several applications of the trephine, and an abscess was exposed in the centre of the bone.

¹ Thèse du Concours de Pathol. Externe, 1831, pl. xii. fig. 7. Also, Des Fract., etc., par Campaignac, 1829, p. 19.

² Boston Med. and Surg. Journ., vol. lv. p. 351. See also Amer. Journ. Med. Sci. for 1857, p. 306, with engraving; and Bigelow on Hip-joint, p. 137.

³ Malgaigne, op. cit., p. 35.

⁴ Campaignac, op. cit., p. 17.

⁶ Campaignac, op. cit., p. 21.

⁵ Malgaigne, op. cit., p. 36.

The patient finally recovered after about four months.¹ M. Campaignac saw also, at the Hôpital la Charité, the tibia of a woman, æt. thirty-eight years, upon which were found four fissures, the report of which case is accompanied with a woodcut illustration.²

Fissures may occur probably at all periods of life, but they are more frequently found in the bones of adults.

Campaignac, however, mentions a fissure of the humerus in a child ten or twelve years old, and Gulliver has seen a fissure in the pelvis of an infant.

Etiology.—Fissures may be occasioned by most of those causes which produce fractures in general, such as direct or indirect shocks; but they are occasioned much more often by direct blows, especially when inflicted upon bones imperfectly covered by soft parts, such as the tibia. Bullets, having violently struck or penetrated the bone, have frequently occasioned fissures. Their course may be parallel with the axis of the bone, oblique, or transverse; they are often multiple; some merely enter the outer laminae, others open into the cellular tissue, and others still divide both surfaces of the bone through and through; and, according as they penetrate more or less deeply the bone, their lips will be found to be more or less separated. They frequently extend into the joint surfaces.

Diagnosis.—The signs which indicate the existence of a fissure must, in a large majority of cases, be insufficient to determine fully the diagnosis during the life of the patient. It is not probable that such fissures could ever be clearly made out by the touch alone, where the skin is not broken, since the pain, swelling, suppuration, etc., are only characteristic of inflammation of the bone or of its coverings, and might be equally present whether a fracture existed or not. In those rare cases only in which the flesh is torn off, and the surface of the bone is brought directly under the observation of the eye, will the diagnosis become certain.

Treatment.—Fortunately, an error in judgment in this matter will not materially, if at all, prejudice the interests of the patient; since, whatever may be the fact in other respects, if the bone, or its periosteum, or its medullary tissue, is inflamed, and rest, with antiphlogistics, does not accomplish its speedy resolution, incisions and perforations become inevitable if we would give either safety or relief to the sufferer. Accordingly, in the inflammation and suppuration consequent upon these fractures, we have seen that it has been occasionally found necessary to lay open the soft tissues freely, and even to trephine the bone at one or more points.

Fissures in Cartilage.—I have once met with a fissure in the thyroid cartilage, which constitutes, so far as I know, the only example upon record of a fissure in cartilage.³

¹ Malgaigne, op. cit., p. 39, et seq.

² Campaignac, op. cit., pp. 21, 21.

³ Buffalo Med. Journ., vol. xiii., article entitled Fracture of the Thyroid Cartilage.

CHAPTER IX.

FRACTURES OF THE NOSE.

§ 1. *Ossa Nasi.*

OF twenty-five cases of fracture of the ossa nasi only fourteen were seen by a surgeon in time to afford relief. From this fact we learn how frequently the nature of this accident is overlooked by the friends, and even by the surgeon, and the necessity of always instituting, in such cases, careful and thorough examinations. In some cases, where surgeons were called in time, and a deformity remains, it is not improbable that the accident was not recognized. The rapidity with which swelling ensues after severe blows upon the nose, concealing at once the bones, and lifting the skin even above its natural level, explains these mistakes. The nose, also, is remarkably sensitive, and the patient is often exceedingly reluctant to submit to a thorough examination. It ought, however, not to be forgotten that the omission on the part of the surgeon to do his duty will not always be excused, even though the patient himself has protested against his interference, especially where an organ so prominent, and so important to the harmony of the face, is the subject of his neglect or mal-adjustment; since the most trivial deviation from its original form or position, even to the extent of one or two lines, becomes a serious deformity.

Causes.—When the ossa nasi are struck with considerable force, from before and from above, a transverse fracture occurs usually within from three to six lines of their lower and free margins, and the fragments are simply displaced backward; if the blow is received partially upon one side, they are displaced more or less laterally. This is what will happen in a great majority of cases, as I have proved by examinations of the noses of those persons who have been the subjects of this accident, and by repeated experiments upon the recent subject.

A more considerable force will break, generally, the ossa nasi transversely, and a little above their middle; while, at the same time, the nasal processes of the superior maxillary bones may suffer slightly.

With neither of these accidents is the cribriform plate of the ethmoid likely to be broken or disturbed. Indeed, in numerous experiments made upon the recent subject, and in which the force of the blow was directed backward and upward, breaking and comminuting the nasal bones above and below their middle, with also the nasal processes of the superior maxillary bones, and the septum nasi, the cribriform plate of the ethmoid was, without an exception, uninjured. The exceeding tenuity and flexibility of the septum nasi at certain points prevents effectually the concussion from being communicated through it to the base of the brain. If, therefore, after these accidents, cerebral symptoms are occasionally present, as I have myself twice seen, they must be due rather

to the concussive effects of the blow upon the very summit of the nasal bones, where they rest immediately upon the nasal spine of the os frontis, or to some direct impression upon the skull itself.

The amount of force requisite to break in the nasal bones, at their upper third, is very great; no less, indeed, than is requisite to fracture the os frontis. If they do finally yield at this point, then no doubt the base of the skull must yield also. A force sufficient to break the base of the skull never fails to comminute and detach almost completely the septum nasi. Proceed in such a case as in a case of broken skull; lay open the skin freely, and with appropriate instruments seek to elevate and remove, if necessary, the fragments. In such accidents our services will be of no value.

Diagnosis.—Occasionally the bones are neither broken at their lower ends nor through their central diameters, but only at their lateral, serrated, or imbricated margins. This is rather a displacement, or dislocation, than a fracture. It is more likely to happen in childhood than in middle or old age.

Thomas Kelley, aged four years, was kicked by a horse. Two hours afterward the nose and face were much swollen, and the fracture was overlooked. One year after the accident both nasal bones were depressed through nearly their whole length, especially in the lower halves. The right nasal process was also much depressed, and the right nostril obstructed. The lachrymal canals upon this side were closed.

Sometimes the lower ends of the nasal bones are bent backward, or laterally, constituting a partial fracture.

A lad, aged ten years, was hit by one of his mates accidentally with his elbow, upon the left side of his nose. The lower end of the left os nasi was displaced laterally and backward, so that it rested under the lower end of the right os nasi. There did not appear to be any fracture beyond that which was inevitable by the mere separation of its serrated margins from the bone adjoining. The angle formed by the bone at the point where the bending had occurred was smooth and rounded, and not abrupt as in a complete fracture. With a steel instrument, introduced into the left nostril, I attempted to lift the bone to its place. The membrane was very sensitive, and the patient very restless under my repeated efforts. I pressed upward with considerable force, and succeeded at length in bringing the bone nearly into position.

If there is more complete displacement, the upper ends are not usually forced backward, but rather a very little forward, from their articulations with the os frontis, and the bones then swing, as it were, upon the lower ends of the nasal spine, as upon a pivot. In this condition they are very firmly locked, and it requires considerable force, applied under their lower extremities, to restore them to place. In children, also, the nasal bones may be spread and flattened, the lateral margins not being depressed or displaced, but only the mesial line or arch forced back, so as to press aside the processes of the superior maxilla; which deformity may become permanent.

A block of wood fell upon a child three weeks old, as she was lying in the cradle. The nature of the injury was not understood by the parents, and no surgeon was called. The ossa nasi are now, twelve years after the accident, much wider than is natural, and depressed; the nasal processes of the superior maxilla appearing to have been spread asunder.

Prognosis.—As to the prognosis in these fractures, I can only say that either owing to the ignorance and carelessness of the patients themselves, who neglect to call a surgeon in time, or to the difficulty of diagnosis, or to the greater difficulty in maintaining an adjustment of the fragments, it has hitherto happened that, after the fracture of the ossa nasi, more or less deformity has usually remained. I have seen but a few which could be said to be perfectly restored.

Benjamin Bell and others have spoken of tedious ulcers, polypi, necrosis, fistula lachrymalis, abscesses, impeded respiration, and impairment of the sense of smell and of speech, as circumstances apt to result from these injuries, and it is certain that such consequences have occasionally followed; but they must generally be regarded as accidents due to the state of the general system, and as having no connection with the fracture, except as this injury served to awaken certain vicious tendencies.

Treatment.—The fragments are generally loose, and easily pressed back into place by the use of a proper instrument. A silver female catheter may answer well enough in a few instances, but it will more often fail. The diameter of the meatus at the point where the instrument must touch in order to make effective pressure upon the ossa nasi, is on the average not more than two lines; and when the membrane which lines it is injured, it becomes quickly swollen, and reduces the breadth of the channel to a line or less. Under these circumstances, any instrument of the size of a female catheter could only be made to reach and press against the nasal process of the superior maxilla, which is too firm and unyielding to allow it to pass without the employment of unwarrantable force. In this way it happens that the operator is occasionally surprised to find how much resistance is opposed to his efforts to lift the bones, and, after repeated unsuccessful attempts, the case is not unfrequently given over. If, however, he had used a smaller instrument, he would have found almost no resistance whatever. A straight steel director, or sound, or sometimes even a much smaller instrument, if possessing sufficient firmness, is more suitable than the catheter. For the same reason, also, one ought never to wrap the end of the instrument with a piece of cotton cloth, as some, without much consideration, have recommended. The facility with which these bones may be replaced, when a proper instrument is employed, is true only when the treatment is adopted immediately, or at most within a few days after the accident.

Boyer, Malgaigne, and others have noticed the fact that these fractures are repaired with great rapidity. Hippocrates thought the union was generally complete in six days; and in a case of my own, the fragments were quite firmly united on the seventh day. Malgaigne states that repair is effected without the interposition of provisional callus, but "*par première intention*." Among the specimens illustrating fractures of the ossa nasi, in all over forty, in no instance has there been detected, after a careful examination, the slightest trace of provisional callus.

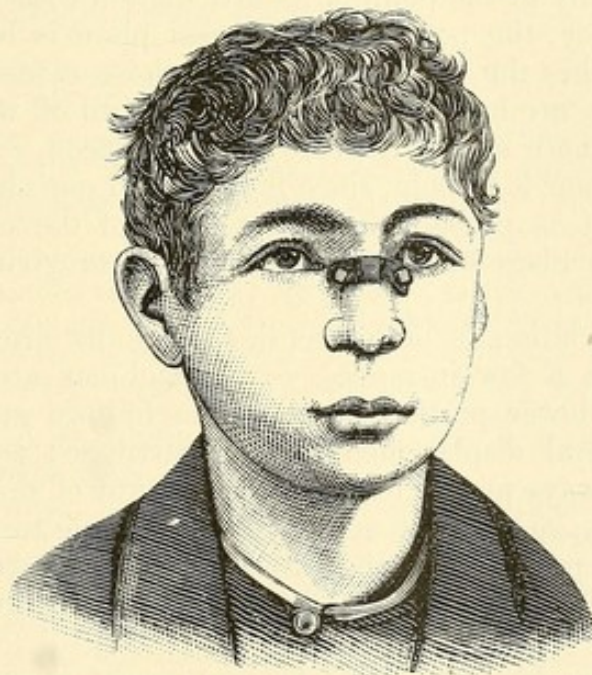It will not always be as easy to retain the fragments in place, as it is to replace them. The very swelling which takes place so promptly under the skin tends to depress the fragments, unsupported as they are by any counter-force; a tendency which, possibly, is in some instances increased

by attempts on the part of the patient to clear his nostrils by snuffing and hawking. I have, in one instance, noticed very plainly a motion in the fragments when such efforts were made. To remedy this, none of the plans suggested possess much practical value. Few patients will consent to the introduction of pledgets of lint, or of stuffed bags, or, indeed, of anything else, sufficiently far up into the nostrils to answer any useful purpose. The membrane is too sensitive and too intolerant of irritants to enable us to have recourse generally to such methods. Then, too, it would require, on the part of the surgeon, more than ordinary tact to accomplish so nice and delicate an adjustment of the supports from below as these cases demand, where the slightest excess of pressure, or the least fault in the position of the compress, must defeat the purpose of the operator.

If the attempt is made, push up in succession a number of small pledgets of sheet lint, smeared with simple cerate, to each one of which there has been attached a separate string, so arranged that their relative position may be recognized, and that they may at a suitable time be removed in the order of their introduction.

The employment of canulas, as recommended by Boyer, B. Bell, and others, allows of the nostrils being stuffed without interfering materially with the breathing; a provision, however, which is quite unnecessary with a majority of persons, so long as there exists no impediment to the free admission of air through the fauces.

FIG. 33.



Mason's dressing.

With nicely adjusted compresses of soft cotton or lint, and secured upon the outside of the nose with delicate strips of adhesive plaster or rollers, we shall be better able to prevent the fragments from becoming displaced outward than by moulds of wax, of lead, or of gutta-percha, under which it is impossible to see from hour to hour what is transpiring.

Supporting the fragments with a nickel-plated or gilded needle, which is made to transfix the nose at a point just below the fragments, was first suggested by Dr. Lewis D. Mason, of Brooklyn, in 1880.¹ The pin is removed on the eighth or tenth day, or as soon as the fragments are sufficiently united not to require support. A narrow strip of rubber bandage is to embrace the ridge of the nose.

§ 2. Fractures and Displacements of the Septum Narium.

Fractures or displacements of the septum narium must occur to some extent in all fractures of the ossa nasi accompanied with depression; but they are also occasionally met with as the results of a blow upon the nose which has been insufficient to break the bones, and in which only the cartilaginous portion of the nose has been bent inward upon the septum. In four of my eight of these simple, uncomplicated accidents, no surgeon was employed, or surgical treatment of any kind adopted, and it is quite probable that only in a small proportion of all the cases was the nature of the accident recognized. Such, at least, has been generally the statement of the patients themselves. The same causes will explain this which have been invoked to explain similar oversights in cases of broken ossa nasi. An additional reason that it may be overlooked is the frequency of lateral distortions or deviations in the natural development of this septum.

The cartilaginous portion of the septum is most frequently displaced by violence, usually at the point of its articulation with the bony septum. Next in frequency, the perpendicular nasal plate is broken, especially where it approaches the vomer. We omit those cases where the nasal bones themselves are broken down, in most or all of which the perpendicular plate is more or less fractured and displaced. We do not know how often the vomer is broken, since it is beyond our observation, except in autopsies. It is probable that the force of the concussion rarely reaches it, the cartilage or the perpendicular plate giving way first and easily.

Where the deviation is only lateral, the results are less serious, yet sufficiently so, in a few instances, to demand our attention. Lateral obliquity of the lower portion of the nose follows generally, but not uniformly, a lateral displacement of the cartilage; and when it does exist, it is not always proportioned to the amount of displacement existing in the septum, so that the septum is then made to project obliquely across the nasal passage, causing often a serious obstruction and permanent inconvenience. It may occasion a chronic catarrh.

A lad, aged fifteen, was struck violently on the nose, which became immediately much swollen, but no surgeon was called. Eight years after I found the septum displaced laterally, and to the left side, producing also a slight lateral inclination of the end of the nose. He was unable to breathe freely through the left nostril, and from the same side a catarrhal discharge had continued from the time of the accident.

¹ Mason, *Annals of the Anatomical and Surgical Society of Brooklyn*, March, 1880.

A depression of the cartilage forming a portion of the ridge of the nose is necessarily accompanied with a corresponding degree of lateral displacement, with or without fracture, of its perpendicular portion, and produces, therefore, not only great deformity, sometimes a complete flattening of the end of the nose, but, also, in some instances, complete obstruction of the nostrils.

We may conclude, therefore, that fractures and displacements of the septum narium are generally followed by permanent deformity, and occasionally with still more serious results; and hence we suggest that there should be a careful examination in recent injuries, with a view to the ascertainment of its lesions.

Treatment.—The treatment is not reliable. It is doubtful if a partition so thin and unsupported can be well adjusted and supported by artificial means. A rational method would be to plug carefully and equally each nostril with pledgets of lint, and cover the outside of the nose completely with a nicely moulded gutta-percha splint or case; this ought to be made to press snugly upon the sides, and should remain for several weeks, or until the cure is completed. The *papier maché* of Dzondi, employed by him in cases of broken ossa nasi, would be equally applicable here; but the gutta-percha, as being more plastic, and hardening more quickly, ought to be preferred.

The remedy of deformities of the nose at a later period belongs to the department of anaplastic surgery, and the modes of procedure must be varied according to the circumstances of the case. The following example will serve as an illustration:

A young man fell from a two-story window, striking upon his face. A surgeon was called, but he did not discover the nature of the injury to the nose. One year after the accident the cartilaginous portion of the septum was found broken just at the ends of the nasal bones, and forced backward about three lines, producing a striking depression at this point of the ridge of the nose, whilst at the same time the end of the nose was thrown up. I introduced a narrow, sharp-pointed bistoury through the skin of the nose on the right side, and resting its edge upon the ridge at the junction of the cartilage with the ossa nasi, cut the cartilaginous septum directly backward about three lines; then, making a gradual curve, I cut downward about eight lines toward the end of the nose. The intercepted portion of cartilage could now be easily lifted with a probe, and the line of the ridge of the nose completely restored. It was at once apparent, also, that lifting the cartilage would depress the tip of the nose and restore its symmetry.

To retain the cartilage in place, I constructed a gutta-percha splint of the length and shape of the nose, but so formed along its middle as that it would not press upon the cartilage which I had lifted, resting well upon the ossa nasi, but not touching the ridge from the lower ends of these bones to the tip of the nose, at which latter point it again received support. I now passed a needle, armed with a stout ligature, through the upper end of the uplifted cartilage, transfixing, of course, the skin on both sides of the nose, and this I tied firmly over the splint. This accomplished the important object of pressing backward and downward the tip of the nose, and thus tilting up the upper part of the ridge and septum, and of more effectually securing the cartilage in place by lifting it directly with the ligature. On the second day the ligature was removed, but the splint was continued two weeks, during most of which time a band was kept drawn across the lower end of the splint, and tied behind the neck. To prevent the cartilage from falling back when cicatrization occurred, I pressed the sides of the splint firmly toward each other, just below the incision, so as to force as much as possible the walls of the nares into the fissure of the septum, made by

lifting it up. The result is a complete and perfect restoration of the nose to its original form.

To rectify an old displacement of the septum, Dr. James Bolton, of Va., makes a stellate incision of the septum in such a manner as to form of it about eight triangles with their apices converging to a common centre. He then seizes each triangle separately with a pair of forceps, and breaks it at its base without detaching it. Having thus comminuted the septum, he is able to restore it to position and retain it until consolidation is effected.¹

CHAPTER X.

FRACTURES OF THE MALAR BONE.

A SIMPLE fracture of the malar bone—that is, a fracture unconnected with a fracture of other bones of the face—probably sometimes occurs, but not being accompanied with much displacement, it is overlooked. I have myself seen a fracture of the upper margin, or of that portion which constitutes a part of the orbital border, in two or three instances, while I was unable to detect any other fracture among the bones of the face; but it is by no means certain that other fractures did not exist, perhaps in some of the bones which form the socket, or in the superior maxilla, as mere fissures, or as fractures with only slight displacement. The prominence of the malar bone, and especially the sharpness of its orbital margin, would enable the surgeon to detect easily the smallest displacement, or even a fissure, whilst a much more extensive displacement elsewhere would escape detection.

The two upper maxillary bones form, as they are placed opposite to each other, an irregular arch, one end of which rests upon its fellow, at the intermaxillary suture, and the other end rests upon the nasal and frontal bones; whilst over the centre of the arch is situated the malar bone. The force of a side blow upon the malar bone will expend itself, therefore, chiefly upon the base of the maxillary apophysis, as being in the line of the direction of the force. The force continuing to act after the apophysis is broken, the portion of the superior maxilla above the floor of the nares will fall inward toward the septum, while the portion below will tilt outward, and open the intermaxillary suture along the roof of the mouth. This suture will also open more widely in front than behind, owing to the greater depth of the suture in front.

These observations I have verified by several experiments made with a hammer upon a clean skull as follows: A fracture of the superior maxilla occurred in every instance, and twice when the malar bone was not broken; in each of the last two cases the antrum alone was broken, and the depression of the malar bone was scarcely noticeable. In the second of these cases, the fracture extended also through the dental arcade. In three cases the nasal apophysis was broken

¹ Bolton, Richmond Med. Journ., April, 1868, p. 241.

near the base, and in one case at two points. One of the three fractures of the nasal apophysis was accompanied with a diastasis of the superior maxilla through its intermaxillary suture. The malar bone has been broken twice by the first blow, and always when the blow has been repeated. The orbital margin and orbital plate have been fissured twice, the outer portion of the orbital plate being pushed a little into the socket. Once this plate has been pushed downward. The zygoma has been broken three times, and always transversely a little beyond its centre, or where the bone is the most slender and most convex. The ethmoid has been broken three times, and always longitudinally through the orbital plate. The sphenoid has been broken once, at the base of the skull by the second blow. In the last experiment, the skull was also found broken at its base, through the lesser wings of Ingrassias; the force of the blow having been conveyed, apparently, along the orbital plate of the superior maxilla and os planum. This is the only example from four experiments in which the fracture extended through the dental arcade, and it was the result of the first blow. The fracture of the base of the skull by the second blow indicates the possibility of producing a fatal lesion of the brain or of its bloodvessels by a blow upon the malar bone.

Prognosis.—The malar bone may be depressed, as we have seen, to the extent of two or three lines, without being broken. This accident will be more properly considered under fractures of the upper maxilla. A fracture of the malar bone implies, therefore, generally, that great force has been applied, and that other fractures exist as complications. This may not be true, however, when only the orbital margin of the socket is broken. If the orbital plate is broken, and a portion of it is pushed into the socket, it may occasion a slight protrusion of the ball, as in two cases related by Dr. Neill as fractures of the upper maxilla, and as has been noticed in the experiments already referred to. This protrusion of the eyeball will probably continue, in some degree, as long as the bones remain displaced. It is quite probable, however, that in some cases, after severe injuries of the face, a moderate protrusion of the eyeball is due entirely to extravasation of blood in the socket; a circumstance which would be likely to follow a fracture of the bones of the socket, and to increase temporarily the protrusion of the eye. If the body of the bone is broken entirely through, and coma supervenes upon the accident, there is some reason to fear that the skull is fractured at its base, and the prognosis must be grave.

Treatment.—It would not appear difficult to restore these bones to place upon the naked skull after an accident, but, in fact, I have found the restoration impossible. It could not be accomplished by an instrument within the nose pressing outward, nor by pressing inward upon the teeth and alveoli; not, certainly, without very great and unwarrantable force. The difficulty consisted simply in the antagonism of the serrated margins of the intermaxillary suture, which, projecting one or two lines on each side, could not be made to interlock again, but were firmly braced against each other. If there is only a fissure of the orbital margin, it will not require attention; but if the fissure extends through the orbital plate, and at the same time the anterior and inferior margin of the bone is depressed, in consequence of which the orbital plate is tilted upward and made to push forward the eyeball, the propriety of surgical interference may be considered. If this protrusion is considerable, and evidently due to the displaced bone, an attempt should be made to lift the body of the malar bone, and thus to restore to position its

orbital plate. The method of accomplishing this will be described particularly when speaking of fractures of the superior maxilla with depression of the malar bones.

CHAPTER XI.

FRACTURES OF THE UPPER MAXILLARY BONES.

THESE fractures assume so great a variety in respect to form, situation, and complications, that it is impossible to speak of them systematically, or to establish other than general rules as to prognosis and treatment. They may be broken, or loosened from each other or from the other bones with which they are articulated, with or without any further fracture; the nasal processes may be broken, generally with a fracture of the nasal bones also; the malar bones may be forced in, carrying with them a portion of the outer wall of the antrum; the alveoli may be broken and more or less completely detached; either of these several fractures may be complicated with fractures of the other bones of the face, or of the base of the skull even.

Prognosis.—Malgaigne remarks: "In all complicated fractures of the upper jaw, there is one principle which surgeons cannot too much study, namely, that all fragments, however slightly adherent they may be, ought to be most carefully preserved, and they will be found to unite with wonderful ease. This remark had already been made by Saviard. Larrey insists strongly upon it, and we have seen that M. Baudens, so great an advocate for the removal of loose fragments, has declared for these fragments a special exemption."¹ Malgaigne has here especial reference to fractures of the dental arcade, and to fractures implicating the alveoli, and extending more or less into the body of the bone.

Exceptions have, however, occurred in my own practice, the fragments becoming loosened and completely detached after the lapse of several weeks. In the case related by Miller, the whole floor of the antrum having been broken off, in an unskilful attempt to extract the second right upper molar, it was found impossible to make it unite, and it was subsequently removed.² Such unfortunate results certainly may sometimes be reasonably anticipated. Yet they occur so seldom as to justify the opinions and practice advocated by Malgaigne.

Our experience during the War of the Rebellion in this country confirms most of the observations heretofore made in relation to these fractures. Owing to the extreme vascularity of the bones composing the upper jaw, the fragments have been found to unite, after the most severe gunshot injuries, with surprising rapidity: the amount of necrosis and caries being usually inconsiderable, compared with the amount of comminution. The same anatomical circumstance, namely, the vascularity, has rendered these accidents peculiarly liable to troublesome hemorrhages, both primary and secondary.

¹ Op. cit., vol. i. p. 376, Paris ed.

² Miller, News Letter, April, 1854.

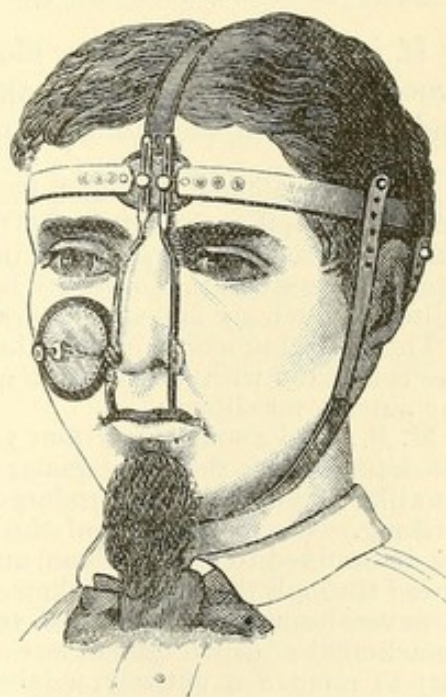The Surgeon-General reports that of 4167 wounds of the face, transcribed from the reports from the beginning of the war to October, 1864, there were 1579 fractures of the facial bones, and of these 891 recovered, 107 died—the terminations are still to be ascertained in 581 cases. He further remarks that secondary hemorrhage has been the principal source of fatality in these cases, and that frequent recourse has been had to ligation of the carotid, with the result of postponing for a time the fatal event.¹

Treatment.—When the harmonies of the upper maxillary bones are only slightly disturbed, nothing but a retentive treatment is necessary.

A man was thrown backward from a loaded cart, one wheel of the cart passing over his face. The right malar bone was broken and forced down upon the antrum about three lines. Both superior maxillæ were loosened from their articulations, and could be moved laterally, the motion producing a slight grating sound. The same motion and grating occurred whenever he attempted to swallow. No effort was made to elevate the malar bones, the amount of displacement being very inconsiderable, and never sufficient to be observed by the eye. Cool lotions were applied constantly to the face, and the patient was sustained by a liquid diet. On the ninth day all motions of the fragments had ceased, and on the twenty-seventh day the patient was completely recovered, with only the depression of the malar bone remaining.

In a case in which the superior maxillary bones had been more completely torn from their connections, complicated with other severe injuries, I found it necessary to support the fragments by closing the lower jaw upon the upper and by suitable bandages.

Graefe recommends, where the bones are thus extensively separated and displaced, an apparatus made of steel, and suitably covered, which is to be applied against the forehead and buckled under the occiput. From which apparel, in front, descend a couple of steel plates, which, having arrived at the free border of the upper lip, are reflected upon themselves, and are made to support upon their extremities long silver gutters, intended for the reception of not only the displaced teeth and alveoli, but also those teeth which are firm.² Goffres has employed a similar apparatus, only that he has substituted gutta-percha for the silver gutters of Graefe.³ In Goffres's case the apparatus was made to support a pad also, intended to make lateral pressure over the displaced fragments. No doubt cases may now and then occur in which this apparatus would serve a useful purpose.



Goffres's modification of Graefe's apparatus.

In most cases two interdental splints of gutta-percha, placed one on either side, leaving an open interval in front for the purpose of conveying

¹ Circular, No. 6, 1865.

² *Traité des Frac., etc., par L. F. Malgaigne*, p. 373.

³ Goffres, *Bullet. de l'Acad. de Méd.*, 1862, t. 27, p. 1157, from Poincot.

food to the stomach, will accomplish every indication, and in a manner much more comfortable to the patient, and more satisfactory to the surgeon, than any form of mechanical apparatus. A pad or compress upon the side of the face, supported by a roller, is better than the pad attached to one side of Goffres's apparatus, as a means of lateral support.

Wiseman, having been summoned to a child with his whole upper jaw forced in by the kick of a horse "beating the ethmoides quite in from the os cribri-forme," and forcing the palate bone against the back of the pharynx, found great difficulty in securing a permanent readjustment. At first he attempted to introduce his finger back of the bone; but, failing in this, he bent an instrument into the form of a hook, and, passing it between the bone and the pharynx, he easily replaced the fragments. But, on removing the instrument, they were again displaced. Immediately he had constructed an instrument by which the bones could be not only easily reduced, but also retained in place, extension being made by the hands of the child, his mother, and others, alternately. In this way the reunion was finally effected, and "the face restored to a good shape, better than could have been hoped for."¹

Harris, of New York, mentions a case in which a child, two years old, having fallen from a height, was found to have a diastasis of both the superior maxillary and palate bones; the separation being sufficient to admit the little finger, and extending from between the alveoli which supported the central incisors, to the soft palate. It is not stated that efforts were made to reduce the bones; six weeks after the injury was received they were still open, and it was proposed to close the space by a plastic operation as soon as the condition of the patient would warrant such a procedure.²

In this example, as in my experiments in fracture of the malar bone, it was probably found impossible to adjust the bones and close the inter-maxillary suture, and for the same reasons.

If, in consequence of a blow received upon the ossa nasi, the nasal processes of the superior maxilla are broken down, they may be lifted and adjusted in the same manner as the ossa nasi.

I have a specimen, in which the nasal bones being driven in by the kick of a horse, the nasal process upon the left side is broken off just above the root of the cuspid tooth, and its upper end inclined inward toward the nasal passage and backward, until it is completely buried. In this situation it has become firmly united to the bony and soft tissues into which it was brought in contact.

The following example will illustrate some of the complications and difficulties connected with a depression of the malar bone, and consequent fracture of the antrum maxillare:

M. P., aged about thirty-four years, was thrown from a height, striking upon his face, forcing the right malar bone down upon the antrum of the superior maxilla. The deformity produced by the sinking of the malar bone was very striking. We found some of the teeth upon the side of the fracture loose, and we determined to extract them, and press up the bone with an instrument introduced through the empty sockets. The first attempt to extract a molar tooth, however, brought down several teeth, and the whole floor of the antrum. The detachment of this fragment was also now so complete that we believed it necessary to remove it entirely, a labor which was accomplished with infinite difficulty, and with no little hazard to the patient, as dissection had to be extended very far back into the throat, and in the end it was not effected without bringing out, attached to the fragment of maxillary bone, a considerable portion of the pyramidal process of the os palati. The time occupied in this operation was at least one hour, during which we were every moment in the most painful apprehensions, lest we should reach and wound the internal carotid, which lay

¹ *Chirurgical Treatises*, by Richard Wiseman, 1734, p. 443.

² *New York Journ. Med.*, vol. xiii., 2d ser., p. 214.

in such close juxtaposition to the knife that we could distinctly feel its pulsation. After its removal the hemorrhage was for an hour or more quite profuse, and could only be restrained by sponge compresses pressed firmly back into the mouth and antrum. When the hemorrhage was sufficiently controlled, we proceeded to examine the antrum, the floor of which being removed entire, permitted the finger to enter freely. The restoration of the malar bone was now accomplished without much difficulty, and with only moderate force. Two years after the accident the face presented, externally, no traces of the original injury. The malar bone seemed to be as prominent as upon the opposite side, and there was no perceptible falling in where the teeth and alveoli were removed. During several months after the removal of the bone, the antrum continued to discharge pus, but at length a semi-cartilaginous structure closed in the cavity below, entirely reconstructing its floor, and the discharge ceased. Since then he has experienced no further inconvenience.

In many instances no difficulty will be experienced in resorting to the usual method. The recent loss of one or more teeth opposite the floor of the broken antrum, or the complete displacement of a tooth by the accident itself, will give an opportunity for the perforation of the antrum through the open socket, and for the introduction of a suitable instrument for lifting the depressed bone.

Unless, however, the opening is quite large, the instrument employed must be so small, such as a straight steel sound or a female catheter, as to expose the parts against which its end is made to press, to some risk of being broken and penetrated. It is even possible in its way to penetrate the socket of the eye, and thus inflict serious injury upon the eye itself. Yet, with some care, such accidents may be avoided, and it is probable that in the cases supposed, where the sockets of the teeth opposite the base of the antrum are open, this method will continue to have the preference.

But if the teeth remain firm in their places, or if they have been removed, and the sockets are filled up, and we wish to enter the antrum at its base, we must either drill through its anterior wall above the roots of the teeth, or we must proceed to extract a tooth. The first method gives an inconvenient opening, and one through which it will be necessary to use a curved instrument; but yet it is a method far less objectionable than the extraction of a tooth which is firm, or which is even tolerably firm, in its socket, and which may require the forceps for its removal.

The objections to this latter procedure were suggested by the tedious and painful operation already detailed. The first attempt to extract a tooth brought down the whole floor of the antrum, with all its corresponding teeth, and the pyramidal process of the palate bone. The tooth was already loose, and we thought it might easily be taken out; but it had not occurred to us that it was loosened by the comminuted condition of the walls of the antrum, and of the dental arcade. The experiments made upon the dead subject would seem to show that this fracture and comminution of the alveoli is not a very frequent result of a fracture of the antrum produced by a blow upon the malar bone; yet it may happen, and whenever it does, the attempt to extract a tooth must always expose the patient to the same hazards. Certainly it is no trifling matter to pull away all of a man's upper teeth upon one side, and to open freely into a broad cavity which might never close again, and which, in this event, must always serve as a place of lodgment for particles of food, and for foul secretions, to say nothing of the external deformity which it is likely to produce, and of the severity and even danger of the operation.

The following procedures, the value of which I have been able to determine by experiment upon the living subject in two or three cases, and which I have carefully and frequently tested upon the cadaver, are suggested:

Attempt to lift the bone by putting the thumb under its zygomatic process and body within the mouth. If the bone is thrown directly downward, or downward and backward, this method can scarcely fail; and even when it is thrown downward and forward, so as to press into the antrum, it is likely to succeed. If, however, for any reason, the thumb cannot be brought to bear upon its under surface, make a small incision upon the cheek over the anterior margin of the masseter muscle, where its insertion into the malar bone terminates, and pushing a strong blunt hook under the bone, lift it.

Where the depression of the malar bone is in the direction of the anterior and superior angle, these means may not be found available, and we may then employ a screw elevator. The instrument ought to be made of the best steel, and with a broad, sharp-cutting thread. A slight incision being made through the skin, and down to the centre of the malar bone, the elevator is then screwed firmly into its structure, and now its elevation and adjustment may be accomplished with the greatest ease.

In some instances, where fragments are displaced, carrying with them several teeth, while others in the same row remain firm, it will be sufficient to close the mouth and apply a bandage as for fracture of the inferior maxilla; in others, the teeth and their alveoli ought to be fastened with silk, or gold or silver thread; gold, silver, gutta-percha, or vulcanite clasps may be applied to the teeth and jaw.

In a case of fracture of the right superior maxilla, reported by Baker, of Norwich, N. Y., complicated with a fracture of the inferior maxilla, the alveoli were retained in place very perfectly by a mould of gutta-percha. Neill, of Philadelphia, has also reported three cases of fracture of the bones of the face, involving the superior maxilla, in two of which the eyes were made to protrude more or less from their sockets. The loosened alveoli were made fast by wire. The subsequent deformity was inconsiderable, yet in no instance was the restoration complete. The same method was adopted successfully by a surgeon in Virginia, in the case of a negro fifty years old, where most of the teeth of the left upper jaw were forced into the mouth, carrying with them their corresponding alveolar processes. The teeth remained firm in their sockets, but the separation of the bone was complete, the fragment being held in place only by the mucous membrane of the mouth. On the eighth day the surgeon found that the negro had removed the wire, and also the cork from between his teeth, and the maxillary bandage; but the soft parts had already united, and the bones showed no tendency to displacement. His recovery was speedy, and it was accomplished without any further treatment.

[Marshall, of Chicago, reports two cases of fracture and diastasis of the superior maxillæ and upper bones of the face successfully treated with the aid of the inter-dental splint. In both cases the cause was a crushing blow which drove the maxilla inward. The apparatus employed was adapted on the principle of Kingsley's inter-dental splint, and gave excellent results.¹]

¹ Journ. Amer. Med. Assoc., 1888, vol. ii.

CHAPTER XII.

FRACTURES OF THE ZYGOMATIC ARCH.

THE zygoma, strictly speaking, is formed in a great measure by the body of the malar bone, and it is broken whenever the malar bone is completely separated through any portion of its body. That portion will be considered which is composed of the two processes, called respectively the zygomatic processes of the malar and temporal bone.

Duverney relates a case in which a young child, having in his mouth the end of a lace-spindle, fell forward and thrust the spindle through the mouth from within outward, breaking the zygoma in the same direction, and leaving the fragments salient outward.¹ To which case of outward displacement Packard, in a note to Malgaigne's work on fractures, etc., has added a second.²

Experiments upon the naked skull show that the zygoma may be broken and displaced in the same direction, by any force which shall fracture the superior maxilla and depress the anterior margin of the malar bone. This happened three times, and always at the same point, viz., a little beyond the middle of the zygoma, near where the suture which joins the two processes terminates below. The fractures were always transverse, and not in the line of the suture. They were, therefore, fractures of that portion of the zygoma which belongs to the temporal bone.

Symptoms.—An irregular projection or depression of the fragments is the only sign which can be relied upon to indicate the existence of this accident; and this must often be concealed by the swelling which follows so rapidly wherever the integuments are severely bruised over a superficial bone. This displacement can scarcely occur in but two directions, either outward or inward; since the attachments of the temporal aponeurosis above, and of the masseter muscle below, must effectually prevent its descent or ascent. Neither motion nor crepitus will often be present. In some cases the difficulty in opening or shutting the mouth, occasioned by the projection of the fragments toward or into the tendon of the temporal muscle, or by the inflammatory effusions, may assist in the diagnosis.

Prognosis.—If the fracture has been produced indirectly by a depression of the malar bone, the prognosis must depend upon the amount of injury done to the other bones of the face; in itself, the fracture of the zygoma cannot be a matter of any moment. The same remark might apply also to any fracture of the zygoma in which the angles were salient outward. If, on the contrary, the angle is salient inward, the fracture having been produced by a blow inflicted directly upon the zygomatic arch from without, or by a blow upon the outer portion of the malar

¹ Duverney, *Bulletin de la Société Anatomique*, p. 138, 1810.

² Malgaigne, *Amer. ed.*, p. 289, vol. i.

bone, it may occasion some embarrassment to the action of the temporal muscles. If the force which produces the fracture has acted more upon the temporal portion of the arch, near where the process arises from the temporal bone, it may be accompanied with a fracture of the skull, and with serious cerebral lesions.

Treatment.—A fracture, accompanied with an outward displacement, and occasioned by a depression of the malar bone, will be adjusted by a restoration of the malar bone in the manner already described, when speaking of fractures of the superior maxilla, etc. If the fragments are displaced outward, in consequence of a direct blow from within, then they may be replaced by pressing upon the projecting angle.

When the fragments, in consequence of a direct blow from without, have been driven inward, and, as a consequence, serious embarrassment to the motions of the temporal muscle ensues, an attempt ought to be made at once to replace them; if, however, no impediment to the action of the muscle exists, no surgical interference will be required. A slight amount of embarrassment may be the result of the direct injury to the muscle inflicted by the blow, without reference to the displacement of the bone, and a few days will suffice to remedy this evil entirely. Where the fragments actually penetrate the muscles and remain thus displaced, the points are gradually absorbed, and rounded, so that after a time they constitute no impediment to the action of the muscles. It is not the muscle, but its tendon, which is liable to be penetrated; and this is usually protected somewhat by a plate of soft adipose tissue lying between the tendon and the arch. If to these considerations we add the difficulties likely to be encountered in the reduction, we shall find but few cases in which a resort to surgical interference will be necessary. If the bone is driven toward the tendon of the temporal muscle at or near its centre, and if its restoration becomes necessary, it can be accomplished only by approaching the bone from without.

Dupuytren found an external wound through which, by the aid of a levator, he easily restored the fragments to place. M. Ferrier, however, of the Hospital of Arles, in a case brought before him, made an incision through the integuments down to the bone, and then attempted to slide underneath the small extremity of a spatula; but the aponeurosis would not yield, and he was obliged to cut it also. He was now able to lift the fragments easily. The wound healed rapidly, and the patient was dismissed without any deformity.¹

[A case came under the care of Levis, of Philadelphia, in which the depressed arch was caught against the coronoid process of the lower jaw, causing fixation. He elevated the fragment through an incision just above the zygoma, when the lower jaw was at once set free.²

Mr. Le Gros Clark met with a case where, at the end of three weeks, the trismus was so extreme, owing to the driving in of the arch, that he was totally unable to separate his jaws or to move the lower maxilla at all. No operation was performed, and the patient in time entirely recovered, and with slight deformity.³]

¹ Ferrier, *Bulletin des Sciences Méd.*, tom. x. p. 160.

² Polyclinic, Philada., 1886.

³ St. Thomas's Hosp. Reps., 1887.

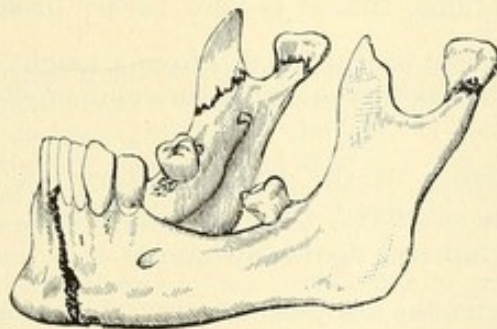
CHAPTER XIII.

FRACTURES OF THE LOWER JAW.

OF 55 examples of fracture of this bone which have been recorded by me, not including gunshot fractures, 52 were broken through some portion of the body. An analysis of 45 of the above examples shows that 16 were broken completely asunder at two or more points, constituting double and triple fractures; and of the remainder, 5 were accompanied with detachment of portions of the alveoli, and one with detachment of a considerable fragment from the body. 13 were compound; not including in this enumeration several examples in which the partial or complete dislodgment of a tooth might entitle them to be called compound. Four fractures through or near the symphysis were nearly or quite vertical, and most of the others were known to be oblique.

Malgaigne has remarked, also, that in fractures of the body of the bone the direction of the obliquity is generally such that the anterior fragment is made at the expense of the internal face of the bone, and the posterior fragment at

FIG. 35.



the expense of the external face, this latter overriding the former. Buck, of New York, has seen the fragments in an opposite condition, requiring the use of the knife and saw for their extrication.¹ I have myself recorded one similar example, but in which the fragments were easily replaced.

In 30 examples of fractures through the body, not including fractures of the symphysis, the line of fracture has been observed to be 20 times at or very near the mental foramen, 3 times between the first and second incisors, 4 times behind the last molar, and 3 times between the last two molars.

Boyer was of the opinion that a fracture never takes place in the symphysis of the chin; but many surgeons since his time have noticed this fracture, and Malgaigne assures us that J. Cloquet has demonstrated its existence upon an anatomical specimen.

¹ Buck, New York Journ. Med., March, 1847. Proceedings of N. Y. Med. and Surg. Soc., Sept. 19, 1846.

Stephen Smith, of New York, has seen two examples;¹ Lonsdale mentions three;² and Gibson has seen one;³ and I have met with two, both of which are recorded in the early editions of this book. Velpeau, Fergusson, Gibson, Henry Smith, and others, have remarked that a separation at the symphysis takes place usually in infancy or childhood. But in the examples in which I find the ages reported, only one, a case mentioned by Lonsdale, occurred in a person as young as ten years; in one of the cases seen by myself, the patient was seventeen years old, and the remainder ranged from twenty-five years to sixty; and the average age of all is thirty-two years.

A fracture of the ramus occurred in a man twenty-three years old, who had been struck by a wooden block on the side of his face. The ramus was broken just above the angle, and the body was broken, also, obliquely near the symphysis. The intercepted fragment was carried inward.⁴ I met with another similar case at Bellevue Hospital, in a woman.

Ledran mentions the case of a child, ten or twelve years old, in whom the fracture was double also; one fracture having taken place through the body, and one extending obliquely from the root of the coronoid process to the neck of the condyle. The intercepted fragment was, however, so little displaced that the fracture of the ramus was not discovered until after death.⁵ Malgaigne refers to this as the only example recorded; but Stephen Smith, of the Bellevue Hospital, has met with it four times: in one case the ramus was broken on both sides; in two cases one ramus only was broken; and in one the body was broken on the right side and the ramus on the left.⁶ In two of these examples the fragments were not displaced.

The coronoid process is so well protected by muscles and by the surrounding bony projections, that it is very rarely broken.

Houzelot mentions a case in which a fall from a height produced at the same time a fracture of both condyles, of both coronoid processes, and of the symphysis.⁷

Nine cases of fracture of the condyles have been reported, in all of which the separation occurred through the neck, and just below the insertion of the external pterygoid muscle.

According to Malgaigne, the analysis of these cases, excepting those mentioned by Packard and Watson, shows two classes of examples: the one occasioned by falls or blows upon the chin, and producing a simple fracture of the neck of the condyle; the other occasioned by injuries inflicted upon the side of the face, and producing a fracture of the neck on the side corresponding to that upon which the injuries are received, and at the same time a fracture of the body upon the opposite side. These two varieties seem to be about equally common.

In Houzelot's case there existed also a fracture of both condyles, of both coronoid processes, and at the symphysis. In Watson's case the face was somewhat deformed by the retraction of the chin; the mouth could not be opened so as to protrude the tongue to any great extent beyond the teeth, and the teeth of the upper and lower jaws could not be brought into contact. In attempting to move the jaw, the patient experienced pain and crepitation just in front of the ears; the crepitation could easily be felt by placing the fingers over the

¹ Smith, New York Journ. Med., Jan. 1857, Hospital Reports.

² Practical Treatise on Fractures. By Edward F. Lonsdale, London, 1838, p. 226.

³ Institutes and Practice of Surgery. By William Gibson. Philada., 1841, p. 261.

⁴ Trans. Amer. Med. Assoc., vol. viii. p. 385. Report on "Deformities after Fractures," Case 17.

⁵ Malgaigne, op. cit., p. 337, from Ledran, *Observ. Chirurg.*, tom. i. obs. vii.

⁶ Smith, New York Journ. of Med., Jan. 1857. Bellevue Hosp. Reports.

⁷ Malgaigne, op. cit., p. 400.

fractured condyles. Nothing was done for the fractures of the jaw. In a few weeks the rubbing of the broken surfaces and attendant soreness ceased to trouble him; but the shape of the jaw, and difficulty of opening the mouth to any great extent, still remained unaltered.¹

Etiology.—The causes have generally been direct blows, in most instances inflicted by a club, or by the kick of a horse; in two examples the blow was inflicted by the fist. A fracture immediately in front of the right cuspid, in a lad eight years of age, was produced by pressure between two wagons, made upon the two angles of the jaw. A double fracture was produced in a young woman by the grasp of her husband's hand. In ten of eleven cases mentioned by Stephen Smith, the causes were direct blows. Examples of fracture of the inferior maxilla from indirect blows have, however, been mentioned by other surgeons, the angles of the bone being pressed together by the passage of a wheel, and the fracture taking place usually toward the symphysis. Fractures of the condyles belong to two classes:² the one being occasioned by falls upon the chin, and the other by blows upon the side of the face; the former acting as a counter-force, and the latter as a direct. The coronoid process can only be broken by a direct blow.

Symptoms.—Fractures of the body of the bone are characterized by the usual signs of fracture elsewhere, namely, displacement, mobility, crepitus, and pain. The displacement is generally present; but its direction and amount vary according to the situation and course of the fracture, and also according to the violence and direction of the force producing the fracture.

I have seen several cases unaccompanied with displacement, and one of these I think ought to be regarded as an example of a partial fracture. A lad, æt. nine, was kicked by a horse on the right side of the jaw. I could not detect any fracture, but the body of the jaw seemed to be bent in. On the third day, however, while endeavoring to straighten the jaw by violent pressure from within outward, I detected a feeble crepitus, which on more careful examination proved to be opposite the second incisor of the right side. I was also able to detect a slight motion at the same point. It was found impossible to rectify the bending, and no further efforts were made. After the lapse of nearly a year, the natural curve was found to be partially, but not completely, restored. Ledran and other surgeons have also seen examples where neither the periosteum nor mucous membrane was torn.

In fractures of the body, the anterior fragment is generally depressed.

Malgaigne affirms that where an overlapping occurs, the anterior fragment lies, generally, within the posterior; a fact which he explains by the direction which the line of fracture usually takes, namely, from without inward and backward, as we have already mentioned. In one instance, where the jaw was broken at the symphysis and also on both sides through the body, the central fragments were found, after about four weeks, lifted two lines above the lateral fragments, and also slightly carried backward.³ I have twice also met with examples in which the posterior fragments were inclined to fall inward toward the mouth, a circumstance which seemed to indicate that the course of the obliquity was in a direction opposite to that which Malgaigne has observed to be most frequent. In each of these examples the jaw was broken upon both sides, by blows inflicted

¹ New York Journ. of Med., Oct. 1840. Hospital Reports.

³ Trans. Amer. Med. Assoc., vol. viii. p. 380, 1855, Case 6.

² Malgaigne.

with a club, and the fractures were situated well back.¹ It is possible, however, that the position of the fragments was due rather to the direction and force of the impression than to the direction of the line of fracture.

The digastricus, the genio-hyoglossus, and the mylo-hyoideus, with several other muscles which act less directly, all tend to depress the anterior fragment, and in some slight degree to carry it backward; a direction which, indeed, it usually takes, and which it would probably always take if left alone to the action of the muscles. If the fracture has occurred through the angle, or at any point within the attachments of the masseter muscle, the action of those fibres of this muscle which remain connected with the anterior fragment will sufficiently explain the fact that it is not now so easily depressed below the level of the posterior fragment; whilst the separation of the fragments along the line of the base, when an attempt is made to close the jaw forcibly, is probably due to the loosening and partial dislodgment of some of the molars, which, being pressed upward, act as a pivot upon which the fragments are made to bend.

An overlapping of the fragments in the direction of the axis is, in simple fractures, no doubt, exceptional, and in such examples as I have seen it was very trivial.

It occurred in case "three" of my "Report," the fracture being near the mental foramen; in case "two," the fracture being just anterior to the last molar; and also in case "six," where the bone had been broken through the centre of the body on both sides and through the symphysis; but in neither case did the overlapping exceed two or three lines, and it was always easily overcome.

The mobility of the fragments is not so striking in these accidents as in fractures of the long bones, yet it is generally sufficiently marked, and especially where the bone is broken upon both sides at the same time. If only one side is broken, both motion and crepitus will be most easily detected by lateral pressure upon the posterior fragment, which, being the smallest and the least supported by antagonizing muscles, will be found to be the most movable. If the fracture is upon both sides, mobility and crepitus will be most readily developed by seizing upon the anterior fragment and moving it gently up and down, while the finger rests upon the alveolus within the mouth. Sometimes a slight swelling or tenderness at some point of the dental arcade, or the loosening or complete dislodgement of a tooth, will indicate the point of fracture. Pain, especially when the fragments are moved, is here more constant than in most other fractures, owing perhaps, in part, to the superficial position of the bone, which renders the soft parts lying over it more liable to injury from the causes of fracture; but also, in part, to the lesion which the inferior dental nerve may have suffered.

It is, indeed, a matter of surprise that injury to this nerve does not oftener seriously complicate these accidents, coursing, as it does, through so large a portion of the angle and body of the bone. One might naturally suppose that its complete disruption would often occasion paralysis of those portions of the face to which it is finally distributed, and that its partial lesions and contusions

¹ Ibid., Cases 1 and 10.

would create, in many cases, the most acute and constant suffering. It is rare, however, that we have present an amount of pain which might not be attributed to a severe shock, or a slight strain upon its fibres. I have myself never seen any extraordinary suffering directly attributable to an injury of the dental nerve after fracture; nor any degree of facial paralysis, except in the case to be hereafter described. Rossi relates a case in which convulsions followed this accident, and in which, as a final remedy, he proposed to expose and bisect the nerve; and Flajani saw a patient, whose jaw had been broken, die in convulsions on the tenth day, the muscular contractions having commenced as early as the fourth day after the accident. The autopsy disclosed a rupture of the dental nerve, but no injury to the brain.

If the displacement is sufficient to occasion a complete disruption of the nerve, some degree of temporary paralysis in the portions of the face supplied by it must be inevitable; and, perhaps this occurs oftener than it has been noticed, since, during the confinement of the jaw by dressings, it is not likely to be observed, and after the lapse of a few weeks it will probably cease altogether. A single case in which the paralysis was reported by Desirabode.¹

Bérard mentions a case of vertical fracture occurring between the second and third molars, without displacement, which was accompanied with complete insensibility of the lip on the same side throughout the space comprised between the commissure and the median line, and between the free border of the lip and the chin. The paralysis disappeared after a few days.²

Dr. F. S. Dennis remarks that hemorrhage into the dental canal, or a slight laceration of the inferior dental nerve, with little displacement of the fragments, may cause a paralysis, which, in the former case after absorption, and in the latter case after repair of nerve-tissues, eventually terminates in complete recovery.

[Spencer, of London, reports a case of fracture between the first and second molar teeth followed by anæsthesia over an area bounded by a line drawn vertically from the angle of the mouth and the middle line, and from the border of the lip to the lower margin of the jaw. The nerve in this case seems to have been torn.³]

To these signs now enumerated, we may add, as occasional complications rather than as diagnostic symptoms, salivation, swelling of the submaxillary and sublingual glands, abscesses, necrosis, etc. If the blow has been vertical upon the chin, and the direction of its force has been toward the articulations, the bony structure of the ear, and even the brain, may have suffered serious lesions, which may be indicated by a deafness or a roaring in the ears, by bleeding from the external meatus, and by fatal coma.

Tessier saw a man who had received the kick of a horse exactly upon the centre of the chin, breaking the bone on both sides, and who, in consequence, bled freely from his ears;⁴ and Alix relates the case of a young man who, falling from a height and striking upon his chin, had broken his jaw. Insensibility immediately followed; convulsions also ensued upon the fourth day, and he died upon the sixth.⁵

If the fracture is at the symphysis, it is generally vertical, and either fragment may be found slightly displaced upward or downward.

¹ Journ. des Connaissances, 1857, No. 20, p. 538.

² Malgaigne, from Gazette des Hôpitaux, 10 Août, 1841.

³ Tr. Lond. Path. Soc., 1888, vol. xxxix.

⁴ Malgaigne, pp. 383 and 386, from Journ. de Méd., 1789, tom. lxxix, p. 246.

⁵ Ibid., p. 386, from Alix, Observata Chir., fascic. 1, obs. 10.

In one of the examples seen by myself, the left fragment fell three lines below the right, and in another the right side had fallen about one line. In a case mentioned by Syme there was scarcely any displacement.¹ Liston remarks that it is usually slight.

The signs which indicate a fracture through the angle have already been sufficiently considered when speaking of fractures of the body; from which it only differs in the less degree of displacement, and in the fact that the posterior fragments are a little more prone to fall inward toward the mouth. Owing probably to the loosening and partial dislodgment of the last molar, it is sometimes difficult to close the mouth, the same as in fractures a little further forward.

In two examples of fracture of the ascending ramus, the bone being broken also through its body, the fracture of the ramus was recognized by both crepitus and mobility.

The signs which indicate a fracture of the coronoid process are inferred from its anatomical relations. There must be some embarrassment in the motions of the jaw, occasioned by the detachment of a portion of the fibres of the temporal muscle; and it is probable that an examination by the finger within the mouth would readily detect mobility and displacement.

A fracture through the neck of the condyle is characterized by pain at the seat of fracture, especially recognized when an attempt is made to open or shut the mouth, by embarrassment in the motions of the jaw, by crepitus, which may usually be felt or heard by the patient himself, by mobility and displacement. The upper fragment, if disengaged from the lower, is drawn forward, toward, and inward, by the action of the pterygoideus externus; and is felt not to accompany the movements of the lower fragment.

The lower fragment is at the same time drawn upward, in consequence of which the lower part of the face is distorted; a circumstance first noticed by Ribes, and which supplies an important diagnostic mark between a fracture of one condyle and a dislocation. In dislocation the chin is commonly thrown to one side, but it is to the side opposite that on which the dislocation has occurred, while in fracture the chin is drawn to the same side.

Prognosis.—In no instance of a simple fracture which has come under my personal care from the first, has the bone refused kindly to unite, although I have seen the union delayed six, seven, ten, and even eleven weeks or more.² In three of these cases the fractures were either compound or comminuted; but in one case the fracture was simple, the delay in union being due to a feeble condition of the system, and in part, perhaps, to neglect of proper treatment. Since the commencement of the late war I have met with several examples of non-union, and of fibrous union, after gunshot fractures; but, so far as I can remember, in all of these cases necrosis existed, or some portions of the bone had been carried away.

The infrequency of non-union after this fracture is a fact worthy of especial attention, because of the extreme difficulty, if not actual impos-

¹ Amer. Journ. Med. Sci., vol. xviii. p. 243.

² My Report on Deformities after Fractures, Cases 2, 14, 15, 18.

sibility, in many cases, of wholly preventing motion between the fragments, by any mode of dressing yet devised. Anyone who has observed attentively, must have seen, not only that his dressings are more often found disturbed and loosened than in the case of almost any other fracture, unless it be the clavicle, and thus the fragments have been through all the treatment subjected to frequent changes of position; but, also, that even while the dressings remain snugly in place, the patient seldom is able to perform the necessary acts of deglutition, so to speak, even without inflicting some slight motion upon the fragments.

Indeed, the rapidity as well as certainty with which this bone unites, has, I think, been observed by other surgeons, and I have myself noticed one instance, in an adult person, in which the bone was immovable at the seat of fracture on the seventeenth day, and perhaps earlier. In other instances the union has been speedily effected after the removal of all dressings.

Physick, of Philadelphia, saw a case of non-union of the body of this bone which had existed nine months.¹ Dupuytren mentions a case which had existed three years.² Stephen Smith, of New York, reports a case of fracture of both the body and the ramus, in a man forty-five years old. The severity of the injury, with the supervention of delirium tremens, prevented the application of dressings until the thirteenth day. On the twentieth day about a pint of blood was lost by hemorrhage from the seat of fracture. He remained in the hospital one hundred and thirty-seven days, and was finally discharged, the fragments not having yet united.³ I have seen four examples of fibrous union. In Dr. Muhlenberg's tables 16 examples are enumerated out of a total of 656 cases of non-union and delayed union.⁴

The amount of deformity resulting, also, from these fractures is usually very trifling, whatever treatment has been adopted. Only nine of the united fractures, seen and recorded by me, are imperfect, and in none of these is the imperfection such as to be noticed in a casual examination of the face. The deformity which is usually found, is a slight irregularity of the teeth, produced, in most cases, by a falling of the anterior fragment, but in one case by a slight elevation of the anterior fragment. But even this does not always interfere with mastication, and would often pass unnoticed by the patient himself. It is probable, too, that time, and the constant use of the lower jaw in mastication, will gradually effect a marked improvement in the ability to bring the opposing teeth into contact.

Packard, of Philadelphia, informs me that in a case of fracture of the lower jaw, occurring near the left anterior mental foramen, the right fragment was so forcibly displaced downward, by the action of the muscles, that he was obliged to sever their attachments at the symphysis, in order to retain the fragments in place. In the second example of fracture through the symphysis mentioned by me, the left fragment remained slightly elevated, and the patient could not close his teeth perfectly, yet he could close them sufficiently for the purposes of mastication. It is probable, however, that ordinarily no difficulty will be experienced in accomplishing a perfect cure when the separation has taken place only at the symphysis.

¹ Phila. Med. and Surg. Journ., vol. v.

² Leçons Orales.

³ Smith, New York Journ. of Med. and Surg., Jan. 1857.

⁴ Agnew's Surg., op. cit., vol. i. p. 804.

In fractures of the condyles more care is requisite to retain the fragments in apposition, and sometimes it may be found to be impossible.

Richerand mentions the case of a man, who, having been three months in the Hôpital de la Charité for a double fracture of the lower jaw, the fracture being near the middle, and the other near the right condyle, left before the cure was complete. Seven or eight months after, he called upon Boyer, who extracted, from a fistula in the meatus auditorius externus, a bony mass which had evidently the form of the condyle.¹ Bichat mentions a similar case as having come under the observation of Desault.² Ribes says that a Parisian surgeon treated a double fracture of the jaw in a gentleman, one fracture being through the body and the other through the neck of the condyle; and, in spite of the most assiduous and skilful attention, the patient recovered with a lateral distortion of the jaw, occasioned by the displacement of the fragments.³ Ribes himself had to treat an accident of a similar character, and, notwithstanding all his care, the result was the same as in the other example just cited.⁴

The proximity of this fracture to the articulating surface may occasion contraction of the ligaments about the joint; and a degree of embarrassment to the motions of the jaw has followed in the experience of Desault and others, even when the cure has been most complete; but this has usually remained only for a short period.

Sanson asserts that when the coronoid process is broken, the fracture never unites; but that mastication is performed very well, the masseter and pterygoid muscles then fulfilling the office of the temporal.⁵

Treatment.—The few attempts which I have made to restore a completely dislocated tooth to its socket, or to retain it in place when very much loosened, have generally resulted in its removal at some later day, and especially where the fracture has been near the angle and a molar has been disturbed. I believe it would be better practice always to remove the molars under these circumstances, unless they remain attached to the alveoli, and cannot be removed without bringing them away also; and this, whether the loosened teeth are situated in the line of fracture or not. It is seldom that they can be made again to occupy their sockets perfectly, and where the teeth are in the line of the fracture, the attempt to restore them to place will sometimes prevent the proper adjustment of the fragments. In cases, also, in which the teeth further forward are completely dislodged at the seat of fracture, it is scarcely worth while to replace them. As to those teeth whose loosened condition is due only to a splitting of the alveoli in a longitudinal direction, the same rule will not always apply. Sometimes, after a careful readjustment, the fragments will reunite, and the teeth remain firm.

If the bone is chipped off upon the outside, through or near the line of the sockets, the teeth may be not always much disturbed, and the loss of the fragments may be of less consequence, nor have I generally succeeded in saving them; yet, if they remain adherent to the soft parts, it is proper to make the attempt. The expedients to which surgeons have resorted for the purpose of retaining in place the fragments, when the

¹ Boyer, *Lectures on Dis. of Bones*, p. 53, Phila. ed., 1805.

² Desault, *Treatise on Fractures and Luxations*, Phila. ed., 1805, p. 3.

³ Malgaigne, *op. cit.*, p. 402.

⁴ *Ibid.*, p. 402.

⁵ S. Cooper's *First Lines*, Amer. ed., 1844, vol. ii. p. 311.

bone is broken through its body, may be arranged under the names of ligatures, splints, bandages, and slings.

The *ligature* has been applied both to the teeth and to the bone itself.

Thus, in an oblique fracture near the angle, where the fragments could not otherwise be prevented from falling inward, Baudens passed a strong ligature, formed of thread, around the fragments and in immediate contact with them, tying the ligature over the teeth within the mouth. No accident followed, and on the twenty-third day, when he removed the ligature, the bone had united firmly and smoothly.¹

Picharel and Béranger-Féraud have successively practised the same method in certain very oblique fractures of this bone, where it seemed impracticable to employ other means.²

In most cases, however, the ligature, when applied directly to the bone, has been employed as a suture, in the form of metallic wire.

In Dr. Buck's case the bone was broken between the two incisor teeth of the left side; the part of the bone on the left of the fracture was driven in, and interlocked behind the end of the right portion, so as to be separated by a finger's breadth. Finding it impossible otherwise to reduce the fracture, he dissected off the under lip, so as to expose the fracture; the right anterior portion of the fractured bone terminated in an angular projection as far as on a line below the left angle of the mouth; the lip was then divided to the chin, and the soft parts holding the fragments together incised; a chisel was then insinuated behind the projecting angle of the bone, while it was being excised by the metacarpal saw. When the bone was restored to its natural position, it was found so apt to become displaced that holes were drilled at the lower angle of the fracture, and adjustment maintained by wiring them together, the wire passing out through the lower angle of the wound. Sutures and adhesive straps, with a bandage, were employed to maintain the adjustment of the parts.³ Dr. R. A. Kinloch, of Charleston, S. C., has reported a similar case, in which he employed successfully the wire.⁴

While trephining at the angle of the jaw for the purpose of cutting out a portion of the dental nerve I accidentally broke the jaw at the point at which the trephine was applied. I immediately bored a hole in the opposite extremities of the two fragments, and fastened them together with a silver wire, by which I was able to maintain complete apposition, and in three weeks the union was accomplished, the wire separating and falling out of itself. No splints were ever used.⁵

A fracture of the inferior maxilla between the second bicuspid and second molar united with a fibrous band, and with a good deal of displacement. I operated, by making an external incision to the point of fracture, exposing the bone thoroughly, and, having freshened the broken surfaces, the fragments were perforated and secured in apposition with a silver wire, and a bony union was effected with but little displacement.

The perforations must be made perpendicularly, not obliquely through the fragments, and some distance from their margins. To withdraw the wire or to return it from within outward, an instrument with a straight shaft, rather smaller than the perforation, and furnished with an abruptly curved, blunt extremity, is required. The wire should be large, strong, and flexible, and the perforation should be twice as large as the wire.

¹ Malgaigne, op. cit., p. 398.

² Béranger-Féraud, *Traité de Immobilization direct*. Paris, 1870. (Poincet.)

³ New York Journ. of Med., etc., March, 1847, p. 211.

⁴ Kinloch, Amer. Journ. Med. Sci., July, 1859, p. 67.

⁵ Buffalo Med. Journ., xiv. p. 148.

[In compound fractures of the lower jaw, Thomas, of Liverpool, drills the bones on each side of the fracture, and fixes the fragments by means of thick, pliant silver wire. He coils the wire on each side with a key. (Figs. 36, 37, 38, and 39.)]

Ordinarily the ligature has been employed only as a means of retention, by fastening it upon the teeth, either upon those which are situated

FIG. 36.

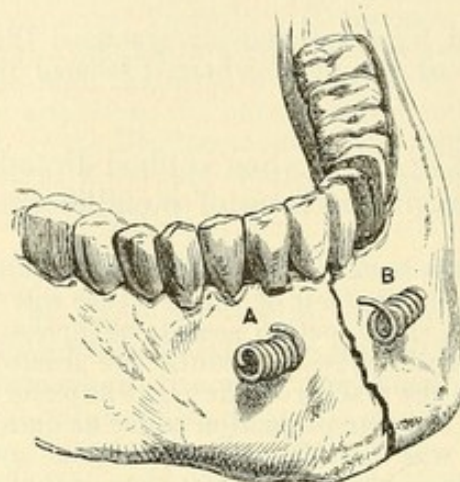



FIG. 37.



Thomas's first method of uniting fracture of the lower jaw; A, B, wires passed through drill-holes and coiled by the key.

FIG. 38.

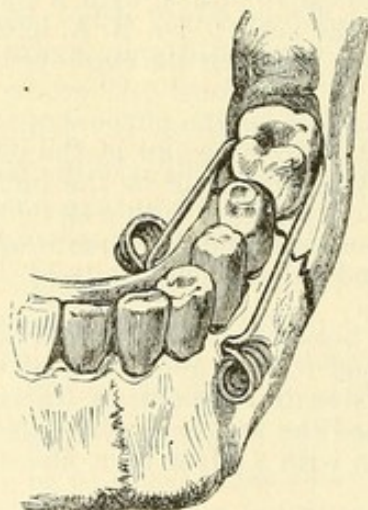
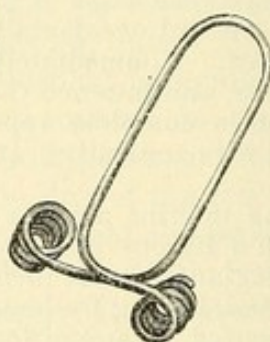


FIG. 39.



Thomas's second method of uniting fracture of the lower jaw by twisted and coiled wire.

on the opposite sides of the fracture, or upon others a little more remote, or upon the corresponding teeth of the upper jaw, or upon the teeth on the opposite side of the same jaw. In most cases the ligature, composed of either fine gold, platinum, or silver wire, or firm silk or linen threads, has been applied to the two teeth on the opposite sides of the fracture, or, if these have not been sufficiently firm, to the next teeth.

Dr. Ellis, of New York, treated a fracture, occurring through the symphysis, by placing the mainspring of a watch within the dental arcade, and securing it

in place with silver wire. The mouth was kept closed by bandages carried under the chin. The fragments united with only a slight vertical displacement.¹ Dr. Hayward, of Boston, says: When the bone is not comminuted and there are teeth on each side of the fracture, the ends of the bone can be kept in exact apposition by passing a silver wire or strong thread around these teeth, and tying it tightly. I have myself in two or three instances used a linen thread with excellent results.

[Dr. Brown,² of Minneapolis, has employed what is styled the anchor splint, originally used by Dr. Angle, a dentist of that city, to correct deformities of the teeth. Two or more firm teeth are selected on either side of the fracture and carefully banded with German silver made into a loop and slipped over the teeth; the band is caught by pliers and drawn tightly about the teeth; the bands are now removed, the ends clipped off and soldered, and again applied to the teeth, and hollow tubing or joint wire is placed against the bands, one on each side of the line of fracture, and marked at the point of contact. The bands are again removed, and the pipes are soldered to them. A traction screw made of hard-drawn German silver, is passed through the tubes and the nut started. A rubber drain is next applied to the teeth to keep them thoroughly dry, and the appliance slipped over the teeth and cemented in place by oxyphosphate of zinc. After this thoroughly sets the nut is tightened until the ends of bone are in place. This apparatus must be useful where the teeth are well set.]

None of these various methods, however, will in general be found to possess much value; for besides that they are all of them, in a large majority of cases, wholly unnecessary, and in other cases, owing to the absence of the teeth, or to their loosened or decayed condition, or to the closeness with which they are set against each other, absolutely impracticable, it must be seen, also, that they will generally prove feeble and inefficient. The wires act only upon the upper extremity of the line of fracture, leaving its lower portion liable to be disturbed by trivial causes; they tend gradually to loosen even the firm teeth which they embrace, and not unfrequently, after having been made fast with much labor, they soon become disarranged or break. They require, therefore, almost always the additional protection afforded by bandages, interdental splints, etc. Alone they are usually insufficient, and if properly constructed bandages, slings, interdental splints, etc., are employed, they are not needed. Sometimes, moreover, they are actually mischievous, as when they loosen a sound tooth or press upon and inflame the gums.

Splints have been employed in various ways. First, simply interdental splints, laid along the crowns of the teeth, and only sufficiently grooved to be easily retained in place; second, clasps, which are applied over the crowns and sides of the teeth, operating chiefly by their lateral pressure, or made fast by screws; third, splints applied to the outer and inferior margin of the jaw; fourth, interdental splints combined with outside splints. Interdental splints have been recommended by many surgeons from an early day, and they continue to be employed occasionally up to this moment.

The objections which have been stated to their use are: that they are unsteady and become easily loosened and disarranged; that they occasionally press painfully upon the inside of the cheeks; that they accu-

¹ Trans. Amer. Med. Assoc., vol. viii, p. 383. My Report on "Defor.," etc., Case 14.

² Med. Record, Oct. 6, 1888.

mulate about themselves an offensive sordes; and finally that they are unnecessary. Their great purpose is to act as splints whenever the absence of teeth, either in the upper or lower jaw, renders the two corresponding arcades unequal and irregular, and prevents our making use of the upper as a kind of internal splint for the lower jaw. Many of the inconveniences which have been found to attend the use of cork or wood, are obviated by the substitution of gutta-percha.

The mode of preparing gutta-percha, and of adapting it between the teeth, is as follows: Dip a couple of pieces of the gum, of a proper size, into hot water; and when they are softened, mould them into wedge-shaped blocks, and carry them to their appropriate places between the back teeth on each side of the mouth; taking care, of course, that on the fractured side the splint extends sufficiently far forward to traverse thoroughly the line of fracture. Now press up each horizontal ramus of the jaw until the mouth is sufficiently closed, and the line of the inferior margin is straight; in this position retain the fragments a few minutes, until the gum has well hardened. Meantime it will be practicable, generally, to introduce the fingers into the mouth, and to press the gutta-percha laterally on each side toward the teeth, and thus to make its position more secure. When it is hardened remove the splints, for the purpose of determining more precisely that they are properly shaped and fitted. In carrying the long wedge-shaped block into the mouth, the apex of the wedge is to be introduced first. If properly made, it is smooth upon its surface, and not, therefore, so liable to irritate the mouth as wood or cork, and it is so moulded to the teeth that it will never become displaced. It possesses this advantage, also, that in case more or less of the teeth are gone in either the upper or lower jaw, it fills up the vacancies, and renders the support uniform and steady.

The "clasp," applied over the crowns and sides of teeth, is not intended to act as an interdental splint; but by its lateral pressure it is expected to hold the fragments in apposition upon nearly the same principle with the ligature.

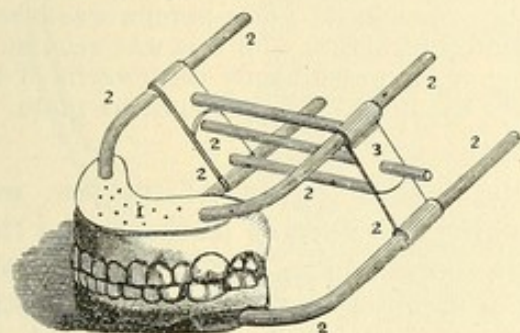
Mütter, of Philadelphia, and N. R. Smith, of Baltimore, employed for this purpose a plate of silver, folded snugly over the tops and sides of two or more teeth adjacent to the fracture. Nicole, of Neubourg, employed for the same purpose a couple of steel plates fitted accurately along the anterior and posterior dental curvatures, secured in place by a steel clasp, furnished with a thumb-screw, in order the more effectually to accomplish the lateral pressure.

Malgaigne substituted a single plate composed of flexible and ductile iron, which is fitted accurately to all the irregularities of the posterior dental arch. From the two extremities of this plate, and from two other intermediate points, four small steel shafts arise perpendicularly, cross the crowns of the teeth at right angles, and then fall down again perpendicularly upon the anterior dental arcade. Each steel shaft being furnished with a thumb-screw, the iron plate can now be made to bear against the teeth so as to form a posterior dental splint. The teeth are also protected in front against the direct action of the thumb-screw by the interposition of a leaden plate. J. B. Gunning, dentist, of New York, substituted vulcanized India-rubber, which he employs both as a clasp and an interdental splint. Dr. Covey¹ states that the same material has been used with excellent results by J. B. Bean, dentist, of Atlanta, Ga., as follows: An impression is taken in wax of the crowns of the teeth of the uninjured jaw, and of each fragment separately of the broken jaw. "From these impressions are made casts of plaster-of-Paris, very carefully prepared, so as to produce a smooth, hard surface, and giving as perfect a representation of the teeth as possible. These plaster models are then adjusted, properly antagonized in their normal position, and placed in the 'maxillary articulator.' (Fig. 40.) The fragments of the model representing the broken jaw are held in their proper position by wax, being

¹ Bean, Richmond Med. Journ., Feb. 1866.

secured thus one to the other, and to the remaining plate of the articulator." . . . The model jaws are now opened from three to five lines, and a wax model of a splint is built up between the molars, covering also the inner and

FIG. 40.



Maxillary Articulator.

- 1, 1. Upper and lower plates.
- 2, 2. Adjustable rods.
- 3, 3. Adjustable hinge.

FIG. 41.

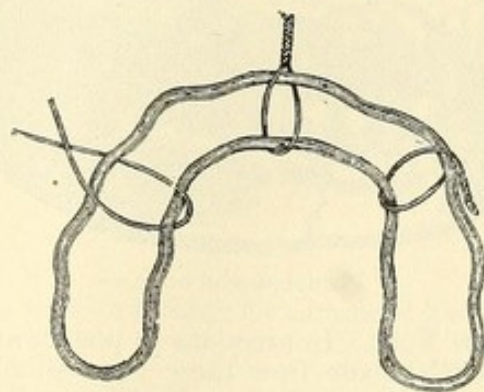


Bean's apparatus for broken jaw, applied.

outer surfaces of the teeth. A connecting band of wax is laid from one side to the other behind the upper front teeth, leaving thus an opening in front for the reception of food. This wax and plaster model, now composing one piece, is then removed from the articulator, and placed in a dentist's "flask," and a complete mould of the model is again formed from plaster laid on in sections, in a manner which those accustomed to make plaster moulds will readily understand. The plaster having fairly set, the flask and mould are opened, the wax carefully removed, and the spaces thus left in the mould at once filled with the rubber rendered soft by heat. The mould is again closed, replaced in the flask, and by heat the rubber is thoroughly vulcanized. The flask is again opened, the plaster removed, and an interdental splint of rubber remains, which is fitted accurately to all the surfaces of the teeth both above and below. The splint is now placed in the mouth, adjusted to the teeth, and the lower jaw secured in position by the apparatus represented in Fig. 41.

[An interdental splint, invented by Mr. G. E. Hammond, has, according to Jacobson, replaced wiring the fragments at Guy's Hospital. Pick also regards it as the most satisfactory interdental splint of the various forms in use. "The splint consists of a framework or collar of iron, which is adapted to the fractured jaw, encircling the necks of the teeth, and to it they are fastened with loops of iron wire. The essential point in the application of the splint is that the collar of iron wire should accurately fit the outline of the jaw, so that it shall remain in the position in which it is placed; otherwise it will probably defeat the object for which it is intended. In order, therefore, to frame it, it is necessary to take a cast of the teeth, on which to model the collar. . . . When moulded it will present somewhat the outline represented in Fig. 42. The collar is to be applied to the teeth of the patient, and fixed, in the manner shown in the diagram, by several pieces of fine, soft wire, the wire being never

FIG. 42.



Hammond's splint.

carried more than one tooth. The wires on each side of the mouth are twisted alternately, and the twisted ends are cut short and turned down under the iron framework, so as to prevent their sticking into or injuring the mucous membrane." The figure shows the collar of metal moulded to fit the teeth of the lower jaw, and the manner of tying the teeth to the metal collar.¹

Newland-Pedley, dental surgeon to St. Thomas's Hospital, London, has recently employed Gunning's dressing with much success. In multiple fractures of the body of the jaw it furnishes a uniform support scarcely secured by any other dressing.]

Dr. J. S. Prout, of Brooklyn, has suggested a mode of employing the interdental splint and wire ligature conjointly. A plate of gutta-percha was placed upon the top of the teeth across the line of fracture, and this was secured in position by silver wire, which had been made to grasp firmly the crowns of the adjacent teeth, and was then brought over the horizontal gutta-percha plate. It accomplished all that was desired.

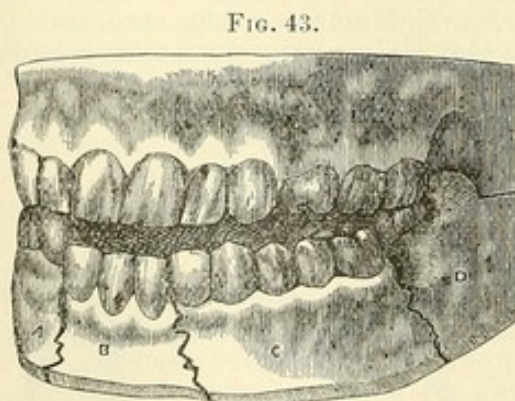
External splints, applied along the base or outside of the jaw, were first recommended by Paré, who used for this purpose leather; and they have been employed in some form, occasionally, by most surgeons. Generally they have been composed of flexible materials, such as wetted pasteboard, first recommended by Heister, felt, linen saturated with the whites of eggs, paste, dextrine, or starch; plaster-of-Paris has also been used; and they have been retained in place by either bandages or the sling. Undoubtedly useful, and even necessary in some cases, especially where there exists a great tendency to a vertical displacement, they will be found, also, in many cases, to render no essential service, and may properly enough be dispensed with.

[J. W. Cousins, surgeon to the Portsmouth Hospital, applies an apparatus which consists of a steel splint encircling the neck, being horseshoe-shaped, and the ends on either side terminate in a loop which supports a movable pad, the pressure of which is regulated by a screw; a webbing extends from loop to loop under the chin, and another passes from side to side over the forehead and is supported by a central strap attached behind to the splint. This splint is recommended in severe cases, as in multiple fracture.²]

Whatever objections hold to the use of metallic clasps, must apply in some degree to the use of those forms of apparatus in which it is attempted to secure the fragments by means of a combination of these clasps with outside splints,

and in which it is proposed to dispense with all bandages or slings, the mouth being permitted to open and close freely during the whole treatment. Motion of the jaw cannot be permitted in any case where the fracture is far back, since it is then impossible to grasp the posterior fragment between the two parallel splints. Nothing but complete immobility of the jaw will now insure immobility to the fracture.

If I were to recommend any form of apparatus constructed with a view of permitting mobility of the jaws during the process of union, it would be that invented by Kingsley, dentist, of



Plaster model of jaws.

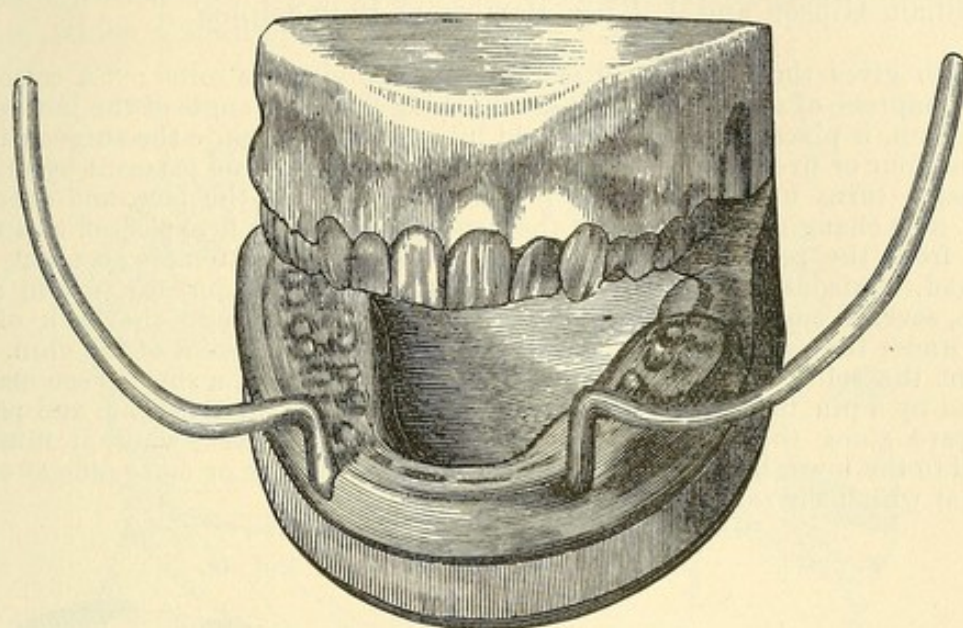
New York. Impressions in plaster are first taken of both upper and lower jaws. Models made from these impressions will represent the lower jaw broken and the fragments displaced. The model of the lower jaw is then separated at the point representing the fracture, and the fragments adjusted to the model of the

¹ Pick, *Fract. and Disloc.*

² *London Lancet*, Sept. 29, 1888.

upper jaw. In most cases the position which these fragments assume when thus placed determines accurately the original form and position of the lower jaw. Upon the plaster model of the lower jaw, obtained and rectified in this

FIG. 44.



Kingsley's apparatus applied to model. (From KINGSLEY.)

way, a splint or clasp of vulcanite rubber is then made, embracing the arms, which are made of steel wire, one-sixteenth of an inch in diameter. The arms

FIG. 45.

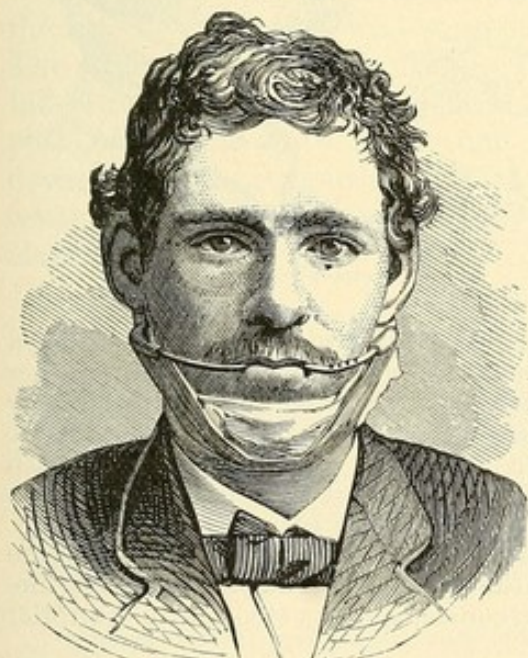
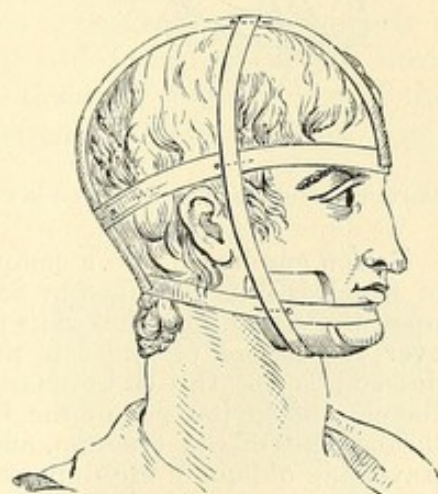
Kingsley's apparatus applied to patient.
(From KINGSLEY.)

FIG. 46.



Gibson's bandage for a fractured jaw.

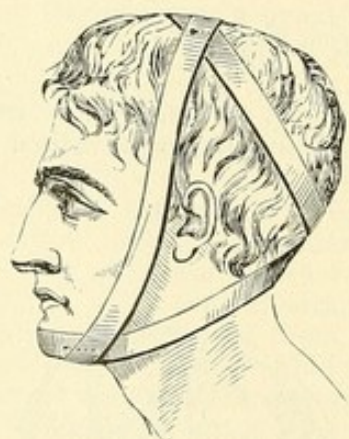must curve upward a little as they emerge from the mouth, to avoid pressure upon the lips, and then curve backward, terminating near the angles of the jaw. When the apparatus is applied, the teeth must be pushed into the sockets

of the splint with some force. The dressing is now completed by a sling made of strong muslin, extending beneath the chin from one arm to the other.

The treatment of fractures of the inferior maxilla by a single-headed bandage or roller, numbers among its distinguished advocates the names of William Gibson and J. Rhea Barton, of Philadelphia.

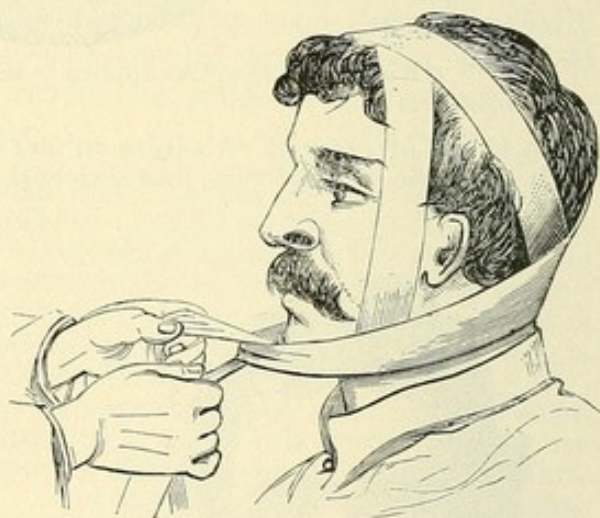Gibson gives the following directions for applying his roller: "A cotton or linen compress, of moderate thickness, reaching from the angle of the jaw nearly to the chin, is placed beneath, and held by an assistant, while the surgeon takes a roller, four or five yards long, an inch and a half wide, and passes it by several successive turns under the jaw, up along the sides of the face, and over the head; now changing the course of the bandage, he causes it to pass off at a right angle from the perpendicular cast, and to encircle the temple, occiput, and forehead, horizontally, by several turns; finally, to render the whole more secure, several additional horizontal turns are made around the back of the neck, under the ear, along the base of the jaw, under the point of the chin. To prevent the roller from slipping or changing its position, a short piece may be secured by a pin to the horizontal turn that encircles the forehead, and passed backward along the centre of the head as far as the neck, where it must be tacked to the lower horizontal turn—taking care to fix one or more pins at every point at which the roller has crossed."

FIG. 47.



Barton's bandage for a fractured jaw.

FIG. 48.



Garretson's bandage.

Barton employed, also, a compress, and a roller five yards long, the application of which is thus described by Sargent: Place the initial extremity of the roller upon the occiput, just below its protuberance, and conduct the cylinder obliquely over the centre of the left parietal bone to the top of the head; thence descend across the right temple and the zygomatic arch, and pass beneath the chin to the left side of the face; mount over the left zygoma and temple to the summit of the cranium, and regain the starting-point at the occiput by traversing obliquely the right parietal bone; next wind around the base of the lower jaw on the left side to the chin, and thence return to the occiput along the right side of the maxilla; repeat the same course, step by step, until the roller is spent, and then confine its terminal end.

These bandages possess the advantages of being easily obtained, of simplicity and facility of application, and, we may add, if considered in relation to the majority of simple fractures, of tolerable adaptation to the ends proposed. The only objections to their use which I have ever noticed are occasional disarrangements, and the tendency, as in all other

continuous rollers, to draw the fragments to one side or the other, according as the successive turns of the bandage are carried to the right or left. There is one other objection, having reference to the occasional inadequacy of this dressing to prevent an overlapping of the fragments; to which objection also the sling, as usually constructed, is equally obnoxious, and of which I shall speak presently.

FIG. 49.

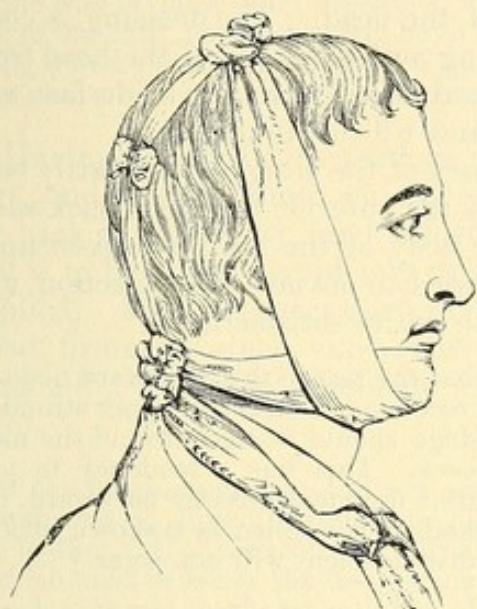
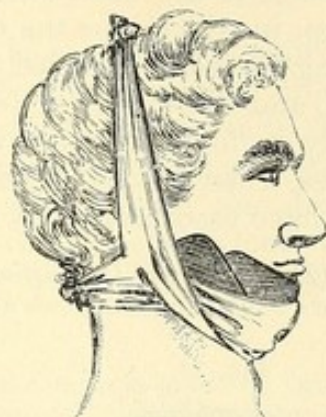

FIG. 50.



Four-tailed bandage or sling for the lower jaw. Gutta-percha or pasteboard splint applied.

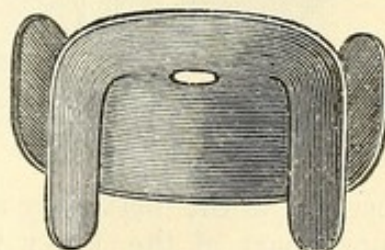
Finally, it is to the sling, in some of its various forms, with or without the interdental splint, that surgeons have generally given the preference. The sling is known, also, by the name of the four-headed or the four-tailed roller or bandage. The favorite mode is to use for this purpose a piece of muslin cloth about one yard long and four inches wide, torn down from its extremities to within about three or four inches of the centre. Others have used leather, gutta-percha, adhesive straps, gum-elastic, etc.

FIG. 51.



Gutta-percha cut into proper shape for splint.

FIG. 52.



Gutta-percha folded for splint.

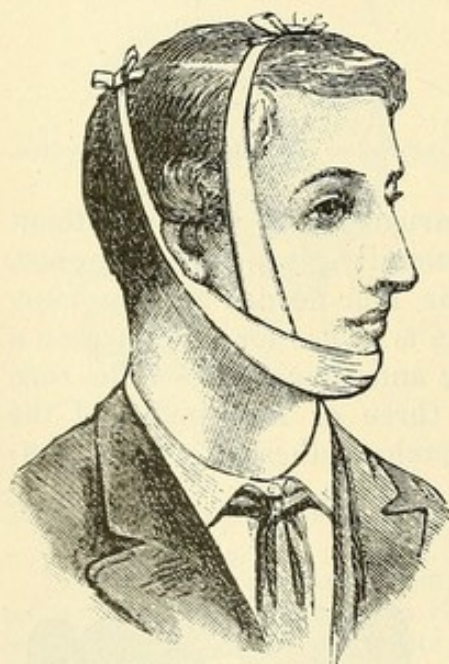
[Pick (*Fractures and Dislocations*) very correctly advises to avoid the splint, if possible, for it is uncomfortable to the patient from retaining perspiration, and often becomes dirty and sodden from the dribbling of the saliva, and if there is any bruising or injury of the soft parts may, by the pressure which it causes, produce suppuration. The gutta-percha and pasteboard are cut and folded as seen in Figs. 51 and 52.]

Where the muslin is used, it is quite customary to lay against the skin a piece of pasteboard, wetted and moulded to the chin, or simply a soft compress; and some choose to open the centre of the bandage sufficiently to receive the chin. The middle of this bandage being laid upon the chin, the two ends corresponding to the upper margin of the roller are now carried across the front of the chin, behind the nape of the neck, and made fast; whilst the two lower heads are brought directly upward from under the sides of the chin, along the sides of the face, in front of the ears, and made fast upon the top of the head. The dressing is completed by a short counter-band extending across the top of the head from one bandage to the other; or the several bands may be made fast to a night-cap, in which case the counter-band will be unnecessary.

Having frequently noticed the tendency of the sling, as ordinarily constructed, and of Gibson's roller, to carry the anterior fragment backward, especially in double fracture where the body of the bone is broken upon both sides, I devised an apparatus intended to obviate this objection, and which I have used now many times with entire satisfaction.

[Pick (*Fractures and Dislocations*) states that the reason this backward dislocation occurs is because surgeons are wont to recommend that the upper strand of the bandage should be tied around the nape of the neck. This has a tendency to pull the anterior fragment directly backward, but if the bandage is applied as is shown in Fig. 53 this displacement will not occur.]

FIG. 53.



Manner of applying the four-tailed bandage.

It is composed of a firm leather strap, called maxillary, which, passing perpendicularly upward from under the chin, is made to buckle upon the top of the head, at a point near the situation of the anterior fontanelle. This strap is supported by two counter-straps, made of strong linen webbing, called, respectively, the occipito-frontal and the vertical. The occipito-frontal is looped upon the maxillary at a point a little above the ears, and may be elevated or depressed at pleasure. The occipital portion of the strap is then carried backward, and buckled *under* the occiput, while the frontal portion is buckled across the forehead. The vertical strap unites the

occipital to the maxillary across the top of the head, and prevents the upper part of the latter from becoming displaced forward. At each point where a buckle is used, a pad must be placed between the strap and the head. The maxillary strap is narrow under the chin, to avoid pressure upon the front of the neck, but immediately becomes wider, so as to cover the sides of the inferior maxilla and face, after which it gradually diminishes, to accommodate the buckle upon the top of the head. The anterior margin of this band, at the point corresponding to the symphysis menti, and for about two inches on each side, is supplied

with thread-holes, for the purpose of attaching a piece of linen, which, when the apparatus is in place, shall cross in front of the chin, and prevent the maxillary strap from sliding backward against the front of the neck.

The advantage of this dressing over any which I have yet seen, consists in its capability to lift the anterior fragment almost vertically, whilst at the same time it is in no danger of falling forward, and downward upon the forehead. If, as in the case of most other dressings, the occipital stay had its attachment opposite to the chin, its effect would be to draw the central fragment backward. By using a firm piece of leather as a maxillary band, and attaching the occipital stay above the ears, this difficulty is completely obviated.

Having removed such teeth as are much loosened at the point of fracture, and replaced those which are loosened at other points, unless it be far back in the mouth, and adjusted the fragments accurately, the lower jaw is to be closed completely upon the upper, and the apparatus snugly applied. It is not necessary in most cases to buckle the straps with great firmness, since experience has shown that a sufficient degree of immobility is usually obtained when the apparatus is only moderately tight.

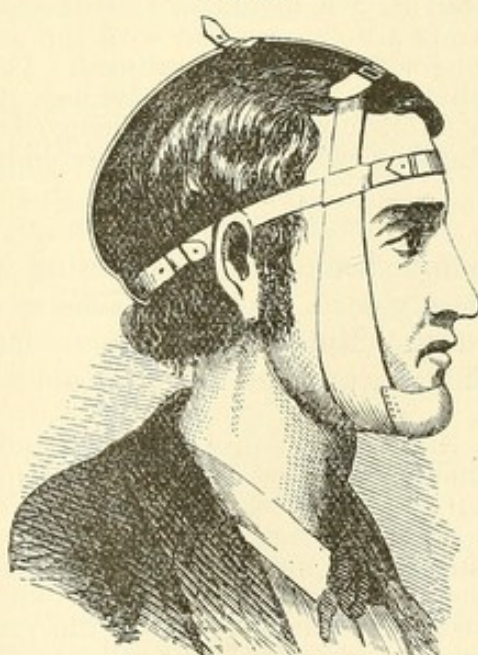If the integuments are bruised and tender, a compress made of two or more thicknesses of sheet lint should be placed underneath the chin, between it and the leather. If the inability to introduce nourishment between the teeth when the mouth is closed, or the irregularity of the dental arcade renders the use of interdental splints necessary, gutta-percha ought, in general, to be preferred to any other material.

The patient must be forbidden to talk or laugh, and when he lies down, his head should rest upon its back, for whatever mode of dressing is employed, and however carefully it is applied, it will be found that a slight motion and displacement will occur whenever the weight of the head rests upon the side of the face.

Occasionally, indeed as often as every two or three days, the apparatus may be loosened or removed, only taking care generally not to disturb the interdental splints, when they are used, and to support the jaw with the hand, during its removal; and, at the same time, the face may be sponged off with warm water and castile soap. It should not be left off entirely, however, in less than three or four weeks, even where the fracture is most simple, nor ought the patient be allowed to eat meat in less than four or five weeks.

To cleanse the mouth and prevent offensive accumulations, it should be washed several times a day with a solution of tincture of myrrh, prepared by adding one drachm to about four ounces of water.

FIG. 54.



The author's apparatus.

The same apparatus, and without any essential modification, is applicable to fractures of the symphysis and of the angle of the inferior maxilla, as well as to fractures of the body of the bone.

Instead of the leather, I have in a few instances, especially of compound fractures where it became necessary to allow the pus to discharge externally, used a sling or a splint composed of gutta-percha, suspended by bands carried over the top of the head. The piece from which this splint is made should be three or four lines in thickness, covered with cloth, and padded under the chin. It will be found convenient to cover it with cloth before immersing it in the hot water. The water should be nearly at a boiling temperature, so that the splint may become perfectly pliable; and it should be laid upon the face and allowed to mould itself while the patient lies upon his back. Having thus fitted it accurately to the face, it may be removed and openings made at points corresponding with the wounds upon the skin, before it is reapplied.

As has been already explained, the gutta-percha, if sufficiently thick, and if the lateral wings are allowed to project a little on either side, will serve effectually to protect the sides of the face against pressure from the bandage; and being more easily moulded to the base and front of the chin than any other material which has yet been employed, must have the preference. The necessity for its use, however, is only occasional.

Dr. S. O. Vander Poel¹ has employed successfully a modification of my apparatus, made of plaster-of-Paris bandage. The apparatus having been applied over a linen nightcap, and having been permitted to harden, the maxillary straps are cut on a line with the ears, or portions removed and pieces of webbing with buckles substituted. The pieces of webbing may be fastened with stitches or with plaster. Perhaps it would be quite as well to leave the bandage as at first applied until a change becomes necessary—possibly a week or two—and then cut and insert the webbing.

In fractures of either condyle, unaccompanied with displacement, the simple leather or muslin sling will sometimes accomplish a perfect and speedy cure, as the two cases reported by Desault will sufficiently demonstrate. But if the fragments have become separated, the replacement is difficult, and the retention uncertain.

Ribes was the first to suggest and to practise a very ingenious method of reduction in these cases. Malgaigne thus describes his procedure: "With the left hand seize the anterior portion of the jaw, for the purpose of drawing it horizontally forward, while you carry the index finger of the right hand to the lateral and superior part of the pharynx. You will meet at first the projection formed by the styloid process, but, moving your finger forward, you will find soon the posterior border of the ramus of the jaw; and following this border from below upward, you will arrive at the inner side of the condyle, which you will push outward in such a manner as to engage it upon the other fragment. This manœuvre cannot be made without causing nausea, as the finger always does when carried into the posterior part of the pharynx; but this is a slight inconvenience. The reduction obtained, bear the jaw upward and backward in order to press and fix the condyle between it and the glenoid cavity, then fasten it in place with a sling. In addition to these means, the angle of the jaw ought to be pressed permanently forward by means of a compress placed between it and the mastoid process, and held in place by a suitable bandage; or we may

¹ Vander Poel, Archives of Clinical Surgery, Jan. 1, 1878.

adopt the method which proved so successful with Fountain, namely, wire the front teeth of the lower jaw to the front teeth of the upper in such a manner as to draw the chin forward, and thus maintain apposition.

If the coronoid process be alone broken, it is sufficient to close the mouth with any form of sling or bandage which may be most convenient.

In cases of *delayed or non-union* of the fragments, we may resort to the wire ligature, or to any other of those expedients described.

In Dr. Muhlenberg's tables, 14 cases are recorded. Of 7 treated by mechanical appliances, 5 were cured, 1 was relieved, and 1 died; and of 7 treated by drilling, with its modification, all were reported cured.

CHAPTER XIV.

FRACTURES OF THE HYOID BONE.

POINSOT collected eleven cases. An analysis of these, with the eleven cases recorded by me, shows that the fracture was caused by hanging, five times; by grasping the throat between the thumb and fingers, six times; by direct blows, eight times; and by muscular action, three times.¹

The observation of Mr. South, that fracture of this bone "is almost invariably found"² in persons executed by hanging, is probably incorrect, since although a large proportion of these subjects are submitted to dissection in this and other countries, yet I know of but these three examples which have been published.

The body of the bone seems to be broken in all of those cases in which fracture resulted from hanging; while in all of the other examples the fracture has occurred in one of the great horns, or at the junction of the horns with the body. Generally the displacement inward of one of the fragments has been so complete that crepitus could not be detected. In two instances the mucous membrane had been penetrated, and in one the fragment was projected between the epiglottis and rima glottidis.

The following cases illustrate some of the peculiarities of this fracture: M. Orfila has reported the case of a man, aged sixty-two years, who had been hanged, and whose os hyoides was broken through its body on its right side. M. Cazauvieilh has also seen a fracture of this bone in two persons who had been hanged, in one of whom the fracture was probably in the body of the bone, and in the other through one of its cornua.³ Lalesque relates (*Journal Hebdomadaire*, March, 1833) the case of a marine "who, in a quarrel, had his throat violently clinched by the hand of a vigorous adversary. At the moment there was very acute pain, and the sensation of a solid body breaking. The pain was aggravated by every effort to speak, to swallow, or to move the tongue, and when this organ was pushed backward, deglutition was impossible. The patient could not

¹ Poinso, Note to French edition of this treatise, p. 149.

² Note to Chelius's Surgery, Amer. ed., vol. i. p. 581.

³ Traité de Méd. légale, troisième éd., tom. ii. p. 423.

⁴ Cazauvieilh, du Suicide, etc., p. 221.

articulate distinctly; and he was unable to open his mouth without exciting a great deal of pain. He placed his hand upon the anterior and superior part of his neck to point out the seat of the injury. This part was slightly swollen, and presented on each side small ecchymoses; one above, more decided, immediately under the left angle of the lower jaw. The large cornu of the os hyoides was very distinctly to the right side," and it could be felt on the left deeply seated by pressing with the fingers; in following it in front toward the body of the bone, a very sensible inequality near the point of junction of these two parts could be perceived. By putting the finger within the mouth, the same projections and cavities inverted could be felt, and even the points of the bone which had pierced the mucous membrane, etc., were evident. Having placed a plug between his teeth to keep the mouth open, the broken branch was brought by the finger back to the surface of the body of the bone, and easily reduced. The position of the head, inclined a little back, rest, absolute silence, composed the after-treatment. To avoid a new dislocation by the efforts of swallowing, the œsophagus-tube of Desault was introduced, to conduct the drinks and liquid aliments into the stomach; this sound was allowed to remain until the twenty-fifth day; at this time the patient could swallow without pain, and began to take a little more solid nourishment, and at the end of two months the cure was complete. By placing a finger within his mouth, a slight nodosity could be felt in the place where, in the recent fracture, the splintered points were perceptible.¹

Dieffenbach recorded a fracture of the great right horn, produced in the same manner, by grasping the throat between the thumb and fingers, which occurred in a girl only nineteen years old. Very slight pressure upon the side of the bone was sufficient to move the fragment inward, and to produce a crepitus; but it immediately resumed its place when the pressure was removed. There being no displacement, the cure was effected in a short time without resort to any remedies. She was not even forbidden to speak.² Auberge saw a similar case in a person fifty-five years old, occasioned by grasping the throat. The fracture was in the great horn of the right side, and the displacement was so complete that crepitus could not be felt, and the mucous membrane of the pharynx was penetrated by the broken bone.³

Dr. Wood, of Cincinnati, examined a fracture of the os hyoides that had occurred about one week before. The patient, a female, had fallen down the cellar-steps, striking the prominent parts of the larynx and hyoid bone against a projecting brick, severely injuring the larynx as well as fracturing the bone. The fracture was on the left side, and near the junction of the great horn with the body of the bone. Crepitus was distinctly felt on pressing the bone between the thumb and finger; or when the patient would swallow; though, at this time, the severe symptoms that followed the accident, and continued for several days, had somewhat subsided. Immediately after the accident there was profuse bleeding from the fauces, and she experienced great difficulty and pain in the act of swallowing, and the power of speech was almost entirely lost. On attempting to depress or protrude the tongue, she felt distressing symptoms of suffocation. Considerable inflammation and swelling of the throat and larynx ensued. In about four weeks the patient had so far recovered as to be able to converse, though the voice was somewhat impaired. She was yet unable to swallow solid food, and was wholly sustained by fluids.⁴ Marcinkovsky saw a woman in whom both the lower jaw and the left horn of the os hyoides were broken by a fall from her carriage against a wall. She died in about twenty-four hours, from suffocation.⁵ Dr. Gründer reports the following: "A laborer, æt. sixty-three, fell from a wagon on his face, and discharged a large quantity of blood by the mouth. He found he could not swallow, and when seen twelve hours afterward, complained of severe pain in the neck and nape, with inability to turn his head, though no injury of the vertebræ could be detected. His voice was hoarse and difficult. On attempting to drink, the fluid

¹ Amer. Journ. Med. Sci., vol. xiii. p. 250.

² Medic. Vereinszeitung für Preussen, 1833, No. 3; Gazette Méd., 1834, p. 187.

³ Revue Méd., July, 1835.

⁴ Western Lancet; also N. Y. Journ. Med., vol. xv. p. 152.

⁵ Medic. Vereinszeitung für Preussen, 1833, No. 15; Gazette Médicale, 1833, p. 354.

was rejected with violent coughing, the patient declaring he felt it as if entering the air-passages. An examination of the fauces led to no explanation of this condition. The epiglottis did not, however, appear to close completely the larynx, or to be in its exact position. The tongue was movable in all directions, and pressing it down with a spatula caused no inconvenience. The hyoid seemed to possess its continuity. No crepitation or abnormal mobility could be perceived, and no pain at the root of the tongue occurred on attempting to swallow. After repeated examinations, the case was concluded to be one in which the functions of the nervus vagus had undergone great disturbance, or the muscles of the larynx had become torn or paralyzed. Medicine and food were administered by means of an elastic tube. The patient had a good appetite and slept well; the pain of the neck was lost, and its motion recovered; a hectic cough, from which he had long suffered, alone remaining. After continuing, however, to go on thus well for six days, the cough increased; the appetite failed; strength was lost; the voice was scarcely audible; and in five more days the patient died exhausted. At the autopsy a fracture of the *os hyoides* was found. One of the large cornua was broken, and had become firmly imbedded between the epiglottis and rima glottidis, inducing the raised position of the epiglottis, loss of voice, and difficulty in swallowing."¹ A woman, fifty-six years old, made a misstep and fell backward, and at the same moment that her head was thrown violently back, she felt distinctly a sensation as if a solid body had broken, in the upper part of her neck and upon its left side. An examination showed that she had fractured the great left horn of the *os hyoides*. Inflammation and suppuration followed, and finally, after about three months, the posterior fragment made its way out in a condition of necrosis, and the fistula promptly healed, but there remained for many years a sense of uneasiness about these parts when she swallowed, sometimes amounting to pain.²

James G. La Roe, of Greenpoint, N. Y., has reported the case of a man *æt.* twenty-seven, in whom the right cornu was broken at its junction with the body in the act of gaping. During fifteen or twenty days he was unable to swallow either liquids or solids, except in very small quantities. Complete rest was enjoined, and he was permitted to hold his head in that position which he found most comfortable, inclining to the right and forward. He made a complete recovery.³

Symptoms.—The accident has been characterized by a sudden sensation as if a bone had broken; in a few instances, by profuse bleeding from the fauces; by difficulty in opening the mouth; by impossibility of deglutition, and by loss of voice in others; with great pain in moving the tongue, the pain being especially at its root; in one instance the tongue was perceptibly drawn to one side. There is usually more or less swelling and soreness about the neck, with ecchymosis; and at a later period, cough, expectoration, hoarseness, etc. The circumstances which, however, indicate certainly the nature of the accident, are preternatural mobility of the fragments, with or without crepitus, and the angular inward projection, which may in most cases be distinctly felt in a careful examination of the pharynx. In the case related by Gründer, the only symptoms were a loss of voice, difficulty of deglutition, and a sensation, when the attempt was made to swallow, as if the fluids passed into the windpipe; with also an imperfect closure of the epiglottis upon the rima glottidis. No preternatural mobility or irregularity in the fragments could be detected, nor was there crepitus, and it was concluded that the bone was not broken, yet the autopsy showed that the fragment was imbedded deeply between the epiglottis and the rima glottidis.

¹ Schmidt's *Jahrbuch.*, vol. lxxviii.; also *Amer. Journ. Med. Sci.*, vol. xlix. p. 253, Jan. 1852.

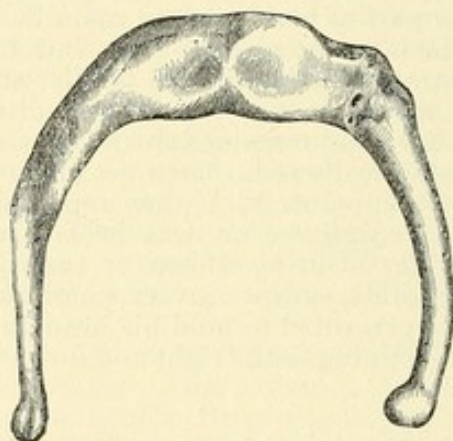
² Malgaigne, *op. cit.*, p. 405.

³ La Roe, *Med. Record*, April 15, 1882.

Prognosis.—It is only in view of its complications that this accident can be regarded as serious; where the severity of the injury has been such as to fracture the lower jaw at the same time, as in the case related by Marcinkovsky, or such as to bury the fragment deep in the tissues about the rima glottidis, as in the case mentioned by Gründer, a favorable termination could scarcely have been expected. Five of the eleven recorded by me have died; but of these, three have died by hanging, and the remaining two from the causes named. Of the three in which the accident resulted from a direct blow, only the patient of Dr. Wood, of Cincinnati, has survived; while of the three whose fractures resulted from lateral pressure upon the cornua, all recovered; so, also, did the two patients in whom the fracture was produced by muscular action.

[Union by callus has been demonstrated in several cases, as in the example given by Gurlt, where the fracture was through the right greater cornu.]

FIG. 55.



United fracture of the hyoid bone.

Treatment.—No doubt when the fragments are displaced an attempt ought to be made to replace them by introducing one finger into the mouth, while with the opposite hand the fragments are supported from without. Lalesque found this a matter of some difficulty, but Auberge experienced no difficulty at all. The degree of difficulty will very much depend upon the degree of displacement, and the consequent lacerations of the soft tissues about the bone. But however this may be, it must be altogether another thing to be able to keep in exact apposition the broken ends of a bone whose diameter is so inconsiderable, and upon which it is quite impossible to apply any apparatus or dressings to retain the fragments in place. Lalesque threw the head of his patient slightly back, with the view of making "permanent extension" upon the fragments through the action of the muscles and ligaments attached to the bone, and he recommends this position as that which is best calculated to preserve the coaptation. Malgaigne, on the contrary, without having himself seen any example of this fracture, believes that the position of flexion of the neck, with entire relaxation of the muscles, would be most suitable; and this was the position in which La Roe's patient found himself most comfortable.

[Pick¹ directs the patient to be placed in a "bed-chair," with the head thrown slightly back, and fixed in this position by a coronal bandage and two braces passing to the shoulder on either side, as is employed in cases of cut-throat. The neck should be encircled by a collar made of soft chamois-leather spread with adhesive plaster and evenly applied.]

In all cases it will be proper to enjoin silence, and to adopt suitable measures to combat inflammation, such as topical bleeding, fomentations, moistening the mouth with cool water, or permitting small pieces of ice to rest in the mouth until dissolved, without in general allowing the fluid to be swallowed; but in some examples, no doubt, the patient may be permitted to swallow. In case the life of the patient is in danger from starvation, the surgeon may be compelled to resort to nutritious enemata, or possibly to the use of the stomach-tube. The latter method is liable to the serious objection that the tube is apt to cause irritation. When asphyxia is threatened, laryngotomy or tracheotomy may be demanded.

CHAPTER XV.

FRACTURES OF THE CARTILAGES OF THE LARYNX.

THE following summary of 62 cases of fracture of the laryngeal cartilages is compiled from the 52 cases collected by Hénocque, and 10 additional cases collected by Durham:²

Cartilages fractured.	No. of Cases.	Deaths.	Recoveries.
Thyroid only	24	18	6
Cricoid only	11	11	
Thyroid and os hyoides	4	2	2
Thyroid and cricoid	9	9	
Thyroid, cricoid, and os hyoides	2	2	
Thyroid, cricoid, and trachea	2	2	
Cricoid and trachea	2	2	
Cricoid, trachea, and os hyoides	1	1	
"Fractures of larynx"	7	3	4
	62	50	12

General Etiology of Fractures of the Laryngeal Cartilages.—As a predisposing cause, advanced age, with its usual concomitant, partial or complete ossification of the cartilages, has been thought to occupy a prominent place.

In the case reported by Plenck, the cartilages were already very much ossified, although the subject was only thirty-seven years old. Morgagni observed that in his experience it had occurred always in advanced life. In my own case, however, the cartilages were only slightly ossified, the patient being forty-one years old; nor did the lines of the several fractures indicate a preference for the bony plates; but it seems to me that they rather avoided them, and in the case of the incomplete fracture the bone appeared to have arrested the fracture. In

¹ Fract. and Disloc.

² Malgaigne, op. cit., p. 408.

fact, a few experiments have satisfied me that the adult laryngeal cartilages are quite as brittle as bone, and, consequently, that ossification in no way increases their liability to fracture. Hunt ascertained the age in fifteen cases, and but one of the whole number was over forty-five years; five occurred in children, one of whom was only four years old.

The immediate causes have been direct blows, as falling upon the edge of a pail, a kick from a horse, or pressure, as in hanging, or in grasping the larynx strongly between the thumb and fingers, and in gunshot injuries.

General Symptomatology, etc.—The signs of this accident are such as may attend any severe injury of this organ, whether accompanied with a fracture or not, such as pain, swelling, difficult deglutition, embarrassed respiration, loss of voice, cough, and perhaps bloody expectoration, with emphysema, etc. But none of those can be regarded as diagnostic; although, when taken in connection with the history of the accident, especially if a very severe and direct blow has been received, or more certainly still when symptoms so grave and complicated have followed an attempt at strangulation by grasping the throat, they may be regarded as probable or presumptive evidences. A positive diagnosis must depend upon the presence of a sensible displacement, or motion of the fragments, with crepitus.

In the case related by Plenck, death followed almost immediately, with convulsions, and without any outcry; indicating, probably, some severe lesion of the spinal marrow; whilst in M. Ollivier's patient suffocation ensued, at first intermittent, and finally permanent. Gurlt reports 12 examples of sudden death following these lesions, of which he thinks at least 3 were unaccompanied by lesion of the spinal cord. In my own case, suffocation was throughout a prominent symptom, with only such slight intervals of amelioration as might have been occasioned by the extrication of the blood or mucus from the larynx.

General Prognosis.—The prognosis ought to depend rather upon the seat, complications, and gravity of the injury, than upon the simple decision of the question of fracture. A fracture produced by grasping the wings of the thyroid cartilage, and without any great contusion or laceration of the soft parts, might reasonably be expected to terminate favorably under judicious management; but when, on the contrary, the fracture is the result of great violence inflicted directly upon the front of the cartilages, producing severe contusion and laceration, and is followed by great swelling, emphysema, very difficult respiration, complete aphonia, impossibility of deglutition, etc., the prognosis cannot but be unfavorable.

By reference to the table at the beginning of this chapter it will be seen that all of the cases—27 in number—in which the cricoid was involved, terminated fatally. The only cases involving the cricoid in which recovery has taken place have been certain examples of gunshot injuries.

General Treatment.—In examples of simple, uncomplicated fracture, "silence, regimen, and a small bleeding" may suffice; but in other cases it may become necessary to introduce a tube into the stomach, to supply the patient with food and drink, since deglutition may be impossible. If, also, suffocation is imminent, there may remain no alternative but a resort to tracheotomy. Indeed this operation ought, we think, to be

resorted to in all cases in which emphysema is prominent, or in which respiration is interfered with seriously.

Hunt, of the Pennsylvania Hospital, who has arranged a tabular synopsis of twenty-nine cases, says that of seventy-seven cases ten recovered and seventeen died. Of eight cases in which tracheotomy was performed, but two died. In the four cases in which recovery took place without an operation, no mention is made of bloody expectoration or of emphysema.¹

[Hunt's opinion of the necessity of an operation is not too emphatic. He says: "I think that our list shows that active and prompt treatment by laryngotomy or tracheotomy gives the only hope of success, where the emphysema and bloody expectorations show that the mucous membrane has been lacerated by the broken fragments."]

As to a "reduction" of the fragments by manipulation, I believe it will be found generally, if not always, impracticable. Whatever displacement exists must be mostly inward, and we can have no means of forcing them again outward. Nor, if once replaced, do I see any reason to suppose that they would not become immediately displaced.

[Pick (*Fractures and Dislocations*) suggests that if there is any difficulty in maintaining the cartilages in position after restoration, an instrument constructed on the principle of Tredelenberg's tampon canula may be devised for this purpose. He also advises, if there is any difficulty in deglutition, to feed the patient with fluid food, introduced into the stomach by means of a large-sized gum-elastic catheter passed down the œsophagus and connected with a stomach-pump in preference to using a stomach-pump tube, which has a tendency to displace the fractured cartilages.]

Chelius has suggested the propriety, in such cases, of cutting open the coverings of the larynx freely in the median line, and, after stanching the bleeding, proceeding at once to divide the larynx itself in its whole length, and then replacing the broken cartilages.² The procedure has an aspect of severity, but I can well conceive of circumstances which would justify its adoption; not, however, so much for the purpose of replacing the cartilages, as for the purpose of arresting a fatal internal hemorrhage, and of giving a free admission of air to the lungs. If this operation were to be practised, the wound ought to be left open for a sufficient length of time to allow of the subsidence of the inflammation, and then permitted to close with such precautions as experience teaches are usually necessary after the windpipe has been opened.

Antiphlogistic measures, combined with fomentations to the neck, so far as these latter are found to be agreeable and practicable, are important measures and not to be overlooked in the general plan of treatment.

My own patient, also, found small pieces of ice, permitted slowly to dissolve in the mouth, very grateful; but he preferred very much, as an external application, the warm fomentations to the cold lotions.

NOTE.—Additional references: Fractures of the Larynx. Gurlt, *der Knochen*, vol. ii. Helwig, *Casper's Viertelj.*, 1861, p. 342. Witte, *Archiv. für klin. Chir.* Langenbeck, Bd. 21, S. 494-7, 503. Fischer, *Krico-Brf.*, 1 Theil Hets., S. 113. Neudorfer, *Handb. der Kniegs*, 2 Hefte, 2 Heft, S. 410. Hénocque, *Gaz. Hebdom.*, Sept. 25 and Oct. 2, 1868. Fredet, *Sur. Frac. du Larynx*, 1868. *Gaz. des Hôp.*, 1868, Nos 90 and 91. Chailloux, *Thèse de Paris*, 1873. Wales, *Amer. Journ. Med Sci.*, Jan. 1861. Hamilton, *Ibid.*, April, 1867. O'Brian, *Ed. Med. and Surg. Journ.*, v. 18. *Bul. Soc. Anat.*, Dec. 1866. Keiller, *Edin. Med. Journ.*, 1855, pp. 527, 824. *Dublin Quart.*, May, 1860. *Lancet*, 1869, p. 707.

¹ Hunt, *Amer. Journ. Med. Sci.*, April, 1866.

² *System of Surgery*, Philadelphia ed., vol. i. p. 581, 1847.

§ 1. Thyroid Cartilage.

In twenty-four of the fifty-two cases collected by Hénocque, the thyroid alone was broken; and in seven of Poinot's gunshot cases the same fact was observed. Poinot remarks: "In all the cases of fracture of the thyroid alone noted by Hénocque, the fracture was produced by lateral pressure, the larynx having been violently squeezed between the thumb and fingers. In the cases of Piédagorel and Martin-Damourette, the same cause existed. Sometimes, however, the fracture seems to have been produced by a direct pressure from before backward. Such was a case reported by Mr. Langlet, where an insane man suffered with this fracture, which had been caused by the pressure of the edge of a straight-jacket. Hénocque, and after him Chailloux, insists upon the fact that fracture of the thyroid cartilage, whether isolated or not, has never been observed to follow hanging. Contrary to what occurs in the case of the hyoid bone, fractures of the thyroid cartilage, whether produced by pressure either lateral or from before backward, are of a grave character. Out of 23 cases, Hénocque counts no less than 18 deaths. As a singular contrast, in gunshot fractures the results are less disastrous; our seven cases only count two deaths, and in these two the fatal termination is explained by the extent of the accompanying lesions. In one of the wounded, the ball, after entering near the symphysis mentis, had broken the jaw, had passed under the hyoid bone, and lodged itself in the thyroid cartilage. In the other, beside the loss of a portion of the anterior part of the thyroid cartilage, the autopsy showed a fracture of the humerus, of the left clavicle and shoulder-blade, and of the right side of the lower jaw. Of the four wounded who recovered, two were operated upon by tracheotomy. In the one operated upon by Maas, a Chassepot ball having fractured the left ala of the thyroid cartilage, considerable emphysema of the neck and chest supervened within a few moments, the blood flowing into the trachea. Maas performed superior tracheotomy during a severe paroxysm of asphyxia, and the patient recovered without any accident. Muller only operated on his patient on the second day, when there existed some cyanosis, resulting from dyspnoea, and a well-marked infiltration of the neighboring tissues; the cure was accomplished also without any untoward event.

"Goetting's patient, who had both lamellæ of the thyroid cartilage traversed through their middle and from right to left by a Chassepot ball, exhibited, as soon as wounded, symptoms of suffocation which he thought would prove fatal; but these phenomena subsided entirely before he was placed in the ambulance, and he recovered without operative interference. In the case of Fischer's patient, no accident occurred; indeed, there was only an incomplete fracture, the projectile having only taken off the most superficial lamellæ of the pomum Adami. But in our last case the cure was no less exempt from complications, although, as in Goetting's patient, the ball had traversed the thyroid cartilage and had wounded the vocal cords. The patient breathed freely through the wound, and at no time were there any symptoms of suffocation. The edges of the wound were approximated by means of a silver suture, and it was healed in two months."¹

The following additional cases illustrate the peculiarities of the fractures of the thyroid cartilage. M. Ladoz examined the larynx of a man who had been assassinated, and upon whose neck he found a handkerchief bound so tightly as to leave, after its removal, a deep furrow; but the neck showed also distinct marks produced by the fingers and thumb. There was a fracture of the thyroid cartilage which extended obliquely downward and outward through its right wing. The whole of the larynx was very much ossified, although the subject was only thirty-seven years old.² In 1823, M. Ollivier communicated to the Academy of Medicine a case in which, this cartilage being broken, the patient died of suffocation.³ M. Marjolin says: "Two women at the hospital being engaged in a quarrel, one of them seized her antagonist by the throat, and gripped

¹ Poinot, French edition of this treatise, p. 152.

² Gazette Médicale, 1838, p. 698.

³ Archives Générales de Médecine, tome ii. p. 307.

her so strongly that she broke the thyroid cartilage from its upper to its lower margin. Silence, regimen, a small bleeding, and the cure was accomplished."¹ Habcott operated successfully, in 1620, by introducing a leaden tube into the trachea in a case in which the thyroid was "damaged."

§ 2 Thyroid and Cricoid Cartilages.

Plenck saw a fracture of both the thyroid and cricoid cartilages produced by falling upon the rim of a pail.² Remer mentions a fracture of the larynx found in a person who had been hanged.³ Dr. O'Brian, of Edinburgh,⁴ reports a case of fracture of both cartilages, involving the trachea also, in a woman who had received a kick under the jaw, and who died on the following day. I am able to furnish one example of fracture of both the thyroid and cricoid cartilages.

J. C., æt. forty-one, is supposed to have been kicked by a horse on the 10th of November, 1856. When found, he was sitting upright, but unable to articulate except in a whisper. His countenance was anxious, his pulse feeble, extremities cold, and he was breathing with great difficulty. A small quantity of blood was issuing from his fauces. His upper lip was cut, and a few of his teeth dislocated; the wound appearing as if inflicted by one of the corks of the horse's shoes. There was no other wound; but over the left wing of the thyroid cartilage there was a slight discoloration, pressure upon which produced intense pain and suffocation, and disclosed the fact that the thyroid prominence was depressed very much and broken. Cold lotions were directed to be applied, and as the thirst was excessive, but deglutition impossible, he was permitted to hold pieces of ice in his mouth. This plan, with but slight modifications, such as the substitution of warm fomentations to the neck for the cold lotions, was continued until the following evening, when, at the request of the attending physician, Dr. Barber, I was called to see him. The symptoms remained nearly the same as at first. He was unable to speak audibly, or perform the act of deglutition; his breathing was difficult, and at times threatened suffocation. The lateness of the hour, with other circumstances, determined me to defer surgical interference until morning. At daybreak of the 12th, I made the operation of laryngotomy, and introduced a large double canula into the cricothyroidean space. This operation was rendered difficult by the great amount of swelling about the neck, due both to emphysema and serous infiltrations. The breathing immediately became easy, and gradually the appearance of asphyxia disappeared from his face; but, after about six or seven hours, he began perceptibly to fail in strength, and died at 3 o'clock P. M. of the following day, apparently from exhaustion rather than from suffocation, having survived the accident about seventy-two hours, and the operation about thirty-four hours. The autopsy disclosed a comminuted fracture of the thyroid cartilage, with a simple fracture of the cricoid. The thyroid was broken almost perpendicularly through the centre, the line of fracture being irregular and inclining slightly to the left side. The left inferior horn was broken off about three lines from its articulation with the cricoid cartilage. The right ala was broken also in a line nearly vertical, but irregular, at a point about six lines from its posterior margin. The pomum Adami was depressed to the level of the cricoid cartilage, and the left ala, being completely detached, was thrown inward and upward several lines. Underneath the perichondrium, especially upon the inner side, there was pretty extensive bloody infiltration. Ossification of the cartilages had commenced at several points, but it had made little progress. The central fracture of the thyroid was through cartilage alone. The fracture of the right ala was through cartilage until it reached a bony belt comprising the two inferior lines of its course. The left lower horn was ossified, and the fracture was through this bony structure. The fracture through the cricoid cartilage commenced close

¹ Marjolin, *Cours de Patholog. Chir.*, p. 396.

² Malgaigne, *op. cit.*, p. 409.

³ Morgagni, *de Sedibus, etc.*, Epis. 19, num. 13, 14, et 16; Remer, *Annales d'Hygiène*, tome iv. p. 171; from Malgaigne.

⁴ O'Brian, *Edinburgh Med. and Surg. Journ.*, vol. xviii.

upon the margin of a bony plate, but in its whole course it traversed only cartilage. It was on the left side. There was also an incomplete fracture on the right ala of the thyroid cartilage, commencing in the line of the principal fracture and extending obliquely downward about three lines, until it was arrested by the bony plate which constituted the lower margin of this wing. A ragged, lacerated wound in the back of the larynx, above the cricoid cartilages, communicated directly with the œsophagus.

§ 3. Cricoid Cartilage.

Both Valsalva and Cazauvieilh have each met with a single example of this fracture, without fracture of the thyroid cartilage; and Weiss has found the cricoid cartilage broken into numerous fragments, and at the same time separated from the trachea. In the table at the beginning of this chapter, eleven similar cases are recorded.

[§ 4. Fracture of the Condyle of the Occiput.

Dr. Morgan, of Leavenworth, Kansas, reports the following case as a fracture of the condyle of the occipital bone: A coal-miner, æt. about thirty-five years, colored, was injured by the fall of a mass of slate upon him, after which for a long time he was unable to turn his head to the right. He partially recovered, but again received a similar injury about three years after. He was never again able to move his head in any direction, nor to work. Hemiplegia soon after supervened, when he took to his bed. His head became rigidly fixed and turned to the left, instead of right, as after the first injury. There was paralysis of motion and sensation of the upper and lower extremities of the right side; the prick of a pin was felt on the left side, and the fingers could be slightly flexed after massage. There was little pain, except when clonic spasms occurred. When his head moved, the whole body had to be moved. His wife, who always moved his head, thought she often detected a crepitus. Death occurred suddenly. The autopsy showed a detached piece of bone which had been part of the right occipital condyle. The axis was intact, except the odontoid process, which was denuded of cartilage and roughened on one side; the cheek ligaments seemed to have been disorganized; the right transverse process of the atlas was found destroyed by caries, and the articular surface of its lateral mass about half absorbed, due to the chronic inflammatory process to which the region had evidently been subjected.¹]

CHAPTER XVI.

FRACTURES OF THE VERTEBRÆ.

It will be convenient to divide fractures of the vertebræ into fractures of the spinous processes, transverse processes, vertebral arches, and bodies.

§ 1. Fractures of the Spinous Processes.

Fractures of the spinous apophyses, independent of a fracture of the arches, may occur at any point of the vertebral column; and they may be occasioned by a blow received upon either side of the spinal column; or by a force directed from above or from below.

¹ Med. Record, April 19, 1890.

Symptoms and Pathology.—These accidents may be recognized by the pain at the point of fracture, produced especially when the patient bends forward, which position renders the skin and muscles tense and drives the fragments into the flesh; by the swelling, tenderness, and discoloration; but chiefly by the lateral displacement of the broken process, and the mobility.

Duverney met with a fracture of two of the processes in the same person, and which could only be recognized by the mobility, since, as the autopsy proved, there was no displacement. Nor would it be surprising if the displacement was absent in a majority of these accidents, inasmuch as the attachment of the ligaments from above and below with the strong and short muscles upon either side, must prevent a deviation in any direction until these tissues are more or less torn. Sir Astley Cooper mentions a case in which, however, such lacerations did occur, and the lateral deformity was quite conspicuous. A boy had been endeavoring to support a heavy weight upon his shoulders, when he fell, bent double. Immediately he had the appearance of one suffering under a distortion of the spine of long standing. Three or four of the processes were broken off, and the corresponding muscles were detached so as to allow the processes to fall off to the opposite side. There was no paralysis, and he was soon discharged with the free use of his limbs, but the deformity remained.¹

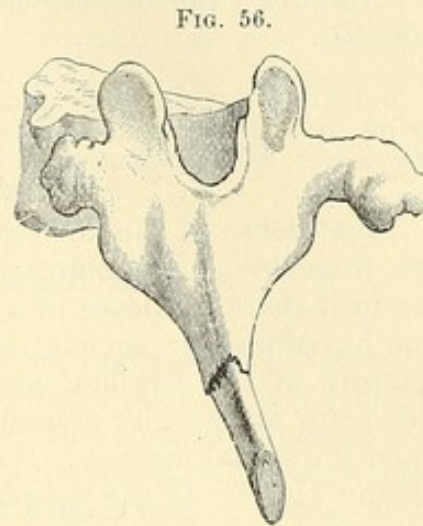


FIG. 56.
Fracture of the spinous process.

If the fragment is thrown directly downward, as it possibly may be, especially in the cervical or lumbar region, yet not without a rupture of the supraspinous ligaments, or of the ligamentum nuchæ, then the displacement will be more difficult to detect, and it may require some more care not to confound it with a fracture of the vertebral arch or of the plates from which the spinous processes arise. The process not being felt in its natural position, nor upon either side, it may seem to have been forced directly forward, when, in fact, it is only thrown downward toward its fellow. The danger of error in the diagnosis will be increased when to these conditions is added paralysis of those portions of the body which are below the seat of the fracture, and which, in this case, may be the result of an extravasation of blood or of simply a concussion of the spinal marrow. Nor do I think it would be possible now to determine positively whether it was simply a fracture of a spinous process, of the arch, or of the body itself of the vertebra. In case, however, the paralysis results from concussion, the fact will in most cases soon become apparent by a return of sensation and of the power of motion.

Prognosis.—Hippocrates affirmed that here, as in fractures of other spongy bones, the union took place speedily. It is quite probable that he has stated the fact correctly, and yet in the only example known to me where the condition of this process, as proved by dissection, has been carefully stated, the fragment had not united by bone at all.

¹ Sir Astley Cooper, *op. cit.*, p. 459.

This is the case related by Sir Astley Cooper as having been examined by Mr. Key. A subject was brought into the dissecting-room in which one of the processes had been broken, and, on dissection, a complete articulation was found between the broken surfaces, which surfaces had become covered with a thin layer of cartilage. The false articulation was surrounded with synovial membrane and capsular ligaments, and contained a fluid like synovia.¹

Ordinarily the displacement continues, whatever treatment may be adopted.

Malgaigne says he has seen one instance in which the twelfth dorsal spine, being broken and displaced laterally, resumed its place spontaneously after a few days. Aurran mentions a similar example.²

Treatment.—If in any case it should be found possible to act upon the fragment, an attempt might be made to press it into place, and to retain it there by means of a compress and bandage; but even this would not be admissible so long as any doubt remained whether it was not a fracture of the vertebral arch, since, if it were, any attempt to restore the bone to place by pressure would be likely to drive it more deeply upon the spinal marrow. Yet what need is there of surgical interference of any kind? If the apophysis remains displaced, it cannot result in any serious, perhaps we may say in any appreciable deformity. The surgeon has therefore only to lay the patient quietly in bed, and in such a position as he finds most comfortable, enjoining upon him perfect rest, and employing such other means as may be proper to combat inflammation.

§ 2. Fracture of the Transverse Process.

A fracture of a transverse process can scarcely occur except as a consequence of a gunshot wound.

Dupuytren relates a case of this kind in which the ball had penetrated the transverse process of the second cervical vertebra.

C. H. was shot with a pistol; saw him on the following day; ball had entered the chin, a little to the left side and below the inferior maxilla, but its place of lodgement could not be discovered; lay with his face constantly turned to the right; left side of his neck was swollen and crepitant; the left arm and leg were paralyzed; slept most of the time, but could be easily aroused, and when aroused he seemed to be conscious, but was unable to speak; by signs indicated that he was suffering no pain. He gradually sank, without hemorrhage, and died in thirty-six hours from the time of the receipt of the injury.

The autopsy enabled us to trace the wound from the chin through the roots of the transverse process of the fourth cervical vertebra; immediately behind which, lying imbedded in the muscles, was the bullet. The cavity of the tunica arachnoides contained considerable serous effusion.

[Dr. Armstrong, of Taylorsville, Ill., reports a case of fracture of the right transverse process of the atlas, caused by a blow on the back of the neck by a baseball-bat or a wagon-spoke. The man, æt. thirty-two, lived only one minute and fifteen seconds. The autopsy showed a complete separation of the right transverse process of the atlas.]

¹ Sir Astley Cooper, *op. cit.*, p. 459.

² Malgaigne, *op. cit.*, p. 412.

Symptoms.—The symptoms arising from this accident can only refer to the complications, since a mere fracture of the process is not likely to present any peculiar signs which could be recognized. Concussion or bloody effusion may take place so as to occasion more or less paralysis; or, at a later period, inflammation and its consequent effusions may give rise to the same phenomenon. In itself considered, and independent of these complications, it is sufficiently trivial; but inasmuch as it has not been known to occur except from gunshot wounds, nor is it likely to occur except from penetrating wounds of some kind, the accident must always be regarded as exceedingly grave, if not actually fatal.

Treatment.—As to the treatment, nothing but strict rest and antiphlogistic remedies can prove of any service.

§ 3. Fracture of the Vertebral Arch.

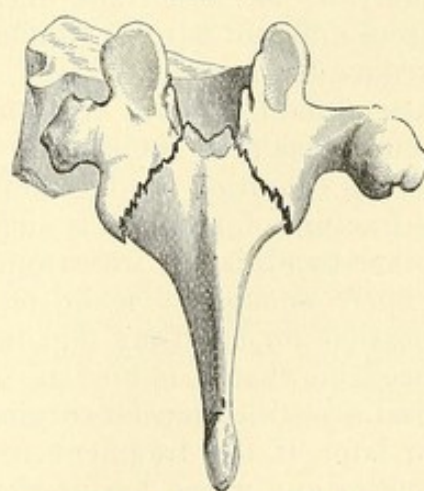
The vertebral arches, upon which both the spinous and transverse processes have their principal support, may be broken at any point of their circumference, by a blow received upon the spinous process; but generally it is the lamellar portion, or the "vertebral plate," which gives way rather than the neck or pedicle of the arch; and in nearly all of the cases recorded the plates have been broken upon both sides. The only exception to this rule, of which the author is informed, is the specimen said to be in the museum of Val-de-Grâce, and mentioned by M. Lequest.¹

A balustrade fell from the top of a high building, striking a man about forty years of age upon the back of his head and neck. He fell to the ground instantly and did not again move his feet or legs, although he never lost his consciousness until he died. The bladder was paralyzed, and his left arm, but he could move his right arm. He conversed freely up to the last moment, and said that he was suffering a good deal of pain, which was always greatly aggravated by moving. His death took place thirty-six hours after the receipt of the injury. Dissection disclosed the fact that the plates of the sixth cervical vertebra were broken upon each side, and that the spinous process, with a small portion of the arch attached, was forced in upon the spinal marrow. There was no blood effused or serum at this point, but about one ounce of serum was found in the cavity of the tunica arachnoides at the base of the brain. The bodies of the vertebræ were not broken. The immediate cause of death was the direct pressure of the spinous process.

[Walker, of Detroit, reports a case of fracture of the fifth cervical vertebra in which the arch separated on both sides at its junction with the body. It was caused by a fall upon the head.²]

Symptoms.—We can imagine a case of fracture of the vertebral arch, with a lateral displacement only, in which the symptoms might not differ

FIG. 57.



Fracture of the vertebral arch.

¹ M. Lequest, *Dic. Encyc.*, 3d Series, vol. i. p. 446.

² *Med. Age*, Detroit, 1886.

essentially from a simple fracture of the spinous process; and it is quite possible that some of the cases which have been supposed to be examples of this latter accident, and in which a speedy recovery has taken place, were really examples of fractures of the arches; yet it must be admitted that such a fortunate result is only possible, since the arches can hardly be broken without communicating a severe concussion to the marrow, nor without lacerations, inflammation, and effusions, which will be most certain to produce compression and paralysis, and probably death.

If, however, it is possible for us to confound a fracture of the process with a fracture of the arches, it is still more possible to confound a fracture of the arches with a fracture of the body of the vertebræ. If, as is usually the fact, the process, in case of a fracture of the arch, is less prominent than natural, and that portion of the body receiving its nervous supply from below this point is paralyzed, we may have reasons to believe that the arch is broken and the process is driven in upon the spine; but dissections have shown that in many of these cases, or in most of them, indeed, the bodies of one or more of the vertebræ are broken also, and in still other cases the bodies alone were broken. If we can feel the plates move separately, the diagnosis might be made out, so far at least as to determine that the plates were broken; but we would be still unable to say that the bodies of the vertebræ were not broken also. Something, perhaps, may be inferred from the direction and manner of the blow which has produced the fracture. Thus, a fall upon the top of the head, the feet, or the nates, would most often produce a comminution of the bodies by crushing them together, whilst a blow upon the back could scarcely break one of the vertebræ without breaking the corresponding arch also. We might thus be led to infer, in the first instance, that the arches were not broken; and, in the second instance, if we could convince ourselves that the arches were not broken, we might rest pretty well assured that the bodies were not.

Treatment.—If the fragments are not displaced, nothing but rest and a cooling regimen are indicated; but if they are forced in upon the marrow, an important question is presented, and which has received from different surgeons different solutions. Shall an effort be made to reduce the fragments? and, if so, by what means shall the indication be attempted? It will be remembered that in nearly all of these cases we must remain in doubt, even after the most careful examination, as to the actual condition of the fracture. It may be that what we suppose to be a fracture of the arch is only a fracture of the apophysis, or that, on the other hand, it is a fracture of the body of the bone itself; and if we are expert enough to make out clearly a fracture of the arch, it is not possible for us to say that the body is not broken also, indeed, it is quite probable that it is broken. With a diagnosis so uncertain, can we ever find a justification for surgical interference? Death is inevitable, sooner or later, if the fragment is not lifted, and we can scarcely make the matter any worse by interference. If it proves to be a fracture of the apophysis our interference was unnecessary, but it has done no harm. If the body of the bone is broken, the operation affords no resources, but the patient is probably beyond suffering damage at our hands. If the diagnosis is correctly made out and the arch only is broken, and if there is no bloody effusion, or laceration of the membranes or of the marrow, and if the concussion was not sufficient to determine much inflammation of the cord, then it would seem possible that an operation might save the patient.

Paulus Ægineta first suggested that the compressing fragments ought to be removed by excision; and in 1762 Louis removed from a man who had received a gunshot wound in his back, after the lapse of five days, several loose pieces of bone belonging to the arch of the vertebra, and the patient recovered, but not without a partial paralysis of his lower extremities. Of course, nothing could be more rational or simple than this procedure, adopted by Louis, in any case of an open wound, where the fragments could be easily reached; but the younger Cline was the first, in the year 1814, to put into practice the more ancient suggestion of Paulus Ægineta, namely, to attempt the removal of the fragments in a case of simple fracture. He made an incision upon the depressed bones as the patient was lying upon his face, raised the muscles covering the spinal arch, removing, by means of a circular saw, chisel, mallet, trephine, etc., the spinous processes of the eleventh and twelfth dorsal vertebræ, and the arch of one of the vertebræ. The patient was in no manner relieved, and died on the fourth day after the receipt of the injury and the third after the operation.¹ Mr. Oldknow repeated this operation in 1819 in a case of fracture of the arch of the seventh vertebra. The patient died on the sixth day.² In 1822, Mr. Tyrrell operated on a man who had been injured four days previously, removing the spinous processes of the twelfth dorsal and first lumbar vertebræ. The operation was accomplished with considerable difficulty, and resulted in only a partial return of sensibility. He died on the thirteenth day after the operation.³ In 1827, Tyrrell operated a second time, and death resulted on the eighth day.⁴ On the 30th of August, 1824, Dr. J. Rhea Barton, of Philadelphia, operated upon a man who had received, twelve days before, a fracture of the arch of the seventh dorsal vertebra. On the third day he was attacked with a violent chill, and death took place twelve hours after. The dissection showed about half a gallon of blood in the posterior mediastinum, and bloody effusion existed along the whole length of the spinal canal.⁵ The patient whom Laugier trephined at the base of the spinous process of the ninth dorsal vertebra, died on the fourth day.⁶ The operation has been repeated unsuccessfully by Wickham, Attenburrow, Holcher, Heine, and Roux.⁷ February 5, 1834, Dr. David L. Rogers, of New York, operated upon a man who had fallen two days before, breaking the arch of the first lumbar vertebra, and forcing the spinous process upon the cord. This man died on the eighth day.⁸ In 1854 Dr. Blackman, of Cincinnati, operated, his patient dying on the fourth day. During the same year, also, Dr. B. removed a portion of the sacrum for an injury of four years' standing, with no benefit.⁹ In 1858 Dr. Stephen Smith, of New York, removed the arch of the tenth dorsal vertebra, death occurring soon after.¹⁰ December 29, 1857, ten days after the receipt of the injury, Dr. J. C. Hutchison, of Brooklyn, operated upon a man, removing the spinous processes of the eighth, ninth, and tenth dorsal vertebræ, with the posterior arch of the latter. The patient survived the operation ten days.¹¹ Dr. H. A. Potter, of Geneva, N. Y., informs us that he has operated three times. In the first case he removed the posterior portion of the three lower cervical vertebræ. The patient died on the fourth day. In the second case he removed the spinous processes of the fifth and sixth cervical vertebræ, and the entire posterior arch of the fifth. The sheath was not broken, "but the cord was much injured." There was almost complete paralysis of the extremities, and this condition was not remedied by the operation. Three years later, the patient being still alive, but only a very slight improvement having taken place, Dr. Potter "removed the fourth, sixth, and

¹ Cline, *Chelius's Surgery*, Amer. ed., vol. i. p. 590.

² Oldknow, *Sir A. Cooper on Disloc. and Frac.*, Amer. ed. 1851, p. 479.

³ *Sir A. Cooper's Lectures*, by Tyrrell, 3d Amer. ed., 1831, vol. ii. p. 17.

⁴ Tyrrell, *Med.-Chir. Rev.*, vol. x. p. 601.

⁵ Barton, *Goodman's ed. of Sir A. Cooper on Disloc.*, etc., p. 421.

⁶ *Malgaigne*, Amer. ed., p. 341.

⁷ *Chelius's Surgery*, Amer. ed., vol. i. p. 590. Also, *Velpeau's Op. Surgery*, 1st Amer. ed., vol. ii. p. 737.

⁸ Rogers, *Amer. Journ. Med. Sci.*, May, 1835.

⁹ *Velpeau's Surgery*, Blackman's ed., vol. ii. p. 392.

¹⁰ Stephen Smith, *New York Journ. Med.*, 1859, p. 87.

¹¹ Hutchison, *Trans. N. Y. Med. Soc.*, 1861, p. 93.

seventh cervical vertebræ." (We presume he intends to say the "posterior arches.") At the time of the report, January, 1863, there was no further improvement. Finally he reports a completely successful case. The injury was of "five months' standing." Lucke operated on the eleventh dorsal vertebra, and the patient died three months later. In 1867 M. Denucé, of Bordeaux, operated, the day following the accident, upon a man aged twenty-four years, who had a fracture of the last dorsal arch. The arches of the last dorsal and first lumbar were elevated. The spinal marrow did not appear to be contused, although he had complete paralysis of the lower extremities. The man died two days later.²

These are all of the cases of which the author has any information in which this operation had been made, and they have all, excepting the case reported by Potter (which is doubtful), terminated fatally in a very short time.

Experience seems to have shown that we have little or nothing to expect from operative measures; and, notwithstanding the strong hope expressed by Sir Astley Cooper that Mr. Cline's operation might hereafter prove a valuable resource, and contrary to the conclusions which I in common with many other surgeons had drawn from the anatomical relations of these parts, I am compelled reluctantly to declare that the expedient is scarcely worthy of a trial.

To the same conclusion, also, many of the most distinguished surgeons have arrived, among whom we may mention, as especially entitled to confidence, Brodie, Liston, Alexander Shaw, Malgaigne, and Gibson. "Chédevergne, after analyzing the previous papers of MacDonnell and of Félizet, has collected 25 cases of trephining of the spine, which give the following results: 12 operations performed in the dorso-lumbar region show 10 deaths, 1 cure, and 1 unknown result; out of 13 operations performed in the cervical region there were 9 deaths and 4 recoveries; making a total of 25 operations, with 19 deaths and 5 recoveries. This ratio of successful cases, as Chédevergne says, might possibly be smaller than that furnished when the cases are left to themselves.³

What more can be said of the attempt to raise the depressed bone by seizing the spinous process with the fingers, or with a pair of strong hooked forceps passed through the skin, or finally, if this cannot be done, by laying bare both sides of the process and seizing upon it with a pair of firm tenacula?

This is the alternative presented to Malgaigne, and which he ventures to recommend as deserving a trial. In the absence, however, of any testimony in its favor, beyond the mere rational argument adduced by this distinguished writer, we must waive any further consideration of the subject; only expressing our conviction that it will be found, after a fair trial, as useless and as inexpedient as the more severe operations of Cline.

[Macewen operated upon a fracture of the spine five weeks after the accident and removed the arches of the twelfth dorsal and first lumbar vertebræ, with most satisfactory results. Horsley removed the eleventh and twelfth dorsal with benefit to his patient. Gordon operated on the twelfth dorsal and first lumbar vertebræ sixty-seven days after the accident and relieved the cystitis, incontinence, and partially the paralysis of motion. Dandridge, of Cincinnati, removed the arches of the eleventh and twelfth dorsal and first lumbar six months after the injury, but the results were negative.

Unsatisfactory as operations have thus far proved to be, there are exceptional cases in which operations will prove useful. Macewen has thus expressed the opinion that is entertained by the most advanced surgeons on this subject:

¹ Amer. Med. Times, Jan. 10, 1863.

² Lucke, Denucé, French ed. of this treatise, p. 167. Poinot.

³ Chédevergne, Poinot, op. cit., p. 167.

"Traumatic lesions are, as a rule, so gross, and the destruction so complete, that in such operative treatment can be of little service. Still there are cases in which traumatism has produced localized pressure, primary or secondary, which can be relieved."]

Jeffries Wyman, of Boston, has met with eleven specimens of old united fractures of the vertebral arches occurring in the fourth or fifth lumbar vertebræ between the lower articulating and the transverse processes. He has also met with the same fracture once in the third lumbar vertebra. The frequency of this peculiar form of fracture in this region, Dr. Wyman ascribes to the fact that the upper and lower articulating processes are widely separated from each other, and connected only by a narrow neck, in which respect they contrast very strongly with the dorsal vertebræ; and he supposes that the fractures may be caused by either a forcible bending of the body backward, or by the shock resulting from a fall from a height in which the force of the concussion is conveyed downward through the pelvis. In no case has the existence of this fracture been recognized during life, nor is it probable that its occurrence would cause any marked symptoms unless it had been caused by a blow directly from behind.¹

As to the therapeutical treatment of the various symptoms belonging to these accidents, and in relation to the prognosis, the remarks which we shall make will be found equally applicable to fractures of the bodies of the vertebræ, and we shall reserve the consideration of these topics for the following section.

§ 4. Fractures of the Bodies of the Vertebræ.

The same causes which produce fractures of the arches may produce also fractures of the bodies of the vertebræ—that is, blows received directly upon the extremities of the spinous processes; but in these cases

FIG. 58.

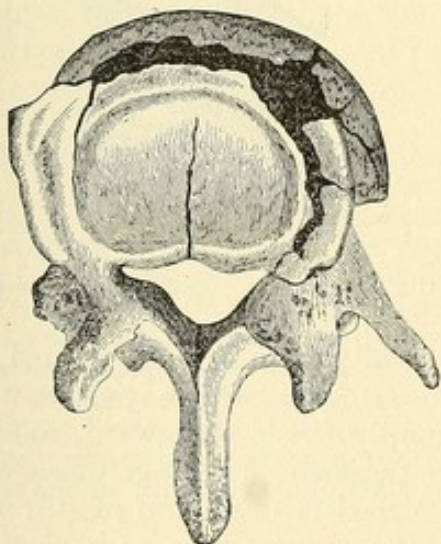
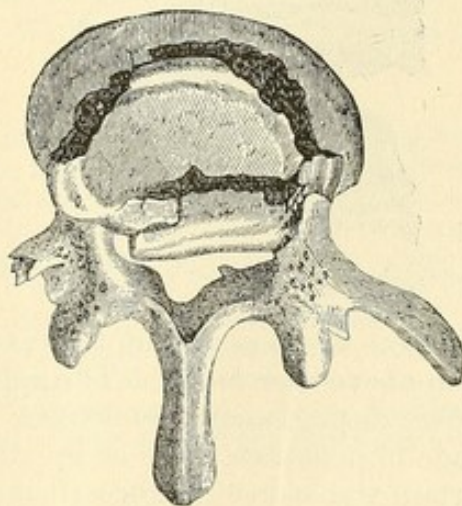


FIG. 59.



Fractures of the bodies with compression.

the arches are generally broken at the same time. In other cases the bodies of the vertebræ are broken by falls upon the top of the head, by which the vertebræ are not only driven forcibly together (Figs. 58, 59),

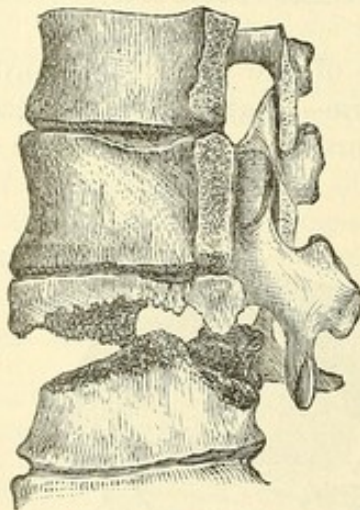
¹ Wyman, Boston Med. and Surg. Journ., Aug. 12, 1860.

but often doubled forward upon each other; or the patient may have alighted upon his feet or upon his sacrum.

Malgaigne says the spine bends at three principal points; comprised, the first between the third and seventh cervical vertebræ, the second between the eleventh dorsal and second lumbar, the third between the fourth lumbar and the sacrum; and that a majority of the fractures of the vertebræ occur at these points of flexion. He makes an argument from this also that these fractures "are generally the result of counterstrokes, as the effect of forcible flexion of the column either forward or backward." Malgaigne observes, moreover, that dislocations follow the same rule. M. Chédevergne thinks that indirect fractures are much more frequent than direct, and he makes of these two varieties, namely, those caused by tearing and those caused by crushing, the former being the result of forced flexion forward or backward, the lesion being usually at the twelfth dorsal or first lumbar. By experiment on the cadaver, M. Chédevergne has determined that in flexion forward the apophysis of the twelfth dorsal vertebra is broken off, the great supraspinous ligament torn, and finally the body of the vertebra is separated into two parts, of which the superior is the smallest. In flexion backward the primary lesion takes place in front.¹

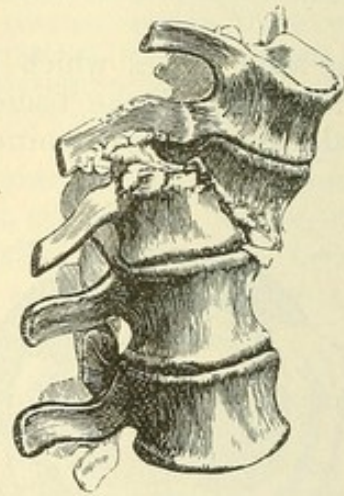
The direction of the line of fracture varies greatly in the different examples which we have seen; some are crushed or more or less comminuted. In some cases a narrow piece is fractured from the margin, others are broken transversely (Fig. 60), and others obliquely. In oblique

FIG. 60.



Transverse fracture of the body of a vertebra.

FIG. 61.



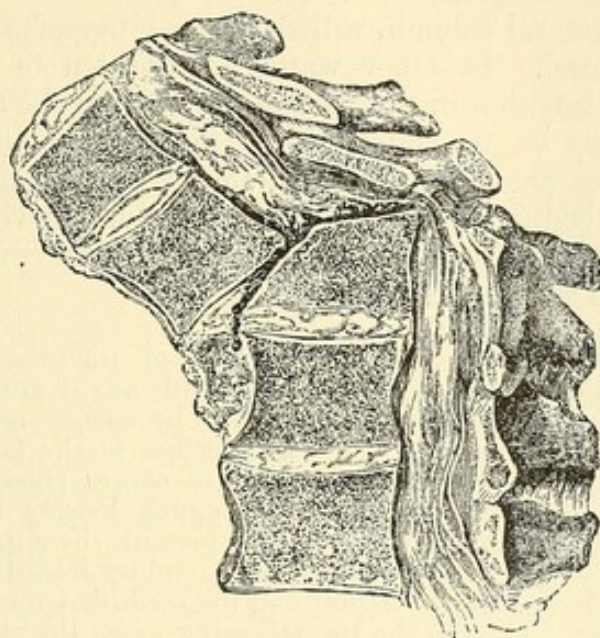
Oblique fracture of the body of a vertebra.

fractures the line of the fracture is generally from behind forward, and from above downward. The upper fragment is almost always that which suffers displacement; sometimes being simply driven downward, and thus made to penetrate more or less the lower fragment; at other times, as in certain transverse fractures, it is only displaced forward, and in still other examples, where the fracture is oblique, the upper fragment is displaced both downward and forward (Fig. 61). In the first and last of these examples the spine becomes bent forward at the point of fracture, producing an angle of which the most salient point posteriorly is represented by the extremity of the spinous process belonging to the broken vertebra; in the second

¹ Chédevergne, *Mém. de l'Acad. de Méd.*, Paris, 1869-70, tom. 29, p. 73.

example the spinous process of the broken vertebra is depressed, and the process of the vertebra next below is relatively prominent. In a pretty large proportion of cases also the fracture of the body of the vertebra is complicated, as we have already stated, with a fracture of the arches, in some instances with a fracture of the oblique processes, and with a dislocation. (Fig. 62.)

FIG. 62.



Displacement of upper vertebra downward and forward with compression of cord.

Symptoms—The usual signs of the accident are severe pain at the seat of fracture, felt especially when the part is touched or the body is moved, tenderness, swelling, ecchymosis, occasionally crepitus, a slight angular distortion of the spine, or simply a trifling irregularity in the position of the processes, and paralysis of all the parts whose nerves take their origin below the fracture.

The paralysis may be due to the mere pressure of the displaced fragments, but it is much more often due to a severe and irreparable lesion of the cord itself. I have, in one instance, seen the cord almost completely separated at the point of fracture, although the displacement of the fragments was inconsiderable. Accompanying the paralysis of the bladder, there has been generally observed an alkaline state of the urine, and subacute inflammation of the coats of the bladder. Priapism is present in a certain proportion of cases. Those who die immediately seem to be asphyxiated; while those who die later wear out from general irritation, this condition being frequently accompanied with an obstinate diarrhœa and vomiting. A few become comatose before death. A certain proportion finally recover, but scarcely ever are all the functions of the limbs and of the body completely restored.

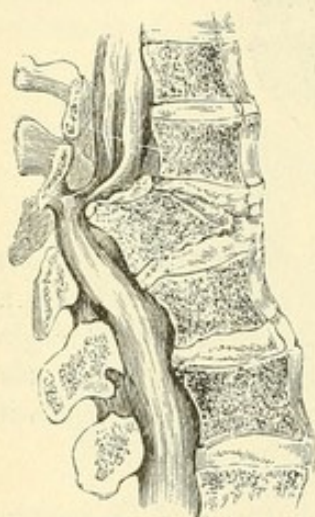
1. *Fractures of the Bodies of the Lumbar Vertebrae.*

The spinal cord terminates, in the adult, at the lower border of the first lumbar vertebra, but in the child at birth it extends as low as the third lumbar vertebra. The remainder of the vertebral canal is occupied by the leash of terminal nerves called collectively the cauda equina. The nerves which emerge from the intervertebral foramina below the

fourth and fifth lumbar vertebræ, unite with the sacral nerves to form a plexus which supplies the sphincter and levator ani, the perineal muscles, the detrusor and accelerator urinæ, the urethra, the glans penis, and a great proportion of the lower extremities. It will be apparent, therefore, that a fracture, with displacement, of even the last vertebra of the column, involves the possibility of more or less paralysis of all those parts supplied by this plexus, and that in proportion as the fracture is higher in the vertebral column, will the probability of additional complications be increased. In other words, in addition to the more or less complete loss of function in the organs supplied by the ilio-sacral plexus, there will probably be associated loss of function in other organs, supplied from sources above this point of the vertebral canal. A fracture, however, of the bodies of the fourth or fifth lumbar vertebra, produced by a direct blow, is exceedingly rare, owing to the protection which it receives from the alæ of the pelvis.

Dr. Alexander Shaw has reported four cases of fracture below the second lumbar vertebra, which were unaccompanied with any degree of paralysis, and

FIG. 63.



Key's case of fracture of the first lumbar vertebra.

which were followed by speedy recovery,¹ a circumstance which he ascribes to the fact that the cauda equina is composed of nerves possessing considerable firmness, and suspended loosely together; for this reason they escape pressure by slipping among themselves, and suffer less injury from the same amount of compression than the medulla spinalis.

In the two following cases the results were less fortunate, yet recoveries seem to have taken place. A boy was admitted into St. George's Hospital with a fracture and considerable displacement of the third and fourth lumbar vertebræ, with a manifest alteration in the figure of his spine. His lower limbs were paralyzed. An attempt was made to restore the displaced vertebræ, but it was attended with only partial success. At the end of a month he had slight involuntary motions of the lower extremities, and at the same time he began to recover the power of using them voluntarily. Three or four months after the receipt of the injury he left the hospital, and the history of his case was interrupted at this date.² Dr. Thompson, of Goshen, N. Y., reports also a fracture of either the third or fourth lumbar vertebra, followed by recovery.

The patient fell from the roof of a house, striking first upon his feet and then upon his buttocks. The usual signs of a fracture were present, such as paralysis, etc. A bed sore formed above the top of the sacrum, and a piece of bone exfoliated, which seemed to belong to the last lumbar vertebra. He was confined to his bed seven months. After eighteen months he began to use crutches. At the end of about three years all improvement ceased, at which time he could not quite stand alone; yet, with the aid of apparatus, he was able to get about the country and vend books, prints, etc. This was also his condition one year later.³

[Chisholm, of New Concord, O., reports a case of fracture and displacement of the third lumbar vertebra. There seems to have been a marked prominence of the spinous process, with paralysis of motion. Gradual recovery took place without active treatment.⁴]

¹ Shaw, London Med. Gaz., vol. xvii.

² Brodie, Sir Ast. Cooper on Disloc., op. cit., p. 471.

³ Thompson, Amer. Journ. Med. Sci., Oct. 1857. Lente's paper.

⁴ Med. Brief, St. Louis, March, 1889.

2. *Fractures of the Bodies of the Dorsal Vertebrae.*

In these examples the same organs are paralyzed as in the fractures lower down, in addition to which there is generally considerable disturbance of the functions of respiration, irregular action of the heart, indigestion, accompanied with a tympanitic state of the bowels.

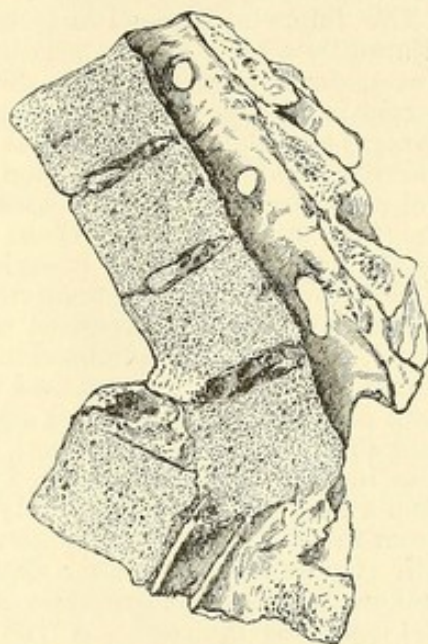
In Sir Astley Cooper's cases, mention is made of a fracture of the twelfth dorsal vertebra, which the patient survived fifty-two days, one of the tenth dorsal, which terminated fatally in six days, and another of the ninth dorsal, which did not result in death until after nine weeks. Dr. Parkman presented to the Boston Society for Medical Improvement a specimen of fracture of the fifth dorsal vertebra, the bodies of the third and fourth being also displaced forward, in which position they had become firmly ossified. The spinal cord had been completely separated, yet the patient survived the accident two months.¹ Dupuytren has related also two examples of fractures, one of the tenth and the other of the last dorsal vertebra, from which the patients completely recovered after from two to four months' confinement.² A similar case is related by Lente, of New York: A man having fallen a distance of twelve or fifteen feet upon his back, was found with nearly complete paralysis of his lower extremities and of his bladder. Swelling existed over the lower dorsal vertebrae, and this point was very tender. Subsequently, when the swelling subsided, the prominence of the spinous processes of the tenth and eleventh dorsal vertebrae put the question of a fracture beyond doubt. Gradually his symptoms improved. In six months he was able to walk about the streets, and four years after the accident he was employed in a foundry under regular wages, being able to stand fifteen or twenty minutes at a time, and to walk half a mile without resting. At this time there remained no tenderness in the spine, but the projection of the process was the same as at first.³

[Erichsen states that when the fracture occurs in the middle or lower dorsal regions, so that the lower portion only of the cord is injured, the patient may live for many years, even though the cord is completely severed and the spinal canal obliterated by the displacement and by the new bone formed in the process of repair. He reports the case of a man who fell fifty feet from a tree and sustained a fracture of the spine with displacement. He lived nine and a half years, and though completely paralyzed below the middle of his body, suffered only from cystitis, and finally pyelo-nephritis. The autopsy showed complete obliteration of the spinal canal.]

3. *Fractures of the Bodies of the Five Lower Cervical Vertebrae.*

We shall now have added to the symptoms already enumerated, paralysis of the upper extremities, greater embarrassment of the respira-

FIG. 64.



Fracture through lower dorsal and first lumbar vertebrae.

¹ Parkman, New York Journ. Med., March, 1853, p. 286.

² Dupuytren, op. cit., pp. 356-7.

³ Lente, Amer. Journ. Med. Sci., Oct. 1857, p. 361.

tion with diminished action of the heart, and more complete loss of sensation and volition in the lower part of the body. In general, also, the eyes and face look congested, owing to the imperfect arterialization of the blood, and death is more speedy and inevitable than in examples of fracture occurring lower down.

In ten recorded examples of fractures of the five lower cervical vertebræ, one died within twenty-four hours, four in about forty-eight hours, one in eleven days, and one lived fifteen weeks and six days, one about four months, one fifteen months, and one, reported by Hilton, survived fourteen years.¹ The most common period of death seems, therefore, to be about forty-eight hours after the receipt of the injury.

The following cases illustrate the accident: A woman, æt. forty-seven, was injured by a blow on the back of her neck; was seen by Mr. Greenwood after eleven days, at which time she was breathing with difficulty, occasioned by paralysis of the intercostal muscles, respiration being carried on by the diaphragm and abdominal muscles alone. This was the extent of the paralysis. There seemed to be a depression opposite the fourth and fifth cervical vertebræ, and pressure at this point occasioned universal paralysis, as did also the acts of coughing and sneezing. About three weeks after the accident, she attempted for the first time to move in order to have her clothes changed, when she was immediately seized with paralysis in the right arm and hand. After this she lost her appetite, had frequent attacks of purging, and thus she gradually wore out.² A patient was admitted into Hôtel Dieu, on account of a fracture of the fourth cervical vertebra, caused by a fall on the back of his neck, and suffering from paralysis of the bladder and extremities. After two months and a half of entire rest, he was convalescent, and quitted the hospital, with only slight weakness in his left leg, and with his head a little bowed forward. In returning from a long walk he fell paralyzed, and remained in the open air all night. From this time he continued to fail, and died thirty-four days after the second fall. On examination after death, the body of the vertebra was found to be broken, and also the processes of the fifth, allowing the fourth to slip forward and compress the cord. A true callus existed in front of these bones, which looked as if recently broken. The cord itself exhibited an annular constriction, which Dupuytren conceived to be the seat of the original lesion narrowed by cicatrization.³

A sailor fell backward from the wharf, striking with the nape of his neck upon a bar of iron. I saw him the following day. He was lying upon his back, breathing rapidly. His lower extremities were completely paralyzed; legs and feet swollen and purple; right arm completely paralyzed, and his left partially; from a point below the line of the second rib there was no sensation whatever; his bowels had not moved, although he had already taken active cathartics; the urine had been drawn with a catheter; the pulse was slower than natural, and irregular. He was constantly vomiting. In reply to questions, he said that he felt well, articulating distinctly and with a good voice. His eyes and face were somewhat congested, but with this exception his countenance did not betray the least physical disturbance. He lived in this condition about forty hours, only breathing shorter and shorter, and his consciousness remaining to the last moment. After death, and before any incision was made, we were unable, upon the most minute examination, to detect any irregularity of the processes of the cervical vertebræ, or any crepitus; but, on dissecting the neck, we found that the arches of the third and fourth vertebræ were broken, and the spinous processes slightly depressed upon the cord. The bodies of the corresponding vertebræ were comminuted, and the vertebræ above were driven down upon them, carrying the processes in the same direction. The theca and the spinal marrow were almost completely severed upon a level with the fourth vertebra.

A man was thrown backward suddenly from the back end of a wagon, alight-

¹ Hilton, Lond. Lancet, Oct. 27, 1860.

² Greenwood, Sir A. Cooper, On Disloc., p. 472.

³ Dupuytren, op. cit., p. 358.

ing upon the top of his head. I found the symptoms almost an exact counterpart of the case just described, except that a crepitus and a mobility of the fragments could be distinctly felt in the upper and back part of his neck. His death occurred in very much the same manner after about forty-eight hours. No autopsy was allowed. We noticed in this case, also, that whenever he was turned over upon his face, respiration almost entirely ceased, but it was immediately restored by laying him again on his back.

[Dr. Powell, of Collinsville, Ill., successfully treated a fracture of the laminæ of the seventh cervical vertebra by means of a wire frame which arched over the head and was supported on the patient's shoulders. By bands passing under the chin and behind the occiput and fastened to this arch the head was lifted from the cervical vertebræ.¹]

Dupuytren, Sir Astley Cooper, South, and other surgeons have related cases simulating fracture, but which proved to be strains of the ligaments uniting the cervical vertebræ, accompanied with more or less injury to the spinal marrow. In one instance, I have met with what has seemed to be a strain of the ligaments and muscles of the neck, but which presented no symptoms of serious injury to the spinal marrow.

4. *Treatment of Fractures of the Bodies of the Vertebrae when the Fracture occurs in any Portion of the Column below the Second Cervical.*


The treatment ought to be, in a great measure, expectant. The patient should be laid in such a position as he finds most comfortable, and, as far as possible, the spine should be kept at rest, since the most trivial disturbance of the fragments, and even that which may cause no pain to the patient, is liable to increase the injury to the spine and prevent the formation of a bony callus. Especially ought the surgeon to be careful, while making the examination, not to turn the patient upon his face, in which position the spine loses its support and a fatal pressure may be produced. The urine should be drawn very soon after the accident, and at least twice daily for the next few weeks. Indeed, it is a better rule to draw the urine as often as its accumulation becomes a source of inconvenience, or whenever the bladder fills, which will in some cases be as often as every four or six hours. It is especially necessary to attend to those urgent demands of the patient during the first few weeks, when the paralysis is most complete generally, and the mucous surface of the bladder, already irritated and inflamed by the excessively alkaline urine, suffers additional injury from any degree of painful distention of its walls. It is unnecessary to say that the frequent introduction of the catheter may itself prove a source of irritation, unless it is managed carefully and skilfully. This duty ought never to be intrusted to an inexperienced operator. It is not desirable to obtain a movement of the bowels during the first few days, by any means, however gentle. The effort to defecate, and the consequent motion, will probably do much more harm than the evacuation can do good; and especially, for the same reason, ought we to avoid putting into the stomach anything which will occasion nausea and vomiting. After the lapse of a few days, if reasonable hopes begin to be entertained of a recovery, it

¹ St. Louis Med. and Surg. Journ., 1889.

will become important to establish regular evacuations of the bowels, either by a judicious management of the diet, by gentle laxatives, or by enemata. At a still later period, when the inflammatory stage is past, and the nerves remain inactive or paralyzed, nothing could be more rational than the employment of strychnia in doses varying from the one-twelfth to the one-eighth of a grain three times daily. No single remedy has more often proved useful in my own practice, or in the practice of other surgeons; but, to derive benefit from this or any other remedy, it must be continued for a long time, perhaps for a year or more. Electricity is sometimes useful. Passive motion and frictions, good fresh air, and nourishing diet, become at last essential to recovery. From an early period, and during the whole course of the treatment, great attention should be paid to the prevention of bedsores, by supporting all those parts of the body upon which the pressure is considerable. For this purpose we may employ circular cushions, air-cushions, and air-beds; but water-beds are very much to be preferred to air-beds as a means of preventing bedsores.

Water-beds must be filled with water at a temperature of 68° Fahrenheit, and they must be secured in position by side boards, or a kind of shallow box, the sides of which are elevated six or seven inches. Permanent extension can be

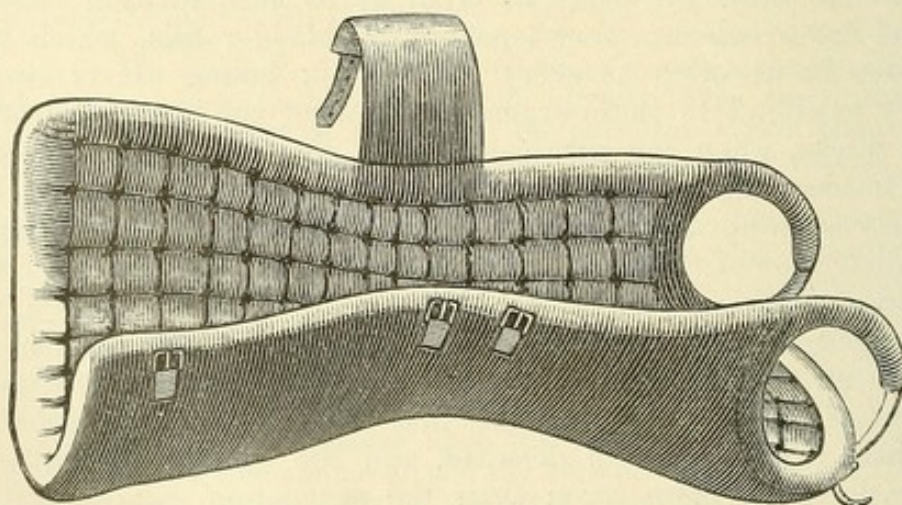
FIG. 65.



Wire-bed.

employed upon these beds as well as upon ordinary beds. Sometimes a section of a bed, three feet square, is found quite as serviceable as an entire bed, inasmuch as the back and nates are the only parts which are liable to bedsores.

FIG. 66.



Bonnet's vertebral gutter.

The wire-bed is an excellent substitute for the water-bed. It is less expensive, more easily managed, more durable, and admits of a much better regulation of the temperature. I have seen no bedsores occur where they were in use. In a

few cases it may be found useful to support the back, including the neck and nates, with a wire cuirass, well padded; and especially where the confinement is greatly prolonged.

When sores have formed, they should be treated, if sloughing, with yeast poultices or the resin ointment. The resin ointment is an excellent dressing for the sores after the sloughs have separated. In case the surface is only slightly abraded, simple cerate forms the best application.

In a few instances surgeons have made some slight attempt to reduce the fracture, or rather to rectify the spinal distortion, generally by the application of moderate extension to the limbs, and by laying the patient horizontally upon a hard mattress. In no case have the patients derived benefit from the attempt, although the deformity was slightly diminished. In no instance did the patient appear to have suffered any damage from the attempt. Such manipulation can seldom serve any useful purpose, and may be a source of mischief; although in cases so generally fatal, it might be very difficult to estimate with much accuracy the amount of injury done. If by any possibility the fragments could be replaced, I know of no means by which they could be kept in place; and in truth we are much more likely to increase the penetration of the spinal cord and the general disturbance, than to diminish it, by extension or pressure. Moreover, it usually inflicts upon the unfortunate sufferer great pain, and for these reasons it ought generally to be discouraged. I have, however, met with two cases of fracture of the lumbar vertebræ, in which relief was afforded by permanent extension. When the fracture is below the middle of the vertebral column, extension, if employed, should be made by adhesive straps, weights and a pulley, as in fractures of the femur; the counter-extension being made by the weight of the body. It will be understood, however, that when paralysis exists the ligation of a limb with bandages will expose the patient to great danger of ulceration and sloughing at and below the points of pressure, and the amount of extension must be very moderate. The proposition to operate in fractures of the bodies of the vertebræ, appears to me too absurd to be entertained for a moment.

[Dr. Bontecou, of Troy, N. Y., recommends extension and counter-extension as in fractures of the thigh. In a case of a severe fracture in the cervical region he shaved the patient's head and applied adhesive plaster to the sides of the face; a fifteen to twenty pounds weight was attached, and the body was placed in an inclined position for over two weeks. He completely recovered, and an autopsy several years after showed an old fracture of the fourth, fifth, sixth, and seventh cervical vertebræ.

Dr. E. M. Moore¹ has long practised extension and counter-extension in fractures of the vertebræ, applying weights to each leg, and recommends this method.

Mr. Barker, of London, reports a case of fracture and displacement of the lower dorsal and first lumbar with paralysis of motion of the left leg and partially of sensation of the left leg, and hyperæsthesia of the right leg. Under ether extension was made from the shoulders and ankles with reduction of the displaced bone, but displacement returned when extension ceased. Crepitus was detected. Permanent extension was then made by attaching a five-pound weight to each leg. Subsequently a plaster-of-Paris jacket, and finally a poroplastic jacket were applied, with the result that the patient made an almost complete recovery.²

Although we are not yet in a position to determine with any accuracy the value of immovable dressings in fractures and displacements of the vertebræ, yet they have given results too favorable in such hopeless cases to be set aside. Plaster-of-Paris dressings have been employed in these cases in Bellevue Hospital by myself and other surgeons, since 1874, but it has not been an established

¹ Tr. N. Y. Med. Assoc., vol. iii, 1886.

² Lancet, Aug. 6, 1887.

method of practice. Dr. Weist, of Richmond, Ind., in 1879, reduced a fracture of the ninth dorsal vertebra during suspension and applied a plaster-of-Paris jacket with great relief to symptoms, and recovery was complete on the sixty-seventh day. König, of Gottingen, in 1880, stated that having used suspension and plaster-of-Paris jackets for caries of the vertebræ with great improvement, he was led to apply a similar treatment to fresh fractures of the spine; he did not advocate its employment in all cases, but in three cases the result was favorable. Wagner, of Königshutte, reported two cases with which he was not at all satisfied; in both he was obliged to remove the jacket; he had seen it produce paralysis, and advises its application only after fourteen days. The German Congress of Surgeons discussed this dressing in 1881, and it was regarded as worthy of trial in selected cases. Dr. Burrell,¹ of Boston, published a paper in 1887 containing a review of this method, and giving the results of his treatment with illustrations. The method consists in suspending the patient with a Sayre's apparatus in the same manner as in caries of the spine, and thus overcoming as far as possible displacement. Then the ordinary plaster-of-Paris jacket is applied and allowed to harden.

Dr. Burrell's conclusions are as follows: 1. In the immediate correction of the deformity and fixation with plaster-of-Paris jacket or other means, we have a rational method of treating a large number of cases of fracture of the spine. 2. Considering the hopelessness of results in fracture of the spine when treated expectantly, almost any risk is justifiable. 3. The immediate correction of the deformity is imperative if softening of the cord can and does occur from pressure at the end of forty-eight hours. 4. The suspension of the patient is only a means of rectifying the deformity; certain fractures could be simply pressed into position while the patient lies prone or supine.

The dangers of this treatment are apparent, viz.: A liability, especially in fractures in the cervical region, of causing shock, collapse and death, or of making greater pressure upon the spinal cord, or even of severing it.]

§ 5. Fractures of the Axis and Odontoid Process.

The phrenic nerve is derived chiefly from the third and fourth cervical nerves. If, therefore, the second cervical vertebra is broken, and considerably depressed upon the spinal cord, respiration ceases immediately, and the patient dies at once, or survives only a few minutes. In such examples of fracture of this bone as have not been attended with these results, the displacement and consequent compression have been inconsiderable, or there has been no displacement at all.

Mr. Else, of St. Thomas's Hospital, says that a woman in the venereal ward, and who was then under a mercurial course, while sitting in bed, eating her dinner, was seen to fall suddenly forward; and the patients, hastening to her, found that she was dead. Upon examination of her body, it was discovered that the processus dentatus of the axis was broken off, and that the head in falling forward had driven the process backward upon the cord so as to cause death.² Sir Astley Cooper also relates the case of a man who was shot by a pistol through the neck, breaking and driving in upon the spinal marrow both the "lamina and the transverse process" of the axis. He died on the fourth day.³ Malgaigne has collected three cases of fracture of the odontoid apophysis, all of which were accompanied with displacement of the atlas. The first, reported by Richet, died on the seventeenth day; the second, reported by Palletta, died after one month and six days; and the third, by Costes, lived four months and two weeks. Swan has reported a case, also, of fracture accompanied with dislocation of the head upon the atlas, in which death ensued immediately after.⁴

¹ Boston Med. and Surg. Journ., August 25, 1887.

² Else, Sir A. Cooper on Disloc., op. cit., p. 462.

³ Sir A. Cooper on Disloc., etc., op. cit., p. 476.

⁴ Swan, Boston Med. and Surg. Journ., 1877, vol. i. p. 226.

Rokitansky says that there is a specimen contained in the Vienna Museum, taken from a patient who survived the accident some time, although the fragments never united.

M. Denucé, of Bordeaux, has seen a case of *incomplete* fracture of this process, caused by a gunshot, the ball having lodged in the body of the bone. The patient survived four weeks.¹

The following case is reported by Parker, of New York :

"The patient was a man forty years of age, a milkman by occupation, of medium height, of active business habits, and capable of great endurance. His life was one of constant excitement, and he was addicted to the free use of liquors. He suffered, however, from no other form of disease than occasional attacks of rheumatism, for which he was accustomed to take remedies of his own prescribing, which were generally mercurials, followed by liberal doses of iodide of potassium, 'to work it all out of the system.'

"On the 12th of August, 1852, while driving a 'fast horse' at the top of his speed on the plank road near Bushwick, L. I., he was thrown violently from his carriage by the wheel striking against the toll-gate. He alighted upon his head and face about fifteen feet from his carriage. Upon rising to his feet he declared himself uninjured, but soon after complained of feeling faint; after drinking a glass of brandy he felt better, got into his carriage with a friend, and drove home to Rivington Street in this city, a distance of more than two miles. There was so little apparent danger in this case that no physician was called that night. Early on the morning of the following day, Dr. B. was called to visit him. He found his patient reclining in his chair, in a restless state, and learned that he had suffered considerable pain in the back part of his head and neck during the night. He was entirely incapacitated to rotate the head, which led to the suspicion of some injury to the articulations of the upper cervical vertebræ; but so great a degree of swelling existed about the neck as to prevent efficient examination. There was no paralysis of any portion of the body, his pulse was about 90, and his general system but little disturbed. The swelling so much subsided that on the fifth day an irregularity was discovered to exist in the region of the axis and atlas, which had many of the features of a partial luxation of these vertebræ.

"At this time he began to walk about the room, having previously remained quiet on account of the pain he suffered on moving. He persisted in helping himself, and almost constantly supported his head with one hand applied to the occiput. He often remarked, if he could be relieved of the pain in his head and neck, he should feel well. He began to relish his food, and the swelling nearly disappeared at the end of a week, leaving a protuberance just below the base of the occiput, to the left of the central line of the spinal column, with a corresponding indentation. Notwithstanding strict orders to remain quietly at home, on the ninth day after the accident he rode out, and in a day or two after returned as actively as ever to his former occupation of distributing milk throughout the city to his old customers. During the following four months no material change took place in his symptoms, although he constantly complained of pain in his head. For this period he did not omit a single day his round of duties as a milkman, which occupied him constantly and actively from five o'clock in the morning to early noon. On the 1st of November, Prof. Watts examined him, and inclined to the opinion that there was a luxation of the upper cervical vertebræ.

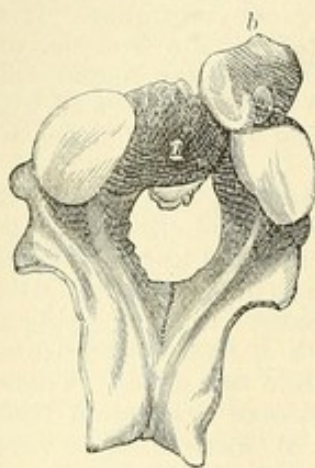
"About the 1st of January, 1853, the pains, from which he had been a constant sufferer, became more severe, and he was heard to complain that he could not live in his present condition; he remarked, also, that he had heard a snapping in his neck. After going his daily round on the 11th of January, he complained of feeling cold, and afterward of numbness in his limbs. In the evening he had a chill, and complained of a pain in his bowels. He passed a restless night, and arose on the following morning about six o'clock; he was obliged to have assistance in dressing himself, and experienced a numbness of his left, and afterward of his right side. He attempted to walk, but could not without help, and it was observed that he dragged his feet. He sat down in a chair and almost

¹ Denucé, *Nouv. Dic. de Méd. et. de Chir. Prat.*, t. iii. p. 810.

instantly expired, at eight o'clock, A. M., on the 12th of January, precisely five months from the receipt of the injury.

"The autopsy was made thirty hours after death. Muscular development uncommonly fine. An unusual prominence discovered in the region of the axis and atlas. On making an incision from the occiput along the spines of the cervical vertebræ, the parts were found to be very vascular. These vertebræ

FIG. 67.



Fracture of the odontoid process of the axis. Parker's case. a. Broken surface. b. Odontoid process.

were removed *en masse*, and a careful examination instituted. The transverse, the odontoid (ligamenta moderatoria), as also all the ligaments of this region, excepting the occipito-axoideum, were in a state of perfect integrity; this latter was partially destroyed. A considerable amount of coagulated blood was found effused between the fractured surfaces, some of it apparently recent, but much of it was thought to have occurred at the time of the accident, and afterward to have prevented the union of the bones. The spinal cord exhibited no appearances of any lesion. The odontoid process was found in the position well represented in the accompanying illustration, completely fractured off, and its lower extremity inclining backward toward the cord. Death finally took place, doubtless, from the displacement of the process during some unfortunate movement of the head, by which pressure was made upon the cord. The destruction of the occipito-axoid ligament, which would otherwise have protected the contents of the spinal cavity, must have favored this result."¹

Vander Poel, of New York, has reported the case of a man, æt. twenty-one, who had fallen from a carriage upon the back of his head. The symptoms which ensued led his surgeons to believe that he had experienced a fracture of the fourth cervical vertebra. His condition subsequently improved to such a degree that he was able to perform light labor; but after six months they became aggravated, and he died six months and a half after the accident, of apnœa. The autopsy revealed a transverse fracture of the odontoid process, the transverse ligament being uninjured. There was no other fracture of the vertebræ.²

Dr. Philip Bevan presented to the Surgical Society of Ireland, in 1862, a specimen obtained from the dead-room, and which was supposed to be an epiphyseal separation of the odontoid process, occurring in early life. The history of the case is not known, although the woman was forty years old when she died. It does not appear very clear to us whether this was really an epiphyseal separation, or the result of some morbid process.³

Dr. W. Bayard, of St. John, N. B., has, however, reported a case of separation of the odontoid process in a child, followed by complete recovery. In August, 1864, Charlotte Magee, of St. John, æt. six years, previously in excellent health, fell five feet, striking on her head and neck, causing an immediate immobility of the head, which continued about two years and a half, when an abscess formed in the back of the pharynx, and the bone was spontaneously discharged. Since then she has been able to move the head freely, and her recovery may be said to be complete.⁴ The specimen was subsequently presented to the New York Pathological Society, and no doubt remains that the entire process was thrown off.

Dr. Stephen Smith,⁵ who has written a very instructive paper on this subject, has collected 23 cases of separation of the odontoid process, at least 20 of which must be regarded as fractures. The ages of the patients range from three years to sixty-eight. Eight of this number were spontaneous, the separation being

¹ Bigelow, New York Journ. Med., March, 1853, p. 164.

² Vander Poel, Arch. Clin. Surg., vol. ii. p. 116.

³ Bevan, Amer. Journ. Med. Sci., April, 1864. From Dublin Med. Press, Feb. 18, 1863.

⁴ Bayard, Canada Med. Journ., Dec. 1869.

⁵ Stephen Smith, Amer. Journ. Med. Sci., Oct. 1871, p. 338.

apparently due to some progressive disease or atrophy of the bone. Two of these recovered after the formation of abscesses in the pharynx and the extrusion of the bone. In four cases the fractures were gunshot, and one died. The remainder, so far as ascertained, were in consequence of blows upon the head; and of these only the girl Charlotte Magee recovered. Of the whole number, 23, three were without history, two of them being dissecting-room cases.

Symptoms.—These will depend much upon the cause and complications of the accident. In all cases there will be more or less inability to support the head in the erect posture, and if displacement exists, or if the products of inflammation press upon the cord, a proportionate impairment of its functions must ensue.

Treatment.—The treatment consists in absolute quietude, with moderate extension, effected by means of suitable apparatus.

[The mode of death in fracture of the odontoid varies. It may be instantaneous from pressure of the broken process upon the medulla; or the pressure may be gradual, in which case the displacement takes place by degrees, giving rise to partial paralysis, generally in one hand first, then in the foot of the corresponding side, and finally complete paraplegia of all the parts below the middle of the neck, and death follows from exhaustion. The symptoms of a well-marked case are very significant. The patient is careful about maintaining the poise of the head, and fears to be jostled; he carries his head as if steadying a weight upon it unsupported by his hands. The foramen magnum being a little posterior to the centre of the skull, patients generally elevate the chin in order to preserve the centre of gravity; whenever they wish to elevate the eyes above the ordinary level they support the occiput in the hand, and in looking downward they support the chin in the hand. If the relations of the head are disturbed by a shock they seize it upon the sides with both hands, and hold it firmly. On attempting to rise from bed they elevate the head with the hand applied to the occiput, and in bed turn the head cautiously with the hand.]

A patient manifesting these symptoms after an injury to the head, demands the most careful treatment. The cervical vertebræ must be immediately immobilized by apparatus which retains the head in a fixed position, as nearly normal as possible. The dressing may be a sole-leather splint applied to the neck and occiput, moulded while wet, or a plaster-of-Paris or silicate dressing may be used. With these forms of dressing a patient may soon move about cautiously. If the case requires the recumbent position the parts may be firmly supported by sand-bags or other firm appliance.]

§ 6. Fractures of the Atlas.

I have been able to find only one example of a fracture of the atlas alone, and this is the case related by Sir Astley Cooper as having come under the observation of Mr. Cline.

A boy, about three years old, injured his neck in a severe fall; in consequence of which he was obliged to walk carefully upright, as persons do when carrying a weight on the head; and when he wished to examine any object beneath him, he supported his chin upon his hand, and gradually lowered his head, to enable him to direct his eyes downward. In the same manner, also, he supported his head from behind in looking upward. Whenever he was suddenly shaken or jarred, the shock caused great pain, and he was obliged to support his chin with his hands, or to rest his elbows upon a table, and thus support his head. The boy lived in this condition about one year, and after death Mr. Cline made a dissection, and ascertained that the atlas was broken in such a manner that the

odontoid process of the axis had lost its support, and was constantly liable to fall back upon the spinal marrow.¹

§ 7. Fractures of the First Two Cervical Vertebrae (Atlas and Axis) at the Same Time.

A woman, æt. sixty-eight, fell down a flight of steps, striking upon her forehead, and died immediately. Upon making a dissection, it was found that the atlas was broken upon both sides near the transverse processes, and the odontoid process of the axis was broken at its base. These fractures were accompanied with a rupture of the atlido-odontoid ligaments, and a dislocation of the atlas backward.²

South says there is a specimen in the museum of St. Thomas's Hospital, showing this double fracture. The man had received his injury only a few hours before admission to the hospital, and died on the fifth day. On examination, the atlas was found to be broken in two places, and the odontoid process of the axis at its root. The fifth vertebra was also broken through its body. With neither fracture was there sufficient displacement to produce pressure, but a small quantity of extravasated blood lay in the substance of the spinal marrow, and its tissue was at one point broken down and disorganized.³

Mr. Phillips relates that a man fell from a hay-rick, striking upon the occiput; after which, although momentarily stunned, he walked half a mile to the parish surgeon, and in two days more he returned to his occupation. About four weeks after the accident he was seen by Mr. Phillips, who discovered a small tumor over the second cervical vertebra, pressure upon which caused a slight pain. He complained also that his neck was stiff, and that he was unable to rotate it. No other disturbance of the functions of the body could be discovered. After a time the tonsils became swollen, and the patient experienced some difficulty in deglutition, and, upon examining the throat, a slight projection or fulness was discovered at the back of the larynx, opposite the second cervical vertebra. Subsequently he became affected with general anasarca and pleuritic effusions, of which he finally died. Up to the last week of his life he was able to walk about his bedroom, and his condition presented no other evidence than has been mentioned, that he was suffering from an injury of the spine. He died forty-seven weeks after the receipt of the injury.

The autopsy disclosed a fracture with displacement of the atlas, and a fracture of the odontoid process of the axis. The two vertebrae were united to each other firmly by complete bony callus.⁴

Wynperse describes a specimen of gunshot fractures of both bones, in which the ball was found imbedded in callus which united the two halves of the anterior arch of the atlas. M. Gaucher has also reported a similar gunshot fracture, the subject of which survived nine months, death finally ensuing upon a secondary displacement of the fragments.⁵

¹ Cline, Sir Astley Cooper, op. cit., p. 459.

² Malgaigne, op. cit., tom. ii. p. 333.

³ Chelius's Surgery, note by South, vol. i. p. 588.

⁴ Phillips, Med.-Chir. Trans., vol. xx. 1837, p. 384.

⁵ Wynperse, Gauchet. French ed. of this treatise, by Poincot, p. 189.

CHAPTER XVII.

FRACTURES AND DIASTASES OF THE STERNUM.

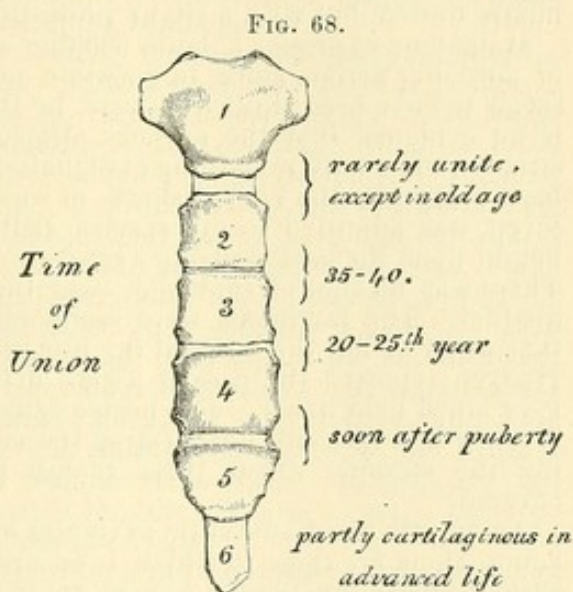
FRACTURES and diastases of the sternum are of rare occurrence, owing, probably, to the elasticity of the ribs and their cartilages, upon which it mainly rests, and also, in part, to the softness of its structure. In advanced life, the ossification and fusion of all of its several portions becoming more complete, and the cartilages of the ribs also becoming more or less ossified, a true fracture is relatively more frequent.

[Gurlt gives the proportion of fractures of the sternum to those of other bones as 1 in 100, and Lonsdale as 2 in 1900. Lane¹ states that the proportion of fractures of the sternum to those of other bones found among the bodies examined in the dissecting-room has been far in excess of these estimates.]

In some cases no doubt these accidents ought to be regarded as true luxations, inasmuch as occasionally the union of the manubrium with the gladiolus is by a perfectly formed diarthrodial articulation, as was first demonstrated by Maisonneuve in 1842. We have, however, in general no absolute means of knowing whether before the accident the several portions which compose the sternum were united by bone, by a single piece of cartilage, or by two distinct cartilages with a synovial surface interposed.

Causes.—These fractures are the result of direct blows inflicted upon the part, such as the passage of a loaded vehicle across the chest, the fall of a tree or of some heavy timber upon the body; the fracture implying always that great force has been applied. Indirect blows and voluntary muscular action alone have been known also occasionally to produce these accidents.

David (*Mémoire sur les Contrecoups*) mentions the case of a mason, who, in falling from a great height, struck upon his back against a cross-bar which intercepted his fall, in consequence of which the abdominal and sterno-cleido-mastoidean muscles were so stretched that the sternum broke asunder between its upper and middle portions.² Sabatier reports another case of separation at the same point, produced in a similar manner;³ and Roland has described a third example in a woman sixty-three years old, who, falling from a height backward



Sternum, showing the periods at which its several parts unite by bone. (From Gray.)

¹ Trans. Path. Soc. Lond., vol. xxxvi.

² Boyer on Diseases of the Bones, first Amer. ed., 1805, p. 57.

³ Malgaigne, from Sabatier, *Mém. sur la Fract. du Sternum*.

and striking upon her back, broke the sternum near its centre.¹ Gross and Hodgen have recorded similar cases.² Cruveilhier saw a man who, having fallen from a height of twenty feet upon his nates, was found to have a fracture of the sternum.³ Cussan saw the same result in a person who fell from a third story, striking first upon his feet and then pitching over upon his back.⁴ Maunoury and Thore have reported an analogous case, where a man fell from a height of twelve or fifteen metres, first striking upon his feet and then falling over upon his back and head.⁵ Johnson reports a case in which a laborer had fallen from the top of a hay-cart, striking only upon his head. He walked with his head much bent forward, and was incapable of either flexing, extending, or rotating it any further. The fracture was transverse, and about three inches below the top of the sternum, opposite the centre of the third rib, the lower fragment projecting in front of the upper. The fragments were easily replaced by simply throwing the head back, and fell into place with an audible snap, but immediately resumed their unnatural position when the head was flexed. They finally united, but with a slight projection and overlapping.⁶

Malgaigne expresses a doubt whether all these can be considered as the results of muscular action, since, in a certain number of the examples cited, the head seems to have been thrown forward by the concussion, and in others, also, there is no evidence that the muscles attached to the sternum were put upon the stretch. The only remaining explanation is that in such cases the sternum has been broken by the violent shock, or *contrecoup*. In 1877, J. McL., æt. twenty-seven, was admitted to my service, Bellevue Hospital, who had fallen from a height upon his back, causing a separation of the manubrium from the gladiolus. There was no sign of contusion over the point of separation, but crepitus was distinct. The fragments were easily replaced and maintained in position, so that when he left the hospital the line of separation could scarcely be felt. Dr. Hodgen reported the case of a man driving under a low bridge, with his head very much bent down. The bridge caught his back, opposite the shoulder, and crushed him forward, "separating the vertebræ in the dorsal region, and breaking the sternum about three inches below its upper end." This man recovered.

Among the most authentic examples of separation of this bone from muscular action alone are those in which it occurred during labor. Chaussier saw two cases occurring in young women in their first labors; the separation having occurred when the head was thrown backward as far as possible. Compte and Martin,⁷ Luchetté, and Posta⁸ have reported similar examples.

Malgaigne collected three of these cases, and Dr. Packard reports two. The separation took place at or near the junction of the first and second pieces of the sternum. Dr. Borland has added one more example, which took place at a point near the fourth costal cartilage.⁹ Malgaigne relates the case of a mountebank, who, leaning back to lift with his feet and hands a weight, felt suddenly a severe pain in the sternal region, and fell over with a fracture of this bone.

Mr. Ancelot has reported a case from gymnastic exercise.¹⁰

The mere act of violent coughing has caused diastasis or fracture of the sternum. Mr. Howbridge remarks that the ribs and sternum have been broken in this way; but he adds, that in all probability they are weakened by partial absorption or atrophy.¹¹ Lutz reports a case also, of a man æt. thirty-eight, the subject of rheumatism and asthma, and who had also emphysema of a portion of one lung. During a violent fit of coughing he felt something give way on his chest. Severe pain followed, and some swelling. Lutz found the manubrium

¹ Ibid., from Bull. de Thérap., tom. vi. p. 288.

² Gross, System of Surg., 5th ed., vol. i. p. 964. Med. Record (N. Y.), Dec. 22, 1877.

³ Malgaigne, from Bull. de la Soc. Anat., Juin, 1826.

⁴ Ibid., from Archiv de Méd., Janv. 1827.

⁵ Ibid., from Gaz. Méd., 1842, p. 361.

⁶ London Med.-Chir. Rev., vol. xvii., new series, p. 536, 1832.

⁷ Classical Diet. Med. and Surgery, xiv. 70, Venice. Quoted by Borland, loc. cit.

⁸ Bolletino delle Scienze Med. di Bologna, 1857. Quoted by Borland, loc. cit.

⁹ J. N. Borland, M.D., Boston Med. and Surg. Journ. April 20, 1875.

¹⁰ Ancelot, from Lutz.

¹¹ Holmes's System of Surgery, 2d. ed., vol. ii. p. 37.

separated from the gladiolus, the former being slightly displaced forward. He was much relieved of his distress by "stretching his neck and throwing his head backward." Lutz directed him to make a deep inspiration, at the same time throwing back the head and shoulders. A compress was placed over the projection, and secured in place by a broad and firm band covering the entire chest. Union took place, but with a slight overlapping.¹

[Mr. Lane has demonstrated by experiments of the subject that blows on a padded shoulder may produce fracture of the sternum.]

Malgaigne affirms that he has collected in all ten cases which should be regarded as luxations. According to the plan which I have adopted of disregarding the distinction between fractures, diastases, and dislocations of the sternum, for the reason chiefly that the exact diagnosis is in general impossible, and never of any practical value, these cases should be included in this enumeration of fractures and diastases.

The following case, which came under my own observation, proves the possibility of backward displacement of the xiphoid cartilage:

A man, twenty-eight years old, fell forward, striking the lower end of his sternum upon the top of a candlestick, breaking in the xiphoid cartilage. During two years following the accident he had frequent attacks of vomiting, which were excessively violent and distressing, the paroxysms occurring every five or six days. Twelve years after the accident I found the xiphoid cartilage bent at right angles with the sternum, pointing directly toward the spine. He now suffered no inconvenience from it, except that it hurt him occasionally when he coughed.² Polaillon relates the case of a woman, æt. thirty-five, who, being pregnant and wearing a very tight corset, bent herself forward so as to press the steel of the corset upon the xiphoid cartilage. The cartilage was thrown back and remained in this position, causing for a long time much distress when the stomach was disturbed. The surgeons were unable to reduce the fracture, but eventually it ceased to cause inconvenience.³ In Martin's case the accident was followed by persistent vomiting; which was finally relieved when the surgeon seized the cartilage with his fingers and restored it to place. In Billard's case the cartilage was restored to its place with a blunt hook, after having made an incision which penetrated the peritoneal cavity.

[Horrocks⁴ reported a case of fracture through the ensiform cartilage leaving a fragment one inch and a quarter in length, the lower end of which projected forward.]

The direction of these fractures and diastases is generally transverse, or nearly so; occasionally a slight obliquity is found in the direction of the thickness of the bone. In three or four examples upon record, the direction of the separation was longitudinal. It is not so unfrequent, however, to find the bone comminuted. Compound fractures are exceedingly rare. When the line of separation is transverse, the lower fragment is generally displaced forward, and sometimes it slightly overlaps the upper fragment; in other cases the direction of the displacement is the reverse.

The following was a remarkable case of separation of the manubrium from the gladiolus, accompanied with a true fracture and other complications:

L. W., æt. sixty, fell through the hatchway of a vessel. He had a compound comminuted fracture of the right leg, a fracture of the first four ribs on each side at their necks, a dislocation of the sternum from the cartilages of both second ribs, a dislocation of the left third cartilage from its rib, a dislocation of the first from the second bone of the sternum, and a transverse fracture of the

¹ Paper read before the St. Louis Medical Society by F. J. Lutz, A.M., M.D. St. Louis Med. and Surg. Journ., July, 1877.

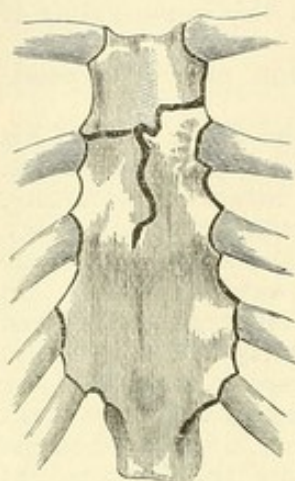
² Buffalo Med. Journ., vol. xii. p. 282, Cases of Fractures of the Sternum.

³ Polaillon, Soc. de Chir. du Paris, p. 97, 1876. (Poinsot.)

⁴ Brit. Med. Journ., Dec. 11, 1886.

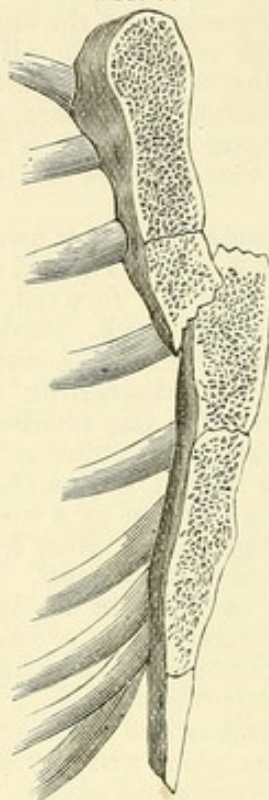
sternum three-quarters of an inch below the top of the gladiolus. The dislocation of the manubrium was complete, and it was thrust behind the upper end of the gladiolus, underlapping it half an inch. The transverse fracture three-quarters of an inch lower down was also complete, and the fragment thus separated was divided into two, namely, an anterior and a posterior fragment, by a trans-

FIG. 69.



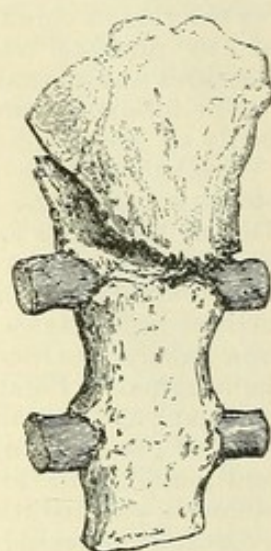
Longitudinal fracture.

FIG. 70.



Transverse fracture.

FIG. 71.

Fracture of the first piece
of the sternum.

verse splitting; the anterior moiety retaining its attachment to the periosteum below, and not being displaced, while the posterior moiety retained its attachment to the periosteum both above and below, and was pushed downward by the descent of the manubrium. His mind was clear, but he had paralysis of the bladder, and was breathing with some embarrassment. I had no difficulty in diagnosing the dislocation of the third cartilage, and of the manubrium. There was no swelling or discoloration on the front of the chest, but it was quite tender. His head was not thrown forward. He complained of some soreness on the back of his head. His general condition was such that I did not attempt reduction. The following day he expectorated blood, and on the third day he died. The autopsy revealed some effusions of blood underneath the pleura, but no lesions of the heart or lungs. The evidence is in this case conclusive that he struck upon his back and head, in fact, that it was a fracture from counter-stroke, by which the head, neck, and three or four upper vertebræ were bent forward with great force, thus doubling forward the top of the sternum. Dr. Robert Watts, Jr., has reported a very similar case, in which death occurred on the same day. The fragments of the sternum were not displaced, but the ribs had suffered similar lesions.¹

Diagnosis.—In a few cases the patients have felt the bone break at the moment of the accident. When displacement exists, it may generally be easily recognized, and the lower fragment will often be seen to move forward and backward at each inspiration and expiration. Crepitus

¹ Watts, Amer. Med. Times, vol. iii. p. 55.

may also be detected in some of these examples. To determine its existence, the hand should be placed over the supposed seat of fracture, while the patient is directed to make forced inspirations and expirations, or the ear may be applied directly to the chest.

Emphysema has, also, occasionally been noticed, indicating usually that the lungs have been penetrated by the broken fragments. The frequent occurrence of congenital malformations of the sternum should warn us to exercise great care in our examinations, lest we mistake these natural irregularities for fractures. The point of junction of the first and second portions has also occasionally been observed to be somewhat projected forward in cases of chronic asthma and emphysema of the lungs.

Bransby Cooper mentions a remarkable instance of malformation of the xiphoid cartilage which he at first suspected to be a fracture. It was so much curved backward that, as Mr. Cooper thinks, its pressure upon the stomach produced a constant disposition to vomit whenever he had taken a full meal, or had taken a draught of water.¹

Prognosis.—In simple fracture or diastasis of this bone, uncomplicated with lesions of the subjacent viscera, and especially when the separation is the result of muscular action or of counter-stroke, no serious consequences are to be apprehended. The bone unites promptly by osseous or fibrous tissue, even were it is found impossible to bring its edges into apposition. Indeed, generally, where the fragments have been once completely displaced, although it is not difficult to replace them momentarily, a redisplacement soon occurs, and they are found finally to have united by overlapping; but no evil consequences usually result from this malposition. In nearly all of the cases reported in which palpitations, difficult breathing, etc., have been charged to the persistence of the displacement, the injuries were of such a character as to furnish for these unfortunate results other and much more adequate explanations. In one instance only, already mentioned, serious inconveniences followed from a displacement of the cartilage backward. In other cases, however, where the fracture is the result of a direct blow, the prognosis is often very grave; a conclusion to which one would naturally arrive from the fact already stated, that the fracture of the sternum, thus produced, in itself implies the application of great force. An abscess occurring in the anterior mediastinum, and caries or necrosis of the bone, are among the most common results of a blow delivered directly upon the sternum; complications which generally end sooner or later in death. Blood may be also extensively effused into the anterior mediastinum.

[Bennett,² of Dublin, reports a fatal case of fracture of the sternum, very oblique in its direction, accompanied by a rupture of the trachea, which had separated an inch.]

Where emphysema is present, we may anticipate inflammation of the pleura and of the lungs.

¹ B. Cooper, *Princ. and Pract. of Surg.*, p. 359.

² *Dub. Journ. Med. Sci.*, vol. lxxxvi.

In several instances, where death has occurred speedily after the injury, the heart has been found penetrated and torn by the fragments. Sanson and Dupuytren have each reported one example of this kind. Duverney has mentioned two, and Samuel Cooper says there is a specimen in the museum of University College exhibiting a laceration of the right ventricle of the heart by a portion of fractured sternum. Watson mentions a case in which the pericardium was torn, but the heart was only contused.¹

Treatment.—When the fragments are not displaced, the only indications of treatment are to immobilize the chest, and to allay the inflammation, pain, etc., consequent upon the injury to the viscera of the chest. The first of these indications is accomplished, at least in some degree, by inclosing the body, from the armpits down to the margin of the floating ribs, with a broad cotton or flannel band. A single band, neatly and snugly secured, and made fast with pins, is preferable to, because it is more easily applied than, the roller which surgeons have generally employed; it is also much less liable to become disarranged. It should be pinned while the patient is making a full expiration. To prevent its sliding down, two strips of bandage should be attached to its upper margin, and crossed over the shoulders in the form of suspenders. Generally the patients prefer the half-sitting posture, with the head and shoulders thrown a little backward; and this is the position which will be most likely to maintain the fragments in place, and also to secure immobility to the external thoracic muscles, while it leaves the diaphragm and the abdominal muscles free to act. The second indication may demand the use of the lancet; but more often it will be found necessary to allay the pain and disposition to cough by the use of opium. If, however, the fragments are displaced, it is proper first to attempt their reduction; which, as I have already intimated, is generally more easy of accomplishment than is the maintenance of them in place until a cure is effected. The fragments may sometimes be made to resume their natural position by a single full inspiration, but then they usually fall back during expiration; or they may be reduced by straightening the spine forcibly, and at the same time drawing the shoulders back.

[Porter,² of Boston, failed in his attempt at reduction by bending the patient backward; on returning to bed the patient took a deep respiration and coughed, when the bones snapped forward into place.

Irwin,³ U. S. A., placed a large, hard pad, covered with soft material, between the scapula; while the patient inspired deeply and the head and shoulders were extended well backward, the displaced fragments were returned and retained in their normal position by a suitable splint applied over the pad and across the spine, the expanded condition of the thorax being maintained by a figure-of-8 bandage to the shoulder.]

Verduc and Petit proposed, in those cases in which it was found impossible to reduce the fragments by these simple means, to cut down and lift the depressed bone. Nélaton suggests the use of a blunt crotchet introduced through a narrow incision; and Malgaigne has thought of another plan, which is, to penetrate the skin with a punch, and directing it to the broken margin, to push the fragment into its place, but which he does not himself regard as a suggestion of much value, since the bone is too soft to afford the necessary resistance; and, moreover, this, in common with all of the other similar methods, is liable, in some degree,

¹ Watson, New York Journ. of Med., vol. iii. p. 351.

² Bost. Med. and Surg. Journ., April 12, 1888.

³ Med. News, June 23, 1888.

to the objection that it may increase the tendency to caries and suppuration, already imminent. If reduced, the fragments will probably immediately again become displaced; and, more than all, it still remains to be proved conclusively that the mere riding of the fragments is in itself ever a cause of subsequent suffering, or even of inconvenience.

When an abscess has formed in the anterior mediastinum, surgeons have occasionally recommended the use of the trephine. Gibson has twice operated in this manner at the Philadelphia Hospital, but in each case the caries continued to extend, and the patient died; an experience which has inclined him latterly to discountenance the operation.¹ There are other considerations mentioned by Lonsdale, which ought to decide us never to use the trephine in these cases:—"For the symptoms denoting the presence of the abscess, when completely confined to the under surface of the bone, will be very uncertain; and when the matter collects in large quantities, it will show itself at the margin of the sternum, between the ribs, when it can be let out by making a puncture with the point of a lancet, without the necessity of removing a portion of the bone."² Ashhurst, referring to the same point, remarks: "The fact that the mediastinal space can be cut into without injury to the pleura is shown by many cases, among others by one which came under my own observation."³

CHAPTER XVIII.

FRACTURES OF THE RIBS AND THEIR CARTILAGES.

§ 1. Fractures of the Ribs.

THE force requisite to break the ribs is scarcely less than that requisite to break the sternum; and in childhood and infancy it is sometimes almost impossible to break them, so that children and even adults are often crushed and killed outright, where, although the pressure has been directly upon the thorax, the ribs have resumed their positions, and have been found not to be broken. I have met with several examples of this kind.

In my records, not including fractures from gunshot injuries, only thirty-two patients are reported as having had broken ribs; but, as in several of the cases, two or more ribs were broken at the same time, the total number of fractures is about sixty-five. If, however, I had always accepted the diagnosis made by other surgeons, the number would have been much greater, since I have been repeatedly assured that the ribs were broken when, upon the most careful examination, no evidence, beyond the existence of a severe pain and of difficult respiration, has been presented to me.

In old age the cartilages ossify, and the ribs themselves suffer a gradual atrophy, which renders them much more liable to break.

Etiology.—The most common causes are direct blows, of very great force, in consequence of which sometimes the fragments are not only broken, but more or less forced inward; occasionally they are the result

¹ Gibson, *Institutes and Practice of Surgery*, vol. i. p. 269.

² Lonsdale, *Practical Treatise on Fractures*, London, 1838, p. 242.

³ Ashhurst, *Amer. Journ. Med. Sci.*, Jan. and Oct. 1862.

of counter-strokes, and then the fragments, if they deviate at all from their natural position, are salient outward; a species of fracture which I have not met with so often.

Malgaigne has collected eight examples of fractures of the ribs produced by muscular action, by the beating of the heart, etc., all of which occurred upon the left side. In six additional cases collected by M. Paulet, the fractures were upon the right side. Three of these were caused by coughing, and two by a sudden movement of the body. It is believed, however, that in all of these cases the ribs had previously become atrophied, and perhaps undergone other changes in their structure, rendering them liable to fracture from the action of trivial causes. Morselli attributes the frequency of fracture of the ribs in the insane to trophic changes in the structure of the ribs, dependent upon lesions of the nervous centres.¹

Pathology, Seat, etc.—The fourth, fifth, sixth, and seventh ribs are most liable to be broken; the upper ribs, and especially the first rib, being so well protected in various ways as to diminish greatly their liability, while the loose and floating condition of the last two ribs gives them an almost complete exemption.

Malgaigne has noticed, also, contrary to the general opinion of surgeons, that the ribs are most often broken in their anterior thirds, whether the cause has been a direct or a counter blow. My own observations confirm this statement.

The direction of the fracture is generally transverse or slightly oblique; sometimes it is quite oblique. It is often compound; and in a few instances I have found it comminuted or multiple. Where the fracture is compound, it is rendered so generally by the fragments having penetrated the lungs, and not by a tegumentary wound. Displacement cannot occur in the direction of the axis of the bone unless several ribs are broken at the same time. The fragments are therefore either not at all displaced, or they fall inward toward the cavity of the chest, or outward, or very slightly downward, in the direction of the intercostal spaces. Sometimes the rib rotates a little upon its own axis.

Prognosis.—Death occurs sooner or later in a pretty large minority of the cases in which the ribs have been broken; yet not often as a direct consequence of the fracture, but only as a result of the injury inflicted upon the viscera of the chest, or of other injuries received at the same moment. The violent compression of the heart and lungs has frequently produced death, and sometimes, as I have more than once seen, almost immediately; or the patients have succumbed at a later period to acute pneumonitis, or pleuritis.

Lonsdale saw a case in which, the body of a man having been traversed by the wheel of a wagon, eight ribs were broken, and, death having followed almost immediately, the autopsy disclosed a rent in the left auricle of the heart, produced by one of the broken ribs.² Dupuytren reports a similar case and has also seen several deaths produced by the emphysema, independent of the fracture.³ Amesbury has seen a case of death from rupture of the intercostal artery, where there was no injury of the lungs.⁴ M. Paulet has studied a series of examples of rupture of this artery in connection with fracture of the ribs, ob-

¹ Paulet, Morselli, French ed. of this treatise, by Poincot.

² Lonsdale on Fractures, p. 258.

³ Dupuytren, op. cit., p. 79.

⁴ Amesbury on Fractures, vol. ii. p. 612.

tained from various sources, and has drawn the following conclusions: First, lesion of the intercostal artery in this class of accidents is much more frequent than is generally supposed. Second, the lesion is always grave, and often mortal. Third, it may occur not only after comminuted fractures, but after simple, and even after incomplete fractures, provided the fracture is on the lower border of the rib.¹

In several instances observed by me, patients have suffered from pains in the side, occasionally from cough, etc., after the lapse of two or more years, and I suspect it is no uncommon thing for these injuries to entail some such permanent disability, but which is a consequence rather of the injury to the viscera of the chest, than of any condition of the broken ribs themselves. In general, simple fractures of the ribs unite in from twenty-five to thirty days.

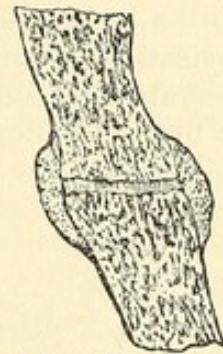
Malgaigne has seen one case of non-union; Huguier met with another upon the cadaver, in which a complete false joint existed, furnished with a capsule and lined with synovial membrane;² Eve, of Nashville, Tenn., saw a case of non-union, occasioned, probably, by a caries or necrosis of the bone, since it was accompanied with a discharge of matter, and in which a removal of the ends of the fragments resulted promptly in a cure of the sinus;³ and Samuel Cooper says there is a specimen in the Museum of University College, of a fracture of six ribs where the fragments are only connected by a fibrous or ligamentous tissue.⁴

The union generally occurs with only a slight degree of displacement. After the union is completed, even where there is no displacement, a certain amount of ensheathing callus may generally be felt at the point of fracture. In some specimens sharp spicula, in others broader sheets of bone extend along the course of the intercostal muscles from one rib to the other, forming a species of ankylosis between their adjacent margins.

Symptomatology.—Acute pain, referred especially to the point of fracture, sometimes producing great embarrassment in the respiration, and crepitus, are the most common indications of a fracture. The pain and embarrassed respiration are, however, far from being diagnostic, since they are often present in an equal degree when the walls of the chest have only been severely contused. The crepitus, also, is often difficult to detect, owing to the thickness of the muscular coverings, or to the amount of fat upon the body, or to the fracture having occurred perhaps directly underneath the mammæ in the female. The crepitus may be discovered sometimes by pressing gently upon the seat of fracture, or by applying the ear or stethoscope over this point while the patient attempts a full inspiration, or coughs; or we may press upon the front of the chest with one hand, while the fingers of the other hand rest upon the fracture.

Occasionally the patient has felt the bone break, and very often he feels or hears the crepitus after it is broken, and will himself indicate

FIG. 72.



Ensheathing callus
in fracture of rib.

¹ Paulet, Poincet, *op. cit.*, p. 200.

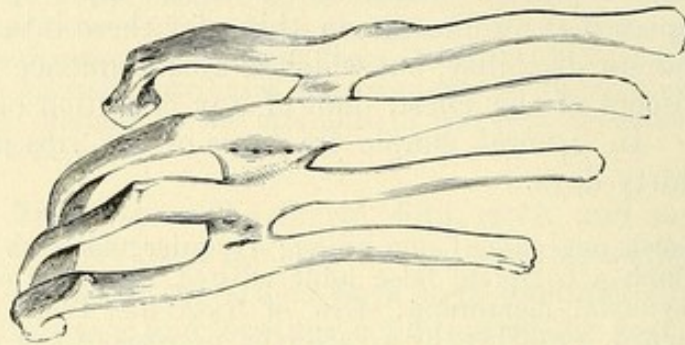
² Malgaigne, *op. cit.*, p. 435.

³ Eve, *N. Y. Journ. Med.*, vol. xv. p. 136.

⁴ S. Cooper's *Surg.*, vol. ii. p. 321.

very clearly the point of fracture. At the same time that we detect crepitus we are able also to discover motion in the fragments, but I have once or twice discovered preternatural mobility without crepitus. Emphysema, which is almost certainly indicative of a fracture, is present in a pretty large proportion of cases.

FIG. 73

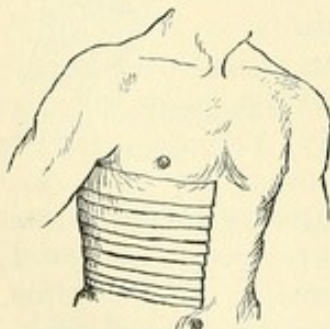


Fractured ribs joined to each other by osseous matter. (From Dr. Gross's cabinet.)

It has been observed by me in 13 out of 32 cases; generally it did not extend over more than two or three square feet of surface; but in two cases it finally extended over nearly the whole body. It is remarkable, however, that in only four of these thirteen cases did the patients expectorate blood, and then in a very small quantity, and usually not until the second or third day.

Treatment.—In simple fractures, where there is no displacement, or where the displacement is only moderate, the chest should be inclosed with a broad belt or band, provided always that it is not found to increase instead of diminishing the patient's sufferings. Some patients cannot tolerate this confinement at all; whilst, with a majority, although it is at first uncomfortable and oppressive, after an hour or two it affords great relief from the distressing pain, and they will not consent to have it removed even for a moment. In nearly all cases of comminuted fracture it is inadmissible, on account of its tendency to force the pieces inward.

FIG. 74.



Strips of adhesive plaster applied.

[A simple and efficient dressing is the application of a single broad strip of rubber adhesive plaster four or five inches broad of sufficient length to pass around the body and lap over three or four inches. Or the plaster may be applied in strips passing half around the body, and overlapping each other.]

The forearm ought also to be brought across the chest at a right angle with the arm, and secured in this position with a moderately tight bandage or sling, so as to prevent any motion in the pectoral muscles. As to position, the patient generally prefers to sit up, or he chooses a position only partly reclining upon his back; but there is no positive rule to be observed in this matter, except that such a position shall be chosen as shall prove most comfortable to the patient. If the fragments are salient outward, the fracture having been produced by a counter-

stroke, they may be reduced by pressing gently upon them from without. If, on the contrary, the fragments are salient inward, they will be found, in a great majority of cases, to have resumed their positions spontaneously or through the natural actions of respiration; but if they have not, it will be exceedingly difficult to restore them. Possibly it may be accomplished by pressing forcibly upon the front of the chest, or upon the anterior extremity of the broken rib; yet if the fragments are comminuted, and the ends are much driven in, this method will avail little or nothing.

In such cases several surgeons have recommended that we should cut down to the bone and elevate the fragments, but Rossi alone claims to have actually put the suggestion into practice. No doubt, if the necessity were urgent, this method might be successfully adopted; or, instead of cutting down to the broken rib, we might even seize the fragment with a hook, as suggested by Malgaigne, or what in some cases might be even more convenient, with a pair of forceps constructed with long teeth, obliquely set upon a firm shaft. Yet the exigency which will demand a resort to any of these measures will be exceedingly rare. In gunshot fractures, which are nearly all compound and comminuted, the loosened or detached fragments should be at once removed. In no case do I attach any value or importance to the advice given by Petit, that we shall place a compress upon the front of the chest, underneath the bandage, in order to reduce the fragments, or to retain them in place after reduction.

The emphysema generally demands no special attention, since it is usually too limited to occasion inconvenience; and when more extensive, it generally disappears spontaneously after a few days, or a few weeks at most.

The advice given by some surgeons, that we ought in these cases to cut down to the pleural cavity so as to allow the air to escape freely through the incision, seems thus far to have rested its reputation upon a more than doubtful theory rather than upon any testimony of experience. Abernethy alone, so far as I know, has actually made the experiment, and his patient died. Dupuytren, in two cases, made incisions with the lancet at various points of the body, more or less remote from the seat of fracture; a practice, however, in which he confesses he has no confidence whatever. These patients both died. Dr. Stedman, of Boston, has reported the case of a man who, in addition to a fracture of one of his ribs, had also a dislocation of the outer end of the clavicle. The emphysema commenced immediately, and reached its acme on the twenty-second day. At this time it had extended over his whole body; his eyes were closed, and he breathed with great difficulty; but on the forty-fifth day the emphysema had entirely disappeared, and he was dismissed cured. The treatment consisted chiefly in the free internal use of stimulants, and in the application of bandages; but the bandages soon became disarranged, and after a few days they were entirely laid aside.¹ In one of my own patients, where the emphysema was almost equally extensive, the patient recovered after a few weeks, under the use of a simple diet, and without any special medication whatever.

§ 2. Fractures of the Cartilages of the Ribs.

The cartilages of the ribs are often broken when there is no ossification, at the same time that the ribs themselves are broken. Sometimes they are broken alone. Not unfrequently, also, the separation takes place at the precise point of junction between the cartilage and the bone.

¹ Stedman, Boston Med. and Surg. Journ., vol. lii. p. 316.

Puel infers, from experiments upon the cadaver, that the fracture would take place at this point most often.¹ Pyper relates a case in which the sternum was broken in a man aged twenty-five years, and also the cartilages of the sixth, seventh, and eighth ribs of the right side, as was proved by the autopsy, yet the cartilages were not ossified. The vena cava ascendens was also ruptured by the force of the compression.²

Etiology.—The causes are the same as those which produce fractures of the ribs, yet it is generally understood that it will require greater force, and that consequently the injury done to the viscera of the thorax will be more complicated and intense.

[Several cases of this fracture have been reported as occurring from muscular action. A violent effort with the arms at the moment of a fall, or in attempting to throw a heavy body, may cause such a strain upon the attachments of the pectoral muscles as to cause a lesion of the cartilages.]

A man was crushed by the fall of a heavy weight upon his body, and died after about sixty hours. An autopsy revealed a fracture of the cartilages of the third and fourth ribs, with a laceration of the intercostal muscles to such an extent that a hernia of the lungs had occurred at this point.

[Legros Clark³ reports the case of a man who was struck in the upper part of the chest by the pointed shaft of a vehicle; a tumor the size of the fist appeared at each inspiration and disappeared on expiration, leaving a deep depression. Examination showed that the cartilage of the second rib had been displaced and driven in. Extensive emphysema followed, but he recovered in six weeks.]

Pathology.—The fracture is clean and vertical, or transverse; never irregular or oblique. The direction of the displacement varies as in fractures of the ribs, but the anterior or sternal fragment is generally found in front of the posterior or spinal. Union takes place in these fractures, according to the testimony of most pathologists, not through the medium of cartilage, but of bone. Sometimes the new bone is deposited only between the ends of the fragments in the form of a thin plate; at other times it is formed around the fragments as well as between them. The latter of these two processes has been most frequently

FIG. 75.

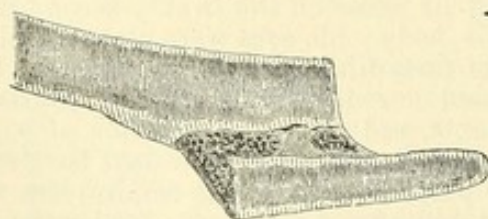
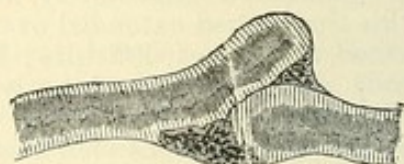


FIG. 76.



Repair of fracture of costal cartilage.

observed. The ensheathing callus appears to be supplied by the perichondrium, whilst the experiments of Dr. Redfern render it probable that the intermediate callus may result from a conversion or transformation of the adjacent cartilaginous surfaces. Paget remarks, also, that

¹ Puel, *Frac. des Cart. cost.* Anvers, 1876.

² Ranking's Abstract, vol. i. p. 147, from the *Lancet*, Oct. 1844.

³ *Diagnosis of Visceral Lesions*, 1869.

the ossification extends to the parts of the cartilage immediately adjacent to the fracture.

I have seen one example, which, after the expiration of more than one year, had not united. The fracture had occurred in the united cartilages of the ninth and tenth ribs. The posterior fragment overlapped the anterior, and they played freely upon each other at each act of inspiration and expiration.

Treatment.—The treatment does not differ from that already recommended for fractured ribs.

CHAPTER XIX.

FRACTURES OF THE CLAVICLE.

FRACTURES of the clavicle may be divided into those occurring through the inner, middle, and outer thirds. By the "outer third" is meant all that portion of the clavicle included between its scapular extremity and the internal margin of the conoid ligament. The remaining portion is intended to be divided equally into separate halves. The peculiarities of these several portions in respect to anatomical relations, liability to fracture, results, etc., will explain the propriety of the divisions.

Causes.—If we except gunshot fractures, the clavicle is broken, in a large majority of cases, by a counter-stroke, such as a fall or a blow upon the extremity of the shoulder. Occasionally it is broken by a direct stroke, as when a blow aimed at the head is received upon the shoulder; it is broken sometimes by the recoil of an overloaded gun, especially when the person lies upon the ground, with the butt of the gun resting upon the clavicle.

Gibson has seen a case in which it was broken in a child at birth, by an ignorant midwife pulling at the arm,¹ and Dr. Atkinson has reported an example of intra-uterine fracture of the clavicle.² Gurlt has collected seven cases of intra-uterine fracture of the clavicle caused by external violence.³ The clavicle may be broken by muscular action alone. A man standing upon the ground attempted to secure the braces of his carriage-top with his right arm, when he felt a sudden snap. Eight days after I found the right clavicle broken near its centre. The fragments were but slightly, if at all, displaced, but motion and crepitus at the point of fracture were distinct. A colonel of cavalry, about sixty years of age, mounting his horse, experienced a sensation as if something had broken, followed by acute pain in his left shoulder, and, on examination, it was found that the clavicle was fractured in the middle. The health of this gentleman had been impaired by repeated attacks of syphilis. W. E. Whitehead, U. S. N., has reported the case of a man, twenty-eight years old, who broke his left clavicle at the junction of the outer and middle thirds, while

¹ Gibson, *Principles of Surg.*, sixth ed., vol. i. p. 272.

² Atkinson, *Bost. Med. and Surg. Journ.*, July 26, 1860.

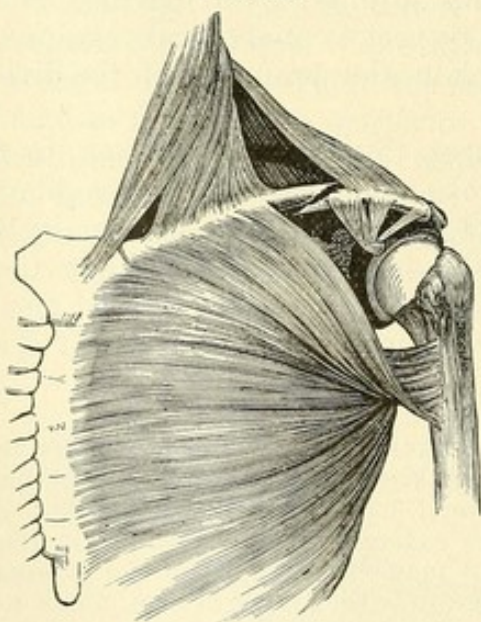
³ Gurlt, *Holmes's Surgery*, ed. of 1870, vol. ii. p. 765.

attempting to raise himself to a platform eight feet high. The fracture was transverse, and unaccompanied with displacement. Malgaigne¹ has recorded three other examples of fracture of this bone from muscular action; and Parker saw a case which was produced by striking at a dog with a whip. The bone, in the latter case, had been previously somewhat diseased, yet it united favorably.² Of these seven cases, five occurred on the right side, and always near the middle of the bone, if we except one case reported by Malgaigne, in which the point of fracture is not mentioned. In neither case did the fragments become displaced, only as they were found, in some of the examples, inclined slightly forward. Gurlt has collected twenty cases of fracture from this cause.³ Dr. Pooley reports an example of fracture of the clavicle in a child, supposed to have been due to muscular action, and which was the result of a fall upon the back.⁴

[McKee,⁵ of Tuscarora, Nev., had a case which occurred in a man while lifting a heavy weight; it was on the right side and near the middle of the clavicle; union had not taken place four months after, and there was evidence of a pseudoarthrosis. Syphilis was denied.]

Pathology.—It has already been observed, in speaking of partial fractures, that this bone suffers an incomplete fracture more often than any other, and that in such cases the lesion occurs generally in the middle third, or rather to the sternal side of the centre, and in a direction nearly or quite transverse. They are not usually accompanied with much displacement; but if a displacement exists, it is a slight forward inclination of the fragments. Fractures which are complete occur mostly after the bones have become firm and unyielding. They are also generally oblique,

FIG. 77.



Complete oblique fracture of clavicle.

seldom comminuted, still more rarely compound. The point of the clavicle at which a complete fracture usually occurs is at or near the outer end of the middle third, and a little to the sternal side of the coraco-clavicular ligaments, near where the trapezius and deltoid cease their attachments. It might be more exact to say that the fracture extends from this point downward and inward, toward the sternum, embracing one inch or less of its entire length. In some cases the obliquity is greater, and the amount of bone involved is much more considerable.

Why the bone should break more frequently at this point, especially in the adult and in the male, it is not difficult to understand. It is smaller here than elsewhere, and less supported by muscular and

¹ Whitehead, *Pacific Med. and Surg. Journ.*, 1871.

² Parker, *N. Y. Journ. Med.*, July, 1852.

³ Gurlt, *Holmes's Surgery*, ed. of 1870, vol. ii. p. 765. See also paper by M. Deleus on Fractures of the Clavicle from Muscular Action, in *Archives Générales*, March, 1875.

⁴ J. H. Pooley, *Prof. Surg. Starling Med. Coll., Columbus, Ohio. A Clinical Lecture*, 1877.

⁵ *Occidental Med. Times*, 1890.

by a counter-stroke, the force of the blow, conveyed from the shoulder through the outer portion of the bone, is suddenly arrested, and expends itself upon the point where the direction of the axis is changed. In a record of 157 fractures, including partial and comminuted, and not including gunshot fractures, 127 have occurred through the middle third; and, with the exception of the partial fractures, the fracture has in nearly all of the cases taken place near the outer end of this third. Four have occurred through the inner third, three of which were within one inch of the sternum; and seventeen through the outer third. A more practical analysis can be based, however, upon the point of fracture with reference to its cause; and I have never, but once, seen a complete fracture of this bone, in the adult, produced clearly by a counter-stroke, which was not near the outer end of the middle third.

When the fracture is in any portion of the middle third, the direction of the displacement is almost uniformly the same. The sternal fragment is slightly lifted by the action of the clavicular portion of the sternocleido-mastoid muscle, notwithstanding the resistance of the rhomboid ligament, the pectoralis major, and the subclavius muscles. On the other hand, the acromial fragment is dragged downward by the weight of the arm, aided by the conjoined action of a portion of the pectoralis major and the latissimus dorsi, feebly resisted by the trapezius and other muscles from above; by the action of the same muscles, aided by the pectoralis minor, and perhaps by some portion of the subclavius, it is drawn toward the body, diminishing thereby the axillary space; while by the preponderating strength of the pectoralis major and minor, the acromial end of the fragment, with the shoulder, is drawn forward; the sternal end of the same fragment being rather displaced backward, and at the same time resting at a point somewhat elevated above the acromial end.

Desault has recorded one example of an overlapping by the elevation of the acromial fragment over the sternal.¹ Syme has mentioned a case of this kind which he had seen.² Guéretin, Malgaigne,³ and Stephen Smith have each reported an example.⁴ In Stephen Smith's case the bone was broken through the outer third, and transversely; the overlapping, to the extent of one inch, remained after the cure was completed. M. O'D., æt. forty years, was admitted to the Charity Hospital with a single fracture of the clavicle, near its middle, caused two weeks before, by a fall on the shoulder. The sternal fragment was lying beneath the acromial, and in this position it finally united.

In nearly all cases of oblique fractures occurring through the middle third there follows immediately an overlapping, varying from one-quarter of an inch to an inch, and sometimes, though very rarely, exceeding this; the average shortening being about half an inch.

There is a specimen in the Dupuytren Museum, in which the shortening equals one-third of its entire length.

Transverse fractures, wherever they may occur, whether in children or adults, are seldom found displaced, at least in the direction of the axis of the bone, and they unite usually without shortening or deformity.

¹ Desault on Frac., op. cit., p. 16.

³ Malgaigne, op. cit., p. 461.

² Amer. Journ. Med. Sci., vol. xvii. p. 251.

⁴ New York Journ. of Med., May, 1857.

A lady, aged eighty years, fell down a flight of stairs, breaking the right clavicle transversely, about one inch from the sternum. Motion and crepitus were distinct, but there was scarcely any displacement. No dressings were applied, but she was directed to keep quiet in bed, and upon her back. In the usual time the fragments had united, without deformity. A man fell backward from a wagon, breaking the collar-bone near the middle. The fragments were movable, but not displaced. He was treated successfully, and without any resulting deformity, by simple confinement in the recumbent posture during a few days, and after this by suspending the arm in a sling, while he was permitted to walk about. A young man, aged twenty-six years, fell while wrestling, and broke the clavicle at the outer end of the middle third. There was some displacement at first, but the fragments, being reduced, were found to support themselves. A cross, secured with straps, was applied to the back, and on the twenty-eighth day the union was complete, and without deformity. A child, aged three years, fell about six feet, striking upon his shoulder. I found the left clavicle broken off completely, about one inch from its scapular end. Crepitus and motion were distinct, but the fragments were not displaced. The arm was placed in a sling, and on the seventh day both motion and crepitus had ceased. The cure was accomplished without any degree of displacement. Stephen Smith, of New York, has met with two examples of transverse fractures without displacement, in a hospital record of eleven cases. Bichat says, Desault has frequently observed the same, it having been seen three times at Hôtel Dieu, in the course of the year 1787. Desault thinks, also, that sometimes the fracture, taking place obliquely upward and inward, the usual form of displacement is prevented, and apposition is preserved. In nearly all of the examples of partial transverse fractures, occurring in children, seen by me, there has been no longitudinal displacement.

If the fracture is near the sternum, and within the fibres of the costo-clavicular ligaments, as in the case of the old lady just cited, the displacement is inconsiderable.

I have seen one other similar case, in an adult also. Lonsdale mentions a case, in a child three years old, which he regarded as a separation of the epiphysis, the point of fracture being half an inch from the sternum. Malgaigne mentions two other examples, in one of which the fracture was so near the sternum that it was difficult to say whether it was not a partial dislocation. The displacement was only trivial. But the only two specimens contained in the Dupuytren Museum offer a considerable displacement, and in both the external fragment is thrown downward and forward.

A similar specimen was from a patient in Bellevue Hospital. The fracture was occasioned by a fall upon the shoulder, and extended from the sterno-clavicular articulation upward and outward one inch and a half. The fragments were overlapped three-quarters of an inch, and were firmly united. A case is reported from Mt. Sinai Hospital, in this city, of a fracture of the clavicle in an adult, at a point about one inch from the sternum. The inner fragment was drawn, by the action of the sterno-cleido-mastoid muscle, into a vertical position, and the outer was drawn down upon the chest. It became apparent that replacement could not be effected without division of the muscle; and, inasmuch as the displacement caused no inconvenience, it was permitted to remain as it was found.¹

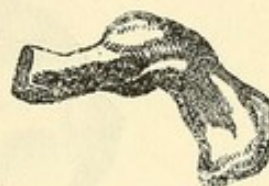With regard to the amount of displacement usually attendant upon fractures near the outer end of the bone, surgical writers have generally united in declaring that it was in a majority of cases very inconsiderable, while some have even affirmed that there would be found no displacement whatever.

Neither of these opinions, according to the observations of Robert Smith, of Dublin, is strictly correct. He has examined eight specimens of fracture of the

¹ New York Med. Journ., Jan. 1877, p. 48.

outer extremity of the clavicle, contained in the museum of the Richmond Hospital School of Medicine; three of which were broken between the conoid and trapezoid ligaments, and are united with very little displacement, whilst the remaining five, broken beyond the trapezoid ligament, present a very marked deformity. The following is a summary of the conclusions to which he has arrived: "When the clavicle is broken between the two fasciculi of the coraco-clavicular ligament, there is seldom any displacement of either fragment, and always much less than in fracture of any other portion of the bone. When displacement does occur, it is usually limited to a slight alteration in the direction of the bone, by which the natural convexity of this portion of the clavicle is increased. The explanation of which facts is found in the attachments of the ligaments from below to the two fragments, and in the action of the trapezius from above, by which they are antagonized. But the case is very different when the bone is broken external to the trapezoid ligament. Here the coraco-clavicular ligaments can have no direct influence upon the outer fragment, which is displaced now partly by muscular action, and partly by the weight of the arm, the sternal end of the outer fragment being drawn upward by the clavicular portion of the trapezius, while, by the action of the muscles passing from the chest, the entire outer fragment is drawn forward and inward, so as to bring sometimes its broken surface into contact with the anterior surface of the inner fragment, and placing it nearly at right angles with this fragment, in which position it is generally united. The displacement in this direction, rather than any degree of overlapping, explains also the shortening which existed in all of these cases, varying in the different specimens from half an inch to one inch, and averaging about three-quarters of an inch." In my own experience, a fracture occurring in a child three years old, within one inch of the acromial end, probably between the ligaments, was never displaced at all; a second, and third, occurring in adults, presented no displacement. Two cases were displaced each one-quarter of an inch, and two cases half an inch; these four latter cases occurred in adults, and always within an inch of the acromial end of the bone. In one of these last examples, the inner fragment was rather behind than above the outer fragment.

FIG. 78.



Fracture outside of trapezoid ligament. United.

It has happened to me only six times to meet with a comminuted fracture of the clavicle, except in cases of gunshot injuries, all of which fractures occurred through some portion of the middle third of the bone; the intercepted fragments being from one inch to one inch and a half in length, and lying obliquely, or, as in one case observed by me, at nearly a right angle with the main fragments. A compound fracture of this bone I have not seen, except as the result of a gunshot injury, although, in many cases, the sharp point of an oblique fracture has seemed just ready to penetrate the skin.

One case is reported as having been presented at St. Bartholomew's Hospital. It occurred in a boy fourteen years old, and was produced by his having been drawn into some machinery while it was in motion.¹ Two similar cases are reported from the New York Hospital, as having been observed during the last ten years preceding the date of the report. The whole number of fractures of the clavicle during this period was 191.² Lente also mentions a case, seen by himself, occasioned by the fall of a derrick upon the shoulder.

A double fracture, or a simultaneous fracture occurring in both clavicles, seldom occurs.

¹ London Med. Gaz., vol. ii. p. 382.


² New York Med. Times, March 16, 1861.

I have recorded two cases (*four fractures*, three of which are incomplete), both occurring in young boys.¹ Dr. Burr, of Binghamton, N. Y., has reported a case which occurred in a man about fifty years old.² To these M. Polaillon has added eight others gathered from various sources. Malgaigne says it has only happened once in 2358 cases at the Hôtel Dieu, and he can recollect only five other examples. And of 158 cases of broken clavicles reported from the New York Hospital, it is stated to have occurred in only four.

[White,³ of Philadelphia, reports a case of simultaneous fractures of both clavicles as the result of a fall from a railroad car. The patient was treated in the recumbent position with sand-bags applied to his head to prevent movement. Good union was obtained, with no more than the average amount of deformity.]

Symptoms.—In all cases of complete fracture with displacement, no difficulty will be experienced in deciding upon the nature of the injury.

FIG. 79.



Complete fracture—Oblique; at junction of outer and middle thirds. (From nature.)

The patient is found generally leaning toward the injured side, whilst the opposite hand sustains the elbow of the same side, to prevent its dragging downward. The shoulder falls downward, forward, and inward; whilst, at the same time, the line of the bone is interrupted by the sharp and projecting point of the sternal fragment. If the fracture is the result of a direct blow, a swelling and discoloration may be seen at the seat of fracture; but if it is the result of a counter-stroke, we must look to the top or point of the shoulder for the signs of a contusion. The patient also experiences pain when an attempt is made to raise the arm at a right angle with the body, and especially in attempting to carry the arm across the body, by which the ends of the broken clavicle are driven into the flesh.

In two cases of oblique fracture, accompanied with displacement, occurring in the middle third of the bone, I have particularly noticed that the patients could easily lift the hands to the head, and in one of these cases the patient, a boy, fourteen years old, raised his arm perpendicularly over his head. Such exceptions are not very uncommon.

Crepitus can be detected sometimes by simply pressing down the sternal fragments, but it is almost always present when we draw the shoulders forcibly back, so as to bring the broken fragments into more perfect contact. If there is no displacement, still crepitus may generally be discovered by grasping the bone between the thumb and fingers, and moving it gently up and down, or by slight pressure upon the point of fracture. When the fracture occurs close to the acromial extremity,

¹ Report on Def. after Frac., Cases 5, 6, 10.

³ Univ. Med. Mag., Jan. 1890.

² Burr, Med. Rec., May 6, 1882.

external to the coraco-clavicular ligaments, quite frequently there is no perceptible or marked displacement, and its diagnosis will require, therefore, more care and attention on the part of the surgeon.

Prognosis in this fracture deserves especial attention. In no other bone, except the femur, does a shortening so uniformly result.

Of seventy-two complete fractures only sixteen united without shortening; and of twenty-seven simple, oblique, complete fractures, which occurred at or near the outer end of the middle third, only one united without shortening, and in this case the patient was but fifteen years old, and the fragments were never much displaced. Six cases of complete transverse fracture, occurring at the same point, united without shortening.

The shortening, after the union is consummated, varies from one-quarter of an inch to one inch or more; and the fragments are almost always, especially when the fracture is through the middle third, found lying in the position in which we have described them to be at the first; the outer end of the inner fragment being above, and often a little in front of, the outer; sometimes, especially in lean persons, and when the fractures are very oblique, presenting a sharp and unseemly projection. The greatest amount of shortening is generally found in those fractures which occur through the middle third, or between the rhomboid and coraco-clavicular ligaments. In fractures near the sternal end, within the region occupied by the rhomboid ligament, there is usually very little permanent displacement. The same is true when the fracture is at the acromial end, and between the fasciculi of the coraco-clavicular ligaments; but if the fracture is beyond these ligaments, near the acromial end, the final displacement and deformity may be very great. The presence of a small amount of ensheathing callus soon after the cure is completed, sometimes increases the deformity. It is rarely seen to encircle the bone completely, and occasionally it appears to be most abundant in the direction of the salient points of the fracture, that is, above and below; so that, unless the examination is made with care, the projecting points of callus which remain, sometimes after many years, may be easily mistaken for an intercepted fragment turned at right angles to the axis of the bone.

Robert Smith has observed, also, that in cases of fracture external to the conoid ligament, osseous matter is freely formed upon the under surface of each fragment, but there is seldom any deposited upon the upper surface of either. These osseous growths, occupying the situation of the coraco-clavicular ligaments, frequently prolong themselves as far as the coracoid process, and in some

FIG. 80



Comminuted fracture.—United.
(From nature.)

cases to the notch of the scapula. Still less frequently these osteophytes become fused with the coracoid process, and a true ankylosis exists.

In comminuted fractures the intercepted fragments generally fall off from the line of the other fragments, and cannot easily be restored. The clavicle, being a spongy and vascular bone, usually unites with great rapidity, generally within twenty days.

In the fourth example of transverse fracture already mentioned as having been seen by me, the union seemed to be tolerably firm in seven days. Wallace reports one case from the Pennsylvania Hospital, which was cured in eight days, and another in nine days.¹ Velpeau says the clavicle will unite in from fifteen to twenty-five days; Benjamin Bell in fourteen; Stephen Smith has seen it firm in fifteen days.

Whatever may be the degree of displacement, or the condition of the system, unless in a case of gunshot fracture, it is very seldom that it refuses to unite altogether, or that the union is ligamentous. In Muhlenberg's tables of 656 cases of delayed and non-union of long bones, there is but one example of non-union of the clavicle. And in the few cases found upon record of a ligamentous union, the functions of the arm do not seem to have suffered any serious ultimate injury, as the following example will illustrate:

An Irish laborer fell from a horse and broke his left clavicle, at the outer end of the middle third; he continued at work, nor from that day forward did he cease from his work. The clavicle presented the same deformity which many other similar fractures present after what is usually termed successful treatment, except that it was not united by bone. The outer end of the inner fragment rode upon the inner end of the outer fragment half an inch. The ligament uniting the two extremities was so long and firm that it could be distinctly felt, and the fragments moved upon each other with great freedom. We ascertained by experiment that with his left arm he could lift as much, within three ounces, as he could with his right, and he was not himself conscious of any difference. The muscles of the left arm seemed as well developed as those of the right. I examined in the Charity Hospital, New York, a fracture of the left clavicle, which had united only by ligament; it had occurred at about the junction of the outer fourth with the inner three-fourths. No treatment had ever been adopted. The ligament was quite long, and the fragments moved freely upon each other, yet the arm was nearly as strong and as useful as before. Chelius also refers to two cases mentioned by Gurdy and Velpeau, in which, although an artificial joint remained, the use of the limb was but little impaired.² In a case of compound and comminuted gunshot fracture reported by Ayres, of Brooklyn, the recovery was remarkable. The clavicle was so extensively comminuted that before the wound closed over one-third of the bone had escaped, and yet at the end of one year from the time of the accident the shoulder was perfectly symmetrical with its fellow, without drooping or falling forward. Dr. Ayres thinks that all of the clavicle which was lost had been reproduced.

A partial paralysis, with atrophy of the muscles of the arm, accompanied, also, with more or less rigidity and contraction of the muscles both of the arm and forearm, is, according to my observation, a more frequent result of these fractures.

Mr. Earle has recorded a case of comminuted fracture of the clavicle, in which the nerves converging to form the axillary plexus were so much injured that

¹ Amer. Journ. Med. Sci., vol. xvi. p. 115.

² Chelius, Amer. ed., vol. i. p. 603.

paralysis of the arm ensued; and it was noticed as an interesting fact, that the patient could not afterward put her hand into even moderately warm water without the effects of a scald being produced, characterized by vesication, redness, etc.¹ Desault saw a case at Hôtel Dieu, in which, although the clavicle was not broken, the force of the blow upon the clavicle was sufficient to produce a severe concussion of the brachial plexus and paralysis of the arm. A timber had fallen from a building, striking upon the external part of the left clavicle. A considerable wound, followed by swelling, pointed out the place on which the blow had been received. No apparatus was applied, and on the third day a numbness and partial loss of the power of motion occurred in the arm of the affected side. Soon afterward an insensibility came on, and by the seventh day the paralysis of the arm was complete. It was not until after a tedious treatment that the limb recovered in part its original strength. In Case 23 of my report to the American Medical Association, which was followed by paralysis of the opposite arm, and spinal curvature, one cannot avoid a suspicion that the apparatus, Brasdor's jacket, contributed somewhat to the unfortunate result. No axillary pad was employed, but the straps over each shoulder were buckled so tight that he was compelled to incline his head constantly to the right side. He was unable to lie down, and could only incline in a half-sitting posture. This treatment was continued four weeks; and two months after its removal the paralysis and spinal distortion commenced.

Gibson relates a remarkable instance of this kind. A young man was struck on the clavicle by the falling limb of a tree, breaking it into numerous pieces, and bruising the parts so severely as to give rise to violent inflammation. "The fragments had been driven behind and beneath the level of the first rib, and so compressed the plexus of nerves as to wedge them into each other, and by the subsequent inflammation to blend them inseparably together. Complete paralysis and atrophy of the whole arm ensued."²

While there is the possibility of a paralysis resulting from concussion of the axillary nerves, produced by a blow upon the clavicle, and of a paralysis resulting from a direct injury inflicted by the points of the fragments upon this plexus in certain very badly comminuted fractures, these conditions will not satisfactorily explain all of the examples in which paralysis has followed simple fractures. In some cases it is no doubt due rather to the injudicious mode of using an axillary pad, by means of which the arm is converted into a powerful lever, and thus the brachial nerves are made to suffer from compression along the inner side of the arm itself. The paralysis is, therefore, sometimes due to the treatment alone, and not to the original injury.

[Chavier,³ in an article on nervous affections following fractures of the clavicle by indirect cause, regards many of these cases due to a neuritis which extends to the nervous centre.]

[M. Blum⁴ reports a case of fracture of the clavicle followed by atrophy of the arm, and a painful condition of the nerves, which he attributed to pressure of an exuberant callus. This was excised partially with slow recovery of the limb.]

Parker, of New York, declares that he has seen one patient who had lost the use of his arm from the pressure upon the nerves by the wedge-shaped pad over which the limb was confined in order to pry the shoulder outward. Stephen Smith mentions a case of partial paralysis from the same cause.⁵ A similar case has come under my own observation. A lady was thrown from her carriage, breaking the right clavicle obliquely at the outer end of the middle third. During the first three weeks the arm was dressed with Fox's apparatus, which

¹ S. Cooper's First Lines, fourth Amer. ed., vol. ii. p. 323.

² Gibson, op. cit., 6th ed., vol. i. p. 271.

³ Gaz. Méd. de Paris, 1889.

⁴ Rev. Clin. Chirurg., 1888.

⁵ Stephen Smith, New York Journ. of Medicine, May, 1857.

was at no time particularly painful. She was then placed under the care of another surgeon, who, finding the fragments overlapped, applied very firmly a figure-of-8 bandage, with an axillary pad, securing the arm snugly to the side of the body; hoping by these means to restore the fragments to their place. The pain which followed was excessive, and, notwithstanding the free use of anodynes, it became so insupportable that at the end of fourteen hours the dressings were removed by another surgeon, and Fox's apparatus again substituted. These were also applied much more tightly than at first, and during the four weeks longer that they remained on, repeated attempts were made to reduce the fragments. Forty-eight days after the accident, she consulted me. The clavicle was then united, and overlapped half an inch. The whole arm was swollen, painful, and very tender, with total inability to move it. I removed all the dressings, and, during the time she remained under my care, in a private room at the hospital, there was a gradual improvement in the condition of her arm, in respect to swelling and tenderness, but the paralysis did not much abate.

Erichsen thinks he has seen one case of comminuted fracture, produced by a direct blow, in which the subclavian vein was ruptured; great extravasation of blood resulted, and the arm was threatened with gangrene. The patient having recovered, however, the diagnosis could not be determined by actual dissection.¹

M. Maunoury, of Chartres, met with a similar case, in which, while attempting to tie the vein, the patient died in consequence of the admission of air.² J. W. Ogle has reported a case of wound of the internal jugular caused by a fragment of a broken clavicle.³

Dupuytren stated that he had seen two examples of aneurism consequent upon fracture of the clavicle. Follin says that Sir Robert Peel having been thrown from his horse, had his left clavicle broken, and death ensued, in consequence, it was believed, of a traumatic aneurism resulting from a wound of an arterial vessel.⁴

"M. Moré reported to the Surgical Society, in 1876, a case of fracture of the clavicle, in which M. Verneuil and the majority of the members admitted the existence of a partial rupture of the subclavian artery. An old man had his clavicle broken in consequence of direct violence. The apparatus (bandage and axillary pad) was only applied on the third day; on the same evening pains and formications occurred in the hand, which, the next day, presented a bluish appearance in color; in addition, no pulsations in the radial or ulnar artery could be felt. In view of these accidents, the apparatus, already loose, was removed. It took two months for the limb to regain its normal strength and appearance; but the pulsations in the vessels did not return until after the lapse of eight months. Indeed, this case is not absolutely conclusive, and, notwithstanding the great authority of the surgeons who admitted the rupture of an artery, it is fair to ask if the pressure produced by the axillary pad was not the real cause of all these accidents."⁵ To these judicious comments of M. Poincot in reference to the case of M. Moré, I wish to add my opinion, that there is good reason for believing, if a vessel were torn, it was done by the surgeon in his attempts to restore the fracture to place; and that if it was not torn, the violent and injudicious efforts of the surgeon to maintain it in place by an axillary pad, bandages, etc., might explain the obliteration of the arterial circulation. The lesson is not, in my opinion, to be overlooked by those who so assiduously attempt, by similar means, to accomplish what, in most cases, is impossible.

¹ Erichsen, *Surgery*, Amer. ed., p. 205.

² Maunoury, *Prog. Méd.*, Avril, 1882.

³ Ogle, *Brit. Med. Journ.*, July 26, 1872.

⁴ Follin, *Path. Ext.*, t. 2, p. 849.

⁵ Moré, *Rev. des Sci. Méd.*, t. 10, p. 235. Poincot.

Fracture of the clavicle may also be complicated with a wound of the lung and with extensive emphysema.

M. Polaillon has published three cases of this kind taken from Vigaroux, Velpeau et Huguier. Very recently, M. Gibier de Savigny reported a case of fracture of the clavicle in which the external fragment had perforated the lung. Considerable emphysema supervened, and the patient recovered almost without treatment; but a pseudarthrosis remained.¹

Since among surgeons some difference of opinion seems to exist as to the practicability of overcoming the displacement in certain fractures of the clavicle, it is proper that I should defend the accuracy of my own observations by a reference to the observations of others.

In nine of eleven cases reported by Stephen Smith, one of the surgeons at Bellevue Hospital, New York, more or less deformity remained after the cure was completed.² Chelius remarks: "Setting of this fracture is easy, yet only in very rare cases is the cure possible without any deformity." . . . "It is considered, also, that the close union of the fracture of the collar-bone depends less on the apparatus than on the position and direction of the fracture (therefore, in spite of the most careful application of this apparatus, some deformity often remains)."³ Velpeau, in a lecture given in 1846, and published in the *Gazette des Hôpitaux*, declares that with all the bandages imaginable, in the case of an oblique fracture at the junction of the outer third with the inner two-thirds, we cannot prevent deformity. Vidal observes: "Fracture of the clavicle is almost always followed by deformity, whatever may be the perfection of the apparatus and the care of the surgeon."⁴

M. Mayor, of Lausanne, thinks that up to this day no successful mode of treatment has been devised. "Here everything appears as yet so little determined, that each day sees some new proposition and different procedures," etc. Says M. Malgaigne: "The prognosis, considering the trivial character of this fracture, is sufficiently difficult. For, little as may be the displacement, the surgeon ought not to promise a reunion without deformity; and certain successful results, proclaimed from time to time, betray, on the part of those who relate them, the most extravagant exaggerations."⁵ M. Néleton having spoken of the various plans which have been suggested to retain this bone in place, and of their inefficiency, comes at last to speak of the handkerchief bandage of M. Mayor, and remarks: "This apparel is very simple; but neither will it remedy the overlapping." . . . "Of all the apparels which we have passed in review, there is, then, not one which fills completely the three indications usually present in the fracture of a clavicle. None of them oppose the displacement; they have no effect, with whatever care they may be applied, but to maintain immobility in the limb. We think, then, that it is useless to fatigue the patient with an apparatus annoying, and, perhaps, even painful; a simple sling, secured upon the sound shoulder, will be sufficiently severe. . . . If there is a tendency to displacement, the consolidation will be effected with a deformity more or less marked; but since this deformity is inevitable, at least with adults, whatever may be the apparel which we employ, it is evident that the apparatus which causes the least constraint ought to have the preference. We may remark, farther, that this union with deformity in nowise impairs the free exercise of all the movements of the members."⁶ Dr. Gross says that, according to his experi-

¹ Polaillon, Dic. Encyc. des Sci. Méd., t. 17, p. 695. French ed. of this treatise, p. 220, note by Poincot.

² New York Journ. Med., May, 1857, p. 382.

³ System of Surgery. By J. M. Chelius, of Heidelberg, with notes by South. First Amer. ed., vol. i. pp. 603, 605.

⁴ Vidal (de Cassis), Paris ed., vol. ii. p. 105.

⁵ Traité des Fractures et des Luxations, par J. F. Malgaigne, tome premier, p. 473. Paris ed., 1847.

⁶ Eléments de Pathologie Chirurgicale, par A. Néleton, tome premier, p. 720. Paris ed., 1884.

ence, "fractures of the clavicle are seldom cured without more or less deformity, whatever pains may be taken to prevent it."¹ Roser says: "The treatment of fractures of the clavicle is, after all that has been said, very imperfect; and it is very often the case that, after a most careful treatment, some deformity will remain, such as protrusion of the inner fragment, crossing of the fragments, and consequent shortening."² Bryant says: "Deformity almost always exists in spite of treatment."³

Treatment.—If evidence were needed beyond that which has been furnished, of the difficulty of bringing to a successful issue the treatment of this fracture, it might be supplied, satisfactorily, by a reference merely to the immense number of contrivances which have been at one time and another recommended. The indications for a complete restoration of the outer fragment, which alone is supposed to be much displaced, are to carry the shoulder upward, outward and backward. But as to the means by which these indications can be most easily, if at all, accomplished, the widest differences of opinion have prevailed. On the one hand, no invention has wanted for advocates; on the other hand, no method has escaped its equivalent of censure.

The first method seems to have been posture. The earliest physicians recommended the recumbent posture.

Hippocrates and Celsus, followed by Dupuytren, Flaubert, Lizars, Pelletan, and others, directed patients to lie upon their backs, with little or no apparatus. S. Cooper and Dorsey recommend that patients should be confined in this position during most of the treatment. Dr. Lente intimates that a similar plan was at one time adopted in the New York City Hospital. He states: "But this result" (angular deformity) "rarely happens when the patient has strictly followed the directions of the surgeon, as to position especially, for it is by position, more than by any other remedial means, that a good result is to be effected." Dr. Post mentions a case treated in this manner, which terminated with very little deformity;⁴ and I have myself treated many cases by this plan, with more than average success. Dr. Edward Hartshorne, of Philadelphia, has published a very ingenious argument in favor of the supine position, in which he seems to have demonstrated that the special efficacy of this plan depends upon the pressure made against the angle of the scapula. In order to accomplish this, and to place the scapula in the position most favorable for the reduction of the clavicle, the back should rest upon a broad, firm, and unyielding mattress, and not upon a pillow between the shoulders, which latter has the effect rather to defeat than to promote the indication; the head should be slightly raised so as to relax the sterno-cleido-mastoid muscles and somewhat extend the trapezius; the arm and forearm of the injured side should be flexed, resting across the chest, with the hand reaching over the sound shoulder, or it should be placed at right angles with the body. The absolute immobility required by the posture treatment must always limit its application, and render its general employment impossible. Dr. J. A. Packard, of Philadelphia, regards the scapula, also, as the bone upon which the restoration of the clavicle chiefly depends; and he finds in the serratus magnus the especial obstacle to this restoration.⁵

In order to carry the shoulders back, a figure-of-8 has been preferred by some and condemned by others. To this apparatus many surgeons add some form of back-splint, extending from acromion to acromion, against which the shoulders may be properly secured.

¹ Gross, *System of Surgery*, vol. i. p. 954, 1872.

² W. Roser, *Handbuch der Anatomischen Chirurgie*, 6 Aufl. Tübingen, 1872.

³ Bryant, *Practice of Surgery*, London, 1872, p. 927.

⁴ N. Y. *Journ. of Med.*, vol. ii. p. 226.

⁵ Packard, *New York Journ. of Med.*, 1867.

Parker says that splints of this kind, with a figure-of-8 bandage, are "better than all the apparatus ever invented," whilst Mr. South gives his testimony in relation to all dressings of this sort as follows: "I do not like any of the apparatus in which the shoulders are drawn back by bandages, as these invariably annoy the patient, often cause excoriation, and are never kept long in place, the person continually wriggling them off to relieve himself of the pressure."

Again, others bring the elbow a little forward, and then lift the shoulder upward and backward; or carry the elbow still farther forward, so as to lay the hand across the opposite shoulder. Guillou carries the hand and forearm behind the patient, and then proceeds to lift the shoulder to its place. Moore, also, recommends that the elbow shall be carried back.

Thus Desault, Fox, and Wattman accomplish the indication to carry the shoulder back, by lifting the humerus, with the elbow in *front* of the body; whilst Guillou and Moore accomplish the same indication by lifting the humerus when the elbow is a little *behind* the body. Chelius also says: "The elbow, as far as possible, is to be laid backward on the body." Sargent, who believes that with Fox's apparatus "the occurrence of deformity is the exception," and not the rule, and prefers it to all others, has treated three cases by Guillou's method, and is perfectly satisfied with its operation. Hollingsworth, of Philadelphia, has also treated one case successfully by Guillou's method, and adds his testimony in its favor. Several surgeons think they have obtained equal success with Moore's apparatus.

But how shall we explain these equal results from opposite modes of treatment? Is the indication to carry the shoulders back, which Fox sought to accomplish by pressing the elbow upward and backward, as easily attained by pressing the elbow upward and forward? Or are we not compelled to infer that there has been some mistake as to the precise amount of good accomplished by the apparatus in either case? Moreover, Coates,¹ Keal, and others instruct us that the only safe and proper position for the humerus is in a line with the side of the body, and that it must neither be carried forward nor backward.

Many surgeons, as Paulus Ægineta, Boyer, Desault, Pecceti, Liston, Fergusson, Samuel Cooper, Erichsen, Miller, Skey, Levis, recommend an axillary pad; whilst others of equal reputation deny its utility or affirm its danger.

Dr. Parker has seen one patient in whom paralysis of the arm resulted from the pressure upon the brachial nerves, in the attempt "to *pry* the shoulder out."

Prof. E. M. Moore,² of Rochester, has called attention to what he terms the "figure-of-8 from the elbow," which renders tense the clavicular

FIG. 81.

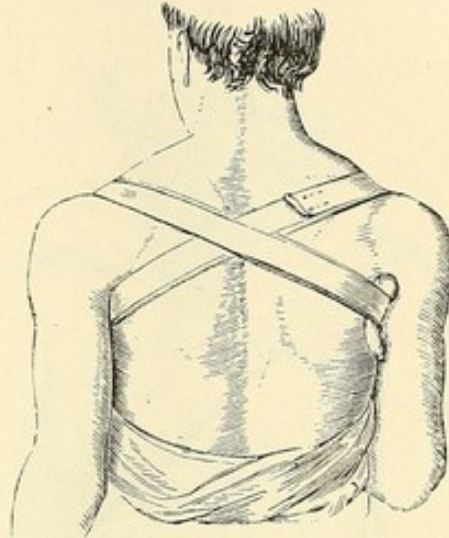


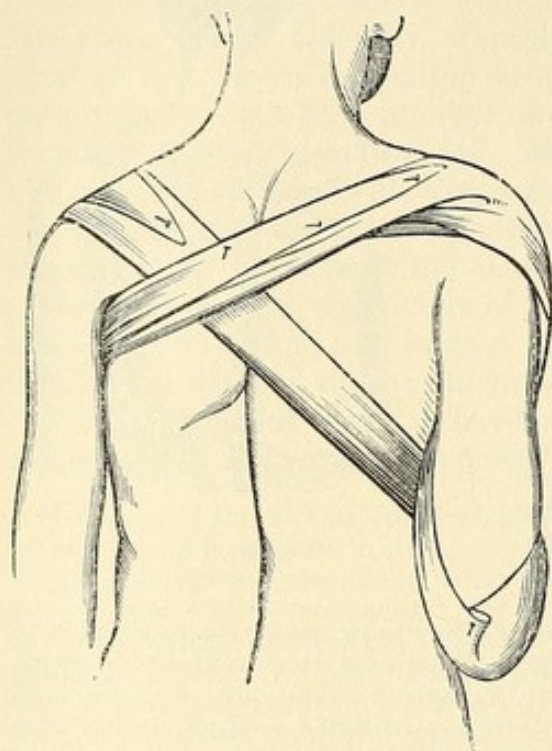
Figure-of-8.

¹ Coates, Amer. Journ. Med. Sci., vol. xviii. p. 62.

² Transactions N. Y. State Med. Soc., 1871.

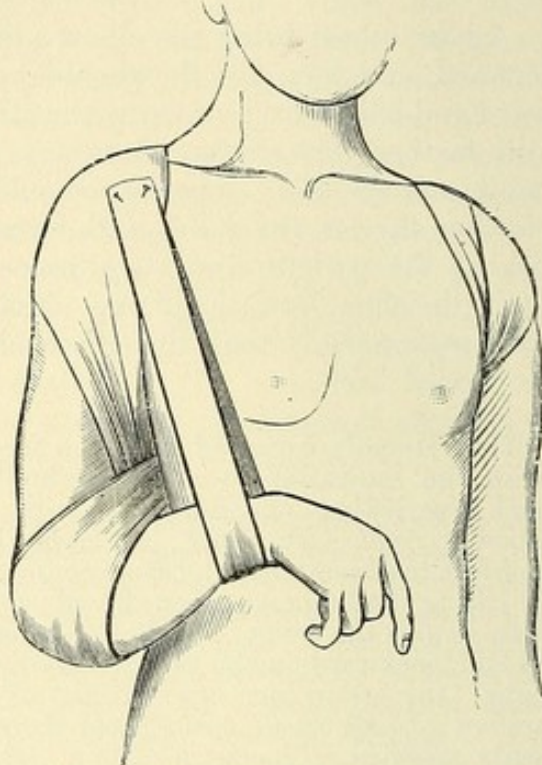
fibres of the pectoralis major, and at the same time draws the scapula backward toward the spine; it overcomes the action of the sterno-cleido-mastoid, which lifts the sternal fragment, and draws the acromial fragment outward and upward.

FIG. 82.



Moore's apparatus. Back view.

FIG. 83.



Moore's apparatus. Front view.

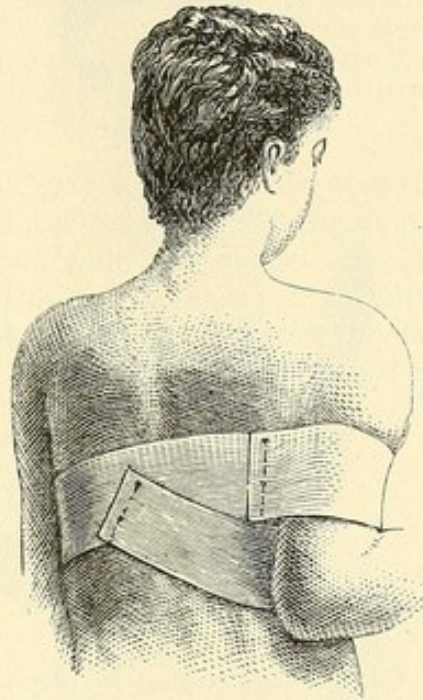
These ends are accomplished by placing the extremity of the middle finger of the broken arm upon the ensiform cartilage, with the forearm and elbow pinned back and against the body. In order to secure the arm in this position, Dr. Moore uses a shawl or piece of cotton cloth, which, when folded like a cravat, eight inches in breadth at the centre, should be about two yards long. Placing this at the centre across the palm of the surgeon, he seizes with his hand the elbow of the patient which corresponds with the broken clavicle. The two ends of the bandage hang to the floor. The one falling inward toward the patient is carried upward, in front of the shoulder, and over the back, making a spiral movement in front of the shoulder. This is intrusted to an assistant. The outer end is then carried across the forearm, behind the back, over the opposite shoulder, and around the axilla. This meets the other end, which may be carried under the axilla and over the shoulder of the opposite side, thus making the figure eight (8) turn, around the sound shoulder. This twist, it will be seen, makes also the figure eight (8) turn, around the elbow of the affected side. The forearm should be sustained by a sling which raises it to an acute angle in order that gravity may assist in moving the whole arm backward. This is best done by a simple strip three or four inches wide, which may be pinned to the shawl at the shoulder, or by a sling across the opposite shoulder and behind the back; the former is much to be preferred. Any tendency on the part of the shawl to slide from the shoulder may be arrested by a pin thrust at the crossing. The shawl at the elbow is kept in place by folding the upper part that fits the arm and securing it by a pin. This makes a sort of cup for the elbow.

The principle upon which this dressing is constructed appears sound; but in the five or six cases in which it has been employed it failed to

accomplish any more than is accomplished by many other forms of dressing. It is especially liable to become disarranged, and to cause excoriations in the sound axilla; in this respect being quite as liable to criticism as the ordinary figure-of-8.

Dr. Lewis A. Sayre, of this city, has employed an apparatus to render tense the clavicular attachments of the pectoralis major, and thus secure more effectually the depression of the sternal fragment, while at the same time the shoulder is lifted and carried back.

FIG. 84.



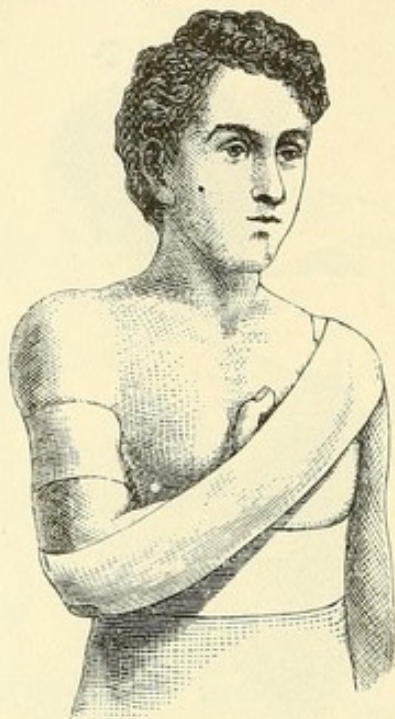
First strip of plaster. (Sayre.)

Two strips of adhesive plaster are prepared, each about three and a half inches wide, for an adult; one long enough to encircle, first the arm, and then the body completely; the other of sufficient length to reach from the sound shoulder, over the point of the elbow of the broken limb, and across the back obliquely to the point of starting. Maw's mole-skin plaster, or some plaster equally strong, is to be preferred. The first strip is looped around the arm just below the axillary margin, and pinned, or stitched, with the loop sufficiently open to avoid strangulation. The arm is then drawn downward and backward until the clavicular portion of the pectoralis major is put sufficiently on the stretch to overcome the sterno-cleido-mastoid, and thus draw the sternal fragment of the clavicle down to its place. The strip of plaster is then carried completely around the body, and pinned or stitched to itself on the back. The second strip is then applied, commencing on the front of the shoulder of the sound side, thence it is carried over the top of the shoulder, diagonally across the back, under the elbow, diagonally across the front of the chest, to the point of starting, where it is secured by pins or thread. A longitudinal slit is made in the plaster, to receive the point of the elbow. Before laying the plaster across the elbow, an assistant must press the elbow well forward and inward, and it must be held firmly in this position until the dressing is completed. It will be now seen that the arm has been converted into a lever, whose fulcrum is the loop of adhesive plaster at the lower margin of the axilla; and upon this it is believed that in a great measure the efficiency of the apparatus depends.

Certainly it no longer depends upon the position of the elbow, which was at first carried back in order to render tense the clavicular fibres of the pectoralis major; since, for the purpose of converting the humerus into a lever, the elbow is subsequently drawn forward, and the clavicular fibres of the great pectoral are again relaxed. If, therefore, the apparatus has any advantages over other modes of treatment, it is solely by its action upon the humerus as a lever; but the fulcrum is too remote from the upper end of the humerus to act very efficiently. Great force has to be applied to secure this end, or at least so much force that, if steadily maintained, it is pretty sure to cause excoriations of the arm where the fulcrum acts; or, as more often happens, it will speedily loosen under the expansion and contraction of the chest in respiration, and thus cease to be efficient. Several cases of fractured clavicles, treated

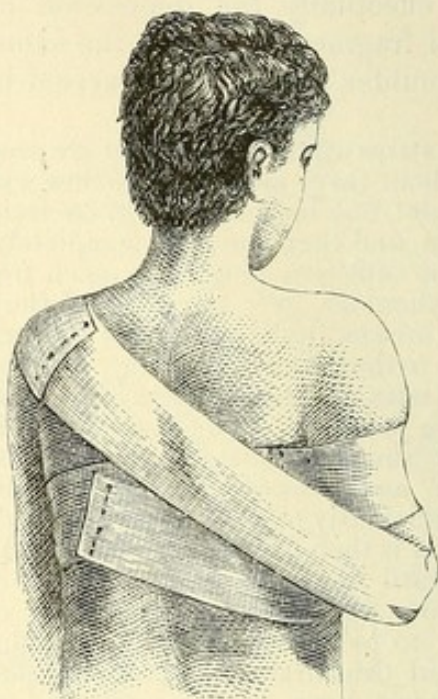
in hospitals by this method, have come under my notice, some of which were dressed by Dr. Sayre himself, and the results have been no better than when my apparatus has been used, whilst they have in most cases caused much more discomfort.

FIG. 85.



Second strip of plaster. (Sayre.)

FIG. 86.



Dressing complete. (Sayre.)

[Spohn,¹ of Corpus Christi, Tex., employs an apparatus which he calls the sub-clavicular or anterior chest splint. It is simply a piece of wood or sole leather made to fit the anterior surface of the chest just below the clavicular bones, two inches wide and long enough to reach the outer side of each arm; the splint is well padded, and two pads are added to place under each end of the splint to fit into what he calls, the lateral triangular space of the chest; the pad should press well against the outer end of the clavicle, coracoid, and acromion processes, and sink in between the upper part of the arm and side of the chest, thus forcing the shoulder-joint outward. A figure-of-8 bandage is next applied and the dressing is complete.

Trimmer,² of White Haven, Pa., states that Dr. Washburn first used an apparatus which he figures, having for its chief peculiarity a crutch in the axilla supported by a steel or iron ring; this ring is sustained by straps, one passing over the opposite shoulder, and the other around the body. The advantage claimed for it is that it can be worn under the clothes and allows the moderate use of the arm. It has the great disadvantage of undue pressure in the axilla.]

No apparatus, perhaps, has been so generally employed, among American surgeons, as that form of the sling introduced by Dr. George Fox into the Pennsylvania Hospital in 1828.

Sargent says of it: "Fractures of the clavicles treated by this apparatus are daily dismissed from the Pennsylvania Hospital, and by surgeons in private practice, cured without perceptible deformity." Norris affirms that "the chief indications in the treatment of fracture of the clavicle are perfectly fulfilled by the use of this apparatus." H. H. Smith declares that Fox's apparatus accom-

¹ Med. and Surg. Reporter, 1887.

² Times and Reg., Oct. 19, 1889.

plishes "perfect cures" in very many cases, and that it is "a very rare thing for a simple case to go out of the house (Pennsylvania Hospital) with any other deformity save that which time cures, viz., the deposition of the provisional callus."

Fox's apparatus (Figs. 87 and 88) consists of a sling (1), a wedge-shaped axillary pad (3) made of muslin, also stuffed, and half the length of the humerus; and of a stuffed collar (1). The axillary pad is placed, with its thickest end upward, in the axilla corresponding to the broken clavicle, and secured in place by tapes attached to its upper end, and made fast to the stuffed collar upon the opposite shoulder. The sling is, in like manner, suspended from the stuffed collar; or, the hand may be suspended over the front of the chest by a piece of muslin, looped under the wrist, and tied around the neck. No bandage is employed to confine the elbow to the body, and no effort is therefore made to convert the arm into a lever, and thus force the shoulder out.

It must be apparent to every practical surgeon that this apparatus could not answer "perfectly" all the indications of treatment, namely, to carry the shoulder up, out, and back, so that the clavicle would be made to unite without shortening or deformity. I must be permitted, however, to express a doubt whether it has made deformities of the clavicle "the exception, instead of the rule," with us. I have used this

FIG. 87.

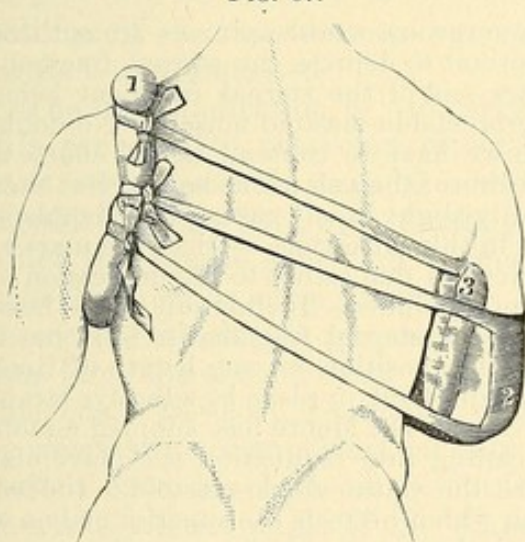
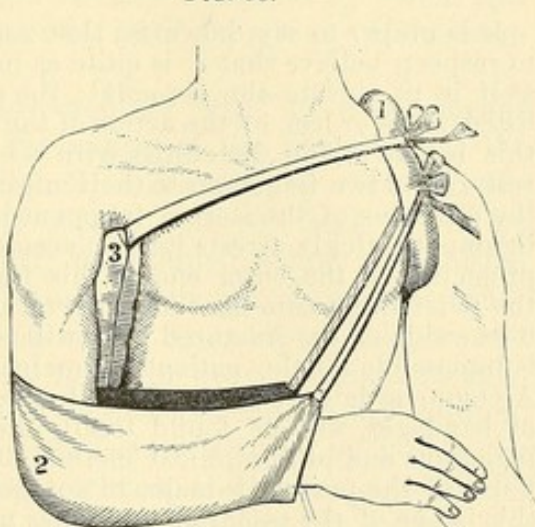


FIG. 88.



Fox's apparatus.

dressing in the early years of my practice quite often, but my success has by no means been so flattering as has been the success of these gentlemen. I have seen others employ it, also, and with [much the same result.

Of the treatment of fractured clavicles by the wire suture, said to have been suggested and practised by Langenbeck,¹ I have only to say that I trust, for the reputation of surgery, and the good of the patients, the practice of this distinguished surgeon will find few imitators.

[The operation of wiring the fragments in fracture of the clavicle is by no means to be discarded when performed aseptically. It has given excellent results where union could not have been obtained without great deformity. Nor is it at all difficult of performance.]

¹ Langenbeck, Dawson, Med. Rec., May 20, 1882.

Finally, while I deprecate incautious assumptions in regard to the capabilities of any form of dressing for broken collar-bones, a disposition to which is manifested by more than one advocate of special plans, I am ready to declare my preference for an apparatus consisting essentially of a sling, axillary pad, and bandages to secure the arm to the chest. Among the considerable variety of dressings which I have used, this has seemed to me most simple in its construction, the most comfortable to the patient, the least liable to derangement (if I except Velpeau's dextrine bandage, and certain other forms of "immovable" dressings), and as capable as any other of answering the several indications proposed, while the patient is permitted to walk about. No apparatus is better able to answer the first indication, namely, to "carry the shoulder up," than the sling. Indeed, in nearly all the forms of dressing hitherto devised, the sling is employed for this purpose. The bandage carried beneath the elbow is, in effect, a sling. In a few instances, men of no practical experience have sought to substitute an upward pressure in the axilla for the sling; but it is scarcely necessary to declare the absurdity of this practice, inasmuch as no patient will be found willing to submit to it beyond a few hours.

It is proper to say, however, that some surgeons, whose opinions are entitled to respect, believe that it is quite as important to depress the sternal fragment as it is to elevate the acromial; the outer end of the sternal fragment being lifted, more or less, by the action of the sterno-cleido-mastoid muscle. No doubt this is one of the difficulties with which we have to contend in our efforts to restore the two fragments to their original line of the axis of the bone. But then the elevation of the sternal fragment is only slight in any case. The rhomboid ligament quickly arrests its displacement in this direction, so that the marked projection of the outer end of this fragment is due rather to the depression of the outer fragments than to an elevation of the inner. Inclination of the head to the side of the fractured limb will allow the sternal fragment to fall; but it is impossible for the patient to maintain this position for any length of time. A compress laid over the sternal fragment, and held in place by adhesive straps or bandages, will be found totally inefficient. Dr. Moore has adopted a more ingenious and philosophical method, by calling into requisition the clavicular fibres of the pectoralis major to antagonize the sterno-cleido-mastoid. Indeed, this is one of the essential principles upon which he rests the superior claims of his dressing; and I have myself observed that when, in the case of a recent fracture, the elbow is thrust behind the body, the outer end of the sternal fragment is depressed. Nevertheless, I have certain theoretical and practical objections to the doctrine as taught so ingeniously by Moore. My theoretical objection is that the clavicular fibres of the pectoralis major will soon, under the continual strain, become relaxed, and after a little time cease to accomplish what they did at first. This is a law in regard to the action of muscles put upon the strain, as every surgeon knows. It may be supposed that, if the pectoral muscle is thus rendered less competent to depress the fragment, the sterno-cleido-mastoid will be rendered, also, less competent to elevate the fragment; but this is not strictly true: the latter operates at right angles with the axis of the bone, and to great advantage, whilst the former acts very obliquely, and to a corresponding disadvantage. The practical objection which I have to offer is, that the dressings required to maintain this position are exceedingly liable to cause excoriations and to become disarranged, and that in fact this has happened in all, or nearly all, of the cases which have been observed by me. Moreover, whatever cause may be assigned for the failure, the results have been no better, so far as overlapping and deformity are concerned, than when my own dressings have been used.

The second indication, namely, "to carry the shoulder back," is certainly more difficult of accomplishment than the first, and it is only imperfectly met by my own method, or by any other form of sling dressing.

Desault taught that when the arm was lifted by the sling, or by any mode of pressure beneath the elbow perpendicularly, the shoulder was necessarily carried back. This is probably true, but its effect is not very marked. The ordinary figure-of-8, which might at first be supposed to be the most rational mode of effecting this purpose, has long since proved to be a failure. None of the contrivances to hold the shoulders back by bands which traverse the axilla, made fast to back-splints, have done any better. They all cause excoriations and soon become intolerable.

After all, it must be said that the indication "to carry the shoulder back," except so far as it incidentally accomplishes the indication "to carry the shoulders out," and thus obviate the overlapping of the fragments, is relatively unimportant. It is seldom that the falling forward of the shoulders is very marked, or in itself a source of deformity; but carrying the shoulder back does diminish or overcome the riding of the fragments, and in this view alone is it important, and for this reason surgery will be indebted to any one who devises a method by which this position of the shoulder can be maintained until the union of the fragments is consummated.

The third indication is "to carry the shoulder out," by which means it is proposed to overcome, directly, the riding of the fragments. We have seen that this may be accomplished, indirectly, by carrying the shoulder back; but, unfortunately, no means has yet been found by which this can be done and permanently maintained, while the patient is in the erect or sitting posture. The thick axillary pad, and all other devices by which it is proposed to act upon the humerus as a lever, and thus force the shoulder out, have totally failed or proved eminently mischievous. In short, I may say that this indication can, in my opinion, be effectually accomplished in only one way, and that is, by laying the patient upon his back on a flat, firm mattress, and thus pressing the base and inferior angle of the scapula strongly and steadily against the back. The requisite pressure upon the scapula cannot be maintained by any plan yet contrived while the patient is in the sitting or standing posture, and especially when permitted to walk about. We shall be warranted therefore in attempting to accomplish this indication fully in only rare and exceptional cases. If a slight overlapping and deformity were to cause any appreciable diminution of the strength or usefulness of the arm, patients might properly enough be subjected to such restraints for a few weeks; but experience has shown that such displacements do not, in any degree, maim the arm. Whether, in the case of women, in examples of unusual displacement, the danger of disfigurement would warrant a resort to this method, must be left to the judgment of the surgeon and the choice of the patient; but in adopting what may be termed the "posture" treatment, it will be advisable also to employ the sling, pad, and bandages in the manner hereafter to be described.

The mode of dressing a fractured clavicle which, while the patient is

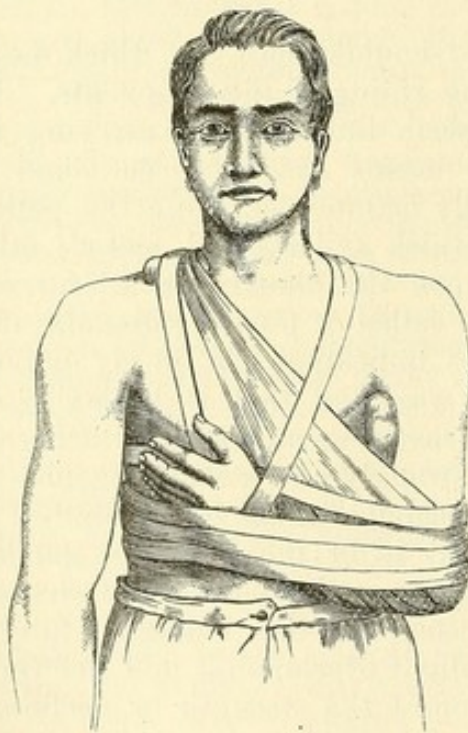
at liberty to walk about, will secure the best results with the least suffering and annoyance, is as follows :

The arm hanging perpendicularly beside the body, a sling is placed under the elbow and forearm, and tied over the opposite shoulder. An axillary pad, composed of cotton batting inclosed in a cloth cover, is placed well up in the axilla, and the elbow is then secured firmly to the side of the body with several turns of a roller.

Dr. Coates,¹ in the excellent paper already referred to, calls attention to the danger of making too much pressure upon the brachial artery and nerves, when the axillary pad is used, and the arm is, at the same time carried forward upon the body. In bringing the elbow forward, so as to lay the forearm across the body, the humerus is made to rotate inward, and the brachial artery and nerves are brought into more direct apposition with the pad ; while in the position which I have recommended and practised hitherto, these nerves and vessels are removed in a great measure, but not entirely, from pressure.

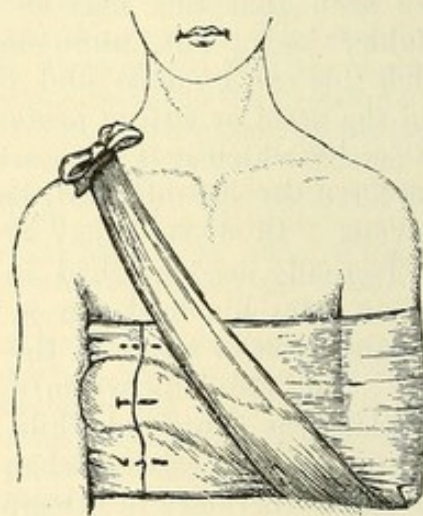
The pad should be no thicker than is necessary to fill completely the axillary space, its purpose being to steady the arm, and, in some slight degree, to counteract the action of those muscles which tend to displace the shoulder inward. It should be long enough in its antero-posterior

FIG. 89.



The author's dressing for fractured clavicle.

FIG. 90.



Four-tailed bandage.

diameter to project distinctly in front and behind, otherwise it will not keep its place. In the adult it needs to be six or seven inches long. In the direction of the axis of the limb, its length should be less, perhaps four inches. Being now well pressed up into the axilla, and secured with a needle and thread to the upper edge of the roller which encircles the lower part of the arm and the body, it will keep its position and serve

¹ Coates, Amer. Journ. Med. Sci., vol. xviii. p. 62.

some useful purpose. The sling may be made of cotton or flannel cloth, and suspended from the opposite shoulder by the aid of four tapes, a broad and thick pad of folded cloth being laid upon the shoulder to support the knots. A considerable experience has satisfied me that the stuffed collar, used in the Fox dressing, possesses no advantage as a means of suspension. The leather sling, also, in use in some hospitals, is liable to the objection that it cannot be stitched to the roller, which encircles the body and lower part of the arm in the manner I shall hereafter describe. The roller should be made to encircle the lower fourth of the arm, and a few turns should pass beneath the forearm as far forward as the hand, in this manner securely fixing the elbow and forearm against the side and front of the body.

If thought necessary, the hand may be supported by a loop of bandage passed under the wrist and tied over the neck. In order that this dressing may retain its place and serve its purpose most effectually, its several parts should be stitched together thoroughly wherever the dressings cross or approach each other. In no other way can anything like permanency be insured in a portion of the body so movable as the shoulder and chest; but even with this precaution, daily attention and occasional readjustment are generally required.

[A simple and very efficient apparatus, especially for children, is illustrated by Fig. 90.¹ It consists of a piece of strong calico, fourteen inches wide, and sufficiently long to go around the body one and a half times: cut a hole in its centre, about four inches from the margin, for the point of the elbow; split up the ends of the bandage in the same line as the hole, that is, four inches from the border to within about six inches of the hole. This makes a four-tailed bandage with tails of unequal breadth, one four inches broad, the other ten. Now place a wedge-shaped pad in the axilla, if thought necessary; lay the patient flat on his back to enable the fragments to fall into position; lay the arm to the side and flex the forearm on the chest; apply the bandage in such manner that the point of the elbow shall stick into the hole and the broad tail of the bandage enclosing the humerus be brought across the chest and fastened to the opposite side of the body, thus binding the arm to the side; the narrow tail, which will be below the elbow, is now crossed over the broad tail and tied over the top of the opposite shoulder.]

Treatment of Incomplete Fractures of the Clavicle.—In case of partial fracture of the clavicle, accompanied with a persistent bend in the line of the axis of the bone, it is proper to attempt the replacement of the fragments by direct pressure. The ends of the bone being fixed, we cannot, as in the case of a partial fracture of other long bones, employ leverage; and with direct pressure alone, applied in a degree which might be regarded as incurring no danger of causing a complete fracture or of a dislocation, our chances of success are very small. I cannot say that I have ever succeeded in accomplishing anything in this way, although I have often made the attempt, and would always advise others to do the same. A failure, however, to restore completely the line of the axis of the bone is not, I imagine, a matter of great consequence, since, as has already been fully explained when speaking of partial fractures in general, the natural form will be in most, if not in all cases, completely restored after the lapse of a few months or years. This observation applies especially to partial fractures occurring in childhood

¹ Pick, Fractures and Dislocations.

and infancy. I have no experience as to what is the result of a similar deformity left after a partial fracture in the adult.

As to the method of dressing these fractures, it need not differ from that recommended for complete fractures; but in a majority of these cases I have thought it sufficient to place the arm in a sling, with a bandage around the elbow and body to keep the arm at rest; or I have directed the mother to make the sleeve fast to the front of the dress with tapes; or the hand and arm of the child may be withdrawn from the sleeve and placed across the body inside the dress, and secured in this position by a belt around the waist. In this case, of course, the dress must remain upon the child until the cure is completed. The axillary pad can seldom, if ever, serve any useful purpose. Union occurs with great rapidity, sometimes as early as the seventh or tenth day; but the arm ought to be kept quiet, as a matter of safety, two or three weeks.

CHAPTER XX.

FRACTURES OF THE SCAPULA.

FRACTURES of the scapula may be divided into those which occur through the body, the neck, the acromion process, and the coracoid.

§ 1. Fractures of the Body of the Scapula.

Under this title I propose to consider not only fractures of the "body," properly speaking, but also fractures of the angles and of the spine.

Causes.—The scapula is usually broken by the fall of some heavy body directly upon the bone, or by some severe crushing accident, by the kick of a horse, by a fall upon the back; in short, by direct causes alone, and by such causes as operate with great violence.

I have recorded six cases which were under my treatment; and I have seen a few other examples of fractures of the body of the scapula not caused by firearms. There are two cabinet specimens of fracture of the body of the scapula below the spine in the Pennsylvania Medical College, and two involving the spine. Dr. Mütter had in his collection a fracture of the posterior angle, and Dr. March had a specimen of fracture of the body. Among 2358 fractures reported from Hôtel Dieu during a period of twelve years, only four examples of fracture of the scapula are recorded; and, at Middlesex Hospital, Lonsdale has noticed, among 1901 fractures, only eight of the body of the scapula.

The infrequency of this fracture is no doubt due in a great measure to the elasticity of the ribs, to the mobility of the scapula, and to the softness of the muscular cushion upon which it reposes.

[McKee,¹ of Sacramento, Cal., reports two cases of fracture of the body of the scapula, one being complicated with fracture of a rib on either side of the clavicle

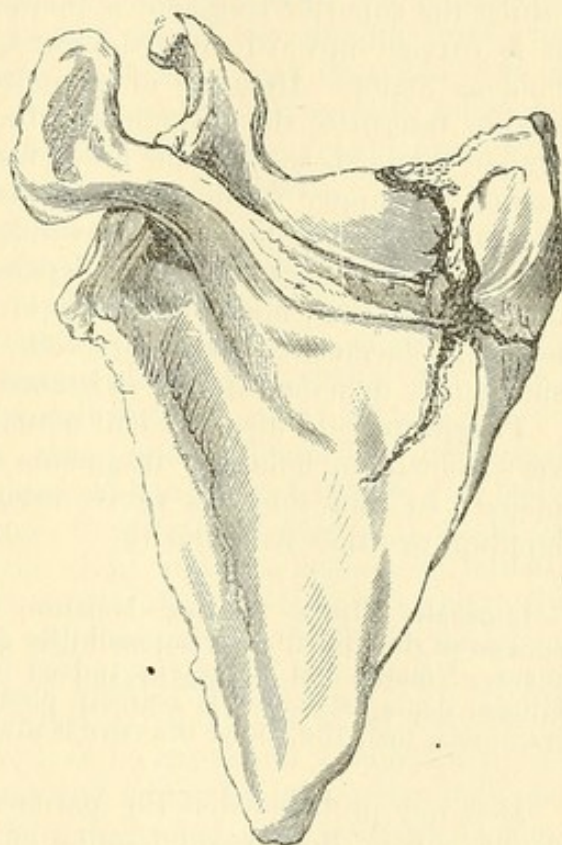
¹ Sacramento Med. Times, May, 1887.

at the junction of its inner and middle thirds. The treatment consisted of compresses with broad adhesive bands.]

Symptoms.—Since this bone is seldom broken except by great force directly applied, the usual signs of fracture are likely to be concealed by the speedy occurrence of swelling. It is for this reason that it becomes necessary, generally, that the examination should be made with great care before we can safely determine upon the diagnosis. When, however, the line of the fracture has traversed the spine, and any considerable displacement has occurred, one may recognize the fracture easily by merely carrying the finger along the crest. If the fracture has occurred through the body, below or above the spine, or through either of the angles, the displacement may not be so easily recognized. The surgeon ought then to trace carefully with his finger the outlines of the scapula; and this he will be able to do more satisfactorily if he places the scapula in such positions as elevate its margins and render them more prominent. In examining the posterior angle, the hand of the injured limb may be placed upon the opposite shoulder, the forearm being carried across the front of the chest; but in searching for a fracture below the spine, the forearm ought to be laid across the back. Crepitus, which is not always present owing to the fact that the fragments overlap completely, or because they have been widely separated by the action of the muscles, may generally be detected by placing the palm of the hand upon some portion of the scapula, so as to steady the fragment upon which it rests, while the arm is moved backward and forward, and in various other directions, until their broken surfaces are brought into contact. Some degree of embarrassment in the motions of the shoulder and arm must always result from this fracture; sometimes this embarrassment is very great, but it ought not to be considered ever as diagnostic of a fracture, since it may be produced equally by a severe contusion; and even when it is accompanied with a fracture, it is due rather to the contusion than to the fracture.

Pathology, Seat, Direction, etc.—Of incomplete fractures of the scapula, I have seen one example. Complete fractures occur most often below the spine, and they are generally oblique or transverse, sometimes

FIG. 91.



Fracture of the posterior angle of scapula, with fissure. Mütter's collection, Specimen C, No. 187.

nearly longitudinal. Fractures involving the spine are noticed occasionally; but I am not aware that any one has ever seen a specimen of a fracture of the spine alone, although many surgeons have spoken of them. One example of a fracture of the posterior angle is in the cabinet of Mütter, of Philadelphia. Occasionally the bone is broken into more than two fragments. As a result of the fracture there is usually more or less displacement; generally, if the fracture is below the spine and transverse, and especially if its direction is oblique from before backward and downward, the inferior fragment is displaced forward, or forward and upward, by the action of the serratus major anticus, or of the teres major, whilst the superior fragment is inclined to fall backward, and sometimes it is carried upward and backward, following the action of the rhomboideus major. In cases of comminuted fractures, and occasionally in simple fractures, the direction of the displacement is reversed, or altogether changed, so that the lower fragment, instead of being in front, is behind the upper fragment; and instead of overlapping, the two fragments are more or less drawn asunder. These are deviations which are not easily explained, but which depend, perhaps, rather upon the direction of the blow than upon the action of the muscles. In a few cases there is no displacement in any direction, although the crepitus and mobility sufficiently demonstrate the existence of a fracture.

Prognosis.—If displacement actually has taken place, it will be found very difficult to hold the fragments in apposition until a cure is completed; so that they are pretty certain to unite with a degree of overlapping, or other irregularity.

Lonsdale, Lizars, Chelius, Nélaton, Gibson, Malgaigne, and others have spoken of the difficulty or impossibility generally of keeping these fragments in place. Nélaton and Malgaigne, indeed, confess that they have never succeeded; Gibson declares that it is scarcely possible; while Chelius affirms that if the fracture is near the angle, the cure is always effected with some deformity.

It is not probable that the patient will ever suffer any serious inconvenience from the irregular union of the fragments, since the perfection of its function depends less upon any given form or size than in the case of almost any other large bone; and if the free use of the arm is not recovered for some time, or if a permanent stiffness results, these should be regarded as due to the injury which those muscles have suffered which envelop the scapula, or to some injury of ligaments and muscles which surround the shoulder-joint. In some few examples upon record, the bone has been so comminuted, and the soft parts adjacent so much injured, that suppuration and necrosis have ensued.

In a case of gunshot fracture of the scapula, resulting in necrosis, I had occasion to remove the entire scapula.¹ The case is briefly as follows: Private W. M. was wounded by grape-shot, which fractured both the scapula and head of the humerus. Six days later the head and a portion of the shaft of the humerus were removed. At a later period necrosis attacked the scapula, and I removed

¹ Surgical History of the War of the Rebellion, vol. ii., Washington, 1876, pp. 492, 494, 498, 499, 500. Proceedings of N. Y. Patholog. Soc., 1866, in Med. and Surg. Reporter, vol. xiv. p. 372.

the entire scapula, including the acromion and coracoid processes. He recovered very good use of the limb, and was able to contract effectively the biceps and coraco-brachialis, although their upper points of attachment were only cicatricial tissue. Dr. Otis, compiler of the Surgical History of the War of the Rebellion, who has gathered a complete account of this case, remarks that "it affords perhaps a solitary example of a successful extirpation, for the results of shot injury, of the scapula, with preservation of the upper extremity."

Treatment.—In the treatment of this fracture, the first object with all surgeons has been to restore the fragments to place, and this they have chiefly sought to accomplish by position; after which they have endeavored to immobilize the fragments by bandages, etc. In seeking to accomplish the first indication, they have placed the shoulder and arm in a great variety of postures. Nearly all seem to have regarded it as of some importance that the shoulder should be elevated, so as to relax the muscles attached to the upper and back part of the scapula, and thus permit the upper fragment to fall downward and forward.

In the treatment of no other fracture, perhaps, have surgeons differed more widely as to the indications than in this; some recommend the elbow to be carried from the body, and some that it shall be made to approach the body; one directs that the elbow shall fall perpendicularly beside the chest, a second prefers that it shall be carried a little back, and a third that it shall be brought well forward. In one thing alone have they nearly all agreed, namely, that the elbow shall be lifted; and generally also it has been recommended that the arm, forearm, and body shall be confined by sufficient bandages to insure quietude. It might be proper to conclude, therefore, that the sling and bandage constitute all of the apparatus which is necessary or useful; and that it is relatively unimportant whether the elbow is near or remote from the body, or whether it is in front of, or behind, or beside the chest. Such, indeed, is the conclusion to which I have myself arrived; yet if, in relation to the position of the elbow, a choice were to be expressed, I would give the preference to that in which the arm is laid vertically beside the body, or, perhaps, with the elbow a little inclined backward, so as to relax as completely as possible the *teres major*. It is quite probable, however, that no single position will be found of universal application; and perhaps it would be more safe to advise the surgeon in any given case first to reduce the fragments as completely as possible by manipulation, and then to place the arm in such a position as, upon careful experiment in this particular instance, he shall find enables him best to retain them in place.

If, however, the fracture is such as to have separated the inferior angle from the body, it will be well to follow the advice of Boyer and of others, and to place a compress in front of the inferior angle, to resist the greater tendency to displacement in this direction. This compress will more effectually accomplish this indication if the roller with which it is secured to the body, and with which we seek to immobilize the scapula and chest, is turned from before backward, or in a direction of antagonism to the action of the muscles which produce the displacement.

Desault, with Chelius and Bransby Cooper, has recommended also, in the case of a fracture through the angle, that the forearm should be acutely flexed upon the arm, and that the hand should be placed in front of the chest, upon the

sound shoulder, a position which is always irksome, and sometimes insupportable, and which does not offer in any case sufficient advantages to render it worthy of a trial.

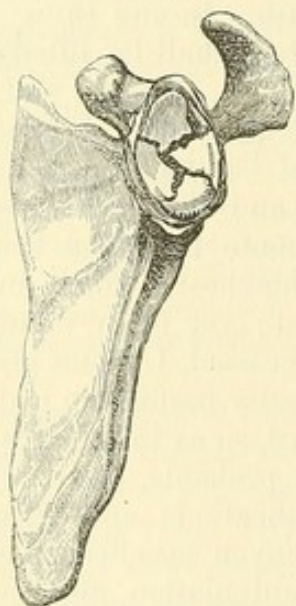
§ 2. Fractures of the Neck of the Scapula.

If by the "neck" of the scapula surgeons mean that slightly constricted portion of this bone which is situated at the base of the glenoid cavity, the "anatomical" neck, its fracture is certainly very rare.

Indeed, the existence of this fracture, uncomplicated with a comminuted fracture of the glenoid cavity, is denied by Sir Astley Cooper, South, Erichsen, and others. Mr. South says there is no such specimen in any of the museums in London; and I have not been able to find one in any of the American cabinets. Dr. Valentine Mott had never seen a specimen, and in the natural condition of the bone he regards its occurrence as impossible. Such, I confess, also, is my own conviction.

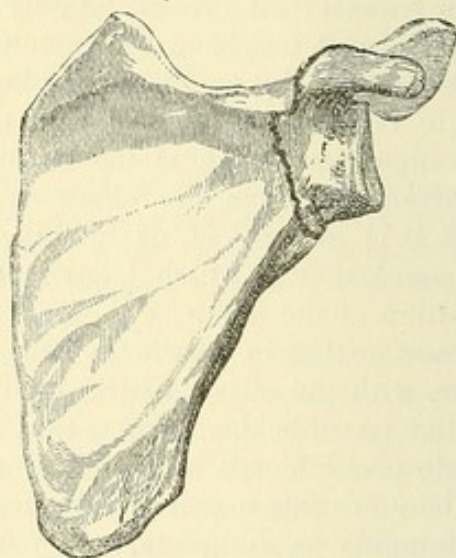
If, however, it is intended, in speaking of fractures of the neck of the scapula, to refer only to fractures extending through the semilunar notch,

FIG. 92.



Comminuted fracture of the
glenoid cavity.

FIG. 93.



Fracture of the neck of the scapula;
according to Sir Astley Cooper.

behind the root of the coracoid process, "surgical" neck, then its existence is certain; yet the fracture is not common.

Duverney has reported one example, the existence of which he established by a dissection. The coracoid process was broken at the same time, but the fracture through the surgical neck was distinct from this; and Sir Astley has recorded three examples in which the diagnosis was very clearly made out, yet not actually proved by an autopsy.

There is one specimen in the museum of Guy's Hospital; another, in which repair has taken place, in the museum of the Royal College of Surgeons.¹ Per-

¹ Holmes's Surgery, vol. ii. p. 776, Amer. ed. 1870.

haps some of the cases, diagnosticated during the life of the patient as fractures of the neck of the scapula, were fractures of the lower or anterior lip of the glenoid cavity; but I have never found such a specimen in any collection of bones which I have yet examined, and it must be admitted to be exceedingly rare.

[Heminway, of Kalamazoo, Michigan, reports a case of injury to the shoulder in the person of a physician which he seems to have correctly diagnosticated as fracture of the neck of the scapula. It was first taken to be a dislocation of the shoulder, but the restoration to place was like that of a fracture of the neck of the scapula, and was followed by crepitus.¹

Parker,² of Liverpool, reports three cases of this fracture, all the result of severe accidents. There was paralysis of the muscles, with the more marked signs of dislocation of the humerus. Reduction was followed by the return of deformity. The position which most completely restored the bone, and was comfortable, required that the arm should be slung with the hand lying on the top of the right shoulder, and retained by a triangular bandage.]

Symptoms.—Sir Astley Cooper justly remarks that “the degree of deformity produced by a fracture of the surgical neck of the scapula depends upon the extent of laceration of a ligament which passes from the under part of the spine of the scapula to the glenoid cavity. If this be torn” (and to this we ought to add the ligaments passing from the coracoid process to the clavicle and acromion process—coraco-clavicular and coraco-acromial), “the glenoid cavity and the head of the os humeri fall deeply into the axilla, but the displacement is much less if this remains whole.” The usual signs are, a depression under the acromion process, the same as in dislocation of the head of the humerus downward, but not so deep; the head of the humerus felt, perhaps, in the axilla; crepitus, and the immediate recurrence of the displacement whenever, after the reduction has been fairly accomplished, the arm is left unsupported. The crepitus is best discovered by resting one hand upon the top of the shoulder in such a manner as that a finger shall touch the point of the process, while the arm is rotated and moved up and down by the opposite hand. It may also be easily ascertained that the coracoid process moves with the humerus instead of the scapula. Occasionally the accident is accompanied with paralysis of the arm, from pressure upon the axillary nerves; and a rupture of the axillary artery is also mentioned by Dugas.³

Treatment.—The indications of treatment are three, namely, to carry the head of the humerus, with the glenoid cavity, etc., up, to carry it out, and to confine the body of the scapula. The first is accomplished by a sling, the second by a pad in the axilla, and the third by a broad roller carried repeatedly around the arm and chest and across the shoulder. In short, the treatment is essentially the same as that which I have recommended for a broken clavicle.

§ 3. Fractures of the Acromion Process.

There is some reason to believe, I think, that a true fracture of the acromion process is much more rare than surgeons have supposed, and

¹ Journ. Amer. Med. Assoc., 1887.

² Brit. Med. Journ., Aug. 22, 1885.

³ Remarks on Frac. of Scapula, by L. A. Dugas, Georgia. Amer. Journ. Med. Sci., Jan. 1858.

that in a considerable number of the cases reported there was merely a separation of the epiphysis; the bony union having never been completed. If such fractures or separations occurred only in children, very little doubt might remain as to the general character of the accident; but the specimens which I have found in the museums, and the cases reported in the books, have been mostly from adults. It is more difficult, therefore, to suppose these to be examples of separation of epiphyses, but I am inclined to think that in a majority of instances such has been the fact. It is very probable, also, that in the case of many of the specimens found in the museums, called fractures, the histories of which are unknown, they were united originally by cartilage, and that in the process of boiling, or of maceration, the disjunction has been completed. The narrow crest of elevated bone which frequently surrounds the process at the point of separation, and which Malgaigne may have mistaken for callus, is found upon very many examples of undoubted epiphyseal separations which I have examined; and this circumstance, no doubt, has tended to strengthen the suspicion that these were cases of fracture.

The opinion is confirmed by the remark of Mr. Fergusson that a fracture of this process is an accident "of rare occurrence." "I have dissected," he adds, "a number of examples of apparent fracture of the end of this process; but in such instances it is doubtful if the movable portion had ever been fixed to the rest of the bone." Dr. Jackson says there are four specimens in the museum of the Massachusetts Medical College, and in the museum of the Boston Society for Medical Improvement, which might easily be mistaken for fractures, but which only illustrate to how late a period the bony union is sometimes delayed. In one specimen the patient could not have been less than forty years of age; "the acromial process of each scapula was fully formed, but having no bony union whatever with the bone itself. The union was ligamentous, but strong and close."

[On the contrary, Lane,¹ of London, states that in a careful examination of the bones of 325 bodies in the dissection he has found that a considerable proportion presented fractures of the acromion, and he concludes that this portion of the scapula is broken more frequently than any other bone in the body. He attributes the discrepancy in the estimate of the frequency of this fracture by those who publish statistics to the fact that fractures of the acromion are generally overlooked. He states that in many instances of so-called contusion of the shoulder of the living subject he has been able to satisfy himself of the presence of an ununited fracture of the acromion.]

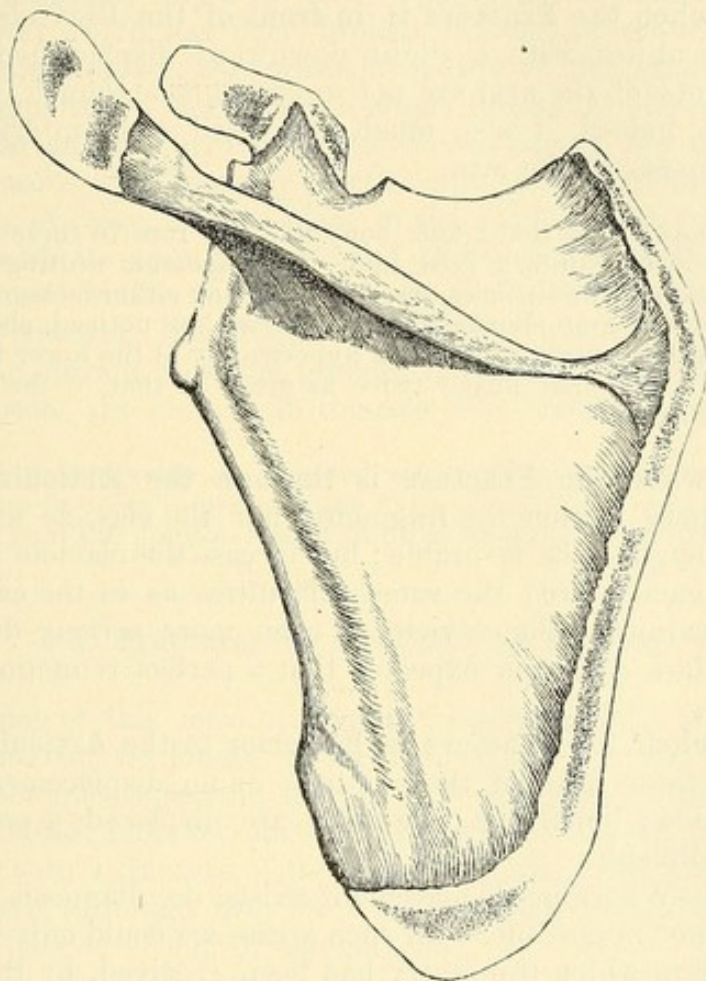
To the same class belong several specimens in my own collection; in March's collection in Albany; two specimens in the Mütter, and one in the Jefferson Medical College museums. In my own specimens, as well as most of the specimens which I have examined, the ends of the fragments were closed with a compact bony tissue.

The mode of development of the scapula will explain these cases. The scapula is formed from seven centres; namely, one for the body, one for its posterior border, one for its inferior border, two for the acromion process, and two for the coracoid. Ossification of the body exists to a certain extent at or near the period of birth. It commences in one of the centres of the coracoid process, about one year after birth, and unites to the body at about the fifteenth year. All the other centres remain cartilaginous until from the fifteenth to the seventeenth year, when

¹ Brit. Med. Journ., May 19, 1888.

ossification commences, and is completed by a common union among all parts, usually between the twenty-second and twenty-fifth years. There is no doubt, however, that a fracture of this process does occasionally take place.

FIG. 94.



Scapula, with epiphysis. (From Gray.)

Examples of fracture of the acromion process have been reported by Duverney, Bichat, Avard, A. Cooper, Desault, Sanson, Nélaton, Malgaigne, West, Brainard, Stephen Smith, and others. I have myself seen five cases. In the case seen by Cooper it entered the articulation of the clavicle, and produced at the same moment a dislocation. Malgaigne says it occurs generally further up, and posterior to the attachments of the clavicle, "near the junction of the diaphysis with the epiphysis," and that the fracture is in most cases transverse and vertical; but Nélaton saw a case in which the fracture was oblique. In the case reported by C. West, of Hagarstown, Md., the fracture was through the base of the process. In two of the examples seen by me the fracture was in front of the clavicle; in the third, occasioned by the fall of a barrel of flour upon the shoulder, the fracture occurred at the acromio-clavicular articulation, and was accompanied with an upward dislocation of the outer end of the clavicle; in the fourth, the fracture occurred at the same point, but there was neither displacement of the clavicle nor of the process, the fracture being only recognized by crepitus and motion. The fifth was brought to my notice by Dr. Sabine, surgeon to Bellevue Hospital. The patient had been struck by a policeman's club. There was distinct crepitus, the fracture being posterior to the acromio-clavicular junction, but there was no displacement of the fragments or of the clavicle. Some of the fractures were confirmed by dissection, and in the case mentioned by Stephen Smith, an autopsy, made three weeks after the accident, showed a

fracture in front of the clavicle without displacement, the periosteum covering its upper surface not being torn; the fragment could be turned back as upon a hinge.

[This fracture was caused by a blast; a fragment of rock being driven upward struck the acromion on the under surface.]

Prognosis when the Fracture is in front of the Clavicle.—The process generally unites with a slight downward displacement. In such cases the motions of the arm are not in consequence much, if at all, impaired; unless, indeed, it is so much depressed as to interfere with the upward movements of the arm.

Sir Astley Cooper says that a true bony union is rare in these fractures, and that there generally results a false joint, the fragments uniting by a fibrous tissue; but sometimes the surfaces, instead of uniting either by bone or ligament, become polished and even eburnated. Malgaigne has noticed, also, a specimen contained in the Dupuytren museum, a hypertrophy of the lower fragment, this portion having a diameter nearly twice as great as that of the portion from which it was detached.

Prognosis when the Fracture is through the Articulation of the Clavicle.—Where neither the fragments nor the clavicle are displaced, the prognosis ought to be favorable; but in case the clavicle is dislocated, there will be encountered the same difficulties as in the case of simple acromial dislocation of the clavicle, or even more serious difficulty, and I do not see how it can be expected that a perfect reduction should be maintained.

Prognosis when the Fracture is Posterior to the Articulation of the Clavicle.—In these cases, if there is little or no displacement, the prognosis is favorable; but if the fragments are displaced, a perfect adjustment may be difficult.

Symptoms.—Where no displacement exists, the diagnosis must always be difficult, if not impossible. In such a case we could only be instructed by the manner in which the injury had been received, by the contusion, and by the presence of mobility or crepitus. In examples attended with displacement, if no swelling is present, the finger, carried along the spine of the scapula to its extremity, will easily detect the fracture by the abrupt termination or elevation of the process, or by the presence of a fissure, or a depression; but as to the other symptoms, they must depend very much upon the point at which the fracture has taken place. If in front of the acromio-clavicular articulation, the position of the arm in its relations to the body will not be changed; but if the fracture is through the articulation, and a dislocation of the clavicle results, or if it is behind the acromio-clavicular articulation, the arm, having in either case lost the support of the clavicle, will be inclined to assume the same position that it does in a fracture of the clavicle; that is, the shoulder will be disposed to fall downward, inward, and forward.

Treatment.—If the fracture has taken place in front of the acromio-clavicular articulation, no doubt the most rational plan of treatment, if one aims at the accomplishment of a perfect bony union, is placing the patient in bed, upon his back, and carrying the arm out from the body nearly to a right angle; since by this method the fragment is not only lifted, but the deltoid muscle is relaxed, and, consequently, the fragment

is no longer forcibly drawn away from the spine of the scapula. If, therefore, the patient will submit to this treatment for a sufficient length of time, the union must be accomplished with the least possible amount of displacement. But in the case of a fracture of the acromion process at the point indicated, only a few fibres of the deltoid muscle are attached to the fragment which has been broken off, and, consequently, even in case no union took place, the muscular power of the arm could not be appreciably impaired. Nor would a slight falling or depression of the fragment cause any embarrassment to the motions of the shoulder-joint. For these reasons it is scarcely worth while to do anything more, in a great majority of cases, than to place in the axilla a pretty heavy wedge-shaped pad, with its apex upward, and then secure the arm to the side with a sling and roller, the same as in the case of a fracture of the clavicle. If, however, the fracture has taken place at or behind the junction of the clavicle with the process, the indications of treatment will be, in all respects, the same as in the case of a fracture of the clavicle.

[Haldeman,¹ of Zanesville, O., applied also a pliable compress immediately over the fracture in order to preserve the natural roundness and fulness of the shoulder. He is of the opinion that it fulfilled its purpose admirably.]

§ 4. Fractures of the Coracoid Process.

The existence of this form of fracture, established by at least nine or ten dissections, can no longer be denied; yet it is often accompanied with serious complications, and such as have sometimes proved fatal. In the only two cases, however, in which I have had reason to believe that I had to deal with a fracture of this kind, the symptoms and termination were less grave, although they were both complicated with an upward dislocation of the outer end of the clavicle.

[Mr. Arbuthnot Lane² has published an interesting paper on "Mode of Fixation of the Scapula: suggested by a study of the movements of that bone in extreme flexion of the shoulder-joint, and its bearing upon the fracture of the coracoid process." He contends that fixation of the scapula occurs only when that bone is in a state of extreme flexion. In that condition the coracoid process presses firmly upon the under surface of the clavicle, and effectually prevents further flexion. If violence continues to be applied in this situation the coracoid process may be broken. This, he thinks, explains the cause of that fracture when a person falls forward with the arms stretched directly forward, and being completely flexed at the shoulder.]

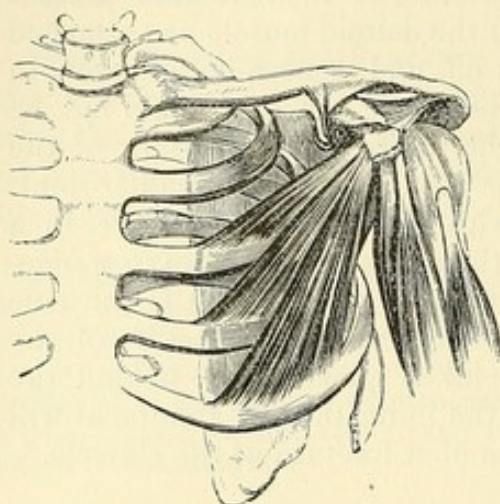
A gentleman residing in the country was struck by a board which fell edge-wise upon his shoulder. An apparatus was applied to retain the clavicle in its place, but after three months, when he called upon me, it still remained displaced as at first. On laying off the dressing, I discovered that the coracoid process was detached, obeying constantly the movements of the head of the humerus, but being not at all subject to the movements of the scapula. The functions of the arm were not impaired. A girl fell upon her left shoulder, and sustained a complete luxation of the acromial end of the clavicle, upward and outward. Upon careful examination, a fracture of the coracoid process was indicated by both mobility and crepitus.

¹ *Cin. Lancet and Clinic*, 1885.

² *Brit. Med. Journ.*, May 19, 1888.

Bransby Cooper relates a case of fracture through the base, which after eight weeks, when the patient died, was found to be united by a ligament. The acromion process was broken at the same time, and had united in the same manner. The head of the humerus was also broken partly united.¹ One example occurred in the practice of Dr. Arnott, London, in consequence of which the patient died, when a dissection disclosed the true nature of the accident.² South has reported a case. The humerus was partially dislocated forward, the clavicle, acromion process, and the olecranon were broken as well as the coracoid process; after the patient died, on the fourth day, the existence of these fractures was ascertained by dissection.³ Holmes has reported a case.⁴ There is in the museum of University College a preparation showing a fracture at the base of the process, the line of fracture extending across the glenoid cavity.⁵ Duverney, Boyer, and Malgaigne have reported four additional examples, confirmed by dissections.⁶

FIG. 95.



Fracture of the coracoid process.

Neill, of Philadelphia, has a specimen of separation of this process at about one inch from its extremity; the scapula is large, and evidently belongs to an adult, and the fact that the acromion process is not yet united by bone renders it probable that this is an epiphyseal separation. Gibson, of Richmond, Va., has a specimen, from an adult, which has been broken obliquely near the end, but which is now united by a ligamentous or fibrous tissue of one line and a half in length. The fragment is displaced a little forward as well as downward. Mussey, of Cincinnati, possessed a very remarkable and conclusive example of this fracture. The humerus is dislocated forward, the head and neck being firmly united to the neck and venter of the scapula, while at the same time the coracoid process is broken and displaced.

Little, of this city, had an example of this fracture. The arm, forearm, and hand were completely paralyzed. The coracoid process seemed to be displaced inward, or toward the median line of the body; but when the humerus was forcibly rotated outward, the coracoid resumed its place, and if now pressure was made upon its extremity, it became again suddenly displaced, with a subdued, grating sensation.

E. Hulme believed that he had met with the fracture, caused by muscular action, in the person of a man who, in falling, was caught by his arm in such a way that it was drawn forcibly from the body.⁷

Bennett, of Dublin, met with a case of separation of the coracoid epiphysis in the person of a boy *æt.* six years. He had been knocked down by a tram-car and so severely injured that amputation of the arm at the shoulder was required; he died of tetanus, and the autopsy showed separation of the coracoid. It was detached at its base, the line of separation passing through the proximal side of the cartilage, and at the upper and back part taking off a scale of bone from the supra-spinous fossa.⁸

[Johnson,⁹ of Baltimore, has collected twenty-seven cases of fracture of the coracoid. In one case the fracture was caused by muscular action. The accompanying injuries are numerous, as dislocation and fracture of the humerus, dis-

¹ B. Cooper, edition of Sir Astley on Frac. and Disloc., Amer. ed., p. 380.

² Arnott, Fergusson's Surg., p. 231.

³ South, Lond. Med.-Chir. Rev., 1840, vol. xxxii., new series, p. 41.

⁴ Holmes, Med.-Chir. Trans., vol. xli. p. 447.

⁵ Erichsen, Surgery, p. 207.

⁷ Hulme, Lancet, vol. ii. p. 737, 1873.

⁸ Dublin Journ. Med. Sci., 1888.

⁶ Malgaigne, *op. cit.*, p. 512.

⁹ Med. News, Nov. 21, 1885.

location of the outer end of clavicle, fracture of the base of the skull, dislocation of humerus, paralysis of arm, etc.]

It has been generally stated that when this process is broken off, it will be carried downward by the united action of the pectoralis minor, the short head of the biceps, and the coraco-brachialis muscles; but this will depend upon whether the coraco-clavicular ligaments are ruptured also; a circumstance which is not very likely to occur, at least to any great extent; and in fact not one of the well-attested examples of this fracture has ever been accompanied with any considerable displacement in this direction.

Treatment.—In a case of simple fracture of the process, unattended with any other lesions, it has been recommended to place the arm in a sling, with the elbow advanced as much as possible upon the front of the chest, as by this position we relax somewhat all of the three muscles having attachments to this process, and then to confine the scapula by a few turns of a roller. It is not probable, however, that by these measures we would accomplish enough to justify their continuance if they were found to be painful, or even exceedingly irksome. Patients under my observation have generally complained very much of the pain and discomfort attending this position of extreme flexion of the arm and forearm, first employed by Velpeau for fractures of the clavicle. Moreover, I do not think the fragments are generally displaced; and if they were, and the final union were to be accomplished solely by ligament, I think the usefulness of the arm would not be at all impaired. Such, at least, has been my experience in the two cases above recorded, and in both of which no bony union occurred. In Dr. Little's case rotation of the humerus outward seemed to effect a reduction, but upon what principle precisely this position acted to effect the reduction I am not prepared to say; perhaps by drawing upon the coraco-brachialis and short head of the biceps—nor am I prepared to say that it would accomplish the same result in any other case, yet it may deserve a trial. In the graver forms of the accident, where other bones about the shoulder are broken or dislocated, or the limb has suffered other severe injuries, which, as we have seen, constitute the larger proportion of the whole number, the treatment must generally have little or no regard to this particular injury.

CHAPTER XXI.

FRACTURES OF THE HUMERUS.

UNFORTUNATELY, surgical writers have not been agreed in the use and application of the terms "head," "neck," "anatomical neck," and "surgical neck" of the humerus; and, as a consequence, the meaning is often obscure, and their teachings are sometimes contradictory and absurd. It is necessary, therefore, that we should define them more

precisely. The "head" of the humerus is that smooth, elliptical surface, covered by cartilage and synovial membrane, which articulates with, and is received into, the glenoid cavity of the scapula. The "anatomical" neck is the narrow line immediately encircling the head, and which receives the insertion of the capsular ligament. The "surgical" neck is that portion which commences at the lower margin of the tubercles, or at the point of junction between the epiphysis and the diaphysis, and which terminates at the insertion of the pectoralis major and latissimus dorsi. The "neck" is all of that portion included between the head and the insertions of the pectoralis major and latissimus dorsi; comprising not only the anatomical and surgical necks, but also the tubercles; which latter occupy the triangular space between these two.

Of 203 fractures of the humerus examined and recorded by me, 51 occurred through the upper third, 43 through the middle third, and 103 through the lower third. Of the fractures belonging to the upper third, 6 were supposed to be epiphyseal separations, one was probably a fracture at or near the anatomical neck, with impaction and splitting of the tubercles, one was a fracture of the greater tubercle alone, and 44 were fractures at or near the surgical neck; some of them probably involving the shaft below the neck. Of the fractures belonging to the lower third, 22 were through the internal condyle, 29 through the external condyle, 18 were at the base of the condyles, 6 through the condyles and across the base at the same time; 1 at the epiphysis; the remaining 27 being through the shaft, but above the base.

§ 1. Fractures of the Head and Anatomical Neck. (Intracapsular; Non-impacted and Impacted.)

Fractures of the Head are due to the penetration of balls or of other missiles directly into the joint, producing thus a compound, and generally comminuted, fracture of the head; and to falls, or direct blows upon the shoulder, without penetration. When the fracture results from the direct penetration of some foreign body into the joint, it is not only a compound fracture, but the head of the bone is almost necessarily broken into many fragments. If the patient recovers, sooner or later the fragments have generally to be removed, or resection has to be practised. Examples of fractures of the head of the humerus, not caused by penetrating injuries, and not accompanied with fracture of the anatomical neck, or of the tubercles, are very rare. Nevertheless now and then a specimen has been found for which this distinction has been claimed; in most of which the fracture has been of the nature of a simple fissure.

Gosselin describes a case in which there were two fissures extending through the articular cartilage, and about one centimetre into the spongy structure. The joint contained half an ounce of blood; death having occurred fourteen hours after an accident the exact character of which was not determined.¹ Malgaigne has described a similar case, in which there were two fissures, one horizontal in its direction, and the other vertical.² Gross refers to a case of single fissure of the head, which had become consolidated.³ Howe speaks of a specimen in the

¹ Gosselin, Gurlt.

² Malgaigne's Atlas, pl. 4, fig. 2. (In the text, vol. i. p. 526, only one fissure is described.)

³ Gross, Treatise on Surg., 1st ed., vol. ii. p. 190.

Dupuytren museum in which about one-third of the head had been broken off and united. He also refers to another specimen in the same collection which Lenoit regarded as a fracture of the anatomical neck and which was ununited.¹ Examples in which the fracture of the head is accompanied with a fracture of the anatomical neck, or of the tubercles, are much more frequently observed.

Fractures of the Anatomical Neck sometimes follow, with a remarkable degree of accuracy, the line of the insertion of the capsular ligament, being always, according to Robert Smith, within the interior or outer margin of this insertion. He calls them, therefore, intracapsular. It is probable, however, since, as we shall presently see, bony union is not denied to certain supposed examples of this fracture—that the line of separation is not always, or generally, perhaps, completely within the insertion of the ligament, but that it is in some degree extra-articular, if not extracapsular.

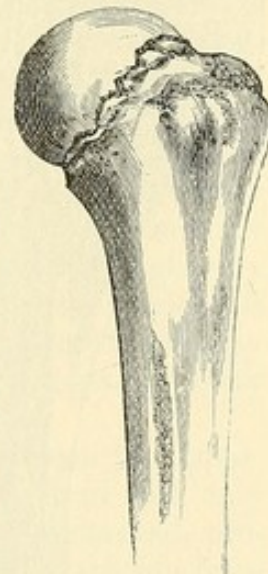Boyer says that he has seen several examples of this fracture, none of which, however, was accurately diagnosticated until after death. He observes that the specimens which have been fully recognized as intracapsular, would seem to show that the superior fragment contributes almost nothing to the process of repair, but that, as in the case of intracapsular fractures of the neck of the femur, they are subjected to a process of partial absorption. He further illustrates the correctness of these conclusions, by reference to a case examined in the autopsy seven days after the accident, in which the head had already suffered a remarkable diminution by the process of absorption. He quotes, also, two cases described by Reichel, in which union had taken place, and the exact line of fracture could not, therefore, be so accurately determined.²

Mr. Spence exhibited a specimen to the Medico-Chirurgical Society of Edinburgh, May 2, 1860. A man advanced in life, in consequence of a fall, sustained a fracture. He died at the end of four weeks, from apoplexy. The fracture was found in the autopsy to have passed "through the anatomical neck;"—that is, between the head and tuberosities, and within the capsular ligament. No union had taken place.³

Gibson, also, thinks that the fragment occasionally remains without becoming necrosed, or causing suppurative action, being gradually absorbed and changed in figure. He says that his museum contains three or four well-marked cases of this kind, in all of which the head has lost its spherical form, and is very much diminished, and rough and flattened next to the scapula.⁴ Other cabinets are said to contain similar specimens.

The displacements to which the upper fragment, or the head of the bone, is subject, are remarkable, and some of them do not seem to be satisfactorily explained. Frequently, indeed, its position is not sensibly disturbed, but at other times it is found impacted, or driven into the cancellous structure of the inferior fragment, in consequence of which one or both of the tubercles are frequently broken off.

FIG. 96.



Fracture of the anatomical neck.

¹ Howe, *Gaz. des Hôp.*, 1858, p. 272.

² Boyer, *Trait. des Mal. Chir.*, 4th. ed., 1831, vol. iii. p. 199.

³ Spence, *Ed. Med. Journ.*, vol. v. p. 1140, 1860.

⁴ Gibson, *Elements of Surgery*, vol. i. p. 279.

Robert Smith relates the following case as having afforded him his first opportunity of ascertaining by post-mortem examination the exact nature of this form of displacement: "A female, æt. forty-seven, was admitted into the Richmond Hospital, under the care of the late Dr. McDowell, for an injury to the humerus, the result of a fall upon the shoulder. Five years afterward, the woman was again admitted, under the care of Mr. Adams, with an extracapsular fracture of the neck of the femur, one month after the occurrence of which she died, in consequence of an attack of diarrhœa. The shoulder was of course carefully examined; the arm was slightly shortened, the contour of the shoulder was not as full or round as that of its fellow, and the acromion process was more prominent than natural. Upon opening the capsular ligament, the head of the humerus was found to have been driven into the cancellated tissue of the shaft, between the tuberosities, so deeply as to be below the level of the summit of the greater tubercle; this process had been split off, and displaced outward; it formed an obtuse angle with the outer surface of the shaft of the bone."¹

FIG. 97.

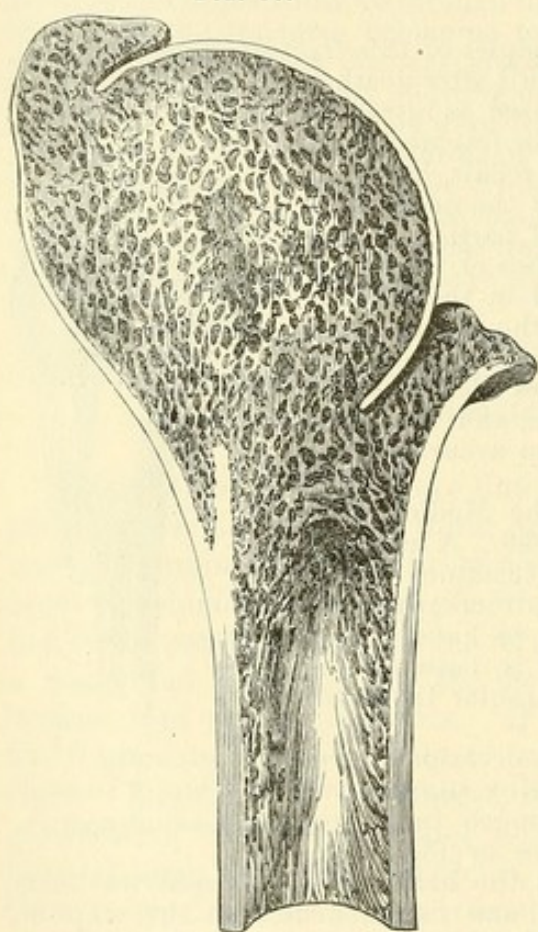
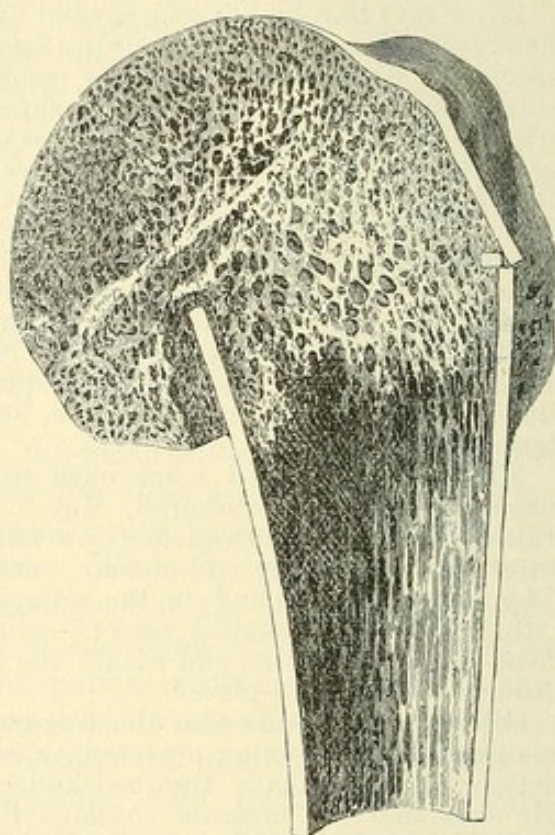


FIG. 98.



Penetration of fragments in fracture at the anatomical neck.

Two excellent drawings (Figs. 97 and 98) of the specimen show the distance to which the superior fragment had penetrated the inferior, and show also complete union by bone.

[The penetration in these cases is rather of the shaft into the cancellated tissue of the head of the humerus.]

I believe, also, that in the following example there was a fracture at or near the anatomical neck, with impaction, and splitting of the tubercles: A young man fell from a height in a gymnasium, severely injuring his left shoulder. I saw him soon after the accident, and found him complaining very much of the shoulder, which was somewhat swollen and tender. He could not tell how he

¹ R. Smith, *Fractures in Vicinity of Joints*, pp. 191-3.

fell, nor could we discover any contusions by which to determine the point where the blow was received. All motions of the shoulder-joint were painful; and there was a remarkable fulness in front of the joint, feeling like the head of the bone, yet not such as is usually present in a forward luxation. To determine this more positively, however, the limb was manipulated as for the reduction of a dislocation. Once during the manipulation a feeble but distinct crepitus was detected; yet the position of the bone remained unchanged. The head was found to be in the socket, but the precise nature of the injury was not made out. Fifteen days later, when the swelling had completely subsided, a careful examination was again made, when we arrived at the conclusion that it was a fracture through the bicipital groove, and that the lesser tubercle was carried forward half an inch or more from its fellow, while the head and the greater tubercle occupied their natural positions opposite the socket. The fragment projecting in front presented a sharp point, and could not be confounded with any swelling of the soft parts. There was a distinct space between the tubercles, into which the finger could be laid. No depression existed under the acromion process behind, but, on measurement, the head of the humerus was found to be half an inch wider in its antero-posterior diameter than the opposite. That this fracture was accompanied with impaction was rendered certain by the repeated and careful measurements of the length of the humerus, which constantly showed a shortening of half an inch.

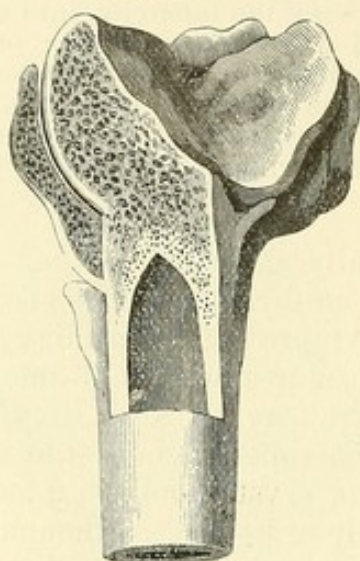
Under these circumstances union generally takes place; but it is usually accompanied with the formation of an irregular mass of osteophytes, which encircle the head like a coronet; presenting in this respect again a remarkable resemblance to extracapsular fractures of the neck of the femur. This ensheathing callus, as it may be called, is an out-growth from the inferior fragment, and it sometimes incloses the upper fragment as the case of a watch incloses the crystal, only in a manner much more irregular, thus retaining it steadily in its place, although very little direct union has occurred. The cancellous tissue, nevertheless, is occasionally found united completely by a new and intermediate bony tissue, and at other times by a fibrous tissue, or by both fibrous and bony tissue.

In some cases a perfect false joint has been formed between the opposing surfaces; while in a few unfortunate examples the head not only refuses to unite, but by its presence, as we have already remarked, produces inflammation and suppuration, resulting in its final extrusion from the joint. At other times the upper fragment turns upon its own axis, and is found more or less tilted or completely rotated in the socket; so that its cartilaginous or articulating surface rests upon the broken surface of the lower fragment, and its own broken surface presents toward the glenoid cavity.

Robert Smith has described a specimen of this kind which he removed from the body of a woman, aged forty, who many years previous to her death fell down a flight of stairs, and struck her shoulder with great violence against the edge of one of the steps. Whether she applied to a surgeon or not at the time of the accident, Mr. Smith was not able to ascertain. After death the shoulder looked somewhat as if there was a dislocation of the humerus into the axilla, there being a marked depression under the acromion process, but the shaft of the humerus was drawn upward and inward toward the coracoid process. When the capsular ligament was opened, the head of the bone was found to have been broken from the shaft through the line of the anatomical neck, and to have completely turned upon itself; and the cartilaginous surface was actually driven one inch into the cancellated structure of the shaft, so as to split off the lesser tubercle with a portion of the greater. Only one-half of the upper fragment

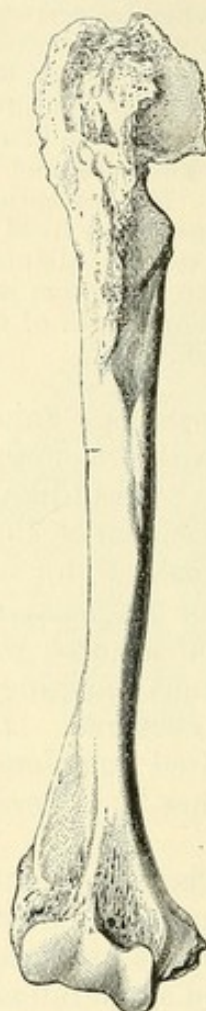
was thus impacted, the other half projecting beyond the margin of the lower fragment. Between the cartilaginous surface and the shaft no union had occurred; but there was complete bony union between the upper and lower fragments, beyond the limits of the cartilage. (Fig. 99.) The upper surface of the superior fragment rested in part against the inner half of the glenoid cavity and upon its inner margin, and in part it rested against the neck of the scapula in the direction of the coracoid process.¹

FIG. 99.



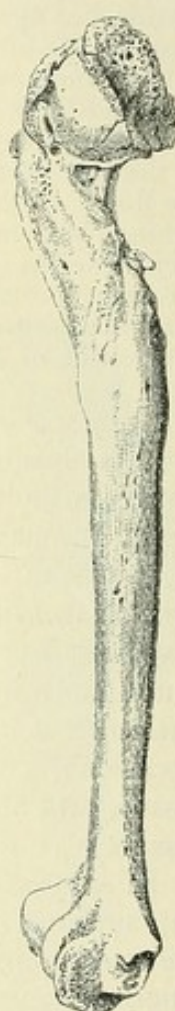
Fracture through the tuberosities of the humerus and reversal of the head. (R. W. Smith.)

FIG. 100.



Front view.

FIG. 101.



Side view.

Dr. Pope's specimen.

Nélaton saw a similar specimen in the possession of M. Dubled, the revolution of the upper fragment being complete; but there was no lateral displacement, and the union had been accomplished in a manner similar to that which is seen after intracapsular, impacted fractures, without reversion.²

I have also been permitted to examine a specimen belonging to the late Dr. Pope, of St. Louis, Mo., which seems to have been broken not only through the line of the anatomical neck, but also through the surgical neck. Both fragments are united by bone, the lower fragment being carried in the direction of the coracoid process, while the upper fragment appears to be reversed, so that its articular surface is directed toward the shaft, and its broken surface articulates with the glenoid cavity. The history of this specimen is unknown.

Reverting to the histories of the several cases above referred to, in which these extraordinary changes of position have taken place, it would

¹ R. Smith, *op. cit.*, pp. 193-6.

² Nélaton, *Éléments de Pathol. Chirur.*, tom. prem., p. 307.

seem to admit of a doubt whether they were the direct results of the accidents which broke the bones, or whether they ensued indirectly, in consequence of a chronic arthritis following the accident, and the constant but long-continued use of the arm, and muscular contraction. There is another theory which, in my opinion, is capable of explaining most of the phenomena presented in some or all of those cases in which union of the fragments is claimed to have taken place, and which, if admitted, renders the supposition of a fracture unnecessary. It is, that in consequence of an injury, perhaps, but not of a fracture, chronic inflammation, softening and absorption have taken place, and that the changed position of the head is due to pressure alone, being acted upon by the muscles which surround the joint, and which act all the more vigorously because they partake also of the inflammation which has invaded the bone.

This theory, which had already more than once suggested itself to me, was very strongly confirmed by its having occupied the mind also of Dr. Neill, of Philadelphia, and who, at his own instance, stated to me that he believed this was their true explanation. We were, at the time, examining Dr. Pope's specimen, already alluded to, and on comparing it with a specimen of dislocation and partial absorption of the head of the humerus contained in Dr. Neill's museum, the points of resemblance were so numerous and striking that we felt compelled to doubt whether Dr. Pope's specimen, together with those seen by Smith and Nélaton, did not belong to the same class with this of Neill's. Other writers have reported similar cases.

I do not mean to deny the possibility of bony union under these circumstances, but only to suggest that such an occurrence would seem to be very improbable, and that its actual occurrence does not seem at present to be absolutely proved. If union by bone is improbable when the head of the femur is broken within the capsule, how much more improbable must it be when the head of the humerus is thus broken; in which latter case there is not even the poor supply of nutrition furnished to the head of the femur by the round ligament.

In a case of fracture of the "cervix humeri within the capsular ligament," examined by Sir Astley Cooper, there was also a complete forward luxation of the head; but ligamentous union had occurred between the fragments.¹

§ 2. Fractures through the Tubercles. (Extracapsular; Non-impacted and Impacted.)

Under this division we intend to speak of all fractures traversing the upper end of the humerus, and involving the tubercles; or of all those which occur between the anatomical neck on the one hand, and the epiphyseal junction, or surgical neck, on the other hand, and which may be more or less oblique as well as transverse. Fractures of the greater or lesser tubercles are, of course, expected, since they are more properly longitudinal fractures, and do not completely traverse the diameter of the bone. Nor do we intend to include those fractures which occur at the epiphyseal junction; since, being below the principal insertion of those muscles which are attached to the tubercles, they present very peculiar

¹ Sir A. Cooper on Dislocations, etc., p. 372.

and distinctive features, which will demand for them a separate classification and consideration.

Causes, Pathology, and Results.—Fractures through the tubercles, like fractures through the anatomical neck, are the results generally of direct blows received upon the shoulder. They are not usually accompanied with much lateral displacement at the point of fracture; a circumstance which finds a partial explanation in the fact that the line of fracture is through the insertions of the muscles converging upon the tubercles, and not entirely above or below them, so that they continue to act nearly equally upon both fragments; but it is also sometimes due in a measure to impaction: the head being forced downward toward the axilla, and upon the shaft, until it is made to ride upon its inner or axillary wall like a cap; the compact bony tissue of the shaft penetrating the reticular structure of the head. These fractures generally unite by bone; yet more or less impairment of the motions of the limb results from the inflammation which occurs in and about the joint, or from the irregular deposits of callus in the vicinity of the fracture.

§ 3. Longitudinal Fractures of the Head and Neck; or Splitting off of the Greater Tubercle.

Causes, Pathology, Symptoms, and Results.—Mr. Guthrie seems to have been the first to call attention to this peculiar injury of the shoulder. In a lecture delivered in November, 1833, he described four cases which had come under his observation, and which he regarded as examples of separation of the small tuberosity, accompanied with more or less of the head, the fracture extending along a portion of the bicipital groove.¹ Robert Smith, however, believes that it was the greater and not the lesser tuberosity which was thus detached in the cases mentioned by Mr. Guthrie, since the external signs were so nearly like those which were present in a woman seen by himself, and in whom an autopsy enabled him to verify his diagnosis.

The following is the case as related by Mr. Smith: In July, 1844, I was requested to examine the body of J. D., æt. eighty years, who had died of chronic pulmonary disease. Upon entering the room, the appearances of the left shoulder-joint at once attracted my attention, and struck me as being different from those which attend the more common injuries of this articulation. The shoulder had lost, to a certain extent, its natural rounded form; the acromion process, although unusually prominent, did not project as much as in cases of dislocation of the head of the humerus. The breadth of the articulation was greatly increased, and, upon pressing beneath the acromion, an osseous tumor could be distinctly felt, occupying the greater part of the glenoid cavity; it formed a prominence which was perceptible through the soft parts; it moved along with the shaft of the humerus, but was manifestly not the head of the bone.

"A second and larger tumor, presenting the rounded form of the head of the humerus, lay beneath the base of, and internal to, the coracoid process, and between the two the finger could be sunk into a deep sulcus, placed immediately below the coracoid process. The elbow could be brought into contact with the side, and there was no appreciable alteration in the length of the arm. Upon removing the soft parts, the head of the bone presented itself, lying partly beneath and partly internal to the coracoid process. The greater tuberosity,

¹ Robert Smith, p. 181, from Lond. Med. and Phys. Journal.

together with a very small portion of the outer part of the head of the bone, had been completely separated from the shaft of the humerus. This portion of the bone occupied the glenoid cavity, the head of the humerus having been drawn inward so as to project upon the inner side of the coracoid process; it was still, however, contained within the capsular ligament. The fracture traversed the upper part of the bicipital groove, which, in consequence of the displacement which the head of the bone had suffered, was situated exactly below the summit of the coracoid process. A new and shallow socket had been formed upon the costal surface of the neck of the scapula, below the root of the coracoid process, and the inner edge of the glenoid cavity corresponded to the posterior part of the sulcus which separated the head of the bone from the detached tuberosity. The latter was united to the shaft only by ligament. The capsule had not been injured, but was thickened and enlarged, and the bone had been deposited in its tissue. The injury had evidently occurred many years before the death of the patient, but the history connected with it could not be precisely ascertained.¹

The following I believe also to have been an example of this rare accident: J. H., æt. seventy-eight, fell upon the sidewalk, striking upon his right shoulder. Eight days after, Dr. Boardman and myself examined the limb carefully. Although we placed him under the influence of chloroform, the diagnosis was not satisfactorily made out. We inclined, however, to the opinion that it was a fracture of the greater tubercle. The antero-posterior diameter of the upper end of the bone was greatly increased; there was occasional distinct crepitus, but the limb was not shortened.

Subsequently, the examinations were repeated many times, and the depression between the fragments becoming more palpable, the diagnosis was at length confirmed.

Dr. Charles, demonstrator of anatomy, Queen's College, Belfast, has reported a case with great care. The man was thirty years old, and it is supposed that the middle of the head of the humerus was struck by the pole of a tram-car. Dr. Charles examined the patient fourteen months after the receipt of the injury; the breadth of the head of the humerus was greatly increased, there was a broad sulcus in the situation of the bicipital groove, and the humerus was shortened half an inch. The motions of his arm were very much limited, especially in abduction.²

Mr. Robert Smith thinks that when the displacement is considerable, the fragments generally unite by ligament, rather than by bone.

§ 4. Fractures through the Surgical Neck. (Including Separations at the Upper Epiphysis.)

I have already defined the "surgical neck" as all of that narrow portion commencing at the upper epiphysis and terminating at the insertion of the pectoralis major and latissimus dorsi. It seems proper, therefore, that we should include under this division both fractures and separations occurring at the epiphysis, especially since, owing to their anatomical relations, they are subject to the same displacements as fractures occurring half an inch or one inch lower down; the capsular muscles, with the exception of the teres minor, having no more influence over the lower fragment when a separation occurs at the epiphysis, than when a separation occurs at any other point of the surgical neck.

Separation at the Upper Epiphysis.—A brief description of the plan of development of the humerus will enable the reader better to understand the occasional separation of the epiphysis, both at the upper and lower ends of the bone.

¹ Robert Smith, *op. cit.*, p. 178.

² J. J. Charles, *British Med. Journ.*, Sept. 26, 1874.

The humerus is originally formed from seven cartilaginous centres, namely, one for the shaft, one for the head, one for the greater tuberosity, one for each epicondyle, and two for the lower, articulating end of the bone. At birth the shaft is ossified in nearly its whole length. Between the first and fourth years ossification commences in the several centres composing the upper end of the bone, and they coalesce by the end of the fifth year, so as to form a single epiphysis, which finally unites with the shaft at about the twentieth year. At the lower end of the bone, ossification commences in the radial portion of the articular surface at the end of two years, in the trochlear portion at twelve years, in the internal epicondyle at the fifth year, and in the external epicondyle at the thirteenth or fourteenth. At the sixteenth or seventeenth year all the centres are joined to each other, and to the shaft, except the inner epicondyle, which

does not unite by bone until about the eighteenth year. It will be observed, therefore, that although ossification commences in the upper epiphysis first, it is the last to form bony union with the shaft.

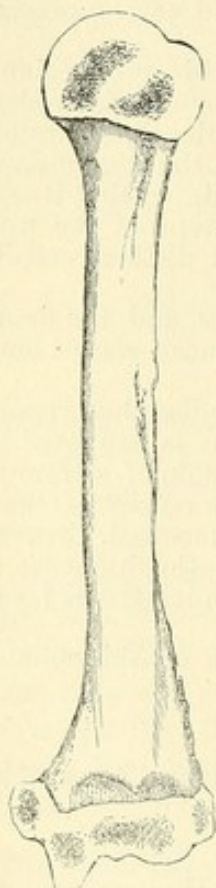
The following cases of separation at the upper epiphysis have come under my notice :

CASE 1.—M. B., æt. thirteen months, fell sideways from his cradle, causing some injury to his arm near the shoulder. Three weeks after the accident he was brought to me, and I found the arm hanging beside the body, with little or no power on the part of the child to move it. There was a slight depression below the acromion process, and considerable tenderness about the joint; but the shoulder was not swollen, nor had it been at any time. The line of the axis of the bone, as it hung by the side, was directed a little in front of the socket. On moving the elbow backward and forward, the upper end of the shaft moved in the opposite directions with great freedom, and could be distinctly felt under the skin and muscles. This motion was accompanied with a slight sound, or sensation—a sensation not unlike the grating of broken bone, but much less rough. There was no shortening of the limb. When the elbow was carried a little forward upon the chest, the fragments seemed to be restored to complete coaptation; and of this I judged by the restoration of the line of the axis of the shaft to the centre of the socket, and by the complete disappearance of the depression under the point of the acromion process. I applied suitable dressings to retain the arm in this position; but five months after the injury was received the fragments had not united, and the child was still unable to lift the arm, although the forearm and hand retained their usual strength and freedom of motion. The same crepitus could occasionally be felt in the shoulder, and the same preternatural mobility. The shoulder was at this time neither swollen nor tender.

CASE 2.—S. R., æt. thirteen, fell through a hatchway, striking on his shoulder. He saw a regular physician within five hours after the injury was received, who said that the arm was dislocated; and on the following day, under the influence of chloroform, he tried to reduce it. The doctor thought he had succeeded, and he then applied bandages to keep it in place. At the end of two weeks I found the upper end of the lower fragment projecting in front, and not united. The arm was shortened half an inch. I have not seen the patient since, and do not know the result.

CASE 3.—J. S., æt. sixteen, fell backward down a flight of steps, striking upon his back and arm near the shoulder, May 10, 1868, causing a separation of the upper epiphysis of the left humerus. Dr. — saw the patient within half an hour, and supposing that he had suffered a dislocation of the head of the humerus, attempted to effect reduction with his heel in the axilla, and without

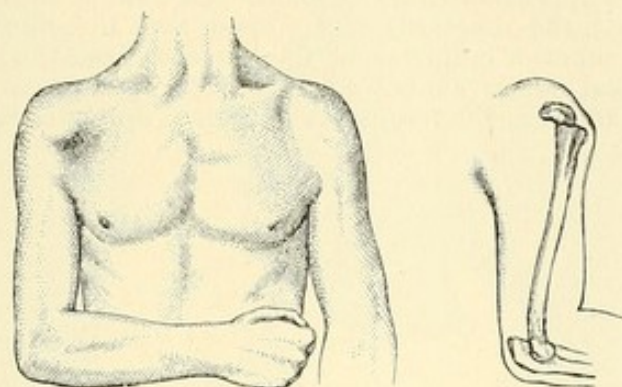
FIG. 102.



Humerus, with epiphyses.
(From Gray.)

anæsthetics. On the following day I found him in Bellevue. All efforts at replacement proving ineffectual, splints were applied, and on the 15th of July the patient left the hospital with the fragments united, but overlapped at the point of fracture, the upper end of the lower fragment being in front of the upper fragment. The limb was shortened one inch, but its motions were free, and there was no reason to suppose that its utility was in any degree impaired.

FIG. 103.



Separation of upper epiphysis of humerus from the shaft. (Bryant.)

CASE 4.—C. H., æt. nineteen, fell from a third-story window. Two very intelligent and experienced physicians thought the boy had received a fracture of the acromion process, accompanied with a dislocation of the head of the humerus, and they attempted to reduce it, but without success. Three weeks after the receipt of the injury I saw the patient in consultation with his physicians, and found a separation of the upper epiphysis of the humerus. The upper end of the lower fragment projected in front of the acromion process, appearing a little above the level of the process, and covered only by the skin. No union had occurred between the two fragments.

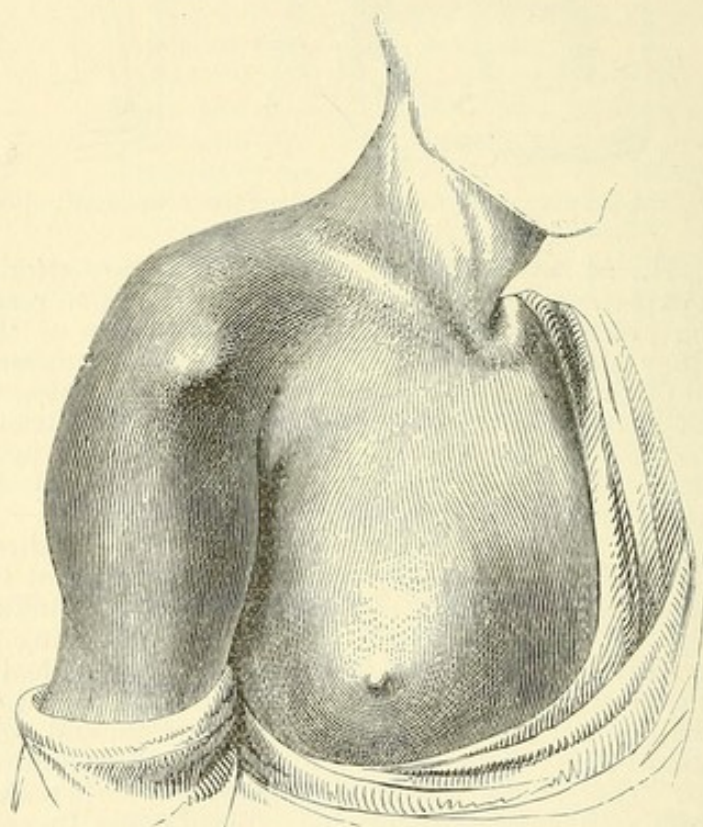
CASE 5.—J. D., æt. eighteen, fell about eight feet. Of the three surgeons first called, two thought the boy had received a fracture; the third believed it to be a dislocation, and having placed the patient under the influence of ether, attempts were made to reduce it. The deformity not being relieved, I was added to the consultation. I found the shoulder a good deal swollen. The upper end of the lower fragment could be felt distinctly in front of the acromion process. At first, the surgeons informed me, the broken end seemed just under the skin and almost ready to be thrust through, but the extension had made it retire somewhat. The end felt rough and serrated. While making extension I was able to detect a slight crepitus or click. Employing Dugas's test, I found the elbow would rest upon the front of the chest; the diagnosis was complete. Applied one long splint, and a sling under the wrist, but not under the elbow. The fragments have united with very little deformity.¹

The following case, mentioned by Robert Smith, is a characteristic example: "A boy, eight years of age, was admitted to the Richmond Hospital. About a week previous to his admission he had fallen upon the shoulder, and at once lost the power of using his arm. It was at first sight evident that there did not exist any luxation of the head of the humerus, and it was equally obvious that the case was not an example of any of the ordinary fractures to which the neck of the bone is liable. There was no diminution of the natural rotundity of the shoulder, nor any unusual prominence of the acromion process; the head of the bone could be distinctly felt in the glenoid cavity, and it remained motionless when the arm was rotated; there was very little separation of the elbow from the side, but it was directed slightly backward. About three-quarters of an inch below the coracoid process there existed a remarkable and abrupt projection, manifestly formed by the upper extremity of the shaft of the humerus, every motion imparted to which it followed. Its superior surface,

¹ Medical Record, May 1, 1874.

which could be distinctly felt, was slightly convex, and its margin had nothing of the sharpness which the edge of a recently broken bone presents in ordinary fractures. When this projecting portion of the bone was pushed outward, so as to bring it in contact with the under surface of the head of the humerus (previously fixed as far as it was possible to do so), a crepitus was produced by rotating the shaft of the bone. It did not, however, resemble the ordinary crepitus of fracture, but it would be extremely difficult, by any description, to convey a clear idea of what the difference consisted in. From a careful consideration of the symptoms and appearances above mentioned (taking into account also the age of the patient), the diagnosis was formed, that the injury consisted in a separation of the superior epiphysis of the humerus from the shaft of the bone. Various mechanical contrivances were employed in this case, but all proved ineffectual in maintaining the fragments in their proper relative position."¹

FIG. 104.



Appearance after separation of the upper epiphysis of the humerus. (R. W. Smith.)

—According to Malgaigne,² Bertrandi found this condition in a child born dead, and Durocher reported a case, in which it was produced at birth by a midwife, who had hooked her finger into the armpit to expedite the delivery.

Prof. E. M. Moore, of Rochester, observes that the displacement is not usually complete; but that the upper end of the lower fragment is carried inward to the distance of about one-fourth of its diameter, when it is arrested, by a convexity of the lower fragment becoming lodged in a natural concavity in the upper fragment. The upper fragment now becomes tilted by the action of the muscles, its internal margin ascending in the glenoid cavity, and its outer margin descending until it is arrested by the capsule. If, under these circumstances, the arm is carried forward and upward to the perpendicular line, the upper fragment or epiphysis will remain fixed, being held fast by the capsule inserted into the outer and posterior margin of the head, while the lower fragment or diaphysis,

¹ Robert Smith, *op. cit.*, p. 201.

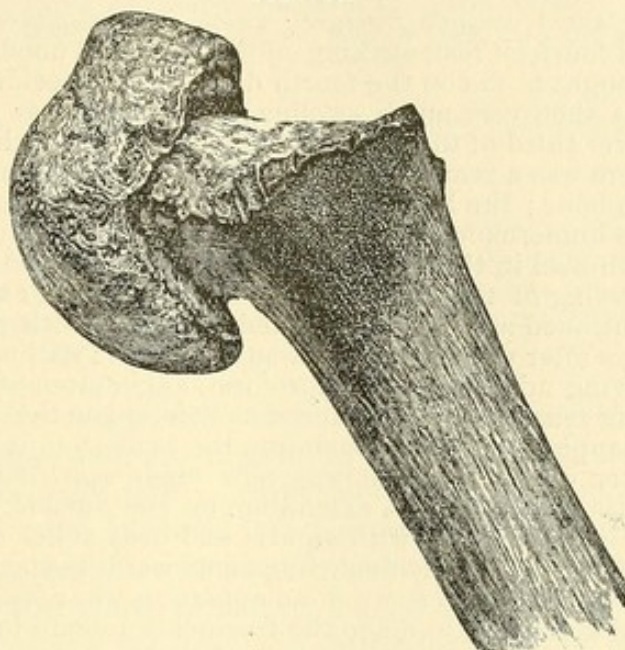
² Bertrandi, Durocher, Malgaigne, *op. cit.*, t. i. p. 60.

aided by the natural action of the muscles, will move outward and resume its original position. The correctness of this opinion he has verified by having in this manner effected the reduction with great ease, in three cases which have come under his observation. The patients were respectively six, fourteen, and sixteen years of age. In the first case the reduction was effected on the four-

FIG. 105.

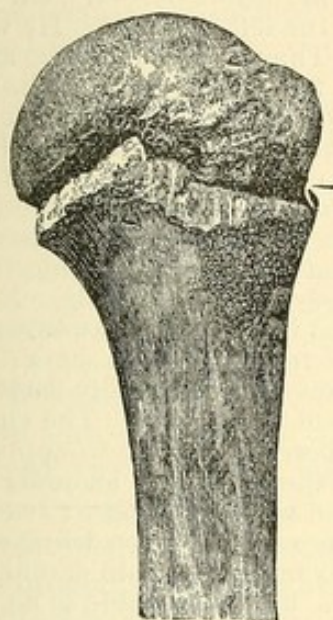

FIG. 106.

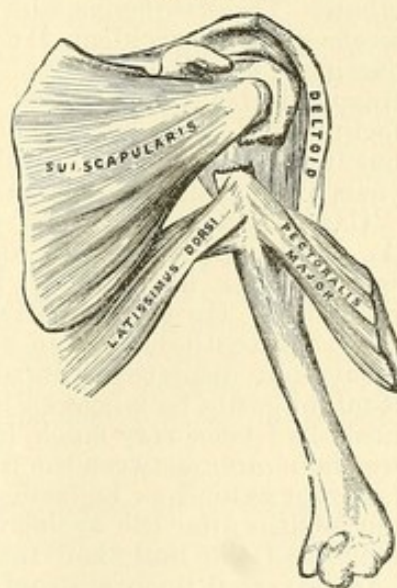


Upper epiphysis of humerus. (From Moore.) Epiphyseal separation. (From Moore.)

teenth day; in the second case, on the second day; and in the third, on the seventeenth day. In both of the latter, ineffectual attempts had been already made to reduce what was supposed to be a dislocation. In order to maintain the reduction, it was only found necessary to bring the arm down while in a state of moderate extension, and to secure it beside the body with a Swinburne extension splint. Any of the forms of dressing applicable to a fracture of the surgical neck would probably prove equally efficient.

The observations made by Professor Moore seem to me exceedingly valuable; yet I do not think it always happens that the separation is incomplete, nor does Professor Moore say that it is, but that was the condition in all the cases seen by him. Professor Pooley, of Columbus, Ohio, reports a case occurring in a boy twelve years old, which he was unable to reduce by Moore's method. Dr. Richmond reports another example in a youth nineteen years old successfully reduced by this method. In three cases reported by myself, the upper end of the lower fragment was above the level of the coracoid process, and seemed to be directly beneath the skin. These were probably examples of complete separation; three presented the symptoms described as characteristic of the partial separation in Professor Moore's paper; the projection was less marked, and on a level with the coracoid process, or a little below it. In all my cases, except the first, the upper end of the lower fragment could be felt, not sharp or pointed, as in most examples of fracture of the surgical neck, but somewhat irregularly transverse, and

FIG. 107.



Fracture of the surgical neck of the humerus. (From Gray.)

when covered with the skin and muscle, might be easily mistaken, by the inexperienced, for the head of the bone.

True Fracture of the Surgical Neck.—The various features of this fracture may best be illustrated by the following cases.

CASE 1. *Simple fracture; union, with displacement and deformity.*—W., æt. 12, fell fourteen feet, striking on the front and outside of the left shoulder. He was brought to me on the fourth day after the accident. The upper part of the arm was then very much swollen; was dressed as for a fracture of the middle or lower third of the humerus; shortened one inch; elbow inclined backward, and there was a remarkable projection in front of the joint, feeling like the head of the bone; the hand and arm powerless; suspected a dislocation of the head of the humerus forward; having administered chloroform, attempted its reduction with heel in the axilla; while making extension, felt a sudden sensation like the slipping of the bone into the socket, but on examination found the projection continued as before; repeated the effort, with precisely the same result. Five days after the accident, it was examined; still believed it was a dislocation, and, having administered chloroform, again attempted its reduction; the same slipping sensation was produced as before, and the deformity was repeatedly made to disappear; but, on suspending the extension, it as often reappeared. The character of the accident was now made apparent; proceeded at once to apply a gutta-percha splint, extending, on the outside, from the top of the shoulder to below the elbow, with an arm and body roller secured with flour paste; twelve days after the accident, fragments were displaced the same as when I first saw it, and the same as when no apparatus was applied; examined it again carefully, and attempted to make the fragments remain in place, but was unable to do so, except while holding them and making extension. Twenty-first day removed all the dressings; motion between the fragments had ceased, but the projection and shortening remained as before; now, also, the irregular projections of the fractured bones were more distinctly felt. The dressings were never reapplied. Three months later no change had occurred. He could carry the elbow forward freely, as well as backward, the motions of the shoulder-joint being unimpaired.

CASE 2. *Simple fracture, with displacement; resulting in deformity and non-union.*—L. B., of Lockport, æt. 43, was thrown from his horse, striking upon his right elbow. Three surgeons, who examined the arm, called it a dislocation. Twelve weeks after the accident, Mr. B. called upon me. The right arm was shortened one inch; the elbow hung off slightly from the body; the upper end of the lower fragment was distinctly felt in front of the shoulder-joint, under the clavicle, feeling very much like the head of the bone. The fragments were not united, but they could be seized easily, and made to move separately and freely. Two years after, I found the bone still ununited.

CASE 3. *Simple fracture, probably impacted: resulting in deformity.*—Wm. A., æt. 15, fell backward, striking upon his back and left shoulder. Dr. L. saw the case immediately, and, regarding it as a dislocation, attempted its reduction. He subsequently repeated the attempt. I saw the patient with Dr. L. on the tenth day. The arm was shortened one inch and a half. The fragments were displaced forward, projecting in front of and a little below the joint; it might easily be mistaken for the head of the bone; but the difficulty of diagnosis had been very much lessened by the subsidence of the swelling. There was no motion between the fragments; nor could the deformity, by any manipulation or extension, be made to disappear. It was probably impacted. Nearly ten months after the accident, I found the fragments remaining as when I first examined the limb, and the arm shortened one inch and a half. The elbow hung a very little back from the line of the body. The upper end of the lower fragment was lifted to within one inch of the head of the humerus; the upper fragment having its head in the socket, with its lower end downward and forward. The arm was, however, in every respect as useful as before it was broken. It was equally strong, and he could raise his arm as high and move it in every direction as freely as he could the other.

Causes.—Epiphyseal separations belong almost exclusively to the period of youth and childhood, but true fractures at the surgical neck occur most often in adult life.

With the exception of one girl and two lads, aged, respectively, eleven, twelve, and fifteen years, all of the examples of this latter accident recorded by me (forty-four) occurred in adults; yet Sir A. Cooper declares these fractures to be most common in infancy, while Malgaigne has never seen a case in a person under fifty-three years.

Both epiphyseal separations and fractures at this point are occasioned, in most cases, by direct blows or falls upon the shoulder.

Of thirty-one examples in which I find the cause recorded, twenty-two were from direct blows, eight from indirect blows, and one from muscular action, as in throwing a ball. Of the eight resulting from indirect blows, one was from a fall upon the hand, seen by Desault, and seven were from falls upon the elbow, of which two were seen by Desault, and five by myself.

Pathology.—I have found the fragments sensibly displaced in twelve cases out of seventeen; a proportion much greater than has been observed by Malgaigne, who has only seen a displacement twice in more than twenty cases. It is certain, however, that complete or sensible displacement is less common in this fracture than in most other fractures, the broken ends being retained in place, probably, by the long tendon of the biceps and the long head of the triceps. As to the direction of the displacement, I have generally found the upper end of the lower fragment drawn forward and upward toward the coracoid process; in one of which examples the upper fragment plainly followed the same direction.

Sir Astley Cooper declares that with infants this direction is constant, and in museum specimens I have seen but one exception. In the specimens of fracture of the surgical neck, with also displacement of the head, belonging to Dr. Pope, this direction of the fragments is plainly seen, as also in one of the specimens belonging to Dr. Neill, of the Pennsylvania Medical College, where the lower fragment almost reaches the coracoid process, and in a specimen contained in one of the cabinets of the University of Pennsylvania, where the upper end of the lower fragment has become united by bone to the coracoid process. The only exception which I have met with is in the possession of Dr. Neill. In this example the two ends are tilted toward the axilla. I am compelled, therefore, to doubt the accuracy of Malgaigne's observations, who thinks he has seen the lower fragment most often drawn toward the axilla, as well as the observations of those who think that the upper fragment is generally displaced outward; yet, no doubt, they do sometimes assume this position. Desault has seen them both thrown backward; while Dupuytren, Paletta, and others have seen them pushed outward; and I have in my collection the copy of a specimen in which both fragments are drawn outward, but the lower fragment is to the inner side of the upper.

When the fracture occurs at or near the epiphysis, it is sometimes accompanied with impaction, of the same character as we have already described when speaking of fractures through the tubercles.

Robert Smith has given, in his treatise, an engraving intended to illustrate the relative position of the fragments in extra-capsular impacted fractures, and the line of separation very nearly corresponds to the line of junction of the epiphysis with the shaft. But in a majority of cases no impaction occurs. Dr. Charles A. Pope, of St. Louis, Mo., has two specimens of this kind, in which no

union has taken place, nor is there any evidence that impaction had ever occurred. In one case the line of fracture commences at the junction of the head with the shaft, and extends thence irregularly across to a point half an inch below the greater tuberosity. In the second specimen the fracture commences at the same point, and terminates three-quarters of an inch below the greater tuberosity. In relation to these bones, Dr. Pope remarks: "These are not cases of detachment of the epiphyses, as the bones are evidently those of adults, and there is, at their lower extremities above the condyles, no trace of an epiphyseal line."

Prognosis.—Sixteen of the cases of fracture of the surgical neck recorded by me are known to have resulted in perfect limbs; that is to say, there is no displacement, overlapping, or shortening, and the patients have recovered the free use of the limbs. These were all, probably, examples in which no displacement ever occurred. Of the remainder, all, so far as I have been able to determine, have united with some displacement; but in nearly all the functions of the limb have been fully or almost fully restored. The only exception I can recall is the single one in which no bony union ever took place.

[**Fracture, with Dislocation of the Head.**—This rare complication is considered in connection with dislocations of the humerus.]

Differential Diagnosis of Accidents about the Shoulder-joint.—The difficulty of diagnosis in the case of accidents about the shoulder-joint has been constantly recognized by surgeons—difficulties which have sometimes rendered diagnosis impossible. A dislocation at the shoulder-joint is the type with which the other accidents may be compared.

a. Signs of a Dislocation. (*Cause*, generally a fall upon the elbow or hand, yet not very unfrequently a direct blow.)

1. Preternatural immobility.

2. Absence of crepitus.

3. When the bone is brought to its place, it will usually remain without the employment of force.

These three are common signs, which apply to any other joint as well as to the shoulder.

4. Inability to place the hand upon the opposite shoulder, or have it placed there by an assistant, while at the same time the elbow touches the breast. This is a sign common to all of the dislocations of the shoulder.¹

The following are special signs, or such as belong only to particular dislocations of the shoulder:

5. Depression under the acromion process; always greatest underneath the outer extremity, but more or less in front or behind, according as the dislocation may be into the axilla, forward or backward.

6. Round, smooth head of the bone sometimes felt in its new situation, and very plainly removed from its socket; moving with the shaft. Absence of the head of the bone from the socket.

7. Elbow carried outward, and in certain cases forward or backward, and not easily pressed to the side of the body.

8. Arm lengthened in the subcoracoid and subglenoid dislocations; and only shortened in the subclavicular and subspinous. Occasionally, in old cases, the head of the humerus, leaving the subglenoid position, becomes subscapular, being placed upon the centre of the scapula, and the arm is shortened.

¹ Report on a New Principle of Diagnosis in Dislocations of the Shoulder-joint, by L. A. Dugas, Prof. of Surgery in the Medical College of Georgia. Trans. Amer. Med. Assoc., vol. x. p. 175.

b. Signs of a Fracture of the Neck of the Scapula. (*Cause*, generally a direct blow; exceedingly rare.)

1. Preternatural mobility.
2. Crepitus generally detected by placing the finger on the coracoid process, and the opposite hand upon the back of the scapula, while the head of the humerus is pushed outward and rotated.
3. When reduced, it will not remain in place.
4. The hand may generally, but with difficulty, be placed upon the opposite shoulder, with the elbow resting upon the front of the chest.
5. Depression under the acromion process, but not so marked as in dislocation.
6. Head of the bone may be felt in the axilla, but less distinctly than in dislocation. Never much forward or backward. Head of the bone moves with the shaft. Head of the bone not to be felt under the acromion process, although it has not left its socket.
7. Elbow carried a little outward, but not so much as in dislocation. Easily brought against the side of the body.
8. Arm lengthened.
9. The coracoid process carried a little toward the sternum, and downward.
10. Pressing upon the coracoid process, it is found to be movable, and it is also observed that it obeys the motions of the arm.

c. Signs of a Fracture of the Lower or Anterior Lip of the Glenoid Cavity. Not yet fully determined.

d. Signs of Fracture of the Anatomical Neck of the Humerus. Intra-capsular. (*Cause*, a direct blow; generally opening to the joint, but not always.)

1. Mobility not increased, nor diminished.
2. Crepitus, generally discovered by pressing up the head of the bone into its socket and rotating; or, when the tubercles are also broken, by grasping the tubercles and rotating the arm.
3. Fragments not generally displaced.
4. The hand can be placed easily upon the opposite shoulder, with the elbow against the front of the chest.
5. Very slight, if any, depression under the acromion process.
6. Head of the bone generally in its socket, but not felt so distinctly as before the fracture.
7. Elbow falls easily against the side of the body, or is easily placed there.
8. Arm not lengthened, nor appreciably shortened, unless the head be driven so much into the body as to separate the tubercles.
9. In this latter case there are present also the signs of fracture of the tubercles.

e. Signs of Fracture of the Humerus through the Tubercles. Extra-capsular. (*Cause*, direct blows.)

The signs which characterize this accident are more obscure than in either of the other shoulder accidents. They are mostly negative, and will not generally be determined positively except in the autopsy.

1. Generally, there is neither marked mobility nor immobility, except what immobility may be due to a contraction of the muscles.
2. Crepitus, discovered, but not so easily as in intracapsular fractures, by rotating the arm while the tubercles are grasped firmly.
3. If displacement exists, the fragments are not always easily kept in place when once reduced.
4. The hand can be placed upon the opposite shoulder, with the elbow against the front of the chest.
5. No depression under the acromion process.
6. Head of the bone in its socket, and moving with the shaft, when, as is usually the case, it is impacted.
7. Elbow hangs against the side of the body.
8. Arm shortened when impacted, but not much.

f. Signs of a Longitudinal Fracture of the Head and Neck, or Splitting off of the Greater Tubercle. (*Cause*, direct blow upon the front of the shoulder.)

1. Mobility of the limb natural.
2. Crepitus; elicited especially by grasping the tubercles and rotating the arm, or by carrying it up and back, and then rotating.
3. When reduced, the fragments will not remain in place.
4. The hand can be placed upon the opposite shoulder, while the elbow rests against the front of the chest.
5. Some depression under the acromion process.
6. A smooth bony projection directly underneath the coracoid process, or close upon its inner or outer side, moving with the shaft. The head of the bone cannot be felt in the socket, yet the space under the acromion is not entirely unoccupied.
7. Generally, but not always, the elbow hangs against the side. Sometimes it inclines a little backward. It can always be easily brought to the side.
8. Arm generally neither lengthened nor shortened.
9. A remarkable increase in the antero-posterior diameter of the upper end of the bone.
10. A deep vertical sulcus between the tubercles, corresponding with the upper part of the bicipital groove.

g. Signs of a Fracture through the Surgical Neck. (*Cause*, generally direct blows, but in old persons frequently a fall upon the elbow.)

1. Preternatural mobility often, but not constantly, present.
2. Crepitus, produced easily when there is no impaction, or when the displacement is not complete, but with difficulty when impaction exists or the displacement is complete.
3. When once the fragments have been displaced, it is exceedingly difficult ever afterward to maintain them in place.
4. The hand can be easily placed upon the opposite shoulder, while the elbow rests against the front of the chest.
5. A slight depression below the acromion, not immediately underneath its extremity, but an inch or more below.
6. Head of the bone in the socket, and moving with the shaft when impacted, but not moving with the shaft when not impacted. The upper end of the lower fragment being often felt distinctly pressing upward toward the coracoid process; its broken extremity being easily distinguished by its irregularity from the head of the bone.
7. Elbow hanging against the side when the fragments are not displaced, but away from the side when displacement exists.
8. Length of arm unchanged unless the fragments are impacted or overlapped; or both fragments are much tilted inward. If the fragments are completely displaced, the arm is shortened.

h. Signs of a Separation of the Epiphysis. (*Cause*, direct blows.)

1. Preternatural mobility,
2. Feeble crepitus; less rough than the crepitus produced when broken bones are rubbed against each other.
3. Fragments replaced are not easily maintained in place, unless the reduction has been effected by Moore's method.
4. Same as in preceding variety of fracture.
5. The depression is not immediately under the acromion, yet higher than in most fractures of the surgical neck, perhaps one inch below the acromion process.
6. Head of the bone in its socket, and not moving with the shaft. Upper end of lower fragment projecting in front, when displacement exists, and feeling less sharp and angular than in case of a broken bone; indeed, being slightly convex and rather smooth, it may easily be mistaken for the head of the bone.
7. Same as preceding variety.
8. Length of arm not changed unless the fragments are overlapped, or both fragments are tilted upon each other. When the fragments are overlapped, the arm is shortened.
9. This accident is peculiar to the young. It can seldom occur after the twentieth year.

Treatment.—I have already spoken of the treatment of fractures of the neck of the scapula, and my remarks will now be confined to fractures of the upper end of the humerus.

Treatment of Intracapsular Fractures of the Neck.—As has been stated, these are generally compound fractures, and, from the extent of the injury, often demand resection, or amputation of the entire arm. If an effort is made to save the arm, splints will not be applied, and the treatment will have little or no reference to the existence of a fracture; it will be directed only to the reduction or prevention of the inflammation, etc. Simple fracture of the anatomical neck, if not entirely within the capsule, without any external wound communicating with the joint, and accompanied, as it is sometimes, with impaction, may unite, or the upper fragment may become incased in the lower. It is not proper in such cases to employ great violence for the purpose of detecting crepitus, lest the fragments should become displaced; and if the arm should be found to be a little shortened, it must not be extended, with a view to overcoming the shortening, since upon the impaction probably depend, in a great measure, the chances of union. The elbow and forearm may be suspended in a sling, while the arm is gently supported against the side, merely to insure quietude. No splints are necessary or useful.

Treatment of Fractures through the Tubercles (Extracapsular); Non-impacted and Impacted.—In these cases, also, the fragments being seldom displaced, very little, if any, mechanical treatment is demanded. A sling is all that is usually required. If, however, on account of displacement of the fragment, a splint is thought necessary, it must be applied in the manner hereafter to be directed in cases of fractures of the surgical neck. If impaction, with shortening, exists, the same remarks are applicable here as in intracapsular impacted fractures, namely, that we ought not to rotate the limb much, nor violently, in order to discover crepitus, nor make extension with the view of overcoming the shortening, since the fragments unite more promptly and certainly when the impaction remains, and its continuance in no way damages the usefulness of the limb.

Treatment of Longitudinal Fracture of the Head and Neck, or of a Separation of the Greater Tubercle.—In the only instance which I have recognized as a fracture of the greater tubercle, and already referred to, the displacement was moderate, and could not be overcome either by change of position or by pressure with extension. The patient was, therefore, merely laid upon his back in bed. No dressings of any kind were employed, and the fragments seemed to unite promptly, and with no increase in the displacement. If the displacement is originally more considerable, attempts ought to be made to reduce the fragments, by extension and abduction of the arm, with direct pressure; yet they will not generally prove completely successful, nor will it be found easy to retain them when reduced.

Treatment of Fractures of the Surgical Neck, including Separations at the Epiphysis.—We have already considered the value of Moore's method of reduction in cases of incomplete epiphyseal separations of the upper end of the humerus; but the reduction having been accomplished, I see no reason to suppose that the indications of treatment can essen-

tially vary in separations at the epiphysis from those in true fractures through any part of the surgical neck, since the relative action of the muscles remains the same, and the direction of the displacement is generally the same. My remarks, therefore, upon this point may be considered as equally applicable to fractures and epiphysary separations. In a considerable proportion of these cases not much displacement of either fragment takes place, and consequently we have only to apply such moderate retentive means as will insure quiet. Indeed, under such circumstances we might not hesitate to adopt the posture treatment practised by Dupuytren in two cases, both of which terminated favorably. The treatment consisted in placing the arm, semi-flexed, on a pillow, the pillow being arranged so as to form a pyramid, the summit of which was lodged in the axilla, while the elbow was secured to the side of the body by a bandage.¹

Unhappily, however, as we have seen, this condition is not always present; the most frequent form of displacement being that in which the lower fragment is drawn upward and inward, or toward the coracoid process. In such cases it will require, often, no little perseverance and skill to effect reduction, if it is not found to be actually impossible, and still more to retain the bones in place when once reduced. Indeed, it is proper to say that a complete reduction is seldom accomplished and permanently maintained, owing, probably, to the advantageous action of the muscles which tend to produce the displacement, and in part also to the difficulty of applying any apparatus or dressing which shall act efficiently upon the fragments.

Sir Astley Cooper recommends for this accident a couple of splints, to be placed one in front of and one behind the shoulder, an axillary pad, a clavicular bandage, and a sling; the sling being made to suspend only the wrist, and not the elbow, since he had observed that when the elbow was lifted the upper end of the shaft was inclined to fall forward.

Mr. Tyrrel informed Mr. Cooper that in a similar case he had found the bone best maintained in its natural position by its being raised and supported at right angles with the side, by a rectangular splint, a part of which rested against the side, while the arm reposed upon the other part; and until he had made use of this plan, he could not succeed in removing the deformity, or in keeping the bone in its place.


The following is the plan which I have myself generally preferred:

Two splints are prepared, made of felt, gutta-percha, gum-shellac cloth, or leather. The two latter are the most economical, generally most easily obtained, and answer the purpose as well as either of the others. The leather to be employed should be sole leather, of medium thickness, and hemlock-tanned. The "long" splint must be long enough to extend from the top of the acromion process to a point just above the external condyle. The form of the leather splint, before it is moulded, is represented in the accompanying woodcut, Fig. 108. It is then to be bevelled or thinned along its edges by shaving a thin ribbon from the margins on the side which is to be laid against the arm; a few holes are to be made with a brad-awl on the margins of the V-shaped section at the upper end. Having soaked the splint in water a few minutes, or

¹ Dupuytren on Bones, Sydenham edition, p. 99.


until it is rendered slightly flexible, it is rolled up from its two sides until it has the natural curve of the circumference of the arm. If it is made too wet it will yield under the pressure of the bandages, and this is not desirable. It ought to be straight, or nearly so, in its longitudinal axis, except at the top, where it embraces the end of the shoulder; and

FIG. 108.




Plan of author's long leather arm-splint.

FIG. 109.



Long leather splint closed at top, and in shape.

FIG. 110.



Short splint.

it should be inflexible when applied, the splint touching the arm firmly only over the head and tuberosities, and along the lower portion of the humerus. The V-shaped section at the top of the splint is then closed with strong linen, or shoemaker's thread; and in order to give it a more regular curve, and to render it smooth, it may be hammered.

Some of the splints which surgeons prepare, in imitation of this general plan, extend too far upon the shoulder, and are liable to be disturbed in the motions of the neck or of the arm. It is only necessary that the splint should embrace the shoulder sufficiently to prevent its sliding down. The splint will now be completed by inclosing it in a loose flannel sack, stitched on the outside. If the arm is swollen and tender, or the skin very delicate, a thin sheet of cotton wadding should be laid between the cover and splint.

The "short" splint made of leather, or gum-shellac cloth—binders' board will answer equally well—carefully trimmed, and covered with flannel cloth, must have sufficient length to extend from the free margin of the axilla to the internal condyle, taking care that it shall not touch either. The purpose of this splint is not to support the fragments, for it is apparent that it cannot extend so high, even, as the point of fracture; but it is solely to protect the delicate skin beneath the arm from the bandages, which are apt to form cords and cause excoriations. In this point of view it is of great importance, and cannot properly be omitted. The splints being laid upon the arm, and while extension and counter-extension are maintained by assistants, for the purpose of restoring the fragments to position if possible, the surgeon will apply a roller, inclosing the splints, from the elbow to the axillary margins. This roller must be carefully stitched to the covers of both splints. A second roller

is then carried from the top of the long splint to the opposite axilla, and by several successive turns the upper end of the splint and the shoulder are completely covered in. This is also to be made fast to the cover of the long splint, by stitches. Finally, a third roller is made to inclose both the body and the lower portion of the arm; and the forearm is secured at a right angle with the arm by a sling, looped under the forearm. It is important that the sling shall not embrace the elbow, since it will, if thus applied, tend to displace the fragments and drive them past each other.

The bandage or roller hitherto applied by surgeons to the hand and forearm, when dressing a broken humerus, is wholly unnecessary and often a source of annoyance. The roller inclosing the arm and splints will seldom give rise to serious congestion or swelling of the forearm and hand unless it is applied too tightly; and when swelling does occur it will be promptly relieved by a few hours' or days' confinement in the horizontal position. The most serious objection, however, to the roller applied to the hand and forearm, is not that it is unnecessary, but that it is, in most cases, injurious. It is exceedingly liable to become disarranged, especially if the patient is permitted to move the arm at the elbow-joint; and in most cases it will soon be found, by its unequal pressure, to cause those congestions and swellings which it was designed to prevent. Perhaps it will be sufficient for me to say that for many years I have rejected this bandage altogether in all fractures of the humerus, and that no harm has ever come of the practice.

It will be readily seen that the first roller performs the most important function in this dressing. The long outer splint being firm and unyielding, and being supported above by the projection of the head of the humerus, the first roller draws the upper end of the lower fragment outward, and thus, as far as possible, accomplishes its readjustment. The upper fragment is always beyond our control. The second roller is not of much use, inasmuch as it soon becomes loose; and in any event it can only hold the top of the splint a little more firmly against the head of the humerus. I occasionally omit it. The third roller insures quietude to the arm, in the best position, namely, beside the body.

FIG. 111.



Apparatus for fracture of the neck of the humerus. (Erichsen.)

When the patient is standing or sitting, the forearm needs to be suspended in the sling; but when reclining, the forearm may, if the patient chooses, be extended. If the entire dressing is well stitched, it is not much liable to disarrangement, and may be worn two or three weeks at a time without removal; but from time to time, as the swelling subsides or the muscles atrophy, the bandages may need to be tightened by over stitching, or by supplementary rollers.

I have been thus minute in my description of this dressing, because its value depends upon the care with which the details are carried out; and because, essentially, the same dressing is used by me in all fractures of the humerus occurring through its upper or middle thirds; moreover, I

do not wish to be held responsible, in any case, for bad results when dressings are applied in an imperfect or slovenly manner.

[Erichsen describes a very useful dressing, consisting of a pad on the inner side of the arm, and a leather splint on the outside and over the shoulder; the hand being supported in a sling, while the elbow remains dependent.]

If union takes place without overlapping, of course the arm is not maimed by the fracture; but even when the union occurs with considerable overlapping, the usefulness of the arm is seldom impaired. In case the functions of the arm are seriously impaired in consequence of the displacement of the fragments, and many months or years have elapsed without any improvement, a result which, to say the least, is very uncommon, the surgeon might consider the propriety of surgical interference, after the method of Lindner, who cut down and reduced the fracture, with the result of only a partial reduction, with fibrous union, but it is added, that the functions of the arm were restored. It is my opinion, however, that the discreet surgeon will not find satisfactory reasons for such a procedure.¹

§ 5. Shaft, below the Surgical Neck and above the Base of the Condyles.

Causes.—In a record of 36 cases in which the cause of the fracture is stated, I find this portion of the shaft broken from direct violence 21 times; from indirect blows, the concussion being received upon the elbow, 9 times; twice it was a consequence of syphilis, once it occurred during birth, and three times in the same patient it has been broken from muscular action alone, each consecutive fracture occurring at a different point. The records of surgery furnish many examples of fracture of the shaft of the humerus from muscular action, as in throwing a stone or snowball.

The most singular examples are those in which the bone has been broken in a trial of strength between two persons, by grasping the hands palm to palm, with the elbows resting upon a table, and twisting, when the humerus has suddenly given way a little above the condyles. This practice is called by the French "*tourner poignet*," the game of turning wrists. I have seen one case of this kind, which was under the care of Dr. Winne, and Malgaigne has collected five other similar cases, two of which were reported by Lonsdale. In *L'Union Médicale* is reported an example in which the fracture occurred on a level with the insertion of the deltoid, a little below the insertion of the pectoralis major and latissimus dorsi. The fracture seemed to be nearly transverse.²

[Lebeuf,³ of Houma, La., reports a case of double fracture of the same humerus in throwing a ball; both were in the shaft.]

The example of fracture during birth, to which I have referred, occurred in a healthy female child, whose parents were also healthy. The mother was in labor six or eight hours, but the labor was not severe. She was attended by a midwife, but does not know whether violence was employed or not. Dr. Lockwood, of Buffalo, was called on the third day, and found the arm broken a little below its middle, and moving as freely as it did at the elbow-joint; he applied lateral splints with bandages, etc. I saw the child with Dr. Lockwood on the seventeenth day after its birth. There was then a perfect ferrule of ensheathing callus surrounding the fragments, and which, owing to the softness of the flesh, could be easily detected and defined. The fragments had been firm at least three or four days. Nearly a year after, I again examined the arm, and could not discover any traces of the accident.

Dr. Löwenhardt has also reported a case in which the evidence was conclusive that the fracture was caused solely by the contractions of the uterus, which forced the arm against the pubes; the arm being heard distinctly to snap when it was passing this point and while the hands of the accoucheur were not aiding in the delivery. In this case the humerus was broken in its upper third.⁴

¹ Lindner, *Centralblatt für Chir.*, 1881, April 16.

² *Amer. Med. Times*, vol. iv. p. 153.

³ *N. O. Med. and Surg. Journ.*, Feb. 1888.

⁴ Löwenhardt, *American Journal of the Medical Sciences*, January, 1841, p. 250, from *Medicin. Zeit.*, Mai 6, 1840.

Dr. N. Fanning, of Catskill, N. Y., has reported to me the following as having occurred in his own practice: "Mrs. H. was delivered, after a short and not severe labor, of a full-grown and healthy male child. The mother was well formed, with ample pelvis. The labor was natural, and the presentation the most favorable, the occiput corresponding to the left acetabulum; but immediately after the delivery of the head, a hand and a portion of the forearm of the child were felt above the pubes. The shoulders and body were delivered very quickly after the head, and during a single pain. Just as the right shoulder of the child was passing under the arch of the pubes, I heard a snap, not unlike that caused by the breaking of a pipe-stem, which I soon found, as I suspected, to be caused by the fracture of the right os humeri of the child in its upper third." The bone united with some deformity. Dr. Fanning is of the opinion that, in this case, the contraction of the uterus, occurring while the arm of the child occupied some unusual position, was the cause of the fracture.

Seat and Direction of the Fracture.—The seat of the fracture is more often below than above the middle of the bone; thus, I have found the fracture fourteen times near the middle, and the same number of times below the middle third, but only seven times above the middle third. The observations of Norris, who found four fractures of the shaft above the middle, and nine below, correspond with my own;¹ but M. Guéretin, in the same number of fractures, found nine above the middle and four below.² The line of fracture is generally oblique, but more often transverse than in fractures of the clavicle, femur, or tibia.

Displacement.—The direction of the displacement depends, no doubt, sometimes upon the precise point of the fracture and upon the action of the muscles operating upon the two fragments; thus, if the fracture takes place just above the insertion of the deltoid, the lower fragment is liable to be drawn upward and outward, in the direction of its fibres, while the upper fragment is carried toward the origin of the pectoralis major, etc.; but, in a great majority of cases, the influence of these muscles is more than counterbalanced by the direction of the force, and by the direction of the fracture. Practically, therefore, it is seldom of much importance to determine the exact point of fracture, as to whether it is just above or below the insertion of a particular muscle; nor, indeed, is it generally very easy to ascertain this point with much precision.

The amount of displacement varies considerably in different persons and in fractures at different points, but it will average about three-quarters of an inch. When the fracture is produced by muscular action alone, it is generally transverse, and displacement seldom occurs. Such was the fact in every instance where my own patient broke the arm three times consecutively at different points; and union was speedily accomplished, and with no deformity.

Dupuytren, however, saw a case which constituted an exception to this general rule. The fragments became completely separated, and were so movable that union could not be effected, and he was compelled, after three months, to resort to resection.

The average shortening after these fractures, exclusive of those which do not shorten at all, seems to be about half an inch; but a considerable

¹ Norris, Amer. Journ. Med. Sci., Jan. 1842, vol. xix. p. 28.

² Presse Médicale, vol. i. p. 45.

number are never displaced, as the fractures are so nearly transverse that they are easily reduced and maintained in place, and consequently the total average of shortening is probably less than half an inch; in a few cases it is much greater. Practically, the shortening is a matter of no importance.

Prognosis.—I have met with a number of examples of delayed and of fibrous union of this bone after a fracture.

In the first example of a complete failure the fracture was in the lower third of the shaft, oblique and compound, and no union had taken place at the end of five months. The man was intemperate, but in pretty good health.¹ In the second case, the fracture had occurred a little below the middle of the bone, and it was simple. Five months after the accident this patient consulted me, when I found the elbow ankylosed, and the forearm was fixed at a right angle.² In the third case, a lad, five years of age, received a fracture about three or four inches above the elbow-joint, by the passage across the limb of a heavy army wagon. The arm was dressed with splints, and in about five weeks several fragments of necrosed bone were removed by Dr. Pope, of St. Louis, and the splints were again applied. Ten months from the date of the injury, Dr. Brinton, of Philadelphia, operated by perforation, and reapplied splints. When the splints were removed, the limb was straight and apparently firm, but the bond of union gradually gave way, and when he came under my charge, more than two years after the accident, the arm was bent at an angle of 45°, and the union was fibrous only. Under my advice all restraint and dressings were removed, and he was sent into the country to improve his general health, with the understanding that I would operate at some future day. Subsequently, I resected the bone at the seat of fracture, securing the fragments with wire, and supporting the arm with a gutta-percha splint. The result was a perfect bony union. The fourth case is briefly as follows: C. C., æt. about thirty-five, broke his right arm a little below its middle; the fragments united only by fibrous tissue. Five months after, I incised to the bone, and with an ordinary steel gimlet trans-fixed the overlapping fragments. Splints were then applied. The gimlet was permitted to remain six weeks, during which time it became quite loose, and an abscess formed below the wound. At the end of this time the bond of union was quite firm, but the splints were continued six weeks longer. The union remains sound, the humerus is straight, and the usefulness of his arm perfect. In a fifth case, that of F. H. F., æt. twenty-one, the right arm was broken below its middle, a simple fracture; pasteboard and wooden angular splints were employed, but only a fibrous union took place. Eight months after the accident the fragments remained ununited, and overlapped one inch.

Muhlenberg, in his tables of delayed union and ununited fractures of long bones, including 656 cases, has recorded 219 of the humerus: of 13 treated by manual friction, 4 were cured and 9 failed; of 10 treated by mechanical appliances, 6 were cured, 3 relieved, and 1 failed; of 42 treated by seton, 12 were cured, 24 failed, and 1 died; of 13 treated by immobilization, 5 were cured, 6 failed, and 1 died; of 83 treated by resection, 43 were cured, 31 failed, 6 were relieved, 2 died, and in 1 the result is unknown; of 35 treated by drilling, 21 were cured, 2 were relieved, and 11 failed.

In a few cases the elbow has remained somewhat stiff a long time after the splints were removed; and in one case which was brought to my notice complete freedom of motion was not restored at the end of fifteen years. Generally, however, the motions of the elbow-joint have been very soon restored after the removal of the splints and sling. Not unfrequently, fractures of the shaft of the humerus, and especially where

¹ Report on Deformities, etc., Case 33.

² Ibid., Case 21.

they are occasioned by direct blows, are followed by great swelling, and sometimes by abscesses.

In one instance, the fracture having taken place within the insertion of the deltoid muscle, the sharp extremity of the lower fragment was made to penetrate the flesh, causing an abscess, and finally tetanus, of which my patient soon died. Dr. Lee writes me that a simple fracture of the lower third of the shaft, occurring in a child six years old, terminated in gangrene, and demanded amputation. Two other similar cases have been reported to me. In all of these cases a question arose as to the causes of the gangrene; but the practice of the surgeons was sustained by the courts.

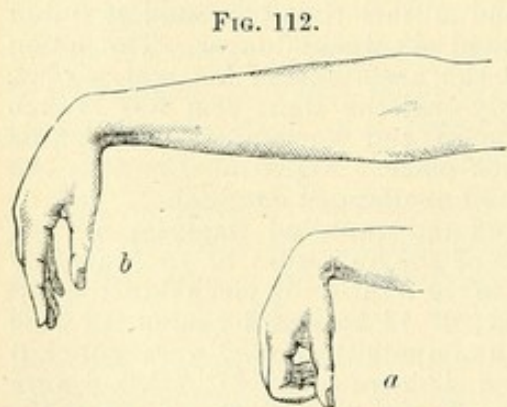
P. F., æt. twenty-one, was admitted to Bellevue, with a fracture of the left humerus, near its middle. The fracture was caused by a fall from a wagon on the same day. My splint was applied, and it was continued four weeks, when the fragments were found united, but he was discovered to have paralysis of the extensor muscles of the left hand and fingers. Two or three months later their condition had much improved. The arm was perfectly straight. The bandage was never tight, and the cause of the paralysis was unexplained.

Muhlenberg, in his tables of united fractures, has recorded 219 of the humerus, in a total of 656 of all of the long bones.

The following remarks of Malgaigne are too pertinent to be omitted in this connection: "When there is great obliquity, with overlapping, or a fracture with splintering, or a multiple fracture, a certain amount of deformity is inevitable, and the formation of callus demands one or two weeks more. With the inflammation comes also the danger of suppuration, and later, a rigidity of the articulations difficult to dissipate. In short, we must not forget that of all fractures, those of the humerus are most liable to fail of consolidation."

On the other hand, we shall find, in the case of this bone, as in all others, some remarkable exceptions, where, although the fracture may be compound, and badly comminuted, yet the limb has been saved and made useful.

[Erichsen notices, as a complication, injury of the musculo-spinal nerve when the fracture is at the point where this nerve winds around the shaft; also, injury of the posterior branch (interosseous) when the fracture is lower down. When the main trunk is involved, all the muscles supplied by it are paralyzed, supination is imperfect, and extension of the hand and fingers is entirely lost; the forearm becomes pronated and the hand and fingers passively flaccid, so that a form of wrist-drop ensues (Fig. 112). Though the extensors of the wrist and fingers have become paralyzed, yet when the fingers are flexed (*a*), they can be extended rapidly and with some force at the interphalangeal articulations (*b*). If the posterior interosseous nerve only is involved, the loss of supination and extension is necessarily not so complete as when the whole trunk is involved. It is important to recognize these forms of paralysis caused by the injury or by the



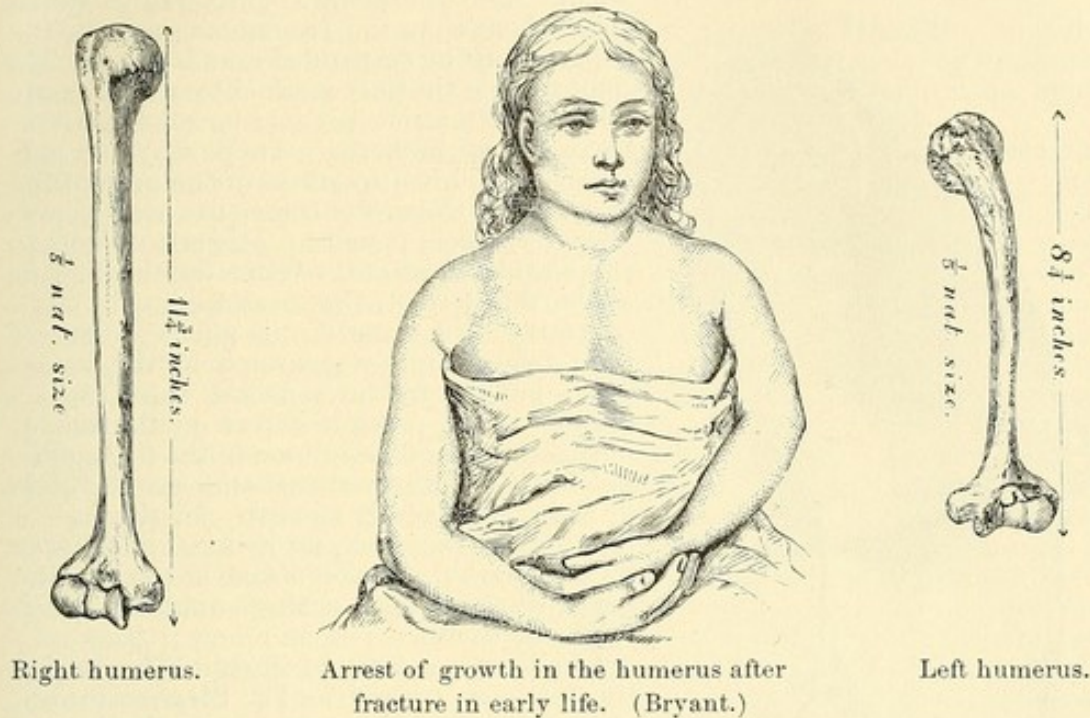
Paralysis of hand (Wrist-drop), after fracture of humerus. (Erichsen).

pressure of callus, as they are liable to be attributed to the dressings. The treatment of paralysis from injury must be directed, first, to relief to the inflammation, and, second, to efforts to secure motion by massage. The false position of the hand and fingers may be overcome by apparatus, as splints. If the paralysis is due to encroachment of callus, this may be removed by operation.]

[Another sequel of fracture of the humerus has been noticed by Bryant, of London, viz., arrest of growth. This condition is liable to be attributed to the treatment. In the two cases which he mentions one is alleged to be due to an

injury to the nutrient artery, and the other to injury to the epiphyseal cartilage at the upper part of the shaft.]

FIG. 113.



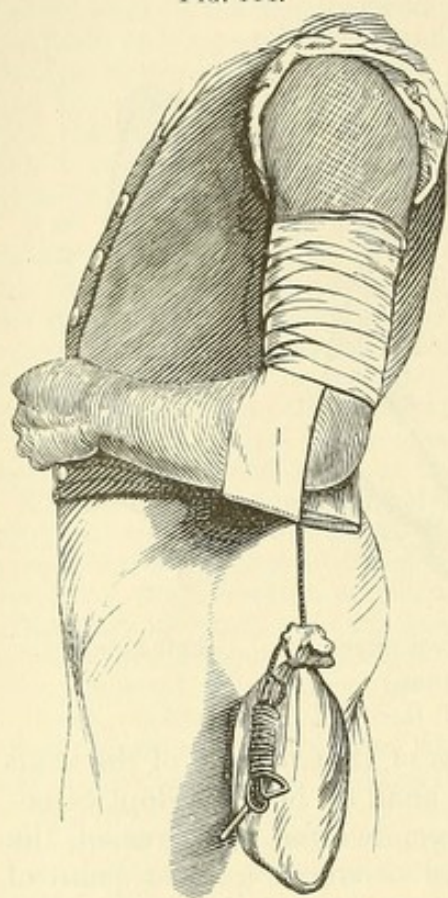
Treatment.—In the treatment of fractures of that portion of the shaft of the humerus now under consideration, we shall do best to adopt essentially the same plan which I have recommended for fractures of the surgical neck. In proportion as the fracture occurs at a lower point of the humerus, however, will it be necessary to extend the long splint downward, in the direction of the elbow; so that, while in fractures of the surgical neck and upper half of the shaft it may not be necessary to extend the splint quite so low as the external condyle, in the case of fractures in the lower half of the shaft it will be necessary to include the condyles with the splints, and sometimes it may be necessary to employ the gutta-percha angular splint, which will be recommended hereafter in fractures involving the elbow-joint. It is in these latter cases, also, that we shall find, sometimes, the plaster-of-Paris dressing, including the forearm, arm, and shoulder, giving the most satisfactory results; never neglecting, however, when using this or any other form of immovable dressing, to observe the condition of the arm frequently as to the swelling or shrinkage. Whenever the splints are made to touch or include the condyles, very great care must be taken to protect them from pressure.

Other surgeons have sought to make permanent extension in these and certain other fractures of the humerus, by various contrivances. Mr. Lonsdale constructed an instrument which might be lengthened or shortened to suit the case. Dr. Martin, of Boston, has invented a splint for the purpose of making extension in fractures of the humerus, the counter-extension being made by adhesive plasters from the side of the chest. The apparatus is elongated by a ratchet operating upon two steel bars, which are thus made to move upon each other. In my opinion, and in the opinion of nearly all practical surgeons who have written upon this subject, it is impossible by these or any other similar contriv-

ances to make extension in fractures of the humerus. The axilla can never be made a proper point of support for permanent counter-extension.

The late Dr. E. A. Clark, of the St. Louis City Hospital, proposed to accomplish the extension, in fractures of the head and surgical neck, by suspending a

FIG. 114.



Clark's extension in fractures of the neck of the humerus.


fast to the hand and forearm, and the pulley and weight being arranged at the foot of the bed.

weight from the elbow. (Fig. 114.) When the patient is in the recumbent posture, the weight must be suspended over a pulley. No doubt this is the only method by which really effective extension can ever be made in fractures of the humerus. There may be, perhaps, examples of fractures of the neck of the humerus in which the fragments overlap persistently, where it will be proper to resort to this novel expedient. When fractures occur above the deltoid, the overlapping is often excessive, and there is not much danger of their being forcibly separated by the extension; but in fractures below this, Clark's method might possibly expose to the danger of separation and non-union of the fragments, but it will be observed that this was the class of cases successfully treated. In the case of fractures of the neck, no splints are advised by Dr. Clark; yet, as a means of holding the lower fragment out, a single outside splint might be useful.

I have seen a case of compound fracture of the humerus treated by Dr. Stephen Smith, at Bellevue, in this manner, while the patient was confined to the bed, with the most satisfactory results; and recently, in a case of fracture of the humerus a little above the middle, complicated with other severe injuries, which eventually proved fatal, this method of extension was employed successfully by me, to prevent the violent spasmodic contractions of the muscles. In this case the arm and forearm were kept extended, the adhesive plaster extension strips being made

In reference to those forms of apparatus which are intended to press upon the axillary margins, it ought to be stated here, since we have omitted to speak of it in connection with fractures of the surgical neck, that in all fractures of the upper half or third of the humerus, including fractures of the surgical neck, they are not only useless, but they actually tend to defeat their own purpose. They are intended to replace the fragments; but by their pressure upon the pectoralis major and latissimus dorsi, which compose the free margins of the axillary space, they must inevitably cause the separation of the fragments.

FIG. 115.



Erichsen's sole-leather splint.

[The application of a narrow pad to the internal surface of the humerus at its upper part is useful in supporting the fragments, and to prevent their falling

inward; the pad should not be so broad as to press on the latissimus and pectoralis major. Erichsen uses in some cases a piece of sole-leather, two feet long by six inches broad, bent in the middle and applied so that one half is lengthwise against the chest and the other against the inside of the arm, the angle being in the axilla (Fig. 115).]

Malgaigne, when speaking of the apparatus of Lonsdale, remarks: "But the surgeon should never lose sight of the fact that permanent extension is a resource always dangerous, often useless, and which demands in its application much caution and watchfulness."

The following example will illustrate the practical difficulty of employing permanent extension in fractures of the humerus: A laborer, aged thirty, was admitted into the Buffalo Hospital of the Sisters of Charity with a simple oblique fracture of the humerus, which had occurred three days before. The fracture was situated within the insertion of the deltoid, and having been produced by the rolling of a log upon the arm, the whole limb was much swollen. The night following his admission, in a fit of delirium tremens, he removed all of the dressings. In the morning I found the fragments displaced and the muscles contracting violently. The ordinary dressings were applied, and continued until the fifth day, when, as the delirium had not ceased, and the muscles continued to contract with great violence, it was determined to attempt permanent extension. For this purpose we lifted the elbow upward and outward, to relax the deltoid, and then, having made extension with the forearm placed at a right angle with the arm, we fitted carefully a large gutta-percha splint to the forearm, arm, axilla, and side, in such a manner that when the splint was secured to these several parts, the arm could not fall to the side of the body completely, and in proportion as it did fall downward, it would make extension upon the arm. This splint was well padded, and secured in place by rollers. On the sixth day the delirium had ceased, and never returned. The dressings were well in place, and seemed to accomplish the indication we had in view; but, on the seventh day, although he had kept very quiet, everything was disarranged, and the whole had to be readjusted. On the eighth and ninth days the same thing occurred. During this time we varied the dressings, position, etc., each day, to meet, if possible, the difficulties; but it was at length deemed unwise to pursue the attempt any farther, and we returned to the use of the ordinary splints, laying the arm against the side of the body. The union was finally completed without either overlapping or angular displacement. I have no doubt now that we would have done much better if we had resorted to extension, as practised by Dr. Clark.

Something may always be accomplished when the patient is walking about, by allowing the elbow to escape from the sling, so that its weight shall make constant traction upon the lower fragment; and the plan which I suggested some years since, of treating certain cases of delayed union of the humerus, namely, extending the arm at full length by the side of the body, so that the lower fragment shall receive the whole weight of the forearm and hand, might occasionally prove valuable in recent fractures where the tendency to override was very great.

Delayed Union.—Non-union results more frequently after fractures of the shaft of the humerus, than after fractures of the shaft of any other bone.

Comparing the humerus with the femur, between which, above all others, the circumstances of form, situation, etc., are more nearly parallel, and in both of which non-union is said to be relatively frequent, I find that of forty-nine fractures of the humerus, four occurred through the surgical neck, twelve through the condyles, and twenty-nine through the shaft. In one of the twenty-nine the patient survived the accident only a few days. In four of the remaining twenty-eight union had not occurred after the lapse of six months, and in many more it was delayed beyond the usual time. Two of the four were simple fractures, and occurred near the middle of the humerus; the third was compound, and occurred near the middle also; the fourth was compound, and occurred near the condyles. This analysis supplies us, therefore, with four cases of non-union, from a table of twenty-eight cases of fracture through the shaft.

Of eighty-seven fractures of the femur, twenty occurred through the neck, one through the trochanter major, and one through the condyles. The remaining sixty-five occurred through the shaft, and generally near the middle, and not in one case was the union delayed beyond six months. To make the comparison more complete, I must add that of the twenty-eight fractures of the shaft of the humerus, six were compound; and of the sixty-five fractures of the shaft of the femur, six were either compound, comminuted, or both compound and comminuted. The six compound fractures of the shaft of the humerus furnished two cases of non-union. The six cases of either compound or comminuted or compound and comminuted fractures of the femur, furnished no case of non-union.

The following seems to me to be the true explanation of these facts: It is the universal practice, so far as I know, in dressing fractures of the humerus, to place the forearm at a right angle with the arm. Within a few days, and generally, I think, within a few hours, after the arm and forearm are placed in this position, a rigidity of the muscles and other structures has ensued, and to such a degree that if the splints and sling are completely removed, the elbow will remain flexed and firm; nor will it be easy to straighten it. A temporary false ankylosis has occurred, and instead of motion at the elbow-joint, when the forearm is attempted to be straightened upon the arm, there is only motion at the seat of fracture. It will thus happen that every upward and downward movement of the forearm will inflict motion upon the fracture; and inasmuch as the elbow has become the pivot, the motion at the upper end of the lower fragment will be the greater in proportion to the distance of the fracture from the elbow-joint.

No doubt it is intended that the dressings shall prevent all motion of the forearm upon the arm; but I fear that they cannot always be made to do this. I believe it is never done when the dressing is made without angular splints, nor is it by any means certain that it will be accomplished when such splints are used. The weight of the forearm is such, when placed at a right angle with the arm, and encumbered with splints and bandages, that even when supported by a sling, it settles heavily forward, and compels the arm-dressings to loosen themselves from the arm in front of the point of fracture, and to indent themselves in the skin and flesh behind. By these means the upper end of the lower fragment is tilted forward. If the forearm should continue to drag upon the sling, nothing but a permanent forward displacement would probably result. The bones might unite, yet with a deformity.

But the weight of the forearm under these circumstances is not uniform, nor do I see how it can be made so. It is to the sling that we must trust mainly to accomplish this important indication. But we have all noticed that the tension or relaxation of the sling depends upon the attitude of the body, whether standing or sitting; upon the erection or inclination of the head; upon the motions of the shoulders; and in no inconsiderable degree upon the actions of respiration. Nor does the patient himself cease to add to these conditions by lifting the forearm with his opposite hand whenever provoked to it by a sense of fatigue.

This difficulty of maintaining quiet apposition of the fragments while the arm is in this position, at whatever point it may be broken, becomes more and more serious as we depart from the elbow-joint, and would be

at its maximum at the upper end of the humerus, were it not that here a mass of muscles, investing and adhering to the bone, in some measure obviates the difficulty. Its true maximum is, therefore, near the middle, where there is less muscular investment, and where, on the one hand, the fracture is sufficiently remote from the pivot or fulcrum to have the motion of the upper end of the lower fragment multiplied through a long arm, while, on the other hand, it is sufficiently near the armpit and shoulder to prevent the upper portion of the splint and arm-dressings from obtaining a secure grasp upon the lower end of the upper fragment.

It must not be overlooked that the motion of which we speak belongs exclusively to the lower fragment, and that it is always in the same plane forward and backward, but especially that it is not a motion upon the fracture as upon a pivot, but a motion of one fragment to and from its fellow. This circumstance I regard as important to a right appreciation of the difficulty. Motion alone, I am fully convinced, does not so often prevent union as surgeons have generally believed. It is exceedingly rare to see a case of non-union of the clavicle. Of forty-seven cases of fracture of the clavicle which have come under my observation, and in by far the greater proportion of which considerable overlapping and consequent deformity ensued, only one has resulted in non-union, and in this instance no treatment whatever was practised, but from the time of the accident the patient continued to labor in the fields, and hold the plough as if nothing had occurred. I have, therefore, seen no case of non-union of the clavicle where a surgeon has treated the accident. Indeed, what is most pertinent and remarkable, its union is more speedy, usually, than that of any other bone in the body of the same size. Yet to prevent motion of the fragments in a case of fractured clavicle with complete separation and displacement, except where the fragment is near one of the extremities of the bone, I have always found wholly impracticable. Whatever bandage or apparatus has been applied, I have still seen always that the fragments would move freely upon each other at each act of inspiration and expiration, and at almost every motion of the head, body, or upper extremities.

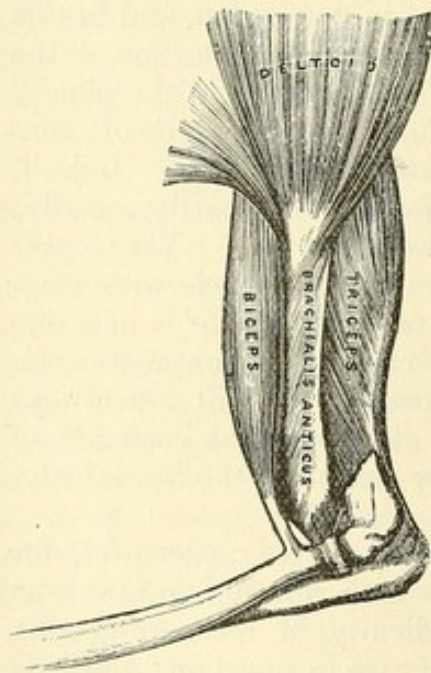
From this and many similar facts I have been led to suspect, for a long time, that motion has had less to do with non-union than was generally believed. I find, however, no difficulty in reconciling this suspicion with my doctrine in reference to the case in question; and it is precisely because, as I have already explained, the motion, in case of a fractured humerus, dressed in the usual manner, is peculiar. In a fracture of the clavicle through its middle third (its usual situation), the motion is upon the point of the fracture as upon a pivot; although, therefore, the motion is almost incessant, it does not essentially, if at all, disturb the adhesive process. The same is true in nearly all other fractures. The fragments move only upon themselves, and not to and from each other. I know of no complete exception but in the case now under consideration.

Aside from any speculation, the facts are easily verified by a personal examination of the patients during the first or second week of treatment, or at any time before union has occurred, both in fractures of the humerus and clavicle. The latter is always sufficiently exposed

to permit you to see what occurs; and as soon as the swelling has a little subsided in the former case, we will have no difficulty in feeling the motion outside of the dressings, or, perhaps, in introducing the finger under the dressings sufficiently far to reach the point of fracture.

I know of no other circumstance or condition in which this bone is peculiar, and which, therefore, might be invoked as an explanation. Overlapping of the bones, the cause assigned by some writers, is not sufficient, since it is not peculiar. The same occurs much oftener, and to a much greater extent, in fractures of the femur, and equally as often in fractures of the clavicle, yet in neither case are these results so frequent. Nor can it be due to the action of the deltoid muscle, or of any other particular muscles about the arm, whether the fracture be below or above their insertions, since similar muscles, with similar attachments, on the femur and on the clavicle, tending always powerfully to the separation of the fragments, occasion deformity, but they seldom prevent union. If I am correct in my views, we shall be able sometimes to consummate union of a fractured humerus where it is delayed, by straight-

FIG. 116.



Fracture at the base of the condyles.
(From Gray.)

ening the forearm upon the arm, and confining them to this position. A straight splint, extending from the top of the shoulder to the hand, constructed from some firm material, and made fast with rollers, will secure the requisite immobility to the fracture. The weight of the forearm and hand will only tend to keep the fragments in place, and if the splint and bandages are sufficiently tight, the motion occasioned by swinging the hand and forearm will be conveyed almost entirely to the shoulder-joint. Very little motion, indeed, can in this posture be communicated to the fragments, and what little is thus communicated is a motion, as experience has elsewhere shown, not disturbing or pernicious, but a motion only upon the ends of the fragments, as upon a pivot.

I do not fail to notice that this position has serious objections, and that it is liable to inconveniences which must always, probably, prevent its being adopted as the usual plan of treatment for fractured arms. It is more inconvenient to get up and lie down, or even to sit down, in this position of the arm, and the hand is liable to swell. But I shall not be surprised to learn that experience will prove these objections to have less weight than we are now disposed to give them.

Measurement.—It may be well to indicate in this place by what method we shall best insure an accurate measurement of the arm or forearm.

In either case, the point from which the measurement can be most satisfactorily made above, is the posterior and inferior edge of the acromion process, at

the most salient point of this margin, about opposite the scapulo-clavicular articulation. If the arm can be straightened, the extremity of either of the fingers can be used as the lower fixed point. If the arm cannot be straightened, we may use as the lower point either condyle, or the point of the elbow. In order to get the point of the elbow accurately, the hands should be clasped in front of the body; and as the elbows are pressed back, a rule may be laid beneath, and the measurements made from the upper surface of the rule.

§ 6. Base of the Condyles.

Syn.—Supra-condyloid Fractures of the Humerus.—Malgaigne.

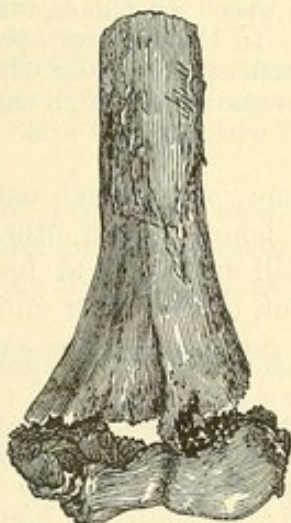Of 18 fractures at this point, 12 occurred in children under ten years of age, the youngest being two years old. In 11 cases the fracture had been produced by a fall, and it is presumed that the blow was received upon the elbow; in the remaining six cases the cause is not stated. This fracture is, therefore, generally the result of an indirect blow, inflicted upon the extremity of the elbow; in a few examples it has been produced by a blow received directly upon the point of fracture, as by the kick of a horse, etc., but I have never, save in a single instance, been able to trace it to a fall upon the hand. Dr. Shearer, U. S. A., has reported a case also, which seems to have occurred in the same manner.¹

FIG. 117.



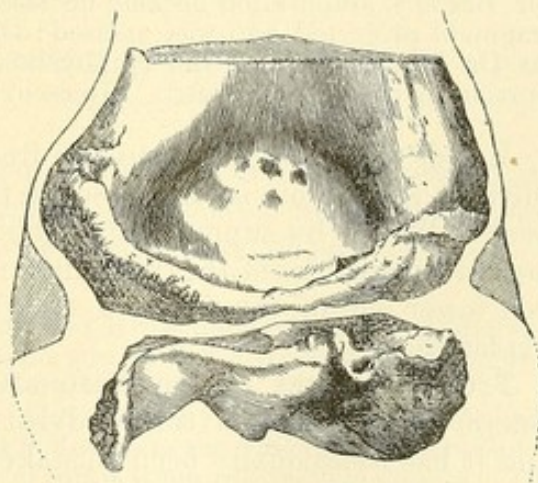
Lower epiphysis.

FIG. 118.



Dr. Reeve's case of separation of the lower epiphysis.

FIG. 119.



Dr. Lange's case of separation of lower epiphysis, and detachment of epicondyles.

Direction of the Fracture, Displacement, and Symptoms.—This fracture is generally oblique, and its line of direction upward and backward:

¹ M. M. Shearer, Act. Asst. Surgeon, U. S. A. Boston Journal of Chemistry, Feb. 1, 1870.

in nine of the eleven cases where this point was determined such has been its apparent direction, and the lower fragment has been found drawn up behind the upper. Once I have found the lower fragment in front, and once on the outside of the upper. Three of the eighteen were compound comminuted fractures, this being a larger proportion of serious complications than is usually found in connection with fractures of long bones.

Separation of the Lower Epiphysis.—Surgical writers have occasionally spoken of this accident, and the late Dr. Watson, of New York, believed that he had seen one example in an infant not quite two years old. The limb had been violently wrenched by the mother, in attempting to lift her. She was not seen by Dr. Watson until the fourth day, at which time the swelling was such that the diagnosis could not be easily made out; but on the ninth day "it was apparent that the shaft of the humerus had been separated from its cartilaginous expansion at the condyles, near the elbow." By the use of angular pasteboard splints the reduction was maintained, and the fragments became united after about four or six weeks.¹

Dr. Reeve, of Dayton, Ohio, sent me a specimen of epiphyseal separation, which occurred in his practice in the year 1864. A girl, aged ten years, fell a few feet, striking, probably, upon her elbow. The fracture was compound, and union not having occurred at the end of three weeks, the condition of the arm rendered amputation necessary. In this case a small fragment of the shaft came away with the epiphysis. Drs. Little, Voss, Buck,² and Lange,³ of this city, have each reported a similar case. Champion,⁴ so long ago as 1818, described the case of a boy thirteen years old, in whom the epiphysis was torn off by the arm being caught in machinery; amputation became necessary, and the boy got well. Mr. Hutchinson⁵ describes one case also. In Champion's case, and in Dr. Reeve's, amputation became necessary. In Hutchinson's patient the upper fragment projected and was excised; the patient recovering with a stiff elbow. In Dr. Lange's patient the epiphysis was removed through the wound, and a portion of the shaft excised. He recovered with a useful arm.

I wish to call attention to the frequency with which examples of epiphyseal separation in the case of this bone, and of other bones, have been followed by suppuration. This will be found to be especially the fact in separations of the trochanter major, of the lower end of the femur, and lower end of the tibia. I shall not attempt at present to offer an explanation.

True Fractures at the Base of the Condyles.—The diagnosis of a fracture at the base of the condyles is attended with peculiar difficulties, and it has occasionally been mistaken for a dislocation of the radius and ulna backward.

Dupuytren says: "There is nothing so common as to see a fracture of the lower end of the humerus, immediately above the elbow-joint, mistaken for a dislocation backward;" and he mentions three cases which have come under his own observation. I have found an opposite error, however, by far the most frequent, namely, a dislocation of both bones backward has been supposed to be a fracture.

¹ Watson, New York Journ. Med., Nov. 1853, p. 430, second series, vol. xi.

² Little, Voss, and Buck, New York Journ. Med., Nov. 1865, p. 133.

³ Lange, N. Y. Surg. Soc., 1880.

⁴ Champion, Journ. Comp. Rend. des Sci. Med., t. 1, 1818, p. 323; Gurlt, op. cit., t. 1, 82.

⁵ Hutchinson, Med. Times and Gaz., 1866, t. 1, p. 360.

The sources of embarrassment are found in the proximity of the fracture to the joint, in the rapidity with which swelling occurs, and in the striking similarity of the symptoms which characterize the two accidents. The following are the signs of fracture:

1. Preternatural mobility, which, owing to the rapidity of the swelling and the contraction of the muscles whose tendons are stretched over the projecting ends of the bones, is often soon lost, being succeeded, sometimes after a few hours, by a rigidity equal to that which is usually present in dislocations, or even greater. It is especially difficult to flex the arm, owing to the projection of the upper fragment into the bend of the elbow.

2. Crepitus. This can usually be detected at any period if the arm is sufficiently extended, so as to bring the broken surfaces again into apposition.

3. When the extension is sufficient, reduction is easily effected, and the natural length of the arm is restored; but the limb immediately shortens when the extension is discontinued—especially if, at the same moment, the elbow is bent. This is a very important means of diagnosis.

4. A careful measurement, made from the point of the internal condyle to the acromion process, declares a positive shortening of the humerus.

5. By flexing and extending the forearm upon the arm, while the fingers are placed upon the lower portion of the humerus, the projecting fragments can be felt. Generally, the upper fragment being in front of the lower, and pressing down into the bend of the elbow, its end cannot be so easily recognized; but the upper end of the lower fragment can easily be made out, posteriorly, when the forearm is considerably flexed. The lower end of the upper fragment feels more rough, and is less wide, than in dislocations.

6. The whole of the lower fragment is carried backward, and with it the radius and ulna, producing a striking prominence of the elbow and olecranon process. Efforts to straighten the forearm upon the arm, when no extension is used, increase rather than diminish this projection.

7. The forearm is slightly flexed upon the arm, the angle made at the elbow being 25 or 30 degrees.

8. The hand and forearm are pronated.

9. The relations of the olecranon process with the two condyles remain unchanged.

In a case of *epiphyseal separation*, the lower end of the upper fragment has greater breadth than in the case of a fracture at the base of the condyle, and the line of separation is nearer the end of the bone.

Signs of a Dislocation of the Radius and Ulna Backward.—1. Preternatural immobility—that is to say, extension and flexion are limited, but there is almost always present a preternatural lateral mobility.

2. Absence of crepitus. It is in this joint especially that surgeons have been deceived by the chafing of the dislocated bones upon the inflamed joint surfaces, and have supposed that they discovered crepitus when no fracture existed. The rapidity with which inflammation develops itself after dislocations of the elbow-joint, and the consequent abundant effusion of lymph, afford the probable explanation of this frequent error.

3. When reduced, the bones are not generally disposed to become again displaced, even though the elbow should be flexed.

4. The humerus is not shortened, but the olecranon process approaches the acromion process.

5. There are no sharp projecting points of bone. The lower end of the humerus may not always be felt in the bend of the elbow; but when it is felt, it is found to be relatively smooth, broad, and round.

6. A remarkable prominence of the elbow and olecranon process, which prominence is sensibly diminished when an effort is made to straighten the forearm on the arm.

7. Forearm flexed upon the arm to about the same degree as in fracture.
8. Hand and forearm pronated as in fracture.
9. Relations of the olecranon process to the condyles changed very greatly.

The most constant diagnostic signs are, then, in the case of a fracture, crepitus, shortening of the humerus, projection of the sharp ends of the fragments, and an increase of the projection of the elbow when an attempt is made to straighten the arm; and in the case of a dislocation, the absence of crepitus, humerus not shortened, while the olecranon approaches the acromion process; the smooth, round head of the humerus lost, or indistinctly felt in the bend of the elbow, and the projection of the point of the elbow diminished when the attempt is made to straighten the forearm on the arm.

It is proper, also, to repeat here what we have already said in relation to the causes of this fracture. A fracture of this point is produced almost always by a fall upon the elbow, but a dislocation of the radius and ulna backward can never be. On the other hand, a dislocation is produced, in most cases, by a fall upon the palm of the hand, while I have never known but one fracture above the condyles to be thus produced.

Prognosis.—Nine times I have found the arm shortened from half an inch to one inch, or a little more. Moderate ankylosis is almost always present when the apparatus is first removed, and it is seldom completely dissipated until after several months; but I have found more or less ankylosis at seven and nine months; and twice after the lapse of three years the motions of the joint have been very limited.

A few years since, I examined the arm of a gentleman who was then twenty-seven years old, and who informed me that when he was four years old he broke the humerus just above the condyles. There still remained a sensible deformity at the point of fracture—he could not completely supine the forearm. The whole arm was weak, and the ulnar nerve remarkably sensitive. The ulnar side of the forearm, and also the ring and little fingers, were numb, and have been in this condition ever since the accident. I know the surgeon very well who had charge of this case, and I have no doubt that the treatment was correct. In June of 1850 I operated upon a lad, nine years old, by sawing off the projecting end of the upper fragment, whose arm had been broken nine months before. This fragment was lying in front of the lower, and the skin covering its sharp point was very thin and tender. There was no ankylosis at the elbow-joint, but the hand was flexed forcibly upon the wrist, the first phalanges of all the fingers extended, and the second and third flexed. Supination and pronation of the forearm were lost. The forearm and hand were almost completely paralyzed, but very painful at times. The ulnar nerve could be felt lying across the end of the bone. In the hope that a favorable change might result by relieving the pressure on the nerve, yet with not much expectation of success, I exposed the bone and removed the projecting fragment. The nerve had to be lifted and laid aside. About one year from this time I found the arm in the same condition. Non-union is a result not so frequent in fractures at this point as higher up; but Stephen Smith, of the Bellevue Hospital, New York, reports a case of non-union in a man of twenty-three years. He was admitted to the hospital on the seventh day after the accident. The fracture was simple and transverse, yet at the end of four months he was dismissed “with perfectly free motion at the point of fracture.”¹ The failure to unite was attributed to a syphilitic taint.

A case was tried a few years since in the Supreme Court at Brooklyn, N. Y.,

¹ Stephen Smith, *New York Journal of Medicine*, May, 1857, third series, vol. ii. p. 386.

in which, after a simple fracture at this point, the arm being dressed with splints and bandages, the little finger sloughed off in a condition of dry gangrene, and the adjacent parts of the hand were attacked with moist gangrene. Drs. Parker and Prince believed that this serious accident was the result of bandages applied too tightly and suffered to remain too long, while Drs. Valentine Mott, Rogers, Wood, Ayres, Dixon, and others, believed the gangrene might have been due to other causes over which the surgeon had no control.¹

A few years ago, a similar case occurred in the town of Spencer, Tioga Co., N. Y.; a boy, six years old, having broken the humerus just above the condyles. The fracture was oblique. The surgeon who was called to treat the case was an old and highly respectable practitioner. I am not informed of the plan of treatment any further than that a roller was applied. On the eighth day, a second surgeon was employed, who, finding the hand cold and insensible, removed all of the dressings; after which the thumb and forefinger sloughed, with other portions of the skin and flesh of the hand and arm. The surgeon who was first in attendance was prosecuted, and the case was tried in the Supreme Court of that county, but the jury found no cause of action. Dr. Hawley, of Ithaca, and the late Dr. Webster, of Geneva Medical College, testified that, in their opinion, the death of the fingers was owing to the pressure of the fragment upon the brachial artery, and not to the tightness of the bandages.

Dr. Gross has also informed us of still another case of the same character, which occurred in Warren Co., Ky. A boy, ten years old, had broken his arm above the condyles, and his parents having employed a surgeon residing at some distance, the dressings were applied, and directions given to send for the surgeon whenever it became necessary. The parents saw the arm swell excessively, and knew that the boy was suffering very much, but did not notify the surgeon until the tenth day, when the hand was found to be in a condition of mortification, and at length amputation became necessary. Long afterward, in the year 1851, when the boy became of age, he prosecuted his surgeon, but with no result to either party beyond the payment of their respective costs.

A similar case has been reported to me by Dr. Lyman Twomley, of Cattaraugus County, in this State. Dr. Twomley is a well-known and experienced surgeon and physician. Dr. T. was called to a boy *æt.* 7, who had fallen ten feet and broken his right arm at the base of the condyles. Although but twelve hours had elapsed, the limb was greatly swollen. The lower end of the upper fragment projected through the skin three inches. His pulse was feeble and intermittent. Dr. T. administered chloroform and adjusted the fragments. Light splints were applied, and cold lotions. On the fifth day gangrene commenced, and on the seventh day Dr. T. amputated at the point of fracture. The wound resulted in the formation of a good stump. Examining the limb after amputation, the joint was found filled with blood in a putrid state, and the tissues above and below were infiltrated with the same. Both of the lateral and the anterior ligaments of the joint were badly torn. The biceps and brachialis anticus were much torn. A small portion of the olecranon process and more of the coronoid processes were broken off. The brachial artery was ruptured, and the median nerve seriously injured. There was also a partial fracture of the carpal extremity of the radius. When this boy became of age he entered a suit against the doctor for malpractice, in having, he affirmed, made an unnecessary amputation of the arm. I am informed that the allegations were not sustained by the Court, and in this decision all surgeons must heartily concur.

While I would not deny that in some of the preceding cases the sloughing might have been solely due to the tightness of the bandages, against which cruel and mischievous practice we cannot too strongly protest, a knowledge of the anatomy of these parts, and the opinions of the very distinguished gentlemen who testified in defence of these surgeons, must compel us to admit the possibility of such accidents where the treatment has been skilful and faultless.

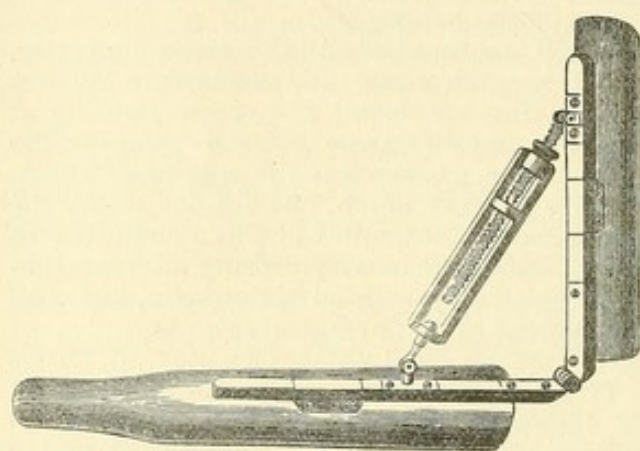
Treatment.—The splints formerly much employed in this country, in fractures about the elbow-joint, and perhaps still used by some American

¹ New York Medical Gazette, vol. xii. pp. 46, 80, 111.

surgeons, are simple angular side-splints, without joints, such as those recommended by Physick;¹ angular pasteboard splints, felt, leather, gutta percha, etc., or angular splints with a hinge, such as Kirkbride's,² Thomas Hewson's, Day's, Rose's, Welch's, or Bond's.

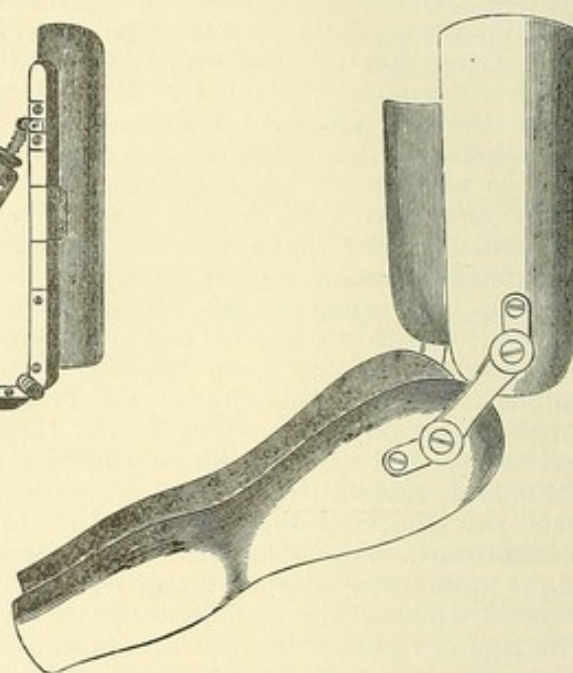
Kirkbride's splint, which is said to have been used in the Pennsylvania Hospital in several instances, is composed of two pieces of board, connected together by a circular joint, and having eyes in the inner edge, two inches apart, and holes through the splint at graduated distances between them. There is also a swivel eye, passing through the upper part of the splint, and riveted below. A wire is fastened to the swivel, and bent at right angles at its other extremity, of a size to fit the eyes and holes in the splint. The splint, properly supported by pads, is to be placed either upon the outside or inside of the arm, and secured by rollers. When the angle is to be changed, the wire is unhooked and removed to another eye, or to some of the intermediate holes upon the side of the splint.

FIG. 120.



Rose's splint.

FIG. 121.



Welch's splint. The hinges may be transferred to splints of different sizes.

Dr. Kirkbride reports two cases of fracture of the lower part of the humerus treated by this plan, one of which resulted in ankylosis, but the other was much more successful.

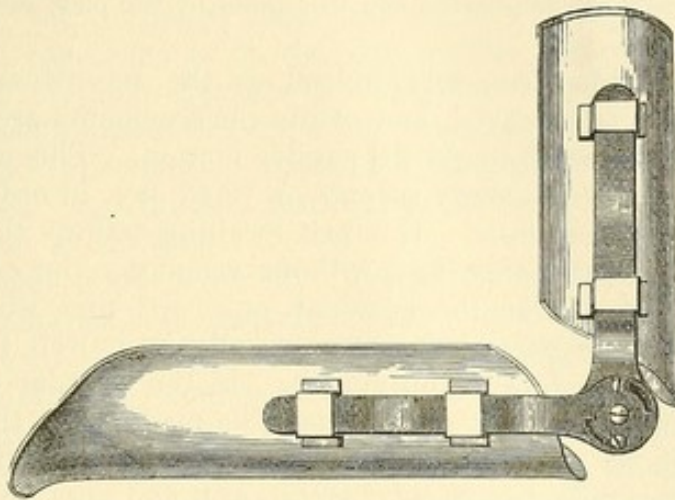
H. Bond, of Philadelphia, has contrived a very ingenious splint for the elbow-joint, and which is designed also to afford a complete support to the forearm.

For myself, I generally prefer a thick sheet of gutta percha, moulded and applied accurately to the limb. It should be extended beyond the elbow to the wrist, so as to support the whole length of the arm, elbow, and forearm. Some experience in the use of wooden angular splints has convinced me that they cannot be very well fitted to the many inequalities of the limb; and neither pasteboard nor binder's board has sufficient firmness, especially in that portion which covers the joint. Angular splints, furnished with a movable joint, possess the advantage of enabling

¹ Elements of Surgery, by John Syng Dorsey, Philadelphia edition, vol. i. p. 145.

² American Journal of the Medical Sciences, vol. xvi. p. 315.

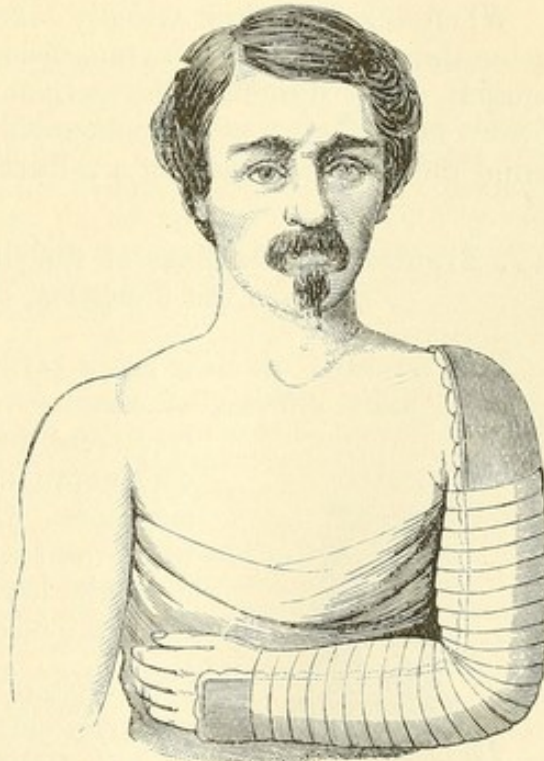
FIG. 122.



Bond's elbow splint.

us to change the angle of the limb at pleasure, and of keeping up some degree of motion in the articulation without disturbing the fracture or removing the dressings; but the crossbars of Day's and Rose's splints render them complicated, and are in the way of a nice application of the rollers; while they are all equally liable to the objection stated against angular wooden splints without joints, viz., that they seldom can be made to fit accurately the many irregularities of the arm, elbow, and forearm. In applying the author's splint, care must be taken that the humeral portion is not too short, or the result will be an unnecessary degree of overlapping of the fragments. This may generally be avoided if the surgeon will first shape his material to the sound arm, while the whole length is underlaid with three or four thicknesses of woollen cloth. Welch's splints, made of a material possessing a slight amount of flexibility, approach more nearly the accomplishment of all the indications than any other manufactured splint with which I am acquainted, but the number of cases in practice to which they are applicable will be found to be limited, while gutta percha has no limit in its application.

FIG. 123.



The author's gutta-percha splint.

Whatever material is employed, the splint should be first lined with one thickness of woollen cloth, or some proper substitute. A pretty large pledget of fine cotton batting ought also to be laid in front of the elbow-joint, to prevent the roller from excoriating the delicate and inflamed skin; and great care should

be taken to protect the bony eminences about the joint, or, rather, to relieve them from pressure, by increasing the thickness of the pads above and below these eminences.

At a very early day, so early, indeed, as the seventh or eighth day, the splint should be removed, and, while the fragments are steadied, the joint should be subjected to gentle, passive motion. This practice should be repeated as often as every second or third day, in order to prevent, as far as possible, ankylosis. If much swelling follows the injury, it is my custom to open the dressings, without removing the splints, on the second or third day after the accident, or at any time when the symptoms admonish of its necessity. Occasionally, it is well to change the angle of the splint before reapplying it. If the angular splint with a movable joint is used, slight changes may be made while the splint is on the arm; but if the angle is much changed without removing the roller, they become unequally tightened over the arm and may do mischief.

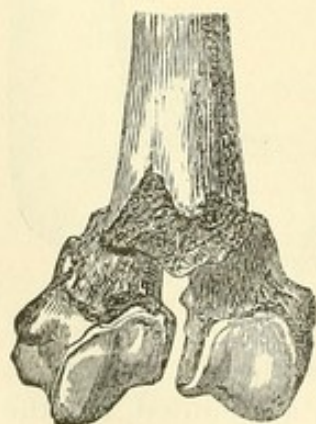
[The plaster-of-Paris dressing should be preferred by those accustomed to its use. The fracture should be reduced and the fragments held in position until the dressing is firm. It should extend from the wrist to the shoulder. The necessity for passive motion during the first three weeks is not so great as to preclude immovable dressings. Indeed, it is believed by many surgeons that early passive motion in this fracture is decidedly detrimental and should never be practised.]

When ankylosis has actually taken place, we may more or less overcome the contraction of the muscles and of the ligaments by gentle passive motion, or by directing the patient to swing a dumb-bell or some other heavy weight, as first recommended by Hildanus; but we must bear in mind the danger of causing a refracture by too early or immoderate force.

§ 7. Fracture at the Base of the Condyles, complicated with Fracture between the Condyles, extending into the joint.

This fracture, which is but a variety or complication of the preceding, is even more difficult of diagnosis; and its signs, results, and proper treatment differ sufficiently to demand a separate consideration. I have recognized the accident six times. Confined to no period of life, it seems to be the result of a severe blow inflicted directly upon the lower and back part of the humerus, or upon the olecranon process.

FIG. 124.



Fracture at the base of, and between, the condyles.

Dr. Parker, of New York, was inclined to regard an obscure accident about the elbow-joint, which he saw in a lad sixteen years old, as a longitudinal fracture of the humerus, with separation of one condyle, but which had been occasioned by a fall upon the hand.¹ For myself, I should regard this latter circumstance as presumptive evidence that it was not a fracture of this character, yet I do not mean to deny the possibility of its occurrence in this way.

Symptoms.—The symptoms are, increased breadth of the lower end of the humerus, occasioned by a separation of the condyles; displacement upward and backward of the radius and

¹ Parker, New York Journal of Medicine, Nov. 1856, p. 391, 3d series, vol. i.

ulna; shortening of the humerus; crepitus and mobility at the base of the condyles, with crepitus also between the condyles, developed by pressing them together; or in case the radius and ulna are drawn up and back, the crepitus may be detected, after restoring these bones to place, by pressing upon the opposite condyles. Its consequences are, generally, great inflammation about the joint, permanent deformity, and bony ankylosis. An opposite result must be regarded as fortunate, and as an exception to the rule.

The treatment must be chiefly directed to the prevention and reduction of inflammation; at least during the first few days. Nor is this inconsistent with an early reduction of the fragments, and moderate efforts, by splints and bandages, such as I have directed in case of a simple fracture at the base of the condyles, to keep the fragments in place. No surgeon would be justified in refusing altogether to make suitable attempts to accomplish these important indications; but he must always regard them as secondary when compared with the importance of controlling the inflammation. When splints are employed, the same rules will be applicable, both as to their form and mode of application, as in cases of simple fracture above the condyles. Plaster-of-Paris, or some of the immovable forms of dressing, furnished with ample fenestræ, will sometimes be preferred.

The following will more completely illustrate the character, history, and proper treatment of these cases than any remarks or rules which I can present: A woman, æt. forty-four, fell upon the sidewalk, striking upon her right elbow. I saw her a few minutes after the accident, but the parts about the joint were already considerably swollen, and it was not without difficulty that the diagnosis was made out. The forearm was slightly flexed upon the arm, and pronated. On seizing the elbow firmly, a distinct motion was perceived above the condyles, and a crepitus. I could also feel, indistinctly, the point of the upper fragment. While moderate extension was made upon the arm, the condyles were pressed together, when it was apparent that they had been separated. On removing the extension, they again separated, and the olecranon drew up. She was in a condition of extreme exhaustion, and the bones were easily placed in position. An angular splint was secured to the limb, and every care used to support the fragments completely, but gently. From this date until the conclusion of the treatment the dressings were removed often, and the elbow moved as much as it was possible to move it. Seven months after the accident, the elbow was almost completely ankylosed at a right angle. The fingers and wrist, also, were quite rigid. Six years later, the ankylosis had nearly disappeared; she could now flex and extend the arm almost as much as the other; the wrist-joint was free, and the fingers could be flexed, but not sufficiently to touch the palm of the hand. The line of fracture through the base could be traced easily, but the humerus was not shortened. There was, moreover, much tenderness over the point of fracture through the base, and at other points. Occasionally, a slight grating was noticed in the radio-humeral articulation. She experienced frequent pains in the arm, and especially along the back and radial border of the ring finger. During the first year or two after the accident, the arm wasted very much; the hand remained weak, but the muscles were well developed. A gentleman was struck with the tongue of a carriage with which a couple of horses were running. The blow was received directly upon the back of the left elbow. Dr. Sprague and myself removed some small fragments of bone, and while opening the wound for this purpose, we could see distinctly the line of fracture extending into the joint as well as across the bone. The condyles were not separated. The subsequent treatment consisted only in the use of such means as would best support the limb, and most successfully combat inflammation. The arm and forearm were laid upon a broad and well-cushioned angular

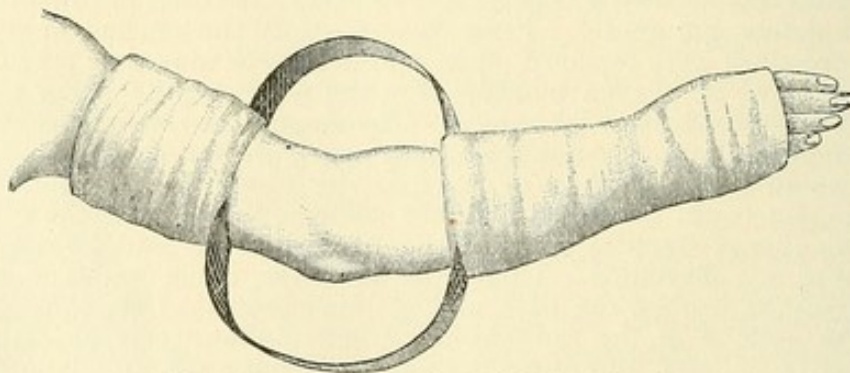
splint, covered with oil-cloth, to which they were fastened by a few light turns of a roller. Twelve years after, I found the humerus shortened one inch and a half. During the first year, he says, there was no motion in the elbow-joint, but he can now flex and extend the forearm through about 45° ; when flexed to a right angle, it seems to strike a solid body like bone. Rotation of the forearm is completely lost, the hand being in a position midway between supination and pronation. He suffers no pain, and his arm is quite strong and useful. No means have been employed to restore the functions of the limb but passive motion at first, and subsequently constant, active use of the hand and arm.

Although the flexed position must usually be regarded as the best in these fractures, for the reason that it most completely relaxes the biceps, brachialis anticus, and the flexors of the forearm, and because if ankylosis ensues the flexed position gives the most useful arm, yet I think it might be proper to try what better may be accomplished by permanent extension, with the forearm straightened upon the arm, according to the method of Dr. Clark, described in the preceding pages.

In a case of compound comminuted fracture of the character now under consideration, Dr. Stone, of the Bellevue Hospital, New York, removed the condyles and sawed off the sharp end of the humerus. The woman was twenty-six years old and intemperate. The operation was made as a substitute for amputation. No serious complications followed. On the ninety-sixth day the wounds were completely healed, and she could bend the forearm to a right angle with the arm, the action of the muscles having drawn up the radius and ulna against the lower end of the shaft of the humerus, so that the motions were natural and free.¹ The practice, as the result sufficiently shows, was eminently judicious; and its practicability ought always to be well considered before resorting to the serious mutilation of amputation. The great principle upon which the success of resection is here based is the shortening of the bone, whereby the reduction may be accomplished without painful tension to the muscles; a principle which will demand of us hereafter a more careful consideration and a wider application.

[The resection of the joint in compound comminuted fractures of the lower end of the humerus is now a safe operation. It is important that the condition of the parts be thoroughly understood, and that the operation leave the joint in

FIG. 125.



Plaster-of-Paris dressing with iron bands.

the best possible state for future use. Fibrous tissues should be saved, and, if possible, the muscular attachments to the coronoid and coracoid processes. A useful splint, after such an operation, is made with iron bands, properly bent, and the plaster-of-Paris dressing.]

¹ Stone, New York Journ. of Med., May, 1851, p. 302, vol. vi. 2d series.

Fractures and Diastases of the Condyles and Epicondyles.

I prefer, as being more familiar, the terms external and internal condyles, to which it will be convenient to add the terms external epicondyle and internal epicondyle, as indicating the abrupt lateral projections on either side of the condyles, of which the largest portions are epiphyseal. These crests or projections are formed in part by a prolongation of the outer and inner elevated margins of the humerus, and in part from separate centres of ossification, which in early life mainly overlies the two sides of the lower epiphysis. In advancing years these lateral epiphyses prolong themselves upward to reach and partially overlie the humeral portions: the outer epiphysis becomes united by bony tissue to the shaft or humeral apophysis, about the sixteenth or seventeenth year; while the inner epiphysis, much larger than the outer, is not united usually to its corresponding apophysis until the eighteenth year. Gurlt places the period of union of both of these epiphyses a year or two later.

I shall hereafter speak of the epicondyles as all of those portions of the lower end of the humerus which project abruptly from the condyles, and are composed in large part of the lateral epiphyses, but not entirely. Practically, this definition leaves no portion of the lower extremity of the humerus outside of the capsule except the epicondyles. We shall therefore have to speak only of fractures of the epicondyles, and of fractures of the condyles involving the joint; the condyles proper, as distinguished from the epicondyles, constituting on the one hand the outer end of the lower extremity of the humerus, including so much of the articular surface as belongs to the eminentia capitata; and, on the other hand, so much of the inner portion of the articular surface as includes the trochlea. The epicondylar separations consist of two varieties, one of which is an epiphyseal separation, and the other a true fracture; one of which includes only a portion of the epicondyle, and the other includes the whole. The remaining fractures will all be intracapsular.

§ 8. Fracture of the Internal Epicondyle; and Fracture or Diastasis of the Internal Epicondylar Epiphysis.

I will here add, to what I have already said in the preceding pages on the anatomy and development of the humerus, the very careful description of the development of the lower end of the humerus given by Dr. Zuckerkandl, Demonstrator of Anatomy in the University of Vienna.¹

"The inferior extremity of the humerus proceeds from a synostosis of five separately developed portions of bone. These are: 1st, the humeral-diaphysis, which includes the supra-trochlear fossa, a minute portion of the eminentia capitata, and on the dorsal surface the ribbon-like zone of the trochlea; 2d, the trochlea; 3d, the eminentia capitata; 4th and 5th, the epicondyles. On the fully-formed humerus that part is called the internal epicondyle which projects lever-like above the trochlea, and serves as the point of origin of the flexor group. Though this bony prominence presents itself as a united whole at this stage, still an examination of the humerus, in the earlier periods of its development, teaches us that the internal epicondyle of the adult consists of two pieces,

¹ Zuckerkandl, on the Epicondylar Fracture of the Humerus. Hosp. Gazette, Sept. 27, 1879. Separat-Abdruck aus der "Allgem. Wiener Mediz. Zeitung," 1878, Nr. 9.

the superior of which belongs to the humeral diaphysis, to the median surface of which the osseous nucleus of the epicondyle applies itself, enlarges, and finally unites with the upper portion to form the lever of the flexor group of muscles. Accordingly what, in ordinary acceptation, is called a fracture of the epicondyle is something more, since it includes also a part of the humerus. It is difficult to believe that only that part of the internal epicondyle which corresponds to the epiphyseal centre of ossification, should be broken off in the adult, so that distinct cases of epicondylar fracture can occur only in youths. "What we call external epicondyle, on the completely developed humerus, and a small portion of which (called '*la petite saillie*,' in the above quotation from Malgaigne) can be felt and seen through the skin of the arm in lean subjects, belongs, as taught by embryological observations, not properly to the external epicondyle, but represents the most inferior prominence of the *crista externa humeri*, with which the more posteriorly extending epiphyseal nucleus of the external epicondyle finally unites. The epicondyles of adults, therefore, belong partly to the humerus and partly to the actual epiphyseal epicondyles, as a glance at the humeri of young persons teaches us. From the real internal epicondyle, which we term epiphyseal, arise the *radialis internus*, *ulnaris internus*, *palmaris longus*, and a small portion of the *pronator teres*, while from that part of the epicondyle which belongs to the humeral diaphysis, arises the greater portion of the *pronator* above named. On the external epiphyseal epicondyle are found the common extensor of the fingers, the *ulnaris externus*, and the *anconeus quartus*."

These views of the anatomy and development of the condyles and epicondyles, and which are no doubt correct, compel me to reconsider the statements I have made in the earlier editions of this work, and to correct certain errors into which the author, in common with all other writers, has fallen in the classification of certain reported examples of fractures of the epicondyles. Hitherto, while in speaking of fractures of the internal epicondyle, I have distinctly stated that my remarks were limited to separations of the epicondylar epiphyses, I have not hesitated to include as proper examples those cases in which I believed the entire epicondylar projection to be included. Other writers have, without exception so far as I know, done the same. The observations of Zuckerkandl, however, show that, as I have before stated, these extreme projections are composed only in part of the true epicondylar epiphyses. We must then hereafter speak of these separations which are epicondylar, and only epiphyseal, as composing one class of accidents, and which must be in a great measure peculiar to children; and of those which are epicondylar, but include also that portion of the epicondyle which is not epiphyseal, as another class, belonging chiefly to adults, but possible in children.

According to Zuckerkandl, it has been observed by Rambaud and Renault that there is sometimes a persistence of the epiphysis, the separation continuing to adult life; from which we must infer that an epicondylar epiphyseal diastasis might take place in the adult, but it must nevertheless be very infrequent. We can have, usually, no means of determining this point except in the autopsy, and we must therefore be left in doubt sometimes whether a particular clinical case is to be regarded as an epiphyseal separation or a true fracture; our only means of differential diagnosis being the probabilities afforded by the age of the patient, the cause, and the size and form of the fragment.

In treating of this subject, then, we can only relieve ourselves of the embarrassment by treating of epicondylar fractures and diastases as a

class, existing in two subordinate forms—namely, one in which only the epiphysis is torn off before bony union to the crista humeri has taken place—a true diastasis; and the second, in which, bony union having been completed, the whole of the extreme projection or epicondyle is separated from the shaft—a true fracture. The differential diagnosis of these two forms of injury to the epicondyle is somewhat difficult to establish by external signs. The age of the patient is doubtless the most important consideration, and in this view diastasis must be regarded as by far the more frequent accident.

This is probably the accident which Granger first described, and which he ascribed solely to muscular action. He does not speak of it, however, as a diastasis of the epicondyle, but as “a particular fracture of the internal condyle.” “A circumstance attending this fracture,” says Mr. Granger, “is that of its being occasioned by sudden and violent muscular exertion; and it will be recollected that from the inner condyle those powerful muscles which constitute the bulk of the fleshy substance of the ulnar aspect of the forearm have their principal origin. The way in which the muscles of the inner condyle are involuntarily thrown into such sudden and excessive action I take to be this: the endeavor to prevent a fall by stretching out the arm, and thus receiving the percussion from the weight of the body on the hand.”¹

It is a fact of significance in this connection, that most of these fractures hitherto reported as epicondylar have occurred in children, before the union of the epiphysis is completed, when muscular contraction might more often prove adequate to its separation, and when the epicondyle is less prominent, and, therefore, less exposed to direct blows, than in adult life.

M. A. César has collected fourteen cases, of which number only four were adults, two were from eight to ten years old, five from eleven to twelve, and three from fifteen to sixteen.² While of five fractures which I have regarded as fractures of the epicondyle, all except one occurred between the ages of two and fifteen years.

It is equally true that a large majority of all the fractures of the internal condyle, including those which enter the articulation, as well as those which do not, belong to childhood and youth. I have seen but two exceptions in fifteen cases. Since, then, direct blows generally produce those fractures which penetrate the joint, no good reason can be shown why they should not sometimes produce fractures of the epicondyle. One of the exceptions to which I have referred as not having occurred in early life, is sufficiently rare to entitle it to especial notice.

A laborer, thirty-four years of age fell from an awning upon the sidewalk, dislocating the radius and ulna backward; the dislocation was immediately reduced by a woman who came to his assistance, but when he called on me soon after, I found a small fragment of the inner condyle, probably the epicondyle alone, broken off and quite movable under the finger. It was slightly displaced in the direction of the hand. I could not learn positively whether in falling he struck the elbow or the hand, but there was presumptive evidence that he struck

¹ “On a Particular Fracture of the Inner Condyle of the Humerus,” by Benjamin Granger, Surgeon, Burton-upon-Trent. *Edinburgh Med. and Surg. Journ.*, vol. xiv. p. 196, April, 1818.

² César, *Essai sur le frac. de l'épitrôchlée*, th. de Paris, 1876.

the hand; if so, then probably the fracture was the result of muscular action, which is the more extraordinary as having taken place in a man of his age, but in which case it must be assumed that the epiphyseal union was delayed.

It is pretty certain, however, that the theory of causation adopted by Granger is too exclusive. A lad was brought to me, aged eleven, who had just fallen upon his elbow, the blow having been received, as he affirmed, and as the ecchymosis showed pretty conclusively, directly upon the inner condyle. The fragment was quite loose, and crepitus was distinct. He could flex and extend the arm, and rotate the forearm, without pain or inconvenience. I am quite sure the fracture did not extend into the joint; the result seemed also to confirm this opinion, for in three months from the time of the accident the motions of the elbow-joint were almost completely restored. Out of fourteen cases collected by César, at least eight, says Poincot, were produced by a direct cause.

Mr. Granger has failed to establish, by any particular proofs, that in more than one or two of his cases the fracture was the result of muscular action; but, on the contrary, I am disposed to infer, from the violent inflammation which generally ensued in his cases, from the frequency of ecchymosis, and especially from the injury done to the ulnar nerve in at least three instances, that most of them were produced by direct blows inflicted from below in the fall upon the ground. Fractures produced by muscular action are seldom accompanied with much inflammation or effusion of blood, and it is much more probable that the ulnar nerve should have been maimed by the direct blow which caused the fracture, than by the displacement of the epiphysis, which is, as I shall presently show, almost always carried downward, and oftener slightly forward than backward. It is only when the fragment is forced directly backward that the ulnar nerve could be made to suffer; a direction which, it does not seem me, it could ever take from muscular action alone.

Of all the cases above alluded to, including Granger's cases, it may be justly said that they were not verified by an autopsy, and that they do not, therefore, prove absolutely the existence of such a diastasis. In a case reported by Denucé, there was an exostosis resulting from a fracture, which caused paralysis of the ulnar nerve; but there is no evidence that the injury to the nerve was the result of displacement of the fragment. It was cured, however, by excision of the exostosis.¹

Poincot suggests that when a fracture of the internal epicondyle is caused by a fall upon the hand, the result may sometimes be due rather to the action of the internal lateral ligament than to muscular action; and he says that Granger, Fergusson, Dale, and Richet have observed cases of this kind. He, however, refers to one case mentioned by Hirtz, in which the accident was declared to be plainly the result of muscular action, it being occasioned in a little boy by the act of raising himself by his arms while suspended from a trapeze.

Malgaigne speaks of this accident as a "fracture of the epitrochlea," evidently including in this term all of the epicondylar projection. He states, however, that "there is good ground for supposing that in some cases, at least, it is a disjunction of the epiphysis." Gurlt distinctly states, also, that clinical experience shows that both the inner and outer epiphyses are sometimes broken, however difficult it may be to demonstrate the fact anatomically. The case of which he furnishes an illus-

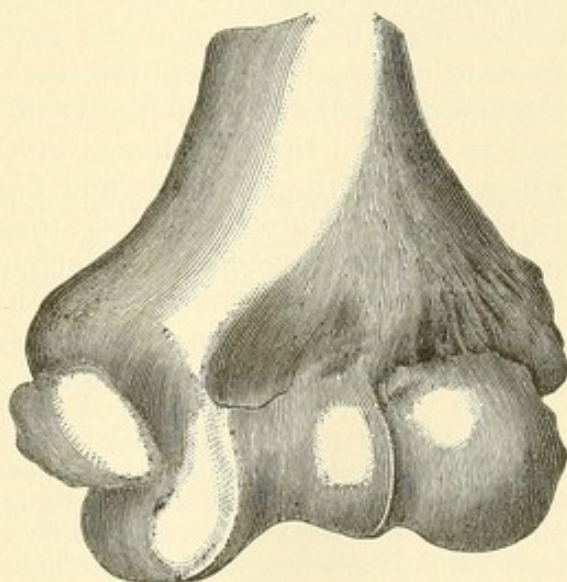
¹ Poincot, *op. cit.*, pp. 314-317.

tration in his book (p. 797, Fig. 109), and as being in the pathological collection at Würzburg, may indeed have been a fracture of the entire internal epicondyle, including both the epiphysis and the apophysis, but there is no evidence or pretence that it was the epiphysis alone.¹

The specimen described by Zuckerkandl, found in the dissecting-room, and without a clinical history (Fig. 126), and which he has kindly sent to me, is probably the only example of which we can speak with any degree of positiveness as having been sustained by an autopsy. The following is his account: "The separation of the internal epicondyle I found on the left arm of a strong-boned man. After the removal of the flexors, the epicondyle appeared projecting forward tumor-like, but immovable, so that at first sight I thought of a fracture healed by callus. As I removed the dense connective tissue, which surrounded the epicondyle, there appeared a furrow, which encircled the irregular bony prominence, and formed a sharp line of demarcation between it and the humeral epicondyle. The tumor-like bony prominence, therefore, represented the epiphyseal epicondyle. On farther examination it was seen that the epiphyseal was connected with the humeral epicondyle only by a dense tissue, was irregularly formed on its uneven upper surface, slightly concave on its superior attached side, and of about the size of an *os lunatum*. In the figure are plainly seen the intact humeral epicondyle, the epiphyseal epicondyle, and between them the above-described furrow, which was filled with fibrous tissue. The separated epicondyle does not correspond in form to that of a youthful person, nor to the inferior part of the flexor condyle in the adult. Its long axis in the latter is parallel with that of the humerus—in our preparation, however, it is sagittal, twisted, as it were, on its axis. The inferior portion of the epicondyle is in the adult about one-half cm. distant from the edge of the trochlea, but it is more than one cm. removed in this preparation; so that the lateral surface of the trochlea is very deep."

The bone is from an adult, as stated by Dr. Zuckerkandl, but he has omitted to mention that the coronoid fossa is small, and the olecranon fossa is nearly obliterated, indicating that for a long time before death the motions of the joint were limited. The presumption is, therefore, that this was an old fracture; a fact which increases greatly the difficulty of determining precisely the original character of the accident. There is a broad vertical and remarkable facet mentioned by Dr. Zuckerkandl on the inner side of the trochlea; the outer condyle is probably not normal in its shape, and altogether there are indications that the bone has at some time suffered a very severe and perhaps complicated injury. Perhaps there was more than one line of fracture; possibly a transverse fracture through the shaft at the base of the condyles, or through the line of the epiphyseal junction. If such were the fact, the specimen does not illustrate a simple fracture of the epicondyle; but these are points which the ancient character of the fracture does not permit us to determine positively. We think, however, this may properly be called a separation of the epiphyseal portion of the internal epi-

FIG. 126.



Separation of the epiphyseal portion of the internal epicondyle. (Zuckerkandl's specimen.)

¹ Handbuch der lehre von den Knochenbrüchen. Von Dr. E. Gurlt, Prof. der Chirurgie an der Königlichen Universität zu Berlin. Hamm, 1862, pp. 796, 797.

condyle, but whether it was a simple fracture or separation, uncomplicated with any other lesion of the bone, cannot now be determined.

Direction of Displacement, Symptoms, etc.—I have seen what I suppose to be this epiphysis displaced in the direction of the hand, or downward, very manifestly, twice, and in two other examples a careful measurement showed a slight displacement in the same direction.

The greatest displacement occurred in a boy fifteen years old. He had fallen upon his arm in wrestling, and his surgeon found a dislocation of the bones of the elbow-joint, which he immediately reduced. The diastasis of the epicondyle was not at that time detected, the arm being greatly swollen. No splints were applied. It was three months after the accident when I saw him, at which time I found the internal epicondyle removed downward toward the hand one inch and a quarter; and at this point it had become immovably fixed. Partial ankylosis existed at the elbow-joint, but pronation and supination were perfect. In one instance I believed the fragment to be carried about three lines upward and two backward toward the olecranon; in each of the other examples the fragment did not seem to be displaced.

Granger found, also, in the five examples which came under his notice, the epicondyle carried toward the hand, with more or less variation in its lateral position, so that while in some instances it touched the olecranon, in others it was removed an inch or more in the opposite direction.

It is probable that, except where controlled by the force and direction of the blow, or by some complications in the accident, the fragment, if displaced at all, always moves downward toward the hand, or downward and a little forward, in the direction of the action of the principal muscles which arise from this epiphysis; and when the fracture or separation is the result of muscular action alone, this form of displacement seems to me to be inevitable. In addition to the small size, mobility, crepitus, and generally slight displacement of the fragment, which, in connection with the age of the patient, are the principal signs of this fracture, it may be noticed that there is usually some embarrassment in the motions of the elbow-joint, which may be due in part to the swelling, and in part to the detachment of the point of bone from and around which most of the pronators and flexors of the forearm have their rise. In one instance, already quoted, that of the lad aged eleven years, who is supposed to have had a detachment of the epiphysis from a direct blow, the motions of pronation, with flexion, were not at all impaired, neither immediately, nor at any subsequent period, but the fragment was never sensibly, or only very slightly displaced.

Granger has recorded another class of symptoms, to which I have already alluded, his explanation of which, however, I am not prepared to admit. One of these cases he describes as follows: A boy, eight years old, fell with violence, and broke off completely the whole of the inner epicondyle of the right humerus. The lad said he had fallen on his hand. The fragment was displaced toward the hand. Severe inflammation followed, but he recovered the free and entire use of the elbow-joint in less than three months after the accident. No splints or bandages were ever employed. From the moment of the accident, the little finger, the inner side of the ring finger, and the skin on the ulnar side of the hand, lost all sensation. The abductor minimi digiti and two contiguous muscles of the little finger were also paralyzed. This condition lasted eight or ten years, after which sensation and motion were gradually restored to these parts. As a consequence of this paralyzed condition of the ulnar nerve, also, successive crops of vesications, about the size of a split horse-bean, commenced

to form on the little finger and ulnar edge of the hand some weeks after the accident, leaving troublesome excoriations. This eruption did not entirely cease for two or three months.

Mr. Granger says he found "the same paralysis of the small muscles of the little finger, the same loss of feeling in the integuments, and the same succession of crops of vesicles on the affected parts of the hand, as occurred in the preceding case, in two other cases."

Prognosis.—As in other accidents about the elbow-joint, a temporary rigidity is likely to ensue. The mere confinement of the arm in a flexed position is sufficient to determine this result without the interposition of a fracture; but when inflammation occurs, more or less contraction of the tendons, muscles, etc., about the joint must ensue. To this circumstance, therefore, added to the confinement, rather than to the fracture, will be due the ankylosis. If the fragment is not displaced, the fracture cannot certainly be responsible for the loss of motion, since it does not in any way involve the joint; and if displacement exists, its ultimate effect in diminishing the power of the muscles which arise from the epiphysis must be only trivial and scarcely appreciable. We might, therefore, reasonably conclude that where the accident has been properly treated, permanent ankylosis would be the exception, and not the rule.

This view of the matter seems also to be sustained by the recorded results. In Granger's cases, the full range of flexion and extension of the forearm has been finally restored, or with so trifling an exception as not to be observable without close attention, in every instance; except in the one already mentioned, which was originally complicated with dislocation; and even in this case the ultimate maiming was inconsiderable. Malgaigne, who says "it ought to be understood that in this accident articular rigidity is almost inevitable," seems nevertheless to admit the justness of Granger's observation as to the final result, if the proper means are employed to prevent it. I have myself found only once any considerable ankylosis of the joint after the lapse of a few years.

[Powers,¹ of New York, reports ten cases, of which nine regained the functions perfectly, and the other had motions nearly complete when lost sight of. In none was there deformity.]

Treatment.—This accident does not constitute an exception to the rule which experience has established, that small epiphyseal projections, when once displaced, can seldom be restored completely to, or maintained in position.

Granger remarks: "I have purposely avoided saying one word about replacing the detached condyle" (epicondyle), "and for these reasons: during the state of tumefaction of the limb, no means could be adopted for confining the retracted condyle in its place, beyond that of the relaxation of the muscles; and both before the tumefaction has commenced, and after it has subsided, all endeavors to replace the condyle, or even to change the position of it, have failed." He even proceeds so far as to declare that, while attention ought to be given to the reduction of the inflammation by appropriate means, we ought, nevertheless, to instruct the patient to flex and extend the arm daily from the moment the accident occurs until the cure is completed, and without any regard to the consolidation of the fragment; "the exercise of the joint in this manner must constitute the principal occupation of the patient for several weeks; and should it be remitted during the formation and consolidation of the callus, much

¹ Med. Record, Dec. 22, 1888.

of the benefit which may have been derived from this practice will be lost, and will with difficulty be regained." With only slight qualifications I would adopt the advice of Mr. Granger.

The limb ought, at first, to be placed in a position of semiflexion, so that if ankylosis should unfortunately ensue, it would be in the condition which would render it most serviceable, and also because in this position the muscles which tend to displace the fragment would be most completely relaxed. While thus placed, an attempt ought to be made, by seizing the epiphysis, to restore it to position; and if the effort succeeds, as it certainly is not very likely to do, a compress and roller ought to be so applied as to maintain it in position; provided, always, that it shall not be found necessary to apply the roller so tight as to endanger the limb, or increase the inflammation. An angular splint would be an almost indispensable part of the apparel, at least with children, where this indication is in view. In no case, however, ought more than fourteen days to elapse before all bandaging and splinting should be abandoned, and careful but frequent flexion and extension be substituted.

[The plaster-of-Paris dressing after about the sixth day gives excellent results. The forearm should be placed at an angle of ninety degrees with the arm, midway between pronation and supination; the plaster bandage should be carefully applied from the wrist to the upper third of the arm, care being taken to cover the parts well with cotton wadding. The turns of the bandage should not press too firmly at the elbow. Examine the joint at the end of ten days, and renew the dressing. After the dressing is finally removed the motions are best restored by bathing with hot water and persistent use.]

In three cases seen by me, a displacement of the fragment, either forward or backward, has occurred whenever the arm was flexed, and it has been necessary, therefore, to treat the case with the arm in a straight position. These are plainly only exceptions to the rule.

§ 9. Fracture or Diastasis of the External Epicondyle. (Epicondyle, *Chaussier*.)

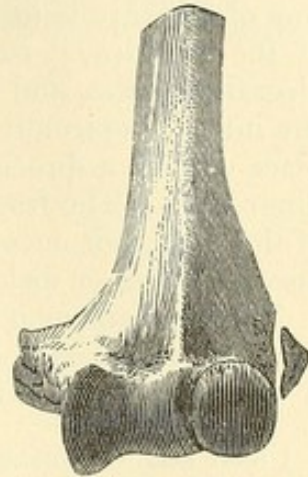The anatomy of the external epicondyle has already been described when speaking of the epicondyles generally. Like the internal epicondyle, it is composed in part of an epiphysis, and in part an apophysis projected from the shaft of the humerus, which portions become united to each other by bony tissue, usually about the sixteenth or seventeenth year of life; occasionally the consolidation is delayed much longer. It is very small, and serves for the attachment of some of the common extensors of the forearm and hand, and the external lateral ligament.

Whether this small epicondyle—speaking now of it as a whole, composed in part of the epiphysis and in part of the process from the shaft of the humerus—can be broken off or separated as a traumatic accident, and as a simple, uncomplicated fracture, needs no longer to be discussed. It is plainly impossible, unless the line of fracture includes a portion of the joint, and in that case it is to be designated as a fracture of the con-

dyle, and not of the epicondyle. At least I may say that no satisfactory clinical example or anatomical specimen has ever been presented. It is not difficult to admit, however, the possibility of a detachment of the epiphyseal portion prior to its consolidation with the shaft of the humerus: and, indeed, the occurrence of such an accident would seem quite probable, yet we lack any absolutely conclusive evidence that it has ever taken place.

The specimen of Zuckerkandl, of Vienna, will not bear the test of a critical examination. It was found in the dissecting-room, and is unaccompanied with any clinical history; but it is evidently from a person near the twentieth year of life. There is, indeed, an apparent absence of a portion of the external epicondyle, and there are two ossicula, situated in the external lateral ligament, with smooth, slightly bosselated surfaces. Dr. Z. explains the presence of two by supposing it was an exceptional process of development; but it is more difficult to explain how the epiphysis should have found its way into the lower or distal portion of the external lateral ligament, where he correctly states that it is situated. The supposed original seat is covered in by perfectly formed lamellated tissue, and underneath the situation in which the ossicula are found is a deep fossa fitted exactly to receive them.

FIG. 127.



Supposed fracture of the entire external epicondyle.

§ 10. Fractures of the Internal Condyle. (Trochlea, Chaussier and Malgaigne. Internal Oblique Trochlear Fracture, Denuce.)

According to the nomenclature which I have adopted, those fractures alone which involve the joint can be so designated. They are those fractures which, commencing outside of the joint above the base of the epicondyle, extend downward and outward through the articular surface of the bone; the condylar fragment carrying with itself more or less of the trochlea, in most cases passing through the olecranon fossa, the anterior fossa, and the groove of the trochlea.

I have a record of twenty examples of this fracture seen by myself, while the number of fractures of the external condyle recorded by me is twenty-nine; this difference in frequency being slight, but a little in favor of the external condyle.

Causes.—It has already been stated that fractures of the internal condyle, as well as fractures of the epicondyle, belong almost exclusively to infancy and childhood, only two instances having come under my notice after the eighteenth year of life. I have seen no instance which could be traced to any other cause than a direct blow, such as a fall upon the elbow, the force of the concussion being received directly upon the elbow.

M. Pingaud¹ thinks that even in this case the force applied acts indirectly, since it is applied usually to the posterior and internal surface of the olecranon

¹ Pingaud, Art. Coude. Dic. Encyc. des Sci. Méd., prem. sér. t. 21, p. 612.

process; and that the condyle yields to the pressure of the crest of the sigmoid cavity of the ulna, supplemented by the tension of the muscles and ligaments attached to the inner condyle.

Line of Fracture, Displacement, Symptoms.—The direction of the line of fracture is tolerably uniform; commencing at or near the centre of the trochlea, it extends obliquely inward through the coronoid and olecranon fossæ, and terminates about one-quarter or half an inch above the internal epicondyle. Displacement of the lower fragment can take place only in a direction upward, backward, forward, and inward (to the ulnar side). The fragment cannot be carried downward, in the direction of the hand, nor outward, in the direction of the radius, unless the radius also is broken or dislocated.

The most common form of displacement is upward and backward, and perhaps, at the same time, a little inward; the ulna remaining attached to the lower fragment, and following its movements.

I have seen one instance in which the fragment was carried directly downward toward the hand, but this action was originally complicated with a dislocation of the radius backward. The dislocation was immediately reduced. Five years after, when the man was twenty-three years old, I found the condyle displaced downward and forward about half an inch, so that when the forearm was extended it became strikingly deflected to the radial side.

The Symptoms which characterize this fracture are crepitus, almost always easily detected; mobility of the fragment, discovered especially by seizing upon the epicondyle, or by flexing and extending the arm; displacement of the smaller fragment and a projection of the olecranon process, this latter being very marked when the forearm is extended upon the arm, but almost completely disappearing when the elbow is bent; projection of the lower end of the humerus in front when the arm is extended; the humerus shortened when measured along its ulnar side, from the internal epicondyle; the breadth of the humerus through its condyles generally increased slightly, sometimes half an inch or more; if the lesser fragment is carried upward, it will also be found that when the limb is extended, the forearm will be deflected to the ulnar side.

Sir Astley Cooper remarks that it is frequently mistaken for a dislocation; and Markoe, of New York, has shown that it is, in fact, frequently complicated with a dislocation of the head of the radius backward; indeed, he expresses a belief that this dislocation of the radius seldom or never occurs without a fracture of the internal condyle.¹

Prognosis.—It is probable that in a majority of cases no permanent displacement exists; although the irregularity of the bony deposits around the base of the condyle, which generally may be easily felt, would lead to a contrary opinion. The fact that the lower fragment usually follows the motions of the olecranon, renders its replacement and retention comparatively easy, unless some complication exists. It is not from displacement, therefore, so much as from permanent muscular, and especially bony ankylosis, that serious maiming so often results. Under any treatment

¹ Markoe, *New York Journ. of Med.*, May, 1855, p. 382, second series, vol. xiv. Also paper read before N. Y. Surg. Soc., May, 1880.

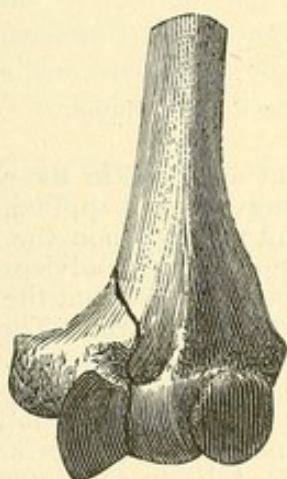
bony ankylosis will sometimes ensue, and under improper treatment it is almost inevitable.

[Powers,¹ of New York, reports twelve cases; nine perfectly recovered their functions; one had 5° short of complete extension; none had deformity.]

Poinsot says, that of five cases reported by Senftleben, only one recovered without ankylosis. In one case where ankylosis resulted, the operation of resection of the elbow terminated fatally.

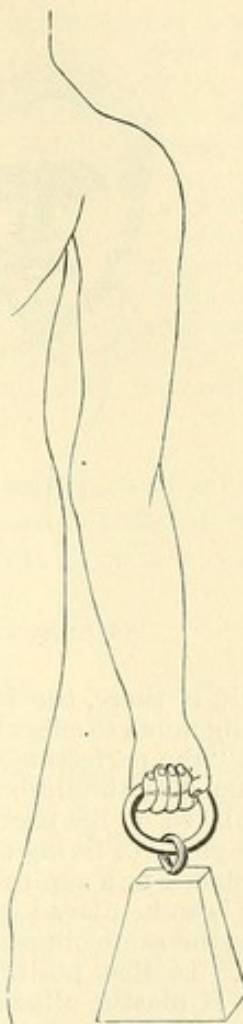
Treatment.—The arm must be immediately flexed to nearly or quite a right angle, when, without much manipulation, the fragments will be made to resume their place. A gutta-percha, or felt, right-angled splint, such as I have already directed for fractures occurring just above the condyles, well and carefully cushioned, may now be applied, and secured by rollers. Suitable pads must also aid the splint and roller, in keeping the fragments in place.

FIG. 128.



Fracture of internal condyle.

FIG. 129.



Position of the arm in carrying a weight.

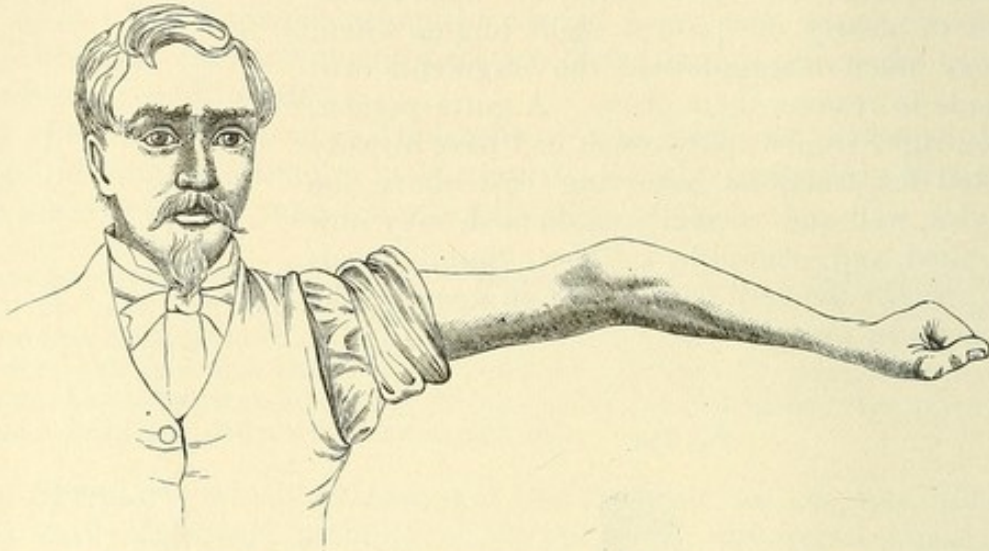Markoe prefers keeping the forearm in a position about ten degrees short of a right angle, believing that, in this position, the ulna itself will act as a splint, and, by its support on the uninjured portion of the trochlea, hold in its place the broken condyle. Very properly, also, he prefers to lay the angular splint, made of tin, and fitted to the arm and forearm, upon the back of the limb, instead of upon the front or sides. If it is upon the inside, it covers the broken condyle, and we are unable to know so well its position; if upon either side, it is apt to press injuriously upon the epicondyles; and if it is in front, the fragments cannot be so well adjusted or supported. Upon this point, however, surgeons are not very well agreed, and no doubt more will depend upon the care with which the splint is applied than upon the surface against which it is laid.

[A fact of much importance in the treatment of fractures of the condyles relates to the preservation of the normal angle of the forearm with the arm,

¹ Med. Record, Dec. 22, 1888.

which gives to the entire limb its "carrying function." This angle is such as to give an outward position of the hand when carrying a weight, the elbow resting naturally on the thigh. This angle may be lost either by the ascent of the internal condyle, or by the descent of the external condyle, and constitutes, in the opinion of Dr. Allis,¹ of Philadelphia, the usual deformity after fractures of the condyles. To prevent or overcome this displacement, which Dr. Allis attributes in part to the flexed elbow and the bandages and splints ordinarily used, he places the whole limb in a straight position. The radius and ulna at the elbow-joint then tend to bring the internal condyle into position, and

FIG. 130.



Deformity after fracture of the lower end of the humerus. (Allis.)

retain it there, the internal lateral ligament attached to the condyle and ulna aiding much to effect this result. The dressings are now applied, bearing in mind that "the perfection of the cure will depend wholly upon the natural position assumed by the limb while the dressing is applied." He advises that the patient be placed on his back, and both arms stripped, in order that the sound arm may be a guide in fixing the final position of the injured arm. The well arm is to be placed in a supine position, with the thumb looking outward, and the injured arm is to be placed in the same position. The forearm of the injured limb must form the same obtuse angle with the arm at the elbow as is noticed in the well arm. In that position, constantly maintained, the dressings are to be applied, and, if plastic, allowed to become firm. Dr. Allis prefers immovable dressings or a moulded splint. He applies a temporary dressing for a week, the patient being in a recumbent position; then he proceeds to the permanent dressing as follows: 1. An envelope of cotton, an inch thick, extends from the shoulder to the wrist, thickest at the bend of the arm; 2. A layer of bandages, applied sufficiently tight to compress the cotton and afford support; 3. The stiffening material selected—starch, plaster-of-Paris, etc.—is rubbed in, and a second and third layer of bandage is applied in the same way. The arm is kept in an easy position until the dressing is perfectly hard. He gives a simpler form of dressing as a substitute: Envelop the arm with cotton and then apply a single covering of bandage; cover the whole of this with adhesive plaster; this dressing may be applied from first to last; it has this advantage, that it permits the patient to flex the joint a little.]

Considerable swelling is almost certain to follow, and no surgeon ought to hazard the chances of vesications, ulcerations, etc., by neglecting to open or completely remove the dressings every day. Within seven days,

¹ Trans. Med. Soc. of Pennsylvania, vol. xiii. part ii.

and perhaps earlier, passive motion must be commenced, and perseveringly employed from day to day until the cure is accomplished; indeed, in many cases it is better not to resume the use of splints after this period; for, although at this time no bony union has taken place, yet the effusions have somewhat steadied the fragments, and the danger of displacement is lessened, while the prevention of ankylosis demands very early and continued motion.

[The liability to excessive swelling, vesications, etc., occurs only after severe injuries, and during the first week. The patient should, at first, remain in a recumbent position with light dressings. When this danger is passed the permanent dressing should be applied, and not removed until union has taken place, unless there are indications that it is doing harm. Constant efforts at passive motion will prove injurious, unless performed by most skilful hands. The better rule is to apply the permanent dressing, as recommended above, and when union is complete restore action to the joint by passive motion and voluntary efforts of the patient, combined with the use of hot fomentations. The liability to permanent ankylosis under this course of treatment is slight. If the fracture is treated with the limb in a straight position, as described by Allis, and ankylosis is apprehended, great care must be taken to secure a flexed position of the forearm; but, unless the ankylosis is due to displacement or callus, the motions of the joint are rapidly regained by gymnastic exercises.]

When the fracture is compound, or otherwise complicated, these simple rules will seldom be found applicable; indeed, fractures attended with no such complications will occasionally be found difficult to reduce, or to maintain in position after reduction.

§ 11. Fractures of the External Condyle.

It is necessary again to call attention to the fact that the author recognizes no fractures as fractures of the condyles, either external or internal, which do not enter the joint. All not included in this definition, and occurring in these regions, are epicondylar fractures or diastases.

Causes.—All the fractures (29) of the external condyle, of which I have a record, occurred in children under fifteen years of age, except two; one, in which a woman, eighty-eight years of age, fell upon her elbow when intoxicated, breaking off the outer condyle. In a large majority of these cases the patients themselves have affirmed, and the surface of the skin has furnished conclusive evidence, that the fracture was produced by a direct blow, generally by a fall upon the elbow.

Line of Fracture, Displacement, and Symptoms.—The direction of the fracture is generally such that, commencing at or just within the capitellum, or articulating surface upon which the radius is received, it terminates above and to the outer side of the external condyle; or, commencing at the middle of the trochlea, it passes through the olecranon fossa and terminates above the condyle, externally.

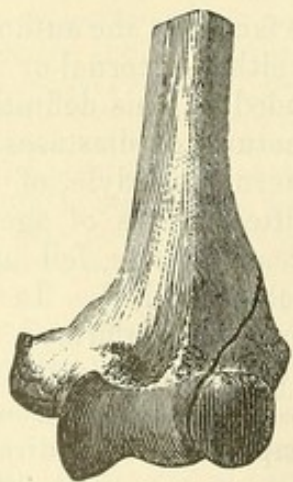It is quite probable that in the latter case the force which occasioned the fracture has been applied directly to the olecranon, and only indirectly to the condyle, as suggested by Pingaud; but this theory of mechanism could not apply to the first class of cases, or those in which the line of fracture is through or just within the capitellum, and which, I think, is the most common. It is in these cases especially, the line of separation being more superficial, that the fragment

is liable to become displaced backward, forward, or outward; generally, I have found it displaced a little outward, sufficiently to increase manifestly the breadth of the condyles, or it has been carried backward; once slightly forward; it is also, in some cases, carried upward in a small degree, although the action of the supinators and extensors would seem to render a downward displacement more common. These displacements are usually not considerable, and in a few cases there is none at all. Whatever may be the direction or degree in which the fragment is moved, the head of the radius is found almost always to accompany it; but in the case which I am about to relate, the head of the radius became completely separated from the condyle.

F. K., æt. eleven years, fell from a load of hay, and he is confident that he struck the ground with the back of his elbow. Six hours after the accident the arm was much swollen, and the external condyle could not be distinctly felt; but when pressure was made directly upon it, crepitus and motion became manifest. The head of the radius was at the same time dislocated backward, and separated entirely from the condyle, its smooth, button-like head being very prominent. It is difficult to conceive how a blow from behind should leave the head of the radius dislocated backward, or how the radius could have separated from the broken condyle; but as the examination was repeated several times, and while the patient was under the influence of ether, I have no doubt of the fact. Several other surgeons who were present concurred with me in opinion fully. While prosecuting the examination, I reduced the dislocation of the radius, but it would not remain in place a moment when pressure or support was removed. The lad recovered with a very useful arm, the motions of flexion and extension, with pronation and supination, after the lapse of a year, being nearly as complete as before the accident, the radius remaining unreduced.

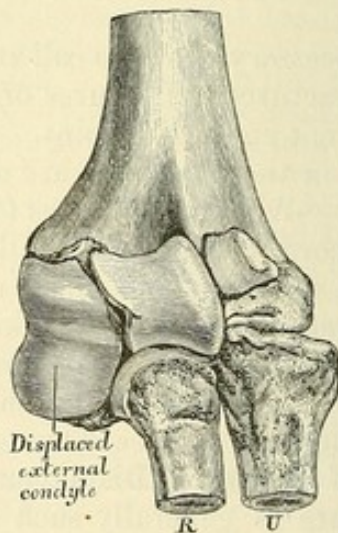
Sometimes it will be noticed that while the portion of the condyle which is attached to the radius falls backward, its upper and broken extremity pitches forward; and this attitude it is especially prone to

FIG. 131.



Fracture of the external condyle through the capitulum.

FIG. 132.



Displaced external condyle with dislocation of radius and ulna. (Bryant.)

assume when the forearm is extended. It is even possible, when the fracture traverses the trochlea, for the ulna also to become displaced backward along with the radius and the lesser fragment. (Fig. 132.) Crepitus, which is usually very distinct, is most easily obtained by rotating the radius, or by seizing upon the condyle with the thumb and fingers, and moving it backward and forward.

[Bryant,¹ of London, resected the elbow-joint of a boy, æt. 10, six weeks after the injury, who fell upon his hand with his arm extended. The external condyle had been broken and vertically displaced; the head of the radius and ulna were both displaced inward and well locked by processes of bone, the coronoid process was in contact with the outer portion of the internal condyle, and its outer edge with the inner margin of the trochlear surface of the humerus. The head of the radius rotated on the displaced inner half of the articular facet of the humerus, with its outer edge in contact with the displaced external condyle.]

Prognosis.—Ordinarily, this fragment unites promptly, and by the interposition of a bony callus; but in five cases, I have noticed that either no union has occurred, or the union has been accomplished only through the medium of fibrous structures, and the fragment continued afterward to move with the radius. As a consequence, probably, of the displacement of the lesser fragment upward, the forearm, when straightened, is occasionally found deflected to the radial side. The surgeon must not, however, confound the deflection which is natural, and which is greater in children than in adults, with the unnatural radial inclination which is occasioned sometimes by this accident.

I have met with this phenomenon three times in children under three years of age, in one of which I could not discover that the condyle was carried toward the shoulder, but only outward; in each of the other cases the fragment had united by ligament. The following is one of the examples referred to:

A girl, æt. 3, fell and broke the external condyle of the left humerus, the fracture extending freely into the joint; crepitus distinct; forearm slightly flexed; prone. Lesser fragment displaced outward and a little backward, carrying with it the radius. On the second day I was dismissed on account of the unfavorable prognosis which I gave, or rather because I refused to guarantee a perfect limb, and an empiric was employed. Several months after the accident the father brought her to me for examination. There was no ankylosis, but the lesser fragment had never united, unless by ligament, moving freely with the head of the radius. When the forearm was straightened upon the arm, it fell strongly to the radial side, but resumed its natural relation again when the elbow was flexed. Two other examples are reported at length, in the second part of my Report on Deformities After Fractures. In one other example, however, mentioned also in my report, the deflection was to the opposite side. I examined the lad one year after the accident, he being then five years old, and I found the external condyle very prominent and firmly united, but not apparently displaced in any direction except outward. The radius and ulna had evidently suffered a diastasis at their upper ends, but all of the motions of the joint were free and perfect.

In more than half of the cases of fracture of this condyle some degree of ankylosis has resulted, lasting at least several months. I have seen it remaining after a lapse of from one to twenty years, but generally it gradually diminishes, and, in a majority of cases, completely disappears after a few years.

Treatment.—Generally, the forearm ought to be flexed upon the arm, especially with a view to overcome the usual tendency in the upper end of the lower fragment to pitch forward, and which form of displacement is greatly increased by straightening the arm.

A remarkable exception to this rule, and one of two which I have seen, must be mentioned. James Cronyn, aged 6, was brought to me in March, 1857,

¹ Practice of Surgery, 4th edition, 1885.

having, a few minutes before, fallen from a height of four or five feet to the ground. His father said the elbow had been broken at the same point two years before, and from that time had remained stiff and crooked. I found the external condyle broken off, and, with the head of the radius, carried backward. This was the position which it occupied constantly, although it was easily restored and maintained in position when the arm was straight, but not by any possible means when the elbow was flexed. I dressed the arm, therefore, in an extended position, with a long felt splint, and the fragments remained well in place until a cure was accomplished.

It is especially deserving of notice that, in the five cases in which I have observed bony union to fail, and the fragments to continue movable, the motions of the elbow-joint have, in a very short time, been completely restored. This fact must abate our apprehensions of the supposed evil results of non-union in the case of fracture now under consideration.

The opinion of Dr. John C. Warren, of Boston, as stated by Dr. Norris in his Report on Surgery, is as follows:

"In the treatment of fractures of the condyles of the os humeri, a course is usually recommended which he believes to be hurtful, inasmuch as it favors the worst consequences of the injury, namely, loss of motion in the joint. By this mode of treatment, the fractured piece becomes sufficiently fixed to create partial ankylosis; and there is so much pain afterward in the proposed passive movements as to cause the omission of these measures until permanent stiffness takes place. The proper course in the management of these accidents, he conceives to be—1st. To apply no splints, but in the earlier days to make use of the proper means to prevent inflammation. 2d. To accustom the patient to early and daily movements of flexion and extension. 3d. When the action of the joint becomes limited, to overcome the resistance by force, and repeat it daily until the tendency of the joints to stiffen ceases."¹

My respect for the distinguished surgeon whose opinion is here given does not permit me to question the correctness of his practice; but I cannot avoid a belief that his language does not convey a precise idea of his views. If he intends to say that he would move the joint freely when it is suffering from acute inflammation, and when motion occasions great pain, I must protest against the practice as likely to do vastly more harm than good in any case; but if he would move the joint from the first, when the inflammation and swelling are trivial, and when it occasions only a moderate amount of pain, then his views are just, and his practice worthy of imitation.

§ 12. Fractures of the Articular Processes of the Lower End of the Humerus; wholly within the Capsule.

Three examples illustrating this variety of fracture have been referred to by Stimson.² The first was seen by Laugier,³ in the person of a girl seventeen years old, who had fallen upon her hand. It was not followed by swelling or by effusion within the joint. Laugier considered it a fracture of the trochlea alone. The treatment consisted in rest, the forearm being slightly flexed and pronated. In a few weeks recovery took place, with complete restoration of the functions of the arm.

The second case is from Gurlt,⁴ a museum specimen, without history. It is an adult bone. The trochlea and capitellum are broken off and displaced forward and upward, and have reunited with the bone above the coronoid fossa; the articular surfaces being still covered with cartilage.

¹ Transactions of the American Medical Association, vol. i. p. 174.

² Stimson, Treatise on Fractures, p. 413.

³ Laugier, Arch. Gén. de Méd., 1853, v. i. p. 45.

⁴ Gurlt, Knochenbrüchen, vol. ii. p. 801.

The third¹ is that of a woman, æt. 67, who having received an injury upon her elbow, the surgeon diagnosticated a fracture of the neck of the radius; but the patient having died four years later, the capitellum was found broken off and displaced; having reunited with its upper border resting in the radial depression (fovea minor). The head of the radius was not broken.

The same difficulties present themselves here as in the supposed examples of intracapsular fractures of the head of the humerus. In the clinical example related by Laugier, the exact line could not have been absolutely determined. And this difficulty is illustrated by the third case, in which the clinical diagnosis was greatly at fault. The third case also, where an autopsy was made after four years, can only be regarded as furnishing conclusive evidence that the capitellum was broken; inasmuch as the changes in its form and size, caused by absorption, as we have seen, happens in intracapsular fractures of both the heads of the humerus and femur, must render it difficult to say that the line of fracture was not outside of the capsule. The second case was a museum specimen, unaccompanied with a history, and for the same reason there can be no conclusive evidence that it was intra-articular. Whenever we find a recent accident, in which the autopsy shall show that the line of fracture was wholly within the capsule, the testimony will be conclusive. At present this kind of testimony is wanting.

CHAPTER XXII.

FRACTURES OF THE RADIUS.

FRACTURES of the radius occur more frequently than of any other bone of the skeleton, except perhaps the clavicle. The location of these fractures may be seen in the following analysis:

Of 127 fractures of the radius which have been recorded by me, not including gunshot fractures, or fractures demanding immediate amputation, 3 belonged to the upper third, 10 to the middle third, and 114 to the lower third. Of those belonging to the lower third 7 were through the shaft, more than two inches above the lower end; 2 were fractures of the styloid processes; and the remainder, 105, were Colles's fractures. 5 were compound, and 122 simple. 69 are reported as occurring in males, and 58 in females; 61 as having occurred in the left arm, and 41 in the right.

Fractures of the Head.—Most of the fractures of the head of the radius which have been satisfactorily demonstrated, were longitudinal or nearly so.

In Dr. Mütter's collection are two specimens of fracture of the outer half of the head of the radius. In one the small fragment is slightly displaced downward in the direction of the axis of the bone; and in the other the fragment is thrown outward, or to the radial side. Both are firmly united in this position. Stimson says, in his treatise on *Fractures*, that he met with two cases, in one of which the injury was the result of a direct blow, and the other was accompanied with a dislocation of the radius and ulna backward. In both cases he practised resection, but he does not say with what result. He has seen, also, one other case treated by Dr. Townsend, of Bellevue Hospital, in which one year after the accident the fragment remained movable, but the motions of the joint were completely restored.

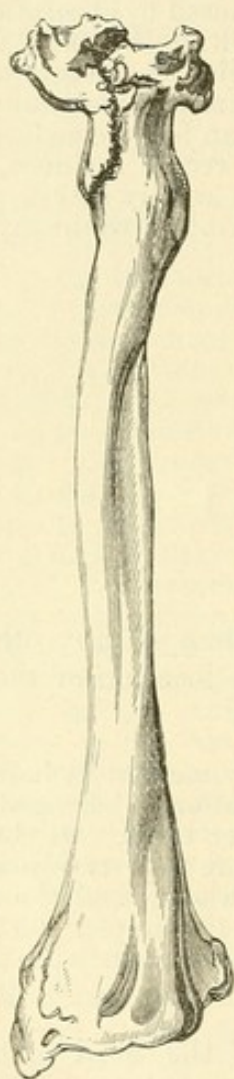
¹ Gurlt, op. cit., vol. ii. p. 831.

Bruns¹ has collected twenty-two cases of longitudinal fracture of the head, recorded or observed by Hodges,² Verneuil,³ Flower,⁴ Gross,⁵ Gurlt,⁶ Weichselbaum,⁷ Lesser,⁸ Hüter,⁹ and himself, respectively. Malgaigne has also mentioned one.¹⁰

[Many additional cases have been reported during the last few years.]

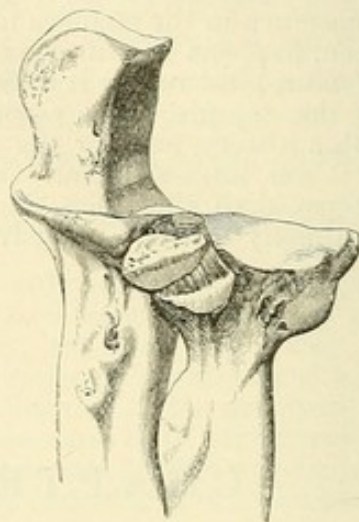
According to Bruns, this fracture "may be incomplete, and then the fissure may be single or multiple. When it is complete, a fragment of

FIG. 133.



Fracture of head of radius. (Mütter's Collection. Specimen A, No. 105.)

FIG. 134.



Gross's specimen.

the anterior border is generally found separated from the bone; at times, then, the fracture is entirely intra-articular, and the fragment of bone is loose in the interior of the joint; at others it extends beyond the articulation, and the fragment may be held in place by the annular ligament. Fracture of the head of the radius may be isolated (five times out of twenty-two cases), but more often it is complicated with lesions of the neighboring bones (four times with fracture of the external condyle, three times with fracture of the olecranon, of the coronoid process, and of the neck of the radius, twice with fracture of the olecranon and the coronoid process, twice with a fracture of the coronoid process and a dislocation of the forearm, once with fracture of the shafts of the humerus and ulna and dislocation of the radius forward.)

As may be seen, the most frequent complication is fracture of the coronoid process.

¹ Bruns, des frak. des radius kopfchens, *Centralblatt für Chir.*, 1880, No. 22, pp. 353-358.

² Hodges, *Bost. Med. and Surg. Journ.*, Dec. 6, 1866, p. 383, and 1877, p. 65.

³ Verneuil, *J. Javay, Frac. des Artic.*, Thèse d'agrég., Paris, 1851.

⁴ Flower, *Holmes's Surg.*, vol. ii. 2d ed. p. 791.

⁵ Gross's *Surg.*, 1859, p. 181.

⁶ Gurlt, *Handbuch der Lehre von den Knochen*, 2d theil, Berlin, 1865, p. 810.

⁷ Weichselbaum, *Virchow's Arch.*, Bd. 57, p. 127.

⁸ Lesser, *Deutsche Zeitschrift für Chir.*, Bd. 1, p. 292.

⁹ Hüter, *Verhandl. der Deutschen Gesellschaft für Chir.*, V. Kongress, 1876, p. 39.

¹⁰ Malgaigne, *Poinsot, op. cit.*, p. 332 et seq.

"Although fracture of the head of the radius is sometimes produced by a direct injury, it is most frequently the result of an indirect cause, such as a fall upon the hand, the arm being extended; in this position, indeed, the external condyle comes in contact only with the anterior part of the head of the radius. This fracture sometimes occurs when the forearm is in a state of extreme flexion; in such case it is probably the result of violent contact of the anterior border of the head with the anterior surface of the humerus."—*Poinsot*.

[Gross illustrates a fracture of the head of the radius in his collection in which a portion of the head has been chipped off and permanently united to the contiguous border of the coronoid process of the ulna. (Fig. 134.)]

The diagnosis of this accident is in many cases difficult. Occasionally, when the fracture is complete, a movable fragment may be recognized, with crepitus; and in other cases its existence may, perhaps, be inferred from the increased breadth of the head of the radius, the condition simulating a partial dislocation forward.

[Powers,¹ of New York, who analyzed fourteen cases, states that the diagnosis must rest on the recognition of the movable fragment of bone; crepitus about the joint he regards as too deceptive.]

Bruns says that out of seven observations where the results could be established, three times bony consolidation occurred, once the fragment united by callus to the coronoid process, and three times the isolated fragment finally became a truly foreign body in the articulation. Hüter, in his case, was obliged to resort to arthrotomy in order to extract this foreign body of a new kind. Kofmohl² affirms that a longitudinal fracture of the head of the radius is more common in childhood than in adult life, he having met with seventeen cases in a total of fifty-two fractures of the forearm, and twelve of the subjects were from one to four years of age. He states, moreover, that it is caused most often by lifting the child by the arms; that the pain accompanying the accident is usually felt at the wrist, and that the results are of the simplest kind, the functions of the limb being completely restored in from three to four weeks. In my opinion, these statements of Kofmohl ought to be received with much hesitation.

The treatment of this fracture, in case it be recognized, ought to be directed chiefly, as in most other fractures involving joints, to the prevention of ankylosis, by careful but persistent motion of the joint by flexion and rotation. The result might be a fibrous union, or perhaps non-union and necrosis of the fragment; but even this latter result would be no more serious than a permanent ankylosis.

[The persistent motion recommended will, in the practice of most surgeons, result in non-union, which would be an unfavorable result. The more consistent course of treatment would be complete rest to the injured parts until union is perfected, and subsequent motion, both passive and active.]

It is probable, however, that in most cases a more or less flexed position of the arm, with supination, will insure the most satisfactory results. In case ankylosis were to result, the flexed position, at a right angle, would give the most useful arm.

b. Fractures of the Neck.—Fracture of the neck of the radius, as a simple accident, uncomplicated with any other fracture or dislocation, is

¹ Med. Record, Feb. 25, 1888.

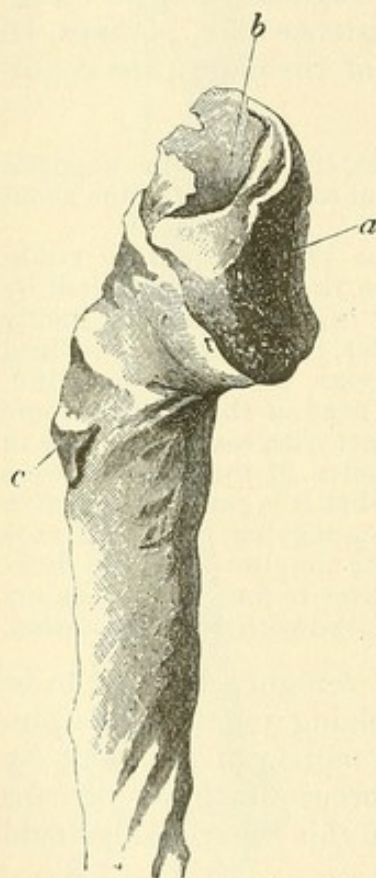² Kofmohl, Ueber den intrakap., Bruch des radius, etc., Wiener med. Presse, No. 12, p. 369, 1879.

exceedingly rare; yet, owing to the depth of the superincumbent mass of muscles, and the difficulty of determining, where so many bones and processes approach each other, precisely from what point the crepitus, if any is found, proceeds, surgeons have often been deceived.

The case reported by Dr. Markoe to the New York Pathological Society will serve to illustrate the same point; the signs of a fracture of the radius at its neck were such as to deceive that experienced surgeon, yet the autopsy disclosed the fact that it was a dislocation of the head of the radius forward, with a fracture of the ulna.

I have seen no specimen obtained from the cadaver, except the doubtful one contained in Dr. Watt's cabinet, and the specimen owned by the late Dr. Mütter, of Philadelphia, of which he has kindly furnished me the following description:

FIG. 135.



Fracture of neck of radius. (Mütter's cabinet.) *a*. Original articulating facet. *b*. New articulating facet. *c*. Projecting fragments.

"History unknown. The line of fracture seems to have passed through the neck of the left radius, just at the upper extremity of the bicipital protuberance. Union with deformity has resulted. Owing to the fracture having taken place within the insertion of the biceps, that muscle appears to have drawn forward and upward the lower end of the short upper fragment. In consequence of this movement, the articulating facet of the head of the radius is tilted backward, so as no longer to be in contact with the humerus. As a secondary consequence, the anterior edge of the head of the radius rests permanently against the articulating surface of the humerus. At this new point of contact a new surface of articulation is seen to have been formed, while the original articulating facet is directed backward, and lies at right angles to the one of more recent formation. At the inner edge of the new articulation of the head of the radius with the humerus, contact with the ulna has developed another surface of articulation. The upper and lower fragments are united at an angle, and the radius does not appear to have lost in length."

Velpeau has once demonstrated the existence of this fracture in a dissection, but the fracture was accompanied with a fracture also of the coronoid process; and Bérard obtained possession of a similar specimen. Malgaigne affirms, with his usual frankness, that although he has occasionally believed that he had met with it, the autopsy, whenever it has been obtained, has shown that it was rather a subluxation than a fracture.

Diagnosis.—The presence of what appear to be the rational diagnostic signs has compelled me to record one case as an uncomplicated fracture of the neck of the radius, and two others as fractures at this point accompanied either with a fracture of the humerus or a dislocation of the ulna. I am prepared to admit that some doubt remains in my own mind as to whether in either case the fact was clearly ascertained; nor do I think, speaking only of the simple fracture, that it will ever be safe to declare positively that we have before us this accident.

Nothing, perhaps, could more fully illustrate the difficulty of diagnosis in the case of injuries received in the neighborhood of the head or neck of the radius

than the testimony given in the case of *Noyes vs. Allen*, tried in the Supreme Court at Cambridge, January, 1856, before Judge Bigelow. Mr. Noyes injured his elbow, January 7, 1854, and Dr. Allen, who was called immediately, believed that the ligaments of the joint had been torn, but that no bones were broken or displaced. On the following morning he was dismissed, and Mr. Noyes went home. Three weeks later it was seen by Dr. Dow, who also thought there was no fracture. About eight weeks after the accident a physician examined the arm, and declared the neck of the radius broken, and the fragments displaced; and when the case was finally brought to trial he testified still that such was certainly the fact; and five other physicians, not one of whom, however, we are told, was a member of the State Medical Society, testified positively that the radius was broken at its neck, producing a bony protuberance; that such an injury only could account for the symptoms manifested at the time of the accident, and that no other fractures or injuries of the joint could explain so well the present appearances of the arm. While, on the part of the defence, six of the most intelligent medical gentlemen of the State, Drs. Kimbal and Huntington, of Lowell, and Drs. Townsend, Lewis, Clark, and Gay, of Boston, testified that the head and neck of the radius were not displaced, nor was there any evidence that this bone had ever been broken. There is every reason to believe that these latter gentlemen were correct; yet it is to be presumed that the gentlemen who first testified were not without some grounds for their opinions so confidently expressed. The case was given to the jury after a trial of five days, which promptly returned a verdict for the defendant.¹

When the fracture occurs, the upper end of the lower fragment will probably be carried forward by the action of that portion of the biceps which has its insertion into the tubercle; and the displacement in this direction must necessarily be increased in proportion as the arm is straightened. In the cabinet specimen belonging to Dr. Mütter (Fig. 135), the line of fracture commencing in the neck, has terminated in the tubercle; consequently the biceps, having still some attachment to the upper fragment as well as the lower, has drawn them both forward. The same anterior displacement I have noticed in all of the supposed living examples, but whether both fragments or only one had suffered displacement I am unable to say.

A girl, æt. 11, fell from a tree, and injured her right arm. Her surgeon, who regarded it as a fracture of the neck of the radius, reduced the fragments, and placed the forearm at a right angle with the arm. On the twenty-eighth day all dressings were removed, and the patient was dismissed, the fragments seeming to be in place. The parents, finding the elbow stiff, now made violent and successful efforts to strengthen the arm. Fifteen months after the accident, the child was brought to me. There was at this time a bony projection in front, opposite the neck of the radius, which I believed to be the point of fracture. The hand was forcibly pronated, and she had only a limited amount of motion at the elbow-joint. The ankylosis was probably due to inflammation directly resulting from the severe contusion; but it is quite probable that the forward displacement of the fragments was alone due to the too early and too violent attempts to straighten the arm; at least, this was the explanation which I ventured to give to the parents at the time.

The second case occurred in a lad eight years old. His parents brought him to me ten weeks after the injury was received, and I then found the forearm bent to a right angle with the arm, and ankylosed at the elbow-joint. The hand was also forcibly pronated, and could not be supinated. In front, and opposite the neck of the radius, there was a distinct bony projection, which I believed to be the point of union of the bony fragments. The external condyle seemed also to have been broken.

¹ Amer. Med. Gazette, vol. vii. p. 299.

The third example was seen by me six months after the accident. The upper end of the lower fragment seemed to be displaced forward. There was very little motion at the elbow-joint, and both pronation and supination were completely lost.

Treatment.—Flex the forearm upon the arm, to relax, as completely as possible, the biceps, whose advantageous insertion into the tubercle of the radius would be certain to produce displacement, unless this position was adopted. A single dorsal splint, properly padded, should support the forearm, while the surgeon, having placed a compress over the upper end of the lower fragment, proceeds to secure the whole with a roller. Especial care must also be taken to prevent the forearm from being extended before the bony union is fairly consummated, lest the biceps, now firmly contracted, should draw the lower fragment forward, as it must inevitably do while the bony union is imperfect; an accident which there is some reason to believe, occurred in one of the examples which I have already cited. If the patient be a child, or if there is any reason to suppose that these rules will not be faithfully complied with, it would be well to secure the arm in this position with a right-angled splint.

Fractures below the Insertion of the Biceps, and above the Insertion of the Pronator Radii Teres.—When the bone is broken anywhere in this portion, the action of the pronators upon the upper fragment ceases; while that of the biceps, which is a powerful supinator, continues; consequently the upper fragment becomes at once, and completely, rotated outward or supinated. Now, if the hand, to which the lower end of the radius alone remains attached, should be forcibly pronated, the radius will also be rotated inward upon its own axis; and although it might be possible in this condition to bring the broken ends into contact, and a bony union, without deformity, might be consummated, yet the power of supination must be forever lost; since the union has been effected while the head and upper fragment are already in a state of complete supination; and if such is the fact, it is evident that the whole bone, together with the hand, will be incapable of any further supination.

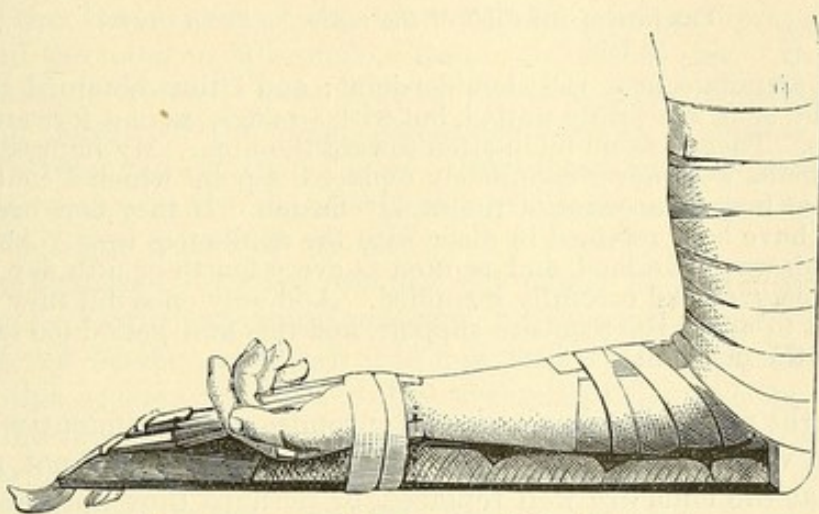
It is not, indeed, the practice with any surgeons, as far as I know, to treat this fracture with the hand placed in a position of extreme pronation; but the case has been supposed for the purpose of rendering the argument more intelligible. The usual practice is to place the forearm and hand in a position midway between supination and pronation, and then to lay it across the body at a right angle with the arm; but it is plain that the same objection, differing only in degree, will apply to this position as to that of pronation. The axes of the two fragments are not made to correspond, since, while the lower fragment is only half rotated outward, the upper fragment is completely, and the result of the union must be the loss of one-half the power of supination in the hand.

It is only, then, by complete supination of the hand during treatment that this difficulty can be avoided, and I have no doubt that we ought to adopt this plan, whenever it is practicable to do so, or whenever we are not hindered by serious obstacles; and the only obstacle which occurs to me as likely to interpose itself, is the practical one which most surgeons must have experienced in treating all injuries of the forearm, whether fractures or only severe contusions of the muscles, etc., namely,

the constant and almost uncontrollable tendency of the hand to assume the prone or semi-prone position. This is due, no doubt, to the great preponderance of power in the pronators; and such is the resistance which they afford to supination that it is often quite impossible to lay the hand upon its back while the forearm is across the body, and, if accomplished, the position generally becomes in a few hours so painful as to be intolerable. By extending the arm, however, and laying it upon a pillow, the hand will be found again to rest easily upon its back, because in this way we avail ourselves of the outward rotation of the humerus at the shoulder-joint.

Dr. X. C. Scott, formerly Resident Surgeon to the Brooklyn City Hospital, in his inaugural thesis, has discussed very fully the advantages of this position in

FIG. 136.



Scott's apparatus for fracture of the forearm.

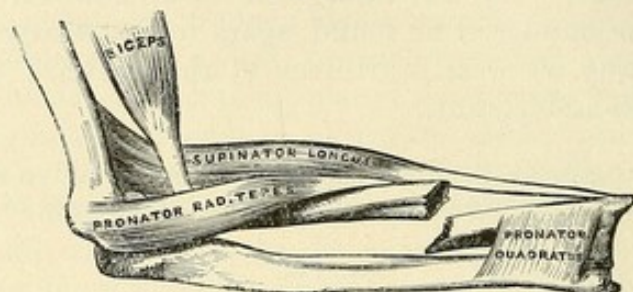
many fractures of the forearm, and he has devised a very ingenious mode of securing the limb after supination is effected, adding also a moderate amount of extension by adhesive plasters and elastic bands.

Fractures of the Shaft.—It has been already stated that of the whole number of fractures of this bone recorded by me, amounting in all to 127, only 10 belonged to the middle third; an observation which is in striking contrast with the remark of Chelius, that it is broken most frequently in its middle. If the fragments are completely separated in the middle third, the lower end of the upper half is drawn forward by the action of the biceps aided by the pronator radii teres, in case the fracture is below its insertion; while the lower fragment is tilted toward the ulna by the conjoined action of the supinator radii longus and pronator quadratus. But as to the direction of the displacement, much will depend upon the direction of the force by which the fracture has been occasioned.

A laboring man, æt. 35, broke the radius near the lower end of the middle third. On the same day I replaced the fragments as well as I could in the midst of the swelling which had already occurred, and applied two broad and well-padded splints, one to the palmar and one to the dorsal surface of the forearm. On the twenty-eighth day I first discovered that the fragments were projecting in front, and I at once proposed to thrust them back by force, but the

patient declined allowing me to do so. I then applied a compress near the summit of the projection, but not exactly upon it, lest it should cause ulceration, and secured over this a firm splint. At first this seemed to produce a change in the fragments, but after a couple of weeks I found there was no improvement, and it was discontinued. About six months after the fracture occurred, this man had the same arm terribly lacerated in a railroad accident, and I was

FIG. 137.



Fracture of the shaft of the radius. (From Gray.)

obliged to amputate near the shoulder-joint; and I thus obtained the broken radius. The bone was firmly united, but with an angle, salient forward, of about ten degrees. There was no inclination toward the ulna. My impression is that these fragments were never completely replaced, a point which I could not well determine at first on account of the rapid effusion. If they had been, I think they could have been retained in place with the appliances used. Almost every day the limb was examined, and as often as every fourth or fifth day the dressings were removed and carefully reapplied. And only once did they become so loose as not to afford the requisite support, and this at a period too late to have occasioned the deformity.

We ought not to be deceived, and promise too confidently a perfect limb, even when but the radius is broken, since we may not always be certain that the ends are well replaced, or perhaps they may become displaced subsequently, and in either case we are not likely to discover the deformity until the swelling has subsided, and it is too late to apply the remedy.

In the treatment of fractures of the middle third, the same rules, with only slight modifications, will be applicable, as in fractures of both bones. Two straight, long, and broad splints must be applied after being carefully padded; and especial attention should be paid to the tendency of the fragments to become displaced forward and toward the ulna through the action of both the biceps and the pronator radii teres; a tendency which may in some measure be provided against by flexion of the arm, but which must be overcome chiefly by steady and well-adjusted pressure, near, but not upon, the ends of the fragments.

Fractures of the Lower End.—Fractures of the lower third, occurring above the line of Colles's fracture, are almost as rare as fractures of the middle or upper third.

I have recorded seven; one example of which it will be proper to relate: G. V., æt. 30, was admitted to the Buffalo Hospital with a fracture of the right radius about three and a half inches above its lower end. The hand was prone, and inclined to the radial side; while the broken ends of the radius fell against the ulna, from which it was found difficult to separate them. The lower end of the ulna was prominent, and projecting upon the ulnar margin of the

hand. I was unable completely to separate the fragments of the radius from the ulna, by either pressure with my fingers between the bones, or by seizing upon them with my thumb and fingers. Having, however, adjusted them as well as possible, I flexed the arm, and applied a broad and well-padded splint to the palmar surface of the forearm, securing it in place with a paste bandage. These dressings were finally removed at the end of four weeks, when I found scarcely any displacement or deformity remaining.

Most of these fractures of the shaft in its lower end, when properly treated, result in perfect limbs. In a certain proportion, however, it will be found impossible effectually to resist the action of the pronator radii teres and of the quadratus, and the fragments will unite at an angle resting against the ulna, and sometimes, by the interposition of intermediate callus, they will become firmly united to the ulna. Occasionally, also, especially where the fracture has been produced by a fall upon the hand, and the radio-ulnar ligaments of the wrist have been torn or stretched, the lower end of the ulna will be found to project permanently, and the hand to fall more or less to the radial side. In examples of this kind, of which I have seen one or two, the cause and, to some degree, the manner of the displacement are such as to entitle them perhaps to be regarded as true Colles's fractures; but we have found it convenient to restrict the use of this title to fractures occurring within at least one inch and a half of the joint.

Colles's Fracture.—I have retained the name "Colles's fracture," so long in use by English-speaking surgeons, for the reason that it is familiar to most of my readers, although it is now well known that Pouteau first described this accident.¹ Of the 114 fractures belonging to the lower third of the radius, 105 were near the lower end, or within from half an inch to one inch and a half from the articular surface: all, except 2 styloid fractures, being included in that class known as "Colles's fractures," most of which were no doubt true fractures, and probably a small proportion separations of the epiphyses.

[Double Colles's fractures are very rare. McIntyre,² of St. Louis, reports such a case. The patient was a man, aged nineteen, who fell from a roof; he recovered, with good use of both arms. Bryden³ reported a similar case occurring in a sailor, who fell thirty feet to the deck of a ship.]

Colles, in his paper on this subject, described the fracture as occurring always about one inch and a half above the carpal end of the bone;⁴ but Robert Smith, who has carefully examined all of the cabinet specimens he could find, about twenty-three in number, has never seen the line of fracture removed farther than one inch from the lower end of the bone, and in several specimens it was within one-quarter of an inch of this extremity. Dupuytren has also described the fracture as occurring from three to twelve lines above the joint.

¹ Pouteau, *Œuvres Posthumes*, t. ii. p. 251, 1783; also Nélaton, *Chir. Path.*, t. i. p. 739.

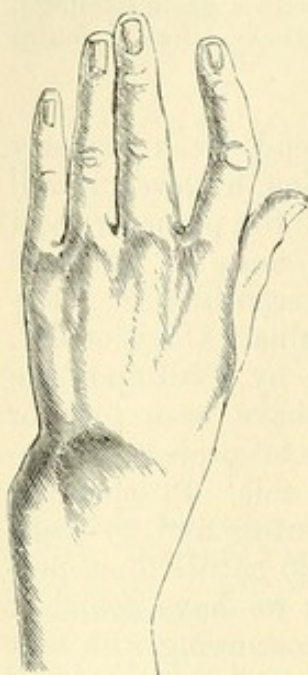
² *St. Louis Med. and Surg. Journ.*, 1885.

³ *Brit. Med. Journ.*, Dec. 8, 1883.

⁴ Colles, *Ed. Med. and Surg. Journ.*, vol. x. p. 182, 1814.

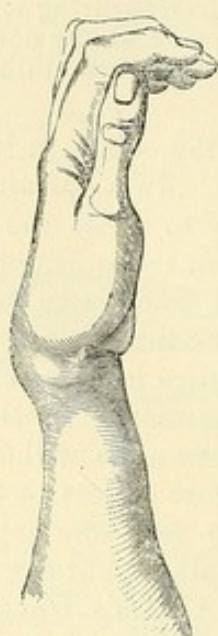
M. Trèlat¹ thinks that in the fractures of old people the line of separation is ordinarily quite at the inferior extremity of the bone.

FIG. 138.



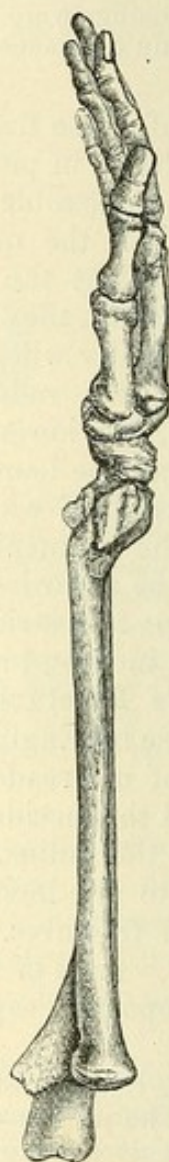
Fracture of lower end of radius; back view.

FIG. 139.



Fracture of lower end of radius; side view.

FIG. 140.



Bones in an old Colles's fracture, showing dorsal prominence made by lower fragment and carpus, and palmar projection caused by lower end of the upper fragment. (Erichsen.)

Contrary to the opinion of Sedillot and Huel, M. Voillemier affirms that, instead of being oblique, as has generally been supposed, the fracture is almost uniformly transverse from the palmar to the dorsal surfaces of the bone, and only occasionally slightly oblique in its other diameter, or from the radial to the ulnar side. I have seen, however, in the museum of the College of Physicians of Philadelphia, a specimen of this fracture in which the line of fracture is transverse, from side to side, but very oblique from before backward, and from below upward. There is also a line of incomplete fracture extending into the joint. It is united by bone, with the usual displacement backward; and there are several similar specimens in the New York Hospital museum. My own cabinet contains two such examples. It is my opinion, therefore, that the direction of the line of fracture described by Voillemier is exceptional.

The observations of both R. Smith and Voillemier have shown, moreover, that the displacement of the lower fragment is seldom sufficient to enable it to escape completely from the upper; and that where, in extremely rare instances, and in consequence of extraordinary violence, such complete separation does occur, a disruption of those ligaments which attach the lower fragment to the ulna occurs also, and the deformity becomes at once very great, so that it no longer presents the peculiar features of Colles's fracture, but resembles a dislocation.

¹ Trèlat, Journ. de Méd. et de Chir. Prat., Avril, 1877.

In Colles's fracture, the lower and outer border of the radius, or its styloid apophysis, is swung around or tilted, as it were, upon the ulna; the lower and inner border of the same fragment being retained in place by the radio-ulnar and internal lateral ligaments, which do not usually suffer a complete disruption, but only a stretching or partial laceration, possibly by the triangular ligament or by some of its untorn fibres, and by one fasciculus of the anterior annular ligament, which is probably seldom torn. The upper or broken margin of the lower fragment, and also the ulnar margin, undergo very little displacement; while the lower or articular surface, and the radial margin, are carried backward, upward, and outward.

Surgeons have spoken of a falling in of the upper end of the lower fragment toward the ulna, as an almost inevitable result of the action of the pronator quadratus, and against which tendency they have sought carefully to provide; but there is much reason to believe that any considerable degree of displacement in this direction is a rare event, and that, when it does exist, it is in consequence mostly of the direction of the force which has produced the fracture rather than of the action of this muscle, only a few of the fibres of which are usually attached to the lower fragment, and, in some instances, when the fracture is within a half or quarter of an inch of the articulation, not any. Besides, there is actually in these latter cases no interosseous space into which the fragments may fall, and its displacement toward the ulna becomes, therefore, impossible.

Still, however, if one were disposed to speculate upon the condition of these parts after the fracture, it might perhaps be easy to persuade ourselves that the action of the pronator quadratus upon the upper fragment, whose broken extremity was not completely, or at all, disengaged from the lower, would carry both fragments together toward the ulna. But whatever might be the result of our speculations, still the fact, as proved by specimens, is not generally so; and this is not the first time that facts and theories have disagreed. The truth is, that it is unusual to find any of the museum specimens of this fracture thus united. But they may be found constantly tilted back in the manner I have described, occasionally tilted forward, and, still more rarely, slightly displaced upon their broken surfaces antero-posteriorly.

The general absence of internal displacement may find its explanation in the direction of the force which generally produces this fracture, in the occurrence of the fracture sometimes at a point so low as to render its displacement in this direction impossible, and in the breadth of the bone, at the seat of the fracture, which does not permit it to fall laterally without actually increasing its length; a circumstance which its secure ligamentous attachment to the ulna at its opposite extremities, and its complete apposition to the wrist and elbow-joint, do not allow. The mistake of those surgeons who have attempted to describe this fracture has originated in the appearance presented in nearly all recent fractures occurring at this point. The hand falls to the radial side, and seems to carry the lower end of the lower fragment with it, while the lower end of the ulna becomes unnaturally prominent in front and to the ulnar side; a condition of things which has naturally enough been ascribed to the displacement of the upper end of the lower fragment in the direction of the interosseous space. But this same radial inclination of the hand, and prominence of the ulna, are present frequently when the radius is broken at its lower end, and no displacement in any direction has taken place; and I have even observed it in simple sprains of the wrist, and

in the hands of old or feeble persons where all the ligaments have become relaxed.

It is seen, however, in a more marked degree when the bone is actually both broken and displaced backward in its usual direction. In short, the deformity in question is due, in a large majority of instances, to the relaxation, stretching, or more or less disruption of the anterior and posterior radio-ulnar ligaments, the triangular fibro-cartilages, and the internal lateral ligaments: to which, I feel satisfied, we must add the influence of the strong and unbroken oblique fasciculus of the anterior carpal ligament. It is probably due to one or all of these circumstances combined that the hand falls to the radial side by a sort of rotatory motion, of which the unbroken external lateral ligaments and the strong fasciculus of the anterior ligament constitute the axis or centre of motion. For this reason, also, because these triangular, internal, and radio-carpal ligaments once lengthened or broken can never, or only after a lapse of many years, be completely restored, this deformity may be expected, in a certain number of cases, to continue, however exact and perfect may be the bony union. It must be added, however, that so long as the tilting of the fragment remains, the articular surface is actually presenting somewhat to the radial side. While in the normal condition it presents downward, forward, and inward, it now presents, when the displacement is considerable, downward, backward, and outward.

Diday maintained that there existed usually in this fracture an overlapping or shortening of the bone in its entire diameter, and Voillemier thought that the specimens which he had examined proved that an impaction was almost universal, and Tillaux has observed it frequently.

Both of these opinions Robert Smith has sought to combat, declaring that the appearance of impaction is due to the ensheathing callus, which is deposited usually, if the displacement is allowed to continue, in the retiring angle opposite the seat of fracture. Jajavay and Fouchat sustain the observations of Smith, but some recent observations made by Mr. Callender, of Saint Bartholomew's Hospital, London, go far to support the opinion that some impaction generally exists, but rather upon the posterior margin than upon either the radial or ulnar side;¹ and my own observations lead me to conclude that a posterior impaction is quite common.

In a case reported by Dr. Cameron, of Glasgow, resulting in speedy death, the impaction was complete posteriorly, and was accompanied with impaction and comminution of the lower fragment, while the fracture in front was "hardly complete, the periosteum holding the fragments together."²

Comminution of the lower fragment has never occurred in the experiments made by me upon the cadaver, but it is quite common to meet with such examples in dead-house specimens, especially when the patients have fallen from a height and have been killed by the accident. Its existence usually implies the application of greater force than results from a fall upon the hand upon the sidewalk. The latter represents the usual accident, while a fall from a height is the exceptional accident, and the character of the fracture is therefore exceptional.

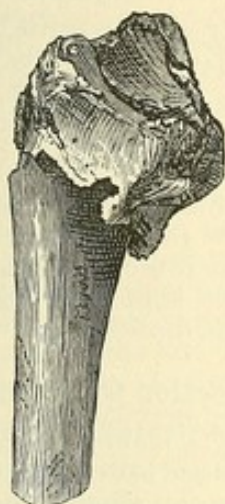¹ Callender, St. Barth. Hosp. Rep. p. 281, 1865.

² Cameron, Glas. Med. Journ., March, 1878.

[Mr. Powers,¹ of London, states that comminution is much more frequent than is supposed, as it is not easily detected. In 59 specimens he found comminution in 31. Callender, Hutchinson, and Bennett, also, have advanced the same view.]

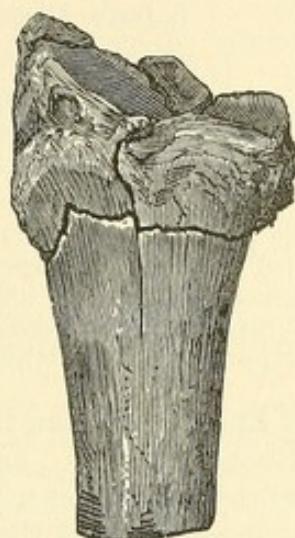In the accompanying woodcut (Fig. 141) is seen an impacted and comminuted fracture of the lower end of the radius. Dr. James Wentworth, of Troy, N. Y., who sent me the specimen, says that the patient, a man, æt. fifty years, in a fit of delirium, jumped from a third-story window, alighting upon the stone pavement. He survived the accident less than one hour.

FIG. 141.



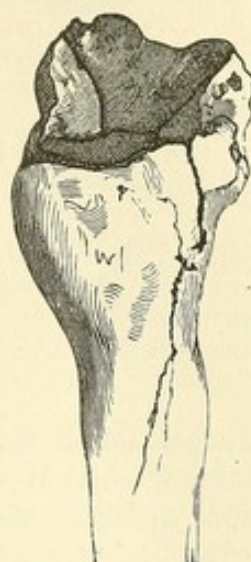
Impacted fracture. (Author's collection.)

FIG. 142.



Comminuted fracture. (Author's collection.)

FIG. 143.



Bigelow's case of comminuted fracture of the lower end of the radius.

Fig. 142 is from a specimen presented to me by Dr. William Van Buren, and was found in an autopsy at the New York City Hospital. In this specimen there is comminution without impaction or displacement. The line of separation between the upper and lower fragments is transverse, and the lower fragment is divided into five distinct pieces, each line of fracture involving the joint.

One curious example of this form of fracture is reported by Dr. Bigelow, of Boston (Fig. 143). The patient had fallen, and, being otherwise seriously injured, ultimately died in the Massachusetts General Hospital. At first he had only complained of lameness at the wrist, as if it had been severely sprained; but at the end of several days the joint became swollen, and from the persistence of the swelling Dr. Bigelow was led to diagnosticate a stellate crack in the articulating extremity of the radius, he having met with a similar case two years before, when a patient with the same symptoms had died of other injuries, and exhibited a crack in the same place, but less extensive than in this case. There was found, in this last example, a star-shaped fissure on the articulating surface, without displacement. These fissures penetrated the shaft for an inch or more. Dr. Bigelow thought that the bones of the wrist acted as a wedge to spread the corresponding hollow of the articulating extremity, and that this specimen would explain the persistence of some cases of sprained wrist.²

Robert Smith has described a fracture occurring at the same point, and probably possessing nearly the same characters as Colles's fracture, in which the lower fragment is thrown forward instead of backward, and which has generally been the result of a fall upon the back of the hand. There is no such specimen, however, in any of the pathological collections in Dublin, nor has Mr. Smith ever

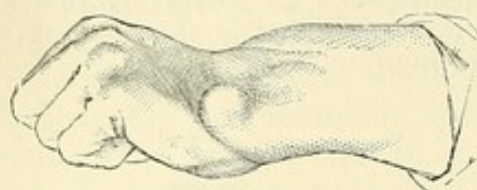
¹ Trans. Path. Soc. Lond., vol. xxxviii.

² Bigelow, Boston Med. and Surg. Journ., vol. lviii. p. 99.

seen a specimen obtained from the cadaver, although he reports a case which fell under his observation in practice. I have myself seen one such case,¹ but I regret to say that my examination of the condition of the arm was not such as to enable me to give a very satisfactory account of the cause and symptoms of

the accident. Referring, however, to the experiments upon the cadaver detailed in the succeeding pages, it will be seen that I have been able to produce this fracture by forced palmar flexion of the hand.

FIG. 144.



Fracture of radius and displacement forward. (R. W. Smith.)

joint, the separated fragment including considerably more than the styloid process; but neither of these cases has been verified by an autopsy.

Nélaton observes that all the varieties of this fracture which he has seen are often accompanied with fracture of the styloid apophysis of the ulna, and with a tearing of the triangular ligament. Cameron, also, thinks it more common in connection with a Colles's fracture than has generally been supposed; and, in confirmation of this opinion, reports five cases which he has himself observed.²

Dislocation of the Lower End of the Ulna in Connection with Colles's Fracture.—Dr. Moore, of Rochester, N. Y., has demonstrated, by examinations upon the cadaver and by experiment, that in a certain proportion of cases the internal lateral ligament, and the triangular fibro-cartilage give way under the force which has occasioned the fracture, the styloid process is thrust under or through the annular ligament and imprisoned; in fact, the ulna becomes dislocated, and is retained by the annular ligament in its new position; this dislocation being accompanied in some cases with a fracture of the styloid process of the ulna. Nor can the reduction of the fracture of the radius be accomplished until the ulna is released from its imprisonment. Reduction is to be accomplished by extension and partial circumduction; the hand being grasped firmly and extended first to the radial side, then backward to the ulnar side, and finally forward, or in the position of flexion. During the entire manœuvre the wrist is held firmly by the opposite hand of the surgeon. The test of reduction is to be found in the presence of the head of the ulna on the radial side of the ulnar extensor. In order to retain the ulna in place when reduction is effected, Dr. Moore places a thick, firm compress over its lower end, on the palmar and ulnar margins of the forearm, and secures this in place with a broad band of adhesive platter drawn firmly around the wrist. The forearm is then placed in a narrow sling passing under the wrist and compress. This completes the dressing.³

The five examples presented by Dr. Moore, and verified by an autopsy, must be regarded as exceptional cases; all of them being results of falls from a considerable height, and most of them had proved speedily fatal, thus affording an opportunity for post-mortem inspection. They are not fair representatives of

¹ Trans. Amer. Med. Assoc., vol. ix. p. 145.

² H. C. Cameron, Glasgow Med. Journ., vol. x. No. 3, 1878.

³ Moore, New York Med. Record, April 1, 1870; March 20, 1880.

that class of cases which are caused by falls upon the hand in the street, and which have been regarded as typical cases. Dr. Moore concludes, however, from autopsies, and from personal observation of other cases, that "luxation of the ulna exists in more than half of the cases. But I was never able to produce it in any of my experiments upon the cadaver—that is to say, the extensor carpi ulnaris was never dislodged from its groove, and this is what he considers essential to the luxation. By the change of position of the lower fragments of the radius and ulna the extensor carpi ulnaris is less distinctly felt, or it cannot be felt at all, but the dissection always shows that it remains in its groove. Indeed, I feel persuaded that it cannot be torn from its normal position except by great force, such as was applied in all the cases mentioned by Dr. Moore.

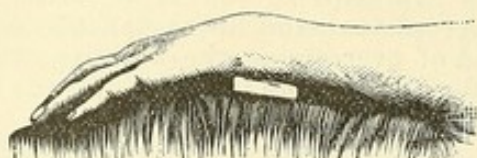[My experience in the treatment of Colles's fracture has led me to attach more importance to Dr. Moore's views than is expressed in the above text. The cases which he reports are by no means exceptional, and his explanation of the conditions which exist, and of the method of overcoming the peculiar form of displacement are deserving of careful study. Dr. Moore thus explains the accident and the dislocation:

"The fall comes upon the palm of the hand, and the radius which sustains the full forces of the strain gives way at a point near the wrist. The line of fracture is usually an oblique one, starting from a point on the anterior aspect of the radius, near the articulation, and running backward and upward, making the posterior surface of the lower fragment longer than the anterior. It is seldom more than an inch from the joint, and seldom so far. But the line of fracture is very various, sometimes simple and nearly transverse, but often comminuted to the last degree. The luxation of the ulna exists in more than half of the cases. I now feel quite sure, though I cannot demonstrate it by dissection, that a proper observation of the relation of the head of the ulna to the carpus will make a just diagnosis of its luxation or non-luxation. The force of the fall may be just balanced by the strength of the radius, but in the nature of such accidents this would not often be the case. In most, there would be some force still to be borne. Upon what structures does this fall? The radius instantly, on fracture, ceases to afford resistance, the hand is carried still further back, and then comes the strain on the attachments at the end of the ulna. It will be remembered that the ulna does not articulate with the wrist, but there is a distinct synovial cavity between its head and a strong membrane called the triangular fibro-cartilage. The membrane takes an origin from the rim and side of the radius, and, covering the head of the ulna, is inserted in the pit at the root of the styloid process. As the hand, with its broken fragment of the radius, is forced backward, the strain is often sufficient to rupture the connection between the two bones or to break the ulna near the head. I have seen this double fracture twice only. The rupture takes place at the weakest point, which is its insertion in the pit at the root of the styloid process. But this is not the only resistance. The styloid is held to the carpus by the internal lateral ligament, which takes a very firm hold upon the end and radial surface of the styloid. This also gives way, and usually does so in a peculiar manner—viz., by pulling off the surface of the bone, which proves to be weaker than the ligament. Thus the remaining styloid is brought to an edge like a gouge-chisel, and is shortened about one-half. When these resisting forces are disposed of, the end of the ulna, now laid bare, is pressed against the posterior annular ligament, and is apt to become engaged upon it either by a fold, or, what is more likely, by splitting its fibres and hooking upon it. If very great violence has been used in the production of these lesions, the head of the ulna will be driven forward through the annular ligament and skin, thus producing a compound luxation."

Dr. Moore attaches much importance to the position of the tendon of the extensor carpi ulnaris in determining the question of the luxation of the lower extremity of the ulna. He says: "It runs alongside of the head of the ulna and behind the styloid. When the luxation does not exist, and the fracture does, the head of the bone maintains its relation with the tendon but little disturbed. When, however, the luxation does occur, the tendon will appear to lie over the head. I feel quite sure that this does not result from any twist of the hand carrying the fragment of the radius. I find proof of the correctness of this

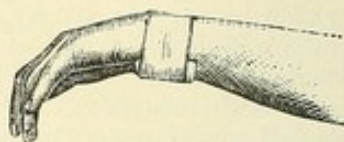
proposition in the specimen before us. The dead tissue presents the tendon curved out of its place. In the living, under muscular contraction, this would be a straight line, and lie over the head of the ulna. I find also in what I deem cases of luxation, a mobility of the end of the ulna incompatible with the integrity of the ligamentous apparatus. Every observer has recognized a difference of the form of the wrist in different cases. Some are curved backward—the genuine silver-fork shape; others have the hand carried more laterally. My convictions are, that those that present the wrist well curved back, are more apt to be those of luxation of the ulna with fracture, but the lateral bend implies generally shortening of the radius from fracture without luxation of the ulna.

FIG. 145.



Position of roller compress.

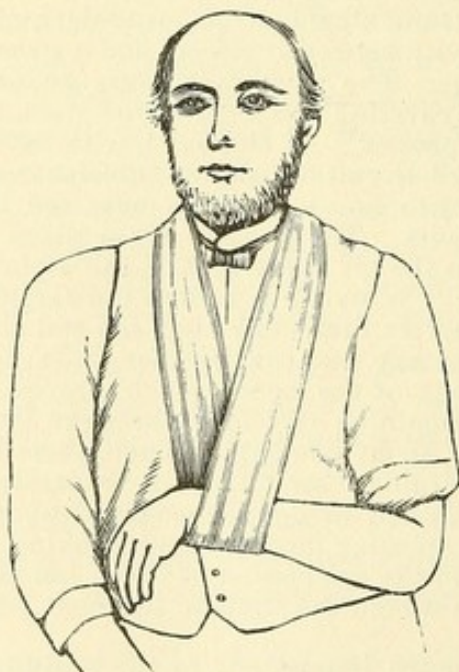FIG. 146.



Roller, with adhesive strap applied.

The methods of reduction and treatment are as follows: "I propose a form of traction and circumduction which is intended to disentangle the ulna and carry it up in its place between the tendons of the extensor carpi ulnaris and extensor minimi digiti. I by no means wish to say that it is always necessary, for the great point should be not to relax any effort until complete restoration has taken place. One of the best methods of reduction is to draw the hand of the patient around the knee of the surgeon, the head of the ulna resting upon his patella. The gentle handling that is ordinarily employed in the management of the fracture is out of place here. Great force is often necessary to restore the symmetry of the parts. We must keep in mind that a luxation is to be reduced, and

FIG. 147.



Colles' fracture; dressing complete.

should not cease our traction until the end is attained. Besides, the muscles will produce consecutive luxation instantly if the parts are not held firmly until the dressing is complete. With the thumb of the surgeon under the ulna, and the hand beneath, and the fingers upon the back of the wrist holding with great firmness, I apply my dressing. This, it will be remembered, consists of a simple

roller from half to three-quarters of inch in diameter and two inches long. This is to be carefully placed under the ulna, abutting against the pisiform bone and slowly displacing the thumb. Then a strip of adhesive plaster of the same width is drawn, with as much force as it will bear, around the wrist and pinned to prevent relaxation. The band of plastered cloth is carefully adjusted so that the distal edge is brought around on a line with the end of the radius. It is manifest that this bandage will grasp the broken fragment, and hold it to the end of the ulna. The rule, of loose dressing at first, is distinctly violated for a purpose. I repeat that I draw it as firmly as I can, often breaking the plaster cloth. The dressing is entirely completed by the use of a sling which must not be more than three inches wide. This must be placed over the roller, and is made of this width to cause the whole bearing to come on the roller, which is both compress and splint. The hand is brought down and allowed to hang naturally. Thus its weight and that of the forearm are used to press the ulna upward into its proper place. "If all this is successfully accomplished, the broken fragments of the radius are easily kept in place.

"The full length of the arm is maintained if the ulna does not fall down, and the tendons that run over the back of the wrist are so closely parallel to to make the best possible splint. I do not continue so gross a violation of the primary rule in dressing fractures, as to retain the bandage in its tight condition; but, after six hours, cut it by thrusting one blade of a pair of scissors under it on the back of the wrist, dividing it completely. The few hours of such retention seem to be sufficient. The meagreness of the appliance has startled some who have attempted its use. But any addition that I have made has injured it. I find there is a strong disposition on the part of the patient to lift up the hand with the sound one. With unintelligent patients this is often troublesome, and a splint of iron, thin, such as hoop iron, bent so as to come over the back of the wrist and hand, and bound upon the forearm but not upon the hand, will guard against this error. I am careful not to bind the hand to it, for I desire the constant action of gravity. The position can be maintained even in the recumbent posture. The slight motion in the joint which will necessarily be produced by allowing it to hang freely, prevents the stiffness that is so often a very serious inconvenience after the treatment of this fracture."]

In the following case, although the patient fell from a considerable height, and the lower fragment of the broken radius was comminuted, there was no displacement of the ulna. J. B., æt. 62, fell twenty-four feet, and was taken to St. Mary's Hospital, Detroit. He was found to have a rupture of the left gluteal artery, and a fracture of the right radius. Dr. McGraw tied the gluteal artery by an external incision, but death occurred on the same day. The autopsy disclosed a Colles's fracture. *The ulna was found in its place.* No ligaments anywhere around the joint were broken or injured in the least, neither was there any extravasation of blood near the fracture. The lower end of the radius was broken into four fragments, which were, however, held together by the periosteum and ligaments. They were broken off the shaft just one-half inch from the articular surface, and were inclined back with the characteristic deformity. It was with difficulty that they could be brought into proper apposition, and only by first making traction, and then bending toward the palmar surface. It was evident that they were held in their acquired position by bony impaction and by nothing else. It was difficult even when the bones were bare of flesh to get much crepitus, owing to the spongy consistency of the bone at that point.¹

Barton's Fracture, as distinguished from a Colles's Fracture.—Dr. J. Rhea Barton,² of Philadelphia, described a form of fracture occurring through the lower end of the radius, which is probably much less common than Colles's fracture, and which had hitherto escaped the notice of surgeons. Its peculiarity consists in the line of fracture extending very obliquely from the articulation, upward and backward, separating and displacing the whole or only a portion, as the case may be, of the pos-

¹ McGraw, Med. Gaz., Jan. 8, 1881.

² Philada. Med. Exam., 1838.

terior margin of the articulating surface. I have not recognized this fracture in any instance which has come under my own observation, nor have I been able to find a cabinet specimen in any pathological collection.

Dr. Barton was not able to prove the correctness of his diagnosis by an autopsy, and the only well-authenticated example which I can find upon record is that to which Malgaigne has alluded, as having been seen by M. Lenoir, and of which an account was published in the *Archives Générales de Médecine*, in 1839. M. Lenoir believed it to be a simple luxation of the hand backward, but the patient having died, he was able to correct his diagnosis by an autopsy. A considerable fragment had been broken from the posterior lip of the articular surface, the line of fracture being from below upward, and from before backward. This fragment had become displaced upward and backward, carrying with it the carpal bones, and producing thus the appearance of a simple dislocation.¹

The possibility of such a fracture must be admitted, since in my experiments upon the cadaver by avulsion, it has several times been produced; but the infrequency of cabinet specimens furnishes a presumption that it is exceedingly rare and exceptional.

Etiology and Mechanism of Colles's Fracture.—In every instance, except one, which has come under my notice, where the cause of a Colles's fracture has been ascertained, it has been occasioned by a fall upon the palm of the hand.

The exceptional case was in the person of Mrs. D. B., who fell in getting out of a street-car in the city of New York, May 20, 1865, striking upon the back of her hand while the hand was shut. The displacement was in the same direction as in cases caused by a fall upon the palm. Robert Smith has seen a similar accident cause a displacement of the fragment forward.

As to the precise mechanism of this accident—speaking now only of the well-characterized Colles's fracture—there can be very little doubt. In a large majority of examples it is the result, primarily and mainly, of two forces acting in an opposite direction, at an obtuse angle, one being the weight of the body in falling, and the other the impact or resistance of the ground, the bone giving way, as is usual in other long bones, nearest the point of impact, where, owing to the unyielding nature of the resistance as compared with the yielding nature of the impulse (or weight of the body), the vibration is the greatest; and in this particular case, the fracture is not only almost always in the lower end of the bone, but also at or near that point where the bone is less strong than elsewhere, namely, where the compact tissue ends and the more spongy tissue commences.

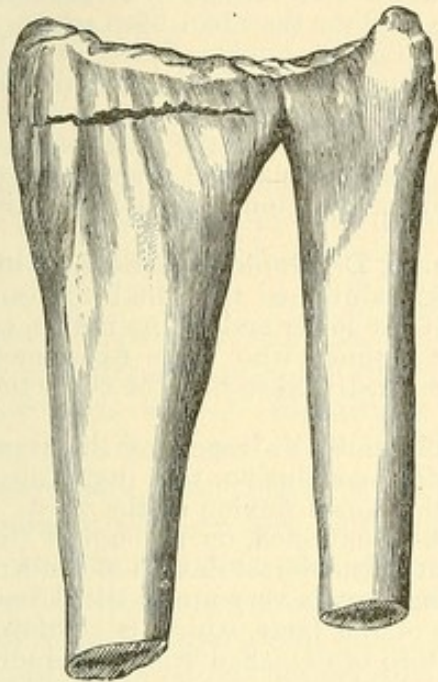
This view of its mechanism was illustrated experimentally by M. Nélaton.² Having amputated the forearm upon a cadaver, and sawn off the olecranon process, he placed the palm of the hand upon a solid surface, the forearm being vertical, and then struck a heavy blow upon the upper end of the two bones. Upon dissection he found the radius broken transversely, twelve to fifteen millimetres from the lower end, the lower fragment being tilted backward.

¹ Malgaigne, *Traité des Frac.*, etc., tom. ii. p. 700.

² Nélaton, *Chir. Path.*, t. i. p. 740.

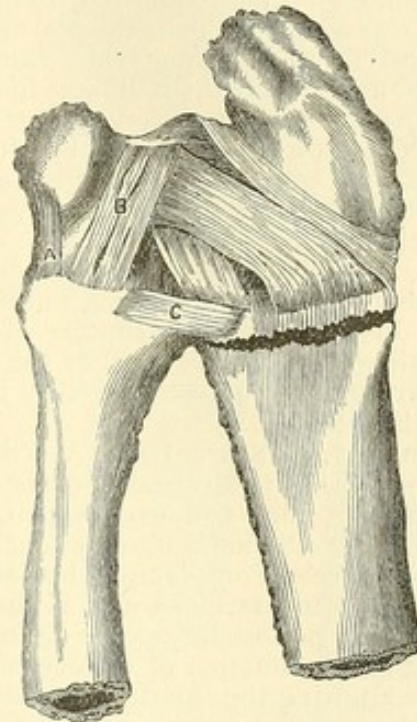
I have repeated this experiment, and with the same result. It is not easy, however, to produce the fracture in this way upon the cadaver, unless we select the bones of young persons or delicate women for the experiment; the force

FIG. 148.



Transverse fracture of the lower end of radius; caused by forced *palmar* flexion; in the cadaver.

FIG. 149.



Transverse fracture of lower end of radius; caused by forced *dorsal* flexion; in the cadaver. A. Internal lateral ligament. B. Third fasciculus of anterior carpal ligament. C. Anterior radio-ulnar ligament.

required to cause the fracture being greater than is required in the living subject, because the muscles are relaxed and the stability of the bones is not well maintained.

We see, then, that in addition to the two forces acting in opposite directions, already mentioned as constituting, in most cases, the efficient cause of the fracture, there must be added, as extrinsic, but important, muscular action, which insures the fixedness of the articulation at the elbow and wrist.

In a few cases also the mechanism of the fracture will admit of another explanation. A Colles's fracture has been caused in the living subject by simply forcing the hand strongly backward, and without a fall or sudden impact.

Thus Voillemier, 1842, relates that he had seen the fracture once caused by a fall upon the lower half of the hand, in which the heel of the hand did not touch the ground; but another case was even more conclusive, the fracture being caused by forced flexion (probably "dorsal flexion") made by a comrade. According to Malgaigne, M. Bouchet was the first to observe this mode of causing the fracture; his observations having been made exclusively upon the cadaver (1834). In trying to dislocate the wrist, he found he could produce only

a fracture of the lower end of the radius, sometimes with other lesions, and especially with fracture of the styloid process.¹

Malgaigne, while accepting the theory of Bouchet—that is, while regarding the fracture as being produced by the action of two opposite forces—the weight of the body, and the resistance of the soil—declared that the observations of Bouchet and Voillemier led him to believe that cases of fracture by arrachement (a cross-strain of the ligaments) might be more common than had been supposed.

In 1860–61, an important memoir by M. Ozanim Lecomte² appeared, in which that surgeon stated that it was his opinion that the fracture was produced solely by arrachement, and that neither muscular action nor shock had any part in it. This opinion was supported by Duplay, Anger,³ and Tillaux,⁴ the latter of whom says: “I agree with Lecomte in admitting that the classical fracture of the lower end of the radius is always produced by an avulsion caused by the ligaments.”

According to Dr. P. S. Conner,⁵ of Cincinnati, Dr. Gordon, of Belfast, in a memoir on Colles's fracture, published in 1875, maintained that the bony lesion is “due to a transverse rupture of the fibres of the lower end of the radius, as a result of forced extension of the hand.” Dr. Conner, who made experiments regarding the subject, says that they have demonstrated to him the correctness of that theory.

In May, 1878, Dr. Lewis A. Pilcher, of Brooklyn, N. Y.,⁶ repeating the experiments of his predecessors, came to an identical conclusion, viz., that Colles's fracture is due to an arrachement, caused by the dorsal flexion of the wrist. A few of Dr. Pilcher's observations deserve to be mentioned, on account of their importance. For example, he has noticed that if the dorsal flexion of the wrist is carried to extremes, and if the inferior fragment is very much tilted backward, the periosteum on the posterior surface of the bone, which is reinforced by a certain number of aponeurotic fibres, is torn or detached from the radius, thus allowing the inferior fragment to ascend backward, and to be penetrated by the posterior border of the superior fragment.

Dr. Pilcher has also observed that the chief cause of the peculiar position assumed by the hand after this fracture was the presence of “a strong oblique fasciculus of the anterior ligament of the wrist, which extended from the cuneiform bone to the anterior border of the styloid process of the ulna. By the backward displacement of the carpus, and the attached radial fragment, that ligament was put upon the stretch, limiting all motion until relaxed.”

It will be seen that Dr. Pilcher attributes nothing of the peculiar phenomena to the integrity of the internal lateral, triangular, and radio-ulnar ligaments; but to my mind it is very plain that this view of the subject is too exclusive, and that whenever these latter ligaments remain untorn they contribute to the malposition of the hand.

I have repeated these experiments of Bouchet, Lecomte, and others, many times upon the cadaver; and while they confirm in some measure the observations of these surgeons, I am far from being convinced that the classical fracture, occasioned by a fall upon the palm of the hand, is due exclusively to the action of the ligaments. I presented to the Surgical Society of New York, twelve specimens of Colles's fracture, and compared them with a still larger number of specimens in which the fracture had been produced upon the cadaver by forced dorsal flexion. The comparison showed that there was a marked difference between the two classes of fractures, as regards the seat and direction of the lesion.⁷

The results of my experiments upon the cadaver may be summarized as follows: 1st. In some there is only a laceration of the anterior annular

¹ Bouchet, *Thèse sur les lux. du poignet*. Paris, July, 1834. From Malgaigne.

² Lecomte, *Archiv Gén. de Méd.*, Dec. 1860, Jan. and Feb. 1861.

³ Anger, *Frac. et Lux. Atlas*, Paris, 1863.

⁴ Tillaux, *Trait. d'Anat. Topograph.*, Paris, 1877, p. 605.

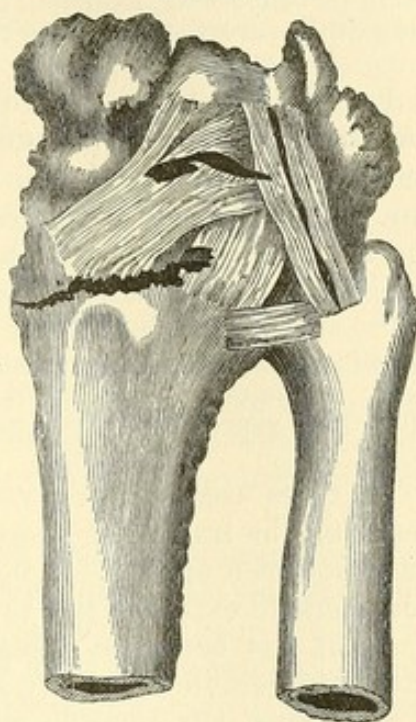
⁵ Conner, *Cincinnati Lancet*, April 23, 1881.

⁶ Pilcher, paper read before the Surgical Section of the New York Acad. of Med., May 16, 1878; *The Med. Record*, July 27, 1878, p. 74.

⁷ *Med. Record*, July 25 and 30, 1881.

ligament of the wrist, which, occurring in the living subject, would pass for a sprain of the wrist. 2d. The styloid process of the radius may be alone broken off at its base. 3d. The anterior lip of the radius may be broken off, the line of fracture being transverse, but not involving the whole thickness of the bone. 4th. The line of fracture is occasionally oblique from the ulnar to the radial side of the radius, commencing outside of the joint and terminating in the joint. 5th. The line of fracture is sometimes transverse, involving the entire thickness of the bone; but it is usually much lower down than when it is caused, in the living subject, by a fall upon the hand; and there is less obliquity in the line of fracture from before back, than in the latter case. 6th. That portion of the carpal ligament which passes obliquely downward to be inserted into the styloid process of the ulna is always untorn, while rupture of the radio-ulnar, triangular, and internal lateral ligament is occasionally found. 7th. In some cases there is a mere fissure or crack of the bone, not extending through its entire thickness, and which could not have been recognized in the living subject. 8th. In others it is more or less tilted or pressed back, but not overlapped; and these, constituting a majority of the whole, were easily replaced in their natural position by simply pressing the lower fragment forward, as has been my practice in many cases hitherto. 9th. When the force applied is greater or longer continued the lower fragment is displaced backward upon the upper, the periosteum is torn up posteriorly; and there would be impaction, no doubt, if the muscles had their normal power of contraction, or if added to the cross-strain there had been the driving force of a fall upon the palm of the hand; and in these cases it was difficult to tilt the lower fragment forward into line without first relieving the strain upon this periosteal ligament by the method described by Pilcher. 10th. The character of the lesions in the opposite wrist of the same cadaver was generally symmetrical; the same lesion being caused by the same manipulation in one arm as in the other. 11th. Fractures of the radius were produced by forced palmar flexion, but not quite so readily, and the fractures occurred a little lower than is usual in a Colles's fracture.

FIG. 150.



Fracture at base of styloid process of radius, and laceration of annular ligament, caused by forced dorsal flexion; in the cadaver.

These are the facts as observed by me in the dead-house experiments, and no doubt they illustrate to some extent the mechanism of this accident as it occurs in life; but it is apparent that in some respects the circumstances differ. There is in the case of the cadaver no muscular contraction to give fixedness to the bones, and to displace the fragments after they are separated, or to maintain them in a position of displacement. The force of sudden impact caused by the

weight of the body in falling is not present. In short, the fractures caused by the experiments were the result solely of the action of the carpal ligaments upon the lower ends of the bones; they were fractures by avulsion or cross-strain, while in the examples presented in the living subject they are usually the result of concussion, avulsion, and muscular action combined, of which causes perhaps the cross-strain is not the least efficient.

Prognosis.—One hundred and five examples of Colles's fracture have furnished no cases of non-union, nor indeed do I remember ever to have seen the union delayed; but in a pretty large proportion of cases occurring in the practice of surgeons whose patients have been brought under my notice, some slight or considerable deformity remains, and in most cases the joint remains more or less stiff and sensitive for some months.

Twice I have found the wrist and finger-joints quite stiff after a lapse of one year; in one case I have found the same conditions after two years, in one case after three years, and in two cases after five years.

In cases treated by myself, where I have exercised great care in reducing the fragments thoroughly, and where the bandages and splints have not been applied too tightly, nor kept on too long, deformity to any considerable extent is the exception, and the stiffness is soon dissipated. I say it has been the exception, not intending to claim that under my care considerable deformity has never resulted.

Confining our remarks still to Colles's fracture, the deformity which has been observed most often, after the lapse of several months or years, is a projection of the lower end of the ulna inward, a phenomenon explained fully in the preceding pages. Rarely it is displaced backward, and still more rarely forward. In a majority of cases this is accompanied with a perceptible falling of the hand to the radial side, while in a few it is not. After this, in point of frequency, I have met with the backward inclination of the lower fragment.

Robert Smith found this displacement almost constant in the cabinet specimen examined by him; and it is very probable that nearly all of the specimens examined by myself would present more or less of the same deviations upon the naked bone; but in the living examples a slight deviation would be concealed by the numerous tendons which cover this part of the arm, and perhaps by some permanent effusions, of which I shall speak more particularly presently.

There remains for a long time, in many cases, a broad, firm, uniform swelling on the palmar surface of the forearm, commencing near the upper margin of the annular ligament and extending upward two inches or more. The swelling continues much longer in old and feeble persons than in the young and vigorous. It is pretty generally proportioned to the amount of ankylosis existing at the wrist and finger-joints, and it disappears usually *pari passu* with these conditions. There can be no doubt that this phenomenon is due to effusions along the sheaths of the tendons, and in the areolar tissue external to the sheaths, and it is as often present after sprains and other severe injuries about this part, as in fractures. In many cases, however, its prolonged continuance and its firmness have led to a suspicion that the bones were displaced, a suspicion which only a moderate degree of care in the examination ought

easily to dispel. A similar effusion, but in less amount, is frequently seen also on the back of the hand, below the annular ligament. When both exist simultaneously the appearances of deformity and of displacement are greatly increased. Here, then, we shall find a partial explanation of the ankylosis in the wrist and finger-joints, which continues occasionally many months, or even years, if, indeed, it is not permanent; an ankylosis produced in a few instances by extension of the inflammation to these joints, but much more often by the inflammatory effusion and consequent adhesions along the thecæ and serous sheaths, through which the tendons all pass in their course to the hands and fingers, and also by simple contraction of the articular ligaments, as a consequence of disuse, or, as it is usually termed, by passive contraction of these ligaments. The fingers are quite as often thus ankylosed after this fracture as the wrist-joint itself; a circumstance which is wholly inexplicable on the doctrine that the ankylosis is due to an inflammation in the joints. Indeed, I have seen the fingers rigid after many months, when, having observed the case throughout myself, I was certain that no inflammatory action had ever reached them.

The peculiar swellings of the wrist and hand which have been described above, commence to show themselves very early after the receipt of the injury; but I have noticed, also, a swelling which is a little later in its accession, namely, an induration and fulness upon the back of the hand, which corresponds accurately to the position of the carpal bones, and presents an appearance as if all the carpal bones were slightly displaced backward. This phenomenon is probably due to a swelling and induration of the numerous ligaments which bind together these bones posteriorly. It usually disappears after a few months. Nor is it any more difficult to show, I think, that the ankylosis of the wrist-joint is not often due to a malposition of its articular surfaces, as has frequently been asserted in the written treatises.

The most superficial examination of the mechanism of this joint ought to satisfy us that any moderate or even considerable malposition of the lower fragment after a fracture of the radius, is not sufficient in itself to occasion ankylosis. It is true that in the fracture now under consideration, the direction of the articular surface of the radius is often changed, and that, while it was directed downward, forward, and to the ulnar side, it is now, perhaps, directed downward, backward, and to the radial side. But of what consequence is this so long as the carpal bones, with which alone this bone is articulated, preserve their relations to the radius unchanged?

If any other evidence be demanded, it may be supplied by the experience of most surgeons in examples of ankylosis without displacement, in examples of displacement without ankylosis, but in which the ankylosis has yielded gradually to the lapse of time, while the displacement has continued.

The following case is in point: J. R., a private in the 15th N. Y. Volunteers, fell from a height into a ditch during the battle of Fair Oaks, Va., May 31, 1862, striking upon the palm of his left hand, and causing a simple fracture near the lower end of the radius, accompanied probably with impaction. I do not know what treatment was adopted, but when he came under my observation, in March,

1863, at the Central Park General Hospital, New York, I found the most extraordinary deflection of the hand to the radial side which I have ever seen after this fracture. The hand could be turned laterally in the direction of the radius, to a right angle with the arm; the motions of flexion and extension were nearly as perfect as in the opposite arm, and the hand was in all respects as useful as before the accident.

To what I have said as to the prognosis in these accidents, I may be permitted to add the opinion of our distinguished countryman Dr. Mott, given in a clinical lecture before his class in the University Medical College of New York: "Fractures of the radius within two inches of the wrist, where treated by the most eminent surgeons, are of very difficult management so as to avoid all deformity; indeed, more or less deformity may occur under the treatment of the most eminent surgeons, and more or less imperfection in the motion of the wrist or radius is very apt to follow for a longer or a shorter time. Even when the fracture is well cured, an anterior prominence at the wrist, or near it, will sometimes result from swelling of the soft parts." The reporter, a surgeon, adds: "As the above opinion of Professor Mott coincides with my own observations, both in Europe and in this city, as well as with many of our most distinguished surgical authorities, I venture to hope that it may assist in removing some of the groundless and ill-merited aspersions which are occasionally thrown on the members of our profession by the ignorant or designing."¹

In evidence that we have not yet attained all that we could desire in the treatment of this fracture, I will quote farther: "In young subjects, fractures of the lower end of the radius are easily reduced, unite readily, and leave the use of the limb perfectly unimpaired; but in old persons, who, as before stated, are especially liable to this injury, the result is often most unsatisfactory, even after the greatest care has been used during the treatment. It is frequently months before the hand is free from pain and regains its proper motions, and too often an unsightly, crooked, and permanently stiff wrist remains, to the great inconvenience and annoyance of the patient."²

Treatment.—The peculiar character of the displacement which characterizes Colles's fracture, and the constant difficulty experienced by surgeons in obviating deformity, have led to much speculation and ingenious invention; and modern surgeons, especially, have thought it necessary to introduce here an essential modification of the usual apparel for broken forearms. This modification consists in employing a pistol-shaped splint, instead of a straight splint, by means of which the hand may be thrown more or less strongly to the ulnar side.

Heister³ speaks of inclining the hand toward the ulna, while reducing a fracture of the radius, but when the reduction has been effected he recommends a straight splint. Among the first to advocate the permanent confinement of the hand in this position, were Mr. Cline,⁴ and Dupuytren.⁵ Mr. Cline, and after him Bransby Cooper,⁶ and Mr. South,⁷ recommend the ordinary straight splints for the forearm, but the rollers by which the splints are secured in place are not permitted to extend lower than the wrist; so that when the forearm is suspended in a sling, in a state of semi-pronation, the hand shall fall by its own weight to the ulnar side.

Dupuytren, and after him Chelius, adopt, in addition to the palmar and dorsal splints, the "attelle cubitale," or ulnar splint; which is a gutter, composed of steel, iron, tin, or some other metal, and made to fit the ulnar margin of the

¹ Boston Med. and Surg. Journal, vol. xxv. p. 289.

² Holmes's System of Surgery, Amer. ed., 1870, vol. ii. p. 798.

³ De Lavrentii Heisteri, Institutiones Chirurgicæ, pars prima, p. 203, Amsterdam ed., 1739.

⁴ Malgaigne, Traité de Frac., etc., tom. i. p. 614, Paris ed.

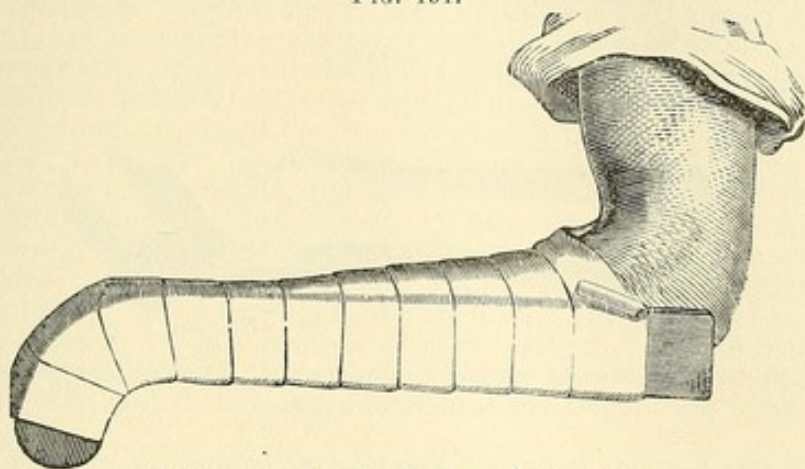
⁵ Dupuytren on Bones, London ed., p. 140.

⁶ B. Cooper, Lectures on Surg., p. 232, American ed.

⁷ Chelius's Surg., vol. i. p. 613.

forearm and hand, when the hand is drawn forcibly to the ulnar side. Blandin,¹ Nélaton,² and Gourand,³ also, under certain contingencies employ the same. Most surgeons, however, employ either a palmar or a dorsal splint; or both


FIG. 151.



Nélaton's splint for fracture of the radius.

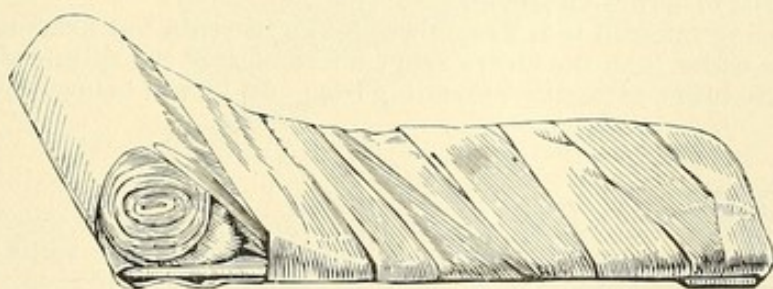
palmar and dorsal splints constructed with a knee, or pistol-shaped, and they thus avoid the necessity of the ulnar splint. Thus, Nélaton,⁴ Robert Smith,⁵ and Erichsen,⁶ recommend this peculiar form only in the dorsal splint; while

FIG. 152.



Bond's splint.

FIG. 153.



Hay's splint.

Bond,⁷ Hays,⁸ E. P. Smith,⁹ G. F. Shrady,¹⁰ and others, especially among the Americans, place the pistol-shaped splint against the palmar surface of the arm. A few modern surgeons have not seen fit to adopt this peculiar principle of

¹ Malgaigne, op. cit., tom. i. p. 614.

² Nélaton, *Elém. de Path. Chir.*, tom. i. p. 747.

³ *Ibid.*, p. 746.

⁴ R. Smith, op. cit., p. 168.

⁵ Bond, *Amer. Journ. Med. Sci.*, April, 1852.

⁶ E. P. Smith, *Buffalo Med. Journ.*, vol. ix. p. 225.

⁷ Shrady, *Amer. Med. Times*, 2 cases, Dec. 22, 1860.

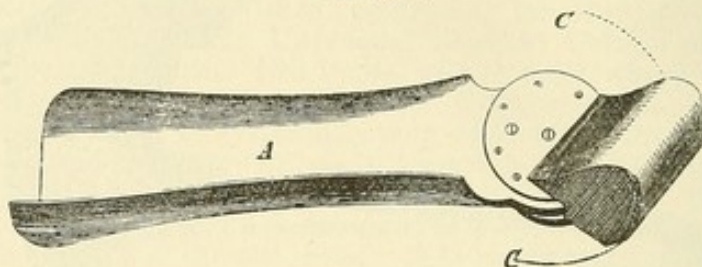
⁸ Nélaton, op. cit., p. 747.

⁹ Erichsen, *Surgery*, p. 215.

¹⁰ *Ibid.*, Jan. 1853.

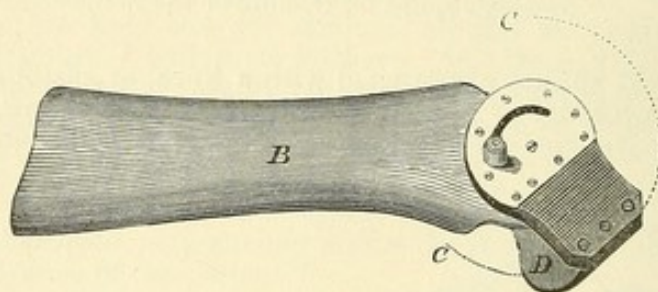
treatment, or this form of dressing under any of its modifications. Colles¹ recommends a straight palmar and dorsal splint, and does not incline the hand. Barton² advises the same, and Skey, having declared his preference for a couple of broad, straight splints, adds: "Great care should be taken to prevent the hand falling, and this object will be attained by inclosing the entire forearm and hand in a well-applied sling."³

FIG. 154.



E. P. Smith's splint. Surface applied to forearm. A. Forearm piece, made of felt, with incurvated margins.

FIG. 155.

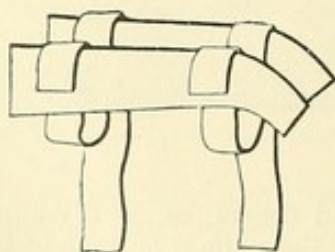


E. P. Smith's splint. B. Opposite surface. D, the hand-block, is connected with the forearm piece by two circular brass plates, which move upon each other, in order that the hand-block may assume any desired angle with the arm. In this way it may be adapted to either the right or left arm. It is fixed by a nut, seen on the brass plate. The letters C C indicate the extent of motion allowed to the hand-block.

Stephen Smith employs two broad, straight palmar and dorsal splints, secured in position by adhesive strips, the hand being thrown to the ulnar side by reversed turns of adhesive plaster.

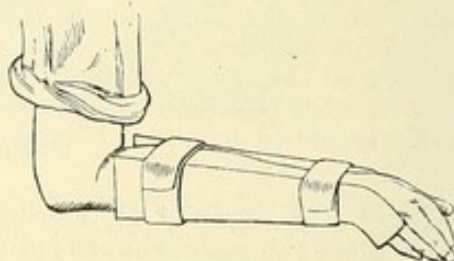
[The dressing referred to is as follows: Take two thin but firm pieces of board, each a little wider than the entire arm; make both of the splints slightly pistol-shaped at the lower extremity extending from two inches below the centre of the

FIG. 156.



Position of strips on the splints.

FIG. 157.



Dressing complete.

elbow when flexed, to the middle of the metacarpal bones of the hand (the splint for the posterior surface may be straight, and extend only to the carpo-metacarpal articulation); place a layer of cotton wadding along the surface of the

¹ Colles, Lectures on Surgery, p. 325.

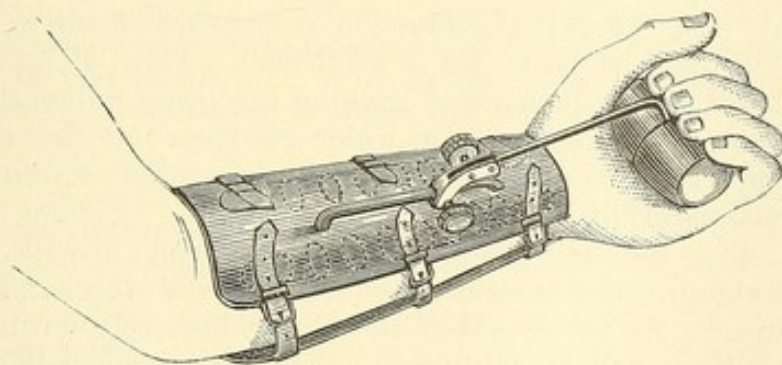
³ Skey, Operative Surgery, p. 161.

² Barton, Phil. Med. Exam., 1838.

splint next to the limb, thickest in the centre line, and add some cotton in mass so as to make compresses for additional pressure on the palmar and dorsal prominences of the misplaced bones, and cover each splint with a firm bandage; next cut two strips of common adhesive or rubber plaster, each two inches wide, and twenty-four inches in length. Apply one end of each to the outer side of the palmar splint, but overlapping the inner side, the adhesive surface next to the splint, the upper strip being near the upper end, and the lower at a point which will bring its lower margin under the styloid process of the ulna. Place this splint on the palmar surface of the forearm, and bring the adhesive strips over the outer side; now place the posterior splint in position, and bring the adhesive strips down over its outside, and around under the arm, then over the two splints, and thus complete the dressing. When properly applied this dressing has the following advantages: 1. The limb is uncovered; 2. It is supported in a sling between the splints; 3. Pressure is made accurately on the dorsal and palmar deformities; 4. Pressure is made on the styloid process of the ulna; 5. The hand is maintained in a position between pronation and supination; 6. If the dressing proves too tight, anyone may loosen it by raising the ends of the plaster sufficiently, and then reapplying them; the fingers and wrist have very free motion.]

Professor Fauger, of Copenhagen, has undertaken to treat this fracture in some sense without any splint, the forearm and hand being simply laid over a double-inclined plane, so as to bring the wrist into a state of forced flexion. "The hand having been brought into a position of strong flexion, the forearm is placed, pronated, on an oblique plane, with the carpus highest, the hand being permitted to hang freely down the perpendicular end of the plane."¹ M. Velpeau, in a report of his surgical clinic at La Charité for the year ending September, 1846, says this plan has been tried during this year, and "the result has not been very satisfactory. The experiment, however, has not been decisive upon this mode of treatment."²

FIG. 158.



Hewit's splint.

The late Henry S. Hewit, of this city, devised a very ingenious splint, by which the mobility of the wrist and fingers might be more perfectly retained, and the wrist put into any desirable position. The following is the description given by himself of the apparatus: "The wooden ball grasped by the hand is connected by a rod to a slender bar running longitudinally upon the face of the splint, and capable of being flexed at any desirable length. The rod is attached to the travelling connection by a universal joint, giving play to the ball in limited movements of flexion, extension, pronation, and supination. The natural tendency is for the patient to make these movements, and perpetually to relax and contract the fingers. The splint upon the inner surface of the arm is antagonized by a plain flat splint on the outer surface, extending to the superior border of the wrist-joint. This splint has been used for upward of two years by myself and others, and has given good results."³

¹ Fauger, London Lancet, May 8, 1857.

² Velpeau, Boston Med. Journ., vol. xxxv. p. 213.

³ Hewit, Med. Record, April 1, 1873.

[Dr. White, of Toronto, Canada, has used a cuff splint, not unlike Hewit's in its application to the wrist, with alleged success.¹]

We come now to consider how far this peculiar treatment, ulnar inclination, is capable of answering the special indication of the case we are studying. It is assumed, as I have already intimated, that by bearing the hand strongly to the ulnar side, the fragments of the radius are brought more exactly into apposition, and more easily and effectually retained; an assumption which supposes two things to have been determined: first, that there exists an overlapping of the fragments, either through the whole extent of their broken surfaces, or especially toward the radial side, or that the upper end of the lower fragment is inclined to fall against the ulna, or that all of these several conditions coëxist; and, secondly, that if such displacements do exist, they can be remedied by this manoeuvre. The first of these suppositions seems to have been sufficiently considered by all those gentlemen who have particularly examined the specimens contained in the various pathological collections, and to whose careful investigations I have already frequently adverted. With rare exceptions, none of these displacements have been found to exist, although, as has been observed, a casual inspection of the arm when recently broken would often lead to an opposite conclusion. I do not here speak of impaction which is usually upon the posterior margin, if it exists at all.

In regard to the second supposition, namely, that, where such displacements do exist, a forced adduction will aid in the retention of the fragments, I shall have to speak more cautiously, because, so far as I know, my opinions have received as yet no public and authoritative indorsement. In order that adduction may prove effective, there must be some point upon which to act as a fulcrum. It is of no use that we rotate the hand for the purpose of making extension unless there can be found a resistance or fulcrum upon which the rotary motion may be performed. Such a fulcrum exists, no doubt, but to determine its availability we must ascertain its character and position. It is not in the lower end of the ulna, for the ulna has no point of contact with the carpal bones, and when, in the natural state of these parts, the hand is inclined to the ulnar side, the lower end of the ulna rides freely downward upon the wrist until arrested by the ligaments which unite it with the carpus, or by the capacity of the joint to admit of motion in this direction. When the lower end of the radius is broken, and the ligaments of the joint are more or less torn, the ulna, although thrust downward much farther, perhaps, than it could ever descend in its normal state, still fails to find a support, and spreading wider and wider from the radius as it is thrust further upon the hand, no limit can be given to its progress in this direction. It was thus that, in one example already mentioned, I found the ulna carried downward one inch or more, and this was the fact in several cases reported by Moore, and verified by the autopsy.

The resistance will, then, in nearly all cases, be found to be in those ligaments which bind the lower fragment to the lower end of the ulna, and the ulna to the carpal bones, viz., the radio-ulnar, the triangular, and the internal lateral ligaments, which in the normal state of the parts

¹ Canada Practitioner, May, 1889.

constitute the centre upon which forced adduction expends its power, and which still continue to be the point of resistance when the radius is broken. But how feeble and uncertain must be a resistance which depends solely on these injured and often lacerated ligaments! And how painful to the patient must be an extension sufficient to overcome the action of nearly all the muscles of the wrist, which is borne entirely by a few torn and inflamed fibres! Even in health this position, when forced, cannot be endured beyond a few seconds, and it must be difficult to estimate the sufferings which the same position must occasion when the ligaments are torn and inflamed.

I am not to be told that surgeons have not intended to advocate this extreme practice; that they have never recommended forced adduction, but only a moderate and easy lateral inclination, such as can be comfortably borne. If they have not, then they should not have spoken of making extension by this means. An easy lateral inclination has no more power to do good, so far as extension is concerned, than it has power to do harm. But the fact is, while a majority of surgeons have no doubt used less force than was hurtful, some have used more than was useful or safe; indeed, the sharpness of the curve given to the splints figured and recommended by Dupuytren, Nélaton, and others, sufficiently indicates that their distinguished inventors intended to accomplish by these means a forced and violent adduction.

Malgaigne, speaking of other means of extension applied to the forearm, suggested by Godin, Diday, and Velpeau, intended to operate only in a straight line, and alluding especially to the modes devised by Huguier and Velpeau, remarks: "Without discussing here the comparative value of the two forms of apparatus, I believe that they could scarcely be endured by the patients; and M. Diday tells us that, in the trials which he has made, the pain produced by the extension was so great that he was compelled to renounce it." Which observations cannot but apply equally to this plan of extension by adduction or to any other which might be adopted. Dr. G. S. Porter, of Lonaconing, Maryland, has used for the purpose of extension a padded wire-splint applied to the dorsal surface of the arm and hand, and in which the extension is supposed to be effected by adhesive plaster strips.¹ Notwithstanding the testimony which the experience of this gentleman has furnished of the value of this method, and not doubting that he obtained satisfactory results, I must be permitted to say that probably they were due to the thoroughness with which he reduced the fracture in the first place, rather than to the efficiency of the apparatus; and I will take this opportunity of saying that the success claimed by Drs. Moore and Pilcher for their peculiar modes of treatment, neither of whom employs splints, depends, in my opinion, wholly upon the fact that they have had the good judgment and skill to reduce the fragments effectually in the first instance, after which, as I have already said, there is usually very little probability that they will become displaced. In cases which have been treated under my observation, these methods have given no better results than have other methods; indeed, I have not thought the success equal to that obtained by my own, and some other modes of dressing, for which, however, much less has been claimed.

It must not be inferred that I have concluded to reject this mode of dressing—the pistol-shaped splint—in all of its modifications; for although I am far from being persuaded of its utility as a means of extension and retention in any case, yet I am not prepared to deny to it

¹ Porter, Med. and Surg. Reporter, April 14, 1877.

some very considerable value in another point of view; and when judiciously employed it can certainly do no harm. It is, I repeat, for another reason altogether than the one heretofore assigned, that I would recommend its continuance, a reason which I cannot so well explain, or hope to render intelligible, except to the practical surgeon. This position throws the whole lower end of both radius and ulna outward toward the radial margin of the splints, and by keeping the radius more completely in view, it enables the surgeon better to judge of the accuracy of the reduction, and to recognize more readily the condition and situation of the compresses, etc. This alone I have always considered a sufficient ground for retaining the angular splint; although I have treated a great number of arms satisfactorily with the straight splints alone.

Finally, while surgeons have been seeking to meet an indication, the existence of which is at least rendered doubtful, and by means which appear to me totally inadequate if it did exist, they have probably too often overlooked or regarded indifferently an indication which is almost uniformly present, namely, to press thoroughly forward the tilted fragment by a force applied upon the wrist from behind, and to retain it in place by suitable compresses. And I cannot help thinking, that, if they had regarded this as the sole indication in most cases, an indication generally so easily met, they would have made fewer crooked arms, and have saved their patients much suffering and themselves much trouble. In support of this opinion, I must be permitted to say again that in my own practice deformity after this fracture is the exception. I never apprehend its occurrence unless there is comminution, or other serious complications.

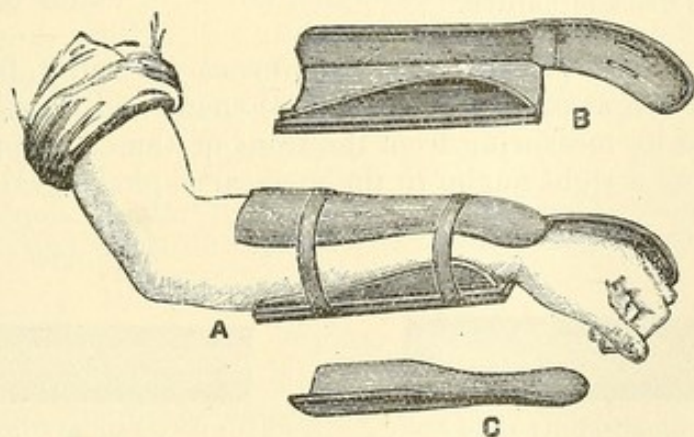
In other, and somewhat exceptional cases where the lower fragment is driven back until its broken surface overrides the broken surface of the upper fragment, and in addition to the consequent impaction there is added a lifting of the periosteum, as described by Pilcher, we must first, as stated by him, increase the dorsal flexion, press the finger against the proximal end of the lower fragment, and then, while making extension from the hand, gradually bring the hand and the lower fragment forward. And I may add that if, by the method of direct and forcible pressure from behind, or by Pilcher's modification of this method, we have once brought the lower fragment thoroughly into place, it will remain in place with little or no retentive apparatus; unless, indeed, the lower fragment be comminuted, in which case some degree of deformity will ensue whatever plan of treatment we may adopt. In case the ulna is dislocated also, and is imprisoned by the annular ligament, circumduction with extension, as practised by Dr. Moore, and heretofore described, will be required.

It only remains for us to determine the precise form of splint which ought to be preferred, and to describe its mode of application. The narrow "*attelle cubitale*" of Dupuytren is inconvenient; nor can I give the preference to the curved dorsal splint recommended by Nélaton, and employed by Robert Smith, Erichsen, and others. It is not to me a matter of entire indifference, in case only one curved splint is employed, whether this be applied to the palmar or dorsal surface of the forearm. Foreign surgeons, so far as I know, have applied this splint to the dorsal surface,

and the straight splint to the palmar; while American surgeons have adopted almost as uniformly the opposite rule—to whose practice, in this respect, I acknowledge myself also partial. It is to the curved splint rather than to the straight that we mainly trust; not simply, or at all, perhaps, because of its form, but because the curved splint is also the long splint. This is the splint, therefore, which ought to be the most steady and immovable in its position. Now, the very irregularities of surface upon the palmar aspect of the forearm and hand, instead of constituting an embarrassment, enable us, when the splint is suitably prepared and adjusted, to fix it more securely. Moreover, upon it alone, after a few days, the surgeon may see fit to rely, and in that case it ought to be applied to that surface of the arm which is most tolerant of continued pressure. The palmar surface, as being more muscular, and as having been more accustomed to friction and to pressure, must necessarily have the advantage in this respect. The palmar splint terminating also at the metacarpo-phalangeal articulations, instead of at the wrist, as the short straight splint must do when the hand is adducted, enables the hand to be flexed upon its extremity over a hand-block, or pad of proper size. Such are the not insignificant advantages which we claim for this mode over that pursued by our transatlantic brethren. The block, suggested first by Bond, of Philadelphia, is a valuable addition, since the flexed position is always more easy for the fingers, and in case of ankylosis this position renders the whole hand more useful.

[Gordon's splint is very highly commended by Irish surgeons, but it is not in use in this country. It "consists of the body, the ulnar, and bevelled portions, with a curved back splint (Fig. 159). The lower end of the ulnar portion is curved forward, and hollowed to receive the inner border of the flexed hand, with a slit for the carpal strap. The bevelled portion is secured to the body of

FIG. 159.



Gordon's splint. B. The palmar splint. C. The dorsal splint. A. The splints applied.

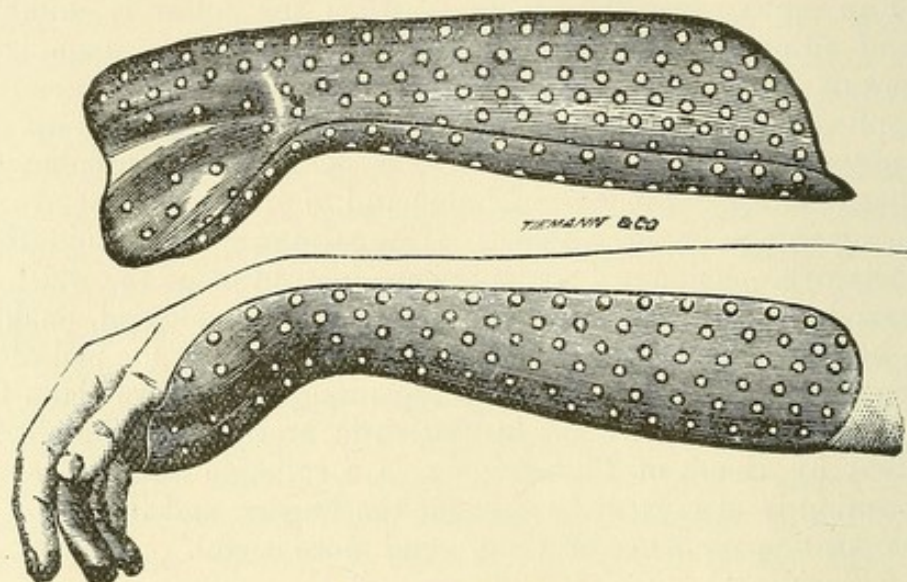
the splint nearly half an inch internal to its margin; it is cut off obliquely from without inward and from below upward; it is applied to the palmar surface of the upper fragment, which it is its office to fix. The lower end of the back splint is much curved forward. The curve, with a thick pad, is necessary to enable it to press the base of the metacarpus, the carpus, and the lower end of

¹ Bryant, *Prac. of Surgery*, 4th ed., p. 880.

the lower fragment well forward for the restoration of the natural aspect of the carpal surface and the concavity of the radius."]

Levis employs a splint made of copper, lined with tin, and furnished with a series of little pointed elevations along the edges to prevent the bandage from slipping.¹ No doubt this splint would answer its purpose well in case it fitted accurately; but to insure this the surgeon must be supplied with a considerable number, differing materially in length, breadth, and form; or it must be made for the patient who is under treatment. I have occasionally employed a splint

FIG. 160.



Levis's metallic splint.

of this form; once when I had broken my own wrist—a Colles's fracture—and with admirable results; but I have always used for this purpose a pretty thick sheet of gutta-percha, which in a few minutes can be fitted with the most absolute accuracy. Gum-shellac cloth can be adapted, after thorough soaking in boiling-hot water, with nearly the same degree of accuracy, and I think sole-leather might also; but in the latter case, after being moulded it would have to be laid aside to dry and harden.

In most cases I prepare extemporaneously a splint from a wooden shingle, which I first cut into the requisite shape and length; the length being obtained by measuring from the front of the elbow-joint, when the arm is flexed to a right angle, to the metacarpo-phalangeal articulations,

FIG. 161.



Author's palmar splint; right arm.

FIG. 162.



Author's dorsal splint; frequently omitted.

the fingers being first flexed. It ought, indeed, to fall half an inch short of the bend of the elbow, to render it certain that it shall make no uncomfortable pressure at this point; and the direction to measure with the arm flexed is of sufficient importance to warrant a repetition. The breadth of the splint should be in all its extent just equal to the breadth

¹ Levis, R. J. (pamphlet without date).

of the forearm in its widest part, except where it is to receive the ball of the thumb, so that there shall be no lateral pressure upon the bones. If the splint is of unequal breadth, the roller cannot be so neatly applied, and it is more likely to become disarranged. Thus constructed, it is to be covered with a sack of cotton-cloth, made to fit moderately tight, with the seam along its back, and afterward stuffed with cotton-batting or with curled hair. These materials may be pushed in, and easily adjusted, wherever they are most needed, from the open extremities of the sack. While preparing, the splint must be occasionally applied to the arm until it fits accurately every part of the forearm and hand, only that the stuffing must be more firm a little above the lower end of the upper fragment, and in the hollow of the hand. Between these two points there should be little or no cotton. The open ends of the sack are then to be neatly stitched over the ends of the splint, after which the splint may be laid directly upon the skin without any intermediate compresses or rollers. The advantages of this form of splint are easily comprehended. They consist in facility and cheapness of construction, accuracy of adaptation, neatness, permanency, and fitness to the ends proposed. There is also no possibility of making painful or injurious pressure upon the arteries or nerves which lie upon the front of the wrist.

The extemporaneous splint recommended by Dr. Isaac Hays, of Philadelphia, is very similar, but it lacks the neatness and permanency of that which I have now described.

In most cases it is better to employ, also, at least during the first fortnight, a straight dorsal splint, of the same breadth as the palmar splint, and of sufficient length to extend from the elbow to the middle of the carpus. This should be covered and stuffed in the same manner as the palmar splint, except that here the thickest and firmest part of the splint must be opposite the carpus and the lower fragment.

Having restored the fragment to place by some one of the methods already described, the arm is to be flexed upon the body, and placed in a position of semi-pronation; when the splints are to be applied, and secured with a sufficient number of turns of the roller, taking especial

FIG. 163.



The author's dressing complete. The curved palmar splint is not in view, only the dorsal. The faint white lines represent the roller. The sling is omitted, for the purpose of bringing the other dressings into view.

care not to include the thumb, the forcible confinement of which is always painful and never useful.

Let me repeat that, in most cases, all of our success will depend not so much upon the particular form of apparatus employed as upon whether we have properly reduced the fracture in the early stage of the accident. When once reduced it is, with rare exceptions, easily kept in place.

I cannot too severely reprobate the practice of violent extension of the wrist in the efforts at reduction, when no overlapping or impaction of the fragments exists and the ulna is not dislocated; and that, whether this extension be applied in a straight line or with the hand adducted. It has been shown that in a great majority of cases no indication in this direction is to be accomplished; and to pull violently, under these circumstances, upon the wrist, is not only useless, but hurtful. It is adding to the fracture, and to the other injuries already received, the graver pathological lesion of a stretching, a sprain of all the ligaments connected with the joint. I am persuaded that to this violence, added to the unequal and too firm pressure of the splints, is, in a great measure, to be attributed the subsequent inflammation and ankylosis in very many cases.

The first application of the bandages ought to be only moderately tight, and as the application and swelling develop in these structures with rapidity, the bandages should be attentively watched, and loosened as soon as they become painful. It must be constantly borne in mind that, to prevent and control inflammation in this fracture, is the most difficult and by far the most important object to be accomplished, while to retain the fragments in place, when once reduced, is comparatively easy. During the first seven or ten days, therefore, these cases demand the most assiduous attention; and we had much better dispense with the splints entirely, as advised by Fauger, than to retain them at the risk of increasing the inflammatory action.

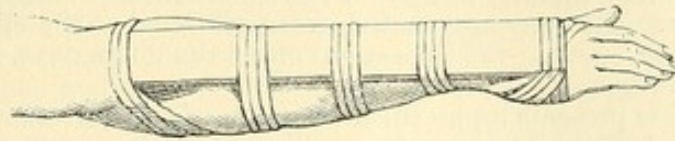
Indeed, I have no doubt that very many cases would come to a successful termination without splints, if only the hand and arm were kept perfectly still in a suitable position until bony union was effected. I must also enter my protest against many or all of those carved splints which are manufactured, hawked about the country, and sold by mechanics who are not surgeons; with a fossa for each styloid process, a ridge to press between the bones, and various other curious provisions for supposed necessities, but which never find in any arm their exact counterparts, and only deceive the inexperienced surgeon into neglect of the proper means for making a suitable adaptation. They are the fruitful sources of excoriations, ulcerations, inflammations, and deformities.

[Swinburne, of Albany, employed a form of dressing which has had some advocates. He proposed its use in all fractures of the lower end of the radius. It consisted of a single splint, a thin piece of wood, extending from the elbow to the metacarpo-phalangeal joints on the posterior aspect the width of the limb; two compresses are provided, one for the concavity of the carpus, and the other for the deficiency of the muscles in the arm above; adhesive strips are employed for fastening the splint to the arm, commencing above, and being repeated at intervals to the hand; the displaced bones are properly reduced before the strips are applied. The following illustrations (Figs. 164, 165, 166) show the application of the dressing and appearance of the limb.

In reference to the treatment of these fractures, the following cases and the accompanying remarks, by that great surgeon, Dupuytren, are too pertinent not to merit a place in every treatise of this character.

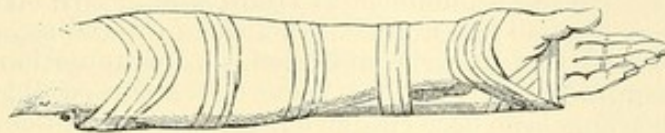
"The two succeeding cases are not only interesting as fractures of the radius, but they are further deserving of attentive consideration, on account of the serious complications which accompanied them, and which were the consequence

FIG. 164.



Posterior aspect of arm.

FIG. 165.



Anterior aspect of arm.

FIG. 166.



The two compresses.

of forgetting an important precept. More than once, indeed, it has occurred that the surgeons have been so intent on preserving fractures in their proper position that the extreme constriction employed has actually caused destruction of the soft parts. A piece of advice which I have very frequently given, and which I cannot too often repeat, is to avoid tightening too much the apparatus for fractures during the first few days of its being worn; for the swelling which supervenes is always accompanied by considerable pain, and may be followed by gangrene. It cannot, therefore, be too urgently impressed on young practitioners, to pay attention to the complaints which patients make; and to visit them twice daily, and relax the bandages and straps as need may be, in order to obviate the frightful consequences which may spring from not heeding this necessary precaution; by carefully attending to this point I have been saved the painful alternative of ever having to sacrifice a limb for complications which its neglect may entail.

"A. R., *æt.* 44, fractured his right radius while going down into a cellar. When the fracture was reduced (it was near the base of the bone) an apparatus was applied, but fastened too tightly; and, notwithstanding the great swelling and the acute pain which the patient endured, it was not removed until the fourth day, when the hand was cold and oedematous, and the forearm red, painful, and covered with vesications. Leeches, poultices, and fomentations were applied, and followed by some alleviation of the local symptoms, though there was much constitutional disturbance. At the close of a fortnight from the accident, the palmar surface of the forearm presented a point where fluctuation was supposed to exist; but when a bistoury was plunged into it no matter followed. Portions of the flexor muscles subsequently sloughed, and the skin mortified. The only resource was amputation, which was performed above the elbow six weeks after his admission; and he afterward recovered without the occurrence of any further untoward symptoms.

"R., *æt.* 36, was at work boring an artesian well when he was struck by part of the machinery on the right arm; he was instantly knocked down and thrown violently on the right thigh. A surgeon who was sent for detected a fracture of the radius, and applied the usual apparatus, consisting of pads and splints, confined by a roller extending from the extremities of the fingers to the elbow,

which compressed the arm so tightly as to give rise to very great suffering. The fingers, hand, and forearm were numbed almost to insensibility, and yet the surgeon in attendance did not think proper to loosen the apparatus. Such was the condition of the patient until he came to the Hôtel Dieu, four days after the accident; the fingers were then black, cold and insensible, and when I removed the splints I found the hand likewise black, especially on its palmar surface. On the twelfth day amputation was performed at the elbow-joint; but the patient did not survive the operation more than ten days, the immediate cause of death being acute pleurisy.

"The above case presents a painful illustration of the neglect to which I have alluded. In nearly every instance the swelling of the limb requires that careful attention should be paid to the bandage or straps by which the apparatus is confined. Similar accidents are likely to result from the employment of an immovable apparatus, of which an example occurred in the practice of M. Thiéry, one of my pupils. He was summoned to visit a young girl, on whom such an apparatus had been applied for supposed fracture of the radius. After suffering excruciating torment, the forearm mortified, and amputation was the only resource; on examining the limb, no trace of fracture could be discovered. Had a simple apparatus been here employed, and properly watched, the patient's limb would not have been sacrificed."¹

Robert Smith mentions, also, the case of a boy, æt. 18, who had a fracture of the lower extremity of the radius, through the line of the junction of the epiphysis with the diaphysis, caused by being thrown from a horse. A surgeon applied, within an hour, a narrow roller tightly around the wrist. On the following day the limb was intensely painful, cold and discolored; still the roller was not removed, nor even slackened. On the fourth day he was admitted into the Richmond Hospital, when the gangrene had reached the forearm. Spontaneous separation of the soft parts finally occurred, and the bones were sawn through twenty-four days after the fracture was produced, from which time "everything proceeded favorably."²

Nov. 21, 1851, a boy, ten years old, living in the town of Andover, Mass., had his left hand drawn into the picker of a woollen mill, producing several severe wounds of the hand and a fracture of the radius near its middle. One of the wounds was situated directly over the point of fracture, but whether it communicated with the bone or not was not ascertained. A surgeon was called, who closed the wounds, covered the forearm with a bandage from the hand to above the elbow, and applied compresses and splints. The lad made no complaint, his appetite remaining good, and his sleep continuing undisturbed until the third day, when he began to speak of a pain in his shoulder; on the same day also it was noticed that his hand was rather insensible to the prick of a pin. Early on the morning of the fourth day his surgeon, being summoned, found him suffering more pain and quite restless; and on removing the dressings, the arm was discovered to be insensible and actually mortified from the shoulder downward. On the sixth day a line of demarcation commenced across the shoulder, and on the twenty-first day the father himself removed the arm from the body by merely separating the dead tissues with a feather. Subsequently a surgeon found the head of the humerus remaining in the socket, and removed it, the epiphysis having become separated from the diaphysis. The boy now rapidly got well. This case became the subject of a legal investigation. Dr. Pillsbury, of Lowell, Mass., declared that in his opinion this unfortunate result had been caused by too tight bandaging, and by neglecting to examine the arm during four days. On the other hand, Drs. Hayward, Bigelow, Townsend, and Ainsworth, of Boston, with Kimball, of Lowell, Drs. Loring and Pierce, of Salem, believed that the death of the limb was due to some injury done to the artery near the shoulder-joint; and in no other way could they explain the total absence of pain during the first two days; nor could they regard this condition as consistent with the supposition that the bandage occasioned the death of the limb.³

¹ Dupuytren, *Injuries and Diseases of Bones*, Syd. ed., London, 1847, pp. 145-7.

² R. Smith, *Treatise on Fractures*, etc., Dublin, 1854, p. 170.

³ Boston Med. and Surg. Journ., vol. xlviii. p. 281.

I cannot but think, however, that these gentlemen were mistaken, and that the gangrene was alone due to the bandages. In a similar case which came under my own observation, and in which both the radius and ulna were broken, the roller extended no higher than just above the elbow, and the patient complained of no pain until the bandages were unloosed, yet the arm separated at the shoulder-joint. I shall refer again to this example in the chapter on Fractures of the Radius and Ulna; and shall take occasion then also to speak more fully of the causes of these terrible accidents.

Norris mentions another case of compound fracture of the lower end of the radius which came under his notice at the Pennsylvania Hospital in August, 1837, the arm having been dressed by a surgeon within half an hour after the accident, with bandages and splints. When these bandages were removed at the hospital, on the fifth day, "the soft parts around the fracture were found to have sloughed, an abscess extended up to the elbow-joint, and sloughs existed over the condyle. Severe constitutional symptoms arose, making amputation of the arm necessary."¹

A lady, æt. 50, was also seen by Thierry, who, having broken the radius near its lower end, lost her fingers by the sloughing consequent upon a tight bandage.²

A woman was admitted into one of Dr. Wood's wards in the Bellevue Hospital about the 1st of February, 1863, who had fallen upon her hand a few days before and broken the radius just above the wrist. Her arm was dressed with splints and bandages at one of the dispensaries in this city. Gangrene ensued, and when I saw her on the 8th of February, the death had extended to the middle of the forearm, the dead tissues being dry and black. Dr. Wood amputated the arm, but she died.

The remarks which have now been made in relation to the treatment of Colles's fracture are applicable, with only such slight modifications as would naturally be suggested, to fractures of the lower end of the radius commencing upon the radial side of the bone and extending obliquely downward into the joint (perhaps, indeed, this ought to be regarded as a variety of Colles's fracture); and it is to this form of fracture, especially, that the pistol-shaped splint must be found applicable. If the fracture actually extends into the joint, it must not be forgotten that, in order to the prevention of ankylosis, the wrist should be early subjected to passive motion.

The following example of a compound comminuted fracture of the radius may serve to illustrate the value of a mode of treatment under certain circumstances: W. C., æt. 30; a large piece of iron casting fell upon his arm, crushing and lacerating the wrist, and comminuting the lower part of the radius. I found the whole of the soft parts torn away in front of the joint, and the fragments of the radius projected into the flesh in every direction. The hope of saving the hand seemed to be scarcely sufficient to warrant the attempt; at least by the ordinary mode of procedure. I, however, believed it could be saved if, having removed the fragments of the radius, I practised resection of the lower end of the ulna, and allowed the muscles to become completely relaxed. Accordingly, after placing him under the influence of chloroform, I enlarged the wounds so as to enable me to remove six or seven fragments of the radius, leaving others which were broken off but not much displaced. I then removed with the saw one inch and a half of the ulna. The hand was immediately drawn up by the contraction of the remaining muscles, but their tension was completely relieved. The wounds were closed and dressed lightly, and the whole limb was placed on a broad and well-padded splint covered with oil-cloth. The hand, which was very pale and exsanguine, was covered with warm cotton-batting. His recovery was rapid and complete, nor was there at any time excessive inflammation in the limb. I

¹ Norris, note to Liston's Surgery, p. 54.

² Amer. Journ. Med. Sci., vol. xxv. p. 461, from *L'Expérience* for 1838.

have seen this man frequently since he left the hospital, and while he has recovered only a little motion in the wrist-joint, his hand and fingers are nearly as useful as before the accident. He is able to perform all ordinary kinds of labor with almost as much ease as most other men; and, what is always gratifying to the humane surgeon, he does not fail to appreciate fully the service which has been conferred upon him by the preservation of his mutilated hand. I have recently adopted the same treatment with equal success in a case of gunshot wound of the lower end of the radius.

[Harte,¹ of Philadelphia, has performed osteotomy for vicious union of this fracture with good results. He operated antiseptically, making an incision along the inner margin of the extensor carpi radialis tendons, and then applying the chisel. Duplay has also operated for the same deformity.]

Fracture of the Styloid Process of the Radius Independently of a Colles's Fracture.—Dr. Butler, of the Brooklyn Hospital, reports a case treated by Dr. J. C. Hutchison of fracture of the right radius at the junction of the middle and lower thirds, accompanied with a fracture also of the styloid apophysis in the above bone.

The accident occurred in a lad fourteen years old, who had fallen from a height of thirty feet upon the pavement. The lower fracture commenced at the base of the styloid process of the radius, and extended down obliquely into the wrist-joint, breaking off about one-fifth of the articular surface. The process was drawn up on the posterior surface of the radius, about one inch and a half, by the supinator radii longus muscle. It was movable, but, in consequence of the contusion and swelling, could not be returned to its place. The hand occupied the same position that it does in Colles's fracture. On the eighth day an attempt was made to force down the process with a compress secured by adhesive plaster straps; but it could not be done. The hand and arm were confined also to a pistol-shaped splint; ulcerations ensued from the pressure of the compress, and the process was laid bare, but it finally became united in its abnormal position; the motions of the wrist, however, were not impaired, and the power of pronation and supination soon returned.²

A lady called upon me having a fracture of the styloid process of the radius, which had occurred about four months previously. The fragment was tilted forward and carried slightly upward by the action of the long supinator. It was movable. The motions of the joint were in no way interfered with, and the form of the wrist was natural. She was somewhat advanced in life, and suffered from pains and soreness about the joint, but no more than is usual after severe wrist-joint injuries. The character of the accident was not recognized by her surgeon, and no treatment had been adopted; nor is it to be supposed that the displacement could have been remedied, except by section of the tendon of the long supinator, if its existence had been recognized; and, if this had been done, I doubt whether she would have had a more useful arm than she has now.

Dr. Wm. Hunt,³ of Philadelphia, reported a case of this fracture, the result of a fall upon the hand, and accompanied with considerable comminution. It became necessary to amputate the arm, and the opportunity was thus afforded to determine the exact nature of the lesion by dissection.

Epiphyseal Separations.—This bone is formed from three centres, namely, one for the shaft and one for either extremity. The shaft is ossified at birth. About the end of the second year ossification commences in the lower epiphysis, and it becomes united to the shaft at about the twentieth year. The same process commences in the upper epiphysis at about the fifth year, and is completed by consolidation with the shaft at the age of puberty.

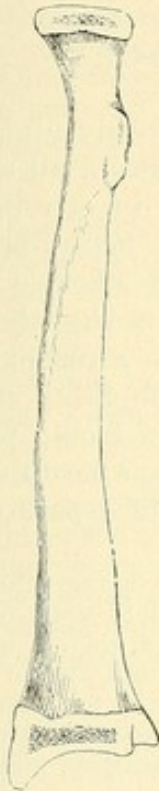
¹ Univ. Med. Mag., Aug. 1887.

² New York Journ. of Med., 1857.

³ Hunt, Phil. Med. Times, Oct. 9, 1880, p. 26.

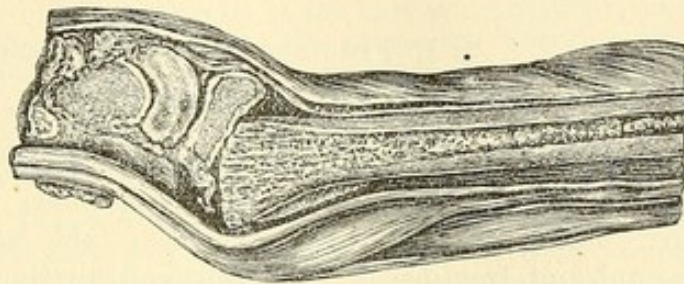
I have met with no recorded examples of separation of the upper epiphysis, and the examples of separation of the lower epiphysis have seldom been clearly made out. I have already mentioned one as having been reported by Robert Smith. He speaks also of other cases occurring in conjunction with a separation of the lower end of the ulna, and which, he thinks, are liable to be mistaken for dislocations.¹

FIG. 167.



Radius with epiphyses.
(From Gray.)

FIG. 168.



Vertical section of radius and soft parts, showing separation and backward displacement of the lower epiphysis of the radius. (Bryant.)

Malgaigne says that we have reasons to suspect this accident when the fracture occurs in persons under twenty years of age. Cloquet ascertained its existence by a dissection in a child of twelve years; Roux also in a child whose age is not given, and Voillemier produced it easily in the dead bodies of children, and once in the body of a robust man of twenty-four.² Schmidt³ and Girdner⁴ have also noticed the frequency of the epiphyseal separation when, in the case of infants, the fracture is caused by avulsion upon the cadaver. The experiments of Dr. Girdner, made at my request, also showed that in early life avulsion sometimes caused a fracture just above the epiphysis, sometimes a bending of the bone, without fracture, and sometimes only a rupture of the liga-

ments. I think I have broken the radius at the epiphyseal junction in some of my experiments of forced flexion in adult females.

[Moullin,⁵ of London, reports a case of separation of the upper epiphysis of the radius in a boy sixteen years of age. Amputation was performed. The upper epiphysis was completely detached, the line of separation passing between the cartilage and the diaphysis. Bryant, of London, gives an illustration of a separation of the lower epiphysis backward. The patient was a boy aged ten years. (Fig. 168.)]

The treatment of this accident will not demand any special consideration, since it will not differ essentially from the treatment required in a fracture occurring at the same point.

Delayed or Non-union of Fractures of the Radius.—Muhlenburg in his tables has recorded 23 cases, of which 17 are reported as having been cured, and in 6 the attempts to cure have failed. Resection and drilling furnish the largest percentage of cures. I have never met with an example of non-union in a fracture of the lower end of the radius.

¹ Robert Smith, *op. cit.*, p. 164.

² Malgaigne, *op. cit.*

³ Schmidt, *Thèse de Paris*, 1878, No. 114.

⁴ Girdner, *Jno. H., Med. Record*, Feb. 26, 1881.

⁵ *Trans. Path. Soc., Lond.*, vol. xxxix., 1888.

CHAPTER XXIII.

FRACTURES OF THE ULNA.

§ 1. Fractures of the Olecranon Process.

Causes.—My records furnish me with accounts of only nineteen of these fractures, and, so far as I have been able to ascertain, all were occasioned by falls upon the elbow, or by blows inflicted directly upon the part. Malgaigne has, however, been able to collect accounts of six examples of fracture of the olecranon, produced, as is affirmed, by the violent action of the triceps; as in pushing with the arm slightly flexed, in throwing a ball, in plunging into the water with the arms extended, etc.; but only four of these reported examples does he think are sufficiently authenticated to entitle them to be received as facts; nor do I think it possible to affirm positively that in any instance, where the whole process is broken off, the triceps alone has occasioned the separation.

For example, Capiomont reports the case of a cavalier, who, being intoxicated, was thrown head-foremost from his horse, and, striking probably upon his head, was found to have broken the olecranon process. We do not, in this example, see evidence alone of a forcible contraction of the triceps, but also of violent pressure against the hand and in the direction of the axis of the forearm toward the elbow-joint, by which the olecranon process might have been so thrown forward against the fossa of the humerus as to cause its separation. The same explanation might apply to several of the other examples.

Point and Direction of Fracture; Displacement, etc.—The process may be broken at its summit, at its base, or intermediate between these two extremes, the last of which is the most common. It is probable that when the action of the triceps alone has produced the fracture, it will be found that only that portion which receives the insertion of the triceps has been broken off.

Malgaigne, who has been able to find upon record only two cases of a fracture of the extreme end of the process, declares that they were both occasioned by muscular action.

Fractures of the middle are generally transverse, or only slightly oblique, occurring in the line of the junction of the epiphysis with the diaphysis. Fractures through the base are generally quite oblique, the line of fracture extending from before downward and backward, so that not only the whole of the process, but a portion of the back of the shaft is carried away; and this accident can scarcely happen, except by a blow received upon the front and lower end of the humerus, while the arm is extended; or by a blow upon the back of the forearm, whether the arm be in a position of flexion or extension, received at a point a little below where the shaft of the ulna joins the olecranon.

[Lloyd,¹ of Birmingham, describes a form of fracture of the olecranon which narrows the great sigmoid notch and obstructs the reduction of a dislocated elbow. The case came under his care about ten months after a fall from a bicycle. The limb was in such condition as to require the operation of excision of the lower, broken end of the humerus. It was found, however, that there was a dislocation of the ulna and radius backward, and a fracture of the olecranon. This fracture ran transversely across the superior surface of the process, nearly an inch from its extremity, corresponding closely to the anterior edge of the insertion of the triceps tendon. The fracture extended obliquely downward and forward, and ended in the great sigmoid notch at its deepest part, the articular surface being thereby divided into two nearly equal halves. Another fracture appeared to have passed from a point half an inch nearer the olecranon tip to join the first fracture at about its centre, separating a small triangular piece from the posterior angle of the whole fragment. This wedge-shaped fragment had been driven downward and forward into the notch, so as to narrow it to a mere cleft, reducing its longitudinal diameter from three-fourths to one-fourth of an inch.]

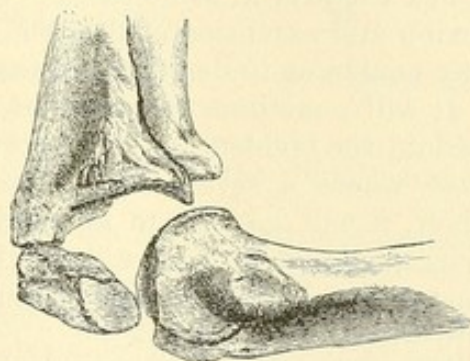
Mr. Lloyd states that from a study of the specimen, it is evident that the man must have fallen upon the extreme top of the olecranon with the joint in acute flexion, and that the same force which detached the fragment drove it forward into the sigmoid notch, thrusting the humerus out of the articulation, and breaking it across just above the condyles. An exact diagnosis would be a matter of extreme uncertainty. The most suggestive symptoms are: the impossibility of reduction, the absence of the characteristic sharp outlines of the top of the olecranon, the shortening of the ulna measured from the top of the olecranon to the styloid process. He thinks the parts might have been moulded into position under an anæsthetic shortly after the injury.]

The only displacement to which the upper fragment seems to be liable, is in the direction of the triceps; and the degree of this displacement does not depend so much upon the point at which the fracture has taken place as upon the violence which has occasioned it, the extent of the disruption of the ligaments, aponeurosis of the triceps and of the capsule, and upon whether, since the accident, the arm has been flexed or kept extended.

In five instances I have found distinct crepitus immediately after the fracture had occurred, produced by only moving the fragment laterally, showing plainly that little or no displacement had taken place.

The following example will show also that this displacement does not always happen even after the lapse of several days, and where no surgical treatment has been adopted. S. D., æt. 14, fell upon the point of the elbow, and two days after was admitted to the Buffalo Hospital of the Sisters of Charity. The elbow was then much swollen, but no crepitus could be detected, and he could nearly straighten his arm by the action of the triceps. On the sixth day, the swelling having sufficiently subsided, a distinct crepitus was discovered when the olecranon process was seized between the fingers and moved laterally. We extended the arm immediately, and applied a long gutta-percha splint to the whole front of the arm and forearm, securing it in place with a roller. On the eleventh day, five days after the first dressing, the splint was taken off and its

FIG. 169.



Fracture of the olecranon at its base.

¹ London Lancet, May 5, 1888.

angle at the elbow-joint slightly changed; and this was repeated every day until the twenty-second from the time of the accident. The splint was then finally removed, when the fragment was found to be united without any perceptible displacement, and the motions of the joint were unimpaired.

It must not be inferred that it is always prudent to leave this fracture thus unsupported, since it has occasionally happened that the displacement, which did not exist at first, has taken place to the extent of half an inch or more, after the lapse of several days. Mr. Earle mentions a case in which the separation did not take place until the sixth day, when it was occasioned by the patient's attempting to tie his neckcloth.

Symptoms.—The usual signs of a fracture of the olecranon process are, when the fragments are not separated, crepitus, discovered especially by seizing the process and moving it laterally; or, when displacement has actually taken place, the crepitus may be discovered sometimes by extending the forearm, and pressing the upper fragment downward until it is made to touch the lower fragment; the existence of a palpable depression between the fragments, partial flexion of the forearm, and inability on the part of the patient to straighten it completely, or even to flex the arm in some cases. If the fragments do not separate, gentle flexion and extension of the arm, while the finger rests upon the process, may enable us to detect the fracture.

It will sometimes happen that, owing to the rapid occurrence of tumefaction, the evidence of a fracture will be quite equivocal; and, in all cases where a severe injury has been inflicted upon the point of the elbow, it will be well to suspend judgment until, by repeated examinations, made on successive days, the question is determined. Meanwhile, the arm ought to be kept constantly in an extended position, as if a fracture was known to exist.

Prognosis.—In a large majority of cases this process becomes reunited to the shaft by ligament, which may vary in length from a line to an inch or more, and which is more or less perfect in different cases. Sometimes it is composed of two separate bands, with an intermediate space, or the ligament may have several holes in it; at other times it is composed in part of bone and in part of fibrous tissue; but most frequently it is a single, firm, fibrous cord, whose breadth and thickness are less than those of the process to which it is attached. If the fragments are maintained in perfect apposition, a bony union may occur, yet it is not invariably found to have taken place, even under these circumstances.

[Macewen,¹ of Glasgow, attributes failure to obtain bony union of the olecranon to the interposition of shreds of fibrous tissue between the bones, as in fracture of the patella.]

Malgaigne thinks, also, he has seen one case in which there was neither bone nor fibrous tissue deposited between the fragments. This was an ancient fracture at the base of the olecranon; the superior fragment remained immovable during the flexion and extension of the arm, yet it could be moved easily from side to side.

In my own cases I have five times found the fragments united without any appreciable separation, and have presumed that the union was bony. One of these examples I have already mentioned; the second was in the person of a lady, aged about forty years, who, having fallen down a flight of steps, I found

¹ Annals of Surgery, vol. v., 1887.

a large bloody tumor covering the elbow-joint, but there was no difficulty in detecting a fracture of the olecranon process. It was easily moved from side to side, and this motion was accompanied with a distinct crepitus. During the first week the arm was only laid upon a pillow, but as it was found to become gradually more flexed, and the swelling having in a great measure subsided, the arm was nearly, but not quite, straightened, and a long gutta-percha splint applied to the palmar surface of the forearm and arm. The fragments united in about twenty or twenty-five days, and without separation, so far as could be discovered in a very careful examination.

The third example to which I have referred, occurred in a boy fourteen years old, and was treated by Dr. Benjamin Smith, of Berkshire, Massachusetts. Sixty-nine years after, he being then eighty-three years old, I found the olecranon process united apparently by bone, but to that day he had been unable to straighten the arm completely, or to supine it freely.

In one instance I found the fragment, after the lapse of one year, united by a ligament, which seemed to be about one-quarter of an inch in length, and the arm appeared to be in all respects as perfect as the other. He could flex and extend it freely.

In the two following examples, also, the bond of union was ligamentous:

J. C., æt. 18, having broken the olecranon, it was treated with a straight splint. Nine years after, I found the process united by a ligament half an inch in length, and he could nearly, but not entirely, straighten the arm. In all other respects the functions and motions of the arm were perfect.

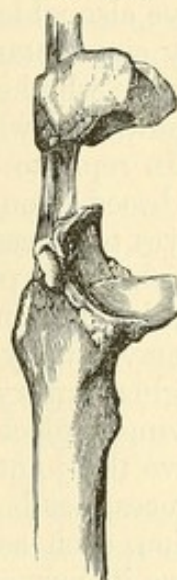A lad, æt. 15, was brought to me, whose olecranon process had been broken by a fall six months before, and at the same time the head of the radius had been dislocated forward. I found the radius in place, and the olecranon process united by a ligament about half an inch in length. He was not able to straighten the arm completely, the forearm remaining at an angle of 45° with the arm.

Treatment.—It will surprise the student who is yet unacquainted with the literature of our science, to learn that in relation to the treatment of a fracture of the olecranon process a wide difference of opinion has been entertained as to what ought to be the position of the arm and the forearm, in order to the accomplishment of the most favorable results; and that, while some insist upon the straight position as essential to success, others prefer a slightly flexed position, and still others have advocated the right-angled position.

Thus Hippocrates, and nearly all of the earlier surgeons, down to a period so late as the latter part of the last century, directed that the arm should be placed in a position of semiflexion; Boyer, Desault, and, after them, most of the French surgeons of our own day, prefer a position in which the forearm is very slightly bent upon the arm; while Sir Astley Cooper, and a large majority of the English and American surgeons, employ complete or extreme extension.

The arguments presented by the advocates and antagonists of these various plans deserve a moment's consideration. In favor of the position of semiflexion, requiring no splints, and, in the opinion of some writers, not even a bandage, but only a sling to support the forearm, it is claimed that it leaves the patient at liberty at once to walk about and to move the elbow-joint freely, so soon at least as the subsidence of the

FIG. 170.



Union by ligament.

swelling and pain will permit, and that in this way the danger of ankylosis is greatly diminished; that, moreover, if ankylosis should unfortunately occur, the limb is in a much better position for the proper performance of its most ordinary functions than if it were extended. Some have also added to this argument a statement that a fibrous union, under any circumstances, is inevitable, and that it is a matter of little consequence whether the ligament thus formed is long or short, since in either condition it will be equally serviceable.

In reply to these statements, it may be said briefly that they are nearly all based upon false premises, or that they have been proved in themselves to be essentially erroneous. Ankylosis is always a serious event, which by all possible means the surgeon will seek to prevent, but position has nothing to do with determining this result; when it does occur, it may usually be ascribed either to the severity and complications of the original injury, to the violence of the consequent inflammation, or to having neglected, at a proper period and with sufficient perseverance, to move the joint. That a fibrous union is inevitable under any circumstances, has been proved to be an error; and while a short ligamentous union, such as is usually obtained when the arm is kept straight, may serve its purposes quite as well as a bony union, yet a long fibrous union, such as must very often be obtained when the arm is kept at a right angle, would seriously impair the usefulness of the limb.

The only argument which remains, and which really possesses any weight, is, that, if permanent ankylosis does not actually occur, the arm, when semi-flexed, is in a better position for the performance of its ordinary functions; and this, considered as an argument in favor of the universal or even general adoption of the flexed position, is successfully met by a statement of the infrequency of permanent ankylosis after a simple fracture, when the case has been properly treated, whether by the flexed or straight position; while, if the limb is flexed, a maiming, as a result of the great length of the intermediate ligament, is quite as likely to occur. Yet if, in any case, from the great severity and complications of the injury, especially in certain examples of compound and comminuted fracture, it were to be reasonably anticipated that permanent bony ankylosis must result, or even where the probabilities were strongly that way, the surgeon might be justified in selecting for the limb, at once, the position of semiflexion; or he might leave the arm without a splint, and at liberty to draw up spontaneously and gradually to this position, as it is always very prone to do.

In favor of moderate, but not complete extension, it is claimed that it is less fatiguing than the latter position, while it accomplishes a more exact apposition of the fragments, if they happen to be brought actually into contact. I am unable, however, to understand how the apposition can be rendered less exact by complete extension, unless by this is meant a degree of extension beyond that which is natural, and which, I am well aware, is permitted to the elbow-joint when this posterior brace is broken off. It would certainly derange the fragments to place the arm in this extreme condition of extension—that is, in a condition of extension approaching dorsal flexion, which is beyond what is natural. Indeed, perhaps, we may admit that, in order to perfect apposition, the

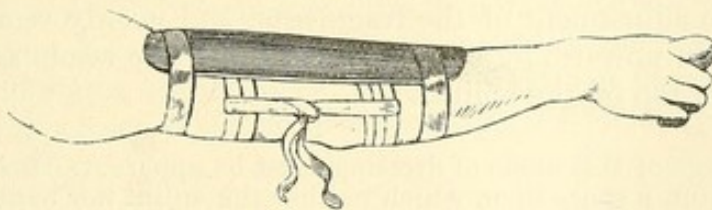
extension ought to be less by one or two degrees than what is natural, sufficient to compensate for the trifling amount of effusion which may be presumed to have occurred in the olecranon fossa, and which would prevent the process from sinking again fairly into its fossa. As to its being less fatiguing, it is well known to those accustomed to treat fractures of the thigh by permanent extension that the muscles rapidly acquire a tolerance, which soon dissipates all feeling of fatigue, and that, after a few hours, or days at most, the patients express themselves as being more comfortable in this position than in the flexed.

Finally, the advocates of complete, natural extension claim that in this position alone is the triceps most perfectly relaxed, and consequently the most important indication, namely, the descent of the olecranon, most fully accomplished. In this opinion we also concur; and regarding all other considerations, in the early days of the treatment, as secondary to this one, we unhesitatingly declare our preference for what has been called the "position of complete extension," as opposed to flexion, semi-flexion, or extreme extension.

It only remains for us to determine by what means the limb can be best maintained in the extended position, and the olecranon process most easily and effectually secured in place.

For this purpose a variety of ingenious plans have been devised, such as the compress and "figure-of-8" bandage of Duverney, without splints; or a similar bandage employed by Desault, with the addition of a long splint in front; the circular and transverse bandages of Sir Astley Cooper, with lateral tapes to draw them together, to which also a splint was added; and many other modes not varying essentially from those already described, but nearly all of which are liable to one serious objection, namely, that if they are applied with sufficient firmness to hold upon the fragment, and Boyer says they "ought to be drawn very tight," they ligate the limb so completely as to interrupt its circulation, and expose the limb greatly to the hazards of swelling, ulceration, and even gangrene. How else is it possible to make the bandage effective upon a small fragment of bone, scarcely larger than the tendon which envelops its upper end,

FIG. 171.



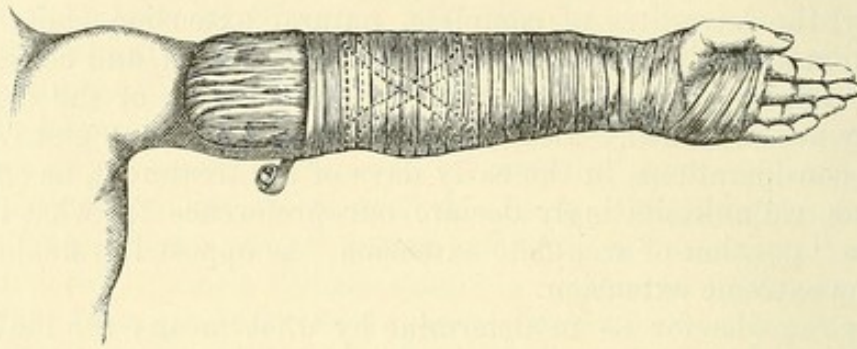
Sir Astley Cooper's method.

and with no salient points against which the compress or the roller can make advantageous pressure? If, then, these accidents—swelling, ulceration, and gangrene—are not of frequent occurrence, it is only because the bandage has not been generally applied "very tight," and while it has done no harm, it has as plainly done no good.

The dangers may be easily avoided, without relaxing the security afforded by the compress and bandage, by a method which is very simple, and the value of which I have already sufficiently determined by my own practice. The surgeon will prepare, extemporaneously always, for no single pattern will fit two arms, a splint, from a piece of thin, light

board. This must be long enough to reach from near the wrist-joint to within three or four inches of the shoulder, and of a width nearly or quite equal to the widest part of the limb. Its width must be uniform throughout, except that, at a point corresponding to a point three inches, or thereabout, below the top of the olecranon process, there shall be a notch on each side, or a slight narrowing of the splint. One surface of

FIG. 172.



The author's method when the fragments are widely separated.

the splint is now to be thickly padded with hair or cotton-batting, so as to fit all of the inequalities of the arm, forearm, and elbow, and the whole covered neatly with a piece of cotton-cloth, stitched together upon the back of the splint. Thus prepared, it is to be laid upon the palmar surface of the limb, and a roller is to be applied, commencing at the hand and covering the splint, by successive circular turns, until the notch is reached, from which point the roller is to pass upward and backward behind the olecranon process and down again to the same point on the opposite side of the splint; after making a second oblique turn above the olecranon, to render it more secure, the roller may begin gradually to descend, each turn being less oblique, and passing through the same notch, until the whole of the back of the elbow-joint is covered. This completes the adjustment of the fragments, and it only remains to carry the roller again upward, by circular turns, until the whole arm is covered as high as the top of the splint.

The advantage of this mode of dressing must be apparent. It leaves, on each side of the splint, a space upon which neither the splint nor bandage can make pressure, and the circulation of the limb is, therefore, unembarrassed, while it is equally effective in retaining the olecranon in place, and much less liable to become disarranged.

Before the bandage is applied about the elbow-joint, the olecranon must be drawn down, as well as it can be, by pressure with the fingers, and a compress of folded linen, wetted to prevent its sliding, must be placed partly above and partly upon the process; at the same time, also, care must be taken that the skin is not folded in between the fragments.

When the fragments are not much, or at all separated, and consequently no such force is required to draw down the upper fragment, and when, from the nature of the injury, there is little cause to anticipate

much swelling, a splint may be employed, constructed like that recommended by Sir Astley Cooper, made of light wood, curved to fit the limb, or of gutta-percha, gum-shellac cloth, or sole-leather. This should be covered with a flannel or cotton sack, and then secured in place by a roller. The sack will enable the surgeon to stitch the roller to the splint, and he can thus employ effectively the oblique and figure-of-8 turns about the elbow-joint. Indeed, the latter method will prove adequate in most cases, while it is less cumbrous than that which I have first described as being required when the separation is very great, and the injuries unusually severe.

The dressing ought, no doubt, to be applied immediately, since, if we wait until the swelling has subsided, it will be found much more difficult to straighten the arm completely than it would have been at first, and the olecranon process will be more drawn up and fixed in its abnormal position. Something will be gained by these means, adopted early, even if the bandage cannot be applied tightly; and moderate bandaging will not in any way interfere with the proper and successful treatment of the inflammation. We must always keep in mind, however, the fact that the fracture being usually the result of a direct blow, considerable inflammation and swelling around the joint are about to follow rapidly; and on each successive day, or oftener if necessary, the bandages must be examined carefully, and promptly loosened whenever it seems to be necessary. For this purpose it is better not to unroll the bandages, but to cut them with a pair of scissors, along the face of the splint, cutting only a small portion at a time, and as they draw back, stitch them together again lightly; and thus proceed until the whole has been rendered sufficiently loose.

As soon as the inflammation has subsided, and as early sometimes as the fifth or seventh day, the dressing ought to be removed completely; and while the fingers of the surgeon sustain the process, the elbow ought to be gently and slightly flexed and extended two or three times. From this time forward, until the union is consummated, this practice should be continued daily, only increasing the flexion each time, as the inflammation and pain may permit. If it is thought best, at length, to change the angle of the arm, and to flex it more and more, it may be done easily by substituting a very thick sheet of gutta-percha for either of the other forms of dressing.

Dieffenbach has several times, in old fractures of both the olecranon and patella, where the fragments were dragged far apart, divided the tendons, so as to be able to bring the two portions together, and, by friction of them one upon the other, has endeavored to excite such action as might end in the formation of a shorter and firmer bond of union. In some instances, it is said, considerable benefit was obtained, after all other means had failed; in others, the result was negative. One example of an old ununited fracture of the olecranon is mentioned, in which he divided the tendon of the triceps, secured the upper fragment in place, and every fourteen days rubbed it well against the lower one; in three months "the union was firm."¹

Mr. Lister, in the case of a patient whose olecranon had been broken many months before, and not satisfactorily united, exposed, with antiseptic precau-

¹ Dieffenbach, *American Journal of the Medical Sciences*, vol. xxix. p. 478; from Casper's *Wochenschrift*, Oct. 2, 1841.

tions, the fragments and brought them together with strong silver wire, thus securing a bony union without any accident. He has repeated this operation in an analogous case, with like success.¹ Rose,² MacCormac,³ and Lesser⁴ have each reported one example of success in the same class of cases. Neither the method of Dieffenbach nor that of Lister is without its hazards, and no doubt ought to be reserved for extreme cases.

[The wiring of the fragments antiseptically is a very simple and safe operation, and secures firm bony union. I have operated in several instances without an unfavorable symptom.]

Plaster-of-Paris, or any other form of immovable dressing which excludes the surface of the limb from observation, and which is made sufficiently tight to hold permanently upon the upper fragment, exposes the patients to the dangers of swelling and gangrene. If not sufficiently tight to expose to these dangers, they serve no other purpose than to keep the limb straight.

In 1850, Rigaud,⁵ of Strasbourg, introduced two screws into the upper and lower fragments, respectively, and drew them together with a string. The screws remained in position two months, and the result was a "perfect cure." One might wish to know more precisely in what sense it was "perfect."

In 1864, Busch applied a plaster-of-Paris splint, furnished with a fenestra at the posterior part of the elbow; after which he made fast a metallic clamp, one point of which penetrated the upper fragment, and the two lower points were made to penetrate the plaster-of-Paris; by means of a screw the fragments were approximated.⁶ Madelung has three times adopted the same method; in one of which the method had to be abandoned on account of the "indocility" of the patient. Pingaud⁷ reports, also, an example of success by this method.

Lauenstein proposes to aspirate the joint where there is much interarticular effusion, in order to secure better apposition of the fragments. The fact that he has seen no serious results from this practice, will hardly justify the prudent surgeon in performing an operation of so much hazard and of so little probable utility.

Separation of the Olecranon while in its Epiphyseal State.—Recently a gentleman called upon me with his son, aged seven years, who had an unreduced dislocation of the radius and ulna backward of nine weeks' standing. While reducing this dislocation, it being necessary to flex the arm forcibly, the epiphysis constituting the olecranon process gave way, and became separated from one-half to three-quarters of an inch. This is the only example of separation of this epiphysis which has come to my knowledge. I have, however, twice since broken the olecranon in attempts to reduce old dislocations of the radius and ulna backward, and I have not regretted the occurrence, since it enabled me to reduce the dislocations without cutting the triceps.

[Eames reports a case of fracture of the olecranon in a child four years of age, which was doubtless an epiphyseal separation.⁸]

§ 2. Coronoid Process of the Ulna.

Dissections have established the existence of this fracture in the living subject. The fact, however, that the number of authentic observations

¹ Lister, *The Lancet*, June 4, 1881, p. 914.

² Rose, *The Lancet*, 1880, vol. 1. p. 835.

³ MacCormac, *The Lancet*, June 4, 1881, p. 913.

⁴ Lesser, *Quentin, Bruch. des Olek., Inaug. Diss., Bonn*, 1881.

⁵ Rigaud, *Rev. Méd. Chir.*, 1850.

⁶ Busch, *Poiusot, op. cit.* p. 397.

⁷ Pingaud, *Dict. Encyc., Art. Coude*, p. 639 (1878).

⁸ *Brit. Med. Journ.*, July, 1887.

is very small, seems to imply that the accident is infrequent, and especially as a simple fracture, unassociated with other fractures.

Malgaigne thought that it was more frequent than the small number of reported examples would lead us to suppose; and especially because he had noticed how often the summit of the process is broken off when dislocation of the radius and ulna backward is produced on the cadaver. In three or four cases also of dislocations of these bones backward and inward which had come under his notice, he was unable to feel this process, and he, therefore, thought it probable that it was broken off. Other surgeons have thought also that it was not an infrequent accident in connection with a dislocation. Fergusson has, indeed, made the extraordinary statement that in dislocations of the radius and ulna backward "the coronoid process will probably be broken."

In the two following cases, the existence of a fracture of the coronoid process was at first suspected by me, but I have now very little doubt that my diagnosis was incorrect. I shall relate them, however, as examples of those accidents which are likely to be mistaken for fracture of this process.

A laboring man, aged about twenty-five years, had been seen and treated by another surgeon, for what was supposed to be a simple dislocation of the radius and ulna backward. The surgeon thought he had reduced the dislocation very soon after the accident. On the following day he found the dislocation reproduced, and he requested me to see the patient with him. The arm was then much swollen, but the character of the dislocation was apparent. By moderate extension, applied while the arm was slightly flexed, and continued for a few seconds, reduction was again effected, the bones returning to their places with a distinct sensation; but on releasing the arm the dislocation was immediately reproduced. These attempts to reduce and retain in place the dislocated bones were repeated several times during this day and on subsequent days, but to no purpose, and the patient was dismissed after about two weeks with the bones unreduced. The possibility of retaining the bones in place, and the existence of an occasional crepitus during the manipulation, inclined me to believe at the time that the dislocation was accompanied with a fracture of the coronoid process.

Another similar case has since presented itself in a child nine years old, and in which the subsequent examinations not only demonstrated the non-existence of a fracture, but also rendered doubtful the justness of the conclusions which I had drawn in the case just related. This lad fell, November 4, 1855, and his parents immediately brought him to me; but as he lived many miles from town, I did not see him until eighteen hours after the injury was received. I found the arm much swollen, slightly flexed, and pronated. Flexion and extension of the arm were very painful, the pain being referred chiefly to the front of the joint, near the situation of the coronoid process; and at this point also there was a discoloration of the size of a twenty-five cent piece. Flexing the forearm moderately upon the arm and making extension, the bones came readily into

FIG. 173.



Fracture of the coronoid process.

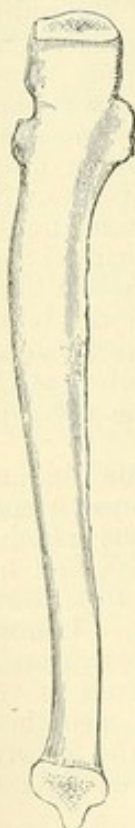place, but without sensation of any kind, either a snap or a crepitus. That the bones had now resumed their position, however, I made certain by a very careful examination with the hand and by measurement, yet they would not remain in place one moment when the extension was discontinued. The reduction was made several times, and constantly with the same result. We then applied a

right-angled splint to the arm, having first reduced the bones, and thus were able to retain them in position. I believe that the coronoid process was broken, and so informed the surgeon, to whose care the boy returned. Five months after, he was brought again to me, and I then found that the radius and ulna had been kept in place; the motions of the joint were perfect, and if the coronoid process had ever been broken it was now again in its natural position, and with every structure about it in a condition as complete as it was before the accident.

Malgaigne mentions three reported examples, namely, one published by Combes Brassard, an Italian surgeon, in 1811, which Brassard saw only after a lapse of three months; one seen by Pennock, and published in the *Lancet* in 1828, the patient then being sixty years old, and the accident having occurred when he was a young man; the third was seen by Sir Astley Cooper, several months after the accident.

Dr. Physick once saw a fracture of the coronoid process. The symptoms resembled a luxation of the forearm backward, "except that when the reduction was effected, the dislocation was repeated, and by careful examination crepitation was discovered. The forearm was kept flexed at a right angle with the humerus. The tendency of a brachialis internus to draw up the superior fragment was counteracted in some measure by the pressure of the roller above the elbow. A perfect cure was readily obtained."¹ In 1830, Dr. William M. Fahnestock reported a case occurring in a boy, who, having fallen from a hay-

FIG. 174.



Ulna, with epiphysis. (From Gray.)

mow, received the whole weight of his body "on the back part of the palm of the left hand," while the arm was extended forward. It seemed to be a dislocation of the forearm backward, but when reduced it was again immediately displaced, with an evident crepitus. The arm was secured in the angular splint of Dr. Physick, and "recovered very speedily."²

Dr. Duer,³ of Philadelphia, has reported a case which occurred in a boy six years old, and in which he felt and moved the fragment with his fingers. It was complicated with a dislocation, which remained unreduced.

Mr. Liston saw a case in which the injury arose in consequence of the patient, a boy of eight years, having hung for a long time from the top of a wall by one hand, afraid to drop down."⁴ The explanation of the accident in the case of the boy, given by Liston, implies two anatomical errors: first, that the coronoid process is an epiphysis during childhood; and second, that the brachialis anticus is inserted upon its summit. The coronoid process is never an epiphysis, but is formed from a common point of ossification with the shaft; the olecranon process and the lower extremity of the ulna having also separate points of ossification; the olecranon becoming united to the shaft at the sixteenth year, and the lower epiphysis at the twentieth. Moreover, the brachialis anticus has its insertion at the base of the process and partly upon the body of the ulna, but in no part upon its summit; indeed, the process seems rather to be intended as a pulley over which the brachialis anticus may play; resembling also somewhat, in its function, the patella; serving to protect the joint and perhaps the muscle itself from becoming compressed in the motions of the joint. Certainly it could never have been broken by the action of this muscle, and the case mentioned by Mr. Liston must find some other explanation. It may have been a rupture of the brachialis anticus itself, or of the biceps, or possibly a forward luxation of the head of the radius. Either of these suppositions is more rational than the statement made by Mr. Liston, because either one of them is possible, while his supposition is impossible.

The first two of the above enumerated (Brassard's and Pennock's) were not

¹ Dorsey, *Elements of Surgery*, vol. i. p. 152. Philadelphia, 1813.

² Fahnestock, *Amer. Journ. Med. Sci.*, vol. vi. p. 267.

³ Duer, *Amer. Journ. Med. Sci.*, Oct. 1863, p. 390.

⁴ Liston, *Practical Surgery*, p. 55.

satisfactory to Malgaigne; the third is spoken of cautiously by Sir Astley Cooper, as if it needed, in addition to his own great name, the indorsement of the "London council." Dorsey reports his case upon hearsay, and the result is quite too satisfactory to give it much claim to credibility. Fahnestock's case is, to my mind, far from being fully proven. Liston's case was simply impossible. Duer's case could have been better verified at a later period.

Ulrichs,¹ Battams,² Laugier,³ Lorinzer,⁴ Zeis,⁵ Lotzbeck,⁶ Comoy,⁷ Gripat,⁸ have also reported clinical examples not verified by dissection.⁹

In the case described by Laugier, a boy, *æ*t. 12, had fallen upon the right hand, the forearm being slightly flexed. He was admitted to the hospital with a dislocation of the radius and ulna backward. The dislocation was easily reduced, and the motions of the joint were completely restored. The swelling having subsided after ten or twelve days, a small, very hard, circumscribed and slightly movable tumor was observed a little below the end of the elbow, which interfered with flexion.

Having described the case, of which I have only given a summary, Poincot relates what he regarded as a similar case sent to him by his colleague, M. Gautier. A man, twenty days before, had fallen upon his hand. Gautier found a dislocation, which he reduced easily, and the motions of the joint were completely restored. When seen by Poincot there existed a hard circumscribed tumor, which seemed united to the tendon of the brachialis anticus. The limb could not be flexed well. Upon careful examination, Poincot, who at first thought it might be a fracture of the coronoid process, decided that it was "an induration such as results from certain contusions; and that opinion seems now to be confirmed by the researches of M. Charvot, on the transformation of sanguinolent deposits at the bend of the elbow. I believe that Laugier's case should receive the same explanation."

Poincot refers also to the two supposed cases reported by Lorinzer and Comoy, respectively, both accompanied with a dislocation backward. In the first case there was marked bony crepitus in the region of the coronoid process, but Lorinzer was compelled to recognize the fact that no swelling existed in the supposed seat of fracture. In the second case, a fine and dry crepitus could be felt at the bend of the arm. Professor Richet, in whose wards the patient was, recognized a fracture, but could not fix its exact location.

The three cases met with by Lotzbeck presented, says Poincot, "a most complete similarity with each other. In the three instances, there was felt at the bend of the elbow a small tumor, hard and circumscribed, movable laterally, and giving rise to crepitation when moved. The displacement (twice both bones, and once the ulna only were dislocated) was easily reduced, but would be reproduced immediately. In the three cases the cure was accomplished and the movements of flexion were regained pretty promptly and with almost their normal freedom."

Of the clinical case reported by Ulrichs, the same writer remarks: "A young boy fell upon his left side while helping to carry a beam whose weight was resting on his left forearm, which was bent at a right angle. He experienced a violent pain and could neither flex nor extend the forearm. The surgeon who was called felt a pretty obscure crepitus in the region of the bend of the elbow; but there being no displacement of the bony prominences, the diagnosis of fracture of the coronoid process was made by exclusion."

"M. J. Scott Battams, of Royal Free Hospital," says Poincot, "thought he had to deal with a fracture of the coronoid process in the case of a man who,

¹ Ulrichs, *Deuts. Zeits. für Chir.*, t. 10, Nov. 1878.

² Battams, *The Lancet*, 1878, vol. ii. p. 607.

³ Laugier, *Bullet. Chir.*, 1840.

⁴ Lorinzer, *Zeits. der K. K. Ges. der Ac. für Wein*, vii. Jahr., Heft 7.

⁵ Zeis, *Schmidt's Jahr. für* 1866, p. 134.

⁶ Lotzbeck, *Die Frak. Pr. Cor.*, München, 1865.

⁷ Comoy, *Frac. de l'Apoph. Cor.*, etc., Thèse Paris, 1881.

⁸ Gripat, *Bull. Soc. Anat.*, 1872.

⁹ When speaking of fractures of the head of the radius I have said that Dr. Hodges had three times found the coronoid process broken in that connection. I ought to have said he had found in the reported dissections. To these I shall hereafter refer.

slipping on a sidewalk, had his elbow caught between his hip and the pavement. At first it was difficult to determine the nature of the lesion; the patient could, with pain it is true, extend and flex the forearm a little beyond a right angle. Supination and pronation were performed slowly, but well; the bony prominences of the elbow had kept their normal relations, and the head of the radius was in its ordinary position. Up to that time the patient had supported the wounded arm with the other hand; suddenly he allowed it to drop, and at once the ulna was dislocated backward, the radius remaining in place. This dislocation was reduced easily, but to be reproduced with the same facility. The limb was placed on an elbow-splint, which was allowed to remain for three weeks. At that time, there existed a small indurated growth on a level with the coronoid process, *at the point where in the beginning there was a bloody effusion.* The movements, at first impeded, were soon completely regained."

The fact, therefore, that so few cases have ever been reported, and that most of these are far from having been clearly made out, remains presumptive evidence that the actual cases are exceedingly rare; but if to this we add such evidence as is furnished by actual dissections, and by examinations of the pathological cabinets of the world, we think the testimony is almost conclusive.

In 1834, M. Bérard¹ examined the arm of a man who had been killed by a fall from a second story. The forearm was dislocated backward. In attempts at reduction and redislocation, there was observed, under moderate pressure, a slight crepitation. There was found a fracture of the coronoid process, of the anterior third of the head, including a portion of the neck. Sir Astley Cooper² says that a person was brought to the dissecting-room at St. Thomas's Hospital, who had been the subject of this accident. "The coronoid process, which had been broken off within the joint, had united by a ligament only, so as to move readily upon the ulna, and thus alter the sigmoid cavity of the ulna so much as to allow in extension that bone to glide backward upon the condyles of the humerus." Mr. Bransby Cooper adds, in a note, that the external condyle of the humerus was also broken and united by a ligament. Samuel Cooper describes, rather obscurely, a specimen contained in University College Museum, "in which the ulna is broken at the elbow, the posterior fragment being displaced backward by the action of the triceps; the coronoid process is broken off; the upper head of the radius is also dislocated from the lesser sigmoid cavity of the ulna, and drawn upward by the action of the biceps. In this complicated accident the ulna is broken in two places." Velpeau has also established by two autopsies the existence of a fracture of the coronoid apophysis.

Lotzbeck³ has seen, as he thinks, an ancient fracture of this process in the cadaver, the line of fracture passing beneath the lesser sigmoid cavity and into the greater sigmoid cavity. The condyle was broken also, and was reunited by fibrous tissue and cartilage. The coronoid was united by bone, and loaded with osteophytes.

Ulrichs⁴ found, in a cadaver, a fissure of the summit of the coronoid process, caused by torsion or twisting of the forearm, without any other lesion of the bone. In a cadaver seen by Gripat, the coronoid process was fractured at its base, and the radius and ulna were dislocated backward and upward.

Allandale⁵ also, having performed resection for an ancient dislocation, found this process fractured, and a bony callus had united the ulna to the humerus.

Gurlt⁶ has described a specimen, contained in the museum at Braunschweig, illustrating a fracture of the extremity of the coronoid process. A small fragment was also broken from the ulnar side of the olecranon. Both fragments have united by bone.

¹ Bérard, Dic. de Méd., Art. Coude.

² Sir A. Cooper, Dislocations and Fractures, p. 411.

³ Lotzbeck, loc. cit.

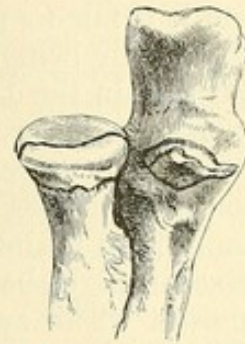
⁴ Ulrichs, loc. cit.

⁵ Allandale, Med. Times and Gaz., May 25, 1875.

⁶ Gurlt, Von den Knochen., 1862, vol. i. p. 41.

Says Mr. Flower, Conservator of the Museum of the Royal College of Surgeons, "The cases that have been reported in which it has been observed in the living subject are exceedingly unsatisfactory." . . . "I have been able to meet with but three or four specimens, and recorded post-mortem examinations of this injury" (alluding, I presume, to clinical cases). "One of the former is in the museum of Guy's Hospital. Another case is that of a man killed by a fall from the roof of St. George's Hospital; in whom the coronoid processes were found to be fractured, and the two bones of the forearm dislocated backward on both sides."¹ The first of the specimens (Guy's Hospital) has been described by Mr. Bryant,² as having occurred in a woman seventy years old, and as having been caused by a fall upon the elbow. In addition to a fracture of the coronoid near its extremity, there was a comminuted fracture of the anterior third of the head of the radius. (Fig. 175.) It will be observed that in several of the cases verified by dissection, the fracture of the coronoid process was accompanied with other fractures in the vicinity of the joint; a circumstance which would not usually permit them to be studied or classified as simple fractures. Perhaps, however, we ought to consider, from the frequency of its concurrence, a longitudinal fracture of the head of the radius as a natural complication of the fracture now under consideration, when it is caused by a dislocation of the radius and ulna backward.

FIG. 175.



Bryant's case of fracture of the coronoid process and head of the radius.

Causes.—Judging from the clinical cases alone, it would seem that the most frequent cause of this accident is a fall upon the outstretched hand, and generally upon the palm of the hand; the force of the blow being received upon the lower end of the radius, and, through its numerous muscles and ligamentous attachments, being indirectly conveyed to the ulna, producing a violent concussion of the coronoid process against the trochlea of the humerus, and resulting finally in a fracture of this process and a dislocation of both bones of the forearm backward. The examples verified by dissection, however, seem to have been produced by a variety of causes.

The gentleman seen by Sir Astley had fallen upon his extended hand while in the act of running. Brassard's patient had fallen also upon his hand with his arm extended in front. The same was the fact in the cases seen by Lorinzer, Richet, and Lotzbeck; the latter of whom has recorded two cases due to this cause. Pennock's patient, a man of sixty years, had fallen upon the palm of his hand, and Fahnestock's fell upon the "back of the palm." In one of Lotzbeck's cases the fracture was supposed to be caused by extreme flexion of the forearm; and in another case of supposed fracture, seen by Lotzbeck, it seemed to be the result of direct violence. While in a case seen by Ulrichs, a longitudinal fissure was caused by violent torsion or twisting of the forearm. In the case mentioned by Bryant, the patient fell upon her elbow. The fracture was compound and amputation was required. He remarks that in aged subjects this step may be demanded.

Symptoms.—Partial or complete displacement of the ulna, or of the radius and ulna, backward, is accompanied with the usual signs of these luxations. In two of the examples mentioned by Malgaigne there was a luxation of the forearm backward; such was also the fact in the case seen by Fahnestock; in Couper's case it was dislocated backward and outward, and in Sir Astley's case I infer that there was only a sub-

¹ Flower, *Holmes's Surgery*, 2d New York ed., vol. ii. p. 790.

² Bryant, *System of Surgery*, 1st London ed., pp. 939, 941.

luxation of the ulna backward. In a case seen by Gripat, verified by an autopsy, there was a dislocation of the ulna. In the cases of Lorinzer and Richet, both bones were dislocated backward, and in two of those seen by Lotzbeck. A feeble crepitus has sometimes been recognized; and it is fair to presume that in some examples the fragment, carried forward by being driven against the trochlea, may be felt displaced and movable in the bend of the elbow. We must be careful, however, not to mistake a hard nodule following traumatism in this region, and the frequent occurrence of which has been signalized by Charvot, for the coronoid process. If only the summit is broken off, the brachialis anticus could have no influence upon it; but if it were broken fairly through the base, it might be displaced slightly in the direction of the action of this muscle. The symptoms, however, which have been regarded as most diagnostic, are the disposition to relaxation manifested in most of these examples when the extension has been discontinued. But it must not be forgotten that other conditions than a fracture of the coronoid process may cause a relaxation, such as a fracture of the internal condyle, of the trochlea, or a splitting of the condyles, or some other derangement of the articular surfaces, or of the ligaments or muscles concerned in the articulation. Possibly, where the force applied has been great, as in falls from a great height, the brachialis anticus may have been detached.

Prognosis.—In the absence of other testimony, we may be allowed to express an opinion that when the fracture has taken place across the summit or above the insertion of the brachialis anticus, nothing but a ligamentous union can be regarded as possible, since the fragment can only derive nourishment from a few untorn fibres of the capsule and perhaps of the internal lateral ligaments; and although it may not be displaced, it cannot have the advantage of impaction, upon which alone, I suspect, a fracture of the neck of the femur within the capsule must rely for a bony union, if it ever does so unite. If, however, the fracture has taken place at the base, and fortunately it has not become much displaced by the force of the concussion against the humerus, it does not seem to me improbable that under favorable circumstances a bony union might occur. It will be remembered that a good portion of the attachment of the brachialis anticus is still below the fracture, and the remaining fibres are not therefore very likely to displace the fragment, especially when the arm is sufficiently flexed, so as properly to relax this muscle. It will be of small importance, however, whether the union is bony or ligamentous, provided only there is not great displacement.

In the case of Couper's patient, seen several months after the accident, the ulna projected backward while the arm was extended, but it was without much difficulty drawn forward and bent, and then the deformity disappeared. He thought that during extension the ulna slipped back behind the inner condyle of the humerus. Brassard's patient, seen after three months, retained the power of pronation and supination, with also extension, but flexion was impossible, the forearm being arrested in this direction by the small, slightly movable fragment of bone in front of the elbow-joint, and which was supposed to be the process itself. Pennock's old man, who had met with the accident in boyhood, had still the radius luxated forward and outward, and the olecranon more salient backward than in the sound arm. Extension and flexion were nearly but not quite complete. Fahnestock informs us that his patient "recovered completely," but whether without deformity or maiming we are not told. Couper says the bone

was united in four weeks, and that only a slight deformity and a little stiffness remained. Physick's patient made a perfect recovery. "The same result," says Poinso, "followed in Dr. Scott Battams's patient, in whom the difficulty in flexion and extension which existed at first, disappeared in a few weeks. In the case of Allandale, the dislocation had remained unreduced, but no mention is made of the kind of dressing employed at the beginning. In Lorinzer's case, the movements of the elbow remained limited, the patient could only flex the forearm to a right angle. On the contrary, Richet's patient showed no remaining trace of the accident when she left Hôtel-Dieu at the end of fifty-two days. It has already been seen that in Lotzbeck's cases the result was no less favorable."

Let us return to the examples verified by dissection and to the cabinet specimens. Rejecting the doubtful specimens belonging to Dr. Gibson, and that of Lotzbeck, also those of "Hodges,"¹ of Gripat, and of Ulrichs, where there was no opportunity to get a history of the fracture, as well as that of Allandale, where it is difficult to determine what part of the tumor surrounding the humerus and ulna is due to the consolidation of the fracture." (Poinso.) In the specimen described by Gurlt, without a history, the fragment is united, in position, with exuberant callus on the anterior surface. And in one specimen referred to by Bryant, the coronoid process and a portion of the head of the radius having been broken, bony union has taken place without displacement of either.

Samuel Cooper says that in the case of the University College specimen the radius remains dislocated forward and upward, and the olecranon is displaced backward, but he does not say whether the coronoid process has united, nor describe its position; but Sir Astley informs us that in the example seen and dissected by him the process was united by ligament, which was sufficiently long and flexible to allow the fragment to move upward and downward in the motions of flexion and extension.

Treatment.—Whatever view we take of the mechanism or pathology of this accident, the rational mode of treatment would seem to be to flex the arm at a right angle, and retain it a sufficient length of time in that position; not forgetting, however, the danger of ankylosis from long-continued confinement in one position. An angular splint may be useful in preventing motion at first, but I think it ought not to be continued beyond seven or ten days at the most. After this, a simple sling is all that is necessary, since from this period some motion must be given to the joint if we would take the proper precautions to prevent stiffness.

Sir Astley Cooper thought the limb ought to be kept immovable three weeks, and Velpeau preferred four; but I cannot agree with them, believing that the question of the future mobility of the elbow-joint is vastly more important than the question of a bony or ligamentous union between the fragments. Couper says that he adopted in the treatment of the case reported by him, extreme flexion; but both Physick and Fahnestock placed the arm at right angles, and Sir Astley Cooper has recommended the same position. The latter position has always the advantage in case permanent ankylosis occurs, and the former cannot add much to the chance of complete replacement of the fragment. Bandages are only serviceable to retain the splint in place, and they may be thrown aside as soon as the splint is removed.

§ 3. Shaft of the Ulna.

Causes.—The shaft of the ulna, when it alone is the seat of fracture, is generally broken by a direct blow.

¹ The case of Hodges probably here referred to, and reported first in 1866, vol. 75, p. 383, of the Boston Medical and Surgical Journal, and subsequently in vol. 96, p. 65, of the same journal, was not, properly speaking, a fracture of the coronoid process, but a longitudinal fracture of the upper end of the ulna.

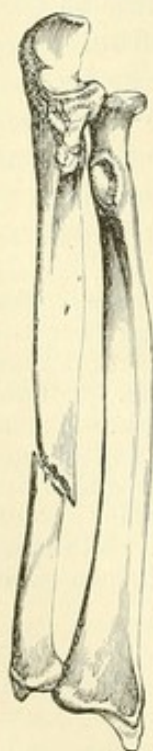I have never seen an exception to this rule; but Voison related a single exception, in which it was said to have been broken by a fall upon the palm of the hand. Malgaigne thinks it most often broken when one seeks to ward off a blow with the arm; but it has happened most often to me to see it broken by a fall upon the side of the arm.

Point of Fracture, Direction of Displacement, etc.—In an analysis of thirty-six cases, I find the shaft has been broken eleven times in its upper third, fourteen times in its middle third, and ten times in its lower third. All portions seem, therefore, to be about equally liable to fracture. I think, also, the fractures have generally been oblique.

Contrary to what has been observed by other writers, I have noticed that no law prevailed as to the direction in which the fragments have become displaced; the broken ends being found directed forward, backward, inward, or outward, according to the direction of the blow which has occasioned the fracture; and this is in accordance with the general rule in other fractures occasioned by direct blows. No doubt, however, other things being equal, the tendency of the lower fragment would be toward the interosseous space, in consequence of the action of the pronator quadratus in this direction; while the upper fragment, owing to its broad and firm articulation at the elbow-joint, can only be displaced forward or backward, at least to any great extent.

Complications.—In no case of the shaft of a long bone have I found serious complications more frequent than in fractures of the shaft of the ulna. Four have been compound; twelve complicated with a forward, or forward and outward dislocation of the head of the radius; one with a partial dislocation of the lower end of the radius backward; and one with a dislocation of both radius and ulna backward at the elbow-joint. It will be seen, therefore, that eighteen, or nearly one-half of the whole number, have been seriously complicated.

FIG. 176.



Fracture of
the shaft of the
ulna.

Symptoms.—Occasionally this fracture is found to exist without sensible displacement. In such cases the diagnosis is sometimes difficult, and can only be determined by the crepitus and mobility. If, however, the ulna is firmly seized above and below the point which has suffered contusion, and pressed in opposite directions, these signs will generally be sufficiently manifest, and will render the diagnosis certain. But in cases where there is considerable displacement, the inner margin of the bone is so superficial as to enable us to detect its deviations with the eye alone, or, when swelling has already occurred, by the fingers carried firmly and slowly along this margin. If the head of the radius is dislocated also, the displacement of the broken ends of the ulna must always be considerable, and the consequent deformity palpable.

Prognosis.—In simple fractures the prognosis is generally favorable, since no overlapping can occur, and the lateral displacements are not usually sufficient to produce a marked deformity, or to interfere materially with the functions of the arm; yet it is not unfrequent to find the fragments inclining slightly forward or backward, inward or outward. If the frag-

ments fall toward the radius, I have noticed in three or four instances a slight projection of the lower end or styloid process of the ulna to the ulnar side; but not interfering in any degree with the motions of the wrist-joint.

I have seen a dislocation of the head of the radius left unreduced nine times after a fracture of the ulna, and in each example the forearm was shortened. A boy, *æt.* seventeen years, was struck by a locomotive and severely injured in various parts of his body. I saw him, with two very intelligent country practitioners, a few hours after the accident. The whole left arm was then greatly swollen. Crepitus was distinct, and we easily recognized the fracture of the ulna about three inches below its upper end, with which an open wound was in direct communication. We suspected, also, a dislocation of the head of the radius forward, but as we could not make ourselves certain, and finding that the arm was in such a condition as to preclude any further manipulation without greatly diminishing the chance of saving the limb, we made no attempt at reduction, but laid the arm upon a pillow and directed cool water lotions. At no subsequent period, in the opinion of the medical gentleman who was left in charge, did a favorable opportunity occur to reduce the radius; and at the end of two months I found the ulna united, with the fragments bent forward and outward toward the radius, while the head of the radius lay in front of the humerus. The forearm was shortened three-quarters of an inch. He could flex his arm freely to a right angle and a little beyond; and he could straighten it perfectly. Hand slightly pronated, with partial loss of supination. Whole arm nearly as strong and as useful as before the accident.

Three times I have noticed after the lapse of several years that the forearm could not be perfectly supinated; but pronation was never permanently impaired. I think, also, that the motions of flexion and extension have always, except where the radius has remained dislocated, been completely restored soon after the splints were removed; and even in these latter cases it is only extreme flexion which has been hindered. I have occasionally met with examples in which this bone has failed to unite, and Muhlenberg, in his tables, records sixteen cases.

Treatment.—In simple fracture we must look carefully to the lateral deviation of the fragments; and if they are found to be salient forward or backward, pressure made directly upon or near their extremities restores them to place; but it often requires considerable force to accomplish this.

A gentleman fell and broke the right ulna near its middle. He came immediately to me, and I found the fragments displaced backward. Pressing strongly with my fingers they sprung forward with a distinct crepitus, and I thought they were now in exact line. A broad and well-padded splint was applied to the forearm, and I took especial pains with compresses nicely adjusted from day to day, to keep everything in place. The arm was placed in a sling. Eight months after the accident this gentleman died of cholera, and I was permitted to dissect the arm. I found the fragments well united, but with a very palpable projection of the fragments backward, in the direction in which they were at first.

If the displacement is in the direction of the radius, it is more difficult to overcome, but its necessity is much more urgent, since, if the fragments fall completely against the radius, a bony union may take place, occasioning a complete loss of the power of pronation and of supination. While moderate extension is being made, and the hand is well supinated, the fingers of the surgeon should be pressed firmly, and in spite some-

times of the complaints of the patient, between the radius and ulna, and the fragments of the broken ulna fairly pushed out from the radius. The forearm may now be laid in the usual position against the front of the chest, midway between supination and pronation, and the same splints applied and in the manner which we shall hereafter describe for fractures of the shaft of both bones.

We ought, however, especially to bear in mind the danger of pushing the fragments toward the radius, by allowing the sling or the bandage to rest against the middle of the ulnar side of the bone. To prevent this the sling ought to support the arm by passing only under the hand and wrist, or the forearm may be laid in a firm gutter, which will touch the forearm only at the elbow and wrist, or it may be laid upon its back, as suggested and practised by Scott, and also by Fleury, the latter of whom, according to Malgaigne, had a case which had been treated in the position of semi-pronation, and which remained not only displaced, but refused to unite; but when the arm was supinated, the fragments came at once into contact, and bony union speedily took place. This position may be adopted whenever it is found to be practicable; but the position of semi-pronation is generally much more comfortable to the patient, at least when the forearm is laid across the chest, and I have found very few patients who would submit to a position of complete supination.

In fractures accompanied with dislocation of the head of the radius forward and backward, nothing should prevent the immediate reduction of the dislocation but a demonstration of its impossibility, or a condition of the limb which would render manipulation hazardous. It can be reduced, generally, by pushing forcibly upon the head of the bone in the direction of the socket, while the arm is moderately flexed so as to relax the biceps, and while extension is being made at the forearm by an assistant. In making the counter-extension, care should be taken to seize the lower end of the humerus by the condyles, rather than by its anterior aspect, by which precaution we shall avoid pressing upon and rendering tense the tendon of the biceps.

A lad, æt. nine years, fell from his bed, breaking the ulna and dislocating the head of the radius. Dr. Austin Flint was called on the following morning, and at his request I was invited to see the patient with him. We found the ulna broken obliquely near its middle, and the head of the radius dislocated forward. While Dr. Flint seized the elbow in front of the condyles, I made extension from the hand, the forearm being slightly flexed upon the arm, and at the same moment I pushed forcibly the head of the radius back to its socket. The reduction was accomplished easily and completely. We then dressed the arm with an angular splint, constructed with a joint opposite the elbow. This was laid upon the palmar surface, and the whole was nicely padded, especially in front of the head of the radius. In two weeks pasteboard was substituted for the angular splint. At the end of six weeks I was permitted to examine the arm, and found the head of the radius perfectly in place, but the points of fracture slightly salient. All of the motions of the arm were fully restored.

C. C., æt. nine years, fell upon his arm, breaking the ulna obliquely near its middle, and dislocating the head of the radius forward. Dr. J. P. White being called, requested me to visit the patient with him. We found one of the broken fragments protruding through the skin on the inside of the arm. With great ease, and by simply pressing with considerable force upon the head of the radius, it was made to slide into its socket. Five weeks after I found all of the motions of the forearm completely restored, except that he could not extend it perfectly.

The head of the radius was also a little more prominent in front than in the opposite arm. Four or five years later, the projection of the head of the radius had disappeared, and the functions of the arm were perfect.

In Dr. Muhlenberg's tables of delayed and non-union, resection was practised three times, but with no recorded cures. This is a result which might reasonably be expected; while drilling was practised six times, with five successes.

§ 4. Fracture of the Styloid Process of the Ulna.

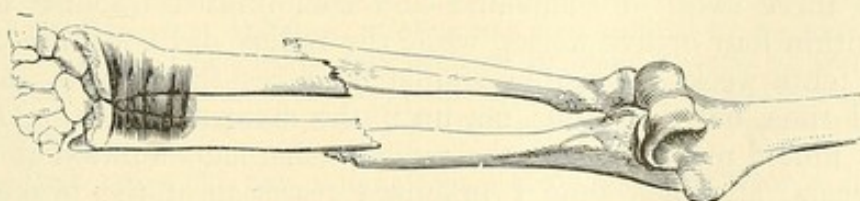
The occasional complication of a Colles's fracture with a fracture of the styloid process of the ulna has already been noticed. Much more rarely this process is broken alone, as a result of direct violence. I am unable to speak of the symptoms or treatment of this accident farther than to say, that it must be easily recognized by its mobility, and probably by the presence of crepitus; and that its treatment demands immobilization, while the wrist is maintained in a straight position, or in a position slightly inclined toward the ulna. At least a fibrous union ought thus to be easily obtained.

CHAPTER XXIV.

FRACTURES OF THE RADIUS AND ULNA.

Causes.—In a majority of the examples of this fracture seen by me, which have been of such a character as to warrant an attempt to save the limb, the accident has been occasioned by a fall upon the palm of the hand while the arm was extended in front of the body. Yet this cause is not so constant as in fractures of the radius alone, since a considerable number have been occasioned by direct blows; and if we were to add to this estimate all of those bad compound fractures which have demanded immediate amputation, the proportion of fractures occasioned by direct and indirect blows might be found to be pretty nearly balanced.

FIG. 177.



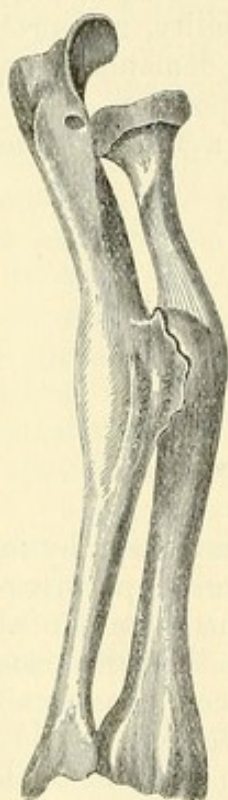
Fracture in the middle third.

Point of Fracture, Character, Direction of Displacement, etc.—In a record of seventy-two fractures of both bones, not including gunshot fractures, or those demanding immediate amputation, I have found six broken in the upper third, thirty-one in the middle third, and thirty-five

in the lower third. In one case the radius was broken three-quarters of an inch above its lower end, and the ulna about one inch below the coracoid process. Four of the fractures belonging to the lower third were probably epiphyseal separations. Fifty-eight were simple, eight compound, one was comminuted, three both compound and comminuted, one complicated with a fracture of the humerus, and one with a partial luxation of the lower end of the radius. With three exceptions, all of these more serious accidents were arranged among fractures of the lower third, and generally the bones had been broken near the wrist.

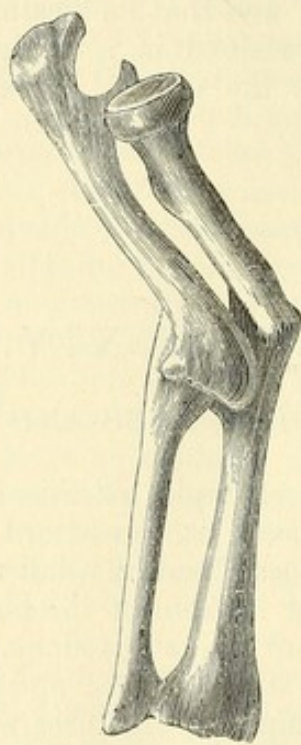
Prognosis.—Generally these bones unite in from twenty to thirty days; but I have seen the union occasionally delayed considerably beyond this time, and this delay has occurred especially in the case of the radius.

FIG. 178.



Joint between bones
at point of fracture.

FIG. 179.



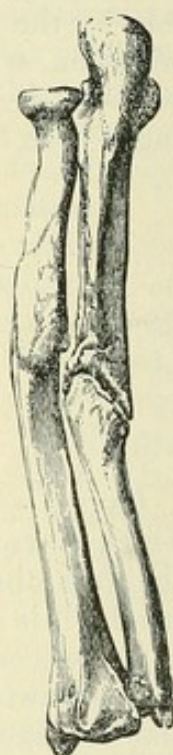
Angular displacement
of both bones.

FIG. 180.



Fracture in the
lower third.

FIG. 181.



Union with slight
lateral displacement.

Thus, in three cases of compound and comminuted fracture, the ulna united within four or five weeks, while the radius did not unite until the ninth or tenth week. Twice in simple fractures the ulna has united in the usual time, but the radius not until the sixteenth week. Once the ulna has united promptly and the radius remained ununited at the end of two years, at which time I practised resection of the broken ends. On the other hand, I have once seen the union delayed four months in the case of the ulna, when the radius had united in the usual time; and in one example of compound fracture both bones refused to unite until after the fifth month. Muhlenberg has recorded thirty-seven cases of delayed and non-union of both bones, out of a total of six hundred and fifty-six similar examples in all the long bones.

A majority of the whole number seen by me have united without any appreciable deformity, and fifteen are known to have left some marked defect, while two have resulted finally in the loss of the arm itself. I have seen the fragments deviate slightly in almost every direction, but most often it has been noticed that the deviation was to the radial or ulnar side. Thus, in three examples, two of which had been compound fractures, the bones have united in such a position as that from the point of fracture downward the forearm has been deflected to the ulnar side, and a marked projection has been left at the seat of fracture on the radial side; while in two examples, both of which were simple fractures, exactly the opposite condition has obtained, the lower part of the forearm being deflected to the radial side.

In most cases the hand has been left with some tendency to pronation; in many instances this tendency was very slight and scarcely appreciable, but in others it has been quite marked, so that the patients have been wholly unable to supine the forearm except by a motion of the humerus in its socket.

From what has been said, it must be seen that the prognosis in these accidents takes the widest range; for while a larger proportion than in the case of almost any other of the long bones, unite without any appreciable deformity, a considerable number delay to unite, or do not unite at all, and some, even where the fracture is most simple, result in the complete loss of the limb. I am not now speaking of those more severe accidents in which the limb is at once condemned to amputation, and which, in the case of the arm, are numerous; but, as I have already mentioned, our observations here apply only to cases which came under treatment with a view especially to the fracture. I shall state the facts more fully, and then perhaps we shall think it proper to inquire why, when, as a rule, the treatment is found to be so simple and successful, and pretty often, indeed, it results so disastrously. I have brought together also no less than six cases of sloughing of the arm, after fracture of the radius, and one of sloughing from tight bandaging, where the radius was supposed to be broken, although the dissection proves that it was not. To these I shall now add eight examples of sloughing after fracture of both radius and ulna.

J. M., æt. 9, fell from a ladder, about thirty feet to the ground, breaking the right radius and ulna in their middle thirds. A surgeon was in attendance about four or five hours after the accident occurred. He then reduced the fractures and applied two broad splints, one on the palmar and one on the dorsal surface of the forearm. Whether a roller was first applied to the arm or not, I am unable to say. The splints were secured in place by a roller and the arm laid in a sling. On the fifth day the surgeon removed the bandages and found the arm gangrenous; the arm finally fell off at the shoulder-joint, after which he made a good recovery.

A child, two years old, had fallen from a chair upon the floor, a distance of about two feet. A German physician being called, found, as he believed, a fracture of both bones of the left arm. The fracture was near the middle. He immediately applied a roller from the fingers to the elbow, and over these three narrow splints made of the wood of a cigar-box. One of these was laid upon the palmar, one upon the dorsal, and one upon the radial side of the forearm, and the whole were bound together by another roller. From this time until the tenth day the child continued to play about on the floor. Ten days after the accident occurred the doctor noticed that the ulnar side of the little finger was

blue. The bandages were immediately removed, and were never again applied tightly. Three days after, I saw the arm with the attending physician. The gangrene had continued to extend, involving now the whole of the little finger and most of the thumb. There were also gangrenous spots over the hand and forearm, extending to within one inch from the elbow-joint; these spots were more numerous in front and on the back of the forearm, and seemed to correspond to the pressure of the splints. The hand was much swollen, and also the arm above the line of the gangrene. The sloughs had already commenced to be thrown off, and the gangrene was only extending in a few points. The child appeared well and rather playful, except when the arm was being dressed. I have since learned that the arm and a large portion of the hand were finally saved. A lad, aged nine years, was brought to the Dispensary, with a fracture of the radius and ulna. It was dressed by the visiting surgeon with splints and bandages. He did not return to the Dispensary as directed to do, and on the third or fourth day portions of the arm and hand were found to be gangrenous. I was consulted by the parents of D. C. on account of a serious distortion of the hand and forearm, caused by sloughing, splints and bandages having been applied by her surgeon for a supposed fracture; but when examined by me, about ten weeks after the accident, there was no evidence that the bones had ever been broken. She complained to her surgeon that the bandages were too tight, but he thought otherwise, and they were not removed until the third day, when the gangrene had already occurred. The child was about five years old. A man, *æt.* 20, suffered a simple fracture of the right radius and ulna March 14, 1874. On the same day it was dressed with a roller next to the skin and over this the splints. On the following day the fingers were black, but the same dressings were continued, and they were not removed completely until the next day. He was admitted to Bellevue on the 16th, and by courtesy of Dr. Gouley I was permitted to examine the arm on the 7th of April. He had then lost all of his fingers, except a portion of the thumb, and there were extensive sloughing and suppuration along the forearm. His death took place a few days later.¹ A. T., *æt.* 50, fell upon her left hand, causing a compound fracture of the radius and ulna, about three inches above the wrist-joint. The surgeon dressed the arm with splints, applying the bandages "snugly." Two days later she was brought to one of my wards at Bellevue, with the back of the hand and most of the forearm in a state of gangrene, evidently caused by the bandages. Seven or eight days later she died before the house surgeon could reach her, from a secondary hemorrhage. In the following case there was probably no fracture; no doubt could be entertained as to the cause of the gangrene. A girl, *æt.* 5, fell upon the palm of her hand. A surgeon saw her within one hour, put on two wooden splints, with cotton-batting laid loosely underneath, securing them with a roller. Half an hour after it was dressed the fingers were blue, and the pain was so great that the surgeon was recalled. On his arrival he said it was not too tight. On the following day the condition was the same, but the surgeon refused to loosen the dressings. Two days later he removed the bandage, and found a slough extending nearly the whole length of the palmar surface of the forearm. Some months later I found the arm straight, but the hand much distorted by the cicatrix.

I have now to relate a case in which sloughing and death occurred as the consequence of a tight bandage, the patient being under my own charge: J. B., *æt.* 22, was admitted to Bellevue Hospital with a fracture of the left forearm, near its middle, caused by the kick of a horse on the day before. On the same day I dressed the fracture before the class of medical students in the hospital, using a palmar and dorsal board splint, covered and stuffed with cotton-batting, according to my usual method; securing the splints with a roller, including the hand and forearm. The arm was then placed in a sling and he was sent to his ward. The following day being Sunday, I did not visit the hospital. On Monday I inquired for him, and learned that he was out walking in the yard. Tuesday I met him, returning from a walk in the yard, just as I was leaving the ward. He was apparently in perfect health, but, as I stopped him a moment to look at his arm, I saw that the hand was swollen and purple. The dressings were immediately

¹ New York Journ. Med., June, 1874.

removed, and the patient placed in bed. There were upon the arm two spots looking like superficial sloughs. He was suffering no pain. The gangrene subsequently extended until it involved a large portion of the hand and forearm, and on the eighteenth day after the receipt of the injury he died. A careful and daily observation of the condition of the hand, and a prompt removal or loosening of the dressings when the hand first showed symptoms of arrest of circulation, would probably have prevented this disastrous result. The splints and bandages were removed the first time I saw him after the original dressings had been made, but this was too late; some one should have seen the approaching cloud before it was ready to burst.

How shall we explain the frequency of these accidents after fracture, especially of the forearm? Malgaigne, speaking of fractures of both bones of the forearm, remarks that "when the displacement is considerable, or more especially when the outward violence has been excessive, we frequently see follow a very intense inflammatory swelling, and there is no fracture which complicates itself so easily with gangrene under the pressure of apparatus."¹

Says Nélaton: "If we make choice of the apparatus of J. L. Petit, it is necessary that it shall not be applied too tightly, for, as Professor Roux has long since remarked, fractures of the forearm are those which furnish most of the examples of gangrene in consequence of an arrest of the circulation. This is easily understood, if we consider on the one hand the superficial position of the two principal arteries of the forearm, and on the other the disposition of the apparel, which must almost infallibly compress the arteries to a great extent."²

I do not think that this accident is due always to the negligence of the surgeon. It may be due many times to the carelessness of the parents or of the patient himself; as in the case of the boy who came under my own observation, and who lost his arm at the shoulder-joint. Sometimes also it may be due rather to the severity of the original injury, which, the experience of every surgeon will prove, is occasionally competent to the production of such bad results. A number of unfortunate circumstances may have concurred, such as a severe injury, especially where the skin has remained unbroken and the effused blood has had no opportunity to escape—the broken bone may have rested against the trunk of a main artery, causing an arrest of its circulation—the constitution may be impaired by previous illness, or it may be suffering under the shock of the injury; yet that it may be and too often is the result of maltreatment on the part of the surgeon, is undeniable. It is proper, however, to discriminate between the responsibility which attaches to the surgeon as the true exponent of the state of his art, and that which attaches to the art itself as taught by the masters. The old surgeons applied first a roller to the hand and forearm, and over this their various splints.

J. L. Petit thought he had made a valuable improvement upon this simple plan, by laying over the roller a compress and splint; the compress being intended to press between the bones, and to antagonize the action of the roller in drawing the fragments toward each other. Duverney believed that this object would be best accomplished by placing the pad against the skin, and under a circular compress; while Desault declared all of these modes inefficient, and announced a method which he regarded as accomplishing at once and completely all of the indications; the sole peculiarity of which method consisted in placing graduated pads against the skin, and securing them in place by a roller. Boyer adopted the same method without any modifications, and Mr. Hind, in

¹ Malgaigne. *Frac. et Disloc.*, tom. i. p. 589.

² Nélaton. *Pathologie Chirurgicale*, p. 735.

his illustrations of fractures, already referred to, has seen fit to recommend the same, at least in fractures of the radius.

It is quite obvious that between these various methods there remains very little if anything to choose, the differences being too trifling and unessential to claim serious consideration. Each alike is inadequate to accomplish any amount of useful pressure between the fragments; each alike is calculated to bind the bones one against the other, and each alike exposes to the danger of ligation and of gangrene of the hand and forearm. Says M. Dupuytren: "The practice of rolling the arm before the splints are applied, whether internal or external to the pads and compresses, is eminently mischievous; and instead of fulfilling, directly counteracts the indications which it is most important to keep in view. As to the width of the splints, surgeons are also very generally agreed, at the present day, that they ought to be wider than the arm, so as to prevent the roller or the tapes from resting against its sides.

I do not intend to deny peremptorily, and without qualification, the value of the graduated compresses, which, as we have seen, are usually laid along the interosseous space to press the fragments asunder. It is necessary, however, to caution the surgeon against their injudicious use. And I suspect that to this portion of the dressing quite as much as to any other cause, are due those frightful accidents of which I have already spoken. The arteries are not only exposed, from their superficial position, to pressure from a compress, but, in addition to this, it will be noticed that the two principal arteries, the radial and the ulnar, are situated upon a broad and flat surface of bone, along which this pressure must operate most advantageously.

I have observed another fact in this connection: when this compress is extended low down on the palmar surface, within an inch or two of the wrist-joint, it soon becomes excessively painful, and sometimes even wholly insupportable, in consequence of the pressure made upon the median nerve; and I find myself always obliged to exercise great care in the adaptation of the pads at this point. For this reason alone, I believe, in case of a fracture near the base of the radius, the lower fragment, if it were thrown toward the ulna, could not be retained in its place by graduated compresses.

In short, finding that broad splints, properly covered and padded, answer very well to crowd the muscles into the interosseous space, so far as it is proper to do so, and believing that this mode is less painful and less dangerous, I never resort to graduated compresses, nor can I appreciate their necessity, or, indeed, their utility.

Mayor, of Lausanne, says: "What signify graduated compresses placed between the bones of the forearm for the purpose of separating them from each other? These bones will not have that constant tendency to approach each other which has been supposed, provided, first, that they have been well reduced; second, that for the purpose of maintaining them in position we do not make use of a preliminary circular bandage, whose action is an absurdity; and, in short, provided we make the retentive means act chiefly upon the palmar and dorsal surfaces of the forearm."¹

¹ *Bandages et Appareils à Pansements, ou Nouveau Système Déligation Chirurgicale*, par M. Mathias Mayor, Chirurg. en Chef de l'Hôpital de Lausanne, Switzerland. Paris ed., 1838, p. 345.

Surgeons have generally, after the splints have been applied, placed the forearm in a position of semi-pronation, or midway between supination and pronation, so that the radius should be uppermost; it being assumed that in this position the two bones are most nearly parallel, and least inclined to displacement.

Says Mr. South, in a note to Chelius: "In fractures of both bones the forearm is best laid supine;" and Nélaton declares that in fractures of the radius and ulna at any point of their upper thirds it will be necessary to supine the arm, both in the reduction and during the subsequent treatment; but that in fractures of the inferior two-thirds we may place the limb in a condition of semi-pronation. It seems very probable, that both of these gentlemen have received their suggestions from Mr. Lonsdale, who, as we have already seen, has treated the question very much at length, and who has finally declared his decided preference for the supine position in the treatment of all fractures of the forearm. The advantages which he claims for this method are, more perfect coaptation of the broken ends, less liability of the fragments to encroach upon the interosseous space, and consequently less danger of ankylosis between the bones and of non-union of the fragments, more complete restoration of the power of supination, and less tendency to lateral distortion, or of falling off to the ulnar or radial sides.

My own cases, treated by the usual method, have shown that while supination is frequently impaired and sometimes entirely lost, pronation is rarely affected; and that lateral displacements are much more common than displacements forward or backward. How this position, semi-pronation, may tend to the production of a permanent pronation, I have fully explained when speaking of fractures of the head of the radius; and the influence of the same position, the forearm resting upon its ulnar margin in the sling, in the production of a lateral deviation, is also easily understood. If the arm rests upon the sling so that its weight bears more upon the point of fracture than upon the extremities of the bones, then the ulna, or both ulna and radius, will incline gradually to the radial side, and the hand will fall off to the ulnar side; or if the sling rests under the wrist or hand chiefly, the hand will ascend to the radial side, and the broken ends of the two bones will project to the ulnar side. If this plan be adopted, viz., laying the hand and forearm upon its back, instead of upon its ulnar margin, the elbow should remain at the side, the humerus falling perpendicularly from its socket; and the forearm should rest in the sling directed forward from the body.

The following is the method usually employed by the author: Two thin, but firm, wooden splints are prepared, of uniform breadth, sufficiently wide that when the roller is applied it shall touch only lightly the radial and ulnar margins of the forearm. The palmar splint should be long enough to extend from the bend of the elbow, the arm being flexed, to the metacarpo-phalangeal articulations, the fingers being flexed. The dorsal splint should be a little shorter, or of a length to extend from the base of the olecranon process to the carpus. Both of these splints must be covered with cloth, and properly padded with cotton-batting; taking care to leave but little of

FIG. 182.



Palmar splint.

the cotton placed where it might press upon the radial and ulnar arteries and median nerve; that is, at the front of the wrist. The splints, being carefully fitted, are applied while the forearm is held at a right angle with the arm, and in a position midway between pronation and supination, one to the palmar and the other to the dorsal surface of the forearm, and secured with a roller. There must be no pressure against the humerus at the bend of the elbow; and the fingers must be flexed easily over the lower end of the palmar splint. The dorsal splint should not extend beyond the lower end of the radius and ulna. It is understood, of course, that while the splints are being secured in place, extension and counter-extension are maintained for the purpose of securing coaptation of the broken extremities as far as possible. The dressing being completed, the forearm is suspended in a sling.

Finally, whatever may be the mode of dressing, let me repeat the injunction to examine the arm frequently. No surgeon can do justice to himself, or to his patient, who does not look at the arm at least once in twenty-four hours during the first ten or fourteen days, and in some cases the patient ought to be seen twice daily. When the fracture is compound, it is often quite impossible to retain the forearm in the half-pronated position; since, when thus placed, and only slightly supported, as it must necessarily be, it inevitably falls over upon its palmar surface. There can be no doubt that in such a case we ought, from the first, if it is found practicable, to place it upon its back, in a position of complete or nearly complete supination. For this purpose, a single broad splint, carefully cushioned, and covered with oiled cloth, is the most suitable. Upon this the forearm is to be laid, and secured gently with a few turns of the roller. If the patient is able to do so, and wishes to walk about, the board may be suspended to the neck.

I have said that we ought, in cases of compound fracture, to lay the forearm upon its back, if practicable. I am sure, however, that the surgeon will find very many patients who cannot endure this position, and he may be compelled, therefore, to lay the limb upon its palmar surface, or to leave it to assume any other position in which it may be the most at ease.

In conclusion, I desire again to call attention to the splint employed by Dr. Scott, and of which an illustration is given in the chapter which treats of Fractures of the Radius.

Of the 37 examples of *delayed and non-union* recorded by Muhlenberg, 30 were subjected to treatment. Of 4 treated by manual friction, 1 was cured and 3 failed. One treated by section was cured. Of 17 treated by resection, 11 were cured and 6 failed; 4 were treated by drilling, and all failed. Of 4 treated by mechanical appliances and immobilization, 2 were cured and 2 failed.¹

¹ Muhlenberg, Agnew's Surg., op. cit., vol. i. p. 805.

CHAPTER XXV.

FRACTURES OF THE CARPAL BONES.

ALL of the cases of fracture of the carpal bones which have come under my observation were, without exception, compound and complicated, and have resulted in the complete loss of the hand, or in some less serious, but never inconsiderable, mutilation or maiming. In no case has a treatment been adopted which might be regarded as having reference to the fracture, or the purpose of which was to insure apposition and union of the fragments. It may be proper to assume, in a matter so easily comprehended, what actual and recorded experience has not proven, namely, that simple fractures of these bones will demand very little surgical interference, and that they will unite generally without much displacement, and without any considerable maiming. It is, indeed, quite probable that some degree of ankylosis between their adjacent surfaces will occur, yet even in the normal condition they enjoy so little motion as to render it doubtful whether its complete loss would be very sensibly felt.

In cases of comminuted, compound, and otherwise complicated fractures of the carpal bones, which accidents are sufficiently common, the surgeon has only, I conceive, to follow carefully those general or special indications which may happen to be present, the precise character of which it would be difficult to anticipate, and for the treatment of which it would be unsafe to attempt in a written treatise to provide.

CHAPTER XXVI.

FRACTURES OF THE METACARPAL BONES.

Development of Metacarpal Bones.—These bones are each formed from two centres of ossification. In the case of the metacarpal bones of the four fingers there is one centre for each shaft, and one for each distal extremity; but in the case of the metacarpal bone of the thumb there is one centre for the shaft and one for the proximal extremity. All these epiphyses unite with the shafts at about the twentieth year.

Causes.—They are generally broken by direct blows; and in that case the injury is often of such a character as to demand amputation, and does not therefore belong to that class of accidents of which it is the purpose of this volume to treat. Not an inconsiderable number, however, are the results of indirect blows, and especially of blows upon the knuckles re-

ceived in pugilistic encounters. Thus, in a record of sixteen fractures, I find this cause assigned in seven; in one other instance it was occasioned by falling upon the clenched fist, and in one by striking a board; so that the fracture has resulted from a blow upon the ends of the bones in nine of the sixteen examples.

Point of Fracture; Direction of Displacement; Symptoms.—Once the fracture has occurred in the metacarpal bone of the thumb; eight times in the metacarpal bone of the index finger; once in the second finger; three times in the ring finger, and three times in the metacarpal bone of the little finger. Two of those belonging to the ring finger, and the three occurring in the little finger, were produced by blows with the clenched fist, and in each instance the fracture was in the lower or distal third of the bone. Three of the fractures of the metacarpal bone of the index finger were produced also in the same way; two of which were near the middle of the bone, and one near the proximal end. Of the whole number, seven were broken through the lower third, five through the middle, and four through the upper third.

In every instance where the bone is known to have been broken by a blow upon the knuckles, the distal end of the distal fragment was thrown toward the palm, and this fragment was salient backward at the point of fracture.

In the following case the bone was probably separated at the epiphysis:

T. R., æt. 8, fell down a flight of steps, breaking the metacarpal bone of the index finger of the right hand near its lower extremity, and apparently at the junction of the epiphysis with the diaphysis. The lower fragment, projecting abruptly into the palm of the hand, could be easily replaced, or with only moderate effort, yet immediately when the support was removed it would become displaced. There was no crepitus. It was dressed very carefully with a splint and compress; but, notwithstanding our continued efforts to keep the fragments in place, the epiphysis united considerably depressed toward the palm.

In one instance, also, I think the bone was rather bent, or partially fractured, than broken completely. This was a case of the fracture of the metacarpal bone of the ring finger, produced in a gymnasium by striking with the clenched fist against a board, and to which I have already alluded. I did not see the young man until four weeks after the accident, when I found the lower end of the bone depressed toward the palm, and the angle made at the point of fracture was rather rounded and quite smooth; it was also tender at this point, but the bone was firm and unyielding. Four years after I was permitted to examine it again, and I found the same slight deformity still continuing.

A partial explanation of the fact that the distal end of the distal fragment is generally displaced toward the palm, may be found in the natural curve of these bones, which is such that when the fracture has been produced by a counter-stroke, the distal end would almost necessarily be driven in this direction; and a farther explanation has been suggested by Mr. B. Cooper, namely, the action of the interossei.

Prognosis.—Generally, when the fracture is simple, and the displacement is not considerable, the nature of the accident is overlooked, and some deformity must inevitably ensue. In a majority of the cases which have come under my observation this has been the fact, and the bone has remained slightly bent at the seat of fracture, but without affecting in any degree the value of the hand.

The following example has furnished the most serious result of any case of simple fracture of these bones which has come under my notice: L. M., æt. 25, struck a man with his clenched fist, breaking the metacarpal bone of the index finger of the right hand near its middle. Great swelling and supuration followed the injury. Nearly four months after the injury was received there existed a complete ankylosis at the wrist-joint, and a partial ankylosis in the fingers. The hand was deflected forcibly to the radial side. At the point of fracture the fragments were salient backward and quite prominent, but firmly united.

Even when the existence of the fracture is recognized, it is not always easy to retain the fragments in place.

Miss E., of Erie, N. Y., æt. 18, fell, striking upon her right hand with her fingers forcibly bent into the palm of the hand. On the following day she consulted me at my office, and I found the metacarpal bone of the ring finger broken at about three-quarters of an inch from its distal end, and the distal extremity of the fragment depressed toward the palm. A feeble crepitus, with distinct motion, completed the diagnosis. The young lady was very anxious to have a perfect hand, and I was determined if possible to accomplish it. Finding that the joint end of the distal fragment was constantly disposed to fall toward the palm, I constructed a gutta-percha splint for the hand and fingers, and after placing a pad directly underneath this fragment, I secured it firmly with a roller. From this time until the end of four weeks she remained under my care, visiting me as often as once or twice a week, and at each dressing I found the distal fragment slightly displaced in the same direction as at first, nor was I able ever to make it resume completely its position.

Ordinarily, however, no such difficulty is experienced, and the bone, supported by simple means, unites quickly and without deformity.

An engineer was struck by a piece of iron in such a way as to break his right forearm and the second metacarpal bone of the same hand. The fracture of the metacarpal bone was compound and about three-quarters of an inch from its proximal extremity. When he called upon me, which was immediately after the injury was received, I found the proximal fragment projecting directly backward, its sharp point rising above the skin, into which position it was evidently drawn by the action of the extensor carpi radialis longior muscle. By pressure alone it could be replaced, but it was much more easily reduced when the hand was forcibly carried backward on the forearm. I therefore secured the hand in this position with appropriate splints, and it was maintained in this posture during most of the subsequent treatment. Union finally took place, but not without some backward displacement. Four months after the accident occurred I examined the hand, and found the skin healed over completely, the end of the fragment having become rounded and smooth, so as not to give him any degree of annoyance. His wrist was as flexible and as strong as before. No doubt the projection of the fragment might have been prevented entirely by cutting at the point of its attachment the tendon of the muscle, but this would have sensibly weakened the wrist-joint, and I preferred the alternative of a projection of the fragment.

Treatment.—With moderate extension made upon the finger corresponding to the broken bone, while the fragments are forced home by firm pressure, the bone may generally be brought at once into line, and we may now proceed to adapt a gutta-percha, felt, or thick pasteboard splint, to either the whole surface of the back or palm of the hand and fingers, while they are held in a position of easy flexion. It is not very material to which of these surfaces the splint is applied; or rather, I may say, it ought to be applied to the one or the other according as circumstances seem to indicate. It should be well padded, and especially at certain points, in order to the more effectual support of the fragments.

It is then to be secured in place with several turns of a roller. When either of the metacarpal bones, except those of the great or ring finger, is broken, the splint must be wide enough to secure the sides of the hand against the pressure of the roller. Thus dressed, the hand may be laid in a sling beside the chest, or while sitting it may rest upon a table. The apparel must be examined daily, and readjusted as often as it shall become disarranged, or as a doubt shall arise as to the condition of the parts. When the fracture is followed by much inflammation, or occurs near, and especially if it actually involves a joint, the same precautions must be adopted to prevent ankylosis as in the case of similar fractures in other bones.

CHAPTER XXVII.

FRACTURES OF THE FINGERS.

Development of the Phalanges of the Hand.—The phalanges of the hand are formed from two centres of ossification, namely, one for each shaft and one for each proximal end. Ossification commences in the shafts at about the sixth week; in the epiphyses of the first phalanges between the third and fourth years, and in the epiphyses of the last two phalanges somewhat later. Complete bony union takes place between the epiphyses and the shafts at from the eighteenth to the twentieth year.

Causes.—I do not remember to have seen a fracture of one of the phalanges produced by a counter-stroke; I am aware, however, that they are occasionally produced in this way, as by falling upon the ends of the fingers, and especially by the stroke of a ball in the game of base.

The fact, however, that they are generally the consequence of a direct blow, and that the finger bones are small and only protected by a thin covering of skin and tendons, renders them peculiarly liable to comminution and to other serious complications. Thus, in a record of thirty fractures, only eighteen were sufficiently simple to warrant an attempt to save them; and only five are recorded as simple fractures without complications.

Point of Fracture and Direction of Displacement.—In the following case there was probably an epiphyseal disjunction:

A lad four years old had a simple fracture of the first phalanx of the ring finger of the left hand, the fracture being at the proximal end of the bone, and at the junction of the epiphysis with the shaft.

The finger was so much swollen at first, that no dressings were applied until the fifth day, at which time a gutta-percha splint was moulded to it carefully. It resulted in a perfect cure.

I have not seen the fragments much overlapped, except in one instance. Occasionally there has been no perceptible displacement; but generally there will be found a slight displacement in the direction of the diameter of the bone.

The case to which I refer as presenting an extraordinary overlapping was that of an Irish laboring woman, aged about thirty-five years, who, having fallen down a flight of steps, broke the first phalanx of the thumb below its middle. The distal fragment was displaced backward, overlapping the proximal fragment a little more than one-quarter of an inch. We made repeated efforts, by pulling upon the thumb with a sliding noose, and with all the strength of our four hands, but to no purpose. The fragments could not be reduced for one moment; and we left the patient as we had found her, only somewhat the worse for our violent and repeated extensions and manipulations. The finger was already considerably swollen when we began our efforts, and we cannot, therefore, say what might have been accomplished at an earlier moment, but I must confess that our defeat was unexpected, and does not seem to me to be satisfactorily explained.

Prognosis.—At least ten have left no appreciable lameness or deformity, and possibly several more. It is, therefore, probably true that these consequences may be avoided with proper care in one-half of the examples in which we attempt to save the finger; and perhaps it will occasion surprise that a perfect result may not be claimed in a larger proportion; but when we consider how frequently the accident is compound, and that even when it is not, the blow having generally been received directly upon the point of fracture, how promptly swelling ensues, it will be easily understood that it will be often found difficult to determine whether the bone is exactly in line or not, or to maintain it in this position after absolute coaptation has been once secured. I have seen the finger in two or three cases deviate laterally, or become permanently deflected to one side or the other; and once I have found it united, but rotated on its own axis. This latter case is not without instruction.

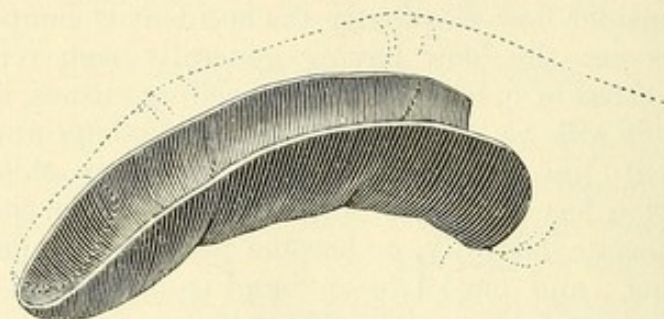
A girl, *æt.* 6, had her little finger caught by a door violently shut, breaking one of the phalanges, and nearly severing the finger. I closed the wound, and dressed the finger with a moulded pasteboard splint. My dressings were repeated often, and applied carefully; nor did I detect the rotation which the lower fragment had made upon its own axis until the union was consummated. I then found the extremity of the finger turned so that its palmar surface presented diagonally toward the ring finger.

Treatment.—Boyer, and after him Bransby Cooper, have taught that when the extreme phalanx is broken, from the small size of the bone, and from its having attached to it the nail and its matrix, it is better in all cases to amputate at once, as the process of reparation is in such case extremely slow and uncertain. Examples must, no doubt, sometimes occur, in which the fracture is so simple in its character as to render prompt reunion pretty certain; and even though the restoration should prove tedious, this ought scarcely to be regarded as a sufficient justification for so serious a mutilation as these surgeons propose, since the loss of even an extreme phalanx is not only a deformity, but must prove in many occupations a troublesome maiming.

Prof. Lizars, of the Toronto School of Medicine, C. W., has reported to me a case exactly in point: "A man fractured the distal extremity of the ring finger of the right hand. The fracture was transverse, and the nail was severely bruised, the accident being caused by a direct blow. Crepitus distinct. A dorsal splint and bandage were applied, and in a short time the fragments were united firmly by bone. The nail subsequently fell off, and a new one was formed."

The rule ought still to be held inviolate, which surgeons have so often repeated in reference to injuries inflicted upon the hand and fingers, namely, that we should save always as much as possible. It is remarkable, too, how much nature, assisted by art, can do toward the accomplishment of this purpose. If the bone of a finger is not only severed completely, but also all of its soft coverings, save only a narrow band of integument, are torn asunder, a chance remains for its restoration. And it is especially interesting to observe what recuperative powers are possessed by the articular surfaces of these smaller joints, so that although they may be broken into, or sawn through, or comminuted, and although small fragments be entirely removed, a complete restoration of their functions is sometimes permitted. I have seen and reported some such examples. It is true, however, that such fortunate results are rare, and they are rather to be hoped for than anticipated.

FIG. 183.



Gutta-percha splint for finger.

Since, in the case of these delicate bones, the slightest deviation from the natural form or position determines in the end an ugly deformity, it becomes exceedingly necessary, especially with females, that we should open the dressings and examine the fingers carefully from day to day, so that, as the swelling subsides, we may discover and correct any displacement which may happen to exist. As a splint, I have found nothing so convenient as gutta percha, moulded accurately to either the dorsal or palmar aspect of the finger; and the form of which I have found it generally necessary to change slightly every third or fourth day, until consolidation is nearly or quite completed. If the fracture is near or extends into a joint, the finger ought to be a little flexed, so as to place it in the most useful position in the event that ankylosis should occur; and as early as the end of the second week the joint surfaces should be slightly moved upon each other, in order to the prevention of fibrous or bony adhesions. Nor is there much danger of preventing the union of the bone by moving the joints at this early day. Union occurs between these fragments very speedily, and I have never met with a case of non-union of the phalanges, nor do I remember to have seen a case reported.

It is the lateral inclination of the distal end of the finger which, according to my experience, it will be found most difficult to obviate, and which may, perhaps, in some cases be most successfully combated by laying the two adjoining sound fingers against the broken finger, and then applying a moulded splint to the palmar surface of the whole. In

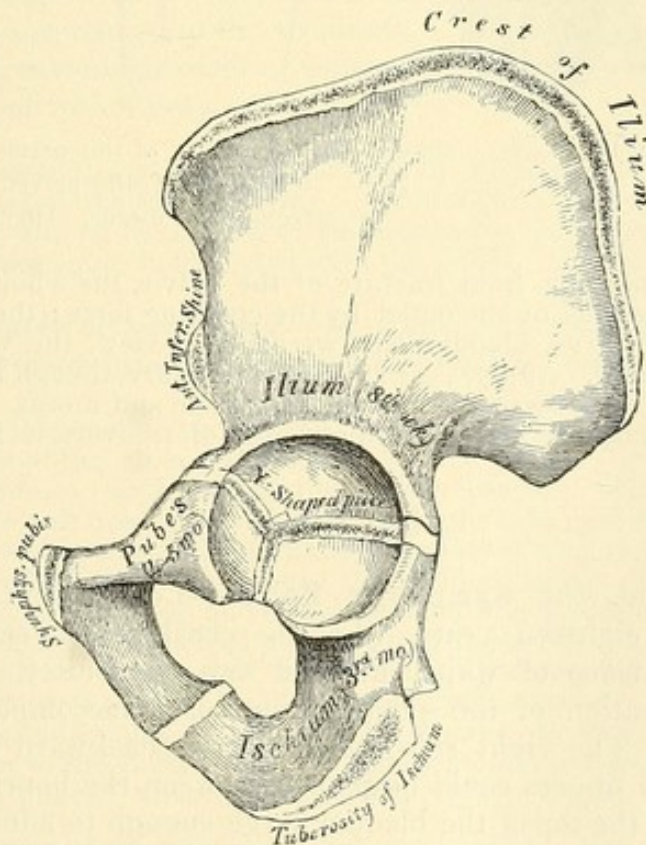
other cases it will be more convenient to apply the splint only to the broken finger. Rotation of the lower fragment on its own axis is especially to be guarded against, as the deformity which it occasions is more unseemly, and the impairment of utility more decided, than that occasioned by a lateral deviation. It may be well also to remind the surgeon of the convenience of extending the splint beyond the end of the last phalanx, and moulding it to this extremity, in order that the finger may be protected against injuries, and that when, from time to time, the splint is removed it may be reapplied with accuracy. In all cases the splint should be lined with cotton cloth, soft flannel, or sheet lint, and secured in place with narrow and neatly cut cotton rollers. Bandages of this width should never be torn, but carefully cut with scissors.

CHAPTER XXVIII.

FRACTURES OF THE PELVIS, AND TRAUMATIC SEPARATIONS OF ITS SYMPHYSES.

Development of the Os Innominatum (Fig. 184).—This bone is formed from eight centres, three of which are called primary, and five secondary.

FIG. 184.



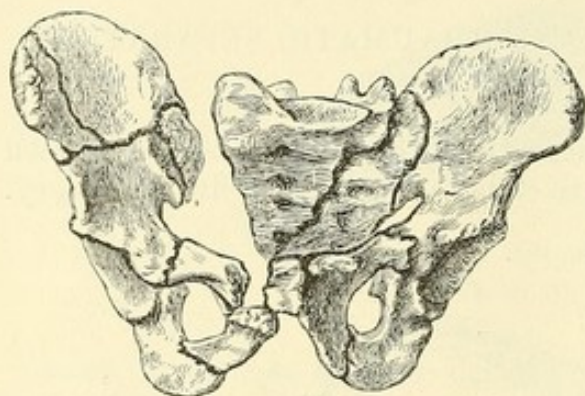
Development of the os innominatum. (Gray.)

The three primary centres belong respectively to the ilium, ischium, and pubes, and by their extension form eventually the greater portion of the

innominatum. They have a common point of union in the acetabulum; and the ischium unites with the pubes, also, by the junction of their rami. These conjunctions occur usually between the fifteenth and twentieth years of life. The secondary centres do not begin to ossify until the age of puberty, and may, therefore, properly be considered as epiphyses. One forms the crest of the ilium; one its anterior inferior spinous process; one forms the symphysis pubis; one the tuberosity of the ischium; while the fifth constitutes the centre of the bottom of the acetabulum. The epiphyses become joined to the primary bones, or the bodies of the innomina, at about the twenty-fifth year.

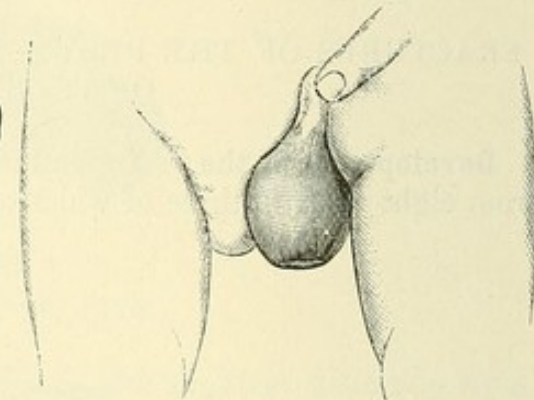
[Fracture of the pelvic bones is usually caused by a crushing injury, as by a wheel passing over the pelvis, or a heavy weight falling upon it, as a bank of earth. These fractures are rarely single, and generally there are several parts involved. (Fig. 185.) Frequently these injuries not only cause fractures, but implicate the viscera of the pelvis, especially the bladder. And it is in this latter complication that their danger largely depends. Bryant, of London, had under

FIG. 185.



Fracture of the pelvic bones. (Bryant.)

FIG. 186.



Fracture of the pelvis of a child with separation of the pelvis, prolapse of the rectum and uterus. (Bryant.)

his care a child suffering from fracture of the pelvis, the whole pelvic organs having been pressed out of the outlet by the crushing force; the large intestine for about a foot, uterus, bladder, etc., were all in view, the whole perineum having been ruptured. And yet she survived the injury, though fourteen months after the accident there was a prolapse of the rectum and uterus. However complicated the case may be there is often a chance of recovery. (Fig. 186.)]

§ 1. Pubes.

Separations at the Symphysis Pubis.—Lente mentions the case of a youth, æt. eighteen years, who was crushed between a couple of cars, in consequence of which he died two days after. The autopsy disclosed a separation of the symphysis pubis, unaccompanied with any other fracture. The right side was displaced backward about half an inch, so that the fingers could be passed between the bones. There was also a wound in the top of the bladder large enough to admit the thumb.¹ Similar accidents have been several times met with by surgeons. Hall

¹ Lente, New York Journ. Med., 2d ser., vol. iv. p. 286.

reports a case in which the pubes, thus separated, was actually thrust into the bladder; but in this example the ilium was broken also. This patient died.¹ Sir Astley Cooper has furnished an example of a simple fracture or traumatic separation at the symphysis, from which the patient after a long time almost completely recovered. The following is Sir Astley's account of the case:

"R. W., æt. twenty-two years, sustained a severe injury in consequence of a large quantity of gravel having fallen upon his back while in the act of stooping. It knocked him down; and on rising, which he did with considerable difficulty, he attempted to walk; this produced violent pain in the region of the bladder, extending upward in the course of the ureters to the kidneys. Upon inquiry, he stated that the urine he had voided since the accident was bloody and passed with difficulty. A fissure was found at the symphysis pubis, producing a separation of about two fingers' breadth. On pressure being made upon any part of the ilium, he complained of increased pain in the region of the pubes, and of numbness down the left thigh. A catheter was immediately passed, and the urine which was drawn off was clear and healthy. He remained in the hospital for three months without any check to the progress of his cure; the length of time it required being accounted for by the difficulty of reparation in the amphiarthrodial articulation; and when he left there was some slight separation of the pubes remaining; nor were the two lower extremities, or the anterior and superior spinous processes of the ilia, perfectly symmetrical, although he could walk very well."²

Malgaigne has collected four cases of simple separation at the symphysis pubis occasioned by external violence, and in three of the four cases it was occasioned by pressing out the thighs with great force; the separation being directly due, therefore, to muscular action. Two of these patients succumbed to the accidents. The same author has brought together, also, seventeen cases of separations of this symphysis occurring in childbirth, of which only seven survived.

[Gay,³ of Boston, saw a case of separation of the symphysis caused by injury from the pommel of the saddle, owing to a fall while riding on horseback. An abscess formed, and on being opened the separation at the symphysis and mobility of the bones could be detected with the finger. He recovered.]

True Fractures of the Pubes.—It is much more common, however, to find the pubic bone broken through its horizontal or ascending ramus.

Clark, of the Massachusetts General Hospital, has described a case of simultaneous fracture of the pubes and ischium in three places. The man, æt. twenty-nine years, had been caught between two heavy timbers. No crepitus could be detected, but he was unable to lie upon the right side, and the right limb was nearly paralyzed. It was evident that the bladder or urethra had been ruptured, and on the third day Dr. Clark opened the bladder through the perineum, evacuating a large amount of blood and urine, and affording to the patient very sensible relief. He died, having survived the accident twenty-five days. The autopsy disclosed several fractures, all of which belonged to the right os innominatum. First, a fracture of the pubes near the symphysis; second, a fracture near the junction of the pubes and ilium; third, a fracture through the ramus of the ischium anterior to the tuberosity.⁴ Sir Astley mentions a case of fracture of the "ramus of the pubes," unaccompanied with injury to the bladder or urethra,

¹ Hall, Amer. Journ. Med. Sci., vol. xxxiv. p. 248.

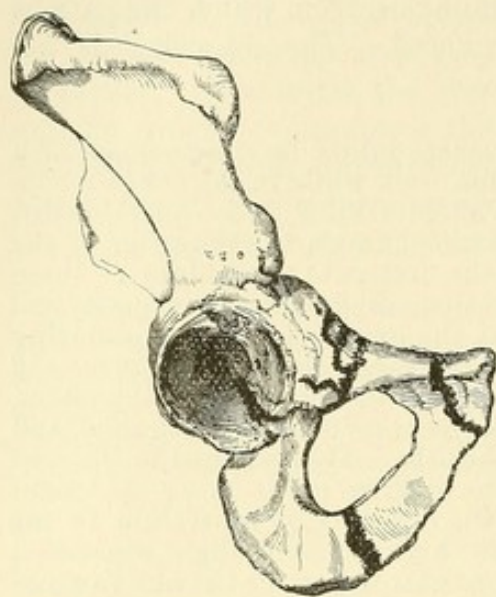
² Sir Astley Cooper, *Frac. and Disloc.*, Amer. ed., p. 144.

³ Med. and Surg. Reports of the City Hospital of the City of Boston, 1889.

⁴ Clark, Boston Med. and Surg. Journ., vol. liii. p. 185.

which resulted in a complete recovery, and in another case the patient recovered in eight weeks, and was able to walk nearly as well as before; he died of disease of the chest. The os pubis was found, at the autopsy, to have been broken in three places; there was also a fracture extending in two directions through the acetabulum, with an extensive comminuted fracture of the ilium, accompanied with great displacement.

FIG. 187.



Clark's case of fracture of the pelvis.

Marat, after a fracture, removed nearly the whole of the body of the pubes by incision, in a girl of eighteen years, and who not only recovered completely, but, having subsequently married, she gave birth to two children in easy and natural labors.¹

[Browne had a case of fracture of the rami of both pubic bones, as proved by the autopsy. They were caused by the fall of a heavy weight. On one side the epigastric artery had been torn off.²]

Cappelletti relates that a man, æt. 44, jumped from a carriage, the horses having run away, and alighted with his feet to the ground, but with one limb in the greatest possible degree of abduction.

Six months after there remained a slight swelling near the ramus of the ischium and pubes, under which a careful examination detected a fragment of bone two and half inches long and of the "size of the finger." The patient was able to walk, but not without pain and limping. On examining anteriorly, Cappelletti found this part of the pelvis defective, and the loose portion of the bone had all of the anatomical characters of the defective part.³

Whitaker, of Lewistown, N. Y., saw the body of the left os pubis broken in a female while in the seventh month of pregnancy. She had fallen down a flight of stairs, striking astride the edge of an open, upright barrel. The fracture was oblique, and with but little displacement; yet she complained of excruciating pain in the left pubic region on the least motion. The accident was followed by no positive attempt at miscarriage.⁴

[Fay, of Denver, had a case caused by a falling bank, in which the fracture was compound. The horizontal ramus was broken, but without any injury of the bladder.⁵

Allis,⁶ of Philadelphia, discussing fractures and disjunctures of the pelvis, regards the pelvis as a single structure, like the adult skull, and so compactly joined at the symphysis that separation without violence to bony connections is practically impossible. From a clinical standpoint he considers the pelvis as a single bone. The main sources of danger in injuries of the pelvis are to the genito-urinary apparatus, and the bloodvessels. These injuries, he believes, are due to the spreading apart of the bones, "the effect of a sudden expansion of the pelvic girdle," rather than to the fractures. The soft tissues, as the urethra and large veins and arteries, are torn or lacerated, and not cut.]

Prognosis.—The danger in these accidents consists not so much in the fracture, as in the injury done to the bladder and other pelvic viscera. If the bladder is opened into the peritoneal cavity, death is almost inevit-

¹ Marat, from Malgaigne, op. cit., p. 646.

² London Lancet, 1889, vol. i.

³ Cappelletti, Ranking's Abstract, No. viii. p. 83; from *Giornale per servire al Progressi della Patologie della Terapeutica*, 1847.

⁴ Whitaker, Amer. Journ. Med. Sci., July, 1857, p. 283.

⁵ Denver Med. Times, Jan. 1885.

⁶ Trans. Amer. Surg. Assoc., vol. viii. 1890.

able; and even when the bladder or urethra has suffered laceration lower down or at any point above the deep perineal fascia, extensive urinary infiltrations, followed by abscesses and gangrene, generally expose these patients to the most imminent hazards.

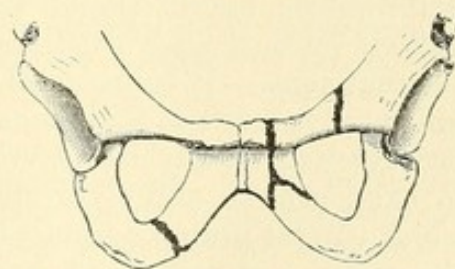
Treatment.—The practice pursued at Guy's Hospital, in the case of separation at the symphysis pubis, commends itself both by its simplicity and by its success. Antiphlogistic remedies steadily pursued, rest in the recumbent posture, the use of the catheter when necessary, and in certain cases the girdling of the pelvis with a firm belt or band, are measures which seem to meet all of the important indications. If the fracture is accompanied with displacement, it will be proper to attempt to restore the fragments; but, except in the case of separation at the symphysis, very little aid can be expected from a band or any similar means in retaining them in place. It will be sufficient, generally, in such examples to place the patient quietly upon his back, with his thighs flexed upon his body, and to treat the accident in all other respects as a case of inflammation. If the urine has become extravasated underneath the pelvic fascia, no time ought to be lost in opening freely through the perineum, and in extending the incision, if necessary, into the urethra and bladder.

§ 2. Ischium.

When speaking of fractures of the pubes, I have already mentioned some examples of fractures of the ischium also; indeed, it is seldom that one of the bones of the innominatum is broken without a coincident fracture of one or both of the others. The records of surgery furnish several other examples, produced generally by a fall upon the tuberosities; but, perhaps, the most remarkable instance is that mentioned by Marat as having occurred in a female during labor.

The following summary of a case of fracture of the ischium, reported by Sir Astley Cooper, will serve to illustrate one of the most fortunate terminations of these accidents when accompanied with a rupture of the urethra: A young man who was driving a cart was thrown down, and a wheel passed over him. On the following morning he was found to have a fracture of the left leg and a contusion of the inner side of the left thigh. There was also great swelling and ecchymosis of the scrotum, with a slight appearance of injury over the pubes and left hypochondrium. No fracture of the pelvis was at that time discovered. The patient was suffering great pain, and was cold and exhausted. Bloody urine escaped from the bladder. On the eighth day an abscess had pointed on the left side of the perineum, which, being opened, discharged a large quantity of pus having the odor of urine; extensive sloughing occurred, and the patient sank very low. On introducing the finger into the wound, the ascending ramus of the ischium could be distinctly felt, and the fracture traced in an oblique course, the upper fragment being slightly displaced forward. When the catheter was introduced into the urethra it was found to enter this wound, and could be felt resting against the naked bone. From this time until the twenty-sixth day, the urine continued to escape freely through

FIG. 188.



Fracture of the pubic and ischiatic bones.

the wound. In about six weeks more the fistulous opening had entirely closed, and after several months his recovery was complete.¹

[Bennett, of Dublin, reports a dissecting-room case in which the ischium was found detached from the left innominate by fracture, which had traversed the junction of the bone with the ilium and pubis. The detached bone had been displaced backward and upward—a displacement which appears to have been limited by the ramus ischii catching against the pubic margin of the acetabulum; in this position the ramus was united both to the pubis, where it forms the superior limit of the notch of the acetabulum, and to the descending ramus of the pubes; the ramus ischii fills up the lower angle of the obturator foramen. Posteriorly the ischium is thrown across the great sciatic notch, which is reduced to a narrow slit just capable of transmitting the great sciatic nerve only; the displaced bone is united to the side of the sacrum, and to the posterior inferior spine of the ilium. In this displacement the head of the femur participated, and it rested much in the position commonly assigned to it in dislocation into the sciatic notch.]

Symptoms.—The signs of this accident are generally even more obscure than those of fractures of the pubes, but in a case of doubt the bones ought not only to be carefully examined from without, but the finger should be introduced freely into the rectum and the anterior surface explored; or the tuber ischii may be grasped between the thumb and finger and moved laterally in order to determine the existence of motion or crepitus. If the patient is a female, this exploration can be best made through the vagina. By flexing and extending the thigh, also, crepitus may sometimes be discovered. The examination will generally be made while the patient lies upon his back; but if turning is not found too painful, it will be well to lay him upon his face, that the tuberosities of the ischium may be more plainly brought into view.

Prognosis.—A considerable proportion of the fractures of both the pubes and the ischium are accompanied with lesions of the bladder or of the urethra, either of which circumstances will render the prognosis very unfavorable; but in simple fractures recoveries may generally be expected, yet only after a tedious confinement.

Treatment.—It is not usual, except in cases which must almost necessarily prove fatal, to find much displacement of the fragments; nor is it probable that by any manœuvres the slight displacements which are found to exist can be entirely overcome. Instances may occur, however, in which careful pressure from without, or the introduction of a finger into the rectum or vagina, may aid in the restoration. The posture best suited to these cases will be indicated usually by the sensations of the patient himself. Ordinarily he will prefer to lie upon his back with his thighs flexed and supported by pillows; and his hips slightly elevated by a firm cushion laid under the upper part of the sacrum. His knees ought also to be gently bound together; but if the patient finds this position painful or excessively irksome, as sometimes he will, he may be permitted to occupy any position which he finds most comfortable.

§ 3. Ilium.

Fractures of the ilium are much more common than fractures of either the ischium or pubes, and they assume a great variety of forms, directions, and degrees of complication.

¹ Sir A. Cooper, by Bransby Cooper, Amer. ed., p. 140.

In the two following examples the anterior superior spinous process alone was broken off: J. K., æt. 36, was admitted to the hospital, having just fallen and broken the anterior superior spinous process of the ilium. The fragment was displaced downward about one-quarter of an inch. Motion and crepitus distinct. A slight ecchymosis existed over the point of fracture, and other signs of contusion about the hip were present. He was intoxicated at the time of the accident, and could not tell how or where he fell. He was laid upon his back in bed, with his thighs flexed upon his body; and in this position we attempted to reduce the fragment and retain it in place with a bandage; but finding this impossible, we left him with only instructions to remain quietly in bed. In about two weeks the fragment was firmly fixed in its new position, and he was allowed to get up and walk about, which he was able to do without inconvenience. M. was caught under a bank of earth. He was unable to stand upon his feet. There was a lacerated wound and an extensive bruise on his left hip; but the thigh was not shortened nor everted, and he could flex it slightly upon his body. Noticing a swelling and discoloration in the region of the anterior superior spinous process of the ilium, I pressed upon it and felt it recede with a distinct crepitus; the fragment, however, immediately resumed its place when the pressure was removed. I was able, also, by a careful manipulation, to trace the line of fracture, and to determine that it included a small portion of the anterior extremity and wing of the pelvis. We directed the patient to remain quietly upon his bed, with his legs drawn up. He soon recovered, but I am unable to say what is the present position of the fragment.

In the case of M., æt. 60, admitted to Bellevue, the fragment was displaced downward one inch, and could not, by flexion of the limb, be replaced. It was not united at the end of three weeks. The ability to move his limb was unimpaired.

More frequently, however, the fracture involves a larger portion of the crest. J. J., æt. 40, was caught by the bumpers between two cars, breaking obliquely the anterior superior portion of the ilium. I saw him within an hour, and found him greatly prostrated; the fragment of the pelvis broken off was quite movable, and crepitus was easily detected. His abdomen was very tender and slightly tympanitic. He was laid upon his back with his legs drawn up, and hot fomentations were directed to be applied to his belly. The broken ala did not seem disposed to become displaced. With no other treatment, his recovery was rapid; and the bones seemed to have united without displacement.

J. R., æt. 41, fell from a height of fourteen feet, breaking off the anterior superior portion of the right ala of the pelvis. The fragment, which was quite large, was movable, and occasionally a crepitus could be detected. It was displaced downward and forward about three-quarters of an inch. He was laid upon his back, with his thighs and limbs moderately flexed. At the end of two weeks he was able to walk without much difficulty, and he immediately left the hospital. At this time the fragment was displaced in the same manner and direction as at first, but I cannot say whether it had united or not.

In one case the fracture was caused by the muscular action. W. A., æt. 70, after riding in a railroad car about half an hour, arose to leave his seat, when he felt "something wrong" in his right groin, and found himself unable to walk without great pain. He was admitted to Bellevue Hospital on the same day, and I found a fracture involving about three inches of the ilium, including the anterior superior spinous process. It was inclined to fall outward, but was easily replaced with a distinct crepitus.

I have once seen a fracture of the posterior superior spinous process, and I do not know of any other example.

Miss B., æt. 19, was thrown from her horse backward, striking with her back upon the ground. She did not come under my care until two weeks after the accident. I found a small fragment broken from the posterior superior spinous process of the ilium, and displaced backward in the direction of the spine about half an inch. It was movable, and by pressure it could be partially restored to place, but it would immediately return to its abnormal position when the pressure was removed. The injured hip was painful, and occasionally numb.

She had previously suffered from irritation. I laid a compress behind the fragment, and secured it in place with a roller, enjoining perfect rest. She recovered from her lameness in a few weeks, but I believe the fragment remains displaced.

Prognosis.—Extensive comminuted fractures of the ilium are generally accompanied with so much injury of the pelvic viscera as to prove rapidly fatal; but the following examples will show that this rule admits of exceptions:

B. D., *æt.* 32, was crushed under a very heavy stone which fell upon his back. I found the left ala of the pelvis broken into several fragments between the different portions of which motion and crepitus were distinct. The fractures were near the superior part of the bone, commencing about two inches back of the anterior superior spinous process, and extending backward irregularly. There was a narrow wound communicating with the fracture, from which I removed a loose fragment of bone. The right leg was also broken. Four months after, he was still confined to his bed, and a fistulous opening continued opposite the point of fracture; there existed also a large and irregular mass of ossific matter or callus around the fragments. He soon after left the hospital. Dr. Sargent, of the Massachusetts General Hospital, has reported a case in which a man received a compound fracture of the left ilium, and several small fragments were removed. He was discharged at the end of three months, with a fistulous opening still remaining, but in other respects he was quite well.¹ Dr. Cheever, of the same hospital, reports a case of fracture of the ilium, with fracture of the ascending ramus of the pubes, resulting in complete recovery; but the leg became shortened and the toes inverted. Dr. Cheever believes that the lines of fracture met in the acetabulum.²

The following cases illustrate the more fatal injuries of this character:

J. O'K. was crushed under a heavy stone, breaking and comminuting the ala of the pelvis on both sides, and wounding also the iliac vein. He was taken to the hospital, and died in a few hours, partly from shock from hemorrhage. Lucas³ has also recorded two cases of lesion of this vein due to the same cause. Lente, of the New York Hospital, has reported a case of dislocation of the hip, which was accompanied with a fracture also of the ala of the pelvis upon the same side. The dislocation was reduced on the third day, and the patient soon after died. The autopsy disclosed what had not been suspected during life, namely, that the left ilium was broken horizontally about through its middle, and vertically through the crest; and also that there was a fracture extending through the sacro-iliac synchondrosis, accompanied with considerable comminution of the articular surfaces. It was found that a portion of the small intestine was ruptured, and probably by one of the sharp fragments of the broken pelvis.⁴

It is seldom, I think, that the fragments become much displaced; such, at least, has been my experience; and I have noticed in Dr. Neill's cabinet three specimens of fracture of the crest of the ilium, all of which had united without any appreciable displacement. Dr. Neill also called my attention to the fact that in two of these specimens the ensheathing callus was confined to the outer surface of the bone; an observation which, this gentleman assures me, he has had frequent occasion to make before where the fracture belonged to a flat bone. If any displacement exists, the upper or loose fragment is generally carried slightly inward; occasionally, however, it is found displaced upward, outward, or downward.

Treatment.—In a large majority of cases the fragments, if displaced,

¹ Sargent, *Boston Med. and Surg. Journ.*, vol. liii. p. 121.

² Cheever, *Boston Med. and Surg. Journ.*, May 3, 1866.

³ Lucas, *The Lancet*, 1878, vol. i. p. 147.

⁴ Lente, *New York Journ. of Med.*, Jan. 1851, p. 29.

cannot be completely replaced. Occasionally, however, as where the anterior superior spinous process is broken off with only a small portion of the crest, the fragment may be seized with the fingers and carried outward or upward, or in whatever direction may be necessary; but to retain it in this position is generally quite impossible. The bandage or broad belt which we have recommended in certain fractures of the pubes would be in these cases not only useless, but absolutely mischievous, since its effect must be to press inward the fragments, and thus to create a displacement which might not otherwise exist.

The surgeon ought to determine by a careful examination the extent and direction of the fracture, and, having done what was in his power to replace the fragments, he should lay his patient upon his back, with the thighs drawn up and supported. This is the position which will generally be found most comfortable; but, as in other fractures of the pelvis, it may be well always to try the effect of other positions, and especially to determine their influence upon the fragments, and finally to adopt that precise posture which accomplishes the indications best.

If the fracture is compound, and the fragments have penetrated the belly, the wound should be enlarged, and, as far as possible, every piece of bone should be removed; but if the fragments cannot be found, the external opening should be allowed to remain so as to favor their escape when suppuration shall have taken place.

§ 4. Acetabulum.

Although, strictly speaking, fractures of the acetabulum belong always to one or all of those bones of the pelvis whose lesions have already been described, yet the peculiar relations of this cavity to the femur render it necessary that they should be considered as a separate class of accidents.

Fractures of the acetabulum divide themselves naturally into two varieties:

First. Fractures of the base of the cavity, with or without displacement.

Second. Fractures of the rim, with or without displacement.

Fractures of the Base without Displacement.—In this species of fracture of the base of the cavity, nothing but crepitus can be present as a sign of the accident; and this will scarcely be sufficient, in itself, to enable the surgeon to distinguish it from a fracture of the neck of the femur within the capsule without displacement. It is probable, therefore, that its existence will only be determined by dissection. Nor is it of much importance that the diagnosis should be made out; since in either case neither splints nor any other surgical appliances could be of service. An injury so severe as to fracture the acetabulum will necessarily so much bruise the body, and concuss the viscera of the pelvis, as to compel the patient to remain quiet for a number of days, and this is all that would be thought necessary if the nature of the accident was exactly determined.

Dr. Neill's cabinet contains a specimen of this kind, in which the fracture, commencing near the centre, extends in three directions across the cotyloid margins, in which perfect bony union has occurred without displacement.

M. Bouvier related to the Academy the case of a man, *æt.* 71, who, in consequence of a fall from his bed, remained for three weeks unable to walk,

and never was able afterward to walk without crutches. No fracture could be discovered during life, but after his death, which occurred some months subsequent to the accident, a fracture was found extending from the ilio-pectineal eminence to the spine of the ischium, and traversing the centre of the acetabulum. The fragments were not displaced but remained slightly movable.¹

FIG. 189.

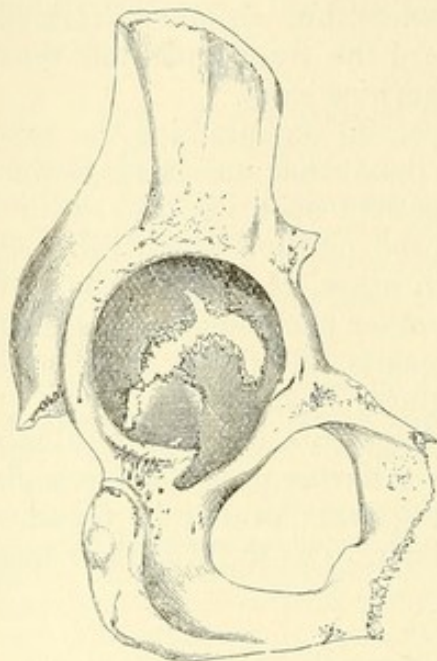
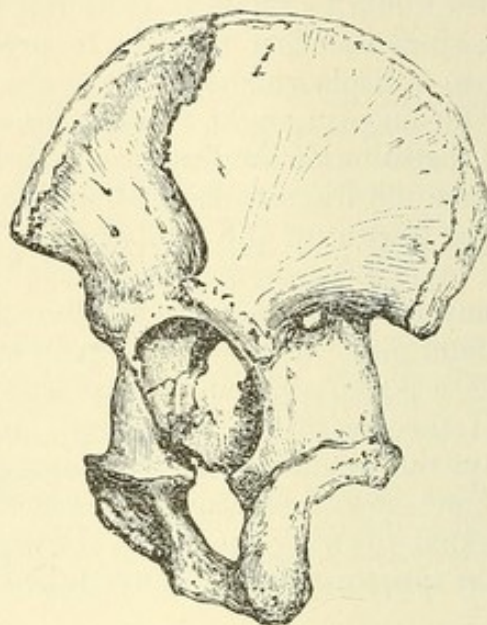


FIG. 190.

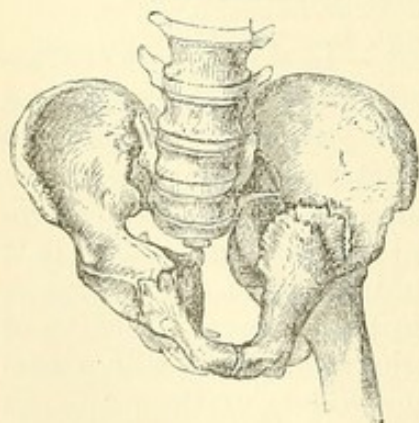


Fractures of the acetabulum.

Fractures of the Base with Displacement.—Fractures with the displacement of the femur into the pelvic cavity constitute a much more formidable, and unfortunately a more common form of accident. Like the preceding variety of acetabular fractures, they are produced generally by falls upon the trochanter major, but the force of the concussion has been greater. Even here, it is not often that the diagnosis has been

clearly made out during life; and indeed, generally, the true character of the accident has not even been suspected, the surgeons believing that they had to do with a fracture of the neck of the femur, or with a dislocation.

FIG. 191.



Head of femur driven through the acetabulum.

with a sensible crepitus. The left trochanter was very much depressed, and when it was pressed upon, the patient complained of deep-seated pain in the

In two examples mentioned by Sir Astley Cooper as having been presented at St. Thomas's Hospital, the thigh was thought to be dislocated backward.

The following case was reported by Mr. Earle: A man, æt. 40, was admitted with a severe injury, caused by having fallen from height of thirty-one feet, and striking upon the left side. The left leg was powerless and shortened. The foot was everted. Any attempt to rotate the limb caused great pain, and was accompanied

¹ Bouvier, Amer. Journ. Med. Sci., vol. xxiii. p. 486; from Bullét. de l'Acad. Roy. de Méd., August 15, 1838.

hip-joint. He recovered in eight weeks, and was able to walk nearly as well as before; he died of disease in the chest. On dissection, a fracture was found extending in two directions through the acetabulum; there was an extensive comminuted fracture of the ilium, with great displacement, and the os pubis was broken in three places. The repair was very complete, and Mr. Earle remarked how nature had guarded against any considerable deposit of new bone within the articulation, which might have interfered with the functions of the joint, while there was an abundant deposit of callus around the other parts of the fractured bone.

[Holmes,¹ of London, reports a case of fracture of the acetabulum in which the head of the femur was driven through into the pelvis, as appeared at the autopsy.]

Mr. Travers has reported two similar cases, and in the paper accompanying the report he maintains that very acute pain caused by pressing upon the projecting spine of the os pubis, and the inability of the patient to maintain the erect posture, may be regarded as signs diagnostic of the accident.² It is doubtful, however, whether these phenomena, so common to many other accidents, could be relied upon as evidence of this peculiar lesion.

[Gunn,³ of Chicago, saw a boy who was thrown from a horse, striking the trochanter against a frozen lump of earth. There was flatness of the trochanter, but free flexion and extension, also rotation, abduction, and adduction. The diagnosis was made by examination *per rectum*, when the head of the femur was felt in the cavity of the pelvis.]

In the following example reported by Lendrick, of Dublin, the patient was supposed to have a fracture of the neck of the femur: An old man was admitted into the hospital suffering from phthisis pulmonalis and acute inflammation of the hip joint. Some years before, he had received a severe injury by the upsetting of a coach, and was under treatment several months for what was supposed to be a fracture of the neck of the femur. Since that time he had been lame, but still able to take a great deal of exercise on foot both in Great Britain and in America. The acute disease of the joint commenced about two months before his admission. This man died, and the dissection showed that there had been no fracture of the femur, but its head and neck were affected with "morbus coxæ senilis." The head was also thrust through a rent in the acetabulum into the cavity of the pelvis; but the head had again been covered by a bony case, complete, except in a small portion about the size of a shilling piece, and at this point the covering was ligamentous. The os pubis had also been broken at the same time, and it had united so much overlapped that the space between the inferior anterior spinous process and the symphysis pubis was shortened nearly an inch. A portion of intestine was found protruding through an opening in the pelvis and adherent to the bone, in which situation it seemed to have been caught by the broken fragments and retained.⁴

Morel-Lavallée, in his thesis upon complicated luxations, mentions a case which had come under his observation, and which had been treated as a fracture of the neck of the femur. The patient survived the accident many years; during a part of which time he suffered such pain in the hip-joint as to induce a belief that it was itself diseased. At his death he was found to have had a multiple fracture of the bones of the pelvis, and the head of the femur had penetrated more than an inch into the cavity of the pelvis, pressing upon the obturator nerve to such a degree as to have, no doubt, caused the severe pain from which he had suffered, and which had been ascribed to coxalgia.⁵

Symptoms.—In the two cases mentioned by Sir Astley Cooper as having been received into St. Thomas's Hospital, the toes were turned in. In the example mentioned by the same author as having been presented to St. Bartholomew's Hospital, the toes were everted.

¹ Trans. Path. Soc. London, 1888.

² Travers, Holmes's System of Surgery, vol. ii. p. 478.

³ N. Y. Med. Journ., Jan. 3, 1885.

⁴ Lendrick, Amer. Journ. Med. Sci., vol: xxiv. p. 481; August, 1839; from London Med. Gazette, March, 1839.

⁵ Morel-Lavallée, from Malgaigne, op. cit., vol. ii. p. 881.

Moore has dissected a subject whose pelvis was broken into many fragments—the left os innominatum was divided into three portions, corresponding to the three bones of which it was composed in infancy; the head of the femur had completely penetrated the basin; the limb was shortened two inches, and in a position of slight flexion and adduction, but neither rotated outward nor inward.¹

There seems, therefore, to be no certain rule in relation to the position of the limb; but it is found to take the one position or the other, probably according to the direction of the force which has inflicted the injury, and perhaps in obedience to circumstances not always easily explained. The shortening has been observed to vary from half an inch to two inches or more; the trochanter is also usually driven in toward the pelvis. Pressure upon the trochanter occasions a deep-seated pain. If the limb is drawn down to the same length with the other, it immediately resumes its position when the extension is discontinued. Crepitus is more uniformly present than in fractures of the neck of the femur, and it is especially felt while the limb is being extended or while it is again shortening, and not so much in flexion or rotation.

Diagnosis.—If, in addition to these facts, we learn that the accident has occurred from a severe blow, or a fall from a great height upon the trochanter; and that the viscera of the pelvis, and especially the bladder, seem to have suffered considerable injury; or if we detect at the same time a fracture of some other portion of the pelvis—we may reasonably conclude that the head of the femur has penetrated the acetabulum. Yet it must be confessed that no one of these symptoms is positively distinctive of this accident, and that they are seldom found sufficiently grouped to render the diagnosis certain. Possibly the displacement may be detected by the finger introduced into the rectum or vagina.

The old “piper” mentioned by Lendrick, and the man dissected by Morel-Lavallée, lived many years, and managed to walk about, but not without considerable pain; the other three, to whom I have alluded, died soon after the injuries were received.

Treatment.—Some have thought of treating these cases by extension and counter-extension; the latter being accomplished through the aid of a perineal band; but it is not probable that after an injury of this character, any patient will be able to endure the requisite pressure about the perineum or groins. It will be better to lay the patient upon Daniel’s invalid bed, or some bed similarly constructed, so that it may be converted into a doubled-inclined plane; allowing the knees to be suspended over the angle thus formed, in order that the weight of the body may have some effect to draw away the pelvis from the femur. Or we may adopt extension without the perineal band, as will be described hereafter when treating of fractures of the femur; or we may resort to Hodgen’s suspension apparatus.

Fractures of the rim of the acetabulum have frequently been discovered in dissections; and the records of surgery abound with cases of unreduced dislocations of the femur, in which the failure to reduce or to retain the bone in place has been ascribed, not always with sufficient reason, perhaps, to this fracture.

¹ Moore, *Med.-Chir. Trans.*, vol. xxxiv. p. 107, 1851.

Dr. McTyer¹ published four cases of this fracture.

The first was that of a man, *æt.* 27, on whose back a number of bricks had fallen while he had his right knee placed on the bank of a trench. His right leg was found shortened about one inch and a half, bent, and the toes turned a little outward. The limb could be moved without much difficulty, but every motion gave him pain; motion was also attended with crepitus. On making extension, the limb was easily brought to the same length with the other, but it became shortened again immediately when the extension was discontinued. The symptoms, differing but little, if at all, from those which are usually present in a case of fracture of the neck of the femur, led to the supposition that this was actually the nature of the accident. Subsequently, the toes became slightly turned in, but this circumstance was not regarded as sufficiently distinctive to warrant a change in the diagnosis. Having succumbed to the injuries, the autopsy revealed a fracture extending through the bottom of the right acetabulum, and about one inch and a half of the rim at its upper and posterior margin completely detached, except as it was held in place by a portion of the capsular ligament. The head of the bone could be easily pushed upward and backward upon the dorsum, the fragment of the acetabular margin being moved aside, and swinging upon its fibrous attachment as upon a hinge, but resuming its place again perfectly when the head of the femur was restored to the acetabulum. In the second case the limb was found shortened, the knee slightly bent, and turned a little forward and inward, and the toes pointing to the tarsus of the other foot. It was thought to be a fracture also of the neck of the femur, but the autopsy disclosed only a fracture of the upper margin of the acetabulum. In the third case, seen only after death, the limb was not shortened much, but the toes were stretched downward, and turned slightly inward. It was supposed at first to be a simple dislocation, but on dissection the posterior and inferior margin of the acetabulum was found to be broken and displaced toward the coccyx, while the head of the femur rested upon the pyriformis muscle, over the ischiatic notch. The fourth was from the dissecting-room, and the history of the case is not known. A fragment of the superior and posterior margin of the acetabulum had been broken off, and had reunited slightly displaced.²

Several other similar examples have been established by dissection;³ and Dr. Nicholas Senn, of Milwaukee, Wisconsin, has collected a number of examples more or less satisfactorily demonstrated without the aid of an autopsy.⁴

The causes are generally the same as those which produce dislocations of the hip, but in most instances the violence has been greater than in the case of dislocations. In a case reported by Miner⁵ it was the result of a gunshot, the fragment having escaped through a fistulous opening.

The symptoms are, first, such as indicate a dislocation, to which must be added crepitus and a difficulty, if not impossibility, of retaining the head of the femur in its place when it is reduced. The crepitus is sometimes discovered the moment we begin to move the limb, and this will aid us to distinguish it from a fracture of the neck of the femur accompanied with much displacement, since, in the latter case, crepitus is not felt usually until the extension is complete, and the fragments are again brought into apposition.

Prognosis.—Some of these accidents, either from a failure to recognize them, or from the impossibility of maintaining the head of the femur in place when once it has been reduced, have resulted in a permanent dis-

¹ Glasgow Med. Journ., Feb. 1830.

² McTyer, Amer. Journ. Med. Sci., vol. viii. p. 517, Aug. 1831.

³ Maisonneuve, Chirurg. Clin., 1863, p. 168. Sir Astley Cooper on Disloc. and Frac., 1823, second London edition, p. 15. M. Beraud, Bulletin de la Soc. de Chir., 1862, tom. iii. p. 185. Ibid., p. 226. Bigelow on Hip-joint, 1869, p. 139 et seq. Eve, British Med. Journ., Jan. 24, 1880 (2 cases). Agnew, Treat. on Surgery, vol. i. p. 929.

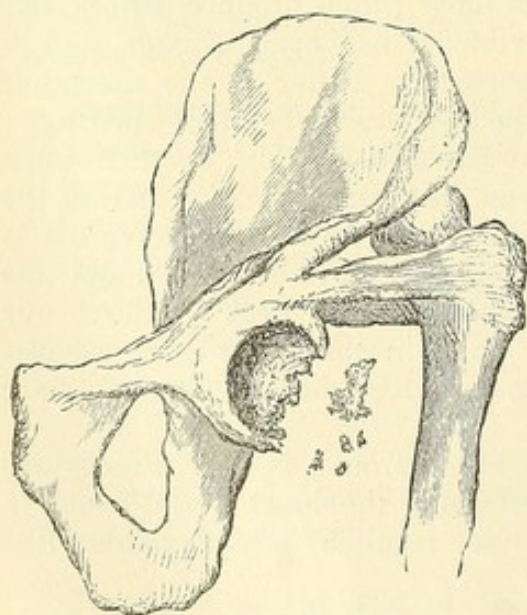
⁴ Senn, Trans. Wisconsin State Med. Soc., 1880.

⁵ Miner, Buffalo Med. and Surg. Journ., vol. v. p. 383.

location of the hip and a serious maiming. In nine out of thirteen cases which Senn has found reported, the reduction was maintained, and in four it was not. The following case was recognized and reduced, but it was found impossible to maintain the reduction :

A strong German laborer was crushed under a mass of iron weighing several tons. Drs. Sprague and Loomis, of Buffalo, were called, and found the left thigh dislocated upward and backward, and by the aid of six men they succeeded in reducing it, the reduction being attended, as the gentlemen informed me, with a slight sensation of crepitus. The legs were then laid beside each other, and the knees tied together, the patient lying on his back ; and now the two limbs appeared to be of the same length. On the second and third days the injured limb was examined by the same gentlemen, and there was no displacement. On the fourth day I was invited to meet these gentlemen, the patient having had muscular spasms during the previous night, and the thigh being redislocated. I found the limb shortened one inch and a half, adducted, and the toes turned in. We immediately applied the pulleys, and soon drew the trochanter down to a point apparently opposite the acetabulum, and a careful measurement showed that the two limbs were of the same length. The pulleys being removed, the leg did not draw up again, nor did the foot turn in, yet we had felt no sensation to indicate that the bone had slipped into its socket, nor had we felt crepitus. The legs and thighs were now laid over a double-inclined plane, and well secured. He remained in this condition three days more, during which time Dr. Sprague saw him each day, and found nothing disarranged. On the night of the seventh day the spasms returned, and in the morning the thigh was displaced. The next day we again applied the pulleys, but soon found that the bone would not remain in place one minute after the pulleys were removed. At this time, while moderate extension was being made at the foot by rotating the foot inward, we could distinctly feel a slight crepitus. A straight splint was applied, and as much extension made as he could conveniently bear, and in this condition the limb was kept several weeks. Seven years after, I found the thigh still displaced upon the dorsum ilii. He limped badly, but he could walk fast, and perform as much labor as before the accident.

FIG. 192.



Walker's case of fracture of the acetabulum.

of the femur was found in the socket, but it was easily displaced. The ligamentum teres and a greater part of the posterior half of the capsular ligament

In one case mentioned by Mr. Keate, the bone had become dislocated downward, and could be felt lying against the tuber ischii, and the presence of a "distinct grating, as of ruptured cartilage," led him to conclude that the cartilaginous labrum of the socket was broken off; but as the fracture was in the lower margin of the socket, no difficulty was experienced in retaining the bone in position.¹

Dr. Walker, of Detroit, Michigan, presented to the Detroit Academy of Medicine a specimen of this fracture, the history of which was as follows : A man, set. seventy-eight years, falling upon his hands and knees, was struck on the lower portion of his back by a passing street-car. He was taken to a hospital, and was found to have a dislocation upon the dorsum ilii. Reduction was readily accomplished, and crepitus was recognized, but its seat not fully determined. The patient died in a few hours from shock. In the autopsy the head

¹ Keate, Amer. Journ. of Med. Sci., vol. xvi. p. 225.

were torn away, leaving a part of the anterior portion, together with the ilio-femoral ligament, un torn. Some of the gluteal muscles were torn from their femoral attachments. The greater portion of the posterior lip of the acetabulum was torn away, making an opening through which the head of the femur had escaped, passing between the fasciculi of the ilio-femoral ligament, and resting finally near the crest of the ilium. Less than one-third of the normal depth of the acetabulum remained to support the head of the femur when it was in place.¹

Treatment.—If the diagnosis is satisfactorily made out, and upon complete reduction the femur will not remain in place, the treatment ought to be nearly the same as for fracture of the thigh, except that no lateral splints or bandages to the thigh will be necessary. If the straight position is chosen, the limb ought to be rotated in a direction opposite to that in which the acetabular margin is supposed to be broken, and kept drawn out to its proper length, as far as this shall be found to be practicable, by extending and counter-extending apparatus. A band around the pelvis, so adjusted as to press the head of the bone into its socket, may also be of service in preventing the tendency to displacement; and in case the bone manifests little or none of this tendency, the hip bandage will probably alone be sufficient, yet even here no harm could come of applying the extending apparatus, secured moderately tight, simply as a measure of precaution.

Dr. Bigelow recommends angular extension, effected by means of an angular splint, such, for example, as Nathan R. Smith's, or Hodgen's, suspended from the ceiling, or from some other point above the patient; "or," he adds, "if any manœuvre has reduced the bone, the limb should be retained, if possible, in the attitude which completed the manœuvre."

§ 5. Sacrum.

Causes.—Simple fractures of the sacrum, known to be rare,² are occasioned either by such injuries as break, at the same time, the other bones of the pelvis, or by blows or falls received directly upon the sacrum. It may be broken at any point, and in any direction, when the fracture is produced by the first of this class of causes; but if the fracture is the result of a fall upon the sacrum, it will generally be transverse, and below the sacro-iliac symphysis. The displacement in this latter class of cases is almost invariably the same, the coccygeal extremity being simply carried forward, yet this is seldom sufficient to interfere in any degree with the functions of the rectum and anus.

In one case seen by Bermond it nearly closed the rectum. Sometimes, also, there is a slight lateral deviation. There is also in the Dupuytren museum, at Paris, a specimen in which the whole of the lower fragment is displaced a little forward.

Symptoms.—The signs of this fracture are pain at the seat of injury, aggravated greatly in the attempts to flex or elevate the body, and especially in the efforts at defecation; swelling and discoloration of the soft

¹ Walker, *Detroit Lancet*, July, 1879.

² Malgaigne has referred to eight cases; and I have not been able to find a record of any others.

parts covering the sacrum; displacement of the coccyx forward; an angular projection at the point of fracture, with a corresponding retiring angle upon the opposite side; mobility.

Prognosis.—Experience has shown that where the fracture of the sacrum is accompanied with other fractures of the pelvis, the patients seldom recover; and only because so extensive an injury implies usually great force in the cause which produced the fractures, and, of necessity, greater lesions among the pelvic viscera. Simple fractures, from falls upon the sacrum, occurring below the sacro-iliac symphysis, are generally followed by speedy recoveries, although the inward displacement is not often completely overcome.

Treatment.—By introducing a finger into the rectum, the lower fragment can be easily pressed back to its natural position, but the difficulty consists in finding any means of retaining it there until bony union is effected. Judes succeeded to his satisfaction with a wooden cylinder, which he compelled the patient to wear forty-five days; removing it however, every third day, in order to cleanse the rectum with an enema. Bermond introduced first a linen bag, which he immediately proceeded to fill with lint; but during the night it became necessary to remove it, in order to relieve the bowels of wind and stercoraceous matter. He now substituted a silver canula covered with a shirt, which latter he filled with lint in the same manner as before. This was retained without much inconvenience nineteen days; having only been removed once during this time. The union now seemed to be firm, and the apparatus was removed. Plugging the rectum in this manner may be necessary whenever the inward inclination of the lower fragment is found to be considerable, but not otherwise; ordinarily it will be sufficient to lay the patient upon his back, with a firm cushion above the point of fracture, so as to prevent the bed from pressing in the lower fragment; and having emptied his rectum thoroughly by an enema of warm water, he should be placed under the influence of an opiate sufficiently to restrain the action of the bowels for several days, or for as long a time as may be consistent with health or comfort. To the same end, also, the diet ought to be light and dry; nothing should be allowed which might prove laxative. By constipating the bowels, two ends may be gained. We shall prevent that frequent action of the sphincters which might tend to disturb the union; and the hardened feces, by their accumulation in the rectum, may serve to press back the lower fragment of the sacrum in a manner much more natural and quite as effective as any apparatus which can be contrived.

Separations at the Sacro-iliac Symphysis.—A case of separation of the bones at the sacro-iliac symphysis, reported by Lente, was accompanied also with a fracture of the ilium and a dislocation of the hip. Several other similar examples have been reported, in some of which both of the sacro-iliac symphyses have been separated, or displaced. Such accidents are the results only of great violence, and the subjects of them seldom recover.

Dr. Banks, of Griffin, Ga., has reported one example of complete recovery in an adult male, in which the right sacro-iliac symphysis was separated "by a blow received upon the tuberosity of the ischium, driving the ilium up an inch

or more, causing complete paralysis and anæsthesia of the right leg for two or three weeks;" motion of the hip caused also severe pain. No attempt was made to reduce the bones, but union occurred, and he gradually regained the use of his limb.¹ In a few instances this articulation has been known to give way during labor, while the symphysis pubis has suffered little or no diastasis; and in these cases recovery has generally taken place.

[Perkins,² surgeon to the Union Pacific Railroad, reports a case of fracture of the sacrum occurring during labor. The line of the fracture was made out, after opening an abscess, at the sacro-iliac junction.]

In nearly all the traumatic examples reported, the diastasis has been accompanied with a fracture extending parallel with the margins of the synchondrosis; and it is for this reason that I have preferred to consider these accidents as fractures, rather than as dislocations.

§ 6. Coccyx.

The bones which compose the coccyx, four in number, develop slowly, the third not presenting an ossific nucleus until from the tenth to the fifteenth years of life, and the fourth not until between the fifteenth and twentieth year. Subsequently the first and second become united into one, and later the third and fourth are united into one; finally, the second and third unite, and the coccyx is complete as a single bone. At a late period of life, later in the female than in the male, the coccyx is united by bone to the sacrum. These facts render it apparent that a true fracture can scarcely occur until late in life; and it seems probable, also, that a diastasis or dislocation will be very unlikely to occur. For myself, I have never met with the accident in any of its forms. Malgaigne says he has seen one example of fracture in an autopsy, in which case there was also a fracture of the sacrum; and he adds that Cloquet had seen another in an old man, caused by a kick.

Treatment.—In case a fracture were to occur, the treatment would be the same as that already described for a fracture of the lower portion of the sacrum.

Dr. Mursick, of Nyack, New York, reports³ two cases of "coccygodynia," in which he practised excision of the last two bones of the coccyx successfully. One of them was a case of fracture, with forward displacement, in a woman twenty-nine years old, and was caused by a fall upon the nates. Fourteen months after the accident she came under Dr. Mursick's observation. She was suffering great pain in the pelvic region, and especially in the region of the rectum, which was aggravated by walking, defecation, and by rising from the sitting position. Dr. Mursick removed the last two bones of the coccyx by making an incision posteriorly of two inches in length, exposing the bone thoroughly, and then having seized the bone with a pair of forceps, it was drawn out and carefully dissected from its attachments. Severe pains in the pelvic region followed the operation, with retention of urine, and the wound healed slowly. As a result of his two operations he concludes that the operation is simple and easy of performance, but that the constitutional disturbance which ensues is out of all proportion to its magnitude. The subsequent pain is very severe, and lasts for several days; and the wound heals slowly.

¹ Banks, *Atlanta Med. and Surg. Journ.*, May, 1866.

² *Kansas City Med. Record*, Nov. 1888.

³ Mursick, *American Journal of the Medical Sciences*, Jan. 1876, p. 122.

Extirpation of the coccyx has been practised occasionally since the first differentiation of coccygodynia by Nott and Simpson, with successful results, but especially in those cases which were of traumatic origin. In other cases, unaccompanied with fracture or dislocation, subcutaneous incision of the attachments of the coccyx has proved sufficient, while in many cases, of purely neurotic origin, the cure has, after a time, been effected without resort to surgical interference. My own experience confirms this latter statement. Nor can I fully appreciate the necessity or advantage of resection in any case of simple fracture or diastasis of this bone. In the case related by Mursick there is no evidence furnished that union had ever taken place between the second and third portions, and the age permits a presumption that it had not, and that it was not therefore in reality a fracture; but even if it had been, what possible harm could come of its being rendered movable by the fracture, since if it were movable it could not interfere with defecation? The coccyx is not without its function, and cannot without injury be lost, inasmuch as it serves for the attachment of muscles and ligaments, most of which are of importance in connection with defecation, and occlusion of the rectum.

CHAPTER XXIX.

FRACTURES OF THE FEMUR.

THE femur constitutes an exception to the rule that in the case of the long bones the lower third is most often the seat of fracture. The shaft of the femur is most often broken in the middle third, and generally near the upper end of this third; that is to say, above its middle.

Of 236 fractures of the femur, not including gunshot, which have been recorded by me, 114 belong to the upper third, 86 to the middle third, and 36 to the lower third; or, if we confine our analysis to the shaft alone, 30 belong to the upper third, 80 to the middle, and 36 to the lower. Hyde, in an analysis of 322 cases, in Bellevue Hospital, states that 95 occurred in the upper third (including fractures of the neck), 169 in the middle third, and 38 in the lower third (including the condyles). In the 20 remaining cases the point of fracture is not stated. A summary of these tables shows that 61 fractures were in the neck, of which 14 are stated in the records to be intracapsular, 17 extracapsular, and 30 undetermined; 34 were in the upper third of the shaft, 169 in the middle third, and 31 in the lower, the exact point of fracture of the shaft being undetermined in 20; 7 fractures belonged to the condyles.¹

The femur is formed from five centres of ossification: namely, one for the shaft, commencing at about the fifth week of foetal life; one for the lower end, including the condyles, commencing at the ninth month of foetal life; one for the head, commencing at the end of the first year after birth; one for the great trochanter, commencing during the fourth year; and one for the lesser trochanter, commencing between the thirteenth and fourteenth years. None of these epiph-

¹ Hyde, Analysis of 322 cases of Fracture of the Femur, at Bellevue Hospital, from 1865 to 1873, inclusive. Medical Record, 1875.

yses are joined to the shaft until after puberty, but consolidation is generally completed at the twentieth year. The order in which union occurs is the reverse of the order in which ossification commences, the lower epiphysis being the first to exhibit traces of ossification, and the last to unite.

§ 1. Neck of the Femur.

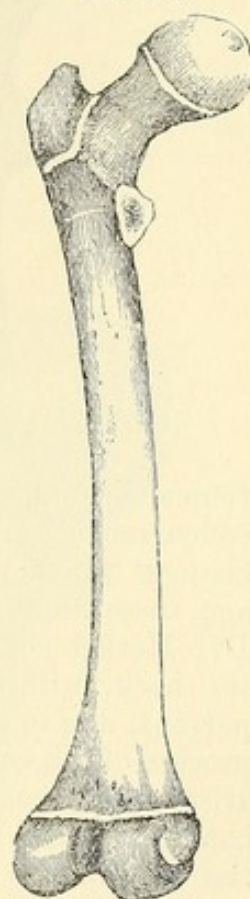
Surgeons have differed in their opinions as to the relative frequency of fractures of the neck of the femur within or without the capsule. This has arisen, no doubt, in part from the difficulty and probable inaccuracy of many of the diagnoses. Malgaigne finds in four large collections sixty-one intracapsular fractures, and only forty-two extracapsular; according to his observations, they stand in the proportion of about three to two; the intracapsular being the most common. On the contrary, Nélaton believes that extracapsular fractures are much the most common, and Bonnet, of Lyons, affirms that they constitute the immense majority. Bonnet made four dissections, and in each case he found the fracture extracapsular. This testimony, so far as it goes, is positive, but the number is not sufficient to establish anything more than a probability in favor of the greater frequency of extracapsular fractures.

Eighty-four of the whole number recorded and analyzed by myself were fractures of neck, either intra- or extra-capsular. The youngest of these patients, excepting one case of supposed epiphyseal separation, was twenty-nine years, the oldest eighty-four; forty-five were males and thirty-nine females. Nearly all were simple. Forty-two were believed to be without the capsule, and thirty were believed to be within; the remainder were undetermined.

We have already given the number of fractures of the neck, both intra- and extra-capsular, reported in Dr. Hyde's tables. Having reference to age, 19 years was the youngest, and 85 the oldest; 20 years and under presented two cases; from 20 years to 30, five cases; from 30 to 40, nine; from 40 to 50, eight; from 50 to 60, fourteen; from 60 to 70, fifteen; from 70 to 80, seven; from 80 to 90, one. Of the whole number, thirty-nine were males, and twenty-two females; none of the fractures were compound; fourteen are recorded as of the right leg; seventeen of the left; and thirty are undetermined. Fourteen were diagnosed as intracapsular, and seventeen as extracapsular, thirty being undetermined.

Clinical observations are in this case too uncertain to be made available in so nice a question. Cabinet specimens may have been collected for a special purpose, and this is well known to have been the fact with the celebrated Dupuytren collection, the specimens in which constitute nearly one-third of the whole number referred to by Malgaigne. I allude to the effort which was made while the controversy was pending between Dupuytren and Sir Astley Cooper as to the probability of bony union in intracapsular fractures, to accumulate cabinet specimens of this fracture; and which effort extended itself, no doubt, both to London and Dublin, from which two latter sources Malgaigne has gathered the remainder of his figures. In Mütter's collection there are three examples of intracapsular fracture, to seven extracapsular. Mussey, of Cincinnati, has in his cabinet twelve examples of fractures of the neck of the femur without the capsule, and only ten within. We ought, therefore, to regard the question of relative frequency as still undetermined. Nevertheless, it is my opinion that the extracapsular fracture is very much the most frequent.

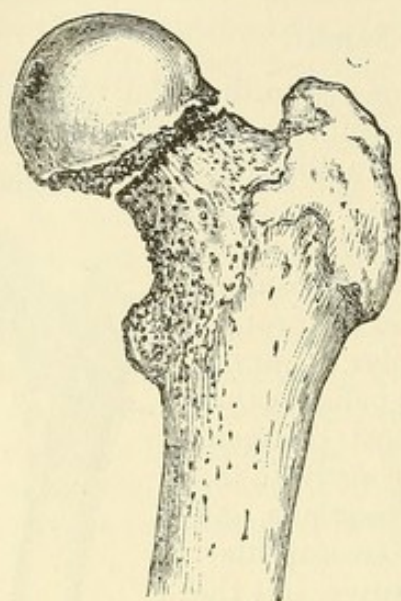
FIG. 193.



Development of femur. (From Gray.)

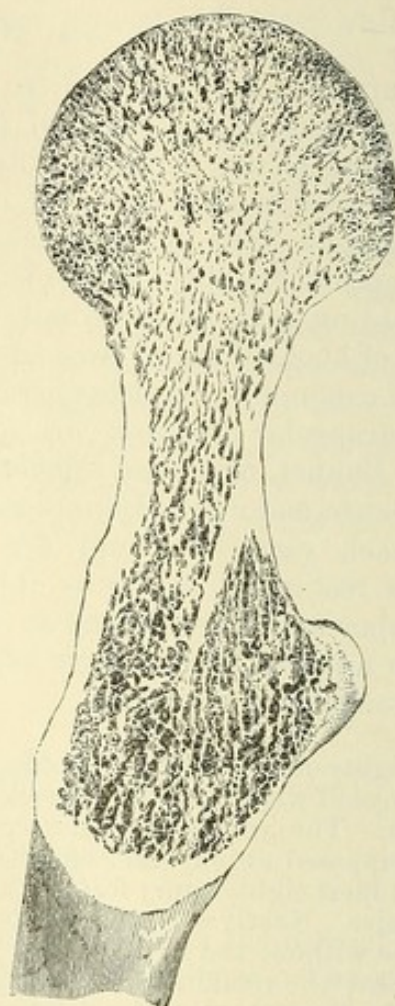
The predisposing causes of this accident to the neck play an important part in fractures whether within or without the capsule; indeed, expe-

FIG. 194.



Intracapsular fracture of the neck.

FIG. 195.

Horizontal section of neck of femur.
(From Bigelow.)

rience has shown that without the concurrence of those pathological changes which usually accompany old age, these fractures can scarcely occur. Dr. Merkel considers the fragility of the neck, within the capsule, in old persons, due to the absorption of that process of the cortical substance which arises from about the level of the trochanter minor, and ends close under the head of the bone, at the anterior part of the neck; thus occupying the situation where the greatest pressure is made in the erect position. This process he calls the "calcar femorale." In newly-born children it is absent; it appears when they begin to walk, attains its greatest development in middle age, and completely disappears in old persons.¹

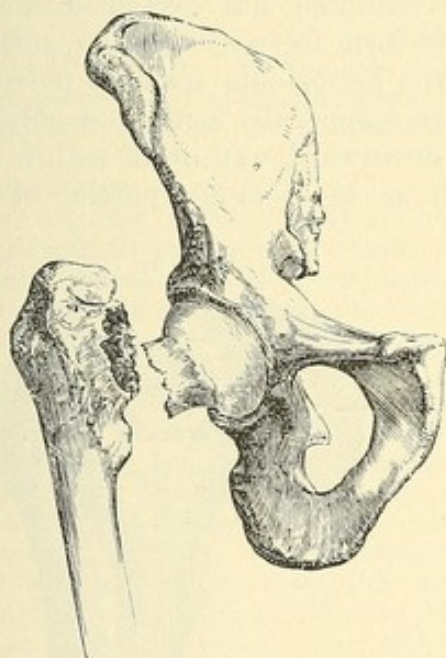
(a) Intracapsular Fractures.

Causes.—The position of the neck, and the great thickness of the muscular coverings, render its fracture from a direct blow a very rare circumstance; indeed, it can only happen as the result of gunshot accidents, or other similar penetrating injuries. It is broken, therefore, usually by indirect blows, such as a fall upon the bottom of the foot, upon the knee, or upon the trochanter major; or by muscular action alone, as has sometimes happened with very old people, who, in walking across the floor, have tripped upon the carpet, breaking the bone in the effort to save themselves.

¹ Merkel, Amer. Journ. Med. Sci., Jan. 1874.

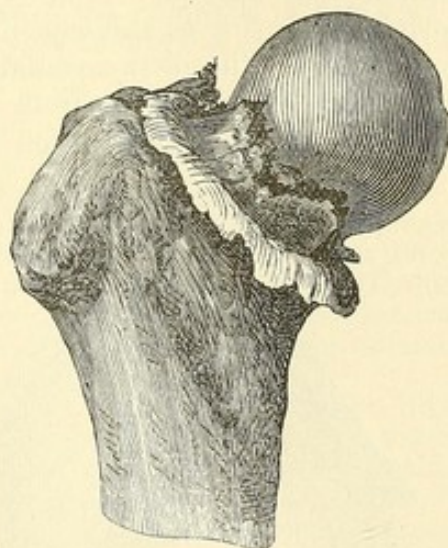We must not always infer, however, because the patient has tripped, that the bone was broken by muscular action; since it is quite as likely that the fall, consequent upon the tripping, has occasioned the fracture; and we ought in such cases to make a careful examination of the hip over the trochanter to ascertain whether it has been bruised, and to ask the patient as to the manner of the fall. Rodet has attempted to show by a series of experiments that when the person has fallen upon the foot or knee, the fracture will be intracapsular and oblique; that if the front of the trochanter receives the blow, the fracture will be intracapsular also, but transverse; if the back of the trochanter is struck, the fracture will be partly intra- and partly extra-capsular; and if the person falls directly upon the side, or receives the blow fairly upon the outer side of the trochanter, the fracture will be entirely without the capsule.¹ Without giving my unqualified assent to the propositions, I admit their general accuracy; and especially has my experience led me to believe that falls upon the feet or knees in most cases produce intracapsular fractures, and that falls upon the outside of the hip, or upon the great trochanter, generally produce extracapsular fractures. There are, however, frequent exceptions to this latter proposition. Especially have

FIG. 196.



Transverse intracapsular fracture.

FIG. 197.



Intracapsular fracture caused by a fall upon the trochanter.

I observed that in persons over fifty years of age, or somewhat advanced in life, a fall upon the trochanter has caused an intracapsular fracture. The following case, verified by an autopsy, is conclusive: A man, seventy-five years of age, was received at Bellevue. He stated that on the same day he had slipped and fallen upon the sidewalk, striking with great force upon the trochanter. The house surgeon examined the limb immediately on admission, and diagnosticated an intracapsular fracture. I saw him during the day and confirmed the diagnosis. He was feeble, but not suffering much, apparently, from shock or from pain. On the following morning he was found to be sinking, and he died before night. The accompanying illustration (Fig. 196), taken from the specimen, shows that the fracture was close to the head, and entirely intracapsular. It was not impacted, and no absorption of the neck had taken place.

Pathology.—A partial fracture, or a fissure of the neck of the femur, is possible, yet its occurrence must be regarded as an exceedingly rare and, we may say, improbable event. It is much more common to meet

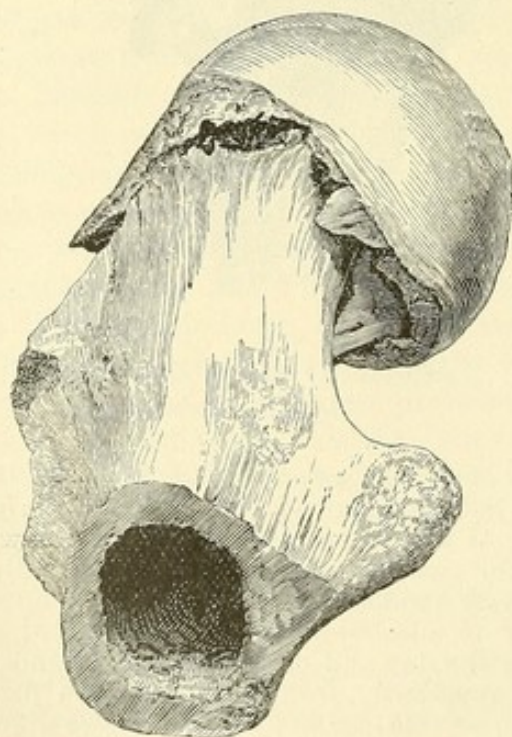
¹ L'Expérience, March 14, 1844.

with examples of complete fractures of the neck both within and without the capsule, unaccompanied with a rupture of either the periosteum or the reflected capsule.

Such was the fact in eight cases examined by Colles; in three of which, however, he believed the fracture not to have been complete, but Robert Smith thinks they were all of them examples of complete fracture.¹ Stanley has also related a case of complete separation of the bone unaccompanied with laceration or injury of either the periosteum or capsular ligament. This was in the person of a man aged sixty years, who had been knocked down in the street. On being admitted into St. Bartholomew's Hospital, shortly after the injury, he complained of pain in the hip, but there was neither shortening nor eversion of the limb, and its several motions could be executed with freedom and power. A fracture was not suspected; but five weeks after this he died of inflammation of the bowels. The dissection showed a fracture extending through the neck, accompanied with a slight bloody effusion, but no displacement of the fragments or laceration of the soft parts.²

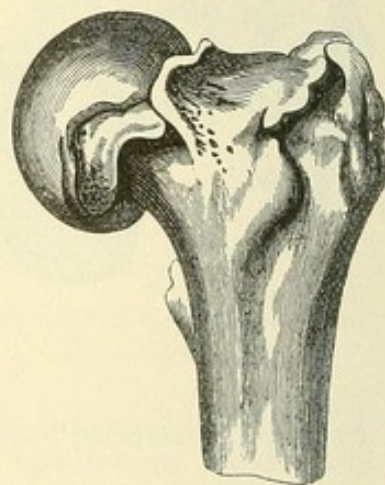
In other examples the bone is not only broken, but displaced to such an extent that the capsule is completely torn in two. But in a large majority of cases both the capsule and the periosteum are only partially torn asunder. The intracapsular fracture is generally somewhat oblique, and its direction is usually from above downward, and from within outward. Sometimes its direction is such as to include a portion of the

FIG. 198.



Impacted fracture within the capsule.
(From Bigelow.)

FIG. 199.



Impacted intracapsular fracture.
(Smith.)

head; occasionally it is quite transverse. Occasionally the intracapsular fracture is impacted. In one example of an old fracture I have seen the ends dovetailed upon each other, the fracture having a double obliquity, and not admitting of displacement.

There may occur also another species of impaction, the lower portion of the neck entering the cancellous structure of the head, while its upper

¹ Colles, Dublin Hosp. Rep., vol. ii. p. 339.

² Stanley, Med.-Chir. Trans., vol. xiii.

portion rides upon the articular surface (Fig. 198); or the impaction may occur without any degree of either upward or lateral displacement.

Separation of the epiphysis which completes the head of the femur may occur in young persons.¹

Mr. South relates a case in a boy ten years of age, who had fallen out of a first-floor window upon his left hip. The limb was slightly turned out, but scarcely at all shortened. The thigh could be readily moved in any direction without much pain, but on bending the limb and rotating it outward, a very distinct dummy sensation was frequently felt, apparently within the joint, as if one articular surface had slipped off another. This was regarded by Mr. South and Mr. Green as an example of epiphyseal separation.²

Dr. Post mentioned a case which he had seen in a girl sixteen years old, who, in taking a slight step with a child in her arms, made a false movement, and feeling something give way, she was obliged to lean against a wall. The next day the affected limb was one inch shorter than the opposite one, movable, the toes turned outward, no swelling, some slight pain at the upper part of the thigh. The trochanter major moved with the shaft. There was also crepitus. From the age of the patient, and the slight amount of violence by which the injury was produced, Dr. Post thought a separation of the epiphysis of the head had taken place. The extending apparatus was applied, but the limb remained from a quarter to half an inch shorter than its fellow.³

A. L., æt. 15, fell from the fourth story. I found his right thigh shortened three-quarters of an inch, and slightly abducted; toes everted. There was a feeble crepitus in the vicinity of the joint, unlike the crepitus of broken bone. I believe it to have been a separation of the upper epiphysis.

Only one case has been established by an autopsy. The subject of this accident, who was fifteen years old, had been run over by a wagon. The limb was shortened and everted. The patient was unable to move the limb. He died in a few hours. There was found in the autopsic examination, complete separation of the epiphysis, which was attached to the neck by a strip of periosteum two millimetres in breadth. The capsule was torn at its inner portion.⁴

Dr. Stetter⁵ has reported a case observed in a child fourteen years old, and supposed by Professor Schönborn, of Königsberg, to be caused by muscular action. The lad having slipped, threw himself backward to save himself, and fell on his left side. He experienced violent pain on the right side, and was unable to run. The right limb was found shortened three centimetres, and strongly everted. No crepitus could be detected, but there was swelling in the region of the right trochanter, and the motion of the limb produced by flexion caused intense pain.

Symptoms.—We have as yet no means of determining absolutely the symptoms of epiphyseal separation. In true fractures the limb will be shortened or not, according as the fragments are impacted or have become displaced in the direction of the axis of the shaft of the femur. If impacted, the broken ends frequently remain in contact for several hours or days, or until the gradual contraction of the muscles or the weight of the body upon the limb occasions a separation, and that consequently there is often at first no appreciable or actual shortening of the limb. To determine, however, its existence, it is not sufficient to lay the patient upon his back and place the limbs beside each other; we ought also to measure carefully with a tape-line from the pelvis to the leg or foot, and from various other points, until we have placed this question beyond a

¹ Liston, *Elements of Surgery*, Phila., 1887.

² South, note to Chelius's *Surgery*, vol. i. p. 619.

³ Post, *New York Journ. Med.*, vol. iii. p. 190, July, 1840.

⁴ *Bullet. de la Société Anat.*, 1867, p. 283.

⁵ G. Stetter, *Centralblatt für Chir.*, 1877, No. 36, S. 561.

Separation
tion of
Epiphy
sis of
head

doubt. If shortening occurs, it may vary from one-quarter of an inch to two inches, or even more; but this extreme shortening is not reached usually, except after the lapse of several weeks or months, when the ligaments have gradually given way under the weight of the body in walking, or not until the neck has undergone a partial or almost complete absorption. In a large majority of cases the shortening does not at first exceed one inch.

Sir Astley Cooper has stated that a shortening to this degree may occur at once; but Boyer, Earle, and others, doubt the accuracy of this opinion, and Robert Smith declares that he does not think the capsule would admit of such an amount of immediate displacement, unless it were extensively torn, an occurrence which he thinks very rare indeed.

Crepitus, unlike shortening, is generally absent when the displacement of the fragments is complete; but under no circumstances is it easily developed. When the fragments remain in apposition, and the femur is rotated for the purpose of moving the broken surfaces upon each other, the small acetabular fragment, resting in a smooth cup-like socket, and holding upon the opposite fragment by denticulations or by the untorn periosteum, or capsule, glides about in obedience to the motions of this latter, and no crepitus can be produced. Nor is the difficulty rendered less by pressing firmly upon the trochanter, as some surgeons have recommended, since, while this pressure tends, no doubt, to fasten the upper fragment in the acetabulum, it tends much more to fasten the broken ends together, and thus defeats the purpose in view. When, on the other hand, the fragments have become completely separated, it is almost impossible to bring them again into contact. The limb may, perhaps, be easily brought down to the same length with the other, but it must by no means be inferred that, consequently, the broken ends are in apposition. It is almost certain, indeed, that in its progress downward the trochanteric fragment has caught upon the acetabular fragment, and pushed its floating and broken extremity downward before it. Under these circumstances, the discovery of a crepitus must be accidental and is scarcely to be looked for. Sometimes, however, we may recognize a sound not unlike crepitus, but less harsh, produced by the friction of the trochanteric fragment against the rim of the acetabulum or dorsum of the ilium.

One thing we ought never to forget, namely, that by extraordinary efforts to obtain a crepitus we may lacerate the capsule or produce a displacement of the fragments which we never can remedy, and which, without such unwarrantable manipulation, might never have occurred.

[The caution here given to avoid extreme efforts to obtain crepitus lest an impacted fracture be separated should be emphasized. This is especially true of those cases where impaction is suspected. If there is but slight shortening, the foot everted, great tenderness and pain at the hip, and the patient has fallen upon the trochanter, it is better to assume that there is a fracture with impaction, and treat it accordingly, than to use any force to make the diagnosis certain. Two cases which have come under my observation have led me to commence at once the treatment of such cases as impacted fractures. The first case was an old lady who fell from a rail car upon the left hip. There was half an inch shortening, slight eversion of the foot, and great pain at the hip on moving the limb. She was seen by Dr. Parker and Dr. Van Buren, and as there was no crepitus, the diagnosis was a bruise of the hip. Two weeks after the injury,

on placing the leg over the edge of the bed, she felt the bone separate at the hip. On examination soon after, the shortening was two inches and the crepitus very pronounced. Union never occurred. The second case was seen in Bellevue Hospital, in consultation with the late Dr. Lidell. The patient was a woman, *æt.* 50, who had fallen on the hip. There was half an inch shortening, pain at the hip, but no crepitus on moderate movements of the limb. An anæsthetic was given and more determined efforts made to obtain crepitus. During these free movements the fragments separated, with abundant crepitus. Union was subsequently obtained.]

Eversion of the foot is almost uniformly present in some degree, taking place immediately or more gradually, in proportion as the fragments become displaced, and the external rotators contract. The opposite condition, or an inversion of the foot, is occasionally present, and sometimes also the foot is neither turned in nor out, but the toes point directly forward.

In sixty cases of fracture of the neck seen by Cloquet the foot was never turned in, and Boyer never met with such an example in all of his immense experience; but Langstaff, Guthrie, Stanley, Cruveilhier, Bigelow, Conklin,¹ have each seen one example, and Robert Smith has seen two.² I have myself seen one.

The explanation of the fact that the foot is usually everted is not difficult. In the case of an intracapsular fracture it is probably due, first, to the relative friability of the laminated or cortical structure on the posterior aspect of the neck, in consequence of which this portion gives way more readily than the cortical structure on the anterior aspect; second, to the natural form and position of the foot and leg, which incline them to fall outward by their own weight; and, third, to the powerful action of the external rotators, which are so feebly antagonized upon the opposite side. In the case of an extracapsular impacted fracture, in addition to the second and third causes assigned as influencing the position of the limb in intracapsular fractures, there are other special causes. The cortical lamina on the posterior aspect of the neck, everywhere more frail than upon the anterior aspect, becomes greatly weakened as it approaches the trochanter by dividing itself into two laminæ, one of which penetrates toward the centre of the bone, and the other, the thinner of the two, being scarcely thicker than a sheet of paper, forming the wall of the bone as it becomes continuous with the trochanter. This delicate papery wall easily gives way under the application of force, while the anterior wall yields only partially, constituting thus a sort of hinge upon which the rotation of the thigh is performed. It is probable, also, as suggested by M. Robert, that the angle at which the external surface of the trochanter unites with the neck increases the tendency to fracture and impaction posteriorly. An explanation of the fact already stated, that in rare and exceptional cases the limb is inverted or the toes are permitted to point directly forward, has been thought to be more difficult.

Dr. Bigelow has had an opportunity of examining a specimen taken from an old woman in the dissecting-room, and he concludes that the inversion was due to the extent of the comminution, which had separated the walls of the shaft so

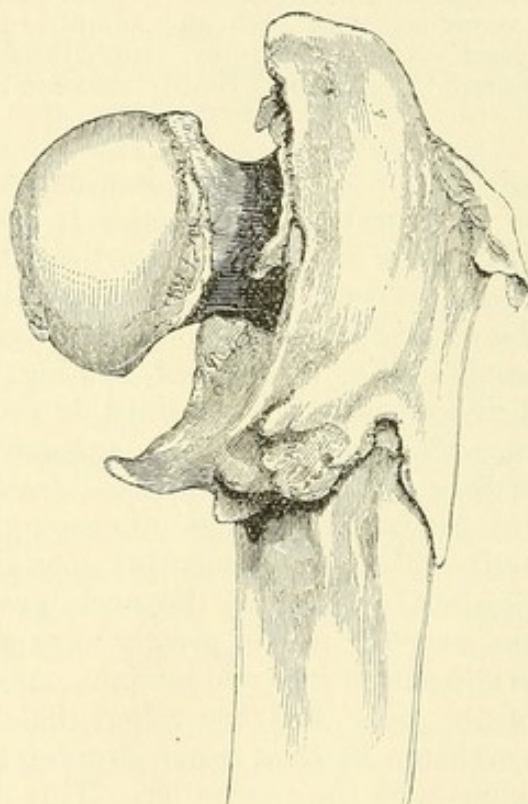
¹ W. J. Conklin, Ohio, Columbus Med. Journ., Nov. 1882.

² Robert Smith, *op. cit.*, p. 25. A. Cooper, by B. Cooper, *op. cit.*, p. 151, note.

as to receive in the interval the whole neck, instead of the posterior wall only, as commonly occurs. Dr. Robert Smith, of Dublin, cites a similar case verified by the autopsy; and Dr. Bigelow remarks that the specimen numbered 248 in the Mütter museum, at Philadelphia, presents the same kind of impaction without either inversion or eversion.

Diagnosis.—Fracture of the neck within the capsule is not usually attended with much pain when the patient is at rest, but any attempt to move the limb produces intense suffering, and especially when an attempt is made to rotate the limb inward, or to carry it upward and inward. Occasionally, also, during the first few days or hours after the fracture, a spasmodic action of the muscles compels the patient to cry out from the severity of the pain which it produces. At first the sufferer is unable to indicate clearly the seat of this pain, or, perhaps, it is diffused and un-

FIG. 200.



Extracapsular fracture, with inversion. (From Bigelow.)

certain in its position; but after a time he is able to refer it chiefly to the region of the groin, opposite the neck of the bone, or to near the point of attachment of the *psoas magnus* and *iliacus internus*. There is also usually in this region a great degree of tenderness and an unusual fulness. If now the limb be seized, and extension gradually but firmly applied, it will be soon made of the same length with the opposite thigh; but, the moment the extension is discontinued, the shortening and eversion will recur, accompanied with pain, and perhaps crepitus. The trochanter major is less prominent than upon the opposite side, and if eversion of the limb exists, the trochanter may be felt indistinctly upward and backward from its usual position. The patient having been placed under the

influence of an anæsthetic, we may prosecute the investigation still further, and by rotating the limb inward and outward as far as it will admit, we shall notice that the trochanter describes the arc of a smaller circle than in the opposite limb, or that the length of its radius has been shortened. This amount of manipulation is, however, often injurious, and seldom proper. The patient is generally unable to move his limb, or to bear the least weight upon it; but many examples are on record of persons who walked some distance after the fracture had taken place, the capsule, and perhaps also the periosteum, not being torn, and consequently the fragments not being displaced; or, possibly, it was at first an impacted fracture.

Mrs. R., of Brooklyn, was ascending a flight of steps when her limb suddenly gave way under her, in consequence of an intracapsular fracture. Mrs. R. was seventy-eight years of age, large, and rather fat. For several years she had suffered from rheumatism of the right leg, which compelled her, in walking, to bear her weight chiefly on the left, and it was this limb which gave way. She was assisted to her feet, and with the aid of her daughter ascended another flight of steps, bearing some weight on the broken leg. On the following day she got out of bed alone, and, unaided, walked a few steps, moving her limb very carefully. On the same day I saw her and found her in bed, the limb shortened half an inch and slightly everted. The head of the femur moved with the trochanter and without causing crepitus or pain. There was very little tenderness about the hip or groin; no swelling, and only a heavy, dull aching pain in the limb. The age, the manner of the accident, and the shortening of the limb were the only signs of fracture, but these were sufficient.

[McTyer¹ reported the case of a woman who, after a fall upon her side, continued to walk for three months, with but slight lameness; an abscess formed which communicated with the hip-joint; she died soon after, and the neck of the femur was found fractured.]

[Hunt, of Philadelphia, had a patient who, after being struck across the thigh, came to the hospital on the following day, walking more than a furlong. He died on the twenty-seventh day, an abscess having formed, when the neck of the femur was found broken near the head.²]

Finally, after having examined the patient as well as we are able to do, in the recumbent posture, if any doubt remains, and it is found practicable for the patient to be elevated upon his sound foot, this should be done. The broken limb can now be examined thoroughly on all sides, and a more accurate opinion formed of the amount of shortening and eversion. It will be especially noticed that if the weight of the body is allowed to rest upon the limb, in most cases it produces insupportable pain.

M. Maisonneuve has lately suggested and practised the following method of diagnosis in certain doubtful cases: Lay the patient flat on his belly, and then bring the suspected thigh into extreme extension backward. If it is not broken, the neck will strike against the posterior lip of the acetabulum and the progress of the thigh in this direction will be arrested. If it is broken, it can be carried backward much farther.³ Of this method as a means of diagnosis, it seems proper to say that, if the fragments have slid past each other and the limb is shortened, it is unnecessary; and if they are still in apposition, it will be pretty certain to cause displacement, and thus do irreparable mischief.

¹ Glasgow Med. Journ., 1881

² Phila. Med. Times, Oct. 26, 1872.

³ Maisonneuve, *Traité du Diagnos. Malad. Chir.*, par Em. Foucher, tom. i. prem. part. p. 287.

[We must again repeat that efforts to determine positively the existence of fracture in doubtful cases of injury to the hip, and especially by the production of crepitus, cannot be too strongly deprecated. Shortening and eversion are the two most reliable symptoms, both of which can be determined without manipulating the limb. If the shortening is one to two inches, with eversion or inversion, a complete fracture of the neck—the injury being to the hip—is undoubted, if there has been no previous injury or disease of the limbs. Shortening to the extent of one-half to one inch, with slight eversion, indicates fracture of the neck in healthy limbs. Shortening of less than half an inch, with eversion and other symptoms, as pain in the hip, after direct injury to the part, are sufficiently suspicious to warrant a surgeon in considering the case one of fracture. Wight,¹ of Brooklyn, says: "In a suspected fracture of the neck of the femur I examine all of the witnesses of fracture except crepitus, and if these witnesses agree substantially, I pronounce a verdict in favor of fracture of the neck of the femur; and if there is a doubt as to the correctness of such a verdict, I give the patient the benefit of that doubt by treating the case as if there was a fracture of the neck of the femur." Post,² of New York, remarks: "The surgeon, in his anxiety to obtain a perfect diagnosis, moves the limb freely in all directions; he overcomes the impaction, rupturing the cervical ligament, demonstrates beyond all doubt the existence of fracture, and effectually destroys all hope of reunion. For my part, I prefer an imperfect diagnosis for the surgeon and a perfect limb for the patient, rather than a perfect diagnosis for the surgeon and a useless limb for the patient."]

Prognosis.—The question of bony union after a complete fracture of the neck of the femur within the capsule has occupied the attention of the ablest surgeons and pathologists for a long period; and while great differences of opinion have been expressed as to the probability of the occurrence, and as to the value of the testimony on the one side or the other, very few have ventured to deny its possibility.

Among these latter are found, however, the distinguished names of Cruveilhier, Colles, Lonsdale, and Bransby Cooper. It has been repeatedly affirmed, also, that Sir Astley Cooper taught the same doctrine, but with how much show of reason, the following paragraphs from his own pen will determine:

"I find in a report of the Baron Dupuytren's lecture that he attributes to me the opinion that fractures of the neck of the thigh-bone, within the capsular ligament, not only 'never unite, but that it is impossible that they should unite by bone.' It is quite true that, as a general principle, I believe that those fractures unite by ligament, and not by bone, as do those of the patella and olecranon. But I deny that I have ever stated the impossibility of their ossific union; on the contrary, I have given the reason why they may occasionally unite by bone. The following are my words: 'To deny the possibility of their union, and to maintain that no exception to this general rule may take place, would be presumptuous,'"³ etc.

Sir Astley, then, so far from denying, frankly admitted the possibility of bony union when the neck was broken within the capsule. The true point in dispute was, whether certain cabinet specimens were actually examples of complete fractures, wholly within the capsule, united by bone. Some of them, Sir Astley thought, were only examples of chronic rheumatic arthritis, or of interstitial and progressive absorption. Some were partial rather than complete fractures; others were partly within and partly without the capsule. The truth is, however, that although the claim has been set up and stoutly maintained for more than thirty cabinet specimens, in one part of the world or another, a majority of these, including several whose claims were urged upon Sir Astley, have been at length declared by all parties unsatisfactory, or absolutely fictitious, and only a fraction of the whole number continue to be mentioned by any surgical writer

¹ Proceedings Med. Soc. of the County of Kings, 1881.

² Trans. Amer. Surg. Assoc., 1883.

³ Lond. Med. Gaz., 1834.

as probable examples.¹ Robert Smith reduces the number to seven, but Malgaigne recognizes only three. Six of the nineteen cases which I have enumerated are declared by him to resemble much more rhachitic alterations of the neck than true fractures.

On this side of the Atlantic, the number of specimens for which the honor is claimed is nearly equal to the original number in Europe; but they have not yet, all of them, been subjected to the same sifting process as their foreign congeners; and it remains to be seen how many of them will come successfully out of a similar fifty years' contest. Dr. Packard, of Philadelphia, has published an excellent critical notice of most or all of the published cases, and suggests that they all admit of the following explanation: The fractures were actually extracapsular; but, after union took place, that portion of the neck attached to the head underwent absorption, until the head was brought into contact with the trochanters.

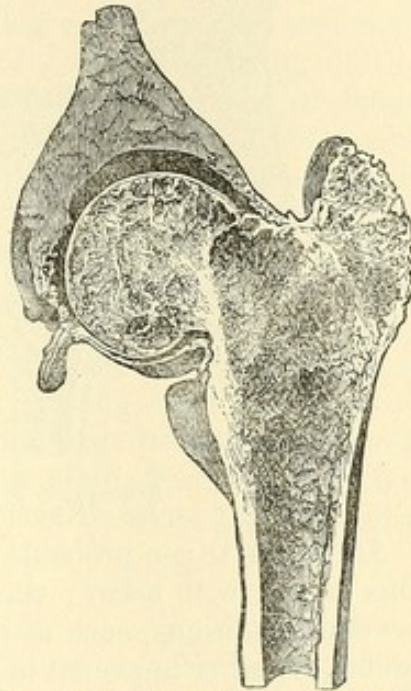
I have also in my own cabinet a femur of no inconsiderable pretensions (Fig. 201), belonging clearly to that class of specimens recognized by Robert Smith. Its neck is greatly shortened, and this surgeon would regard it, I think, as an impacted intracapsular fracture, but its claim would be promptly denied by Malgaigne, on account of the absorption and distortion of its neck.

Dr. George K. Smith, of the Long Island College Hospital, has made a most valuable contribution to our knowledge of the anatomy and pathology of the hip-joint, which will explain in a great measure the discrepancies of opinion which at present exist among surgeons as to the character of certain specimens, and may hereafter enable us to decide with more accuracy, and may lead to a better agreement of opinion.

His observations prove that anatomists have not hitherto correctly described the attachment of the capsule; that the capsule is seldom, if ever, attached at the same point in different persons, while it is as uniformly found attached at the same point in the opposite femurs of the same person. In order, therefore, to determine whether the line of fracture in any given specimen was without or within the capsule, we must always compare the fractured bone with its congener, and not with the femur of another person.

He has further shown that after a fracture, and the consequent absorption of the neck, the normal position of the capsule is almost constantly changed; so that its present attachment does not declare what were the points of its attachment before the fracture occurred; and, finally, that the absorption proceeds unequally and irregularly, yet with great rapidity, in the two fragments; and as

FIG. 201.



Vertical section of Mrs. Wakelee's femur, acetabulum, and capsule.

¹ The following European surgeons have claimed to have in their possession, each, one example: Langstaff (*Med.-Chir. Trans.*, vol. xiii., 1827); Brulatour, *Ibid.*, vol. xiii., 1827); Stanley (*Ibid.*, xviii.); Swan (*Swan on Diseases of Nerves*, p. 304); Adams (*Todd's Cyclop.*, p. 813); Jones (*Med.-Chir. Trans.*, vol. xxiv.); Chorley (*Amesbury on Frac.*, p. 125); Field (*Ibid.*, p. 128); Soemmering (*Chelius's Surgery by South*, vol. i. p. 621); South (*Ibid.*, p. 621). South also mentions another example as being in the museum of St. Bartholomew's Hospital. This is probably Jones's case, which Robert Smith says is preserved in this museum, and which has already been enumerated. Bryant (*Memphis Med. Rec.*, vol. vi. p. 108, from *British Med. Journ.*, March 14); Fawcington (*Amer. Journ. Med. Sci.*, vol. xv. p. 534, from *London Med. Gaz.*, Aug. 16, 1834); Harris (*Ibid.*, vol. xviii. p. 246, from *Dublin Journ.*, Sept. 1835). Robert Hamilton says that Prof Tilanus showed him three specimens in the museum of the Hospital of St. Peter, at Amsterdam (*Ibid.*, vol. xxxi. 470, from *Lond. Med. Gaz.*, Jan. 6, 1843). Malgaigne says there are three specimens in the Dupuytren museum which have been described with the same interpretation. The whole number claimed by transatlantic surgeons is therefore nineteen.

the bony union, if it ever takes place, probably occurs subsequent to the arrest of the absorption, the line of union cannot in itself alone determine whether the fracture was near the head or near the trochanters.¹

[Bryant, of London, has illustrated these changes. (Figs. 202, 203.)]

FIG. 202.

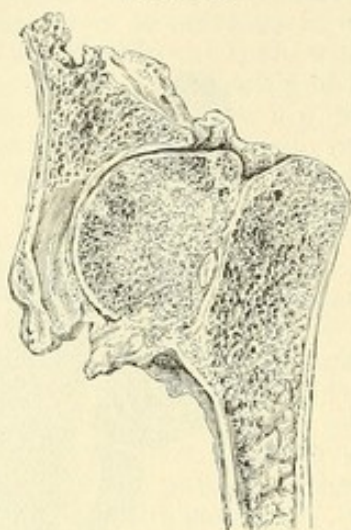
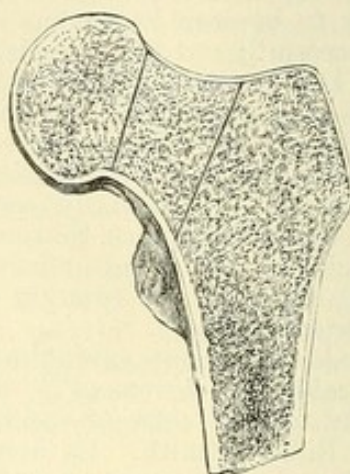


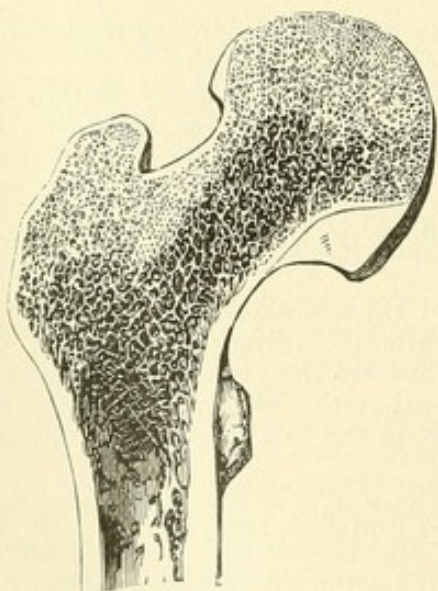
FIG. 203.



Absorption of the neck after fracture. (Bryant.)

It seems to me probable that, under certain favorable circumstances, this union will occur; these favorable circumstances have relation to several conditions, such as age, health, degree of separation of the fragments, whether impacted or not, laceration of the periosteum and capsule, treatment, etc. But such a combination

FIG. 204.



Section of a sound adult femur.

of circumstances is probably exceedingly rare; and, what is more unfortunate, if they exist, the fracture is not likely to be recognized, and the surgeon will fail to avail himself of those advantageous coincidences which might, if understood and properly treated, secure a bony union. There will not be wanting, however, examples in which surgeons will believe or affirm that they have recognized the fracture and wrought the cure.

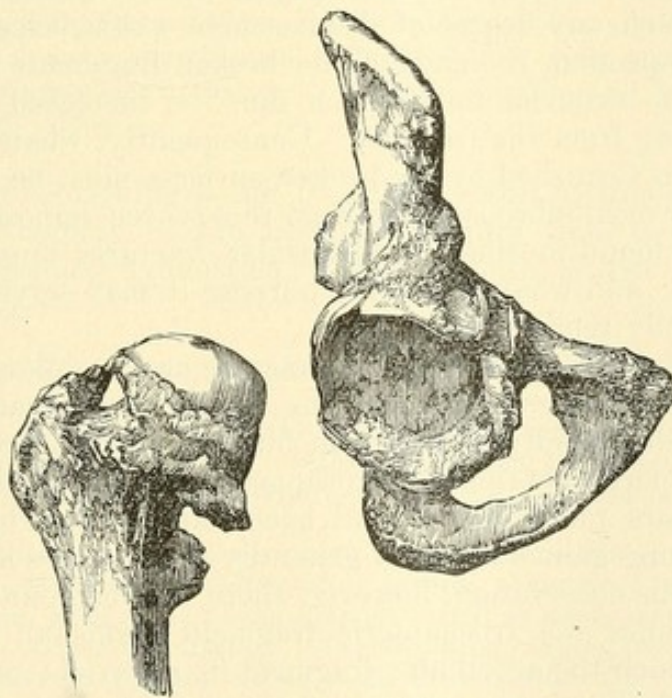
These fractures may be confounded with several pathological conditions, but it will be sufficient to allude to what has been variously termed "morbus coxæ senilis" (Robert Smith); "chronic rheumatic arthritis" (Adams); "interstitial absorption of the neck of the "thigh-bone" (B. Bell); "rheumatic gout"

(Fuller); and by others "*dry arthritis*," "interstitial and progressive absorption." We shall, perhaps, find a partial explanation of this diversity and frequency in one single circumstance, namely, the peculiar ana-

¹ George K. Smith, Insertion of the capsular ligament of the hip-joint, and its relation to intracapsular fracture. Medical and Surgical Reporter, Philadelphia, 1862.

tomical structure of the neck. The neck of the femur stands nearly at a right angle with the shaft, or at an angle so great as that the weight of the body, even in health, has the effect to depress gradually the head below the top of the trochanter major, and to diminish its length. This is seen constantly in the striking change of form which occurs between childhood and old age. Now, if from any cause whatever, such as a blow upon the trochanter or upon the foot, the neck or head is made to suffer; and inflammation, or, perhaps, only a slight degree of increased action in the absorbents, ensues, resulting in an equally slight softening of the bony tissue, these pathological circumstances may end, sooner or later, in a striking change of form in the neck or head. But it is not necessary to suppose an external injury to explain the occurrence of this inflammation, and consequent softening of the bone; a scrofulous, or rickety, or tuberculous constitution may occasion it, and we see no reason why these conditions are not as likely to lead to a change of form here as in the bones of the leg or of the spine. A change of form in the head may be the result of an ulceration of the cartilage; and a change of form in the neck, of ulceration of the neck. Among other causes, also, "chronic rheumatic arthritis" may operate in a large proportion of those examples which belong to advanced life. It is plain, from the direction which the deviation of the head and neck usually takes, that pressure performs an important part in the causation.

FIG. 205.



Chronic rheumatic arthritis. (Miller.)

From these various causes, operating in these diverse ways, we shall have the different deformities enumerated and described by surgical writers. The head flattened, irregularly spread out, depressed, and polished; the neck shortened and irregularly thickened and expanded; the trochanter major rotated outward and drawn upward; sinuous chasms traversing the neck, produced by ulceration; and finally, short-

ening of the neck, by a true interstitial absorption, and with little or no increase in its breadth, the trochanter major also being rotated outward. It would be strange, moreover, if the interior of these bones did not present some changes in structure, such as have been frequently observed, namely, an irregular expansion or condensation of the cellular tissue, and which latter might easily be supposed, by one who was inattentive to all of these circumstances, to indicate the line of an imaginary fracture.

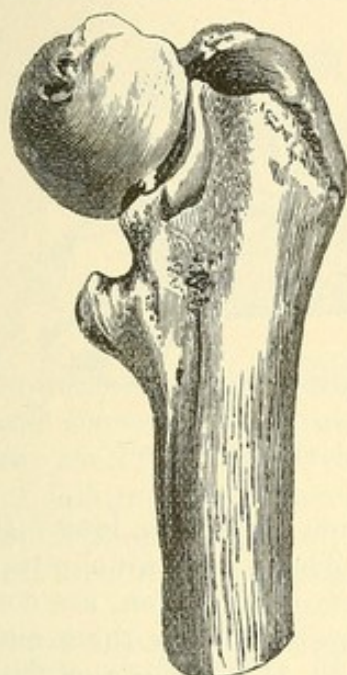
The chief difficulties in the way of union by bone within the capsule are as follows: The persons to whom the accident occurs are generally advanced in life, and consequently the process of repair is feeble and slow. The head of the bone receives its supply of blood chiefly through the neck and reflected capsule, and, when both are severed, the small amount furnished by the round ligament is found to be insufficient. When the fragments are once displaced, it is difficult, as I have already explained, if not impossible, to replace them. The direction of the fracture is generally such, that the ends of the fragments do not properly support and sustain each other when they are in apposition. The fracture is at a point where the most powerful muscles of the body, acting with great advantage, tend to displace the broken ends. Aged persons, who are chiefly the subjects of this accident, do not bear well the necessary confinement, and especially as the union requires generally a longer time than the union of any other fracture; so that a persistence in the attempt to confine the patient the requisite time often causes death. In all cases in which any degree of displacement exists, except it be in the direction of impaction, the ends of the broken fragments are constantly bathed with the synovial fluid, which must be increased by the inflammation resulting from the fracture. Consequently, whatever reparative bony material is furnished by the broken surfaces must be lost, rendering bony union, or even fibrous union from this source impossible. Lastly, there is never found in these intracapsular fractures anything like provisional callus; and whatever useful purpose it may serve in other fractures, it certainly renders no aid here.

The most common results of this fracture are as follows: The bones, more or less displaced, undergo various changes. The acetabular fragment is generally rapidly absorbed as far as the head; and occasionally a considerable portion of this latter disappears also; while the trochanteric fragment appears rather as if it had been flattened out by pressure and friction, it having gained as much generally in thickness as it has lost in length. To this observation, however, there will be found many exceptions. Sometimes the trochanteric fragment forms an open, shallow socket, into which the acetabular fragment is received; or its extremity may be irregularly convex and concave, to correspond with an exactly opposite condition of the acetabular fragment. (Fig. 206.)

Ordinarily the two fragments move upon each other, without the intervention of any substance; but often they become united, more or less completely, by fibrous bands (Fig. 207), which bands may be short or long, according to the amount of motion which has been maintained between the fragments while they are forming, or to the degree of separation which exists. The capsular ligaments are usually considerably

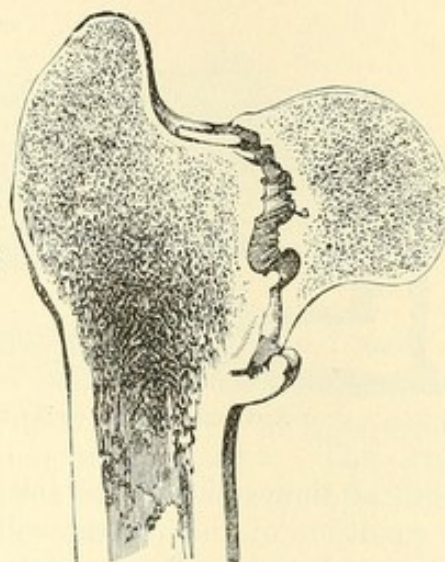
thickened, and elongated in certain directions, and not unfrequently penetrated by spicula of bone. They are also found sometimes attached by firm bands to the acetabular fragment.

FIG. 206.



Intracapsular fracture. Ununited. Opposite surfaces irregularly convex and concave, and polished; moving slightly upon each other. (From a specimen in the possession of Dr. Josiah Crosby.)

FIG. 207.



Mayo's specimen. United by ligament. Patient lived nine months after the accident. The trochanter minor arrested the descent of the head. (From Sir A. Cooper.)

A permanent shortening is the invariable result of this accident; and a few succumb rapidly to the injury, perishing from a low, irritative fever, or from gradual exhaustion, within a month or two from the time of its occurrence.

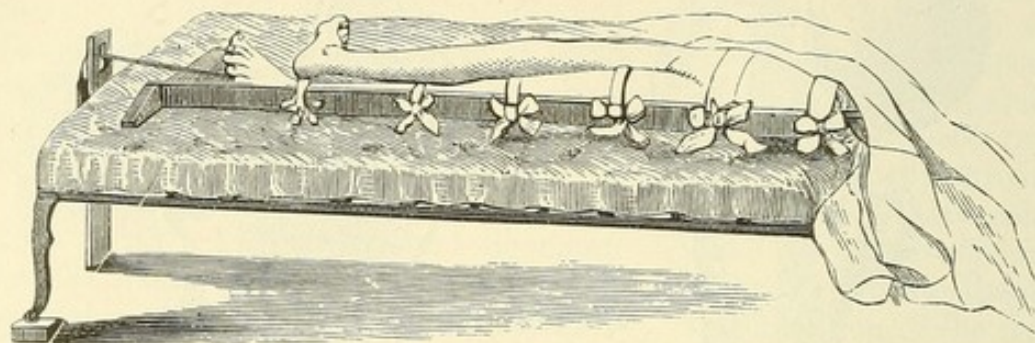
Says Robert Smith: "Our prognosis, in cases of fracture of the neck of the femur, must always be unfavorable. In many instances the injury soon proves fatal, and in all the functions of the limb are forever impaired; no matter whether the fracture has taken place within or external to the capsule—whether it has united by ligament or bone—shortening of the limb and lameness are the inevitable results."

Dr. Hyde, of this city, has made a very careful examination of twenty cases of fracture of the neck of the femur, after several years from the date of the fracture. Thirteen of these had been diagnosticated as intracapsular, and seven as extracapsular. All were shortened; the shortening ranging from three-eighths of an inch to two and a quarter inches in the intracapsular fractures; and from one-quarter to one and a half inches in the extracapsular. Some of the cases had never been treated by apparatus of any kind, and it was observed that, omitting one case in which the contracted position of the limb did not permit an accurate measurement, the average shortening was one and three-eighths of an inch; while in those which had been treated as fractures, the average shortening was about one inch. All, or nearly all of them, were still suffering with more or less pain and stiffness about the joint, and walked with a manifest halt.¹

¹ Hyde, Deformity after Fracture of the Neck of the Femur; 20 cases, arranged and tabulated. Med. Gazette, April 17, 1880, p. 244.

Treatment.—The treatment is as follows: In case of a complete fracture within the capsule, existing without laceration of the reflected capsule, or displacement of the fragments, and equally in case of a fracture at the same point with impaction, the treatment ought to be directed to the retention of the bone in place, by suitable mechanical means, for a

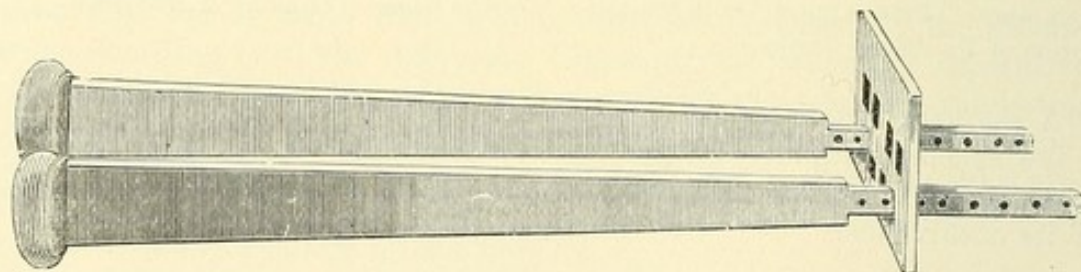
FIG. 208.



Author's apparatus for fractures of the neck of the femur.

length of time sufficient to insure bony union, or for so long a time as the condition of the patient will warrant. The means which are, in my judgment best calculated to fulfil this important indication, are complete rest in the horizontal posture, the limb being secured by the same apparatus which we employ with so much success in fractures of the shaft. In fractures of the neck, however, whether within or without the capsule,

FIG. 209.



Gibson's modification of Hagedorn's splint.

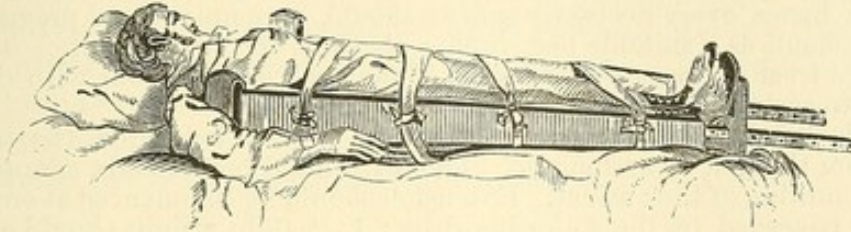
we employ no coaptation splints; and the amount of extension ought to be only one-half of that generally employed in fracture of the shaft, say about ten pounds. The long side-splint, with a foot-board, to prevent eversion of the limb, must not be omitted.

Another apparatus is Gibson's modification of Hagedorn's, in which the sound limb is first secured to the foot-board, and the broken limb is subsequently brought down to the same point. By this method, as by my own apparatus, we may avoid the necessity of a perineal band, which is so painful, insupportable often when the fracture is at the neck.

In treating this fracture, supposing no displacement to exist, no extension beyond that which is necessary to insure perfect quiet can be proper, inasmuch as the fragments are not overlapped; and they need only a moderate assistance to enable them to maintain their present position against the action of the muscles. Moreover, if the fragments are im-

pacted, violent extension would disengage them, and render their displacement and non-union inevitable. How long the patient will submit to this, or to any other mode of securing perfect rest, is very uncertain,

FIG. 210.



Gibson's modified splint applied.

and the decision of this question must rest with the individual cases and the good sense of the surgeon. Not very many old and feeble people will bear such confinement many days without presenting such palpable signs of failure as to demand their complete abandonment. The careful and judicious application of splints, long continued, and employed under the most favorable circumstances, will sometimes fail.

In the practice of Dr. James R. Wood, a girl, *æt.* 16 years, of vigorous constitution, perfectly free from any constitutional taint, either of scrofula, syphilis, or cancer, was caught between the wheels of two carriages, the one stationary, the other in motion. The blow was received directly on the trochanter major of the right side. The symptoms which presented themselves showed conclusively that there was a fracture. There were shortening, loss of voluntary motion, and eversion; by placing the finger on the trochanter major, and the thumb on the groin, a well-marked crepitus could be felt on extension and rotation being made. There was no laceration or other complication of the injury. She was placed on Amesbury's splint, with side-splints accurately adjusted, and every precaution taken to insure a perfect union. The limb was kept on this splint without being disturbed for six weeks. At the end of that time it was taken from the splint, and examined with care; the signs of fracture still remained. The limb was replaced on the splint, and the dressings applied as before; everything was attended to in the general management of the case which the doctor thought would be conducive to perfect union. The patient was kept for three weeks longer on the splint, which was then removed. It was found that there was no union. At the expiration of three years she died of an acute disease. It was found that there had been a transverse fracture of the bone just at the junction of the head and neck. The head of the bone was still attached to the acetabulum by the ligamentum teres. The process of absorption had been going on, and the head of the bone had already been absorbed below the level of the acetabulum, and what remained was soft and spongy, easily broken with the handle of the scalpel. The neck of the bone was rounded off, and covered with a fibrous deposit. This was not a case of diastasis.

The reasons why I would prefer my own plan have already been stated in part, to which I will now add, that if an error should occur in the diagnosis—if it should prove finally to have been a fracture without the capsule—then this treatment would be correct, and no injury would come to the patient from the error in diagnosis; but if we adopt Sir Astley Cooper's suggestion, namely, to get the patient upon crutches as soon as possible, perhaps as early as fourteen days, an error in diagnosis might be followed by the most disastrous consequences.

[The treatment of fractures of the neck of the femur is still too much governed by the opinions of the authorities of the past, who held that bony union in intra-capsular fractures is impossible, or so doubtful that old people should not be

subjected to the necessary confinement. There is now abundant evidence that intracapsular fractures, properly treated from the first, may unite by bone; and there is still more evidence that, owing to the difficulty of differentially diagnosing intra- and extra-capsular fractures, many patients fail of correct treatment, and, as a consequence, remain cripples for life. Nor should too much stress be laid on the popular opinion that old people cannot bear confinement. The ability of the aged to bear confinement depends altogether upon the care given them, and hence every necessary means should be employed to prevent injury by confinement, as a suitable bed, rubber air-rings for the hips, etc. The wiser course is to treat every case of fracture of the neck of the femur with the determination to secure union if possible.

The rule being that every case should be treated for union, the treatment should from the first be systematic. The bed should be perfectly adapted to the age and condition of the patient. Extension should be commenced at once, but it should be governed by the following rules: 1. A light weight should at first be used, as one to four pounds; 2. If the diagnosis is impaction, this weight should be but little, if any, increased, the object being simply to counteract the muscles; 3. If there is proof of complete fracture the weight should be increased from day to day until the shortening is overcome, or as nearly as possible within one week; 4. During this time the limb may be supported laterally by sand-bags; 5. At the end of a week permanent dressings should be applied; if the fracture is impacted, a firm bandage extending from the waist to the upper part of the thigh, tightly fastened by pins or tapes, will serve to keep the fragments in apposition; if not impacted, and the patient is old, this dressing may be sufficient, but with younger and more restless patients a long splint, extending from the waist to the foot, will give better support, the splint being well padded and held in place by bandages around the body above, and around the limb below; 6. In hospital practice, and in the hands of those familiar with immobile dressings, the plaster-of-Paris or silicate appliance is preferable. The patient should not be too early released from the dressings. The limit of time required for a cure sufficient to bear the weight of the body is scarcely less than six months.]

In gunshot intracapsular fractures, if suppuration ensues, the head of the bone and other fragments ought to be removed; and there may occur cases in which the fragments should be removed immediately, as has been done occasionally with satisfactory results. So, also, if after a simple intracapsular fracture, suppuration within the joint were to ensue, resection would be the proper resort.

(b) Extracapsular Fracture.

Like fractures within the capsule, these also occur most frequently in advanced life. They are not, however, as often met with in extreme old age as are fractures within the capsule; and they are much more often met with in persons of middle age, and in younger persons, than are intracapsular fractures.

Of fractures recognized as extracapsular, in Dr. Hyde's tables, ten were under fifty years, and seven at or over fifty. The three youngest were respectively thirty, twenty-five, and twenty years of age. Of the 42 recorded by me as extracapsular fractures, I have made no careful tabulation of the ages, but it is certain that in general they belong to a younger class of persons than the cases recorded as intracapsular.

Causes.—As to the immediate causes, fractures without the capsule seem to be the result generally of falls or of blows received directly upon the trochanter; occasionally, also, they are produced by falls upon the feet or upon the knees.

Pathology.—These fractures may occur at any point external to the capsule, but generally the line of fracture is at the base, corresponding very nearly with the anterior and posterior intertrochanteric crests. Almost invariably the acetabular penetrates the trochanteric fragment in such a manner as to split the latter into two or more pieces. The direction of the lesions in the outer fragments preserves also a remarkable uniformity; the trochanter major being usually divided from near the centre of its summit, obliquely downward and forward toward its base, and the line of fracture terminating a little short of the trochanter minor, or penetrating beneath its base; while one or two lines of fracture usually traverse the trochanter major horizontally.

In an examination of more than thirty specimens, I have noticed but two or three exceptions to the general rules above stated. In Mütter's collection, specimen B 115 is not accompanied with either impaction or splitting of the trochanteric fragment; but the neck, having been broken close to the intertrochanteric lines, has, apparently, slid down upon the shaft about one inch, at which point it is firmly united by bone. Dr. Neill has also a specimen of fracture at the same point, but without union of any kind, in which no traces remain of a fracture of the trochanters. The acetabular fragment has moved up and down upon the trochanteric until it has worn for itself a shallow socket three inches and a half long, the approximate surfaces being smooth and polished like ivory.

The trochanter major is usually turned backward, the shaft of the femur being rotated in this direction, the same as is usually observed in other fractures of the neck of the femur.

I have seen one exception to this general rule in a specimen belonging to Mütter (No. 29); the trochanter in this instance is turned forward, so that the neck is shorter in front than behind.

The upper fragments of the trochanter major, whenever the lines of fracture are transverse, are generally inclined inward toward the neck, as if displaced in this direction by the force of the blow, or perhaps by the resistance offered by certain muscles and ligamentous bands which find an insertion upon its summit. The neck is found, in most cases, standing inward at nearly a right angle with the shaft, the head being much more depressed than the outer extremity of the neck; in consequence of which the lower margin of its broken extremity is driven much deeper into the trochanteric fragment than is the upper margin.

Malgaigne believes that impaction, with consequent fracture of the trochanters, is never absent in true extracapsular fractures, unless it be in that very unusual variety in which the trochanter forms a part of the inner fragment (fractures through the trochanter major and base of the neck). Robert Smith entertains the same opinion. I cannot agree, however, with either of these gentlemen that the rule is so invariable.

It is certain that impaction and comminution of the outer fragment are very constant, and that, whether the fracture is produced by a fall upon the feet or upon the trochanter major. But the impaction does not necessarily continue; sometimes, indeed, it does, and the position of the limb, whatever it may be at the moment, remains unalterably fixed; either very little or considerably shortened, according to the degree of

impaction; rotated outward or inward, or in neither direction, perhaps, according to the direction of the force and the amount of comminution. In other cases, owing to the extreme comminution, and to the wide separation of the trochanteric fragments, or to the contraction of the muscles inserted into the top of the femur, or to the weight of the body in attempts to walk, or to injudicious handling on the part of the surgeon, such as forcible rotation, by which the neck is made to act as a lever, and actually to pry the fragments apart, or to violent extension, by which the impaction is overcome—owing to some one or several of these causes it often happens that the fragments separate, and the leg becomes immediately more shortened, movable, and more inclined to rotate outward.

FIG. 211.

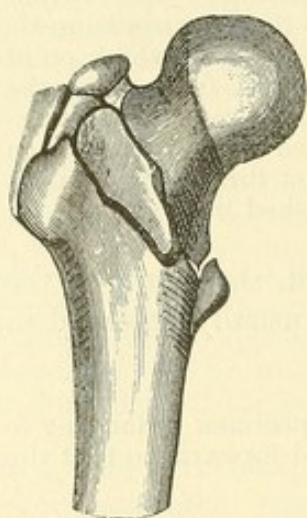


FIG. 212.

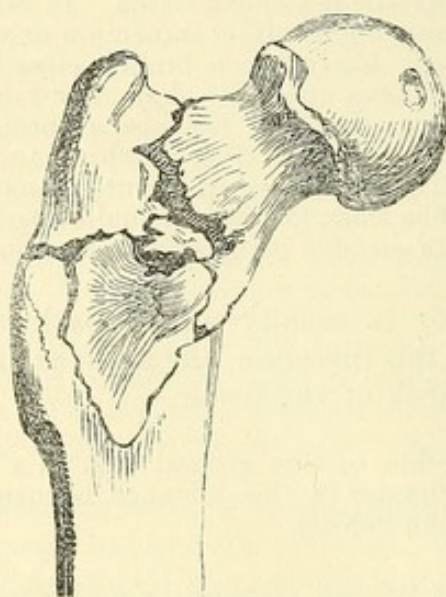
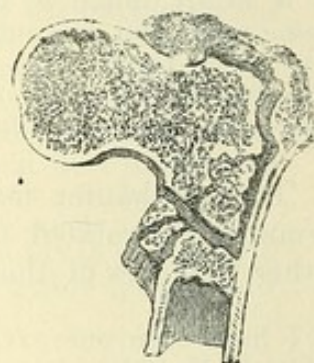


FIG. 213.



Impacted extracapsular fractures. (R. Smith, and Erichsen.)

Symptoms.—The symptoms which indicate a fracture of the neck of the femur without the capsule are pain, mobility, crepitus, shortening, and eversion of the limb. The trochanter major is not as prominent as upon the opposite side; and especially where the fragments are not impacted, but are completely separated, it rotates upon a shorter axis. There are also several other signs to which I shall refer when considering the differential diagnosis.

Before considering more in detail the value of these several signs, I wish to call attention to a fact which has been often observed by myself and others, namely, that the patient is able, sometimes, immediately after this accident, to take a few steps; yet never, perhaps, without considerable pain. The same may happen in an intracapsular impacted fracture, but it happens much more often in the extracapsular impacted fracture.

The pain and tenderness, accompanied sometimes with swelling and discoloration, are situated most often in front of the neck of the bone. Articular mobility exists in a majority of cases; that is, the limb can be moved pretty easily in any direction by the surgeon, but not without producing pain or provoking muscular spasms. In most cases the

patient himself is unable to move the limb by his own volition, or he can only move it slightly. Crepitus is present whenever there exists a moderate but not complete impaction. It is also present generally when, the trochanteric fragment having been extensively comminuted and loosened, the impaction becomes excessive; and it is only absent when the impaction is such that the fragments are completely and firmly locked into each other. A shortening is inevitable, at least in all cases accompanied with either temporary or permanent impaction, and we have seen that one of these conditions seldom fails. Eversion of the toes is very constant; but in a few instances upon record the toes have been found turned in, or even directed forward. The trochanter major usually seems depressed or driven in; and when the two main fragments are completely separated, if the limb is rotated, the trochanter will be found to turn almost upon its own axis, or upon a very short radius.

Robert Smith has established the following distinction: When the fracture is extracapsular and impacted, that is, when it remains impacted, the shortening is only moderate, varying from one-quarter of an inch to one inch and a half; in fourteen cases measured by him the average was a fraction over three-quarters of an inch; but when it does not remain impacted it ranges from one inch to two inches and a half; indeed, Mr. Smith mentions one example in which the shortening reached four inches, and forty-two cases gave an average shortening of something more than one inch and a quarter. Mr. Smith's experience as to the amount of shortening in these cases agrees very nearly with my own.

In enumerating the signs of a recent extracapsular fracture, it will be seen that I have, with only slight variations, repeated the signs of a fracture within the capsule. It will become necessary, therefore, to indicate, as far as possible, a differential diagnosis.

SIGNS OF A FRACTURE WITHIN THE CAPSULE.

Produced often by slight violence.

A fall upon the foot or knee, or a trip upon the carpet, etc. Possibly a fall upon the trochanter: especially when an old person is the subject of the injury.

Generally over fifty years of age.

More frequent in females.

Pain, tenderness, and swelling less and deeper.

Ecchymosis not often seen.

(The two following measurements to be made from the lower margin of the anterior superior spinous process of the ilium to the lower extremity of the malleolus externus or internus.)

Shortening at first less than in extracapsular fractures, often not any.

SIGNS OF A FRACTURE WITHOUT THE CAPSULE.

Produced usually by greater violence.

A fall upon the trochanter major in nearly all cases.

Often under fifty years of age.

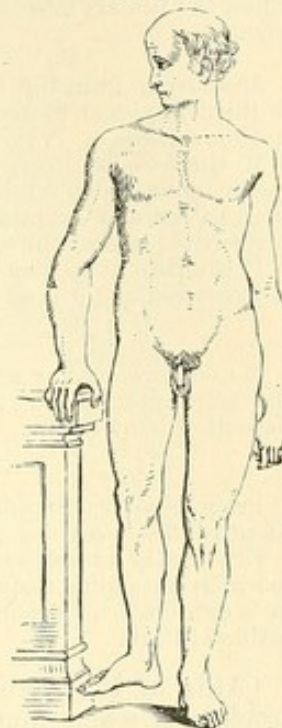
Relative frequency in males or females not established.

Pain, swelling, and tenderness greater and more superficial. It is especially painful to press upon and around the trochanter major.

Superficial and extensive ecchymosis quite frequent.

Shortening at first greater, almost always some.

FIG. 214.



Fracture of the neck of the femur. (Fergusson.)

SIGNS OF A FRACTURE WITHIN THE CAPSULE
(continued).

Shortening after a few days or weeks greater than in extracapsular fractures. Sometimes this takes place suddenly, as when the limb is moved, or the patient steps upon it.

Measuring from the top of the trochanter to the condyles or to the malleoli, the limb is not shortened.

If there is no impaction, the trochanter major moves upon a relatively longer radius than in cases of extracapsular fractures, the pivot being nearer the acetabulum.

If the patient recovers the use of the limb, not restored under many months, or years.

No enlargement or apparent expansion of the trochanter major, after recovery, from deposit of bony callus.

Progressive wasting of the limb for many months after recovery.

Eventually excessive halting, accompanied with a peculiar motion of the pelvis, such as is exhibited in persons who walk with an artificial limb.

SIGNS OF A FRACTURE WITHOUT THE CAPSULE
(continued).

Shortening after a few days or weeks less than in intracapsular fractures, provided proper extension has been maintained. That is, the amount of shortening changes but little, if at all, if the impaction continues. If it does not continue, it shortens more.

Measuring from the top of the trochanter to the condyles or to the malleoli, the limb may be found a little shortened.

If there is no impaction, the trochanter major moves upon a relatively shorter radius, the pivot being more remote from the acetabulum.

The patient usually recovers the use of the limb sooner. In many cases, however, very slowly, and walking is for a long time difficult and painful.

Enlargement or irregular expansion of trochanter, which may be felt sometimes distinctly through the skin and muscles, and which is especially manifest after the lapse of some months.

The limb preserving more nearly its natural strength and size

Comparatively slight halt, motions of hip more natural.

[Allis, of Philadelphia, has noticed the relaxation of the fascia lata above the trochanter when there is fracture of the neck of the femur, and illustrates the method of detecting this sign (Fig. 215).]

Prognosis.—In attempting to establish the differential diagnosis, we have necessarily been led to consider most of the essential points of prognosis. Very little, therefore, remains to be said upon this subject. Union occurs as rapidly in this fracture as in fractures of the shaft; and perhaps in general more promptly, owing to the existence of impaction. But whether it occurs promptly or slowly, or, indeed, if it does not occur at all, a remarkable deposit of ossific matter almost invariably takes place along the intertrochanteric lines, where the bone has separated from the shaft, and also, not unfrequently, along the lines of the other fractures of the trochanter. This deposit is no less remarkable for its abundance than for its irregularity, long spines of bone often rising up toward the pelvis and forming a kind of knobby or spiculated crown, within which the acetabular fragment reposes. In a few instances these osteophytes have reached even to the bones of the pelvis, and formed powerful abutments, which seemed to prevent any farther displacement of the limb in this direction, and by some writers they have been supposed thus to fulfil a positive design. A sufficient explanation of their existence, however, I think, can be found in the fact that they proceed entirely from the trochanteric fragments, whose extensive comminution and great vascularity would naturally lead to such results. The same, but in a less degree, has already been noticed as occurring in impacted fractures at the anatomical neck of the humerus, where certainly such bony abutments could not serve any useful purpose.

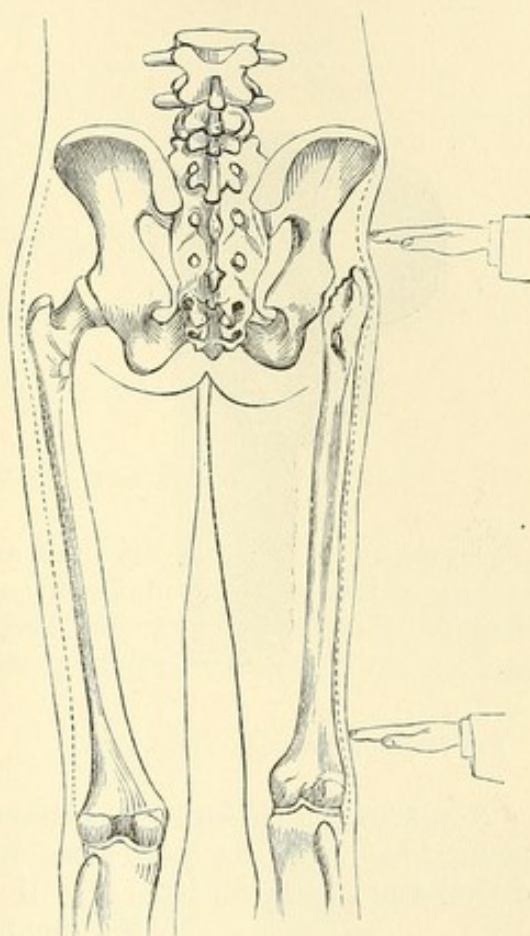
Probably in all, certainly in nearly all cases, the limb will be found, after the union is consummated, more or less shortened, generally between

half an inch and an inch. If exceptions ever occur, it must be in those examples in which there is no impaction, and it is certain that such examples are very rare. Such is the united testimony of all surgeons whose opinions have ever been respected as authority; and the same is true of intracapsular fractures. What ignorance of the elementary facts of surgical science, or insincerity, then, do these men exhibit who affirm that they are able to treat *all* fractures of the femur without shortening! Eversion of the foot is not so constant as shortening, but it will be found to exist in some degree in a large majority of cases, even when the case has been managed in the most skilful manner; yet in this regard something will depend upon the position in which the limb is maintained during the treatment.

Treatment.—The same principles of treatment are applicable here as in fractures of the neck within the capsule; by which I mean to say that, as in all of those examples of fracture within the capsule where the relation of the fragments is such as to warrant a hope that a bony union may be consummated, namely, where the fragments are not displaced or are impacted, the straight position, with only moderate extension, constitutes the most rational mode of treatment; so also in this fracture, whenever the fragments are impacted and remain impacted, the straight position, with moderate extension, employed only as a means of retention, but not so as to overcome impaction, is the most suitable. It is only by employing this plan of treatment that those serious misfortunes to the patient can be avoided which would necessarily continue to occur if the patient were in the one case to dispense with apparatus wholly, or to get upon his crutches as soon as the condition of his limb and of his body will permit. This conclusion is based upon the admitted difficulty of diagnosis.

If, as is well understood, the diagnosis between these two varieties of fracture is often impossible during the life of the patient, then how shall we know in any given case which of the two plans to adopt? If we act upon the supposition that it is within the capsule, adopting Sir Astley Cooper's method, and it proves to have been a fracture without the capsule, we may do irreparable injury to our patient. It is precisely here that this distinguished surgeon committed his great error; not in denying that certain specimens were fractures of the neck of the femur within the capsule united by bone, nor in constantly urging

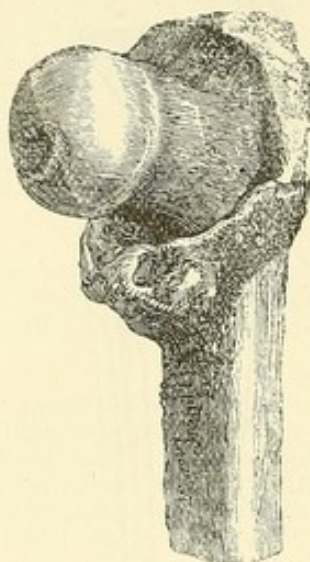
FIG. 215.



Method of recognizing the relaxation of the fascia lata after fracture of the neck of the femur. (Allis.)

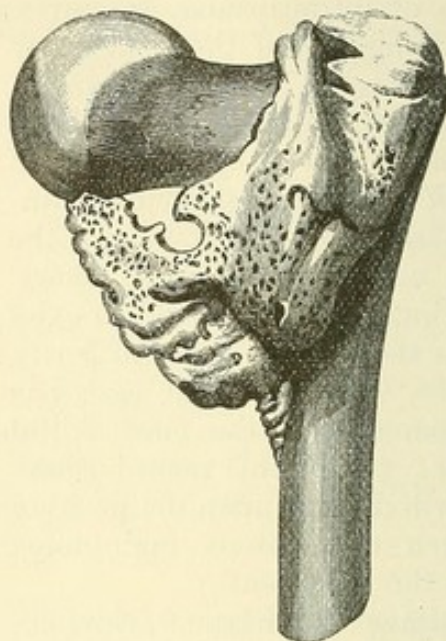
upon his contemporaries the improbability of such an event; but in that, while he admitted its possibility, he chose to recommend a plan of treatment which was unlikely to insure such a union, and which, in the uncertainty, if not impossibility of diagnosis, was liable, upon his supposed authority, to be adopted in many cases of extracapsular fractures.

FIG. 216.



Extracapsular fracture. (Erichsen.)

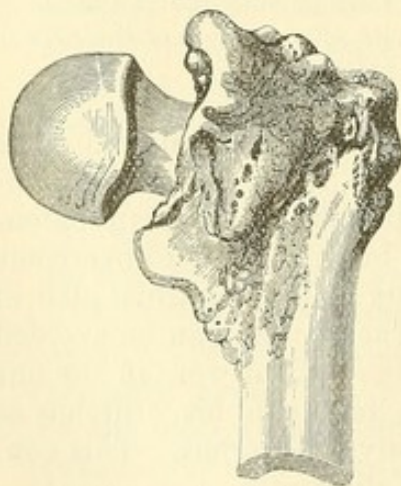
FIG. 217.



Extracapsular fracture. (R. Smith.)

Again, if the fracture be extracapsular and not impacted, or the impaction has been, for any cause, overcome; or, if the fracture be intracapsular and not impacted; or if the capsule is lacerated and the frag-

FIG. 218.



Extracapsular fracture.

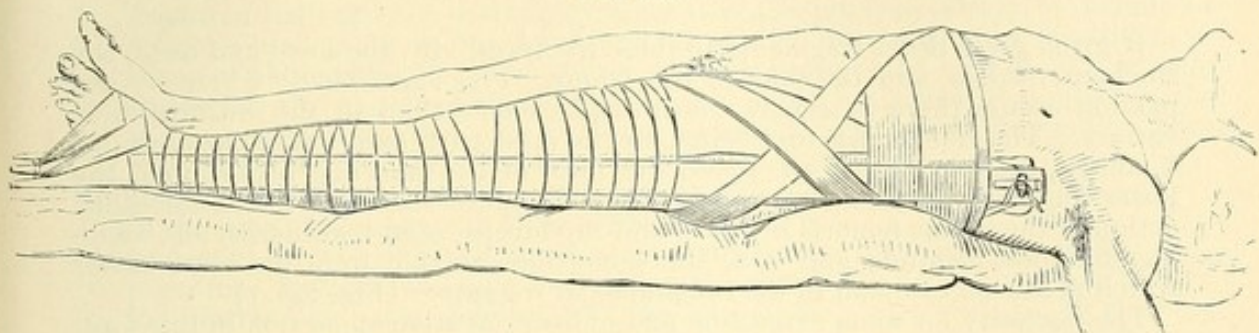
ments are in consequence displaced; then, again, no injury need result from the treatment, if we adopt the straight position with moderate extension. That it is or is not impacted we may know generally by the amount of displacement, although we may not easily decide whether the fracture is within or without the capsule. Now, the amount of shortening will determine properly enough the amount of extension to be employed. In either case, however, we shall not employ as much extension as in fractures of the shaft; and while, if it be an intracapsular fracture, we may only gain a shorter and firmer ligamentous union, if it proves to be extracapsular we shall in-

sure a better and more speedy bony union.

If any surgeon, acting upon the suggestions here made, shall confine a feeble or an aged person in the horizontal posture, with or without a straight splint, until the powers of nature have become exhausted, and death ensues, as our readers have already been admonished may happen, we are not to be held responsible for his want of judgment or of skill. We have advised this plan of treat-

ment only for so long a period as the condition of the patient renders it entirely safe, or as it can prove useful. No doubt, then, in a large number of cases, it will have to be abandoned very early, and in not an inconsiderable proportion all constraint will be plainly inadmissible *from the beginning*.¹

FIG. 219.

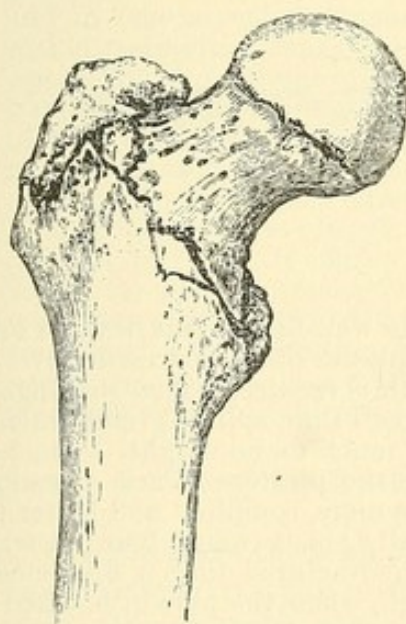


Miller's splint for extracapsular fracture. (From Miller.)

(c) Fractures of the Neck, Intra- and Extra-capsular.

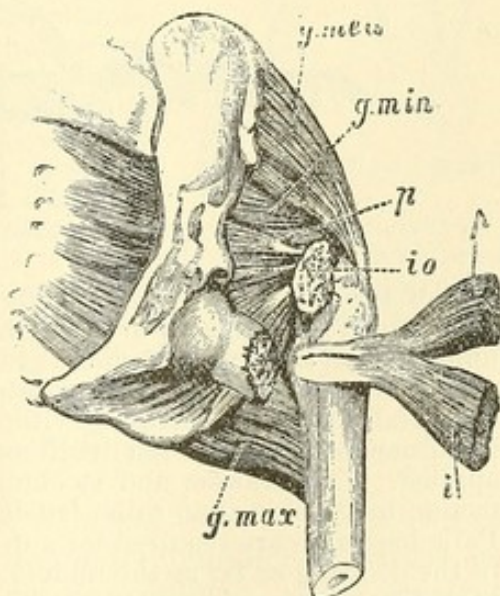
It is scarcely necessary to say that the line of fracture through the neck of the femur may be such, that it shall be in part within and in part without the capsule; and such fractures will be even more difficult to diagnosticate than either of those forms of which we have just spoken.

FIG. 220.



Fracture along the intertrochanteric line, being intra- and extra-capsular. (Pick.)

FIG. 221.



Displacement which results from muscular action in fracture of the neck; the letters indicate the several muscles. (Hind.)

The symptoms will be mainly, however, those which characterize fractures within the capsule, while the treatment ought to be such as we would adopt in those fractures which are wholly without the capsule.

¹ Fracture at the Neck of the Femur. Clinical Lecture at the Bellevue Hospital, by the Author. Priority in Employment of Extension, etc. The Medical Record, March 9, 1878.

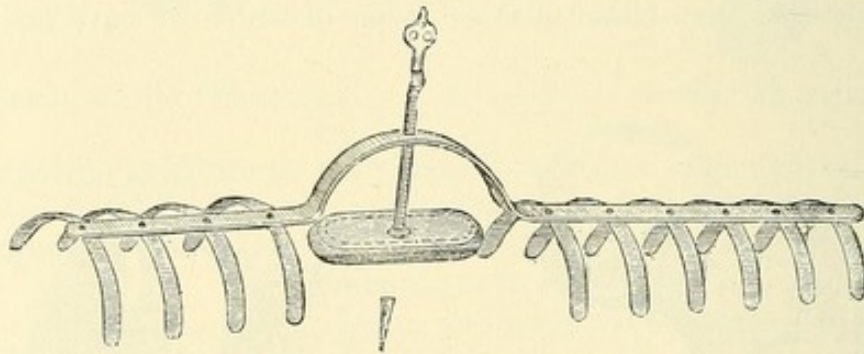
The chances for bony union are increased in proportion as the line of separation extends outside of the capsule, and we ought to be diligent in our efforts, if we have made ourselves certain that the fracture is partly extracapsular, to secure a good bony union; a result which experience has shown may be reasonably anticipated.

[Ogston gives three fragments to these fractures, viz., the head and neck, the trochanter major, and the shaft of the femur. Pick states that "where no impaction occurs there is always more displacement than in the intracapsular variety. The line of fracture being, for the most part, external to the capsular ligament, there is nothing to oppose the force of the muscular action upon the lower fragment, which is drawn upward by the glutei muscles and the combined action of the rectus femoris in front, and the biceps, semi-tendinosus, and semi-membranosus behind; and is, at the same time, everted from the same causes which produced eversion in the intracapsular fracture. (Fig. 221.)]

The necessity for some extension, and of firm retentive apparatus in this form of fracture, furnishes another argument in favor of the employment of the same means in fractures wholly within the capsule. We shall thus avoid the mischief which might arise from mistaking a fracture of the character of which we are now speaking, for a fracture wholly within the capsule.

[Senn, of Milwaukee, advises fixation of the limb in impacted fractures, and in non-impacted fractures reduced, by means of a plaster-of-Paris dressing, with a splint and pad for compression. The following is his description of the applica-

FIG. 222.

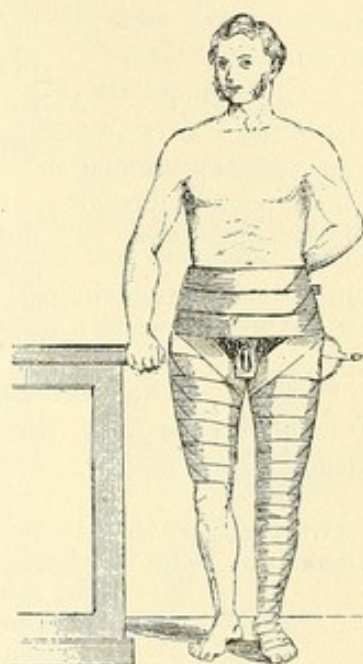


Senn's splint.

tion of the apparatus: The patient is dressed in well-fitting knit drawers and a thin pair of stockings. For strengthening the plaster-of-Paris dressing over the joints, and at other points where greater strength is required oaken shavings are placed between the layers of plaster; these small thin, splints greatly increase the durability of the dressing without adding much to its weight. The bony prominences are protected with cotton before the plaster-of-Paris dressing is applied. The drawers and stockings furnish a more complete and better protection to the skin than roller bandages. Usually about twenty-four plaster-of-Paris bandages are required for a dressing. The fractured limb is first encased in the dressing as far as the middle of the thigh, when the patient is lifted out of bed by two strong persons, the physician supporting the limb so as to prevent disengagement of the fragments if the fracture is impacted, and to guard against additional injuries in non-impacted fractures. The patient is placed in the erect position, standing with his sound leg upon a stool or box about two feet in height; in this position he is supported by a person on each side until the dressing has been applied and the plaster has set. A third person takes care of the fractured limb, which is gently supported and immovably held in impacted fractures until permanent fixation has been secured by the dressing. In non-impacted fractures the weight of the fractured limb makes auto-extension, which is often quite sufficient to restore the normal length of the limb; if this is not the case, the person who has charge of the limb makes traction until all shortening has been overcome, as far as possible, at the same time holding the limb

in a position so that the great toe is on a straight line with the inner margin of the patella and the anterior superior spinous process of the ilium. In applying the plaster-of-Paris bandages over the seat of fracture, a fenestrum, corresponding in size to the dimensions of the compress with which the lateral pressure is to be made, is left open over the great trochanter. To secure perfect immobility at the seat of fracture, it is not only necessary to include in the dressing the fractured limb and the entire pelvis, but it is absolutely necessary to include the opposite limb as far as the knee, and to extend the dressing as far as the cartilage of the eighth rib. The splint, which is represented by Fig. 222, is incorporated in the plaster-of-Paris dressing, and must be carefully applied so that the compress, composed of a well-cushioned pad with a stiff, unyielding back, rests directly upon the trochanter major, and the pressure which is made by a set screw is directed in the axis of the femoral neck. The set screw is projected by a key which is used in regulating the pressure. Lateral pressure is not applied until the plaster has completely set. If the patient is well supported and the fractured limb is held immovably in proper position, but little pain is experienced during the application of the dressing. Syncope should be guarded against by the administration of stimulants. As soon as the plaster has sufficiently hardened to retain the limb in proper position, the patient should be laid upon a smooth, even mattress, without pillows under the head, and in non-impacted fractures the foot is held in a straight position, and extension is kept up until lateral pressure can be applied. The lateral pressure prevents all possibility of disengagement of the fragments in impacted fractures, and in non-impacted fragments it creates a condition resembling impaction by securing accurate apposition and mutual interlocking of the uneven fractured surfaces. No matter how snugly a plaster-of-Paris dressing is applied, as the result of shrinkage in a few days it becomes loose, and without some means of making lateral pressure, it would become necessary to change it from time to time in order to render it efficient. But by incorporating a splint, as shown in Fig. 222, in the plaster dressing (Fig. 223) this is obviated, and the lateral pressure is regulated from day to day by moving the set screw, the proximal end of which rests in an oval depression in the centre of the pad. From time to time the pad is removed, and the skin washed with diluted alcohol for the purpose of guarding against decubitus.]

FIG. 223.



Senn's dressing complete.

§ 2. Fractures of the Trochanter Major.

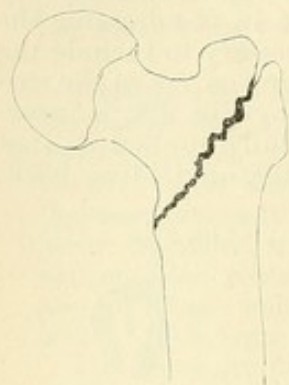
(a) **Fracture through the Process.**—Cooper¹ says: “Fractures sometimes happen through the trochanter major obliquely, and the cervix ossis femoris does not participate in the injury.” The illustration, Fig. 224, “exhibits,” he says, “the seat of fracture of the trochanter major often mistaken for fractured cervix femoris; this fracture unites by bone.” The line of this supposed fracture, as shown in the illustration, is from near the top of the trochanter major downward and inward, and terminating on the shaft just below the trochanter minor. It does not, therefore, involve the neck, but it severs the thigh-bone completely.”

Sir Astley Cooper believed that he had seen three other similar cases in the course of his practice, none of which, however, was established by dissection.

¹ Sir Astley Cooper, on Dislocations and Fractures of the Joints, London, 2d ed., 1823, p. 158.

I am compelled to state that the fracture described by Sir Astley, unaccompanied with comminution of the trochanter major, has probably never been met with. The illustration which he

FIG. 224.



Sir Astley Cooper's imaginary fracture through the trochanter major.

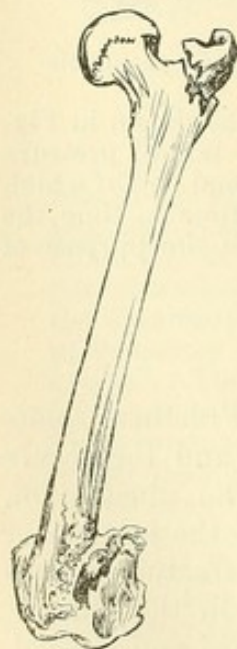
furnished of this accident was drawn, not from any such specimen seen by himself, but from his own ideas as to what conditions of the fracture would best explain the clinical phenomena presented. Surgeons of Sir Astley's day had not become so well acquainted with the variety of conditions in which an extracapsular impacted fracture may be found—in some cases the penetration being almost imperceptible, while in others the penetration is such as to separate the trochanter into several fragments, some of which may be completely detached and displaced.

Sir Astley Cooper's error in diagnosis, as Malgaigne does not hesitate to call it, has embarrassed and misled many who have attempted to study this subject; and which embarrassment can only be relieved by a complete rejection of all that Sir Astley has written upon it.

(b) **Fracture of the Process.**—[A distinction should be made between a fracture through the trochanter major and a fracturing off of the process.]

[Fracture of this bone is very rare, but its existence has been proved by dissection. The epiphysis may be fractured off at its base, or it may be crushed.

FIG. 225.



Fracture of the trochanter major.

The more frequent cause is direct violence, as a fall upon the trochanter. The symptoms are, pain and swelling at the seat of fracture, absence of prominence of the trochanter, ability to seize the fragment of bone and move it separately from the shaft, crepitus when the limb is abducted, and no shortening. The prognosis is unfavorable as regards union. The treatment must be such as will maintain the fragments as nearly in apposition with the shaft as possible. Abduction of the limb was recommended by Bransby Cooper, and this position will certainly approximate the separated parts. In other respects the patient should be confined to the recumbent position for a period of at least one month.]

The case reported by Waechter¹ may be given as an illustrative example. A man 71 years old, fell upon his left hip; there was no sign of contusion and no crepitus. Outward rotation alone caused pain. Subsequently the limb became flexed, rotated inward and adducted. Four weeks after the accident he died of pneumonia. "The upper and inner portion of the trochanter was separated by a line of fracture which lay entirely outside the joint, beginning close by the upper edge of the insertion of the capsule, running downward and outward, and then up across the top of the trochanter. The fragment, which was split into two pieces that were slightly movable on each other, was slightly displaced backward and inward, and the periosteum was torn in front, but not on the outer side. The tendons of the pyriformis, obturator internus and gemelli, and the anterior fibres of the glutæus medius, and upper fibres of the glutæus minimus remained attached to the fragment.

¹ Deutsche Zeit. für Chirurgie, 1877, p. 104.

I have also myself reported one example of this fracture as having come under my own observation. The patient, J. R., æt. 23, fell from a high wagon, striking upon his left hip. When he got upon his feet, he found himself unable to walk, and was carried to his room. Fourteen days after the accident I saw the patient with Dr. Wilcox. The thigh was not appreciably shortened, nor was there any eversion or inversion; but the epiphysis of the trochanter major was carried upward toward the crest of the ilium half an inch, and slightly sent in. No crepitus could be detected. The splint was continued five weeks; and about a month after, I found the fragment in the same place, but he was able to walk with only a slight halt.

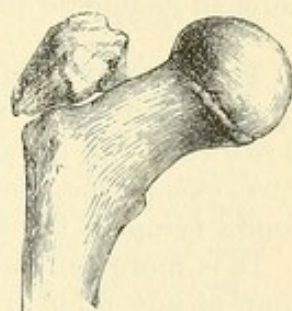
(c) **Separation of the Epiphysis of the Trochanter Major.**—[Separation of the epiphysis of the trochanter in young persons is a rare accident. It is more often caused by a direct injury to the trochanter, but in some cases it seems to have been due to muscular action. There is eversion of the foot, a swelling over the trochanter, and inability to use the limb freely. In many cases there was the rapid formation of an abscess, with a tendency to pyæmia. The treatment must be, rest with the limb straight but abducted.]

Mr. Key reported the following case: A girl, aged about 16 years, fell upon the sidewalk, and struck her trochanter violently against the curbstone. She arose, and, without much pain or difficulty, walked home. The right leg, which was the one injured, was considerably everted, and appeared to be about half an inch longer than the sound limb. It could be moved in all directions, but abduction gave her considerable pain. She had perfect command over all the muscles, except the rotators inward. No crepitus could be detected. Four days after admission she died. The autopsy disclosed a fracture through the base of the trochanter major, but without laceration of the tendinous expansions which cover the outside of this process, so that no displacement of the epiphysis had occurred, nor could it be moved, except to a small extent upward and downward. A considerable collection of pus was found, also, below and in front of the trochanter. The absence of displacement in the fragment, with its peculiar and limited motion, sufficiently explained why the fracture could not be detected during life.

A case was reported by McCarthy to the London Pathological Society, and is printed in its Transactions as "a traumatic separation of the trochanteric epiphysis." The patient was a girl eight years old, who, when brought to the hospital, was considered too ill to be examined, and died a few hours afterward. The history was, that she had never had any illness previous to a fall on the left side a week before, while playing. A day or two later a lump was noticed on the left hip, and the child was kept in bed in consequence. A few days later her breathing became so difficult that she was brought to the hospital, walking the distance, half a mile, and not complaining of pain. The autopsy showed "pyæmic pericarditis, pleurisy, and pneumonia," a large extra-peritoneal abscess in the pelvis, connecting along the tendon of the pyriformis with another around the neck of the femur. The trochanteric epiphysis was completely detached from the shaft, but held in position by tendinous attachments and reflections of the capsule.¹

Prof. Roddick, of Montreal, Canada,² reports a case. A lad, æt. 16, became lame in consequence, as Dr. Roddick thinks probable, of leaping a fence in pursuit of a ball. Subsequently an abscess formed over the trochanter, which was opened. A few weeks later he died, apparently as a consequence of pyæmic infection. It was then found that the trochanter was lying in a mass of pus, entirely separated from the shaft, and with no other lesion.

FIG. 226.



Mr. Aston Key's case.
Prep. 1195, Guy's Museum. (From Bryant.)

¹ McCarthy, Trans. Path. Soc. London, vol. xxv., 1874, p. 200 (Stimson).

² Roddick, Canada Med. and Surg. Journ., Nov. 1875, p. 207.

§ 3. Fractures of the Shaft of the Femur.

Causes.—Unless the fracture has taken place just above the condyles, or immediately below the trochanter minor, in a very large proportion of cases it has been produced by a direct blow. The bone is most frequently broken in its middle third, and usually at a point somewhat above the middle of the shaft.

In an examination of twenty-four fractures of the shaft belonging to Dr. Mütter three were in the upper third, two in the lower, and nineteen in the middle third.

In the adult these fractures are, with only an exceedingly rare exception, oblique; and the obliquity is generally greater than in the case of other bones.

This fact, which is very difficult to determine, in most cases, upon the living subject, I have established by a considerable number of observations made upon cabinet specimens. A transverse fracture is found only twice in Dr. Mussey's collection, containing thirty examples of fracture of the shaft; and in Dr. Mütter's collection, specimen B 71 is an adult femur, broken nearly transversely through its middle third; and it is united with a shortening of about one inch.

The direction of the obliquity varies exceedingly, especially in the middle and upper thirds; in the middle third, however, it is generally downward and inward; but in the lower third its direction is, with only rare exceptions, downward and forward, and the superior fragment is found lying in front of the inferior.

It is more common to find a transverse fracture in the middle third than at any other point of the shaft of the bone; but in the upper third the obliquity is extreme and almost constant. At whatever point of the shaft the bone is broken, the degree of obliquity is generally such that the fragments cannot support each other when placed in apposition; unless indeed the fracture is near the condyles, where the greater breadth of the bone creates an additional support; but even here the cabinet specimens still present a striking obliquity, with more or less overlapping. In the case of children, and especially of infants, the bone is not unfrequently broken transversely or nearly transversely, or it is serrated or denticulated, so that complete lateral displacement is much less frequent.

The direction of the displacement, however, in fractures of the shaft of the femur, does not always depend upon the direction of the line of fracture. In fractures of the upper third, whatever may be the direction of the line of fracture, the lower end of the upper fragment inclines forward and outward, and the upper end of the lower fragment inward; unless, indeed, this inclination is controlled by actual entanglement of the broken ends with each other. In the middle third the fragments also generally take the same relative position, whatever may be the direction of the fracture; but when the fracture takes place at or near the condyles, where the diameter of the bones is much greater, the direction of the obliquity determines pretty uniformly the direction of the displacement.

Symptoms.—The symptoms which characterize a fracture of the shaft of the femur are those which are common to all fractures, namely, mobility, crepitus, displacement of the fragments, pain, and swelling, to which are added generally a shortening of the limb, with eversion of the foot and leg. Owing to the great amount of muscle covering the thigh, or to the swelling which immediately follows the injury, it is sometimes difficult to determine at what precise point the fracture has occurred; and it is generally still more difficult to say whether the fracture is oblique or transverse; indeed, this latter question is sometimes decided approximately by a reference to the age of the patient rather than by the examination of the limb. The immediate shortening varies from half an inch to an inch and a half, or even more; and it will average about one inch in the case of healthy adults.

Prognosis.—Whatever may have been the general opinion of experienced surgeons as to the question of shortening in other fractures, very few certainly have ever claimed that in fractures of the femur a complete restoration of the bone to its original length was generally to be expected. There seem, however, to have existed only certain vague and indefinite notions as to the proportion and amount of this shortening, and which had for their basis nothing better than a few imperfect observations. The average shortening in fractures of the upper third of the femur, in the cases examined by me, was about four-fifths of an inch; in the lower third it was a fraction over three-quarters, and in the middle third a fraction less than three-quarters of an inch; and the average of the whole number was almost exactly three-quarters of an inch (three-quarters and one forty-seventh). These analyses were made upon simple fractures, and were exclusive of those in which no shortening at all occurred. An analysis which included also those which had not shortened, reduced the average shortening to half an inch and about one-tenth.

An examination of cabinet specimens does not present a result so favorable even as this. Of nineteen fractures of the shaft of the femur contained in Mütter's cabinet, not one seems to have been shortened less than one inch.

Says Chelius: "Fracture of the thigh-bone is always a severe accident, as the broken ends are retained in proper contact with great difficulty. The cure takes place most commonly with deformity and shortening of the limb, especially in oblique fractures, and those which occur in the upper and lower third."¹ Says John Bell: "The machine is not yet invented by which a fractured thigh-bone can be perfectly secured." And Benjamin Bell declares that "an effectual method of securing oblique fractures in the bones of the extremities, and especially of the thigh-bone, is perhaps one of the greatest desiderata of modern surgery."² Nélaton remarks: "A fracture of the body of the femur, with an adult, is always a grave accident, inasmuch as it demands so long a confinement to the bed, and especially on account of the shortening of the limb, which it is almost impossible wholly to prevent; accordingly, Boyer recommends to the surgeon, from the first day, to announce to the parents of the patient the possibility of this accident. With infants, on the contrary, it is almost always easy to avoid the shortening."³

Malgaigne declares his opinion on this subject thus: "At a period quite recent, Desault pretended to cure all fractures without shortening, and his journal contains several examples. In imitation of Desault, various practitioners have

¹ System of Surgery, by J. M. Chelius, translated, etc., by South. First Amer. ed., vol. i. p. 627, 1847. See also p. 625, paragraph 679.

² System of Surgery, by Benjamin Bell, vol. vii. p. 21. Edinburgh, 1801.

³ *Eléments de Pathologie Chirurgicale*, par A. Nélaton, tom. prem. p. 752. Paris, 1844.

modified, corrected, and improved the apparatus for permanent extension, and they claim to have themselves obtained as complete success. I ought, then, to declare here, in the most positive manner, that I have never obtained like results, either in the use of my own apparatus, or with that of others, nor indeed, where, in pursuance of my invitation, several inventors have applied their apparatus in my wards. I have examined, more than once, persons declared cured without shortening, and yet, upon measurement, the shortening was always manifest. The misfortune of all those who believe that they have obtained those miraculous cures is, that they have not even thought of instituting a comparative measurement of the two limbs; I will say even more, that they are most generally ignorant of the conditions of a good and faithful measurement. Sometimes, also, they have been deceived in another way—in falling upon fractures which were not displaced, especially with young persons; and they have believed that they have cured with their apparatus a shortening which had never existed. In short, when the fragments are not displaced, or even when they are brought again into contact and maintained by their reciprocal denticulations, it is easy to cure the fracture of the femur without shortening; aside of those two conditions, the thing is simply impossible."

Dr. Buck, of New York, thinks that with a shortening of one inch, or even one inch and a half, the patient may have "a useful limb, with little or no halt."¹ Mott testified, in a suit for malpractice, that "more or less shortening of the limb is uniformly the result after fractured thigh, even in the most favorable circumstances."² Knight says: "I have seen but few fractures of the femur in the adult, unless of the most simple kind, in which there was not some remaining deformity; often slight, so as not to impair the usefulness of the limb, and in others considerable and apparently unavoidable. In the greater proportion of the fractures in children the recovery has been so nearly perfect that no marked deformity or lameness has followed." Detmold, of New York, declares his belief that a shortening of the femur always occurs after fracture, and that "but one inch of shortening in an average of twenty cases is a good result."³ Dr. J. Mason Warren, of Boston, writes as follows: "I would state that, after a long and very careful observation, I have never yet seen, either in Boston or elsewhere, an oblique fracture of the thigh, in a patient over seventeen years of age, in which there was not some shortening. I have had cases shown to me in which it was averred that the limb was not shortened, but on measuring myself I have found the fact otherwise. In children, I believe that union without shortening may be accomplished."

Bigelow, of Boston, writes as follows: "In our hospital cases shortening is the rule in adults. Young subjects do better. Three-quarters of an inch shortening in the adult is a good result, and easily compensated by the pelvis. Greater shortening may occur."

Says Dr. Buck, of New York: "After carefully scrutinizing over one hundred cases of fracture of the femur, taken from the register of the New York Hospital, and eliminating such as involved the cervix, or condyles, or belonged to the class of compound fractures, there remained an aggregate of seventy-four cases, of both sexes, and of all ages from 3 to 63, in which the shaft of the femur alone was fractured." In all these cases the difference in the length of the fractured limb, resulting from the treatment, was ascertained by careful measurement with a graduated tape, and the following deductions were drawn from the analysis: "Of the 74 cases of all ages, 19 resulted without any shortening, a proportion of about one-fourth. The average shortening of the remaining 55 cases was a fraction less than three-fourths of an inch. Seventeen cases in the above aggregate were under 12 years of age, of which six resulted without any shortening, a proportion of about one-third. The average shortening in the remaining eleven cases was a fraction less than one-half an inch. Of the 57 cases over 12 years of age, 13 resulted without any shortening, a proportion of about one-fourth; and

¹ New York Journ. of Med., vol. xvi. p. 294.

² Boston Med. and Surg. Journ., vol. xxxiv. p. 450. See also opinions of Drs. Reese, Post, Parker, Cheeseman, Wood, etc., in relation to the prognosis in this particular case.

³ New York Journ. of Med., second series, vol. xvi. p. 261.

the average shortening in the remaining 44 cases was a fraction over three-fourths of an inch."¹

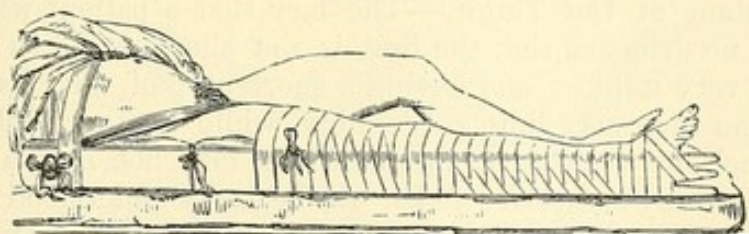
Mr. Holthouse, surgeon to Westminster Hospital, states that a careful examination of fifty cases of fractures of the femur in the various London hospitals, made by himself, showed that 90 per cent. (including twenty children) were shortened, the amount of shortening ranging from one-half an inch to three and one third; and as some of these cases were still under treatment, he entertains a doubt whether the final result will prove to be as favorable as above stated. He declares, with a frankness which is most creditable to his courage and honesty, that at Westminster, with all the appliances known to surgery at his command, he has never succeeded, in the adult, in effecting union without shortening. He has also examined more than one hundred specimens in the various museums of the metropolis, and they are all shortened.

After quoting the opinions of several writers upon this subject, including the author of this treatise, Mr. Holthouse adds in a footnote: "Notwithstanding this strong testimony, surgeons are still to be found hardy enough, or ignorant enough, to repeat the fallacies which have been so often refuted, and to vaunt their success in the cure of oblique fractures in the adult without shortening. Why do not these surgeons, instead of publishing their cases in the journals, produce their patients at some of the medical societies?"²

Dr. Agnew,³ after referring to these statements of Mr. Holthouse, says: "My own experience accords entirely with these statements. I have not met with a single case among all the specimens in Philadelphia of fracture of the shaft of the femur which was entirely free from deformity; and I am equally certain that neither in hospital nor in private practice, save in the case of children, have I ever succeeded in curing a case without an appreciable deformity."

It is not to be denied, however, that a few surgeons in all parts of the world have claimed, and still continue to claim, in their own practice, or from the adoption of their own peculiar plans of treatment, much better success. Indeed, some of them do not hesitate to affirm that, as a general rule, any degree of shortening is quite unnecessary.

FIG. 227.



Liston's method, recommended by Samuel Cooper, Fergusson, Pirrie, and others.

In conclusion, I wish to say briefly that, in view of all the testimony which is now before me, I am convinced—

First. That in the case of an oblique fracture of the shaft of the femur occurring in an adult, whose muscles are not paralyzed, but which offer the ordinary resistance to extension and counter-extension, and where the ends of the broken bone have once been completely displaced, no means have yet been devised by which an overlapping and consequent shortening of the bone can generally be prevented.⁴

¹ Buffalo Med. Journ., vol. xv. p. 22, June, 1859.

² Holthouse, Holmes's System of Surgery, 2d ed., 1870, vol. ii. p. 866.

³ Agnew, Principles and Practice of Surgery, vol. i. p. 948.

⁴ In the first three editions of this treatise the word "generally" is omitted; but a later experience, with improved appliances, has supplied to me, both in my own practice and in the practice of others, a few examples of perfect union under the conditions named. The word

Second. That in a similar fracture occurring in children or in persons under fifteen or eighteen years of age, the bone may quite often be made to unite with so little shortening that it cannot be detected by measurement; but it must not be forgotten that with children especially it is exceedingly difficult to measure very accurately.

Third. That in transverse fractures, or oblique and denticulated, occurring in adults, and in which the broken fragments have become completely displaced, it will generally be found equally difficult to prevent shortening; because it will be found generally impossible to bring the broken ends again into such apposition as that they will rest upon and support each other.

Fourth. That in all fractures, whether occurring in adults or in children, where the fragments have never been completely or at all displaced, constituting only a very small proportion of the whole number of these fractures, a union without shortening may always be expected.

Fifth. That when, in consequence of displacement, an overlapping occurs, the average shortening of simple fractures in adults, where the best appliances and the utmost skill have been employed, is from one-half to three-quarters of an inch.

If we consider the muscles alone as the cause of the displacement in the direction of the long axis of the shaft, the shortening of the limb, other things being equal, must be proportioned to the number and power of the muscles which draw upward the lower fragment. This will vary in different portions of the limb, but nowhere will this cause cease to operate, nor will its variations essentially change the prognosis. Other causes operate occasionally in the production of shortening, but muscular contraction is the cause by which this result is chiefly determined, and its power will be ordinarily the measure of the shortening.

Measurement of the Thigh.—The fact that a patient walks without any halt, is no evidence that the limb is not shortened. In this regard patients are very unlike; one having a shortening of only half or three-quarters of an inch may limp perceptibly, while another with a shortening of an inch, or even an inch and a half, may not limp at all. This has been frequently observed; and it will be easily understood if, standing erect with the right foot on a block one and a half inches in height, the left foot is planted upon the floor. It will then be seen that the left foot can be brought to the floor without disturbing the erect position of the body. Nor is it any more a proof that the limb is not shortened because, while in the recumbent posture, the heel can be brought down to the level of the other.

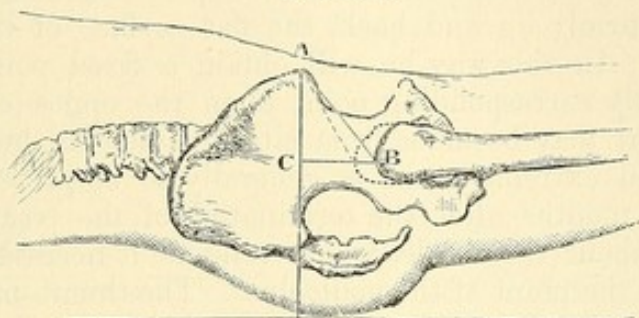
Measurements made from the umbilicus, or from the symphysis pubis, are always indefinite and unreliable. Velpeau's idea of measuring from the folds of the belly, immediately above the ilium, is unsound. Mr. Bryant's suggestion that we measure from the trochanter major, by what he terms the ilio-femoral triangle, in order to determine the question of

"generally" was, therefore, added in the fourth edition, and is retained in this. Exactly what percentage of perfect cures may reasonably be expected cannot at present be determined, but it is certainly very small. It has never been my opinion that a shortening must inevitably result as a consequence of the absorption of the ends of the bone. When shortening occurs I think it is always, or almost always, the result of overlapping of the fragments.

a fracture of the neck, is liable to the very serious objection that the exact position of the top of the trochanter cannot, in most cases, be clearly determined.

[Bryant's ilio-femoral triangle (Fig. 228) is formed as follows: C B is the base-line, the two sides of the triangle are made up of two lines drawn from the ante-

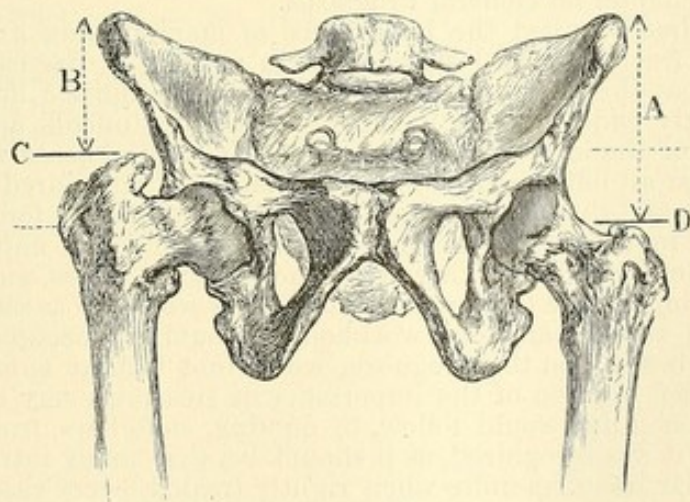
FIG. 228.



Bryant's ilio-femoral triangle.

rior superior spinous process of the ilium, one, A C, being vertical and traversing the outside of the hip to the horizontal plane of the body; and the second, A B, impinging on the tip of the trochanter major; the test-line, C B, for fracture or shortening of the neck joins the two at right angles to the vertical line and extends from it to the trochanter. The pelvis must be straight. Any shortening of this line, on comparing it with the same taken on the other side, indicates with precision a shortening of the neck of the thigh-bone. Bryant states that "compared with this line, all other measurements are uncertain." For practical purposes the vertical line A C, and the test-line C B, are alone required. In Fig. 229, the line A shows the normal length of the base of the ilio-femoral triangle, and B, the shortened base of the ilio-femoral triangle; C shows the horizontal level of the fractured bone, and D the horizontal level of the sound bone.]

FIG. 229.



Elevation of trochanter of fractured bone. (Bryant.)

The method most generally practised, is to measure from the round end of the anterior superior spinous process of the ilium to the internal or external malleolus; but even this is not very trustworthy. It is exceedingly difficult to note accurately the same point upon the two sides; and an error of half an inch is very common when this method is adopted.

The patient should repose upon his back, upon an even surface, with the lower extremities as nearly as possible in line with the axis of the body, the two wings of the pelvis being in the same (horizontal) line. A flexible, but firm, graduated tape is to be preferred to the steel tape measure. The foot being steadied by an assistant, the surgeon should put his thumb-nail against the line where it joins the ring, and push his nail into the skin just *below* the anterior superior spinous process of the ilium, pressing firmly up and back, the flat surface of the nail resting upon the skin. In this way he will obtain a fixed point, and he can obtain an exactly corresponding point upon the opposite side. Below, the measurement may be made from either malleolus, but the outer has the most defined extremity, and is generally to be preferred. In most cases, for some months after the termination of the treatment, there is some swelling about the ankle, which renders it necessary to use great care in defining the point of the malleolus. The thumb-nail of the opposite hand may be used for this purpose, resting vertically upon the skin (flat against the lower end of the malleolus). The same method may be employed in measuring a leg as in measuring a thigh.

Allusion has already been made in the chapter on General Prognosis to the fact that the bones of the lower extremities, as well as other long bones, are not always, nor perhaps generally, in the normal condition, of exactly equal lengths. J. G. Garson, of London, in the examination of seventy skeletons, ranging from twelve years upward, found only ten per cent. which were of exactly equal length.¹ Corydon La Ford, Professor of Anatomy at Ann Arbor, however, in the measurement of skeletons, found the inequality of the length of the lower limbs exceptional rather than as constituting the rule. Garson and Wight agree that the left leg was most often the longest. In Garson's measurements the left leg was longest in 38 cases, and the right in 25 cases. In most cases these differences are slight, but occasionally they are considerable. As to the practical deductions to be made from this fact of asymmetry, it has been sufficiently considered in the chapter on General Prognosis.

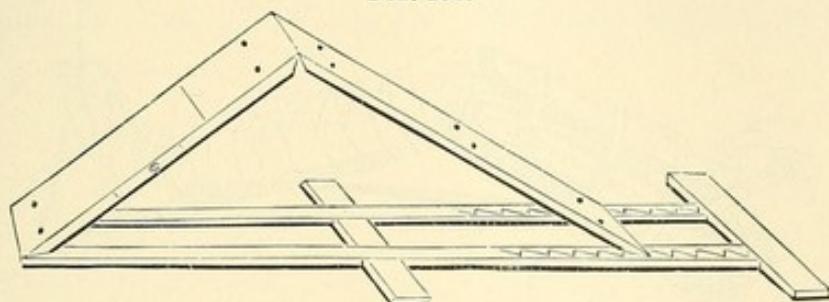
[We have already urged the importance of manipulating a thigh which is supposed to be fractured the least possible in making a diagnosis. Bryant, of London, enforces this precaution in the following emphatic language: "If it were as distinctly understood as it should be by all students and practitioners that a fracture of the neck of the thigh-bone can be diagnosed without seeking for crepitus, that all but the gentlest manipulation of an injured hip is likely to prove injurious, and that any attempt to elongate the limb by forcible extension, to flex it, or to rotate it with the view of restoring it to its natural position is likely to be followed by a breaking up of the impacted bones, and consequently by irreparable injury, the treatment of these cases would be as satisfactory in its results as it is simple, and our workhouses would be occupied with fewer cripples." As bearing on the prognosis, we cannot forbear enforcing our previously expressed opinion of the importance of treating every case of fracture of the thigh as if union would follow, by quoting, as follows, from Mr. Bryant: "If, moreover, it was recognized, as it should be, that many intra-capsular and all extra-capsular fractures unite when rightly treated, every case of fracture of the neck of the femur, impacted or non-impacted, intra- or extra-capsular, in the young, middle-aged, or old, would be treated as if repair and union were sure to take place if the parts are kept at rest and in apposition, and in the large proportion of cases the hopes of the surgeon will not be disappointed."]

Treatment.—All the early surgeons, so far as we know, adopted the straight position in the treatment of fracture of this bone, either with

¹ Garson, Amer. Journ. Med. Sci., Oct. 1879, from Journ. Anat. and Phys., July, 1879. vol. xiii. p. 502.

simple lateral splints, or with long splints, with or without extension, or with only rollers and compresses, or with extension alone. Such was the unanimous opinion and practice of surgeons until about the middle of the last century, at which time Percival Pott wrote his remarkable treatise on fractures, a work distinguished for the originality and boldness

FIG. 230.

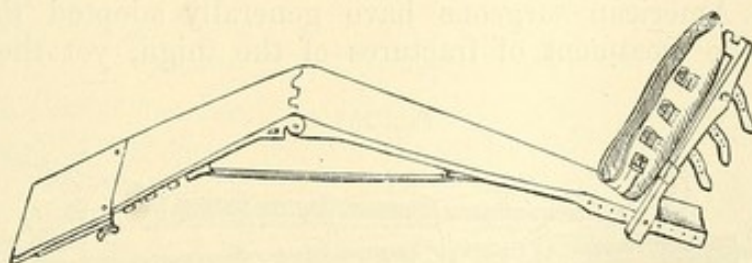


Double inclined plane formerly employed in Middlesex Hospital, London.

of its sentiments, and which was destined soon to revolutionize, especially throughout Great Britain, the old notions as to the treatment of fractures, and to establish in their stead, at least for a time, what has been called, not inappropriately, the "physiological doctrine," the peculiarity of which doctrine consisted in its assumption that the resistance of those muscles which tend to produce shortening can generally be sufficiently overcome by posture, without the aid of extension; and that for this purpose, for example, in the case of a broken femur, it was only necessary to flex the leg upon the thigh, and the thigh upon the body, laying the limb afterward quietly on its outside upon the bed.

Very few surgeons, even of his own day, ever gave in their full adhesion to the exclusive physiological system as taught and practised by Pott himself; but multitudes, especially among the English, adopted in general his views, only choosing to place the patients upon their backs rather than upon their sides, and laying the limbs flexed over a double inclined plane. To the support of this system of Pott's, thus modified, Sir Astley Cooper, C. Bell, John Bell, Earle, White, Sharp, and Amesbury, lent the influence of their great names, and its triumph, so far as the judgment of British surgeons was concerned, soon became complete.

FIG. 231.

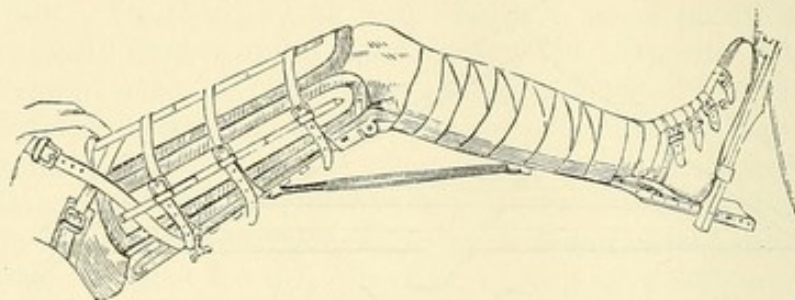


Amesbury's splint.

In France, and upon the Continent generally, the reception of this system was more slow and reluctant; but Dupuytren, now for once taking ground with his great rival, Sir Astley Cooper, adopted almost without qualification these novel views. The decision of Dupuytren determined the opinions of a large portion of the Continental surgeons; and had it not been for the early and decisive opposition of Desault and Boyer, the great surgeon of St. Bartholomew might

have continued for a long time to enjoy a triumph upon the Continent, and perhaps throughout the world, equal to that which had already been decreed to him in Great Britain. On this side of the Atlantic, the practice of Pott, at least in so far as it applied to the treatment of fractures of the thigh, never gained a distinguished advocate; and but few ever adopted the practice as modified by White, Amesbury, Bell, A. Cooper, etc.

FIG. 232.



Amesbury's splint applied.

But whatever may have been the early success of these doctrines, either here or elsewhere, it is certain that a strong reaction has taken place, and that gradually, in all parts of the world, the opinions of practical surgeons have been settling back into their old channel. It would be difficult to find to-day, in France or Germany, a dozen distinguished surgeons who adopt universally the flexed position in the treatment of fractures of the femur; and in England the reaction is, if possible, even more complete.

There have been, then, three grand epochs in the history of the treatment of fractures of the thigh.

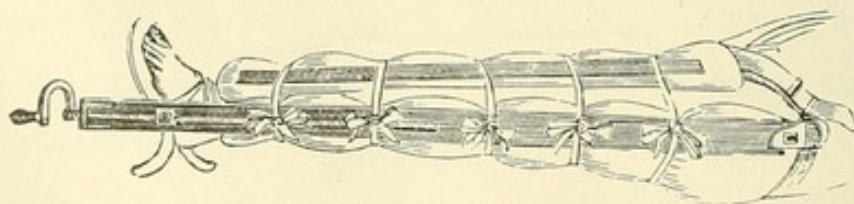
First. That in which the straight position was universally adopted, and which reaches from the earliest periods to the period of the writings of Pott, or to about the middle of the last century.

Second. The epoch of the flexed position, which, inaugurated by Pott, had already begun to decline at the beginning of the present century, and which may be said to have been completed within less than one hundred years from the date of its first announcement.

Third. The epoch of the *renaissance*, or that in which surgeons, by the vote of an overwhelming majority, have declared again in favor of the straight position. This is the epoch of our own day.

Although American surgeons have generally adopted the straight position in the treatment of fractures of the thigh, yet the form and

FIG. 233.



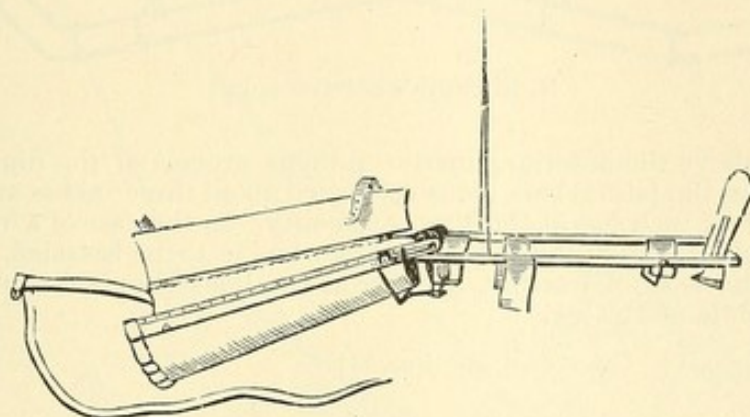
Boyer's splint.

construction of the splints employed have been greatly varied. The simple long splint of Desault, and the more complicated apparatus of Boyer (Fig. 233) have each had their advocates; but it is seldom that we

meet with these, or with any of the other forms of apparatus originally employed in foreign countries, without noticing that they have been subjected to considerable modifications; indeed, most of the straight splints as well as double inclined planes in use at present among American surgeons may fairly be regarded as original inventions.

Nathan Smith, of New Haven;¹ Nathan R. Smith, of Baltimore;² Dr. James McNaughton, of Albany;³ J. T. Hogden, of St. Louis; and Nott, of Mobile, are

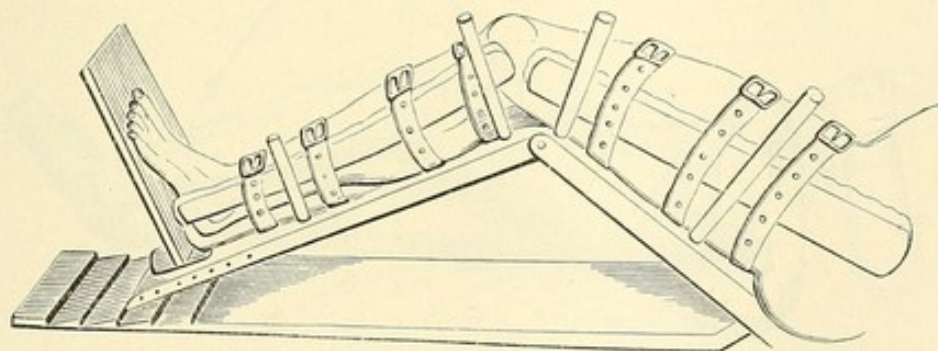
FIG. 234.



Nathan R. Smith's suspending apparatus, or double inclined plane.

the only American surgeons of distinguished reputation, and with whose practice I am familiar, who have recommended exclusively the double inclined plane.

FIG. 235.



Joseph C. Nott's double inclined plane.

In this apparatus the limb is secured to the splint by vertical pins and leather straps; the upper surface of the thigh-splint is carved out a little, to fit the thigh; the two portions are articulated by a joint like that of a carpenter's rule, and this joint may be steadied by a horizontal bar underneath. For the rest, the drawing sufficiently explains itself.

Dr. Nathan R. Smith has introduced a modification of the double-inclined plane in what is known as his "anterior splint," and which is intended also as a suspending apparatus. I saw it employed a good deal in the treatment of gun-

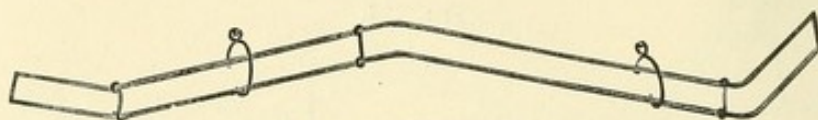
¹ Amer. Med. Rev., Philadelphia, 1825, vol. ii. p. 355; also Medical and Surgical Memoirs of Nathan Smith, pp. 129-141.

² Med. and Surg. Memoirs, pp. 143-162. See also Geddings, Baltimore Med. and Surg. Journ., vol. i. 1833; and Sargent's Minor Surgery, p. 171.

³ Trans. Amer. Med. Assoc., vol. x. p. 317. Rep. on Deform. after Frac.

shot fractures of the thigh and leg in our various military hospitals during the progress of the civil war, especially at the South. It is my opinion, however, that it is more applicable to gunshot fractures of the leg than to those of the thigh. The splint, if splint it can be properly called, is simply a frame composed of stout wire and covered with cloth, which, being suspended above the limb, allows the limb to be suspended in turn to it by rollers; the rollers passing around both limb and splint from the foot to the groin. Wire of the size of No. 10 bougie is usually employed. The length of the splint should be sufficient to

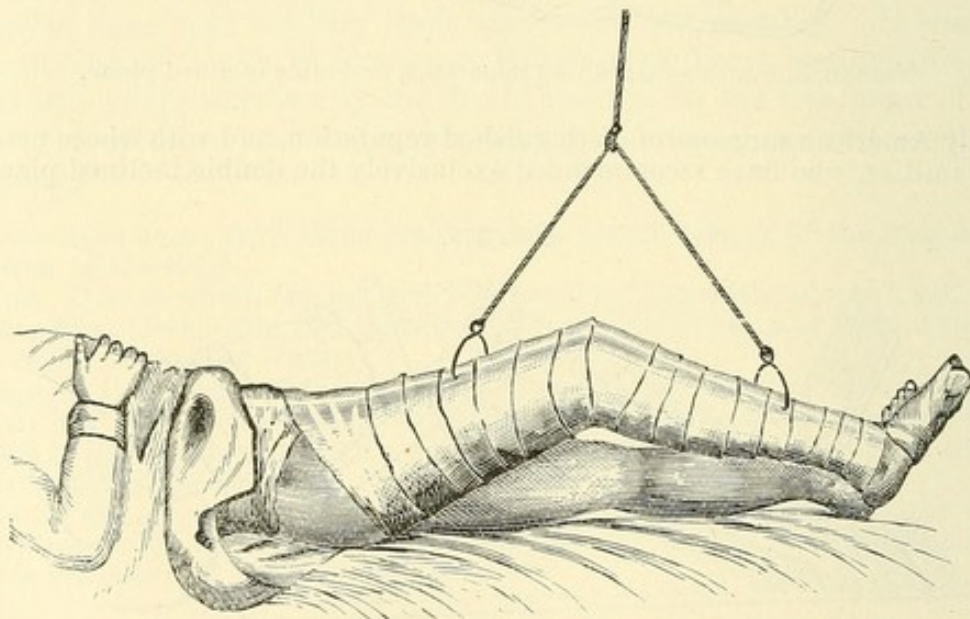
FIG. 236.



N. R. Smith's anterior splint.

extend from above the anterior superior spinous process of the ilium to a point beyond the toes, the lateral bars being separated about three inches at the top and one-quarter of an inch less at the lower extremity. In the case of a broken thigh, the upper hook, to which the cord for suspension is to be fastened, ought to be nearly over the seat of fracture, and the lower hook should be placed a little above the middle of the leg.

FIG. 237.



N. R. Smith's anterior splint, applied for a fracture of the thigh.

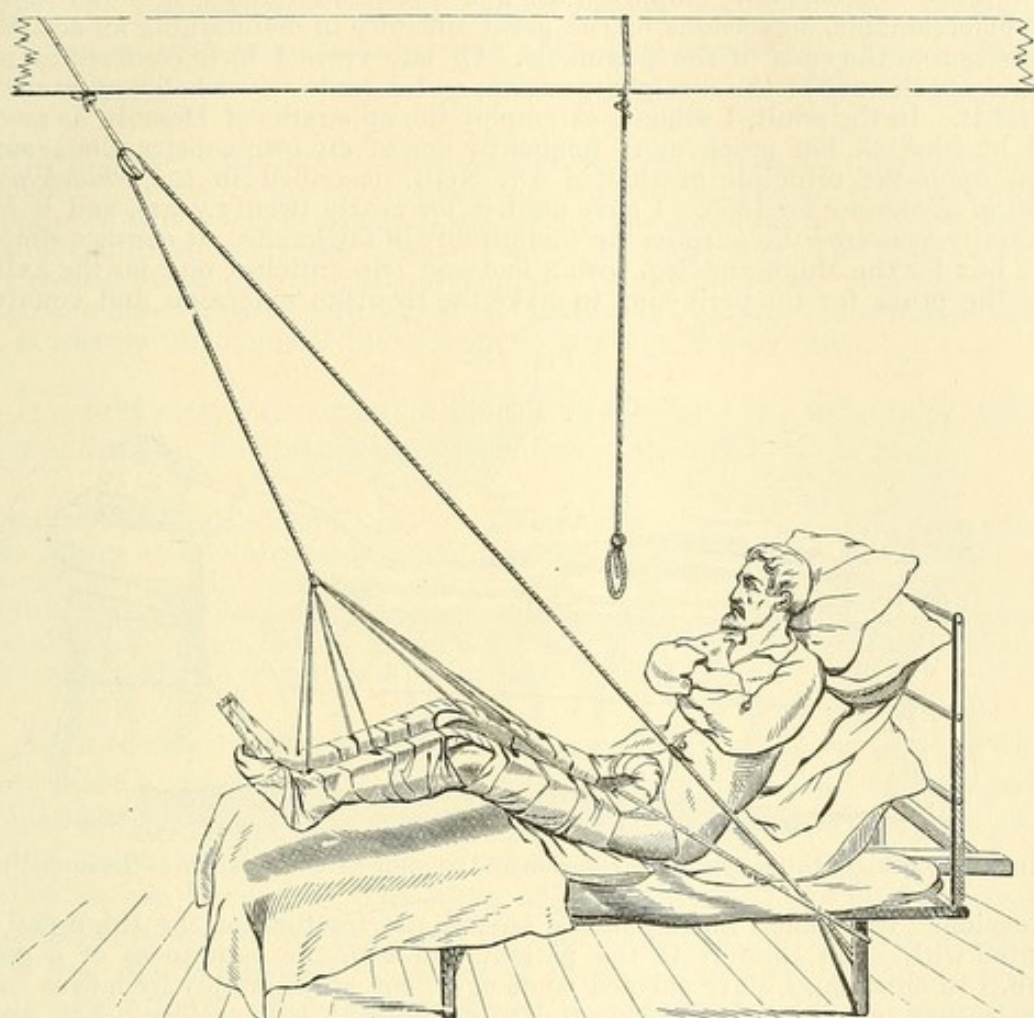
The modification of Smith's anterior splint, suggested by Dr. James Palmer, United States Navy, will be sufficiently explained by the accompanying woodcut,¹ Fig. 237.

Hodgen, of St. Louis, Mo., has for many years employed a wire suspension splint, which I much prefer to Smith's. The bars of wire are traversed with a cotton sacking, upon which the limb is laid.² I regret that in earlier editions, when referring to this apparatus, I have spoken of it as having been employed by Dr. Hodgen in gunshot fractures alone, while in fact it is employed by him in all, or nearly all, fractures of the femur. The error came, probably, from the circumstance that I had myself seen it used only for gunshot fractures.

¹ Amer. Journ. Med. Sci., 1865; also, Mechanical Therapeutics, etc., by Philip S. Wales M.D., U. S. N., 1867.

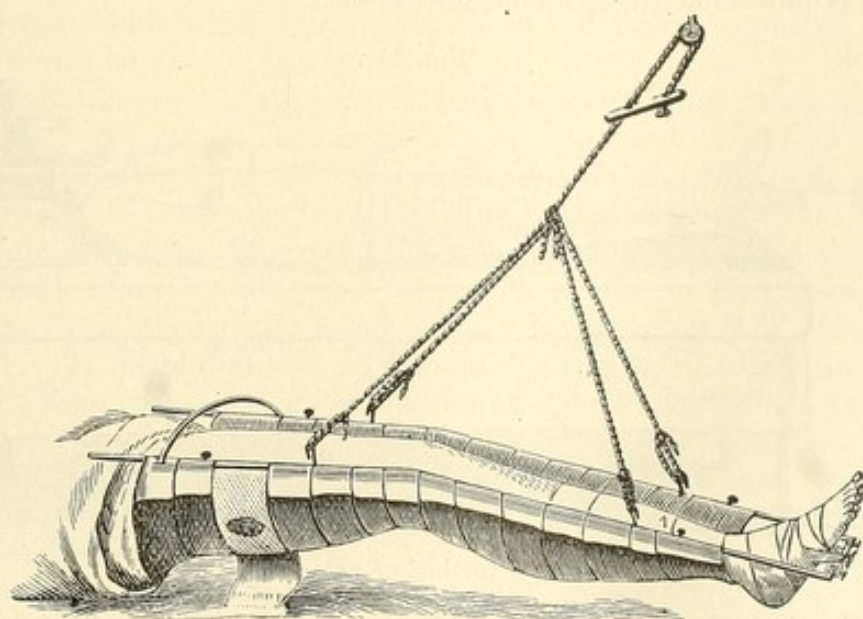
² Hodgen, Treatise on Military Surgery, by F. H. Hamilton, 1865, p. 411.

FIG. 238.



Palmer's modification of the anterior splint.

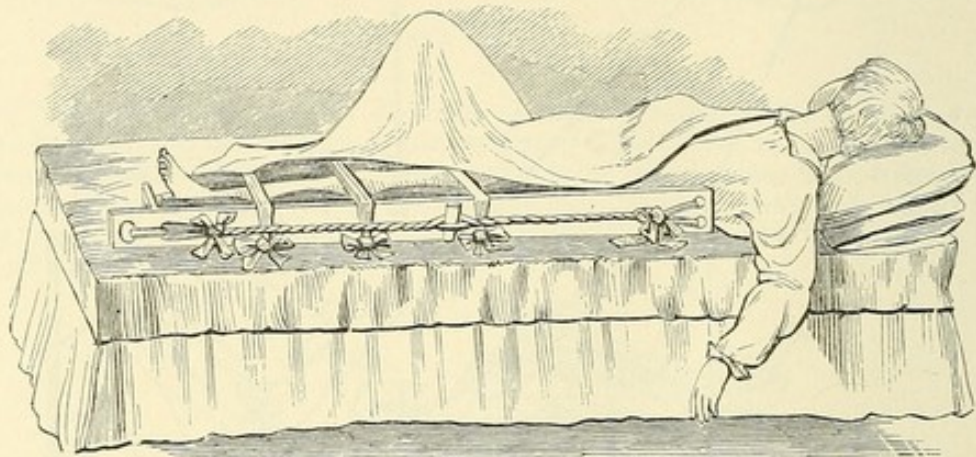
FIG. 239.



Hodgen's suspension apparatus.

Says Dr. Gross: "Many years ago, before I had much experience in this class of injuries, I occasionally employed the flexed position, but I soon found that it was objectionable, on account of the great difficulty in maintaining an accurate apposition to the ends of the fragments. Of late years I have confined myself entirely to the use of the straight position, and I have never had any cause to regret it. In the adult, I sometimes employ the apparatus of Desault, as modified by Physick, but much more frequently one of my own construction, somewhat upon the principle of that of Dr. Neill, described in the *Philadelphia Medical Examiner* for 1855. I have used it for nearly twenty years, and it has generally answered the purpose most admirably in my hands. It consists simply of a box for the thigh and leg, with a foot and two crutches, one for the axilla and the other for the perineum, to make the requisite extension and counter-

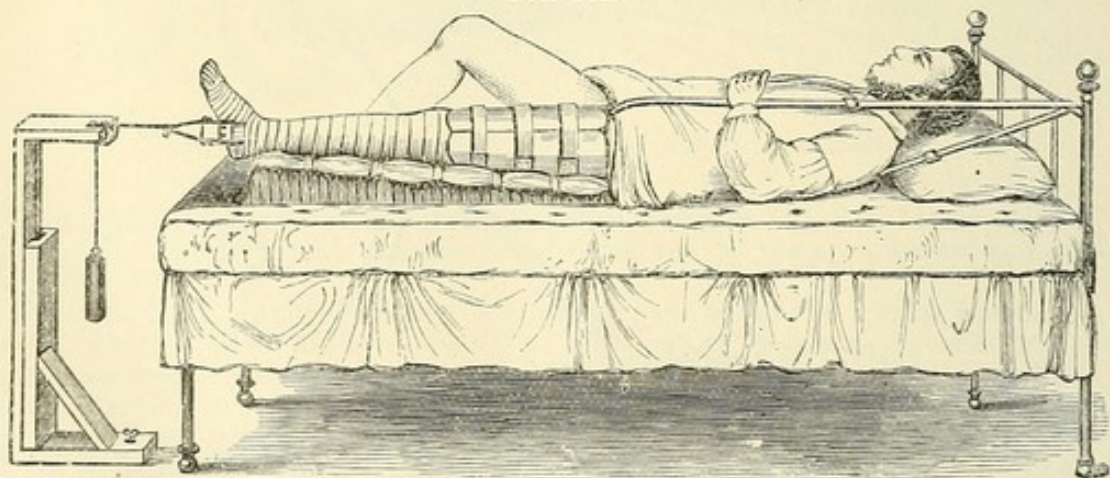
FIG. 240.



John Neill's straight thigh-splint.—Extension and counter-extension made at the same time.

extension. With such an apparatus, an oblique fracture of the thigh can be treated with great comfort to the patient, and with the assurances of a good limb. In children, I have effected some excellent cures simply by means of a sole-leather trough, well padded, and provided with a foot-piece. The great objection to the flexed position is the difficulty of keeping the ends of the broken bones in apposition; the upper one having a constant tendency to pass away from the inferior. Other objections might be urged against the flexed position, but this is quite sufficient to induce me to reject it."¹

FIG. 241.



Buck's method of extension.

Dr. Gurdon Buck, of New York, used the pulley, without the long side-splint. His perineal band was composed of India-rubber tubing, "of

¹ Trans. Amer. Med. Assoc., vol. x.; also System of Surgery, by S. D. Gross, 1859, p. 221.

one-inch calibre, two feet in length," stuffed with bran or cotton lamp-wick, and covered with canton flannel, which covering may be renewed as often as may be necessary; the extending bands or adhesive plasters terminating below the foot in an elastic rubber cord. (Fig. 240.)

The practice of treating fractures of the thigh, as well as all other fractures of the long bones, with the roller alone, and without either lateral splints or extending apparatus, first suggested by Radley, has found in this country but one distinguished advocate, the late Dr. Dudley, of Lexington, Ky.¹ Nor, with all my respect for that truly great surgeon, can I persuade myself that the practice is able to accomplish in any degree the indications proposed, nor indeed that it is, at least in the hands of inexperienced surgeons, wholly safe.

It would seem almost superfluous to defend the use of side or coaptation splints in the treatment of fractures of the shaft of the femur.

Radley, of England, and Dudley, of Kentucky, treated these fractures without side splints and without extension. In 1844 Jobert, at l'Hôpital St. Louis, employed only extension without side splints. Swinburn, of Albany, rejects side splints in all fractures of long bones, relying solely upon extension; and recently, Kronline, of Zurich, has recommended in the treatment of fractures of the thigh extension with the weight and pulley, without side splints.

Against side splints, considered independently of the means by which they must necessarily be maintained in position, there can be no possible objection. It is only the constriction, and obstruction to the free circulation caused by the bandages which bind them to the limb, to which any objection can be made. The same objection would hold against a roller applied directly to the skin, but in a much greater degree, inasmuch as it is less easily removed or loosened in case the swelling increases the bulk of the limb. This I have always considered a valid objection to the roller applied immediately to the skin to this or in any other fracture, and as of one of the reasons why the plaster-of-Paris dressings or any other form of immovable dressing is relatively unsafe. In a degree, also, this objection holds against the continuous roller as a means of holding the splints in place.

If side splints are light, properly adapted to the limb, with no rough or unequal bearings; if they are not bound too tightly to the limb; if they can be loosened or removed without disturbing the limb and are not continued beyond the period of their usefulness, they can do no harm, while they give important aid in preventing motion at the seat of fracture and in maintaining the fragments in line. This is especially true in fractures occurring through the middle portions of the shaft of the femur. If absolute quiet to the limb could be insured during the period of union, while asleep and while awake, if the patient had never occasion to move his head, shoulders, or nates, the protection usually afforded by side splints would be less needed; but even then the conical-shaped limb would find a very unequal and inadequate support upon the straight surface of the mattress. In short, the omission to employ side splints in most simple fractures of the shaft of the femur would greatly

¹ Amer. Journ. of the Med. Sci., vol. xix. p. 270; Transylvania Journal, April, 1836; Boston Med. and Surg. Journ., vol. xxxix. p. 35.

increase the danger of non-union and of deformity, and would therefore be inexcusable.

[Dr. Van Slyck¹ states that he has been very successful in treating fractures of the thigh without splints. He resorts to extension and counter-extension, with sand-bags to support the foot in position. The extension is by plaster applied to the leg in the usual way, but instead of a weight to the foot he fastens the rope to the foot of the bed. For counter-extension he uses rubber tubing passed over the groin and around the thigh, the ends meeting at the head of the bed, where they are fastened as at the foot.]

The treatment of these and other fractures by plaster-of-Paris, paste, starch, or dextrine has been already considered when speaking of the treatment of fractures in general. Thus far my experience will not warrant me in recommending the immovable apparatus, as a general plan of treatment in fractures of the thigh.

In order to assure myself as to whether we were able to make longer and straighter thighs by the use of the plaster of Paris than by the method of extension as employed by myself and others, my later experience has been carefully collated, but not selected; every case in which the opportunity was afforded being recorded, and the results being confirmed by my own testimony and the testimony of others. Of the cases treated by plaster of Paris, and recorded in the accompanying tables, a majority were from the hands of other surgeons, and all were hospital cases; in almost every instance the surgeon treating the case having had a large experience in the use of plaster. With very few exceptions, the plaster was applied while the patient was under the influence of ether. After the plaster was applied most of the patients walked about with crutches; but there were pretty frequent examples in which, for one reason or another, this was found impracticable, and the patients remained in bed. The amount of shortening has six times exceeded one inch. A considerable bend at the seat of fracture has occurred six times; ankylosis of the knee, requiring surgical interference, has occurred six times, and in almost all cases it has been more troublesome than it is usually found to be after other plans of treatment; once gangrene, amputation, and death followed, and once abscesses of the leg, paralysis, etc.

The cases reported as treated without plaster were all treated by myself. The method adopted being in the case of adults essentially that which is known as Buck's extension, but which I have, as will hereafter be seen, considerably modified. In the case of children, the method has been uniformly that which I shall hereafter describe in its proper place as the method preferred by me in these cases; permanent extension, such as is used in Buck's apparatus, being very seldom employed. Not one of these limbs has presented an excessive shortening—one inch being the maximum. Not one is bent at the point of fracture. None of the patients had bedsores, or troublesome ankylosis at the knee-joint. In one there was delayed union. Case 23 has been measured by many of the gentlemen connected with Bellevue, and all agree that the broken limb is longer than the other, yet it united promptly, and he walks without a halt. We have been unable, thus far, to find any other explanation of the increased length except the now well-established fact that the normal lengths of thighs and of other long bones are pretty often unequal, and that probably this limb was originally longer than the other. The experiments of Reid² and of others have conclusively shown, I think, that it is impossible, unless at least fifty or one hundred pounds were employed in the extension, to stretch the muscles beyond their normal length. If a limb after fracture and bony union is found longer than its fellow, no doubt it was longer before the fracture. Five children and one adult had perfect limbs; or, if we are permitted to include the case in which the limb is lengthened, two adults have recovered with perfect limbs.

¹ Boston Med. and Surg. Journ., Jan. 29, 1885.

² Reid, W. W., Buffalo Med. and Surg. Journ., vol. vii. p. 134, Aug. 1851.

CASES TREATED WITH PLASTER-OF-PARIS, CONTINUOUS ROLLER.

No.	Age.	Character of fracture.	Point of fracture.	Hospital.	Amount of shortening.	Deformity.	Remarks.
	Yrs.				Inches.		
1	11	Simple.	Middle.	Bellevue.	$\frac{3}{4}$	{ Slightly bent.	Ankylosis of knee
2	15	"	"	St. Francis.	$\frac{3}{16}$		
3	16	"	"	Park.	$1\frac{1}{2}$	Much bent.	{ Ankylosis broken up under ether.
4	17	"	"	99th Street.	1		
5	12	{ With frac. of legs.	{ Below troch. }	Park.	1	" "	{ Ankylosis broken up under ether.
6	16	Simple.	"	Bellevue.	$\frac{3}{16}$		
7	7	"	Middle.	"	$\frac{1}{16}$		
8	39	"	"	"	1		
9	37	"	"	"	1		
10	63	"	Extracap	"	$\frac{1}{16}$		
11	26	"	Middle.	Park.	$\frac{4}{16}$		
12	24	"	"	"	$1\frac{1}{4}$		
13	25	"	"	"	1		
14	36	"	"	"	$1\frac{1}{8}$	Ankylosis.
15	21	"	"	Bellevue.	$1\frac{1}{16}$	"
16	26	"	"	"	$\frac{3}{16}$		
17	29	"	"	"	$\frac{4}{16}$		
18	24	"	"	"	$\frac{3}{16}$	Delayed union.
19	39	"	"	99th Street.	$1\frac{3}{4}$		
20	70	"	"	Bellevue.	No union.
21	44	Compound.	"	"	2	Bent.	
22	66	Simple.	"	"	1	Much bent.	Ankylosis.
23	50	"	"	"	1	Bent.	
24	22	"	"	"	$\frac{3}{16}$	Ankylosis.
25	33	"	Extracap.	"	$\frac{3}{16}$		
26	23	"	{ Below troch. }	"	Perfect.		
27	27	"	"	"	$1\frac{1}{2}$	{ Paralysis, abscess, etc.
28	46	"	{ Above cond. }	{ Park.	$\frac{5}{16}$		
29	51	Compound.	"	Bellevue.	$\frac{1}{2}$		
30	23	Simple.	Middle.	99th Street.	{ Gangrene, amputation, death.

It will be seen that this table includes two cases in which serious results ensued. In Case 30 gangrene supervened on the third day after the accident, and on the second after the dressings were applied; amputation was made, and the patient died. In Case 27 the plaster was applied on the fifth day after the accident (November 13, 1873), and removed twenty days later, when the patient found he had no sensation in the limb below the knee; the leg was also much swollen below the knee. Subsequently abscesses formed in the leg, large sloughs occurred, and the calcaneum became carious.

These two constitute the only examples of serious accidents which might possibly have been due to the mode of dressing, in the table of 30 cases, which, as has already been explained, were recorded without selection; but they are not all which have come under the writer's notice. In one case at Bellevue an enormous perineal slough was caused by the pressure of the plaster. In addition, also, to the case of gangrene and death included in the first of the preceding tables, the following have to be recorded:

L. G., æt. 24, fell upon the sidewalk and broke her thigh about six inches above the knee-joint. She was carried to Bellevue Hospital, and on the same day, under the influence of ether, and with limb extended by pulleys, plaster dressings were applied. Twenty-four hours later the toes looked dark, and the splint was opened about the foot. On the following morning the house surgeon found the limb cold, and sensation greatly impaired. The dressings were at once opened freely. Death took place on the third day.

CASES TREATED BY MYSELF, BY MY OWN AND BUCK'S METHODS.

No.	Age.	Character of fracture.	Point of fracture.	Hospital.	Amount of shortening.	Deformity.	Remarks.
	Yrs.				Inches.		
1	2	Simple.	Middle.	Bellevue.	$\frac{1}{4}$	Straight.	
2	6	"	"	"	Perfect.	"	
3	4	"	"	Private.	$\frac{2}{3}$	"	
4	6	"	"	"	Perfect.	"	
5	10	"	"	Bellevue.	"	"	
6	9	"	"	"	$\frac{1}{4}$	"	
7	15	"	"	"	$\frac{1}{4}$	"	
8	5	Compound.	"	"	Perfect.	"	
9	18	Simple.	"	"	"	"	
10	33	"	"	"	$\frac{2}{3}$	"	
11	20	"	"	"	$\frac{2}{3}$	"	
12	50	"	"	"	$\frac{4}{12}$	"	
13	35	"	"	Long Is. C.	$\frac{4}{12}$	"	
14	60	"	Intracap.	Park.	$\frac{3}{8}$	"	
15	50	"	Extracap.	"	1	"	
16	40	"	"	Bellevue.	$\frac{3}{8}$	"	
17	40	"	"	"	1	"	
18	35	"	"	"	$\frac{3}{8}$	"	
19	40	"	"	"	$\frac{1}{2}$	"	
20	60	"	"	Long Is. C.	$\frac{1}{2}$	"	Toes everted.
21	45	"	"	Private.	$\frac{1}{2}$	"	" "
22	70	"	Neck.	"	$\frac{1}{2}$	"	" "
23	40	"	Middle.	Bellevue.	Lengthened.	"	
24	22	"	Above knee	"	"	Delayed union.

C. G., æt. 62, admitted to Bellevue Jan. 2, 1871, with a fracture of the cervix femoris, which had just occurred from a fall on the ice. On the fourth day plaster-of-Paris was applied with the aid of ether and pulleys. Two days later the record reads: "Patient has a large sore on sacrum, extending almost to the loins; splint taken off; extremities cold and blue; pulse felt with difficulty; suffering from some dyspnoea; lungs emphysematous, and old fracture (?) somewhere; this P. M. he died."¹

The two following cases deserve to be mentioned in this connection, inasmuch as the class of casualties to which they belong are chiefly incidental to the plaster-of-Paris method. In no other form of dressing have anæsthetics been employed so universally:

J. S. was admitted to Bellevue Hospital with a fracture of the left femur below the trochanter. Buck's extension was applied at first, and on the eighteenth day the patient was placed under the influence of ether, the pulleys attached, and the application of the plaster commenced. The breathing was soon observed to be gasping. Ether was withheld a few minutes, when, as the breathing became regular, it was resumed. Soon after the pupils rapidly dilated, the breathing ceased, and in a few minutes more, in spite of every effort to resuscitate him, death supervened. There is every evidence to sustain the opinion that the ether was given carefully and in the usual manner.²

In the case of M. S., No. 11 of the second table, ether was administered for the purpose of applying plaster; and while extension with pulleys was employed, and the bandages were being applied, "she suddenly ceased to breathe, and her face became purple." By prompt resort to various expedients, including Marshall Hall's method, Sylvester's method, and electricity, she was rescued. "Dr. Figaro thinks her respiration was completely suspended for two or three min-

¹ A Comparison of the Results of Treatment of 308 Cases of Fracture of the Femur, etc., Bellevue Hospital, by Frederick E. Hyde, M.D., New York. New York Med. Journ., October, 1874, p. 368.

² Death from Ether, by W. B. Dunning, M.D., Acting House Surgeon, Bellevue Hospital. New York Med. Record, October 1, 1872.

utes."¹ The attempt to apply plaster was then abandoned, and Buck's extension substituted, with the result of giving her a limb shortened only three-eighths of an inch.

A danger in the use of plaster-of-Paris as a dressing for compound fracture of the femur has not hitherto been mentioned, namely, that in case of a secondary hæmorrhage from the femoral artery, it would be impossible to compress the artery over the pubes, in Scarpa's space, or at any other suitable point, and the patient might die before succor could be given. In cases of compound fracture of the femur, from gunshot injuries, such secondary hæmorrhages are not very uncommon; and such a hæmorrhage has occurred when the femur has been broken very obliquely, and thrust through the flesh, and has in its course so contused the femoral artery, or has passed so near to it as to have caused a subsequent sloughing of the artery. I do not see how one is to provide for such a possible accident, since a fenestra opposite the wound would not give space sufficient to secure the bleeding vessel, and a sufficient fenestra over the groin might so much weaken the splint as to render it of little or no value. The accident has occurred, and may occur again; the surgeon ought, therefore, in case he uses the plaster after a compound fracture, so far as possible, to provide an opening sufficient for a free approach to the upper portion of the femoral artery, in order that pressure could be applied and the bleeding controlled until the vessel was secured. In no other limb than the thigh is this danger so imminent, for the reason that nowhere else are the vessels which are liable to rupture so large.

It has been almost the constant practice of late, in this country, to employ ether and the pulleys while applying the plaster, and this is considered one of the great essentials to success. It is proper, then, to put into the account, as against this method, the danger from anæsthetics; and to inquire, perhaps, whether the usual danger attending the exhibition of these agents is not increased by the condition of forced decubitus, and of extension to which the patients are subjected while the plaster is being applied.

Dr. Gibbes, of Columbia, S. C., furnishes the first opportunity yet presented to me to observe in the autopsy the result of treatment in a case in which plaster-of-Paris has been employed according to the method just described. W., æt. 83, weighing 165 pounds, enjoying robust health, fell upon the right hip, causing a fracture of the right femur just below the trochanters. Fifteen hours after the accident, Dr. Gibbes applied "the plaster-of-Paris dressing after the well-known method in vogue for several years past in Bellevue Hospital, my venerable patient being kept for some time suspended above the table and fully under chloroform." On the fourth day he made an attempt to walk, but the attempt was not resumed until about the eighteenth day, after which "he began to walk around his room daily." The apparatus was removed on the forty-third day. The union was firm, and the limb appeared to be shortened three-quarters of an inch, as determined by several careful measurements. On the 29th of June, about six months after the accident, he died of apoplexy. At the autopsy it was found that the femur was broken just below the trochanters into three fragments.

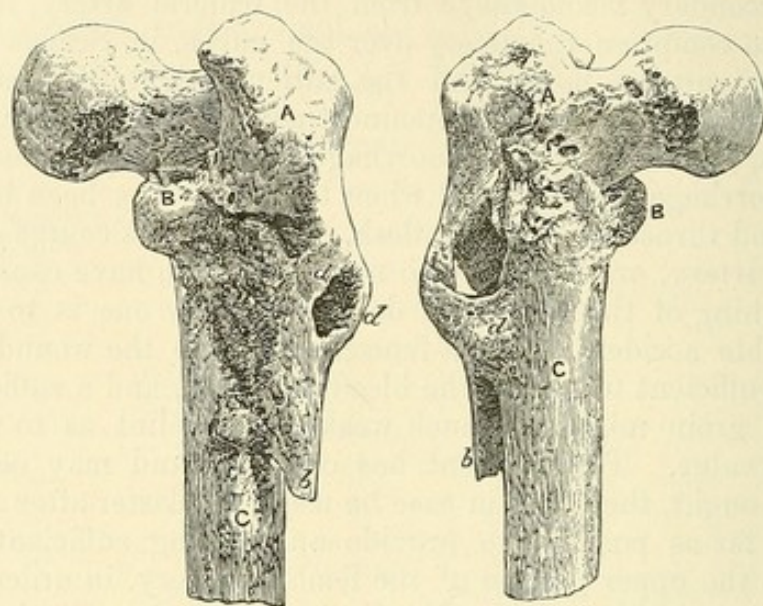
In this case there is, according to the measurements made before death, a shortening of three-quarters of an inch. An examination of the specimen convinces me that it is somewhat more; but however this may be, one thing is certain, the limb shortened to the same degree that it would have done if no apparatus whatever had been employed. It shortened until the upper end of the lower fragment struck and was arrested by the neck. The apparatus enabled

¹ New York Med. Journ., August, 1874, p. 134.

the patient to walk sooner than he could otherwise have done; and this is a consideration of more importance often in an old man than the length or form of the limb, and I doubt whether any other plan would have made the limb in this case any longer.

FIG. 242.

FIG. 243.



Dr. Gibbes's case.

Posterior view.

Anterior view.

A, B, C, three fragments; *d*, bony ridge.

It will be necessary to describe a little more in detail the method of applying the plaster-of-Paris in fractures of the thigh.

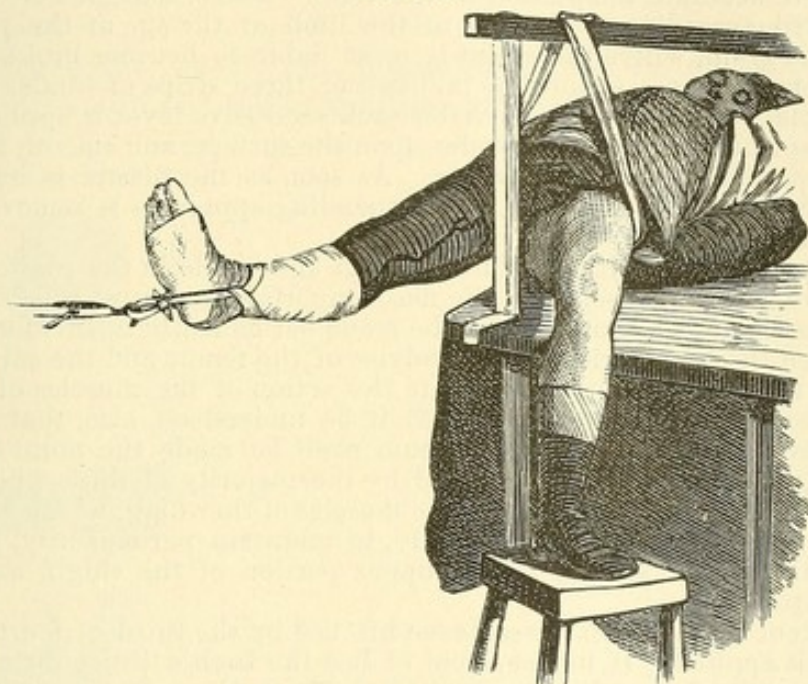
A plaster-of-Paris bandage is applied to the foot and leg some hours before the complete dressing is made. It is better that this should be done twelve or twenty-four hours before, in order that this portion of the apparatus may become solid, and not remain liable to be indented, or pressed inward toward the limb when extension is applied, and also in order that the surgeon may know by an examination of the toes after the lapse of a sufficient time that the dressing is not too tight.

This section of the apparatus should extend from a little above the metatarsophalangeal articulation of the toes to about the junction of the middle and lower thirds of the leg. Instead of the soft woollen cloth, which is generally to be preferred in the upper part of the limb, we may here lay next to the skin a sheet of cotton-batting, and this should be thicker over the instep and above the heel than elsewhere. We cannot take too many precautions in protecting the limb about the ankle from undue pressure. It will be remembered, also, that while at the ankle the splint should be thick, composed of five or six consecutive turns of the roller, it may be light upon the foot, and near the upper end of the splint upon the leg. While the dressings are being applied, and until they have hardened, the foot must be held carefully at a right angle with the leg, and in a proper line as to inversion or eversion; but the assistant must take care that he does not, with his hand or fingers, indent the plaster. A temporary congestion of the toes almost always ensues upon the application of the bandage, but this usually subsides within twenty-four hours. If it does not, the bandage is too tight, and must be cut open.

In applying the final dressings on the following day, or when the first dressing has become solid, the patient is laid upon a bed composed of two or three mattresses, or of a sufficient number of folded blankets, his loins, shoulders, and head resting upon the bed thus constructed, while his hips, thighs, and legs extend beyond the bed. In order to support the lower portion of the body in

this position a piece of a cotton roller, three inches wide and two yards long, having been lubricated with sweet oil, is passed under the pelvis, and tied above to a bar supported by a stanchion, as seen in the woodcut (Fig. 244). Various methods of supporting the pelvis have been devised, but this is the most simple and efficacious. The piece of bandage is directed to be softened with oil, in order that it may be easily withdrawn when the dressing is hard; but if it has not formed a cord this may not be necessary, and it is sometimes cut off and left inclosed with the splint.

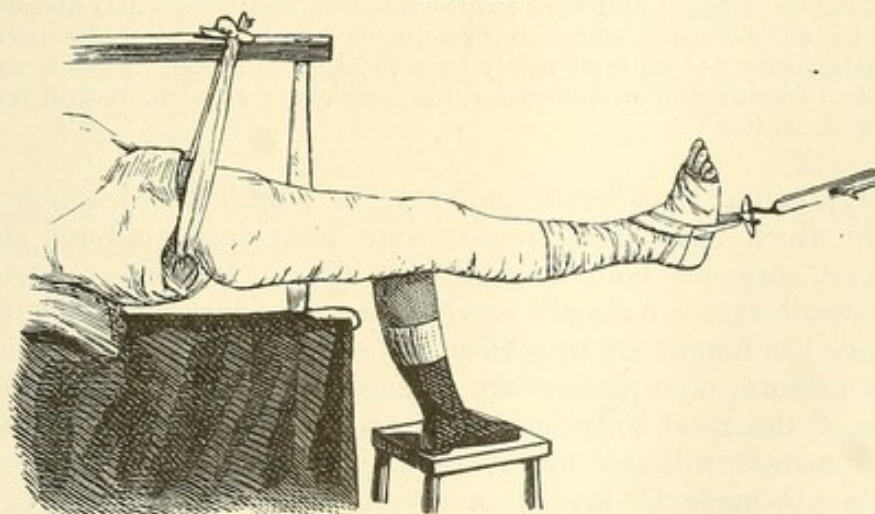
FIG. 244.



Extension during application of plaster of Paris.

The iron stanchion, wrapped with woollen cloth, is now brought against the perineum, and the pulleys made fast to the foot by a noose of cotton bandage. Moderate extension is made sufficient to support and steady the limb, but not sufficient to overcome the shortening.

FIG. 245.



Extension continued until the plaster is hard.

The surgeon now wraps the limb, including the pelvis, thigh, and leg, down to the first splint, with soft but coarse woollen cloth, cutting out portions here and there, and fitting it smoothly to all the irregularities of surface, and stitching

it loosely, when it is in place, over the region of the tuberosity of the ischium and perineum. Where the splint is liable to make undue pressure, two or three thicknesses of cloth may be placed, or cotton-batting may be used instead.

Everything being ready, the assistant places the patient completely under the influence of an anæsthetic, and then extension is made with the pulleys until the limb is restored, if possible, to the same length as the other. The bandages, filled with dry plaster, and previously soaked a few minutes in water, are then applied from below upward, including, finally, the pelvis as high as the loins. At no point must they be drawn tightly, but only with sufficient firmness to insure their accurate adaptation to the limb. Three, four, or five thicknesses are required, according to the size of the limb or the age of the patient. In front of the groin, where the splint is most liable to become broken when the patient gets up, there should be laid two or three strips of binder's board, or narrow metal strips, tin or zinc. After each successive layer is applied, the surgeon will sprinkle a little dry powder upon the surface, and smooth it over with his hand previously dipped in water. As soon as the plaster is hard, usually within twenty or thirty minutes, the suspending apparatus is removed, and the patient placed in bed.

The surgeons who omit to include the foot and ankle in the plaster splint do not, I think, avail themselves of the most important and most reliable means of making the little extension that can be made permanently in this form of dressing. When the limb shrinks, the condyles of the femur and the calf of the leg offer very imperfect or no resistance to the action of the muscles of the thigh, and extension is completely lost. Let it be understood, also, that the author does not recommend that the perineum shall be made the point of counter-extension; and in this he is sustained by the majority of those who have used this dressing; and the shrinkage of the muscles of the thigh, which soon ensues, renders it equally impossible, ordinarily, to maintain permanently, against the only slightly conical surface of the upper portion of the thigh, any effective counter-extension.

The patient can, in most cases, leave his bed by the third or fourth day after the splint is applied. If he keeps out of bed the limb will not shrink as much, and the necessity for readjustment will less often arise. But he cannot remain in the erect position all the time, and at the best there will be, as experience shows, opportunity enough for the limb to shrink, and for the apparatus to become loose. In case it becomes loose it cannot be refitted by cutting out a portion and folding the splint in again, since it is too inflexible, and will not be made to bear upon the same points as before. At Bellevue, when a plaster dressing becomes loose it is always removed and a new one applied in the same manner as at first.

[The dangers of the injudicious employment of plaster-of-Paris dressings have not been too emphatically stated in these pages, but it should not be inferred that this dressing may not be used safely by a prudent surgeon. It is a method of treatment of fractures of undoubted value, and every surgeon should familiarize himself with its use.]

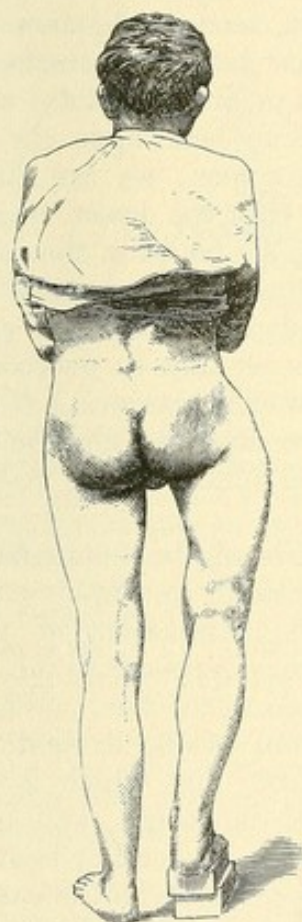
Finally, having considered somewhat at length the leading plans of treatment which have, from time to time, been suggested and employed by our best surgeons both at home and abroad, I desire to describe in greater detail those methods and forms of apparatus which my own experience has taught me to prefer.

As to posture, my opinions are in accord with the opinions of a vast majority of the most experienced surgeons of the present day. The straight position will, on the average, give the best results. Careful measurements made by myself in several hundreds of cases, a portion of which have been published in my statistical tables,¹ have demonstrated that the average shortening of the limb is greater after any method of

¹ Fracture Tables, by F. H. Hamilton, 1853.

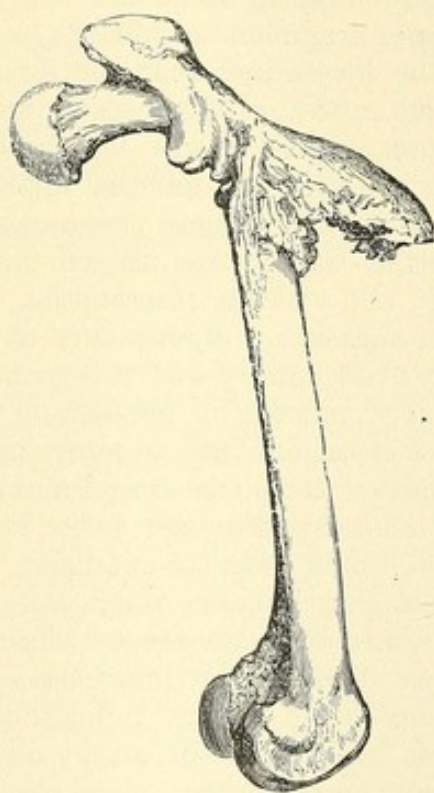
treatment in which the flexed position is employed, than after treatment with extension in the straight position. These same carefully recorded observations, and my later observations, have also shown that the flexed position, contrary to the reiterated statements of most of its advocates, is more apt to entail angular deformity. Fig. 246 is a fair illustration of what I have seen occur more than once when the flexed position has been adopted; a condition which is impossible when proper extension is employed in the straight position. There are a few who, rejecting the flexed position in fractures of the middle of the shaft, still declare for this position a preference when the fracture occurs just below the trochanters, and in the case of fractures at the base of the condyles.

FIG. 246.



Badly united fracture of the femur; treated without permanent extension.

FIG. 247.



Fracture of femur just below trochanter minor.

According to Malgaigne, who has devoted especial study to this subject, there is no satisfactory evidence in favor of the flexed position when the fracture occurs below the trochanters. It is not directly forward but forward and outward, that the lower end of the upper fragment is carried by the action of the *psoas magnus* and *iliacus internus*; so that in order to meet the supposed indication it would be necessary to carry the lower part of the limb outward also, a position which would certainly be found inconvenient, if not actually impracticable, in the majority of cases. Nor can the tendency of the upper fragment to advance in the forward direction, and consequently to separate from the lower, be met

effectually by posture alone, unless the thigh is completely flexed upon the body. Indeed, it is apparent that the position of moderate flexion will rather favor the action of those muscles which are supposed to be chiefly responsible for the displacement. When the thigh is extended upon the body, the *psoas magnus* and *iliacus internus* are acting in the direction of, and merely parallel to, the axis of the femur, and consequently to a disadvantage; but when the limb is lifted, their action is more nearly at a right angle with the shaft, and their ability to displace the fragment is greatly increased.

Moreover, it ought to be understood that broken bones are seldom or never displaced or separated, in the same manner they would be if they were not surrounded with many other structures which have suffered little or no disruption; they pass each other, but do not separate widely, being held together by shreds of periosteum, muscles, tendons, ligaments, etc. The same happens when this bone is broken just below the trochanters; the upper fragment lies always, or almost always, in immediate contact with the lower, and whatever force is brought to bear upon the lower fragment more or less directly influences the upper; we can then by extension applied to the leg, draw down not only the lower fragment, but we can drag into line the upper fragment. No doubt in this attempt we shall meet with some resistance from the muscles above named; but experience has always shown that even moderate extension, applied steadily and without interruption, seldom or never fails to overcome, in a great measure, the resistance of the most powerful muscles. We constantly avail ourselves of this principle in overcoming the abnormal contraction of muscles in connection with diseased joints, in the reduction of old dislocations, and in many other ways.

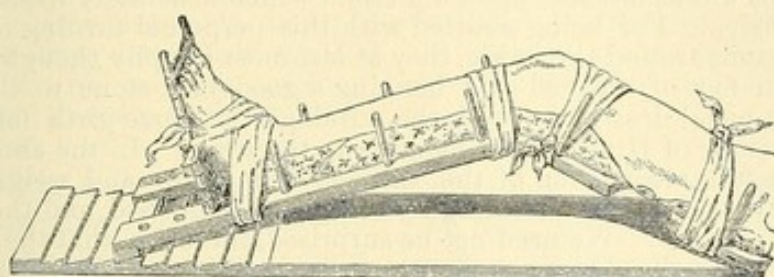
Whatever the advocates of flexion in fractures of the femur may say to the contrary, they are never able in this position to employ effective extension and counter-extension. A careful examination of all the double-inclined planes which have been devised, it appears to me, ought to convince any experienced observer that such is the fact. Whatever other excellences they may possess, this does not belong to them. But extension is, of all the indications of treatment, that which is of the greatest importance in nearly all fractures of the thigh, and no less important in the upper third than in the lower. Indeed, it is of more importance in case of a fracture through the upper than in the case of a fracture through the lower third, since, as my measurements have shown, the higher the point of fracture the greater is the tendency to shorten, in consequence of the action of those powerful muscles which, arising above, have their insertions into the lower fragment.

In the case of all those doubled-inclined planes where the body rests upon a bed, there can be no counter-extension except the weight of the pelvis and its contents. It will not do to fasten the pelvis to the bed by bands, as every one who chose to make the experiment might soon learn; nor will the groin tolerate the pressure of counter-extending splints or bands. These things have been tried in a thousand ways, and abandoned. The weight of the pelvis alone, not of the entire body, is the only counter-extending force which can be made available in these forms of apparatus, and this is wholly insufficient. In Nathan R. Smith's

anterior suspension splint, not even the weight of the pelvis is employed as a means of counter-extension, the pelvis being secured to the splint by rollers, equally with the thigh and leg, and there is no possible chance for extension or counter-extension.

[It is still maintained, by many competent surgeons, that the double-inclined plane is best adapted to the treatment of fractures just below the trochanter. If it is used the surgeon must secure extension by the fixation of the leg to the distal portion, and counter-extension by the weight of the hips resting against the lower end of the proximal portion, but not supported by it. The thigh piece should, therefore, be slightly longer than the thigh to secure proper counter-extension of the upper fragment, the lower fragment being fixed by the leg and knee. A very simple but useful double-inclined plane is that known as Esmarch's.]

FIG. 248.



Double-inclined plane. (Esmarch.)

After all, I prefer to leave this question to the verdict of experience, and happily this seems to be conclusive, if we may accept the almost unanimous testimony of those surgeons who have enjoyed the largest hospital practice. In my own experience the ordinary double-inclined planes have constantly given the worst results both in regard to length and lateral displacement; they are the most difficult to manage, and are the most fatiguing to the patients. Nathan R. Smith's suspending apparatus permits the limb to shorten indefinitely; and it affords inadequate support along the centre of the shaft, in consequence of which the limb is apt to unite with a backward curvature or angle. In some gunshot fractures treated by this apparatus this posterior curve or angle has been excessive. Even the old methods of extension were preferable to flexion; but they had always two serious drawbacks. First, in the excoriations and ulcerations incident to the application of extending bands or gaiters, or whatever else was employed for this purpose. Again and again I have seen ulceration of the instep, of the integuments above the heel, and of other parts of the foot and ankle, from extending bands. And, second, from similar excoriations, ulcerations, and deep sloughs about the groin and perineum, caused by the counter-extending band. It is true these accidents did not occur often, and sometimes they were due wholly to negligence; but, in order to avoid them, we were compelled to limit very much the amount of extension, and to exercise unceasing vigilance.

[Commingor, of Indianapolis, Ind., a strong advocate of plaster-of-Paris in the treatment of fractures of the thigh,¹ does not approve of the straight position, but prefers the flexed. He also discards the weight and pulley extension. His method of treatment consists in bringing the bones into apposition at once, then applying the plaster-of-Paris, the limb being one-third flexed at the knee and hip. When the plaster becomes hard there is no necessity for the weight, as the flexures of the limb prevent any possible shortening.]

Our first great step of progress in the treatment of fractures of the thigh—first in importance, but not in order of discovery—consists in having secured counter-extension by the weight of the body alone, and

¹ American Practitioner, 1885.

this is accomplished by simply elevating the foot of the bed from four to six inches.

I have not used a perineal band, except in cases of children, for twenty years; and, in case of children, the weight of the body is still my chief reliance. The first to suggest and practise this was Dr. James L. Vaningen, of Schenectady, New York.¹

The second step was the employment of the weight and pulley as a means of extension.

This method of making extension was known to Hildanus, in the 16th century, although it seems to have passed very much into disuse until recently revived by American surgeons.² John Bell, in his *Principles of Surgery*, published at Edinburgh in 1801, speaking of a method described by Hildanus, says: "But surgeons did at last fall upon a method which absolutely insured the permanent extension. For being wearied with this perpetual turning of screws to tighten the bands around the ankle, they at last most happily thought of putting a pulley to the foot of the bed and hanging a good jack-stone to the heel. I have (in next page) drawn the bed, the surcingle or horse-girth for the body, and the jack-stone of Hildanus for hanging to the heel." In the above description we see a full recognition of the value of the pulley and weight, but the body was prevented from descending by being tied to the bed, and the extension was made by a garter. We need not be surprised, therefore, that the pulley and weight under these disadvantages were soon laid aside and forgotten. Guy de Chauliac, Suetin, and Nathan Smith, according to Malgaigne,³ employed occasionally the pulley and weight. Boyer says the practice is very ancient. Dr. W. C. Daniell, of Savannah, Georgia, treated a case in this manner in 1819, and again in 1824, the latter of which he published. The ordinary perineal band and a garter were used for counter-extension and extension.⁴ In 1854, L. A. Dugas, of Savannah, Georgia, published an account of the method employed by himself, with an illustration.⁵ He used a piece of bandage as his means of applying extension; but he omitted the perineal band, which had not been done by Buck when he first made public his own method. Dugas relied upon the weight of the body to make counter-extension, saying that "the resistance of the patient's body will effect counter-extension;" a statement which later experience has shown to be not correct, unless, as first recommended by Vaningen, the foot of the bedstead is somewhat raised. *

The third great step of improvement, and that which alone makes adequate extension, in most cases, possible, was the substitution of adhesive strips, laid along the whole length of each side of the leg, in place of the gaiter.

Of this, also, we are no longer permitted to speak as a novelty, the researches of Dr. Martin, already referred to, having brought to light the following paragraph in the works of Dr. Gooch: "To answer the same purpose, I have confined one end of a strong strip of sticking plaster, of a suitable length and breadth, under a circular piece of the same, about the middle of the side of the foot, carrying it over the heel, up the leg, and confining the other end above the calf with another circular plaster, first, gradually bring down the muscul. gastrocnem. as far as they will readily yield; giving the limb, at the same time, the position described in my treatise on wounds. On the like occasion, I have also fixed one strap by the circular about the foot, and another by that above the calf of the leg, passing the one through a slit in the other, and using them as the

* 1 Vaningen, Trans. Amer. Med. Assoc., 1857, pp. 436-7.

2 Martin, N. C. Med. Journ., Feb. 1878.

3 Malgaigne, op. cit., p. 239.

4 Daniell, Amer. Journ. Med. Sci., vol. iv, p. 330.

5 Dugas, Southern Med. and Surg. Journ., Feb. 1844, p. 69.

uniting bandages; but then two more circulars are requisite to confine the other ends of the longitudinal straps securely."¹

This also, like extension by a pulley and weight, seems to have been forgotten until revived by some American surgeons. The first allusion I find to it in recent literature is by Dr. F. W. Sargent, of Philadelphia, in 1848, who says he derived the suggestion from Dr. E. Wallace, of Philadelphia, by whom they were used successfully while he was the Resident Surgeon of the Pennsylvania Hospital. Both of these gentlemen used long strips of adhesive plaster, of an inch or more in width, carrying them spirally down the leg from a point about midway between the foot and knee, after which they were, in some cases, made secure with rollers.² The same method is described as being recommended by Dr. Josiah Crosby, of New Hampshire, the only difference being that he carried the adhesive plaster as high as the knee.³ In this notice of Dr. Crosby's plan, the editor remarks that Dr. Sargent had in his *Minor Surgery* described essentially the same, as being first practised by Dr. Wallace. Vaningen suggested the same in connection with the elevation of the foot of the bed, in 1857. Dr. Buck spoke of it in his communication to the Academy of Medicine in 1861. Of the claims instituted for Dr. Mosely, of New Hampshire, who says his use of these strips dates back to 1840, and the like claims of Gross, Swift, Ennis, and others, we can only say they were unfortunate in not earlier giving their views and practice to the public.

Finally, it is by the combination of these three essential principles with the short side-splints and one long side-splint, which shall reach from near the axilla to beyond the foot, to prevent the outward bowing of the thigh and to prevent eversion of the leg, that the superiority of extension in the straight position can alone be demonstrated. The long outside splint, which I have myself added to the apparel, is only second in point of importance to either of the others, and that whether the fracture be in the neck or the shaft, in children or in adults. In children, however, it is supplied by the double splint.

With regard to fracture beds, which, when surgeons adopted the flexed position in the treatment of fractures of the thigh, were often very useful and sometimes necessary, I must say that, in the treatment of these fractures in the extended position, they are not needed. If the bed is sufficiently long and the mattress is smooth, firm, and even, nothing more is required. Properly shaped bed-pans can always be used without disturbing the limb, and the arrangements for changing the position of the limb are not only useless, but such changes are actually injurious. In certain complicated cases of fracture of either the thigh, leg, or foot, adjustable or movable "invalid" beds may be needed, when extension is not to be attempted.

As invalid beds, the best known and most ingenious American contrivances are those invented by Jenks,⁴ Daniels, the Burges, Addinell Hewson, of Philadelphia,⁵ J. Rhea Barton, B. H. Coates, of the same city,⁶ and J. Crosby, of Manchester, N. H.⁷

¹ "Medical and Chirurgical Observations as an Appendix to a former Publication, by Benjamin Gooch, Surgeon, London, printed for G. Robinson, in Pater Noster Row, and R. Beatniffe, in Norwich." No date, but about 1771. N. C. Med. Journ., Jan. 1878, Martin.

² *Minor Surgery*, by F. W. Sargent, M.D., Lea & Blanchard, Philadelphia, 1848.

³ Crosby, *Trans. Amer. Med. Assoc.*, 1850, vol. iii. p. 383.

⁴ Jenks, *Gibson's Surgery*; also the 5th ed. of this treatise, Fig. 185, p. 445.

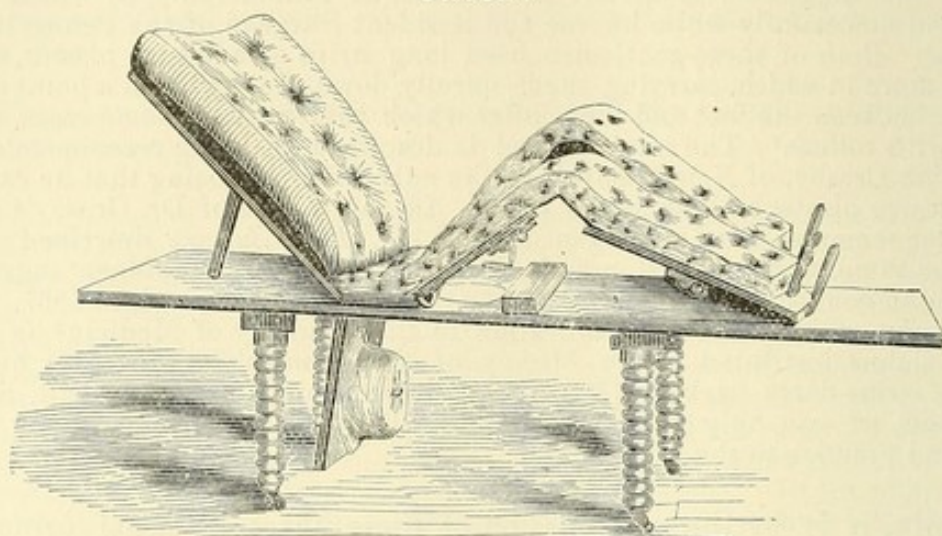
⁵ Hewson, *Amer. Journ. Med. Sci.*, July, 1858, p. 191.

⁶ *Eclectic Repertory*, 5th and 9th vols.

⁷ Crosby, *Treatise on Military Surgery*, by Frank H. Hamilton, 1865, p. 413.

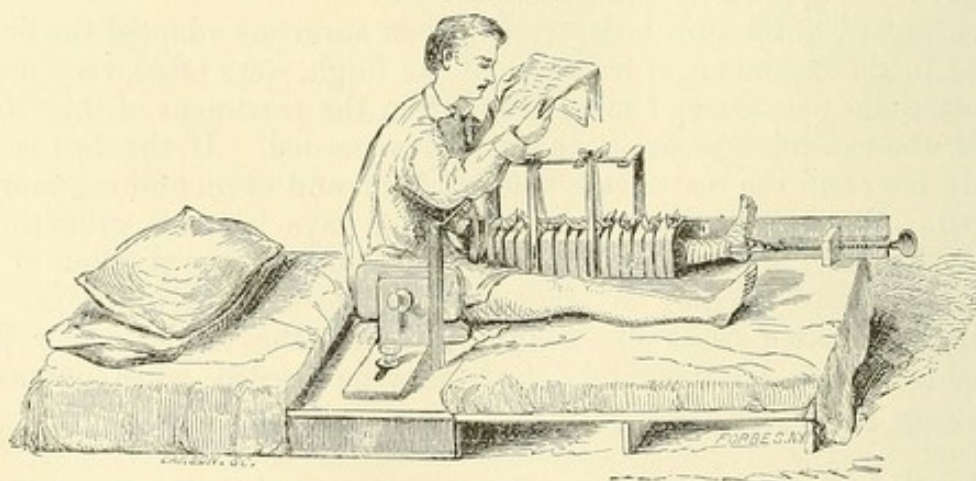
In my earlier practice I have had constructed a simple frame, covered with a stout canvas sacking, having a hole at a point corresponding with the position of the nates, and this I have laid directly upon a common

FIG. 249.

E. Daniel's invalid bed.¹

four-post bedstead. A mattress and one or two quilts must be placed upon the boards of the bedstead underneath the sacking, and a sheet or two above the sacking, upon which last the patient is to be laid. In arranging the linen underneath the patient, the most convenient plan is,

FIG. 250.



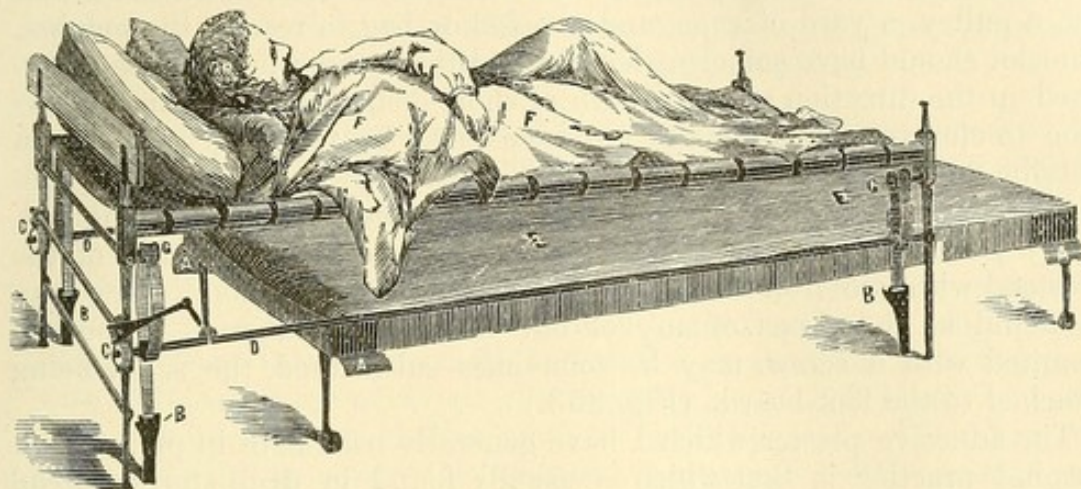
Burge's apparatus applied; this is a very servicable appliance as it comprises both a bed and a splint, and enables the patient to lie or sit without pressure in the groin.

instead of using only one sheet, which will require that a hole shall be made in it corresponding to the hole in the sacking, to employ two sheets, and, doubling them separately, to bring the folded margin of each from above and from below to the centre of the opening. When the patient has occasion to use the bed-pan, it is only necessary that two or four persons should lift this frame, and place under each corner a block about

¹ See Figs. 186 and 189 of 5th edition of this treatise.

one foot in height, or it may be raised by a pulley and ropes suspended from the ceiling.

FIG. 251.



Crosby's invalid bed, open.

The bed is movable, and can be run out from under the patient and changed. It is then run back, the hooks *B* being made fast to the catches *A*. By turning a crank at *C*, the rail *D* is revolved, which winds up a strap passing over the pulley *G*, and the bed is raised to its position, thus taking off the weight of the patient from the bands by which he was temporarily suspended.


My usual practice now, in a private house, is to remove the foot-board and lengthen the bed by boards laid longitudinally, and projecting one or two feet beyond the bottom rail. This furnishes a firm support for the mattress. Sometimes, of course, it will be found necessary to lengthen the bed. No hole is made in the flooring of the bed or of the mattress, to provide for fæcal evacuations.

A very comfortable bed, especially for children, can sometimes be made from a cot. But it will be necessary always to nail a piece of board firmly across the top and bottom of the bedstead when the sacking is at its utmost tension, in order to prevent the side rails from falling together. The top board must be nailed on vertically, like an ordinary head-board, so as to prevent the pillows from falling off, but the bottom piece, at least one foot wide, should be laid horizontally to support and steady the apparatus as it extends beyond the foot.

Having had occasion to assist the late Dr. Treat in the management of a fracture of the thigh in the case of a little girl not quite three years old, I was struck with the simplicity and completeness of an arrangement which he had made to prevent the bed and the dressings from becoming soiled with the urine. It was only to leave directly underneath the nates a complete opening through to the floor for the escape of the urine, and to protect the margins of the sacking and sheets, which came nearly together at the opening, with pieces of oiled cloth folded upon themselves. It was found that not only the bed was in this way kept dry, but the dressings also; it being now observed that the dressings had become wet heretofore by soaking up the moisture from the bed, rather than by the direct fall of the urine upon them.

Having prepared the bed for the reception of the patient, and elevated its lower end about four inches by placing blocks underneath the footposts, the following additional preparations should be made before we

FIG. 252.

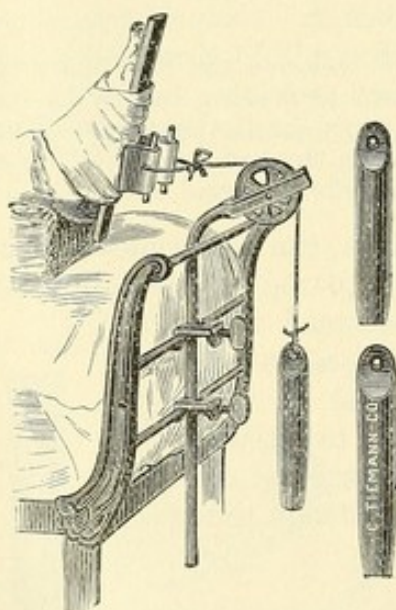


Standard.

proceed to reduce the fracture and dress the limb. There should be provided a piece of board of the requisite length and breadth, furnished with a slot to receive the pulley, and called the "standard," a small iron rod, a pulley, a yard of rope, and a vessel or bag to receive the weights. The slot should have sufficient length, and the standard should be perforated in the direction of its breadth at short distances, to enable the surgeon to elevate or depress the pulley, as may be required. In case a metallic pulley cannot be obtained, a spool will answer as a tolerable substitute. We now employ generally, at Bellevue, an iron upright rod, with a pulley affixed, and which is made fast to the iron frame of the bedstead with two iron clamps, secured in place by screws. They may be found at the shops of any of our instrument-makers. A pulley, mounted with a screw, may be sometimes substituted, the screw being attached to the foot-board. (Fig. 253.)

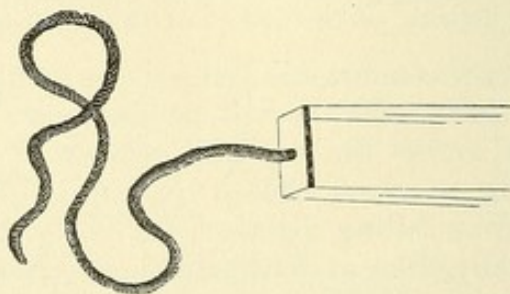
The adhesive plaster which I have generally used both in private and hospital practice is that which is usually found in drug-stores, spread upon linen; but some prefer the plaster spread upon jeans or canton flannel as being stronger. I cannot, however, appreciate the advantage, since the ordinary plaster seldom gives way when properly applied.

FIG. 253.



Iron upright and weight.
(From Tiemann.)

FIG. 254.



Foot-piece.


A thin block or piece of board, called the "foot-piece," is to be provided, perforated in the centre to receive the cord, and of sufficient length to prevent the adhesive strips or "extension bands" from pressing upon the malleoli. An average size for the foot-piece in the case of an adult is about three inches and three-quarters in length, by two and a half in breadth. The adhesive plaster may be cut in the shape shown in the illustration (Fig. 255); five and a half inches wide in the centre, and two and a half inches wide at the narrowest point, and gradually widening again toward each extremity to four inches; the narrower portions being slit down two-thirds of their length. For an adult we gener-

ally require a strip of about four feet and eight inches in length, namely, sixteen inches for the central and widest portion, and twenty inches for each extremity. The shoulders of the central portion are cut as represented, in order that when folded upon the foot-piece and upon itself it may reinforce the lateral bands at their weakest points.

[It is quite unnecessary to shape the strips in the manner here directed. They may be cut of equal width the whole length, about three inches for an adult limb will meet every indication. The foot-piece to which the cord is attached may be strengthened by an additional strip applied with the plaster to the plaster.]

The lateral or side-splints may be made of thick pieces of gum-shellac cloth, of stout leather cut and moulded to the limb, or of thin pieces of board covered with cotton cloth and stuffed on the sides next to the skin with cotton-batting to fit all the inequalities of the limb. Of these several materials gum-shellac cloth is much the best. It is thin, light, firm, and after immersion in hot water can be sufficiently moulded to the contour of the thigh. The cotton cloth must be stitched over the splints like a sac, but left open at the ends until the padding is properly adjusted. Loose cotton-batting always becomes displaced. Four splints are generally required: one for the anterior surface, extending from the groin below the anterior inferior spinous process of the ilium to within half an inch of the patella; one for the posterior surface, extending from the tuberosity of the ischium to a point six or eight inches below the

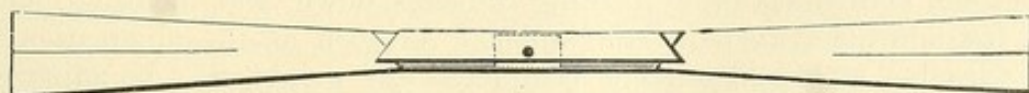
FIG. 255.



Extension-band and foot-piece.

knee; one for the inside, extending from near the perineum to the inner condyle; and one for the outside extending from above the trochanter major to the outer condyle. These splints ought to encircle the limb almost completely, only leaving an interval of from half an inch to one inch between each of the adjacent splints. The outer and inner splints may be extended below the knee when the fracture is low down; but in that case they must be carefully fitted to the irregularities of the condyles. The posterior splint is the most important of them all. It should be wider and much longer than either of the other splints, and it must be fitted with great accuracy to the back of the thigh, ham, and upper

FIG. 256.



Same, folded and ready for use.

part of the leg. It is important also to cover this with a sack of cotton cloth so that it may be stitched to the centre of the bands, which are to inclose all the splints. If this is not done, it is very liable to become displaced.

A long side-splint must now be prepared, long enough to extend from about four inches below the axilla to five inches below the heel; four and a half inches wide, by half an inch in thickness, and provided with a cross-piece at the lower end, two feet long by three inches wide and half an inch thick. The purpose of this splint is not to make extension, but to prevent the femur from becoming bent outward at the seat of fracture; which is accomplished more certainly by this splint than by the short splints, inasmuch as it keeps the whole body, including the upper part of the femur, in a straight line. Its purpose is also to prevent eversion of the foot, which purpose is never accomplished effectively by junks or by any other method I have yet seen adopted. It is to be employed in all fractures of the thigh, including fractures of the neck. The inner surface of this long splint must be padded throughout its whole length, and thus fitted accurately to the sides of the body and limb.

[Dr. A. D. Smith,¹ of Philadelphia, recommends the following splint to prevent eversion of the foot: A posterior splint eighteen inches long, shaped somewhat like the leg, with a hinged foot-piece held in position by hooks at the base; at the upper end two pieces of leather, sufficiently large to embrace the leg, are fastened, having eyelet holes, and laces at their free border; two similar pieces are fastened to the foot-board to embrace the instep and base of the toes; on the under surface, just beyond the foot-board, is fixed a strip of wood twenty inches long and one and a half to two inches wide, one end held by a bolt on which it may revolve, the other free.]

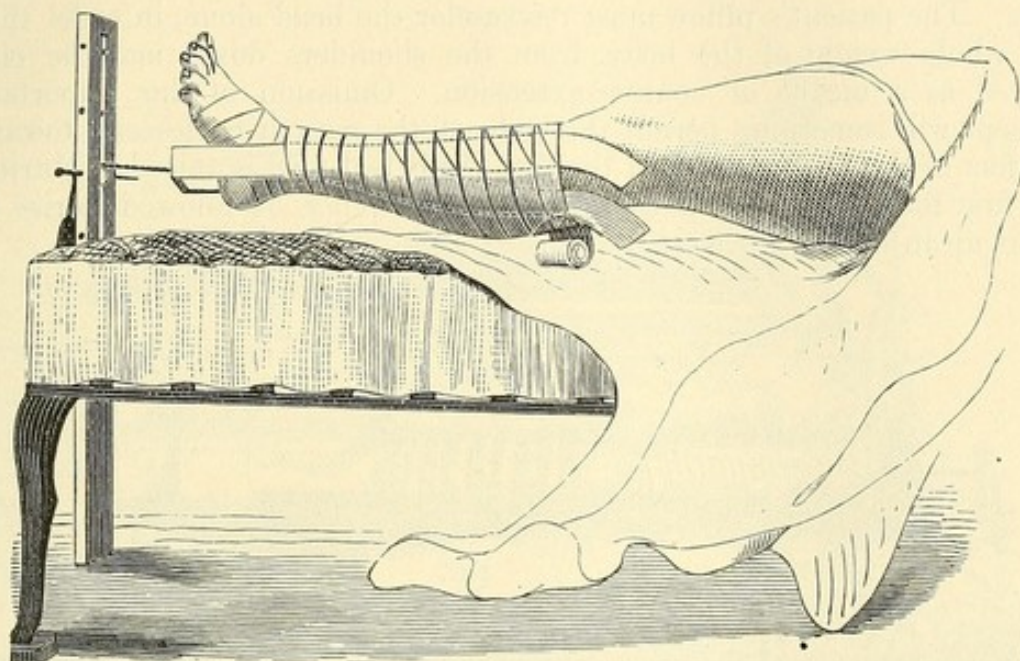
Four or six strips of cotton cloth, each two inches wide by one yard in length, are stitched by their centres to the back of the posterior splint, and these are laid upon the bed in position to receive the limb. Supplied with rollers, several additional strips of bandage, and cotton-batting, we are now ready to reduce and dress the fracture.

The patient being placed in position upon the bed, one assistant seizes the limb by the knee, and a second by the foot, drawing upon it firmly and steadily, at the same moment lifting it from the bed so as to render it more accessible; while the surgeon lays the extremities of the extension strip upon each side of the leg, with the centre, containing the foot-piece and the rope, about one inch below the sole of the foot. With a muslin roller, inclosing the limb from near the metatarso-phalangeal articulation to the tuberosity of the tibia, the adhesive strips are held in place. As a rule, and especially in the case of women, and of persons of a delicate lax fibre, it is well to lay against the tendo Achillis, and over the instep, a little cotton-batting before applying the roller. In some cases I am in the habit of applying a thin sheet of cotton-wadding over the whole surface of the limb. Any excess of the bands at the upper end is disposed of by turning the ends down, and inclosing them in a few additional turns of the roller. As soon as the application of the adhesive strip and roller is completed, the weight may be adjusted, and extension applied. The amount of extension required for adults will vary from eighteen to twenty-three pounds. In a large proportion of cases, twenty or twenty-one pounds will be borne without complaint; and the ability of the patient to tolerate the extension, alone limits the

¹ Therapeutic Gazette, Nov. 15, 1888.

amount. Occasionally, even a few pounds, when first applied, cause pain in the ligaments about the knee-joint; but in a few hours the amount may be increased. It is better to apply eighteen or twenty pounds at once, if it can be borne. Lifting the knee slightly by a pad placed underneath will often relieve the pain caused by the extension.

FIG. 257.



Mode of applying adhesive plaster.

(When the dressings are completed, the limb is to rest on the bed.)

[It is better to have the plaster strips extend above the knee, and nearly to the point of fracture. If they are applied altogether below the knee, the joint will be subjected to an unnecessary strain, which may cause a certain degree of weakness of the fibrous structures.]

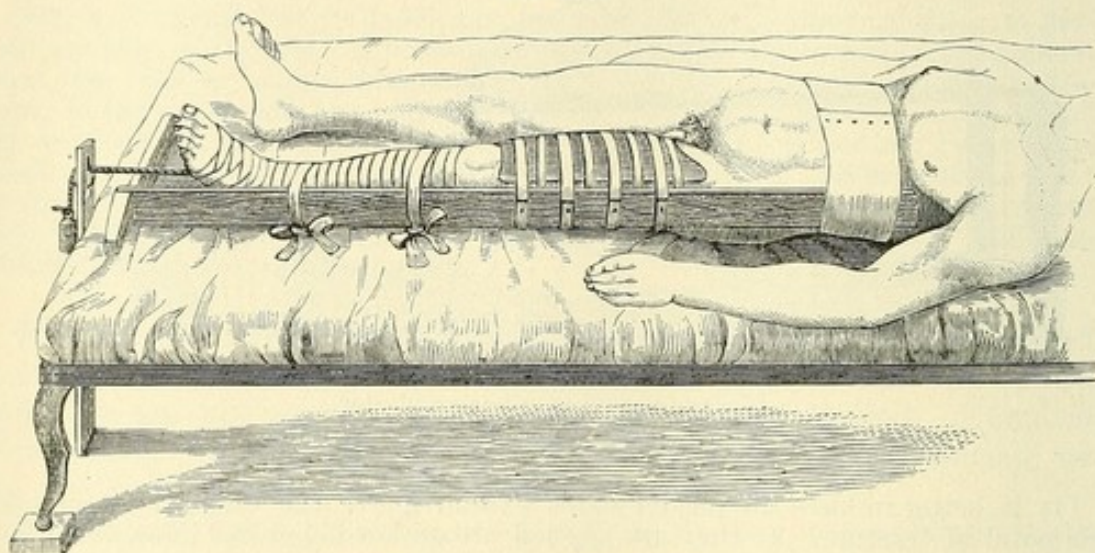
Sometimes, in the case of very muscular patients, and where the primary shortening is considerable, I believe we make a positive and permanent gain if we place the patient under the influence of chloroform for a few minutes when the weight is first applied. In these cases, as in dislocations, I generally prefer chloroform to ether, for the reason that the patient is less liable to muscular contractions when he is passing under the influence of the anæsthetic.

Extension being effected, and the patient already resting upon the posterior coaptation splint, the three other side-splints are applied, and the whole four secured in place by the four or six transverse bands already described as attached to the posterior splint; the bands being tied over the front splint firmly.

It remains only to lay the long splint beside the body, and to secure it in place by separate strips of bandage. Three strips for the leg, one broad strip for the pelvis, and one for the chest, are all that are required. The leg strips may be drawn pretty firmly to prevent all outward rotation of the limb. The pelvic band also ought to be tight enough to insure the constant contact of the pelvis with the long splint; but the thoracic band may be rather loose, as its function in this respect is not so important. One broad band may be substituted for the two latter, which

should be sewed to the cover of the long splints to prevent its becoming displaced. In the drawing (Fig. 258), narrow strips inclose the thigh and long splint, but I often omit them as being unnecessary; indeed, it is better sometimes to omit them when the fracture is high up, lest they should hold the lower fragment out, when the pelvis was not firmly secured to the long splint; in which case the other fragment might incline in the opposite direction, causing thus a bowing out at the point of fracture. The patient's pillow must rest under the head alone, in order that the whole weight of the body, from the shoulders down, may be employed as a means of counter-extension. Omission of this important precept will sometimes permit the body of the patient to descend toward the foot of the bed, even when the foot of the bedstead is raised. During the first four or five weeks the patients should not be allowed to rise or to sit up in bed.

FIG. 258.



Author's dressings for fracture of shaft of femur, complete.
(The long splint extends nearly to the axilla.)

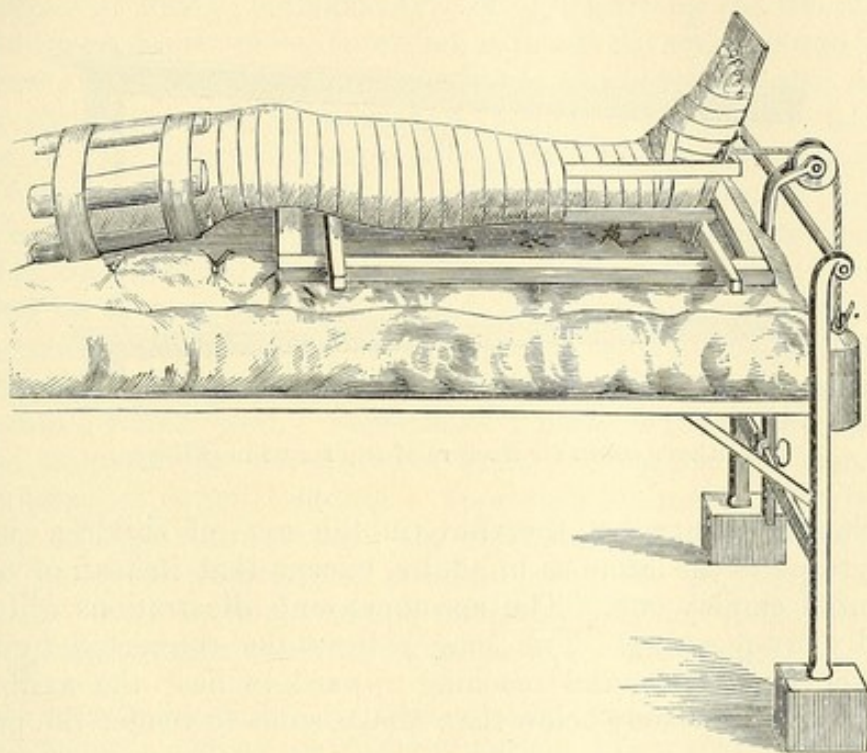
It is an error to suppose that such restraint is irksome. In my experience, no patient has ever complained of it; and I have no doubt that such movements increase the danger of non-union; a misfortune which has never happened when a patient has been under my treatment from the first to the last. I have, however, seen several cases of non-union, or of delayed union, in the practice of other surgeons, which I attributed to the patient having been permitted to rise in bed. For this reason, also, I reject all modes of treatment which are intended to permit these motions of the body.

In order to evacuate the bowels, the patient may draw up the sound limb, when a properly constructed bed-pan is easily placed under the nates. This occasions no disturbance to the fracture. From the time of the first dressing the patient should be seen daily, and the coaptation splints loosened or tightened from time to time, as may seem necessary. To open the limb, and even to remove temporarily all the coaptation splints except the posterior one, is harmless, and it is often a source of comfort to the patient. Ordinarily it is not necessary or prudent to disturb the extension until the union is completed. The usual time required for consolidation in the case of an adult is from six to eight weeks; but

if the bone feels pretty firm at the end of four weeks, the extension may be a little relaxed. When at length the patient is permitted to leave his bed, a pair of crutches is indispensable; and during the following two months but little weight should be borne upon the limb.

[Volkmann's sliding rest is a very useful appliance, as it allows the leg to slide on the frame during extension without any friction (Fig. 259).]

FIG. 259.



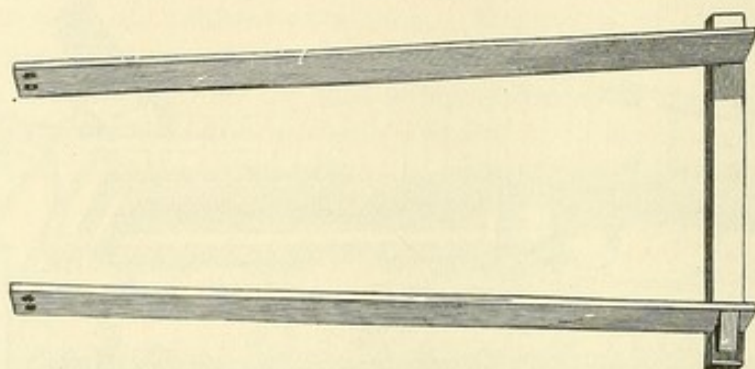
Volkmann's sliding rest.

Fractures of the thigh in children have generally been found more difficult to manage than fractures of the same bone in the adult, owing chiefly to the shortness and softness of the limb, the delicacy of the skin, its liability to become excoriated or to become soiled, and the restlessness of the patient. I have tried nearly all forms of apparatus in these cases, including double-inclined planes, boxes, single long splints, etc., and the result of my experience is that they are all inefficient; and for some years I have employed a mode of dressing, partly my own and partly the suggestion of others, but of which I am able to say that it never disappoints me in the result obtained; while it is simple, easy of management, and comfortable to the little patients.

Extension by means of adhesive plaster and a weight employed in the same manner as in adults, constitutes a valuable aid in many cases; but I cannot say that it is indispensable, since, with children under five or seven years, the fractures are pretty often so nearly transverse that, when once reduced and well supported by lateral splints, union without shortening may generally be expected; but these results become less and less frequent as we advance toward adult life. It is safe and proper, according to my experience, to employ in any case extension, somewhat accord-

ing to the following rule. One pound for a child one year old, two for a child two years old, and so on, adding one pound for every year up to the twentieth. Of much more consequence, however, is it to confine, at the same time, both limbs, for as long as one is at liberty it is almost impossible to secure any degree of quiet. It is of equal importance, in my opinion, to give to the limbs an extended rather than a flexed position.

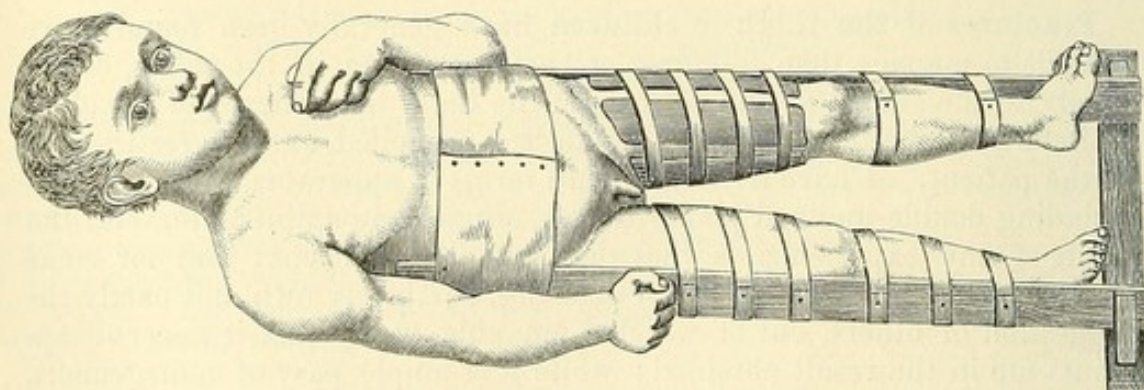
FIG. 260.



Author's splint for fracture of the femur in children.

My plan of treatment, therefore, in the case of children, is in all essential respects the same as in adults, except that instead of one long side-splint, I employ two. The accompanying illustrations will explain more fully my meaning. Two long side-splints connected by a cross-piece at the lower ends, and reaching upward to near the axillæ, separated a little more widely below than above, so as to render the perineum

FIG. 261.



Author's dressing for fracture of the femur in children, complete.

more accessible, are laid upon each side of the body. The four short thigh splints, made of binders' board and covered with cotton cloth, are secured in place by four or five strips of bandage tied in front and then stitched to the covers of the splints. These must not embrace the long side-splint. The broken limb below the knee, and the opposite thigh and leg are then secured to the long splints by separate and broader strips of cloth. My object in substituting, in this case, separate strips for the roller, is to render the limb more accessible to the surgeon, to enable him

more readily to remove portions which are soiled, and to leave the leg more free to be drawn downward, in case permanent extension is employed.

Thus secured and laid upon a bed, such as I have already described as appropriate for children, the least possible annoyance will be given to the surgeon. The dressings are but little liable to become wet with urine, and when the bed is soiled, the child can be taken up with the splint and carried to another; indeed, this may be done as often as the patient becomes restless or weary, without any risk of disturbing the fracture. In case the surgeon desires to use extension with adhesive plaster and weights, the necessary apparatus may be made fast to the bedstead, and taken off when the child is moved; or it may, if thought best, be made fast to the foot-piece of the splint. Occasionally, with children, I employ, as a means of extra safety, a perineal band, drawn moderately tight, and fastened to the top of the splint on the side corresponding to the broken limb. The best perineal band is a piece of soft cotton-cloth, one or two yards long by three inches wide, folded lengthwise to a flat band of one inch in breadth, and inclosing, where it passes through the perineum and under the nates, a few thicknesses of paper. The paper prevents its drawing into a round cord. Sometimes I place between the paper and the folded cloth, on the side which is to be laid next to the skin, one or two thicknesses of cotton-wadding. To absorb the moisture, it is well to lay a piece of sheet lint between the band and the skin. The perineal band may be removed daily and renewed; and the perineum examined and washed. Four or five weeks is generally a sufficient length of time for perfect consolidation in children under five years of age.¹

If I have been unable to give my approval to the treatment of fracture of the shaft of the femur in adults with plaster-of-Paris, or to any other form of immovable dressing, I am still less able to give it my approval in fracture of the same bone in children. The following case will illustrate its dangers: A boy, four years old, fell thirty feet, breaking his right thigh near its middle, causing one of the fragments to protrude through the flesh. The surgeon in charge, having reduced the fracture, applied on the fifth day a plaster-of-Paris splint from the toes to the groin, leaving a fenestra opposite the wound in the thigh. The child suffered much pain that night, and on the following morning his toes were cold. On the second morning after the dressing there were vesications on the toes. On the fourth day the toes were discolored, and an offensive odor escaped from the dressings. The dressings were now removed, and the toes, with a part of the foot, were found to be gangrenous. Subsequently the gangrene extended to the middle of the leg. This case had been seen and the condition of the toes noted each day by the surgeon, but he did not become alarmed until the fourth day. I was consulted, and advised the continuous hot-water bath as preferable to amputation under the circumstances. The surgeon adopted my suggestion, and in about three weeks the limb separated spontaneously, the gangrene having never extended after the limb was submerged in the bath. His recovery has been complete.²

[While this case is most instructive, and conveys a forcible lesson as to the dangers of the careless use of the plaster-of-Paris dressing in children, it should not deter those who are competent to employ this dressing from its use. The unfavorable results which follow its application are always due to strangulation of the limb. This condition can certainly be avoided, and will only occur when

¹ Fractures of Shaft of Femur in Children. A clinical lecture by the author at Bellevue, Medical Record, Jan. 5, 1878.

² Medical Record, March 15, 1879, p. 257, case reported by Dr. Forest.

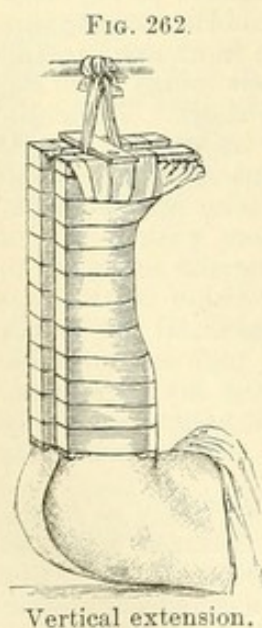
there is culpable carelessness. To prevent strangulation of the limb it is only necessary—(1) to delay the dressing until the swelling due to the injury has abated; (2) to underlay the plaster with a proper yielding medium, as cotton-batting; (3) to apply the turns of the roller so lightly as merely to encase the limb with moderate firmness.]

In 1877, Schede, of Berlin, adopted a method of treating fracture of the thigh in children, which he calls "vertical extension." The method of treatment is as follows: "A long, continuous band of plaster is fixed to both sides of the injured limb, as high as the seat of fracture, and applied so as to form a free loop below the sole. This long strip is then secured in the ordinary way by circular strips of plaster, and by circular turns of a bandage. The leg, having been elevated, is then kept in the vertical position, with the corresponding side of the pelvis suspended by means of a piece of cord fixed to the loop of plaster, and either attached above to some object over the bed, or slung over a pulley, with its free extremity supporting a weight." This does "not necessitate constant and complete rest on the back." At the end of about three weeks, when the fragments are usually consolidated, the extension is removed, and the limb is permitted to rest upon the bed. The only disadvantage stated is the occurrence, in some cases of females, of a severe vaginal catarrh, due, as is supposed, to the free entrance of air into the gaping ostium vaginæ.

By Schede's method the patient is during the entire period of treatment confined to the bed, while in horizontal extension he is not. Inconvenience must also be experienced in the vertical extension in the adjustment of the coverings, and especially in cold weather, which inconvenience is avoided in horizontal extension. It must be added, also, that although in children of this age the fragments are usually firm in three or four weeks, it has not been found safe, in my experience, to remove wholly restraints until a week or two later. The contrary practice has every now and then resulted in a bending at the seat of fracture, which had subsequently to be remedied. My double splint, with only moderate

confinement of the body and limbs, without extension or short splints, prevents this unfortunate accident in the later days of the treatment, while in Schede's method the limb must be left, after the extension is removed, wholly without support. No evidence is presented that results are any better than my own, by which latter method rotary displacement is impossible; lateral displacement or bending, improbable; and there is no shortening, of course, unless it is a complete fracture, and if it occurs then it is trivial.

[Bryant, of London, states (*Prac. Surgery*) that he began this form of practice at Guy's Hospital in 1870, and illustrates it (Fig. 262). The ages of his patients varied from eight months to five years; for older patients he prefers the double splint. I have employed Bryant's dressing with good results.]



Vertical extension.

It must be understood, however, that with any mode of treatment, almost, occasional good results are obtained; but this is only because fractures of the thigh in infants are generally green-stick fractures; and the tendency to displacement is very slight, and

union occurs very speedily.

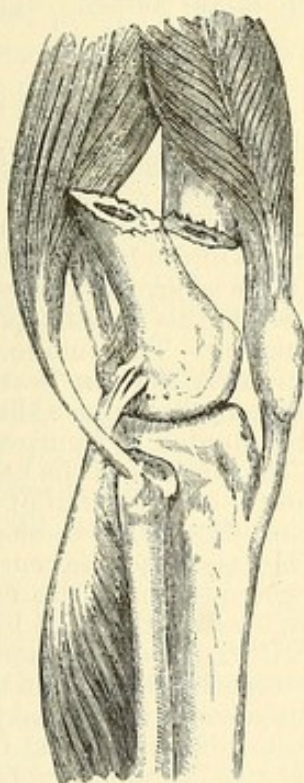
Badly comminuted and compound fractures of this bone are to be managed upon the same general principles as gunshot fractures. Those com-

pound fractures of the femur which have been caused by the thrusting of the sharp fragments through the flesh, and in which reduction has been easily effected, have in most cases done as well as simple fractures, except that the limb is generally a little more shortened. The wound usually soon heals, and the future progress of the case is the same as that of a simple fracture. They may be treated, therefore, in the same manner as those which have just been described.

§ 4. Fractures of the Shaft, at or near the Base of the Condyles.

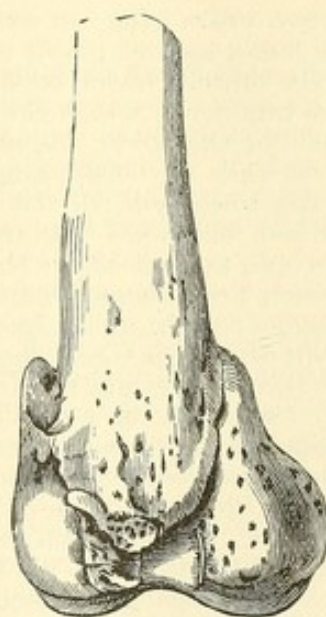
Causes.—These fractures are not so common as fractures of the shaft elsewhere; twenty examples are contained in my records as having come under my personal observation. According to my own experience, they are caused generally by a fall upon the knees or feet. In at least nine of the cases seen by me the fracture was caused in this manner. In seven it is known that the fracture was caused by a direct blow. The direction of the line of fracture is generally from behind forward and downward,

FIG. 263.



Fracture at the lower part of the shaft of the femur; action of muscles. (Hind.)

FIG. 264.



United fracture at base of condyles.

the upper fragment being driven downward toward the patella; in other cases the line of fracture preserves the same general direction, but inclines inward or outward; and in these cases the upper fragment is found lying more or less on the inner or outer margins of the knee, probably most often on the inner side. In one instance I found both femurs broken at the same point and in the same manner.

L. B., aged about forty-five years, fell from a fourth-story window to the stone pavement blow, striking upon his feet. In addition to several other fractures, I found both femurs broken obliquely downward and forward, just above the condyles. Very little inflammation ensued, and although it was found impossible to employ extension, union occurred readily, and with only a moderate overlapping. In the left limb, however, the upper fragment pressed down sufficiently to interfere somewhat with the patella, and the patient was unable, after several months, to straighten the knee completely. The motions of the right knee were unimpaired.

I have only once met with a fracture at this point in which the line of separation was downward and backward. A boy, *æt.* 7, in jumping down a bank of about three feet in height, broke the right thigh obliquely, just above the knee-joint. Direction of the fracture obliquely downward and backward. The limb was not then much swollen. The surgeon applied side-splints, rollers, etc., carefully, and then laid the limb over a double-inclined plane. The knee was elevated about six or eight inches. Before applying the splints, suitable extension had been made, and after completing the dressings, the two limbs seemed to be of the same length. On the second or third day the toes looked unnaturally white, and were cold. The result was that a considerable portion of his foot died and sloughed away, leaving only the tarsal bones. The fracture united, but with considerable overlapping and deformity.

Nearly two years after, on examining the limb, I noticed that the anterior line of the femur seemed nearly straight, and this appearance was owing in some degree to the muscles which covered and concealed the bone, and in some degree, also, to the manner in which the fragments rested upon each other; the pointed superior end of the lower fragment resting snugly upon the front of the upper fragment, so that no abrupt angle existed in front. On the back of the limb, however, the lower end of the upper fragment, quite sharp, projected freely downward and backward into the popliteal space, so that its extreme point was only about half an inch above the line of the articulation. The limb had shortened one inch, and this enabled us to determine accurately that the lower point, or the commencement of the fracture, was one inch and a half above the articulation, while the point where the line of fracture terminated in front was probably quite three inches and a half above the joint. The motions of the knee-joint was pretty free. The leg was extremely wasted, and the anterior half of the foot having sloughed off, the sores had now completely healed over. He was able to walk tolerably well without either crutch or cane. The case came into court, where it was claimed that the death of the foot was in consequence of the bandages being too tight. It was shown that the death of the toes was preceded by a total loss of color, and that it was not accompanied with either venous or arterial congestion. The medical gentlemen examined as witnesses declared that this circumstance furnished the most positive evidence which could be desired that the death of the toes was not due to the tightness of the bandages, but that its cause must be looked for in an arrest of the arterial or nervous currents supplying the limb, or in both. They believed, also, that the projection of the superior fragment into the popliteal space was sufficient to cause this arrest. They also believed that overlapping and consequent projection could not have been prevented in this case, and that, therefore, the treatment was not responsible for this unfortunate result; indeed, they regarded the treatment as correct, and the result as a triumph of skill, in that any portion of the limb was saved; the leg and foot now remaining being far more useful than any artificial leg and foot could be.

Specimen 121, in Marsh's collection at Albany, presents a similar disposition of the fragments. The fracture is oblique, from above downward and backward, and the upper portion lies behind the lower. It is firmly united by bone, but with an overlapping of from two and a half to three inches. It had been found

impossible, owing to an ulcer upon the heel, and to other causes, to employ in the treatment any degree of extension.

Amesbury has recorded one case, which came under his own observation, where, although the bloodvessels and nerves escaped, the bone projected through the skin in the ham, and finally exfoliated.¹ And he thinks the point of bone may sometimes so penetrate the artery and injure the nerves as to render amputation necessary in order to save the life of the patient. M. Coural also has related a case in which an epiphysary disjunction, occurring in a child twelve years old, was attended with a displacement of the upper fragment backward, and amputation became necessary.²

The popliteal artery hugs the bone so closely at this point, that a displacement of the upper fragment in a direction downward and backward must always greatly endanger its integrity. Indeed, it is here that the artery and vein are in the closest contact with each other, and with the bone.

Prognosis.—The prognosis in this fracture has, according to my own experience, a wider range than in the case of other fractures of the shaft. In a proportion of cases the union has been effected with little or no shortening; a result which is not surprising when we consider that at this point the muscular resistance which has to be overcome is less than at any other point of the shaft of the femur; and that occasionally the line of fracture is so little oblique that the fragments being once adjusted support themselves completely.

Malgaigne says that here "oblique fractures are more rare" than those which are nearly transverse; but Sir Astley Cooper had never met with a transverse fracture at this point, nor have I; yet no doubt they do occur here more often than in other portions of the shaft. Malgaigne says that M. Denonvilliers thought he had found in the Dupuytren museum four or five examples of exactly transverse fractures at this point, but he had not found one higher up.

While a considerable number of these fractures may be reasonably expected to reach a favorable termination, a much larger proportion than usual of fractures of the shaft at other points are to be considered as very grave accidents, and in some cases as demanding immediate amputation. This increased gravity is due, in certain examples, to the greater violence required to cause the fracture; in others, to the penetration of the joint by the upper fragment, and in all cases the hazard may be considered increased by the proximity of the fracture to the joint; the thinness of the soft coverings renders them more liable to be made compound by the penetration of the skin by the upper fragment; and, finally, there exists the danger that this fragment will penetrate the tendon of the quadriceps, or its tendinous expansions on either side, and become button-holed, thus interposing a portion of this dense fibrous tissue between the fragments, and preventing bony union, as happened in two of the cases already recorded. If the direction of the fracture is from before upward and backward, as happens only very rarely, there is danger of the fragments pressing upon the popliteal artery, vein, and nerves, and causing a secondary hemorrhage, or gangrene of the leg, as happened with the boy Aiken.

¹ Remarks on Fractures, etc., by Joseph Amesbury, vol. i. p. 293. London, 1831.

² Archiv. Gén. de Méd., tom. ix. p. 267.

The treatment of the accident has already been discussed in connection with fractures of the shaft in general; and the conclusion would seem to be that, except in the last-named and exceptional fracture, as a rule, the straight position with moderate extension affords the most comfort to the patient and insures the best results. No doubt there will be cases in which Hodgen's swing, or some other form of the flexed position, will be found the most comfortable, and give equally good results; especially when the parts about the knee are much swollen, or the knee-joint itself has been penetrated. However, in the few cases in which this position was adopted by myself and others, a change had to be soon made. The most serious question is, perhaps, What shall be the course to be pursued when the bone becomes buttonholed in the tendon, without penetrating the skin? In neither of the two cases seen by me could the fragment be withdrawn from the tendon by flexion or extension, even when the patient was under the influence of the anæsthetic. Will it be proper, then, to cut through the skin, expose and remove the projecting bone, and then reduce it? In one of my cases this was not done, and although the union was very long delayed, it is reported to have been finally accomplished; but of the correctness of this report I do not feel assured. In the other case I resected the bone, and my patient died. I confess that I do not think I would be inclined to repeat the operation, but that I would prefer to submit my patient to the risks of non-union, or of a fibrous union.

[With antiseptic precautions resection of the protruding fragment would be an entirely proper operation.]

Bryant says that he has once cut the tendo Achillis in a case of fracture at the base of the condyles, and he recommends it in all cases.¹ I cannot agree with Mr. Bryant as to its necessity or utility ordinarily, since I do not think that the lower fragment has that tendency to tilt backward which, in Mr. Bryant's opinion, renders a paralysis of the gastrocnemius necessary. This point has been discussed elsewhere in this chapter. Dr. Morris, of Harvard, Charlestown, Mass., has repeated Mr. Bryant's operation in a case in which the fracture was through the base and between the condyles at the same time. In this case the operation proved very serviceable.²

§ 5. Fractures of the Condyles.

[In these injuries one condyle is separated from the other by a fracture into the joint. Direct violence, as a blow or fall upon the knee, is the more frequent cause. A condyle has been fractured by the mere twisting of the leg. The diagnosis is readily made, owing to the mobility of the separated fragments and the mobility of the leg toward the fractured condyle. There is no shortening, but the breadth of the knee is increased.]

(a) **Fractures of the External Condyle.**—Crosby³ relates a case of fracture of the external condyle, in a man twenty-one years of age. He was "standing on a shelving bank, with the right leg flexed over the left in order to remove his pantaloons; he lost his balance, partially twisted the leg, and fell to the ground."

¹ Bryant, Lond. ed., 1872, p. 936.

² Morris, Med. Record, March, 1878, from Boston Med. and Surg. Journ., Nov. 1877.

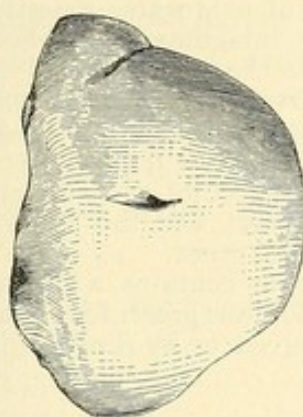
³ Crosby, New Hampshire Journ. of Med., 1857.

Six months after the fragment was removed by Dr. Crosby, through an incision below the condyle. The recovery has been complete. The accompanying drawing represents the specimen as seen from its lower or cartilaginous surface, and of its actual size. (Fig. 265.)

J. O'N., æt. 40, fell down stairs, bending his left leg under his body, and fracturing the external condyle. About three months later the patient was brought under my notice. He was able to walk with a slight halt; the fragment, apparently about one inch in diameter, moving upward about half an inch when the leg was flexed, with a distinct and painful crepitus. When at rest, the fragment formed a marked projection. It is not certain whether the line of fracture entered the joint. I examined the limb several times during the succeeding two years, and found the condition of matters unchanged, except that the usefulness of the limb has steadily improved. Bandages and knee-supports have served no useful purpose, and have been laid aside.

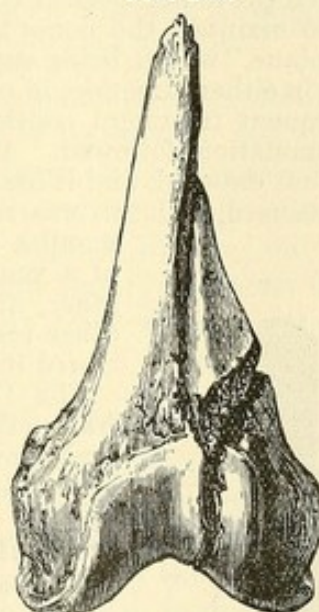
Dr. T. S. Kirkbride has also reported an example of simple fracture of this condyle, which was produced by the kick of a horse, the blow having been received upon the inside of the knee. When this patient entered the Pennsylvania Hospital, Dec. 1834, the knee was much swollen, and crepitus was plainly

FIG. 265.



Dr. Crosby's specimen of fracture of the external condyle.

FIG. 266.



Sir Astley Cooper's case of fracture of the external condyle.

felt, but the fragment was not displaced; the muscles upon the outer side, however, were so strongly contracted as to abduct the leg, and produce considerable angular deformity. The limb could be easily made straight, but it returned to its former position of abduction as soon as it was released. When fully extended, slight bending of the joint did not give severe pain; but when in any degree flexed, all motion was very painful. The limb was placed in a long straight fracture-box, and cold applications were made; great swelling followed. It was kept extended in this manner, or in the long splint of Desault, twenty-eight days; at which time union seemed to have taken place, but the motions at the joint were very limited, and productive of great pain. From this period the limb was laid in a splint, so constructed that the angle of the knee could be changed daily. At the end of about six weeks he began to walk on crutches, and he could then flex the leg to a right angle.¹

Sir Astley Cooper has related a case of compound fracture of the same condyle, produced by falling from a curbstone upon the knees. The man died on the twenty-fourth day. On examination after death, the external condyle was

¹ Kirkbride, Amer. Journ. Med. Sci., May, 1835, vol. xvi. p. 32.

found to be broken off, and also a considerable fragment was detached from the shaft higher up.¹ (Fig. 266.)

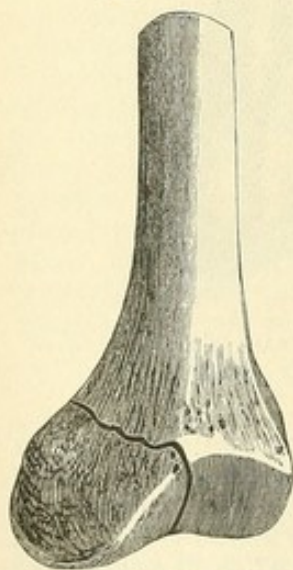
(b) **Fractures of the Internal Condyle.**—Dr. Rggs, of Homer, N. Y., reports the following case:

A lad, æt. 15, was kicked by a horse, the blow being received upon the right knee. The internal condyle of the right femur was broken off, carrying away more than half the articulating surface of the joint; the tibia and fibula were at the same time dislocated inward and upward, carrying with them the broken condyle and the patella. The displacement upward was about two inches, and the sharp point of the inner fragment had nearly penetrated the skin. There was no external wound. The knee presented a very extraordinary appearance, and the lad was suffering greatly. The first attempt at reduction was unsuccessful; but in the second attempt, when the men aiding him were nearly exhausted in their efforts at extension and counter-extension, and while pressing forcibly with both hands upon the two condyles, the bones suddenly came into position, except that the breadth of the knee seemed to be slightly greater than the other, a circumstance which was probably due to the irregularities of the broken surfaces, which prevented perfect coaptation. Neither splints nor bandages were required to maintain the bones in place; the limb was placed upon "a double inclined plane," which, being supplied with lateral supports, would prevent any deflection in either direction, in case the limb was disposed to such displacement. The subsequent treatment consisted in the use of cold-water dressings. Very little inflammation followed. A portion of the integument sloughed, but the bone was not exposed, and it healed rapidly. On the twenty-fourth day passive motion was used, and this was repeated at intervals until, at the end of three

months, he was able to walk with a cane. At the end of a year, the knee was a very little larger than the other, and flexion was not quite as complete. In all other respects it was perfect, and the boy himself declared it was as good as the other.

The Dupuytren museum contains a specimen illustrating this fracture, which was presented to the museum by Verneuil, and is referred to by Trélat.² The fragment was not displaced.

FIG. 267.



Fracture of the internal condyle. (Verneuil's case.)

Treatment of Fractures of either Condyle.—

The few cases of these accidents which I have seen reported have been, with one or two exceptions, treated in the straight position. In Kirkbride's case any degree of flexion was painful, although there was little or no displacement of the fragment; and we think we can see, in the relative position of the articular surfaces of the tibia and femur, a sufficient reason why the straight or nearly straight position must generally be preferred. Whichever condyle is broken, the remaining condyle will be sufficient to prevent a dislocation and consequent shortening of the limb, unless, indeed, the dislocation has already occurred as an immediate consequence of the injury. It is very certain that it would not take place from the action of the muscles when the limb was straight. In the flexed position I can conceive that it might take place, but yet not easily. It is not a dislo-

¹ Sir Astley Cooper, on Disloc., op. cit., p. 239.

² Verneuil, Trélat, Arch. Gén. de Méd., 1854, t. ii. p. 78.

cation of the limb, then, that we seek chiefly to avoid, but a deflection of the leg to the right or to the left, according as one or the other of the condyles has been broken. It will be readily seen that, in order to resist this tendency, nothing but the straight position will answer, and that for this purpose it will be necessary to lay a long splint upon one or both sides of the limb, and to secure the whole length of both thigh and leg to this splint. The long fracture-box used by Kirkbride, if well cushioned on all sides, seems to me at once to answer most completely this important indication, rendering it even unnecessary to employ a bandage, since the opposite sides of the box will compel the limb to adopt the proper position. As to the remainder of the treatment, it must consist essentially in the employment of such means as are calculated to prevent and allay inflammation.

[When the acute swelling has begun to subside the plaster-of-Paris dressing is most useful. The knee should be protected by a layer of cotton-batting, and the plaster should extend from the middle of the leg to the middle of the thigh. While the dressing is being applied the limb should be held in proper position, and the condyle fixed in firm contact with its fellow by pressure.]

As soon as the union is consummated the joint-surfaces should be submitted cautiously to passive motion, in order to prevent ankylosis; and it would be better to commence this so early as to hazard somewhat a displacement of the fragment, rather than to wait too long. It may not, in some cases, be improper as early as the fourteenth day, and in nearly all cases it should be practised as early as the twenty-eighth. Of course, the presence of active inflammation in the joint would render motion improper.

(c) **Fractures between the Condyles and across the Base.**—A fracture of this character may be produced by a blow received directly upon any point of the lower extremity of the femur; sometimes the blow has been received upon the patella when the knee was bent, and Bichat mentions a case in which it was produced by a fall upon the feet.

Symptoms.—This fracture is easily distinguished from the preceding by the much greater mobility of the fragments and by the palpable shortening of the limb, since an overlapping of the broken end is here almost inevitable. Each fragment may be felt to move separately, and the motion will be accompanied with crepitus.

Prognosis.—The danger of violent inflammation in the joint is imminent, and ankylosis of the knee is to be anticipated as the most favorable result, since the joint-surfaces are likely to be rendered immovable by fibrinous deposits in their immediate vicinity, and also by the adhesion of the muscles to one another and to the bone higher up, at the point where the fracture of the shaft has occurred. More fortunate results than these may, indeed, be hoped for, inasmuch as they have occasionally been noticed, but they cannot fairly be expected.

In a majority of cases such accidents have demanded, either immediately or at a later period, amputation. If recovery takes place, a shortening of the thigh is inevitable. Mr. Canton, of London, has twice performed successfully resection of the joint-end of the bone in such accidents.¹

¹ Canton, *Lancet*, Aug. 28, 1858. *Trans. London Path. Soc.*, 1850.

Treatment.—Malgaigne saw a patient who had been treated by Guérbois, with the aid of extension and counter-extension, who was confined to his bed five months, and who had at the end of eight years very little motion in the joint, and he seems disposed to charge in some measure these unfortunate consequences to the position in which the limb was placed, namely, the straight position. But, in my opinion, it is much more reasonable to suppose that, if the treatment was at all responsible for the results, the error consisted in too long and unnecessary confinement and in too much extension. I suspect that the mere matter of position had nothing to do with the ankylosis. Malgaigne does not, however, himself recommend anything more than a very slight amount of flexion at the knee; and to this practice I am prepared to give my assent; since it will give to the limb a useful position in case ankylosis does occur, and it is not inconsistent with the employment of the moderate amount of extension which alone is justifiable after this accident. If the young surgeon should differ with me in opinion as to the necessity or propriety of using great force to retain the fragments in place and prevent overlapping, I beg him to consider that this fracture probably never happens except from the application of an extraordinary force, and that consequently intense inflammation and swelling are almost certain to ensue; and that in some cases, the very fact that immediately after the accident, or for some hours succeeding, no swelling occurs, or muscular contraction, and that replacement of the fragments is easily accomplished, is evidence only of the great severity of the injury, and that the whole system is prostrated by the shock; to which, if the patient does not succumb, sooner or later reaction will ensue and the fragments will be gradually drawn up with a resistless power. The surgeon ought to remember also that to make extension in this case, he is obliged to pull upon those very ligaments and tendons about the joint which, having been torn or bruised, must soon become exquisitely sensitive.

The long straight box, already recommended when speaking of fracture of one condyle, is equally applicable here; only that it needs a foot-board, or some sort of foot-piece to which an extending apparatus may be secured, and that a pillow should be placed under the knee to give the limb the proper flexion.

A man was admitted into St. Thomas's Hospital, London, Sept. 17, 1816, with a fracture between the condyles, accompanied also with a fracture through the shaft higher up, occasioned by being caught in the wheels of a carriage while in motion. There was a small wound opposite the point of fracture, and the external condyle was displaced outward. The limb was laid in a fracture-box, and in a position of semiflexion. On the 18th of November, the external condyle, having protruded through the skin, and being dead, was removed with the forceps, bringing with it a portion of the articular surface. On the 6th of December he was discharged from the hospital, and in February following he was walking without any support, and with the free use of the joint.¹

A gentleman living about eighty miles from town was thrown from his carriage, breaking the left femur just above the condyles into many fragments, so that when I saw him on the following day the attending physician showed me about four or five inches of the entire thickness of the shaft which he had removed. The external condyle was completely separated from the internal, and

¹ Sir A. Cooper on Disloc., etc., op. cit., p. 239.

was quite movable. In this case the attempt to save the limb resulted in the loss of the patient's life on the sixth or seventh day. In a case of this kind, Dr. Morris, of Charlestown, cut the tendo Achillis with an excellent result.¹

(d) **Separation of the Lower Epiphysis.**—M. Coural² relates the case of a boy eleven years old, who, while his leg was buried in a hole up to his knee, fell forward, separating the lower epiphysis from the shaft, and at the same time driving the shaft behind the condyles into the popliteal space. The epiphysis also became tilted in such a manner that its lower extremity was directed forward. The limb was amputated.

Madame Lachapelle mentions a case in which traction at the foot of a child in the act of birth, caused at the same time a separation of the lower epiphysis of the femur and the upper epiphysis of the tibia. The child was born dead.³

Dr. Halderman,⁴ of Columbus, Ohio, Professor of Surgery in the Starling Medical College, reports a case in a boy, 18 years old, caused by a violent blow upon the front and lower part of the thigh. The limb was shortened two inches. It was found impossible to reduce the fracture, even under the influence of ether. Gangrene ensued, and on the fifth day the limb was amputated. On examination it was ascertained that the epiphysis was separated completely, and carried backward by the action of the popliteus and gastrocnemius; the popliteal artery and vein, and the internal popliteal nerve were displaced forward, lying between the upper and lower fragments, and were much contused. The epiphysis was lodged above the internal condyle in such a way that it would have been impossible to displace it by traction.

Dr. Little presented to the New York Pathological Society a specimen obtained from his own practice. A boy, æt. 11, while hanging on the back of a wagon, had his right leg caught between the spokes of the wheel which was in rapid motion. A few hours after the accident, Dr. Little found the upper fragment of the femur projecting through an opening in the upper and outer part of the popliteal space. On examination, the wound did not appear to communicate with the knee-joint. Under the influence of an anæsthetic the fragments were reduced; the reduction occasioning a dull cartilaginous crepitus. There was at the time no pulsation in the posterior tibial artery, and the limb was cold. The limb was laid over a double-inclined plane. The following day the upper fragment was again displaced, and it was found that it could only be kept in place by extreme flexion of the leg. This position was therefore adopted and maintained; considerable traumatic fever followed, with swelling, and on the thirteenth day a secondary hemorrhage occurred from the anterior tibial artery near its origin, and it became necessary to amputate. The boy made a good recovery. The specimen showed that the line of separation had not followed the cartilage throughout, but had at one point traversed the bony structure.

Dr. Voss, at the same meeting, remarked that he had met with the same accident. There was no protrusion of bone, but an abscess formed, and it became necessary to amputate.

Dr. Buck saw a case which occurred in the practice of Dr. Hugh Walsh, of Fordham. The subject was a boy 14 years old, and it happened in the same manner as with Dr. Little's patient.⁵

Tapret and Chenet⁶ have reported a similar example caused in the same manner, in a boy 9 years old. The integuments were lacerated and there was considerable hemorrhage. The limb was dressed with plaster-of-Paris, but after a few days gangrene ensued in the region of the parts wounded, and it became necessary to amputate. On examination, it was found that the fracture, commencing externally, followed the line of union between the epiphyseal cartilage and the shaft, but toward the inner side it deviated a little, so as to include a small portion of the diaphysis.

The same accident has been frequently caused by attempts to straighten the

¹ Morris, Boston Med. and Surg. Journ., Nov. 1877.

² Coural, Arch. Gén. de Méd., vol. ix. 1825, p. 337.

³ Mad. Lachapelle, Prat. des Accouch., t. 2, p. 225, and t. 3, p. 180.

⁴ Halderman, Med. Record, July 3 1882, p. 600.

⁵ Little, Voss, Buck, New York Journ. Med., Nov. 1865.

⁶ Tapret and Chenet, Bull. Soc. Anat. de Paris, 1875, p. 25.

limb in cases of ankylosis in children. Chauvel¹ saw a case in which, the separation having been produced in this manner, suppuration ensued, and the patient died of pyæmia. Volkmann² says that he has three times detached the epiphysis by rotating the thigh while seeking for crepitus in patients suffering from hip-joint disease, or by traction made while applying a plaster-of-Paris dressing.

Wm. Smallwood, æt. 12, August 11, 1877, had his right leg caught in the spokes of a wagon-wheel, breaking the thigh at the junction of the lower epiphysis with the diaphysis, the lower end of the upper fragment protruding five inches through the flesh. The end was nearly square. His father, Dr. S. B. Smallwood, of Astoria, N. Y., the lad being under the influence of ether, reduced it within one hour by violent extension and flexion of the leg over his knee, one finger being in the wound, and adjusting the fragments. Lateral splints were employed. The wound closed in about nine months, and in the meanwhile two small fragments of bone escaped. He had also a sharp attack of synovitis. I examined him April 18, 1880, and found the leg straight, but shortened three-quarters of an inch. There is complete ankylosis of the knee-joint, but the muscles of the leg are well developed, and he walks with very little limp.

§ 6. Non-union and Delayed Union of Fractures of the Shaft of the Femur.

Examples of delayed and of non-union of the shaft of the femur are not very infrequent, yet I must be permitted to say that complete failure to unite by bone has never occurred in my practice when I have had charge of the patient throughout; and I cannot but think that in some of the cases which have come under my notice the mode of treatment was responsible for this unfortunate result. The fragments have not been properly supported, or there has been allowed too much freedom of motion. In other cases, no doubt, the cause of delay was some of those conditions of the patient or of the fracture which have been explained in the general chapter on delayed and non-union.

A strong conviction has forced itself upon me that it is never proper, in the case of this bone, to resort to either resection and the wiring of the bones together, or to a seton, or to other means of establishing any considerable continuous or permanent irritation, with the view of exciting the tissues to the deposit of bony callus. The femur lies too deeply imbedded in a mass of muscular and tendinous tissue to make it safe or prudent to excite suppurative action in the neighborhood of the bone, even if the drainage were the most perfect; and both of these methods, thoroughly carried out, insure suppuration. To this danger these methods have to add the necessity, during a long period of time, of confining the patient in splints and in bed; while in the case of all the other long bones—even in the case of the leg, but especially of the upper extremities—it is possible to permit the patient to go about, and thus to retain his general health—a condition most essential to the process of repair.

[The opinion that it is unsafe to perform any operation for ununited fracture of the femur which would excite suppuration is correct. I passed a seton between the fragments twenty-five years ago and lost my patient by pyæmia. But resection and wiring these bones do not, to-day, excite suppurative action, and hence are proper operations when antiseptically performed. The statistics of

¹ Chauvel, *Dict. Encyc.*, Art. *Cuisse*, p. 233.

² Volkmann, *Virchow's Jahresb.*, 1866, 2, p. 337.

mortality from resections performed in the pre-antiseptic period are valueless except for historical comparisons.]

The strictly surgical expedients which are most likely to prove successful in cases of simply delayed union, and which sometimes have proved successful in cases of non-union, after the lapse of months or years, are violent twisting of the limb and drilling; the drilling being made thoroughly through the ends of the fragments, at several points, and repeated from time to time, while the limb is at rest and inclosed in splints.

In Muhlenberg's table of cases published by Agnew, there are 17 cases treated by "manual friction," of which 7 were cured, 10 failed, and none died. Of 18 cases treated by "drilling with its modification," 9 were cured, 8 failed, and 1 died.

In the following case I succeeded by manual frictions, drilling, perforation, and mechanical apparatus combined, or successively employed: May 1, 1877, I perforated the fragments in various directions with Brainard's instrument, then bent the limb violently and applied splints. On the 7th I opened and tightened the dressings. The following day I pushed an ordinary shawl-pin down to and between the fragments, leaving it in place twenty-four hours. On the 10th of May I again introduced a shawl-pin and left it in seven days, causing a slight suppuration near the skin. This was repeated on the 23d, and it was allowed to remain again seven days. I think this was repeated once or twice more. July 12th, bored through both fragments with a gimlet, and left it in forty-eight hours. Aug. 7th, I again used the perforator very thoroughly, and left it in forty-eight hours. Then had constructed for him an artificial support for his thigh and leg. On the 17th of August the fibrous union was very close and firm. November 1, 1878, the fragments were firmly united by bone—a period of six months since the treatment was commenced. He walks long distances without a cane or other means of support, and the consolidation is complete.

In another similar case I was not equally successful. I have twice seen the same measures fail in the hands of other surgeons. As to the value of mechanical supports, which permit the patient to go about with or without crutches, there can be no doubt; yet the reported successes of this method are not very numerous, at least in the case of *old* ununited fractures of the femur.

Muhlenberg, in his tables, reports 29 cases treated by mechanical appliances alone, of which 22 were cured, 2 were relieved, 4 failed, and 1 died. Probably some of these were recent cases.

CHAPTER XXX.

FRACTURES OF THE PATELLA.

IN 1880, I made a careful study of 127 cases of fracture of the patella. Of these, 71 were either treated by me, or they were seen by me in consultation in the course of the treatment, or came subsequently under my notice. Of nearly all of these I made careful notes at the time. The remainder of the 127 cases (56) are copied from the Bellevue Hospital records, including all that had been recorded up to the date of the completion of the study; excluding only those which had been

treated by myself, and were included, therefore, in the class of cases first mentioned. The following is a summary of those cases:¹

Sex.—Males, 99; females, 28.

Age.—Ten years and under, one case. This is the case (52) of a lad five years old, in whom from a direct blow, a small piece of the margin of the patella was broken off.

From ten years, including twenty, six cases; of which 1 (113) was 16 years old—a boy—the fracture being oblique and caused by a direct blow; 1 (case 19) was 19 years old—the fracture was transverse, and was caused apparently by a direct blow. In this case the ligament subsequently gave way completely on the outside, and a new patella formed in the very much elongated ligament on the inner side. The remaining four cases were at the age of 20 years; all were transverse; two are known to have been caused by muscular action—one by direct force, and in one the cause is not stated.

Before the twentieth year of life, then, there were only three fractures, and these were all supposed to be caused by direct blows. Up to this period, muscular action seems to take little or no part in the production of these fractures.

From twenty years, including thirty, 48 cases. From thirty years, including forty, 33 cases. From forty years, including fifty, 22 cases. From fifty years, including sixty, 8 cases. From sixty years, including seventy, 4 cases. From seventy years, including eighty, 1 case. In this one case, the patient, a woman, was eighty years old.

In all the six cases included in the last two decades—that is, from sixty years, including eighty, four are known to have been caused by direct blows, and the remaining case, 80 years old, fell fifteen feet, and it is fair to presume that the fracture was caused by a direct blow.

It would seem, then, that after the sixtieth year, muscular action alone seldom causes these fractures, the largest number of cases having occurred between the twentieth and fortieth years of life; the total in these periods being 103, out of 122 whose ages are known, or, if we include the three at the twentieth year, 106 out of 122 cases.

Of 134 in which this fact is recorded, ninety-three were in the left limb, and forty-one in the right.

Of the whole number, all were simple, except eleven; and of these, nine were comminuted, and two were both compound and comminuted. Of the comminuted fractures, cases 61 and 94 were accompanied with fractures of the thigh also—one died of shock on the fourth day, and one died after amputation, rendered necessary by gangrene.

The fractures were transverse in 106 cases—not including two which were transverse and vertical (comminuted)—of these 106 cases, twenty-two are recorded as below the middle of the patella, sixteen at the middle, and seven above the middle. Twenty-five are known to have been the result of muscular force alone; and fifty-eight are recorded as having received blows upon, or as having fallen upon the patella, and have been placed in the list of those caused by direct blows. In forty-three cases nothing is said as to the cause.

Of the transverse fractures, a majority of those occurring below the middle are ascribed to muscular action—that is, twelve out of twenty in which the cause is given. Of four oblique fractures, three are known to have been from direct force; and all of the comminuted fractures, except case 127, were from direct blows, as were also the two compound fractures.

I infer that active synovitis ensued in at least thirty-four cases, and probably in many others. Inflammation of the bursa of the patella is mentioned once. Probably in most cases the bursa is torn open as the patella ascends, and communicates freely with the joint, so that bursitis could not be recognized as a distinct phenomenon.

In case 90, a compound fracture, the presence of blood in the joint was actually demonstrated. Probably it was present in many other cases, but the fact could

¹ Fracture of the Patella. A Study of 127 Cases, by Frank H. Hamilton, M.D. New York: Charles L. Bermingham & Co., 1880.

not be proven. Pretty extensive subcutaneous *ecchymoses* on the sides of the knee and in the ham were very frequently observed.

Nearly all of the recognized plans of treatment were adopted, but in a majority of cases the same plan of treatment was not continued from the beginning to the close; and it would be difficult in most cases to say to which particular method the result must be ascribed. Of the specific forms of apparatus, there are mentioned Lausdale's, Wyeth's, Turner's, Mott's, Malgaigne's hooks, Sir Astley Cooper's, both of my own methods, plaster-of-Paris, and other forms of immovable dressings, the "lock strap," "wooden-fingers," pulley and weight, crescentic pads, and figure-of-8 bandages, also elastic bands, rollers, etc. Most of the patients have been kept in the recumbent posture, with the foot elevated; but some have been allowed to walk about on crutches, especially when either of the forms of immovable apparatus has been employed.

It is stated distinctly in 84 cases that the union was fibrous. The bond of union did not permit the fragments to be moved upon each other soon after the treatment was concluded, and therefore may have been constituted of bone, in three or four other cases. In three cases no union ever occurred.

The length of the bond of union is given as $\frac{1}{4}$ of an inch in 16 cases; $\frac{1}{2}$ in 33 cases; $\frac{3}{4}$ in 13 cases; 1 inch in 3 cases; $1\frac{1}{2}$ in 2 cases; 2 in 3 cases; $3\frac{1}{2}$ in 1 case; 4 in 1 case, and 5 in 1 case. The last four cases, or those in which the separation exceeds $1\frac{1}{2}$ inches, are respectively cases 22, 23, 54, and 111. The above records, it will be understood, do not include cases of rupture subsequent to union, but only the results of the first treatment. It is not to be supposed that these estimates of the length of the bond of union are absolutely accurate. Probably the length of the ligament was generally a little more than is stated, but the records are sufficiently accurate for our purposes. All but 8 are united with a ligament of one inch or less in length, and the largest number have a ligament of only half an inch.

Ankylosis—more or less complete—has existed in nearly all of the cases when the limb was first removed from the apparatus; being most complete, as a rule, in those cases in which the joint has been kept the longest in the dressings, without the use of passive motion. In no case recorded has force been resorted to to overcome this ankylosis; but it has gradually disappeared under passive and active use of the limb within a year or two.

The new ligament has given way more or less completely in 27 cases. Possibly we may have included in this number one or two which were never held well in position, in which the inner portion of the ligament alone is elongated. This unilateral elongation occurred three times on the inner side and once on the outer. Of the entire number, 5 were gradual, the elongation commencing soon after the patients began to walk; and 18 occurred within ten weeks after the receipt of the original injury, generally on the seventh or eighth week, when the patient in his first attempt to walk has slipped, and the limb has been suddenly bent. After the eighth week there are, 4 cases at 3 months, 3 at 5 months, and 1 at 2 years and 4 months (case 18). Case 21 is put down as refractured after 4 years; but the history of the case is doubtful. I think, in the light of this experience, it may be said that after the fifth month there is usually no more danger to the injured limb than to the sound one.

The lower fragment was found slightly tilted forward in one case; and the lower fragment overlapped the upper a little in another. The upper fragment was tilted over by the elongation of the inner portion of the ligament in three cases; and in the opposite direction by the giving way of the outer portion in one case. In one case a new patella was formed in the much-elongated ligament.

Five cases belong to this class. These latter accidents have evidently resulted from the fact that the sound limb has been compelled to receive alone the resistance in efforts to prevent a fall.

Hypertrophy has been noticed in 9 cases; namely, twice in the upper fragment alone, once in the lower, and six times in both. It is probable that its occurrence is much more frequent than this record implies.

Of the primary accidents, that is, of those in which there was no subsequent rupture of the union, I have been permitted to examine 23 cases, at periods of time ranging from four months to twenty-nine years. Only four of these are said to have acquired perfect, or nearly perfect, use of the limb in a less period

than two years, although in general they have resumed work within about one year. The cause of this inability to labor has almost invariably been the lack of the necessary freedom of motion of the knee-joint—a partial ankylosis.

It is remarkable, however, that in one case, a British soldier, there being no union and a separation of the fragments to the extent of five inches, he was able to walk well at the end of twenty-nine years, when I saw him. One case was seen after four years with a separation of four inches, and another was seen after seven years, and both walked badly.

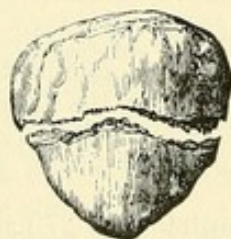Of 15 cases in which the ligament gave way within a period of three months from the time of the original accident, that is, soon after the union had been effected, 12 have terminated very satisfactorily. Under a renewal of the treatment the fragments have united with a short ligament.

Having given this brief analysis of these cases, I shall proceed to consider the subject of fractures of the patella in a more general way.

§ 1. Etiology of Fractures of the Patella.

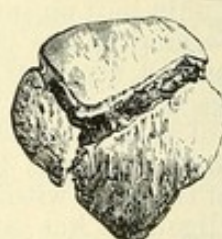Twenty-five of the cases reported by me are known to have been the result of muscular force alone; the fractures having occurred without a fall or while the patient was standing, and in some cases when the knee was not bent, the fracture being announced by a distinctly felt snap. I believe, however, that muscular action was more or less efficient in caus-

FIG. 268.



Simple transverse fracture.

FIG. 269.



Comminuted fracture.

ing the fracture, in all the simple transverse fractures, and in at least one of the comminuted fractures. My reasons for this opinion are: the great power of those four strong muscles which unite to form the tendon of the quadriceps—the fact that ninety-nine occurred in males—that only three occurred in persons under twenty years of age, and only five after the sixtieth year—the largest number being between the twentieth and thirtieth years of life—the remarkable uniformity in the direction of the fracture; and finally, because I am unable to cause a transverse fracture on the cadaver by a direct blow. I might have added also the fact, as attested by museum specimens, that the fracture is very uniformly from before backward and downward, as would be the case if it were caused by a cross-strain, the active force being attached to the upper fragment. That the bone breaks most often in the lower third is probably due to the fact that when the knee is slightly bent—and this is the position of the limb in which the fracture generally occurs—the centre of the patella rests upon the condyle of the femur, leaving the upper and lower portions unsupported, when the lower portion, being the weaker of the two, gives way under the cross-strain. A patella having given away, transversely, to muscular action, those fibres of the quadriceps which are inserted into the sides of the patella still continuing to act, may break the bone vertically, or cause them to separate laterally.

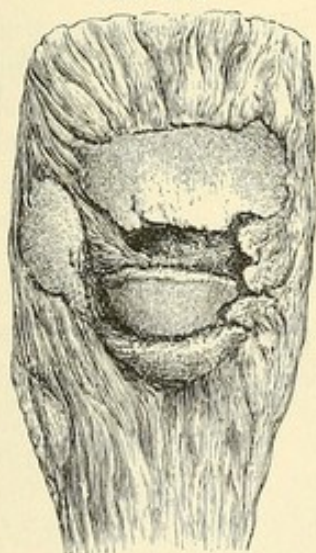The source of error in estimating the value of muscular action in the production of this fracture has been, that in the majority of cases the patients have actually fallen upon their knees, and all such cases have been set down as caused by direct force; but in a fall on the knee upon a plane surface, when the leg is flexed to a right angle with the body, the patella does not touch the plane; it is only the tubercle of the tibia which touches, and the contact with the plane has had nothing to do with the fracture, except as causing, by the concussion, a more active contraction of the muscles already rendered tense by the position and by the effort to prevent the fall. If a man falls headlong, with his knee slightly bent, the patella may strike the floor, and in this way, and by other methods, the patella may receive a direct blow; but even then, if the fracture is transverse, it is probable that the blow induced the fracture by causing a sudden spasmodic action of the muscles, for, as I have said before, we cannot imitate the fracture by a direct blow on the patella of the cadaver.

[When a person falls directly upon the patella there is a liability to a stellate fracture.]

§ 2. Anatomy, Pathology, and Semeiology.

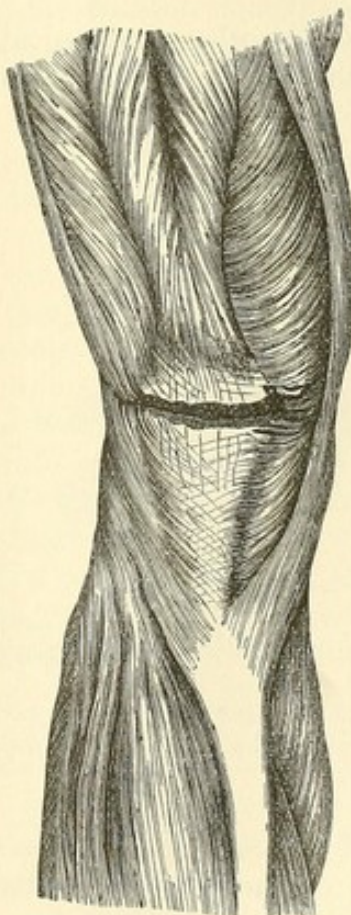
I have already stated that the fracture is almost uniformly transverse, occasionally oblique, and in a few cases the line of fracture is slightly curved; very seldom is the line of fracture vertical. The fracture occurs most often in the lower third, and least often in the upper third. In the

FIG. 270.



Stellate fracture. (Erichsen.)

FIG. 271.



Transverse fracture of the patella.

transverse fractures the direction of the fractures is from before backward and downward.

In a large majority of cases the lesion is limited to the bone, its periosteal coverings, and the thin and scattered fibres of the tendon of the quadriceps which traverse the front of the bone to become continuous with the

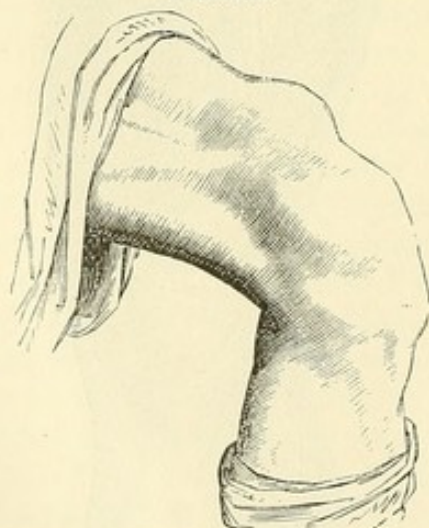
ligamentum patellæ. Perhaps a few of the fibres of the aponeurosis on either side of the patella give way also, but the lesion of this aponeurosis is ordinarily not extensive. For this reason the upper fragment seldom separates from the lower more than one inch, and in most cases only about half an inch. It is only when great and extraordinary muscular force has caused the fracture, that the aponeurosis is sufficiently torn to permit the upper fragment to ascend two inches or more; and we may always estimate the extent of this latter lesion by the extent to which the upper fragment is drawn up.

In a dissection which Dr. Girdner kindly prepared for me, he exposed the patella and the quadriceps with its broad lateral aponeurosis, which passes down, spreading out, to be inserted finally into the sides of the tibia and fibula at their upper extremities. He then divided the patella transversely with a chisel, leaving the aponeurosis untouched, and we observed now that by no amount of pressure upward short of that which would cause a laceration of the aponeurosis could the upper fragment be made to ascend more than half or three-quarters of an inch. By cutting the aponeurosis on either side, the fragment could be pushed up further, but the cutting had to be very extensive before it could be pushed up three inches, as has happened in some of the recent cases which have come under my observation. Such extensive separation, therefore, implies necessarily extensive laceration of the aponeurosis.

[Much light was thrown upon the question of the liability to ligamentous union in fractures of the patella, by Macewen,¹ who proved by dissections that one of the most constant conditions of the recent fracture is the interposition between the fragments of the lacerated prepatellar aponeurotic structures. This fact has been repeatedly established by those who operate upon recent fractures. In the majority of cases it is apparent that bony union could not take place except after the operation of wiring.]

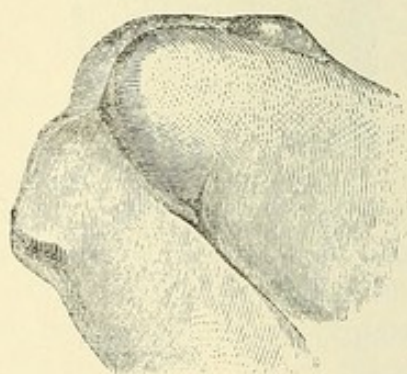
There is another anatomical lesion, the existence of which it may be proper to assume in the majority of cases, although we have not the

FIG. 272.



Separation of the fragments in moderate flexion when the whole aponeurosis and tendon is torn.

FIG. 273.



Fragments separated by forced flexion of the knee.

means of demonstrating its occurrence. The posterior wall of the bursa in front of the knee is probably lacerated, and the joint surfaces, or

¹ Annals of Surgery, March, 1887.

articular synovial capsule is made to communicate freely with the cavity of the bursa.

This bursa is usually present in adult life, and is especially well developed in males. Its posterior wall is composed of a thin synovial membrane, which is in direct contact with the front of the patella and its immediate investments; so that a separation of the fragments to the extent of half an inch could scarcely occur without laying open the bursa. The exception must be found in those cases in which the bursa is not at all, or is only imperfectly developed, or the fracture has taken place at a point which does not exactly correspond to the under surface of the bursa. I have once or twice observed, a few days after the fracture, a fulness in front of the patella so defined as to seem to indicate that the bursa had not been torn, but that it had inflamed and become filled with serum; but I imagine that this appearance might be presented sometimes when a communication with the joint had been established, and the bursa had become filled, its anterior wall being simply pressed forward by the fluids of the joint.

There remain then, usually, in front of the joint nothing but the skin and a thin layer of areolar tissue, or probably the skin alone, which if it were not at this point very redundant and elastic would often be torn, rendering the fracture compound.

In no case under my notice has the skin been torn as an original accident, however much the fragments may have separated; but in one case, not recorded in the preceding report, but which was at the time under the care of Dr. Erskine Mason, the skin was torn in a subsequent accident—a rupture of the new ligament—the fragments being separated very widely. Suppuration of the joint ensued, and it became necessary to amputate at the knee-joint by Cardan's method, after which he made a good recovery.

It has been found possible sometimes for the patient, immediately after the accident, to continue standing, or even to walk by exercising great care, but in most cases the patients have at once fallen to the ground and been unable to rise. Very speedily, often within a few minutes after the injury is received, the joint appears swollen. This early swelling must be in part attributed to the effusion of blood into the joint from the broken patella and adjacent tissue. The presence of blood in the joint was demonstrated in one case, and there can be no reason to doubt that it is often, perhaps always, present in the joint in some amount, after the fracture, where it probably undergoes a pretty rapid disintegration and is mostly absorbed. There is quite often, also, at an early date, considerable discoloration of the skin on the sides and back of the knee, caused by the infiltration of the blood into the subcutaneous areolar tissues. A synovitis and bursitis (when the bursa is torn) are inevitable also; the amount of inflammation being more or less in different cases, but being, in most cases, sufficient to fill the joint with serum and probably some lymph, within the space of a few hours, or days at most. This effusion, caused by the synovial inflammation, generally begins to disappear within a week or ten days, and cannot usually be detected after the second week; but meanwhile, pretty often, a more or less extensive cellulitis ensues, involving the front and sides of the knee and extending some distance up and down the limb. Usually this is moderate, but it has occasionally, and especially when injudicious pressure has been employed, resulted in suppuration of the areolar tissue.

§ 3. Mode of Union and Prognosis.

The frequency with which, according to my observations, the bond of union has given way at some subsequent period, renders it necessary that I should speak of the character of the union and the prognosis relating to primary accidents, and the character of the union and the prognosis relating to secondary accidents, separately.

1. Character of the Union and Prognosis in Primary Accidents.—

In my published cases the bond of union is known to have been fibrous in one, and in no case is it known to have been bony; but quite often it has been thought, when the patient was first dismissed, that the union was bony, and in almost every case a much later examination has shown that it was fibrous. When the dressings are first removed there is often such a degree of hardness of the tissues between the fragments as to lead one to suppose that the fragments have united by bone, and they are so fixed that they cannot be made to move separately, but which deceptive appearance is removed in the course of a few weeks or months.

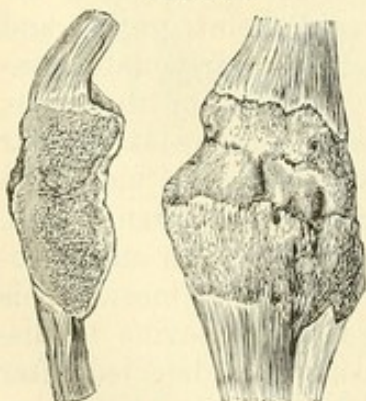
I do not know positively that in any case the union was by bone. If I were to state my convictions, I would say that probably none of the tabulated transverse fractures were united by bone; and that only a small proportion of the vertical and comminuted fractures were thus united. I do not deny the possibility of union by bone. A few cases, verified by the autopsy, have been reported from time to time, but I have never seen but one case verified by dissection.

Bony union was for a long time considered impossible.

Pibrac challenged all surgeons of his time to show him a patella thus united. Dupuytren, who thought he had obtained a union of this kind, offered for the patella of his patient its weight in gold. According to Velpeau, however, Wilson and C. Bell had seen a case of bony union; Lallemand had demonstrated its possibility, and there was a specimen of it in the Hunter museum.

The length of the fibrous bond, in primary cases, is usually about half an inch, and ranges from one-quarter of an inch to five inches; but of

FIG. 274.



Fracture of patella united by bone. (Bryant.)

the whole number recorded by me, there are only four in which the new ligament is more than one and a half inches in length. These latter are, therefore, exceptional cases; and were rendered so by the greater violence inflicted, and the more extensive rupture of the aponeurosis and muscle, or by injudicious treatment.

[The formation of bone in the ligamentous material has been noticed by Page,¹ of London. In a man who had fractures of both patellæ many years previously, he found a mass of bone between the fragments, which was of the same width as the ligament, and seemed to be separate from the other portions of the patella.]

We may appreciate where the responsibility generally lies, when fragments unite with so much separation, as in the following cases: S. H. had an abscess which had formed without any appreciable cause

¹ London Lancet, March 17, 1888.

in the areolar tissue, just above the left knee. He had an old fracture of the patella in the same limb, the fragments being separated nearly four inches. He was unable to extend the limb by muscular action, there being apparently no bond of union between the fragments. The accident occurred about three years and five months before. He was immediately taken to Bellevue Hospital. On the fourth day the limb was laid upon an inclined plane. On about the seventh day a plaster-of-Paris splint was applied, from the foot to the hip. He was permitted to go about on crutches. When the splint was removed the fragments were separated two inches. He has had no treatment for the fracture since.

J. S., æt. 24, was struck in the right knee while he was sitting with his leg bent under him. Severe inflammation and swelling ensued, and no apparatus was employed until the twelfth day; a compress was then laid over both fragments, and they were bound on with a roller, the limb being laid upon an inclined plane. The bandages were removed at the end of four months, when the upper fragments at once drew up toward the body. It was eighteen months before he could walk without a cane. Twenty-nine years after the accident I found, when the limb was straight, that the upper fragment lay two and a half inches above the lower, and when the limb was flexed it separated five inches. No trace of a ligament or other bond of union could be felt. He walked well, without a cane, there being very little or no halt, but he could not walk fast.

J. M., æt. 56, broke his *left* patella transversely, below the middle, by a fall upon the knee. A surgeon was called, and applied bandages. He was four or five weeks in bed, and then went out, using a cane. The fragments were then found to be much separated. Seventeen years after the accident, I found the fragments separated three and half inches when the leg was straight, and four and three-quarters when it was flexed. Fragments of normal size. No ligament between the fragments; but along their outer and inner margins the tendinous fibres of the quadriceps are prominent, and especially on the outer side. He cannot extend the leg by muscular action when sitting, but he can flex it to an acute angle with the thigh. Standing he can flex and extend it perfectly. In extending he turns the foot out, in order to bring into action the outer portion of the quadriceps. He has always, since this accident, been somewhat lame, but could walk several miles and carry loads without a cane. May 25, 1879, he slipped and fell, striking upon the right knee, and breaking the *right* patella transversely about its middle. June 1, a surgeon applied adhesive strips over and above the patella, then a plaster-of-Paris bandage from the hollow of the foot to above the knee. Fragments were separated an inch or more. Began to walk. A few days later the leg suddenly gave way, and he fell back. The skin became discolored, and it swelled very much. When he consulted me the fragments of the right patella were separated one and three-quarters inches when the limb was straight, and three inches when it was flexed. He walked slowly without a cane, but was in constant fear of falling. I advised him to submit to a second trial to obtain a more satisfactory result in the case of the right leg, but he declined to do so.

[The position of the fragments in transverse fracture should be borne in mind in treatment. The upper fragment is generally found tilted upward, and care must be taken to force it into position by the application of the bandage directly around the knee.]

I have found the fragments *tilted*, in consequence of a yielding of the new ligament, or because of a pressure of the bandages, in four cases. In three of these it was the inner portion of the ligament which had given way, and in one the outer. If from so few examples it is proper to infer the existence of a rule, and to declare that the inner portion gives way most often, we may perhaps find a reason for the rule in the fact that the inner portion of the quadriceps is more powerful than the outer portion, and might therefore act more energetically upon the inner margin of the upper fragment, and cause it to separate more widely from the lower.

Malgaigne made the same observation which I have made, and does not hesitate to speak of it as a rule, or absolute law; declaring that it is always the inner portion which is found elongated; but I have mentioned one example in which the fact was otherwise. Boyer also alludes to the tendency in the upper fragment to tilt outward; and both of these writers think that the phenomenon is due to the manner in which the pressure of the apparel was made to bear upon the upper end of the upper fragment.

The upper margin of this fragment is not horizontal, but oblique, its outer portion being considerably above the plane of its inner portion; so that any form of adjustment in which the plane of pressure from above is horizontal will press more effectively upon the outer than upon the inner portion, and cause the upper fragment to tilt, or incline outward. It seems to me that both unequal muscular action and the direct but unequal, or maladjusted, mechanical pressure of nearly all forms of apparel employed to bring down the upper fragment, may be considered as alike responsible for this result. This I have sought to avoid by employing a somewhat elastic cotton roller for the purpose of making the downward pressure.

Occasionally it is found, when the fragments have united, that one or both of the fragments are *inclined a little forward* at the point of fracture, forming an angle salient in front. Usually it is but one of the fragments that is thus inclined; and in most cases, if not in all, that fragment which is the longest is the one which projects. Thus, of my published cases, two were transverse and in the upper third, and when union was completed the upper margins of the lower fragments overhung the lower margins of the upper. The longest fragment resting upon a convex surface, and being no longer held in position by a counter-force, the ligamentum patellæ or the quadriceps must inevitably incline forward. Indeed, I have seen this condition present in a recent fracture before any apparatus had been applied; but in such cases very slight pressure, applied from before backward, was sufficient to restore it to place; and it is quite certain that for this result after union is consummated, the apparatus employed to bring the fragments together is mainly responsible. Both the quadriceps and the ligamentum patellæ have their insertions nearer the anterior than the posterior margins of the patella, a thin layer of tendinous fasciculi actually traversing its anterior face. The upper and lower margins of the patella, therefore, present no elevations for the application of concentric pressure; and if by any form of apparatus concentric pressure is made, it must be accomplished by causing a depression in these firm ligamentous bands, or a recession from the tegumentary surface, in order that the concentric forces may have a *point d'appui*. This pressure must depress the corresponding margins of the two patellar fragments, and elevate their broken margins; and in this case the longest fragment will suffer the greatest displacement. Both these displacements, namely, the tilting and the forward projection, are imperfections which contribute their proportion to the subsequent maiming; causing, in the one case, a relative loss of strength in the ligament, and in both cases causing some irregularity in the movements of the patella over the surface of the femur.

There is another form of displacement to which I have not yet referred,

but which seems in most cases to be temporary, although it is probable that it is not in all cases—namely, a simple *lateral displacement*. This existed in one case before the treatment was fully terminated. The upper fragment was found displaced inward one-quarter of an inch, and it could not be moved from this position—at least not without greater force than it seemed proper to apply. In this case, however, the fragment subsequently, when he had used the limb some time, gradually loosened and resumed its natural position.

I think the same happened in one or two cases, and that they subsequently came into line. Probably in each case it was caused by the lateral pressure of the bandage, or of other parts of the dressing, and might, therefore, have been avoided. It is easy to imagine that if the fragments are thus displaced the bond of union may be imperfect or unequal on the two sides, or that it might diminish the chances of union, and in either case the evil results might be permanent and serious.

Hypertrophy of the fragments must be distinguished from an exostosis, such as is frequently observed along the margins of the fracture, and which is never considerable, only causing a slight irregularity in the surface of the bone, but which may be present without any peripheral enlargement or expansion of the fragments.

This actual hypertrophy has been observed by me in nine cases, namely, twice in the upper fragment alone, once in the lower fragment alone, and six times in both. The occasional hypertrophy of the fragments has been noticed by other writers, and Malgaigne has furnished two illustrations. The same thing is known to happen pretty often in some of the long bones when broken near their extremities, where the structure is cancellated. I have noticed it often in the fracture of the humerus near its lower end, the lower fragments being in all such cases the ones which become hypertrophied. In the case of the humerus the hypertrophied fragment, sometimes after many months or years, is found to diminish; but whether such a gradual diminution in size takes place in examples of hypertrophied patellæ I am not certain. It has not seemed to me that it does occur.

(a) **Period required for Recovery of the Perfect Use of the Limb.**—More or less loss of freedom in the motions of the joint, and of strength and stability in the limb, remains in the majority of cases for a long period of time, and often during life. In a few exceptional cases, where the separation does not exceed one inch, the functions of the limb are completely restored within one or two years. It is remarkable, also, how well the functions are restored, after a long time, in some cases where the separation is very great.

Malgaigne says: "Camper has stated that in one or two years the power is recovered, whatever may have been the intervals between the fragments; an evident exaggeration, since he speaks of a lady with a separation amounting to three fingers' breadth, who still limped four years after the receipt of the injury. Mr. Benjamin makes one inch the line of separation, allowing for the restoration of the firmness of the knee; Boyer follows him; M. Velpeau, on the contrary, affirms that he has seen the functions of that joint completely reestablished, with an interval of two or three inches between the fragments. Such assertions are, in my opinion, only accounted for by some inaccuracy of examination, and for my own part I have never seen the functions of the limb completely restored, even when the separation was limited to one-third of an inch."¹ For myself, I have

¹ Malgaigne, op. cit., p. 606.

seen three or four perfect results, so far as the use of the limb is concerned. In one case, after nineteen years, there was not the slightest difference in the freedom of use of the two limbs; yet the union is by a ligament of three-quarters of an inch in length.

The first and main impediment in the restoration of the functions of the joint is the *ankylosis*, which is, in many cases, at first nearly complete. This ankylosis is due to the passive contraction of the articular ligaments, as a consequence of long disuse; to adhesions and inflammatory infiltrations among the torn muscular and tendinous fibres; and between these latter and the upper fragment of the patella as it lies more or less buried in the torn tendinous tissues. It is never safe to attempt to overcome this ankylosis by force, consequently the process of restoration must be slow and uncertain, and it will generally be found to be many years before the leg can be flexed upon the thigh to the same angle as in the case of the opposite limb.

[The impairment of the function of the limb must be in part ascribed to the wasting of the quadriceps. Verneuil attributes it to atrophy of the rectus femoris. Richelot (*Union Médicale*, 1882) thinks this atrophy is due to the arthritis which accompanies the fracture of the patella. Whatever may be the cause of the atrophy the indication in treatment is apparent, viz., that early efforts should be made to improve the condition of the quadriceps, as by massage.]

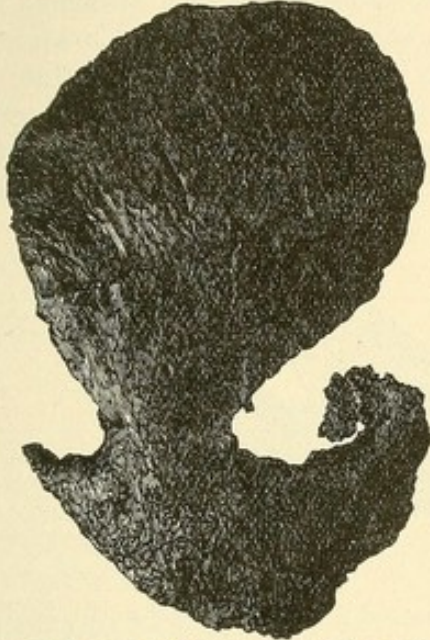
In a certain degree, also, the changed relations of the fragments to the articular surface of the femur may be responsible for the lameness. As to what influence the nature and length of the new bond of union have upon the usefulness of the limb, I am prepared to say, first, that the fact that it is generally fibrous and not bony is probably of no consequence, provided the bond of union does not exceed one inch in length. It certainly is in no way responsible for the ankylosis; and, as to its effect upon the stability or strength of the limb, there is no reason to suppose that this slight diminution in the range of the contraction and elongation of the quadriceps will have, after one or two years of use, any appreciable effect upon the stability of the limb. Indeed, so far as I have been able to ascertain, in most of these cases the patients have been able, after a time, to extend the limbs as completely if not as forcibly as before. If, however, the length of the fibrous bond is much more than one inch, there is generally an appreciable loss of the power of complete and fixed extension.

We have had recorded too few well-attested examples of bony union to enable us to declare whether the fibrous union or the bony union is most liable to a secondary accident—a refracture. It would seem reasonable to suppose that the newly-formed bone would be thinner than the original bone and less spongy, and that in consequence of its compactness and thinness it would break more easily under a cross-strain than would an equally thick, but flexible, ligament.

Dr. Kendig, of Ohio, has kindly sent a specimen to me in which union of the two fragments of the patella has taken place by means of two thin plates of bone, corresponding to the inner and outer margins of the patella, leaving between them an open space, which in the recent state was probably occupied by fibrous tissue. Of the two plates which compose the bond of union, the inner is much the larger. It is evident, upon the most superficial examination, that the least flexion of the limb would have been sufficient to cause a rupture of the bony callus; indeed, the outer plate was broken and partly destroyed in cleaning it.

My conviction is that a fibrous union of less than one inch in length is quite as advantageous as a bony union, and probably much stronger—a conviction which is enforced, also, by a case of Dr. Little, of this city. A fractured patella united by fibrous tissue with a separation of half an inch. About five and a half months later the same patella was fractured at a point about half an inch above

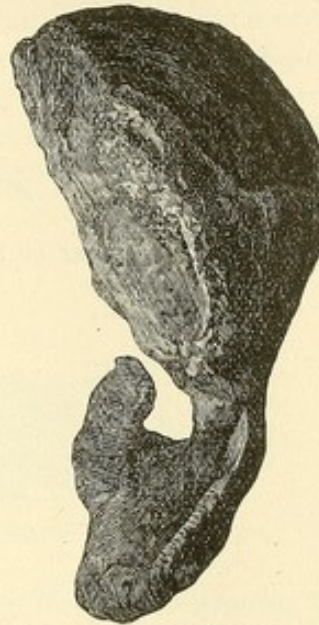FIG. 275.



Dr. Kendig's case of bony union after a fracture of the patella. (From author's collection.)

Front view.

FIG. 276.



Side view.

the first fracture and transversely. This united also by fibrous tissue of the same length as the first. The three fragments were movable upon each other, and no doubt can exist as to the character of the accident. In this case at least, then, after the lapse of a little more than five months, the new ligament has proven itself to be stronger than the original bone.

(b) **Rupture of the Newly-formed Ligament.**—In the prognosis of original fractures we have to include the danger of a rupture of the newly-formed bond of union. Indeed, my statistics, already referred to, show a startling frequency of this accident. It is known to have occurred in twenty-five cases, and in two additional cases the ligament has given way partially. A knowledge of this fact is of the greatest importance, as indicating the necessity for great care in the use of the limb after the surgeon has practically dismissed the patient.

Some of these cases were persons who sought my advice only after the treatment had terminated, and they might not therefore correctly represent the true proportion in a given number of consecutive cases. On the other hand, it will be remembered that a considerable number of the one hundred and twenty-seven tabulated cases were not seen or heard from by me, after the treatment was terminated; so that, on the whole, I think that twenty-seven out of every one hundred and twenty-seven represents fairly the average ratio of these accidents.

It is reassuring to know that two-thirds of the whole number were ruptured very soon after leaving off the apparatus; that is, within ten weeks after the original fracture had taken place; and that five of these took place gradually, commencing when the patient began to walk. Only two occurred later than five months after the injury, or about three months after the apparatus was

removed. It would seem, therefore, that it is only necessary to provide against the accident during the first three months after removal of the splint, and that after this a rupture is no more likely to take place than if it had not been broken.

FIG. 277.

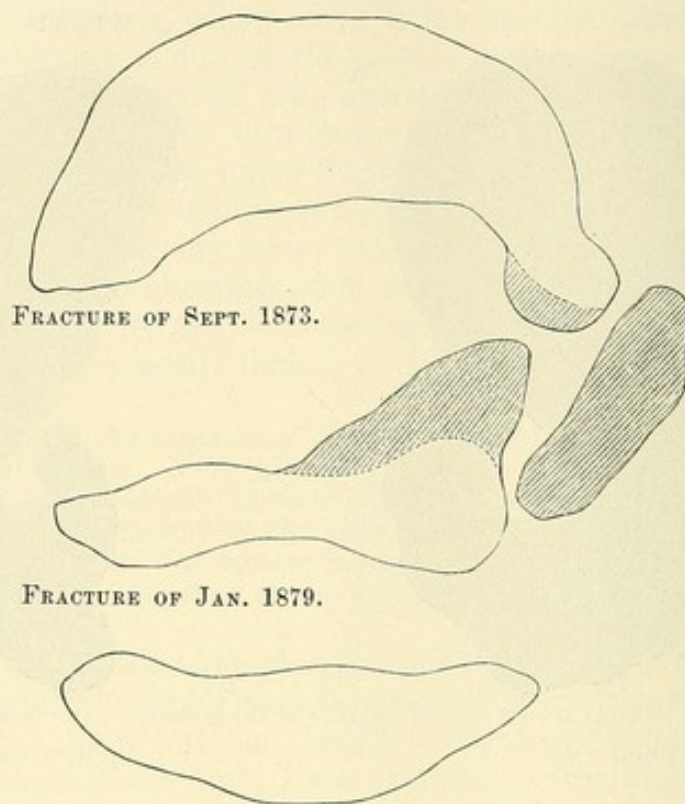


Fig. 277 represents the position of the fragments after two successive fractures, in the person of Dr. E. Cutter, of New York, examined by the author in 1884. Actual size. Fragments united by ligament. The shaded lines represent new bone.


(c) **Fracture of the opposite Patella.**—This has happened five times in the one hundred and twenty-seven cases, and was no doubt due in each case to the greater effort made by the quadriceps of the sound limb to sustain the body, when the equilibrium of the body had been disturbed.

2. Character of the Union, and Prognosis after the Secondary Accident.—A majority of cases refuse to unite again, even by fibrous tissue, whatever means may be employed; and the few cases of union after rupture of the fibrous bond which have come to my knowledge, are confined almost entirely to those examples in which the rupture took place very soon after the apparatus was removed, and in which the limb was immediately subjected to treatment. When the fragments do not unite the patients are for a long time seriously maimed, the limb lacking stability, and often giving way suddenly under the weight of the body. In most of these cases, however, a judicious treatment will eventually give considerable stability to the limb, and enable the patient to walk with much safety and ease.

§ 4. Treatment of Fractures of the Patella.

Treatment, in Primary Accidents.—Our investigations have brought us to conclude that in a large majority of cases, under any plan of treatment, a fibrous union of the fragments is all that can be expected; and that probably a fibrous union, with only a separation of a half or three-quarters of an inch, is as useful as a bony union. Probably more useful. The only methods which could encourage a reasonable hope of procuring a bony union, are Malgaigne's hooks, and wiring the fragments together. Malgaigne's hooks have hitherto not been proven to accomplish this result, not even in the hands of the distinguished inventor. In fact,

FIG. 278.



Malgaigne's hooks.

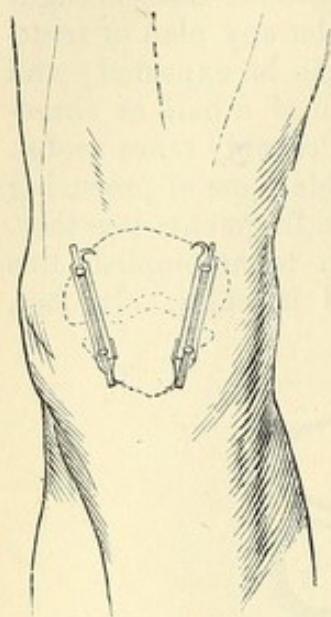
contrary to what I would have expected, there have been among the cases reported as many examples of fully-recognized fibrous union, as have occurred where some other plans of treatment have been followed; the fibrous band has been no shorter; and the number of cases in which a bony union has been said, but not proven, to exist soon after the removal of the apparatus, is no greater than almost every other method has supplied. On the other hand, several cases have been reported of dangerous or disastrous inflammation induced by the hooks, and to this objection many other methods are never liable. There seems no possible reason, therefore, why in any ordinary, simple transverse fracture, in which the original separation does not exceed one inch or even one and a half inches, the hooks should be employed; but in cases in which the original separation exceeds this, and especially in cases of a refracture or rupture of the fibrous bond, accompanied with great separation, it is my opinion that Malgaigne's hooks are entitled to a further trial.

[The opinions of surgeons in regard to the dangers of Malgaigne's hooks, and their value, have been greatly modified since the introduction of antiseptics into practice. They are now used antiseptically without inflammation. At a meeting of the Harveian Society, London, in 1888, Mr. Silcock presented a patient treated by Malgaigne's hooks in which he considered that bony union had been obtained. Antiseptics were used. Mr. Treves considered them an almost perfect method of treatment, although it was difficult to obtain properly manufactured hooks. Mr. Wm. Adams thought this method gave excellent results and did not injure the joint. All who use them insist upon the most careful attention to the antiseptic precautions. The limb must be thoroughly cleansed, the parts shaved and treated with sublimate douches; the instrument must be placed in carbolic acid solutions; the punctures must be made for the teeth with a tenotome; the knee must be dusted with iodoform.]

"That Malgaigne's hooks," says Volkmann, "have caused ulceration of the joints and death of the patient in a number of cases, is only too true; I know

of two which occurred in the practice of friends, and which were never published; and another sad experience was met with in my own clinic a number of years since."¹ A death occurred in a London hospital from the use of these hooks.² The modification of

FIG. 279.



Levis's hooks in position.

Malgaigne's method suggested by Valette, of Lyons,³ in the substitution of adjustable forks for the hooks, does not render the apparatus less liable to do harm.

Farther modifications of the apparatus have been made by Levis, of Philadelphia, Verneuil, Le Fort, and Trélat, but without materially diminishing the possible or probable danger.

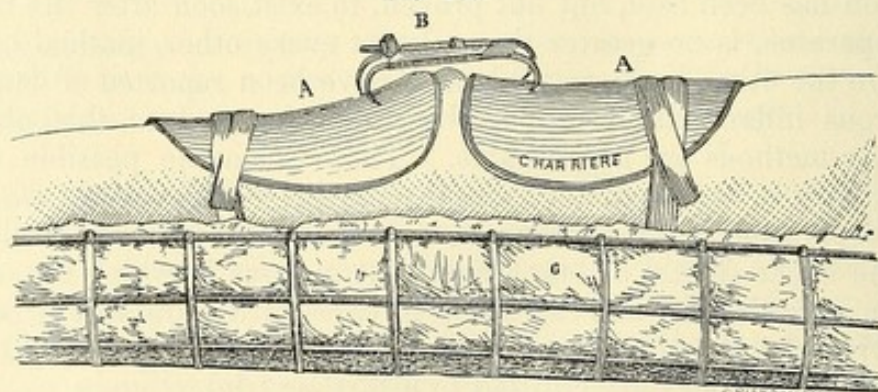
[Levis separated the hooks (Fig. 279), and Trélat fixed the hooks in gutta-percha splints (Fig. 280). These modifications will be understood by the illustrations.]

Séverin was the first to suggest exposing the bone "by an incision, so as to refresh the surfaces directly;" "which happily," says Malgaigne, "was not done."⁴

[Stimson,⁵ of New York, has employed a "coaptation fork," which is of iron, two-pronged, the prongs bent on the flat at an angle of about 45° at their junction with the shaft; the prongs are one inch long and three-fourths of an inch apart; the shaft is about three inches long; there is a small ring at the base of the prongs for the attachment of a rubber cord, and another at the end of the shaft for the attachment of a bandage encircling the thigh. The instrument is

used by inserting the prongs through the skin above the patella and pressing them down until they rest against the upper border of the upper fragment; the shaft lies along the median line of the front of the thigh, and is prevented from tilting or moving to either side by a roller bandage wrapped around it and the

FIG. 280.



Trélat's method of applying hooks.

thigh. Traction downward is made by a piece of rubber tubing one end of which is attached to the ring at the base of the prongs, and the other made fast to the front of the shin by adhesive plaster. The introduction of the prongs is made after chilling the surface with ice, and making punctures of the skin with a knife. The punctures are dusted with iodoform. The lower fragment is kept gently pressed forward by an oblique turn of a roller bandage.]

[W. K. Otis,⁶ of New York, has devised a new form of hooks (Fig. 282), which is designed to remedy some of the defects of Malgaigne's hooks. Its peculiarities

¹ Volkmann, *Cent. f. Chir.*, 1880, 24.

² *London Lancet*, Nov. 22, 1879.

³ Valette, Poincot, *French ed. of this treatise*, p. 611.

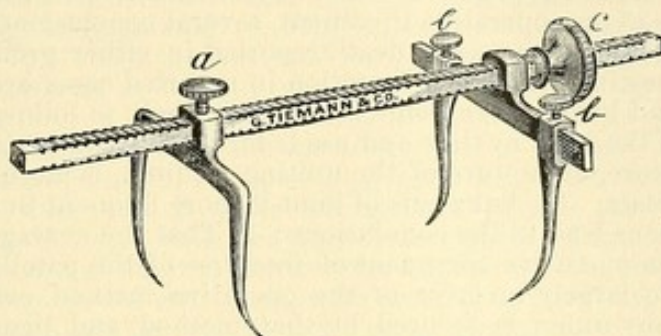
⁴ Séverin, *Chir. efficacie*, part ii. chap. vii. Malgaigne, *op. cit.*, tom. i. p. 775.

⁵ *Amer. Surg.*, St. Louis, vol. i. 1885.

⁶ *New York Med. Journ.*, Dec. 31, 1889.

will be understood from the illustration. It is applied as follows: An ordinary straight posterior knee-splint having been applied, and the knee and instrument rendered thoroughly aseptic, the movable pair of hooks are adjusted to fit one fragment and firmly clamped to the cross-bar. Four punctures are made with a tenotome, or small bistoury, through the integument down to the bone, at points corresponding to the insertion of the hooks. The hooks having the set screw (a) are removed from the bar and adjusted, the points being passed through the punctures and pressed into the bone. The second pair are applied to the

FIG. 281.



Otis's hooks for fractures of the patella.

other fragment in a similar manner; the fragments are now brought together as near as possible by manual force, the main bar is slipped through the slot on the cross-bar of the first pair of hooks and clamped in position by a turn of the screw (a); any separation which may still exist may be overcome by the thumb-screw (c).]

Norris¹ knew of one case in which the fragments were exposed and approximated by wire (Dec. 1842), and the patient died on the fourth day. Dr. J. Rhea Barton, of Philadelphia, operated in the same manner and his patient died.² Dr. Moses Gunn, of Chicago, lost his patient from suppuration.³ Dr. Cabot,⁴ of Boston, had the same result. Cooper⁵ and Logan,⁶ of San Francisco, made a similar operation, and Dr. Byrd⁷ says it was made "many years ago" by Dr. George McClelland, of Philadelphia. The precise dates and results of the three latter operations are not published. Since the introduction of Mr. Lister's antiseptic treatment it has been thought, by some, that the operation of exposing and wiring the fragments together could be made with more safety. The operation, under antiseptic precautions, has therefore been lately practised by a considerable number of surgeons.

[The primary treatment of simple fracture of the patella by wiring the fragments must be regarded as still unsettled. It is true that the operation has but few advocates, yet it is by no means wholly discarded even by those who would not recommend it as a method of general application. Exceptional cases occur which invite to its performance, especially in hospital practice. The most recent and instructive contribution to the subject is a paper by Dr. Charles Phelps,⁸ of New York, which is based on 42 operations by himself. Antiseptic precautions were carefully taken in each. The following facts are gathered from the table in this paper: males 82, females 10; ages averaging from 21 to 83; right 15, left 27; intemperate 15, temperate 19, not given 8; physique good 24, bad 18; complications none 31, local poisoning by hyd. perchlor. dressing 3, rupture of quadriceps extensor muscle 2, non-union of previous fracture of same patella 2, typho-malarial fever and phlegmonous erysipelas 1, periostitis 2, septicæmia and

¹ Norris, Amer. Journ. Med. Sci., Jan. 1842, p. 51.

² Barton, Gross's Surgery, 5th ed., vol. i. p. 1004.

³ Gunn, Wyeth's paper, Med. Record, July 3, 1882.

⁴ Cabot, San Francisco Med. Press, 1861.

⁵ Cooper, Pacific Med. and Surg. Journ., Dec. 1866.

⁶ Logan, Pacific Med. and Surg. Journ., Dec. 1866.

⁷ McClelland, New York Med. Journ., Dec. 1866.

⁸ New York Med. Journ., vol. li., 1890.

⁴ Cabot, Ibid.

diffused inflammation 1; *immediate results*—firm or bony union and good use of limb or joint 38, bony union 3 (of which 1 had flexion 15°), ankylosed 1, flexion not begun 1; fragments could not be coaptated 1 (ankylosed and strong limb); *definitive results*—bony union 41 (ankylosed and strong limb 1); *condition of joint*—perfect 27, ankylosed 2, flexion 90° 4, 45° 1, 40° 1, 30° 1, 15° 1, limited 1, not begun 1, not given 3. The period at which patients were seen after the operation varied from one month to five years; after one year 24. There was no death. Of the 24 cases seen after one year, all are reported as having bony union.

If these statistics are compared with those compiled by Prof. Hamilton, and summarized in preceding pages, and also by Brunner, Beck, and Bull, illustrating the results of non-operative treatment, several conclusions of importance will follow. 1. Though there is no death reported in either group of cases, the complications resulting from this operation in reported cases are more serious. 2. Bony union, and hence a firm joint, is far more likely to follow the operation. 3. Impairment of the joint by time and use is far more frequent in non-operated cases. 4. Refracture, or rupture of the uniting medium, is more liable to occur in non-operated cases. 5. Ankylosis of joint is more frequent in operated cases.

These comparisons lead to the conclusions: 1. That the average results of the operative and non-operative treatment of fractures of the patella, in the cases which do well, are largely in favor of the operative method, owing to the fact that, as a rule, bony union is secured by that method, and ligamentous union by the non-operative treatment. While it is abundantly proved that ligamentous union is not incompatible with a serviceable limb, it is nevertheless equally proven that bony union gives the most stable joint, and for the longest period. Bony union in fracture of the patella is the result which we seek, and which we regard as the perfection of cure. 2. The operative method is liable to be complicated by accidents which do not occur in the non-operative treatment. These accidents have for the most part resulted from simple defects in the details of treatment easily avoidable. 3. The period of recovery is much less in the operated than in the non-operated cases. Laboring men have resumed work, Dr. Phelps remarks, when patients treated by other methods are still in bed, or, at least, on crutches; in two instances patients resumed heavy work within six weeks of the operation; one in two months; and many others during the third month. Prof. Hamilton states that in non-operated cases the bond of union may be considered complete in six or eight weeks, but that for the next three or four months the patient should walk only upon crutches, and the knee-joint should be constantly supported unless it is completely at rest.

The following conclusions of Dr. Phelps appear to be the logical deductions from all the facts which he has presented:

"1. Osseous union is prevented by the intervention of aponeurotic fibres between the fragments, and becomes possible only after their removal by an operation which involves opening the joint.

"2. In recent refractures after wiring, and in very exceptional primary fractures, these fibres do not intervene, and osseous union can be obtained without operation if coaptation of the fragments can be otherwise effected and maintained.

"3. Osseous union is always obtained after removal of these fibres and coaptation or close approximation of the fragments by wiring.

"4. There is no danger to life in this operation from sepsis or articular supuration, provided aseptic laws are fully observed, and no greater danger from accidental complications than in trivial forms of surgical interference.

"5. There is no danger of osteitis or necrosis.

"6. There is no danger of ankylosis if proper care be taken in the use of passive motion, and if in certain cases forcible flexion under ether be employed.

"7. There is less danger of refracture, or of subsequent fracture of the opposite patella, than when union is by ligament.

"8. The treatment by this operation is less fatiguing to the patient, requires a shorter period of confinement in bed, and enables him to walk and to resume his occupation sooner than any other method of treatment."

The surgeon who contemplates this operation should remember the injunction of Sir J. Lister, viz.: "No man is justified in performing such an operation

unless he can say with a clear conscience that he considers himself morally certain of avoiding the entrance of any septic mischief into the wound."

The operation is as follows: All the materials used are of known aseptic quality; the instruments are constantly kept in carbolic solution, 1 to 20, except when actually in use; the surgeon and assistants are thoroughly prepared by antiseptics; the room is clean and free from septic matter. Proceed as follows: 1, wash the limb thoroughly with soap and water from the foot to the hip; 2, shave the knee from three inches below to the same distance above the fracture; 3, douche the entire limb with bichloride solution 1 to 2000; 4, wrap the limb above and below the knee with towels wet with bichloride solution; 5, with knife taken from a carbolic solution make a transverse incision in the line of fracture exposing the fragments; 6, douche the wound frequently with bichloride solution 1 to 4000; 7, clean the fractured surfaces of blood-clots, and with scissors clip away all shreds of membrane which are liable to fall between the bones; 8, with bone-drill or a brad-awl make a hole through the fragments at the centre, obliquely, entering the bone anteriorly, not to exceed half an inch from the margin, if there is space, and emerging near the posterior articular surface; 9, pass the wire and twist it while an assistant presses the fragments firmly together; 10, cut the wire ends, leaving three-eighths of an inch of the twist, and bend this over and bury it between the fragments; 11, with carbolized catgut stitch the deep fibrous structures, with a continuous suture, firmly together; 12, place in each angle of the wound a small drain, or if the angle forms a pocket, as is generally the case, make an opening, at its lowest part, through the skin and apply the drains, which should nearly or quite meet at the highest part of the wound; 13, close firmly the external wound throughout with prepared silk suture; 14, douche the knee with the solution and throw it into the drains to prove that they are open; 15, dust the wound and knee liberally with iodoform, and surround the knee with mussed bichloride gauze several inches in thickness; 16, over this, and extending from the foot to the hip, apply a thick layer of prepared sheet cotton well sprinkled with iodoform; 17, over all apply a plaster bandage three thicknesses; or first place the limb in a wire cradle, and then apply plaster-of-Paris bandages; 18, on the third to the fifth day make small openings at the site of the drains and remove them, injecting their tracts with the bichloride solution, and closing the opening with iodoform and cotton.]

Kocher, recognizing the dangers attending the use of bony sutures, substituted a metallic suture which, by means of a curved needle, was passed under the upper and lower margins of the fragments and secured in front of the patella by twisting the extremities. It is difficult to see how this method should materially diminish the dangers, as the suture, or ligature more properly, "is drawn through the joint." (Volkman.)

[Laplace,¹ of New Orleans, was led to perform an operation very similar to Kocher's, with good results, by the breaking of the drill with which he was wiring the bones.]

Volkman² says: "Long before the introduction of antiseptics I attempted suture of the *tendons* in fracture of the patella, and though the ligature was left in place only a very short time, until the plaster-of-Paris bandage which was at once applied had hardened, I twice met with very satisfactory success. The two cases were described in Virchow's and Hirsch's *Jahresbericht*, f. 1868, Bd. ii. p. 364. 'In two cases I drew through the tendon of the quadriceps and the ligamentum patellæ, while the integument was strongly retracted, at first in an upward, then in a downward direction, a simple loop of thread, and knotted the same over the patella; by this means the fragments were brought into contact, and at the same time the prominent edges were depressed. Then a very tightly fitting plaster-of-Paris bandage was applied, and directly after it had hardened, a fenestra as large as a two-cent piece was cut into it, corresponding to the spot where the ligatures had been tied, and the latter were cut and withdrawn. In one case, firm osseous union resulted; in the other, a very narrow, fibrous, intermediate substance was formed; in a third case, one of my clinical assistants

¹ Trans. Louisiana State Med. Society, 1889.

² Volkman, *Centralb. f. Chir.*, 1880, 24.

applied the bandage in the same manner, and though the ligature was removed after remaining in place hardly a quarter of an hour, ulceration of the articulation and *death* from pyæmia ensued.¹ The autopsy showed that in this unfortunate case the ligature had been introduced too deeply, and transfixed the joint, and that the plaster dressing had not been padded, but applied directly to the limb after enveloping the latter in moist blotting paper. More recently I repeated the above operation with some slight variations, and the result was all that could be desired."

Volkman¹ advises opening the joint for the purpose of evacuating the extravasated blood; but Kocher calls attention to the fact that the blood has been found coagulated as early as the third day, and he thinks, therefore, that the opening ought to be made as soon as possible. Schede² proposes to wash out the joint with carbolic water; but Kocher says he has seen this produce carbolic-acid poisoning.

Lastly, it is proposed to aspirate the joint for the purpose of evacuating the synovial fluids, and thus relieve the distention which tends to separate the fragments. The objections to this procedure are that it is not unaccompanied with danger; but the joint will, in most cases, become speedily refilled; that usually the effusion begins to be absorbed as early as the seventh day and soon disappears entirely, so that practically it does not seriously interfere with the process of union.

In a case aspirated by Dubrueil³ purulent arthritis ensued, but the final result is not given. In a case reported by Dr. Robert McDonald,⁴ aspiration of the knee-joint having been made for chronic effusion, inflammation ensued ending in death on the seventh day. And in the same manner Dr. George H. Hammond, one of the house staff at Bellevue Hospital, lost his life in 1881.⁵

Cutting the quadriceps demands a very extensive subcutaneous incision, and I venture to say that no surgeon has divided all of its fibres, or even the fibres of the rectus, in his subcutaneous incision, and certainly not without carrying his incision freely into the upper part of the joint. The method of injecting between the fragments fresh marrow cells, has as yet yielded no results. Nor do I think it is likely to succeed for many reasons, and especially because the "germs" cannot be placed actually between the fragments without being in the cavity of the joint, where of course they could serve no purpose. To place them in the thin tegumentary covering, which alone remains, when the separation exceeds half an inch, would be, I think, equally useless.

[A. W. M. Robson⁶ reports a case treated as follows: First he aspirated the joint and removed the blood and serum. Then he took two long steel pins, with glass heads, such as ladies use to fasten on their bonnets. One of these, thoroughly purified, was pushed from without inward through the quadriceps tendon and out on the opposite side, immediately above the upper fragment, the skin being first drawn upward. The other pin, properly prepared, was passed in like manner through the upper end of the ligamentum patellæ, just below the lower fragment. Gentle traction on the pins brought the fragments into contact. A suture of aseptic silk was next passed in the form of a figure-of-eight around the pins. The ends of the pins were cut off and antiseptic dressings applied. A straight splint was applied to the posterior part of the leg. This dressing

¹ Volkman, Kocher, loc. cit.

² Schede, *Centralb. für Chir.*, 1877, p. 657.

³ Dubrueil, *Bull. de Soc. Chir.*, Oct. 1872, p. 438.

⁴ McDonald, *Amer. Journ. Med. Sci.*, April, 1873, p. 548; from *Irish Med. Gaz.*

⁵ *Medical Record*, June 11, 1881.

⁶ *Trans. Clinical Society of London*, vol. xxii.

was continued three weeks, when the pins were removed and a plaster-of-Paris dressing substituted. The result was in every respect satisfactory.]

Finally, in order to accomplish the best results with the least possible danger to life or limb—that is, to produce the shortest ligament, while the complete integrity of the joint is preserved—there are presented four simple indications of treatment, namely:

First. Approximation of the lower fragment to the upper by straightening—extending—the leg upon the thigh.

Second. Securing immobility of the knee-joint by a splint.

Third. Relaxation of the quadriceps muscle. This indication is accomplished in a small degree by flexing the thigh upon the body; but the effect of this posture is not so great as some writers have supposed. The quadriceps has but one origin from the pelvic bones, and consequently flexion of the thigh does not very greatly relax its muscular fibres. Yet that it possesses some value in this direction is easily demonstrated by experiment. The quadriceps is chiefly relaxed by extending the leg upon the thigh; that is, by placing the limb in a straight position and maintaining it in this position.

The fourth indication is to approximate the fragments by direct pressure; so far as this can be done, without inflicting serious injury upon the integument, or other structures. Without this pressure the relaxation of the muscle will not bring the fragments into actual juxtaposition, or even make them approximate this condition. In order to make direct pressure, surgeons have devised a great variety of methods; most of which are liable to the serious objection that they press too tightly upon the entire circumference of the limb to render them perfectly safe under all circumstances; and especially when the opposing forces, which are intended to approximate the fragments, are applied with the view of securing absolute coaptation, as many of the inventors declare to be their intention.

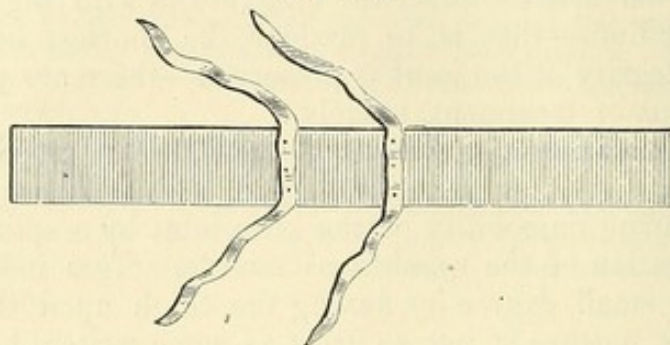
That danger exists from this source, the following case will illustrate: "A vine-dresser, æt. 40, received a simple transverse fracture of the patella. The medical officer applied first a bandage, for the purpose of drawing together the fragments, and afterward a starched bandage, extending from the toes to the upper part of the thigh. The limb was placed upon an inclined plane. The patient was visited a few times, but, as he scarcely suffered, the apparatus was in no way disturbed. On the sixteenth day the attendant returned to remove the bandage, when the odor arising from the limb led him to believe that gangrene had taken place." The bandage being removed, the gangrene was found to extend to within seven inches of the knee. The ankle-joint was opened and the ligaments destroyed. The bones of the leg were also exposed in their lower third, and the tendons were in a sloughy state. Amputation was performed, and the patient recovered.¹ In one of my published cases, plaster-of-Paris had been upon the limb one week when gangrene was threatened, and the plaster had to be removed. Two other cases illustrate the danger also of tight bandages in causing gangrene after a fracture of the patella.

Dr. Dorsey, of Philadelphia, employed an apparatus which will serve to illustrate in its most simple form the principle of approximating the fragments by the use of a splint and bandage. His apparatus consisted of a piece of wood half an inch thick and two or three inches wide, and long enough to extend

¹ Amer. Journ. Med. Sci., vol. xxiv, p. 462, from Gaz. Méd., No. 28.

from the buttock to the heel; near the middle of this splint, and six inches apart, two bands of strong doubled muslin, a yard long, are nailed. The splint

FIG. 282.

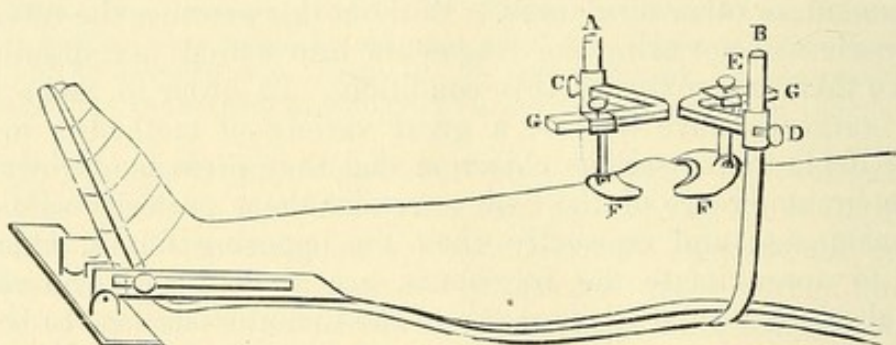


John Syng Dorsey's patella splint.

is then cushioned, and the limb laid upon it, a roller being first applied from the ankle to the groin, encompassing the knee in the form of the figure of 8; after which the two muslin bands are secured across the knee in such a manner as that the lower one shall draw down the upper fragment, and the upper one elevate the lower fragment.

Mr. Lonsdale devised a very complicated apparatus.

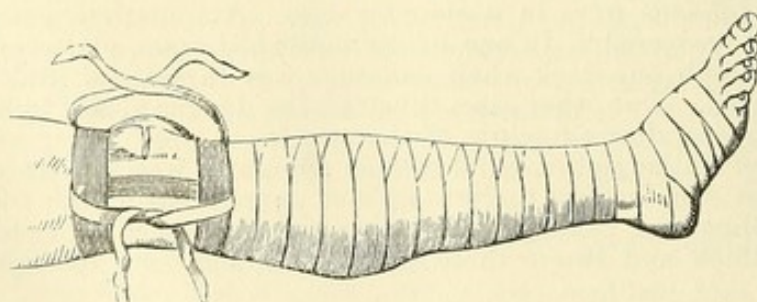
FIG. 283.



Lonsdale's apparatus for fractured patella.—A B. Two vertical iron bars, each supporting a horizontal one; these horizontal arms slide upon the vertical bars, but can be secured at any point by the screws C D. To the horizontal beams are attached other vertical rods, which are movable, and yet fixable by screws, as at E. Finally, to each of these last upright pieces is fixed an iron plate, F F, by means of a hinge-joint, which keeps the patella in place. The foot-piece is movable up and down upon the main body of the apparatus, and can be made fast at any point, so as to adapt the splint to limbs of different lengths.

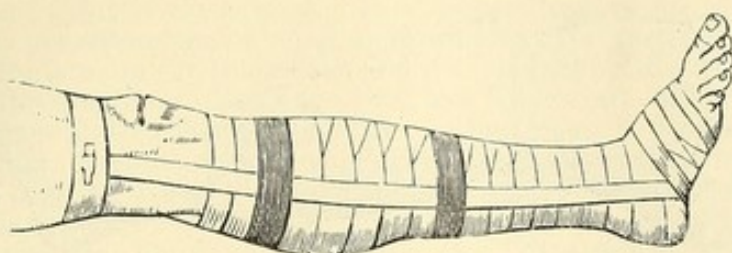
Sir Astley Cooper employed two methods of approximating the fragments, which will be sufficiently illustrated by the following woodcuts:

FIG. 284.



Sir Astley Cooper's method by circular tapes.

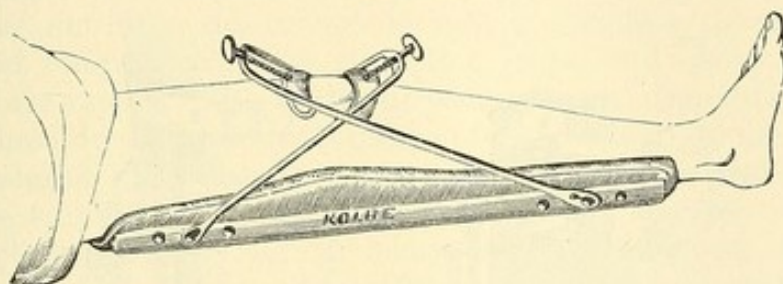
FIG. 285.



Sir Astley Cooper's method by a leather counter-strap.

The apparatus devised by Lausdale, U. S. N., is more simple than Lonsdale's, but both of them can only approximate the fragments when they press very

FIG. 286.

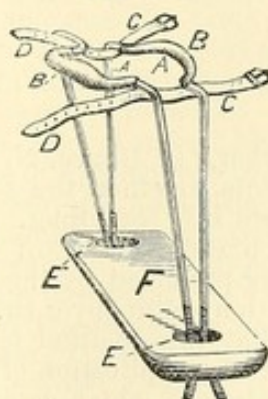


Lausdale's apparatus.

firmly, and then they will necessarily tilt the fragments and expose the patient to the risk of ulceration at the points of pressure. This happened in the only case which I have seen which had been treated by Lausdale's apparatus on the fifth day after it was applied. This is the case of Assist. Surg. Meyers, reported near the close of this chapter. In neither of these forms of apparatus can bandages be properly applied to restrain the tilting of the fragments, and to give the knee-joint a smooth and equal pressure when it is swollen, as it usually is.

The apparatus of Beach, of Illinois, is liable to the same objection.¹ The device of Burge, of Brooklyn, in which the fragments are approximated by care-

FIG. 287.



Beach's apparatus.

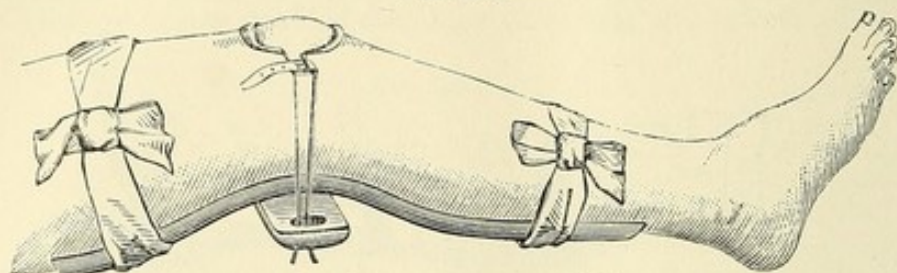
Wires in semicircular form (A), the posterior part of each segment (B) being curved upward and the sides a little depressed. A shoulder is formed (C) on each side of the segments for the reception of the two straps (D), which connect them, and projects far enough on each side to permit the wires to be bent downward at right angles with the shoulder, and descend perpendicularly to the slot or mortise (E) which is placed near each end of the block (F).

fully-adjusted leather pads, operated upon by weights, cords, and pulleys, is too complicated, and possesses no marked advantages over the simple roller employed in my own dressing.²

¹ Beach, St. Louis Med. and Surg. Journ., Jan. 1875.

² Burge, Med. Record, April 15, 1868. For illustrations see 5th ed., p. 471.

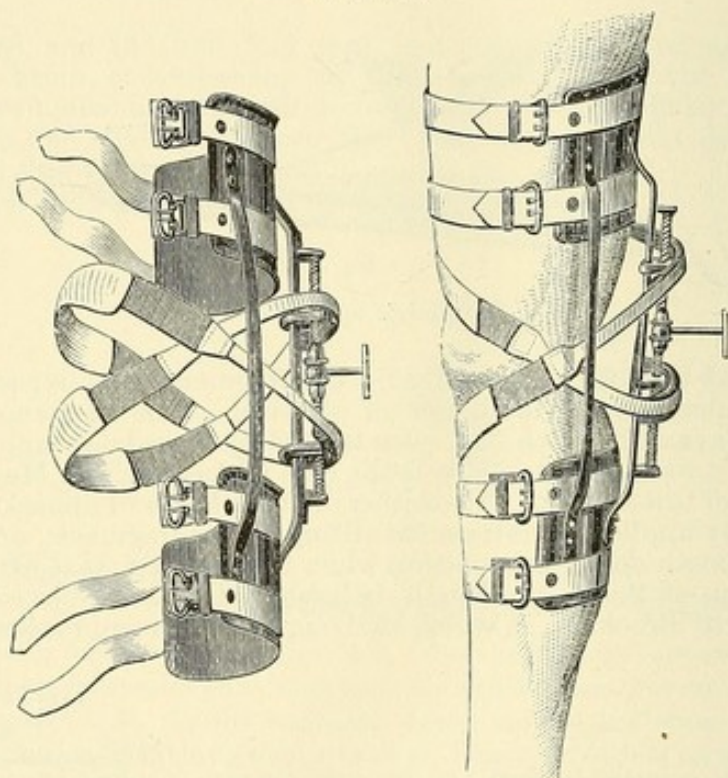
FIG. 288.



Beach's apparatus applied.

The apparatus of Dr. Turner,¹ of Brooklyn, and of Dr. John A. Wyeth, of this city, involve the same principles, and are equally liable to objections, on account of the limited surface against which the pressure is made.

FIG. 289.



Turner's apparatus.

[Parker,² of Ithaca, N. Y., had gold screws made with which he fastened the fragments together, the screw passing from below upward through the lower fragment into the upper. The result was very firm union.

Beach and Newell (of the Mass. Gen. Hosp.) have recently illustrated the dressing preferred by them. The essential features are a long ham splint and coaptation splints over the quadriceps firmly bound on the thigh. The authors state that this method is distinguished from others by its simplicity and the more direct application of control to the action of the great patellar muscle, the contraction of which determines, provided the leg be kept straight, the degree of separation of the fragments.³]

Gibson, of St. Louis, has revived, in a modified form, the circular ring of Albucasis.⁴ Drs. Eve, of Nashville, and Blackman, of Cincinnati, have spoken favorably of this method.⁵ Its application must, however, be limited to such

¹ Turner, Medical Record, July, 1867.

² The Polyclinic, Feb. 15, 1885.

³ Medical Record, Mar. 15, 1890.

⁴ Gibson, Amer. Journ. Med. Sci., Jan. 1867, p. 281.

⁵ Eve, Blackman, Nashville, Journ. Med., February, 1867; Western Journ. Med., May, 1868.

cases as are unattended by inflammation, and can tolerate the pressure applied only to a small point of the surface. It is essentially the same as Beach's apparatus, but has the advantage of being more simple. Its efficiency depends upon its holding firmly upon the fragments, and not permitting them to slide from its grasp. All the tendinous insertions into the patella are continuous with the anterior margins and surface of the bone; so that there is no natural sulcus to receive the ring, or uplift against which the ring or any similar form of dressing can obtain a bearing, unless it is very firmly pressed into the tissues above and below, as I have before explained. Such pressure as is required in the case of a ring, or any similar hard and unyielding mode of pressure, will not often be borne by an inflamed and swollen structure.

Plaster-of-Paris and all other forms of immovable dressings do not possess one single point of excellence or advantage. When first applied they are liable to constrict the limb dangerously; and how insidiously a fatal gangrene may progress, giving no sign either by pain or general disturbance until the destruction is nearly complete, the case seen by Defer, and referred to in the preceding pages, will show. The cases which I have reported also in the preceding pages demonstrate how inefficient these dressings are as a means of approximating the fragments; the examples of the widest separation being drawn almost exclusively from cases treated by the plaster-of-Paris or the silicates. The dressings, which within a few days or hours are apt to become very tight in consequence of the increased swelling, soon begin to loosen, from the subsidence of the swelling at first, and finally from atrophy of the muscles and other soft tissues, and the limb lies loose in its case, which may not even touch the patella, much less make any effective pressure upon it. Whatever the result may be under such circumstances, so far as the separation of the fragments is concerned, the dressing has nothing to do with it. It may be that the final separation will be found to be very little, but, if it is, it would have been the same if the limb had been laid horizontally in bed without dressings or apparatus of any kind.

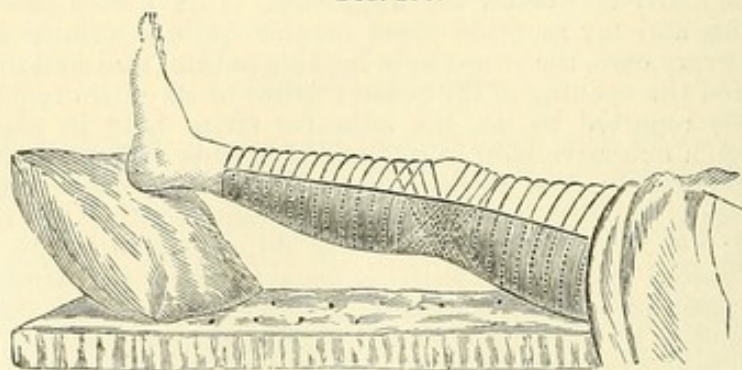
Some have attempted to remedy this serious objection to these dressings by first applying adhesive plaster in the form of a lock strap, and in various other ingenious ways, above and below the fragments. I have seen this done repeatedly at Bellevue, and my reported cases furnish quite a number of examples; but, in almost every case, the straps soon became painful and had to be removed, and this required the opening of the plaster splint or its entire removal. In one of the cases (33) reported by me, the adhesive strips held in place by elastic bands caused such excessive pain as demanded the use of hypodermic injections of morphine repeatedly, and it resulted in almost complete paralysis of the extensor muscles of the foot, which continued many months after the treatment was suspended; yet from all this there was no appreciable gain, inasmuch as the fragments united by ligament with the usual amount of separation. Indeed, so far as the position of the fragments is concerned, the dressings had only proved mischievous by thrusting one of the fragments laterally. Plaster-of-Paris is of all the forms of immovable dressings the worst, because it is the heaviest; but of them all it must be said that they are unnecessarily cumbrous as a form of portative apparatus; they are to some extent dangerous, especially in the hands of inexperienced surgeons; they are inefficient as means of approximating the fragments; they actually serve but one single purpose, namely, to keep the limb straight, and this they do too effectually in many cases, causing an unnecessary degree of passive ankylosis. The limb can be maintained in a straight position by a much simpler and lighter dressing than a plaster-of-Paris splint, and by means which permit it to be daily examined and the condition of the fragments noted and corrected.

My own method is as follows: The limb being placed extended, with the foot elevated about six or eight inches, a long splint is applied to the back of the thigh and leg. This splint may be made of leather, of gum-shellac cloth (not felt), or of any other material having the necessary qualities of firmness, lightness, and plasticity, so that it can be properly moulded to the limb. Of late I have preferred the gum-shellac cloth, as possessing in a greater degree the necessary qualities than either of the others. The splint should be long enough to extend from above the middle of the thigh to two or three inches above the heel. Its width should be sufficient to inclose the posterior semi-diameter of the leg and thigh. It should be placed in hot water, and then moulded to the back of the limb: only that it is rather better not to fit it accurately to the popliteal space, in order that a small amount of cotton-batting may be placed between the splint and the skin. The splint should then be removed; and, if made of shellac-cloth, in a few minutes it will be sufficiently hard to retain its form. It is now covered completely with a firm cotton or woollen sack, and the sack stitched along the back of the splint. The splint having been curved to fit the circumference of the limb, the sack must hang loose across the concave surface of the splint, so that the limb may be allowed to fall back to the splint, but the ends of the sack may be drawn and stitched tightly.

One object of the covering is to furnish a protection to the skin against the splint; but the chief object is to supply a basis to which the bandage, which is to inclose the limb and splint, may be stitched.

The splint must be applied while the limb is in the position already described, a small wad of cotton-batting having been placed in the ham. A roller, made of unglazed cotton-cloth, is then turned around the leg and splint to within about three inches of the knee, and another from the upper end of the splint over the splint and thigh to within three inches of the knee. While an assistant approximates the fragments with

FIG. 290.



The Author's mode of dressing.

(The final turns of the roller, in the front of the knee, are not shown in the woodcut.)

his fingers, the surgeon makes two or three turns with a third roller around the limb and splint, close above the knee; after which the roller descends below the knee, and an equal number of circular turns are made close below the lower fragment of the patella; and finally, a succession of oblique and circular turns are made above and below the frag-

ments, which turns are to approach each other in front until the whole of the patella is covered—the last turns being again circular. The dressing now being completed, the rollers are carefully stitched to the cover of the splint through its whole length, on both sides; and the limb is left supported in the elevated position by a suspending apparatus, or by some other mode which will insure its maintenance in this position.

The cotton-cloth roller is preferred, especially for the purpose of approximating the fragments, because, if unglazed, it yields a little, and adapts itself smoothly to the skin, even sinking down a little just above and below the patella, thus rendering it less liable to slide over. Reversed turns are omitted altogether, because they cause sharp cords where they are folded, and sometimes produce painful constrictions and excoriations. Adhesive strips, recommended by me in the first edition of this work, I have long since laid aside. They are just as liable to slide, they are apt to cut at their free margins, and they have to be raised up from time to time to be tightened, and they cannot be stitched and thus permanently secured to the cover of the splint. No pads above and below the knee are recommended, because they are apt to become displaced, and if they remain in place they no more effectually press the fragments together than does the cotton roller. No pad is placed in front of the patella, because the last turns of the roller press back the fragments as effectually as a pad. Care must be taken when the roller is applied and the fragments are approximated, that the loose skin in front of the patella is not pressed between the fragments. No lotions must be applied, to saturate the dressings. They render the skin more liable to excoriations, and they are in no way useful.

On the second or third day the swelling of the knee will be found, probably, to have subsided somewhat, and the oblique turns of the bandage from above and below the patella will need to be tightened. This will be done by over-stitching, with strong thread, the oblique turns; taking care to do this on both sides and so far back that the doubling of the cloth will not be over the sides of the exposed portions of the limb. The same thing may be required to be done every day, or every second or third day, for two or four weeks.

Meanwhile it will generally be found—for the position of the fragments can always be felt—that the space between them has not been increased, and in most cases that it has sensibly diminished from the day of their first adjustment.

At the end of about four weeks the apparatus should be removed carefully. It is now observed, generally, that the knee is pretty stiff, and that the upper fragment cannot without considerable force be displaced in any direction. It is ankylosed, and there is very little danger that it will thereafter draw up further, and it is not probable that any apparatus will make it descend. But as a matter of safety, an assistant should now press the upper fragment gently downward while the surgeon flexes the knee very slightly, so as to diminish its stiffness. He ought, in doing this, never to cause pain, or to use any degree of force. The splint is then to be reapplied in the same manner as before. Daily, thereafter, the splint should be removed with the same care, and the limb gently flexed. In the meanwhile the patient may go about upon crutches if he chooses. In six or eight weeks the bond of union may be considered completed, and the patient may be dismissed from the immediate care of the surgeon, but not until he has been fully informed of the danger of a rupture of the new ligament, and has been provided with the means of

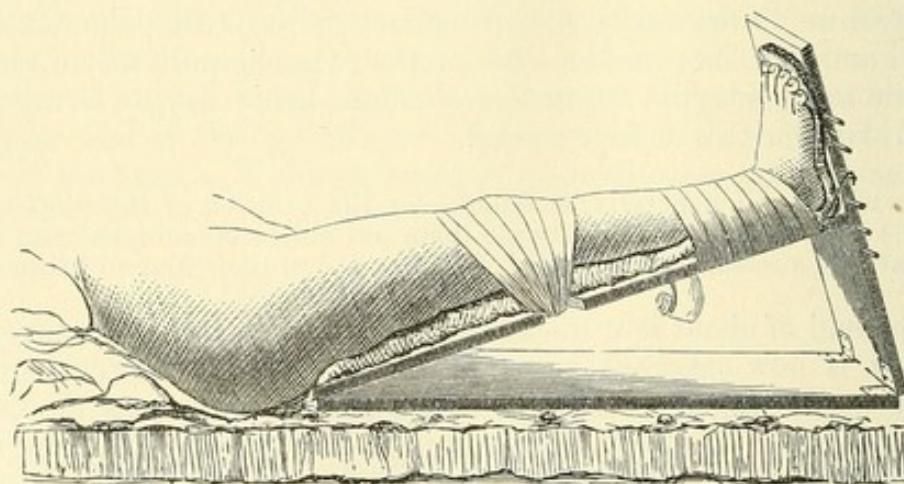
protection as far as possible. He must be taught that for the next three or four months this danger is great; and that any sudden flexion of the limb may cause it; and, indeed, that it may be caused by simple muscular action, when the limb is not flexed. During this period he should walk only upon crutches, and the knee-joint should be constantly supported, unless he is completely at rest.

The knee-caps usually furnished for this purpose are wholly unreliable. They allow the knee to bend too freely. Indeed, nothing but an inflexible splint can insure safety; and the same splint employed in the treatment, reduced one-half in length and secured by straps and buckles, is the best I have yet employed.

Under no circumstances, in my opinion, is the surgeon justified in attempting to overcome the ankylosis by force, either with or without an anæsthetic. The chances are more than equal that he would substitute a ruptured ligament and an ununited patella for an ankylosed knee. I have been informed that this accident actually occurred at one of our city hospitals a few years ago, in the presence of a class of students. In time, and generally within a year or two, the ankylosis will disappear wholly under careful and moderate use of the limb.

I no longer recommend the wooden inclined plane (Fig. 291) in all cases. The principle of its construction is correct, and the results have been satisfactory, but it is unnecessarily cumbrous for a majority of recent and primary accidents, and I reserve it now only for exceptional cases, such, for example, as those in which the separation is very great, or the inflammation and swelling are unusual.

FIG. 291.



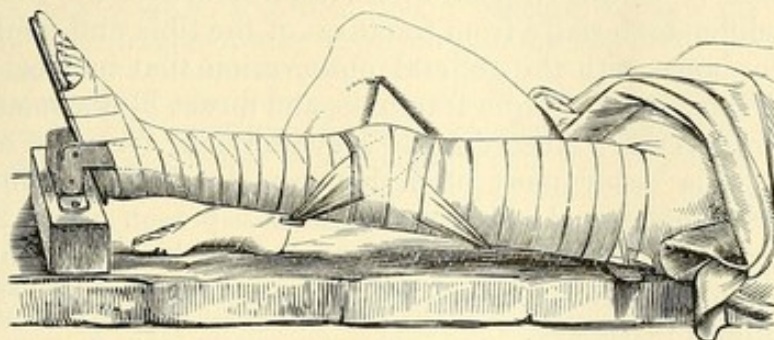
The author's wooden inclined plane. To be used in only exceptional cases.

Mr. Hutchinson, of London, has of late omitted to elevate the foot in the treatment of this fracture, and he thinks that the fragments are maintained in apposition with quite as much ease.¹ I cannot agree with him that nothing is ever gained by the elevation of the foot. On the contrary, in the treatment of a certain proportion of cases this position will be found essential to the best success, while in others it may be of little consequence whether the foot is elevated or not. The dressing and apparatus employed by Wood, of King's College Hospital, are very similar to my own wooden inclined plane, but the splint is only five or six inches wide. Wood has substituted hooks for the notches.²

¹ Hutchinson, London Hospital Reports, vol. xi.

² Fergusson's Surgery, p. 307.

FIG. 292.



Wood's apparatus.

Treatment of a Rupture of the New Ligament.—In all cases the patient should, as soon as possible, be subjected to the same plan as for original fractures, but with smaller hope of a reunion. The time always arrives, according to my experience, both in primary fractures and secondary accidents or ruptures of the new ligament, when supporting and retentive apparatus is worse than useless. The period is within five months after the original accident, and within about the same period after the secondary accident.

Under proper and free use of the limb, aided by friction, electricity, etc., the muscles will become developed in size and strength, and through their remaining attachments to the sides and front of the leg, below the knee, will give to the patient often a very useful limb.

[**Compound and otherwise Complicated Fractures.**—In these forms of fractures antiseptic wiring of the fragments with thorough antiseptics of the wound is the proper treatment.]

CHAPTER XXXI.

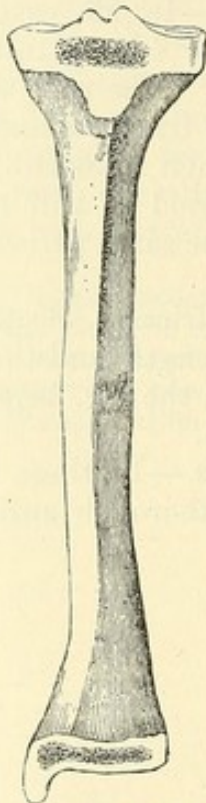
FRACTURES OF THE TIBIA.

Development of the Tibia.—The tibia is formed, usually, from three centres of ossification—one for the shaft, and one for either extremity. Ossification commences in the shaft at or about the fifth week of foetal life. In the upper epiphysis it appears at birth, and unites with the shaft at about the twenty-fifth year. Generally it forms the tubercle, but occasionally the tubercle has a distinct point of ossification. The lower epiphysis commences to ossify during the second year, and unites with the shaft at about the twentieth year. The malleolus internus is occasionally formed from an independent centre.

Pathology, Division, etc.—In an analysis of twenty-seven fractures of the tibia, not including fractures of the malleoli, six were found to have occurred in the upper third, eleven in the middle third, and eight in the lower third. Six of the twenty-seven are known to have been transverse, or only slightly oblique. It is probable, also, that several of the remainder

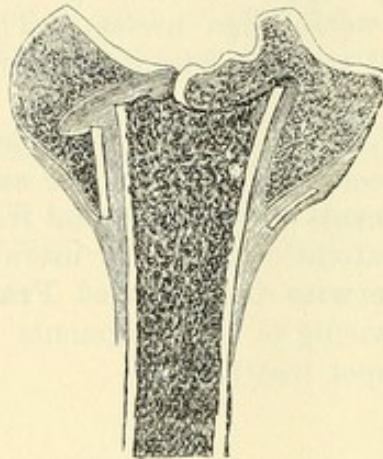
were transverse. In this respect, therefore, fractures of the tibia alone will be found to differ materially from fractures of the tibia and fibula; but it is only in accordance with the general observation that indirect blows produce almost constantly oblique fractures, and direct blows somewhat more frequently transverse. According to Heydenreich,¹ fractures of the upper third of the tibia occur most often between the 30th and 50th years of life, and he has not found a case recorded in a person under 22 years of age. Fractures of the tibia extending into the knee-joint are in most cases compound, or otherwise so seriously complicated as to render amputation sometimes necessary.

FIG. 293.



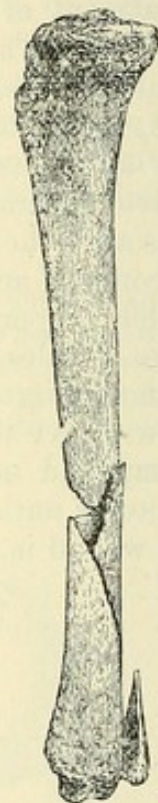Development of the tibia.
(From Gray.)

FIG. 294.



Penetrating fracture in which
the shaft has produced commi-
nution of the head.

FIG. 295.



V-shaped fracture.

Etiology of Fractures of the Tibia.—Fractures of the tibia alone are, in a large majority of cases, produced by direct blows, such as the kick of a horse, or a blow from a stick of wood. It is occasionally broken by a fall upon the foot, the force of the impulse being expended before the fibula gives away, but usually the fibula breaks at the same moment, or immediately after the fracture has taken place in the tibia.

Heydenreich relates the case of a man whose tibia was broken above the tubercle in an attempt to straighten an ankylosed knee. The patient died on the eighth day, from a hemorrhage caused by the pressure of the displaced fragment upon the popliteal artery. Dr. Proudfoot, of New York, has reported an example of fracture of the tibia *in utero*, produced in the sixth month of pregnancy, by violent pressure upon the abdomen.²

¹ Heydenreich, *Frac. Ext. Sup. du Tibia*, th. de Paris, 1877, No. 43.

² Proudfoot, *Boston Med. and Surg. Journ.*, vol. xxxv. p. 268, 1846; from *New York Journ. Med.*

[Fractures of the head of the bone may be complicated by injuries of the joint. This may occur by a vertical line of fracture through the head into the joint, or the lower fragment may be driven into the upper and produce a separation and comminution of the head. (Fig. 294.)

Other varieties of fractures have been noticed. A person was thrown violently to the ground, while wrestling; he died of pleuro-pneumonia on the twenty-third day, when it was found that the spine and central portion of the head of the bone and a part of the left articular surface had been torn from the rest of the bone.¹ Prof. Dittel, of Vienna, mentions the case of a man who was kicked by another in the calf; blood was effused into the knee-joint; it was punctured, after which amputation was performed; on examination of the limb it was found that the anterior crucial ligament had become detached from its lower origin, detaching an oval piece of the upper surface of the tibia. These fractures have been described as "*sprain fractures*" by Mr. Callender.²

A form of fracture of the shaft known as V-shaped (Gosselin) may give rise to great difficulties in treatment. (Fig. 295.) The upper fragment is somewhat pointed and presents on the inner and subcutaneous aspect, and the lower fragment has a triangular depression with a prominent point posteriorly. A line of fracture usually extends from the lower point of the V around the bone, inward, backward, and outward, across its posterior surface toward the lower articular facet, where the tibia and fibula articulate; the fissure then passes horizontally inward across the lower articular facet of the tibia to the posterior border of the inner malleolus to join the one on the posterior aspect of the bone, thereby cutting off a triangular fragment of the tibia at its lower extremity. This fracture is believed to be produced by a twist of the body when the foot is fixed. It may be diagnosed when the joint is found to be involved in the fracture. If it is compound the bones should be aseptically wired.]

Separation of the upper epiphysis of the tibia, and of the lower epiphysis of the femur, has been occasioned by pulling at the foot during confinement.³ Blasius⁴ relates the case of a boy, 16 years of age, in whom the upper epiphysis was separated completely from the shaft by having his foot caught in machinery. M. Peulevé⁵ has in his possession a similar specimen obtained from a lad 6 years of age. The accident had been caused by the leg being caught in the revolving wheel of a carriage, and the severity of the injury was such that it became necessary to amputate. Fischer and Hirschfeld⁶ have observed the same lesion in a boy 17 years old. Voss has seen a separation of the lower epiphysis in a boy 14 years old, who in falling had caught his foot between two blocks of wood. The upper fragment protruded through the skin. Reduction was effected, but subsequently a portion of the epiphysis became necrosed and was removed. He finally recovered with a useful joint.⁷

Dr. R. W. Smith has reported a similar case in a boy 16 years of age, and which, having occurred six months before, remained unreduced. The lower end of the shaft was displaced forward. Richard Quain records one other example, in a lad 17 years old, which was easily reduced and maintained in position.⁸ Powell,⁹ of Canada, reported an example of congenital displacement of the upper epiphysis of both tibiae in an otherwise healthy girl. Reduction was easily effected, but was with difficulty maintained. When about 14 months old, however, the epiphyses were kept in place by means of plaster-of-Paris splints with which she was permitted to walk about, and a perfect union was finally obtained.

Inasmuch as the *tubercle* has sometimes a separate point of ossification it may occasionally be detached, and the accident will then be distinguished from a fracture of the ligamentum patellæ, by the presence of a hard and movable body and by crepitus.

¹ System of Surgery, vol. i.

² St. Bartholomew's Hospital Reports, vol. vi. p. 51.

³ Madame Lachapelle.

⁴ Blasius, Poncet, Nouv. Dic. de Méd. et de Chir., t. 19, p. 513.

⁵ Peulevé, Bull. Soc. Anat., 1865.

⁶ Berlin. klin. Woch., 1865, ii. 10. (Poincet, op. cit.)

⁷ Voss, New York Journ. Med., Nov. 1865, p. 133.

⁸ New York Journ. Med., June, 1868; from British Med. Journ., Aug. 31, 1867.

⁹ Powell, Canada Lancet, July 1, 1881.

Prognosis.—No shortening can occur in this fracture unless one or both ends of the fibula are displaced, a complication which I have noticed in two instances, but in neither case did the shortening exceed one-quarter of an inch; unless, indeed, the fibula bends and remains bent, or the comminution and direction of the fracture are such at either end as to allow the femur or the astragalus to become impacted. I have never recognized either of these conditions. Occasionally the upper fragment has been slightly displaced forward. With these exceptions, and one other of delayed union which I shall presently mention, this bone, in my experience, has been found to unite promptly and without any appreciable deformity. Other surgeons have noticed occasionally that the upper end of the lower fragment has become displaced toward the fibula. Delayed union has been observed pretty frequently in fractures of the upper third of the tibia.

Muhlenberg, in his tables comprising 656 examples of delayed and non-union of long bones, records 84 of the tibia alone; of which number 2 were cured by friction, 7 by mechanical appliances, 3 by seton, 11 by resection, and 15 by drilling.¹

If the fracture extends into either the knee- or ankle-joint, the danger of ankylosis is imminent, yet experience has shown that it may sometimes be avoided. When the malleolus is broken off, it generally becomes slightly displaced downward, and in this position a complete bony or ligamentous union of the fragments generally takes place.

Treatment.—The tendency to displacement, in a fracture of the shaft of the tibia, is usually so slight, if it exists at all, that simple dressings, light splints of leather, felt, or binder's board, with rest in the horizontal posture upon a pillow, fulfil nearly all the indications which are present.

The following cases will illustrate the usual course of these accidents:

Mrs. W. fell, striking on her right knee, breaking the tibia transversely just below the tuberosity. The fall was the result of a misstep on level ground, and was attended with only slight bruising of the soft parts. On attempting to rise the bone projected very distinctly, and she pushed and pulled it into place with her own hands. I dressed the limb by laying it upon a pillow, outside of which were placed two broad deal splints, tying the whole snugly together with several strips of bandage. At a later period the leg and thigh were laid over a double inclined plane. At the end of six weeks all dressings were removed, and the fragments were found to have united firmly, and so perfectly that the point of fracture could not be traced.

P. H., æt. 29, was admitted into the hospital with an injury to his left leg, which had occurred two days before. A surgeon had examined the limb, and thought the femur was broken just above the joint, and applied a roller from the toes to the thigh; and to the thigh were applied lateral splints. I could not discover any fracture or displacement, and the dressings were discontinued. One month later I detected a slipping sensation, like that produced in a false joint, through the upper end of the tibia. It was a transverse fracture through the upper end of the tibia, and without displacement. No splints were afterward applied, and three months after admission he was dismissed, the motion between the fragments having ceased, but the knee still remaining quite stiff.

The presence of inflammation, with other complications, may occasionally render the treatment more difficult and the results less satisfactory.

¹ Muhlenberg, Agnew's Surg., op. cit., vol. ii. p. 806.

In case the fracture extends into the knee-joint, it is best to lay the limb upon pillows in a nicely-cushioned box, and nearly straight. No extension or counter-extension is necessary here any more than in other fractures of the tibia alone, nor are lateral splints or rollers necessary or proper at first as a general rule; but especial attention should constantly be given to the prevention of inflammation, and of subsequent ankylosis.

The omission to employ splints in a case of this kind was charged against a surgeon in Vermont as evidence of malpractice. I am happy to say, however, that, in this particular case, he was sustained by the testimony of the medical men and by the verdict of the jury; but the attempt which the reporter has made to defend this as a universal practice in fractures of the leg, or of the tibia alone, is unfortunate, and evinces a lack of practical experience.

Whatever position is adopted, and whatever means of support or retention are employed, if bandages or splints are applied tightly or injudiciously, great suffering and irreparable mischief to the knee-joint may be the consequence.

A man, æt. 23, entered the Pennsylvania Hospital, July 18, 1839, with an oblique fracture through the head of the tibia. A physician had applied a bandage and splint to the leg, and sent him twenty miles to the city, and, on examination after his arrival, the whole limb as high as the groin was much swollen, red, and excessively painful. The knee-joint was distended and very tender. All dressings were immediately removed, and the limb laid in a fracture-box slightly elevated at the foot; cool lotions were applied, and the patient was freely bled, both from the arm and by the application of leeches. The limb was kept in this position about six weeks, and at the end of two or three weeks more he was dismissed cured. Dr. Norris, who was the hospital surgeon in attendance, has, in his report of the case, very properly taken this occasion to warn surgeons of the danger of excessive bandaging and splinting in this kind of fracture, as well as in other fractures of the lower extremities.

Fractures of the malleolus, unaccompanied by any other accident, demand only that the limb should be laid upon its outer or fibular side, with the foot so supported that it shall incline inward toward the tibia. In this simple disposition of the limb we have done all that can be done by any mechanical contrivance toward approaching the lower fragment to the shaft from which it has been broken.

In a case of a transverse fracture just below the tubercle of the tibia, the union was delayed many months. I perforated the bone with Brainard's drill several times, and, binding a firm splint upon the back of his thigh and leg, he was laid in bed. After the first week I pushed an ordinary shawl-pin between the fragments, and left it in place three days. This was repeated several times, and at the end of a few weeks union was complete.

[If drilling should not succeed after repeated trials, the better treatment is the antiseptic wiring of the fragments. It often happens that something is found between the fragments, as muscle or loose bone. After wiring the bones the limb should be placed in a wire-gauze splint and lightly covered with a plaster bandage.]

CHAPTER XXXII.

FRACTURES OF THE FIBULA.

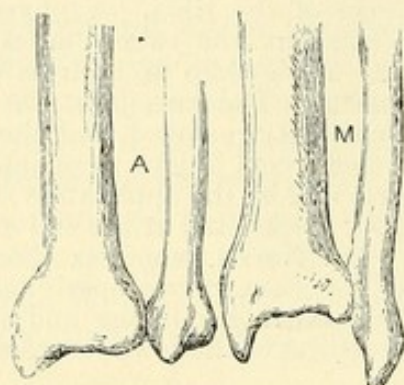
Development of the Fibula.—The fibula is formed from three centres of ossification—one for the shaft, and one for each extremity. Bone begins to be deposited in the shaft at about the sixth week of foetal life,

FIG. 296.



Development of the fibula. (From Gray.)

FIG. 297.

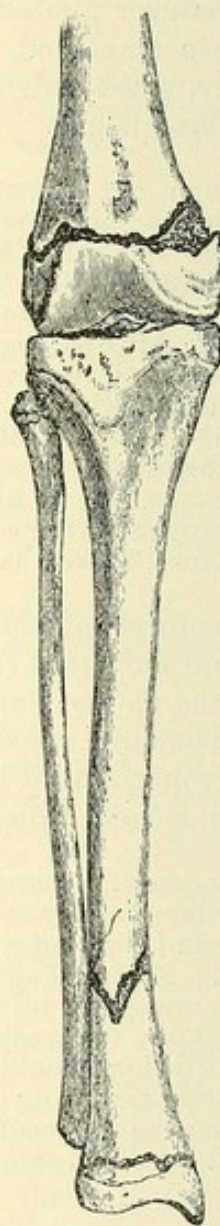


Comparative difference between the external malleolus of man and the higher mammal; A, ape; M, man.

in the lower extremity during the second year, and in the upper extremity during the fourth year. The lower epiphysis unites with the shaft about the twentieth year, and the upper about the twenty-fifth year.

[Dr. J. B. Sutton, of London,¹ notices the comparative length of the external malleolus in man. If this malleolus in man is compared with that of mammals, which so closely approach him in anatomical characters, it will be found to descend much lower. (Fig. 297.) He

FIG. 298.



Separation of several epiphyses in the lower limb. (Pick.)

¹ Amer. Journ. Med. Sci., 1888.

states that no one has ever described an example of Pott's fracture in a monkey, nor, indeed, in any mammal save man; he concludes that Pott's fracture is peculiar to the human kind, and occurs as a distinct result of the extraordinary length of the fibula malleolus, in that it affords excessive leverage when the foot is suddenly and violently twisted laterally, the force applied to the distal end causing the fibula to snap at some point in its lower fourth.]

Epiphyseal Separations.—Stimson relates that "in April, 1883, a child, about two years old, was run over by a street-car and brought to the Presbyterian Hospital. In addition to other wounds, which were promptly fatal, there was a lacerated wound on the outer side of the right leg exposing the upper end of the fibula and opening the knee-joint. The epiphysis of the fibula was completely detached from the shaft and from the tibia, and remained attached to the external lateral ligament and the tendon of the biceps; there was also an incomplete fracture of the shaft of the fibula three-fourths of an inch below the epiphyseal line, and the intermediate portion was denuded of its periosteum, which remained attached to the epiphysis."¹

[Pick illustrates this accident (Fig. 298) by a specimen showing several epiphyseal separations in the same subject.]

Causes of Fracture.—In a record of forty-eight cases I have been able to ascertain the cause satisfactorily in thirty-two, of which number six were the results of falls directly upon the bottom of the foot, but which were probably accompanied by a twist of the foot, eleven of a slip of the foot in walking on level ground or on ground only slightly irregular, and fifteen of direct blows.

I shall here take the liberty of quoting the careful studies and observations of Poincot:

"Muscular contraction is sometimes the cause of fracture of the fibula. In this case, the superior extremity detaches itself from the rest of the bone. This variety of fracture, very rare however, was noted as early as 1854, by Professor Hergott, of Strasburg;² at the same time, two practitioners of the upper Rhine, Weber and Müller, reported each an observation of the same kind. Brand, in 1877, reported a case of fracture of the head of the fibula which complicated a dislocation of the leg forward.³ Similar facts were recently published by Messrs. Duplay, Perrin, and Terrier.⁴ Hergott's patient, a woman fifty-two years old, fell; throwing herself quickly backward, she felt a crack in her left leg on which her body was resting. A slight tumefaction was discovered opposite the head of the fibula, as also a manifest crepitus, felt by the patient as well as by the doctor. The fracture in Weber's patient, and probably also in Terrier's, was produced in the same way. In Müller's case, two young men were wrestling; one of them, on the point of being thrown, made a violent effort; but cried out so that his adversary let go; he did not fall, although he could not use his leg. Müller recognized a fracture of the head of the fibula. Brand's patient was knocked down backward by a cow on a pile of stones and wood. The leg, in M. Perrin's case, was caught between the ground and a fallen horse. M. Duplay's patients, men of forty-eight and sixty years, had been caught, one by the shaft of a machine, the other by a transmission belt, and their bodies, drawn in a rapid movement, struck a neighboring wall repeatedly. The patients explained perfectly, that in the movements of rotation to which they had been subjected, their

¹ Stimson, *op. cit.*, p. 586.

² Hergott, *Gaz. Méd. de Strasburg*, 1854, p. 344.

³ Brand, *Bayr. ärztliches Intell.*, 1877, No. 52, p. 543.

⁴ *Bull. Soc. de Chir.*, 1880, p. 218.

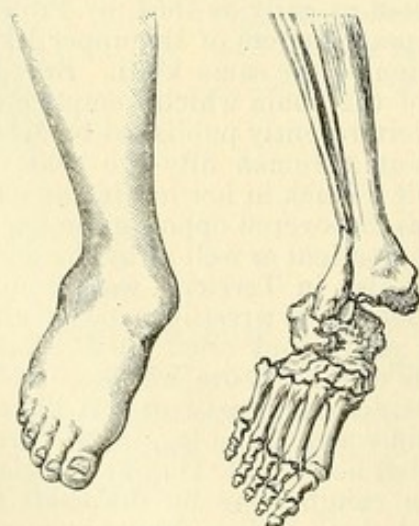
legs came in contact with the ceiling, so that the inferior right limb (where the *arrachement* of the fibula existed) was struck from outward inward, and consequently tended to bend violently inward. It seems to us that the mechanism admitted by Hergott can be applied to all the cases: the leg being slightly bent on the thigh, the biceps contracts with all its strength perpendicularly to the line of the fibula, which breaks at its feeblest point. This mechanism, which cannot be contested in Hergott's, Weber's, and Müller's cases, is equally admissible in Perrin's and Duplay's. One can well understand, that the upper part of the leg being fixed in slight flexion by contact with the ground or the ceiling, the biceps should act with more efficacy. As to Brand's case, it furnishes no details in reference to the mechanism of the lesion; it seems, however, that Hergott's theory may well be applied to it."¹

Pathology of the True Fractures.—In all of the fractures recorded by me which have been produced by falls upon the bottom of the foot, and in all except one produced by a slip of the foot, the accident was accompanied by a partial dislocation of the ankle, the foot being turned outward. In the one exceptional case mentioned, the dislocation may also have occurred, but the fact is not known. In at least ten of the fifteen fractures produced by direct blows, the tibia has been thrown more or less inward, and consequently the foot has turned out. Occasionally the tibia slides a little forward upon the astragalus. But this seldom happens as the primary accident; it occurs later, perhaps within the first ten days after the accident, when the heel has been insufficiently supported.

In thirty-seven examples the fracture of the fibula has taken place within from two to five inches of the lower end of the bone. Three times the external malleolus was broken off, and eight times the internal malleolus. Five of the fractures occurring in consequence of direct blows were compound, and one was also comminuted.

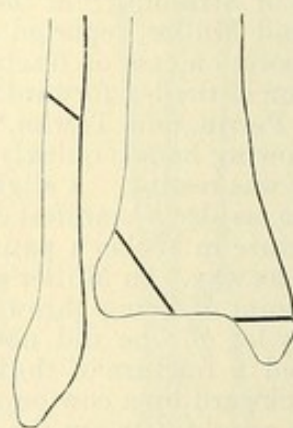
The most frequent form of fracture of the fibula is that first described by Pott as follows: "This is the case when, by leaping or jumping, the fibula

FIG. 299.



Pott's fracture.

FIG. 300.



Lines in Pott's fracture.

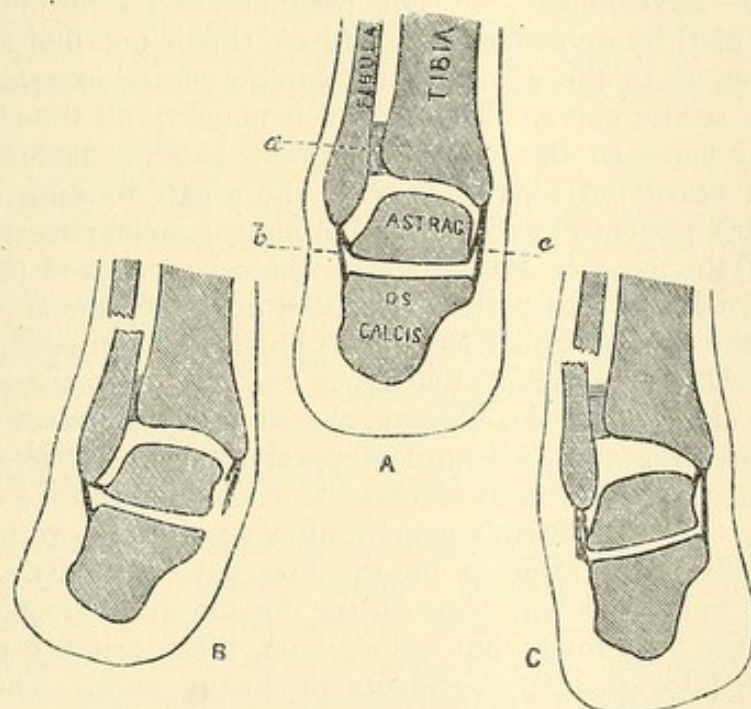
breaks in the weak part already mentioned; that is, within two or three inches of its lower extremity. When this happens the inferior fractured

¹ Poinso, op. cit., p. 652. See, also, *Lésions du Sciat. poplit. ext. dans frac. de l'ext. sup. du Perone.* Duplay, *Prog. Méd.*, Paris, 1880, viii. 257.

end of the fibula falls inward toward the tibia, that extremity of the bone which forms the outer ankle is turned somewhat outward and upward, and the tibia, having lost its proper support, and not being of itself capable of steadily preserving its true perpendicular bearing, is forced off from the astragalus inward, by which means the weak bursal or common ligament of the joint is violently stretched, if not torn, and the strong ones, which fasten the tibia to the astragalus and os calcis, are always lacerated; thus producing at the same time a perfect fracture and a partial dislocation, to which is sometimes added a wound in the integuments made by the bone at the inner ankle."¹

Maisonneuve² thinks he has established, by experiments upon the cadaver, that the fracture of the fibula at its lower extremity is caused not by forced abduction of the foot, but by violent outward rotation; while M. Tillaux,³ by the same mode of experimentation, has reached a different conclusion. According to M. Tillaux, the first effect of the forced abduction is to tear the internal lateral ligament, or to fracture the internal malleolus. The force, continuing to

FIG. 301.



Mechanism of fracture of the lower end of fibula; A, parts in normal position; *a*, tibio-fibular ligaments; *b*, external lateral ligaments; *c*, internal lateral ligaments. B, fracture of fibula due to eversion of the foot. C, fracture of the fibula due to inversion of the foot. (Treves.)

operate in the same direction, presses the astragalus against the external malleolus and tends to separate the fibula from the tibia, and may so far rupture the inferior peroneo-tibial ligament as to cause a diastasis of the articulation; or a portion of the lower end of the tibia upon which the ligament is attached may be torn off; or, the diastasis not having taken place, the fibula may break above the peroneo-tibial ligament. To this fracture M. Tillaux gives the name "bi-

¹ The Chirurgical Works of Percival Pott, F.R.S., Surgeon to St. Bartholomew's Hospital. First Amer. ed., 1819, p. 248.

² Maisonneuve, Arch. Gén. de Méd., fév. et avril, 1840.

³ Tillaux, Anat. Top., Paris, 1877, pp. 1172-1175.

malleolar by abduction." It is essentially the typical Pott's fracture, although it was not so described in all points by him. In the forced movement of adduction, on the other hand, the external lateral ligament is first put upon the stretch, perhaps ruptured, or the external malleolus is torn off, sometimes at its summit, but most often at its base. In this case the fragment is not usually displaced, nor is the foot in any way deformed. It is a fracture by *arrachement* alone, and is not complicated with any other fracture. But the astragalus released by the rupture of the external lateral ligament, or of the malleolus externus, and continuing to press inward upon the malleolus internus, finally causes a fracture of this latter also, at its base. This he calls the "bi-malleolar fracture by adduction." It may happen, also, that neither the external lateral ligament nor the malleolus externus having given way, the fibula will break above the inferior peroneo-tibial ligament, and, the force continuing to act, the lower end of the body of the tibia will be torn off in whole or in part. This he terms a "transverse supra-malleolar fracture."

These observations made by Tillaux, like all similar observations made exclusively upon the cadaver, must be accepted, as applied to the living subject, with some degree of reserve, since they lack the conditions of rigidity of the muscles, with force and direction of impact, which in a degree more or less contribute to the peculiar lesions in the latter.

Prognosis.—Says Poinso¹: "The prognosis of fracture of the fibula (at its upper end) by *arrachement* is grave; this is not due so much to the bony lesion as to the consequent wounding of the external popliteal branch of the sciatic nerve. This wound is noted in all the observations mentioned by me. In the case of Hergott's patient, flexion made the primary pain cease, but for two months and a half walking was impossible. Weber's patient experienced a permanent incomplete paralysis of the flexors of the foot; in Müller's case, the calf remained painful for a long time. In Brand's case, there persisted for some time an incomplete paralysis of the muscles and a local anæsthesia of the integument, in the treatment of which the inducted currents had to be resorted to. In the two patients observed by M. Duplay, the one who survived exhibited, after the lapse of a year, a complete paralysis of the extensors of the foot and of the lateral peroneal muscles; he could hardly take a few steps with crutches. In M. Perrin's patient, after a period of two months, the paralysis remained the same as on the first day. Finally, M. Terrier noticed in his patient violent pains in the dorsum of the foot with anæsthesia, from the beginning; but before long, these primary phenomena were succeeded by secondary accidents producing pain. The relations of the external peroneal nerve with the head of the fibula, the contour of which it follows before lodging into the interosseous space, explain the reason why it is frequently wounded under those conditions. Being torn by the bone at the time of the accident, that nerve may afterward be included in the effusion which, later on, will constitute the callus."

In a majority of cases, where the fibula has been broken from two to five inches above the lower end, the fragments have united inclined toward or resting against the tibia; occasionally I have seen them displaced backward or forward. Once the fibula refused to unite altogether. The malleoli have generally united nearly or quite in place, but in two instances the external malleolus has been found displaced very much downward.

¹ Poinso^t, op. cit., p. 655.

Of the compound fractures, two required amputation, one was treated by resection of the lower end of the tibia, and two died without any operation. Douglas has reported a case of compound dislocation with fracture of the fibula, which being reduced he was able to save the limb, but not without much difficulty, and the ankle remained stiff.¹

Of those which recovered, forty-six in number, twelve were found to have more or less unnatural prominence of the internal malleolus, and in two of these the malleolus, or lower end of the tibia, projects very much. In nearly all of these latter examples the foot appears somewhat inclined outward. Generally the ankle-joint has remained stiff for some time after the bandages have been removed; and probably in all cases in which the accident was accompanied by a dislocation of the tibia. But this stiffness has usually disappeared after a few weeks or months.

Twice I have noticed considerable stiffness after about six months; three times after one year; in one case after two years; and in one case after twenty years the ankle would occasionally swell, and become quite stiff. In one case it remained almost immovable after twenty years; and in a still more remarkable instance, I examined the limb thirty years after the accident, when the man was sixty-three years old, and although there existed no swelling or deformity, yet this leg was not as muscular as the other, and he declared that up to that time the ankle remained quite tender to the touch, and that occasionally it became painful.

When I come to speak of dislocation of the ankle, I shall adopt the usual nomenclature, and shall name all those dislocations in which the tibia projects inward from the foot, "inward dislocations of the tibia;" yet I have some doubts as to the propriety of calling this a dislocation, either partial or complete. This accident seems to me to have been in general rather a lateral *rotation* of the foot, or of the astragalus, upon the lower articulating surfaces of the tibia and fibula. Of all the ginglymoid joints, the ankle approaches most nearly in form to a ball-and-socket joint, in consequence especially of the marked prolongations of the malleolus internus and externus. In other ginglymoid articulations lateral displacements are not infrequent, but lateral rotation can scarcely by any accident occur. Here, however, the reverse holds true; lateral displacement is difficult, while lateral rotation is comparatively easy of accomplishment.

The majority of cases which occur, involving a disturbance of the relative position of the ankle-joint surfaces, are lateral rotations within the capsule rather than true dislocations; and although the restoration of the joint surfaces to position is, in general, easily accomplished, yet in consequence of either a fracture of the fibula or malleolus internus, or of a rupture of the internal lateral ligaments, it will generally happen that some deformity will remain. The fragments of the fibula will fall inward toward the tibia, and the foot, unsupported by either its fibula or its internal ligaments, will incline perceptibly outward. Nor can this be wholly prevented, in most cases, by any mechanical contrivance.

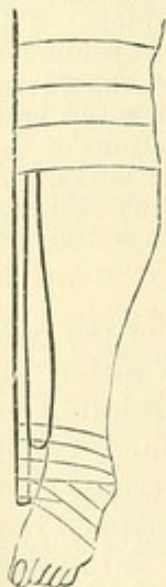Indeed, it would be easy to demonstrate that even Dupuytren's splint, heretofore so much employed in this accident, must fail of success in a great majority of cases; since the subsequent deformity is due less to the fracture of the fibula and its consequent displacement than to the loss of the internal ligaments, which loss nature can seldom fully repair. As further evidence of the correctness of this view, I will state that in three of the examples in which I found the fractured fibula united and resting against the tibia, the motions of the ankle-joint have been completely recovered.

¹ Boston Med. and Surg. Journ., vol. xxxiv. p. 335, from Southern Journ. of Med.

I do not here refer to those cases in which a portion of the outer and lower extremity of the tibia being also broken off obliquely, and more or less displaced, perhaps rotated upon its axis, the perfect approximation of the tibio-peroneal articulation becomes impossible. Such cases necessarily entail serious deformity. If, however, it were true that a fracture and displacement of the fibula is the sole or essential cause of the subsequent deformity, it would still be found often impracticable to avoid the maiming, since it would still remain impossible to lift the broken ends from the tibia, against which, or in the direction toward which, they are so prone to fall. Inversion of the foot does not accomplish it, nor have I ever been able to make anything but the most trivial impression upon the upper end of the lower fragment by pressure upon the lower extremity of the fibula.

Treatment.—Too much confidence has been placed in the efficiency of "Dupuytren's splint." I believe, indeed, that this splint is, in many cases, a very appropriate means of support and retention after this accident; but I doubt whether it is able to accomplish all that its illustrious inventor proposed, and especially in those cases in which, the fibula being broken, and the internal lateral ligaments torn, the astragalus is disposed to glide backward; of which I have seen several examples, some of which have left a permanent and serious deformity, in the elongation of the heel and shortening of the foot in front of the tibia. It does not appear that either Pott or Dupuytren was aware of this form of displacement from this cause:

FIG. 302.



Dupuytren's
splint, incor-
rectly applied.

Dupuytren's mode of dressing is essentially as follows:

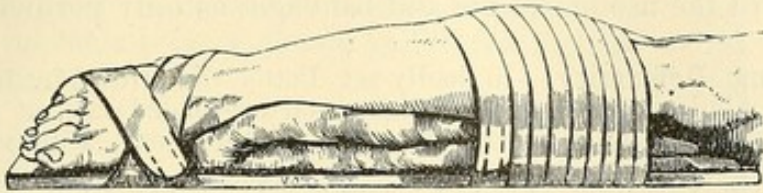
A pad, or long junk, made of a piece of cotton-cloth, stuffed with cotton-batting, is constructed of sufficient length to extend from the condyles of the femur to a point just above the malleolus internus. This pad must be about five or six inches in width, and thicker by two or three inches at its lower than its upper end. This is to be laid upon the inside of the leg, with its base or thickest portion resting against the tibia just above the internal malleolus. Over this pad is to be placed a long firm splint, extending also from above the knee to three inches beyond the bottom of the foot. With a few turns of a roller the upper end of the splint must now be made fast to the knee, and with a second roller the lower end secured to the foot. The application of this last bandage requires, however, some care in its adjustment. Its purpose is simply to rotate the foot inward, while at the same time the tibia is pressed outward; and to this end it must be applied in the form of a figure-of-8 over both splint and foot, embracing alternately the heel and the instep. In order to be effectual, it must be drawn pretty firmly, and no portion of the bandage must pass higher than the malleolus externus. In some surgical books I have seen this apparatus represented with a roller embracing the whole length of the leg; and in others it is represented as encircling the limb two or three inches above the malleolus (Fig. 302); but it is evident that these modes of dressing must defeat the great object which Dupuytren had in view, namely, the throwing out of the upper end of the lower fragment.

When the limb is thus dressed, the knee may be flexed and the leg laid upon its outside, supported by a pillow, or upon its inside, as in the accompanying engraving (Fig. 303).

If it is only a fracture of the external malleolus, or if the fracture has occurred in the middle or upper third of the bone, this treatment is no

longer appropriate, and it will generally be found sufficient to place the limb at rest for a few days upon a suitable cushion or upon a pillow.

FIG. 303.



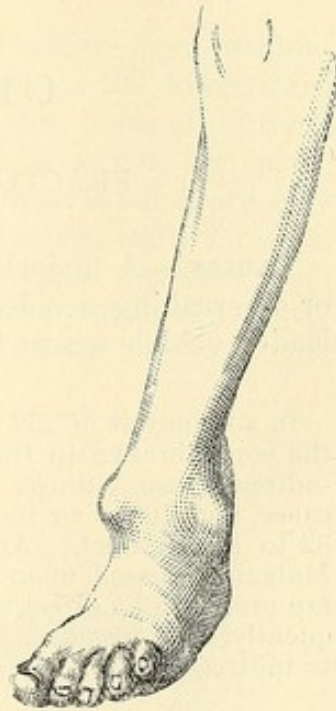
Dupuytren's splint as originally applied by himself.

Of late years I have not employed Dupuytren's splint, and especially because I have met with several examples of backward displacement of the foot following fractures of the fibula, which Dupuytren's splint is not competent to prevent or to remedy. This accident can be most certainly avoided by employing the plaster-of-Paris or starch dressing; taking care in applying the dressing to secure a thorough inversion of the toes and foot, the same as in case the limb were dressed with Dupuytren's splint. Care must be taken, also, not to permit the bandages to press upon the limb above the malleolus externus. The same results may be attained by well-adjusted leather, felt, shellac, or gutta-percha splints, which inclose the heel as well as the sides and front of the limb.

[It is of the utmost importance to overcome completely the displacement outward while the dressing is being applied, and to maintain it until the plaster is hard. The inversion of the toes is useless unless the tarsus is restored from its outward luxation. To effect this, pressure must be made upon the outside of the foot below the malleolus, and counter-pressure upon the tibia above the joint.]

It is scarcely necessary to say that, since after the accident ankylosis is so frequent, early and unremitting attention should be given to the establishment of passive motion in the joint. Indeed, I cannot but think that a desire to accomplish the indications recognized and urged by Dupuytren has led to the neglect of the indication which ought to have been regarded as of equal, if not of the greatest, importance, namely, the prevention of contractions and adhesions around and between the joint-surfaces. I cannot too often call the attention of the surgeon to the danger of tight bandages, to which I have frequently made reference elsewhere; and especially does it seem necessary here because I have recommended the use of the plaster-of-Paris bandage in this form of fracture, from which the greatest dangers are always to be apprehended, unless it is used

FIG. 304.



Badly-set Pott's fracture,
curable by operation.
(Erichsen.)

carefully and skilfully. As a general rule, the dressings ought to be wholly laid aside by the end of the third or fourth week; and although it may be well for a somewhat longer time to keep the foot turned in, by having it properly supported as it lies upon the pillow, yet after this date I regard the use of splints and bandages as only pernicious.

[Correcting Deformity.]—In badly-set Pott's fractures Mr. Erichsen has divided the fibula subcutaneously, with a narrow-bladed saw, at the point of greatest curvature, and then forcibly adducted the foot. Dupuytren's splint was then applied.

Le Dentu employed an osteoclast, which made pressure at three points, viz., two on the outside, one on the leg and the other on the instep and malleolus, and the third on the inside of the tibia just above the malleolus. On refracture the limb was placed in proper position, and a plaster dressing applied.

Fenger, of Chicago, performed osteotomy in a similar case. The operation consisted in cutting from the tibia a wedge-shaped piece, having the base, one inch thick, on the inner side, and the apex on the outer surface; the fibula was next broken, or drilled and broken. The foot was then brought into position.

Sabine, of New York, divided each bone with a chisel subcutaneously, about an inch above the malleoli, and obtained good results.]

CHAPTER XXXIII.

FRACTURES OF THE TIBIA AND FIBULA.

Causes.—A majority of these fractures are the results of direct blows or of crushing accidents, such as the kick of a horse, the passage of a loaded vehicle across the limb, the fall of heavy stones or timber, etc.

In an analysis of 217 cases, where I could ascertain the cause, I have found the bones broken in the upper third from a direct cause 7 times, and from an indirect cause 3 times. In the middle third 52 have been referred to a direct cause, and 10 to an indirect; and in the lower third 50 to a direct cause, and 32 to an indirect. An observation which does not sustain the remark of Malgaigne, based upon his analysis of cases, that fractures of the upper third are produced by direct causes alone, those of the middle third much more frequently by indirect causes, and that those of the lower third are especially due to indirect causes.

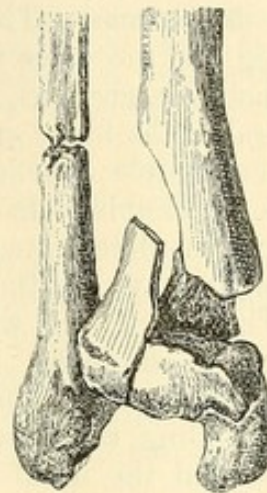
Of the indirect causes, falls upon the feet from a considerable height—as from a scaffolding, or from a top of a building—are by far the most common. Eight times I have found the bones broken by muscular action alone.

Pathological Anatomy.—We have seen that fractures of both bones through some part of the lower third are most frequent. Thus, of 217 fractures, 22 belonged to the upper third, 7 to the middle, and 125 to the lower. In some cases the two bones were broken in different divisions. It is often

difficult, and sometimes quite impossible, to determine precisely where the fibula is broken; but the analysis is sufficiently correct to illustrate the much greater frequency of fractures of the lower third, and also the fact that the two bones generally break nearly on the same level; usually the point of fracture in the tibia is between two and three inches above the joint.

In an examination of twenty museum specimens, I have found both bones broken at the same point, or within two or three inches of the same point, sixteen times, and at extreme points four times; and in these last examples the tibia has always been broken in the lower third, while the fibula has been broken in the upper third. In twenty of the fractures mentioned as belonging to the lower third only the malleolus of the tibia was broken, while the fibula was broken two or three inches above its lower end. Some of these were complicated with dislocation of the angle. I have seldom seen a transverse fracture of the tibia, except in its lower or upper extremity, in the expanded portions of the bone; and even in those examples which we are accustomed to call transverse, because they are sufficiently so to prevent any sliding or overlapping of the fragments, there has existed, generally, a marked inclination of the line of fracture in one direction or another.

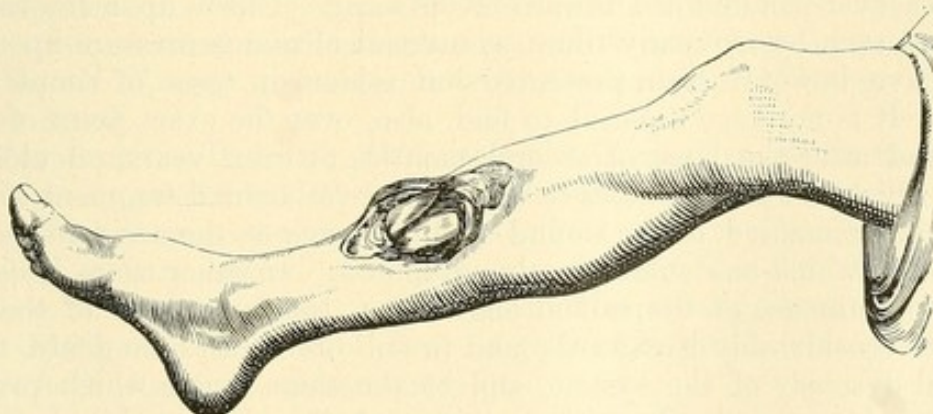
FIG. 305.



Fracture of tibia and fibula.

The examples of fracture produced by muscular action have, without an exception, occurred in adults. Five of them were in the lower third of the leg, and three in the middle third. I think they were all of them nearly transverse, since they never became much, if at all, displaced. Most of the fractures of the tibia produced by falls upon the feet are very oblique, and the direction of the fracture is generally downward, forward, and inward; but I have found almost every conceivable variation from this general rule. The fracture in the fibula is even more constantly oblique than the fracture in the tibia; but this is a point of very little

FIG. 306.



Compound and comminuted fracture of the leg.

practical consequence, and one which we can seldom determine positively, unless one of the fractured ends protrudes through the flesh. Compound and comminuted fractures are more frequent here than in any other of the bones of the body.

Of 217 fractures, 74 were compound, and also, frequently, more or less comminuted. Of 80 cases reported by W. W. Morland, of Boston, from the Massachusetts General Hospital, in which the character of the accident is recorded, 39 were compound.

Symptoms.—The symptoms indicating a fracture of both bones of the leg are the same which are usually present in other fractures, namely, mobility, crepitus, shortening of the limb, distortion, swelling, etc. Generally, the lower end of the upper fragment projects in front, and can be seen or felt; but in some instances the swelling follows so rapidly that it is impossible to feel distinctly the point of fracture, and its existence can only be determined by the crepitus, mobility, and shortening of the limb, or, perhaps, by the marked deformity or deviation from the natural axis. The shortening, where it exists at all, varies at the first from a line or two to one inch. Generally, it is about half an inch.

Prognosis.—The average period of perfect union in twenty-nine cases, including those in which union was delayed by extraordinary causes beyond the usual time, was forty days. The general average, under ordinary circumstances, may be stated at about thirty days. Union has been noted as delayed a few weeks beyond the usual time in at least twelve cases of simple fracture. Cases of complete non-union are less frequent here than in the femur or humerus, the union taking place spontaneously often after the lapse of several months. In most oblique fractures of the shafts of these bones, union takes place with some shortening, the average being, even in simple fractures, about half an inch, but in some cases I have found the shortening one or even two inches. With judicious management, however, in simple fractures, this amount of shortening seldom or never occurs.

Generally, when a shortening has occurred, I have found the upper fragment in front of the lower, and oftener a little more upon the inner than upon the outer side. A deviation from the natural axis of the limb has been noticed by me in a good many instances. Several times the lower part of the limb has fallen backward; or, in consequence of its having rested too much upon the heel, it has inclined forward; and in other cases it has inclined inward or outward. Ulcers upon the back of the heel, seen by me many times, as a result of undue pressure upon this part, have, however, been presented but seldom in cases of simple fractures. It is not very unusual to find, also, over the exact point of fracture, and after the lapse of several months, or even years, an ulcer, or sinus, which is due sometimes to the presence of a small fragment of bone which has remained in the wound from the time of the accident, or to a thin scale which has subsequently exfoliated. In other cases it is due to the prominence of the salient angle when the lower part of the limb inclines considerably backward; and in still other cases, no doubt, to the general dyscrasy of the system, and to the same causes which produce chronic ulcers in the lower extremities where only the skin has been originally injured.

A boy, four years old, received an injury, breaking both bones of one of his legs near its middle. The fracture was compound. Twenty-three years after the accident he called upon me on account of a paralysis of his lower extremities which had recently occurred. He stated that from the time of the fracture until

within about one year an open ulcer had existed over the seat of fracture, and that soon after it had closed over completely he began to lose the use of his limbs. During the time it was open, small scales of bone have frequently been thrown off. The limb is half an inch shorter than the other, but straight.

A gentleman had his tibia and fibula broken near the ankle-joint by the passage of a carriage-wheel across his limb. The skin was a good deal lacerated. The wounds, however, healed kindly, and the broken bones united in the usual time without any apparent deformity; but the limb continued swollen and painful, until finally suppuration took place. After twelve years of great suffering, I amputated the leg near its middle, from which time he made a speedy recovery. I found the lower end of the tibia inflamed, softened, and expanded, and containing in its interior about three ounces of pus, but no sequestrum.

Ankylosis of the knee- or ankle-joint may follow as a result of the accident or of improper treatment; and at one or both of these joints I have found more or less ankylosis at the end of nine months, one year, six years, twenty-five, thirty, and forty years. Generally, however, it disappears in a few weeks, and seldom remains to any considerable extent in the knee-joint after the dressings have been removed two or three weeks.

In Muhlenberg's tables, already referred to in previous chapters, there are recorded 94 cases of delayed union or of non-union of these two bones at the same time; also 84 similar cases in which the tibia alone was ununited, and 2 in which the fibula alone was ununited: making a total of 180 cases.

After all that has been said as to the occasionally serious nature of the consequences of these accidents, as shown in the shortening of the limbs, in their deviations from their natural axes, in the stiff ankles, ulcers, and abscesses, it must be still admitted that in another point of view these results are not extraordinary, and may hereafter continue to be fairly anticipated in a certain proportion of cases, even under the best management; since it must be understood that more fractures of the leg are attended with serious complications than of any other limb; and that while many produce death rapidly from the severity of the shock, and very many are condemned at once to amputation, a large number of those which are saved have been in that condition which has rendered the application of bandages or splints impossible for many days. Indeed, not a few of these crooked limbs may still be presented as real triumphs of the art of surgery, inasmuch as by consummate skill alone have they been saved.

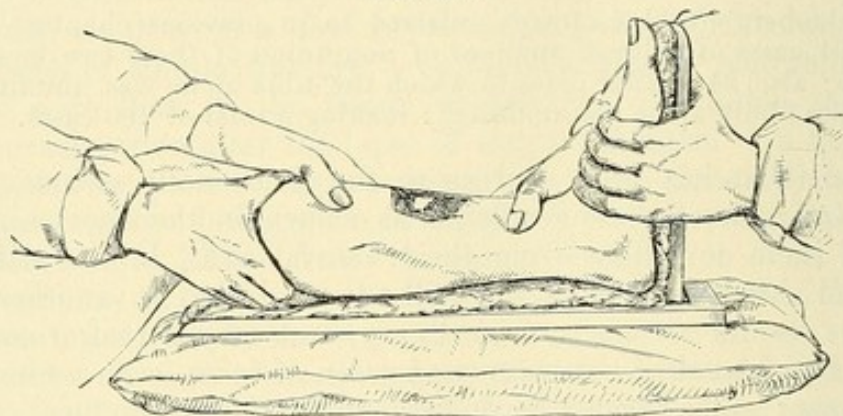
Treatment.—It is wholly impossible in a class of fractures which present so great a variety in regard to form, seat, and complications, to establish any universal system of practice; nevertheless, it is possible to declare certain general principles in reference to a few well-recognized classes or varieties: and I shall deem it especially important to record my disapproval of certain plans of treatment which have from time to time been suggested and adopted.

It is seldom that I have found it necessary or useful to apply any bandages directly to the skin, whatever form of apparatus has been employed; but in certain cases of compound fractures, where primary dressings have been applied which needed support and protection, a bandage has been of service. The roller, unless the patient is a child, whose limb can be easily lifted and managed, is always objectionable; but the many-

tailed bandage, made of narrow strips of cloth, laid upon each other, as we have already described in our general remarks upon bandages, etc., is occasionally useful.

Having made these preliminary dressings, we flex the leg to a right angle with the thigh, and by the hands make extension and counter-extension as much as the patient will bear, or as much as may be necessary to restore the fragments to place, in case this restoration is found to be practicable. If the fracture is compound, and the point of bone protrudes through the skin, it is often difficult to replace it. That is, we are unable to overcome the action of the muscles sufficiently to make the limb of its natural length, and for this reason, mainly, we are unable to get the point of bone beneath the skin. If we cannot then "set" the bone, or bring the ends into apposition, and this will be the fact pretty often, we still have no apology generally for leaving the bone outside of the skin. First, an attempt must be made to accomplish this reduction by pulling aside the skin with the fingers, or with a blunt hook. This

FIG. 307.



• Method of reducing a compound fracture.

simple procedure has often succeeded with me in a moment, when others have been trying in vain to accomplish the same end by pulling upon the limb. If this fails, then the skin should be cut sufficiently to allow the bone to retire, or if the point is sharp, and especially if it is stripped of its periosteum, it may be sawn or cut off. Resecting thus the end of an oblique fragment does not generally affect in any degree the length of the limb, or interfere with a prompt and perfect cure, but, on the contrary, it often is advantageous in every point of view. In certain exceptional cases we may find it advantageous to employ an anæsthetic to aid us in the reduction.

Before, however, considering the character and form of the splints to be applied, it seems proper to call attention again to the danger of ligation of the limb from the tightness of the bandages, and especially from the use of a bandage or roller placed beneath the splints and directly against the skin. The large size and irregular form of the bones of the leg, the small amount of muscular tissue covering them, especially near the articulations, the severity of the injuries to which they are liable, with their remoteness from the centre of circulation—these circumstances altogether, render them exceedingly exposed to injury from the too great

or unequal pressure of splints or of bandages; and it has often occurred to myself to find the skin vesicated, or even ulcerated and sloughing, when the patients are first admitted to the hospital; a condition which, in nine cases out of ten, is due to the maladjustment of the splints or to the tightness of the bandages. If bandages are used under the splints, and next to the skin, they must be applied very moderately tight, and loosened or cut as the swelling augments; and, from the first day of treatment to the last, the surgeon must be careful to loosen or tighten the dressings when the swelling increases or subsides.

Dr. Krackowizer presented to the New York Pathological Society, June 10, 1863, a leg which he had amputated for gangrene occasioned by tight bandages. A boy, five years old, sustained an injury of the ankle-joint, which his medical attendant pronounced a fracture of the fibula, and for which he applied only a tight bandage. The child suffered a good deal after the bandage was applied, and the following morning the toes were blue, but the doctor paid no attention to this circumstance. The pain subsided on the third day, and on the fourth the bandages were removed, and the limb found to be gangrenous. The specimen showed that the fibula was not broken, but that there was a fissure or crack in the lower part of the shaft of the tibia.¹

The following case has been communicated to me by Dr. Fuller, of Wyoming, N. Y. A man, æt. 71, fell from a tree, striking upon his foot, producing a backward dislocation of both the tibia and fibula upon the astragalus, and also a fracture of both bones of the leg a few inches above the ankle. An empiric immediately applied lateral splints and a firm roller from the toes to the knee. Notwithstanding the remonstrances and prayers of the patient to have the bandage loosened, it was kept on until the ninth day, when the doctor cut the bandage upon the top of the foot, and it was found vesicated. Ignorant, however, as to the cause of this vesication, and of the danger which it threatened, he omitted to loosen the remainder of the bandages, and the limb was left in this condition until the twenty-third day, when Dr. Fuller removed all the dressings, found the integuments covering the whole foot dead and dried down to the bones. The dislocation had not been reduced. Soon after this the limb became oedematous, and on the 27th of October the leg was amputated, from which time the patient recovered rapidly.

The fragments being adjusted, two lateral splints of leather, long enough to extend from near the knee-joint to the metatarso-phalangeal articulations, and wide enough nearly to encircle the limb, are moulded to the limb on each side, and secured in place by successive turns of the roller. When the skin is delicate or tender, these should be underlaid with a thin sheet of cotton wadding or of sheet lint. A soft woollen cloth may answer the purpose equally well. A rack is then placed over the limb, such as will be seen figured for the suspension of the limb when dressed with plaster-of-Paris, and from this the leg is suspended. The objects to be obtained by the suspension are threefold: first, to avoid the danger of pressure upon the heel, and consequent ulceration; second, to prevent that driving down of the upper fragment upon the lower which constantly ensues when the foot rests upon the bed, or in a box which is immovable; third, to obviate movement of the fragments upon each other when the patient sits up or lies down in bed. This movement, I observe, is peculiar. It is not simply a motion of the fragments upon each other, as upon a pivot at the point of fracture, which motion seldom interferes

¹ Krackowizer, Amer. Med. Times, Nov. 7, 1863.

materially with consolidation, but it is a rising and falling of the upper fragment, or a motion to and fro of the fragments, and also a riding motion; either of which latter movements necessarily delays or defeats bony union. It is because these motions are generally permitted to occur in the usual modes of dressing these fractures, more than for any other reasons, that union is so often delayed in the case of these bones. In my own practice, when this plan of suspension is enforced, delay seldom occurs; but nothing is more common than for me to meet with it when other surgeons have had charge of the limb, and the suspension has been omitted. In suspending the limb, it is only necessary that the leg should float clear of the bed; and I think it worth while to say that when lateral splints only are used, broad oval pieces of leather or of some other firm material should receive the limb in suspension, rather than narrow pieces of bandage, which soon become cords, and press unequally. To the sides of these oval pieces bands are attached, and their ends tied over the top of the rack. One must be placed under the knee and one under the ankle. If the fracture is above the middle of the leg, complete quietude of the fragments can only be obtained by carrying the splints and the bandages above the knee.

I have already, in my remarks on the treatment of fractures in general, declared my acceptance of the so-called "immovable apparatus" in the treatment of certain fractures of the leg below the knee, and especially of the plaster-of-Paris dressings. In hospital practice, where these dressings can be applied by experts, and where the limb can be watched daily and hourly, most or all of the dangers incident to this form of dressing may be avoided; but even here I have occasionally seen, from a little too much delay in opening the dressings, serious trouble ensue. Its most devoted advocates, Seutin, Velpeau, and others, have never denied the necessity of caution in its use. On the other hand, when applied judiciously, even immediately after the receipt of the injury, and when carefully watched and opened freely on the first notice of danger, it has, in my wards, and in the hands of my excellent house surgeons, often served its purpose more completely than any other apparatus or splints I have even seen employed. It has steadied and supported all parts of the limb more completely, and permitted it to be handled more freely, than anything else could do. In simple fractures patients have been permitted to walk about upon crutches after the third or fourth day, and generally no harm has resulted. In one case, however, I believe this liberty caused a serious delay in the union; and in another an abscess resulted, which would have been avoided if he had remained in bed.

Inasmuch, however, as among the claims lately instituted for the plaster-of-Paris dressing, it has been affirmed by at least one surgeon that it is competent to prevent in all cases shortening after fractures of the bones of the leg, as well as of the thigh (see chapter on General Prognosis), it may be necessary to refer the question at once to the test of experience, and thus dispose of it before considering the subject of treatment.

F. A., æt. 24, fell, breaking his left leg three inches above the ankle, and was admitted to Bellevue. Dr. Thomas, while the limb was extended to its utmost, applied the plaster-of-Paris dressings from the toes to the knee. The dressings were removed in my presence, at the end of six weeks, when the bones were found united with a shortening of one inch.

T. M., æt. 30, fell and broke his left leg by a twist of his foot. Fracture simple, oblique, and in lower third. Plaster-of-Paris was applied at once, while extension was made to the utmost. The splint was renewed once during the treatment, and on the 19th of April, the splint being removed, I found the limb united, and shortened three-quarters of an inch.

These two cases will serve to illustrate what has been my experience at Bellevue and elsewhere with the plaster-of-Paris as a means of extension. Of fifteen cases of oblique fractures of the shaft in my record, the average shortening is nearly three-quarters of an inch, and all are shortened. It is not the practice generally at Bellevue to give an anæsthetic in applying plaster to the leg, nor is it mentioned as having been used in more than one of the cases contained in Dr. Van Wagenen's tables, referred to in the chapter on General Prognosis. But, to determine the value of this method in a case of simple oblique fracture of both bones, I first measured the limb carefully before it was dressed, and found it shortened half an inch. The patient was then placed under the influence of an anæsthetic, and forcible extension made with pulleys until the limb was of the same length as the other. In this position it was retained until the plaster was applied, from the toes to above the knee, and had hardened. At the end of about six weeks the dressings were removed, and the limb was found to be shortened half an inch precisely the same as before the extension was employed.

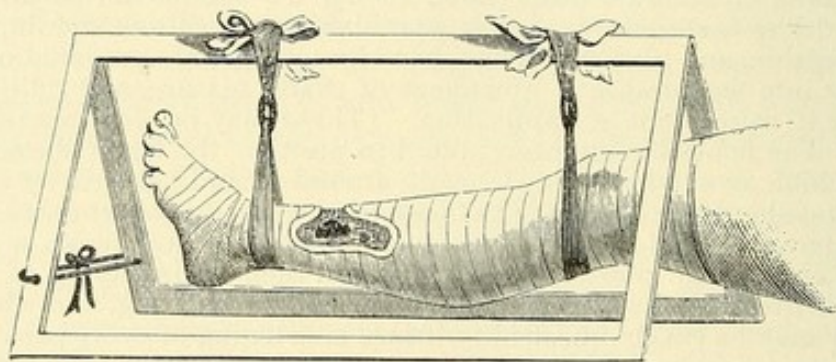
It is certain that this form of dressing makes no permanent extension within a range of three-quarters of an inch, and that, therefore, for all practical purposes, as a means of preventing shortening, it is useless.

The following careful description of the proper mode of applying plaster-of-Paris bandages in fractures of the leg, has been prepared at my request by Dr. S. B. St. John, late House Surgeon to Bellevue Hospital. His large experience and his habits of accurate observation render his statements peculiarly trustworthy. "The materials necessary are blanket or cotton-wadding, blanket being preferable, and plaster-of-Paris bandages, which are prepared by rubbing dry plaster into the meshes of a bandage of coarse texture, and rolling it up so as to make it convenient of application. (These may be kept ready for use in tin cans.) The bones having been placed in position, the leg is placed upon the blanket, which is cut and folded neatly around it, and secured by a few pins. The blanket should extend from the base of the toes to the knee, or in case of fracture above the middle, or of compound fracture at any point, a few inches above the knee. The plaster bandages should then be immersed in hot water, to which a little salt has been added to hasten the setting, and while in the water they may be gently kneaded to insure moistening of every part. In about three minutes, or when bubbles of air cease to rise from them, they will be ready for use, and should be taken out as they are wanted, and gently squeezed to get rid of superfluous water. They are then to be applied after the fashion of an ordinary bandage, over the blanket, with just sufficient firmness to insure a complete fit. If, at any revolution of the bandage, the plaster is seen to be dry, it should be moistened by dipping the hand in water and rubbing it over the dry surface. Extra turns of the bandage should be taken at the places where it is necessary to secure extra strength to the splint. Three or four bandages (six yards long) are usually sufficient to make a firm splint. This splint will usually be sufficiently pliable just after its application to allow of rectification of any faulty position which may have occurred during its application. It should then be kept in shape by the pressure of the hands until it hardens, which will be in from ten to thirty minutes, according to the freshness of the plaster and texture of the bandages used. If, for any reason, it is desirable to cut the splint so as to admit of its removal, or to cut a fenestra through which to observe any part, this may best be done before the plaster becomes perfectly dry, say in from two to five hours after its application, depending upon the quality and freshness of the plaster. It will then cut like hard cheese, and a stout, sharp knife should be used. In splitting a splint anteriorly, it is convenient at the same time to take out a piece about an inch wide, by making two parallel cuts one inch apart, one on either side of the median line, extending nearly through to the blanket, and then by raising the strip at the upper edge and cutting on either side alternately, the section may be completed, and the central slip removed without danger of cutting through the blanket and wounding the patient. The blanket may then

be cut with scissors and the splint sprung off to examine the limb, if necessary. When replaced, a bandage should be applied over it. If it should be necessary to cut a splint which has already become dry, and cuts with great difficulty, it may be softened with hot water, applied by a sponge in the track of the proposed section for ten or fifteen minutes.

"If it is necessary to cut such a large fenestra that only a small strip of the splint would be left connecting its upper and lower portions, it is better to adopt a different plan of application. For this it is necessary to have a solution of plaster-of-Paris in water of the consistency of cream. A piece of blanket is then cut long enough to reach from the toes to the top of the proposed splint, and about fifteen inches wide. This is to be thoroughly soaked in the solution, and folded several times so as to be about two or three inches wide when folded. This is to be applied along that part of the limb which it is not necessary to keep under observation (if convenient, along its posterior aspect), and it is then to be secured in position by circular turns of the plaster bandage above and below the portion to be left exposed. Whenever a plaster apparatus extends above the knee, and it is proposed to sling the leg from a cradle, the leg should be flexed slightly upon the thigh, so that it may be swung horizontally. Any portion of a plaster splint exposed to the moisture of discharges or of water used in dressing should be carefully protected by oil silk and cotton-wadding. In cases where not much swelling is anticipated, blanket is preferable to cotton-wadding, as an elastic medium between the splint and skin, because it is of more even thickness and retains its place better when the splint is removed, but cotton answers better when much swelling is anticipated, as being more elastic."

FIG. 308.



Plaster-of-Paris dressing, and suspension.

The accompanying illustration (Fig. 308) has also been made for me by Dr. St. John, and furnishes a faithful picture of one of the many similar cases which have been under treatment by this method at Bellevue Hospital.

Dr. George A. Van Wagenen, while acting as house surgeon at Bellevue, devised a most ingenious, simple, and effective apparatus for suspending the limb, which will be found illustrated in the accompanying woodcut (Fig. 309). "It consists of an elbow γ of wood projecting over the foot of the bed, from which the leg is suspended by two pieces of rubber tubing; one above the ankle, the other just below the knee. The tubes have common grooved iron pulleys or wheels at each end; those above, rolling on a large iron wire to allow motion toward the head or foot of the bed; those below, at right angles to the others, holding the rings of rope in which the leg rotates; this last being far the most important, allowing the patient to turn on either side. Motion on these rollers is accomplished with so little resistance that there is no pain.

"The upright of the elbow to go at the foot of the bed should be long enough to rest on the floor, or any convenient part of the bedstead, and project about two feet above the level of the mattress—the horizontal piece long enough to reach nearly to the knee; pine $\frac{3}{4}$ by 2 inches is heavy enough. The angle made by these pieces is braced, and a strap of hoop-iron outside makes it very strong. In the horizontal piece two slots are cut wide enough to allow the iron pulleys to pass through, and of sufficient length to allow the patient to draw himself


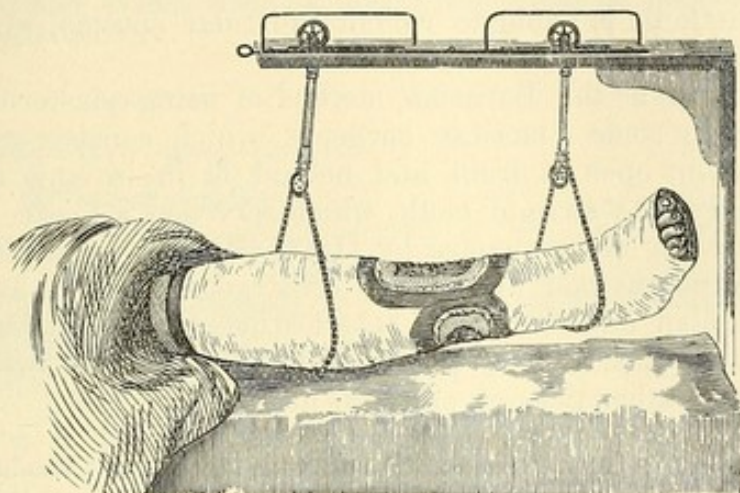
up and down in bed. A $\frac{1}{8}$ inch iron wire passes the whole length of this piece above the slots, steadied by small staples, so that it may be withdrawn. On this the upper pulleys run. The wire shields  above these slots are to prevent the bedclothes from resting upon the rollers.

FIG. 309.

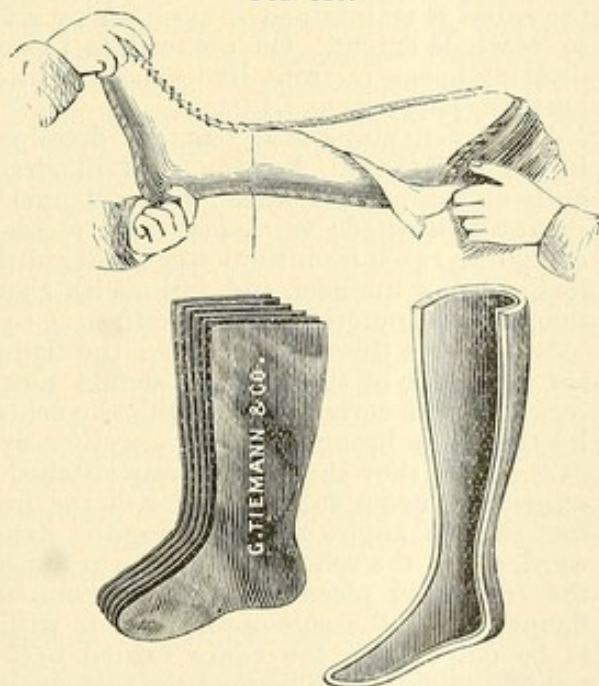


Van Wagenen's suspension apparatus.

"The pulleys or wheels are fastened in the rubber tubes by making a few turns of copper wire around the iron screw of the pulley. This is pushed into the tube and bound outside with fine wire.

"Rings of rope large enough to pass over the foot are then put through the lower pulleys. If these rings open, or the foot is slipped out of them, the leg is taken down without any of the apparatus about it, and the large wire may be withdrawn and the leg lowered, with the pulleys and rings still attached."¹

FIG. 310.



G. Wackerhagen's method.

There are a few cases in which a very much better position of the fragments can be secured by placing the patient under the influence of an

¹ Van Wagenen, Med. Record, April 1, 1873.

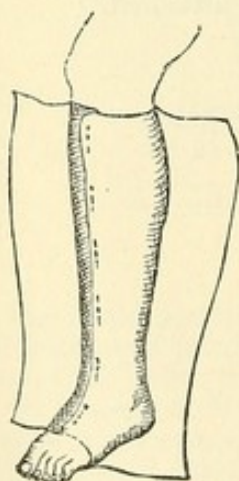
anæsthetic, and by applying the dressings during complete anæsthesia. But the surgeon needs to be warned of two things in this connection: First, that just as much harm can be done to the soft parts by violent wrenching and pushing when the patient is insensible as when he is fully conscious; second, that while the patient is passing under the influence of an anæsthetic he is liable to violent muscular spasms, which may do serious injury.

What is known as the Bavarian method of using plaster-of-Paris has been adopted by some American surgeons, which consists essentially in leaving the splint open in front and behind, or in leaving it connected posteriorly only by a strip of cloth, which serves as a hinge. This plan has been especially recommended by Dr. G. Wackerhagen, of Brooklyn, N. Y. By this method all danger of strangulation is avoided. As between this plan and the use of sole leather, which can be made to fit as accurately, or nearly so, as plaster-of-Paris, it is, therefore, a question of convenience rather than of practical utility.

[The Bavarian splint or some modification of it is one of the best as well as simplest dressings for fractures of the leg. In its simplest form this splint consists of two pieces of heavy flannel cut to fit the limb, but sufficiently large more than to envelop it; they are now stitched together by a straight seam along the back; then this dressing is placed under the limb and the inner layer is folded evenly around the part and secured by long pins or stitches (Fig. 311); while the leg is held firmly in position mix the plaster-of-Paris with about an equal bulk of water and rapidly apply it, partly by pouring it over the outer

layer of flannel and partly with a spoon; now quickly bring the two portions of the outer layer over the limb so as to meet, and smooth them with the hands so as to remove the inequalities in the distribution of the plaster before it hardens; the edges are to be trimmed and the pins removed; the splint is maintained in position by a firm roller applied to its whole extent. On removal, to examine the limb, the dressing opens in front like a book, while the seam at the posterior part acts as a hinge.

Mr. Bryant states that a similar dressing is in general use in Guy's Hospital, London, and illustrates its application quite elaborately. Coarse "house-flannel" which has been shrunk is selected; two equal-sized pieces are first cut long enough to reach from the lower border of the patella to three inches below the heel, and in breadth about six inches more than the circumference of the calf, so as to allow the edges to overlap about three inches when the flannel is folded round the leg. One of these pieces should now be applied to the leg, its centre corresponding with the centre of the calf, and its two flaps brought tightly together over the skin (Fig. 312), where they should be firmly stitched together from the upper part down to the hollow of the instep; holding the foot at right angles and dragging the flannel tightly downward, stitch the sole from the toes to the heel; finally stitch the remaining piece along the dorsum of the foot. The flannel along the sole of the foot to within an inch of the

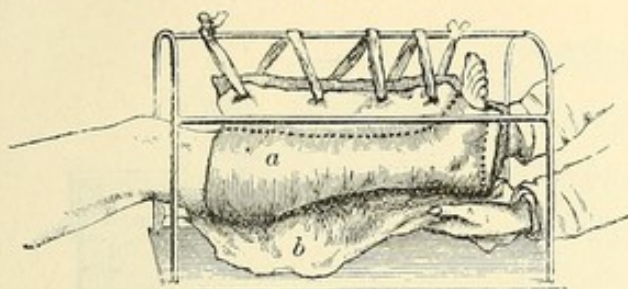


The Bavarian splint; the first piece of flannel applied and the second ready for the plaster.

stitches should next be cut off and the edges turned back; the superfluous flannel along the front of the leg and dorsum of the foot should be used to sling the leg in the cradle. The next step is to apply to the flannel a paste made of precipitated chalk and mucilage of gum acacia, stirred to the consistence of honey (or plaster-of-Paris); use the hand or a brush so as to spread it evenly and make it enter all the inequalities of the flannel. Now apply the outer layer of flannel, placing it just as the first was placed, with its centre corre-

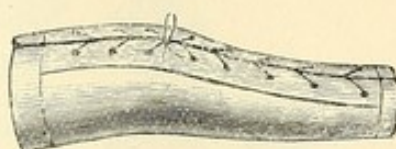
sponding with the median line of the calf, folding its edges around the leg and bringing them up together in front over the edges of the previous layer, and retaining it by stitches at intervals down the leg close to the skin. When the dressing is dry the limb is removed from the cradle, and the splint removed from the leg and dorsum of the foot by cutting up the stitches along the front, and then forcibly separating the edges of the flannel. The edges of the splint may then be bound, eyelets made for tape, when it may be reapplied and laced firmly in its position.

FIG. 312.



Bryant's dressing; *a*, first layer of flannel applied to the limb; *b*, second layer about to be applied.

FIG. 313.



Bavarian splint completed.

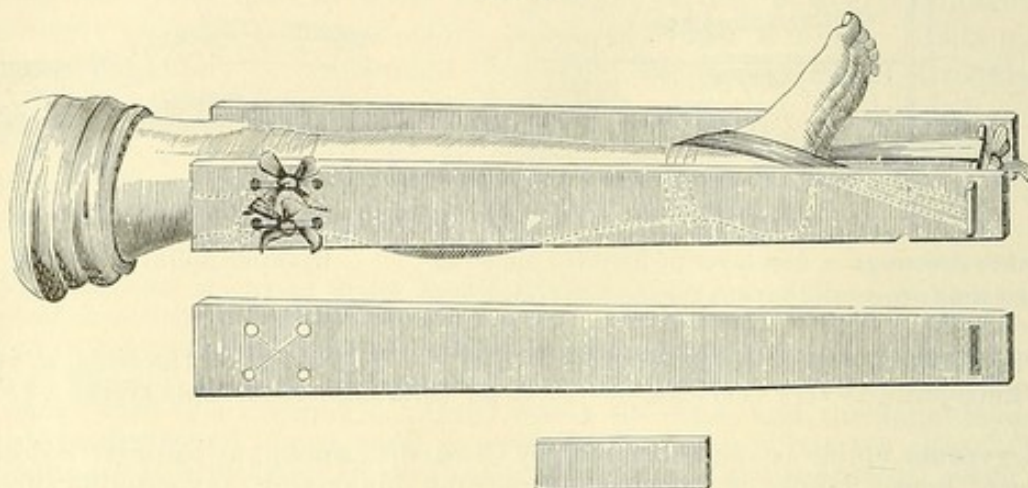
This form of splint applied in fractures of the upper part of the tibia, or into the knee-joint, is very serviceable. It is an immobile removable splint. (Fig. 313.)

A gypsum splint is recommended by Croft, of London, as follows: Select a piece of house flannel, or an old, thin, shrunk blanket, or any suitable substitute; shape the pieces by measurement, taking the circumference of the limb below the knee, at the biggest part of the calf, just above the ankle-joint, from the front of the ankle-joint round the heel to the front again, and at the middle of the metatarsus; the flannel of each splint should be in width half an inch less than half the circumference at any of those points; the width of the two splints should be one inch less than the circumference of the limb at any corresponding part, and long enough to extend from the tubercle of the tibia to the middle of the metatarsus; four pieces are required, two for each splint; prepare two bandages of common muslin each five to six yards long and two inches and a half in width; mix about a handful of good dry plaster with water to the consistence of thick cream; lay the inside pieces of flannel on the table or bed, the outer surface being upward; soak the outside pieces in the plaster separately and lay them out on their respective inside pieces. Whilst traction is kept up, and the ends of the broken bones are maintained in apposition, the splints are to be applied and smoothed; then the bandage is to be put on; traction is to be maintained during the hardening of the plaster; then the limb should be laid on a large soft pillow, the toes directed upward and the knee a little bent. Great caution should be taken that the bandage is not drawn tightly anywhere, and that no one turn is tighter than another. The two splints should not meet each other by about half an inch in front or behind, the intervals being spanned by the dry, porous muslin. At the sides the bandage is fixed to the splints by the plaster which oozes into it from the outer layer of flannel. When it becomes necessary to inspect the limb the bandage can be split up along the middle line in front, and the dressing opens as it is hinged by the muslin bandage which spans the interval behind.]

In such few cases as demand or warrant a resort to permanent extension and counter-extension, a double inclined plane furnishes a convenient mode for its accomplishment; but it is only occasionally that, in fractures of the leg, permanent extension and counter-extension can be employed; an assertion which, however much it may surprise the inexperienced, observation will prove to be true. If the fracture is near

the middle of the leg, quite remote from the points upon which the appliances for extension, etc., are to be made fast, and the inflammation is moderate, something may be done in this way; but when the point of fracture approaches the ankle-joint, as it actually does in a great majority of cases, a gaiter, made of any material whatever, if it has sufficient firmness to overcome completely the action of the muscles, will inevitably cause congestion and swelling, accompanied sooner or later with great pain and with ulcerations, and simply because the extension is made

FIG. 314.

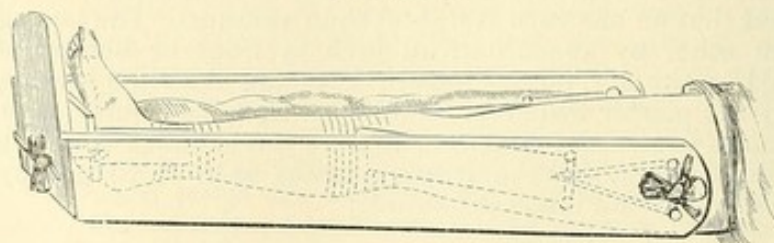


James Hutchinson's splint, for extension, etc., in fractures of the leg. (From Gibson)

directly upon parts already tender and inflamed from the accident itself; and when we add to this complete and violent ligation of the limb near the seat of fracture, a similar ligation of the limb just below the knee, for the purpose of making counter-extension, we are prepared to understand how the worst consequences may ensue.

Neill, of Philadelphia, and others have sought to overcome some of the difficulties in the way of making extension in fractures of the legs, by substituting adhesive plaster for the usual extending or counter-extending bands. Says Dr. Neill: "For simple fractures of both bones of the leg, attended with shortening and deformity not easily overcome, the limb should be placed in a long fracture-box with sides extending as high as the middle of the thigh, and a

FIG. 315.



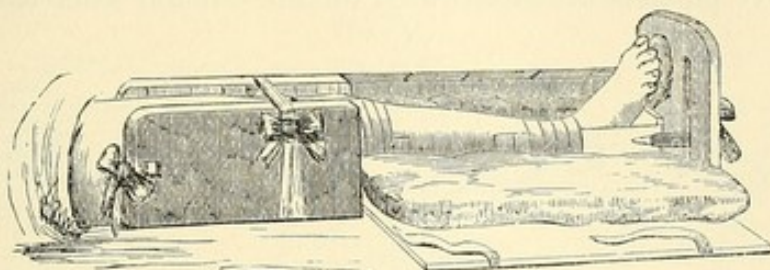
John Neill's apparatus for fractures of the leg requiring extension and counter-extension.

Pillow should be used for compresses. The counter-extension is made by strips of adhesive plaster, one inch and a half in breadth, secured on each side of the leg below the knee, and above the seat of fracture by narrower strips of plaster applied circularly. The end of the counter-extending strips may then be

secured to holes in the upper end of the sides of the fracture-box, by which the *line of the counter-extension is rendered nearly parallel with the limb*. The extension is also to be made by adhesive strips, in a mode which is now well known and understood. The ends of the extending bands may be fastened to the foot-board of the box."¹

Dr. Neill further remarks: "In compound fractures of the leg, shortening and deformity are often difficult to overcome, as is well known to experienced

FIG. 316.

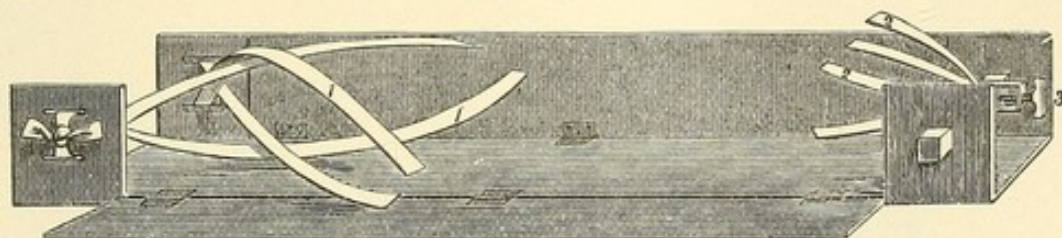


John Neill's apparatus for compound fractures of the leg.

surgeons. In such cases we may wish to dress the wounded soft parts, and, at the same time, maintain a certain amount of extension and counter-extension. This can be readily accomplished by having the sides of the fracture-box sawed in two parts at the knee, so that the sides of the box above the knee, from the upper end of which the counter-extension is made, need not be disturbed during the dressing, while that portion of the side of the box corresponding to the leg may be opened at pleasure without diminishing the tension of the extending or counter-extending bands."

In compound fractures of the leg, Dr. Gilbert recommends a modification of the common fracture-box. In this apparatus the foot-board is omitted, and a block for the reception of the frame of the tourniquet is substituted. Each side of the box consists of three separate segments. Of these the upper and lower are permanently screwed to the bottom board, and the central one is attached by hinges. By this arrangement there is full access to the wound, which may be

FIG. 317.



Gilbert's box for compound fracture of the leg.

1. The four counter-extending adhesive strips, as if encircling the knee and upper part of leg. 2. The two extending adhesive strips crossing at the bottom of the foot, ready to be applied to the foot. 3. Tourniquet.

dressed from day to day without disturbing the extension and counter-extension maintained by the permanently attached upper and lower segments.

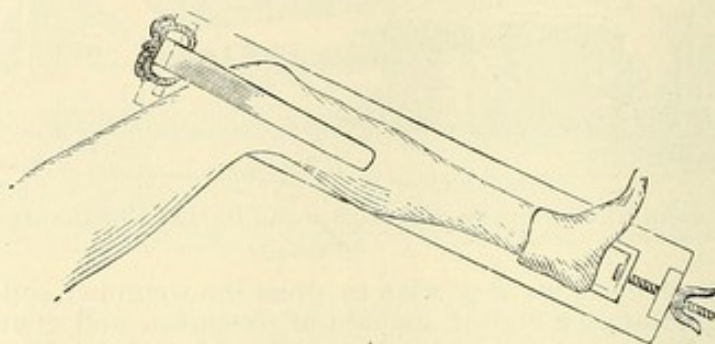
The following woodcuts are intended to illustrate an apparatus invented by R. O. Crandall, for the purpose of making permanent extension. The extension is represented as being made by a gaiter, but Dr. Crandall leaves it to the choice of the surgeon whether he shall employ the gaiter or adhesive strips.²

¹ Philadelphia Med. Exam., vol. xi. p. 580, 1855.

² Crandall, Phil. Med. Journ., vol. iv. p. 193, Jan. 1856; also Transac. of Med. Assoc. of Southern and Central New York, 1855, pp. 81, 82.

Without intending to deny to these contrivances for permanent extension much ingenuity and some little practical value, I am far from conceding that they will be found capable of overcoming the action of the muscles where the ends of the fragments do not support each other. Their mode of action is such that they can scarcely do more than to steady the limb, and if they operate upon the fragments at all in the direction of their axes, it must be only in the most inconsiderable degree. The adhesive plasters are substituted for the circular knee-bands and the

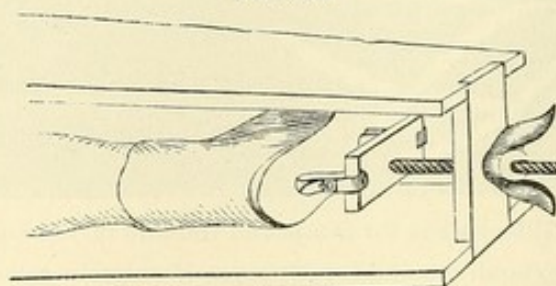
FIG. 318.



Section of Crandall's apparatus, applied to the limb; showing adhesive plaster, counter-extending bands, and gaiter for extension, etc.

gaiters, with a view to avoid ligation; but in order to do this they must not encircle the limb, but only be laid parallel to its long axis. The leg of an adult, or that portion to which the adhesive plasters can be applied, supposing the fracture to be exactly at the centre, may be sixteen inches, that is, eight inches for extension and eight for counter-extension; but when we employ the same means for extension in fractures of the thigh, we find it necessary to apply the strips over the whole of these sixteen inches, the entire length of the leg, or they will not hold. It will be

FIG. 319.

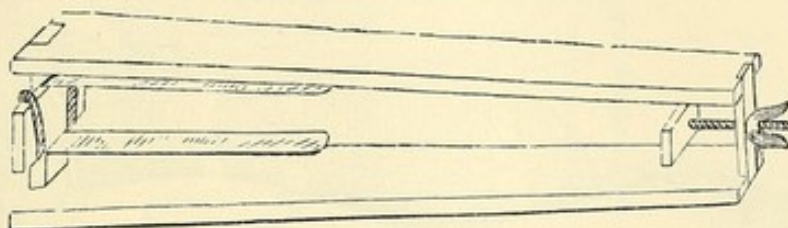


Crandall's apparatus complete. The counter-extending straps are passed over a block of wood, supported above the knee, to prevent their pressure upon the sides of the knee.

apparent also that we cannot use even the eight inches which we have, for the purpose of argument, allowed these gentlemen in fractures of the leg. There must be at least a space of eight inches between the ends of the two opposing strips in order that they may operate at all upon the fragments; indeed, I do not believe that even then their influence would reach beyond the skin to which they were directly applied; but if a space of eight inches is left, only four remain for the strips at either end; and this is an amount of surface wholly insufficient for our purpose.

What, then, shall we do when the fracture is near one of the extremities of the bone? These gentlemen seem to have forgotten, moreover, that the whole leg is tender, and that the skin easily vesicates. In short, they have not seen the many points of difference between the application of these means in fractures of the thigh and leg, and which, while they allow us to accomplish all that we could desire with the one, are of little

FIG. 320.

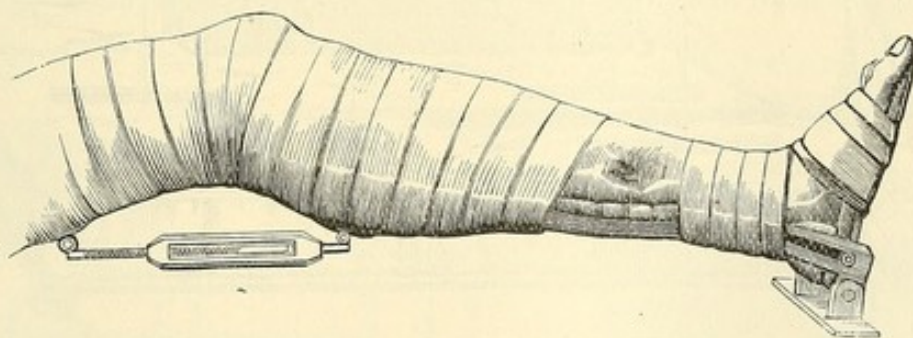


Posterior view of the lower portion of Crandall's apparatus.

or no use in the other. We shall then always come to the same conclusion: whatever means we may employ to make permanent extension in fractures of the leg, we must either fail to accomplish all that we desire, or incur the hazards incident to complete and firm ligation of the limb; and if the preference is given to any form of apparatus to accomplish these ends, it must be to some form of the double-inclined plane, by which we may at least avoid ligation in the upper part of the limb, the counter-extension being made against the under surface of the thigh, while it is resting upon the thigh-piece; or to one of the long straight thigh-splints, which will enable us to make the counter-extension from the thigh and perineum.

If a double inclined plane is used, I prefer either a plain apparatus, such as we have already described as in use for fractures of the thigh,

FIG. 321.



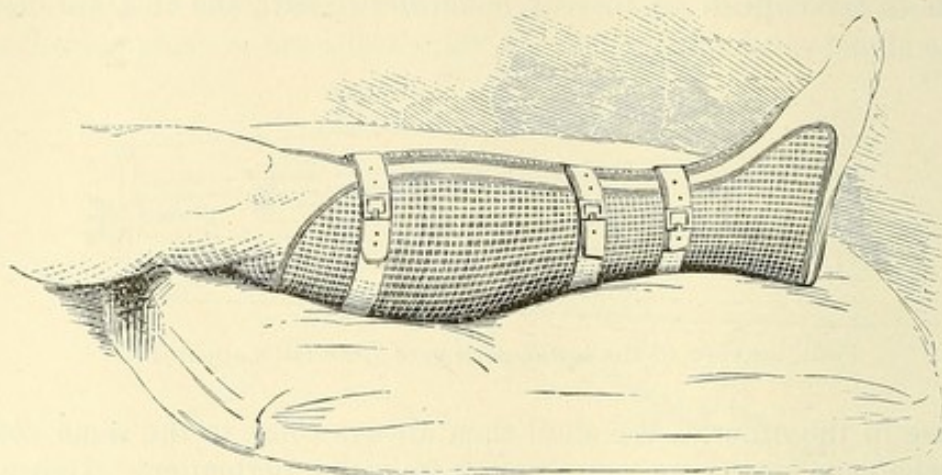
Liston's double inclined plane, applied to the leg in case of compound fracture.
(From Miller.)

constructed of boards, joined together by hinges opposite the knee, and with an upright foot-board, upon which a carefully-arranged and thick cushion has been placed; or the more elegant double inclined plane of Liston.

In using Liston's apparatus, it must not be inferred that the knee is always to be bent. The apparatus is designed to be used occasionally

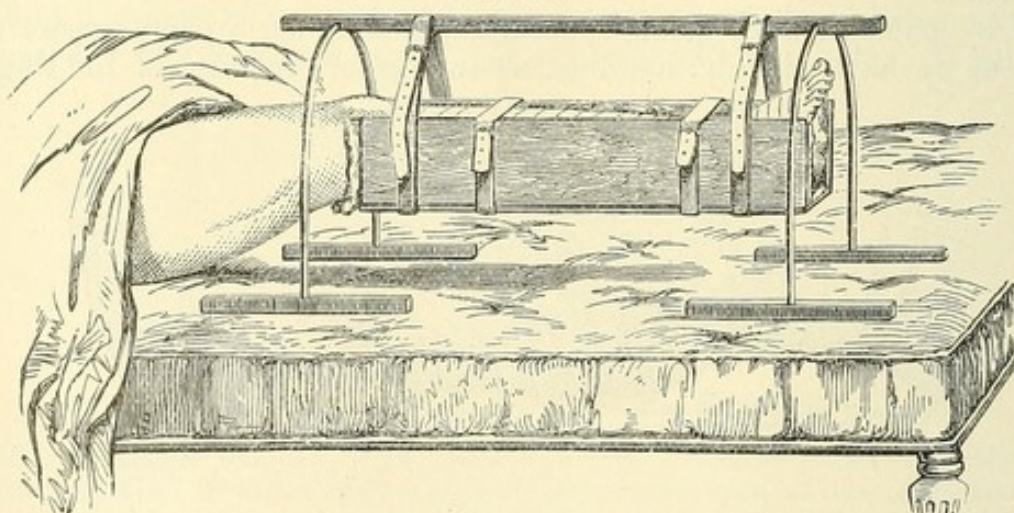
as a straight splint; and there will be found many cases of fractures of the legs in which the straight position will be most suitable: this is especially true of such fractures as, occurring just below the knee-joint, have

FIG. 322.

Louis Bauer's wire splints for the leg.¹

the line of fracture directed obliquely downward and forward. But there are many compound fractures which demand the same extended position; and in nearly all cases where this form of apparatus is used as a double inclined plane, the lower end of the splint should be elevated so that the heel shall not be much below the level of the knee.

FIG. 323.



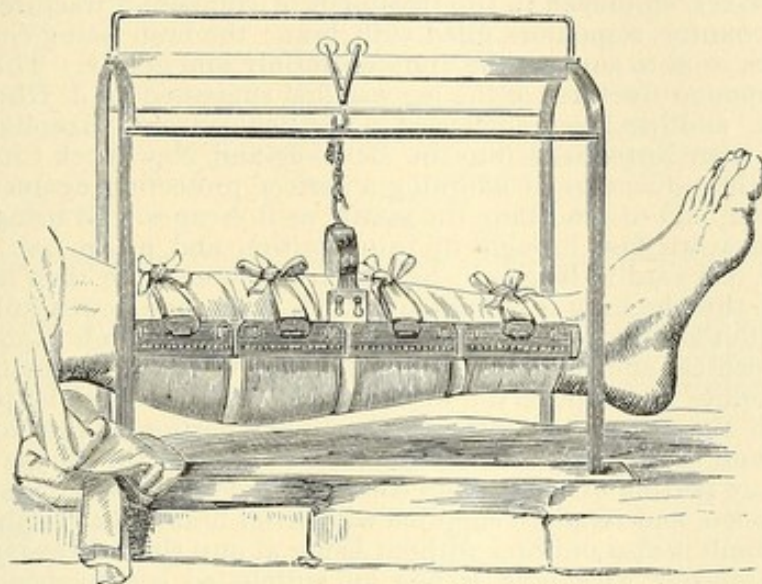
Swing box or "eradle." (From Skey.)

Bauer's wire splints, used also for side-splints, when they are formed to fit the limb accurately, possess some advantages which must recommend them to the attention of surgeons; but neither these splints nor any other, however accurately fitted, ought to be applied directly to the naked skin. They require always the interposition of a well-padded lining.

¹ Bauer, Buffalo Medical Journal, April, 1857, vol. xii.

Boxes are rarely useful except in certain compound fractures. They are heavy and awkward machines, which prevent the patient from moving readily in bed; or which, being fixed, if he does move, allow the upper fragment only to descend, or to move upon the lower as a fixed point.

FIG. 324.

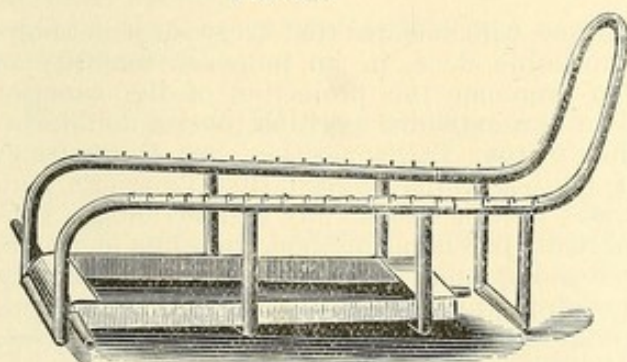


Salter's cradle. (From Fergusson.)

If used at all, they ought generally to be suspended, or made to move on a suspended railway. But however they are arranged, the limb is a great part of the time concealed from sight, and the surgeon is prevented from making use of such means to rectify deviations in the line of the bone as he would probably have otherwise employed.


The swing invented by James Salter, of London, is constructed so as to allow not only a lateral motion, but also a more complete motion in the direction of the axis of the limb, by which the danger of pushing the fragments upon each

FIG. 325.



John W. Trader's suspension apparatus for compound fractures.

FIG. 326.



Fracture-box, with movable sides.

other is obviated. This is accomplished by the rolling of two pulley-wheels upon a horizontal bar. The case in which the leg rests may be made of metal or of wood, and the frame of iron, for the sake of lightness and strength.

Dr. Hodgen, of St. Louis, suspends the box over a pulley placed transversely, so that by drawing the rope to the right or to the left, the box may be turned

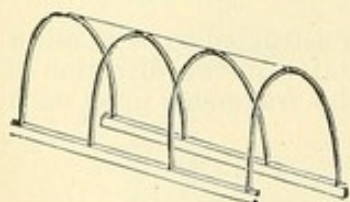
upon either side. The suspension apparatus devised by Trader, of Sedalia, Mo. for the treatment of compound fractures of the leg, when it is desired to employ irrigation, I have found very useful in my wards at Bellevue. The limb is suspended by transverse strips of cloth, over a tray, from which the water is conducted by nozzles. I have found it convenient to attach India-rubber tubing to these nozzles, through which the water may be conveyed to a pail placed beside the bed. We have used it satisfactorily, also, for other cases than fractures.

Fracture-boxes, employed in the treatment of compound fractures of the leg, are, in this country, sometimes filled with bran; the bran being closely packed upon all sides so as to support the limb uniformly and gently. This method of treating compound fractures of the leg was first suggested by J. Rhea Barton, of Philadelphia,¹ and has been much used in the Pennsylvania Hospital; and more lately it has been introduced into the Bellevue and New York City Hospitals. It possesses the advantage of affording a perfect protection against flies in the summer season, and of absorbing the matter as it escapes. In using the "bran-box," the sides are first brought up into position and made fast. A piece of muslin cloth, one yard in length by half a yard in breadth, is then laid upon the box, and into this the bran is poured, until it is about one-fourth full. The bran is then distributed so as to fit the back of the leg, and the limb is placed in position. After which, additional bran is packed on either side of the limb, until it is nearly or quite enveloped; the wounds being first covered by pieces of lint smeared with simple cerate. Finally, the upper portion of the muslin sack is fastened around the limb just above the knee, to prevent the escape of the bran. Whenever any portion of it becomes soiled by blood or pus, it may be dipped out with a spoon, and its place supplied with fresh bran. The support which it gives to the limb is also uniform without being at any time excessive.

[The fracture-box with bran is now an antiquated contrivance designed to meet conditions of suppuration which do not exist in the practice of any competent surgeon. It is occasionally employed, however, but its presence indicates ignorance of the principles which now govern in the treatment of open wounds.]

In whatever position the leg is placed, and with many of the forms of apparatus enumerated, it will be found necessary to protect the limb from

FIG. 327.



Wire rack for fracture of leg.

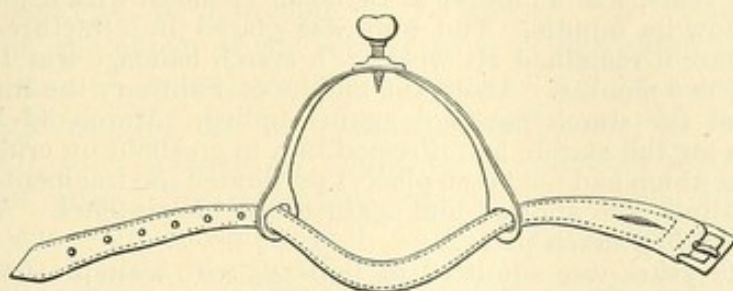
the weight of the bedclothes by some contrivance similar to that figured in the accompanying drawing; or by a rack, such as is represented for suspending the leg when leather splints or the immovable apparatus is employed.

Malgaigne, who declares that every surgeon knows how impossible it is, in an immense majority of cases, to overcome the projection of the superior fragment when the limb is placed in the extended position (over a double inclined plane), and who affirms that neither Pott's position, nor Dupuytren's modification of it, will do much if any better, nor, indeed, that Laugier's plan of cutting the tendo Achillis possesses in this respect any real advantage, concludes at last to resort to a new and really ingenious method, the value of which, also, he claims to have already fully demonstrated. His apparatus consists simply of a steel band of sufficient size to encircle three-fourths of the limb, at the two extremities of which are two horizontal mortises through which a band is passed, and which may be buckled upon itself behind. The centre of the metallic arch, in front, is penetrated with a firm metallic screw, terminating in a very sharp point, and which is moved by a flat thumb-piece. The limb being laid over a double inclined plane, and the pads being carefully adjusted, as we have already directed when speaking of other forms of apparatus, and the limb properly extended, the apparatus of Malgaigne is placed over the limb, with the sharp point of the screw resting upon the upper fragment, a few lines above the point of

¹ Barton, Amer. Journ. of Med. Sci., vol. xvi. p. 31, and vol. xix. p. 515.

fracture; and at the same moment that this point is pressed firmly down to the bone, the fragments being held together by an assistant, the strap is buckled as tightly as possible under the splint. A few turns of the screw will now make

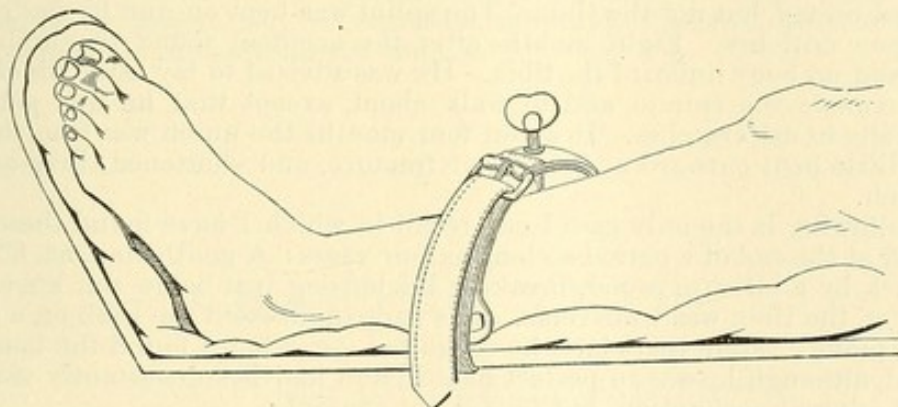
FIG. 328.



Malgaigne's apparatus for oblique fractures of the leg. (From Malgaigne.)

its point penetrate more deeply into the bone, and insure the most complete apposition of the broken extremities. "This is accomplished," says Malgaigne, "with very little pain to the patient;" and, as will be seen, the steel arch effect-

FIG. 329.



Malgaigne's apparatus applied. (From Malgaigne.)

ually prevents any ligation of the limb. I cannot say the plan receives my unqualified approval; yet I have employed it to advantage in some cases of old ununited fractures.

[In obstinate cases of overriding the surgeon is justified in wiring the bones antiseptically.]

Treatment of Delayed or Non-union.—It has already been remarked that pretty frequently in this fracture union is delayed considerably beyond the usual period of six or eight weeks, but that in a large majority of these cases of delayed union consolidation is finally accomplished without any surgical operation. This is most often effected by permitting the patient to rise and go about on crutches, the fragments being supported by some light but firm splint, which will permit also the limb to be opened daily and washed or rubbed gently, so as to restore its circulation. In some few cases, after the lapse of several months, if this method has not succeeded, the bones have been known to unite firmly in a year or two, without side-splints, and even when the patient has been bearing his weight upon the limb. But such a result is rare, and is scarcely to be expected. If, indeed, the union is not effected within four or five months with the splints and crutches, it is better to resort at once

to perforation between the fragments, as has been directed in the general chapter on Delayed or Non-union of the Bones. A few illustrative examples will serve, perhaps, to enforce these statements.

J. C., æt. 28 years, was admitted to Bellevue Hospital with a simple fracture of the leg below its middle. The limb was placed in a fracture-box, but not suspended, where it remained six weeks. A starch bandage was then applied, and continued two months. About the middle of February the fragments were perforated, and the starch bandage again applied. March 3d I substituted leather splints for the starch, and directed him to go about on crutches. April 2d, finding that union had not taken place, I perforated the fragments thoroughly, applied the splints, and allowed him again to use his crutches. A few months later bony union had taken place.

M. W., æt. 28 years, was admitted to Bellevue with a simple fracture of the leg near the upper end of the lower third. Within one week it was inclosed in a plaster-of-Paris dressing. At five weeks there was no union. The plaster splint was renewed, and she was allowed to go about on crutches. No bony union at ten weeks. Splints and bandages were then removed, and she continued to walk with crutches, and in one month the union was firm.

C. H., æt. 36 years, had his left leg broken—fracture comminuted. A surgeon placed the limb in a "bran box" until the swelling had subsided, and then applied a plaster-of-Paris dressing, which was removed in four weeks. The fibula had united, but not the tibia. The splint was kept on, and he was allowed to go upon crutches. Eight months after the accident found the limb much wasted, and no bony union of the tibia. He was advised to lay aside his crutches and to remove the splints, and to walk about, except that he was permitted occasionally to use crutches. In about four months the union was firm, the limb being a little bent outward at the seat of fracture, and shortened three-quarters of an inch.

The following is the only case I can recall in which I have found these bones ununited at the end of a period so long as four years: A gentleman, æt. 33 years, was struck by a billet of wood, breaking his left leg just below the knee. The fracture of the tibia was transverse. His surgeon dressed the limb on a double inclined plane. Four years later he consulted me, when I found the bones still ununited, although he was in perfect health, and had been constantly using the limb. I advised perforation, but he did not consent.

In Dr. Muhlenberg's tables of delayed union and ununited fractures, in a total of 94 examples involving both bones, 71 were finally cured, 3 were relieved, 19 failed, and 1 died. It might be more proper to say 71 were cured, and 23 failed. Of these, 10 were cured by friction, 26 by mechanical appliances and immobilization, 4 by seton, 20 by resection, and 10 by drilling. 1 died after resection.¹

Resection and Refracture of Crooked Legs.—In some cases of extreme deformity of the legs consequent upon badly united fractures, *resection* of the bones has been practised with more or less success.

Gurlt,² in a record of 25 resections for badly-united fractures of these bones, reports 19 as cured, 2 deaths, 1 amputation, and 2 failures.

More often cases are presented of badly-united fractures of the leg, which seem to justify a resort to *refracture*; and, while this procedure is attended with little or no danger to life, after neither resection nor refracture can we always make sure of a reunion. If, moreover, the surgeon expects, by a refracture, to lengthen a limb much, where it is merely overlapped and shortened, he is, I am certain, destined to disappointment, at least in all cases where sufficient time has elapsed for the bones to have become firmly united. I have myself several times

¹ Muhlenberg, Agnew's Surg., vol. i. p. 866.

² Poinso, op. cit., p. 692.

refractured bones; and I have several times met with cases of old fractures newly broken; and I have constantly observed that I could never, in the end, make them but very little if any longer than they were before the refracture. The muscles had contracted and shortened, and their contraction could not be overcome.

If, however, the object of the refracture is to straighten the limb, then no doubt it may be sometimes accomplished; and in some degree also by the straightening of the limb the shortening may be overcome; but in my opinion, such procedures ought to be reserved for extraordinary circumstances, unless the refracture can be made soon after the union has taken place. In those cases in which I have refractured the tibia and fibula after a recent union, the bones have reunited promptly.

In the case of a limb that had been broken eight weeks, and was quite crooked, but was not very firmly united, Dr. Horner, having refractured it, was able at once to restore it to a nearly straight line.¹

T. B. J. had his right leg broken near its middle. Ten years after the first accident he was thrown from a horse, and it was refractured at the same point, after which the tibia refused to unite. Six months later I advised perforation at the seat of fracture. Dr. Pancoast, of Philadelphia, subsequently brought about union by perforation, but extensive suppuration ensued, and the cure was not accomplished in less than six months.

CHAPTER XXXIV.

FRACTURES OF THE TARSAL BONES.

Causes.—The astragalus is generally broken by a fall from a height, the patient having struck upon the bottom of the foot. Monahan, in an analysis of ten cases, found it had been broken by a fall upon the foot nine times,² and only once by a crushing accident.

Shepherd,³ of Montreal, has called attention to a fracture of the "little process of the astragalus external to the groove for the tendon of the flexor longus hallucis muscle," to which is attached the posterior fasciculus of the external lateral ligament of the ankle-joint. He has met with four examples in the dissecting-room; all of them without a history. The first was a man about 25 years old; right foot; and it had united to the main portion by fibrous tissue. The second was also in a young man; right foot; with neither fibrous nor bony union. It remained attached to the posterior fasciculus of the external lateral ligament, but it was displaced slightly outward, and was quite movable. In the third case the process had been broken off; right leg; and it had become reunited by bone. The fourth case was found in a woman aged about 69, whose bones had undergone fatty degeneration. The fragment had united by fibrous tissue. Dr. Shepherd was unable to produce this lesion upon the cadaver; but he calls attention

¹ Horner, New York Journ. Med., May, 1851, p. 432.

² Fracture of the Astragalus, with Analysis of the Recorded Cases of this Injury. An inaugural thesis presented to the faculty of the Buffalo Med. Coll., March, 1858, by Bernard Monahan, M.D.

³ Shepherd, Journ. Anat. and Physiology, vol. xvi. p. 79.

to the fact that this process is much more prominent in some persons than in others; and furthermore, since in none of these cases was there a noticeable deformity of the foot, it would naturally be overlooked, or be regarded as a mere sprain.

The calcaneum is also occasionally broken by violent lateral pressure, but much more often by a fall upon the foot, or rather upon the heel.

Abel,¹ of Stettin, has called attention to a fracture of the little apophysis of the calcaneum (lesser process, or sustentaculum tali; the tubercle situated above the groove for the tendon of the peroneus longus, and called by Henle the "trochlear apophysis"), the apophysis being broken by a fall upon the foot when in the position of varus. Bidder² has seen the same lesion, caused in the same manner, in a man 39 years old, and which he ascribed to the action of the peroneo-calcanean ligament (middle fasciculus of the external lateral ligament). After the lesion the foot becomes everted, and flattened as in valgus, and the length of the heel is apparently shortened by a slight displacement of the calcaneum forward.

In some instances both heel-bones have been broken at the same moment.

Malgaigne has collected eight cases of fracture of this bone by muscular action, as in jumping upon the toes, the posterior portion of the bone being thus violently acted upon by the tendo Achillis. South has mentioned two other cases. One received the injury by jumping off a stage-coach. The fragment was found to be drawn upward slightly, but not so far as to prevent crepitus when the muscles on the back of the leg were relaxed. The other is a cabinet specimen contained in the museum of St. Bartholomew's Hospital. The fracture had taken place just below the attachment of the tendo Achillis, but the upper fragment was not displaced.³ Mr. Cooper mentions two other cases, both produced by violent efforts on the part of the patients to sustain themselves when falling. In one of these the fragment was immediately drawn up three inches.⁴ Burggraëve,⁵ Coote,⁶ Anningson,⁷ and Poinot⁸ have met with the same accident from a similar cause.

The other bones of the tarsus are generally broken by crushing accidents, such as the fall of heavy weights upon them, by the passage of loaded vehicles, etc.

Pathology.—The astragalus often, indeed generally, escapes without injury in those crushing accidents which break many or most of the other bones of the foot, and, as we have seen, it is seldom broken except when the patient has fallen upon the bottom of his foot; but at the same moment, the foot being turned forcibly out or in, a dislocation of the tibia takes place, and the fibula is broken. In nine of the cases collected by Monahan, one or the other of these forms of dislocation had occurred, in eight of which the dislocation was compound. The direction of the fracture is found to vary greatly; thus, it has been found broken in its length antero-posteriorly, in its breadth or transversely, and in one instance it has been divided nearly horizontally, so as to separate the upper

¹ Abel, Arch. für klin. Chir., 1878, Bd. xxii. Hft. 2.

² Bidder, Cent. für Chir., 1881, p. 733 (Poinot).

³ South, Notes to Chelius's Surgery, p. 639, Amer. ed.

⁴ B. Cooper's ed. of Sir Astley, Amer. ed., p. 311.

⁵ Burggraëve, Bull. Acad. Roy. de Méd. de Belgique, t. vi. p. 886, 1863.

⁶ Coote, *Thetanest*, 1867, t. i. p. 270 (Poinot).

⁷ Anningson, Brit. Med. Journ., 1878, vol. i. p. 128.

⁸ Poinot, op. cit., p. 695.

face completely from the lower. Sometimes it suffers a species of impaction, the fragments being actually driven into each other; at other times, as in one case related by Amesbury, the bone may be split without the occurrence of any displacement.

The calcaneum also may be broken in any direction, and it is equally with the astragalus liable to impaction, by which its vertical diameter is sensibly diminished, while its transverse diameter is increased. If the fracture is a consequence of muscular action, the line of fracture is always posterior to the astragalus, and in some cases only that portion is broken off to which the tendo-Achillis has its attachment. It may be broken also vertically, directly underneath the astragalus, in which case the lateral and interosseous ligaments will prevent anything more than a slight displacement of the posterior fragment. When the fracture takes place posterior to the lateral ligaments, the detached fragment is liable to be drawn very far from the body of the bone, even to the extent of four or five inches, and possibly farther when the leg is extended upon the thigh and the foot flexed upon the leg.

Constance relates a case in which the tuberosity, having been broken off by a direct blow, was drawn up five inches.¹

Fractures of the calcaneum produced by contraction of the sural muscles are generally simple, but those which result from a crushing of the bone are more often compound. The same remark is applicable also to the other bones of the tarsus, the fractures of which, being only produced by direct blows, are generally complicated with external wounds.

Symptoms.—All fractures of the bones of the tarsus demand especial care in their diagnosis, since only a few of the usual signs of fracture are in a majority of the cases presented. The explanation of this fact will be found in the number, size, and strength of the bones of the tarsus, and in their close and firm union by ligaments, by which they give to each other a mutual support, so that the fracture of a single bone does not necessarily or usually result in displacement or deformity, and even crepitus is with difficulty detected; and when we consider, moreover, that the fracture is generally produced by great violence, directly applied, in consequence of which the foot in most cases becomes rapidly and enormously swollen, we shall understand the true nature of the difficulties which are usually presented in the way of an accurate diagnosis. Of all the usual signs of fracture, crepitus alone is pretty generally present, but even this often fails to tell us which bone is broken, and still more often does it fail to inform us as to the direction and extent of the bony lesions. If the whole or a portion of the tuberosity of the calcaneum is separated by the action of the muscles, and the fragment is drawn upward, it may be discovered in its new position, and the heel will be flattened or shortened, but no crepitus can be felt unless the fragments are again brought in contact.

¹ Constance, Amer. Journ. Med. Sci., vol. v. p. 222, Nov. 1829, from the Midland Med. and Surg. Reporter.

Treatment.—Not any of the fractures of the tarsal bones in themselves demand the use of splints, and it is only when complicated with a dislocation of the ankle and fracture of the fibula that it is proper to employ apparatus of this sort; certainly the exceptions to this rule must be very rare; so that our practice in these cases will be confined chiefly to the prevention and reduction of inflammation. This will be the sum of the treatment demanded during the first few days after the receipt of the injury in probably all cases of simple fracture, and in many cases of compound fracture.

If single bones, or fragments of single bones, are displaced to any considerable extent, and there is an external wound communicating with the fracture, I have no doubt it would be best in all cases to remove at once by dissection the projecting bone, even although it were possible, or perhaps easy, to force it back again to its place, as has been done successfully by Ashhurst, of Philadelphia.¹ The same rule I would apply to examples of fractures uncomplicated with any external wound, if the fragments were very much displaced, and could not by the application of moderate force be replaced, since the bone left to project would prevent the patient from ever wearing a boot with comfort, and would entail as much weakness upon the limb as would be likely to follow from its complete separation. But such cases as I have last supposed are exceedingly rare; indeed, I have never met with a simple fracture of a tarsal bone accompanied by displacement.

Norris has, however, reported a case of fracture of the astragalus accompanied by displacement of about one-half of the bone, but without any lesion of the soft parts. A man, æt. 30, who was admitted into the Pennsylvania Hospital. An hour previous to admission, while descending a ladder, he slipped and fell in such a manner as to throw the entire weight of his body upon the outer part of his left foot. Upon examination, the foot was found to be turned inward and nearly immovable. A slight depression existed immediately below the lower end of the tibia, and there was a considerable hard and rounded projection on the outer part of the foot, a little below and in front of the extremity of the fibula. The skin covering this projection was reddened, but not excoriated. There was no fracture of either bone of the leg. These appearances led Drs. Norris and Barton, under whose care the patient was placed, to regard the accident as a simple luxation of the astragalus forward and outward; and a short time after admission efforts were made to reduce it. "This was done, after relaxing in as great a degree as possible the muscles of the leg, by flexing the knee, and having assistants to keep up extension, by seizing the heel and front part of the foot, at the same time the bone being pushed inward and toward the joint by the surgeon. These efforts were continued for a considerable time, but had no effect in changing the position of the bone. Excision was performed. After removal it was discovered that about one-half of the surface which plays in the lower end of the tibia had been fractured, and remained firmly attached to the extremity of that bone; no attempt was made to extract it. Subsequently that portion of the astragalus which was permitted to remain, having become carious and loosened, was removed also. No healthy action ensued, and the patient soon died."²

Poinsot³ has reported a case in which he practised resection. An insane woman, æt. 40 years, had jumped from a second floor. Poinsot readily recog-

¹ Ashhurst, Amer. Journ. Med. Sci., April, 1862.

² Norris, Amer. Journ. Med. Sci., vol. xx. p. 379.

³ Poinsot, French ed. of this treatise, p. 699.

nized the displacement of a portion of the astragalus of the right foot, which was accompanied with a marked deformity of the foot. There was no external wound. The extreme tension of the skin over the protruding bone determined him to proceed at once to remove the fragment, which was composed of the entire body of the astragalus exclusive of its neck. The fragment was rotated on its axis, so that its articular portion was directed downward and inward, and the broken surface presented toward the skin. The skin retained its relations to the scaphoid. A second fracture had separated by *arrachement* that portion which articulates with the malleolus internus. Both of these latter fragments were removed, the head of the astragalus only being permitted to remain in place. Notwithstanding the utmost care to insure immobility, the indocility of the patient rendered this impossible; inflammation and gangrene ensued, and on the tenth day it became necessary to amputate. Death ensued two days later.

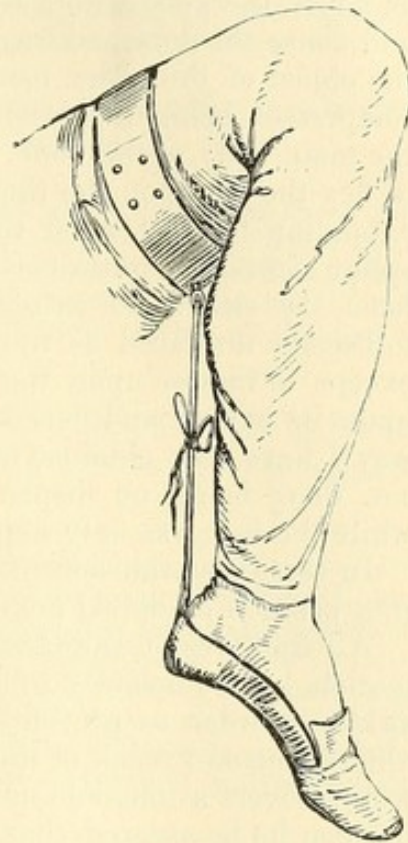
"Mr. Hancock¹ obtained," says Poinso, "a magnificent result in a carpenter, aged 47 years, who presented a fracture of the astragalus 'at its inferior portion,' with displacement forward and outward. There was no wound; but the skin was so stretched on the displaced bone that gangrene was imminent. Mr. Hancock immediately made, by excision, the total extraction of the astragalus. The wound was closed and dressed with lint dipped in a phenic acid solution; the leg was put on a posterior splint with a foot-piece, and suspended in a Salter's crib. Phenic irrigations were made without interruption. When the first dressing was taken off, after eight weeks, the wound was completely filled up. Three months after the operation the patient could lean on the injured foot, and walked easily with a high-heeled boot."

[The former failures of resections in these cases are now no argument against a similar operation performed antiseptically. Hancock's success, with the use of phenic acid, proves the safety of the operation antiseptically performed.]

A fracture of the posterior portion of the calcaneum, especially when it has been produced by muscular action, constitutes one exception to fractures of the tarsal bones generally, and demands usually that apparatus of some kind should be employed in its treatment.

In order to replace the posterior fragment when displaced, or to maintain it in apposition until a bony union is accomplished, it may be necessary to shorten the gastrocnemii by flexing the leg upon the thigh and extending the foot upon the leg. But to retain the limb in this position it will be expedient always to employ apparatus. A very simple contrivance, however, will generally answer all the indications. A bandage, padded strap, or a stuffed collar may be fastened about the thigh just above the knee, and made fast to the heel of a slipper by a tape (Fig. 330). The apparatus is the same which has been recommended for a rupture of the tendo Achillis.

FIG. 330.



Apparatus for fracture of the posterior extremity of the calcaneum.

¹ Hancock, Anat. and Surg. of the Human Foot, London, 1873, p. 251.

In addition to this, the limb ought to be covered from the foot upward as far as the knee with a snug roller, underneath which, on each side of and above the detached fragment, ought to be placed suitable compresses, the object of the roller being to diminish muscular contraction, and the compresses being intended to retain the detached piece in contact with the main body of the bone. Some surgeons have not found it necessary to flex the leg upon the thigh; but they have contented themselves with extending the foot upon the leg, and confining it in this position by a splint of wood or gutta-percha laid along the front of the leg, ankle, and foot. In still other cases, the fragment has shown so little disposition to become displaced as to render no precautions of any kind necessary, except to impose upon the patient complete quiet, with the limb resting upon its outside and flexed, as in Pott's fracture of the fibula. In this way I have once obtained a perfect union; and in the case seen by Poincot, there being no displacement of the fragment, union was effected while the foot was only kept at rest in a pasteboard splint.

In case, also, the sustentaculum tali is torn off, the foot should be kept in a position of dorsal flexion.

All fractures of the tarsal bones demand that as soon as the inflammation has sufficiently subsided, passive motion should be given to the ankle, in order to prevent, as far as possible, the ankylosis which is an almost constant result of these accidents. Indeed, the patient is fortunate who recovers a tolerable use of his foot after the lapse of many months; nor can he be assured that the inflammation will leave these bones and their dense fibrous envelopes for a long period, and that it may not result in caries of more or less of the tarsal bones, demanding finally amputation of the whole foot.

I have not intended to speak in this place of those severer accidents, accompanied with comminution and extensive laceration, which forbid the hope of saving the foot, and for which immediate amputation is the only proper resource, but which constitute, in fact, the great majority of all the fractures of the tarsal bones.

CHAPTER XXXV.

FRACTURES OF THE METATARSAL BONES.

THESE bones can scarcely be broken except by direct blows, and the great majority of their fractures are the results of severe crushing accidents, such as render amputation sooner or later necessary. Of those which do not demand amputation, by far the larger proportion are compound fractures.

A man was run over by a loaded car, crushing his right arm so as to render its immediate amputation necessary. I found also a compound comminuted fracture of the fourth metatarsal bone of the right foot. Considerable hemorrhage occurred from the wound, but this ceased spontaneously. Cool water dressings.

were diligently applied, without splints or bandages, and although some inflammation and suppuration ensued, the parts finally healed over and the fragments united, with only a slight backward displacement at the seat of fracture.

When only one bone is broken, the displacement is usually very trivial; but when several are broken, it may be considerable.

Malgaigne relates an example of this latter accident in which, the three middle bones being broken by the wheel of a carriage, and the integuments being badly torn and bruised, it was found impossible to retain the fragments in place. The patient recovered, and was able to place the foot well to the ground, but the proximal fragments continued to project upward upon the top of the foot to such a degree as to require a special shoe.

In a majority of cases the direction of the displacement is backward (upward), especially when the middle metatarsal bones are the subjects of the fracture.

I have in my cabinet a second metatarsal bone broken obliquely near its middle, with only a very slight displacement of the lower fragment backward; and also the cast of a bone which has united with an enormous backward projection. In one instance I have seen the metatarsal bone of the little toe cut in two with an axe, and the fragments united in about thirty days, but with the lower fragments slightly displaced outward. Delamotte relates a case also in which the first four metatarsal bones were cut off, and complete union was accomplished on the fortieth day; at the end of two months the patient walked without lameness.

Treatment.—If the fragments are not displaced, nothing is required except that the foot shall be kept at rest, and the inflammation controlled by suitable means. In case, however, a displacement exists, it ought to be remedied, if possible, since, if only very slight, it may become the source of a serious annoyance. If the fragments project upward, they interfere with the wearing of a boot, and if they sink toward the sole, the skin beneath is liable to remain constantly tender, and the patient may thus be seriously maimed for life.

In case the displacement is not due to the action of the muscles, but only to the nature and direction of the force producing the fracture, or to entanglement of the broken ends, and it is likely to cause any of the inconveniences which I have mentioned if permitted to remain, it will be advisable at once to employ considerable force in the way of pressure, or to elevate the fragments through an opening previously made upon the dorsum of the foot, calling to our aid even the saw or the bone-cutters, if necessary. After which the fragments may be retained in place by carefully-applied pasteboard splints and compresses.

CHAPTER XXXVI.

FRACTURES OF THE PHALANGES OF THE TOES.

IF fractures of the other bones of the feet are generally of such a character as to require immediate amputation, these fractures demand this extreme resort still more often. Our experience, therefore, in the treatment of fractures of the phalanges of the toes is extremely limited.

Lonsdale observes that it is not uncommon to find great irritation arise after fracture of the great toe; an inflammation extending along the absorbents on the inside of the leg to the groin, causing abscesses to form in different parts of the limb, and producing sometimes great constitutional disturbance. An illustrative case has come under my own observation. The patient, M. McM., æt. 18, several days before received an injury upon the great toe, which contused the flesh severely and broke the first phalanx. He was then suffering from severe pain in the foot and leg, and the absorbents were inflamed quite to the groin. Poultices being applied to the foot and cool lotions to the limb, the inflammation soon subsided, but not until a portion of the toe had sloughed away. Eventually also it became necessary to remove some portion of the phalanx, which had died; after which the wounds healed kindly.

When any of the smaller toes are broken, it will be found easier to support the fragments by a broad and long splint which shall cover the whole sole of the foot and all the toes at the same time, than to attempt to apply a splint to the broken toe alone. If, however, we prefer this latter mode, a thin piece of gutta-percha will be found altogether the most convenient material for the purpose.

If the great toe is broken, its great breadth may prevent any displacement, and a well-moulded gutta-percha splint will generally secure a perfect and rapid union.

CHAPTER XXXVII.

GUNSHOT FRACTURES.

GUNSHOT fractures have already been considered, more or less in detail, in the several portions of this work, wherever it seemed to be necessary to call especial attention to them. This chapter will be devoted, therefore, to a brief *résumé* of my own observations and conclusions in this department.

Causes.—Gunshot fractures are caused by a great variety of missiles, such as musket- and rifle-balls, solid shot and shell, grape, canister, Shrapnel, chain- and bar-shot, fragments of iron, stone, splinters of wood,

etc., etc. The only qualities which these missiles possess in common is, that they are all projected by the elastic power of gunpowder, and generally strike the body with great force; and that they cause fractures by direct violence—seldom, if ever, by counter-stroke. Round, smooth balls frequently impinge upon bones without causing a fracture, for the reason that they are easily deflected; and this happens especially when they are not moving with great velocity. Conical rifle-balls seldom fail to fracture the bones which lie in their direct course; never, perhaps, when, at the moment of contact, the ball is moving with its average velocity. The peculiar destructiveness of this missile is due to its weight, momentum, and form. Canister, grape, Shrapnel, solid shot, shells, and chain- and bar-shot are still more destructive; generally tearing the limbs from the body in such a manner as to render readjustment and restoration impossible.

Pathology.—These fractures may be simple, compound, comminuted, or complicated; and in addition to these common varieties of fractures there is occasionally presented an example of simple “perforation,” or mere penetration of the bone without fissure or other fracture; and still more frequently are seen examples of perforation with fissures.

Probably ninety-nine per cent. of all gunshot fractures are both compound and comminuted; the comminution being, in general, excessive.

As in gunshot wounds of the soft parts it has been generally observed that the point of entrance is more round, more smooth, and somewhat smaller than the point of exit, and that the tissues are a little depressed at the entrance, while they are slightly protruded at the exit; so also in gunshot fractures it will often be found that the side of the bone on which the ball has entered, or upon which it first impinged, is less comminuted than the opposite side; and, if it is a “perforation,” that the opening is smaller upon the one side than upon the other; that the edges are slightly depressed upon one side, and elevated or protruded upon the other; and, finally, that numerous small, as well as some large, fragments of bone have been carried into that portion of the track of the wound which lies between the bone and the point of exit of the missile. When a ball fractures the shaft of a long bone, although the blow may have been received three, four, or even six inches from an articulation, the comminution or a single longitudinal fissure may sometimes be found extending into the joint. These fissures or splittings of the shaft often extend also a long distance up or down, without terminating in the joint.

Perforations without fissure occur most often in the broad bones of the pelvis, in the scapula, or in the spongy extremities of the long bones. In the latter, however, it is exceedingly rare to find perforation without fissure. Perforations with fissure are pretty common in the head of the humerus and in the head of the tibia; they occur also, but less often, in the lower ends of the femur and tibia, in the trochanteric portion of the femur, and in the head of the femur.

I wish to be understood to say that fissures occur less often at the points last mentioned, simply because perforations are there less common. It should be known that if perforations do occur at these points, a splitting or fissure com-

municating with the joints is almost inevitable. A misunderstanding here would lead to a very fatal error in many cases.

Prognosis.—In general it may be stated that gunshot fractures of the upper extremities do not demand amputation, and that similar injuries in the lower extremities do demand amputation.

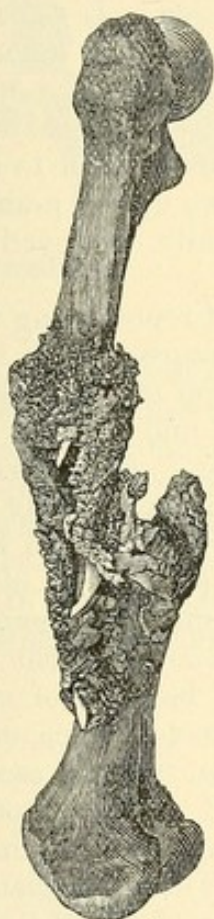
This statement is very broad, and cannot be understood except by a consideration of these accidents somewhat in detail. It may be stated that gunshot fractures of the clavicle, scapula, of the shaft of the humerus, of the shafts of the radius and ulna, and of the carpal, metacarpal, and phalangeal bones, notwithstanding these bones have suffered extensive comminution, do not usually demand amputation; they will in most cases eventually unite, and give to the patients tolerably useful limbs. If, however, at the same time that the shaft of the humerus, or of the radius and ulna, is thus broken, the large nervous trunks are torn asunder, so that the extremity is cold and insensible, the limb cannot probably be saved, nor, if it could be, would it be of any value. Destruction of the main artery supplying the limb diminishes the chance of its being saved, but does not, in the case of the upper extremities, necessarily demand amputation. Penetration of the shoulder-joint by a musket- or rifle-ball, producing a fracture of the head of the humerus or of the glenoid cavity of the scapula, demands amputation when either the axillary artery or axillary nerves are injured; but resection can generally be practised with a reasonable chance of success when the arteries and nerves are untouched. Resection is also made successfully at the shoulder-joint in some cases where larger missiles have traversed the joint, such as canister, fragments of shell, etc.

Penetration of the elbow-joint by a large shot, or by a Minié rifle-ball, the missile fairly entering or traversing the joint, demands amputation when the main arterial and nervous supplies are cut off, and resection, generally, when both remain uninjured. Resection may be attempted at the elbow-joint, also in some cases where, the nervous supply remaining good, only one of the principal arterial trunks is cut off. Frequently a ball strikes the outer or inner condyle of the humerus, making but a small opening into the joint, and producing only slight comminution, and in such cases we often save the limb with more or less ankylosis, and without resection. The remarks which have been made in reference to gunshot fractures of the elbow-joint apply, almost without qualification, to the same accidents at the wrist-joint. For gunshot wounds with fracture of the carpal, metacarpal, and phalangeal bones neither resection nor amputation is often required, unless the soft parts are almost completely torn away.

The prognosis which, as we have now seen, is so favorable in the upper extremities, will be found very different in the lower extremities; indeed, it is almost reversed. Thus: Gunshot fractures of the shaft of the thigh, of the shafts of the tibia and fibula, and of the tarsal bones, generally demand amputation; or, to be more precise, gunshot fractures of the head and neck of the femur almost always terminate fatally under amputation or excision, and equally under treatment as fractures, that is, where an attempt is made to save the limb, without interference with

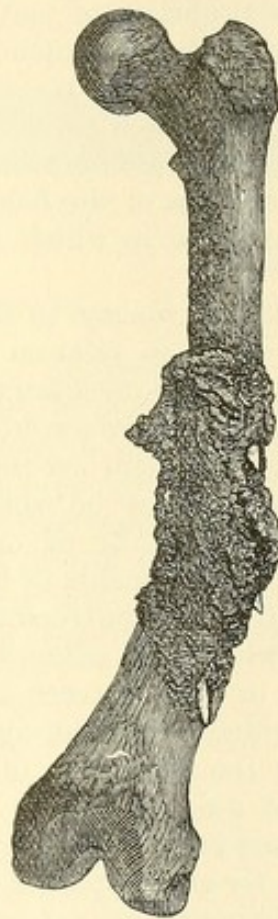
the knife. The same accidents in the upper third of the shaft of the femur are generally fatal; but if the main artery and the principal nerves are uninjured, the life is, in general, less hazarded by an attempt to save the limb than by amputation. In the middle third, under the same circumstances, the chances may be considered equal, as between amputation and the attempt to save the limb by apparatus; in the lower third the chances are in favor of amputation.

FIG. 331.



Gunshot fracture of thigh. (Author's collection.)
Side view.

FIG. 332.



Front view.

The above statements in relation to fractures of the femur are based mainly upon my own experience, and have been carefully considered. I have seen no resections of the knee-joint, and but few of the shaft of the femur, after gunshot fractures, which have not terminated fatally.

[These opinions belong to the period antedating the use of antiseptics and were undoubtedly correct. But the surgeon can now prevent suppuration, and this fact should determine the treatment of each case.]

Gunshot fractures of the shafts of both tibia and fibula demand amputation where the comminution is extensive, or the pulsation of the posterior tibial artery is lost, or the foot is cold and insensible. It is not intended to say that some limbs thus situated have not been saved, but only that the attempt to save such limbs greatly endangers the life of the patient, while amputation at or below the knee is relatively safe.

Amputation is the only safe expedient in deep penetrating wounds of the tarsal bones produced by missiles of the size of musket-balls or larger. The only exceptions, which can safely be made, are in cases where balls have opened partially and superficially these articulations. Resections at the ankle-joint are much more hazardous than amputations, and scarcely to be preferred, in army practice, to attempts to save the foot without surgical interference.

Treatment.—While considering the prognosis in these accidents, I have necessarily spoken of the treatment in certain cases; especially with a view to the propriety of amputation or resection. It remains only to speak briefly of the treatment of those cases in which we may attempt to save the limb without resection, properly so called; for we must not forget that pretty often we find it necessary to remove small, loose fragments of bone by the finger, or by the aid of the knife, or to resect sharp points with the saw or the bone-cutters, when we do not practise “resection” in the sense in which this term is usually employed by surgical writers.

I shall take the liberty, in this connection, of reproducing what I have written elsewhere in relation to gunshot fractures, since it comprises nearly all that seems necessary to be added upon this subject.¹ “If an attempt is made to save a limb badly lacerated and broken, certain conditions in the treatment are necessary to success. All projecting pieces of bone which cannot be easily replaced and are not firmly attached to the soft parts, must be at once cut or sawn away. All foreign substances, such as fragments of balls or other missiles, pieces of cloth, wadding, dirt, etc., must be removed. Any portions of integument, fascia, or muscles, which are entangled in the wound, and prevent a thorough exploration, or may obstruct the free escape of blood or of matter, must be freely divided. Counter-openings must be made at once, or at an early period after the formation of matter, to insure its easy escape (and in certain cases a drainage-tube must be carried through both wounds). The limb must be placed in an easy position, and not confined by *tight* bandages or *forcibly* extended by apparatus. The inflammation must be controlled by constitutional and local means, and especially by the use of water lotions whenever their employment is practicable.

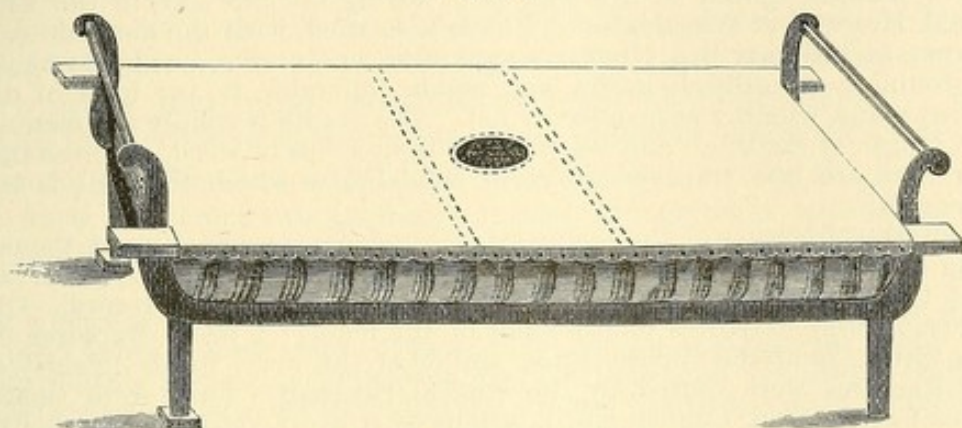
[It should be stated in this connection that the value of antiseptics in the treatment of gunshot wounds cannot be over-estimated. Vast numbers of limbs suffering from gunshots can now be saved by the prompt and persistent use of antiseptic solutions. The following instructions of Dr. Charles Smart, Surgeon U. S. Army,² are pertinent: “A clean incised wound, the sides of which have been immediately approximated, punctured wounds by lance or bayonet, even gunshot penetrations, if they do not contain fragments of clothing, or other foreign matters, may be so free from the bacteria of putrefaction as to heal like an aseptically treated wound, provided that their subsequent treatment be thoroughly antiseptic. The first care given to a wound of this character is to preserve it from the contact of investigating fingers or probes, lest it be converted from a surgically clean wound into one invaded by germs. . . . The hands of the operator and his assistants must be well washed in the antiseptic liquid;

¹ Treatise on Military Surgery, by Frank Hastings Hamilton. 1 vol., 8vo. Published by Baillière Brothers. New York, 1861. Also enlarged edition of same work in 1865.

² Handbook for the Hospital Corps of the U. S. Army.

instruments, ligatures, sutures, sponges, etc., must be immersed in it before being used, and all the dressings saturated with it." This method rigidly carried out in the treatment of gunshot fractures would prevent suppuration and practically reduce compound to simple fractures.]

FIG. 333.

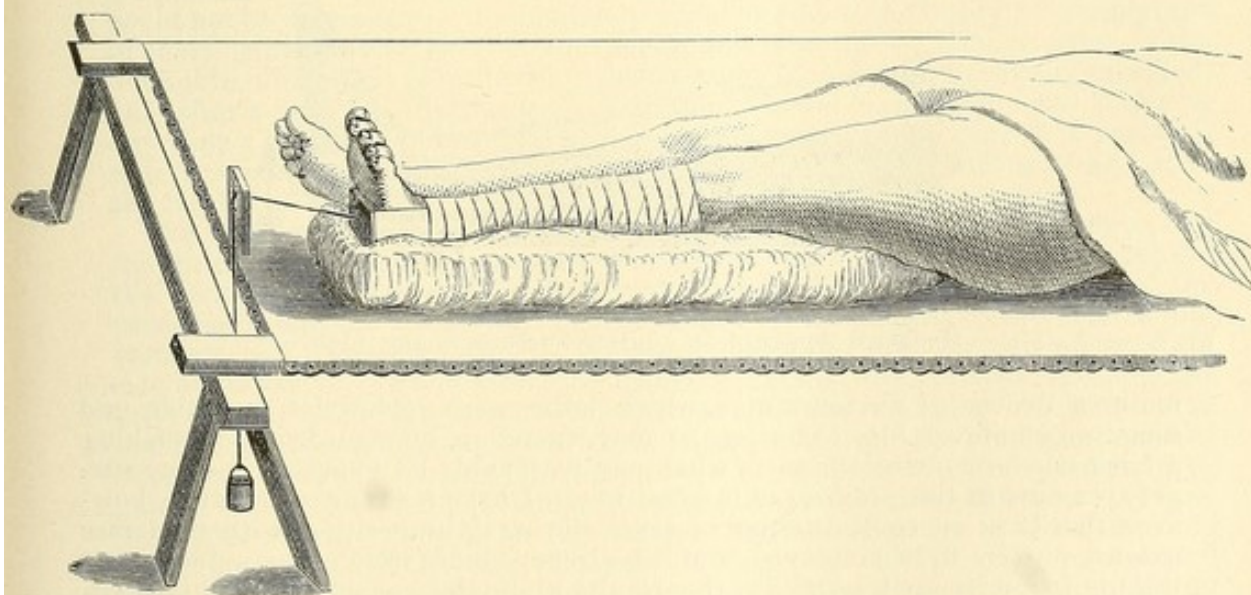


Author's movable canvas.

If joints are implicated seriously, and an attempt is still made to save the limb, the joint-surfaces must be laid freely open, so as to prevent all possibility of the confinement of blood, serum, or pus; and the joint must be placed perfectly at rest, without adhesive strips, bandages, or any apparatus which shall compress the limb or embarrass its circulation.

I still give the preference, in fractures of the femur, to the straight position. In most cases I have preferred my own apparatus, already described when speaking of fractures of the thigh in general, with

FIG. 334.



Movable canvas, with extension, on "horses."

moderate extension; and by moderate extension is to be understood such as may be effected with from five to ten pounds.

A movable canvas, such as is shown in the accompanying woodcuts

with a hole in the centre, and reinforced by an additional piece of canvas where the weight of the hips rests, will enable the surgeon to move his patient and clean the bed when necessary. The standard which supports the pulley can be received in a slot in the frame.

An apparatus similar to this was used, during our late war, in the Lincoln General Hospital at Washington. I have also used, with the movable canvas, and upon an ordinary bed, Hodgen's apparatus, or "cradle," as he terms it, and have found it exceedingly useful, and much preferable to any form of double inclined plane, whether suspended or not. The cradle is simply a skeleton-box, of the length of the thigh and leg, made of light strips of wood. Across the two upper bars are laid, transversely, cloth bands, upon which the limb is laid at full length.¹

Of gunshot fractures of the femur many hundreds, probably many thousands, during and since the close of our civil war, have come under my observation; but of these, only 92 have been made the subject of especial record. Of this number, 75 were fractures of the shaft of the femur; 9 being fractures of the upper third; 36 of the middle third; and 30 of the lower third. Nearly all of these fractures were caused by the conical rifle-ball. They were treated in various Federal and Confederate hospitals by a great variety of methods, and

FIG. 335.

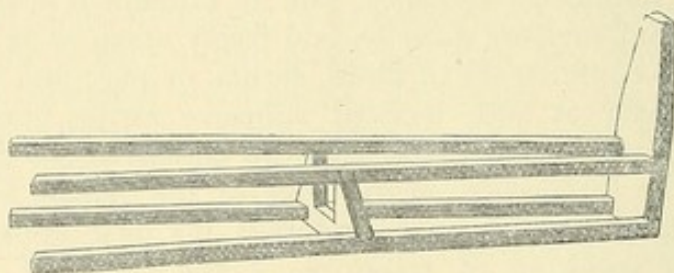
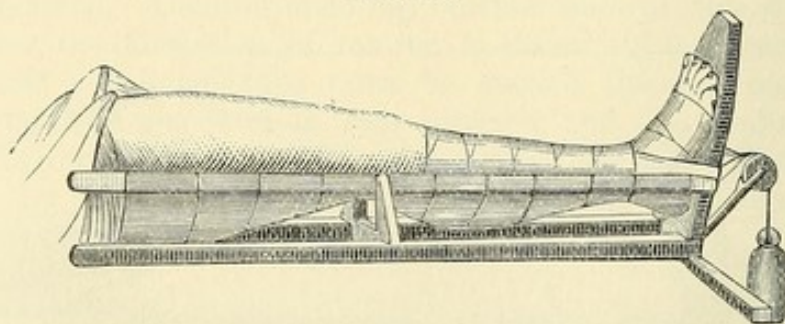


FIG. 336.



Hodgen's apparatus for gunshot fractures of the thigh.

under a variety of circumstances, which latter were sometimes favorable and sometimes unfavorable. The results may, therefore, be regarded as furnishing a fair basis for conclusions as to what may reasonably be expected in army surgery, or during the progress of a great war. I have a strong conviction, however, that if in an equal number of cases the straight position, with moderate extension, were to be employed, and the circumstances were as favorable as are usually found in civil hospitals, the results would be considerably better than are here shown. Indeed, my own recorded cases show, in a marked degree, the advantages of the straight position, with slight extension, over the double inclined planes. In a number of these cases, while the limb was flexed, the shortening and bending were excessive, and the substitution of Buck's apparatus,

¹ Hodgen, *Treatise on Military Surgery*, by the author, p. 408.

Hodgen's, or my own, has made at once a great improvement in both regards, besides contributing manifestly to the comfort of the patients.

The average shortening, in those fractures of the shaft of the femur which were measured by myself after union was effected, was in the upper third, two inches and one eighth; in the middle third, two inches and one-quarter; and in the lower third, a little more than one inch and a half. In the upper third three were shortened two inches or more; the greatest shortening being three inches and one-quarter. In the middle third, twenty were shortened two inches or more, six three inches or more, two four and a half, and one five inches. In the lower third, two were shortened two inches or more; the greatest shortening being two inches and three-quarters.

In a large proportion of the cases the thigh was bent at the point of fracture, the bend being in most cases outward, or to the fibular side of the limb. Where N. R. Smith's suspension apparatus was used, the bend was usually backward, while in most of the cases treated in the straight position, with moderate extension, the limb was nearly or quite straight.

It is somewhat remarkable that in this table of ninety-two cases there are only three examples of union delayed beyond four months, and one of these patients was evidently about to die. In a pretty large proportion of cases the union was not delayed much beyond the usual period of union for a simple fracture, although the limb might be much shortened and crooked, and still discharging pus, with fragments of bone occasionally.

Among the cases which have come under my especial notice the following is of peculiar interest:

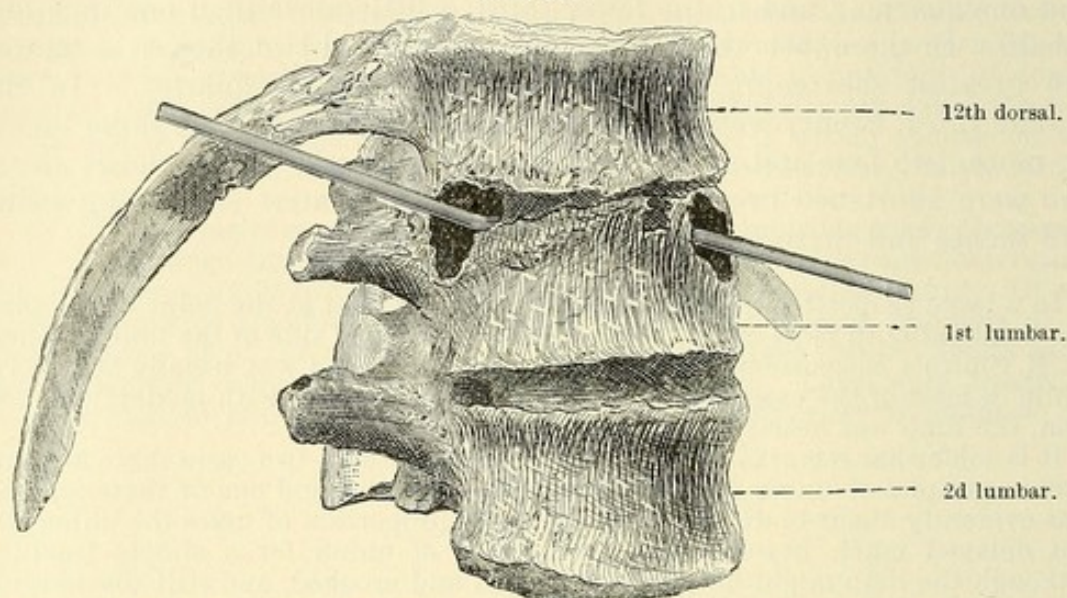
President James A. Garfield was shot by the assassin Guiteau, July 2, 1881, the weapon employed being a "bulldog" pistol of large size, which was fired at short range, the ball entering his body on the right side, about three and one-half inches from the spine. Its direction, after penetrating the muscular parietes, could not be determined. Immediately upon receipt of the injury he complained of sharp pains in his right foot and ankle, and later he felt similar pains in the left ankle, with slight pains in the right scrotum. These pains gradually subsided, and after a few days disappeared altogether. Beyond this there was never at any time a symptom pointing to an injury of the spine. No degree of paralysis ever ensued. President Garfield died September 19, 1881, eleven weeks after the receipt of his injury. The autopsy disclosed the following facts:

The ball, after penetrating the thoracic wall at the tenth intercostal space, and fracturing the adjacent ribs, passed through the connective tissue and fat behind the upper edge of the right kidney, without wounding the liver, perforated the psoas fascia and the psoas magnus muscle near its attachment to the first lumbar vertebra, and penetrated the first lumbar vertebra in the upper part of the right side of its body. The aperture by which it entered the vertebra involved the intervertebral cartilage next above, and was situated just below and anterior to the intervertebral foramen, from which its upper margin was about one-quarter of an inch distant. Passing obliquely to the left and forward through the upper part of the body of the first lumbar vertebra, the bullet emerged by an aperture, the centre of which was about half an inch to the left of the median line, and which also involved the intervertebral cartilage next above. The cancellated tissue of the body of the first lumbar vertebra was very much comminuted and the fragments somewhat displaced. Several deep fissures extended from the track of the bullet into the lower part of the body of the twelfth dorsal vertebra. Others extended through the first lumbar vertebra into the intervertebral cartilage between it and the second lumbar vertebra. Both this cartilage and that next above were partly destroyed by ulceration. A number of minute frag-

ments from the fractured lumbar vertebra had been driven into the adjacent soft parts.

It was further found that the right twelfth rib also was fractured at a point one inch and a quarter to the right of the transverse process of the twelfth dorsal vertebra; this injury had not been recognized during life.

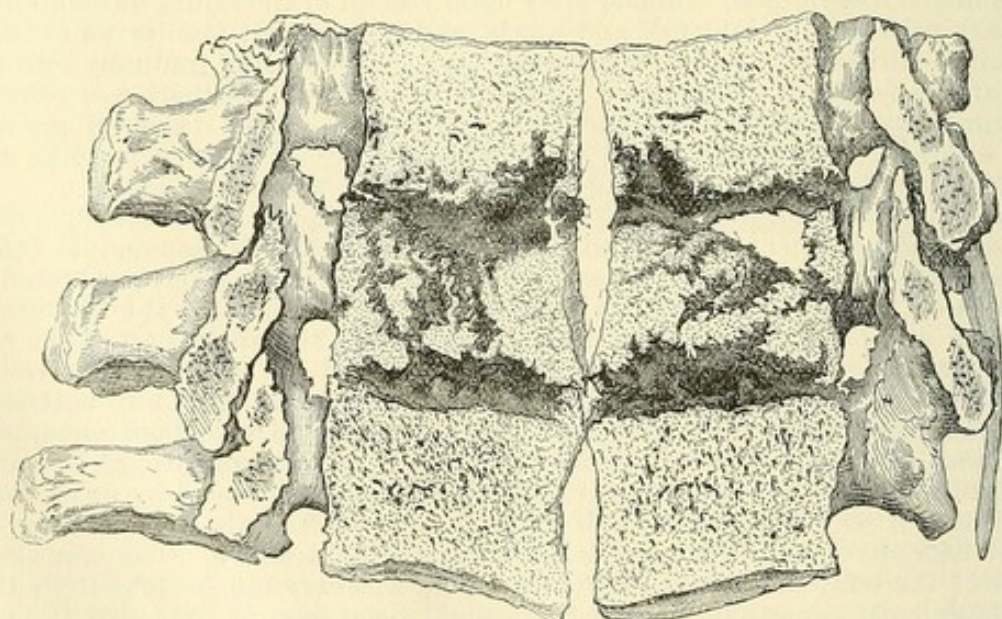
FIG. 337.



Course of the ball through the first lumbar vertebra, its direction being indicated by the probe.

On sawing through the vertebra, a little to the right of the median line, it was found that the spinal canal was not involved by the track of the ball. The spinal cord and other contents of this portion of the spinal canal presented no abnormal appearances. The rest of the spinal cord was not examined.

FIG. 338.



Same specimen sawn open.

Beyond the first lumbar vertebra the bullet continued to go to the left, passing behind the pancreas to the point where it was found. Here it was enveloped in a firm cyst of connective tissue, which contained besides the ball a minute quan-

tity of inspissated, somewhat cheesy pus, which formed a thin layer over a portion of the surface of the lead. There was also a black shred adherent to a part of the cyst-wall, which proved on microscopical examination to be the remains of a blood-clot. For about an inch from this cyst the track of the ball behind the pancreas was completely obliterated by the healing process. Thence, as far backward as the body of the first lumbar vertebra, the track was filled with coagulated blood, which extended on the left into an irregular space rent in the adjoining adipose tissue behind the peritoneum and above the pancreas. The blood had worked its way to the left, bursting finally through the peritoneum behind the spleen into the abdominal cavity. The rending of the tissues by the extravasation of this blood was undoubtedly the cause of the paroxysms of pain which occurred a short time before death.

The fatal hemorrhage proceeded from a rent nearly four-tenths of an inch long in the main trunk of the splenic artery, two inches and a half to the left of the celiac axis. This rent must have occurred at least several days before death, since the everted edges in the slit in the vessel were united by firm adhesions to the surrounding connective tissue, thus forming an almost continuous wall bounding the adjoining portion of the blood-clot. Moreover, the peripheral portion of the clot in this vicinity was disposed in pretty firm concentric layers. It was further found that the cyst below the lower margin of the pancreas, in which the bullet was found, was situated three inches and a half to the left of the celiac axis.¹

¹ See official report of the autopsy; made at Elberon, Long Branch, N. J., September 20, 1881, eighteen hours after death, by D. S. Lamb, of the Army Medical Museum, Acting Asst. Surgeon U. S. Army, in the presence of the attending physicians and surgeons—Joseph K. Barnes, Surgeon-General U. S. Army; J. J. Woodward, Surgeon U. S. Army; D. W. Bliss, M.D.; Robert Reyburn, M.D.; and of the consulting surgeons—Dr. Hayes Agnew, M.D., and Frank H. Hamilton, M.D.

The report was signed also by Andrew H. Smith, M.D., who was present as a representative of the coroner of the State of New Jersey.

See, also, the author's summary of the President's case, *Med. Gaz.*, Oct. 1881.

PART II.

DISLOCATIONS.

PART II
DIRECTIONS

DISLOCATIONS.

CHAPTER I.

GENERAL CONSIDERATIONS.

§ 1. General Division and Nomenclature.

A **DISLOCATION** is the displacement of one bone from another bone or cartilage at the place of natural articulation.

Dislocations may be divided into *accidental* or *traumatic*, *spontaneous* or *pathologic*, and *congenital*.

Our remarks upon the etiology, pathology, symptomatology, prognosis, and treatment of these injuries must be considered as applicable only to accidental or traumatic dislocations, unless the fact is in any case otherwise stated.

Accidental dislocations are those in which the bones have suffered displacement in consequence of the application of a sudden force; and surgeons have divided these accidents into Complete and Partial, Simple, Compound and Complicated, Recent and Ancient, Primitive and Consecutive.

A *complete dislocation* is one in which no portions of the articular surfaces remain in contact.

A *partial dislocation* is one in which the articular surfaces are not completely removed from each other.

A *simple dislocation* is that form of the accident in which the bone has only slid from its articulation, and is accompanied with the least or only an average amount of injury to the soft parts or to the bones adjacent to the joint.

A *compound dislocation* implies that the articulating surface of the bone has been thrust through the flesh and skin; or that in some other way a wound has been made which communicates with the joint.

Complicated dislocation is a term employed by some writers to designate a condition wholly differing from a compound dislocation, or, in some cases, a condition of extra complication.

Thus, a simple dislocation may be complicated with a fracture, or with the laceration of an important bloodvessel, etc.; and a compound dislocation may be complicated in the same way, and with the addition, perhaps, of extensive laceration and destruction of integument, muscles, nerves, etc.

A *recent luxation* has taken place within a period of a few days, or, at most, of a few weeks; and an *ancient luxation* has existed during a

longer period. The exact point of time at which a dislocation shall be called recent or ancient is not fully determined by surgeons, and the application of these terms is therefore always somewhat arbitrary.

A *primitive luxation* is a luxation in which the bone remains nearly or precisely in the position into which it was at first thrown; while a secondary or consecutive luxation is one in which the bone has subsequently, in consequence of the action of the muscles, or from unsuccessful efforts at reduction, or from some other cause, changed its position sufficiently to entitle the accident to a new designation. Thus a primitive dislocation upon the ischiatic notch may become a secondary dislocation upon the dorsum ilii, or the reverse.

General Predisposing Causes.—According to Malgaigne, whose conclusions are based upon an analysis of six hundred and forty-three cases, dislocations are very rare in infancy, only one having occurred under five years; but the frequency increases gradually up to the fifteenth year, from this period more rapidly up to the sixty-fifth year, and from this time onward, again, dislocations become more rare. He has mentioned none after the ninetieth year; and the period of greatest frequency is between the thirtieth and sixty-fifth year. To this middle period belong four hundred and seven of the whole number.

Kronlein¹ from an analysis of 400 cases has constructed the following table:

Articulations.	1-10 yrs	11-20.	21-30.	31-40.	41-50.	51-60.	61-70.	71-80.
Hip	4	1	...	2	1	...
Knee	3	2	1	...	1
Foot	1	1	...
Metatarso-phalangeal	1	2
Shoulder	2	55	45	48	36	19	2
Elbow	31	49	15	5	4	3	1	1
Hand	1
Metacarpo-phalangeal	6	8	4	8	1
Interphalangeal	1	...	5	1	1
Sterno-clavicular	1	3	2
Acromio-clavicular	1	...	2	4	3	1	...
Lower jaw	2	4	1	2	1
Spine	1
Totals	44	69	88	65	60	48	23	3

The inference from these analyses may be thus briefly stated: Age, as a general predisposing cause, is most active in middle life, and least active in advanced and in early life.

It is proper, however, to observe that while such statistics may be relied upon as indicating the relative frequency of these accidents at different periods of life, they cannot be regarded as determining absolutely the value of age alone as a predisposing cause, since the direct or exciting causes may be more active at one period than another, and in some measure these latter causes may be, and doubtless are, responsible for such results.

¹ Kronlein, Luxationen, Deutsche Chir. Von Billroth u. Luecke, 1882, p. 5.

It may be stated as a general fact that persons of feeble constitution, and whose muscular systems are much weakened, suffer dislocation from slighter causes than those who are in health, and whose muscular systems are firm and vigorous; and that a relaxation of the ligaments which surround a joint, however this may have been occasioned, predisposes to dislocation. Thus, a paralyzed and atrophied limb is predisposed to luxation; a joint in which the capsule has become stretched by effusions, or by violent extension, or weakened by laceration from a previous dislocation, or by ulceration—or if in any other way the articulation is deprived of these natural protections, we need scarcely say, it is thereby rendered more liable to luxation.

Ball-and-socket joints, other things being equal, are more liable to displacement than ginglymoid; but then much more depends upon the relative exposure of the joint than upon its anatomical structure, so that the elbow is much more frequently dislocated than the hip; the shoulder-joint, however, being, from its position and extent of motion, peculiarly exposed, and being also a ball-and-socket joint, is, of all others, most liable to dislocation.

Direct or Exciting Causes.—These may be classed under two general heads, namely, external violence and muscular contraction. The action of certain ligaments in determining the direction of some dislocations is also a direct cause, but only subsidiary to the other causes named.

External violence operates either directly or indirectly. When a person falls upon the knee and dislocates the head of the femur, the force is said to have acted indirectly, and this is by far the most frequent mode of dislocation; but when the blow is received upon the upper end of the humerus, and its head is sent into the axilla, it is said to have been dislocated by direct violence.

Muscular action produces a dislocation slowly, as in some cases of chronic rheumatism, and then it is termed a spontaneous or pathologic dislocation; or suddenly, as in the violent spasmodic contractions which accompany convulsions; or sometimes by the mere voluntary effort of the muscles; and both of these are true accidental luxations.

It is very probable that external force can seldom be regarded as the sole cause of a dislocation, but that, in a large majority of cases, muscular action consenting with the shock, performs an important *rôle* in the history of the accident. The limb, being driven obliquely across its socket by the external violence, is seized by the stretched and excited muscles with such vigor as to contribute not a little to the unfortunate result. Thus it will be found that the same force which is adequate to the production of a dislocation in the living and healthy subject is wholly insufficient to accomplish the same in the dead; and a man who is fully intoxicated seldom suffers a dislocation.

General Symptoms.—As fractures are characterized by preternatural mobility and crepitus, to which may be generally added the circumstance that when reduced the fragments will not remain in place without external support; so, on the other hand, dislocations are characterized by preternatural rigidity, an absence of crepitus, and by the fact that when reduced the bone does not generally require support to maintain it in position. These three are the usual, and they may be termed the com-

mon, signs of distinction between fractures and dislocations, but no one of them can be alone depended upon as positively diagnostic. Generally, when a bone has been dislocated, we shall find the limb in a certain position, which is uniform for all dislocations of the same character, and almost immovably fixed; but when the ligaments and muscles about the joint have been extensively torn, or the whole body is still suffering under the shock, or in any other circumstances where the power of the muscles is weakened, this rigidity may give place to extreme mobility.

True crepitus does not exist without fracture, but it is not always present in fractures; and there is often a sensation produced in the rubbing and chafing of dislocated bones which very much resembles certain kinds of crepitus, and by the inexperienced has been often mistaken for it. I allude to the subdued rasping sound or sensation which is found generally on the second or third day, and sometimes earlier, and which is the result of fibrinous effusions, or, perhaps, in some instances, of the mere rubbing of firmly-compressed ligamentous and cartilaginous surfaces upon each other. The crepitus of a recent fracture can be scarcely confounded with this obscure sensation, unless it is in some cases of incomplete fracture, or of a fracture situated remote from the surface, as in the case of the hip; but a fracture which is a few days old, whose surface has become softened by inflammation and more or less covered with lymph, when the rigidity is great, may sometimes deceive the most experienced surgeon: so exactly will it be found to imitate the sensations produced by the chafing of an inflamed joint, or of closely approximated fibrous surfaces.

I have said that a true crepitus does not exist without a fracture; but then a very minute fracture, such as the detachment of a scale of bone by the tearing away of a tendon or of a ligament, may produce crepitus; or even the separation of a piece of cartilage may sufficiently expose the bone to determine the presence of this phenomenon. These are, however, no longer examples of simple dislocation. Nor are the two inverse propositions, in relation to the retention of the bones in place, invariable in their application. A broken bone, well reduced, does not always manifest a tendency to displacement; nor does a dislocated limb, when restored to its socket, in all cases maintain its position, without support.

The other general signs of dislocation are pain, swelling, and discoloration. The pain is generally more intense in dislocations than in fractures, the expanded end of the bone resting often upon one or more large nerves, which usually, with the arteries, approach very near the joints; this pressure being also greatly increased by the extreme tension of the muscles. Not unfrequently numbness and temporary paralysis of the whole limb are the consequences. In other cases the pain is due solely to the pressure upon the muscles or to the tension of the muscles, or, perhaps, to the tension of the untorn ligaments and capsule.

Generally the limb is shortened, but in a few cases it is found slightly lengthened, while the natural axis of the bone with its socket is always changed. If examined early, and before the supervention of swelling, the joint end of the displaced bone may be felt in its unnatural position, and a corresponding depression may be discovered in the situation of the articulation, especially if the bones are superficial.

Pathology.—The dissection of recent dislocations produced by external violence, shows the capsular ligaments more or less torn, and also a rupture of some of the lateral and other short ligaments, with a complete rupture in most cases of some of the tendons which immediately surround the joint, or of those which are attached to the capsule: the muscles, nerves, arteries, etc., through which the bone in its passage has passed, or upon which it is found resting, being also contused, stretched, or torn asunder.

This description, however, does not apply to dislocations produced by muscular action alone, in a majority of which cases the capsule is only stretched, and not torn, and no lesions of other structures are necessarily present.

If the dislocation remains unreduced, the margins of the old socket, in the cases of enarthrodial articulations, become gradually depressed, while the concavity of the socket is filling in with a fibrous or bony tissue, until at length the whole of this portion of the joint apparatus is nearly or entirely obliterated. This process is generally very slow, and may not be consummated until after the lapse of many years. At the same time, but with much greater rapidity, the head of the bone in its new position, and the soft or hard parts upon which it rests, are undergoing certain changes to adapt them to their new relations, and calculated in some measure to restore the limb to its normal functions. If the head of the bone rests upon muscle, the cellular and fibrous tissues which enter into the composition of the muscle become condensed and thickened, forming a shallow or elongated cup, whose margins are attached to the neck, or shaft of the bone, and whose walls are lubricated with synovia. If it rests upon bone, by a process of interstitial absorption a true socket is formed, sometimes deep and sometimes shallow, whose edges, receiving additional ossific depositions, become lifted so as to form a rim. At the same time the head of the bone is undergoing corresponding changes, to adapt itself to the newly-formed socket; it is flattened or otherwise changed in form, and in the progress of this change its natural secreting and cartilaginous surfaces are gradually removed, a porcelaneous deposit taking its place. The same kind of hard, polished, ivory-like deposit is found also in those portions of the new socket which have been especially exposed to pressure and friction. Instead of the eburnation, an imperfect fibro-serous surface or synovial capsule may be formed.

I have in my cabinet an example of ancient luxation of the hip-joint in which the head of the femur, having rested upon the dorsum ilii, has formed a nearly flat but smooth surface—a kind of elevated plateau; in other cases I have seen the margins of the new socket so elevated as to rest against the neck of the femur, and completely lock it in.

Coincident with these changes, and in consequence partly of the disuse of the limb, the muscle, and even the bones sometimes suffer a gradual atrophy. In some measure these alterations may be due also to the pressure of the dislocated bone upon arterial and nervous trunks, by which their functions become partially or completely annihilated, and their structure even may be wholly obliterated. In consequence also of the inflammation which immediately results, we ought not to omit to

notice that the trunk of a large artery sometimes becomes firmly adherent to the capsule or periosteum of a displaced bone, and its reduction is attended with imminent danger of laceration and of a fatal hemorrhage. Numerous instances of this grave accident, especially in attempts to reduce old dislocations of the shoulder-joint, are upon record.

General Prognosis.—We shall study the prognosis of these accidents to better advantage when we come to speak of the individual bones and their various forms of dislocation; but it is proper to state in this place, generally, that very few joints, having been once completely displaced from their sockets by external violence, are ever so completely restored as not to leave some traces of the accident, for many years, if not for the whole of the subsequent life of the patient, either in the partial limitation of their motions, or in the diminished size and power of the muscles of the limbs, or in the presence of an occasional arthritic pain: the degree and permanence of these sequences depending upon the joint which is the subject of the displacement, the extent of the original injury, the length of time it has remained unreduced, the means employed in its reduction, the health and condition of the patient, with so many other contingent circumstances as to preclude the idea of a complete specification. If the bone is not reduced, a permanent maiming is inevitable; but it is surprising how much time and the intelligent processes of nature can eventually accomplish toward a restoration of the natural functions, especially when aided by a good constitution and judicious treatment. If the symmetry of form and grace of motion are never replaced, the value of the limb, for all the practical purposes of life, is not unfrequently completely reëstablished.

General Treatment.—The first indication of treatment is to reduce the bone. Whatever delays may be proper or justifiable in certain cases of fracture, such delays are never to be argued in cases of dislocation. The sooner the reduction is accomplished the better. For this purpose we resort at once to such manipulations or mechanical contrivances as the nature of the case demands; and if these fail, or if at the first they are deemed insufficient, we invoke the aid of constitutional means, or such as are calculated to diminish the power and antagonism of the muscles. Many dislocations may be reduced promptly by manipulation alone; which mode is always to be preferred when it will prove sufficient, for the reasons that it is generally the least painful to the patient, and the least apt to inflict additional injury upon the muscles and ligaments.

A person wholly unacquainted with anatomy or surgery may occasionally succeed in reducing a dislocated limb; indeed, it frequently happens that the patient himself, by mere accident in getting up or in lying down, accomplishes the reduction; and even in a very large majority of cases, force and perseverance will finally succeed by whomsoever they may be employed; but the observing student of surgery will soon discover the difference between accident and brute force on the one hand, and intelligent manipulation on the other. The charlatan bone-setter does not often allow himself to fail, unless the courage of his patient gives out, or he ignorantly supposes the reduction to be effected when it is not; but his success, achieved through great and unnecessary suffering, is often obtained, also, at the expense of the limb; while the surgeon, whose knowledge of anatomy enables him to understand in what direction the muscles are offering resistance, and through what ligaments the head of the bone must be guided, lifts the limb gently in his hands, and the bone seeks its socket

promptly and without disturbance, as if it needed only the opportunity that it might demonstrate its willingness to return.

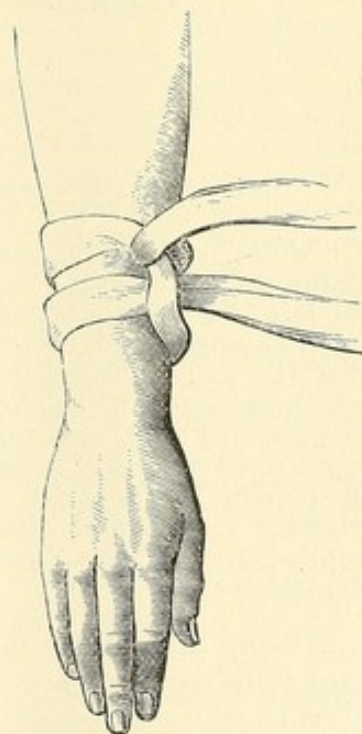
We must understand not only what muscles and ligaments antagonize the reduction, if we would be most successful, but also what muscles, by being provoked to contraction, will themselves aid in the reduction. In short, to become expert bone-setters in the department of dislocations, one must possess a complete knowledge of the physiognomy or the external aspect of joints, acquired only by repeated and careful examinations, he must be familiar with the anatomy and functions of the muscles, he must understand thoroughly the ligaments, he must have experience, tact, and fertility of resource.

Without these qualifications a man will do better never to undertake to treat dislocations, since he is constantly liable to mistake fractures for dislocations, and dislocations for fractures; he will submit a sprained wrist to violent extension, under the conviction that the joint is displaced; he will mistake natural projections for deformities, and fail to recognize the real deformity when it actually exists; he will leave bones unreduced, fully believing that they are reduced; and he will, all in all, within a few years, accomplish vastly more evil than he can ever do good. Let a man practise any other branch of surgery if he will, without experience or scientific knowledge, but he must not attempt to reduce dislocated bones. The most learned and the most skilful we shall find falling into error, embarrassed by the uncertainty of the diagnosis, or successfully resisted by the power of the opposing agents. What, then, can be expected of those who are both ignorant and inexperienced but failures and disasters?

As a means of disarming the muscles, or of placing them off their guard, we often practise successfully the diversion of the mind of the patient. At the very moment that the limb is moved or extension is made, a question is addressed to him, or he may be suddenly surprised by some unexpected intelligence.

Extension and counter-extension, made with our own hands or with the hands of assistants, constitute the second resort where manipulation alone has failed. The surgeon, seizing upon the limb firmly with his hands, makes the extension, while the assistants make the counter-extension; or, instead of grasping the limb directly, the operator may use for this purpose circular and longitudinal bandages, or the bandage or handkerchief tied in the form of the clove-hitch. Extension is thus applied in connection with manipulation, aided, perhaps, by direct pressure upon the head of the displaced bone. Failing in this, we employ some one of the various mechanical contrivances which, while they are capable of exerting much more power, possess also the important advantage of operating gradually and steadily, by which mode the resistance of the muscles is always more speedily and more completely overcome.

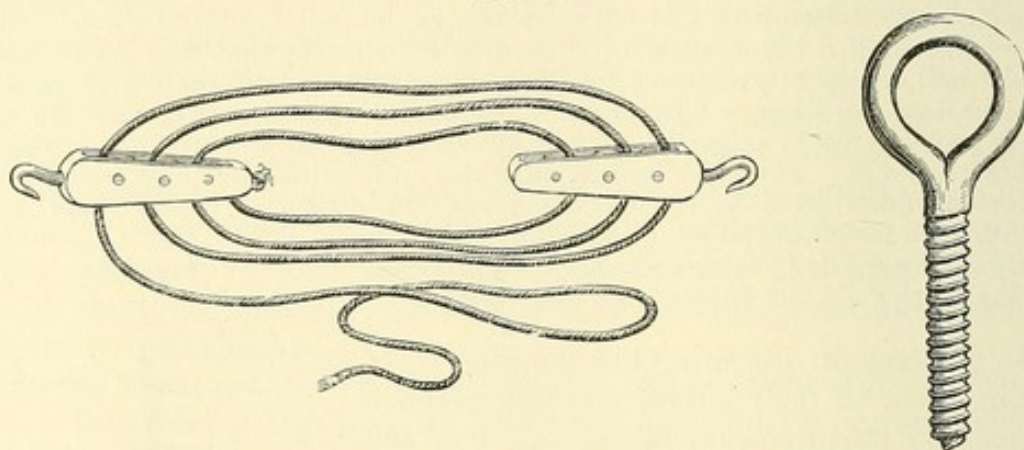
FIG. 339.



Clove-hitch. (From Erichsen.)

For this purpose, Legros and Anger¹ have proposed the use of India-rubber tubes, to the number of five or six, extended gradually and successively to a proper tension, and maintained in this degree of tension for twenty or thirty minutes; and others have advised the use of the pulley and weights, the latter of which methods I have often employed myself; but surgeons employ generally, in the case of the large limbs, the compound pulleys, or the simple rope windlass, which is thus described by Dr. Gilbert, of Philadelphia: "Place the patient, and adjust the extending and counter-extending bands as for pulleys; then procure an ordinary bed-cord or a wash-line, tie the ends together, and again double it upon itself, pass it through the extending tapes or towels, doubling the whole once more, and fasten the distal end, consisting of four loops of rope, to a window-sill, door-sill, or staple, so that the cords are drawn moderately tight; finally, pass a stick through the centre of the double rope, then by revolving the stick as an axis or double lever, the power is produced precisely as it should be in such cases, viz., slowly, steadily, and continuously." Jarvis's adjuster, although very complex, possesses some advantages over the pulleys, which may, perhaps, entitle it to the preference in a few cases.

FIG. 340.



Compound pulleys, and ring to which one end of the pulley-rope is fastened.

Sédillot,² recognizing the danger of over-extension in the employment of mechanical apparatus, and especially in the employment of the pulleys, conceived the idea of attaching to the latter a dynamometer, by which the exact amount of force applied could be determined. It is not, however, by any means certain that the dangers would be lessened by this means, since the amount of force which can safely be employed is seldom the same in any two cases which may be presented; but, depending, as it must, upon the limb to which the traction is applied, its muscular power or resistance, the age, sex, and general condition of the patient, it is apparent that the limits of safety must be determined by the constant and careful observation of the limb while the extension is being applied, and, in short, by the judgment of the surgeon rather than by any fixed dynamic rule.

Among the constitutional means, ether and chloroform occupy the first rank; indeed, they are, at the present day, almost the only means of this class to which surgeons resort, and their value in this point of view can scarcely be over-estimated. Only when some unusual circumstance or condition of the patient forbade the use of an anæsthetic, would the surgeon return to the ancient practice of bleeding *ad deliquium*, of prostrating the system with antimony, or to the use of those vastly less efficient agents, opium and the warm bath.

¹ Legros and Anger, Arch. Gén. de Méd., 1867.

² Sédillot et Gross, Art. Luxations, Dic. Encyc. Sci. Méd., Ser. 2d, t. iii. p. 295.

CHAPTER II.

DISLOCATIONS OF THE LOWER JAW (TEMPORO-MAXILLARY).

THERE are two principal forms of this dislocation, namely, the double or bilateral dislocation, and the single or unilateral; in both of which the direction of the displacement is forward. To these there may be added as having been occasionally observed an outward displacement accompanied with a fracture, and occasionally a backward dislocation, with fracture of the meatus auditorius externus.

IN order that we may better understand the pathology of this accident, it will be proper to say a few words in relation to the anatomy of the temporo-maxillary articulation and the other parts concerned in the dislocation now under consideration. The articulation is formed by the condyloid process of the inferior maxilla and the glenoid fossa of the temporal bone, in front of which fossa, and at the root of the zygomatic arch, is a slight elevation, called the articular eminence. Between the joint surfaces, both of which are covered with cartilage of incrustation, is placed an interarticular cartilage, which divides the joint into two cavities, one corresponding to the condyle of the inferior maxilla, and the other to the glenoid fossa, each of which is furnished with a distinct synovial membrane. Properly there is but one ligament—namely, the external lateral—which passes from the outer surface of the articular eminence to the corresponding surface of the neck of the condyle. What is called the internal lateral ligament arises from the apex of the spinous process of the sphenoid bone, and is inserted into the margin of the dental foramen, and has therefore no immediate connection with the articulation, although it tends to strengthen the joint. The same is true of the stylo-maxillary ligaments. The lower jaw is drawn upward, or closed upon the upper jaw, by the action of the temporal, masseter, and internal pterygoid muscles; it is drawn downward by the action of the digastricus, mylo-hyoideus, and genio-hyoglossus muscles; forward by a few fibres of the masseter and by the external pterygoid muscles; and laterally by the alternate action of the external and internal pterygoid muscles. When the mouth is open to its utmost extent, the maxillary condyle rises upon the articular eminence until it rests upon its very summit. Indeed, it is probable that in most persons it advances rather in front of the centre of the eminence; so that in order to become actually dislocated it only needs that the capsule shall be somewhat relaxed, or that it shall actually give way in front, when the condyles slide forward and occupy a position directly in front instead of behind this eminence.

§ 1. Double or Bilateral Dislocation Forward.

THIS form of dislocation of the lower jaw is much the most frequent, being met with in about two out of every three cases. It appears also to occur oftener in women than in men, and usually between the twentieth and thirtieth year of life. In infancy and extreme old age it is exceedingly rare.

SIR Astley Cooper mentions a case in which, "two boys" being at play, one had an apple thrust into his mouth, producing a double dislocation; and Nélaton saw the same accident in an old man of seventy-two years, who was toothless.

This comparative immunity in youth and old age has been ascribed to certain peculiarities in the form of the jaw at these periods of life. Nélaton attributes its more frequent occurrence in middle life to the great length and strong anterior inclination of the coronoid process.

Pathology.—It is easy to comprehend how the combined action of the two external pterygoid muscles, with a portion of the fibres of the masseter, may alone produce the dislocation when the mouth is wide open, and especially when, in consequence of a slight blow upon the chin, the anterior portion of the capsule becomes lacerated; for it must be noticed that the ascending ramus, with its prolonged condyloid process, constitutes a lever of the first kind, in which the temporal muscle, attached to the coronoid process, the masseter, and even the mastoid process, constitute the fulcrum, the anterior portion of the capsule the weight, and the force acting against the front of the chin the power.

In this position of the condyle, drawn upward and forward by the action of the pterygoid and temporal muscles, the chin descends toward

the neck, and the coronoid process rests against the back of the superior maxilla, or against the malar bone at the point of its junction with the upper maxillary. The temporal, masseter, and internal pterygoid muscles are very much upon the stretch, if not more or less lacerated.

In addition to the influence of muscular action and the hooking of the condyle upon the malar and maxillary bones in maintaining the dislocation after it has once taken place, and in offering an obstacle to its reduction, there is to be considered the occasional

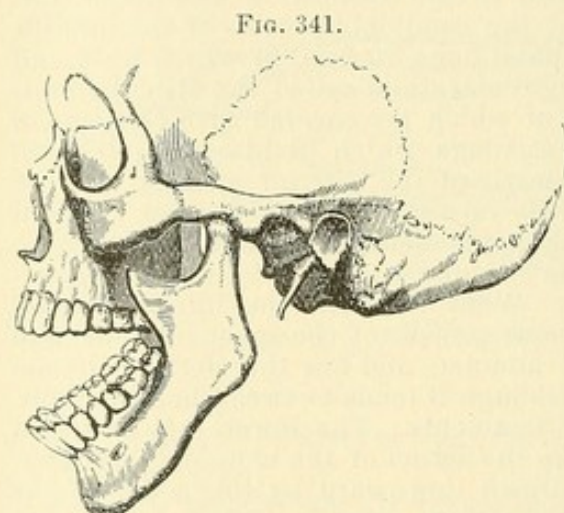


Fig. 341.
Double dislocation of the inferior maxilla, forward.

displacement of the intra-articular cartilages, as demonstrated by Demarquay, Mathieu, and Périer.

Cause.—In a majority of cases the *direct or immediate cause* has seemed to be muscular action alone.

Malgaigne found this cause to prevail in twenty-five out of forty cases; and of the twenty-five cases fifteen were occasioned by gaping, five by convulsions, four by vomiting, and one by rage. Dr. Physick, of Philadelphia, found both condyles dislocated in a woman in consequence of the violent gesticulation of her jaw while scolding her husband. But in a more remarkable case still, this surgeon found the jaw dislocated after recovery from a profuse salivation, and of the cause of which, or the time of its occurrence, the patient, a young girl, could give no account. Dr. Physick made several ineffectual attempts at reduction, and only succeeded at last after he had made her completely intoxicated with ardent spirits.¹ Andrews found both condyles dislocated by a lobelia emetic. The patient had often taken these emetics before, and had frequently

¹ Physick, Dorsey's Elements of Surgery, vol. i. p. 202. Philadelphia, 1813.

experienced a sensation "of catching" at the joint, but the jaw had always until this time resumed its position spontaneously.¹

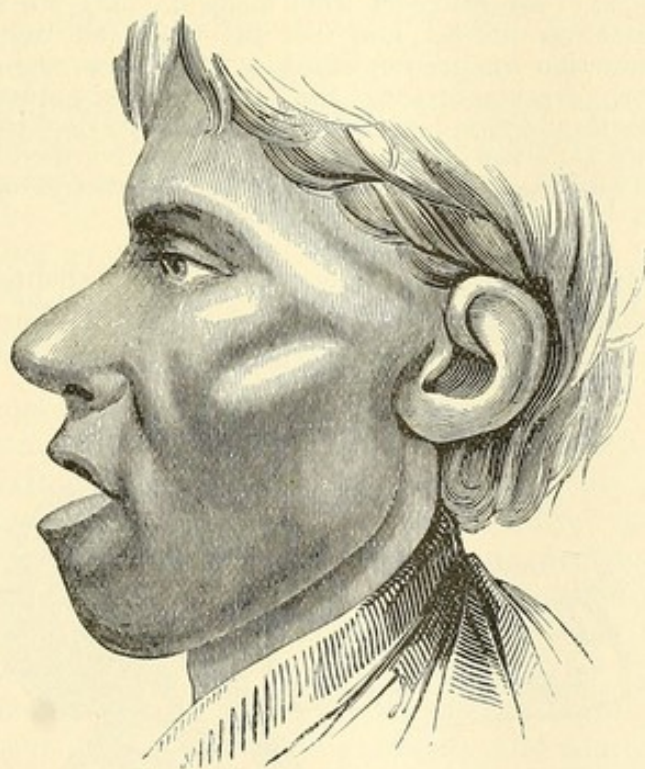
Dr. H. A. Steen, of Minnesota, met with a bilateral dislocation caused also by vomiting.² Dr. Edwin Morris³ has seen the same occur during sleep with a young lady who from infancy had been accustomed to suck her tongue.

Among the causes from outward violence, the introduction of some foreign body into the mouth, and the extraction of teeth, occupy the most important place. In fifteen cases seven were from the former and six from the latter cause.

Dr. A. W. Gilbert has related a case which came under his own observation, produced by a similar cause. During his apprenticeship he was requested to insert a set of teeth for a young man, and while opening his mouth to take an impression of his gums, he dislocated "both condyles forward, under the zygomatic arches;" but so perfectly were the muscles relaxed, that he immediately reduced them, without the least difficulty, by placing his thumbs as far back as possible upon the molar teeth, depressing the back part of the jaw, and at the same moment elevating the chin.⁴ Prof. James Webster, of Rochester, N. Y., dislocated the jaw of a lady while attempting to pry out a root of one of the molars.

Symptoms.—The mouth is widely open and the jaw nearly immovable. It has been noticed generally that, by pressure, the chin may be slightly

FIG. 342.



Dislocated lower jaw.

depressed, but that, owing probably to the pressure of the coronoid process against the body of the upper maxilla, or against the malar bone, it

¹ Andrews, *Peninsular Journ. Med.*, vol. iii. p. 101, 1855.

² Steen, *Virginia Med. Monthly*, June, 1878, p. 220.

³ Morris, *Brit. Med. Journ.*, Aug. 31, 1872.

⁴ Poincet, *op. cit.*, p. 743.

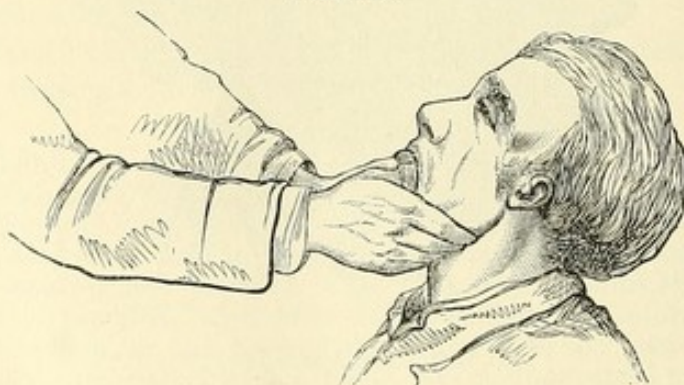
is generally impossible to elevate the jaw in any degree whatever. The jaw is also slightly advanced; a depression, covering a considerable space, exists between the auditory canal and the posterior margin of the condyle. A slight fulness is observed in the temporal fossa, and also upon the side of the cheek in the region of the masseter muscle. Ordinarily the patient suffers considerable pain, but not always, from the pressure of the condyles upon the branches of the temporal nerves. There is a constant flowing of the saliva from the mouth; the patient is unable to articulate, and even deglutition is performed with great difficulty.

Prognosis.—When the dislocation remains unreduced, the lower jaw gradually approximates the upper, and its anterior projection sensibly diminishes, the saliva ceases to dribble from the mouth, deglutition and speech are restored, mastication is performed with considerable ease, and, in short, the patient comes at length to experience no great inconvenience from the displacement.

Robert Smith relates the case of a woman whose lower jaw was dislocated during an epileptic convulsion. She was at the time in one of the metropolitan hospitals, but the accident was not noticed by the surgeons, and it remained ever afterward unreduced. At the end of a year she could close the lips perfectly, but was able to open the mouth only to a limited extent; the teeth of the lower jaw remained advanced, the involuntary flow of saliva had ceased, and the faculty of speech had been regained.¹ In Professor Webster's case, to which I have before referred, although the jaw was immediately and easily reduced, after the lapse of several years, when I saw the lady, she still complained that it hurt her whenever she ate, and that she often felt the condyles slip in their sockets. Reduction was accomplished by Physick in the case already related, after the lapse of several weeks; Sir Astley Cooper reduced a double dislocation after a month and five days, which had been overlooked by the surgeon in attendance;² and Donovan succeeded after ninety-five days.³ In two cases treated by Michon and Gosselin the reduction was effected at one hundred and thirty days.⁴

Treatment.—Reduction may generally be accomplished with ease in cases of recent dislocation, in the following manner: The patient being seated upon the floor with his head between the knees of the operator, a

FIG. 343.



Method of reducing lower jaw.

¹ Robert Smith on Fractures and Dislocations, p. 288. Dublin, 1854.

² Sir Astley Cooper on Disloc. and Frac., Amer. ed., p. 316.

³ Donovan, Amer. Journ. Med. Sci., Oct. 1842, p. 470; from Dublin Med. Press, May 25, 1842.

⁴ Poincet, op. cit., p. 744.

couple of pieces of cork, gutta-percha, or pine wood are placed as far back between the molars as possible, when the surgeon seizing upon the chin draws it steadily upward, taking care not to draw it forward at the same time, since by this movement he would resist the action of the muscles which naturally tend to restore it to place whenever the condyloid processes are lifted sufficiently from the zygomatic fossæ.

Many surgeons prefer to sit or stand in front of the patient, and depress the condyles by means of the thumbs placed inside of the mouth and upon the tops of the molars. If the thumbs are used in this way, it would be well to protect them with a piece of leather, or to slip them off from the teeth suddenly when the condyles are gliding into their places, as the muscles sometimes close the mouth with sufficient violence to bruise severely anything which might at that moment be interposed between the teeth.

The method practised by Ravaton, of simply lifting the chin gradually and forcibly toward the upper jaw, was essentially the same, but far less efficient; for, although he placed nothing between the molars to serve as a fulcrum, the backmost teeth themselves must in some degree perform this service whenever, the lower jaw being dislocated and drawn upward, the chin is forcibly approximated toward the upper.

In other cases it has been found necessary first to disengage the coronoid process, by depressing the chin gently, and then pressing backward in the direction of the articulation; a method which would certainly deserve a trial in case of the failure of that first described. This was the method practised by Hippocrates. Lateral pressure made directly upon the condyle may facilitate the reduction. A more effectual expedient, however, consists in reducing one side at a time; taking good care always that the side first reduced is not redislocated while the attempt is being made to reduce the other, a thing which happened in one of the cases treated by Sir Astley Cooper, and has happened many times in the practice of other surgeons.

Finally, if all other expedients fail, we ought not to hesitate to resort to anæsthetics, nor indeed could any objection exist to their employment at any period of the treatment, were it not that in a large majority of cases the reduction is effected so easily and promptly as to render their employment wholly unnecessary. After the reduction is accomplished, it will be a matter of wise precaution to sustain the jaw by a double-headed bandage passed under the chin, and secured upon the top of the head; so as to prevent the mouth from being accidentally opened too far, especially during sleep, since experience has shown that a tendency to a reproduction of the dislocation remains for some time. It will be prudent to continue these measures of protection for at least one week; after which the danger of ankylosis should be borne in mind, and the extent of passive motion should be gradually and cautiously increased.

In illustration of this tendency to redislocation, Malgaigne refers to the case mentioned by Putégnat of a woman whose jaw for many years became dislocated at least once a month; but she was always able to reduce it herself.

§ 2. Single or Unilateral Dislocations Forward.

Causes.—The causes of this accident are in general the same as those which produce double dislocations, and it occurs most often in middle life.

Tartra has seen one exceptional example in a child only fifteen months old, and Levison saw a case in an old man who had lost all his teeth.¹

Symptoms.—The mouth is open, but not so widely as in double dislocation; the jaw is nearly immovable; the teeth are advanced; the condyloid process can be felt in front of the articular eminence, leaving a depression in its natural situation, and the coronoid process is more prominent than in the bilateral dislocation. It will be remembered that we have already pointed out an important diagnostic mark between a fracture of the neck of the condyloid process and a dislocation of one condyle. In the latter the chin inclines to the opposite side, while in the former it falls toward the side upon which the accident has occurred.

According to Hey, this lateral deviation of the chin is not always present in dislocations; and Robert Smith mentions one case in which the surgeon was misled by the circumstances so far as to attempt a reduction upon the left side when the dislocation was upon the right.

Treatment.—The same rules of treatment for dislocations of both condyles will be applicable to the single dislocations, with only such modifications as will be naturally suggested to the surgeon.

In the case mentioned by Levison, the dislocation was constantly recurring upon the left side; and it was especially liable to happen when just awakening from sleep. "He would then pull his jaw, press it backward, when, after about half an hour's work, bang it seemed to go, and all was right again." This old gentleman was finally relieved of these annoyances by a band fastened under the chin. In such a case, an apparatus constructed after the same plan as my lower jaw apparatus might perhaps serve a useful purpose.

§ 3. Dislocations Outward, with Fracture.

Robert² was the first to observe this fact. The dislocation (left side) occurred in a man whose face had been traversed by the wheel of a cart, and was accompanied with a fracture in front of the ascending branch of the jaw on the right side. The dislocated condyle projected outward and could be distinctly felt and seen under the skin. The chin was inclined to the same side.

In 1879 Dr. Neis³ observed a second example of this dislocation, which he describes as "outward and upward into the temporal cavity," unaccompanied with fracture of the jaw. The subject was a young man whose chin and occiput were pressed between two boats. Dr. Neis supposed a fracture of the glenoid cavity, but he was not able to establish it.

¹ Levison, Boston Med. and Surg. Journ., vol. xxxiv., 1846, p. 388, from London Lancet.

² Robert, Journ. de Chir., 1844, p. 265.

³ Neis, Thèse de Paris, 1879, No. 252. (Poinsot.)

§ 4. Dislocations Backward, with Fracture.

According to the researches of Baudrimont, this accident had been described by Lanfranc, Guy de Chauliac, and Jean de Vigo, but not until recently had any well-authenticated examples been published. Indeed, Baudrimont alone has recorded an example of bilateral dislocation backward. In a case reported by Croker-King the dislocation was unilateral, and was reduced by a method similar to that employed by Baudrimont, but it was not followed by any accidents; while Lefèvre mentions a unilateral dislocation backward which resulted in a cerebral abscess and death about five months after the injury was received. The dislocation was not recognized until the autopsy was made. In all of these examples the condyle, which rests with its centre over the point where the bony portion of the external auditory canal joins the cartilaginous portion, being thrust backward has broken the margin of the bony portion and displaced or torn the cartilaginous portion, but without rupture of the ligaments.

Baudrimont,¹ of Bordeaux, relates the following case: "September 25, 1879, M. M., a carman, aged 63, who had lost all the teeth of the upper jaw, and a number of the molars of the lower, fell violently on his chin, experiencing at the moment a violent pain in both ears, and when he arose he found himself unable to move his jaw. There was a wound on the chin, absolute deafness existed, accompanied with an otorrhœa which continued until the following day. He was on the same day admitted to the Hospital of St. André, Bordeaux. His mouth was half open, the chin receded behind the upper jaw, as determined by the position of the incisors, fifteen millimetres. The lips could be closed, but the jaws could not. The backward displacement of the lower jaw caused a flattening of the cheeks, and gave to the mouth a peculiar grimace. The posterior portion of the jaw touched the sterno-mastoid muscle. The condyle was absent from its socket. Both auditory canals were closed by hard antero-inferior projections, which obeyed the slight movements which alone could be given to the jaw. The reduction was immediately attempted as follows: "The patient is seated on a chair, his head slightly thrown back and held by an assistant. Both thumbs are with difficulty introduced on both sides between the jaws, which can only be done by exaggerating the backward rocking movement of the jaw; the thumbs press, by their palmar surfaces, on the lower molars. The other fingers brought under the chin, seize the body of the jaw, in a firm grip, on both sides. I press progressively and very energetically downward at first, then downward and forward. A sudden disengagement of the right condyle, which regains its place, is at first obtained with comparative ease. The dislocation is now single. The chin is deviated to the left. The same attempt is then made on the left side, but I then experience far more difficulty; a considerable effort proves insufficient; but with the help of the fingers pressing upon the condyle which is disengaged, the jaw rotates on itself and seems to make the hand which accompanies it describe a large circle, and the condyle resumes its articulation with a noise heard at a distance. The last phase of the reduction seems very painful, and as soon as the condyle leaves the ear the blood begins to flow from the left side. The movements of the jaw are reëstablished, and are not very painful. Deafness partially disappears. "Examination of the ears shows that the membrane of the tympanum is torn on the right side, and there are in both auditory canals wounds of the integuments in which the probe detected bony splinters. Different local accidents ensue; sero-sanguinolent, serous, and sero-purulent discharges take place; also a swelling of the articular regions, and, later on, suppuration. The patient left the hospital in a good condition. Three months after there still remained some swelling, articular stiffness, and a certain degree of deafness."

¹ Baudrimont, Journ. de Méd. de Bordeaux, 1882, 13, 20, 27 août. (Poincot.)

§ 5. Conditions of the Jaw simulating Dislocations.

There is a condition of the temporo-maxillary articulation called by Sir Astley Cooper "subluxation of the jaw," in which it is assumed that the condyles slip before the anterior margins of the interarticular cartilages, and thus for the time render the jaw immovable. No positive evidence, however, has ever been presented, either by Sir Astley or others, that any such derangement of the joint apparatus does actually take place, the opinion being based, not upon dissections, but only upon the symptoms which are known to accompany the accident. It is quite probable that this explanation of the phenomenon in question is the true one, yet it is not impossible that, in some rare cases, it has no relation whatever to the interarticular cartilages, but that it indicates a true subluxation of the inferior maxilla upon the zygomatic eminences.

Causes.—It occurs mostly in young people, and in those of a feeble or scrofulous diathesis. Relaxation of the capsule, ligaments, and muscles about the joint may, therefore, be regarded as the principal predisposing cause. The exciting causes are generally yawning, or biting upon some very hard substance.

The symptoms are a sudden arrest of the motions of the jaw, with the mouth about half-open, the arrest of motion being accompanied or preceded generally with a sensation of slipping in one of the articulations. The chin is slightly inclined to the opposite side. The condyle may be felt somewhat advanced in its socket, and while it remains in this position the patient experiences some pain. In most cases the condyle resumes its place spontaneously, or after a slight lateral motion of the jaw; but at other times it requires some little manual force to replace it.

I had, during several years of my early life, while pursuing my studies at college, experienced this accident many times. It was peculiarly prone to occur in the morning, and it became necessary that I should eat with some care at my first meal. Sometimes the locking of the jaw was upon the right and sometimes upon the left side; it was always slightly painful. Generally the condyle was made to fall into place by a voluntary lateral motion of the jaw, but occasionally I was obliged to press gently against the chin with my hand. I never adopted any measures to remove the predisposition, but as I became older the annoyance gradually ceased.

Benevoli, in a dissertation published at Florence, Italy, in the year 1847, describes another condition very analogous to this which we have now described, but which evidently depended upon a contraction of the muscles. A priest, having opened his mouth very widely in gaping, found himself unable to close it. A surgeon who was called diognosticated a dislocation of the jaw, and attempted to reduce it, but failing, Benevoli was called, who, observing "that the jaw was not absolutely immovable, that the articulations were not separated, and that the chin did not incline outward or toward the sternum," concluded that it was only a contraction of the depressing muscles. He therefore prescribed fomentations and oily unctions. The same night the temporal muscles had acquired the size of a couple of eggs, from contraction, but the next day the patient could shut his mouth, and by the following day the tumefaction of the temporal muscles had also disappeared, and the restoration of the functions of the mouth was complete. Malgaigne, to whom I am indebted for the above case, relates two others, one in the person of the surgeon Mothe, and the other in a young man who was suffering from paralysis and spasmodic contractions of the muscles. Mothe observes that it had occurred to him very often, and that it still continued to happen sometimes, and when he gaped pretty widely, the

genio-hyoid and myelo-hyoid muscles contracted with so much force as to render it impossible for him to close his mouth; these muscles being thus in a state of cramp, their bellies became hard under the chin, and so painful that he was obliged immediately to press upward against the under surface of the chin in order to oppose their action. This condition would last from one to three minutes, and was relieved, generally, by frictions made with the hand over the contracted muscles. Sometimes he actually believed that the lower jaw was dislocated, although the result always convinced him that it was not.

Treatment.—In most or all of the cases of this peculiar derangement of the temporo-maxillary articulation, which have come under my notice, a spontaneous cure has been soon effected. It will be proper, however, in all cases, to instruct the patient to avoid using the jaw in a manner to produce the sensation of slipping; and if the general health is impaired, to adopt suitable measures to improve his condition. Cold water affusions to the side of the face and jaw would seem also to be rational measures, and I have generally recommended their use.

CHAPTER III.

DISLOCATIONS OF THE HYOID BONE (THYRO-HYOID ARTICULATION).

DR. RIPLEY, of South Carolina, and Dr. Gibb, of London, have alone furnished us with examples of this accident, but as I am unable to consult the original communications of either of these gentlemen, I will take the liberty of reproducing a brief summary of their papers contained in Mr. Durham's contribution to Holmes's Surgery.¹

"Gibb² has recorded in the following words a case of dislocation of the hyoid bone in a patient under his care: 'The patient, a man, æt. 45, would feel a sudden click in the left side of his neck, which produced a sensation as if something was sticking in his throat. On examination, this appeared to me to depend upon a displacement of the left horn of the hyoid bone, and was generally reduced by throwing the head backward, toward the right side, so as to stretch the muscles of the neck, and then suddenly depressing the lower jaw, and so putting the depressors of the hyoid bone into operation. He died some years after of pulmonary consumption. On examining his throat after death, I found a sort of pouch, which answered the purpose of a synovial capsule, embracing the horns of the left thyro-hyoid articulation. It was filled with a clear fluid, had a comparatively large rhomboid sesamoid bone developed in its outer wall, and permitted an extraordinary amount of motion.' This was the fourth case of the kind which had come under the notice of Gibb. All the patients were males. He subsequently met with a fifth case in which the patient was a female.

"Reference is made in the work quoted to a paper, read in 1848 before the Parisian Medical Society, by Dr. Ripley, of South Carolina, on 'Dislocations of the Os Hyoides, especially illustrated in his own person, and the manner of reducing them.' The latter process consisted in throwing the head backward as far as possible, so as to place the muscles of the neck on the stretch, then

¹ Holmes's Surgery, 2d Amer. ed., vol. ii. p. 460. Art. Injuries of the Neck.

² Gibb, on Diseases and Injuries of the Hyoid Bone, by G. D. Gibb, M.D., Churchill, London, 1862, p. 20, and Trans. Path. Soc., London, vol. x. p. 66.

relaxing the lower jaw, at the same time gently pressing or rubbing over the displaced part, when the displacement becomes reduced after a few attempts with a click. Two cases of dysphagia described by Abercrombie are considered by Gibb to have been examples of double displacement of the thyro-hyoid articulation."

CHAPTER IV.

DISLOCATIONS OF THE SPINE.

THIS accident is, no doubt, exceedingly rare, at least without the complication of a fracture, and it is not improbable that the actual number is smaller than the reported examples would indicate. Those who make autopsies do not always perform their duties with that exact fidelity which might be necessary to determine so nice a point as a fracture of an oblique process, and it is quite likely that the circumstance may have been overlooked in some cases; but a considerable number of well-authenticated examples of simple dislocations of cervical vertebræ have accumulated within the last fifty years. The reported examples of simple dislocations of the other vertebræ are not so numerous, nor as well attested.

Delpech and Abernethy denied the possibility of a dislocation of the spine, either in the cervical, dorsal, or lumbar region, without the concurrence of a fracture. Says Sir Astley Cooper: "I have never witnessed a separation of one vertebra from another through the intervertebral substance, without fracture of the articular processes; or, if those processes remain unbroken, without a fracture through the bodies of the vertebræ." He would not, however, be understood to deny the possibility of a dislocation of the cervical vertebræ, their articular processes being placed more obliquely than those of the other vertebræ.

The causes are in general the same as those which produce fractures of the vertebræ, such as falls upon the head, feet, or back, and violent flexions of the spine backward or to the one side or the other.

Several examples are recorded of "spontaneous" dislocations, the result of some morbid changes in the bones or in the ligaments of the spinal column; which accidents seem to belong more properly to general treatises upon surgery.

The symptoms, also, partake of the same general character with fractures; the accident being accompanied with more or less complete paralysis of those portions of the body which receive their nervous supply from below the point at which the dislocation has occurred; the spinal column presenting at the seat of displacement an angular projection or some form of irregularity; and the distortion being attended with pain, especially when an attempt is made to move the body. In very many cases the symptoms are so nearly like those presented in a case of fracture, that the diagnosis is rendered exceedingly difficult. The presence or absence of crepitus may aid in the diagnosis, and yet it is well understood that this symptom is often absent in simple fractures, and that it

may be present in all those examples of dislocation which are accompanied with a fracture of an oblique process, or of any other portion of the vertebræ, which class of examples constitutes a large majority of the whole number.

There is usually present, however, in the dislocation, whether partial or complete, a peculiar fixedness or rigidity of the spine, which serves to distinguish this accident from a fracture of the spine as plainly as the preternatural rigidity of the limb in dislocations of the long bones serves to distinguish these accidents from fractures of the same bones. The head or upper portion of the spinal column is bent forward, or backward, or more commonly to one side, and in this position it remains immovably fixed until the reduction is accomplished. Sometimes, also, the surgeon may feel distinctly the lateral deviation of the spinous process, and, in the neck, the transverse processes become an important guide in the diagnosis.

§ 1. Dislocations of the Lumbar Vertebræ.

Without wishing to insist upon the actual impossibility of these accidents, I am prepared to affirm that no well-authenticated case has yet been reported—at least of a complete dislocation, unaccompanied with a fracture of the articulating apophyses. I can conceive it possible that a lumbar vertebra may be dislocated forward or backward, and that a dorsal vertebra may be dislocated laterally, without a fracture; but neither of these events can be considered probable. It is certain, however, that no evidence has yet been furnished of the actual occurrence of such a dislocation.

Colquet mentions the case of a "tiler" who fell from the roof of a house backward, and dislocated one of the lumbar vertebræ. This patient lived many years after the accident, and at the autopsy it was found that the second lumbar vertebra had been dislocated to the right by a movement of rotation about the left articular process, the two oblique processes of the left side preserving their connection, while those of the right were separated quite half an inch. The right vertebral plate was broken, and the canal of the vertebra was thus thrown open and widened.¹

Dupuytren says that a man was crushed by the falling of a bank of earth upon his loins, when in the act of bending forward. On the third day he was brought to Hôtel Dieu, when it was observed that his lower extremities were completely paralyzed; and that there existed in the upper part of the lumbar region a hard tumor, by pressure upon which a crepitus was manifest. A second tumor could be distinctly felt in front through the abdominal parietes, and the length of the spine was evidently diminished. This man died on the sixth day from a gradual asphyxia. When the body was examined it was found that the last dorsal and the first lumbar vertebræ had been pushed forward more than one inch, lacerating the spinal marrow, breaking the transverse and oblique processes of the last dorsal and first lumbar vertebræ, and tearing off a small fragment of the body of one of the vertebræ where the intervertebral substance adhered to it.²

Vincent³ presented in 1850 to the Anatomical Society of Paris a complex dislocation of the first lumbar vertebra, with destruction of the extremity of the spinal marrow, and interruption of the nervous function of the cauda equina.

¹ Cloquet, Malgaigne, op. cit., t. ii. p. 390, from Journ. des Différences, tom. i. p. 453.

² Dupuytren, Injuries and Diseases of Bones, Syd. ed., p. 340.

³ Vincent, Bull. Soc. Anat., 1850 (Poinet).

Despite the most complete paraplegia the fracture became consolidated, and the patient survived eight months.

All of these cases were accompanied with fractures. In neither case was any attempt made to reduce the dislocation. In the second, it is scarcely probable that any means could have been employed which would have succeeded in restoring the bones to their places; nor is it probable that, if the bones had been restored to place, the patient would have survived the accident a day longer, probably not so long. The cord was greatly lacerated, and the diaphragm torn up and displaced, rendering a recovery almost impossible. In the first example, where the dislocation was less complete, and the complications less grave, could reduction have offered any reasonable chance for relief? By extension, combined with a movement of rotation in a direction opposite to that in which the displacement had taken place, it is possible that a reduction might have been accomplished. The attempt certainly would have been justifiable; but since the man lived "many years" without the reduction, it is doubtful whether the result of a reduction would have been more fortunate.

§ 2. Dislocations of the Dorsal Vertebrae.

A moment's consideration of the anatomy of these processes will render it apparent that even a partial dislocation forward without a fracture of the oblique apophyses is impossible; and that in the direction backward the dislocation can only occur to the extent of about one-quarter of an inch, constituting only a species of articular diastasis, without breaking off the articulating apophyses of the lower corresponding vertebra.

Malgaigne enumerates twelve examples of dislocations of the dorsal vertebrae. I have found reported by American surgeons, at dates too recent to have been included in his analysis, two other examples. Poincot has added three more cases, one reported by Thompson, of Dublin,¹ a second by Socin, of Bâle,² and a third by himself.³ In Thompson's case there was a complete dislocation of the twelfth dorsal upon the first lumbar, with fracture of the spinous process, accompanied with rupture of the aorta and spinal cord. In Socin's case it was the eleventh and twelfth; and in Poincot's case there was dislocation forward of the twelfth dorsal upon the first lumbar. A portion of the anterior and superior border of the first lumbar was torn off; the left articular and right transverse processes were also broken. The patient survived the accident twenty-four days. I am unable to subject them to a more complete analysis. But of this number only three are claimed to have been simple dislocations, unaccompanied with fracture. One of the fourteen was a dislocation of the fifth dorsal vertebra upon the sixth, one of the eighth, two of the ninth, five of the eleventh, and five of the twelfth; the relative frequency of their occurrence in the different vertebrae corresponding with the observation of Weber as to the points of the spinal column which allow of the greatest freedom of motion, and are consequently most liable to dislocations. The direction of the displacement in ten cases was observed to be six times forward, twice backward, and twice to the one side. Two of those which were unaccompanied with fracture, occurring respectively in the tenth and sixth dorsal vertebrae, were examples of a dislocation forward, and the third, belonging to the ninth vertebra, was a dislocation backward. A lateral dislocation without fracture has not been recorded. It is worthy of remark, also, that these three examples of uncomplicated dislocations, being all which our science up to this moment possesses, have happened in the experience of the same surgeon.⁴

The first two examples, therefore, notwithstanding they have been received without question by Malgaigne, I shall unhesitatingly reject. The third, which

¹ Thompson, Dublin Journ. of Med. Sci., Oct. 1880.

² Socin, 1880.

³ Poincot, op. cit., p. 754.

⁴ Melchiori, Gaz. Medica Stati Sardi, 1850.

alone carries evidence of its having been correctly reported, and which was only a partial dislocation, is related as follows: "A mason having fallen from a height in such a manner that the lower part of his back struck upon the angle of the upper step of a ladder, died on the following day. After death it was observed that the spinous processes of the dorsal vertebræ were prominent down to the tenth; and that the tenth process with all of the processes below were depressed. It was also noticed that this depression, very marked when the trunk was thrown backward, gradually diminished, and finally disappeared altogether when the body was bent forward. On removing the soft parts it was found that the ligaments were extensively torn asunder and detached, so as to permit the articulating apophyses of the tenth vertebra to be carried into contact with the back of the ninth. The spinal marrow had undergone no visible alteration."¹

Malgaigne thinks he has once observed the same thing in a living subject, and that by simply bending the body forward he accomplished the reduction and effected a perfect cure, except that a slight curvature remained at the point of injury.

Among the cases reported as having been complicated with fracture, the following example, reported by Dr. Graves, of New Hampshire, to Dr. Parker, of this city, possesses unusual interest: A man, æt. 25 years, was struck on the back while in a stooping posture by a falling mass of timber, causing a dislocation of the last dorsal upon the first lumbar vertebra. His lower extremities were completely paralyzed, and priapism continued for several hours. The surgeon determined to make an attempt at reduction, and for this purpose he placed the patient upon his face, and secured a folded sheet under his armpits and another around his hips, directing four strong men to make extension and counter-extension by these sheets. Chloroform was administered, and when the patient was completely under its influence the extending and counter-extending forces were applied, and in a few minutes the vertebræ glided into place with a distinct bony crepitus. The restoration of the line of the vertebral column was found to be nearly but not quite perfect. On the sixteenth day he began to have slight sensation in his feet, and at the end of six or eight weeks he was able to control the evacuations from the bladder and rectum. Several months later he had recovered so completely as to walk with only the aid of a cane.²

I know of only one similar case. Rudiger has published an account of a dislocation obliquely backward and to the right side, which occurred at the same point in the spinal column. The subject was a musketeer, who had been struck upon his back by a falling wall which he was endeavoring to pull down. Rudiger laid him upon his belly, and with the assistance of others he was able, but not without causing pain, to reduce the bones. Immediately, however, when the extension was discontinued, the action of the muscles caused the displacement to recur. The surgeon then directed four men to make extension, while another man retained the bones in place by pressing upon them with his hands. After several hours this method of pressure was replaced by a board underlaid with compresses and sustaining a weight of more than fifty livres. On the following day it was found sufficient to bind compresses over the projecting bone, and in this condition the patient remained fifteen days; during all of which time he lay upon his belly with his shoulders more elevated than his pelvis. On the twentieth day he could lie upon his back, and in about six weeks he was so completely restored as to be able to pursue his trade as before!³ This is certainly a very extraordinary case, whether considered in reference to the means employed to restore the bones to place, or to its results; and if the statements are to be received at all, it must be with some hesitation and allowance.

On the other hand, we are able to present at least one example in which, although no reduction has been accomplished, the patient has survived the accident many years; yet it must be admitted that his recovery is far from having been as complete as in the two cases just mentioned.

¹ Melchiori, loc. cit.

² Graves, New York Journ. Med., March, 1852, p. 190.

³ Rudiger, Journ. de Chir. de Desault, tom. iii. p. 59.

J. S., æt. 11 years, was crushed under the body of an ox-cart in such a manner as to produce a dislocation of the last dorsal from the first lumbar vertebra, causing immediately almost complete paralysis of all the parts below. This young man was seen by Dr. Swan, of Springfield, Mass., in the summer of 1834, at which time he was occupied as a portrait-painter. His lower extremities remained paralyzed, and of the same size as at the time of the receipt of the injury. He was unable to sit erect, owing to the mobility of the spine at the seat of dislocation, and he had, therefore, lain constantly upon his side. The upper portion of his body was well developed, and his intellectual faculties were of a high order.¹ A result so fortunate as this, where the bones remained unreduced, is unique; in all the other cases reported the patients died miserably after periods ranging from a few days to one year or a little more.

Charles Bell has related the case of an infant who was run over by a diligence, and who died thirteen months after the accident. On examination after death, the last dorsal vertebra was found to be completely dislocated backward and to the left, upon the first lumbar vertebra.²

With these facts before us, I think we cannot hesitate, when the nature of the accident is fully made out, and especially when the dislocation has occurred in the lower dorsal vertebræ, to attempt the reduction by forcible extension, united with judicious lateral motion, or with a certain amount of direct pressure upon the projecting spines.

§ 3. Dislocations of the Six Lower Cervical Vertebræ.

It is much more common to meet with simple dislocations of the vertebræ of the neck uncomplicated with fractures, than of either of the other vertebral divisions. This is doubtless owing to the greater extent of motion which their articulating surfaces enjoy. They may be dislocated forward or backward. The forward dislocation may be complete or incomplete; with both sides equally advanced ("bilateral" of Malgaigne), or one of the articulating apophyses may be dislocated forward, holding the opposite apophysis in its place ("unilateral" of Malgaigne).

Schrauth³ has collected twenty-four examples of dislocation of the cervical vertebræ, of which four are recorded as dislocations forward, two back, and six to the one side or the other. Three of this number were dislocations of the atlas, two were dislocations of the second vertebra, five of the fourth, two of the fifth, two of the sixth, and one of the seventh. In the other cases the seat was not stated. Malgaigne has brought together forty-five examples; of which twenty-one were complete forward dislocations, nine incomplete forward dislocations, nine unilateral and forward, and four were backward dislocations. Three were dislocations of the second vertebra upon the third, four were dislocations of the third vertebra, ten of the fourth, eleven of the fifth, fifteen of the sixth, and two of the seventh.⁴

Causes.—The bilateral forward dislocations are generally caused by a fall upon the top and back of the head, or upon the top of the head while the neck is very much flexed forward. The unilateral is caused sometimes by a direct blow upon the back of the neck, the blow being probably directed somewhat to one side or the other. It may also be

¹ Swan, Boston Med. and Surg. Journ., vol. xxii. p. 102, March, 1840.

² Charles Bell, on Injuries of the Spine, 1824.

³ Schrauth, Amer. Journ. Med. Sci., May, 1848, from Archiv für Phys. Heilkunde.

⁴ For additional cases see Dublin Journ. Med. Sci., March, 1879, p. 260.

caused by muscular action, and especially by the action of the sterno-cleido-mastoid, as in a sudden movement of the head to one side.

Malgaigne found this to have been the cause in six of the seven cases collected by him. Such also was the fact in the cases reported by Rotter,¹ Foelker,² Koch,³ Schuh, Moxon, Berthold, and Wyeth, to the four latter of which I shall again make reference.

The number of backward dislocations which have been reported are too few to enable us to indicate very accurately the general causes, but it seems probable that they are most often occasioned by a fall upon the fore and top part of the head, received while the neck is bent forcibly back.

Symptoms.—In dislocations of the cervical vertebræ forward the head is usually depressed toward the sternum, in dislocations backward the head is thrown back, and in unilateral dislocations the head is turned over one of the shoulders. Neither of these malpositions of the head is uniformly present in these several dislocations, and indeed not unfrequently, especially in case the system is greatly shocked by the accident, the head and neck assume a preternatural mobility, and may be turned easily in any direction. The spinous process, unless the patient is very fleshy or considerable swelling has supervened, can easily be felt, and its deviations to the right or to the left, forward or backward, furnish us with the most valuable and important sign of the dislocation. Even the transverse processes may be felt sometimes, especially in the upper part of the neck, with sufficient distinctiveness to render them useful in the diagnosis. To these circumstances we may add paralysis of the body below the seat of injury, with pain and swelling at the point of dislocation. In some cases also the patient has himself distinctly felt a cracking or sudden giving way in the neck at the moment of the accident.

Prognosis.—The complete bilateral dislocations, whether backward or forward, have in most cases terminated fatally within a short time, generally within forty-eight hours. Unilateral dislocations are less speedy in their results, but when the dislocation remains unreduced, death generally takes place in a month or two.

Lente relates a case of incomplete dislocation of the fifth cervical vertebra backward, unaccompanied with fracture, which accident the patient survived five days.⁴ A patient of Roux's lived eight days; but in the case of a second patient mentioned by Lente, with a complete dislocation, without fracture, of the fifth vertebra, the patient survived the injury only two hours.⁵

On the other hand, occasional examples are presented of partial or complete recovery with the dislocation unreduced.

Horner, of Philadelphia, presented to the class of medical students of the University of Pennsylvania, in 1842, a lad, æt. 10, who had fallen a distance of twenty feet, alighting upon his head. He was found senseless and motionless, with his head bent under his body. He gradually recovered from the shock, but his neck was stiff, distorted and motionless, his face being inclined down-

¹ Poincot, *op. cit.*, p. 758.

² *Ibid.*

³ *Ibid.*

⁴ Lente, *New York Journ. Med.*, May, 1850, p. 284.

⁵ Lente, *ibid.*, p. 397.

ward to the right side. Two days after, his "common and accurate perceptions returned, but he was affected for some time with tingling and numbness in his left arm." When presented to the class the transverse processes, from the fifth upward, were about half an inch in front of those below, showing that the left oblique process of the fourth was dislocated forward upon the fifth. The rotary motions of the neck could not be executed to some extent, but much more freely to the right than to the left. Professor Horner refused to make any attempt to reduce the dislocation.¹

Dr. Purple, of New York, has reported a case of what was called a dislocation of the fifth and sixth cervical vertebræ, producing complete paralysis of the lower part of the body, in which the patient survived the accident many years; but his lower extremities were so useless and cumbersome as to induce him, in the year 1851, six years after the injury had been received, to submit to the amputation of both at the hip-joint. In 1852, having become very intemperate, he died, but no autopsy was obtained, so that the exact character of the injury was never ascertained.² Sanson, of Paris, has reported also a case which came under his observation at Hôtel Dieu, of dislocation of the "third cervical vertebra backward," from which, although unreduced, the patient partially recovered. The character of this accident was not much better determined; for, although he felt a severe and sharp pain at the moment of the injury, which was greatly aggravated by motion, and his head was bent forward and to the left, "the chin being fixed on the upper part of the sternum," there was no paralysis of either the motor or sentient nerves. After the lapse of about four months he left the hospital, still unable to lift his chin more than four inches from the sternum; after which he resumed his usual occupations, suffering no further inconvenience than what was occasioned by the unnatural position of his head.³ Notwithstanding the authoritative testimony of Sanson that this was a dislocation backward, one cannot avoid the conclusion that it was either an incomplete unilateral dislocation, or perhaps a mere diastasis of the articulation, or else that it was an example of sprain of the muscles, and consequent contraction of one set, or paralysis of the opposing set of muscles. It is certain that it was not a complete dislocation; nor, since there was no paralysis of the body below the point of injury, can it be properly made use of as an argument for non-interference where such paralysis does actually exist.

Poinsot saw, in 1883, a case occurring in a man aged 35 years, caused by the fall of a heavy weight upon his head while it was in a position of extension. He lost consciousness at once, but when he recovered his senses after a few moments there was no paralysis. On the following day when examined by Poinsot, the symptoms seemed to point to a dislocation of the fifth cervical vertebra upon the sixth, but no attempt at reduction seems to have been made. Gradually the head regained its position and motions, but after a time, and at the date of the last observation, more or less of the deformity and immobility continued to exist.⁴

Treatment.—The following cases illustrate what encouragement attempts at reduction may offer in cases which present so little ground of hope where the reduction is not accomplished.

Dr. Spencer, of Ticonderoga, N. Y., relates that a man, æt. 50, fell backward from a board fence, striking upon the superior and anterior portion of his head, dislocating the second from the third vertebra of the neck. His head was thrown back so far as to prevent his seeing his own body, and all below the injury was completely paralyzed. Repeated attempts were made to reduce the dislocation, "but the transverse processes had become so interlocked that every effort proved abortive," and he died forty-eight hours after the injury was received.⁵ Gaitskill also attempted reduction in a case of dislocation of the

¹ Horner, *Amer. Journ. Med. Sci.*, April, 1843, from *Med. Exam.*

² Purple, *New York Journ. Med.*, May, 1853, p. 319.

³ Sanson, *Amer. Journ. Med. Sci.*, Feb. 1836, p. 514, from *Gaz. des Hôpitaux*.

⁴ Poinsot, *op. cit.*, p. 761.

⁵ Spencer, *Boston Med. and Surg. Journ.*, vol. xv. No. 11.

seventh cervical vertebra, but failed.¹ Boyer failed in two cases. It is related by Petit Radet, that a young patient at La Charité expired in the hands of the surgeons, upon such an attempt being made a few days after the accident;² and Dupuytren says "the reduction of these dislocations is very dangerous, and we have often known an individual perish from the compression or elongation of the spinal marrow which always attends these attempts."

Dr. Schuh, of Vienna, relates that a man, æt. 24, while engaged at his work twisted his head suddenly round, in consequence of one of his companions roaring into his ear, when he instantly felt something give way in his neck, and found it impossible to move his head. Next morning his head was turned to the right and bent down toward the shoulder. Every attempt to move his head caused great pain. He complained of weakness in his right arm, but all the other functions of his body were perfect. An attempt was immediately made to reduce the dislocation by lifting him by the head, but without success. On the second day the weakness and numbness of the right arm had increased, and the attempt to reduce the bones was renewed. The patient was laid horizontally upon a bed, and extension made from the chin and occiput while counter-extension was made from the shoulders. The force thus employed was gradually increased until the patient and assistant felt a snap as of two bones meeting, when it was found that the head was restored to its natural position, and the power of moving it had returned. The next day his arm was more powerless than before, and on the following day he had vertigo, but these symptoms soon yielded to copious bleedings, and he left the hospital cured on the 13th.³

Dr. Hickerman, of Ohio, has also reported a case of dislocation of one of the cervical vertebræ. By exploring the pharynx a prominence was felt opposite the junction of the fourth and fifth cervical vertebræ; and the action of the heart was barely perceptible. Seizing the patient's head under his left arm, Dr. Hickerman in this manner made traction, while with the index finger of the right hand in the patient's throat, he made firm pressure obliquely upward, backward, and to the left; after continuing the pressure for about forty or fifty seconds, the part against which the finger was placed gradually yet quickly receded in the direction in which the pressure was made, and instantly, as quickly indeed as the act could be possibly executed, the patient opened her eyes, and natural respiration was established. She then almost immediately became conscious of what was transpiring about her, and signified by signs, for she was yet unable to speak, that she had suffered pain in the epigastrium. Complete recovery took place.⁴

Schrauth received under his care a patient who had a dislocation of the "right transverse apophysis" of the fourth cervical vertebra, without lesion of the spinal marrow, which he reduced on the seventh day. The first attempt was unsuccessful; but the second, made with great caution, by the aid of four assistants, three of whom pulled the head upward, while the fourth pressed with his whole weight upon the shoulders, was completely successful. During the time that the traction was being made, the head was occasionally rotated slightly and moved laterally, and at the same moment the surgeon pushed firmly against the displaced apophysis. The reduction was attended with "various distinct crackings in the neck," which were loud enough to be heard. After some days of repose he resumed his occupation, no stiffness remaining in the movements of the neck.⁵ According to Malgaigne, Newman and Seifert have each reported one successful case, while Barny and Malgaigne have each met with two analogous examples successfully reduced.

Dr. Maxson, of Geneva, N. Y., was called to see a child about 9 years old, who had met with a similar accident about forty hours before, namely, a dislocation of the right articulating apophysis of the fifth or sixth cervical vertebra, occasioned by suddenly turning her head around while at play. She at first complained only of pain and inability to straighten the neck; but whenever

¹ Gaitskill, London Repository, vol. xv. p. 282.

² Petit Radet, Note to Boyer, *Malad. Chir.*, vol. v. p. 115.

³ Schuh, *Amer. Journ. Med. Sci.*, July, 1841, p. 207.

⁴ Hickerman, *Buffalo Med. Journ.*, vol. x. p. 702, April, 1855.

⁵ Schrauth, *Amer. Journ. Med. Sci.*, May, 1848.

moved she became faint and irritable. A short time before the surgeon was called, the mother had, in attempting to move her in bed, turned the face a little more to the left, when a severe convulsion immediately ensued. On examining the neck, Dr. Maxson discovered the displacement of the transverse process. Having advised the parents of the danger necessarily incident to an attempt at replacement, and of the probable consequences of its being permitted to remain as it was, they consented that the trial should be made. "I grasped the head," says Dr. Maxson, "with both hands, and proceeded according to Desault's method, only I first carried or turned the face very gently a little further toward the left shoulder to disengage, if possible, the process; then lifting or extending the head, I turned the face very gently toward the right shoulder, when the difficulty was at once overcome, and she exclaimed: 'I can move my eyes.' Her countenance soon acquired a more natural appearance; the faintness passed off; she rested quietly through the night: had no return of the difficulty, and needed only an emollient anodyne to soothe the irritation and slight swelling which remained at the point of injury."¹

Dr. Berthold, of Nuremberg, reduced a dislocation of one of the oblique processes of the sixth vertebra in a boy, *æt.* 19 years, by extension with his hands and rotation.² Dr. Wm. J. Morton, of New York, has reported a case of dislocation of the fifth oblique process in a boy 12 years old, reduced after the lapse of one week, by suspension of the head between the hands and rotation.³ Dr. John A. Wyeth, of this city, relates a case of dislocation of the right articular process of the fourth vertebra forward, from muscular action, in the person of a lady who had turned her head strongly to the left side. Her head became fixed immovably; there was great pain at the point of this articulation; oppressed breathing and a numbness extending down the arm of the same side. Dr. Wyeth was immediately summoned and attempted to rotate the head into position, but was unable to do so. He then seized the head and rotated it slightly to the left, then made strong extension and rotated to the right, when the head returned to and retained its natural position. During the next two days there was considerable pain along the spinal cord and in the right arm. Three months after the accident she was perfectly well.⁴ Rust,⁵ Wood,⁶ of this city, and others, have seen and reported similar cases attended with like success.

So far, the cases of successful reduction to which I have referred were examples of dislocation of only one of the articulating apophyses, and they have been sufficiently numerous and successful to establish the value of attempts at reduction. I have now to relate a case in itself almost unique, namely, a successful reduction of a dislocation of the fifth cervical vertebra, in which both apophyses appear to have been thrown forward. It occurred in the practice of Dr. Daniel Ayres, of Brooklyn, N. Y., and will be best understood by a reproduction of his own published account of the case:

"E. K., the subject of this accident, was a laboring man, 30 years of age, tall and muscular, but not fat, with a neck longer than the average among men of equal height. On the evening of the 2d of October he became intoxicated; was brought home insensible, and did not recover from the combined effects of the shock, and his libations until the following morning, when he was supposed by his wife to be laboring under cold and a stiff neck. She made some domestic applications to the affected part, and administered a dose of cathartic medicine. When it was thought sufficient time had elapsed without obtaining relief, he was

¹ Maxson, Buffalo Med. Journ., Jan. 1857, p. 476.

² Berthold, Month. Ab. Med. Sci., June, 1875.

³ Morton, Med. Record, Oct. 4, 1879.

⁴ Wyeth, Hosp. Gaz., N. Y., Aug. 1879.

⁵ Rust, Chelius, note by South.

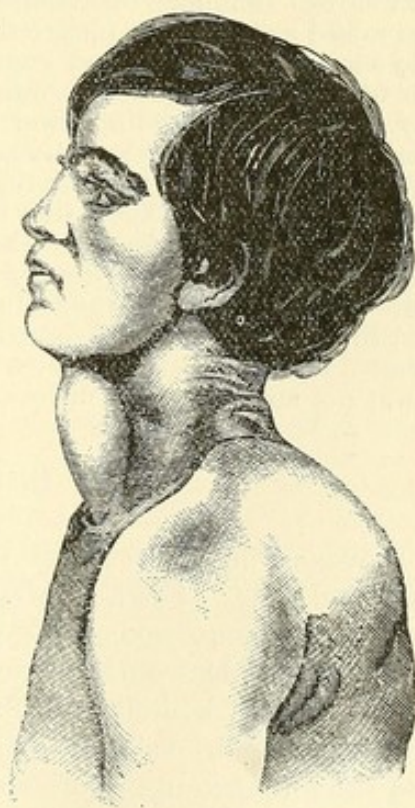
⁶ Wood, New York Journ. Med., Jan. 1857, p. 13.

seen by Dr. Potter, of this city, and afterward by Dr. Cullen, both of whom recognized a condition which was not only very unusual, but one which they had never before observed. I was then requested to examine the case, which I did on the ninth day after the accident. With some assistance, and great personal effort he was able to get out of bed, moving very slowly and cautiously. Desiring to expectorate, he was obliged to get down on his hands and knees, which he accomplished with the same deliberation. When seated on a chair, the head was thrown back and permanently fixed; the face turned upward with an anxious expression. The anterior portion of the neck, bulging forward, was strongly convex, rendering the larynx very prominent. The integuments of this region were exceedingly tense and intolerant of pressure. The posterior portion of the neck exhibited a sharp, sudden angle at the junction of the fifth and sixth cervical vertebræ, around which the integuments lay in folds. It was difficult to reach the bottom of this angle even with strong pressure of the fingers, and, of course, the regular line formed by the projecting spinous processes was abruptly lost. He complained of intense and constant pain at this point, which was neither relieved nor aggravated by pressure. With difficulty he swallowed small quantities of liquid, pausing after each effort, and could not be induced to take solid food, since the first attempt to do so after the accident was followed by violent paroxysms of coughing and choking. His breathing was obstructed and somewhat labored, being unable fully to clear the bronchi of their secretion. This, however, seemed rather an effect of the tense condition of the soft parts of the neck, than the result of pressure upon the spinal cord, since he presented no evidence of paralysis, either of motion or sensation, in parts below the neck. The sterno-cleido-mastoid muscles of both sides were felt quite soft and relaxed.

"But one conclusion could be formed upon this state of facts, to wit: that the oblique processes of both sides were completely dislocated. The marked rigidity of the head seemed to preclude the probability of fracture through the vertebral bodies, and although the cartilage might be separated anteriorly, yet the body not pressing backward sufficiently to produce paralysis of the cord, it was hoped that the posterior vertebral ligament remained uninjured; it was, therefore, determined to make an effort at reduction on the following day. In addition to those originally connected with the case, I am under obligations to Drs. Ingraham, Turner, Palmedo, G. D. Ayres, and a number of other medical gentlemen, who were present by invitation, all of whom confirmed the diagnosis, and rendered efficient services.

"The patient was placed upon a strong table, in a recumbent position, with a pillow resting under the shoulders, the head being supported by the hand during the administration of chloroform, of which an ounce was given before anæsthesia ensued. Counter-extension being made by two folded sheets placed obliquely across the shoulders and properly held, the head was grasped by one hand placed under the chin, the other over the occiput, and by steadily and firmly drawing the head directly backward, and then upward, an attempt was made at reduction, but failed for want of sufficient power. Dr. Ingraham was then requested to place his hands immediately over my own in the same position as before, and steady traction was again made in the same direction. Our united strength was required in drawing the head backward and upward to dislodge the superior

FIG. 344.



Ayres's case of bilateral dislocation of the fifth cervical vertebra.

oblique processes from their abnormal position. When this was felt to be yielding by Dr. Cullen (who kept one hand constantly at the seat of dislocation), Dr. Potter was directed to place his hands under our own, still in position, and assist in bringing the head forward; at the same time the chest was depressed toward the table. The bones were distinctly felt to slip into their places; the line of the spine was instantly restored, the head and neck assuming their natural position and aspect. As soon as the patient became conscious, he expressed himself ignorant of what had taken place, but free from pain, and, in his own language, 'all right.' A bandage was arranged to support the head and keep it bent forward. He had an anodyne for two nights following, after which no further treatment was necessary, and at the end of one week he had complete control over the movements of the head and neck. Beyond the debility and emaciation immediately dependent upon protracted fasting and loss of rest, he has experienced no uneasiness since the operation. His appetite is now good, and all the functions perform their duty normally. In a subsequent inquiry, to determine, if possible, the cause of the accident, he states that he distinctly recollects going into a store in Atlantic Street, near the ferry, and there having angry words with an acquaintance; that he left the store, and was proceeding up the street (which is here a rather steep ascent), when he was violently struck from behind, over the lower portion of the neck. He likewise remembers falling forward, and striking against some object, but he does not know what it was, nor what took place until the following morning."¹

So far as I know, the only other example of supposed successful reduction of a complete bilateral dislocation of these vertebræ has been reported by Vriennonneau;² but of which Malgaigne expresses some doubt as to whether it was an example of partial or complete dislocation. After alluding to Gosselin's success upon the cadaver, Malgaigne says:³ "Some surgeons have even thought that they had obtained it upon the living subject. M. Vriennonneau was called to see a man 39 years of age, who had just fallen upon the head from a height of six metres. The face was bent upon the chest; the whole body was rigid, and was raised as if all of a piece; the patient, however, could still move his limbs. The surgeon diagnosticated—but he does not say how—a dislocation forward of the fifth cervical vertebra; and at first he did not dare to interfere. The next day, however, all the limbs were paralyzed; the following day death was imminent, as shown by the stertorous respiration and by the almost imperceptible pulse; he then concluded to try the reduction, which was accomplished with a distinct *craquement*. From that time all the symptoms subsided as if by enchantment, and two months later the man could work, there remaining only some stiffness in the neck, especially during the lateral movements, which remained quite limited. I praise the fortunate determination of the surgeon; but I regret that the diagnosis was not more fully established; and even while admitting the forward dislocation, the absence of paralysis(?) leaves one in doubt as to whether it was not an incomplete dislocation, such as those we are about to consider."

§ 4. Dislocations of the Atlas.

Surgeons have met with several forms of displacement between the atlas and axis. First, a forced inclination forward of the atlas upon the axis; in consequence of which the body or anterior arch of the atlas is made to recede from the odontoid process, and the transverse ligament glides upward without breaking; so that the extremity of the odontoid process comes to occupy a position underneath or behind the ligament, and thus presses upon the cord. It is apparent, also, that this form of displacement cannot occur without a rupture of the vertical ligaments which bind the transverse ligaments to the axis; nor without a separa-

¹ Ayres, New York Journ. Med., Jan. 1857, p. 9.

² Vriennonneau, Journ. des Conn., Méd. Chir., t. 1, p. 21.

³ Malgaigne, op. cit., t. 2, p. 363.

tion of the atlas from the axis posteriorly and a rupture of the posterior atlo-axoidean ligament. Second, a similar inclination of the atlas, accompanied with a rupture of the transverse and superior vertical ligaments, in consequence of which also the odontoid process is allowed to fall upon the cord. Third, the atlas in the same position, with the odontoid process broken at its base. Fourth, the atlas displaced directly forward or backward. Fifth, a displacement of only one articular process in a direction forward; and sixth, a displacement of one articular process forward, and of the other backward.

I have already, when speaking of fractures of the atlas, or of the atlas and axis together, called attention to several examples of that form of the dislocation which is accompanied with a fracture of the odontoid process. The other forms of dislocation are characterized by so few symptoms peculiar to themselves, or which can be regarded as diagnostic and not already sufficiently studied in connection with other dislocations of the neck, that I shall not deem it necessary to do more than remind my readers, that if permitted to remain unreduced a speedy and fatal issue is inevitable, and to point them to some examples of recovery, after reduction has been fortunately accomplished. These may suffice to show that Dupuytren was in error when he declared that such accidents were wholly beyond the resources of our art.

An old man received upon his head a bundle of hay cast from the top of a wagon. He fell with his head bent forward so that his chin touched the top of the sternum, and in this position it remained immovably fixed; all the other portions of his body preserving their natural functions. A surgeon, who was indeed the father of Malgaigne, being called, assured the patient, that unless he could give him relief he certainly would die; but that inasmuch as the attempt might itself prove fatal, he ought at once to put in order his affairs. Accordingly the man partook of the sacrament; then the surgeon seated him upon the ground, and placing himself at his back with his knee resting upon his shoulders for the purpose of making counter-extension, and with a towel brought over his own shoulders and under the chin of the patient for extension, he proceeded to act upon the neck in the direction of the axis of the spine. The efforts were long and painful; but at last, while the head was lifted, as far as possible, it was suddenly drawn backward, and immediately it resumed its natural direction. Absolute quietude was enjoined, and the patient recovered in a short time and without any accident.

Another example is related by Ehrlich, but in this case the dislocation was backward. A young man, *æt.* 16, while carrying a sack of flour up a ladder, fell backward, and the sack falling over upon his face and head came to the ground before him. He was found lying with his head thrown back and to the right, the head resting upon the scapula of this side, but having so completely lost its "solidity" that by its own weight it would fall from one side to the other. On the front and left side of the neck there existed a prominence supposed to be formed by the atlas; the patient was unconscious; the pulse was scarcely perceptible, and the whole body was suffering under paralysis. Ehrlich directed the shoulders to be held by one assistant, and the head to be drawn upon by another, while he pressed with his own hands forcibly upon the displaced atlas from behind. After several fruitless attempts, the reduction took place, accompanied with a sound distinctly audible to all of the assistants; the head resumed its position firmly, and the arms began to move. The head was afterward maintained in place by a bandage. The cure proceeded rapidly, and after a time no trace of the injury remained but a disagreeable tension in the nape of the neck whenever he moved his head briskly to the one side or the other.¹

¹ Malgaigne, Ehrlich. Malgaigne, *op. cit.*, tom. ii. p. 334.

Peabody,¹ in the case of a man who had subluxation of the atlas, occasioned by a fall from a height upon his head, and in whom death seemed imminent, succeeded after several trials. The patient was unconscious, his eyes were closed, and his pupils dilated. Immediately upon the reduction having been effected, which was accompanied with a violent *craquement*, the patient opened his eyes, spoke to those who were about him, and complained of pain in the back of his neck. On the following day he could be considered as in his normal condition.

Uhde, Wagemann, and Boettger, of Braunschweig, report a case of bilateral dislocation of the atlas, in which the right inferior articular process of the atlas was displaced forward, in front of the corresponding superior articular surface of the axis, and the left inferior articular surface of the atlas backward, behind the corresponding superior articular surface of the axis, as shown by the position of the left transverse process of the atlas. "The patient, a roofer, fell from a height of thirty feet. The head was rotated upon all three of its axes, the right half of the face being turned forward, the facial line forming an angle with the median line of the body, and the chin thrown forward, and the forehead backward. On the left side there was paralysis of the plexus pharyngeus and the hypoglossal nerve; on the right, simply paralysis of the glosso-pharyngeus. Careful anatomical and experimental research proved that the injuries of the nerves depended upon the dislocation. The nervus accessorius W. also suffered at a point corresponding to that on the hypoglossus, and to this the paralysis of the left velum palati, observed in the patient, was attributed; the plexus pharyngeus, of which the anterior branch of the accessorius forms a part, suffering by traction on the trunk of the nerve. The experiments also proved that, in this dislocation the cord is not subjected to pressure, and that the vertebral artery is not injured. The dislocation was partially reduced two days after the accident by extension, extreme flexion of the head on the left shoulder, and rapid rotation backward and to the right, together with direct pressure upon the left transverse process of the atlas. The condition of the patient improved materially after extension had been made for some time with Glisson's apparatus. After the lapse of several weeks the patient was able to move his head in every direction. Barely a trace of the paralysis remained."²

Bernhuber³ treated a young man who had fallen, striking the back of his neck upon a piece of furniture. He lost consciousness, but when a point opposite the atlas was pressed upon he became convulsed. On the second day the convulsions were continuous, and death seemed imminent. The surgeon seized the head with both of his hands, and made traction upward, when the patient opened his eyes and became conscious. By means of bandages and a gallows the head was maintained in that position. All symptoms at once disappeared, but it was observed that whenever the extension ceased and the head was permitted to fall upon the trunk, the somnolency was prone to return, and for this reason the extension was continued. The patient recovered, with only a slight rigidity of the neck.

§ 5. Dislocations of the Head upon the Atlas, or Occipito-atloidean Dislocations.

It is unnecessary to say that only in examples of partial dislocation of the head could a hope be entertained that surgical resources would be of any avail; and even in these cases death has, in all the reported examples, taken place too speedily to permit surgical interference.

Lassus, Palletta, and Bouisson⁴ have each reported one example of this dislocation. In neither case was the dislocation complete, but death occurred speedily

¹ Peabody, Boston Med. and Surg. Journ., 1876, vol. ii. p. 79.

² St. Louis Courier of Med., Jan. 1879, from Arch. für klin. Chirurg. Sept. 1878.

³ Bernhuber, Denucé, Art. Region Atloïdienne, Nouv. Dic. de Méd. et de Chir. Prat. t. 3, p. 809. (Poincot, op. cit., p. 722.)

⁴ Lassus, Palletta, Bouisson. Malgaigne, op. cit., p. 320.

in every instance. Dariste exhibited to the Anatomical Society of Paris, in 1838, a specimen of incomplete dislocation of the occipito-atloidean articulation, with stretching of the transverse ligament; the patient from whom the specimen was taken having lived more than a year after the accident, when he died from a tubercle in the brain.¹

Milner, of London,² has reported a case of complete dislocation of the head upon the atlas. A man, æt. 38, fell from a height of seventy feet, and was killed instantly. On examination it was found that all the ligaments uniting the occiput with the atlas were ruptured, and dislocation was complete. The posterior arch of the atlas was fractured; the spinal marrow, the two arteries, and the two vertebral veins were ruptured.

CHAPTER V.

DISLOCATIONS OF THE RIBS.

THE ribs may be separated from the bodies of the vertebræ, from the cartilages of the ribs, and from each other. The cartilages of the ribs may also be separated from the sternum.

§ 1. Dislocations of the Ribs from the Vertebræ (Vertebro-costal).

The heads of the ribs are joined to the bodies of the vertebræ by strong ligaments. The articulations are ginglymoid, admitting of motion chiefly in the direction of the axis of the spine. The mobility gradually increases as we proceed from the first rib downward to the last. Each joint is furnished with a capsule. The necks and tubercles are also united to the transverse processes by ligaments, and the articulations are furnished with synovial capsules. I am not aware that any examples have ever been reported of dislocations of the ribs from the transverse processes.

Examples of dislocation of the heads of the ribs have been mentioned by Ambrose Paré, Bransby Cooper, Alcock, Donnie, Henkel, Kennedy, Buttet, and some others; but most of these reputed cases have not borne the test of a critical analysis, and while Vidal (de Cassis) is in doubt whether the claims of even one have been fully established, Boyer denies absolutely its possibility. We see no reason, however, to question the authenticity of several of these examples. The case mentioned by Bransby Cooper, although very briefly narrated, leaves no room for doubt as to its real character. "Mr. Webster, surgeon to St. Albans, when examining the body of a patient who had died of fever, found the head of the seventh rib thrown upon the front of the corresponding vertebra, and there ankylosed. Upon inquiry, Mr. Webster learned that this gentleman, several years before, had been thrown from his horse across a gate, for which accident he had been subjected to the treatment usually followed in fractures of the ribs, and there is every reason to believe that it was at this time the dislocation occurred."³

¹ Dariste, Amer. Journ. Med. Sci., Nov. 1838, p. 237, from Archives Gén., May, 1838.

² Milner, St. Barthol. Hosp. Rep., vol. x.

³ Webster, B. Cooper's ed. of Sir Astley Cooper, Amer. ed., p. 450.

Causes.—These accidents seem to have been generally occasioned by a fall or a blow upon the back, and the dislocation has been accompanied, usually, with a fracture of some other rib, or of the transverse or spinous processes of the corresponding vertebræ. The head of the rib has always been found to be displaced inward. The lower ribs, including the false and floating, are those which have been most frequently displaced.

Symptoms.—It would be difficult, if not impossible, during the life of the patient, to make a positive diagnosis, since the symptoms resemble so closely those which accompany a fracture of the rib near its posterior extremity. The nature of the accident producing the dislocation, the depression, mobility, and pain, are equally indicative of a fracture; while the failure to detect crepitus might easily be explained by the thickness of the muscular wall at this point, or by the riding, or by other displacements of the broken fragments. Chelius speaks of a peculiar "rustling," perceived when the body and ribs are moved by the surgeon or by the patient himself, and which is different from the sensation produced by emphysema or fracture.

The treatment ought to be the same which would be adopted in case the rib was broken. Replacement of the dislocated bone must be regarded as impossible; and it only remains that we insure quiet as far as possible in this portion of the chest, and combat the pain and inflammation by suitable remedies.

The circular bandage, however, recommended in these cases by Sir Astley Cooper, could only be serviceable in dislocations of those ribs which have an attachment to the sternum. The floating ribs, which have been found dislocated quite as often as either of the others, could derive no support from circular pressure, or from any other mechanical contrivance.

§ 2. Dislocations of the Cartilages of the Ribs from the Sternum (Chondro-sternal).

The cartilage of the first rib has no proper articulation at either extremity, but the remaining six upper ribs, where they join the sternum, are furnished with synovial capsules. In old age these articulations generally disappear, but not always.

Charles Bell observes: "A young man playing the dumb-bells, and throwing his arms behind him, feels something give way on the chest; and one of the cartilages of the ribs has started and stands prominent. To reduce it, we make the patient draw a full inspiration, and with the fingers knead the projecting cartilage into its place. We apply a compress and bandage, but the dislocation is with difficulty retained." Ravaton, Manzotti, and Monteggia have each, according to Malgaigne, reported one example of traumatic dislocation; in all of which the cartilages were thrown forward in advance of the sternum. When treating of fracture of the sternum, I have related one case, which came under my own observation, of dislocation of three or four cartilages at the same time.

Dr. Flagg, of St. Paul, Minn., relates the following case: A girl, æt. 10, while playing with several children, ran violently against the corner of an ordinary deal-table. It is stated that the child was faint and breathed with difficulty for a short time, but soon returned to play. No swelling or other evidence of injury was observed by her friends. About forty-eight hours after receiving the injury, while exercising somewhat violently, she complained of sudden pain at the left

costo-sternal articulation and a sensation of something having given way. Soon afterward I saw the child for the first time, and found a slight non-crepitant swelling at the latter point, and the sternal extremity of the cartilage of the fourth rib displaced forward, its posterior surface being very nearly on a plane with the anterior surface of the sternum. A minute fragment of bone unconnected with the sternum or cartilage was noticed, which I took to be a fragment chipped off from the margin of the articular depression on the edge of the sternum. Neither pain nor embarrassed respiration was notably prominent; crepitus could be detected, but not very distinctly; preternatural mobility was very evident."¹

By pressure alone restoration has generally been effected, the cartilage resuming its position suddenly and with a sound. The reduction may, nevertheless, be facilitated by bending the trunk backward, or by directing the patient to make a full inspiration. To maintain the reduction has been found more difficult, and Sir Astley directs that "a long piece of wetted pasteboard should be placed in the course of three of the ribs and their cartilages, the injured rib being in the centre; this dries upon the chest, takes the exact form of the parts, prevents motion, and affords the same support as a splint upon a fractured limb. A flannel roller is to be applied over this splint, and a system of depletion pursued, to prevent inflammation of the thoracic viscera." Instead of the pasteboard, we might use either felt, sole-leather, or gutta-percha.

Mr. Bransby Cooper says that a baker's boy applied for relief at Guy's Hospital, who was the subject of displacement of the cartilages of the fifth and sixth ribs from their junction with the sternum, produced partly by the constant action of the pectoral muscles in kneading bread, but principally by his defective constitution.²

The outer extremities of these cartilages being continuous with the bony structure of the rib, and destitute, therefore, of articular or synovial surfaces, may be subject to fracture, but not, properly speaking, to dislocation.

§ 3. Dislocations of One Cartilage upon Another.

The cartilages on the sixth, seventh, and eighth ribs are furnished at their lower borders with a true arthrodial joint, by which they articulate with the corresponding cartilages. This arrangement sometimes extends to the fifth and ninth ribs. A displacement of these articulations may take place when one falls upon his back, striking upon some projecting body, so that the chest is suddenly thrown forward; in consequence of which the upper margin of the lower cartilage is depressed and entangled behind the lower margin of the upper. The inferior cartilage is, therefore, the one which is displaced rather than the superior, although this latter, being made prominent by the pressure of the other from behind, seems alone to be displaced. Boyer, Martin, and Malgaigne³ have each reported one example. It is probable that the contraction of the pectoral and abdominal muscles has a chief agency in the production of these

¹ Flagg, *Northwestern Med. and Surg. Journ.*, Aug. 1871.

² B. Cooper's ed. of Sir Astley Cooper, etc., *op. cit.*, p. 447.

³ Malgaigne, *op. cit.*, p. 398.

dislocations, and that they are not solely or directly due to the shock of the accident.

The treatment consists in pressing firmly upward and backward against the inferior margin of the upper, or overlapping rib, so as to disengage it from the lower, when by its own elasticity it will resume its natural position. The reduction might also be aided by a full inspiration.

CHAPTER VI.

DISLOCATIONS OF THE CLAVICLE.

OF 57 dislocations of the clavicle observed and recorded by me, 13 belonged to the sternal end and 44 to the acromial. Of those belonging to the sternal end, 11 were dislocations forward, forward and upward, or forward and downward, and 2 were upward. I have never met with a dislocation backward. Of the acromial dislocations the whole number were dislocations upward, or upward and outward.

§ 1. Sterno-clavicular.

Dislocations of the Sternal End of the Clavicle Forward.—This accident is generally caused by a fall upon the point—outer surface—of the shoulder, in consequence of which the sternal end of the clavicle is driven forcibly inward and forward. It is probable, also, that the blow which produces the dislocation is received rather upon the anterior and outer than exactly upon the outer face of the shoulder. A sudden effort of the muscles, as in the attempt to balance a weight upon the head, or to throw the shoulders backward when under drill, has been known also to produce this dislocation. In one example, it was occasioned by placing the knee against the spine and drawing the shoulders forcibly back. Various other accidents, the philosophy of whose agency is not so easily explained, are said to have produced the same result; but it is not improbable that in many of these cases the precise manner in which the injury was received has not been correctly understood or reported.

Mr. Fergusson has once seen this displacement in a newly-born infant, which had happened during birth. It could be replaced with ease, but immediately slipped out again when left to itself. "Nothing was done; a new joint formed, and the child afterward possessed as much power in the one arm as in the other;"¹ and Dr. Shaw, of Pittsburg, Pa., has also seen a congenital case.² The following is an example of double forward dislocation at the sternal end: A. M., æt. 17, in a collision on the railroad, was thrown violently, it is supposed, against the door, striking her left shoulder, and then by a rebound striking the floor of the car with the right shoulder. I saw her on the fourth day after the accident. Exposing her shoulders, we observed an extensive ecchymosis on the outer surface of the right shoulder, extending some distance down the arm. While seated in a chair both clavicles were subluxated forward and a little upward, the right ascending a little higher than the left. She could not raise her arms

¹ Fergusson, *System of Practical Surgery*, Amer. ed., 1853, p. 203.

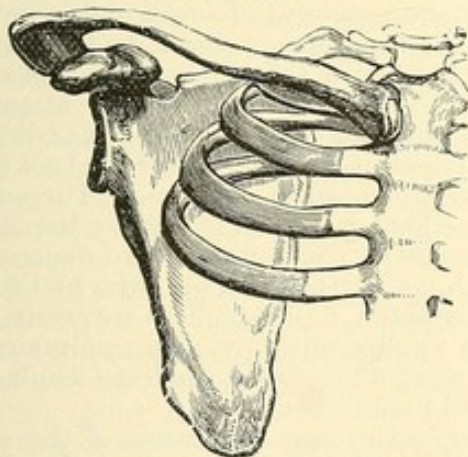
² Shaw, *Med. Record*, Aug. 18, 1877.

to her head; but when lifted to this position the dislocations became complete, and when let fall bones would resume their positions of subluxation with a click. The bones could not be pushed completely into their sockets, and pulling the shoulders back increased the displacement; but when lying flat on her back they went nearly into place. At my suggestion, she was kept in this position six weeks, but with no result; the bones still becoming displaced whenever she got up. Some months after the accident she was still suffering from the general disturbance to her spine and nervous system caused by the shock, and the arms had not recovered their original strength. It seems probable, from the history of the case as subsequently ascertained, that there had existed prior to the accident a laxity of the capsule, permitting of the existence of a partial displacement, and which was rendered complete by the traumatism.

[Duckett,¹ of Manchester, reports a case of ante-sternal dislocation which occurred while swimming.]

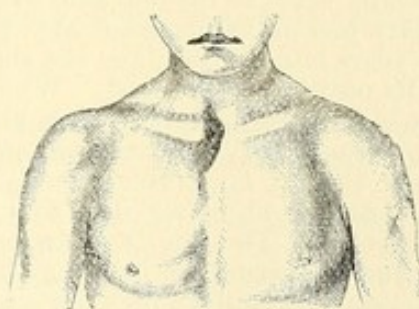
Symptoms.—The head of the bone, unless the person is exceedingly fat, or great swelling has supervened, can be distinctly felt and seen in front of the sternum; the corresponding shoulder falls a little back; the head inclines also sometimes to the same side; the movements of the arm are embarrassed, and accompanied almost always with an acute pain at the point of dislocation. The clavicular portion of the sterno-cleido-mastoid muscle presents an unusually sharp and projecting outline, and a careful measurement indicates, if the dislocation is complete, a sensible approach of the acromion process toward the centre of the sternum. If now the surgeon places his knee against the spine, and draws the shoulders back, the projection of the clavicle in front usually diminishes or disappears; if he carries the shoulder up, it descends; and if he depresses

FIG. 345.



Dislocation of the sternal end forward.

FIG. 346.



Appearance of a dislocated clavicle.

the shoulder, it ascends. The simplicity and uniformity of the symptoms which usually characterize this accident will generally prevent the possibility of a mistake.

Pinel mentions the case of a man who, having presented himself at one of the hospitals of Paris, suffering under this dislocation, the surgeon-in-chief thought it a tumor of the bone, and advised the application of a plaster; and, on the other hand, a patient presented himself to Velpeau, who had been treated for a dislocation, when the bone was only expanded by disease. I have myself also seen a fracture so near the sternal end of the bone as not to be easily distinguished from a dislocation.

¹ London Lancet, Oct. 6, 1888.

Pathology.—In complete anterior dislocation of the clavicle, the capsular ligament suffers a complete disruption, and also the anterior with the posterior sterno-clavicular ligaments. The rhomboid and interarticular ligaments suffer more or less, according to the extent of the displacement. The interarticular cartilage may retain its attachment to the sternum, or it may be carried forward with the clavicle. The head of the bone lies immediately underneath the skin and in front of the sternum; and generally it is found to have descended a little upon its anterior surface.

Richerand saw a case in which the sternal extremity of the bone was placed three inches below the top of the sternum. In some cases it is situated in front and a little above the sternum. Wherever the bone lies, it carries with it the clavicular fasciculus of the sterno-cleido-mastoid muscle.

Treatment.—Not one of the 11 forward dislocations of the clavicle at the sternal end seen by me has been completely reduced, or if reduced they have not been retained in place. In the following example the reduction, although faithfully attempted, was never accomplished.

Mr. H., of Buffalo, æt. 45, was thrown by a horse, suffering at the same moment a fracture of the leg and a forward dislocation of the left clavicle at its sternal end. Prof. J. P. White, with whom I was in consultation, made several attempts to reduce the dislocation by placing the knee against the spine and pulling the shoulder forcibly back, and the same efforts were repeated by myself, but without accomplishing the reduction. We also endeavored to reduce it by pressing directly upon the projecting bone and by placing a pad in the axilla, using the arm as a lever, as recommended by Desault, and with no better result. The patient was tolerably muscular, but while we were manipulating he was very much enfeebled by the shock of the accident. Finding that it was impossible to reduce the dislocation by any moderate amount of force, and believing that if it were to succeed we could not retain the bone in place, and the more especially because his left side was so much bruised that he could not bear an axillary pad or bandages of any kind, we desisted from any further attempts. Two years later I examined the shoulder and found the clavicle still unreduced, and its position unchanged. When he carries the shoulder forward or backward there is a corresponding motion at the sternal end of the clavicle. The arm is not quite as strong as the other, and its freedom of motion is slightly impaired. I have also in my museum the cast of a case of complete forward dislocation at this point; which accident occurred in a lad twelve years old, who had fallen into a cellar. The late Dr. Lewis and Dr. Dayton, both excellent surgeons, had examined the arm, and dressings had been applied with a view to maintain the reduction; but on the fifth day after the accident I found the bone displaced; nor do I think reduction was ever afterward maintained.

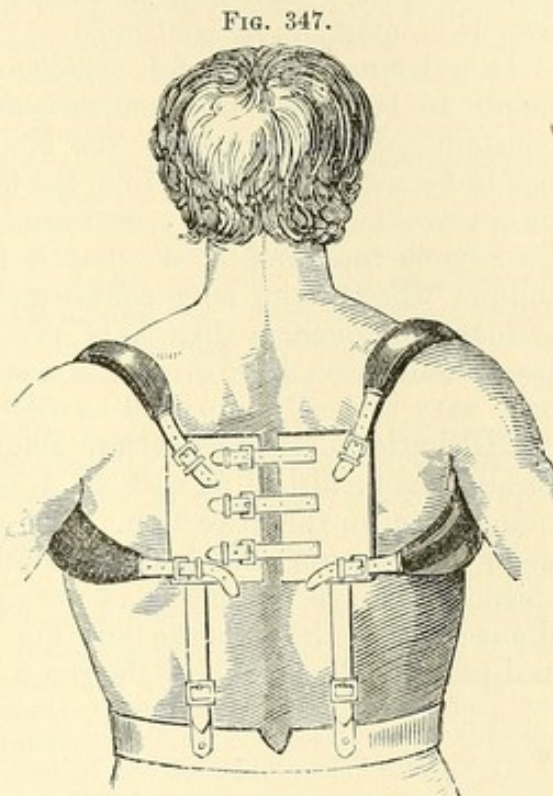
A lad was brought into the Buffalo Hospital with a dislocation of the same character, who had been run over by a wagon on the same day. Dr. E. P. Smith, one of the surgeons of the hospital, attempted faithfully to reduce it, but was unable to do so. Five days after, I found the bone out and quite movable. All apparatus having been removed, we laid him upon his back in bed, and kept him in this position three weeks. He was then dismissed with no change in the appearance of the bone, but he could move the arm as well as before the accident. Surgeons have not met with, or, at least, they have not mentioned, any cases in which the reduction of this dislocation was attended with difficulty, nor am I prepared to explain the difficulty which was experienced in my own (Mr. H.) and in Dr. E. P. Smith's case; unless it be as suggested by Sédillot, and as illustrated by Smith's case of dislocation upward hereafter to be mentioned, that the reduction was prevented by the displacement of the inter-articular cartilage. But most surgeons have testified to the difficulty of retaining it in place when reduction has been fairly accomplished.

Nevertheless, Desault (or, rather, his pupil Bichat, who has published his lectures), who always speaks very confidently of his ability to retain either

broken or dislocated bones in their places, says that he "almost always obtained complete success" with his apparatus. It is remarkable, however, that of the three examples furnished by Bichat to confirm this statement, all of which were treated by Desault himself, one recovered after a long time with a "very perceptible protuberance in front of the sternum," one with a "very slight protuberance," and in the other the "swelling was almost gone" on the twentieth day, and we are left in doubt as to whether the reduction was any more complete than in either of the other cases.¹ Richerand and Guersant succeeded no better with Desault's dressings.²

Other surgeons have made similar claims for their own forms of apparatus, but experience still continues to show that a complete retention of the dislocated bone is seldom to be expected.

Sir Astley Cooper recommends an apparatus, the construction and application of which are illustrated by the accompanying sketch, the object of which is to draw the shoulders back, and at the same time, by the aid of two pads or cushions in the axillæ, to carry the shoulders outward. The dressing is then completed by placing the arm in a sling. He advises, however, that in some way direct pressure should be made upon the projecting point of bone.



Sir Astley Cooper's apparatus for dislocated clavicle.

Velpeau objects to any plan which will draw the shoulders back; but, on the contrary, he thinks that the shoulders should be kept slightly forward, so as to diminish the tendency of the sternal end of the clavicle to escape in this direction.

[Dr. Holden reports a case of dislocation of the clavicles occurring while practising in a gymnasium. The reduction was effected, and the bones were retained in position six months, when they were displaced while putting on a coat. This was now often repeated until an apparatus was applied consisting of a leather splint shaped like the sternum with projections at the upper angles covering the sterno-clavicular articulations. This splint was moulded into position when wet, and the articulations were thus completely and firmly supported. The leather was then lined with buckskin and firmly retained in position by straps extending from each angle over the shoulders and back, led to a broad belt around the waist, the lower end being also fastened to the waist-belt. With prolonged use of this splint recovery was effected.³]

Treatment.—Until further observations have determined the relative value of these and of many other processes, it will be well to adopt no fixed rule of action; but having reduced the bone by either placing the knee upon the spine and drawing the shoulders back, or by making use of the humerus as a lever, the surgeon should attempt to maintain it in

¹ Desault on Fractures and Dislocations, by Xav. Bichat, Philada. ed., 1805, p. 52.

² Malgaigne, *op. cit.*, tom. ii. p. 417.

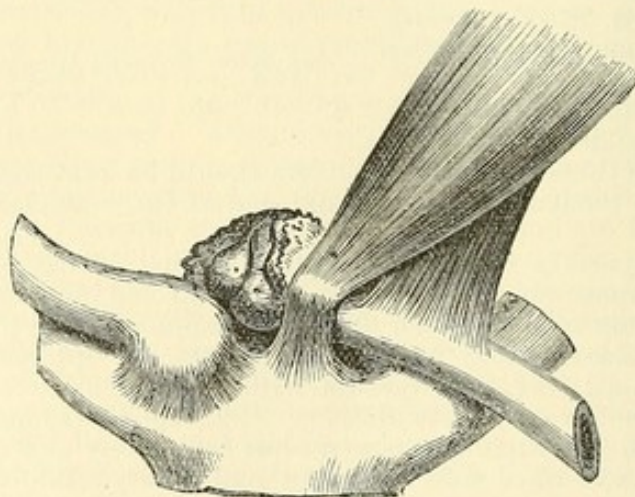
³ New York Med. Journ., 1873.

place by such means as the experiment shall prove are most successful. Among these means, direct pressure upon the sternal end of the clavicle, the sling, and perfect quietude of the muscles of the arm through the aid of bandages, with the dorsal decubitus, are no doubt of the greatest importance. If we find that a position of the shoulders more or less forward or backward best maintains the apposition, this position, whatever it is, ought to be continued.

In order to be successful, sufficient time must elapse for the torn ligaments to become firmly reunited, during which the reduction must be constant; since every time the bone escapes, the whole work of repair has to be recommenced as from the beginning. To this end at least four or six weeks are necessary, and sometimes the period must be lengthened far beyond these limits; so that it may often become a grave point of inquiry whether the long confinement of the limb will not entail more serious consequences than have ever been known to arise from leaving the bone displaced. In no case seen by me has the function of the arm been very seriously impaired by the displacement.

Dislocations of the Sternal End of the Clavicle Upward.—R. W. Smith¹ has furnished us with an account of one example of this dislocation as seen in the dissection. The extremity of the left clavicle rested upon the sternum, and had passed the median line until it touched the sterno-cleido-mastoid muscle of the right side. Posteriorly it rested upon the sterno-hyoideus muscle and the front of the trachea. The anterior and posterior ligaments of the joint, as well as the rhomboid ligaments,

FIG. 348.



Dislocation of sternal end of clavicle upward. (R. W. Smith.)

were torn. The inter-articular cartilage was detached from the sternum and the cartilage of the first rib, and had followed the clavicle.

Malgaigne has collected four undoubted examples of this dislocation. Mr. Bryant mentions two cases seen by himself, one of which was a double dislocation. He refers also to a specimen in Guy's Museum, dislocated upward and forward.² Dr. Shaw, of Pittsburg, Pa., has reported a case in an adult caused

¹ Smith, Dublin Journ. of Med. Sci., Dec. 1872.

² Bryant, Practice of Surgery, p. 787, London, 1872.

by a fall.¹ Vanvert has reported a case caused by a blow upon the side of the chest, which he was unable to reduce.² The following very extraordinary case was described by Dr. Rochester to the Buffalo Medical Association. I saw the case several times.³ J. McA., æt. 44, while seated upon a load of wood, was caught under the bar of a gateway and violently crushed, the right shoulder being forced downward and a little backward. Dr. Rochester saw him very soon after the accident. On examination, it was found that the sternal extremity of the right clavicle was thrown upward so far as to rest upon the front of the thyroid cartilage, occasioning considerable pain, difficulty of respiration, and loss of speech. Reduction was easily effected, and a retentive apparatus was immediately applied, consisting of a gutta-percha splint, moulded to the clavicle and ribs, and retained in place with adhesive plaster. Suitable bandages, a sling, etc., were also employed to maintain complete rest. Notwithstanding all the care employed, the bone again became displaced, and nearly four months after the accident we found the sternal end of the clavicle carried upward half an inch, and across toward the opposite side also about half an inch, and projecting somewhat in front. It was fixed in this position by ligaments which allowed it to move much more freely than natural, but which would not permit any great displacement. The corresponding shoulder was slightly depressed. He said that he felt no inconvenience or abatement of strength in the arm except when he attempted to lift weights above his head.

I met with a similar case in a woman fifty years of age, which had been caused by a fall upon the shoulders nine weeks before, and which had been overlooked by her surgeon in the first instance. When seen by me it was immovably fixed in its new position.

[Dr. Finley,⁴ of Queensland, reports the following case: A man was riding home on a dark night, when his horse stumbled over a cow, throwing him with great force upon his right shoulder, the deltoid muscle receiving the force of the fall, and causing an upward dislocation of the clavicle at its sternal end. When I was called in, reduction of the dislocation had been obtained by the previous attendant, the treatment being loose bandages for the arm; and the injury was reported to be the same as when first incurred. Examination showed that the sternal extremity of the clavicle was pushed up in the neck, so as nearly to touch the cricoid cartilage, and causing some pain in speaking and swallowing. The raising of the arm increased the pain. I first fixed the shoulders with a figure-of-8 bandage as firm as could be borne. I then placed a roller on the axilla, and fixed another roller over the sterno-clavicular articulation, so as to retain the clavicle. A few turns of the bandage were then used to fix the arm on the chest, as is generally done in cases of fractured clavicle, and the whole was then encased in starched bandages. In a little over three weeks these were removed and it was found that the clavicle had become once more firmly fixed to the sternal articulation, and after wearing the arm in a sling for two weeks the patient resumed work. Now the articulation is as strong as ever.]

Causes.—The accident seems to have been produced, in all the cases, so far as can be ascertained, by a force operating upon the end and top of the shoulder; in consequence of which the head of the clavicle is pushed and at the same time lifted, as it were, from its socket, tearing not only its capsule with the ligaments which immediately invest the capsule, but also in some instances the costo-clavicular ligament with some fibres of the subclavian muscle. The sternal end of the clavicle is found riding upon the top of the sternum, its head being placed between the sternal fasciculus of the sterno-cleido-mastoid muscle on the one hand, and the sterno-hyoid muscle on the other. In one of the cases seen by Malgaigne, the head had traversed in this direction completely the intra-

¹ Shaw, Med. Record, Aug. 18, 1877.

² Vanvert, New York Med. Journ., March, 1879, p. 329.

³ Rochester, Buffalo Med. Journ., vol. xiv. p. 262.

⁴ Austral. Med. Gaz., 1885.

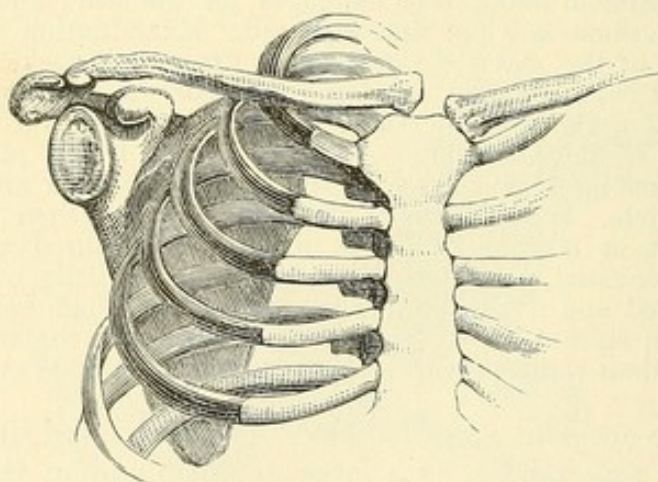
clavicular space, and lay behind the sternal portion of the opposite sternocleido-mastoid muscle.

[Dr. Blodgett¹ reports an upward dislocation which occurred while a man was carrying one end of a piano, at the moment when the men carrying the other end let it fall; he felt a sharp pain at the root of the neck and front of the chest; the clavicle was luxated upward and inward, and the first and second costal cartilages of the same side were dislocated from the sternum forward and upward.]

Symptoms.—The symptoms are, a depression of the shoulder, with an elevation of the sternal end of the clavicle so as to increase sensibly the space between it and the first rib. The clavicle also encroaches more or less upon the supra-sternal fossa, occasioning a corresponding diminution of the space between the end of the shoulder and the centre of the sternum. The sternal portion of one or both of the sternocleido-mastoid muscles may also be seen raised and rendered tense by the pressure of the head of the bone from behind.

Treatment.—Reduction has been found easy, but Malgaigne thinks a perfect retention impossible—at least it does not seem to have been accomplished in any of the cases reported. In no case did the displacement seriously impair the functions of the arm. The same apparatus to which I shall give the preference in cases of dislocation upward of the acromial end of the clavicle, at least with only such slight modifications as the

FIG. 349.



Dislocation of the sternal end of the clavicle upward.

peculiarities of the case will naturally suggest, will be suitable for this accident. The shoulder must be lifted by a sling, while the sternal end of the clavicle is pressed downward by a pad and bandages; and all the muscles of the arm and chest, so far as is consistent with respiration and comfort, must be maintained in a state of perfect rest until the ligaments have become reunited.

Dislocations of the Sternal End of the Clavicle Backward.—Two forms of the accident have been described; one in which the head of the clavicle is driven backward and a little downward, and another in which

¹ New York Med. Journ., 1883, vol. xxxviii.

it is displaced directly backward, or backward and a little upward. In both of these classes, the end of the bone falls inward toward the opposite clavicle, and occupies a space in the cellular tissue back of the sterno-hyoid and sterno-thyroid muscles, and in front of the œsophagus; the trachea, if reached at all, being probably thrust to the opposite side. The examples in which it has been found below the top of the sternum are much the most numerous; indeed, it is probable that the other form is only a secondary displacement, occasioned by the action of the fibres of the sterno-cleido-mastoid muscle.

The first case upon record of this kind of accident, caused by violence, was published by Pellieux, in 1834, in the *Revue Médicale*; until which time its existence had been generally denied. In the *London and Edinburgh Journal of Medical Science* for October, 1841, several cases are mentioned.

Causes.—Of the eleven examples mentioned by Malgaigne, four were occasioned by direct blows, and most of the remainder by crushing accidents, as by powerful lateral compression of the shoulders. One of the cases produced by a direct blow was accompanied with an external wound, and is the only instance of a compound dislocation of this kind which I have found upon record.

The man was admitted into St. Thomas's Hospital in September, 1835, and, according to his own account, the sharp end of a pickaxe had been driven through the flesh against the bone. The sternal end of the clavicle was found to be displaced backward, and with the finger thrust into the wound on the front of the chest, it could be felt resting upon the side and front of the trachea, where it interfered somewhat with respiration and deglutition. He had a great desire to cough, with a sensation of pressure on his windpipe, which was greatly increased when his head was thrown back. There was a slight emphysema in the region below the collar-bone and over the top of the sternum. The shoulder having been brought back with straps attached to a back-board, the bone readily resumed its place. The elbow was then brought forward and bound to the side, and the wound being closed with adhesive plaster, he was put to bed with the shoulders much raised. No unfavorable symptoms followed, and in three weeks he left his bed. Three weeks later he left the hospital with the sternal end of the bone still falling a little backward, and rather more movable than natural.¹

The following example, related by Morel-Lavallée, will illustrate the class in which the dislocation results from an indirect blow, or from a crushing accident. L., 17 years old, had his right shoulder violently pressed against a wall by a carriage. He experienced at the moment some pain at the bottom of his neck, and a great sensation of suffocation, which lasted for more than a quarter of an hour. The dyspnœa gradually subsided, but the motion of the right arm not returning, he, on the eighth day after the accident, entered La Charité. On examination, the two shoulders were found to be on the same level, but the right one was nearer the median line. The internal extremity of the clavicle was half concealed behind the sternum. On depressing the shoulder, the inner end of the clavicle arose and disengaged itself from behind the sternum; but reduction was effected by elevating the shoulder, while at the same time it was carried outward and backward. Desault's bandage was then applied, but as it became loosened Velpeau's was substituted, which kept the bone completely in position until the eighteenth day, when the patient was lost sight of.²

Symptoms.—The most constant symptoms are, the absence of the head of the bone from its socket, and its complete or partial disappearance

¹ South, note to Chelius's Surgery, Amer. ed., vol. ii. p. 218.

Morel-Lavallée, Amer. Journ. Med. Sci., vol. xxix. p. 229, 1842, from Gaz Méd.

behind the sternum, an approach of the corresponding shoulder to the median line, an inclination of the head to the opposite side, elevation of the shoulder, pain at the bottom of the neck, impairment of the motions of the arm, sometimes difficulty in respiration and in deglutition, partial arrest in the circulation of the arm from pressure upon the subclavian artery, and a slight projection of the acromial end of the clavicle, noticed twice by Morel-Lavallée.

Prognosis.—As in the other cases of dislocation at this point, the patients have generally recovered nearly the full use of their arms, even in one or two instances in which the reduction has never been accomplished.

Treatment.—It has not generally been found difficult to reduce this dislocation, nor when reduced is it so liable to become again displaced as are the dislocations forward; yet in only a few instances has the restoration been so complete as not to leave some deformity. In order to the reduction, the shoulder must be carried generally upward, outward, and backward; and it may then be best maintained in position by laying the patient on his back upon an elevated cushion, as practised by Tyrrell in the case related by South. To this may be added such other measures, differing but little from those employed in other dislocations of the clavicle, as are necessary to insure complete rest to the muscles. Of course, no pads or bands across the clavicle can be of any service in this case.

[Mr. Crompton reduced a backward dislocation of the clavicle as follows: "I found a large, thick pair of worsted stockings, rolled up in the usual manner when clean, which I placed high up under the axilla, and asked the attendant surgeon to keep them there, and when I gave the word to press the elbow down closely to the side. The patient sitting, I got in the bed behind him; now placing my knee on the spine between the two scapulæ and my hands grasping the shoulders, I suddenly pulled them firmly back, and the bone as suddenly slipped into place."¹]

§ 2. Acromio-clavicular Dislocations.

Dislocations of the Acromial End of the Clavicle Backward.—Of all the dislocations of the clavicle, this form is most frequent. I have met with it either as a partial or complete traumatic luxation forty-three times. The youngest subject was seven years of age, and the oldest sixty-three. All but two were males.

I have seen one example of congenital complete upward and outward dislocation of the acromial end, which was not traumatic—the case of M. A. H., who was examined by me February 8, 1876, when she was four weeks old. The labor had been easy and natural, and there was no soreness over the joint. It was easily reduced, but could not be maintained in place.

Causes.—It is produced generally by a fall upon the extremity of the shoulder. Twice the blow has been received rather upon the back than upon the extremity, and once it was occasioned by the fall of a board

¹ Guy's Hospital Reports, xliv. 1887.

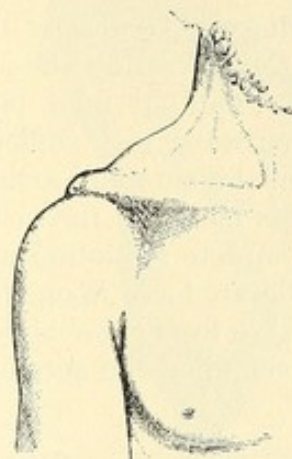
directly upon the top of the shoulder, and once by a bolt thrust directly up from under the clavicle.

Symptoms.—When the dislocation is complete, the clavicle not only is lifted from its articular facet to the extent of the breadth of the bone, but it is pushed more or less outward over the top of the acromion process; generally less than half an inch, but I have once seen it riding the process to the extent of three-quarters of an inch. In this last example, the case of J. M., a strong, healthy, laboring man, the clavicle was easily reduced, and it always went into place with a sensible click; but although every possible care was taken to retain it in place by bandages, compresses, an

FIG. 350.

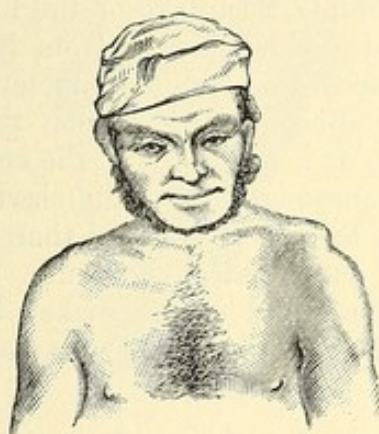

FIG. 351.



Dislocation of the acromial end of the clavicle.

axillary pad, and a sling, yet it was not accomplished, and on the third day he removed all the dressings, and refused to have them reapplied. I have usually found the shoulder slightly depressed; and in one instance, where it is probable the deltoid muscle had suffered some injury, the elbow hung away from the body, and any attempts to lay it against the side produced an acute pain in the shoulder.¹ It has been noticed also, in most cases, that the clavicular portion of the trapezius muscle appeared lifted and tense, especially when the neck was straight.

Inability to raise the arm to a right angle with the body is a general but not constant symptom. In two instances, where the displacement was only moderate, the patients were at first and for some time afterward unable to lift the arm in any degree from the side. In one example, a lady sixty years of age had fallen upon her shoulder and produced a dislocation upward, but she had not consulted a surgeon until she called upon me, five months after the accident. The clavicle was then raised from its socket about half an inch, but it could be easily pressed back to its place, the reduction being attended with a grating sensation, a circumstance which I have not noticed in any other instance. She was not even then able to raise her arm to her head, nor had she been able to do so since the accident occurred. In all the motions of the arm and shoulder, the clavicle is seen to move more freely than natural immediately

¹ Report on Dislocations, by the author. Transac. of New York State Med. Soc., 1855, p. 19.

under the skin, and these motions are usually attended with some pain at the point of dislocation.

[Bryant describes this dislocation as that of the scapula. He says it seems only consistent with common sense, although not with custom, to follow Skey, Maclise, and Flower, and call what has hitherto been described as dislocations of the acromial end of the clavicle, dislocations of the scapula.]

This accident has been sometimes mistaken for a dislocation of the humerus, but, unless the shoulder is already greatly swollen, the error is not likely to happen. If the point of the acromion process can be made out, it will be easy to determine, by sliding the finger along its spine, whether the clavicle is displaced or not, and by these means to settle the question of its complicity in the accident. The question as to whether the shoulder is dislocated or not may be more difficult of solution, as we shall hereafter have occasion again to observe.

Pathology.—Generally there exists simply a rupture of the ligaments immediately investing the joint, so that the clavicle rises from its socket only about half an inch, more or less, according to its diameter, and is carried outward just sufficiently far to allow it to rest upon the upper margin of the acromial articulation. In at least thirty of the cases seen by me this has been the position of the acromial end of the clavicle, and for its complete reduction nothing more has been required than to press with moderate force upon the upper and outer end of the bone. In nine cases I have found the bone not only thus lifted on its socket, but also driven over upon the acromion process from half to three-quarters of an inch.

In one instance, that of a gentleman, Mr. B., who was injured in a railroad accident, the acromial end of the clavicle was displaced outward half an inch, and backward three-quarters of an inch, while the sternal end also was considerably lifted in its socket and slightly sent inward. The shoulder fell forward and the coracoid process was one inch nearer the sternum than the same process upon the opposite side. In such cases more or less of the fibres of the coracoclavicular ligament must have suffered a disruption; indeed, without a rupture of its external fasciculus, which anatomists have called the trapezoid ligament, such dislocation cannot take place. M. Nicaise¹ has reported a case analogous to the above, in which he was unable to effect reduction; and he has added the results of his own experiments upon the cadaver, which confirm the statement already made by me, that this dislocation cannot take place without a rupture of the trapezoid ligament.

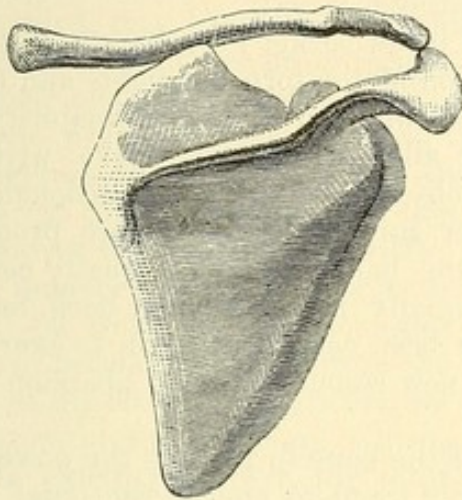
Prognosis.—It is impossible for me to say what has been the precise result in all the cases which I have seen, but my notes furnish only two cases of perfect retention after a complete dislocation at this point.

One of these, D. T., aged about 25 years, fell sideways upon the ground, striking upon the extremity, and, as he thinks, a little upon the top of the shoulder. The clavicle was dislocated upward and outward, so that it overlapped the acromion process half an inch. It was easily replaced, and having applied my own apparatus for broken collar-bones, with the addition of a band across the shoulder and under the elbow to keep the clavicle down, I succeeded in retaining the bone in place. This dressing was continued until the forty-second day, when, on being removed, the clavicle was seen to be closely confined upon its articulation; and after a lapse of two years it still retains its position so completely that no difference can be detected between the opposite articulations.

¹ Nicaise, *The Lancet*, Oct. 14, 1876, vol. ii. p. 535.

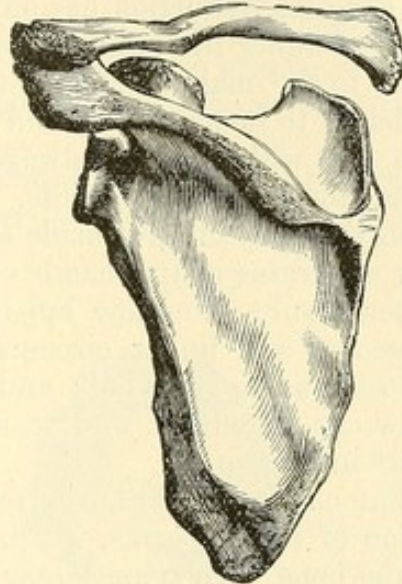
In the case of Moran, already mentioned, whose clavicle overlapped the acromion process three-quarters of an inch, and who threw off the dressings at the end of three days, the same degree of displacement existed at the end of two years; the scapular end of the clavicle moving freely in every direction under the skin according as the arm was moved. In lifting, he says, the strength of his arm is undiminished until he raises the weight nearly to a level with his shoulders, and from this point upward he can lift but little. For a laboring man it amounts to a serious maiming.

FIG. 352.



Dislocation of the acromial end of the clavicle upward.

FIG. 353.



Dislocation of the acromial end of the clavicle upward and outward.

I have seen the same loss of power in the arm to raise bodies above the head in at least two or three of the examples of less complete dislocation, continuing after the lapse of several years; but in the majority of cases, although the bone does not remain reduced, the patients have recovered eventually the complete use of the arm in whatever position it may be placed.

The case to which I have already referred as having been caused by a bolt thrust upward under the clavicle, will furnish the best illustration of this general principle. James O'Brien, 1st U. S. Artillery, was injured in September, 1862, by being run over by a horse-car. A bolt, three-quarters of an inch in diameter, was driven through the skin on the anterior margin of the left axilla, breaking the first rib, severing the coraco-clavicular ligaments, and forcing the clavicle upward from its socket. No attempt at reduction was ever made. When seen by me one year after the accident, the outer end of the clavicle was lifted directly up two inches from the acromion process, to which it was united only by a long and slender ligament. He was not conscious of any loss of power or limitation of motion in the injured arm. At my request, my son, then in the U. S. service, instituted a series of experiments to test the relative strength of the two arms, and with the following result: First with the right arm, and then with the left, he lifted from the ground fifty-six pounds and three ounces, and sustained this weight above his head thirty seconds, with his arms fully extended. With his right arm extended at full length, at right angles with his body, he sustained twenty-five pounds for fifteen seconds. With the left arm he sustained the same weight, in the same position, seventeen seconds.¹

¹ Amer. Med. Times, Oct. 24, 1863.

Treatment.—When the bone simply rises upon its socket, the reduction is always easily accomplished by pressing firmly upon its extremity with the fingers; but if, at the same time, it has been carried outward, or outward and backward, the reduction is only accomplished by pulling the shoulder backward, or by placing a pad in the axilla, using the arm as a lever, or by lifting the arm by the elbow and at the same time pressing the clavicle down; and it will sometimes require the application of all or several of these procedures at the same moment. In some cases the complete reduction has only been effected when the patient has been brought under the influence of an anæsthetic.

As to the maintenance of the bone in its socket for a length of time sufficient to insure a firm and close union of the torn ligaments and capsule, this will be found always more difficult, and in a great majority of cases absolutely impossible. Nearly all surgeons who have written upon this subject have made the same observation; and if occasionally a new apparatus in the hands of a clever surgeon has seemed to promise better results, the same apparatus in the hands of other equally clever surgeons, and under circumstances equally favorable, has been found almost constantly to fail; and we have been compelled again to exercise anew our ingenuity, and to seek for new resources, or to abandon the effort in despair.

The chief obstacle to the retention of the bone in place is the powerful action of the trapezius, which constantly tends to elevate the outer end of the bone. In some measure this may be overcome by elevating very forcibly the shoulder, or by inclining the head, but both of these positions are extremely fatiguing, and will not be long endured.

Dr. Folts, of Boston, believed that he had found in Bartlett's apparatus for broken clavicles, modified by the application of a shoulder-strap, the infallible remedy for this one of the many sad defects in our art. The most important part of this dressing, according to Dr. Folts, is the compress placed upon the upper and outer end of the clavicle, and the bandage or strap passed over the compress and under the point of the elbow.¹ Dr. Folts is no doubt correct in regarding this strap as an important if not the essential part of the apparatus; and it is surprising that by Sir Astley Cooper, as well as by many other experienced surgeons, its value should have been overlooked.

The bandage or strap, adjusted in the manner which Dr. Folts has recommended, is the only means of counteracting the action of the trapezius, upon which any substantial reliance can be placed; but the principle has long been understood and practised upon. Brasdor's tourniquet, or Petit's, secured by a strap brought under the point of the elbow, Boyer's double shoulder-straps, and Desault's third bandage, all aimed at the accomplishment of the same purpose; yet Boyer and Desault found all these contrivances fail in a majority of cases. Mayor employed a dressing constructed with a strap to buckle over the dislocated clavicle; but Nélaton has seen this apparatus fail also, when applied in his own wards.

The experience of Dr. Folts at the time of his report did not extend beyond three cases, and the apparatus had been completely successful in only two of the three. My own experience is sufficient to show that it will be found occasionally, but by no means constantly, successful. I have already mentioned two cases in which I succeeded perfectly by this mode, but in several others which seemed equally favorable I have met with partial or complete failures.

¹ Folts, Boston Med. and Surg. Journ., vol. liii. p. 259.

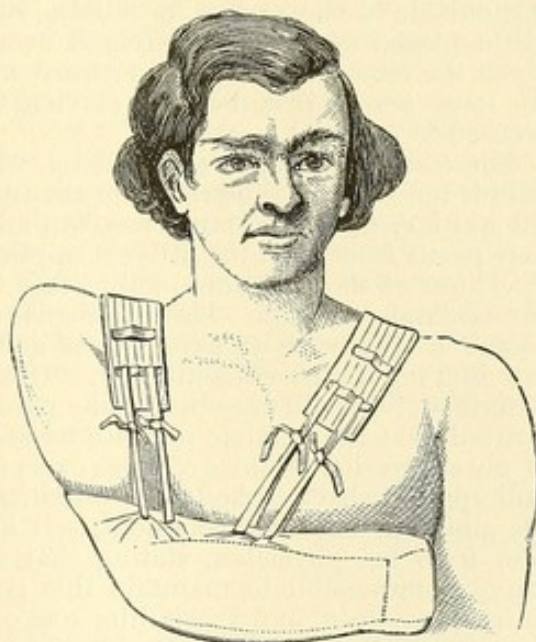
The source of error, generally, on the part of those who think that they have devised an apparatus, or a method by which they can always or generally succeed in holding the bone in place until the ligaments are reconstructed, is, first, that they have not sufficiently noted how slight is the elevation, or projection, in a large majority of cases, before any dressing is applied, so that finding eventually very little projection, they call it perfect; second, that they examine the shoulder, to determine whether the restoration is complete, too soon after the apparel is removed, when a very slight remaining effusion into, and induration of the adjacent tissues, render it impossible to say what has been accomplished; and third, they have sometimes had under treatment too small a number of cases to entitle them to form a just conclusion as to the general value of their method of treatment.

The practical difficulties are, the sensibility and consequent inability sometimes of the point of the elbow to bear the requisite pressure, and the even greater sensibility of the skin over the top of the clavicle; the tendency of the bandage to slide off from the shoulder, and also to become displaced from the end of the elbow; the gradual relaxation of the bandages, which, when existing even in the most inconsiderable degree, is sufficient sometimes to allow the bone to slip out from its shallow socket; the impossibility of fixing the scapula, upon whose immobility as well as upon the immobility of the clavicle the retention depends; and, finally, the great length of time requisite to unite firmly the ligaments, if indeed they ever again become actually united.

The band can be prevented in some measure from sliding off from the clavicle by a counter-band attached to a collar upon the opposite shoulder, but not without causing some pain, and giving rise to excoriations generally in the opposite axilla; and, in a degree, all the other difficulties may be met by patience and ingenuity, but unfortunately the smallest failure in any one of these numerous indications insures defeat.

The axillary pad employed as a fulcrum upon which extension may be made is equally as dangerous here as in fractures, and I do not think it ought ever to be used for this purpose, but only as a means of moderate support and retention; indeed, it would be well, perhaps, if it were discarded altogether.

FIG. 354.



Mayor's apparatus for dislocated clavicle.
("Triangle cubito-bis-scapulaire.")

[Dr. Powers,¹ of New York, applied the following dressing successfully: The upper end of the arm being firmly grasped, the humerus could be used as a lever on which to pry the shoulder up and out; the dislocation being thus reduced, a small, firm pad was placed over the outer end of the clavicle; a strip of rubber plaster, three inches in width, was then applied beneath the flexed elbow and carried up to the back of the arm over the outer end of the clavicle to the front of the chest; then up the front of the arm and over the clavicle to the back of the chest. The elbow was placed against the chest and a roller bandage carried around the body.

Dr. Pilcher, of Brooklyn, succeeded with the following bandage: A loop of one end of a bandage two inches wide, was placed around the middle of the forearm, and then passing the bandage directly up and over the acromial end of the clavicle, where a few folds of bandage had already been placed to serve as a compress. Thence the bandage was carried diagonally downward, and across the back. Continuing straight around the body until, having encircled the trunk, it reached again the middle of the back; it was then slipped under the first line of bandage and brought back upon itself again to the front, by this manoeuvre forming a loop around this first bandage and securing it from slipping from its proper place. In bringing the bandage to the front, after having been thus looped around the back bandage, it was made to pass under the elbow and thence directly upward in front over the point of injury again; thence it followed the line of the course of bandage across the back and about the body, this time passing outside of the arm at its middle, so as to bind it to the side, thence it was again passed around the body and over the arm, but then was made to return about the elbow, from behind forward, and then upward in front once more over the loose acromial end of the clavicle to the middle of the back, where it was secured by a pin.²]

The case of Mr. B., already quoted, with a dislocation outward and backward, affords not only an illustration of the inefficiency of either the shoulder-strap or the axillary pad in certain cases, but also, it seems to me, of the mischief which may result from their too diligent application; for I cannot persuade myself but that most of the maiming in this case was due to the apparatus rather than to the original accident. This gentleman was injured on the 10th of November, 1855. A sling with an axillary pad and bandages was immediately applied. I saw him on the seventeenth day. The displacement was then such as I have described, but I did not observe any paralysis or emaciation of the limb. Having noticed that the clavicle fell into its socket when he lay upon his back in bed, at my suggestion all the dressings except the sling were removed, and the patient laid upon his back in bed, with instructions to continue in this position, if possible, until the cure was complete; but after a few days I received a communication from his physician, stating that, owing to a troublesome cough, he had found it impossible to maintain this position. His residence was forty or fifty miles from town, and I sent him one of my dressings for broken collar-bones, with instructions as to its use; directing especially that a shoulder-strap should be used to keep the clavicle down. The dressing was applied and continued six weeks, and on being removed, the elbow, wrist, and finger-joints were found to be stiff. The whole arm was emaciated and almost powerless. One year later there was no improvement in the condition of the arm; every joint from the shoulder down was almost completely ankylosed, the muscles were greatly wasted, and the hand trembled constantly. These results, it seems to me, were due to too long and too tight bandaging of the arm, and especially to the pressure of the axillary pad. I do not state this positively, but this is my belief.

Is it worth while, then, to incur the dangers of too long confinement and of excessive bandaging for the purpose of attaining the always uncertain result of maintaining the bone in its socket? We certainly may be permitted to make the attempt within certain reasonable limits; and especially if the patient is a female, and the avoidance of deformity is a

¹ New York Med. Journ., Jan. 1889.

² Ibid., April 10, 1886.

point of serious consideration; but never without keeping constantly in mind the possibility of a permanent ankylosis and paralysis of the limb.

Dr. Gross says he first suggested the use of strong silver wire to keep the parts in place, and this suggestion was carried into effect by Dr. Cooper, of San Francisco, and by Dr. Hodgen, of St. Louis.¹ Dr. Hodgen has made the operation twice, and both resulted well, the parts being kept well in position; but that with his present experience he would not repeat the operation, except in cases of *very great* displacement. In this latter opinion, as to the circumstances under which alone the operation would be justifiable, I fully concur; and even in such a case its propriety is questionable.

Dislocations of the Acromial End of the Clavicle Downward.—This form of dislocation is exceedingly rare, only five well-authenticated cases are known to me as having been placed upon record, one of which was seen and dissected by Melle in 1765, the second was met with by Fleury in 1816, and the third is described by Tournel.

Dr. W. B. Chase, of Brooklyn, N. Y., has reported a case in a boy 8 years old, who fell headforemost twelve or fifteen feet, striking the top of his shoulder upon the round of a ladder. The patient was thin, and the exact position of the clavicle was easily traced. The axis of the bone was changed, carrying the acromial end downward and a little backward. The anterior portion of the shoulder was flattened, and the acromion process was very prominent. He could move the arm slightly when it hung by his side. The boy was anesthetized, and the reduction easily effected "by throwing the shoulder outward and backward, while at the same time I grasped the clavicle in its outer third with the extremities of my fingers and thumb, and carried it upward and forward into its normal position. There was no subsequent tendency to displacement."² Dr. Allen³ has seen a case of dislocation downward in a boy, æt. 16, who was in good health and vigorous. The dislocation had been caused while splitting wood with an axe, the arm being elevated and carried slightly outward. There ensued disturbance of motion and of sensibility in the arm, which Dr. Allen ascribed to pressure upon the nerves. Under the use of electricity these disturbances disappeared, and the cure was complete.

Cause.—So far as I can ascertain, except in the case reported by Dr. Allen, it has been produced by a force which has acted directly upon the top of the clavicle.

In the case mentioned by Tournel, a horse had trod upon the shoulder; and in the example recorded by Melle, the accident occurred in a child six years old, from an attempt to support a great weight upon the top of the collar-bone. In this last example the humerus was dislocated also, and both dislocations had remained unreduced many years when the patient was seen by Melle.

This force acting directly upon the top of the clavicle would fail to dislocate the bone, except by first breaking down the coracoid process, if it did not happen sometimes that at the same moment the lower angle of the scapula was thrown outward, in such a manner as to depress slightly the coracoid process, and thus to permit the outer end of the clavicle to fall below the level of the acromion process.

Symptoms and Pathology.—This dislocation, whether it has been produced artificially upon the dead subject, or accidentally upon the living,

¹ Hodgen, Amer. Journ. Med. Sci., April, 1876, p. 452; Ibid., April, 1861, p. 389.

² Chase, Transactions Med. Soc. State of New York, 1879, p. 174.

³ J. L. Allen, Med. Record, Feb. 19, 1881.

has always been found to be accompanied with a complete rupture of the acromio-clavicular ligaments not only, but also of the coraco-acromial and coraco-clavicular ligaments; the outer extremity of the bone resting between the acromion process and the capsule of the shoulder-joint, and a little posterior to the articulating facet which originally received the clavicle. The superior angle of the scapula approaches the body slightly, and its inferior angle is thrown outward. A marked depression exists at the point of dislocation, accompanied with a sharp pain, increased especially when an attempt is made to move the arm. The patient is unable to lift the arm voluntarily, but it can be moved pretty freely in the direction forward and backward by the hands of the surgeon; abduction is much more difficult.

Treatment.—Reduction is easily accomplished. At least, in all of the examples presented in the living subject, and referred to above, where the attempt was made, it was effected promptly by drawing the shoulders outward and backward; nor has it been found any more difficult to maintain it in position when once replaced. When the scapula is restored to its natural position, and its lower angle approaches again the side of the body, a redislocation becomes impossible; since the coracoid process now effectually prevents that descent of the clavicle upon which the displacement always depends. It is only necessary, therefore, to secure the scapula at its base and lower angle snugly to the body, by a broad band and compress, and all the indications of treatment are completely fulfilled.

Dislocations of the Acromial End of the Clavicle under the Coracoid Process.—Pinjou met with one example of this singular dislocation,¹ and Godemer, of Mayenne, has recorded five more,² and these constitute the whole number which are at this day known to science.

Cause.—Age and a consequent relaxation of the ligaments seem to constitute a predisposing cause, since of the six recorded examples four were between the ages of sixty-seven and seventy-one, and the other two were adults. In all the cases, also, the dislocations were the results of falls upon the shoulder.

The symptoms which have been said to characterize this accident are pain and a very marked depression at the point of displacement, with a corresponding projection of the acromion and coracoid processes; a rapid inclination outward and downward of the line of the clavicle, its outer extremity being felt in the axilla; the corresponding shoulder depressed and inclined forward; freedom of motion in all directions except inward and upward; the lower angle of the scapula thrown outward and backward; to which Morel-Lavallée has added an actual increase of space between the acromion process and the sternum.

Treatment.—Godemer reduced all the examples which came under his notice easily, by directing an assistant to pull the arm backward and outward while he himself seized upon the clavicle with his fingers, and disengaged it from under the process; but Pinjou, after many efforts by the same method, failed completely, and the patient having left him, the

¹ Pinjou, Journ. de Méd. de Lyon, Juillet, 1842, from Vidal (de Cassis).

² Godemer, Recueil des Travaux de la Soc. Méd. d'Indre et Loire, 1843, from Vidal.

clavicle was reduced the next day by an empiric. Vidal (de Cassis) recommends that instead of pulling the arm outward, by which procedure the pectoralis major is made to antagonize the surgeon, the elbow shall be brought down to the side, and kept there by the left hand, while the right hand, placed in the axilla, shall pull the upper end of the humerus outward, converting the arm into a lever of the third kind. This process, I confess, seems to be much the most rational.

The author will scarcely have performed his duty as a faithful writer if he does not state frankly that he entertains a suspicion that both the gentlemen who have reported these curious examples have entertained us with fabulous or imaginary stories; and especially do these suspicions rest upon the cases reported by Godemer, who in five years saw five cases, each presenting throughout the same class of symptoms, the same facility of reduction, accomplished by the same means, and always with the same perfect result. If to these singular coincidences we add the fact that only one other surgeon has ever claimed to have met with the accident, and if we notice the actual anatomical difficulties which stand in the way of its occurrence, such especially as the complete occlusion of the subcoracoidean space by the tendons and muscles which pass from its extremity toward the chest and arm, we shall find a fair apology for some degree of scepticism.

Dislocations of the Clavicle at Both Ends, simultaneously.—[This dislocation usually results from severe injury, but in one case it occurred from so slight a cause as the effort of the patient to wash the back of her neck (Haynes). The sternal end has always been dislocated forward, but the acromial end has assumed various positions, though the luxation backward is the more frequent displacement. Reduction has been effected, when possible, by drawing the shoulder backward, and manipulating both extremities of the bone in such manner as to force them to their respective articulations. In several cases it was found impossible to reduce both ends, and retain them. The appliance must be some modification of that used in dislocations and fractures of the clavicle. The following detail of cases will afford useful suggestions.]

On the 26th of January, 1863, Dr. North, of Brooklyn, N. Y., was called to see a lad fourteen years of age, who had been thrown with violence backward from a stool upon which he was sitting, striking the back of his left shoulder against the floor. Dr. North found him suffering severely from pain, and with some difficulty of breathing. The shoulder was depressed and thrown forward. The sternal end of the clavicle, turned forward, formed an abrupt, rounded prominence; the acromial end, turned forward also, presented its longest diameter toward the surface, and rested above the acromion process; while the central portion seemed depressed or thrown back, an appearance which was caused by the rotation of the clavicle upon its axis. Reduction was accomplished by throwing the shoulders forcibly backward, and at the same time pressing with the thumbs upon the two extremities in such a manner as to reverse the rotation, as follows: pressing at the acromial end backward and downward, and at the sternal end backward and upward. The restoration was complete, and the bones were retained in place by compresses and adhesive plaster, with the aid of Day's "neck yoke." At the end of three weeks the dressings were removed; and when last seen by his surgeon "there was but little, if any, trace of the accident remaining." It is the opinion of Dr. North that the rotation was caused by the action of the pectoralis major and deltoid after the dislocation took place.¹ Erichsen says that Richerand and Morel-

¹ N. L. North, M.D., New York Med. Record, April 16, 1866.

Lavallée have each reported one example of double dislocation of the clavicle. Another example has been reported by Dr. Col.¹ In a case observed by Lund,² and reported by Jones, the patient, a man 32 years of age, was struck on the posterior portion of the right shoulder, dislocating the sternal end of the right clavicle forward, and the acromial extremity upward and backward. It was found impossible to reduce the dislocation except under the influence of an anæsthetic. In a few days the functions of the arm were completely restored. Rombeau³ met with a similar case, which is reported by Gros. The dislocation, having been first recognized several days after the accident, was reduced and maintained by an apparatus similar to that of Desault, which remained in place five weeks. Ultimately the patient recovered with slight remaining deformity, and with the motions of the arm completely restored.

Dr. Stanley Haynes, of Malvern Link, has reported the only remaining case of which I have been able to find a record: "A girl, aged 13, rapidly growing, of lax tissues, and of a consumptive family, but who had always had good health, while washing the back of her neck with her left hand, one morning in September, felt something give way in the shoulder of the same side. I found dislocation forward of the sternal end of the clavicle and partial dislocation upward of the acromial one. There was very little pain. Both extremities of the bone were easily replaced by drawing the shoulder backward and downward, but the double deformity was reproduced immediately the shoulder was liberated. A pad was applied under a figure-of-8 bandage over the sternal end, and the arm was placed in a sling as a temporary measure. To a strap, fastening round the chest, a strap bearing a truss-pad was attached in such a manner that the pad kept the sternal end of the clavicle reduced, the other end of the strap passing over the shoulder and diagonally across the back to the horizontal strap: the wearing of a sling kept the acromial end in its natural position. The patient soon afterward returned to school at a distance. She is now at home, and I have found the sling has been discontinued some time; that the straps have stretched and are useless; and that the ends of the bone are as mobile as, but not more than, they were when I first saw the patient, but that the sternal end does not become dislocated unless the arm is raised, when it nearly always starts forward."⁴

[Mr. Hulke, of London, reports the following case: A woman was struck on the left clavicle by the knee of a horse, and as a result both ends of that bone were dislocated. The left shoulder had fallen inward and forward, and the head was inclined toward the left side; the sternal end rested on the upper part of the anterior surface of the manubrium sterni, forming a marked projection under the skin; the acromial end was displaced backward and inward, resting on the scapular spine opposite its junction with the acromial process. The long axis of the bone was placed in an antero-posterior, rather than in the normal transverse, direction. Both the manubrial and the acromial articular facets could be plainly felt as concavities beneath the skin. By drawing the shoulders backward the bone slipped easily into position, but on relaxation luxation immediately recurred. The reduction was maintained by a gutta-percha splint fitted to the shoulder and reaching past the point of the sternum in front and maintained by a bandage.

Mr. Newman reports the case of a laborer who was injured in the fall of a building, receiving among other injuries two fractures of the left clavicle and a dislocation of both ends of the right clavicle—the sternal end was elevated and the acromial end depressed. No efforts were made at reduction, owing to other injuries, and he soon passed from observation.⁵]

¹ Col, *Gaz. des Hôpitaux*, 1872, p. 893.

² Lund, *Brit. Med. Journ.*, 1874, No. 682, p. 106.

³ Rombeau, *Bull. Gén. de Thérapeutique*, 1874, vol. lxxxvi. p. 537.

⁴ *The British Medical Journal*, Jan. 27, 1872.

⁵ *London Lancet*, Sept. 19, 1885.

CHAPTER VII.

DISLOCATIONS OF THE SHOULDER (SCAPULO-HUMERAL).

OWING to the great exposure and the peculiar anatomical structure of the shoulder-joint, its structure having reference mainly to freedom of motion rather than to firmness and security in the articulation, dislocations of the humerus are very common.

My private and hospital records furnish me with 117 cases of dislocation of the shoulder, seen and recorded by myself. Of these, 41 were recognized as subglenoid, 33 as subcoracoid, a very small proportion as subclavicular, 2 as subspinous, and the remainder were not accurately diagnosticated.

Writers have not been agreed as to the precise anatomical relations of these dislocations, nor as to the nomenclature. Velpeau, Malgaigne, Vidal (de Cassis), Skey, and Sir Astley Cooper have each adopted explanations and classifications peculiar to themselves. With the arrangement established by this latter surgeon English and American students are the most familiar; and believing that it is more simple, and quite as appropriate as either of the others, I shall adopt it as the basis of my own descriptions.

According to Sir Astley Cooper, there are three complete dislocations of the shoulder; namely, downward, forward, and backward. The so-called "*supra-coracoid*" dislocation, without a fracture of the coracoid or acromion processes, the possibility of which has been denied by Boyer, but examples of which are declared to have been seen by Malgaigne, Holmes, Hewitt, have now sufficient affirmative testimony to justify me in devoting a section to its consideration.

[The classification of dislocations at the shoulder, herein given, is wanting in scientific precision, as well as in exact pathological conditions. Flower and Hulke (*System of Surgery*) well remark: "As want of precision in the terms used in describing varieties of luxation has hitherto been a principal source of obscurity, it will be necessary, before proceeding further, to adopt a definite and intelligible system of nomenclature. The obliquity of the glenoid fossa, and the variations in the position of the scapula, render such words as downward, forward, inward, etc., very inefficient as distinctive designations of particular forms of dislocation. Names derived from the relation of the head of the bone to its new situation to important contiguous osseous structures are more concise, expressive, and definite."

Acting upon these opinions, they find that all the possible dislocations of the humerus readily group themselves into the following subdivisions:

1. *Subcoracoid*.—Forward and slightly downward; upon the neck of the scapula, in front of the glenoid fossa, and immediately below the coracoid process. Common.

2. *Subglenoid*.—Downward and forward; head of the humerus in front of the inferior costa of the scapula, below the glenoid fossa. Rare.

3. *Subclavicular*.—To the inner side of the coracoid process, under the clavicle. Very rare.

4. *Supracoracoid*.—Upward and forward; upon the fractured coracoid process. Only three cases reported.

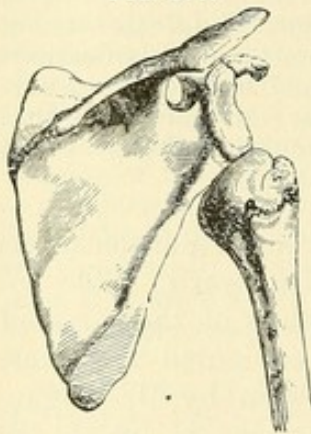
5. *Subspinous*.—Backward; upon the back of the neck of the scapula, beneath the spine or posterior edge of the acromion. Very rare.

Of these different dislocations, Mr. Flower regards the subcoracoid as the most common, while other authorities make the subglenoid most frequent. This discrepancy arises chiefly from the inaccuracy of the terms downward and forward; many dislocations classified under the old nomenclature as subglenoid, or downward, were, in fact, subcoracoid.]

Dislocations of the Shoulder Downward (Subglenoid).—This is usually called a dislocation into the axilla; the head of the bone resting rather upon the inner side of the inferior border of the scapula, near the base of that triangular surface which is found below the glenoid fossa. Since in both the other complete dislocations of the shoulder the head of the humerus, in order to escape from its socket, must be made to descend more or less downward, *I shall regard this dislocation as the type of all the others, and shall make it the subject of especial consideration, as well as of reference, when speaking of the other forms of dislocation.*

Causes.—The most frequent cause of this accident is a blow received directly upon the upper end and outer surface of the humerus. I have found the arm dislocated into the axilla by this cause thirty-one times; five times by a fall upon the extended hand; three times by a fall upon the elbow; and in these latter cases the arm was probably carried away from the body at the moment of the receipt of the injury. In all the above examples the shoulder has been dislocated by the simple force of the blow, or with only slight aid from muscular action; but in a considerable number of cases the bone is displaced almost wholly by the action of the muscles, the arm having been previously violently abducted; and perhaps in some cases the capsule being torn before the resistance of the overstrained muscles

FIG. 355.



Subglenoid dislocation.

has accomplished the displacement. Thus, in three instances I have known the dislocation to result from holding on to the reins after being thrown from a carriage; in two cases the patients have fallen through a hatchway and been caught and suspended by the arms; once a woman met with this accident by holding on to a pump-handle when she had slipped and fallen upon the ice.

A few years since I examined the arm of a Swiss woman, Maria Norregan, who was then sixty-five years old, and whose humerus had been dislocated into the axilla seventeen years before, where it still remained. Her own account of the accident was, that she was returning from the Jura Mountains, near Neuchâtel, with a load of hay upon her head. She had carried it a long way with her hands held upward, without once stopping to rest, and when at length she threw down the load at her door, the right shoulder was dislocated. The arm soon became very painful, and swollen to the fingers' ends; but she was too remote from, and too poor to employ, a surgeon. A tailor, who used to do the minor surgery of the neighborhood, bled her three or four times, but the dislocation was not recognized until many months after. A Mrs. Hunn informed me that when she was twenty-two years old she had a convulsion, and that her attendants in trying to hold her upon her bed actually pulled the shoulder out of joint. After the first accident the dislocation was not repeated for four years, but since then it had occurred from very slight causes many times. She was in the habit of reducing it herself by placing a ball in the axilla and using the arm

as a lever. Dr. Scatliff, of Brighton,¹ Coombs, of Castle Cary,² and others, have published examples of this dislocation caused by epileptic convulsions. I have myself seen such examples. Dr. Lehman reports the case of a sailor on board an American brig, who was subject to a dislocation into the axilla from very slight causes, and especially if he bent his body far over to raise anything. He could also, by pulling horizontally, remove the head of the bone from its socket. It was reduced easily, and he experienced no pain either in the reduction or dislocation, nor, indeed, during the displacement.³

[Brackett,⁴ of Nashua, Ia., reports a dislocation of the humerus into the axilla occurring in a child two years old; the accident was due to the sudden lifting of the child by the extended arm.]

Pathology.—In this accident the head of the bone is made to press against the capsule below and immediately in front of the long head of the triceps, until the capsule gives way, and continuing to descend in the same direction it is finally arrested by the triangular surface of the inferior edge of the scapula immediately below the glenoid fossa. Owing to the pressure of the tendon of the triceps behind, it occupies a position also a little in advance of the centre of this triangle, or rather upon its anterior edge, so that it rests more or less upon the belly of the subscapularis muscle.

The capsule is generally torn quite extensively, especially below and in front; and the tendon of the long head of the biceps may be broken asunder, or detached completely from its insertion; the supra-spinatus muscle is stretched or lacerated; the infra-spinatus, subscapularis, and coraco-brachialis are put upon the stretch; the subscapularis being also sometimes completely torn from its attachment to the head of the humerus, and in either case, whether torn or merely compressed and stretched, the circumflex nerve, which runs along its lower margin, is subject to severe injury; the deltoid muscle is also placed in a condition of extreme tension; while the teres major and minor in this respect are subjected to but little change. In some cases a portion or the whole of the greater tuberosity is completely detached, and the fragment displaced by the action of the muscles inserted into it.

[Mr. Avill reports a case of dislocation of the shoulder without rupture of the capsule: J. B., aged 69, fell a distance of eighteen feet upon the pavement, pitching on his right elbow and side, producing a dislocation of the shoulder and a T-fracture of the elbow. He died on the twelfth day after admission. Post-mortem examination revealed the following: The head of the humerus was in its proper position in the glenoid cavity, and the capsule of the joint quite intact; it seemed more lax than it normally should be, and its attachment to the anterior border of the glenoid cavity somewhat raised, being stripped off the bone to a slight extent, but still continuous with the periosteum. The coracoid process was torn off the scapula, but was still attached to the short tendon of the biceps, and all the muscles surrounding the joint were quite sound, with the exception of the subscapularis, which was slightly lacerated.⁵]

In one case the axillary artery has been ruptured. The patient had been thrown down by a runaway horse, and was taken to Jervis Street Hospital, London. On the tenth day Surgeon O'Reilly tied the subclavian artery, and the patient recovered after the loss of two fingers from erysipelas and gangrene.⁶

¹ Scatliff, *The Lancet*, 1878, vol. i. p. 31.

² Coombs, *Idem*, p. 150.

³ Lehman, *Amer. Journ. Med. Sci.*, vol. i. p. 242, 1828.

⁴ *Medical Record*, Sept. 27, 1890.

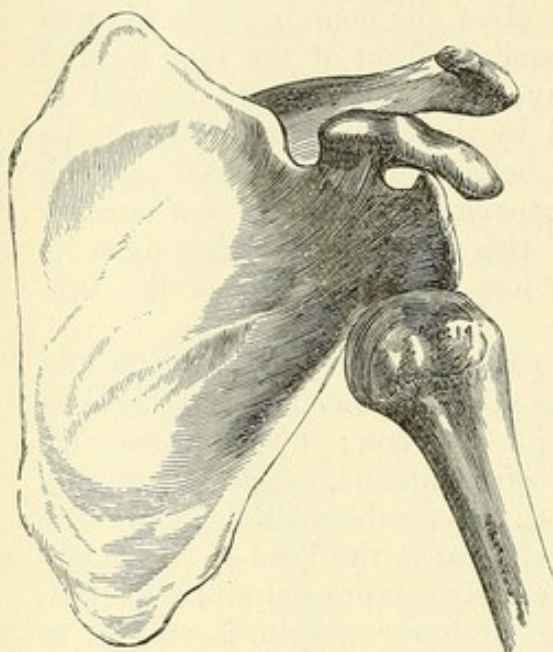
⁵ St. Barth. Hosp. Reports, vol. xxiv., 1888.

⁶ Todd's *Cyclop. Anat. and Surg.*, p. 616; Holmes's *Surg.*, vol. ii. p. 827.

With more or less rapidity, after the occurrence of the dislocation, if the bone remains unreduced, various changes take place in the anatomical relations and structure of the parts.

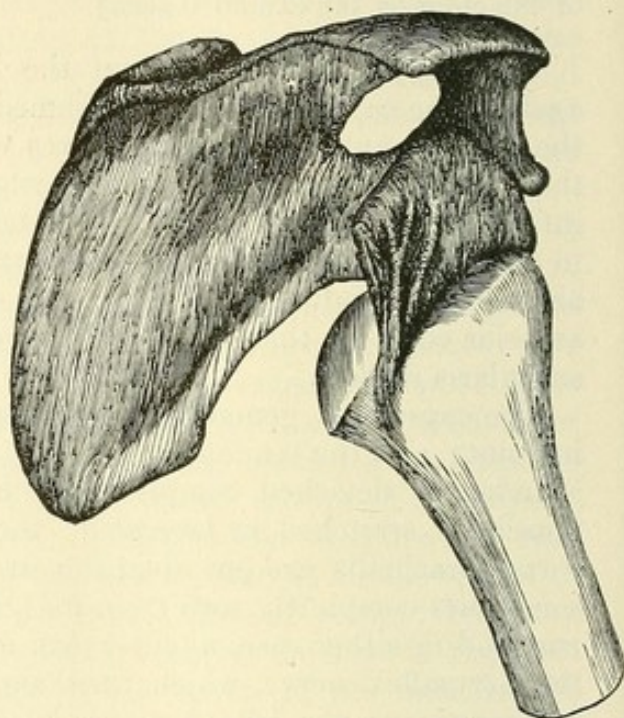
The following is a brief account of the condition in which the parts were found in the case of an old man, whose history is unknown. The dissection was made by my assistant, Dr. Deems, at the Bellevue dead-house. The head

FIG. 356.



Dislocation of the shoulder downward into the axilla. (Subglenoid.)

FIG. 357.



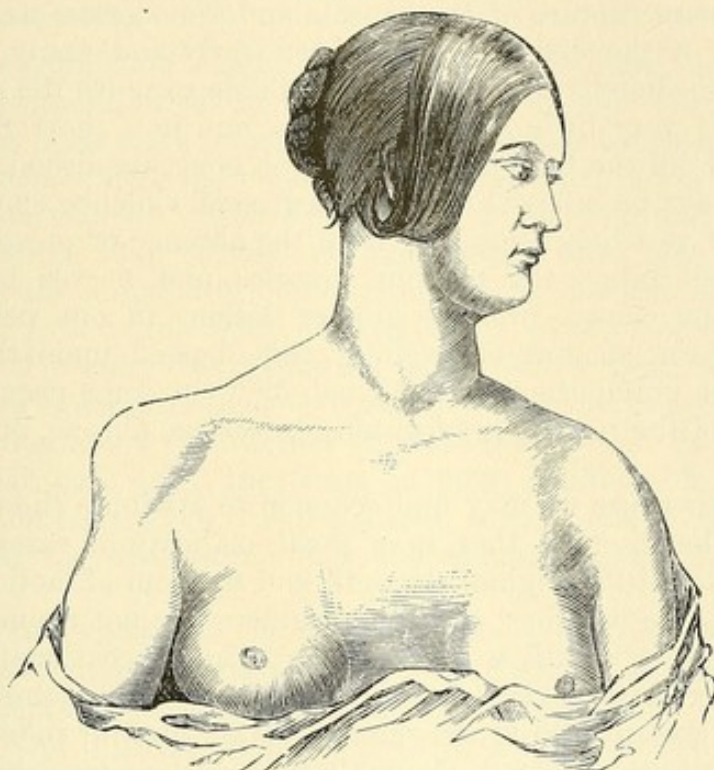
Dislocation downward, showing the untorn portion of the capsular ligament. (Gunn.)

of the humerus was in front of the socket, below, but not in contact with, the coracoid process, lying upon the anterior surface of the neck of the scapula. A new socket was formed in the bone at this point, mostly cartilaginous, and a fibrous capsule inclosed the head of the humerus. The margins of the old socket were removed, and the socket was filled with fibrous tissue. The axillary nerves and artery were not injured or compressed. The biceps tendon was not torn. All the muscles about the shoulder were atrophied.

Symptoms.—A palpable depression immediately under the extremity of the acromion process, more distinct in children, in very old, and in thin people, than in adults of middle life or than in fat or muscular people, but never absent completely, unless the shoulder is very much swollen; the elbow carried out from the body three or four inches, sometimes a little backward, and the line of its axis directed toward the axilla; the outer surface of the arm presenting two planes inclined toward each other, and meeting at the point of insertion of the deltoid muscle; the head of the humerus felt in the axilla, particularly when the elbow is carried away from the body; numbness of the arm, accompanied generally with pain, especially when any attempt is made to press the elbow against the side; rigidity with inability to move the arm freely in any direction, but especially inward; allowing, however, of pretty free passive motion, but not permitting the elbow to touch the body without great

pain, which pain is occasioned mostly by the pressure of the humerus upon the axillary plexus ; under no circumstances can the hand be placed upon the opposite shoulder while at the same moment the elbow touches

FIG. 358.



Appearance of dislocation of the shoulder. (Subglenoid.)

the thorax ; the head of the patient, and sometimes the whole body, inclined toward the injured arm ; the arm lengthened from half an inch to an inch ; a chafing or friction sound is not unfrequently present, especially if the bone has been some days dislocated.

Mr. Lawrence mentions a case in which there was a distinct crepitus, yet there was no fracture ; Dr. Hays saw a similar case in Wills Hospital, Philadelphia, in a woman 60 years old, whose arm had been dislocated forward eight weeks.¹ Other surgeons have related like examples, but it is probable that in all these cases there has been an exposure of the bone at or near the edge of the glenoid fossa, by the partial detachment of its ligamentous margin, or some portion of the head has become divested of its cartilaginous covering.

Decisive as these signs usually are of the true nature of the accident, cases will occur in which the diagnosis will be attended with great difficulty, and especially if a few hours have been permitted to elapse since the occurrence of the injury, so that considerable effusions of blood and of lymph may have taken place ; while at a still later period, when the swelling has subsided, the diagnosis again becomes easy.

In a rapid review of the cases of dislocation of the shoulder which have come under my notice, and of which I have taken pains to make a record, I find thirteen subglenoid and ten subcoracoid dislocations which were not recognized as such by the surgeons first called. Some were mistaken for fractures, and some

¹ Lawrence, Hays, Amer. Journ. Med. Sci., vol. xxiv. p. 236, May, 1839.

were called contusions or sprains. And among the surgeons who fell into these errors are some of our oldest and most experienced hospital surgeons.

Prognosis.—If the force which displaced the bone was not great, or if the shoulder-joint has not suffered any injury from the accident itself beyond the mere rupture of the capsule and a moderate straining of the muscles, and if the dislocation has been early and easily reduced, the patient is immediately after the reduction able to move the arm freely in all directions; very little swelling follows, and in a short time a perfect restoration of all the functions of the limb is accomplished. It cannot, however, always be inferred from the degree of violence employed in the production of the dislocation, nor from the absence or presence of swelling, how much injury the tendons, muscles, and nerves have suffered, since the same causes produce greater lesions in one person than in another, and the amount of swelling may depend upon the accidental rupture of an unimportant bloodvessel, or upon some peculiarity in the constitution of the patient predisposing to serous, fibrous, or sanguineous effusions.

To whatever cause we may find occasion to attribute the result, it will nevertheless be observed that, in a great majority of cases, the limb is not restored to all its original strength and freedom of motion until after the lapse of some months; and the shoulder does not resume its perfect form and symmetry until a much later period; occasional pains, especially after exercise of the muscles, and in certain conditions of the weather, are present also at irregular intervals and for indefinite periods of time. Opposite and more favorable terminations must be regarded as exceptions to the rule. Where the reduction has been made within a few hours, I have found the shoulder affected with muscular ankylosis with more or less weakness of the arm after a lapse of from a few days to one or two years.

A laborer, *æt.* 41, had dislocated his right shoulder into the axilla. Dr. H., an intelligent young surgeon, reduced the bone easily with his hands alone, while the patient was still unconscious from the shock of the injury. After six weeks he called upon me, accompanied by his surgeon, thinking that it was not properly reduced because the arm was still painful, and he could not move it freely. The bone was, however, well in its socket. One year later I examined this man, and found some ankylosis remaining in his shoulder-joint.

J. R., *æt.* 39, fell while running, and struck upon his right shoulder. Dr. Eastman reduced the dislocation four hours after the occurrence, in the following manner: The patient being seated in a chair, Dr. Eastman placed his knee in the axilla and manipulated, while one assistant supported the acromion process, and another pulled downward upon the forearm. The time occupied in the reduction was about two minutes, and the bone finally resumed its position with a snap audible to all the persons in the room. For some months after, and at the period when I saw him, the muscles about the shoulder were rigid, and the motions of the joint embarrassed; but at the end of two years, Dr. Eastman informed me that the joint had become free and the arm as useful as before, except that he could not throw a stone.

In another case, a gentleman residing in an adjoining county, *æt.* 42, was thrown from his carriage, falling forward upon his hands. The dislocation was reduced promptly, by placing the heel in the axilla, and within fifteen minutes after it had occurred. Three months after this the patient consulted me on account of the immobility of the shoulder-joint, and because several surgeons had expressed a doubt whether it was properly reduced. The ankylosis was then

so complete that the humerus could not be moved separately from the scapula, but there was no displacement. This gentleman again called upon me at the end of four years, and I then found the arm nearly restored to its original condition, but it was not quite so strong as before. He experienced also "curious" sensations in his arm and hand occasionally. The ankylosis had continued with very little improvement about two years, after which it had been gradually disappearing.

In those examples in which the reduction of the bone has been delayed beyond a few hours, or for several days or weeks, the continuance of the ankylosis has been more persistent; but in no case which has come under my observation, unless the bone still remained unreduced, has the ankylosis been permanent. For this reason I am disposed to think that muscular, rather than fibrous or ligamentous ankylosis, is the cause, generally, of the immobility of the joint. I have certainly never in any instance met with a true bony ankylosis as a consequence of a shoulder dislocation. The ankylosis in question seems to be a result simply of laceration, or more generally of a severe strain of the muscular fibres, resulting in inflammation and a contraction of these fibres; and its occurrence in any particular case may, therefore, be justly attributable either to the position of the bone when it is dislocated, to the force of the blow which has produced the dislocation, or to the violence applied in the attempts at reduction.

Paralysis and wasting of the muscles of the arm, either with or without muscular contraction and rigidity, are also observed in a certain number of cases. Especially has it been noticed that the deltoid muscle is liable to atrophy; and in their attempts to explain the frequency of its occurrence in this latter muscle, surgeons have generally referred to a probable rupture of the circumflex nerve, a circumstance which the autopsies show does occasionally take place; or to a mere stretching of this nerve; yet it is quite as fair to presume that in many cases it is due solely to the greater injury which the deltoid muscle has sustained by the unnatural position of the head of the bone during the continuance of the dislocation, for, with the exception of the supraspinatus, it is placed more upon the stretch than any other. Nor is it improbable that in some cases it is due to the mere force of the blow, which, having been directly upon the top of the shoulder, has contused the muscle. In short, any of the causes which may determine in the deltoid inflammation and consequent rigidity, must finally result in desuetude and consequent atrophy.

In the case of an adult, P. Madden, who consulted me in June, 1874, there were slight atrophy and paralysis of the deltoid, and almost complete atrophy of the supraspinatus, with much ankylosis, due to prolonged efforts at reduction. In quite a number of cases my attention has been called to a remarkable fulness just in front of the head of the bone, which has continued sometimes for many months and even years after the reduction has been effected; the patients having in several cases applied to me to know whether this did not indicate that the bone was not in its socket, especially as it has usually been attended with some stiffness in the joint. Not unfrequently I have been told that surgeons who had noticed this fulness thought the bone was not reduced; and in one instance I am informed that a jury returned a verdict against the surgeon, where there was no other evidence of malpractice than this fulness with some ankylosis, but which, in the opinion of some medical gentlemen who testified, was conclusive evidence that the bone was not properly set. The deception is also often the more complete from the fact that there may exist a corresponding depression

underneath the acromion process, behind. These phenomena may be present where but little force has been used, either in the production of the dislocation or in its reduction. I have seen it in a girl only 14 years of age, who had dislocated her left shoulder into the axilla, by a fall upon a slippery sidewalk. I reduced the bone within half an hour after the accident. I lifted the arm to a right angle with the body, and pulled gently, and the reduction was at once accomplished; but I immediately noticed that the head of the bone seemed to press forward in the socket so as to resemble what Sir Astley Cooper has described as a partial forward dislocation. There was also a corresponding depression behind. Carrying the elbow back rendered the projection more decided, but bringing it forward did not make it entirely disappear.

In other instances where the deformity in question has been present, more force has been employed in the reduction.

A man weighing two hundred pounds, fell from a load of hay, striking upon the top and front of the left shoulder. It was immediately ascertained that he had dislocated his arm into the axilla, and broken his leg. A young surgeon attempted within a few minutes to reduce the dislocation, but failed; and about two hours later it was reduced by another surgeon, with the aid of chloroform and Jarvis's adjuster. Four years after the accident this gentleman came to me accompanied by the surgeon who had made the reduction, in consequence of its having been intimated by some medical men that it was not properly reduced. The arm was not as strong as the other; some ankylosis existed at the shoulder-joint; but especially it was noticed that there remained a remarkable fulness in front, as if the head of the bone was pressed forward. By no manipulation or position could this fulness be made to disappear, yet the bone was plainly enough in its socket.

This phenomenon is probably due in some cases to a rupture of the supraspinatus muscle, and the consequent preponderating action of the antagonizing muscles, or to the extensive laceration of the capsule; but in others to a rupture or possibly to a displacement of the long head of the biceps, a circumstance to which I shall more particularly allude under the subject of "Partial Dislocations." Among the results of this dislocation must be placed a tendency to redislocation, which, although it may not often be made manifest by its actual occurrence, owing perhaps to the prudence of the surgeon, yet it does take place in a sufficient number of cases to establish its peculiar liability. Indeed, we need only consider how imperfect is the protection against this accident, when once the capsule has been torn, to appreciate this observation. Examples of spontaneous dislocation, or of dislocation of the shoulder from very trivial causes after it has once been dislocated, may be found in the experience of almost every surgeon. I have met with several persons who have had repeated dislocations from a slight cause, and in some instances where the patients were subject to epilepsy the dislocations have occurred whenever the convulsions returned.

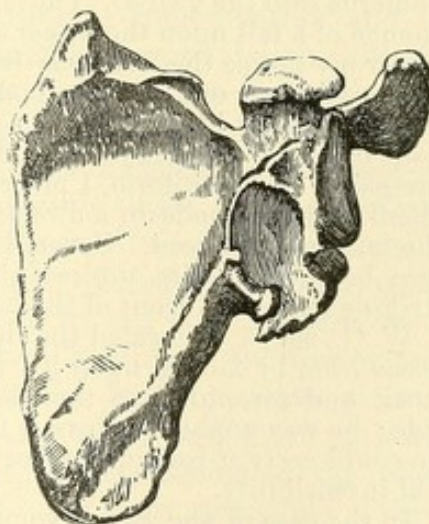
A gentleman had a dislocation of the right shoulder into the axilla when he was quite a child, and the accident was renewed when 29 years old by falling from a carriage head-foremost, with his right arm extended and uplifted. Since then, a period of about six years, he has been constantly subject to the same dislocation; and he cannot raise his arm high above his shoulders without producing a partial dislocation, the head of the humerus resting upon the outer margin of the lower and anterior edge of the glenoid fossa, but by rotating the arm outward it immediately resumes its place. I found the whole limb as fully developed, and he said it was quite as strong, as the opposite limb.

I have already mentioned the case of Mrs. Hunn, whose arm had been dislocated more than twenty times during five years. A lad, aged 19 years, dislocated his left arm by falling from the masthead of a vessel, and hanging by his hand. No attempt was made to reduce it until fourteen hours after the accident, at which time it was set by two German doctors, but not until they had pulled upon it three hours. Four months after, it was again dislocated by the slipping of an oar while he was rowing a boat. A surgeon having failed this time to bring it into place, I succeeded readily, and without the aid of an anæsthetic, by raising the arm directly upward in the line of the body, while my foot was pressed upon the top of the scapula. Many other similar examples have come under my notice.

I have referred to the writers who mention many examples of unreduced dislocations of the shoulder, for which surgeons of skill and experience were responsible. I have myself met with these cases quite often. I have seen two dislocations of the humerus into the axilla, both of which had been seen and examined by New York hospital surgeons within a few hours after the receipt of the injury, but the nature of the accident had not been recognized. One of these I reduced at Bellevue Hospital on the seventh day, and one on the tenth. In other cases the dislocation has been clearly made out, but the surgeon has been unable to reduce the bone.

M. K., æt. 49, a large, fat, laboring woman, was admitted into the Buffalo Hospital with a dislocation of the right humerus into the axilla, which had occurred twelve hours before. This is the same woman of whom I have before spoken as having produced the dislocation by a fall while holding upon the handle of a pump. Drs. Lockwood and Baker were first called, and attempted reduction. They made extension and counter-extension in every possible direction, and for a long time, but to no purpose. Having placed her completely under the influence of chloroform, the manipulations were made assiduously during one hour, without success. On the following morning she was bled freely from the opposite arm, and chloroform again administered; extension being made with Jarvis's adjuster. After more than an hour, the effort was again suspended. On the following day we made a third attempt, the patient being completely under the influence of chloroform, but with no better success. The chloroform produced a condition approaching apoplexy, and it was not again used. On the tenth day, assisted by other surgeons, we applied the compound pulleys, moving the arm in various directions. Twice we thought the reduction was accomplished, but as often we proceeded to examine it attentively we found it was not. If it did ever pass into the socket, it was immediately displaced. Sir Astley Cooper has thus described the appearances presented on dissection of a dislocation which had been long unreduced: "The head of the bone altered in its form; the surface toward the scapula being flattened. A complete capsular ligament surrounding the head of the os humeri. The glenoid cavity entirely filled by ligamentous matter, in which were suspended small portions of bone, which were of new formation, as no portion of the scapula or humerus was broken. A new cavity formed for the head of the os humeri on the inferior costa of the scapula; but this was shallow, like that from which the bone had escaped."

FIG. 359.



New socket, in an ancient dislocation of the shoulder downward. (From Sir A. Cooper.)

When the dislocation into the axilla remains unreduced, the consequences are always sufficiently grave; but they differ very much in degree, in character, and in persistence, according as the arm has re-

mained a longer or a shorter time unreduced, and according to the presence or absence of complications. These conditions will be best illustrated by a reference to examples.

Wm. S., a German, æt. 51, fell down a flight of steps while intoxicated, producing a dislocation of the left arm into the axilla. Eleven hours after the accident he was received into the Buffalo Hospital. No attempt had been made to reduce the bone. The reduction was effected by myself with tolerable ease, by extending the arm perpendicularly above the head, while my foot pressed upon the top of the scapula. The head of the humerus could be plainly felt in the axilla, approaching the socket, until it seemed to be directly over it, when, on lowering the arm, it was found to be reduced. After the reduction the patient could not raise the arm more than eight inches from the body. The fingers, hand, and forearm were almost paralyzed. Three weeks later, when he left the hospital, his arm had improved, but he could not flex his fingers.

Mrs. G., æt. 70, fell down a flight of steps and dislocated her arm into the axilla. She did not suspect the nature of the injury, and no surgeon was called. I was consulted one week after the accident, at which time she was suffering great pain from the pressure of the head of the bone upon the axillary nerves. We first attempted to reduce the bone by resting the knee in the axilla while she was sitting, but without success. We then placed her in bed, and with my knee in the axilla, the acromion process being supported by the hands of an assistant, we restored the bone after a few moments of pretty firm extension downward and outward. After the reduction she could not raise her arm, but the pain was much abated. One month later the arm remained very weak. She could not raise it more than six inches toward her head, but I could raise it to a right angle with the body without causing pain. The whole hand felt numb, and was occasionally painful. The deltoid muscle was slightly atrophied. There was also a slight flatness under the acromion process behind, and on the outer side, with a corresponding fulness in front.

M. A. H., æt. 47, was admitted to the hospital with a dislocation of the right humerus into the axilla. The arm had been dislocated three weeks, in consequence of a fall upon the upper and outer part of the shoulder. When she came under my notice the arm was lengthened about one-quarter or one-half of an inch, and hung out from the body in a condition of almost complete paralysis. There was very little swelling about the shoulder or arm, and the head of the bone could be distinctly felt in the axilla. The patient being rendered partially insensible by chloroform, I placed my heel in the axilla, and pulling moderately about thirty seconds in a direction slightly outward from the line of the body, the bone was reduced. Seven days after the reduction she left the hospital, the arm being yet quite useless, though not greatly swollen. There was also a striking fulness in front of the head of the bone.

W. G., æt. 75, dislocated the right humerus into the axilla, twenty years before I saw him, by falling upon his hands with his arm extended. I found the arm weak and atrophied, so that he could raise it but slightly outward from his side; he was unable to move it forward much beyond the line of his body; but he could carry it back quite freely. The whole hand was in a condition of partial insensibility.

In the case of the Swiss woman, whose arm had been dislocated downward seventeen years, the deltoid muscle has become greatly wasted; the head of the bone can be felt obscurely in the axilla; the arm is shortened perceptibly; the elbow hangs freely against the side; the little and ring fingers are numb, and also one-half of the forearm; the whole hand and arm are weak and atrophied; she complains also occasionally of a troublesome sensation of formication over the arm and hand; she cannot straighten her fingers perfectly; the elbow may be raised from the side to a right angle with the body, but she cannot raise it herself more than one foot; she carries it back a little more freely than forward.

In compound dislocations the prognosis must always be regarded as exceedingly grave.

In the only example which has come under my notice, the circumstances attending which I shall hereafter mention in the general chapter devoted to Compound Dislocations, the patient died from sloughing of the axillary artery. Mr. Scott has, however, reported a case, in a boy fourteen years of age, who recovered rapidly after the reduction was effected, and in thirteen months his arm was nearly as useful as before.¹

Treatment.—The principles of treatment in this dislocation are very simple and easy to be comprehended. I speak now of recent uncomplicated cases of dislocation into the axilla; and, notwithstanding the various and sometimes almost contradictory views which surgeons have entertained as to the best and most rational modes of procedure, I continue to affirm that the laws which are to govern the reduction in a great majority of cases are established and indisputable. Observe now the obvious anatomical facts, and then consider the inevitable inferences. The capsule is torn, generally extensively, along the inner and lower margins of the socket. The head of the bone is lodged below and slightly in advance of its natural position, in consequence of which the points of origin and insertion of the deltoid muscle and the supraspinatus are separated somewhat and their fibres rendered tense, insomuch that the arm is abducted and actually lengthened.

At first, and in the most simple cases, these are the only muscles which are in a state of extreme tension, but after the lapse of a few hours, or of a few days, nearly all the other muscles about the joint, most of which were originally only in a condition of moderate extension, and some of which were rather relaxed than extended, sympathize with those which are suffering the most, and a general contraction and rigidity ensue, increased also at the last by the supervention of inflammation and its consequences. What, from these simple premises, must be the obvious practical deductions? That in the simplest forms of the dislocation the most rational mode of reduction will be to elevate the arm sufficiently to relax the overstrained deltoid and supraspinatus muscles, which, together with the upper and untorn portion of the capsule, bind the head of the bone in its new position, and to pull gently in the same direction, in order to overcome the moderate resistance offered by several other muscles, but whose tension cannot be relieved by the same manœuvre.

Failing in this, that we shall increase the relaxation of the first-named muscles, by pulling at a right angle with the body, or even directly upward; and meanwhile, as we carry the arm more and more upward, we shall operate more powerfully against the resistance of the other muscles. If in all these modifications of the same procedure except when drawing directly upward, we keep the arm a little back of the axis of the body, we shall accomplish the indications the most perfectly.

Such are the conclusions which must be drawn from the anatomical, or, as Mr. Pott would call it, the "physiological," argument; and which assumes as its basis that the muscles with the untorn portion of the capsule constitute the sole or the main obstacle to the return of the bone to its socket.

¹ Scott, Amer. Journ. Med. Sci., vol. xx. p. 515, Aug. 1837, from the London Lancet, March 4, 1837.

It must not be forgotten that in all these modes of extension, for with nearly all of them some slight degree of extension is found necessary, there must be afforded some point of resistance beyond the bone; and this it is really which has constituted one of the greatest impediments to reduction. It is not that the muscles are in such an extraordinary state of extension or rigidity that they must be operated against with great force; it is not that the margin of the glenoid fossa is an elevated barrier, like the margin of the acetabulum, over which the bone must be lifted before it can fall into its socket; but the explanation of the difficulty so often experienced in producing effective extension and counter-extension is to be sought for mainly in the fact that the scapula, upon which the humerus rests, is movable, being held to the body by little else than muscles, which, in fact, bind the scapula much less firmly to the body than the muscles of the shoulder now bind the scapula to the arm; while at the same time the scapula itself presents very few points against which a counter-extending force can be properly and efficiently applied.

Occasionally it will be only necessary to elevate the arm to an acute angle, or to a right angle with the body, when, the resistance of the deltoid and supraspinatus being overcome, the bone will at once resume its place. In several instances which have come under my notice nothing more has been necessary; and where it can be done, the least possible pain and injury are inflicted. It is the method, therefore, which in all recent cases I have first tried and would wish to recommend. By it I have more than once succeeded when other and more violent efforts failed. At other times it will be necessary to add to this simple manipulation only a moderate degree of extension, such as the hands of the surgeon can make, without the application of direct counter-extension except what is effected by the weight and resistance of the body.

Professor Moses Gunn, of the Rush Medical College, Chicago, who regards the upper and untorn portion of the capsule as the chief obstacle to the reduction, says: "For the reduction of this dislocation it is convenient to have the patient sit upon the floor. The arm is then raised to an angle of 45 degrees from the horizontal, and intrusted to an assistant, while the surgeon places his hands on the shoulder with the tips of the fingers in the axilla, resting on the dislocated head. The assistant now makes upward and outward traction, and the head glides into place followed by the surgeon's fingers in the axilla. The arm is then lowered to the pendent position, keeping up the tension till the arm is by the side of the body."¹

The late Dr. John T. Darby, Professor of Surgery in the University of the City of New York, informed me that he had been very successful in reducing dislocations of the shoulder, by adopting a rule similar to that which I have laid down for reducing dislocations of the thigh, namely, to carry the arm only in those directions in which it meets with the least resistance. He found that, in most cases, he could carry the arm up to nearly or quite a perpendicular, by humoring the action of the muscles; and that in this position the reduction was easily effected. I have no doubt that the principle, as stated by Professor Darby, is sound, and that in nearly all dislocations the same may be applied successfully, whenever we can depend upon manipulation alone.

If, however, the bone refuse to move, we shall then be obliged to consider upon what point and by what means we can best apply a counter-extending force. Ample experience has taught me that the extremity of the acromion process is the only available point when we are making

¹ Gunn, *The Philosophy of Manipulation in the Reduction of Hip and Shoulder Dislocations*. Read before the American Surgical Association, 1884. Also *Chicago Med. and Surg. Journ. and Exam.*, May, 1884.

the extension in a line below a right angle, or in a line downward more or less approaching the axis of the body. It has been supposed that the counter-extension could be made in the axilla against the inferior margin of the scapula; but several obstacles are presented to the successful application of force at this point. The axillary space is narrow and deep, so that even with the ingenious contrivance of placing first a ball of yarn in the axilla, and upon this the heel of the operator, it will be found exceedingly difficult to enter the axilla without at the same time pressing with considerable force against its muscular margins; but to press upon the pectoralis major and latissimus dorsi is to neutralize our own efforts. If, however, the heel or the ball does press fairly into the axilla, it will not find the scapula readily, but it must impinge first upon the head of the humerus, which is always a little to the inner side of the scapula. If it ever is made to reach actually the inferior border of the scapula, and I do not think it is, the effect must be still only to tilt the scapula upon itself by throwing back its lower angle, and not to separate the glenoid cavity or its upper and anterior margin from the head of the humerus.

Whatever success, therefore, may have attended this mode of practice, either in my own hands or in the hands of other surgeons, must be ascribed not to the counter-extension thus effected, but simply to the operation of the heel as a wedge, which, by insinuating itself between the body and the head of the bone, has thrust it outward and upward into its socket; or to its having acted as a fulcrum upon which the humerus has operated as a lever. It is to the extremity of the acromion process, then, that we must apply our counter-extension when we are employing this mode of extension. The fingers or hands of a faithful assistant may answer the purpose, or, having removed his boot, the operator may often press successfully with the ball of his foot, and the more he carries the arm outward, the more secure will be his seat upon the process; or we may adopt some of the contrivances for securing the process which have been suggested by other surgeons; such as a band crossing the shoulder, and made fast to a counter-band, which passes through the armpit and against the side of the body.

Dr. Physick, of Philadelphia, reduced a dislocation in this way as early as the year 1790, in the case of a patient admitted to St. George's Hospital, in London, while he was a student of medicine, and he subsequently taught the same in his lectures. Physick directed that an assistant should press firmly against the process with the palm of his hand. Dorsey and Hays approved of the same method,¹ and perhaps a majority of American surgeons have regarded it favorably.

If we pull directly outward, at a right angle with the body, we may still continue to press upon the acromion process with the foot.

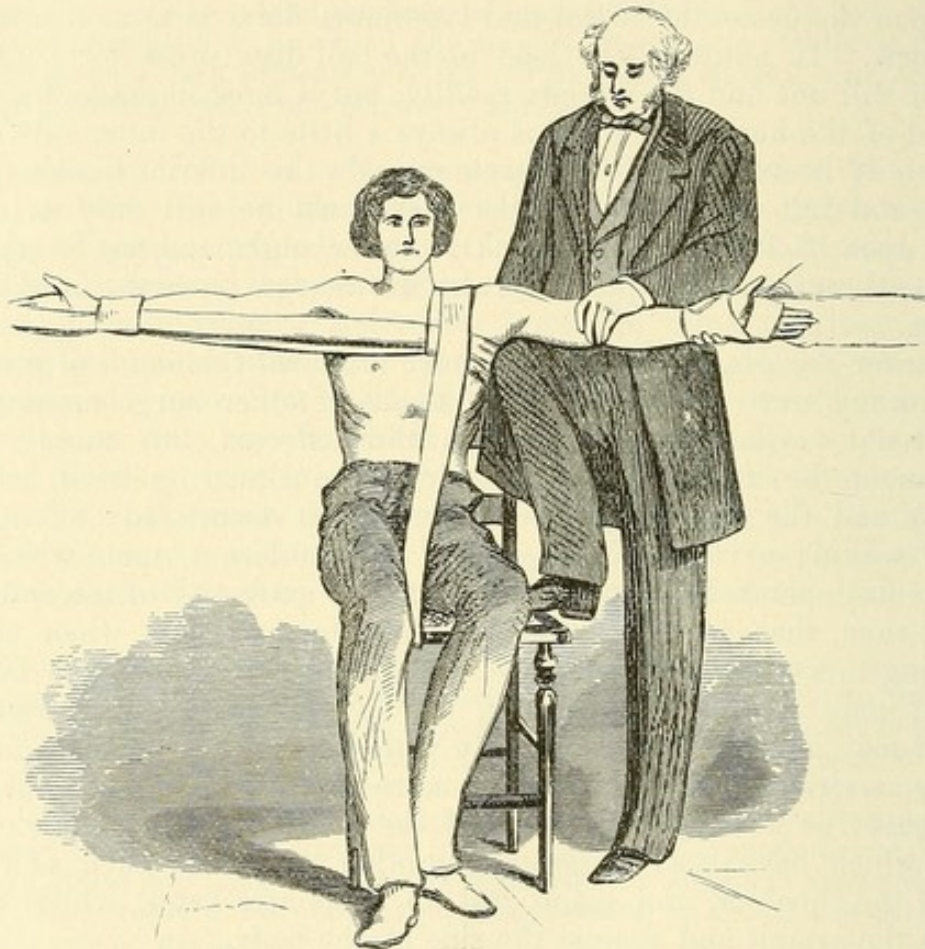
Prof. N. R. Smith² says: "What surgeon of experience has not encountered the difficulty which almost always occurs in fixing the scapula?" and he then

¹ Physick, *Amer. Journ. Med. Sci.*, vol. xix. p. 386, Feb. 1837. Dorsey's *Elements of Surgery*, vol. i. p. 214. Philadelphia, 1813.

² Smith's *Med. and Surg. Memoirs*, Baltimore, 1831, p. 337; also *Amer. Journ. Med. Sci.*, July, 1861; also *Amer. Med. Times*, Nov. 9, 1861; paper by Stephen Rogers, M.D.

proceeds to give what seems to him the most effectual mode of rendering the scapula immovable, namely, to make the counter-extension from the opposite wrist. By this method the trapezii are provoked to contraction, and the scapula of the injured side is drawn firmly toward the spine and the opposite scapula. In illustration of the value of this procedure he relates the case of a gentleman who had suffered a dislocation of his left shoulder, and upon whom an unsuccessful attempt at reduction had already been made by a respectable surgeon. Dr. Smith, being called, proceeded as follows: Two gentleman made counter-extension from the opposite wrist, while Dr. Smith made extension from the wrist of

FIG. 360.



N. R. Smith's method.

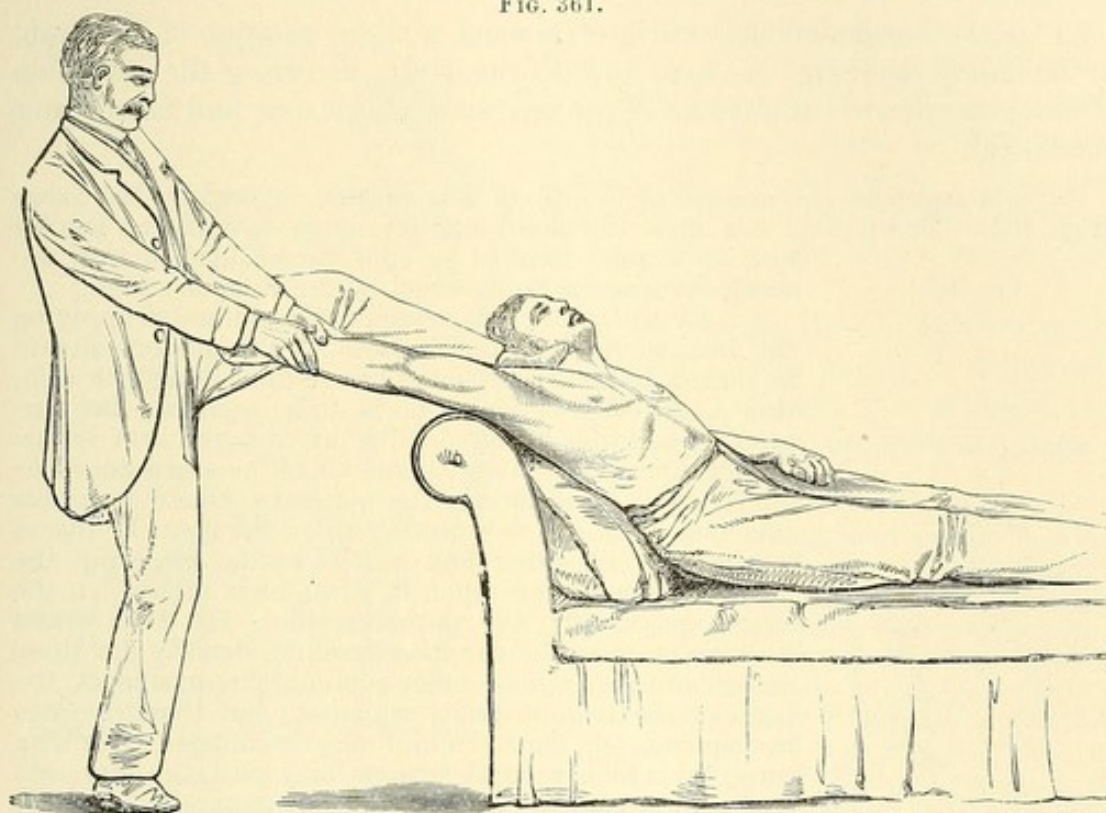
the injured side, at first pulling it downward, but gradually raising it to the horizontal direction, and then gently depressing the wrist. On the effort being steadily continued for two or three minutes, the bone was observed to slip easily into its place.

But no position places the scapula so completely under our control as that in which the arm is carried almost directly upward, and the foot is placed upon the top of the scapula. By this method we may succeed generally when every other expedient has failed; but it probably increases the danger of lacerating the axillary artery and vein; and even when employed in recent cases, it must sometimes do serious injury to the muscles about the joint (Fig. 361).

In Lister's case of rupture of the axillary artery, and in Agnew's case of rupture of the axillary vein, the accidents occurred when the arm was drawn upward.

La Mothe was the first to recommend pulling directly upward;¹ but as early as the year 1764, Charles White, of Manchester, made fast a set of pulleys in the ceiling, and placing a hand around the wrist of the dis-

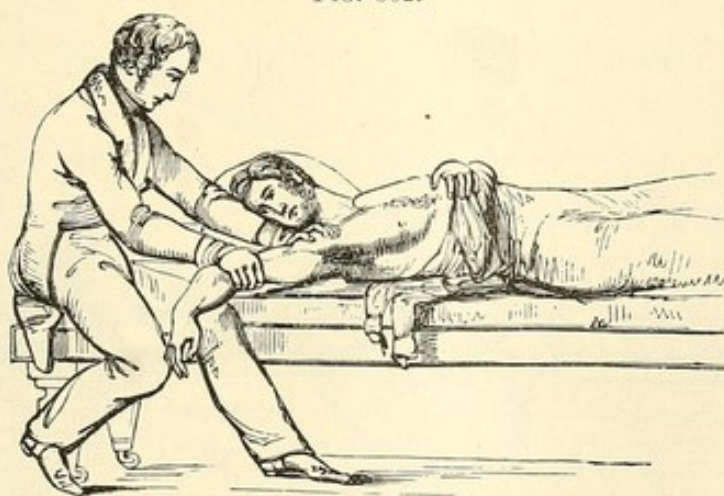
FIG. 361.



Reduction by extension upward.

located arm, he drew the patient up until the whole body was suspended. No pressure, however, was made upon the scapula from above, which is, no doubt, the most essential part of the process.²

FIG. 362.



La Mothe's method, modified.

¹ La Mothe, Amer. Journ. Med. Sci., vol. xix. p. 387, Nov. 1836, from *Mélanges de Méd. et Chir.*, Paris, 1812.

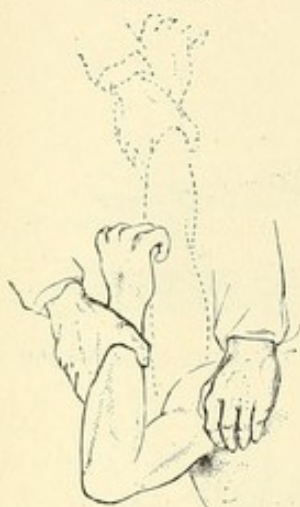² C. White, Amer. Journ. Med. Sci., Nov. 1836, from *Med. Obs. and Inquiries*, vol. ii. p. 273, London, 1764.

By La Mothe's plan, Jobert succeeded after twenty-three days, when all the usual methods had failed.¹ Sometimes this procedure is modified by placing the hand of the operator against the top of the scapula, as is shown in the accompanying drawing (Fig. 363); and I have several times succeeded in this way after other measures have failed.

A gentle movement backward or forward, a slight rotation of the limb, or suddenly dropping the arm toward the body, diverting the attention of the patient, are little tricks of the operator, which now and then prove successful.

[Bryant approves the method of White, of Manchester, revived by Mr. Lowe (Fig. 363). The patient sits upon the floor, and the surgeon, standing behind him on a sofa, forcibly extends the dislocated arm upward, the scapula being fixed by the surgeon's foot.]

FIG. 363.

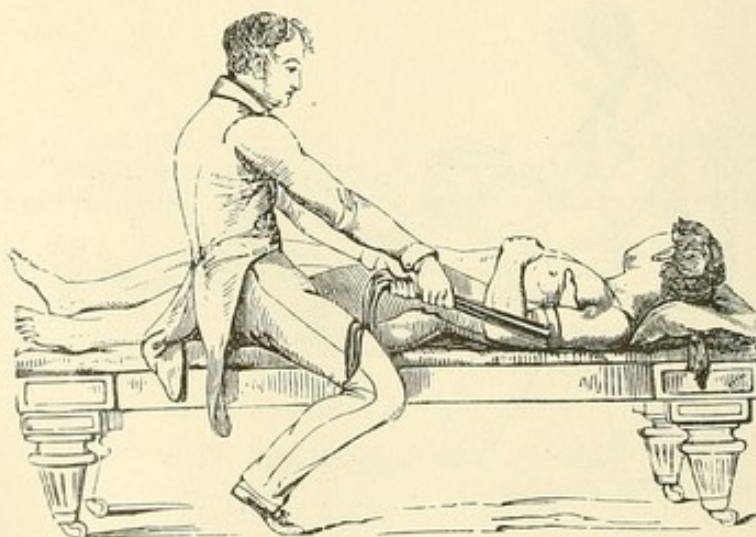


Reduction by extension of the arm upward. (Bryant.)

Sir Astley Cooper thus describes his method of applying the heel to the axilla (Fig. 364): "The patient should be placed in the recumbent posture upon a table or sofa, near to the edge of which he is to be brought; the surgeon then binds a wetted roller around the arm immediately above the elbow, upon which he ties a handkerchief; then he separates the patient's elbow from his side, and, with one foot resting upon the floor, he places the heel of his other foot in the axilla, receiving the head of the os humeri upon it, while he is himself in the sitting posture by the patient's side. He then draws the arm by means of the handkerchief, steadily, for three or four minutes, when, under common circumstances, the head of the bone is easily replaced; but if more force be required, the handkerchief may be changed for a long towel, by which several persons may pull, the surgeon's heel still remaining in the axilla. I generally bend the forearm nearly at right angles with the os humeri, because it relaxes the biceps, and consequently diminishes its resistance."

Sir Astley Cooper was also accustomed in some cases to reduce the dislocation by substituting the knee for the heel. Placing the patient upon a low chair, the axilla is laid over the knee of the operator, and while one hand

FIG. 364.



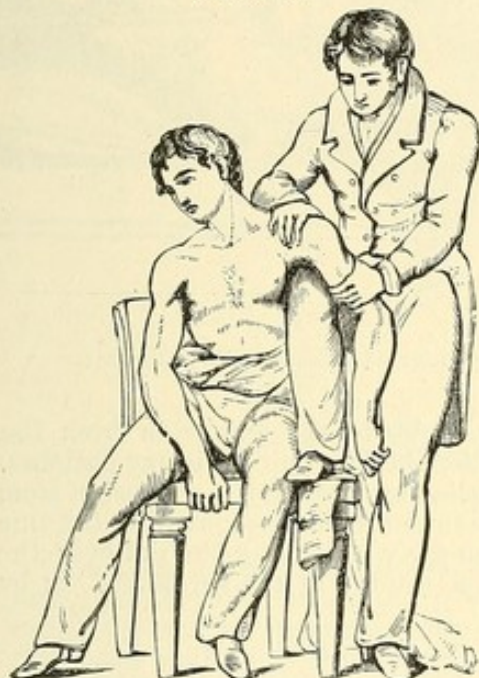
Sir Astley Cooper's method of applying extension with the heel in the axilla.

¹ Ibid., vol. xxiii. p. 237, Nov. 1838.

steadies the acromion process and scapula, the other presses downward upon the lower end of the humerus (Fig. 365.)

If some hours or days have elapsed since the occurrence of dislocation, it will be necessary to resort to chloroform or ether for the purpose of paralyzing the muscles, as well as with the view of preventing pain; and it may be necessary, in addition, to resort to pulleys, or to some similar permanent mode of extension. The same measures also sometimes become necessary in very recent cases, especially in muscular subjects.

FIG. 365.



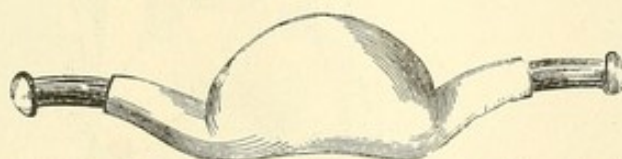Sir Astley Cooper's mode of operating with the knee in the axilla.

In employing the pulleys we generally operate, not exactly in a line with the axis of the body, nor at more than a right angle, but between an angle of 45° and a right angle.

Mr. Skey has suggested a plan by which we may combine the principle of the heel in the axilla with the pulleys, but which plan would, in my judgment, be very much improved by a counter-extending force applied to the acromion process. I ought to say, however, that Mr. Skey prefers that the scapula should not be fixed, believing that the reduction is much more easily effected when the glenoid cavity is drawn downward in the act of making the extension.

With all respect for the opinion of this distinguished surgeon, I cannot precisely agree with him; and while I would be disposed to recommend in some cases a trial of his method of applying the pulleys, I would, at the same time, or certainly in the event of its failure, add the acromial support, and especially

FIG. 366.



Iron knob employed by Skey, instead of the heel.

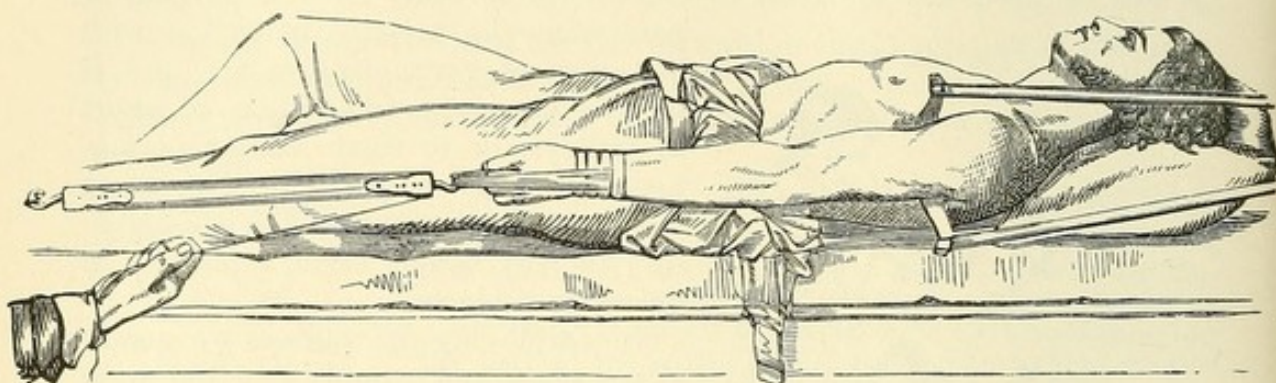
would I advise that the arm should be more abducted. The following is Mr. Skey's method, as described by himself: "There is no reason why, in very muscular subjects, or in old dislocations, the same principle may not be applied conjointly with the use of pulleys. For the purpose of retaining this admirable because most efficient principle, I employ a well-padded iron knob, which may represent the heel, from which there extend laterally two strong straight branches of the same metal, each ending in a bulb or ring of about four inches in length, the office of which is designed to keep the margins of the axilla as free from pressure as possible." The iron knob is to be pressed well up into the axilla and attached to cords fastened to a staple; the patient lying upon his back or inclined a little to the opposite side. The arm is then to be drawn downward by the pulleys, "as nearly as possible parallel to, and in contact with, the body."¹

In this way Mr. Skey says that he has succeeded in reducing a great many dislocations, even when occurring in very muscular men, and after some days,

¹ Skey, *Operative Surgery*, Amer. ed., p. 93.

weeks', or even months' duration; and he thinks the plan especially applicable to cases which require long and persistent extension.

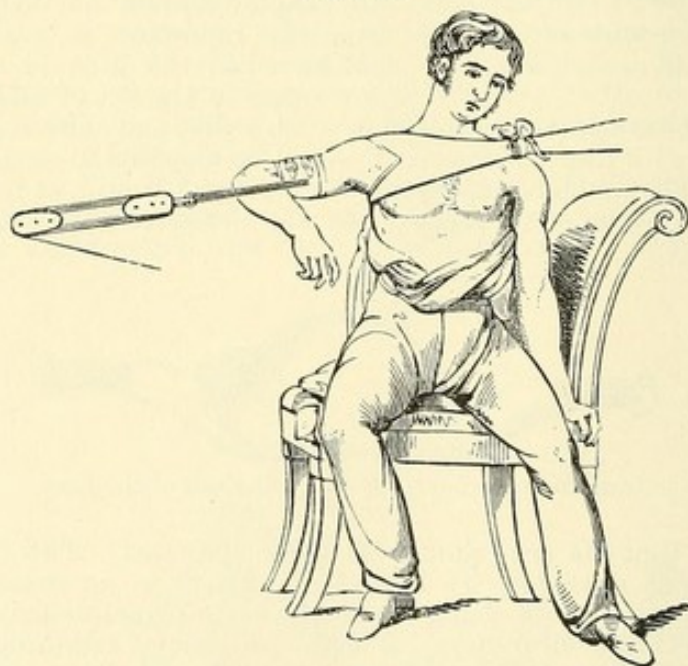
FIG. 367.



Skey's method of making extension and counter-extension with pulleys.

Mr. Skey and many other surgeons prefer to make the extension from the hand. I have succeeded as well, and it seemed to be less painful to my patients, when I have followed the practice of Sir Astley, and made the extension from the arm. Sir Astley always made the extension more or less out from the line of the body, and generally almost at a right angle when using the pulleys; the scapula being made fast by "a girt buckled on the top of the acromion," or by a split cloth (Fig. 368).

FIG. 368.



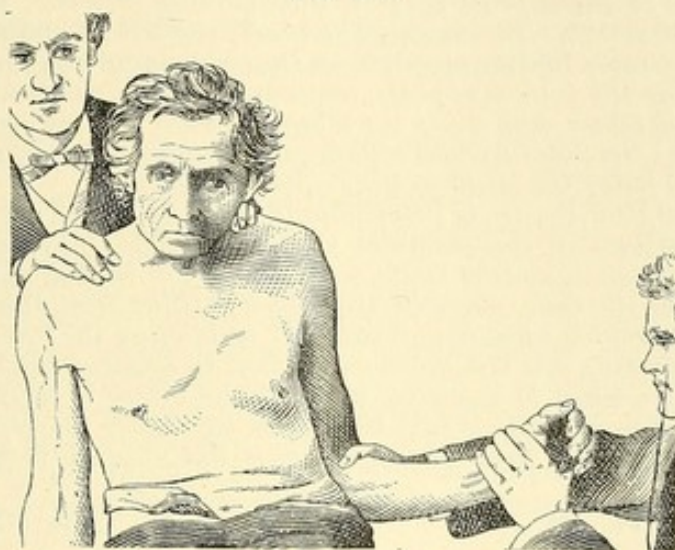
Sir Astley Cooper's mode of making extension with pulleys.

Kocher¹ flexes the forearm upon the arm; carries the elbow against the side of the body; abducts the hand, in order to rotate the head of the humerus outward, until resistance is experienced; carries the elbow forward, upward, and slightly inward, while the arm is still flexed at a right angle, and the hand maintained in a position of forced abduction;

¹ Kocher, *Rev. Men. de Chir.*, 1882, t. 2, p. 834.

then the arm is rotated inward, and the hand is carried upon the sound shoulder. All of these manœuvres are to be executed as slowly and gently as possible.

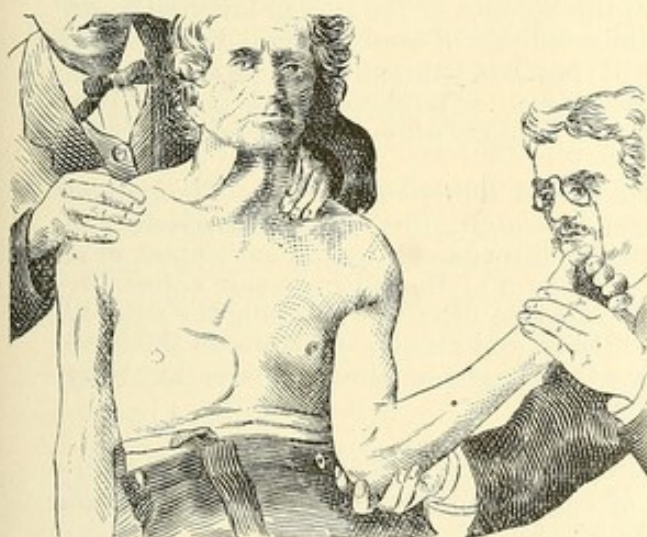
FIG. 369.



Kocher's method; first movement, outward rotation.

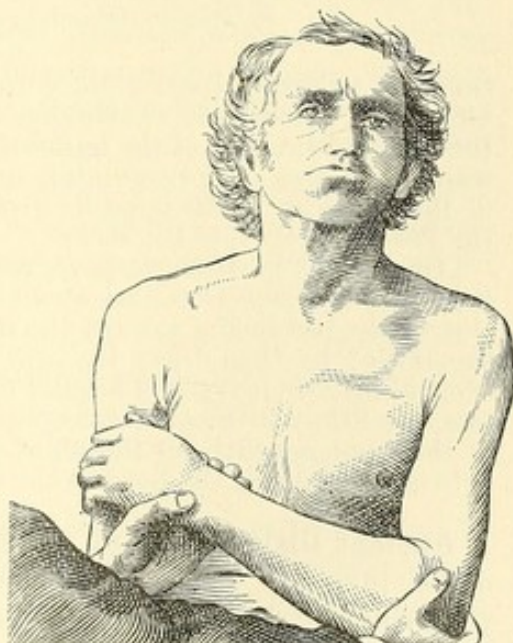
[Kocher's method has proved very successful. It is based on the following facts: In this dislocation the posterior portion of the capsule is untorn. The same is true of the tendons of the scapular muscles which cover it posteriorly; the lower portion of the capsule, forming the rent, is tense, but the tension is greatest at the upper part of the capsule, between the long tendon of the biceps and the upper margin of the subscapular muscle, where it is strength-

FIG. 370.



Kocher's method; second movement, elevation of elbow.

FIG. 371.



Kocher's method; third movement, inward rotation and lowering of elbow.

ened by the coraco-humeral ligament. This part of the capsule is twisted like a firm cord, and stretched. If the humerus is rotated outward, so that the forearm is turned out, this cord will also be rotated outward, the posterior part of the capsule will be removed from the fossa, and the torn capsule will

gape. The head of the bone remains fixed against the edge of the glenoid fossa, as the upper and lower parts of the capsule are still tense. But when the elbow is carried forward and raised, while the arm is held rotated outward, the upper part of the capsule relaxes and the head enters its socket, for the tension of the lower part of the capsule keeps it from moving forward; rotation inward completes the reduction. In rotating the head outward by abducting the hand there should be greater fulness apparent in the outer deltoid region; if the resistance begins before the fulness appears, maintain the external rotation of the arm and flexion of the elbow, and move the elbow forward and inward until the arm is horizontal. As the outer deltoid region now becomes more marked, rotate the arm inward, and carry the hand to the opposite shoulder.]

The practice of Prof. Smith, of Philadelphia (Figs. 372, 373), according to whom nearly all dislocations of the shoulder, of a recent date, may be promptly and easily reduced by manipulation alone, consists, first, in flexing the forearm upon the arm, while, at the same moment, the elbow is lifted from the body; second, in rotating the humerus upward and outward, employing the forearm as a lever; and third, in reversing this last movement—that is, rotating the humerus downward and inward—while at the same moment the elbow is carried again to the side.¹ When the dislocation is into the axilla, this latter manœuvre will generally succeed; but if the head of the humerus has slipped forward, even only

FIG. 372.

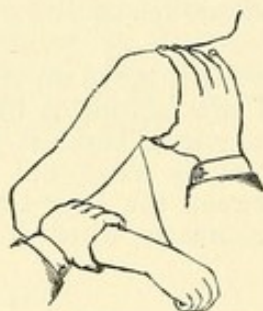
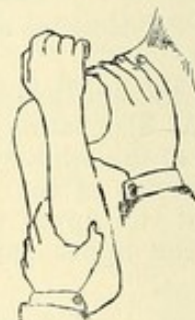


FIG. 373.



Extension, adduction, and rotation outward. (Smith.)

sufficient to engage itself slightly under the tendons of the coraco-brachialis and biceps (approaching to, or actually in the condition of a subcoracoid dislocation), the outward rotation of the humerus will inevitably thrust the head further forward, and fasten it more certainly underneath these tendons; while the rotation of the humerus in the opposite direction will alone often be sufficient to carry the head directly into the socket.

[Dr. Kelly,² an Irish surgeon, resorts to the following method: The patient lies upon the edge of a bed about three feet high; the surgeon stands by the side of the bed facing toward the head, his hip against the patient's chest near the axilla; he then draws the arm and forearm of the affected side across the front of his own pelvis and around to the opposite hip; now, holding the wrist of this arm firmly with one hand against himself and making pressure on the head of the humerus with the thumb of the other hand, he slowly rotates his body outward and draws the head to the socket.]

Ancient Dislocations of the Shoulder.—The procedure and the principles involved in the reduction of old dislocations, or of dislocations requiring the interposition of mechanical appliances needs a more complete exposition. If the dislocation is recent, and reduction is found impossible without the aid of mechanical apparatus, the difficulty will be understood to consist mainly, if not altogether, in the resistance offered by the muscles. If, in a few exceptional cases, a “buttonholing” of the

¹ H. H. Smith, *Gross's Surg.*, ed. of 1863, p. 152.

² *Dublin Journ. Med. Sci.*, Sept. 1882.

head and neck by the capsule, or the margin of the glenoid fossa, presents itself as an obstacle, it must be considered an unusual and extraordinary impediment, the existence of which may be regarded rather as possible than probable. Almost our sole purpose, then, it will be understood, in all recent cases requiring mechanical appliances, and in some ancient cases, is to overcome the contraction of the muscles.

I prefer always to place the patient upon a mattress laid upon the floor; two silk handkerchiefs, or two pieces of a cotton roller, are then laid along the radial and ulnar sides of the humerus, and over the middle of these, immediately above the condyles, a wetted roller is applied, its end being made fast with a needle and thread rather than with a pin. The upper ends of the longitudinal strips, or of the handkerchiefs, are now turned down and tied to the opposite ends, thus converting them both into lateral loops. For the purpose of making counter-extension, a sheet is passed around the body under the axilla, and made fast to a staple; while an intelligent assistant is to manage the scapula with his naked hands, either by pulling with his fingers placed under the process, or by pushing with the palm of his hand and ball of his thumb. The pulleys, secured to a staple exactly opposite to that which holds the counter-extending band, are made ready, but not for the present attached to the arm.

As soon as the patient is placed completely under the influence of an anæsthetic, the operator is ready to proceed with the reduction. It is my maxim never to attempt to accomplish by complicated and violent measures what may be done as well by more simple and gentle means. I think it proper, therefore, to make several attempts at reduction by manipulation alone, aided now by the anæsthetic, the extending and counter-extending bands, etc., before resorting to the pulleys. Seating himself upon the mattress, his boots being removed, the surgeon should bend the forearm to a right angle with the arm, and planting one heel in the axilla, with one hand he should seize upon the loops at the elbow, and with the other steady the hand and forearm of the patient, while he proceeds to make firm traction for a few seconds in the line of the body, or only a little out from this line. Failing in this, he may direct the assistant to seize upon the scapula, and make counter-extension; still not succeeding, he may change his foot from the axilla to the acromion process, and pull directly outward at a right angle with the body, or he may swing himself gradually around until he comes to be above the head of the patient, and the foot presses firmly upon the top of the scapula; now descending again in the same direction, he will very probably find the limb reduced, or capable of being reduced easily, by operating upon it as a lever by laying it across the body while at the same moment it is rotated slightly inward.

If still the reduction is not accomplished, the pulleys must at once be put in requisition. The sheet, passed around the chest and fastened to a staple, is only a means of supporting the body and rendering it more steady; as a means of counter-extension its value is inconsiderable. To make fast the scapula, we must still rely mainly upon the naked hands of strong men, or upon a strap drawn firmly across the process and held in place by an assistant.

Whenever we employ extension without the aid of anæsthetics, as sometimes we are compelled to do, it must be constantly borne in mind that it is proposed

to conquer the muscles by fatiguing them, and that this cannot be done by a force suddenly applied, however great it may be, but only by gentle, steady, and long-continued extension. The muscles, when attacked openly and vigorously, resist, and will suffer laceration rather than yield, while, on the other hand, an insidious but persevering approach seldom fails to end in their defeat. The same is true, but in a much less degree, when the patient is insensible from anæsthesia.

The forearm is again flexed, and the arm carried out to a right angle with the body, the pulleys secured to the loops, and the assistant takes hold upon the process, while the surgeon draws gently upon the rope attached to the pulleys; as soon as everything is moderately tense, he is to desist for a few moments. Again the rope is drawn upon gently, and again the progress of the extension is suspended. In this way the operator is to proceed during half an hour, or two hours, as the nature of the case may demand; occasionally rotating the humerus, and occasionally lifting its head toward the socket. Meanwhile, it is understood that the principal counter-extension is made by the assistants, who must relieve each other, at the acromion process. The sheet in the axilla, or rather against the side of the chest, has some value in this respect when the arm is at a right angle with the body, but in itself it cannot control the scapula, only as it holds the body to which the scapula is attached. Much, therefore, as we may regret the inconvenience of making counter-extension by hands alone, experience and anatomy alike must teach that here it is the only mode. If these dislocations are reduced often by other methods, as no doubt they are, then it is only an evidence that in these examples little or no counter-extension was necessary. Sometimes the dislocation is not reduced when the extension is given up, but if then a resort is promptly made to some one of the simple methods already described, while the muscles are still exhausted, it very often happens that the reduction is easily accomplished. It will be prudent in all cases, in order to prevent a redislocation, whether the dislocation is recent or ancient, as soon as its reduction is effected, to place the arm in a sling and secure the elbow to the side by a few turns of a roller. I do not think the axillary pad necessary, and I am afraid that it has sometimes done as much mischief as the dislocation itself.

The following example will illustrate the variety of expedients to which we are obliged sometimes to resort before our efforts prove successful:

T. L., of Niagara Co., N. Y., æt. 52, a laborer, and a muscular man, dislocated his right arm into the axilla, by jumping from the cars when they were in full motion. The blow was received upon the shoulder. An intelligent country surgeon, assisted by several other persons, attempted reduction within an hour after the accident, but failed, and as the patient had some distance to travel, he was not brought under my notice until eighteen hours had elapsed. We first administered chloroform, and then, while an assistant held firmly upon the acromion process, I pulled in the line of the body, then outward, and finally upward, but to no purpose. Having then applied Jarvis's "adjuster," and after the arm had been kept extended at a right angle with the body fifteen minutes, we removed the apparatus, and found the bone in its place.

J. H., æt. 50, a very large and powerful man, fell while intoxicated, and dislocated his left humerus into the axilla. No surgeon was called until the tenth day, when he first consulted Dr. Dudley, who at once brought him to me. Without delay we applied the pulleys, and placing the arm at a right angle with the body, we made extension fifteen minutes; occasionally also rotating the arm.

We then removed the pulleys, and while an assistant held upon the acromion process, with my heel in the axilla, I made extension in the line of the axis of the body, then outward, and finally upward with my foot upon the top of the scapula. I next seated my patient in a chair, and drew his arm and axilla forcibly over my knee. The bone was not yet reduced; I therefore bled him twenty-four ounces, or until partial syncope was induced, and proceeded to repeat most of these processes, but with no better result. At this moment I determined to use sulphuric ether, which had just been introduced as an anæsthetic, and while he was completely under its influence the pulleys were again applied, and the extension continued for some time, and until the rope broke. He was then again placed in a chair, and the axilla brought over my knee, when in a moment the reduction was accomplished.

J. McK., æt. 89, was admitted to ward 28, Bellevue, in Nov. 1866, with a dislocation of the humerus into the axilla, which had existed seven weeks and one day. The deltoid was much wasted and the hand somewhat numb. Before the class of medical students, the patient being under the influence of ether, the reduction was effected; but not until various methods of manipulation and extension had been tried and had failed. Having finally carried the arm directly upward—La Mothe's method—and in this position employed extension, the arm was again brought down, and with moderate manipulation the reduction was effected. The return of the bone was sudden, and was accompanied with a slight grating sensation; it was observed also, that a hard bony projection was left in the axilla, which was no doubt the margin of a new socket. The head of the humerus could be plainly seen and felt in its socket, rendering it certain that I had not broken the surgical neck of the humerus.

J. B., of Buffalo, aged 45 years, an Irish laborer, tolerably muscular, but spare, fell down a flight of stairs, and dislocated his left humerus into the axilla. The shoulder became much swollen, and was very painful, but he did not suspect a dislocation and did not consult a surgeon. Eight weeks after the accident he applied to me. There were present the usual signs of this dislocation, but the arm was by careful measurement one inch and half longer than the other. The reduction was accomplished on the same day. The time occupied in the reduction was about two hours. An attempt was first made with the heel in the axilla and with violent rotation and extension. The same plan was repeated with the aid of ether, which was administered freely. Jarvis's adjuster was now applied, with no result, except that, either in consequence of the force employed by the adjuster, or in consequence of the free use of ether, or of both, he became convulsed violently, which was accompanied by frothing at the mouth and other grave symptoms. The adjuster was removed, and the exhibition of ether discontinued. As soon as the convulsions ceased, and before consciousness had returned, extension, rotation, etc., were again made by hands. Finally, after all extension was relinquished, placing my knee in the axilla, I reduced the bone by a very slight rotary action upon the arm; the bone was at once plainly in its socket, but the unusual length of the limb continued, being one inch and a half longer, though it could be shortened to the same length as the other by lifting the elbow. A pad was placed in the axilla and the arm secured with a sling and roller. The next day the arm remained in place, but it was now only one inch longer than the other. At the end of a fortnight it was only three-quarters of an inch longer, and could be reduced to the same length by lifting; the pain and swelling about the shoulder, which never were great, were subsiding, and the patient was dismissed.

However skilfully our efforts may be directed, they will be found occasionally to fail; either owing to adhesions which have taken place between the head of the bone, or rather its capsule, and the adjacent tendons, muscles, etc., to some extraordinary position of the head and neck of the bone in its relation to ligamentous or tendinous structures, to a filling up of the glenoid fossa, or to some other cause not fully explained. Such failures have happened not only in the hands of ignorant and unskilful surgeons, destitute of appliances, but also in the hands of

those who are the most expert, and who are the most completely provided with all the necessary apparatus. Indeed, if the truth were known, it would probably be found that the number of failures after the sixth or eighth week has been greater than the successes. The records of surgery, however, furnish a great many examples of ancient dislocations of the humerus reduced after periods ranging from one month to six, or even longer.

Sédillot¹ claims to have succeeded after one year and fifteen days, and Koenig² after eight years.

In 1819, Weinhold, for the purpose of reducing an ancient dislocation of the humerus, cut the pectoralis major three fingers' breadth from its insertion, and obtained an easy reduction. Wutzer,³ in two cases, cut the coraco-brachialis. Poincot, to whom I am indebted for this statement, adds that the result is not known to him. Dieffenbach was able to accomplish the reduction of a forward dislocation after two years, but not until he had cut the tendons of the pectoralis major, latissimus dorsi, teres major, and teres minor, and had divided the ligaments surrounding the new joint.⁴ Simon,⁵ in 1852, and Polaillon,⁶ in 1881, combined subcutaneous incisions of the fibrous tissues surrounding the joint, with prolonged extension, and were thus enabled to reduce this dislocation. Poincot, however, does not think these incisions were of any particular value. In a woman, æt. 48, who had a forward and downward dislocation of seven months' standing, accompanied with great pain and inability to use the limb, H. Burckhardt⁷ through an open incision divided the adhesions, and during the efforts at reduction the great tuberosity was partially torn off. The result was a very sensible improvement in the condition of the arm. Mears,⁸ of Philadelphia, has twice practised subcutaneous osteotomy, in order to establish a false joint, and with results satisfactory to himself. Desprès⁹ has had recourse, in two cases, to fracture of the neck of the humerus, without intending to establish a pseudoarthrosis. Poincot, in commenting upon these cases, says that the results of the two cases, as reported, are not likely to impress the reader favorably. In a case in which the head of the humerus, long dislocated, pressed upon the brachial plexus, causing great suffering, Dr. Edward Warren, of Baltimore, practised resection, in 1869, giving immediate and permanent relief.¹⁰

Dr. Thomas Annandale, Surgeon to the Edinburgh Infirmary, in the case of a woman 62 years old, with a subclavicular dislocation of six weeks' standing, having failed to reduce the bone, and the patient suffering great pain on account of the pressure upon the axillary nerves, cut down upon the head of the humerus, along the inner border of the deltoid, and after separating the axillary artery, which was adherent to the bone, and having sawn through the surgical neck of the humerus, he removed the head in fragments and with great difficulty, inasmuch as it was firmly bound to the ribs by fibrous and bony tissues. In the course of this procedure he wounded the circumflex artery so near to its origin that he was obliged to tie the subclavian above and below the origin of the circumflex. The operation was performed February 16, 1875. On the 18th the hand and forearm became gangrenous, and on the 19th she died.¹¹

Volkmann¹² practised resection in a man, æt. 53, who had a subcoracoid dislocation of five weeks' standing, and which it was found impossible to reduce.

¹ Sédillot, *Art. Lux.*, *Die. Encyc. des Sci. Méd.*, 2d ser. t. iii. p. 281.

² Koenig, by Ceppi, *Rev. Men. de Chir.*, 188, t. ii. p. 828.

³ Wutzer, *Kronlein, die Lehre von Lux. in Deuts. Chir. von Billroth u. Lueke, Lieferung.* 26, p. 71.

⁴ Dieffenbach, *Boston Med. and Surg. Journ.*, vol. xxii. p. 382, from *Medicin. Zeitung*.

⁵ Simon, from *Kronlein*, loc. cit.

⁶ Polaillon, Poincot, op. cit., p. 834.

⁷ Burckhardt, *Württemberg Med. Correspond.*, 1878, No. 4, p. 35.

⁸ Mears, *Phila. Med. and Surg. Reporter*, Oct. 1877.

⁹ Desprès, *Bull. Soc. de Chir. de Paris*, 1879, pp. 24 et 742.

¹⁰ Warren, *Gross's Lecture, Amer. Journ. Med. Sci.*, April, 1876, p. 452; also *Baltimore Med. Journ.*, Sept. 1871, p. 532.

¹¹ Annandale, *Med. Times and Gaz.*, May 29, 1875, p. 576.

¹² Volkmann, Popke, *Inaug. diss. Halle*, 1882; *Anal. in Centralblatt für Chir.*, 1883, p. 28.

The incisions were made through the axillary space, and at once opened into a cavity of the size of the fist, inclosing the head of the bone, and containing blood and serum. It was ascertained now that the blood, which still continued to flow, came from the axillary vein, which had been wounded by a sharp fragment of bone, separated from the lesser tuberosity. The vein was ligated, and the resection made, but notwithstanding the resection the head of the humerus could be only partially replaced. At the end of three weeks this patient left the hospital, with some improvement in the position and motion of the arm. In the case of a man, *æt.* 30, with a dislocation of seven or eight months' standing, and in which redislocation was constantly occurring, Cramer¹ practised resection with most satisfactory results. In a case of repeated redislocations of the humerus Kuster² also practised resection, and obtained at the end of seven weeks "very satisfactory results." Volkmann³ has also practised resection in the case of a man, *æt.* 30, who had repeated spontaneous redislocations. The incisions were made from the anterior surface of the arm. Subsequently the patient informed Volkmann, by letter, that he could use his arm a great deal better than before the operation.

[Open arthrotomy has been practised with a gratifying measure of success, and with antiseptic precautions gives promise of being an accepted method. Albert operated for a subcoracoid dislocation, making an incision in front; while making rotatory movements to return the head to the socket, a fracture occurred at the surgical neck; the head was drawn into place by two hooks, and the fragments were united by suture; a false joint resulted, which, however, gave a more useful limb. Thiersch failed to effect a reduction. Burkhardt operated on a woman seven months after luxation; the incision was midway between the coracoid and acromion; after dissecting away the strong fibrous bands which were attached to the head, reduction was effected, though the greater tuberosity was torn off. Recovery followed, and three months after the limb could be abducted 45° and the hand carried to the opposite shoulder.

Dr. Heron Watson operated four weeks after the accident on a subcoracoid dislocation. An incision was made about eight inches long over the interval between the deltoid and the clavicular portion of the pectoralis major; the capsule was found torn completely away; the finger first felt the glenoid cavity, then a rough surface on the head of the humerus which proved to be the place from which the two upper facets of the greater tuberosity had been broken off. The head of the humerus lay under the coracoid process. All efforts to replace the bone failing, a narrow lithotomy-scoop was passed to the inner side and underneath the head, which was thus lifted into the glenoid cavity. A drainage-tube was inserted and the wound closed, which mostly united in a week. The patient developed insanity, but recovered, and at the end of eight months could abduct his arm 70° and place his hand on the top of the head; external rotation and supination are impaired. Garmany, of New York, operated on a recent case successfully.

Mr. Lister has recently performed this operation twice on the same person with most satisfactory results. The patient was a man, *æt.* 47, who fell a distance of forty feet on his outstretched arms, producing subcoracoid luxation of both shoulders. Eight weeks after the accident he entered King's College Hospital in a very helpless state, unable to dress himself, with the arms almost fixed in a slightly abducted position, and rotation very limited, particularly on the right side. The first operation was on the left side, as follows: An incision was made from the coracoid process downward and somewhat outward in the interval between the deltoid and pectoralis major; the tendon of the subscapularis was divided, and with a periosteum-detacher the soft parts were separated from the head of the bone and the inner part of the neck so completely as to leave no doubt that the vessels were entirely detached from the bone; pulleys were then applied, and as they put fibrous bands on the stretch these were divided; the head of the bone still refusing to return to its position, the bone was more completely cleared and the pulleys again applied; this failing, the head of the bone was protruded as for resection, the external rotators cut

¹ Cramer, *Berliner klin. Wochenschrift*, 1882, No. 2.

² Kuster, *Rev. Mens. Chir.*, 1882, p. 867.

³ Volkmann, Popke, *loc. cit.*

through at their insertions; the pulleys were again employed and suddenly relaxed by pulling a slip-knot, and at the same moment rotation outward and adduction of the limb were performed; the head was thus brought nearer to the glenoid cavity; it went still nearer on a second attempt of the same description, and at a third the head of the bone slipped into its normal place. The wound did well, and the following week he operated on the other shoulder in a similar manner, except that he at once protruded the head of the bone, dividing all of the attachments of the rotators; at the second attempt the pulleys drew the bone into its proper position. The wound also did well. There was no suppuration in either wound, but the passive motion which was maintained seemed to keep up a serous oozing, and it was nearly two months before the last wound was perfectly cicatrized. Fifty-one days after the first operation the patient put on his coat unaided. About four and a half months after the operation the patient exhibited all the natural movements of the arm in their normal degree except elevation of the limb, and he stated that he could do any hard farm work as well as ever.

A second case of double dislocation of the head of the humerus came under the care of Mr. Lister, caused by epileptic seizures. He performed the same operation on the left shoulder, but not with as satisfactory results as regards the usefulness of the limb as in the preceding case. The operation on the right humerus, six months later, consisted in exposing the head and chiselling away its articular portion, but without interfering with its tuberosities; this allowed the bone to drop back into the glenoid cavity. Recovery was prompt, and the patient gained usefulness of this arm much more rapidly than of the other. The final result proved to be good on both sides, for it is stated that he had nearly gained the full use of his arms two years after the first operation, the defect being inability to raise the arms above the horizontal.¹

Accidents Occurring during Attempts at Reduction of Dislocation.

Rupture of the Axillary and other Arteries.—Blackman, of Cincinnati, having met with one of these unfortunate accidents in his own practice, had the candor to make a public statement of the case and of the circumstances which attended it. In a letter to the editor of the *Western Lancet*, published in the November number for 1856, he wrote as follows:

"About the 10th ult., aided by yourself, I succeeded in reducing by manipulation, without the pulleys, a dislocation into the axilla, of eighty days' standing. The reduction was accomplished in a very few minutes, under the influence of chloroform and ether, and the next morning the patient left for the country, in a comfortable condition. Since that I have received no tidings from him. Encouraged by the result in this case, another patient, himself a physician, a tall, athletic man, and about fifty years of age, decided to submit to the same manipulation, although his arm had been dislocated for about sixteen weeks. The dislocation was downward and inward, and about the tenth week an unsuccessful attempt, by another surgeon, had been made with the pulleys, to which the force of six men was applied for two and a half hours. The patient being under the influence of chloroform and ether, I commenced my manipulations, adducting, rotating, abducting, and elevating the arm. These efforts had been made for about ten minutes, and the least possible violence employed, when a tumefaction appeared in the pectoral region, which, in a few minutes, attained a considerable size. Supposing that the axillary artery was ruptured, as no pulse could be felt at the wrist, a ligature was immediately applied to the vessel at the upper part of its course. The operation was performed about 10 o'clock A. M., and compression of the pectoral region made by means of a sponge and broad roller. On removing this the next morning, the tumefaction had nearly disappeared. The patient continued comfortable, and about nine days after the

¹ London Lancet, Jan. 1, 1890.

application of the ligature I was compelled to leave the city on a professional visit to Indiana. I left on Friday afternoon and returned on Monday morning, at which time I learned that my patient had died on Sunday morning, from hemorrhage at the seat of ligature."

M. Panas¹ saw at the Hospital St. Louis a diffuse aneurism in the armpit supervening fifteen days after a reduction of a dislocation (intracoracoidean) which was of forty-eight hours' standing. The reduction had been by ordinary manual extension, while the head was pressed forcibly outward by the thumbs sunk deeply into the axilla. M. Panas tied the subclavian artery in the neck, outside of the scaleni muscles. The patient succumbed three months later from articular suppuration.

Gunther² reduced a recent dislocation under anæsthetics, by elevation and direct pressure upon the head of the humerus, in a man 20 years of age, who had before dislocated the same arm. At the end of three weeks an aneurism was discovered in the axilla. The subclavian was tied, suppuration ensued, the abscess opened, and death resulted from hemorrhage. W. Korte³ reports a case in which a recent dislocation forward and inward was reduced by a bone-setter, an axillary tumor formed, which was punctured several times, and the patient died five weeks after the accident, of septicæmia. He reports also another case of a similar but ancient dislocation, in which several attempts were made at reduction, during one of which the axillary artery was ruptured. The aneurism soon opened spontaneously, and the patient died of hemorrhage. In the case of a man, æt. 62, admitted to the General Infirmary of Sheffield, England, with a dislocation of eight weeks' standing, slight attempts at reduction, with the heel in the axilla, resulted in the formation of an axillary tumor. The next day the axillary artery was tied, and new attempts at reduction were made. The patient died at the end of twenty-four hours.⁴ M. Letiévant,⁵ of Lyons, found in his wards a patient with a dislocation of twenty days' standing. The reduction was effected under chloroform, but not until violent tractions had been made. It was followed immediately by an axillary aneurism and paralysis of the radial nerve. M. Letiévant, after having tried successively digital and elastic compression, resorted to ligature of the axillary artery, outside of the scaleni. The aneurism got well, and the paralysis eventually disappeared. In Carruther's⁶ patient, a dislocation having been promptly reduced, was soon reproduced. The second reduction was again easily effected, but on the following day there existed tumefaction and signs of incipient gangrene. Carruther amputated the arm and the patient died the next morning. The autopsy revealed a laceration of the axillary artery below the origin of the subscapular. A man 55 years of age, and having a dislocation of forty-eight days' standing, was subjected to repeated attempts at reduction, which resulted in a diffuse aneurism. Four months later he was admitted to Charing-Cross Hospital. Dr. Bellamy amputated the arm at the shoulder-joint, and the patient died during the operation.⁷ Desault twice observed, after attempts to reduce old dislocations of the shoulder, "*tumeurs aériennes*." It is quite probable, however, that in each case the tumor was caused by the rupture of a bloodvessel, and probably an artery.⁸ Pelletan, also, attempting to reduce a dislocation of four months' standing, thought he produced a *tumeur aérienne*, but it being opened the patient bled to death.⁹ Probably the axillary artery was torn. Malgaigne, attempting to reduce a dislocation of sixty-eight days' standing, was surprised by a sudden tumefaction in the axilla, and on the shoulder, which caused so much alarm as to induce him to discontinue his efforts. Ice was applied, and the hemorrhage, which he thought came from muscular branches, was arrested.¹⁰ Verduc saw the axillary artery ruptured in the same manner, in consequence of which the patient died.¹¹ J. L.

¹ Panas, Art. Epauule, Nouv. Dic. Méd. et Chir. Prat., t. xiii. p. 441.

² Gunther, quoted by Marchand, Thèse d'Agrég., Paris, 1875, p. 40.

³ Korte, Arch. für klin. Chir., Bd. 27, Hft. 3, p. 631.

⁴ British Med. Journ., Feb. 2, 1883.

⁵ Letiévant, Lyon Méd., 14 Juil., 1878, p. 383.

⁶ Carruther, Brit. Med. Journ., May 18, 1872.

⁷ Bellamy, The Lancet, 1880, vol. ii. p. 260. (Poinot, op. cit., pp. 838, 839.)

⁸ Desault, Journ. de Chir., t. iv. p. 301.

⁹ Pelletan, Chir. Clin., t. ii. p. 951.

¹⁰ Malgaigne, Paris ed., 1855, p. 150.

¹¹ Verduc, Opérat. de la Chir., 1693, t. i. p. 559.

Petit, Dupuytren, and Nélaton met with similar cases. C. Bell reports an example of rupture of the artery with extensive laceration of the muscles, which demanded immediate amputation. Delpech ruptured the artery, and his patient died immediately.¹ Flaubert was more fortunate, the effused blood being absorbed after a few days.² John C. Warren, of Boston, tied the subclavian artery to arrest the progress of an enormous aneurismal tumor in the axilla, caused by the reduction of a recent dislocation.³ Gibson, of Philadelphia, lost two patients from rupture of the artery in attempting to reduce old dislocations of the humerus,⁴ and he relates another fatal case occurring in the practice of David, of Rouen. Leudet, of Rouen, lost a patient in this way in 1825. In this latter case, and in both cases occurring in the practice of Gibson, there was a fracture, also, of the lower margin of the glenoid cavity. Callender ruptured the artery in an attempt to reduce a dislocation at six weeks.⁵ Mr. Lister met with the same accident.⁶

Poinsot suggests that in some of these accidents the dislocation itself, rather than the attempts at reduction, might have been responsible for the rupture of the axillary artery; and in support of this suggestion he cites the observation of M. Panas,⁷ that the rupture always takes place on the level of the subscapularis. He refers also to examples furnished by Berard,⁸ Le Dentu,⁹ Adams,¹⁰ and Korte,¹¹ in which the existence of the aneurism seemed to precede the attempt at reduction. Berard's patient succumbed speedily. Le Dentu's patient, in whom scapulo-humeral disarticulation was practised, died also. Adams reduced the dislocation, then tied the subclavian, and the patient recovered. In Korte's case the dislocation, caused by a direct blow, was reduced spontaneously. An aneurism ensued and the subclavian was tied, but the patient died of secondary hemorrhage. Neither of the first three cases, it seems to me, so far as their history is related by Poinsot, furnishes absolutely conclusive evidence that the rupture did not take place during the preliminary examination. In Korte's case one is struck with surprise that a traumatic dislocation should be reduced spontaneously. Yet I do not deny that rupture of the axillary artery may in some cases result from dislocation.

Rupture of the Axillary Vein.—Froriep attempted reduction in a woman, the dislocation having existed twenty days. The axillary vein was torn entirely across, and death ensued in an hour and a half.¹² A woman came under the observation of Price¹³ who had an old dislocation of the shoulder. Reduction having been effected, she died the next day in consequence of a rupture of the axillary vein. Hailey¹⁴ reduced a dislocation easily, but two months later a tumor appeared in the axilla, the patient succumbed to pyæmia, and the autopsy disclosed a rupture of the axillary vein. Professor D. H. Agnew, of the University of Pennsylvania, ruptured the axillary vein while attempting to reduce a dislocation of six weeks. The woman, æt. 60 years, had a subcoracoid dislocation, and while the arm was lifted and extension made according to La Mothe's method, the vein was ruptured, causing a very large tumor covering the entire breast. Compresses and bandages were at once applied and continued for several weeks, the case resulting in a complete cure, but with the bone unreduced.¹⁵

Rupture of Artery and Vein.—Platner mentions a case in which death ensued from subsequent rupture of the sac.¹⁶ Charles Bell reports a case in which the artery was ruptured, at the New Castle Infirmary, and the parts adja-

¹ Malgaigne, *op. cit.*, p. 152.

² Mémoires sur plusieurs cas de Luxationes, etc. Répertoire d'Anat. et de Phys., 1827, Obs. 3. Four cases of Injury to the Axillary or Brachial Vessels or Nerves.

³ Warren, Amer. Journ. Med. Sci., vol. xi., N. S., 1846.

⁴ Gibson, Elements of Surg., vol. i. p. 824, 4th ed.

⁵ St. Barthol. Hosp. Rep., 1866, vol. ii. p. 96.

⁶ Med. Times and Gaz., Feb. 1, 1873.

⁷ Panas, Bull. Soc. Chir. de Paris, 1877, p. 193.

⁸ Berard, *Ibid.*, p. 193.

⁹ Adams, The Lancet, 1880, vol. ii. p. 260.

¹⁰ Malgaigne, from Froriep.

¹¹ Price, quoted by Marchand, *op. cit.*, p. 63.

¹² Hailey, Brit. Med. Journ., 1863, vol. ii. p. 684.

¹³ Agnew, Phila. Med. Times, Aug. 16, 1873.

¹⁴ Malgaigne, Paris ed., 1855, vol. ii. p. 151.

⁹ Le Dentu, *Ibid.*, p. 187.

¹¹ Korte, *loc. cit.*

cent so much injured that immediate amputation became necessary. It seems quite probable, therefore, that the vein was also torn, but this is not stated.¹

Dr. H. B. Sands, of New York, in attempting to reduce a downward dislocation of seven or eight weeks' standing, in a lady 86 years of age, found a tumor rapidly forming in the axilla, which soon attained the size of a child's head at full term; discoloration ensued, and the pulsations of the brachial, ulnar, and radial arteries were lost. She was also greatly prostrated. It was evident that some vessel had given way, but inasmuch as she finally recovered without any surgical operation, it is scarcely probable that it was, as at first suspected, a rupture of the axillary artery. I ought to add that the patient was, at the time of attempted reduction, under the influence of ether, and that great care was said to have been exercised by Dr. Sands not to employ great force in the attempt. The reduction was not accomplished.²

[Dr. Strong reports a case of rupture of both artery and vein during an effort at reduction of an old dislocation at the shoulder. The adhesions were first thoroughly broken up, and as manipulation failed the operator placed his heel in the axilla with a towel over his shoulders, and fastened to the arm. On the fourth attempt there was a gush of blood from the axilla. The patient died in thirty-six hours, and the autopsy showed rupture of both axillary artery and vein.³]

Cerebral Accidents.—Lisfranc, reports a death from cerebral congestion.⁴ Flaubert⁵ in making a second attempt to reduce a dislocation of the shoulder, caused what he supposed to be a cerebral hemorrhage. Poincet, in commenting upon these cases, says that the frequency of syncope during the work of reduction has been remarked by M. Verneuil; and that M. Desprès and Gosselin have thought that dislocations of the shoulder "lend themselves badly" to the use of chloroform. Poincet further suggests that some of these cerebral accidents may be due to fatty emboli, or thromboses.

Injury to Axillary Nerves.—Very many accidents of this kind have happened from time to time, some of which have been reported by Flaubert, Malgaigne, Lenoir, Larrey, Nélaton, Panas, Marchand, Verneuil, and others.⁶

Lesions of the Soft Parts.—Guérin tore the arm completely from the body, in an attempt to reduce a dislocation of three months' standing, in a woman 63 years of age.⁷ Dr. Thomas Smith,⁸ of St. Bartholomew, London, saw in a man, æt. 58 years, the skin and muscles turn until the head of the bone was exposed, by simple manual extension with the heel in the axilla. The patient died on the ninth day.

Inflammation, etc.—Hutchinson reported that inflammation, suppuration, and death had resulted from an attempt made to reduce an old dislocation of the humerus, under his own observation.⁹ A like result followed the reduction of a recent subclavian dislocation, in the practice of Dr. Courtright, of Ohio.¹⁰ Trélat's¹¹ patient died of inflammation caused by attempts at reduction of a subcoracoid, incomplete dislocation. The dislocation had existed four months and had been subjected to repeated unsuccessful attempts at reduction with India-rubber lacs, Jarvis's adjuster, etc.; and Norris¹² has seen a enormous axillary abscess caused by a successful reduction of a dislocation of seven weeks' standing. Norris's patient eventually got well.

Fracture of the Humerus.—An attempt to reduce a dislocation of the humerus occasioned a fracture of the surgical neck: M. H., æt. 70 years, of Brooklyn, N. Y., was admitted into the Long Island College Hospital during

Willard, Summary of Cases, Phila. Med. Times, Aug. 16, 1873.

² Sands, Med. Gaz., March 8, 1880.

³ Peoria Med. Monthly, Aug. 1888.

⁴ Malgaigne, Paris ed., 1855, vol. ii. p. 161.

⁵ Flaubert, Marchand, op. cit., p. 106.

⁶ Malgaigne, Paris ed., 1855, vol. ii. p. 151. Marchand, op. cit.; Poincet, op. cit.

⁷ S. Cooper's First Lines, vol. ii. p. 466; Amer. Journ. Med. Sci., 1828, p. 136.

⁸ Smith, The Lancet, 1878, vol. ii. p. 3.

⁹ Hutchinson, Lond. Hosp. Reports, vol. ii. (Cincinnati Journ. Med., Aug. 1866, p. 361.)

¹⁰ Courtright, Cincinnati Lancet and Observer, Jan. 1877.

¹¹ Trélat, Marchand, op. cit., p. 114.

¹² Norris, Amer. Journ. Med. Sci., vol. xxxvi. p. 24.

the spring of 1860. The dislocation had existed six weeks, and was subcoracoid. On the day of admission an attempt was made to reduce it, both by Dr. Johnson and myself, without an anæsthetic, in which we both failed. I then gave her ether, and now discovered that she had a fracture of the second and third ribs on the same side. The fractures were ununited. While manipulating, pulling the arm gently and rotating, the surgical neck of the humerus gave way. She did not survive the injury many days, and the autopsy confirmed this diagnosis.

In December, 1874, Dr. Stephen Smith, of Bellevue, met with the same accident in attempting to reduce a subglenoid dislocation of eight weeks' standing, before the class of medical students. The patient, a man about 40 years, was under the influence of ether. Manipulation and extension had been freely employed in various directions, but the fracture took place when, at my suggestion, extension was for a moment relinquished, and while Dr. Smith was rotating the humerus with the elbow at a right angle with the body.

In December, 1865, R. C., æt. 32, was admitted to Bellevue with a subcoracoid dislocation of the left shoulder. The accident occurred six weeks before. On admission, one of the house surgeons attempted reduction, and, as I am informed, fractured the surgical neck of the humerus. After which, Dec. 9th, I attempted reduction before the class, the patient being under the influence of ether, but without success. Malgaigne has recorded four similar cases.¹ Two cases are referred to in the *Lancet*, February 6, 1876; one by Howse² and the other by Sheen³; in the latter of which, however, a suspicion is expressed that the fracture occurred at the same time as the dislocation. In my opinion the fracture was caused by the attempt at reduction.

Summary.—Rupture of an artery, 28 cases; most of which were ruptures of the axillary artery. Callender, Lister, Blackman, and Korte tied the axillary, and the patients all died. The same was the fact in the Sheffield case. Warren and Letiévant tied the subclavian artery successfully. Gibson, Gunther, and Panas, who resorted to the same operation, were unsuccessful. Nélaton tied the subclavian, but the result is not stated. Carruther and Bellamy practised disarticulation, and their patients died. Bell did the same, but the result is not stated. Rupture of vein alone, four cases. Price, Hailey, and Froriep's patients died; Agnew's patient was saved. Rupture of artery and vein; this occurred in Platner's case, and the patient died. Rupture of unknown vessel, one case; no operation; recovery. Lesions of the soft parts, two cases. Two deaths. Of the whole number, thirty-six, twenty-five terminated fatally; in four the results are uncertain, and seven recovered.

Of fractures of the neck of the humerus I have reported three cases, and I have drawn from other sources six cases, making in all nine. My own patient died, but probably not in consequence of any injury suffered in the attempt at reduction. Norris has reported three cases of ancient dislocation into the axilla, treated at the Pennsylvania Hospital; one, of four weeks' standing, was reduced in thirty seconds by the aid of pulleys; the second, which had existed seven weeks, was reduced by the same means in about one hour; and the third, dislocated ten weeks, was left unreduced after extension and counter-extension had been made for an hour. In the second case, however, suppuration occurred in or about the joint, and, on the tenth day, the abscess was opened, giving exit to a large amount of pus. He left the hospital with the parts about the shoulder still much hardened and stiff.⁴

Dislocations, with Fractures of the Humerus near its Upper End.—

The older writers, almost without an exception, agree in declaring the reduction of these dislocations impossible, until the fracture had united. And so late as the year 1828, we have the report of a case treated in this manner by a surgeon in Massachusetts. Dr. Warren, of Boston, himself reduced the dislocation at the end of four weeks, when the fracture was

¹ Malgaigne, Paris ed., 1855, vol. ii. p. 143.

² Howse, *The Lancet*, 1876, vol. i. p. 212, from *Guy's Hosp. Gaz.* 1876.

³ Sheen, *Ibid.*, p. 211.

⁴ Norris, *Amer. Journ. Med. Sci.*, vol. xxxi. p. 24.

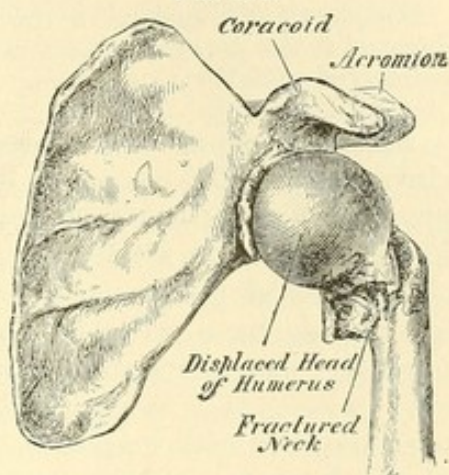
found to have united.¹ But since the introduction of anæsthetics, immediate attempts at reduction have more often proved successful; and in no case can the surgeon excuse himself for having omitted to make the effort.

Richet reports an example of this kind in a man 68 years of age, in whom the dislocation was complicated with a fracture of the neck of the humerus. The attempt was not made until the fourth day, when it proved successful without extension. The fracture was afterward adjusted and consolidated, so that he recovered the complete use of his arm.² At a meeting of the New York Academy of Medicine in May, 1855, Dr. Watson reported a case of fracture of the humerus near its head, complicated with a dislocation into the axilla. The patient was a robust man, past middle age, and had received the injury by a blow on the shoulder from a steam-engine. He was very much prostrated at the time of admission into the hospital, and the examination was not made until the following morning. The arm was then found lying close to the side, but in other respects it presented the usual signs of a dislocation. Ether was immediately administered; and while extension and counter-extension were applied, and a sweeping motion given to the arm, drawing it from the body, firm pressure with the fingers was made in the axilla, forcing the head toward the socket, and the bone slipped into its position.³

I have reported a case of supposed dislocation, accompanied with a fracture, which I succeeded in reducing on the eighth day.⁴ I have, however, twice failed in attempts to reduce similar dislocations. The first patient, J. R., æt. 49, was admitted to Bellevue Hospital, having received the injury two days before. The dislocation was subcoracoid, and the humerus was broken at its surgical neck. Having placed him under the influence of ether, assisted by Dr. Stephen Smith and several other surgeons of the hospital, I attempted to reduce the dislocated bone, but after a trial, prolonged through one hour or more, the effort was abandoned. The second case was in a man aged about 40 years, who was admitted to Bellevue Hospital in July, 1864, with a dislocation of the head of the humerus forward, and a fracture of the surgical neck, of four weeks' standing. A surgeon had attempted reduction immediately after the receipt of the injury, but had failed. We found the fracture still ununited, and placing him under the influence of ether, we tried faithfully, by pushing and pulling, and by various other manœuvres, to reduce the dislocation, but without success. The fractures united in both cases promptly, and attempts were subsequently made to reduce the dislocation, but to no purpose.

Examples have been recorded, however, by surgeons, in which the reduction has been accomplished immediately, and without much difficulty, by simple pressure upon the head of the bone while the patient was under the influence of an anæsthetic, and without the aid of extension; indeed, it is quite doubtful whether extension in these cases is of any service. I have already said that I have once succeeded in replacing the head in

FIG. 374.



Dislocation of the head of the humerus associated with fracture. (Bryant.)

¹ Boston Med. and Surg. Journ., No. 1, 1828; also, Amer. Journ. Med. Sci., vol. ii. p. 233.

² Richet, Amer. Journ. Med. Sci., vol. xii., new ser., p. 293, from Bulletin de Thérap.

³ Watson, Amer. Journ. Med. Sci., vol. xvi., new ser., p. 383.

⁴ Op. cit., vol. ix. p. 93.

its socket after the lapse of eight days. But if the surgeon were to fail by pressure alone, it would be proper to employ extension, especially with abduction, and manipulation.¹ In the event of a failure by these means, the case ought to be treated as a fracture, and the earliest period after the union of the fragments should be seized upon to accomplish the reduction of the dislocation. The occasional success of the older surgeons by this method is sufficient to warrant the attempt.

Compound dislocations of this joint will be discussed in a separate chapter devoted to the general consideration of compound dislocations of all the joints connected with the long bones.

Dislocations of the Humerus Forward. (Subcoracoid and Subclavicular.)—The causes of this dislocation are the same as those which produce dislocation downward into the axilla, except that it is more likely to occur in a fall upon the elbow or upon the hand when the line of the axis of the arm and forearm is thrown behind the body. Where my records have stated the cause, it has been ascribed to a direct blow upon the shoulder sixteen times, and to a fall upon the hand or elbow only twice. If it is the result of a direct blow, the impulse has usually been received rather upon the back than upon the outer side of the head of the humerus; or the upper end of the bone, having been originally thrown directly downward upon the inferior edge of the scapula, may have been made to assume the position forward, beneath the pectoral muscle, in consequence of the peculiar action of the muscles, or of the position of the arm in an attempt to rise. By this latter mode of explanation, the dislocation forward is consecutive only upon a dislocation downward.

In several instances which have come under my notice the dislocation has been due to muscular action alone. In one example the dislocation occurred frequently in consequence of epileptic convulsions. This was in the person of a lad, æt. 18, of a slender frame and feeble muscles. When the dislocation had taken place, he was frequently able to reduce it himself; sometimes he was obliged to call upon a surgeon, and at other times he left it out a day or two, or until it became reduced spontaneously. This spontaneous reduction generally took place at night, during sleep. At the time he called upon me the bone had been out two days, and he could not reduce it. I administered chloroform, and then made repeated and prolonged efforts at reduction, adopting all the usual modes of manipulation, but without resorting to mechanical appliances. The father now refused to allow me to proceed, and he was taken home with the bone unreduced. The following day he called at my office, to say that during the night, while asleep, and he thinks, while turning over in bed, the bone suddenly resumed its place.

Drs. E. L. Pardee and G. C. Arnold, of this city, have recently met with a case of simultaneous dislocation of both shoulders, in a man æt. 38, caused by a fall from his carriage, his arms being extended in front of him, and the force of the concussion being received upon his hands. Both of the dislocations were subcoracoid; and they were easily reduced by Dr. Arnold. Surgical writers occasionally refer to similar examples, but the number of cases of double dislocation on record is small. Most of those recorded have happened when the arms were extended in front of the body, as in Dr. Pardee's case just cited; and the dislocations were generally subcoracoid.

¹ Hartshorne, Case reduced by Manipulation, Amer. Journ. Med. Sci., Jan. 1855, pp. 273-4, from Med. Examiner.

[J. S. McLaren¹ reports two cases of dislocation at the shoulder occurring during sleep. Both cases occurred in Dr. Watson's practice. The first was a man about 30 years of age, who awoke one night with an acute pain in his left shoulder, and complete loss of power in the arm. Three months after Dr. Watson reduced the luxation with the heel in the axilla. The second was a man under 40, who by his moans awoke his brother; he had great pain in the left shoulder and loss of power in the arm. One month after Dr. Watson, failing to reduce it by ordinary means, opened the joint and forced the head from its location under the coracoid process into the glenoid fossa with a lithotomy scoop. The capsule was torn completely away, and the two upper facets of the greater tuberosity had been broken off.]

Pathology.—The anatomical relations and the various lesions which generally accompany a complete dislocation forward are of two principal varieties, differing mainly in the degree or extent of the displacement. Thus we may find the head of the humerus resting *beneath the coracoid process* (subcoracoid), having the conjoined tendon of the short head of the biceps and of the coraco-brachialis lying upon its anterior surface, while its posterior and outer surface rests upon the venter of the scapula in front of the glenoid fossa; in which position it has usually thrust up, to a greater or less extent, the belly of the subscapular muscle.

Sir Astley Cooper, Fergusson, and others, mentioning this form of dislocation, call it a "dislocation into the axilla;" by Boyer it is called a "primary luxation forward." Dr. Wood, of New York, has reported an example, accompanied with a fracture of the neck of the humerus, which he has named "dislocation under the subscapularis muscle. The drawing which accompanied the report, made from the autopsy, sufficiently shows that it was a dislocation of the same character as that which I am now describing.² Dr. Parker has called attention to a similar case, an account of which was first given in Reese's edition of Cooper's *Surgical Dictionary*. The head of the humerus reposed in the "subscapular fossa."³ By Malgaigne, Vidal (de Cassis), and others, this is called a subcoracoid dislocation, a term which, as being more distinctive and appropriate than either of the others, I shall choose to adopt.

In the second variety, the head, having escaped from underneath the coracoid process, is made to approach nearer to the sternum, *so as to apply itself more or less closely to the inferior edge of the clavicle* (subclavicular). In which case the head and neck will be placed behind the pectoralis minor, and also behind the short head of the biceps and coraco-brachialis; or between these several muscles on the one hand, and the serratus magnus, covering the second and third ribs, on the other hand. Upon the appearances which accompany this more advanced form of dislocation writers have generally based their descriptions, diagnosis, treatment, etc., of forward dislocations.

In either form of the accident, the deltoid, with the supra- and infraspinatus, is greatly stretched, and the two latter sometimes torn; the subscapularis is displaced upward and backward, while its tendon is in some instances completely wrenched from the head of the humerus. Mr. Erichsen has seen the lesser tubercle itself completely broken off in two examples of this accident which he has been permitted to examine after

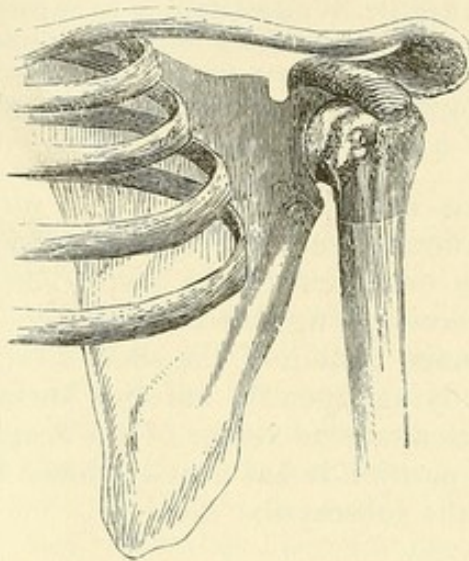
¹ Edin. Med. Journ., July, 1889.

² Wood, New York Journ. of Med., May, 1850, p. 282.

³ Parker, Ibid., March, 1852, p. 187.

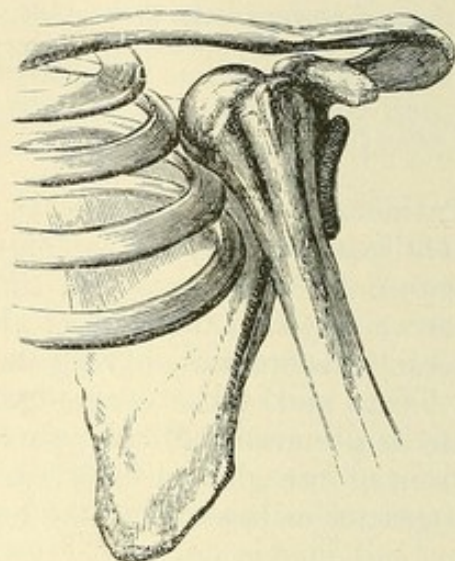
death.¹ Occasionally the axillary nerves are carried forward with the head of the bone; and in this case the pain produced by their being thus pressed upon is even greater than in dislocations into the axilla. In this

FIG. 375.



Subcoracoid dislocation.

FIG. 376.



Subclavicular dislocation.

accident, as in dislocation downward, the long head of the biceps is sometimes broken; the circumflex nerve may be contused or ruptured, and the capsule is generally torn very extensively.

[Mr. Flower² affirms, as a result of the examination of numerous specimens and reports of dissections, that "the long tendon of the biceps is rarely, if ever, injured" in this dislocation.]

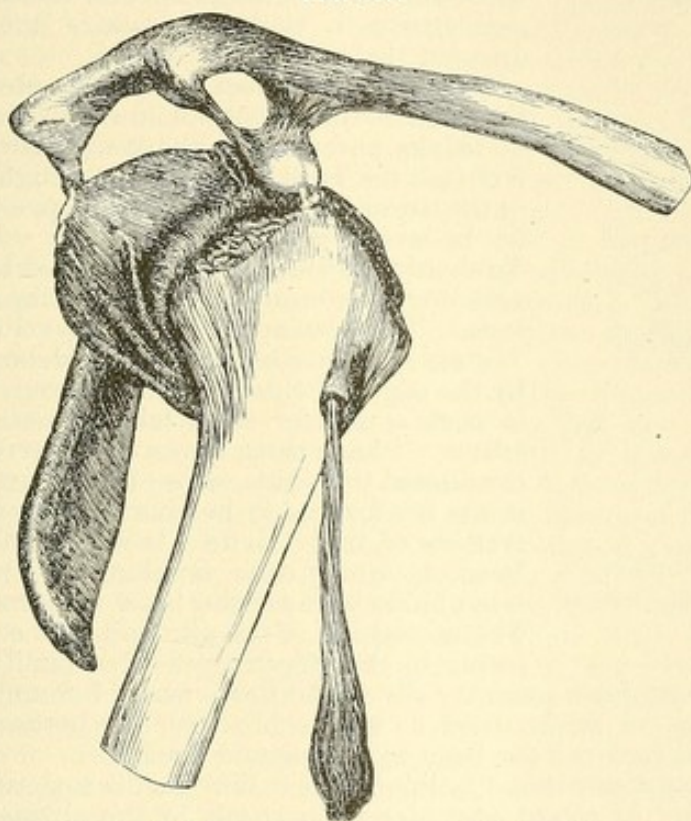
Symptoms.—If the dislocation is subclavicular (Fig. 376), a depression exists under the outer end of the acromion process, extending also underneath its posterior margin; the elbow hangs away from the body, and a little backward; the axis of the limb is much changed, being thrown inward in the direction of the middle of the clavicle, the whole body inclining moderately to the same side; there is also more or less inability to move the arm, especially in a direction forward or outward; a fulness is seen underneath the clavicle, and to the sternal side of the coracoid process, occasioned by the head of the humerus, and the head moving with the shaft the arm is lengthened. To these we may add the common sign of all dislocations of the humerus, mentioned by Dugas, viz., the impossibility of placing the hand upon the opposite shoulder while at the same moment the elbow is made to touch the front of the chest. If the dislocation is forward, but subcoracoid, the head of the bone will be found below this process and deep in the anterior margin of the axillary fossa. It cannot, therefore, be so distinctly felt; but the other signs are the same as in the dislocation forward under the clavicle, except that the arm is usually longer than the opposite arm.

¹ Erichsen, *Science and Art of Surgery*, 2d Amer. ed., p. 250.

² *System of Surgery*, vol. ii.

Prognosis.—While on the one hand experience has shown that the axillary nerves and artery are less liable to suffer serious and permanent injury than in dislocation downward (subglenoid), and that the capsule, with the tendinous and muscular tissues about the joint, are no more liable to laceration—on the other hand, the difficulty of reduction has been often increased, and consequently a large number of examples, in proportion to the actual number which occur, have been left unreduced.

FIG. 377.



Showing untorn posterior half of capsule in subcoracoid dislocation of humerus. (Gunn.)

Dr. Norris relates a case which the surgeon who was first called supposed to be a mere contusion, but which, on being admitted to the Pennsylvania Hospital, three months after the accident, was found to be a dislocation forward under the clavicle. The arm was almost useless. Dr. Norris made extension and counter-extension with compound pulleys nearly an hour, but to no purpose; and finally, at the request of the patient, the attempt was given over.¹

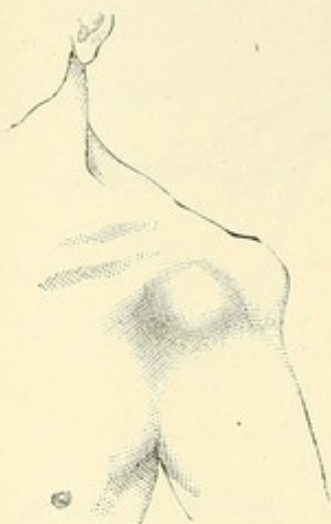
Treatment.—The same rules of treatment which I have established in relation to dislocations into the axilla (subglenoid) will be found to be applicable to this dislocation; with the exception that the position of the arm in manipulation, or in extension, will be at first somewhat in a line backward, and that our efforts will frequently have to be continued with more perseverance, although with less fear of injury in consequence of supposed adhesions between the artery and the adjacent tissues. The extension also must always be made downward and outward, if the dislocation is subclavicular, until the head of the bone has escaped from beneath the coracoid process; we may then pull directly outward or even

¹ Norris, Amer. Journ. Med. Sci., vol. xxv. p. 279.

upward, while at the same moment pressure is made with the hand upon the head of the bone in the direction of the socket, and the arm is rotated inward. If the dislocation is subcoracoid, our modes of procedure need scarcely vary in any respect from those which I have recommended for dislocation into the axilla.

Professor Gunn, of Chicago, having in mind the probable resistance offered by the posterior and untorn portion of the capsule, directs that, in the subcoracoid dislocation an assistant shall fix the shoulder while the surgeon raises the arm to a horizontal position, carries it backward, rotates it externally, and draws it into position.¹

FIG. 378.



External appearance of a subcoracoid dislocation. (Erichsen.)

Professor Gunn does not fail to observe, however, that this method does not always succeed, owing, as he thinks, and as others have suggested before, to the fact that the head has slipped through a narrow rent in the capsule. The same thing happens occasionally, he believes, in other dislocations of the shoulder. To shoulder dislocations complicated by this peculiar pathological condition, he applies the term "anomalous." "The escaped head," says Professor Gunn, "under such circumstances, would be firmly grasped by the edges of this fissured opening in the capsule, in such a manner as to foil all mere manipulatory efforts. I have three times encountered what I have considered to be this state of the parts. In one case it was my fortune to be able to demonstrate the correctness of these views. It was an old forward dislocation, when, after breaking up the adhesions, I was unable to cause the head to reënter the socket. The uselessness of the arm and the necessity of relief, owing to the dependence of a family on this arm, induced me to cut down upon the dislocated head, when I found the condition above described. I freely divided, with a bistoury, one border of this slit in the capsule, and replaced the head in the glenoid fossa."

While I do not doubt that "buttonholing" the head is sometimes a cause of the irreducibility of recent shoulder dislocations by the ordinary methods of manipulation, yet it is not plain to me that, in the case of the ancient dislocation cited, the bands, which being cut permitted the bone to return to its socket, were not supplementary or adventitious structures. Nor am I prepared to admit that in all recent cases, where well-directed manipulation does not effect reduction, the impediment consists solely, or in all cases, in a buttonholing of the head.

The plan adopted in the following case has been found sufficient in several examples of subcoracoid dislocation: Mr. McA., of Buffalo, æt. 73, moderately muscular, fell through a trap-door, striking upon his right elbow, and dislocating the humerus forward. Within two hours after the accident, I found the head of the bone resting under the coracoid process, where it could be distinctly felt and seen. There was a marked depression under the acromion process, and the arm was carried out from the body and slightly back. He had not suffered much pain. The patient was seated in a chair, and while Dr. Lemon supported the acromion process, I pushed the head of the humerus outward toward the socket with my left hand, while with my right I pulled gently upon the arm in the direction of the axis of the body. After about twenty seconds it slid suddenly into its place with an audible snap.

Simple manipulation alone will also be found sufficient in many cases of subclavicular dislocation. S. G., æt. 21, fell upon the sidewalk, and dislocated his right humerus under the clavicle. We found him about an hour after the accident, sitting with his head inclined to his right side, and supporting his elbow

¹ Gunn, loc. cit.

with his left hand. A marked depression existed under the outer end of the acromion process, and instead of the usual fulness there was a flatness under the process behind. The elbow was carried out from the body, and very slightly backward. While Dr. Boardman supported the acromion process I lifted the elbow from the side, carrying it first upward and backward, and then forward, making thus a short detour with the arm, and when the manœuvre was nearly completed the bone slid into its socket with a slight snap. No extension was used, and no more force employed than was sufficient to lift and rotate the arm. He was not at the time of the reduction faint, nor were his muscles relaxed from any other cause.

More than once I have accomplished the reduction by extension made directly upward, as in the following example: A gentleman, 45 years of age, had his left shoulder dislocated forward under the clavicle in a railroad collision. A young surgeon had been making extension in various ways for half an hour, when, by placing my foot upon the top of the scapula and drawing the arm directly upward, I accomplished the reduction immediately and without much effort. Six months after the accident, I found the deltoid muscle considerably wasted, and he was still unable to raise his arm to a right angle with the body.

I have in this way also reduced a dislocation which had existed seventeen days, the nature of the accident having been misunderstood by the attending surgeon. The man was 23 years old, and quite muscular. The dislocation had been produced by a severe blow received directly upon the shoulder, and the arm was still considerably swollen and very tender. The reduction was accomplished in a few seconds while the patient was under the influence of chloroform, by my hands alone, aided only by the pressure of the foot upon the top of the scapula. The method adopted successfully in both of the preceding cases, namely, pulling directly upward, ought generally to be considered a last resort, inasmuch as it especially exposes the axillary artery, vein, and nerves to injury.

In December, 1857, Dr. White, of Buffalo, and I, reduced a subclavicular dislocation of the right shoulder, which had existed sixty days, in a man 68 years of age. The surgeon who first saw the man thought it was only a sprain or a severe bruise. When he came to Buffalo, the whole limb was enormously swollen, and we had not much expectation of accomplishing a reduction without a resort to pulleys and anæsthetics. He was, however, placed upon the floor, and after extension made for about half an hour, during which time we had pulled the arm in various directions, upward, outward, and downward, I at last succeeded while my heel was placed in the axilla, and while the limb was undergoing a slight rotation. No anæsthetic was employed.

Dr. Cuykendall, of Bucyrus, Ohio, informs me that he has recently reduced a subclavicular dislocation on the sixty-fourth day, in a man 62 years old, by the following method: "As a last resort I secured the pulleys to the arm above the elbow, making the counter-extension with Skey's knob in the axilla, flexed the arm and made extension downward and forward; and when well extended I moved his body under the pulley ropes, so as to bring the arm forcibly across the breast; then, keeping up the extension, I had Dr. Richey place his knee upon the top of the scapula, and lock his fingers around the elbow, while I placed my knee against the elbow and locked my fingers around the top of the scapula, and directing the extension removed, we forced the bone upward and outward to its sockets;" adhesions were felt to give way, and the restoration of the bone was found to be complete. It will be understood that this method did not succeed until after repeated and long-continued efforts had been made by other methods, such as pulling down, pulling out, and pulling directly up. Dr. Cuykendall informs me that this is the second time he has succeeded in "completing" the reduction of old dislocations of the shoulder by this manœuvre.

These several cases are mentioned that the surgeon may understand how impossible it is always to establish absolute and invariable rules of procedure which shall be applicable to every accident of this character. The method which will succeed readily in one case may fail completely in another, although belonging to the same class, and not apparently

differing in its anatomical relations. Before relinquishing the attempt, we ought to have put into requisition all the expedients which the experience of other surgeons has shown to be worthy of trial.

During the year 1865, two ancient subcoracoid dislocations came under my observation at Bellevue Hospital. One of these cases, in the person of J. T., æt. 49, had existed two years or more. He was employed about the hospital as a carpenter, and had a tolerably useful arm. The second, in the person of R. C., æt. 32, had existed six weeks when she was admitted. Various attempts had been made to reduce the dislocation before admission. During the week following her admission, an attempt was made at reduction by Dr. Verona, an intelligent house surgeon, subsequently by Dr. James R. Wood, and at the end of three months the attempt was made by myself, before the class of medical students, the patient being each time under the influence of an anæsthetic. She was finally discharged with the bone still unreduced. M. C., æt. 46, was admitted also to the Charity Hospital, in Feb. 1864, with the same dislocation, which had existed six months, having been mistaken at first for a fracture. I found her arm free from swelling or paralysis, and moving quite freely in its new socket, and declined to make any attempt at reduction. July 28, 1873, an Irishman, about 40 years of age, was admitted to St. Francis's Hospital with a subcoracoid dislocation of the humerus of eight or nine weeks' standing. The surgeon who first saw him believed that he reduced the dislocation, but several weeks later he found it was again out of place, and he tried ineffectually to reduce it. My own efforts, continued for an hour or more, were equally unsuccessful.

The two following cases are recorded in order that they may illustrate the apparent inutility of a successful reduction in some cases. W. E. D., of Bridgeport, Conn., received a subcoracoid dislocation of the right arm, in consequence of a violent and direct blow. Dr. George Lewis, of Bridgeport, a very intelligent surgeon, reduced the dislocation within half an hour, the patient being under the influence of ether. The restoration of the bone was complete, and attended with an audible sound. The arm was subsequently very painful, and at the end of three weeks Mr. D. consulted a "natural bone-setter," who manipulated the limb violently, and perhaps dislocated it. July 9, 1870, eight weeks after the original accident, I found the bone unreduced, and in the presence of a number of medical gentlemen at Charity Hospital, effected reduction. The patient was anæsthetized, and the reduction was accomplished only after considerable extension and manipulation had been practised; the return of the bone to its socket being accompanied with a grating sensation. A thick pad was then placed in the axilla, and the arm and forearm secured across the front of the chest. Mr. D. remained under observation for some time; but it was soon evident that the head of the bone was gradually receding from the socket, and that he was not to have a very useful limb.

Jan. 10, 1875, L. B., æt. 40, was thrown from a carriage at Norwich, Conn., causing a subcoracoid dislocation of the left arm. Five days later Dr. Cassidy, of Norwich, reduced the dislocation, the reduction being accompanied with a grating sensation. Four days later Dr. Cassidy found the arm again dislocated, and he again reduced it. Feb. 11th, thirty-two days after the original accident, the arm was examined by myself and other visiting surgeons at Bellevue. Some of the gentlemen doubted whether it might not be a fracture of the surgical neck of the scapula. In my opinion it was a dislocation. On the same day before the class, and under ether, I effected reduction by manipulation, very little extension being employed. The arm was, however, manipulated in various directions, and considerable adhesions were torn before success was attained, the bone returning to its socket suddenly, and with a grating sensation, while the heel was in the axilla, and I was pulling moderately upon the arm. No one doubted the fact of reduction; the arm was now done up as in the preceding case, and the patient remanded to his ward. A few days later I found the head of the bone had receded from its socket, and was evidently tending to assume the position in which I first saw it; and the motions of the joint were very limited.

It is quite probable that among the successful cases of reduction of old dislocations of the shoulder, reported from time to time, many have completed their history in a similar manner. Possibly there may have been in each of these examples a fracture of the inner lip of the glenoid cavity, a condition which has been verified in several autopsies of old shoulder dislocation. The rapid changes which often take place in the socket, and in the condition of the adjacent tissues, may also account for the difficulty which we often experience in reducing these dislocations, and of retaining them in place after reduction. In Professor Lister's case, already referred to, at the end of seven weeks there was a complete socket formed, smooth, cartilaginous, and partly bony; and strong fibrous bands had formed between the coracoid process, the surgical neck of the humerus, and the axillary artery, containing a spiculum of bone.

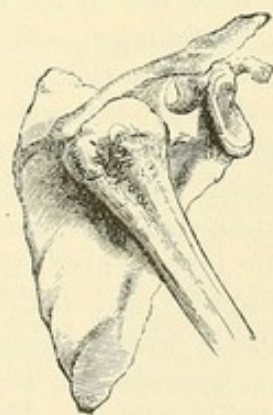
Dislocations of the Humerus Backward. (Subspinous.)

This form of dislocation has been seldom met with. Only two cases, according to Sir Astley Cooper, occurred in Guy's Hospital in thirty-eight years.¹

Sédillot,² Malgaigne, Desclaux,³ Van Buren,⁴ W. Parker,⁵ Lepelletier,⁶ Trowbridge,⁷ Physick, Snyder,⁸ Stephen Smith, and myself, have each seen one example. Examples have also been seen by Dupuytren, Arnolt, Best, Levacher, Berard, Fizeau, Velpeau, Fergusson, Kirkbride,⁹ and by Rogers.¹⁰ To these the researches of Poinso^t¹¹ have added the observations of Lacausade, Ph. Boyer, Goyrand, Alaboissette, Enright, Laugier, Bouisson, Piel, Markham, D. Mollière, Ball, C. Périer, Desprès, Duplay, Sebilleau, Schmidt, and Tillaux.

Dr. Stephen Smith's case was seen by myself ten days after the accident, by courtesy of Dr. Smith. The patient, J. C., æt. 36, fell down a flight of stairs, striking on the front of his shoulder. A surgeon, who saw him a few hours after, thought it was simply a bruise. Sept. 21, he was an inmate of Bellevue Hospital. The head of the humerus could be distinctly seen in its new position, and there was a marked depression under the acromion process, especially in front. The elbow hung very slightly from the body, and scarcely more forward than the opposite elbow. He could carry it forward pretty freely, and a little out, but he could not carry it back. He suffered very little pain, and there was no swelling of the arm or hand. On the following day Dr. Smith reduced the dislocation easily, by pulling the arm forward, and at the same time pushing upon the head from behind. Dr. Smith informs me, however, that the bone became displaced on the following day; but that it was easily reduced, and afterward remained in place.

FIG. 379.



Subspinous dislocation.

¹ A. Cooper, *op. cit.*, p. 352.

² Sédillot, *Amer. Journ. of Med. Sci.*, vol. xiii. p. 551, Feb. 1834.

³ Desclaux, *New York Journ. of Med.*, Nov. 1851, p. 109, from *Revue Médicale*.

⁴ Van Buren, *Ibid.*, Nov. 1851, p. 110.

⁵ Parker, *Ibid.*, March, 1852, p. 186.

⁶ Lepelletier, *Amer. Journ. Med. Sci.*, vol. xvi. p. 526, from *Arch. Gén.*, Nov. 1834.

⁷ Trowbridge, *Boston Med. and Surg. Journ.*, vol. xxvii. p. 99.

⁸ Gibson's *Surgery*.

⁹ *New York Journ. Med.*, March, 1852.

¹⁰ *Amer. Med. Times*, November 9, 1861, vol. v. p. 303.

¹¹ Poinso^t, French ed. of this treatise, p. 860.

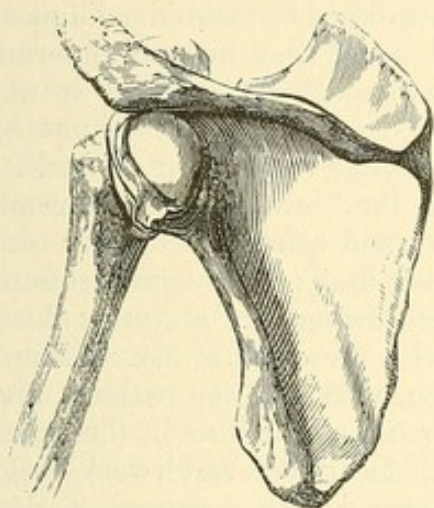
Causes.—One of the patients mentioned in Mr. Cooper's book had his shoulder dislocated backward in an epileptic convulsion; one had fallen upon his shoulder; another met with the accident while pushing a person violently with the arm elevated; and a fourth, seen by Coley, was "pulled down by a calf which he was driving, a cord having been tied to one of the calf's legs, and being held fast by the man's hand." Markham's patient being thrown from his horse and holding upon the bridle with his right hand, the arm was drawn forcibly upward. Desprès's patient had his left arm engaged in the collar of his horse, when the animal lifting his head suddenly threw his arm upward. Bell's patient, a minor, æt. 18 years, had been caught in an earth-slide when his arm was extended upward. My own patient, F. K., had his arm caught in machinery on the 14th of January, 1860. The dislocation was discovered when I was preparing to amputate the arm soon after the accident occurred. Pile's patient, a woman, had her arm forcibly twisted by her husband during an altercation. Desclaux's patient fell from a height with his arm in front of him. The same was the fact with Molière's patient, except that the fall was upon the sidewalk. In the case seen by Dr. Parker, of New York, a woman, æt. 60 years, had fallen forward and was struck upon the outside of her elbow, arm, and shoulder. No attempt was made to reduce it until the fourteenth day, she not having for some time called the attention of any surgeon to its condition. Trowbridge's patient was thrown from a horse, striking on the palm of his hand. With the patient of Périer the dislocation was recurrent, but it occurred in the first instance during an epileptic fit.

Pathology.—Mr. Cooper has given us a careful account of the dissection in the case of Mr. Complin, already alluded to, whose arm had been dislocated by muscular spasm. This gentleman was 52 years of age, and had been subject to epileptic fits, in one of which the shoulder was dislocated. Many attempts were made to reduce it, but although it seemed to be easily drawn into its socket by extension merely, yet, as soon as the force ceased, the head of the bone slipped again upon the dorsum scapulæ, and in this situation it was finally permitted to remain until his death, which did not take place until five years after. In the meantime he was able to move the limb but very slightly, so that his arm was almost useless. Mr. Cooper, to whom the arm was sent after death, found the head of the bone resting under the spine of the scapula, and against the posterior edge of the glenoid fossa, where it had formed a slight depression, and the head itself had become somewhat changed in form by absorption. The tendon of the subscapularis muscle and the internal portion of the capsular ligament were torn at the point where the muscle was inserted, but the greater portion of the capsule remained, having been pressed back by the head of the bone. The supraspinatus was stretched, while the infraspinatus and teres minor were relaxed. The long head of the biceps was elongated, but not ruptured. The glenoid fossa was rough and irregular upon its surface, the cartilage being absorbed. The fact that the bone would not remain in place when reduced was explained by the rupture of the subscapularis, and the consequent loss of antagonism to the action of the infraspinatus and teres minor.¹

¹ Sir Astley Cooper, op. cit., p. 354.

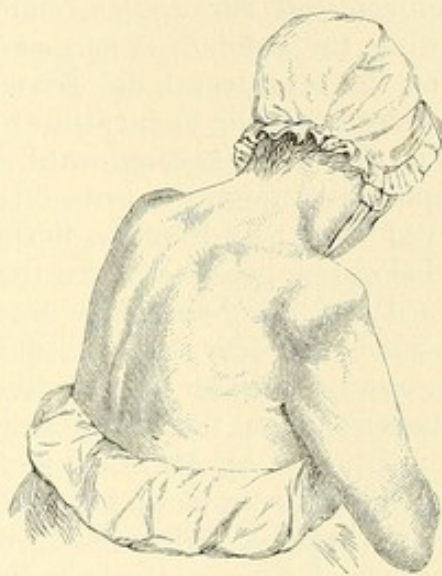Laugier, who dissected a recent case, found the tendon of the subscapularis torn from its attachment. The same was the fact with the supraspinatus, and the head, having passed between the infraspinatus and the teres minor, lay exposed under the deltoid. In Malgaigne's case the infrascapularis was intact; but the greater tuberosity was torn off, and remained attached to the infra- and supraspinatus muscles. The head, having passed between the teres minor and the infraspinatus, was situated under the deltoid, below the posterior angle of the acromion, one-third of the articular surface overhanging the glenoid cavity. Périer dissected the arm of an epileptic woman who had been subject to recur-

FIG. 380.



Cooper's case of subspinous dislocation.

FIG. 381.



Dislocation of the right humerus backward.

rent backward dislocation. The capsule was not ruptured; the outer margin of the glenoid cavity was partially absorbed; the head lay slightly overhanging the glenoid cavity under the acromion process, and was greatly changed in form and texture. Kronlein describes a specimen contained in the Museum of the Clinic at Berlin, in which the head had rested just back of the glenoid cavity, where it had formed for itself a complete bony socket.

This case has been regarded by Vidal (de Cassis), Malgaigne, and others, as only subacromial, and as a variety of the dislocation backward, differing from that in which the head of the bone occupies a position underneath the spine. But as I can see no difference except in the degree or extent of the displacement, I prefer not to regard the distinction made by these surgeons.

Symptoms.—The signs of this accident are, a projection under the spine of the scapula, produced by the head of the bone, the head being obedient to the motions of the arm; a corresponding depression in front and under the outer extremity of the acromion process; a wide space between the head of the bone and the coracoid process, into which the fingers may be pushed deeply; the axis of the shaft of the humerus directed upward and outward toward a point posterior to the glenoid fossa. The forearm is usually carried forward across the chest, and the humerus rotated inward, unless the subscapularis muscle is torn. Immobility exists, but the motions of the arm are not generally so much impaired as in either of the other dislocations; and finally, as in all other dislocations of the humerus, the hand cannot be laid upon the opposite shoulder while the elbow touches the front of the chest.

In Parker's case the elbow was thrown outward, although the arm was carried very much across the chest. In Stephen Smith's case the arm was nearly vertical. Desclaux's patient held his hand upon his head, with his arm horizontally across his body. In Ball's case the position of the arm was also horizontal. In Duplay's patient the arm was hanging beside the body with a slight rotation inward, the elbow being carried a little forward. In Markham's patient the arm hung beside the body and was immobile.

Diagnosis.—Usually the diagnosis will be easily made; in my own and Stephen Smith's case the position of the head of the bone was easily recognized, but Sir Astley relates one case in which, on the morning following the accident, a surgeon was unable to discover the dislocation, and on the seventeenth day Bransby Cooper failed to make the diagnosis; nor, indeed, on the twenty-third day, did Sir Astley himself determine that it was a dislocation, until he had unexpectedly reduced it while manipulating upon the arm. In a second example, Sir Astley at first believed it to be a fracture, but a more careful examination showed it to be a dislocation backward. In this instance the limb could not be rotated outward, as the subscapularis was not torn, and continued to offer resistance when the arm was moved in this direction; he was also suffering much more pain than did the other patients, owing, as Sir Astley thinks, to pressure upon the articular nerves. In the case of Mr. Collinson, also mentioned by Mr. Cooper, a surgeon, who saw the patient immediately after the accident, failed to discover the true nature of the injury; and Trowbridge's patient had suffered a dislocation several weeks before the nature of the accident was fully determined. In a patient of Sédillot's, Dupuytren, who was first consulted, thought it was a simple inflammation of the joint; and Nélaton related to Panas in 1870, three errors in diagnosis committed by surgeons of merit in connection with this accident.

Prognosis.—In B. Cooper's case the arm was not reduced, and never recovered any considerable degree of usefulness. Sebillieu reports a case in which the reduction having been attempted fifteen days after the accident, proved unsuccessful. Three months later the attempt at reduction was repeated by Richet, at Hôtel Dieu, but without success; and at the end of four years the arm was nearly immobile, the muscles of the forearm and hand being much contracted. Tillaux's patient, æt. 59 years, having a dislocation of six years' standing, which being reduced could not be maintained in place, had but limited use of his arm. Elevation of the arm was impossible. In Schmidt's case, the dislocation was of eighteen years' standing, and the motions of the arm were almost completely restored. Mr. Collinson's arm, reduced on the second day, was restored to all its functions within one month. Dr. Parker's patient had nearly recovered the complete use of her arm at the end of four weeks, although it was not reduced until it had been out fourteen days. Sédillot succeeded in reducing the dislocation in the case of his patient, at the end of one year and fifteen days; Lepelletier, after forty-five days; Trowbridge, after forty days; and in this latter case we are informed that the arm was restored to usefulness.

Treatment.—In the first case mentioned by Sir Astley Cooper, "the bandages were applied in the same manner as if the head of the humerus

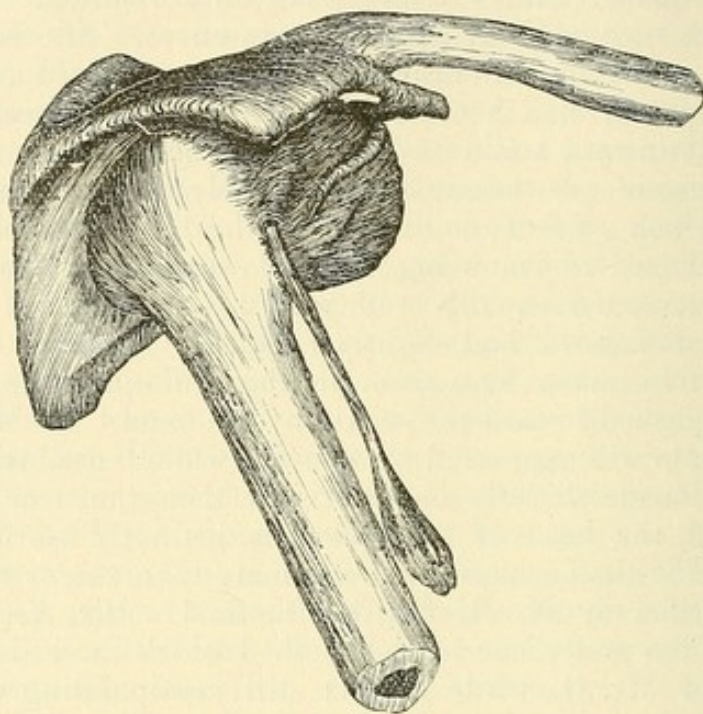
had been in the axilla, and the extension was made in the same direction as in that accident" (downward and a little outward). In less than five minutes the bone slipped into its socket with a loud snap. The second case was treated successfully in the same way. Mr. Dunn also having failed to reduce by pulling upward, finally succeeded by pulling at the wrist downward and forward, while an assistant pushed the head of the bone toward the socket; the heel was not placed in the axilla, which Mr. Bransby Cooper thinks would have only retarded the reduction. Stephen Smith succeeded by a similar manœuvre. Mr. Key also failed to accomplish reduction while carrying the arm upward and backward, but when the patient had become faint, by placing the heel in the axilla and pulling downward a minute or two, the bone was reduced. Vidal (de Cassis) recommends the same plan, namely, that we shall pull in the direction in which we find the limb; Trowbridge employed the pulleys successfully, the extension being made downward and forward; while Dr. Parker succeeded equally well with his patient, by "pulling the arm outward, downward, and slightly forward." Counter-extension was at the same time made by a sheet in the axilla, and the head of the humerus was pushed toward the socket by the hand. In Mr. Collinson's case, the scapula was supported by a towel, while "gradual extension of the limb was made directly outward, and then the arm being moved slowly forward, the head of the bone was distinctly heard to snap into its socket." The time occupied was not more than two or three minutes. Rogers succeeded by N. R. Smith's method. Sir Astley, however, seems to give the preference to the method which succeeded so happily in the case of Mr. G., while he was still manipulating with a view to determine the character of the accident. "I readily reduced the bone," he remarks, "by raising the hand and arm, and by turning the hand backward behind the head." In one other instance, having failed to reduce it by slight extension outward he raised the arm perpendicularly, at the same time forced it backward behind the patient's head, and the reduction was promptly effected. Markham succeeded by a similar manœuvre. In the case of Kretner, I first attempted reduction by pressure directly upon the head of the humerus; but failing, I proceeded to pull the arm with moderate force outward and downward, which procedure was attended with immediate success. The patient was under the influence of chloroform. Slight forward traction was sufficient in the case of Duplay. Molière combined direct pressure upon the head with slight extension. Arm. Deprès succeeded by traction made at a right angle with the body, combined with moderate rotation.

Prof. Gunn, in describing the specimen from which the accompanying illustration is taken, remarked: "It is seen that the head rests on the dorsum of the scapula, while the vacated glenoid cavity is covered by the untorn anterior half of the capsular ligament, which is stretched across the articular surface, holding the head snugly against the posterior edge of the fossa, and by its inferior fibres causing the advanced position of the lower end of the humerus, which is so characteristic of the accident. Internal rotation relaxes this untorn portion of the ligament, as does also a still more advanced position of the elbow with the humerus elevated to a horizontal position. For a reduction of this luxation the shoulder should be properly fixed by an assistant, while the surgeon seizes the

arm by the elbow and forearm, raises it to a horizontal position, carries it to the front, rotates inwardly, and draws it into place."¹

After the reduction, a compress should be placed against the head of the bone, and underneath the spine of the scapula, and this should be secured in its place by several turns of a roller. The forearm ought also

FIG. 382.



Showing untorn anterior half of capsule in dorsal dislocation of the humerus. (Gunn.)

to be placed in a sling, with the elbow thrown a little back of the centre of the body, so as to direct the head of the humerus forward.

Dislocations of the Humerus Upward.—The existence of this form of dislocation, unaccompanied with a fracture of the coracoid or acromion processes, or of both, has been denied by Boyer, Sédillot, and most other surgical writers. A certain number of facts and observations, however, tend to establish its possibility or its actual occurrence.

Malgaigne,² who was the first to admit of its possibility, says: "A man, æt. 68, was seated upon a wagon loaded with fagots, when the wagon was overturned. He was thrown a great distance, and struck upon the point of the shoulder, with the arm against the side of the body. The man immediately experienced a sharp pain, and it was impossible to move the arm. A bone-setter made violent tractions, and sent him away with his arm in a sling. Eight days after he tried to move it, but without much success; and he came to consult me at the end of two months and a half. The head of the humerus was dislocated forward and upward above the acromio-coracoid ligament, corresponding outward to the internal border of the acromion, covering inward the coracoid process, and resting above against the inferior surface of the clavicle, raising the deltoid muscle to such an extent that a pin inserted into the most projecting part did not show more than eight millimetres of flesh; while the pectoralis major and the deltoid were six millimetres from the surface. The arm was not shortened more than half a centimetre. I attempted reduction by elevating the arm to a right angle,

¹ Gunn, loc. cit.

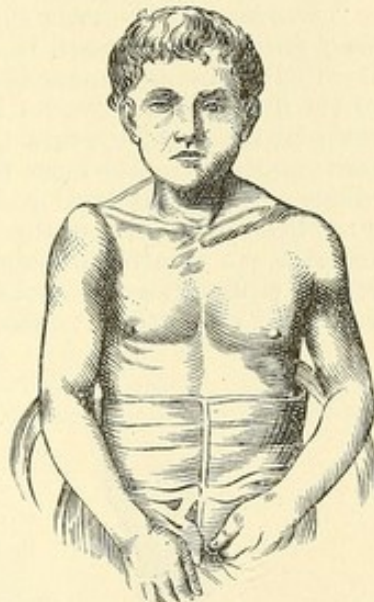
² Malgaigne, op. cit., vol. ii. p. 530.

at the same time pressing on the head to push it downward, outward, and backward, while an aid tried to press the acromion upward, inward, and forward. At 205 kilogrammes I heard a cracking as if a bone had been broken, although the reduction did not seem to have been effected. I ceased traction, and explored all the points of the shoulder without discovering any fracture. There did not even ensue any sensible tumefaction. The head was more movable, and it was possible to draw it downward until the fingers could be laid in the space thus created below the clavicle. There was also some gain in the freedom and extent of the movements. I thought of dividing the acromio-coracoid ligament, but after some reflection I judged it preferable not to do so."

According to Poincot, similar examples have been reported by Verneuil, Le Dentu, Busch, Laugier, Chassaignac, and Denonvilliers. Verneuil and Le Dentu were unable in their patients to find a fracture of the coracoid process. The same was the fact with Busch; while Laugier, Chassaignac, and Denonvilliers are silent upon this subject. In the case seen¹ by Busch, the patient, while holding the reins of a restive horse, seized the bit with his right hand, when the horse rearing struck the shoulder with its foot at the antero-internal portion of the scapulo-humeral region. In Laugier's case, a lad, 16 years old, having his arm stretched out and fixed on a machine, with his body resting on his arm, and his feet far from the resting-point, felt suddenly a violent torsion of the body from before backward, and from right to left. M. Poincot thus explains the mechanism of the accident in this case: "In that movement, the head of the humerus, on which the body rotated, underwent a movement of rotation outward, being carried at the same time upward and forward, so as to correspond to the superior and anterior part of the articular capsule; which latter being torn where it was stretched, the bone was permitted to go upward, so as to place itself outside the beak of the coracoid apophysis."

In a case seen by Holmes,² the patient, a man, 60 years of age, had fallen a great height (about 30 feet) upon a pile of stones, striking upon the head, the left side of the body, and the left elbow. When brought to St. George's Hospital, his unconsciousness, indicating cerebral concussion, rendered it necessary to postpone the reduction for several days. When it had been decided to attempt it, he was taken with septicæmic symptoms, which originated in a compound fracture of the elbow, and he died fifteen days after the accident. On examining the dislocated shoulder, the head of the humerus was found immediately under the skin, with the cephalic vein at its internal portion. It had fractured the coracoid apophysis in its movement from below upward, and was resting behind on the projection of that apophysis and on the clavicle, pulling with it a small portion of the acromio-coracoid ligament which had not been torn. At its internal portion, besides a few fibres of the deltoid and of the cephalic vein, the fractured extremity of the coracoid process was found, with the muscles which are inserted in it: the pectoralis minor, the coraco-brachialis, and the short portion of the biceps. At the external portion and a little backward was the acromion, separated from the head by a few fibres of the deltoid. Below and a little outside was the glenoid cavity, whose superior border was situated entirely below the level of the humeral extremity. The tendon of the longer portion of the biceps was still attached to the scapula, and was consequently situated below and outside of the dislocated head, which, as it came out of its socket, had slightly torn this tendon, so that a few of its internal fibres had been separated

FIG. 383.



Busch's case, supra-coracoid dislocation.

¹ Busch, *Arch. für klin. Med.*, Bd. xix. Hft. 3, p. 400.

² Holmes, *Med.-Chir. Trans.*, vol. xli.,

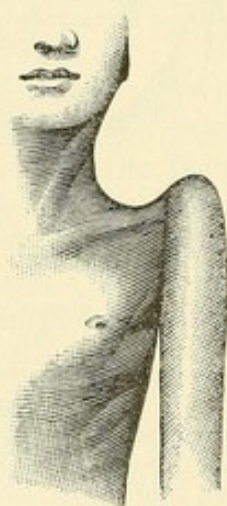from the muscle, and remained floating freely, with a cluster of muscular fibres attached to them. The coracoid apophysis had been fractured near its base, the coraco-acromial ligament remaining attached to the two fragments, so that they could not be much separated from each other; the summit was pulled from above downward, and from out inward, by the muscles inserted in it. The humeral head rested directly on the projection of the apophysis, which had produced a slight erosion on the corresponding articular cartilage. The humerus had slightly turned on its axis, so that the greater tuberosity was relatively more in front than in its normal position. The subscapularis muscle was intact. The muscles inserted into the greater tuberosity had been lacerated, except a portion of the teres minor, which had remained uninjured; the capsular ligament, torn at its superior and internal portion, presented a large opening which had given passage to the head.

Albert,¹ of Innsbrück, has reported a case of double dislocation upward, in a man 60 years old, which had existed many years. This man having died of pneumonia, an autopsy was obtained. All that was known about the origin of the dislocation was, that it was caused while he was trying to hold a pair of spirited horses by the bridle.

The following condition of the parts was found at the autopsy:

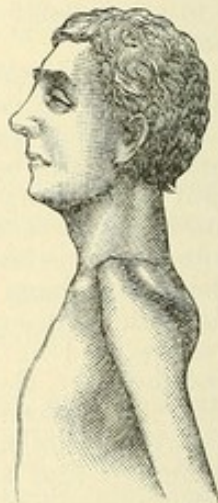“Left Shoulder.”—After the removal of the skin, the great pectoral muscle was seen gathered on itself, from below upward, so that its vertical diameter, on a level with the mammary line, was ten centimetres long; the fan-like direction of its fibres at the level of its insertion being consequently far more noticeable than in the normal state. The deltoid was very much stretched in its middle part, and was relaxed, on the contrary, in its scapular portion. In the movements of slight abduction, the great pectoral and the teres major muscles were stretched and resisted the effort. The deltoid being detached at its inferior insertion, a small independent subdeltoid bursa was found; the subacromial bursa, situated more backward and small, presented on its internal surface papillary vegetations. After removing the great pectoral, at the inner side of

FIG. 384.



Front view.

FIG. 385.



Side view.

Albert's case of double upward dislocation.

the humerus, the coraco-brachialis and the smaller portion of the biceps were found intact, as well as the plexus and the vessels which were also situated at the inner side of the bone; the tendon of the longer portion of the biceps could be followed to the inferior limit of the surgical neck, where there existed a bony prominence, which we shall mention further on; but the tendon ended there by a sort of swelling; the bicipital groove was no more distinguishable. The capsule, of medium thickness, was inserted into the whole circumference of the

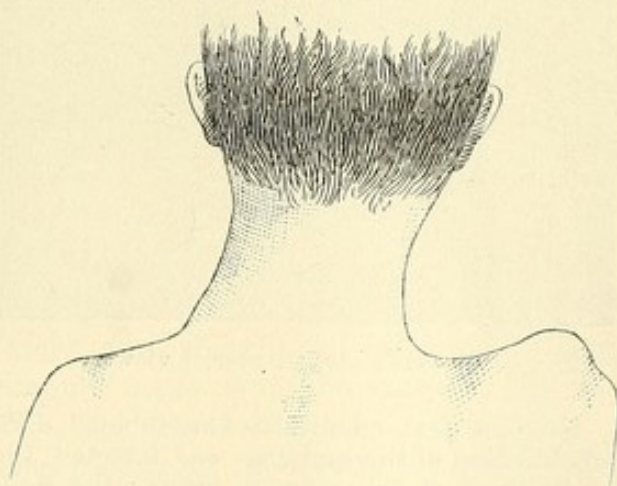
¹ Albert, Wiener med. Blatter, 1879, xix. S. 453.

anatomical neck; on a level with the humeral head it adhered also to the articular surface; looking downward and backward to its central insertion, the capsule presented in front and above a considerable enlargement of its cavity so as to touch the lateral part of the coracoid apophysis, and it was attached to the edge of the acromio-coracoid ligament. The acromio-coracoid, the trapezoid, and conoid ligaments were intact. The humeral head overlapped, by its superior third, the edge of the acromio-coracoid ligament, but could easily be pushed upward, into the space comprised between that ligament, the acromion, and the coracoid processes, so as to overlap the ligament by all its superior half when the humerus was carried outward and backward. The glenoid cavity was filled with cellular tissue, which on a level with the margin presented a highly-polished surface. From the inferior edge of the surgical neck to the head of the humerus, was a bony lamella, starting from the postero-lateral part of the bone and terminating backward by a very irregular free edge. From the base of the coracoid apophysis a very nodulated bony prominence was detached, its shape being that of a crow's beak, or rather a deer's horn, and measuring two centimetres and a half in length.

"*Right Shoulder.*—The muscles, the large vessels, the acromio-coracoid, conoid, and trapezoid ligaments, as well as the scapula and the humerus, were all in their normal state. The acromial extremity of the clavicle was enlarged, with a flattening of the portion corresponding to the head. The capsule presented the appearance of a large sac with walls very much thickened at certain points. In the part corresponding to the superior margin of the glenoid cavity were a number of superposed horizontal folds, of the size of a centimetre, and projecting into the interior of the cavity; these folds divided it into two portions, an inferior one, corresponding to the old articular cavity, and a superior one, corresponding to the new one. The head could be abnormally moved in all directions within the capsule, and it appeared flattened above and behind and was denuded of its cartilage. On the level of the anatomical neck, the cartilage was worn out in places; in others it presented a velvety alteration, at which points it was of a yellowish-gray color. The bicipital groove was very shallow."

Panas and Angers¹ have demonstrated upon the cadaver that the head of the humerus could be dislocated upward above the acromio-coracoid vault without destroying it.

FIG. 386.



Robson's case of supracoracoid dislocation of humerus. Posterior view. (Robson.)

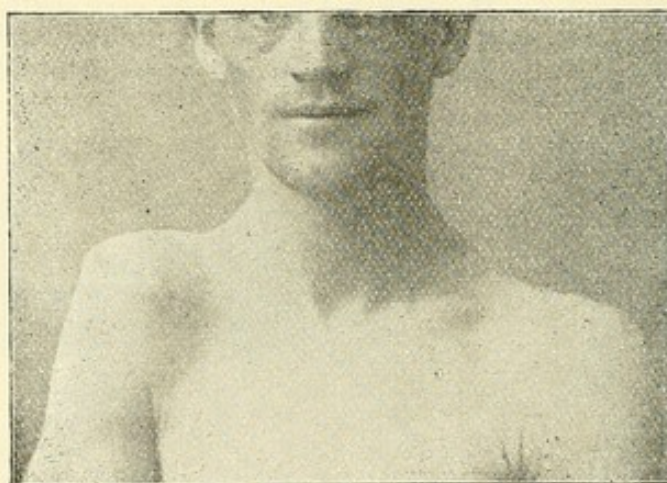
[A. W. M. Robson, of Leeds, reports a case of supracoracoid dislocation of the shoulder: A boy, æt. 16, was putting on his coat, and having got his right arm into the sleeve, was commencing to introduce the left, when the loose sleeve was caught by the "breast-strap" of the machinery and quickly twisted round, the right arm being pulled violently in an upward and backward direction, away

¹ Panas, *Art. Epauule*, *Nouveau Dict. de Méd. et de Chir. Prat.*, t. xiii. p. 466.

from the body. A sudden pain was felt in the shoulder at the time, but afterward the whole arm felt numb, although on touching it or on attempting to raise it there was very acute pain. Six weeks after the accident there was a large, hard, slightly-irregular, rounded swelling about a finger's breadth in front of the right acromion and immediately to the outer side of the coracoid process. In front a depression was seen immediately beneath the acromion, and again below this a rounded elevation; the bony prominence moved with the shaft of the humerus in flexion, extension, adduction, abduction, etc., so that there was no doubt that it was the head of the bone. The arm could be readily placed against the side of the chest, with the hand touching the opposite shoulder and the tips of the fingers on the occiput. The arm could be moved anteriorly to the angle of forty-five degrees, and was then arrested by the contact of the head of the bone with the acromion; backward movement not limited. Rotation outward was prevented by the head of the bone coming in contact with the acromion. Efforts at reduction failing, an incision was made on the outer side of the shoulder, disclosing a longitudinal fracture separating the greater tuberosity and extending down the shaft; the fossa being filled with plastic material, the operation was discontinued. The patient recovered good use of the arm.¹

Dr. Charles A. Powers, of New York,² reports a case of dislocation of the right humerus of long standing, accompanied by exceptional displacement, which is evidently allied to the upward displacement, though it had other features quite anomalous. The patient was a man, æt. 20, and the displacement had existed three years. In October, 1886, his arm and forearm were caught in machinery in such a way that he was thrown forcibly against it, the forearm being violently wrenched and the shoulder contused. Pain and disability of the shoulder followed. Three months after, reduction, under ether, was attempted, but the bone could not be retained in place, and he resumed his work

FIG. 387.



Powers's case. Anterior view.


—brush-making. He was next examined December 1, 1889, by Dr. Powers, when an anterior dislocation of the humerus was detected, the head of the bone resting above and in front of the glenoid cavity; the deltoid was extremely atrophied; the humerus could be made to undergo complete internal rotation, but external rotation was a little restricted; abduction was possible to but forty-five degrees. When the arm was lifted the head of the humerus could be made to undergo a very marked excursion forward and upward, resting without and above the coracoid process (Figs. 387 and 388), and could be forced to lie entirely above the clavicle. On bringing the elbow to the side, twenty degrees in front of the mid-axillary line, the head of the humerus could be forced into the glenoid cavity, or rather to a glenoid position, but when the force was

¹ *Annals of Surgery*, vol. viii., 1888.

² *Medical News*, Sept. 1, 1890.

released it would at once fly forward. When the elbow was at the side, and the head dislocated forward, the right hand could easily be placed on the opposite shoulder. The axillary acromial measurement was three-quarters of an inch greater than that on the opposite side. The functions of the hand and forearm were excellent. The entire head, tuberosities, and neck of the bone could be intelligently palpated. At the inner side of the neck a prominent ridge could

FIG. 388.



Powers's case. Lateral view.

be distinctly felt, and the presence of this raised the question of longitudinal fracture at the time of the original injury. Dr. Powers states that "it would seem highly probable that the patient suffered, at the time of his accident, an anterior luxation, probably complicated by a longitudinal fracture through the upper part of the bone, and that constant use of the arm enabled the head of the humerus to make its wide excursion inward and upward."

The possibility of this form of dislocation without fracture is now definitely established by dissection. Additional cases show, however, that some form of fracture generally exists. In Robson's case a longitudinal fracture separated the greater tuberosity, while the existence of a fracture, longitudinal in its direction, was believed to exist in Powers's case.]

It may be here stated briefly, by way of summary, that the testimony which is to establish the possibility of this accident unaccompanied with a fracture, is found in seven clinical cases not verified by an autopsy, in certain experiments made upon the cadaver, and in the single case reported by Albert, and demonstrated by a dissection. With the imperfect knowledge in my possession relative to the purely clinical cases, I am not warranted in subjecting them to criticism. As to the value of Panas's experiments made upon the cadaver, I must repeat what I have often said before in reference to similar experiments made upon other joints. The results of such experiments cannot be applied without great reserve to dislocations occurring upon the living subject, and when the muscles have their normal power and activity. Of the case of the man æt. 60, reported by Albert, and in which case alone has a dissection revealed a dislocation without a fracture, the fact that it existed in both shoulders at the same time, connected with the obscurity of its history, suggests the

possibility that, instead of having been primarily a dislocation, it was at first only a sprain, from which resulted an arthritic and muscular affection, in consequence of which latter conditions the displacement had gradually been produced.

The following remarks are quoted from Poinso, who accepts the dislocation as an established fact :

“Prognosis.—In all cases of absolutely recent dislocation, and where reduction has been effected without great efforts, the prognosis is possessed of little gravity ; but it soon becomes very serious, both on account of the extreme hindrance resulting from the persisting displacement and of the infinite, if not insurmountable, difficulties which are met with during the attempts at reduction after a certain lapse of time. Laugier, on the twelfth day, could not reduce the dislocation in his patient ; Malgaigne, after two months and a half, and Busch, after five months, were also unsuccessful. Professor Verneuil, it is true, was able to effect reduction on the thirty-sixth day, but it was a dislocation which had already been reduced on the very day of the accident, and which had been reproduced.

“Treatment.—Malgaigne, in the case of his patient, had attempted reduction by making tractions upon the arm elevated at a right angle, and by pressing upon the head in such manner as to push it downward, outward, and backward, while an assistant tried to pull the acromion upward, inward, and forward. Busch employed, without being more successful, Schinzinger's procedure (rotation outward), and that of A. Cooper (elevation of the arm at different degrees). Denonvilliers and M. Verneuil effected reduction by means of tractions downward, combined with a tilting motion, with the view of bringing back the head toward the cavity. M. Verneuil had failed the first time, when tractions downward were made alone, and, during his second attempt, he thought it necessary to anæsthetize the patient. M. Panas, being guided by experiments, advises ‘to carry the arm away from the body until the head is sufficiently lowered to pass under the coracoid ; at the same time that the elbow is being raised, it is necessary to give the humerus a movement of rotation inward, gradually increased.’ Albert, of Innsbrück, recommends abduction, extension backward, and rotation inward. Verneuil, in order to prevent the dislocation from being reproduced, as had already happened twice, placed the arm (strongly adducted) in front of the chest, the hand being placed upon the sound shoulder, and maintained in that position by means of a silicate bandage.”

Partial Dislocations of the Humerus.

The existence of this or of any other form of partial dislocation of the shoulder-joint, as a traumatic accident, has not up to this moment been fairly established. The anatomical structure of the joint renders its occurrence exceedingly improbable, if not absolutely impossible.

The only example mentioned by Sir Astley Cooper, in which a dissection was made, showed that the long head of the biceps had been ruptured, and that the capsule was torn, while the head of the humerus was resting under the coracoid process. We shall have no difficulty, therefore, in assigning it to its proper place as a complete subcoracoid dislocation. In Mr. Hargrave's case, also, the tendon of the biceps was torn ; while Dupuytren omits to mention what was the actual fact in relation to this tendon in the case seen by him, but it is distinctly stated that the head of the bone rested upon the ribs. Mr. Hargrave seems, therefore, to have described a case of rupture of the long head of the biceps, and it is possible that Dupuytren, who knew nothing of the previous history of the subject, has given us a faithful account of a pathological dislocation, a result of

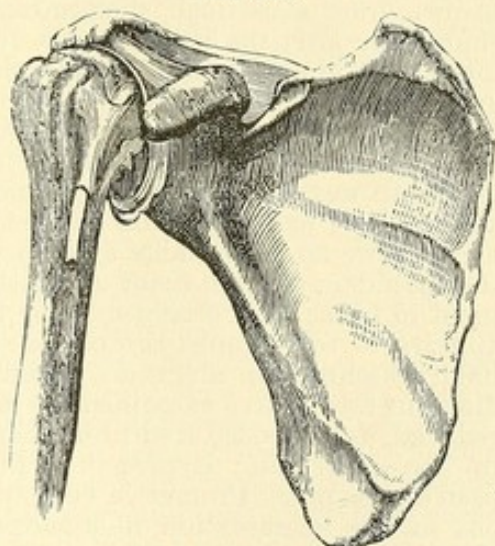
disease, and not of a direct injury. Poinsoy remarks, also, that the four cases mentioned by Owen¹ were examples of chronic lesion.

If the head of the humerus is driven from its socket by violence, and remains thus displaced, it is a complete dislocation; since it is only by having placed the semi-diameter of the head of the bone outside of the margin of the glenoid fossa that it can be made for one moment to retain its abnormal position. To accomplish this amount of displacement upward, or upward and forward, or directly forward, the acromion or the coracoid process must be broken; while its occurrence in any other direction must involve at least a most extraordinary extension, if not an actual laceration, of the capsule. If we admit, with Malgaigne, that occasionally the capsule has been found capable of such extraordinary extension without actual rupture, I am still unwilling to regard this as a fair example of a partial dislocation, since the head of the bone no longer moves in its socket, being at no point in actual contact with the articular surface of the glenoid fossa. It is essentially a complete dislocation, according to all the admitted definitions of this term.

It is quite probable that a majority of these accidents were examples of rupture or displacement of the tendon of the long head of the biceps, the effect of which, as Mr. Jno. G. Smith² and Mr. Soden³ have shown by a number of dissections, is to allow the head of the humerus to be drawn upward and forward in its socket, until it is arrested by the two processes, and by the coraco-acromial ligament. Says Mr. Soden: "To enable the bone to maintain its equilibrium, it is necessary that the capsular muscles should exactly counterbalance each other; and as there is no muscle from the ribs to the humerus to antagonize the upper capsular muscles" (that is, to draw the head of the humerus downward), "it is suggested that this office is performed by the singular course of the long tendon of the biceps, which, by passing over the head of the bone, when the muscle is put in action, tends to throw the head downward and backward; it follows, therefore, that, the tendon being removed, the head of the bone would rise upward and forward."

The head of the humerus sometimes remains for a long time after the reduction has been effected slightly advanced in its socket, so as to lead to a suspicion that it is not properly reduced.

FIG. 389.



Soden's case of displacement of the long head of the biceps.⁴

¹ E. Owen, *The Lancet*, 1875, vol. i. p. 759.

² *Amer. Journ. Med. Sci.*, vol. xvi. p. 219, May, 1835, from *London Med. Gaz.*

³ *Ibid.*, vol. xxix. p. 489, from *Lond. Med. Gaz.*, July, 1841.

⁴ *Pirrie's System of Surgery*, Amer. ed., p. 255; also *Sir Astley Cooper*, edited by Bransby Cooper, Amer. ed., p. 363.

The same thing, also, has been noticed by me occasionally where the shoulder had been subjected to a violent wrench, but no actual dislocation had ever occurred. In either case the explanation is perhaps the same—the long head of the biceps has been broken or displaced; or, when it follows a dislocation, some of the muscles inserted into the greater tuberosity have been torn from their attachments.

In these circumstances we may find a sufficient and perhaps the most frequent explanation; yet it is quite probable that, in a considerable number of cases, the laceration of the capsule, and the action of the muscles, are alone concerned in the production of this phenomenon. I have seen one example in the person of Mr. Craig, of Brooklyn, in which the tendon of the biceps suddenly resumed its position after the lapse of several days, and the prominence of the head of the humerus at once disappeared. David Prince,¹ Hewitt,² and Holmes³ have reported similar cases. In Mr. Holmes's case, however, the coracoid process was broken also.

Dr. Mercer, of Syracuse, N. Y., relates several examples of forward displacement after injuries to the shoulder-joint, one of which is exceedingly pertinent. Mrs. B., a well-developed woman, of full habit, aged 56, seven years since was thrown from a carriage, dislocating her right shoulder, which was reduced a short time after the accident, but the shoulder was painful, and tender to the touch, and almost useless for months after. She could carry the arm forward and backward, but could not raise it from the side, or carry her hand behind her, or raise it to her head, for fourteen months. She has gradually gained better use of her arm, but now she cannot raise her elbow from the side more than half-way to a horizontal position without assistance; but with assistance, the arm may be carried into any position without pain or resistance. Measurement shows no appreciable difference in the size or length of the arm, or size of the shoulder; but the point of the shoulder is still tender to the touch, is prominent in front, and correspondingly flattened behind. The head of the humerus appears to rest against the outside of the coracoid process, but the fulness of habit obscures the diagnosis, compared with other cases. Several doctors, at different times, have examined the shoulder; some have said it was not properly reduced, and advised a suit for malpractice. "I examined the shoulder again in November last; it presented the same general appearance, although the patient was much thinner in flesh from recent sickness. Some six weeks previous to this examination, in a sudden and thoughtless effort to raise the arm above the head, the muscles unexpectedly obeyed the will; since which time she has had perfect use of it, though the deformity still remains. She thinks she felt or heard a snap when the arm went up, but it was followed by no pain, soreness, or swelling."⁴

There cannot be much doubt, I think, that in this case, at least, the deformity and maiming were due in a great measure to a displacement of the long head of the biceps.⁵

[The frequency with which the long tendon of the biceps is displaced or ruptured is very doubtful. Recent investigations seem to show that it is a comparatively rare accident.]

If a displacement of the tendon necessarily causes a displacement of the head of the humerus, it might seem proper to infer that a rupture of the tendon would do the same. The only example of rupture of the tendon which has come under my observation does not confirm this opinion.

¹ Prince, St. Louis Med. and Surg. Journ., Nov. 1879.

² Hewitt, Holmes's Surgery, 2d Lond. ed., vol. ii. p. 820.

³ Holmes's Surgery, 2d Lond. ed., vol. ii. p. 820.

⁴ Mercer, Buffalo Med. Journ., vol. xiv. p. 641, April, 1859.

⁵ Broomfield's Chirurg. Observ., vol. ii. p. 76.

J. W., æt. 46, a sailor, and a man of remarkable muscular development, while pushing a swing with his arms extended felt something snap in his right arm, and the arm at once became powerless. The sensation of snapping was at a point about four and a half inches below the acromion process. The pain was like that caused by hitting a nerve; on the following day there was an extensive ecchymosis over the upper end of the humerus, and the belly of the biceps was full and flabby. He was examined by me about eight months after the injury. The belly of the biceps had shortened upon itself, and made a remarkable prominence on the front of the arm, but he could not render it firm by contraction. He could flex the arm slowly, but not against any considerable resistance. The head of the humerus was not advanced in the socket. I could feel the tendon of the biceps in its groove, and inferred that the rupture took place near its insertion into the muscle. J. L. Petit has reported a similar case, in which the rupture was caused by the extension employed in an attempt to reduce a dislocation of the arm.¹ Poincot records an example of rupture of this tendon in a man, caused by lifting, and in which the head of the humerus was not displaced. Three weeks later the same accident was reproduced in a similar manner.

Dr. Gerster, in a paper on "Subcutaneous Injuries of the Biceps Brachii,"² has made the following historical notes and observations: "Older surgeons (Stanley, Bromfield, Knox, Monteggia, for instance), up to the middle of this century, diagnosed as dislocations of the long head of the biceps, cases similar to the one related" (case of partial rupture of the tendon, and of the corresponding part of the sheath of the long head of the biceps). "They supposed that the tendon left its groove, and slipped upon the major tubercle. True, none of them ever found the tendon in its dislocated condition, but they assumed that a spontaneous reduction took place by a rotation of the humerus, before a competent judge could ascertain the nature of the injury. William Cooper and Boerhaave accepted the possibility of such an injury. Fergusson expressed himself cautiously on the subject. Bardeleben, Pitha, and Volkmann deny its existence, referring to a series of exhaustive articles in the *Gazette Hebdomadaire* (2d ser., [xiv.], 21, 23, 25, 1867), written by Jarjavay, which completely disposes of this 'mysterious dislocation,' as Pitha sarcastically calls it." Gerster states, moreover, that Pouteau had long before doubted the existence of this dislocation, and that Malgaigne had expressed scepticism as to the true character of Mr. Soden's case. In short, Dr. Gerster claims that its existence, uncomplicated with other accidents, has never been demonstrated satisfactorily upon the living or dead subject; and that, to say the least, it is doubtful whether it has ever occurred. The entire argument, together with the anatomical reasons assigned, are very ingenious; and while they do not settle conclusively the question of its possibility, they seem to throw a doubt upon the true nature of some of the cases reported.

Dr. White,³ of Philadelphia, in an excellent *résumé* of this subject, concludes that the occurrence of a traumatic dislocation of the long tendon of the biceps, unaccompanied with a dislocation of the humerus, has not been absolutely proved. He reports, however, a case which both Dr. Agnew and himself believed to be such a dislocation. A man, æt. 37, had fallen upon his shoulder from a considerable height. Seen by these surgeons soon after the accident, it was thought that the empty bicipital groove and the displaced tendon could be distinctly felt. At the end of two years the displacement continued, and at this period the patient had recovered nearly, but not wholly, the free use of his arm.

¹ Malgaigne, op. cit., Paris ed., 1855, vol. ii. p. 145.

² Gerster, New York Med. Journ., May, 1878, p. 487.

³ White, J. W., Surgeon to the Philadelphia Hospital, and Asst. Surgeon to the University Hospital, Amer. Journ. Med. Sci., Jan. 1884.

CHAPTER VIII.

DISLOCATIONS OF THE HEAD OF THE RADIUS
(HUMERO-RADIAL).

I HAVE recorded thirty-two examples of traumatic dislocation of the head of the radius as having been seen and examined by me; of which twenty-seven were dislocated forward, or forward and outward, and only five backward; or, rejecting those cases which were complicated with fracture, I have recorded fourteen cases of simple forward dislocation, and three of simple backward dislocation. My experience, therefore, does not correspond with the experience of Boyer, Velpeau, Vidal (de Cassis), Chelius, B. Cooper, Guthrie, Gibson, and some others, who declare that the dislocation backward is the more frequent of the two. Indeed, I ought to say of two of the examples of backward dislocation of the radius which have come under my notice, and which I have marked as simple, that they were ancient dislocations; and I am not entirely certain, therefore, that they had not been originally complicated with a fracture, although at the time of my examination they presented no such evidence. The third, which I believe to have been a genuine, simple backward dislocation, I will mention again in connection with this latter form of dislocation. I have seen one congenital dislocation of the radius outward and forward, which I will describe more particularly in the chapter on Congenital Dislocations.

§ 1. Dislocations of the Head of the Radius Forward.

Causes.—A fall upon the elbow, the blow being received directly upon the posterior face of the head of the radius; a fall upon the hand with the forearm extended and pronated; extreme pronation of the forearm; or, according to Denucé, a blow upon the inside of the elbow, which is equivalent to a violent adduction of the forearm.

In children, and especially in those of a strumous habit, whose ligaments are feeble, a subluxation forward, or even a complete dislocation, is occasionally produced by being lifted suddenly from the floor by the hand, or by an attempt to sustain the child when he is about to fall. I have seen examples of this dislocation produced in this way.

Batchelder,¹ Sylvester,² Goyrand,³ and many other surgeons, have mentioned similar cases. In the case of Lydia Merton, four years old, the dislocation was caused by holding on by the hands after having fallen from a swing. Dr. Krackowizer related a case of complete dislocation forward, produced, as was supposed, in the act of turning the child in delivery. The arm was ecchymosed, and the dislocation was very distinct.⁴ Leisrinck⁵ saw an ancient dislocation forward in both arms, which were said to have been produced immediately after birth by violent torsion of the forearms, practised for the purpose of resuscitating the child.

¹ Batchelder, New York Journ. Med., May, 1856, p. 333.

² Sylvester, Amer. Journ. Med. Sci., vol. xxxi. p. 206, Jan. 1843.

³ Goyrand, Ibid., vol. xxxii. p. 228, July, 1843.

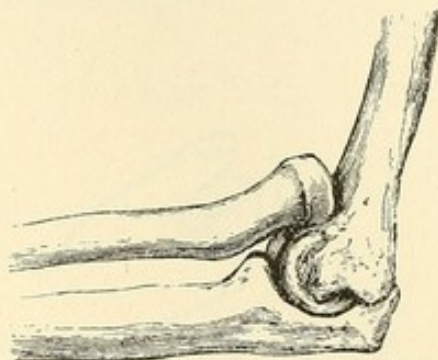
⁴ Krackowizer, New York Journ. Med., March, 1857, p. 262.

⁵ Leisrinck, Deuts. Zeitschrift für Chir., Dec. 12, 1873.

Pathological Anatomy.—The head of the radius is carried forward upon the humerus, and generally a little outward. In the case of Lydia Merton, already mentioned, the head of the radius, on the ninety-fourth day after the accident, was nearly in the centre of the humerus. The anterior and external lateral ligaments, with the annular, are in most cases more or less broken. Sometimes the anterior and external lateral are alone broken, the annular ligament being then sufficiently stretched to allow of the complete dislocation; or the anterior and annular having given way, the external lateral may remain intact.

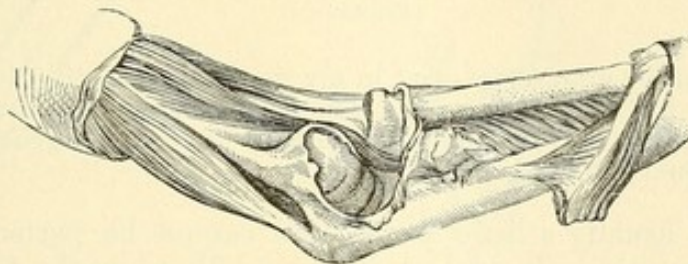
In the specimens dissected by Danyau¹ and Debruyne,² and also in the specimen deposited by Prestat³ in the Dupuytren Museum, the annular ligament was not torn. In a specimen obtained by J. Hilton,⁴ this ligament was only partially torn (Fig. 391), and the head of the radius had formed for itself a new socket on the front of the humerus. The same is

FIG. 390.



Position of the head of the radius dislocated forward. The head of the radius rests on the anterior surface of the humerus, in the hollow above the external condyle, in front of the external condyloid ridge. (Pick.)

FIG. 391.



Dissection of a dislocation of head of radius forward. (Hilton.)

the fact in a specimen represented by Kronlein, and contained in the Pathological Museum at Zurich, so that the movements of pronation and supination were completely restored.

Symptoms.—The head of the radius can in general be distinctly felt in its new situation, rotating under the finger when the hand is pronated and supinated; we may sometimes also recognize a depression corresponding to its natural situation, behind and below the little head of the humerus.

[Erichsen says that the forearm is slightly flexed and in a mid-state between pronation and supination. (Fig. 392.) The hand and arm can be fully pronated, but cannot be supinated more than half. The whole of the outer side of the arm is deformed, being carried somewhat upward. (Fig. 393.)]

The external border of the forearm is slightly shortened, and the arm inclines unnaturally outward. The tendon of the biceps is relaxed. The

¹ Poincet, op. cit., p. 885.

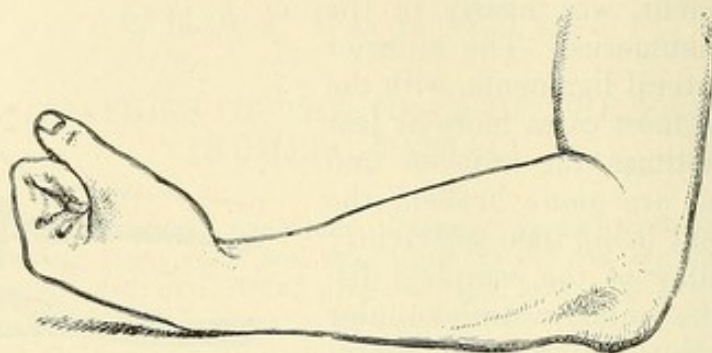
² Ibid.

³ Ibid.

⁴ Hilton, Bull. Gén. de Thérap., t. xxxviii., 1850, p. 113.

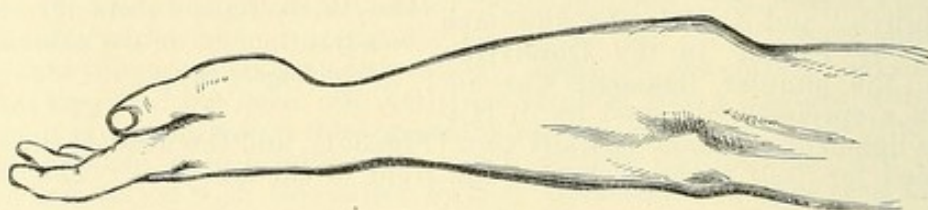
forearm is generally pronated, sometimes it is in a position midway between supination and pronation, but I have never seen it supinated.

FIG. 392.



Dislocation of the head of the radius forward; limit of flexion at elbow. (Erichsen.)

FIG. 393.



Dislocation of the head of the radius; deformity of outer side of the arm when extended. (Erichsen.)

I have particularly noticed this fact in my report made to the New York State Medical Society in 1855; and Denucé, who has also examined these cases carefully, affirms that it is seldom supinated, notwithstanding the general statements of surgeons to the contrary.

The arm is usually a little flexed, and cannot be perfectly extended without causing pain. In some cases, especially when the dislocation has existed for a considerable length of time, the arm is capable of extreme and unnatural extension. This was the case with Lydia Merton. There is usually preternatural lateral motion; but, except in old cases, the forearm cannot be flexed upon the arm beyond a right angle.

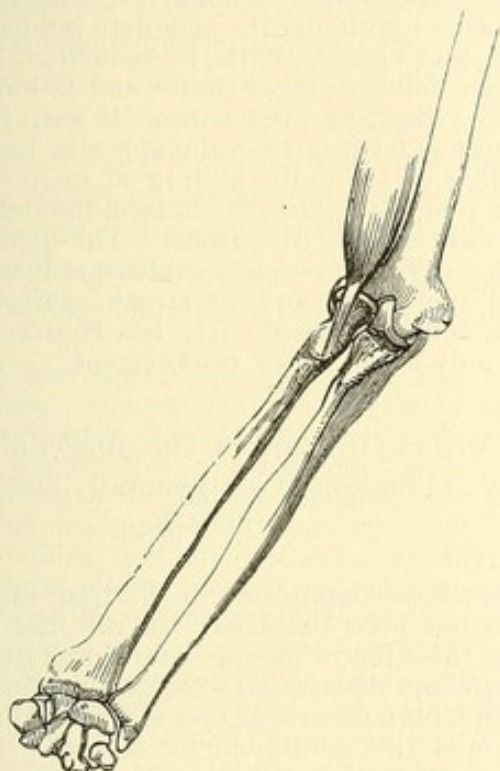
Prognosis.—Denucé says: “The reduction is often impossible; more frequently still, difficult to maintain.” In proof of which he refers to the observations of Danyau and Robert. In the case of recent dislocation related by Robert, it was found impossible to maintain a reduction which he thought he had several times accomplished, and he believed that the difficulty consisted in a portion of the torn annular ligament having become entangled between the head of the radius and the condyle of the humerus.¹ Sir Astley Cooper was unable to accomplish the reduction in two recent cases; and of the six cases which came under his immediate observation, only two were ever reduced.

Malgaigne says that in a collection of twenty-five cases which he has made, the accident was unrecognized or neglected in six, and ineffectual efforts at reduction had been made in eleven; so that only eight of the whole number

¹ Mémoires sur les Luxations du Coude, par Paul Denucé. Paris, 1854.

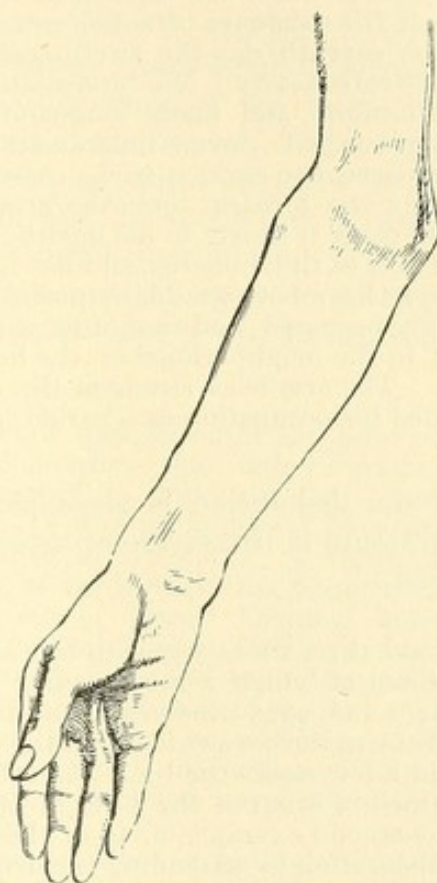were reduced. I have myself met with six of these simple dislocations which were not reduced, three of which, however, had not been recognized, and no attempt at reduction had ever been made; one had been treated by an empiric, Sweet, a "natural bone-setter," but without success; one had been reduced, but it had become redislocated, and in the remaining example I was unable to reduce the dislocation on the seventh day.

FIG. 394.



Head of the radius forward. Anatomical relations.

FIG. 395.



Head of the radius forward. External appearance of limb.

The following are brief notes of four of these cases:

In a man, *æt.* 23, the accident had occurred about one year before. The surgeon did not recognize the dislocation, and no attempt had ever been made to replace the bones. The forearm was forcibly pronated and could not be supinated, but he could extend it completely, and flex it somewhat beyond a right angle. It was strong, and nearly as useful as before. H. H. B., *æt.* 6; dislocation produced by a fall upon the elbow. The surgeon did not detect the nature of the injury. Eighteen years after, I found the head of the radius lying in front of the old socket, having formed a new socket, in which it moved freely. From the elbow to the hand the arm inclined outward, or to the radial side; pronation and supination were perfect. He could flex the arm to an acute angle, but not so completely as the other. The arm was as strong as the other, but it was frequently hurt by lifting. A lad, *æt.* 12, had a dislocation of the head of the radius forward. Thirty-nine years after he could not flex the forearm upon the arm beyond a right angle; and when the attempt was made, the radius struck against the humerus. Complete supination was impossible. The arm was as strong as the other, except in raising a weight above his head. Occasionally he was annoyed with slight pains in this limb. U. L., *æt.* 48, was thrown from a carriage, producing a dislocation of the right radius, and severely bruising the elbow-joint. He did not see a surgeon until six hours had elapsed.

The elbow was then much swollen, and exquisitely tender, and L. would not permit much, if any, examination to determine its condition. The doctor applied simple dressings, and the next day requested me to see him. The whole arm was then swollen and tender, and very little examination was admissible. The dressings were, therefore, not completely removed, but only laid open sufficiently to enable us to see the joint. We suspected a forward dislocation of the head of the radius, but could not positively determine the point—the patient not permitting any kind or degree of manipulation. We decided, therefore, to wait a few days until the inflammation had somewhat abated, and then, if the existence of a dislocation was ascertained, to attempt its reduction. On the seventh day the swelling had measurably subsided, and the diagnosis became satisfactory. We immediately placed him under the complete influence of chloroform, and made long-continued and violent efforts at reduction, but without success. Severe inflammation again followed these efforts, and L. would never consent to another trial. After four years I find the bone still out. He can flex the forearm upon the arm almost as far as he can the opposite limb; he can carry it nearly to his mouth, the head of the radius sliding off upon the outer face of the humerus, and not resting plumply against it; indeed, the radius seems to have been gradually pushed outward as well as forward. The hand is forcibly pronated, and cannot be supinated. The attempt to supine produces a click in the neighborhood of the head of the radius, as if it struck against a bone. The arm is as strong as the other, and not wasted. He has constantly pursued his occupation as a barber, after only a few weeks' confinement.

If the dislocation is accompanied with a fracture of the ulna, unless the fracture is transverse or incomplete, reduction is not generally accomplished.

I have three times met with this accident thus complicated in children, in the treatment of which a much better result has been obtained. In the first example, a lad, aged nine years, had broken the ulna in its upper third and dislocated the radius forward. Both the fracture and dislocation were easily reduced, and in a few weeks the limb was sound and perfect, except that a slight fulness remained in front of the head of radius, and this continued for several years. In the second example, a lad of the same age, I reduced both the fracture and the dislocation by extending the arm from the wrist, while at the same moment pressure was made upon the head of the radius from before backward. A right-angled splint was applied and continued during a period of four weeks, being removed daily for the purpose of giving to the joint gentle, passive motion, etc. After this the arm was permitted to straighten gradually, and at the end of a month more the joint was moving freely, and with no degree of displacement at the point of fracture or dislocation.

It is quite probable that in each of the above cases the separation was not complete, although crepitus was distinct, and the displacement of the broken ends was very marked. In the following case the fracture was certainly incomplete: E. C., æt. 4, had a fracture of the ulna, two inches below its upper end, the fragments being inclined backward, while the radius was dislocated forward. Both bones were easily replaced, and the functions of the arm were soon completely restored.

Where the restoration has been promptly effected and maintained steadily, the motions of the joint are soon restored; but in one case the head of the radius has been found to play very freely and loosely after the lapse of two years, and in others it has remained slightly prominent in front, as if it was a little in advance of its socket.

Treatment.—Extension and counter-extension should be made in the direction in which we already find the limb, namely, with the forearm slightly bent upon the arm, while at the same moment the surgeon should

seize the elbow with his hands, and press the head of the radius back with his two thumbs.

Other methods will often succeed; but by this we relax the biceps, and put the parts in the best position to accomplish the reduction easily and promptly. Sir Astley directed to supine the forearm while the extension was being made from the hand, but Denucé prefers that the forearm should be in a position of pronation.

After the reduction is effected it is never safe to straighten the arm completely at once, nor indeed for some weeks; not until the ligaments have been sufficiently restored to resist the action of the biceps. The arm must, therefore, be flexed and placed in a sling, or, if the radius is disposed to become redislocated, a right-angled splint ought to be placed upon the back of the arm and forearm, and, by the aid of a compress and roller, an attempt should be made to retain it in place. Nor will it be found safe at any period to compel the arm by force to resume the straight position, since this bone, when it has once been dislocated, will for a long time be liable to dislocation.

A boy, aged about four years, had a forward dislocation of the head of the radius. The dislocation had existed several months. The father's purpose in bringing the child to me was to ascertain whether he could not claim damages for malpractice. The account which he gave was as follows: The surgeon called it a dislocation forward, and pretended to reduce it. A right-angled splint was applied with a roller. At the end of three weeks the father removed the splint, but did not discover anything out of place. Finding, however, that the elbow was stiff, he took measures to straighten it forcibly. In a few days he discovered the head of the bone out of place, and so it has remained ever since. I explained to him that there was much reason to suppose that the surgeon had properly reduced the dislocation, and that he had himself reproduced the accident, by straightening the arm, through the action of the biceps upon the upper end of the radius. The father declined any further surgical interference, and no prosecution has followed.

The late Dr. Batchelder, of New York, has described a method of reduction suggested to him first by Dr. Goodhue, of Chester, Vt., and which he had himself found more successful than any other method; indeed, he says it never fails, yet he does not inform us in precisely how many cases he had made the trial. The plan suggested consists essentially in first making extension from the hand, and pressing at the same time downward and backward upon the head of the radius until it has descended to a level with the articulating surface of the humerus. As soon as this is accomplished, the forearm is to be suddenly flexed upon the arm in such a direction as that the hand shall pass outside of the shoulder; at the same moment, also, the pressure must be continued vigorously upon the head of the radius.¹

§ 2. Dislocations of the Head of the Radius Backward.

Denucé has collected fourteen examples of this dislocation; but Malgaigne, who rejects a portion of the cases, and adds one or two more, admits only twelve.

In addition to those mentioned by these two writers, I have found recorded, or incidentally noticed, one by May,² one by Bransby Cooper,³ one by Lawrence,⁴

¹ Goodhue, *New York Journ. of Med.*, May, 1856, p. 333.

² May, *Sir Astley Cooper on Dislocations, etc.*, by B. Cooper, op. cit., p. 403.

³ B. Cooper, *Ibid.*, p. 404.

⁴ Lawrence, *Pirrie's System of Surgery*, p. 259.

one by Liston,¹ two by Case,² two by Gibson,³ one by Parker,⁴ three by Markoe,⁵ two by Conner,⁶ one by Mack,⁷ and one by Rivington,⁸ and to these my own observations have added five more, in all thirty-three supposed examples.

Of the examples brought under my own notice I have already affirmed that two of them were accompanied with fracture, and I am not certain but that all except one were. Markoe, of New York, who reported three cases, found in each a fracture of the internal condyle of the humerus, and, after an examination of a number of the reported examples, he does not find any evidence that this dislocation ever occurs as a simple uncomplicated accident. It seems quite certain, however, that the backward dislocation does so occur, yet it is no doubt exceedingly rare.

The following case, brought to my notice by Dr. Berry, of Fall River, Mass., must be accepted as a genuine example, inasmuch as the mode of its occurrence seems to preclude a fracture: "Frederick Kuger, of New York, was seen by me when he was fifteen years old, having a dislocation of the head of the left radius backward, which the mother stated was caused by a convulsion when he was one year old. The button-like head of the radius could be distinctly felt, and there was no evidence of any other injury."⁹

Dr. N. K. Freeman, of this city, reports one of the few cases which seems to admit of but very little doubt. A gentleman, æt. 37, by jumping from the railroad cars received a backward dislocation of the head of the radius of the right arm. "The symptoms," says Dr. F., "were marked; the hand and forearm were prone, and the attempt to place them in the supine position caused great pain; while the head of the radius formed a considerable projection posterior to the external condyle of the humerus, where the cavity on its extremity could be distinctly felt. Assisted by Dr. Walsh, who firmly grasped the humerus, I was enabled to reduce it by extending the forearm and flexing it upon the arm, at the same time pronating the hand, and pressing forward the head of the radius with my thumb. After the reduction was effected, I requested Dr. Walsh to examine it; when upon slight extension being made upon the forearm, with supination of the hand, the bone was again dislocated. I immediately reduced it in the same manner as before, and directed the patient to keep the forearm flexed and the hand prone, and, laying it upon a pillow, apply cold water. He complained of severe pain for two days, which gradually subsided, and on the fourth day he was able to move and extend the forearm."

Causes.—The usual causes are, a direct blow upon the front and upper part of the radius; a fall upon the elbow, or upon the hand; a violent effort to supinate the forearm while it is grasped and held firmly in a state of pronation; and probably it is sometimes occasioned by a twisting of the arm in machinery, etc.

[The precise action of the forces by which this dislocation is produced is not yet determined. Experimentally it has been found by Barros¹⁰ that it may be produced in children by a direct blow upon the head of the bone from the front and by violent extension of the hand, pronated, with sudden flexion of the forearm. This force caused a rupture of the posterior part of the lateral ligament, which

¹ Liston, *Practical Surgery*, p. 88.

² Case, *Amer. Journ. of Med. Sci.*, vol. vi. p. 254, from 11th No. of *Provincial Med. Gazette*.

³ Gibson, *Institutes and Practice of Surgery*, 6th ed., vol. i. p. 379.

⁴ Parker, *New York Journ. of Med.*, March, 1852, p. 188.

⁵ Markoe, *Ibid.*, May, 1855, p. 382.

⁶ P. S. Conner, *The Clinic*, Aug. 15, 1874.

⁷ G. J. Mack, *The Med. Record*, Dec. 2, 1876, p. 779.

⁸ Rivington, *Lond. Hosp., Lancet*, Dec. 27, 1879.

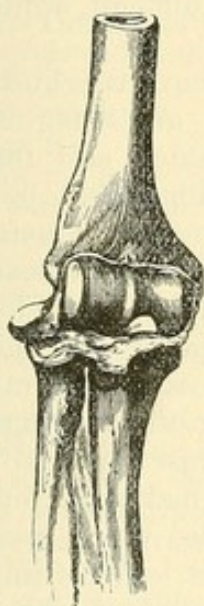
⁹ Berry, *New York Med. Gaz.*, vol. vii. No. 6, Feb. 7, 1880.

¹⁰ Barros, *Centralblatt für Chirurgie*, 1886.

seemed to be necessary to the dislocation. Streubel¹ employed hyperextension of the forearm while supinated, with forcible flexion upward and to the radial side. Cameron reports a case in which a man had a dislocation caused by the pressure of a cart upon the hand while the elbow rested against a wall. These various conditions may all be explained, probably, by the supposition that the lateral ligament is first torn, and then, by a twisting force, with flexion, the partially-liberated head is thrown backward.]

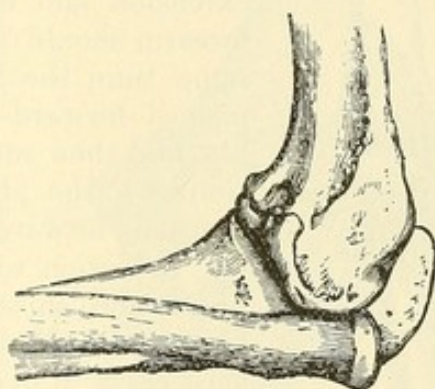
Pathological Anatomy.—In the case reported by Sir Astley Cooper, in which a dissection was made, "the coronary ligament was found to be torn through at its forepart, and the oblique had given way. The capsular ligament was partially torn, and the head would have receded much

FIG. 396.



Dislocation of the head of the radius backward; front view.

FIG. 397.



Dislocation of the head of radius backward; radial side.

more, had it not been supported by the fascia which extends over the muscles of the forearm." The head of the radius was thrown behind the external condyle of the humerus, and rather to the outer side. This was an ancient dislocation found in the dissecting-room of St. Thomas's Hospital, and the accompanying drawing is copied from the sketch made at the time.

Two specimens have been presented to the Anatomical Society of Paris of complete ancient dislocation backward, one by Guion² and one by Petit.³ In Guion's specimen the man was at the time of his death about fifty years old, and the ligamentous apparatus of the joint seemed to be untorn; a fact which might easily be explained by supposing that in the great lapse of time since the accident it may have been reconstructed. The same was the fact in Petit's case, and probably admits of the same explanation. The accident had happened in childhood, and death occurred when the patient was twenty-eight years old. Osteophytes existed to a considerable extent, and the trochlear surface of the humerus was notably deformed.

¹ Streubel, Prag. Vierteljahrschrift, 1850.

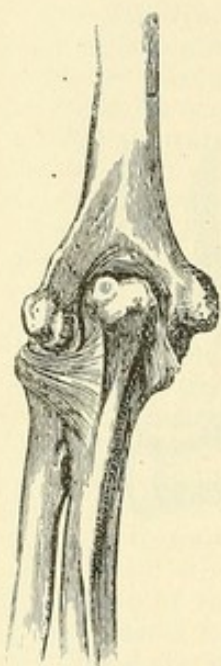² Guion, Bull. Soc. Anat. de Paris, 1859, p. 350.

³ Petit, Ibid., 1874, p. 904.

If the dislocation is not complete, as occasionally happens with children, the annular ligament may not be torn. In such examples the projection of the head of the radius may not be easily recognized, but the motions of flexion and rotation would be impaired. The reduction is sometimes effected spontaneously, or with slight manipulation. In some cases, however, the reduction is difficult or impossible, owing perhaps to the slipping of the annular ligament over the head of the bone, or to some other inter-articular complication.

Symptoms.—The head of the bone is felt rotating behind the outer condyle, and a depression exists corresponding to its original position.

FIG. 398.



Dislocation of the head of the radius backward.

The forearm is slightly flexed and prone; and the whole arm is deflected outward from the elbow downward; flexion and extension are difficult, while supination is impossible.

Treatment.—Most surgeons have taught that while extension and counter-extension are being made, the forearm should be forcibly supinated, and that at the same time the head of the radius must be strongly pushed forward. Martin recommends to extend forcibly, and then suddenly flex the arm; in a manner very similar to the plan recommended by Batchelder in dislocations forward. In Dr. Freeman's case, just quoted, the reduction was effected while the forearm was pronated, and supination seemed to throw it again out of place. Dr. Middleditch, in the case reported by Mack, succeeded in his first effort by making extension with the arm flexed to a right angle, while pressure was made upon the head of the radius. According to Markoe, where the accident is complicated with a fracture of the inner condyle, when the reduction is accomplished the arm should be placed in a position about ten degrees less than a right angle, and supported by a splint with bandages, etc.

If the dislocation is simple, however, I can see no objection to its being nearly or quite extended, since in this dislocation the action of the biceps would only tend to retain the head of the radius in place.

§ 3. Dislocations of the Head of the Radius Outward.

Denucé has collected four examples of this accident, unaccompanied with a fracture, and he proceeds to speak of it as a distinct form of dislocation. In two of the examples, however, mentioned by him, it was consecutive upon a forward dislocation, and I have several times seen the head of the radius very much inclined outward in what are properly termed forward dislocations. For these reasons it is not very plain to me that we ought to consider this as a distinct form of primary dislocation; but it would seem that we ought rather to regard it as a consecutive dislocation, or at least as only a modification of the forward or backward dislocation. Indeed, I think the radius never will be found

thrown directly outward, but always in a direction inclining forward or backward.

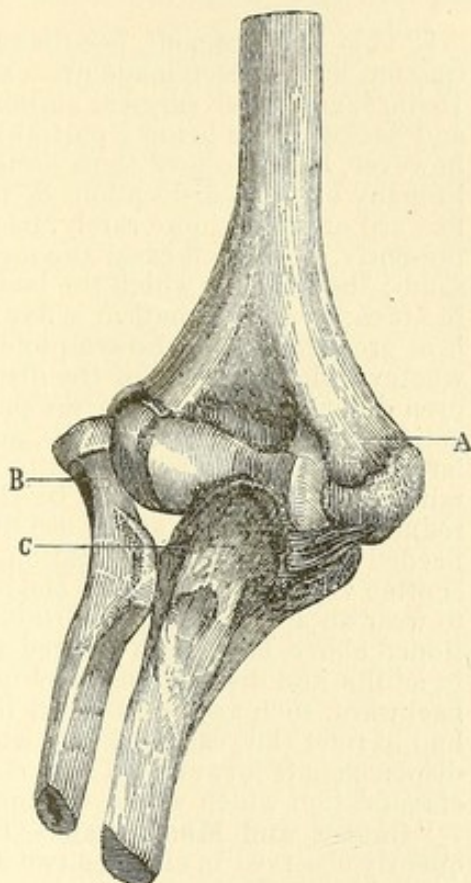
Parker, of this city, mentions a case which came under his notice, in a child four years old, who, six weeks before, had fallen down stairs "backwardly, with the right arm twisted behind the back, in such a position that the whole weight of her body came upon her arm." No attempt was ever made to reduce the bone, and the head of the radius continued to project externally. By pressure it was easily reduced, but became immediately displaced when the forearm was either flexed or extended. The motions of the joint were completely restored. Dr. Parker recommended no treatment.¹

[The following is a summary of the more important facts in cases not mentioned in the text: In Thomassen's case "the head of the radius projected at the top of the convex border of the forearm, pressing outward the mass of the supinator and radial muscles which cover it;" in Chedieu's case "the head of the radius projected at the outer and upper part of the forearm, rising higher than the external condyle." Nélaton illustrated his case (Fig. 402); it occurred in childhood and had existed twenty years. Gerdy found in his case the head of the radius projecting considerably outside of the epicondyle. Von Pitha's patient was a girl, æt. 9; a servant stepped with her heel upon the elbow while the arm lay on the floor extended and supinated; the head of the radius lay on the outer surface of the condyle. Broca's case was a girl, æt. 11; the head of the radius lay external to the condyle very superficial and movable. Wagner reports three cases, as follows: 1. A boy, æt. 18, while pushing a wagon with the forearm pronated and flexed was struck on the elbow; one year later flexion, extension, and rotation were almost entirely lost; excision of the head restored in some degree the usefulness of the joint. 2. Man, æt. 26, same cause; reduction effected with difficulty; five months after, joint so firm that excision was performed; no improvement. 3. Man, who was injured, when six years old, by a fall; movements of joint normal; head of radius outside of the external condyle. Töbken reports two cases, with fracture of the head, treated by excision. Bartels reports a double displacement in a man, due to the practice, when a boy, of pushing a loaded cart before him.]

Poinsot, in a note to the French edition of this treatise, has seen fit to recognize these partial dislocations forward or backward, when occasioned in childhood by lifting the body by the arms, as a distinct variety of radial dislocations, or, as he has designated them, "dislocations of the head of the radius downward (by elongation)." The grounds upon which he bases these distinctions are ingenious and specious, but they do not seem to me satisfactory.

¹ Parker, New York Journ. Med., March, 1852, p. 189.

FIG. 399.



Nélaton's case of dislocation of the head of the radius outward.

§ 4. Dislocation of the Head of the Radius Downward (by Elongation).

[There is a form of injury at the elbow-joint frequently noticed in children. It more often occurs when the child is lifted by the hand and has been variously explained by writers. The following very full discussion of the subject under the above title, by Dr. Poincot, the editor of the French edition of this work, embraces the more important facts relating to this accident:]

["This displacement, peculiar to childhood, and which results from violent traction having been made upon the forearm, has been described by Malgaigne, Denucé, and most surgical authors, when speaking of the dislocations forward and backward, as being a partial variety of one of those. For several reasons, however, it has seemed to us preferable to devote to it a separate paragraph; if, in many of those dislocations of infancy, the head of the radius is found either forward or, much more rarely, backward, it is nevertheless true, as we shall see presently, that in all cases the mechanism of the primitive displacement is the same; the cause by which the bone is kept in its abnormal situation is identical; in all cases the traumatism is due to a violence of the same order. The analogy is as great regarding the symptoms and the prognosis. So alike between them, whatever the direction of the displacement may be, these dislocations in children differ absolutely from the partial dislocations in the adult; the former are entirely of a benign character, and their reduction is often spontaneous; the latter, on the contrary, are apt to be irreducible, or they always necessitate certain efforts for reduction. In the first case, after the displacement is once reduced, the child is apt to use his arm as well as before, and no precaution is needed to prevent the dislocation from being reproduced; in the second case, it is often very difficult to keep the parts in place, and the patient is always obliged to wear an apparatus for a certain length of time. Therefore, the authors mentioned above have been obliged to divide partial dislocations into dislocations in adults and dislocations in children, and, again, when coming to dislocations backward, such as are observed in the latter, in order to avoid repetition, they had to refer the reader back to what they had said when speaking of analogous displacements forward. Those reasons seem to us amply sufficient to justify the classification which we have adopted.

Causes and Mechanism.—The dislocation downward has been most frequently observed in children two or three years of age; after six years it becomes exceptional. Bourguet, however, met with an example of it in a child thirteen and a half years old.¹ Again, Dugès has met with it in a newly-born infant,² and Malgaigne in children still nursing. At all events, certain subjects seem predisposed to this accident; thus, in two cases, Perrin has seen the displacement take place in both forearms simultaneously or successively with a persistent tendency to its recurrence.³ The immediate cause, noted in the immense majority of cases, is a traction, *with or without torsion*, made upon the hand or forearm, such as in the act of lifting a child to make him pass over an obstacle or to prevent him from falling or in trying to force his hand through a sleeve that is too narrow. Rendu⁴ and Descamps⁵ have observed the dislocation downward in children who had been made to jump, as an amusement, while being held by the hands.

"The mechanism of these dislocations in children has been variously understood by authors. Fournier, and, with him, Duverney, Jr., had admitted an elongation of the radius by stretching of the ligaments; but, being devoid of any anatomical proof, this theory was forgotten before long. The articular

¹ Bourguet, d'Aix, *Revue Médico-Chirurgicale*, 1854, t. xv. p. 288.

² Dugès, *Journal Hebdomadaire de Médecine*, 1831, t. iv. p. 197.

³ Perrin, *Journal de Chirurgie de Malgaigne*, t. i. p. 136; *Revue Médico-Chirurgicale*, t. v. p. 146.

⁴ Rendu, *Gazette Médicale de Paris*, 1841, p. 301.

⁵ Descamps, *Luxation Incomplète des Enfants*, Th. de Paris, 1876.

displacement being most often very difficult to establish, it was preferred to deny its existence. Gardner¹ and Rendu maintained that the characteristic difficulty in movements of the forearm was due to a hooking of the bicipital tuberosity by the external border of the ulna, and Bourguet, in addition to that, supposes that there are muscular fibres of the supinator brevis interposed between the two bones. The editor of the *Medico-chirurgical Review* has thought of an epiphyseal separation.² Goyrand, observing that the interosseous space was too large to allow the hooking of the tuberosity of the radius, admitted at first that the head of that bone was displaced forward by the biceps, and was fixed in that position, against the inferior extremity of the humerus, by the contraction of the other muscles; but, later on, he abandoned this first opinion and denied that the radius had any participation in the traumatism in question, seeing in the latter only a subluxation of the inter-articular cartilage of the wrist upon the inferior extremity of the ulna.³ Perrin finally came back to the idea, already enunciated by Duverney, of a displacement downward, and, in order to explain its persistency, he supposed that the edge of the radial cup was pressing against the condyle. Each one of those theories was liable to palpable objections; we have seen Goyrand criticise very justly the theory of hooking; the one in which muscular contraction intervenes in order to pull and fix the radius forward implies a flexion of the forearm, and especially a muscular rigidity which are far from being constant. The localization of lesions at the elbow cannot be disputed; as to the epiphyseal separation, it has yet to be confirmed, not only anatomically, but also clinically. Finally, the mode of displacement admitted by Perrin would necessarily require a lowering of the radius to the extent of eight or nine millimetres, which would consequently be very difficult to discover, since it is often impossible to establish the least change of relations between the bones.

"Thus stood the question when M. Pingaud, resuming some experiments formerly made by Streubel, threw an entirely new light upon it. Streubel, while regarding the partial displacement of the radius forward as the characteristic anatomico-pathological feature of the dislocation of childhood, and while considering the movement of torsion of the forearm as the principal factor in the production of this accident, had noticed that the fixedness of the bone in its abnormal position was due to the interposition of a portion of the capsule and of the annular ligament.⁴ The results of M. Pingaud's experiments were also to demonstrate beyond doubt interposition of the capsule, while establishing, contrary to Streubel, that the displacement of the radius downward, its elongation, to use Duverney's expression, constitute the primitive displacement. 'If,' says M. Pingaud, 'we examine what is going on toward the humero-radial articulation, when the wrist and the hand of the little cadaver are carried into a state of forced adduction, so as to pull the radius from below, a noticeable separation is seen to take place over the articular interline, and the atmospheric pressure drives and depresses the integuments toward the interior of the articulation. So soon as the traction is abandoned, the radius reascends and resumes its place. In this manner the radius may be made to move back and forth in a parallel direction to the ulna and without any great effort.

"If the traction is suddenly carried somewhat further, a slight click is heard, and then the following facts are witnessed: 1. The moment traction is abandoned, the radius does not go up so easily nor so high as it did previously, and a line of depression, perfectly appreciable to the eye and to the finger, is seen to separate its head from the articular condyle. 2. The head, however, is in its place under the condyle, inasmuch as it does not project abnormally either forward, backward, or outward. 3. The movements of rotation of the hand, especially that of supination, are not so free as before; in a word, there is *somewhere* a slight but perfectly appreciable obstacle to the regular performance of those movements. 4. Finally, these movements of rotation cause a slight displacement of the head of the radius in front of the condyle when pronation is slightly forced.

¹ Gardner, *Gaz. Méd. de Paris*, Oct. 21, 1837, p. 664.

² *Medico-chirurgical Review*, 1839.

³ Goyrand, *Annales de la Chirurgie*, 1842, t. v. p. 129.

⁴ Streubel, *Prager Vierteljahrsschrift*, 1850, Bd. i. u. ii.

"If the parts be dissected, they are found in the following condition: No tearing of muscle or ligament can be perceived at the humero-radial articulation, but there is seen a small segment of the radial cup completely uncovered by the annular ligament, which has moved upward only in front. It is evident that the narrow fibrous ring which, in a physiological condition, terminates the annular ligament below and surrounds the neck of the radius, has, owing to its elasticity during youth, been gradually stretched by the lowering of the head of the bone, and that it has gradually slipped above it, at the point only where it is not adherent to the deep surface of the muscles covering it, and where the bony cylinder representing the head of the radius offers so little prominence in the child as to be reduced, so to speak, to a simple border."

"If, then, the forearm be placed in a state of pronation, a larger portion of the radial cup is seen to emerge from below the annular ligament, and to such an extent that, at the extreme, it might be entirely disengaged from under it, and the head of the radius might be entirely dislocated forward; but the latter displacement is always secondary, and the first stage of the accident now under our consideration consists in the displacement of the head downward.¹ Such is, therefore, the mechanism of the subluxation in all the rather numerous cases where the head is found slightly displaced forward; but it could not be applied to the cases where an opposite displacement is observed—viz.: that of the head backward. M. Pingaud has remained almost silent on this latter point, but an experiment of Streubel will help us to solve the difficulty; indeed, Streubel remarked that, if a sudden movement of extension and supination be applied to the forearm of a young subject, the head of the radius is plainly felt being displaced backward. If the same experiment be repeated after having removed the skin and the muscles covering the articulation, the posterior portion of the capsule and of the annular ligament may be seen to be highly distended, while at the same time a depression of more or less depth is produced at the anterior portion, the atmospheric pressure determining at that point the interposition of the corresponding portion of the capsule. Here, again, a primitive displacement downward is necessary to allow the separation of the bones and the interposition of the ligaments, the movement of supination intervening only to determine the direction of the secondary antero-posterior displacement."

"To sum up regarding the partial dislocation in children: 1. The primitive displacement, resulting always from a traction applied in the direction of the axis of the radius, consists essentially in a lowering of that bone which allows the interposition of the capsule and of the annular ligament. 2. The movement of torsion of the forearm has influence only upon the secondary displacement, in order to determine its direction antero-posteriorly."

Symptoms.—At the time of the accident, the person holding the child by the hand can generally perceive a cracking in the joint. At the same time the child experiences in the elbow a very sharp pain, which he manifests by his cries, and the limb is seen to be powerless; it falls inert, generally flexed one-quarter, and in a position midway between pronation and half-pronation. In a few exceptional cases, however, almost complete extension and supination of the forearm have been met with. The deformity is ordinarily very slight; Bourguet had called attention to an increase of the antero-posterior diameter of the elbow which has not been confirmed by the other observers. Is is pretty rare, notwithstanding Malgaigne's statement, to see a prominence of the head of the radius in front; the prominence behind is scarcely ever observed. The symptoms of the partial dislocation in children are, as may be seen, pretty vague; those that may be considered as characteristic are the inertia of the limb and the impossibility to give the forearm the necessary movement of torsion in order to bring it back in the opposite position to that in which it is found (movement of supination if, as is generally the case, the forearm is found in pronation, and *vice versa*).

Prognosis.—Left to itself, that dislocation gets well almost always, and often there is no time even to consult the surgeon. My brother, then two years and a half old, experienced an accident of this kind; he had been made to jump

¹ Pingaud, art. "Coude," in Dict. Encyclopédique des Sci. Med., 1re série, t. xxi. p. 581.

over a gutter by being lifted by the hand. Before the family physician could arrive, the displacement was reduced by means of a few frictions applied at the bend of the elbow, and, probably, also of a few attempts at extension of the forearm; the symptoms disappearing at once. Nevertheless, that spontaneous reduction may be tardy, and it is better to act without delay.

Treatment.—The different modes of reduction indicated in the case of complete dislocations are applicable in this instance. Generally, when the forearm is in a state of pronation, it is sufficient, during extension, to bring back by force the limb into supination, and then to flex it suddenly. If the forearm is in a state of supination, it will be necessary, after having exaggerated the extension, to put the limb in pronation, but without flexing it. In case some displacement of the radius should be noticed, it would be well to add to these manœuvres a certain amount of pressure upon the head of the radius in the direction of the condyle of the humerus.”]

CHAPTER IX.

DISLOCATIONS OF THE UPPER END OF THE ULNA (HUMERO-ULNAR).

§ 1. Dislocations Backward.

THIS accident, the existence of which, as a simple dislocation, is placed beyond doubt, has nevertheless been described so variously, and often indefinitely, that it is impossible to declare its history, except in a few points, with any degree of accuracy. No doubt, many of the cases which have been reported were examples only of a subluxation of both radius and ulna backward. In other cases, the radius or the external condyle of the humerus being broken, the ulna has been actually displaced, not only backward, but upward; indeed, it is very certain that without either dislocation of the radius or a fracture with displacement of the external condyle of the humerus or a fracture or bending of the radius, an upward displacement of the ulna, to the degree represented by the reporters of these cases, could never have occurred.

The example mentioned by Sir Astley Cooper, and of which a dissection was made, is plainly a case of subluxation of both bones; or if the dislocation of the ulna may be regarded as having been complete, the head of the radius was also displaced more or less upward from its original socket; a new socket, Sir Astley himself informs us, having been formed for its reception, upon the external condyle. But this is the only example the actual condition of which has been proven by an autopsy.

Nevertheless, it seems certain that a simple dislocation or subluxation of the ulna backward may occur without either of the above-mentioned complications, and that, to the extent of a few lines, it may be made to pass upward upon the back of the humerus, by the falling of the forearm to the ulnar side; in which case the character of the accident would probably be recognized by the projection of the olecranon process, while the head of the radius might be felt moving in its socket; by the partial

flexion and complete pronation of the forearm, and by the general immobility of the joint.

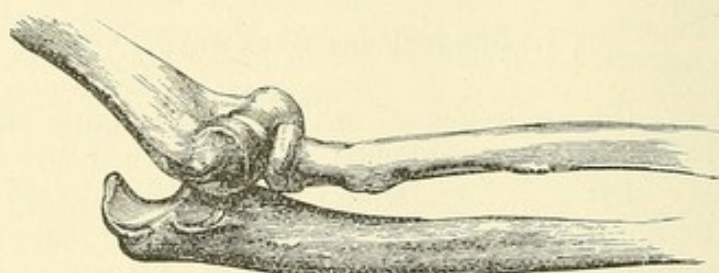
In a case reported by Dr. Waterman, caused by a fall on the hand, the arm was at a right angle, and pronated.¹

[Three forms of dislocation are now recognized, though they are but varieties depending upon the kind and amount of violence: 1. The coronoid process may merely have passed backward over the trochlea; 2. Or it may have gone farther and lodged in the olecranon fossa; 3. Or the olecranon may be thrown behind the radius. The diagnosis of these varieties depends upon an examination and correct appreciation as to the position of the head of the radius, which is not disturbed, and of the olecranon process, which projects posteriorly more or less, or laterally, according to the variety.]

Treatment.—Its reduction ought to be accomplished easily by the same measures which have been found successful in reducing a dislocation of both bones backward; but in Waterman's case this method failed, and the reduction was promptly effected by bending the forearm forcibly back.

Pirrie says that in a case occurring in the practice of Mr. Gosset, in which the coronoid process rested on the internal condyle, and the pain on bending

FIG. 400.



Dislocation of the upper end of the ulna backward.

the arm was insupportable, owing, it was supposed, to the pressure of the coronoid process against the ulnar nerve, "reduction was accomplished by extension and counter-extension applied by two persons pulling in opposite directions, and by the pressure of the olecranon process downward and outward, while the forearm was suddenly flexed."² Rosner³ employed with success the same procedure in a case of incomplete dislocation, which had existed eight months in a boy, æt. 18.

[Scott, of Bath, reports⁴ a case of dislocation of the ulna backward and of the radius forward, in a man æt. 46. The patient was thrown over the head of a horse while riding rapidly and struck on his hands. The arm was almost straight, the prominences of the external and internal condyles had disappeared; the olecranon was about one and a half inches above the condyles; there was a sulcus on each side of the triceps; the head of the radius could not be felt behind the elbow. The dislocated ulna was easily reduced by the knee in the bend of the elbow, but the forearm could not be fully flexed. The head of the radius could not be readily felt resting on the anterior surface of the external condyle. With the knee again in the bend of the elbow pressure was made at the same time that flexion was gradually induced and pressure was made upon the head of the radius. Reduction of both bones was thus effected.]

¹ Waterman, Boston Med. and Surg. Journ., vol. iv., new series.

² Gosset, Pirrie's Surg., Amer. ed., p. 259.

³ Rosner, Wiener Allgem. med. Zeitung, 1875, No. 32.

⁴ British Medical Journal, 1886.

§ 2. Dislocations Inward.

Dr. George Wright, of Toronto,¹ reported an example in a girl nine years old, of dislocation inward of the upper extremity of the ulna, the head of the radius remaining in place, caused, as was supposed, by a fall upon the elbow.

Dr. Wright saw the patient the same day and recognized the dislocation, but as some of the surgeons who saw the case expressed a doubt as to the character of the accident, no attempt at reduction was made. Twenty-eight days after the accident "a careful examination was made by almost all the members of the staff, and accurate measurements between the bony prominences were taken, and all agreed that there was dislocation inward of the olecranon process upon the inner condyle of the humerus, the head of the radius remaining in its normal position. There was no pain or swelling; all the motions of the arm were perfect; but the patient was unable to sustain any weight upon the arm in extension by reason of the tendency to rotate inward, and the 'carrying power' was lost. I attempted reduction under anæsthetics, but after an hour and a half's effort by myself and all the gentlemen present, and by every means suggested by the best authorities, we failed to reduce the dislocation. The arm was put in an elevated easy position, with patient in bed, cold water applied, and not a single bad symptom followed this somewhat violent manipulation. The friends refused to allow any further attempts at reduction."

In explanation of the peculiarity of the displacement, Dr. Wright states that there existed a congenital laxity of the ligaments of all the joints, and that "when the child was two years of age she received an injury to this same elbow which caused the separation of this epiphysis, the external condyle being broken off, and it may be that this accident left a condition in the joint which favored the possibility of the inward displacement of the upper extremity of the ulna without carrying the radius with it."

CHAPTER X.

DISLOCATIONS OF THE RADIUS AND ULNA (FOREARM) AT THE ELBOW-JOINT.

THE radius and ulna may be dislocated at the elbow-joint backward; laterally, that is, either inward or outward; and forward. They may also be dislocated in opposite directions.

§ 1. Dislocations of the Radius and Ulna Backward.

My records of private and hospital practice supply seventy-two cases; the youngest being four years old, and the oldest sixty-one. Twenty-nine of this number occurred in children under fourteen years of age.

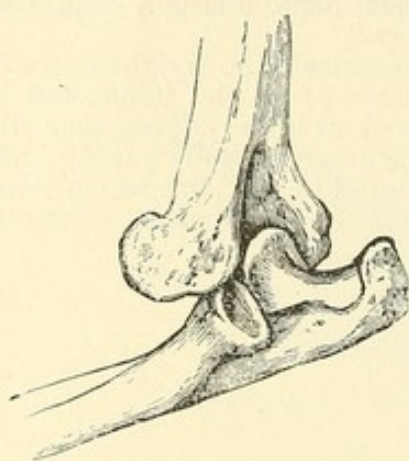
Causes.—Generally the dislocation has been produced by a fall upon the palm of the hand, as, when in running, a person has fallen forward with the forearm extended in front of the body, or he may have fallen

¹ Wright, Canadian Journ. Med. Sci., Feb. 1882.

from a height; once I have known it produced by a blow received upon the back and lower part of the humerus; and in several instances the patients have declared that they had fallen upon the elbow; it is produced occasionally by twisting the forearm violently, as when the limb has been caught and wrenched about by machinery, by a blow upon the front and upper part of the forearm, and by forced flexion.

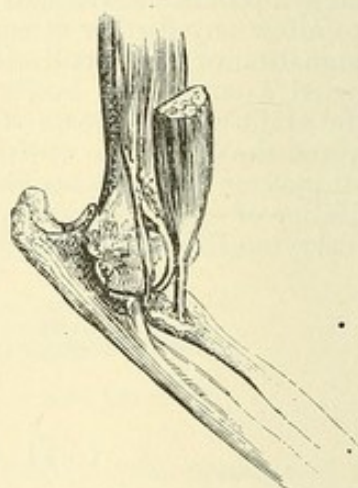
Pathological Anatomy.—The radius and ulna are not only carried backward behind the articulating surface of the humerus, but they are also, through the action of the triceps, almost always drawn more or less upward, so that often the coronoid process of the ulna rests in the olecranon fossa. In some cases it has been known to mount even higher, while in others it is arrested short of this point. The radius still retaining its relative position to the ulna, lies upon the back of the humerus, or rather upon the posterior margin of its articulating surface. The anterior and two lateral ligaments are generally more or less completely torn asunder; but the posterior ligament and the annular do not usually suffer disruption. The biceps muscle is drawn over the lower articulat-

FIG. 401.



Position of bones in dislocation of the radius and ulna backward.

FIG. 402.



Brachialis anticus and biceps muscles in dislocation of the radius and ulna backward.

ing surface of the humerus, but is in a condition of only moderate tension, while the brachialis anticus is forcibly stretched, or even torn. (Fig. 402.)

Malgaigne says the tendon of the biceps has once been found behind the humerus. The median nerve is also pressed upon in front by the humerus, and the ulnar is occasionally painfully stretched over the projecting extremity of the ulna from behind.

Symptoms.—The arm is almost constantly found only slightly flexed, or forming an angle in front of about 120° .

This fact is especially noticed in my records twenty-six times, and, if it had ever been found in any other position, it would certainly have been stated. Once, where the dislocation was accompanied with a fracture of the outer condyle of the humerus, the arm was at first straight, a position in which it is said to be found occasionally with children; and in the case of a patient admitted to Bellevue Hospital, the dislocation having existed thirty-one days, but unaccom-

panied with a fracture, I found the arm straight, and there existed also a preternatural lateral mobility of the elbow-joint; but never, in any case of a recent dislocation, and but once in an old dislocation, have I found it flexed to a right angle; yet I will not deny that such unusual phenomena are possible in recent dislocations; indeed, it is certain that they have occasionally been presented, but they must be regarded as only exceptional, and as by no means diagnostic of this accident. Sir Astley Cooper and Miller declare that in this dislocation the forearm is usually supinated; Pirrie says "the hand is between pronation and supination, but more inclined to the latter." Desault thinks it is sometimes in supination and sometimes in pronation; Denucé concludes that it will occupy that position, whatever it may be, in which the force of the blow has thrown it; while by most surgical writers no allusion is made to the position of the forearm in reference to pronation or supination. I have found the forearm and hand almost constantly in a position of moderate but positive pronation, and I am compelled to regard it, therefore, as one of the usual signs of a backward dislocation of these bones.

The limb can be neither flexed nor extended without force, and such motion is almost always accompanied with pain. It is, however, possible in most cases to give to the arm a slight lateral motion, such as does not belong to it in its natural condition. In front, and deep in the fold of the elbow, is felt the lower end of the humerus, forming a hard, broad, and somewhat irregular projection, over which the integuments and muscles are swollen, and tender to pressure. Behind, the head of the radius may be felt, when not much tumefaction exists, rotating or moving under the finger when the forearm is supinated or pronated; while the olecranon process projects strongly backward and upward. If now we flex the arm slightly, this projection of the olecranon process will be sensibly increased, but if an attempt is made to straighten the arm, it will be diminished, the reverse of what we have seen to happen in cases of fracture of the lower end of the humerus (at the base of the condyles). This circumstance becomes, therefore, an important diagnostic mark between these two accidents. The relation of the olecranon process, also, to the condyle is changed, and the upper end of this process, instead of being a little below the internal condyle, as it would be naturally when the arm is slightly flexed, is found generally carried upward toward the shoulder, from half an inch to one inch or more above the condyle. Measuring from the internal condyle to the styloid process of the ulna, the forearm is shortened; the same result will be obtained also by measuring from the acromion process to either of the styloid processes; while from the acromion process to the condyle, the length will be the same in both arms.

The signs which have now been enumerated will be sufficient to enable us to make the diagnosis promptly in the great majority of cases, but, if considerable swelling has already taken place, the diagnosis may be rendered exceedingly difficult, if not impossible; and in such cases we should confine the patient at once to his bed, and proceed to reduce the tumefaction by appropriate means as rapidly as possible, examining the limb carefully from day to day, in order that we may seize the earliest opportunity to ascertain its actual condition and to effect the reduction.

In relation to the difficulty of diagnosis in certain examples of this accident, and under certain circumstances, Mr. Skey has made some very judicious remarks: "Severe injuries of the elbow-joint, whether in the form of fracture,

dislocation, or a compound of the two, are frequently followed, at a short interval, by swelling of a formidable kind, in which it is impossible, but by the aid of a perfect intimacy with the anatomical structure of the joint, to detect the relations of one part with another; but even under this difficulty, the two points in question are readily distinguishable. In such forms of swelling, the arm, including the length of six inches both above and below the joint, may be involved in the extravasation, and this swelling may distend the arm to a circumference of one-third beyond its natural size. In such circumstances, in which it is impossible to determine with any certainty whether any, or what bones are broken, or whether or not dislocated, the difficulty of the case should at once be stated to the friends of the patient."

Prognosis.—If the dislocation is recent, reduction is in general easily effected; but if considerable time has elapsed, the reduction is often accomplished with difficulty. As to the probability of its redislocation, I have already spoken when considering the subject of fractures of the coronoid process. Unless this process is broken, it is not likely to occur except where some violence has again been applied. It has happened to me, however, to find these bones unreduced in several instances. In some of these examples surgeons recognized the accident and supposed that they had accomplished reduction, while in others the dislocation was mistaken for a fracture.

J. P., æt. 25, had a dislocation backward of both bones at the elbow-joint. A surgeon recognized the dislocation, and by pulling the arm straight forward he supposed he had reduced it; the patient also thought he felt the bones slip into place. No attempt was made subsequently to flex the arm, and it was immediately dressed with a straight splint laid along the palmar surface. On the sixth day it was found to be unreduced, and the surgeon again attempted to reduce it as before, and thought he had succeeded. The same splint was reapplied. At about the end of six weeks three surgeons placed the patient under the complete influence of chloroform, and attempted the reduction. They first made extension for half an hour in a straight line, then five men seized upon the arm and forearm, bending it with great force to a right angle. It was now believed that the ulna was reduced, but not the radius. Four days after, the attempt was renewed. Three months after the accident the young man called upon me, and I found the arm nearly straight, with almost complete ankylosis at the elbow-joint. Both the radius and ulna were displaced backward, but not upward. The arm was of the same length with the other, and the relation of the condyles to the olecranon was so manifest, that the absence of the usual displacement upward was easily determined. I was unwilling to make any further attempts at reduction, not believing that I should succeed after so much time had elapsed, and after so many ineffectual attempts had been made by clever surgeons.

In the following examples the dislocation was supposed to have been a fracture of the lower end of the humerus. A man, residing in Pittsfield, Mass., dislocated his left arm by falling from a horse. The surgeon who was called regarded it as a fracture at the base of the condyles, and treated it accordingly. Ten weeks after, the error was discovered and an attempt was made to reduce it, but without success. A second attempt was also made, with the same result. Eight months after the accident the bones were still unreduced. The forearm hung at a very obtuse angle with the arm, and there was very slight motion at the elbow-joint. I discouraged any further attempts at reduction.

Mr. W., æt. 43, fell from a load of hay, striking upon his left arm. A very intelligent young surgeon thought the humerus was broken just above the condyles. After eight weeks, the fact that it was a dislocation having become apparent, three surgeons of large experience attempted its reduction aided by pulleys and chloroform. The patient was also bled and nauseated with antimony. The efforts were protracted through many hours, and frequently varied. A second attempt made by these same gentlemen, a few days after, was equally

unsuccessful. On the ninth week, assisted by Prof. Moore, of Rochester, I renewed the attempt at reduction. The patient was placed under the influence of chloroform, and during a great portion of the time occupied the pulleys were in use. The elbow was pulled upon, twisted, flexed, and extended, until there seemed to be neither adhesions, nor ligaments, nor capsule, to prevent the reduction. We could move the joint in every direction, even laterally, as well as forward and backward. Still the bones would not return to their sockets. Section of the triceps seemed to be the only remaining expedient, but the injury already done to the joint was so great that we did not deem it prudent to prosecute the attempt any further. We had occupied two hours in the various procedures. Violent inflammation supervened, but he was able to return home in about two weeks. Two years after, I learned that the arm still remained unreduced, and nearly ankylosed; the whole limb was also much atrophied and very weak.

In at least eleven cases, according to my records, the accident has been overlooked by reputable surgeons; the injury having been supposed to be either fracture or a mere contusion. In three or four instances the accident has been overlooked by the patient himself, or by some empiric, no surgeon having been called to see the case until after the lapse of several days or weeks.

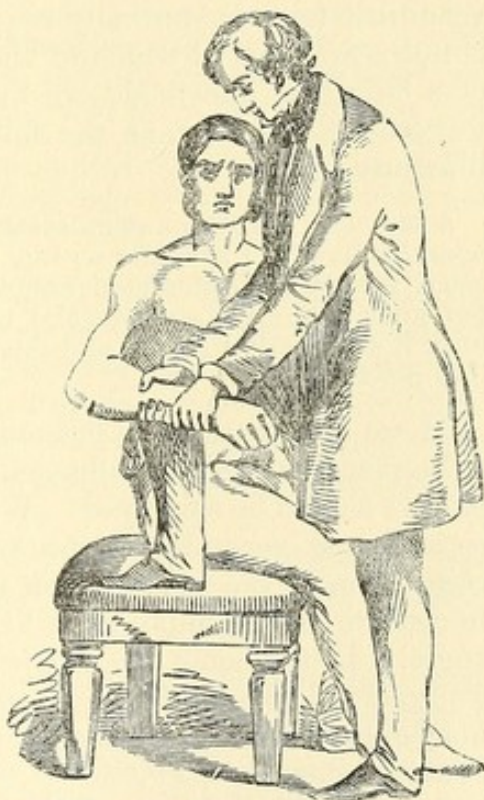
In general, when the reduction has been effected promptly, the patients have recovered the complete use of the elbow-joint within a few weeks; but many exceptions have from time to time come under my notice.

A lad 8 years old was brought to me, whose arm had been dislocated six months before, and the reduction of which had been accomplished easily and promptly by Sir Astley Cooper's method. At this time the arm was bent to a right angle, and quite stiff at the elbow-joint.

Treatment. — Sir Astley Cooper thus describes his own method of reducing this dislocation: "The patient is made to sit upon a chair, and the surgeon, placing his knee on the inner side of the elbow-joint, in the bend of the arm, takes hold of the patient's wrist, and bends the arm. At the same time he presses on the radius and ulna with his knee, so as to separate them from the os humeri, and thus the coronoid process is thrown from the posterior fossa of the humerus; and while this pressure is supported by the knee, the arm is to be forcibly but slowly bent, and the reduction is soon effected."

The plan recommended by Dorsey is nearly identical with that just described, only that, instead of the knee, he advises that the surgeon "interlock his fingers in front of the arm, just above the elbow, and draw it backward." On the other hand, Liston and Miller recommend, as a better mode of procedure, that the

FIG. 403.



Reduction with the knee in the bend of the elbow.

patient shall be seated upon a chair, and that the arm and forearm shall be pulled directly backward, so as to relax as completely as possible the triceps muscle, while counter-extension is made against the scapula. Skey says: "Extension of the forearm should be made from the hand or wrist in a straight direction downward, as if for the purpose of simply elongating the arm." Pirrie prefers that an assistant shall grasp the forearm near its middle, instead of the wrist, and pull the arm straight forward, while at the same moment the surgeon seizes upon the olecranon process with the fingers of one hand, and, placing the palm of the other against the front and upper part of the forearm, pulls forcibly backward, so as to draw out the coronoid process from the olecranon fossa. Waterman recommends forced extension; that is, bending the forearm forcibly back, as preliminary to flexion, with the view of lifting the coronoid process from the olecranon fossa.¹

Having generally practised the method recommended by Sir Astley, and having usually succeeded in the first attempt and with the employment of only moderate force, my predilections are in its favor; yet I am not certain but that an equal experience with either of the other modes recommended might have changed these convictions. In recent cases very little force is generally requisite to accomplish the reduction, and it is not very material which of these several modes we adopt; but in case of a failure by one mode, we ought immediately and without hesitation to resort to another, as the following case of a failure by flexion will illustrate:

A lad, æt. 11, fell in a gymnasium from a height of six feet, striking probably upon his hand. I saw him within twenty minutes, and found the arm in the usual position. I attempted immediately to reduce it by Sir Astley's method, but after a fair yet unsuccessful trial, I extended the forearm upon the arm until it was nearly straight, and then, with only moderate force, drew it promptly into place.

If we still continue to encounter difficulties, the patient ought at once to be placed under the influence of an anæsthetic, and, if necessary, the pulleys should be employed. When the reduction is accomplished, which is indicated generally by the sudden slipping of the bones and by the restoration of the natural form to the elbow-joint, the surgeon, in order to confirm his opinion, must flex the forearm upon the arm to a right angle. If the bones are in place, and there is not much swelling, this can generally be done without causing much, if any, pain; but if it cannot be done, this fact furnishes presumptive evidence that the reduction is not effected.

In one instance, however, of recent dislocation, this rule has not held good. A girl, æt. 10, fell from a tree upon her hand. I found the usual signs characterizing this accident. Reduction was accomplished readily by pulling at the hand moderately, with the forearm flexed, while my left hand pressed back the lower part of the humerus. After the reduction it was found impossible to flex the arm to a right angle without causing severe pain, and it became necessary, after placing it in a sling, to allow the hand to drop very low beside the body. A good deal of inflammation followed; but in a few weeks the arm was well, only that for a period of two years or more the elbow remained very tender.

On the other hand, an omission to apply this rule has often led the surgeon to believe the reduction accomplished when it was not.

¹ New Method of Reduction of the Elbow, by Thomas Waterman, M.D., Boston Med. and Surg. Journ., vol. iv. Nos. 12, 13, new series, 1869.

This has happened to me, and as it is the only instance in which I have omitted to adopt this test, and the only one also in which I have left a bone unreduced which I believed to have been reduced, it will be proper to state the case and its results more fully. A lad, *æt.* 11, dislocated both bones backward. I saw him within two hours from the occurrence of the accident. The elbow was already considerably swollen and quite tender, but the signs of dislocation were very manifest. Seizing the wrist with one hand, and placing my knee against the front and lower part of the humerus, I pulled steadily for some time, and with much more force than is usually necessary, until at length two distinct and successive snaps were felt, such as one often feels when the two bones resume their sockets. Relinquishing my grasp, it was observed by myself and the parents that the deformity had disappeared. The reduction seemed to be complete, and so I announced. I then requested the lad to permit me to bend the elbow, and place it in a sling, but this he peremptorily refused to do, and ran away from me, nor would any arguments or entreaties persuade him to allow me again to touch it. I reassured the parents and child, however, that all was right, and left the house. During several successive days I saw the little patient, but although the arm remained swollen and very tender, I did not suspect the cause until the ninth day; and on the tenth day, having placed him under the influence of chloroform, the reduction was easily and satisfactorily accomplished. The recovery was slow. As the end of six weeks I found the motions of the elbow-joint not completely restored, and the forefinger was partially paralyzed; but from this condition it gradually recovered, and two months later the functions of the arm and hand were completely restored. The mistake in this instance was the more mortifying because I had just seen a case in a lad only a little older, in which another surgeon had committed the same error, and after the lapse of twelve or fourteen days I had myself made the reduction; and I was fully awake, therefore, to the possibility of the mistake.

The circumstance of the diminution and apparent disappearance of the deformity, and the sensation of a double click, can only be explained by assuming that originally the coronoid process was resting in the olecranon fossa, and that by manipulation the bones had been removed nearer their sockets, yet not actually reduced. The swelling, also, rendered more difficult a diagnosis which, now, nothing but the flexion of the forearm could have determined positively.

If much time has elapsed since the occurrence of the dislocation, the reduction is accomplished with difficulty, if, indeed, it can be reduced at all.

There are many cases upon record, however, in which surgeons have been successful after the lapse of many weeks, or even months. Boyer thought it was not possible to effect the reduction after four or six weeks; but Cappelletti, of Trieste, succeeded after seventy days;¹ Sir Astley Cooper, at three months;² Malgaigne, after three months and twenty-one days.³ Roux succeeded in a case of a man twenty-two years of age, whose elbow had been dislocated five months.⁴ Blackman, of Cincinnati, informs me that he has reduced a lateral dislocation after five months. Brainard, of Chicago, reduced a dislocated elbow in a boy of nineteen years, after five months and thirteen days. In this case the surgeon who had first seen the patient supposed that he had reduced the dislocation.⁵ Gorre, Gerdy, and Drake succeeded in four cases after six months;⁶ I have succeeded at seven months; and Starch claims to have been successful after two years and one month.⁷ To which enumeration Denucé had added seventeen

¹ Cappelletti, *Amer. Journ. Med. Sci.*, vol. xix., from *Annal. Univ. de Méd.* for Oct. 1835.

² Sir Astley Cooper, on *Dislocations and Fractures*, *Amer. ed.*, p. 388.

³ Malgaigne, *Amer. Journ. Med. Sci.*, vol. xxiii. p. 238. from *Revue Méd.*, Dec. 1837.

⁴ Roux, *Amer. Journ. Med. Sci.*, vol. xvi. p. 526, from *Archives Gén.*, Dec. 1834.

⁵ Brainard, *Illinois and Indiana Med. Journ.*, 1847.

⁶ *Mémoire sur les Luxations de Coude*, par Paul Denucé, Paris, 1854, pp. 86, 87.

⁷ Denucé, *op. cit.*, p. 87.

other examples said to have been reduced at various periods ranging from one month to one hundred and fourteen days.¹ I have reduced a number of these old dislocations, the last five of which will be briefly recorded.

T. R., æt. 35, was admitted to Bellevue Hospital with a simple dislocation of the radius and ulna backward, which had existed thirty-one days, but which had not been recognized. I reduced it by Sir Astley's method, the patient being under the influence of ether. Considerable force was required.

J. G., æt. 7, had a backward dislocation of the right radius and ulna, which had existed nine weeks. The arm was nearly straight and fixed. Having placed him under the influence of ether, assisted by Dr. Buck, of this city, I proceeded to flex the arm slowly, and after a few seconds, and when the elbow was bent about ten or fifteen degrees, the olecranon process separated at the line of epiphyseal union. In a few moments the reduction was completed, and the arm brought to an acute angle, but the olecranon had separated fully half an inch. We were quite certain that the ulna was perfectly reduced, but the head of the radius did not seem to occupy its original position fully. Only moderate inflammation ensued. Passive motion was soon commenced, and considerable motion of the joint was finally obtained.

A gentleman, æt. 30 years, consulted me on account of a dislocation which had then existed ten weeks, and which had not been recognized by his surgeon. In attempting to reduce the dislocation I fractured the olecranon, and brought the ulna into position, but I could not reduce the radius. Almost complete ankylosis of the elbow remains. A man was brought to me whose elbow had been dislocated eight weeks. Under ether, I succeeded in reducing the dislocation, but fractured the olecranon process in doing so. He has recovered very good use of the joint. I reduced the dislocation in the case of a woman, æt. 37 years, which had existed since a little more than seven months. I have seen her often since; she has a somewhat limited but very useful motion of the joint. I assisted Dr. Sayre in reducing an old backward dislocation of these bones in the case of a boy. Other means having failed, while Dr. Sayre forcibly flexed the arm, I cut the triceps, after which the reduction was easily effected. Some months later the arm was nearly ankylosed at the elbow-joint, and it did not promise very well, so far as the usefulness of the member was concerned. Dr. W. F. Westmoreland, of Atlanta, Ga., has reported a case in which he succeeded readily in reducing a dislocation of the elbow backward, of five months' standing, in a woman aged 22 years. The reduction was followed by great pain, a good deal of swelling, temporary impairment of circulation in the radial artery, complete paralysis of the little finger, and partial paralysis of the middle and ring fingers. On the fourteenth day, at which period the history of the case closes, all these symptoms were rapidly disappearing.²

The fact is in the main as stated by Boyer; and if so many cases can be found in which surgeons have succeeded at a late period, they are not probably in the proportion of one to five as compared with the failures. But the failures have not received the same publicity. Nor, indeed, have all the severe accidents, such as violent inflammation, suppuration, gangrene, and even death, been faithfully declared.

Denucé says he has been able to trace out five or six examples in which, although the arm was reduced, grave accidents resulted, and Velpeau's patient actually died in consequence. Michaux, at the Hôpital de Louvain, in 1841, in reducing an elbow dislocation, tore off the median nerve and brachial artery. Amputation was made and the life of the patient saved.³ Dixie Crosby, of New Hampshire, has treated two cases of ancient dislocation of the forearm backward, by bending the elbow forcibly so as to break the olecranon process, after which the reduction was easily accomplished by extension. R. D. Mussey, of Cincinnati, has succeeded once in the same manner.⁴ I have reported three

¹ Op. cit.

² Westmoreland, *Atlanta Med. and Surg. Journ.*, May, 1866.

³ Debruyne, *Des Luxations du Coude*. Thèse Inaug. Louvain, 1842, p. 77.

⁴ Crosby, *Mussey, Trans. Amer. Med. Assoc.*, vol. iii. p. 357.

similar examples. Malgaigne says that Cappelletti published an example in 1835, and that Morel-Lavallée, Roux, and Maisonneuve had each met with the accident.¹

In 1879, Trendelenburg,² in a girl, æt. 15 years, with an irreducible dislocation of eight weeks' standing, having made an external incision, with a chisel separated the olecranon process from the shaft, and then reduced the dislocation. Observing now that when the arm was flexed there was a wide separation of the fragments, he again straightened the arm and brought the fragments together with a wire suture. He states that the results were satisfactory!

Voelker,³ in an old incomplete backward and outward dislocation in a boy, æt. 13 years, attended with complete paralysis of the parts supplied by the ulnar nerve, severed the olecranon with a saw and then wired the fragments together. The result of the operation was a certain degree of improvement in the motions of the arm, and the disappearance of the paralysis.

In 1839, Gerdy,⁴ in a dislocation of six months' standing, divided subcutaneously the triceps and the adjacent adhesions, but he was still unable to reduce the dislocation.

Maisonneuve⁵ and Blumhart⁶ only effected the reduction after the most extensive tegumentary, muscular, and ligamentous dissections. Von Wahl,⁷ in two cases made an external incision, and having divided in one case both of the lateral ligaments, and in the other the external only, and having destroyed the adhesions, was unable to effect reduction. He proceeded, therefore, to practise resection of the joint.

Emmert⁸ and Boeckel⁹ have each practised resection in similar cases; and Ollier¹⁰ has three times resorted to the same expedient in old irreducible dislocations.

All of these latter surgical expedients should be reserved for exceptional cases. Not one of them is wholly free from danger, and the results are not in all cases such as might be hoped for. Moreover, experience has abundantly shown, and especially when the accidents have occurred in early life, that a persistence of the dislocation is not incompatible with the subsequent formation of a new and very useful joint.

In a recent case, the dislocation being reduced, it may be a matter of prudence, sometimes, to apply a right-angled splint, first carefully padded, to the palmar surface of the arm and forearm; remembering, however, that considerable swelling will soon occur, and that it ought not, therefore, to be bandaged to the limb very tightly. At least once a day it should be removed, and the arm examined; and in very few cases can it be necessary or judicious to continue its application beyond one week. At the same time, if there is any especial tendency in the radius to become displaced backward, owing to a rupture of its annular ligament, this must be prevented, if possible, by a compress and bandage. Some surgeons regard these precautions as necessary in all cases, but I have seldom employed any splint or bandage whatever, nor have I ever had reason to regret this omission. Finally, we are to place the arm in a sling, and adopt such measures as are calculated at first to reduce the

¹ Malgaigne, *op. cit.*, Paris ed., 1855, vol. ii. p. 144.

² Trendelenburg, *Centralblatt für Chir.*, 1880, No. 52, p. 833.

³ Voelker, *Deutsche Zeitschrift für Chir.*, Bd. 12, Hft. 6.

⁴ Gerdy, *Annal. de Chir. Française et Étrang.* t. 2. p. 151.

⁵ Maisonneuve, *Poinsot, op. cit.*, 918.

⁶ Blumhart, *Gaz. Méd. de Paris*, 1847, p. 238.

⁷ Von Wahl, *St. Petersburg med. Wochenschrift*, 1879, No. 23, p. 221.

⁸ Emmert, *Rev. Méd. Chir.* t. 3, p. 177.

⁹ Boeckel, *Frag. de Chir.*, Paris, 1882, p. 85.

¹⁰ Ollier, *Rev. Mens. de Chir.*, 1882, pp. 722-734.

inflammation; and at a very early day we ought to begin to move the elbow-joint, in order to prevent ankylosis.

§ 2. Dislocations of the Radius and Ulna Outward (to the Radial Side).

(a) **Complete Outward Dislocations.**—The large majority of outward dislocations of the forearm are incomplete; indeed, only nine examples of a complete dislocation have been collected by Denucé, including two seen by himself.¹ In his last memoir he has added four more.

Malgaigne has recorded two;² Mollière, of Lyons, has reported one.³ Amboni,⁴ Hatry,⁵ Bertin,⁶ have each reported one. Andrews⁷ has also reported one, and Salleron one,⁸ Osborne one,⁹ Varick one,¹⁰ Wylie one.¹¹ Dr. Erskine Mason has reported two, in children of seven and twelve years respectively, and he refers to another reported by one of his colleagues at Bellevue in the Medical Record for October 9, 1875, in the person of a lad, æt. 17 years,¹² making in all nineteen cases. Dr. Varick's case is reported as follows: G. K., æt. 9 years, was thrown violently from a wagon, striking on his head and back, with his left arm behind him in a state of flexion. He was brought to my office within ten minutes after the receipt of the injury, and, consequently, in the most favorable condition for manipulation, no swelling of the soft parts having yet occurred. The forearm was in a state of semiflexion, supported by the hand of the opposite side, the ulna lying to the outer side of the external condyle with slight posterior projection of the olecranon. The olecranon, coronoid process, and greater sigmoid cavity could be distinctly defined, and the head of the radius, in its normal relations to the ulna, could be felt rotating subcutaneously on pronating and supinating the forearm. Free motion of the forearm in every direction was present, giving the impression of being attached to the arm solely by the soft parts. The projection of the internal condyle was out of all proportion to what is seen in cases of incomplete dislocation. The trochlea, coronoid depression, and the olecranon depression were distinctly recognized. Complete dislocation of the radius and ulna outward was diagnosticated, which diagnosis was corroborated by my friend, Dr. B. A. Watson, who was present and assisted in the reduction. The patient was placed fully under the influence of ether, and moderate extension, combined with lateral pressure, effected the reduction without difficulty. The subsequent treatment consisted of rest and cold irrigation for a few days, followed by passive motion of the parts, which resulted in perfect recovery. The amount of inflammation which followed the injury was exceedingly slight, due unquestionably to the prompt reduction of the dislocation.

Dr. Wylie, who was at that time House Surgeon at the Long Island College Hospital, Brooklyn, relates the case as follows: E. B., aged 38 years, fell with one arm raised, striking on the inner side of the elbow; at the same moment a barrel of fish, weighing two hundred and fifty pounds, fell over, striking the arm about three inches above the external condyle. Upon rising he found the arm flexed at a right angle, pronated, and immovable at the elbow-joint. No attempt at reduction was ever made, nor was there any retentive apparatus applied. He put the arm in a sling, and after a couple of months he commenced using it a little. At the end of two years his arm was sufficiently recovered to

¹ Denucé. *Mém. sur Lux. des Coudes*. Paris, 1854.

² Malgaigne, *op. cit.*

³ Mollière. *Monthly Abstract Med. Sci.* vol. i. p. 269, 1874.

⁴ Amboni. *Annal. Univ. di Med.*, July, 1872.

⁵ Hatry. *Lyon Méd.*, t. 18, p. 13, 1875.

⁶ Bertin. *Union Méd.*, 1876, p. 609.

⁷ Andrews. *Med. Record*, Oct. 23, 1875, p. 720.

⁸ Salleron. *Pingaud, Art. Coude, Dic. Encyc. Sci. Méd.*, sér. 1, t. 21.

⁹ H. B. Osborne. *Hosp. Gazette*, Nov. 29, 1879, p. 613.

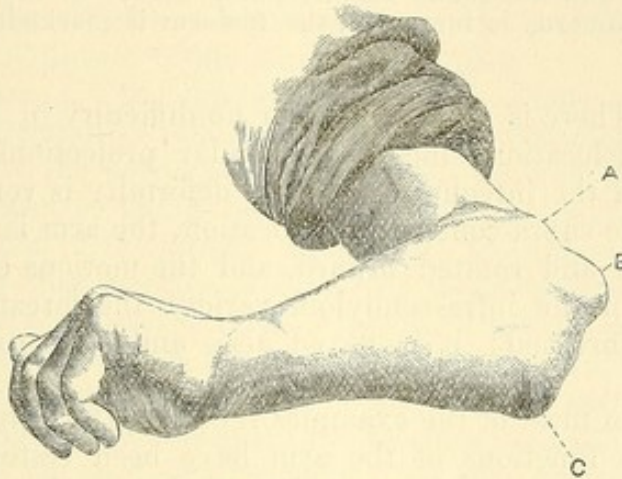
¹⁰ T. R. Varick. *Med. Record*, Nov. 1, 1867, p. 387.

¹¹ W. Wylie. *Med. and Surg. Rep.*, March 22, 1879, p. 250.

¹² Mason. *Med. Record*, April 10, 1880, p. 397.

permit him to return to his sailor life, which he followed up to six months ago, when he was admitted to the Long Island College Hospital, for other injuries. At the present time, seventeen years after the accident, the inner border of the olecranon process rests upon the external border of the humerus, above the external condyle, where, probably, an articular facet has been developed. Just

FIG. 404.

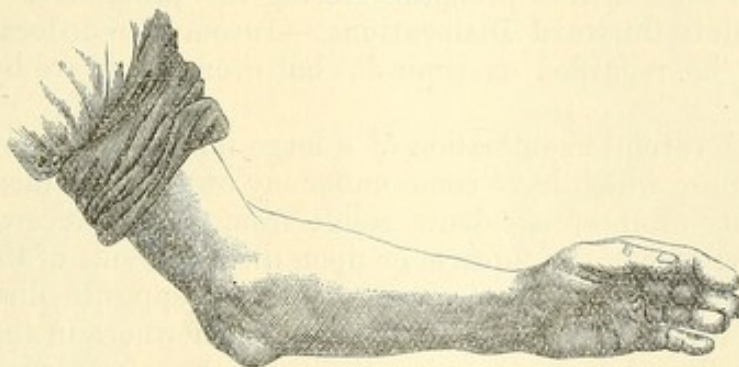


Dr. Wylie's case.

A. Radius; B. Olecranon process; C. Lower end of humerus.

anterior to and to the inner side of this is the head of the radius, which can be recognized by sight, but more surely identified by touch. The internal condyle of the humerus projects greatly, and the trochlea can be distinctly felt. When extended, the radial border presents a gentle outward inclination from the elbow down. This may be greatly increased or diminished by manipulation.

FIG. 405.



The same. Arm nearly extended; the lower end of the humerus projecting below.

This extremity is one and three-quarters of an inch shorter than the other. (This is my own measurement, and differs a little from that given by Dr. Wylie.) The patient has full control of this limb, can flex or extend, pronate or supinate it nearly as well as the other, and he thinks it is in every particular as serviceable as the other.

Causes.—This accident has been produced generally either by a fall upon the hand or upon the elbow. In the latter case, it has been occasionally noted that the force of the concussion was received upon the internal portion of the elbow.

Pathological Anatomy.—Two varieties of this accident have been recognized; one in which the sigmoid fossa of the ulna is situated exter-

nally and above the epicondyle, and one in which the sigmoid cavity embraces the epicondyle externally or is situated below it; while the head of the radius is carried forward by the resistance offered by the pronator muscles.

[A third variety has been described as "infra-epicondylar." The bones are displaced upward and are found on the outer border of the humerus. The diameter of the humerus is increased, the forearm is markedly shortened and strongly flexed.]

Symptoms.—There is usually little or no difficulty in recognizing the nature of this dislocation, since the articular projections are easily felt and seen beneath the integuments. The deformity is very marked, and in the case of the supra-condyloid dislocation, the arm is shortened, the forearm is flexed and rotated inward, and the motions of the joint are limited; while in the infra-condyloid variety, the forearm is very little or not at all shortened; it is flexed also, and the pronation is more extreme.

Prognosis.—In most of the examples reported, the reduction has been effected, and the functions of the arm have been restored; and even when not reduced, the usefulness of the arm has not been diminished in such a degree as might naturally have been expected. In the case of Baker, reported above, the arm seemed after the lapse of seventeen years to be as useful as before.

Treatment.—Extend the forearm upon the arm, with the hand in a position of forced supination, and make traction; and at the same time make direct pressure with the thumbs upon the projecting point of the ulna. In case the dislocation is infra-condyloidian, the hand may be maintained in a position of pronation during this procedure.

(b) **Incomplete Outward Dislocations.**—Incomplete dislocations must, in this case, be regarded as typical; but even these are by no means frequent.

Causes.—A careful examination of a large number of recorded examples, and of those which have come under my own eye, renders it certain that a majority of these accidents result from a blow received directly upon the inner side of the forearm or upon the outer side of the humerus, or from the action of two forces pressing in an opposite direction. Of course, these forces must act upon the bones somewhere in the neighborhood of the elbow-joint. Occasionally it has been produced by a fall upon the hand; sometimes by a violent twist of the arm, as when the hand is caught in machinery; and in other cases it has been found consecutive upon a dislocation backward, being produced in the attempts made to accomplish reduction of this latter form of dislocation.

Pathological Anatomy.—In most of the examples of simple incomplete outward dislocation of the forearm, the great sigmoid cavity of the ulna still embraces the lower end of the humerus; but instead of reposing upon the trochlea fairly, it is carried outward half an inch or more, so as to rest its central crest upon the depression which separates the trochlea from the lesser or radial head of the humerus. If the annular ligament remains unbroken, the radius is displaced in the same direction and to the same extent. Occasionally, however, where the violence has been

greater, the central crest of the great sigmoid cavity rests fairly upon the condyle, or upon the articulating surface of the humerus where the head of the radius was formerly applied, and the dislocation approaches more nearly to the character of a complete dislocation. At the same time, owing, perhaps, to the resistance afforded by the skin, or some of the ligaments, the head of the radius may be thrown either forward or backward, so as to be out of line with the ulna. Such a displacement generally implies a rupture of the annular ligament.

We have now only to suppose the action of a more considerable force in the same direction to render the dislocation complete; in which case the upper end of the radius is sometimes thrown completely forward, and its head may even be found resting in front of the ulna, occasioning an extreme pronation of the forearm and hand. The anconeus and brachialis anticus are the only muscles in either of these dislocations whose fibres are generally much disturbed; the biceps and triceps being made also to traverse the articulation a little more obliquely. In examples of fracture of the external condyle, the condyle being carried outward, the radius may remain in contact with the trochlea, and the ulna may accompany it in this outward displacement; but this must be regarded as a fracture rather than as a dislocation.

FIG. 406.

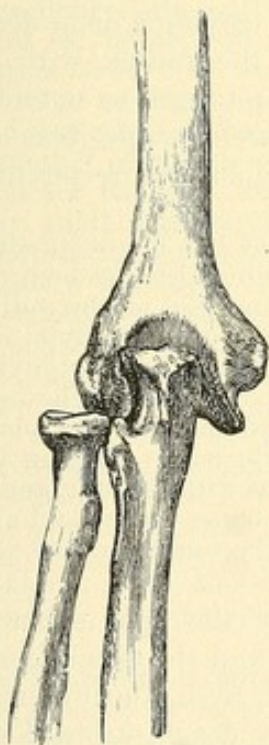
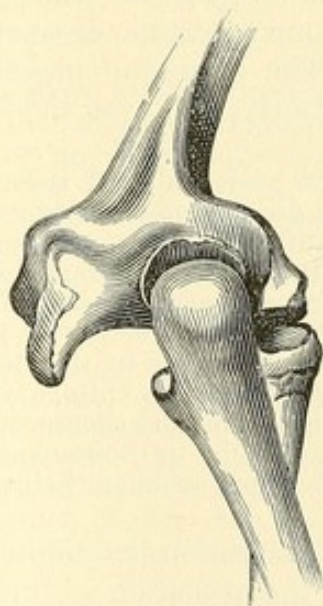


FIG. 407.



Forms of outward dislocation of radius and ulna.

[Poumet presented a specimen of this dislocation, of long standing, to the Société Anatomique; the ulna displaced outward; has completely left the trochlea; latter contains a large sesamoid bone; external articular surface of sigmoid cavity in relation with capitellum; radius displaced outward and forward. (Fig. 407.)]

Denucé, Malgaigne, A. Cooper, and others have preferred to speak of the dislocation *backward and outward* as a distinct form or species of dislocation. I prefer to regard it as only a variety of the outward dislocation, since it may, and

no doubt often does, occur consecutively upon a simple incomplete outward dislocation; and if the dislocation outward is complete, the bones of the forearm can scarcely fail to be drawn more or less upward. Sometimes, also, it has been consecutive upon a simple backward dislocation, or upon unsuccessful attempts at reduction where the form of dislocation was originally backward; yet, as it does not so naturally follow upon a complete backward dislocation as upon a complete outward dislocation, I find sufficient reason for studying its mechanism in this place.

The beak of the olecranon process not only, but a large portion of the body of this process, now lies above and behind the condyle; the brachialis anticus becomes more stretched, if not actually torn; and the biceps is laid against the articulating surface of the humerus; but the triceps becomes again relaxed; as in simple dislocation backward and upward. In all these dislocations the capsular ligaments are more or less extensively torn, but the principal arteries and nerves do not generally suffer greatly, if at all.

Symptoms.—The forearm is usually flexed to about the same angle at which I have found it in dislocations backward; once I have found it nearly or quite straight; occasionally it is flexed to a right angle. In all the cases seen by me the forearm has been pronated, and the elbow-joint has been very immovable. The most striking diagnostic sign, however, consists in the unnatural form of the elbow-joint, which is so remarkable as not to be easily misunderstood. The internal condyle of the humerus (epitrochlea) projects strongly to the inner side, leaving a deep depression below; while upon the other side, the head of the radius, with its cup-like extremity, can be distinctly felt, and made to rotate outside of its socket. The olecranon process, driven from its fossa, projects more or less posteriorly, and even the fossa itself may sometimes be plainly felt.

A girl, 12 years old, had fallen upon the inside of her elbow, producing an incomplete dislocation outward of the forearm. The forearm was bent upon the arm about fifteen degrees, and immovably fixed. The head of the radius could be distinctly felt external to and a little in front of the outer condyle, while the olecranon process of the ulna, which rested upon the back and outer surface of the humerus, was less distinctly felt than in the opposite arm. The inner condyle projected sharply to the inside, and the olecranon fossa was plainly felt with the fingers. The child was suffering very little pain. Seizing the wrist with my right hand and the lower end of the humerus with the left, and making moderate extension in these opposite directions, the bones easily, and after only a moment's effort, resumed their places. Her recovery was rapid and complete.

If the dislocation is complete, the position of the arm is usually the same, but the pronation of the hand is greater, and the projection of the inner condyle more striking. If now the bones, by a continuance of the original force, or by the action of the triceps, are drawn upward also, the arm becomes a little more flexed, and the olecranon process more prominent, while the length of the whole limb is sensibly diminished.

Prognosis.—In recent cases, and where no complications exist, the reduction is generally easily effected.

M. Thierry claims to have reduced an outward and backward semi-luxation after eight months. A patient of whom Debruyne has spoken was not so fortunate. On the 16th of April, 1841, a lad, æt. 18, fell upon the palm of his hand and semi-luxated both bones outward and backward; on the following morning

a surgeon attempted to reduce the dislocation, and the attempt was repeated on the next day by another surgeon; but on the day following this last attempt, gangrene ensued in consequence of the great violence employed by the surgeons, and although the limb was amputated, the patient died. The autopsy showed that both the brachial artery and the median nerve were torn asunder, and that the tendons of the biceps and the brachialis anticus were slipped behind the outer condyle, probably having been thrown into this position during the violent twistings to which the arm had been subjected.¹

I have seen three examples of semi-luxations upward and outward which the medical attendants had failed to reduce. The first was in the case of a lad, 14 years old, who had fallen upon the palm of his left hand. The surgeon who was immediately called made extension, and supposed that the reduction was accomplished. The lad was brought to me a few months after the accident. The arm was slightly flexed, and neither prone nor supine. There existed only a slight motion at the elbow-joint. I did not think it worth while to make any attempt at reduction. Several years after this I had an opportunity of examining the arm again. He had now recovered considerable motion in the joint, but he could not tie his cravat. Pronation and supination were perfect.

In the second example, a lady, æt. 33, had fallen upon the inside of her elbow, and reduction not having been accomplished, I found her, nine weeks after the accident, with scarcely any motion at the elbow-joint, and complaining of a numbness in the forearm and hand.

The third instance of unreduced semi-luxation I will relate more at length: F. B., aged twenty-two years, fell a distance of about five feet, striking upon the palm of his hand, his arm being extended in front of him. On rising, he found his arm forcibly flexed and abducted. He straightened it without difficulty, and it assumed the position it now occupies. A physician was called and saw the patient an hour and a half after the accident, who pronounced it a case of dislocation of the radius and ulna, and made efforts at reduction, which he continued from 8:30 A. M. until 2 P. M., a period of five and a half hours, to no purpose, when he abandoned the attempt. During the attempt at reduction, the extension was made at times with the arm flexed, and at others extended. At 9 P. M. another physician was called, who made efforts at reduction until 3 A. M., upward of six hours, at which time he also abandoned the attempt. On the third day another physician, the patient being under the influence of ether, made efforts at reduction for twenty minutes, when he pronounced it in place, and applied a bandage. From the patient's account, the arm was swollen to such an extent as to render this point difficult to determine. On the fifth day the first physician was called, and, believing that he discovered a grating, pronounced it a fracture of the external condyle. Four months after the accident the limb presented the following appearances: The "forearm extended upon the arm; looking at the limb along its radial margin, we notice a gentle outward inclination of the forearm from the elbow down, but by manipulation this may be greatly increased; the power of pronation and supination is not affected; the inner condyle projects an inch to the ulnar side; the head of the radius, completely removed from its socket, projects to an equal extent on the radial side. The top of the olecranon process is an inch higher than the top of the inner condyle, so that the radius and ulna are carried upward as well as outward."

I believe that the external condyle was not broken, as in that case the arm would be *permanently* deflected outward to a much greater extent. For, although this arm may be deflected outward by the surgeon to an angle of 135°, still the degree of mobility which exists would be adverse to the supposition of its being a fracture of the external condyle. The condyles also can be plainly felt in their natural situations, which would not be the case if a fracture of the external condyle existed. The patient was advised not to submit to any further attempts at reduction.

The following will serve as an illustration of a recent accident of this character: A boy, æt. 8, fell while wrestling, his companion falling upon his arm. I found the forearm slightly flexed, pronated, and both radius and ulna thrown

¹ Denucé, op. cit., p. 103.

over to the radial side and carried upward. Pressing firmly upon the radius from the outside, the bones assumed suddenly the position of a backward and upward dislocation, from which position they were readily reduced to their original sockets by simple extension.

Treatment.—In relation to the treatment of these accidents I have little to add to what has already been said of the treatment of dislocations backward. The reduction, if effected at all, has generally been accomplished by moderate extension, or by extension combined with lateral pressure. If the head of the radius is in front of the humerus, or of the ulna, the hand should be first supined, and then the extension should be applied. In some cases the reduction has been effected by placing the knee in the bend of the elbow and flexing the forearm, while the surgeon was making extension from the hand.

§ 3. Dislocations of the Radius and Ulna Inward (to the Ulnar Side); Always Incomplete.

This form of dislocation has generally been considered as much more rare than the incomplete dislocation outward, a fact which may perhaps find a sufficient explanation in the peculiar form of the trochlea, the inner half of which rises much higher than the outer, forming thus an elevated inclined plane, over which the articulating surface of the ulna must rise before the dislocation can occur.

Hahn and Sprengel have, however, observed the incomplete inward dislocation more often than the incomplete dislocation outward.

Like the opposite dislocation, the typical form of the accident is that in which the displacement is *incomplete*; indeed, *no example of a complete inward dislocation has, I think, been yet recorded.*

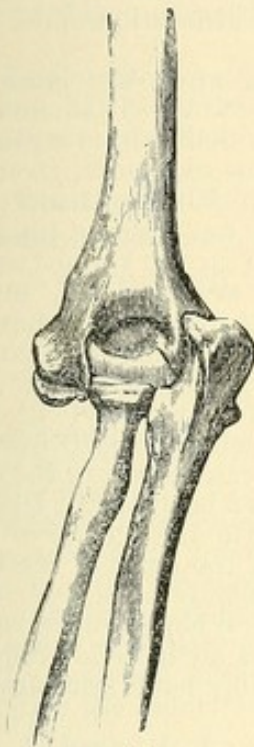
Causes.—A fall upon the hand or forearm, a blow upon the radial side of the forearm near its upper end, or upon the ulnar side of the arm near its lower end, a violent wrenching or rotation inward, of the forearm, are among the causes which may occasion this dislocation.

Pathological Anatomy.—The ridge which divides antero-posteriorly the greater sigmoid cavity of the ulna, having been driven over the elevated inner margin of the trochlea, falls down upon the epitrochlea, so as, in some sense, to embrace it instead of the trochlea; while the head of the radius passes inward also, and is made to occupy the trochlea, from which the ulna has escaped. Generally the head of the radius is found in the same line with the ulna (Fig. 408), but it may suffer a dislocation and be found a little in advance of the ulna, or possibly a little back of the ulna.

I choose also to regard the semi-dislocations *inward and upward* as only a variety of the semi-dislocation inward; in which form of the accident the coronoid process of the ulna is thrust upward above the epicondyle, and the head of the radius occupies the olecranon fossa, or rests upon the back of the humerus somewhere in this vicinity. In addition to the injury suffered by the ligaments and muscles, the ulnar nerve in both varieties of inward dislocation is peculiarly liable to contusion, in

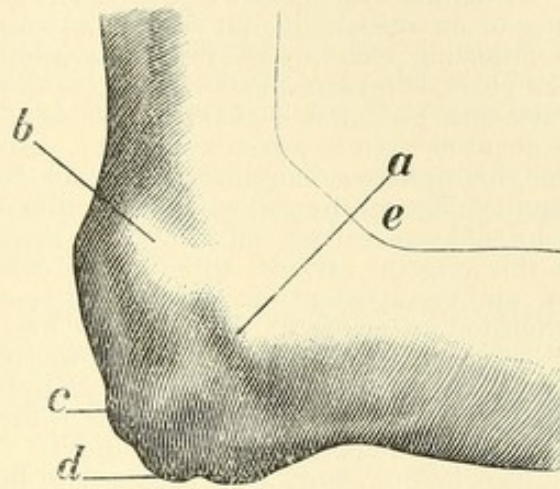
consequence of its being crushed between the olecranon process and the epitrochlea. As in fractures of the external condyle, so in fractures of

FIG. 408.



Most frequent form of incomplete inward dislocation of the forearm.

FIG. 409.



Broca's case of incomplete dislocation inward; *a*, epitrochlea; *c*, *b*, olecranon; *d*, head of radius.

the internal condyle the radius and ulna are apt to suffer a lateral displacement also; these examples are more properly to be considered as fractures rather than dislocations.

[Broca dissected an old incomplete dislocation inward. A new joint had been formed which admitted of flexion and extension nearly complete; though the lateral and annular ligaments had disappeared and a new capsule seemed to have been formed. The external appearances are seen in Fig. 409.]

Symptoms.—If the displacement is only inward, the olecranon process can be felt projecting upon the inner side, and completely concealing the epicondyle; while the head of the radius, having abandoned its socket, may be felt indistinctly in the bend of the arm. The external condyle (epicondyle) is remarkably prominent. The forearm is generally more or less flexed. The natural outward deflection of the forearm is also lost, or it may be even inclined slightly inward. This phenomenon is explained by the position of the epicondyle, upon which the greater sigmoid cavity now rests, allowing the ulna to overlap a little upon the humerus; rendering the forearm actually somewhat shorter along its ulnar margin, although the head of the radius may still occupy the summit of the trochlea. If the bones are displaced *upward*, as well as *inward*, a considerable shortening is declared, and the head of the radius may now be felt behind the trochlea, or over the olecranon fossa.

In three of the four examples seen by Malgaigne, all of them ancient, the forearm was in a state of supination.

A girl, æt. 5, fell, striking upon her right elbow. A physician was called, who supposed it to be a fracture. Five weeks later it was seen by Prof. Prewitt, of St. Louis, Mo. The forearm was flexed, and could not readily be extended beyond a right angle; it occupied a position midway between pronation and

supination ordinarily, but could be supinated and pronated perfectly. The olecranon process was on a line with the extreme point of the inner epicondyle, and the head of the radius could be felt below the olecranon fossa. A finger could be pressed readily into the fossa. A small, sharp spiculum of bone had been torn off, and lay loose over the external condyle, which was very prominent. Attempts were made by Dr. Prewitt to reduce the dislocation under the influence of an anæsthetic, but without success.¹

The following example of this dislocation, unreduced after the lapse of fourteen years, is reported by Dr. T. H. Squier, of Elmira, N. Y.: T. C., now in his nineteenth year, was 4 years and 10 months old when he fell from a pile of boards about as high as a man's shoulder. According to his statement, given at the time, his right arm caught between the boards, and, in falling, he turned a somersault. The mother, to whom the child immediately ran, grasped his arm which he said was broken, and found that it would roll and turn in various ways. When the surgeon arrived, three hours afterward, the arm was very much swollen, and the accident was supposed to be a fracture. At present the flexion and extension are perfect. The forearm has an inward deflection of a hand's breadth more than the other. The power of pronation is complete, but the forearm and hand cannot be supinated entirely. The external condyle is very prominent, but the internal is almost hid by the olecranon, which projects inward nearly as far as the point of the epicondyle. The finger can be laid in the olecranon fossa behind, and all the back part of the trochlea can be distinctly traced. By flexing the forearm slowly, as it approaches a right angle, the tendon of the triceps may be felt, lodged, as it were, on the back part of the point of the epicondyle; and by continuing the flexion, the tendon suddenly slips over this point and places itself on the anterior aspect of the arm. When the forearm is fully flexed, the tendon is advanced full three-quarters of an inch in front of the epicondyle. The arm is very serviceable, but invariably pains him after a hard day's work.

[The following case was reported by Hauck, of St. Louis: P. B., aged 13, was brought to our office at noon on the 7th of September. A half hour previous, while playing, he slipped on a banana peel and fell. Striking on the point of his right elbow, and turning on this as a pivot, he struck his right cheek and forehead. On examination, I found the external condyle prominent, olecranon lying over internal epicondyle, and the head of the radius on the trochlea, where it could be felt rotating. A depression existed between the olecranon and the external condyle. Passive flexion and extension were very limited; pronation and supination possible but very painful. Reduction was easily accomplished by drawing on flexed forearm in a line with the humerus, and pushing the olecranon outward, while the humerus was being firmly held by an assistant. Immediately after reduction the severe pain disappeared, and extension and flexion, pronation and supination were almost perfect, but painful. The radius had returned to its normal position.²]

Prognosis.—Malgaigne was unable to reduce the bones in a recent case of incomplete internal dislocation which came under his own notice. Triquet succeeded in a child seven years old, on the fifteenth day, after many trials; but the movements of the elbow-joint were never restored. Debruyne succeeded on the fifth day, but not without difficulty; Prewitt failed at the end of five weeks; the case reported by Squier was mistaken for a fracture, and no attempt at reduction was made; and in a case seen by Velpeau, reduction was easily accomplished, and on the eighth day the patient was dismissed.³ Of the four examples of *inward*, *backward*, and *upward* dislocation seen by Malgaigne, not one was ever reduced; but as the history of them all is not complete, it is by no

¹ Prewitt, St. Louis Courier of Med., Jan. 1879, p. 43.

² The Weekly Medical Rev., Nov. 28, 1885.

³ Denucé, op. cit., pp. 154-156.

means to be inferred that the reduction could not have been easily accomplished, at least in some of them, at the first. Nor, with such imperfect details before us, can we understand fully what complications may have existed, such as would perhaps render these exceptional rather than illustrative examples.

One of these patients had a completely ankylosed elbow at the end of two years, but pronation and supination were preserved. In the case of another, however, even flexion and extension were as perfect as in the normal condition.

Treatment.—The indications of treatment are the same as in semi-dislocations outward, with only such slight modifications as the judgment of every surgeon must naturally suggest.

I prefer to employ, by way of illustration, the example diagnosticated by Velpeau. A. G., æt. 22, entered the hospital with an incomplete inward dislocation of the forearm which had just occurred. The hand and forearm were in a state of forced pronation, half-flexed, and the whole limb from the elbow downward was deflected inward. There were present, also, all the other usual signs of this dislocation, and Velpeau had no doubt as to its true character. In order to accomplish reduction, one assistant made counter-extension upon the arm, while a second made direct extension upon the forearm. At first the tractions were made in the direction of the forearm (flexed and prone), but gradually the arm was straightened and supinated. Then the surgeon, seizing with one hand the superior extremity of the forearm and with the other the inferior extremity of the arm, acted forcibly upon the two portions in opposite directions, and immediately the reduction was effected with a noise.¹

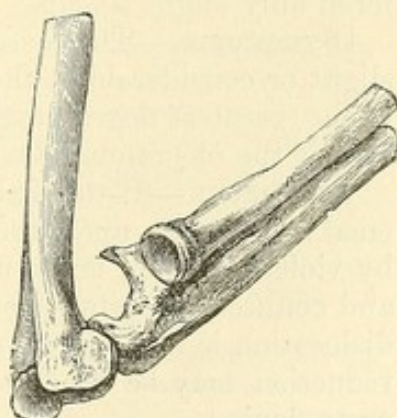
§ 4. Dislocations of the Radius and Ulna Forward.

Sir Astley Cooper, Vidal (de Cassis), and others, have denied that this dislocation was possible without a fracture of the olecranon process; but Monin, Prior, Velpeau, Canton,² and Denucé have each reported one example, also Wittlinger, Flaubert, Secrestan, and Cannin,³ so that its existence may now be considered as established.

The following is a summary of the facts in Velpeau's case: A. C., æt. 23, was knocked down by a carriage, the wheel passing over the right arm. The arm was found in a right-angled position, and it could neither be flexed nor extended; the forearm was strongly supinated; the projecting angle usually made by the olecranon process was replaced by the irregular extremity of the humerus; the forearm was shortened upon the arm; the head of the radius resting in the coronoid fossa, and the olecranon process being also carried upward and a little outward. Reduction was easily accomplished, and the patient left on the nineteenth day, with only a slight remaining stiffness in the joint.⁴

A case is reported to have come under the observation of Mr. J. W. Langmore, House Surgeon at the University College Hospital, London. It was occasioned by a fall upon the elbow. The reduction of the ulna was easily accomplished

FIG. 410.



E. Canton's case of dislocation of the radius and ulna forward.

¹ Denucé, *op. cit.*, p. 155.

² Poinot, *op. cit.*, p. 939.

³ Dublin Quart. Journ. of Med. Sci., Aug. 1860.

⁴ Denucé, *op. cit.*, p. 110.

by placing the knee in the bend of the elbow and flexing the arm. The radius was then reduced by pressure and extension.¹ Chapel has reported a case of dislocation forward and outward, which he readily reduced soon after it occurred, while Colson, Leva, Ancelon, and Guyot have each reported one example of *sub-luxation* forward, in which the extremity of the olecranon process has been found resting upon the extremity of the humeral trochlea.² In a case of incomplete dislocation forward, mentioned by Date,³ the internal condyle was broken. The fracture of the olecranon as accompanying this accident, has, according to Poinso, only been observed in six cases, namely, by Richet, Velpeau, Guérin, Morel-Lavallée, and Guerre. In the latter case, according to Pingaud, the dislocation was easily reduced, and the result was a very useful limb.

Causes.—This accident seems to have been, in most cases, caused by a fall upon the elbow while the forearm was forcibly flexed.

In Date's case, however, a boy 14 years old, the fall was upon the palm of the hand.

In case it is caused by a fall upon the elbow, with the arm in a position of forced flexion, the olecranon receives the impact, and this fact, aided perhaps by torsion and abduction of the forearm, drives the bones forward.

Pathological Anatomy.—In the case reported by Canton, amputation became necessary, and an opportunity was thus afforded to make a careful dissection of the parts involved in the injury. At the time of the accident the arm was in a position of forced flexion, with the forearm twisted upon the chest. The olecranon was found lying in front of the little head of the humerus, the radius was in a position of supination, preserving its normal relations with the ulna. The anterior ligament was torn, as were also the posterior and lateral ligaments. The annular and oblique ligaments were intact. The triceps was torn from its insertions. The two external radial and most of the muscles originating at the epicondyle were more or less torn. The biceps and brachialis anticus were in a state of tension. The larger vessels were unbroken. The ulnar nerve was torn opposite the condyle. The median nerve had suffered only slight lesions.

[**Symptoms.**—The forearm is lengthened with flexion, which may be slight or considerable; there may be quite free movement and extension to the greatest degree may be possible without pain; there is a depression at the olecranon fossa, and some flattening at the sides of the elbow.]

Treatment.—If the dislocation is complete, and the forearm is lengthened and flexed upon the arm, the reduction should first be attempted by violent flexion, or by flexion combined with extension from the wrist, and counter-extension from the lower portion of the humerus. If the dislocation is incomplete, and the forearm is extended upon the arm, the reduction may be readily accomplished by extension alone, or by moderate flexion.

Dislocation of the Radius and Ulna Forward, with Complete Retroversion of both Bones.—Maisonneuve⁴ has reported a case in which both

¹ New York Med. Record, March 1, 1867, from the London Lancet.

² Denucé, p. 120.

³ Date, The Lancet, 1872, vol. ii. p. 97.

⁴ Maisonneuve, Gaz. des Hôp., 1867, No. 37. Poinso, op. cit., p. 944.

bones being dislocated forward, the ulna was turned upon itself, so that its sigmoid cavity embraced the articular extremity of the humerus. The patient, a woman, æt. 43, had fallen upon the internal margin of the humerus. The inferior extremity of the humerus projected posteriorly, covered only by the skin. The triceps, slightly stretched, was carried outward and forward, and lay in front of the condyle. The olecranon, unbroken, was in front of the trochlea; its great sigmoid cavity embraced the articular pulley. The radial cup was entirely hidden. The forearm was forcibly pronated. Reduction was effected by carrying the forearm outward, by which the olecranon was disengaged, and the cup of the radius presented itself externally; continuing to press the forearm outward, the olecranon now abandoned the trochlea, embraced the condyle, and then slid outward. The forearm at once took the position of supination, and the great sigmoid cavity again presented forward, passing behind the humerus. The dislocation, having thus been transformed into a backward dislocation, was easily reduced.

Diverging Dislocations of the Radius and Ulna.

(a) DISLOCATIONS OF THE RADIUS FORWARD, AND ULNA BACKWARD.

This accident was first recognized, according to Malgaigne, by M. Michaux and M. Bulley in 1841, when each of these gentlemen met with a case.

Michaux's patient was a man, 44 years old, who had fallen eight feet, striking upon his elbow while it was carried away from his body. At first the dislocation of the radius was not recognized, but having reduced the ulna by traction, he discovered the head of the ulna in front, which was finally reduced by direct pressure made upon it with the thumb. M. Bulley's patient was a male, also, æt. 28, who had been thrown violently upon the palm of his hand. The forearm was slightly flexed, and could not be moved from this position without causing great pain. The coronoid process rested in the olecranon fossa and the head of the radius in the coronoid fossa. With slight traction the ulna was reduced, and afterward the radius was reduced by methodic processes.

M. Mayer reported a case which was not recognized until the fourteenth day, and then he found himself unable to reduce it.¹ Denucé mentions these three cases and no others. Tillaux² also saw a case, of eight days' standing, in a girl 22 years of age, which he was unable to reduce. Minich,³ in a case which came under his observation, reduced the ulna easily, but did not succeed in reducing the radius until he had made several attempts. Minich, in his report of this case, refers to three other cases as having been seen by Vignolo, Bardeleben, and Chevalier. Poincot has also reported a case seen by his colleague Arnozan, which was accompanied with a fracture of the internal condyle, but which for that reason cannot be considered as representing a true dislocation.

To these cases I will add the case reported by Dr. Erskine Mason as having been seen by himself and Dr. Whybrew. The man was 28 years old, and the accident had happened in a fall when he was intoxicated. He had supposed it was a sprain, and these gentlemen were not consulted until the eighteenth day. The character of the dislocation was apparent, but they could not positively determine but that a portion of the external condyle had been broken off; there was, however, no crepitus. The limb was nearly straight, and would admit of

¹ Michaux, Bulley, Mayer. From Malgaigne, Paris ed., 1855, vol. ii. p. 631.

² Tillaux, *Gaz. des Hôp.*, 1877, No. 99.

³ Minich, *Lo Sperimentale*, 1880, fas. 6.

but slight flexion. Under ether, prolonged efforts at reduction were made, with the result of finally reducing the ulna, but the radius remained unreduced.¹

(b) TRANSVERSE. ULNA INWARD, AND RADIUS OUTWARD.

The following case, reported by Warmont, was presented in the service of Guersant,² at the Hôpital des Enfants, June 29, 1854: A boy, 15 years old, had fallen a few feet, striking upon the palm of his left hand. The elbow was enormously swollen; its transverse diameter was much increased, while the antero-posterior seemed flattened. No abnormal protrusion existed in front, but externally the head of the radius projected, having ascended along the external border of the humerus. The olecranon was displaced inward, so that the inner condyle was embraced by the great sigmoid cavity. Between the bones of the forearm, thus separated, almost the whole of the articular surface of the humerus was lodged. The forearm was semiflexed and semipronated.

(c) OBLIQUE. ULNA BACKWARD, AND RADIUS OUTWARD.

Samuel Withe³ has described the case of a boy, æt. 13, who had fallen violently upon his left elbow. "The condyles of the humerus protruded through the skin at the internal portion of the articulation, exposing entirely the trochlea of the humerus; the ulna was dislocated backward and the radius outward." Reduction was easily effected, and a satisfactory result ensued.

(d) OBLIQUE. ULNA FORWARD, AND RADIUS OUTWARD.

Mahner Mons⁴ witnessed this dislocation in a man who had struck his elbow violently against a wooden obstacle while it was in a position of forced flexion. The ulna was displaced forward without fracture of the olecranon, the radius was completely displaced outward. Reduction was easily effected by traction and pronation. The cure was effected in two months.

CHAPTER XI.

DISLOCATIONS OF THE WRIST (RADIO-CARPAL).

REGARDED as an accident of not unusual occurrence by Hippocrates, J. L. Petit, Duverney, Boyer, and by most if not all of the older writers, its frequency began to be questioned by Pouteau, and finally its existence was almost absolutely denied by Dupuytren, who remarks:

"I have for a long time publicly taught that fractures of the carpal end of the radius are extremely common; that I had always found those supposed dislocations of the wrist turn out to be fractures; and that, in spite of all which has been said upon the subject, I have never met with, or heard of, one single well-authenticated and convincing case of the dislocation in question." Dupuytren subsequently declared that he would not positively deny the possibility of the

¹ Mason and Whybrew, Medical Record, April 10, 1880, p. 397.

² Warmont, Rev. Med.-Chir., t. xvi. p. 303.

³ Withe, A. Cooper, Œuv. Chir., ed. de Chassaignac et Richelot, Paris, 1837.

⁴ Mahner Mons, Deut. Milit. Zeitschr., 1887, Hft. 8 u. 9, p. 401.

accident, yet that "it must at least be admitted that the accident is an extremely rare one." Wishing to explain this infrequency, he says: "In examining the structure of the soft parts, one cannot fail to perceive that it is not the ligaments which prevent the displacement of the articular surface forward, but that this effect is especially due to the multitude of flexor tendons, deprived as they are at this point of all the fleshy parts, and reduced to the simple fibrous tissue which composes them. These tendons are bound together beneath the anterior annular ligament of the wrist, and thus offer so efficient a resistance that severe falls are insufficient to tear them through; the hand is forced into a state of extreme extension, and the tendons are firmly applied on the anterior part of the radio-carpal articulation. If the extension is still further augmented, the wrist-joint is yet more closely clasped by these parts, and their power of resistance is incalculable; I am convinced that a force equivalent to one thousand pounds weight would be inadequate to overcome it; and the known power of the tendo-Achillis is sufficient to prove that this computation is not exaggerated.

"The risk of dislocation backward by a fall on the dorsal surface of the hand is equally precluded by the tendons of the extensor muscles. Their arrangement and relations at the back of the joint are similar; it is true, they are not quite so strong, but we must admit that their power of resistance is very considerable, when we take into consideration how they are inclosed in sheaths as they cross beneath the posterior annular ligament of the wrist. I have not alluded to the ulna, for it has really little or nothing to do with these movements, as it does not articulate (directly) with the hand. To sum up, then, the extreme rarity of dislocation forward or backward is owing to the obstacles opposed by the flexor or extensor tendons."

The opinion of such a writer as Dupuytren, whose experience was very great, and who described only what he had seen, is always entitled to profound respect; yet it has been the practice of nearly all who have made any reference to his opinions in this matter to speak of them lightly, and not a few have falsely represented him as saying that a dislocation was "impossible." The fact is, that surgeons do still constantly mistake fractures of the lower end of the radius for dislocations, as my own personal observations can attest; and notwithstanding examples have been reported by René, Marjorlin, Padieu, Cruveilhier, Voillemier, Poinot, Malgaigne, Scoutetten, Bransby Cooper, Fergusson, W. Parker, and others, yet the whole number of cases for which the distinction is claimed is, to this day, so inconsiderable as only to establish the value and accuracy of Dupuytren's opinion that the "accident is an extremely rare one." But it is, perhaps, most remarkable, that while very few of these supposed examples have been permitted to be examined after death, in a large majority of the cases in which the autopsy has been made, the dislocation has been found to be complicated with a fracture, generally of the lower extremity of the radius or of the styloid apophysis of the ulna.

The existence of a complication, however, does not render the accident any the less a dislocation, although it may render the diagnosis more difficult, and modify somewhat the indications of treatment. A knowledge of the fact, also, that such complications have always been observed in the autopsy, may leave us in doubt as to what is the natural history of a simple uncomplicated dislocation, if, indeed, it does not warrant a suspicion that such a case never occurs. We shall, nevertheless, after a careful analysis of the cases as they have been reported, and by a consideration of the anatomy of this articulation, be able to determine with some degree of accuracy, perhaps, what are, or what ought to be, the usual causes, signs, treatment, etc., of these accidents.

Partial dislocations have also been frequently described by surgeons. I have never met with an example, but the following case, related to me by the patient himself, I believe to have been a case in point.

Lewis C., of Buffalo, æt. 18, by a fall upon his hand, broke the left forearm below the middle, and at the same time, as he affirms, partially dislocated the carpal bones backward. Dr. Spaulding, of Williamsville, N. Y., took charge of the limb, and pronounced it a fracture, with partial dislocation, and for more than a year after the accident the bones had a tendency to become displaced in the same direction. Whenever he attempted to lift even the weight of half a pound, with his hand supinated and his forearm extended horizontally, the lower end of the radius would spring suddenly forward, and all power in the arm would be lost. When this happened, as it did quite often, he always reduced the bones himself, by simply pushing upon them in the direction of the articulation. Fourteen years after the accident, I examined the arm and found it in all respects perfect, except that the forearm was shortened about one-third of an inch, which shortening was due, no doubt, to the overlapping of the broken bones.

I am unable to verify the accuracy of the statements made in the following paragraph; but as there seems to be no reason why they should not be accepted, it will be proper to give them a place in this treatise.

"According to Francis L. Parker, M.D., Professor of Anatomy in the Medical College of South Carolina (*Trans. S. C. Med. Assoc.*), there are thirty-three cases of so-called dislocations of the wrist-joint on record (omitting the cases of W. Parker and René), including his own, viz., case of dislocation of the wrist-joint backward. Of these, twenty-three are said to have been dislocated backward and ten forward; of this entire number only seven, five backward and two forward, are free from all objection. Of the twenty-six cases of doubtful or unsatisfactory dislocations, sixteen were complicated with fracture of one of the bones or processes connected with the joint; three were compound, three were incomplete, two were arthritic or pathological specimens, and two were objected to from other causes. Of the thirty-three so-called dislocations, the sex is recorded here in fourteen instances; of these eleven were males and three were females. Of the seven cases classed as genuine ones, one post-mortem was made (case of M. Malle), which confirmed the diagnosis; in six remaining cases the patients regained the use of the limb in a very short time, without a tendency to displacement or deformity. Of these seven cases accepted as genuine, two backward dislocations were produced, the force of the fall being received, in one instance, on the dorsum of the hand (Hamilton's); in the other upon the palmar surface (Parker's); in M. Malle's case, a forward displacement, the presumption is that the patient fell on the palm of his hand, but this is not definitely stated; and in the four remaining cases this point is not specified. He lays down the following practical conclusions, which may be derived therefrom: 1st. The wrist-joint may be dislocated backward or forward without fracture or a rupture of the integuments; both are extremely rare; the backward displacement is the most frequent. 2d. Cases of so-called dislocation of the wrist may be associated with fracture of the radius and ulna, or with either of these bones separately, with both styloid processes, or either of them, or with fracture of the articulating surface of the radius; no instance has been recorded of a dislocation of this joint complicated with fracture of the carpal bones. 3d. Dislocation of the wrist backward or forward may be complicated with rupture of the integuments anteriorly or posteriorly, or laterally, with or without fracture of the styloid processes."¹

¹ F. L. Parker, *Med. Rec.*, Nov. 1, 1871.

§ 1. Dislocations of the Carpal Bones Backward.

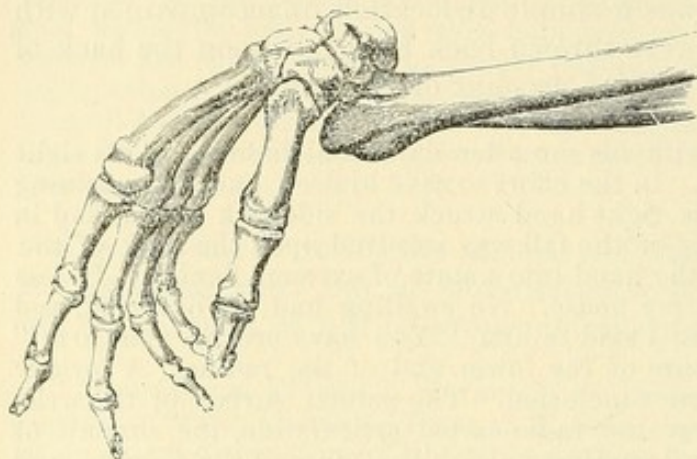
Causes.—The same casualty, namely, a fall upon the palm of the hand, which, as we have elsewhere noticed, produces frequently a fracture of the lower end of the radius, occasionally a dislocation of the radius and ulna backward, at the elbow-joint, may also, it is believed, occasion sometimes a dislocation of the carpal bones backward. In several of the cases reported, this cause has been assigned; but in the only example of simple dislocation which has ever come under my notice, and which I have every reason to believe was a simple dislocation unaccompanied with a fracture, the carpal bones were thrown back by a fall upon the back of the hand. The following is a brief account of the case:

S. P., æt. 75, while walking with his son after dark, and holding in his right hand a satchel, slipped and fell. In the effort to save himself, and still retaining his grasp upon the satchel, his right hand struck the sidewalk flexed, and in such a way that the whole force of the fall was received upon the back of the hand and wrist, thus throwing the hand into a state of extreme flexion. In less than twenty minutes he was at my house. No swelling had yet occurred, and the moment I looked at the wrist I said to him, "You have broken your arm;" so much did it resemble a fracture of the lower end of the radius. A further examination led me to a different conclusion. The palmar surface of the wrist presented an abrupt rising near the radio-carpal articulation, the summit of which was on the same plane and continuous with the bones of the forearm, and a corresponding elevation existed upon the dorsal surface terminating in the carpal bones and hand; the hand was slightly inclined backward, but the fingers were moderately flexed upon the palm. To this extent the accident bore the features of a fracture of the radius; but the hand did not fall to the radial side; the projections upon the palmar and dorsal surfaces were more abrupt than I had ever seen in a case of fracture, and which, if it were a fracture, would imply that the broken extremities had been driven off from each other completely; the most salient angles of these projections were abrupt, but not sharp or ragged; the styloid apophyses could be distinctly felt, and I was not only able to determine that they were not broken, but, by observing their relations to the palmar and dorsal eminences, it was easy to see that these latter correspond to the situation of the articulation. In addition to these evidences that I had to deal with a dislocation, and not a fracture, I had the testimony furnished by the reduction, which was not made, however, until by every possible means the diagnosis was definitely settled. Seizing the hand of the gentleman with my own hand, palm to palm, and making moderate but steady extension in a straight line, the bones suddenly resumed their places with the usual sensation or sound accompanying reductions. There was no grating, or chafing, or crushing, nor was the reduction accomplished gradually, but suddenly. To test still further the accuracy of the diagnosis, I now pressed forcibly upon the wrist from before back, but without producing any degree of displacement, nor could any crepitus still be detected. No splint was applied, and on the following morning Mr. P. preached from one of the pulpits in the city, only retaining his arm in a sling. Sixteen months after the accident this gentleman again called upon me, and I found the arm perfect in all respects, except that it was not quite as strong as before; the lower extremity of the ulna was preternaturally movable, and occasionally he felt a sudden slipping in the radio-carpal articulation.

Pathological Anatomy.—In the examples of compound or complicated dislocations, which have been exposed by dissections, the posterior and lateral ligaments have been found extensively torn, as also frequently the anterior ligament, with or without separation of the radial or ulnar apophyses; the extensor muscles torn up from the lower part of the fore-

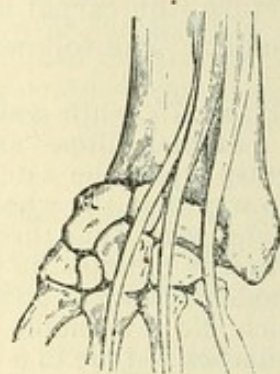
arm and displaced; the first row of the carpal bones lying underneath the tendons, and upon the bones of the forearm, sometimes having been carried directly upward, sometimes upward and a little inward, and at other times upward and outward; the arteries and nerves have occasionally escaped serious injury, but more often they have been displaced, bruised, or torn asunder. Such are, briefly, the pathological circumstances which may be supposed to exist, also, in a less or greater degree, in nearly all cases of simple dislocations.

FIG. 411.



Dislocation of the carpal bones backward.
(From Fergusson.)

FIG. 412.



Dislocation of the carpus backward; scaphoid broken and its upper half with the semilunar remains in connection with the radius. (Pick.)

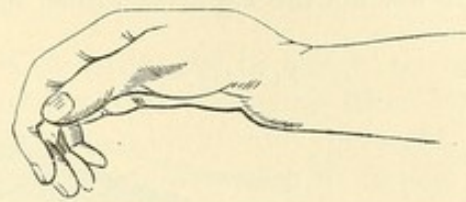
[Pick (*Fractures and Dislocations*) gives an illustration of a backward dislocation of the carpus with transverse fracture of the scaphoid. (Fig. 412.)]

In compound dislocations, however, the muscles, or rather the tendons, are twisted, torn, and thrust aside, producing very extensive lesions among the deeper structures of the forearm and hand before the integuments can be made to yield.

S. U., æt. 54, had his right arm caught between the bumpers of two cars, bruising the hand and dislocating the carpal bones backward, the radius and ulna being thrown forward and pushed completely through the skin into the palm of the hand. Most of the flexor tendons had been merely thrust aside, but one or two were torn asunder; the median nerve was torn off, but the radial and ulnar nerves were apparently uninjured, and there was no fracture. The patient being a temperate man, in perfect health, and the bones having been easily replaced by moderate extension, it was determined to make an effort to save the arm. The limb was, therefore, laid on a carefully padded splint, and cool water lotions diligently applied. Phlegmonous erysipelas began to develop itself on the third day; and on the ninth, gangrene having attacked the limb, I amputated a little above the middle of the humerus. On the fourteenth day hemorrhage occurred suddenly from the stump, and when I reached him he was pulseless and dying. The result demonstrated the error of the attempt to save the limb without resection of the lower ends of the bones of the forearm. I will also add, that according to my later experience it would have been better, if an attempt were to be made to save the hand without resection, to have used warm instead of cold water, and when gangrene occurred, to have applied hot water, or water at a temperature of 105° or 110° F., either in the form of fomentation or a bath.

Symptoms.—The usual signs have already been sufficiently stated in the example which I have given. The most important diagnostic marks are found in the abruptness of the angles formed by the projecting bones; the relation of these prominences to the styloid apophyses; in the total absence of crepitus; and in the reduction, which is accomplished easily, suddenly, and with a characteristic sensation. If a fracture complicates the accident, crepitus may also be present. It should be remembered, moreover, that when the styloid process of the radius is broken, if the hand is moved backward and forward this process will move also, which might lead to the supposition that the radius was broken higher up, and that it was not a dislocation at all.

FIG. 413.



Dislocation of the carpal bones backward.

Prognosis.—In compound dislocations the prognosis is exceedingly grave, unless the surgeon determines to resort to amputation, or, what is generally much preferable, to resection. In dislocations complicated with fracture of the posterior edge of the articulating surface of the radius ("Barton's fracture"¹), some difficulty may be experienced in retaining the bones in place; but when this fracture does not exist, the posterior margin of the articulation, considerably elevated above its anterior margin, constitutes a sufficient protection against a redislocation in that direction. In all cases, also complicated with fracture, even of an apophysis, intense inflammation and swelling are likely to follow, and the danger of a permanent ankylosis is greatly increased.

Treatment.—Extension in a straight line has generally been found sufficient to accomplish the reduction; to which may be added a slight rocking or lateral motion, if necessary. The reduction may be effected also by pressing the hand backward, while the surgeon pushes the carpus downward from behind and above, in the direction of the articulation. Unless a tendency to displacement exists, no splints or bandages of any kind ought to be applied, but the case should be treated by rest and fomentations until all danger from inflammation has passed.

§ 2. Dislocations of the Carpal Bones Forward.

The causes, mechanism, symptoms, pathology, treatment, etc., of this accident resemble those of the preceding dislocation with only the differences necessarily due to a change in the direction of the bones.

Mr. Haydon, of London, reported the following case,² which is especially interesting as furnishing an example of a dislocation of both wrists at the same moment, and from similar causes, but in opposite directions.

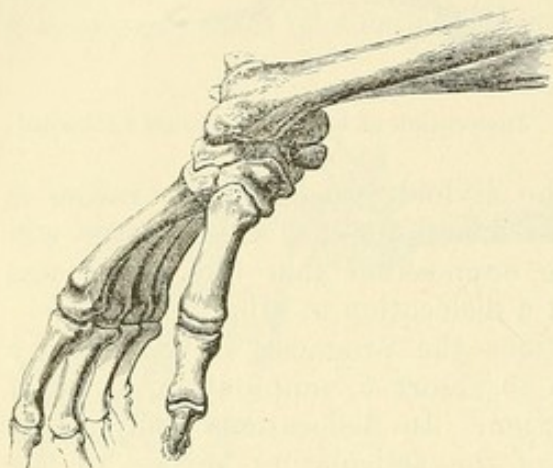
A lad, aged about thirteen years, was thrown violently from a horse on the 11th of June, 1840, striking upon the palms of both hands and upon his forehead. The left carpus was found to be dislocated backward, the radius lying in

¹ Philadelphia Medical Examiner, 1838.

² Bransby Cooper's edition of Sir Astley Cooper's work on Fractures and Dislocations.

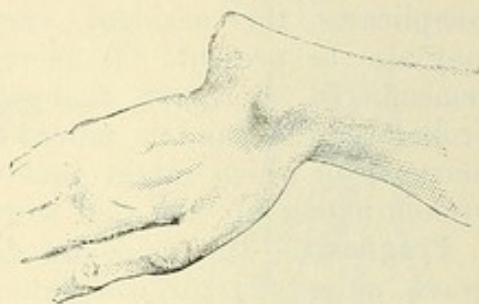
front and upon the scaphoides and trapezium. The right carpus was dislocated forward, the radius and ulna projecting posteriorly, and the bones of the carpus forming an "irregular knotty tumor terminating abruptly" anteriorly. A very careful examination was made to determine what parts came in contact with the resisting force, but although the palms of both hands were extensively bruised, there was not the slightest bruise on the back of either hand. Nor were the

FIG. 414.



Dislocation of the carpal bones forward.

FIG. 415.



Appearance of a dislocation of the carpus forward.

gentlemen present able to find any evidence whatever that the dislocation was accompanied with a fracture. "Moreover," says Mr. Haydon, "we were strengthened in our opinion that this was a case of dislocation, unattended with any fracture, because the dislocations appeared so perfect; the two tumors in each member so distinct; the reduction so complete; the strength of the parts after reduction so great; and lastly, by the very trifling pain felt after reduction, for within an hour after, the patient could rotate the hand, and supinate it when pronated—this could not, we believe, have been done had there existed a fracture."

CHAPTER XII.

DISLOCATIONS OF THE LOWER END OF THE ULNA (INFERIOR RADIO-ULNAR).

IN connection with fractures of the lower end of the radius this accident is not very uncommon. I have myself met with it under these circumstances several times; but without a fracture of the radius it is quite rare. Dupuytren met with but two cases in his long and extensive practice. Sir Astley Cooper does not record a single instance, and many surgeons affirm that they have never seen the dislocation in question, uncomplicated with a fracture of the radius.

§ 1. Dislocations of the Lower End of the Ulna Backward.

Malgaigne never met with a case, but he refers to eleven or twelve examples which had been reported up to the time he wrote. I have met with three cases.

Causes.—Dugas mentions the case of a little girl in whom the accident occurred in both arms, but at different periods, by being lifted by the hands. One of the patients seen by Desault, a child five years old, had the ulna dislocated backward by extension accompanied with forced pronation; and in another example, cited by him, forced pronation alone, as in wringing wet clothes, was found to have been sufficient. In Herteaux's case the patient had fallen upon her wrist.

Pathological Anatomy.—Rupture of the synovial membrane (saciform ligament), and also rupture of the internal lateral ligament, and of the triangular fibro-cartilage, the little head or lower extremity of the ulna abandoning its socket in the radius, and being thrown backward or in some cases backward and outward, so as to cross obliquely the lower end of the radius; or it may incline inward as well as backward.

M. F., æt. 27, having puerperal mania, was confined some time in a strait-jacket, and the accident happened during this confinement, about six weeks before she came under my notice. I found the right ulna displaced backward so that its articular surfaces were completely separated; but it did not override the radius and with moderate pressure it was returned to place. The dislocation and reduction, which had been frequently made by the house staff since the accident, caused no pain, but was accompanied with a slight grating sensation.

Mrs. M. H. fell upon her left hand. I saw her four weeks after the accident. The radius was not broken. The ulna projected backward, and she was unable to pronate the forearm. It was easily reduced, but would not remain in place without support. She was not under my care, and I am not informed as to the treatment or its results. Mr. S., æt. 50 years, fell striking upon his hand and elbow, causing a fracture of the external condyle of the humerus, and a dislocation backward of the lower end of the ulna. The dislocation was reduced promptly and easily by Dr. Dwyer, of this city, and when I saw the patient on the following day, the arm was much swollen, but the ulna had remained in place without bandages or other means of support.

Prognosis.—In recent cases the reduction has generally been accomplished without difficulty, and in only three or four instances has the bone become spontaneously displaced.

Loder reduced the ulna after eight weeks, and Rognetta after sixty days. In one of the examples to which I have already referred as having been seen by myself, the dislocation had existed twenty years, the accident having occurred in Ireland when the person was fifteen years old. When I examined the arm the right ulna projected backward and a little outward, about half an inch. He said he had been lame with it for several years, but the motions of the wrist-joint were now completely restored, and both pronation and supination were perfect.

Symptoms.—The hand is usually fixed in a position midway between supination and pronation. Boyer, however, found the hand in a state of extreme pronation. The extremity of the ulna is felt and seen distinctly upon the back of the wrist, prominent and movable; and the styloid process is no longer in a line with the metacarpal bones of the little finger: the fingers, hand, and forearm are slightly flexed.

Treatment.—The reduction may be accomplished by holding firmly upon the radius and at the same moment pushing the ulna forcibly toward its socket; or by simply supinating the hand strongly. Some cases demand also extension and counter-extension. Generally the bone has been found to remain in its place without assistance, yet in three or four of the examples upon record the constant tendency to displacement when the pressure was removed has rendered it necessary to employ splints and compresses.

§ 2. Dislocations of the Lower End of the Ulna Forward.

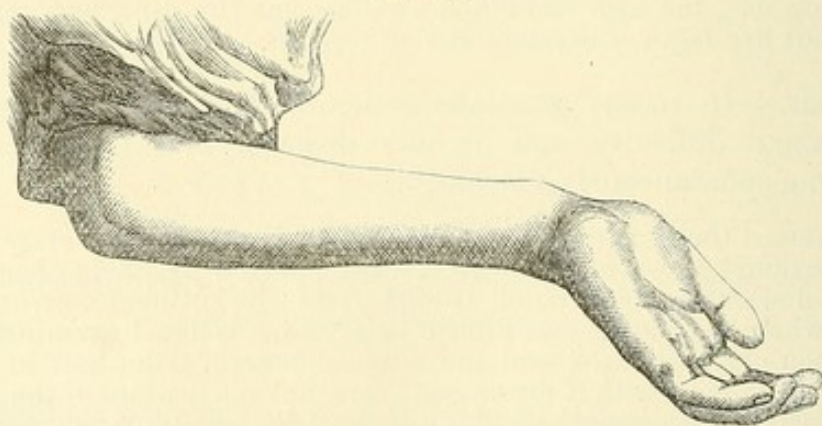
The dislocation forward is said by Malgaigne to be more rare than the dislocation backward.

In addition to the nine cases collected by him, I have been able to add one reported by Parker, of Liverpool, one by R. F. Weir, of New York,¹ and one seen by myself.

While the dislocation backward is usually caused by violent pronation of the hand, this dislocation is most often occasioned by violent supination. The hand is, therefore, generally found to be supinated forcibly, and the projection formed by the end of the bone is seen upon the front of the wrist instead of the back. By pushing the ulna toward its socket while an attempt is made to flex the hand, or by extension, supination, etc., it is made to resume its position readily. In the case reported by Parker, however, the reduction was effected only while the hand was pronated.

Parker's case is thus related: J. D., aged 40 years, states that he is a carter, and falling down, the shaft of the cart fell upon his arm and forearm in such a way as to supinate them forcibly. He complains of pain in the left wrist. The

FIG. 416.



Dislocation of lower end of ulna forward. (Case of Wm. C.)

forearm is supinated, and cannot be pronated, the attempt causing much suffering. The wrist-joint can be flexed or extended without much pain. On looking at the back of the wrist, the appearance is characteristic: the natural prominence of the ulna is wanting; an evident depression exists, as if the lower end of the

¹ Weir, Arch. Clin. Surg., April 15, 1877, p. 10.

ulna had been dissected out; it can be traced, however, on a plane anterior to the radius, its button-like head being distinctly felt under the flexor tendons. Several ineffectual and very painful attempts were made to accomplish the reduction, by pushing the head of the ulna into its natural situation. This was at last effected by seizing the hand to make extension (counter-extension being made at the elbow), then forcibly pronating the hand, at the same time pressing backward the dislocated head of the bone with the fingers of the left hand. After persevering for a short time, the bone was felt to assume its natural position, the wrist acquired its usual appearance, and the ordinary movements of the joint could be readily performed. There was no tendency to dislocation, and the man was dismissed with directions to keep the bone quiet, and to foment it. He attended as an out-patient for two or three days, after which, complaining of nothing but a little weakness in the part, a bandage was applied, and ordered to be worn for a short time.¹

The following is the case seen by me: Wm. C., æt. 27 years, had his left arm caught in machinery and "twisted," or rotated violently, causing a simple dislocation of the ulna forward. No attempt was made at reduction. He consulted me several months after the accident occurred, when I found the lower end of the ulna projecting on the palmar surface, and inclined toward the radius. It could be reduced easily, but would not stay in place; pronation was lost, but all other movements of the arm were preserved. He was a laboring man, and declined to have the necessary apparatus applied to secure permanent reduction, since it would prevent his immediate return to work.

Dr. Weir's patient was a woman, æt. 49 years, in whom the accident occurred by a direct force applied to the back of the ulna near its lower end. She was seen within a few minutes by Dr. Weir, the wrist presenting a singular deformity. It was much narrower than the other, and in place of the usual prominence posteriorly, there was a deep depression, and the head of the ulna projected slightly in front. The hand was semiflexed and nearly supinated. An attempt to reduce the dislocation without an anæsthetic failed; but under the influence of an anæsthetic the reduction was accomplished easily, by direct pressure made upon the lower end of the ulna. The recovery of the use of the hand was speedy and complete.

I found in the Long Island College Hospital a girl 13 years old, who, two years before, had fallen upon the palm of the right hand causing a dislocation of the lower end of the ulna. A doctor applied a splint and kept it on four weeks, but when the splint was removed the ulna became displaced as at first. When examined by me, the ulna became displaced *backward* in the act of supination, and *forward* in the act of pronation; in consequence of which the strength of the wrist was considerably impaired.

CHAPTER XIII.

DISLOCATIONS OF THE CARPAL BONES (AMONG THEMSELVES).

BOUND together on all sides by strong ligaments, and enjoying only a very limited degree of motion among themselves, the carpal bones seldom become displaced except in gunshot wounds, or in connection with extensive lacerations and fractures of the neighboring parts. Simple dislocations, or rather subluxations of these bones, do, however, occasionally take place, but, so far as I have been able to ascertain, except in the case

¹ Parker, Amer. Journ. Med. Sci., April, 1843, p. 470, from Lond. and Edin. Month. Journ. Med. Sci., Dec. 1842.

of the pisiform, only in one direction, namely, backward. The bones of the carpus, which are said occasionally to have suffered simple backward subluxation, are the semiulnar, cuneiform, and pisiform of the first row, and the trapezium, magnum, and unciform of the second row.

Magnum.—Richerand, the editor of Boyer's Lectures, says that he once met with a subluxation of the os magnum backward, of which he has given the following account:

"Mrs. B., in a labor-pain, seized violently the edge of her mattress, and squeezed it forcibly, turning her wrist forward; she instantly heard a slight crack, and felt some pain, to which her other sufferings did not allow her to attend. Fifteen days afterward, happily delivered, and recovered by the care of Professor Baudelocque, she showed her left hand to this celebrated accoucheur, and expressed her disquietude about the tumor which appeared on it, especially when much bent. I was called to visit the lady. I found that this hard circumscribed tumor, which disappeared almost totally by extending the hand, was formed by the head of the os magnum, luxated backward; I replaced it entirely by extending the hand and making gentle pressure on it. As the affection did not impede the motion of the part, as the tumor disappeared on extending the hand, and as it would have been but little apparent in any state of the hand had Mrs. B. been more in flesh, I advised her not to be uneasy about it, and to apply no remedy to it."¹

Bransby Cooper saw the os magnum displaced backward in a stout, muscular young man, by a fall upon the back of the hand when in extreme flexion. The hand remained slightly bent, and the projection of the os magnum was very distinct. Reduction was attempted by extending the whole hand, at the same time making pressure upon the displaced bone; this not succeeding, extension was made from the middle and forefingers only, while pressure was kept up on the os magnum, when suddenly the bone resumed its natural position. On flexing the hand, however, the dislocation was immediately reproduced; and it became necessary to apply a compress and splint. For several days after, he was in the habit of pushing it out by flexing the hand, in order that the young men at Guy's Hospital might see its reduction; which was always easily accomplished by simply pushing upon it.

Magnum and Cuneiform.—Sir Astley says that both the os magnum and cuneiform are sometimes thrown a little backward, from simple relaxation of the ligaments, producing a great degree of weakness, so as to render the hand useless unless the wrist be supported; and he mentions the case of a young lady in whom the os magnus was thus displaced, and who was obliged to give up her music in consequence; for when she wished to use her hand, she was compelled to wear two short splints, made fast to the back and forepart of the hand and forearm. Another lady, whose hand was weak from a similar cause, wore, for the purpose of giving it strength, a strong steel chain bracelet, clasped very tightly around the wrist.²

Pisiform.—South³ says that Gras has described a dislocation of the pisiform bone, and Fergusson says he has known an example in which this bone was detached from its lower connections by the action of the flexor carpi ulnaris.⁴ Little benefit, he thinks, can be expected from any attempts to keep it in place when it is dislocated, nor is its displacement

¹ Richerand, Boyer's Lectures on Diseases of Bones, Amer. ed., 1805, p. 261.

² Sir A. Cooper, op. cit., p. 435.

³ Note to Chelius, by South, op. cit., p. 234.

⁴ Fergusson, op. cit., p. 190.

of much consequence. In case it were dislocated without a rupture of the flexor carpi ulnaris, it would necessarily be drawn more or less upward, in the direction of the tendon and muscle. In children this bone moves very freely upon the cuneiform, and even in adults it is quite movable, and I have seen a surgeon mistake this natural mobility for a partial dislocation.

Lunare.—Erichsen thinks he has seen a dislocation of the os lunare produced by a fall upon the hand when forcibly flexed. By extension and pressure it was easily replaced, but when the hand was flexed the dislocation was immediately reproduced.¹ Notwithstanding that Sir Astley, Miller, and others have taught that the cuneiform bone is liable to displacement, and that South has affirmed the same of the unciform, I have found no account of an example of simple dislocation of single carpal bones except in the cases of the os magnum, pisiformis, and lunare, as above mentioned.

Middle Carpal Articulation.—Maisonneuve has reported an example of simple dislocation, without wound of the integuments, at the middle carpal articulation.

A man had fallen forty feet, and was carried dying to l'Hôtel Dieu. The symptoms were almost precisely those of a dislocation of both rows of the carpal bones backward. The reduction was not accomplished during life, but after death a simple effort of traction was sufficient to replace the bones. The dissection showed that the bones of the second row were almost completely separated from those of the first, upon which they were overlapped backward. A small fragment of both the scaphoids and cuneiform remained attached to the second row, but, with this exception, the separation was complete.² Analogous cases have been reported by Desprès³ and Richmond.⁴

CHAPTER XIV.

DISLOCATIONS OF THE METACARPAL BONES (CARPO-METACARPAL ARTICULATIONS).

§ 1. Dislocations of the Metacarpal Bone of the Thumb Backward.

MALGAIGNE has seen two *complete* dislocations of this bone backward upon the trapezium, and he mentions two other cases seen by Michon and Bourguet, respectively.⁵ Other surgeons have met with similar examples.

Causes.—They have been found to be caused by falls upon the back of the distal extremity of the thumb, forcing the metacarpal bone into a position of extreme flexion; and also by blows received upon the end of

¹ Erichsen, *Sci. and Art. of Surg.*, Amer. ed., 1859, p. 259.

² Maisonneuve, Malgaigne, *op. cit.*, from *Mém. de la Soc. de Chirurg.*, t. ii.

³ Desprès, *Bull. de la Soc. de Chir. de Paris*, 28 avril et 4 mai, 1875.

⁴ Richmond, *The Lancet*, 1879, vol. i. p. 844. Poincot, *op. cit.*, p. 969.

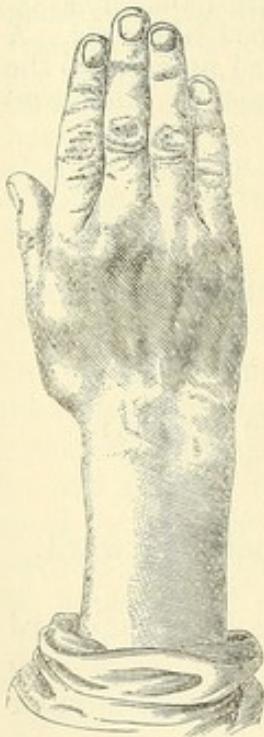⁵ Malgaigne, *op. cit.*, vol. ii. p. 728.

the thumb, forcing it into an opposite direction. In some cases they have been caused by blows received directly upon the articulation.

Symptoms.—The symptoms are sufficiently clear, although the position of the thumb is not always the same. It has been found perfectly straight, without any inclination either way, or flexed more or less, with the metacarpal bone also inclined inward toward the palm. The motions of the joint are interrupted, and the proximal extremity of the metacarpal bone riding upon the back of the trapezium, projects sensibly in this direction, and the trapezium is also felt unusually prominent under the thenar eminence. The overlapping varies from a line or two to three-quarters of an inch. In the patient mentioned by Bourguet, the head of the metacarpal bone almost reached the styloid process of the radius.

Treatment.—The reduction is to be effected by extension alone, or by extension with moderate pressure. In two of the examples reported, although the reduction was accomplished very easily, the dislocation was reproduced when the extension ceased, and it became necessary to apply splints. Malgaigne did not observe, in the case seen by him, any such tendency to displacement. In the case of Bourguet's patient the reduction was never accomplished, although the attempt was made on the second day by a surgeon, and repeated after about two months by Bourguet himself. Fergusson, who has met with several of these dislocations, says that he has seen even a splint and roller fail of keeping these bones in place.

FIG. 417.



Case of Peter Golden.

The following is the only example seen by myself: C. F., æt. 27, caused an incomplete backward dislocation of this bone by striking a man with his clenched fist. It was never treated by a surgeon; and although it always projected a little, and the joint was so loose that he could easily push it into place, it caused him no inconvenience, and after a time the motions became as free as in the other thumb. About four weeks before he called upon me, and twenty-five years after the first accident, he wrenched it again. He was then employed as a stage-driver, and was fifty-three years old. The dislocation was now complete, and the overriding was about one-quarter of an inch. The thumb was nearly straight, the line of its axis being nearly parallel with that of the bones of the forearm or only slightly flexed. I reduced it easily by extension, and applied a gutta-percha splint, but I have never seen him since, and do not know the result.

Incomplete backward dislocations of the metacarpal bone of the thumb seem to be produced by the same causes which cause complete dislocations. The signs of this accident are sometimes obscure, owing to the presence of considerable swelling, and they have often been left unreduced.

In order to the accomplishment of the reduction it will be necessary to employ extension, while at the same moment pressure is made directly upon the displaced extremity; and to maintain it in place a splint and bandage will be required. It is doubtful, however, whether in any case the bone can be made to retain so completely its original position as not to leave a perceptible deformity.

Peter Golden, æt. 16, caused a partial dislocation of this bone backward by a blow upon the back of the distal end. Two medical men whom he consulted on the first and seventh day after the accident failed to recognize the displacement. On the thirteenth day he consulted me. The projection of the metacarpal bone was now quite manifest, the swelling having in a great measure disappeared. Having secured the accompanying photograph (Fig. 417), he was placed under the influence of ether, and the reduction easily accomplished, and with a carefully padded splint of gutta-percha, which included a portion of the arm, it was retained in place. At the end of six or eight months he was again examined by me. The motions of the joint were nearly as free as before, but there remained a slight prominence of the metacarpal bone.

§ 2. Dislocations of the Metacarpal Bone of the Thumb Forward.

Probably Sir Astley Cooper has reference to an accident of this character when he says—speaking of Dislocation of the Head of the Metacarpal Bone from the Trapezium—"In the cases which I have seen of this accident the metacarpal bone has been thrown inward, between the trapezium and the root of the metacarpal bone supporting the forefinger; it forms a protuberance toward the palm of the hand; the thumb is bent backward, and cannot be brought toward the little finger."¹ Sir Astley does not, however, refer to any of the cases which he has seen, and Malgaigne says he has not met with such a case, or found one recorded. My own experience and observation correspond with that of Malgaigne; although I must confess I have not made it a special purpose to look for examples in surgical writings.

One can never call in question the accuracy of Sir Astley Cooper's statements, as to what he professes to have seen, however, and I shall, therefore, add what he has said of the mode of reduction. "For the facility of reduction, as the flexor muscles are made stronger than the extensors, it is best to incline the thumb toward the palm of the hand during the time extension is making, and thus the flexors become relaxed and their resistance diminished. The extension must be steadily and for a considerable time supported, as no sudden violence will effect the reduction. If the bone cannot be reduced by simple extension, it is best to leave the case to the degree of recovery which nature will in time produce, rather than divide the muscles, or run any risk of injuring the nerves and bloodvessels."

Vidal (de Cassis) says he met with an *incomplete* forward dislocation, which he reduced readily, but the patient removed the dressings and the dislocation was reproduced, and the bone was not again replaced.²

§ 3. Dislocations of the Metacarpal Bones of the Fingers.

Examples of these accidents are so rare that no attempt will be made to establish systematically the causes, symptoms, or treatment. Such examples as I have found recorded, or as have come under my own observation, will be, however, briefly related.

¹ Sir Astley Cooper's Treatise on Dislocations, and on Fractures of the Joints, 2d London ed., 1823, p. 526.

² Vidal (de Cassis), *Traité de Path. Ext.*, 3d Paris ed., vol. ii. p. 564.

Dislocations of the Metacarpal Bones of the Fingers Backward.—

Roux has recorded one *complete* dislocation of the second metacarpal bone upon the os magnum, caused by an explosion in a mine. It was reduced by pressure and extension, but could only be retained in place when the hand was flexed. The patient died on the tenth day, and the diagnosis was verified by the autopsy. The remaining backward dislocations of the metacarpal bones of the fingers, and all others that I have found recorded, were *incomplete*, and were generally produced by striking with the clenched fist. I will mention a few of several cases which have come under my notice.

S. P., æt. 24, was admitted with a partial dislocation backward of the proximal ends of the metacarpal bones of the index and great fingers of the right hand; produced, as he affirms, by striking a man with his clenched fist, about one year previously. He says that he called upon a surgeon immediately, but he was unable to keep the bones in place. The projection was very manifest at the time of my examination, and the hand had never recovered the power of grasping bodies firmly.

During the same year I found in the hospital a precisely similar case, in the person of F. McC., æt. 32, a sailor, which had occurred four years before, in consequence of a blow given with his fist. The same bones were partially displaced backward, and remained unreduced. This man had also consulted a surgeon soon after the injury was received.

In both of the above examples I instituted a careful examination to determine whether it was not the bones of the carpus which were thus displaced; but the result was conclusive as to the nature of the accident, and I have obtained casts of both, in order to illustrate partial dislocations of the metacarpal bones.

In 1866 I met with a similar case, except that the metacarpal bone of the index finger was alone dislocated, at Bellevue Hospital, in a woman 28 years of age, caused by falling upon her hand with the fingers closed. Reduction was easily effected.

The following example of dislocation of all the metacarpal bones, except that of the thumb, is probably without a parallel. Corporal G., while holding his gun at "ready," was hit by a ball on the back and ulnar side of his left hand, the ball traversing the back of the hand between the last row of carpal bones and the skin, and emerging on the radial side, sending the carpal bones forward and dislocating the metacarpal bones backward. Great swelling ensued, and the nature of the accident was not known for some months. When I examined the hand, five years later, the displacement was very conspicuous; no fragments of bone had ever escaped. The motions of all the fingers, except the index and little fingers, were unimpaired.

Dislocations of the Metacarpal Bones of the Fingers Forward.—

According to Malgaigne, Bourguet met with a forward dislocation of the metacarpal bone of the index finger, caused by a great force applied to the back of the hand near the carpus. Reduction was effected by extension and pressure. With the aid of splints it was retained in place, and a cure effected.

The following case of forward dislocation of the second metacarpal bone at its proximal end has been reported to me by J. Marsh, Asst. Surg. U. S. A.: Corporal Charles C., æt. 25, was struck accidentally on the back of his right hand by a hammer weighing seven pounds. The hand was at the time firmly clenched, and covered with a buckskin glove. The blow was received obliquely. Dr. Marsh saw him half an hour after the accident. A marked depression existed on the back of the hand, corresponding to the proximal end of the bone, and from this point a gradual elevation of the bone could be traced to its natural level at the distal end. On the palm of the hand the displacement was equally

manifest. In this position it was fixed, and seemed immovable. It was easily and quickly reduced, however, by making extension from the fingers, while at the same moment pressure was made by the thumb in the palm of the hand. It returned to its place with the usual sensation accompanying a reduction of a dislocation, and the deformity at once disappeared; a ball of tow was now placed in the palm of the hand, and secured there by a roller. On the 13th of April he returned to duty, but his hand did not acquire its full strength for some time longer.

CHAPTER XV.

DISLOCATIONS OF THE FIRST PHALANXES OF THE THUMB AND FINGERS (METACARPO-PHALANGEAL).

(a) Dislocations of the First Phalanx of the Thumb Backward.

THIS bone may be dislocated backward or forward, but more frequently the dislocation is backward. I have met with the backward dislocation ten times.

[According to Farabeuf, the backward dislocation may be incomplete or complete. The first is caused by slight dorsal flexion of the phalanx, such as many

FIG. 418.

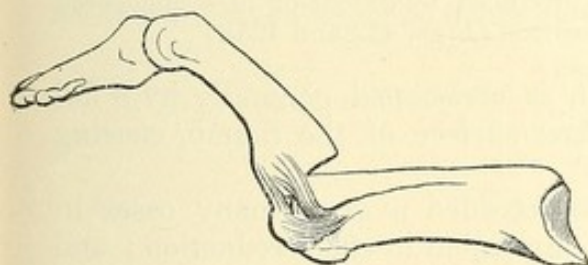
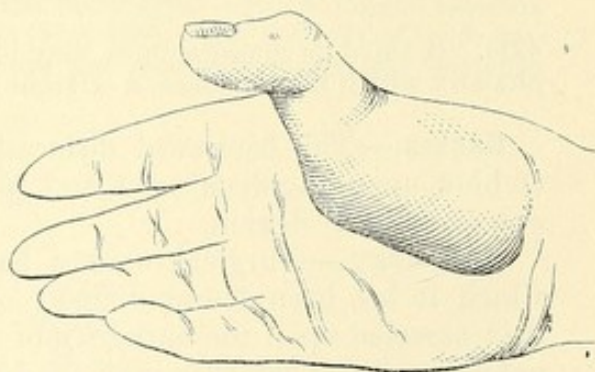


FIG. 419.



Incomplete dislocation of the thumb. (Farabeuf.)

persons can voluntarily effect (Figs. 418 and 419); the second requires more complete dorsal flexion (Figs. 420 and 421). In the former the ligaments are not

FIG. 420.

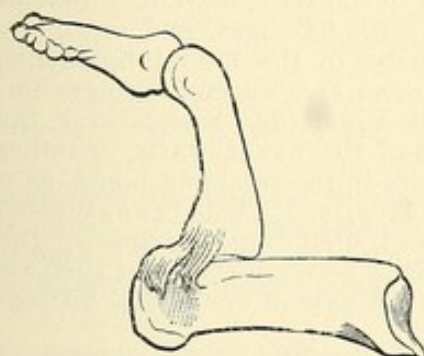
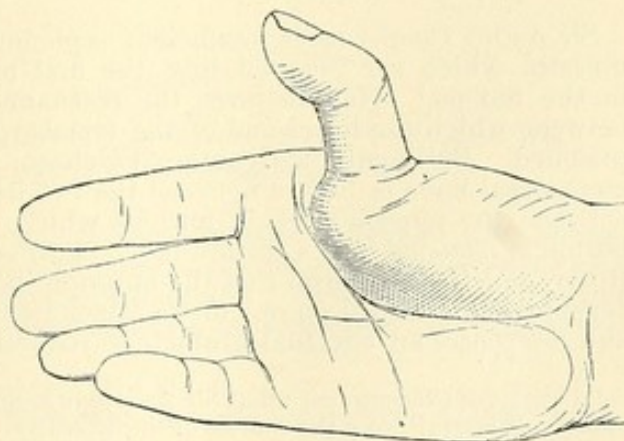


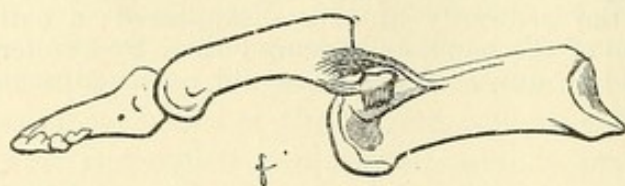
FIG. 421.



Simple complete dislocation of the thumb. (Farabeuf.)

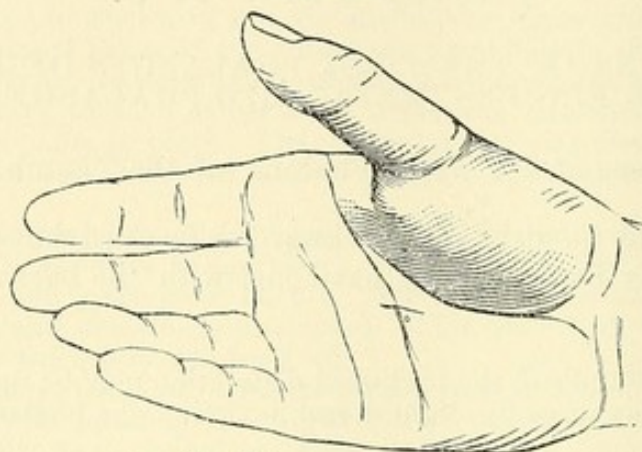
torn, but in the latter the ligaments usually yield, and the round head of the metacarpal bone is protruded through the capsule and becomes prominent (Fig.

FIG. 422.



Complex dislocation. (Farabeuf.)

FIG. 423.



Complex dislocation. (Farabeuf.)

- 421). A third or complex form may be produced by extension of a dislocated phalanx which then assumes a straight position (Figs. 422 and 423).]

Causes.—The backward dislocation is occasioned generally by a fall or blow upon the distal end and palmar surface of the thumb, causing extreme dorsal flexion.

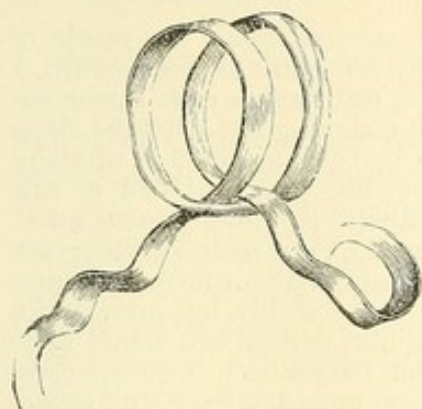
Pathology.—Surgical writers have recorded a great many cases in which it has been found difficult or impossible to effect reduction; and it is asserted upon the authority of Bromfield, quoted by Hey, that the extending force has been increased to such an amount as to tear off the last phalanx without having succeeded in reducing the first; but while surgeons have united in their testimony as to the exceeding obstinacy of a large proportion of these dislocations, they are far from being agreed as to the source of the difficulty.

Sir Astley Cooper finds a sufficient explanation in the six short and powerful muscles which are inserted into the first and last phalanges, and especially in the flexors.¹ Hey believes the resistance to be in the lateral ligaments, between which the lower end of the metacarpal bone escapes and becomes imprisoned. Ballingall, Malgaigne, Erichsen, and Vidal (de Cassis) think the metacarpal bone is locked between the two heads of the flexor brevis, or rather between the opposing sets of muscles which centre in the sesamoid bones, as a button is fastened into a button-hole. Pailloux, Lawrie, Michel, Leva, Blechy, Roser, and Hueter affirm that the anterior ligament, including a portion of the capsule, being torn from one of its attachments, falls between the joint surfaces and interposes an effectual obstacle to reduction. A case of compound disloca-

¹ Lawrie, of Glasgow, says that Sir Astley, in a conversation with him, declared that the "sesamoid bones" were the sources of the difficulty. See Amer. Journ. Med. Sci., vol. xxii. p. 230, with observations and experiments by Lawrie.

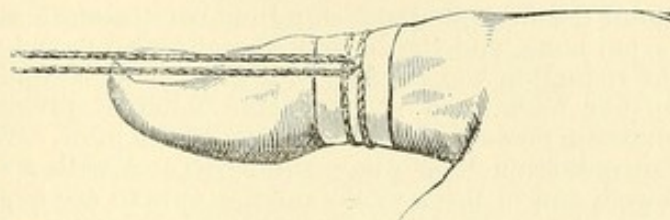
tion is recorded, in which Esmarch saw the capsule in this position, and button-holed upon the distal end of the metacarpal bone.¹ Dupuytren ascribes the difficulty to the altered relations of the lateral ligaments, which are naturally parallel to the axis of the metacarpal bone, but which are now placed at a right angle; to the spasm of the muscles, and to the shortness of the member, in consequence of which the force of extension has to be applied very near to the seat of the dislocation. Lisfranc found in an ancient dislocation the tendon of the

FIG. 424.



Clove-hitch.

FIG. 425.

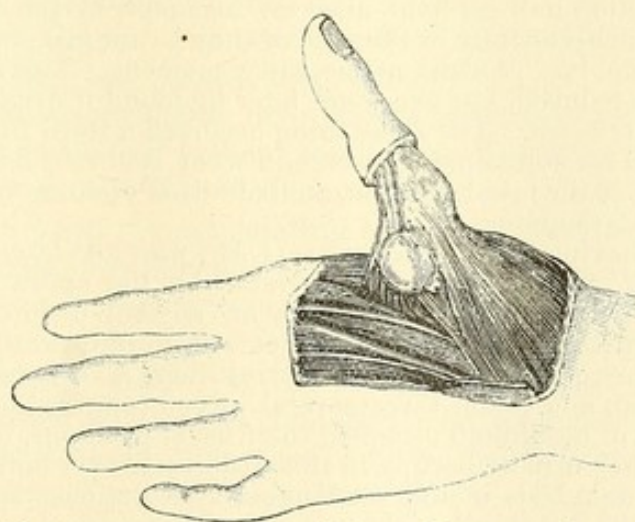


Sir Astley Cooper's method of reducing dislocations of the thumb, with pulleys.

long flexor so displaced inward and entangled behind the extremity of the bone as to prevent reduction. Esmarch met with a similar case, in which he opened the joint and replaced the tendon with a satisfactory result.² Deville discovered in an autopsy a similar displacement of this tendon outward. Wadsworth has made the same observation.³

[In complete dislocation the head of the metacarpal bone is forced between the two heads of the flexor brevis pollicis (Fig. 426). The tendons of these two heads contain the sesamoid bones, to which are attached, also, 1, the abductor

FIG. 426.



The head of the metacarpal bone forced forward between the two heads of the flexor brevis pollicis, which tightly embrace its neck. (Fabbin.)

muscle to the external sesamoid, and 2, the adductor muscle to the internal sesamoid. By the interlacement of the fibres of the tendons of these muscles a capsule is formed for the palmar surface of the joint. To effectually relax these muscles the end of the metacarpal bone must be firmly pressed into the palm.}

¹ Esmarch, *Berliner klinische Wochens.*, 1876, No. 44.

² *Ibid.*

³ Wadsworth, *Am. Med. Times*, Feb. 13, 1864, p. 77.

Symptoms.—I have found the two phalanges in the same axis with the metacarpal bone at least twice; that is, neither flexed nor tilted backward; but in most of the cases the first phalanx inclines backward upon the metacarpal bone, and the second phalanx is flexed upon the first.

Prognosis.—The reduction is sometimes, in recent cases, accomplished with great ease.

A servant girl, *æt.* 25, fell down a flight of steps, striking upon the inside of her right hand and thumb. When I saw her, only a few minutes afterward, I found the first phalanx standing back almost at a right angle with the metacarpal bone, and the second phalanx also flexed to a right angle with the first; the reduction was effected in about twenty seconds, by bending the first phalanx further back, and at the same moment pressing the proximal end of this phalanx forward in the direction of the joint. Without employing great force, the reduction took place suddenly and with a snap. Very little swelling followed, and in three weeks she was able to use her needle without inconvenience.

M. W., *æt.* 35, fell from a height, causing a fracture of his left arm, and a dislocation of his right thumb backward. I saw him within two hours after the accident. The thumb was much swollen, and its position the same as in the case just described. Although W. was a strong, muscular man, the reduction was accomplished in a few seconds by applying over the last phalanx the Indian toy called a "puzzle," and making extension in a straight line, while an assistant made counter-extension from the hand and wrist. The use of the joint was soon completely restored.

Examples, however, are constantly occurring which are only reduced after long-continued and painful efforts, or which, indeed, completely exhaust the patience and baffle the skill of the most experienced surgeons.

Mary J. S., *æt.* 23, fell upon her right hand with her fingers and thumb extended and dislocated this bone backward. A young surgeon attempted to reduce the dislocation half an hour after the accident, by the same manœuvre adopted by myself successfully in the case of the servant girl, only that he made extension upon the last phalanx at the same moment. The surgeon believes that the bone was reduced, but one week later he found it displaced, and, as he believes, reduced it again. The same thing occurred a third time. Six months after this, the girl consulted me to ascertain what could be done for her relief. The thumb occupied the usual position, and admitted of no motion except at the carpo-metacarpal articulation.

In May, 1848, having been called to see G. H., who had attempted suicide by cutting his throat, my attention was arrested by the appearance of his left thumb, which I found to be occasioned by an ancient dislocation of the first phalanx backward. The accident had occurred, he afterward told me, twelve years before, in consequence of a fall while wrestling. A very respectable country surgeon was called, and made three several attempts to reduce it, but failed. The several bones of the thumb occupied their usual positions, that is to say, the positions which they usually occupy in this dislocation, yet notwithstanding the almost complete ankylosis of the phalangeal articulations, and the awkward encroachment of the distal end of the metacarpal bone upon the palm, the hand was quite useful.

C. E. was brought to me, having a dislocation of the first phalanx of the right hand, which had already existed some days, and upon which several unsuccessful attempts at reduction had been made. The dislocation was backward, but the phalanges, instead of standing at an acute or right angle with each other and with the metacarpal bone, as is usually the case, were in a straight line with each other and parallel with the metacarpal bone. Whether this phenomenon existed from the first, or was due to the efforts already made at reduction, I could not determine, but the same thing has been noticed occasionally by other surgeons. The first phalanx, moreover, instead of being placed

directly behind the metacarpal bone, occupied a position upon its back a little to the radial side of the centre. During quite half an hour I made continued and varied attempts to reduce the bone, by extension, by forced dorsal flexion, and by pressing the upper end of the first phalanx in the direction of the joint while pressure was made against its lower end so as to bring it into dorsal flexion, and finally by calling to my aid the "puzzle" and chloroform, but all to no purpose. One week later I repeated these efforts, and with no better success. The parents peremptorily refused to allow me to cut the lateral ligaments, or flexor tendons, so the bone remains unreduced.

Treatment.—The modes of reduction practised and recommended by surgeons are as diversified and irreconcilable as their views of the mechanism and pathological anatomy of the accident. Sir Astley Cooper recommends that extension shall be made by bending the thumb toward the palm of the hand, to relax the flexor muscles as much as possible, and then, by fastening a clove-hitch upon the first phalanx, previously covered with a piece of soft leather, the extension is to be continued, only inclining the thumb a little inward toward the palm of the hand. If these means fail after having been continued a considerable length of time, he advises that a weight shall be suspended to the thumb, passing over a pulley. Finally, in the event of the failure of this method also, Sir Astley thought that no further attempt should be made, and especially that no operation for the division of these parts is justifiable.

Charles Bell proposed flexing the joint, employing at the same time pressure; and in obstinate cases he advised subcutaneous section of the lateral ligaments with a small knife, a method which has since been practised successfully by Liston, Reinhardt, Gibson, of Philadelphia, Parker, of New York, myself, and others. Syme and Lizars justify the practice in certain cases. In one case which has come under my notice, after failing to effect reduction by the usual methods, I succeeded promptly after cutting one lateral ligament; and in the second case I only succeeded after cutting both lateral ligaments.

Roser, from his experiments upon the cadaver, concludes that the dislocated phalanx must first be bent forcibly backward, or into the position termed by some writers dorsal flexion, so as to throw the head of the phalanx forward upon the articulating surface of the metacarpal bone.

Vidal (de Cassis) recommends also that the extension should be made first backward, so as to increase the displacement of the first phalanx in this direction, and to throw forward its articular surface in the direction of the articular surface of the metacarpal bone. Hueter believes that if this method fails, when combined with some rotation and lateral motion, no other is likely to succeed, and he then advises resection. He has, however, himself in all cases been able to effect reduction, but the difficulty has been to maintain it, owing to the interposition of the capsule; and in such cases he has reduced the dislocation and then applied a plaster bandage, grasping the splint and thumb with his hand until the plaster was hard, and leaving it undisturbed for fourteen days, at the end of which time he has found that the bones would remain in place without the aid of the splint. He believes that the interposed ligament has been in the meanwhile absorbed. To me it seems quite certain that with the capsule thus interposed, permanent ankylosis must be the final result, even though it might be possible to retain the dislocated surfaces in apposition, and that resection would be preferable.

Dorsal flexion as the first and most essential part of the manœuvre, seems to have met with more general approval than any other, and the following observations, made by the late Reuben D. Mussey, of Cincinnati, illustrate the general practice among American surgeons at this day :

"I tilt the dislocated phalanx up until it stands upon its articulating end, place both forefingers so as to hold it in that position, and at the same time press against the distal extremity of the metacarpal bone, make firm pressure with the thumbs against the base of the dislocated phalanx, and slide it into its place, which can generally be accomplished with ease. More than twenty-five years ago, the chairman of this committee, from attention to the mechanism of the metacarpo-phalangeal joint of the thumb, convinced himself that the principal impediment to the reduction of the first phalanx from backward displacement is the short flexor of the thumb, between the two portions of which (lying close together where they are fastened to the sesamoid bones) the head of the metacarpal bone has been thrust, the contracted part or neck of this bone lying firmly grasped by them. Fifteen years ago, a case occurred of this dislocation which he could not reduce in the ordinary way. A subcutaneous division of one of the heads of this muscle was made with an iris knife, and the reduction was accomplished with the greatest ease. Last year another case occurred, in which we failed of reduction by Dr. Crosby's method, which we believe to be the best, and the subcutaneous division of both heads of the muscle was made, and the reduction instantly effected."¹

Dr. J. P. Batchelder, of New York, in a paper read before the New York Medical Association in 1856, says: "The surgeon should take the metacarpal portion of the dislocated thumb between the thumb and finger of one hand, and flex or force it as far as may be into the palm of the hand, for the purpose of relaxing the muscles connected with the proximal end of the phalanx, particularly the flexor brevis pollicis. He should then apply the end of the thumb of his hand against the displaced extremity of the dislocated phalanx, for the purpose of forcing it downward, and at the same time grasp the displaced thumb with his other hand, and move it forcibly backward and forward, as in strongly forced flexion and extension, the pressure against the upper extremity of the first phalanx being kept up. In this way the dislocated bone may be made to descend, so as to be almost or quite on a line with the articulating surface of the metacarpal bone, when the thumb may be forcibly flexed, and, if it be not reduced, as forcibly extended, and brought backward to a right angle with the metacarpal bone; when, if the downward pressure, with the thumb placed as before, directed for that purpose, has been continued (which thumb, by maintaining its position, acts as a fulcrum, as well as by its pressure), the bone will slip into its place, and the reduction be effected in less time than has been spent in describing the process."²

[The very thoughtful and judicious opinions here given are in full accord with the most recent writers on this subject. Dorsal flexion is the initial step in the procedure; then press the end of the metacarpal bone into the palm; finally, crowd the proximal end of the phalanx over the end of the metatarsal bone while extending the phalanx. This method should always be pursued, even in the third form, where the axis of the phalanx is the same as the metacarpal bone. Simple extension of the phalanx, as is often practised, and sometimes with powerful apparatus, is contrary to every indication, and is usually unsuccessful.]

By those who have regarded extension as an important element in the reduction, various instruments have been devised for the purpose of obtaining a secure hold upon the dislocated member. Sir Astley Cooper, as we have already seen, recommended the sailor's clove-hitch;³ Lawrie advises that the thumb shall be thrust into the open handle of a large door-key;⁴ Charrière and Luër, of Paris, have each invented forceps, so

¹ Mussey, Trans. Amer. Med. Assoc., vol. iii. p. 357, 1850.

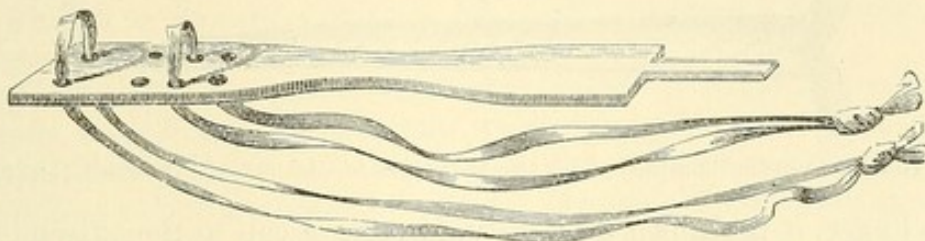
² Batchelder, New York Journ. Med., May, 1856, p. 340.

³ Op. cit. 561; also Boston Med. and Surg. Journ., Oct. 1, 1857.

⁴ Lawrie, Amer. Journ. Med. Sci., vol. xxii. p. 229

constructed with the fenestra and straps that when the blades are closed the member is held very firmly in its grasp. Richard J. Levis, of Philadelphia, recommends "a thin strip of hard wood, about ten inches in length, and one inch, or rather more, in width. One end of the piece is perforated with six or eight holes. The opposite end is partly cut away, forming a projecting pin, and leaving a shoulder on each side of it. Toward this end of the strip, a sort of handle shape is given to it, so as to insure a secure grasp to the operator. Two pieces of strong tape or other material, about one yard in length, are prepared. One of these

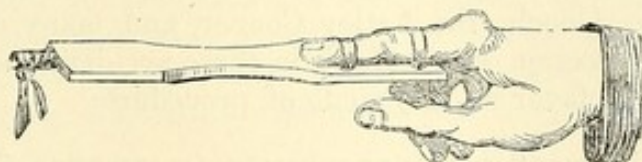
FIG. 427.



Levis's instrument for reduction of dislocations of fingers or the thumb.

is passed through the holes at the ends of the strip, leaving a loop on one side. The other tape is passed through another pair of holes, according as it may be a thumb or a finger to which it is to be applied, or varied to suit the length of the finger, leaving a similar loop. If a dislocated thumb is to be acted on, the second tape should be passed through the holes nearest the first. The ends of each separate tape are then tied together. To apply this apparatus, the finger is passed through the loops. The loop nearest the first joint is then tightened by drawing on the tape, which is then brought along the strip to the opposite end, across one of

FIG. 428.



Levis's instrument applied to the first finger.

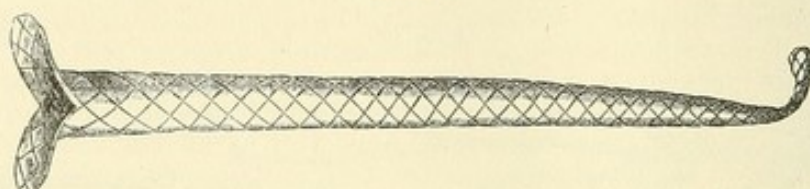
the shoulders, and secured by winding it firmly around the projecting pin. The other tape is tightened in a like manner, crossing the other shoulder, and winding around the pin in an opposite direction, when, for security, the ends of the tapes are finally tied together.¹ This apparatus enables the operator to apply both extension and flexion or leverage in any direction. The proximal end of the phalanx may be lifted, or even rotated so as to allow one side of the bone to approach the socket before the other.

I have described² an instrument, or rather a toy, in my possession, which I suggested might be useful for the purpose of making extension upon dislocated fingers; and which, as will be seen by a reference to one of the cases already reported in this chapter, I have since applied successfully. It is made by the Indians, and may always be obtained during

¹ Levis, Amer. Journ. Med. Sci., Jan. 1857, p. 62.² Buffalo Med. Journ., 1847.

the watering season, at the Indian toy-shops at Niagara Falls. The Indians call it a "puzzle," and know no other use for it than to fasten it upon the thumb or finger of some victim, and then pull him about until he begs to be released. The "puzzle" is an elongated cone of about sixteen or eighteen inches in length, made of ash splittings, and braided; the open end of the cone being about three-fourths of an inch in diameter, and the opposite end terminating in a braided cord. When applied

FIG. 429.



Indian "puzzle," employed for the reduction of dislocations in small joints.

to the finger, it is slipped on lightly, forming a cap to the extremity, and to half the length of the finger, but on traction being made from the opposite end, it fasten itself to the limb with an uncompromising grasp. If constructed of appropriate size and of suitable materials, it becomes the more securely fastened in proportion as the extension is increased; yet applying itself equally to all the surfaces, it inflicts the least possible pain and injury upon the limb. When we wish to remove it, we have only to cease pulling, and it drops off spontaneously.

Finally, in some compound dislocations it would be better not to attempt the reduction of the dislocation until resection has been practised. Samuel Cooper relates a case in which the reduction was followed by inflammation and death within a week after the accident, and Norris, of Philadelphia, mentions an instance which came under his observation, where violent inflammation and tetanus followed the reduction.¹ Roux, Evans, Wardrop, Gooch, Sir Astley Cooper, and many other surgeons, have practised resection successfully in these accidents, and have added their testimony in favor of this mode of procedure.

[It should not be forgotten in using apparatus for extension, that dorsal flexion is the position during extension most likely to secure reduction.]

(b) Dislocations of the First Phalanx of the Thumb Forward.

Up to the present moment, I have met with but two examples of this dislocation, while the backward dislocation has been seen by me ten times.

H. K., of Rochester, N. Y., æt. 24, dislocated the first phalanx of the right thumb forward, by striking a man with his clenched fist; the force of the blow being received upon the back of the second joint of the thumb. The dislocation had existed three days, and in the meanwhile several attempts had been made to reduce the bone by simple extension. The first phalanx was in front of the metacarpal bone, and in the same plane; but the last phalanx was slightly inclined backward. The hand was already swollen and quite painful. Seizing the dislocated thumb in the palm of my right hand, with my fingers resting

¹ Norris, Amer. Journ. Med. Sci., vol. xxxi. p. 16.

upon the back of the patient's hand, I forced the two phalanges into flexion by firm and steady pressure continued for a few seconds, when suddenly the bones resumed their places, and all deformity disappeared. Intense inflammation resulted, followed, after a few days, by suppuration under the palmar fascia; and in the end the thumb was almost completely ankylosed.¹

J. M. B., æt. 19, called at my office, having a dislocation forward of the first phalanx, occasioned, about half an hour before, by being thrown from a horse. The last two phalanges were neither flexed nor extended, but straight, and parallel with the metacarpal bone. By the same manœuvre adopted in the preceding case, but with only very moderate force, the dislocation was promptly reduced.

Causes.—The usual causes of this accident are falls or blows upon the thumb while it is flexed; Lombard has seen it produced by a fall upon the palmar surface of the thumb.

Symptoms.—The symptoms which characterize it are, in general, such as we have seen in the two examples which have just been given. The metacarpal bone projects posteriorly, and the first phalanx produces a corresponding projection toward the palm; the two phalanges are extended upon each other, and parallel with the metacarpal bones. Nélaton saw a case in which the first phalanx was flexed about 45° ; and in several examples it has been observed to be slightly rotated inward.

Treatment.—In the few examples of this accident which have been reported, the reduction was easily accomplished; or, at least, I may say that the difficulties in the way of reduction were not so great as they are usually found to be in dislocations backward. Malgaigne has been able to collect but four undoubted examples, all of which were reduced; Lenoir was able to effect the reduction by moderate measures, after the bone had been dislocated thirty-eight days. Ward succeeded by simple extension.² Lombard, after the trial of other plans, finally succeeded by reversing the phalanx, employing, as I have before termed it, "dorsal flexion," with extension and lateral motion; but in all, or nearly all, the other examples the reduction has been effected by flexing the thumb forcibly toward the palm—the reverse of the method which we have seen preferred, especially by American surgeons, in dislocations backward. My own experience, also, authorizes me to recommend this plan.

(c) Lateral Dislocation of the Last Phalanx.

[A gentleman struck the inner side of the last phalanx of the right thumb violently against the edge of a door. The result was a lateral dislocation of the proximal end of the last phalanx, inward, half the width of the articular surface. The skin was broken on the inner surface, but the joint was not opened. The reduction was readily effected by simple extension.]

(d) Dislocations of the First Phalanx of the Fingers.

The index and little fingers, owing to their exposed situation, are most liable to these dislocations. I have met with three examples of traumatic

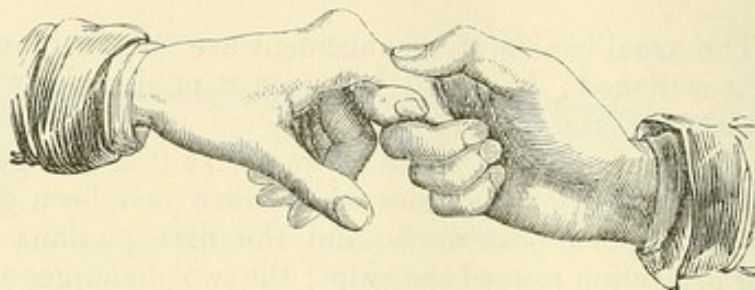¹ Trans. N. Y. State Med. Soc., 1865, p. 73.

² Ward, New York Med. Times, Sept. 8, 1860.

dislocations of these joints, one of which was a forward and two were backward dislocations, and all had occurred in the index finger.

J. N., æt. 11, dislocated the index finger of the right hand backward by a fall down a flight of stairs. On the same day I found the finger neither flexed nor extended, but straight and immovable. The projections occasioned by the ends of the two bones were very marked, and such as to render an error in the diagnosis impossible. Reduction was accomplished with great ease by reversing the

FIG. 430.



Backward dislocation of first phalanx. Reduction by extension.

finger and employing moderate extension, while at the same time the proximal extremity of the first phalanx was pushed toward the distal end of the metacarpal bone. In short, the process was the same as that which I have recommended in dislocations of the thumb backward.

In a woman, 35 years of age, the dislocation was caused by her husband having pulled the finger violently backward. The metacarpal bone was thrust through the skin on the palm of the hand. Four weeks had now elapsed, and the wound had healed. A few days before, the house surgeon had placed her under the influence of ether and had attempted reduction, but had failed, and she refused to allow me to repeat the attempt.

In the example of dislocation forward, occasioned by a blow from a hard ball, received upon the end of the finger, the first phalanx was in a position of extreme extension, and the second moderately flexed. Reduction was effected with great ease by extension in a straight line. But if the surgeon were to experience difficulty in the reduction, it would, no doubt, be advisable to resort to the method of extreme flexion. In one instance, I have seen nearly all the fingers of the left hand, and the thumb of the right, dislocated backward by the contraction of the cicatrix after a severe burn.

CHAPTER XVI.

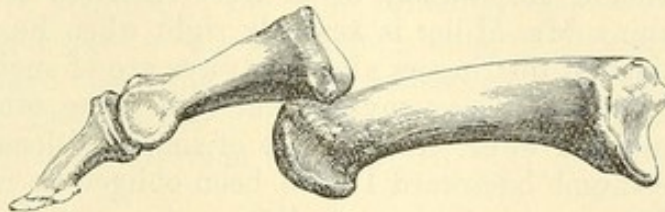DISLOCATIONS OF THE SECOND PHALANX OF THE THUMB AND THE SECOND AND THIRD PHALANGES OF THE FINGERS.

NOTWITHSTANDING slight differences in the form of the articulations between the thumb and fingers, and in the size and situation of the bones which compose the phalanges of the fingers, I am disposed, contrary to the practice of some other writers upon this subject, to consider all the

dislocations to which these several joints are liable, under one section. Nor, indeed, after the attention which I have given to the dislocations at the metacarpo-phalangeal articulations, do I find much to add in relation to these accidents; since in almost every point of view in which they may be considered, they have so much in common. The last phalanx of the thumb is, of all the phalanges, most liable to dislocation, and this generally takes place backward. Very frequently, also, it is accompanied with such a laceration as to render it compound. The dislocated phalanx is usually reversed in the backward dislocation, and straight, or nearly so, in the forward dislocation. In most cases reduction may be accomplished easily by forced dorsal flexion in the case of the backward dislocation, and by forced palmar flexion in the case of the forward dislocation.

A young man was brought to my clinic who had met with a forward subluxation of this phalanx about one month before. He had fallen upon the end of his thumb, and as the accident was followed by a good deal of inflammation and swelling, he did not notice the displacement until some time afterward. The proximal end of the last phalanx projected two or three lines toward the palm; the finger was straight, and this joint ankylosed. I did not think the chance of restoring and maintaining the bone in position sufficient to warrant any interference, and he was dismissed with an assurance that after a few months it would occasion him no great inconvenience.

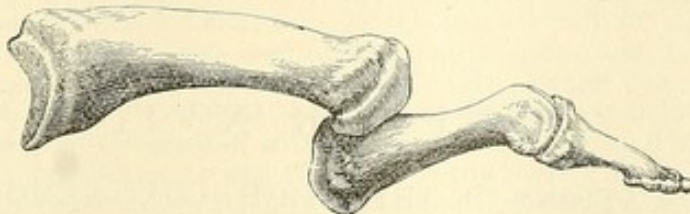FIG. 431.



Dislocation of the second phalanx backward.

T. B., aged about 22 years, by a fall dislocated the second phalanx of the middle finger of the right hand backward. The force of the concussion was received upon the extremity of the finger. Nine hours after the accident I found the bones unreduced; the finger nearly straight, or with only slight flexion of the second phalanx upon the first; the third phalanx forcibly straightened upon the second; all the joints rigid; finger very painful and somewhat swollen. By moderate extension alone, applied for a few seconds, the reduction was accomplished.

FIG. 432.



Dislocation of the second phalanx forward.

J. C., æt. 23, came to me to obtain counsel in relation to his finger, which had been dislocated the day before, but which he had himself reduced by simple extension made in a straight line. His own account of it was, that he fell upon a slippery sidewalk, striking upon the end of his ring finger in such a way that

it seemed to double under him. On examination he found the second bone dislocated inward, or to the ulnar side, completely, the end of the first phalanx forming a broad projection upon the opposite side; the last two phalanges fell over toward the middle finger, but they were neither flexed nor extended. Seizing upon the end of the finger with his right hand and pulling forcibly, he promptly reduced the dislocation himself. The bones were now completely in place, but the joints were swollen, tender, and quite stiff.

Dislocation of the last phalanx is frequently occasioned in the game of base-ball, by the ball being received upon the extremity of the finger.

A private pupil of mine in attempting to catch a very hard ball, received it upon the extremity of the middle finger of the left hand, dislocating the last phalanx forward. Twenty minutes after the accident I found the distal extremity of the second phalanx projecting backward through the skin, the tendon of the extensor muscle being torn completely off from its point of attachment to the last phalanx. The last phalanx was in a position of slight dorsal flexion, or extreme extension. Seizing upon the extremity of the finger, I attempted to reduce the dislocation by direct traction, aided by pressure upon the exposed end of the second phalanx, but I was unable to succeed until I brought the last phalanx into a position of palmar flexion. A slight disposition to redislocation was manifested, and a gutta-percha splint was therefore applied; and, to prevent inflammation, the young man was directed to keep it moistened with cool-water lotions. Only a moderate amount of inflammation followed, and in a few weeks the cure was complete.

Such accidents, attended with laceration of the integuments, may occasionally demand amputation, or at least resection of the projecting bone; but I think Mr. Miller is scarcely right when he says that compound dislocations of the fingers almost always are of such severity as to demand amputation. I have myself met with three other cases which were reduced and did well. In one case of simple dislocation of the last phalanx of the thumb backward I have been obliged to resort to section of the lateral ligaments before accomplishing the reduction.

This was in a woman admitted to Bellevue Hospital. The accident had happened seven days before, by falling and striking upon the end of the thumb. The position of the last phalanx was extended, that is, in a line with the axis of the first phalanx. She said, however, that it was at first "bent straight back," but that a man took hold of it and pulled it out. Having placed her under the influence of ether, I attempted reduction by forced backward flexion, but failed. I then cut the lateral ligaments by subcutaneous incision, and the reduction was accomplished with great ease.

CHAPTER XVII.

DISLOCATIONS OF THE THIGH (COXO-FEMORAL).

THE femur is especially liable to dislocation in four directions, namely, upward and backward upon the dorsum ilii, upward and backward into the ischiatic notch, downward and forward into the foramen thyroideum, and upward and forward upon the pubes. Dislocations are occasionally met with which cannot be arranged properly under either of these divi-

sions; indeed, it is scarcely necessary to say that the head of the bone may be thrown in almost every direction from its socket, upward, downward, inward, and outward, or in either of the diagonals between these lines; and that while in a vast majority of cases it will assume one of the positions first named, it may in a few exceptional examples fall short of, or much exceed, the limits assigned in this division. Thus, I shall have occasion hereafter to mention examples of dislocation directly upward, in which the head of the bone will be found resting upon the fossa between the upper margin of the acetabulum and the anterior inferior spinous process of the ilium; or still higher, between the anterior superior and the anterior inferior spinous processes; or a little to the one side or to the other of these points. Examples will be shown of dislocations directly downward, in which the head of the femur will rest upon the notch between the lower margin of the acetabulum and the tuber ischii; or still lower, and actually below the tuberosity; or downward and backward below the spine of the ischium, into the lower or lesser sacro-sciatic notch. The head may be thrust across the foramen thyroideum, and be only arrested in the perineum upon the ramus, or even beyond the ramus of the ischium and pubes; it may lodge upon the anterior surface of the body of the pubes, as well as upon its superior edge; it may rest against the posterior margin of the acetabulum, instead of rising upon the dorsum; or it may only mount upon its margin, in either of the directions named.

In regard to frequency, the four principal dislocations occur in the order in which I have mentioned them; thus, of 104 dislocations of the hip which I have taken the pains to collate, excluding the anomalous or extraordinary dislocations, 55 were upon the dorsum ilii, 28 into the great ischiatic notch, 13 upon the foramen thyroideum, and 8 upon the pubes.

Chelius and Samuel Cooper have, however, reversed the order of the last two varieties, arranging dislocations upon the pubes, in the order of frequency, before dislocations into the foramen thyroideum.

Coxo-femoral dislocations may occur at any period of life.

A case¹ of thyroid dislocation is reported which occurred in a child six months old. One example is mentioned² of a recent dislocation upon the dorsum ilii in a child eighteen months old.³ Dr. N. Fanning, of Catskill, N. Y., informs me in a letter dated June 25, 1867, that he has reduced a dislocation upon the dorsum ilii, on the tenth day, in a little girl eighteen months old. Mr. Kirby has reported a case of recent dislocation in the same direction, in a child of three years,⁴ and Dr. Buchanan has seen another, at the same age, in a little girl; the dislocation being into the ischiatic notch.⁵ Mr. Image communicated to the Suffolk branch of the Provincial Medical and Surgical Association the case of a boy, three and a half years old, with a dislocation upon the dorsum ilii. It had existed twelve days when he was admitted to the Suffolk Hospital. Mr. Image, in reporting this case to the Society, remarked that he had been induced to lay it before them "in consequence of a charge having been urged against a neighboring surgeon of pretending to reduce a dislocation of the femur in the dorsum

¹ London Lancet, May 16, 1868.¹

² Gazette Médical.

³ New York Journ. Med., Nov. 1850, p. 416.

⁴ Amer. Journ. Med. Sci., Jan. 1843 and Jan. 1847.

⁵ London Med.-Chir. Rev., Dec. 1828, p. 251.

ilii, in a child only four years old, that child being a pauper and chargeable to the parish. It was agreed and proved by authorities that no such case was recorded, and therefore had not occurred, and that seven years old was the earliest period at which this accident had taken place."¹ Litten, of Austin, Texas, reports a case of dislocation upon the dorsum ilii in a girl four years old, which he reduced by manipulation.² Gibney, of New York, has reported a case in a boy of four years, which he reduced after six weeks.³ Dr. Thompson, of Onondaga, N. Y., has reported another case in an Indian boy four years old. The dislocation was upon the dorsum ilii, and it was reduced promptly, under ether.⁴ Dr. Mason, of Leonardsville, N. Y., has reduced a dorsal dislocation in a girl of the same age.⁵ There are reported a forward dislocation in a boy aged five years and a dislocation into the ischiatic notch in a girl of the same age. Dr. A. B. Cook, of Louisville, Ky., has reduced a dorsal dislocation in a boy six years old.⁶ Loewell⁷ reduced, in a child four years old, an iliac dislocation without difficulty, which had existed twenty-six days. Laurence⁸ reduced a dislocation in the foramen ovale easily, which was six weeks old, without an anæsthetic.

Dr. J. C. Warren, of Boston, met with an incomplete dislocation toward the foramen thyroideum in a child six years old, which, having been displaced eight or ten weeks, he was unable to reduce.⁹ Sir Astley Cooper mentions a case in a girl seven years old.¹⁰ I have myself met with two dislocations upon the dorsum ilii, which occurred at ten years, and one into the foramen thyroideum.¹¹ Norris reports a case at eleven years,¹² and Gibson at twelve.¹³

On the other hand, Dr. P. J. Kline, of Portsmouth, Ohio, has reported to me a case of dislocation of the femur in a woman aged seventy-three, and which thirteen years later he found unreduced; and Gauthier has seen a dislocation of the hip in a woman eighty-six years of age.¹⁴ The large majority, however, occur between the fifteenth and forty-fifth years of life. From an analysis of eighty-four cases I have obtained the following results:

Under 15 years	15 cases.
15 to 30	"	32 "
30 to 45	"	29 "
45 to 60	"	7 "
66 to 85	"	1 case.

Dislocations of the hip are much more frequent in men than in women, owing, probably, to the greater exposure of the former to the accidents from which these dislocations usually result, and possibly, also, in some measure, to certain peculiarities in the form and structure of the neck of the femur in the male.

Of one hundred and fifteen cases collected by me, one hundred and four were in males and eleven in females. Dr. J. K. Rodgers, of New York, stated at a meeting of the Kappa Lambda Society that he had seen and reduced four dislocations of the femur upon the dorsum ilii in females, and that a fifth case had recently come to his knowledge in the New York City Hospital.¹⁵

¹ New York Journ. Med., Sept. 1848, p. 281.

² Ibid., March, 1852, p. 259.

³ Amer. Journ. Med. Sci., Oct. 1879.

⁴ Hosp. Gaz., Nov. 15, 1879.

⁵ Mason, Med. Gaz., April 21, 1883.

⁶ Richmond and Louisville Med. Journ., May, 1878.

⁷ Loewell, Rec. Mém. de Méd. Mil. Janv. Fev. 1876.

⁸ Laurence, Centralblatt für Chir., 1878, No. 11, p. 183.

⁹ Boston Med. and Surg. Journ., vol. xxiv. p. 220.

¹⁰ A. Cooper, on Disloc., Amer. ed., p. 83, Case 27.

¹¹ Buffalo Med. Journ., vol. viii. p. 6. Trans. New York State Med. Soc., 1855. My Report on Disloc.

¹² Amer. Journ. Med. Sci., Feb. 1839, p. 296.

¹³ Gibson's Surg., vol. i. p. 389.

¹⁴ Gauthier, Malgaigne, op. cit., p. 805.

¹⁵ J. K. Rodgers, New York Journ. Med., July, 1839, vol. i., first ser., p. 220.

Gibson mentions an example of dislocation of both thighs at the same moment,¹ and Schinzinger has reported a case of double dislocation in which the right femur was found in the ischiatic notch and the left above the pubes.²

Sigonowitz, Andreini, Crawford, Bigelow, Steiner, and Pollard have each reported examples of double dislocations of the hip.³

§ 1. Dislocations Upward and Backward on the Dorsum Ilii.

Syn.—"Upward on the dorsum ilii;" Sir A. Cooper, Miller, Pirrie. "Upward and outward;" Boyer, Dupuytren. "Upward and backward upon the back of the hip-bone;" Chelius. "Iliac;" Gerdy, Vidal (de Cassis), Malgaigne.

Causes.—Generally they are occasioned by some violence which forces the thigh into a state of extreme adduction, or of adduction united with rotation inward; and especially when at the same moment the head of the femur is driven upward and backward. Thus, a dislocation upon the dorsum may result from a fall from a height, when the force of the concussion is received upon the outside of the knee, the thigh being thus converted into a lever of the first kind, whose long arm is outside of the margin of the acetabulum; or the dislocation may be occasioned by a fall upon the foot or knee while the limb is adducted, by which the head of the femur will be at the same moment driven upward and outward from the socket. The accident is equally liable to result from the fall of a heavy weight, such as a mass of earth, upon the back of the pelvis when the body is much bent forward.

The following case presents an extraordinary example of this form of dislocation produced by a force acting upon the thigh as a lever of the first kind: B., of Rochester, N. Y., æt. 10, fell from the top of a high bank, a distance of about one hundred feet. Before he reached the bottom of the precipice, he struck upon an oblique plane of ice, from which he slid gradually down upon the surface of the river, which was then completely frozen over. He did not lose his consciousness in the descent, nor after his arrest upon the river, but began immediately to call for assistance. He remembers very well that when he struck the glacier, the concussion was received upon the right side of the right knee, and a mark of contusion at this point confirmed his statement. Dr. Ellwood, of Rochester, assisted by myself, reduced the dislocation within one hour after its occurrence. We employed pulleys, but the reduction was accomplished easily in about two minutes, and without the application of much force; the bone resuming its place with an audible snap. His recovery was rapid and complete.⁴

Pathological Anatomy.—The capsule is lacerated more or less extensively, but especially in its posterior half; the round ligament is ruptured; some of the small external rotator muscles are generally stretched or torn completely asunder, the glutæus maximus, medius, and minimus are pushed upward and folded upon each other, the head of the femur resting upon or within the fibres of the deep muscles; the triceps adductor is put upon the stretch. Surgeons have not been agreed as to the cause of the great difficulty which has sometimes been experienced in the reduction of this and of all other forms of coxo-femoral dislocations.

¹ Gibson's Surg., vol. i. p. 385, sixth ed.

² The International Surgical Record, vol. i. No. 2; from Wiener med. Presse, 1880, No. 3; Centralb. f. Chir., 1880, No. 11.

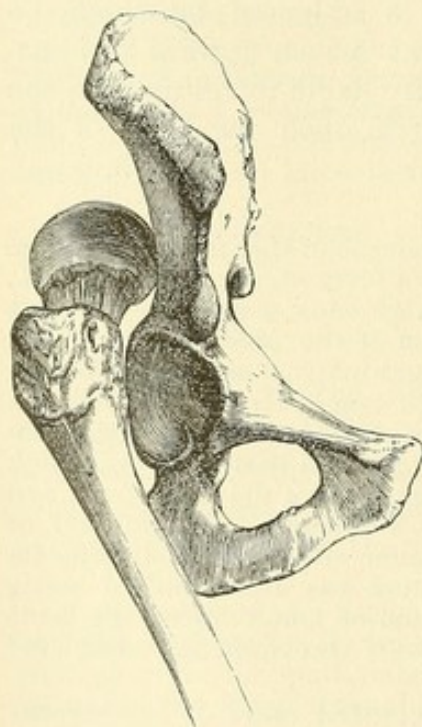
³ Poincot, op. cit., p. 1007.

⁴ Trans. New York State Med. Soc., 1855, p. 76. My report on Dislocations.

While some have ascribed it alone to the resistance of the muscles, others have with equal confidence ascribed the opposition to an entanglement of the head and neck of the bone in the rent capsule, or to the resistance offered by certain untorn ligaments; and still others believe that the impediment ought to be looked for sometimes in the muscles and sometimes in the untorn portion of the capsule.

Sir Astley Cooper thought that the capsular ligament was generally too much torn to offer any impediment to reduction, and he refers to some dissections in confirmation of this opinion. Nathan Smith affirmed that the chief obstacle to reduction by extension was to be found in the resistance offered by the glutei muscles, which, although at first relaxed, would soon become tense under the stimulus of the extension, and which, in order that the bone might resume its position, must actually be stretched considerably beyond their normal length.¹ W. W. Reid declares that the sole resistance is at first in the abductors and rotators, but that finally the *psoas magnus*, *iliacus internus*, and *triceps adductor* become tense when the pulleys are employed.² Chassaignac recognizes no other impediment to reduction than the contractions of the muscles.³ Parmentier, in a dissection, found the head imprisoned between the *pyramidalis* and *ob-*

FIG. 433.



Dislocation upon the dorsum illi.

turator internus; while Servier⁵ found the head and neck strangled between the *pyramidalis* and the *glutæus medius*.

Dr. Fenner, of New Orleans, gives the particulars of a dissection of the hip of a man admitted into the Charity Hospital, who died from injuries received by the bursting of a steamboat boiler. His condition being considered hopeless, no attempt was made to reduce the dislocation. The limb was shortened one inch and a half, and the toes turned inward. Extensive ecchymosis existed. On raising the *glutæus maximus* and *medius*, the naked head of the femur was found lying on the *dorsum illi* with the *ligamentum teres* hanging to it, but partially torn off. Portions of the *obturator externus*, *pyriformis*, and *gemelli*, were ruptured and lacerated. The capsule was torn through one-half of its extent. Dr. Fenner now proceeded to cut away the muscles, and when all the external muscles about the joint had been removed the thigh could not be brought down; the *iliacus internus* and *psoas magnus* were then severed, which permitted it to descend a little, but the head could not be replaced; the *triceps adductor* was then divided without effect. The *ilio-femoral* ligament was found tensely stretched.

All the muscles between the pelvis and the thigh were then severed, and still it was impossible to reduce the dislocation; the head of the femur could not be forced back through the rent in the capsule from which it had escaped; and it was not until the opening was enlarged from one-half to three-quarters of an inch, that the reduction was accomplished.

Dr. Fenner infers that the capsule possesses sufficient elasticity to allow the small head of the femur to pass out through a lacerated opening, which might

¹ Surgical Memoirs by N. R. Smith, 1831.

² Buffalo Med. Journ., 1851. Trans. N. Y. State Med. Soc., 1852.

³ London Med. Times and Gazette, Dec. 1865, p. 661.

⁴ Parmentier, Bull. Soc. Anat., Paris, 1850, p. 177.

⁵ Servier, Bull. Soc. Chir. Paris, 1863, p. 485.

at once contract, so as to offer considerable resistance to its return, and that occasionally this is the true explanation of the difficulty in reduction.¹

Prof. Gunn, of Chicago, says: "In dislocations of the hip and shoulder, the untorn portion of the capsular ligament, by binding down the head of the dislocated bone, prevents its ready return over the edge of the cavity to its place in the socket; but its return can be easily effected by putting the limb in such a position as will effectually approximate the two points of attachment of that portion of the ligament which remains untorn."²

Dr. Moore, of Rochester, who has often repeated the same experiments upon the cadaver, declares, also, that in attempting to reduce the femur by extension

FIG. 434.

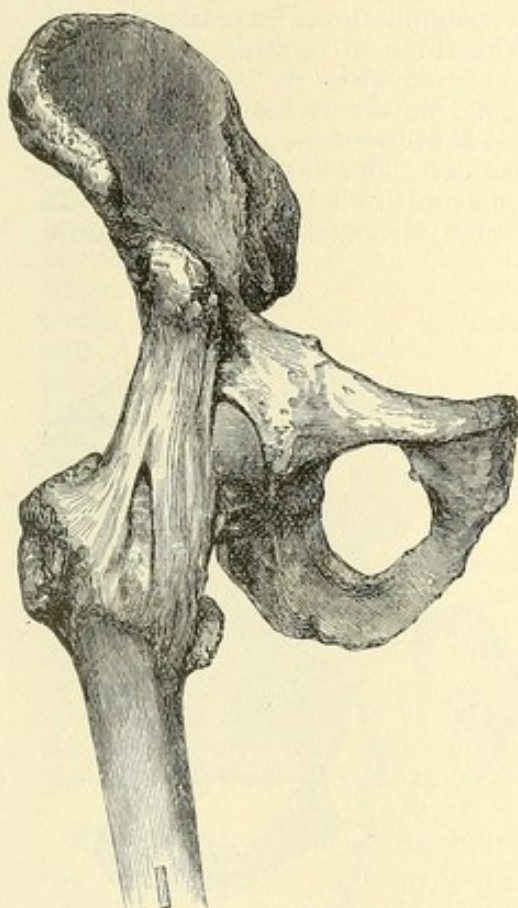
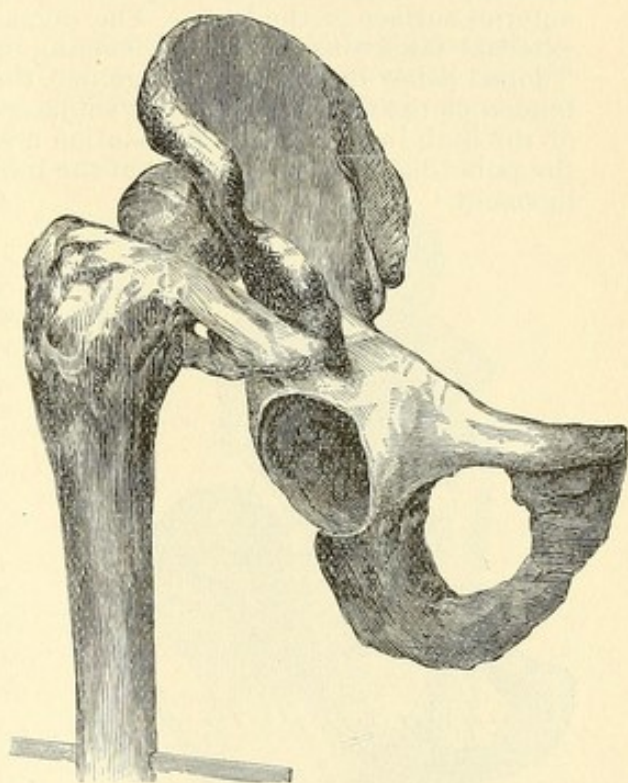


FIG. 435.



Ilio-femoral ligament. (Bigelow.) Dislocation upon the dorsum ilii. (Bigelow.)

alone he has constantly observed that the untorn portion of the capsule offered the main resistance, and that reduction could not be accomplished until this was more completely broken up.³

Busch, of Bonn, has arrived at similar conclusions;⁴ as also Professors Roser, Weber, and Gellé.

Professor Von Pitha declares that upon a knowledge of the *ilio-femoral ligament* is based the correct understanding of the various forms of hip-joint dislocations.⁵

¹ New York Journ. Med., Sept. 1848, p. 268, from New Orleans Med. and Surg. Journ., July, 1848.

² Gunn, Paper read before the Detroit Medical Society by Moses Gunn, M.D., A.M., LL.D., Professor of Surgery, Rush Med. College, Peninsular Journal, Sept. 1853.

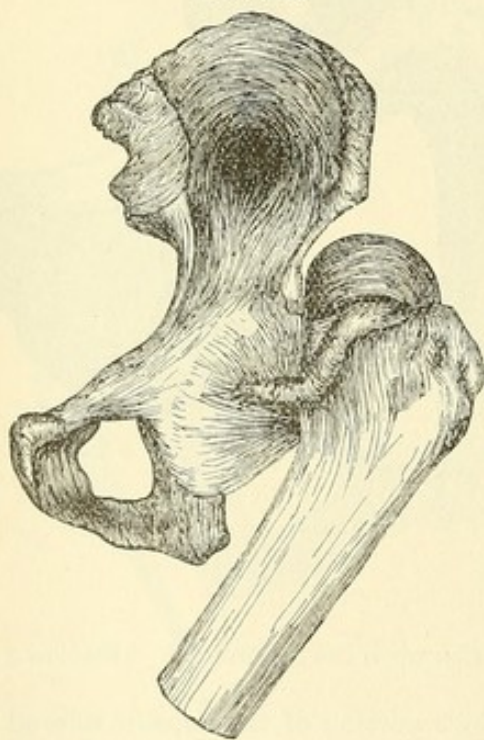
³ New York Journ. Med., Jan. 1855.

⁴ Year-Book of Med. and Surg. for 1864. Sydenham Soc. Publications; from Archives of Clinical Surgery, vol. iv. part i. Berlin, 1863. (Poinsot.)

⁵ Von Pitha's and Billroth's Surgery, vol. iv., 1865. (Poinsot.)

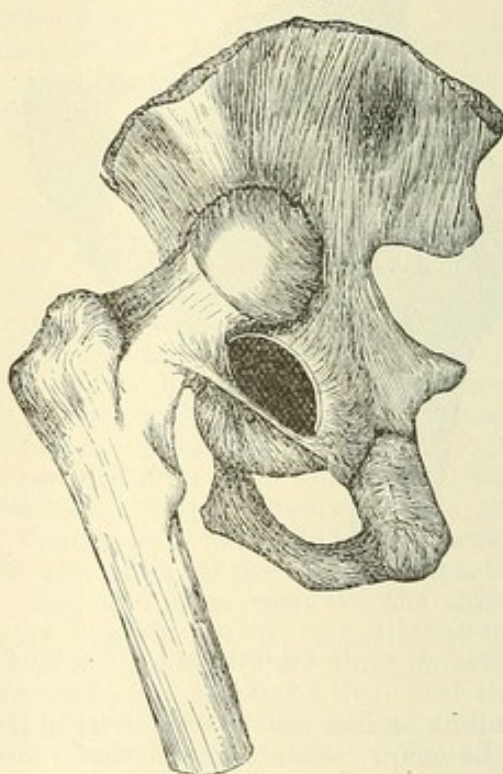
A very elaborate exposition of the relations of the ilio-femoral ligament to these accidents has been furnished by Dr. Henry J. Bigelow, the Professor of Surgery in Harvard University. The following is a brief summary of his opinions. The ilio-femoral ligament, called by Dr. Bigelow the Y-ligament (Bertin's ligament), the internal obturator muscle, and that portion of the capsule of the joint which is immediately subjacent, are alone required to explain, and are chiefly responsible for, the phenomena of the four regular dislocations. The regular dislocations are those in which complete disruption of the ilio-femoral ligament has not taken place. The irregular dislocations are those in which the ilio-femoral ligament has suffered complete disruption. In reducing either of the regular dislocations the limb must be flexed, in order to relax the ilio-femoral ligament; but if other portions of the capsule are not sufficiently torn to admit the return of the head within its socket, it must be torn by circumduction of the limb. After flexion, and perhaps circumduction, the reduction may be completed by rotation, or by extension of the thigh at right angles with the anterior surface of the body. The dorsal dislocation owes its inversion to the external fasciculus of the ilio-femoral ligament. In the ischiatic dislocation, "dorsal below the tendon" (Bigelow), the head is arrested, in extension, by the tendon of the obturator and the subjacent capsule. The flexion and eversion of the limb in the thyroid dislocation are due to the ilio-femoral ligament. In the pubic dislocation the ascent of the limb is finally arrested by the ilio-femoral ligament.

FIG. 436.



Anterior view, showing tense condition of anterior and inferior portion of capsule, and the loose state of the ilio-femoral portion in the dorsal dislocation. (Gunn.)

FIG. 437.



Posterior view of same specimen, showing the tense state of the anterior and inferior untorn portion of capsular ligament. (Gunn.)

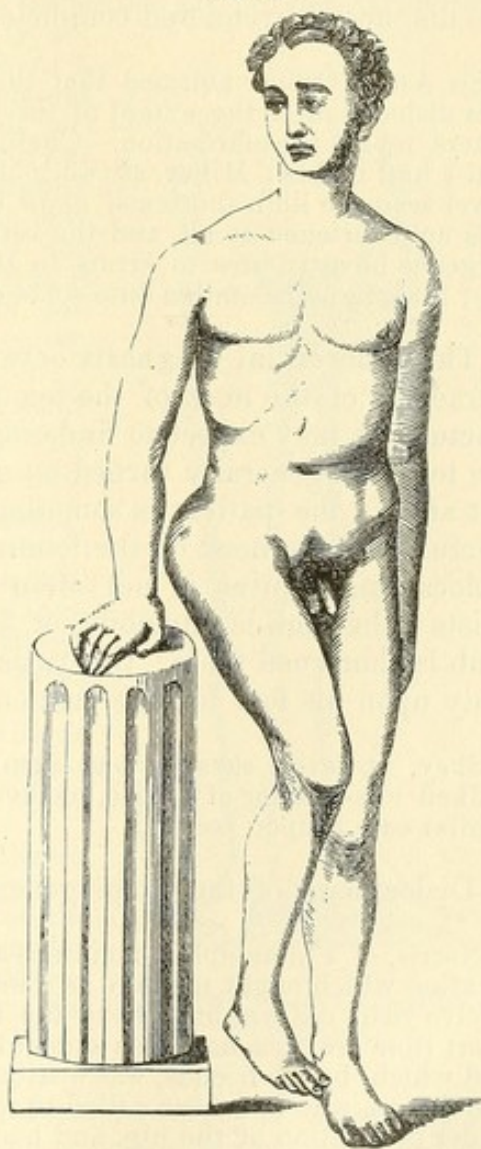
Prof. Gunn, who is not fully in accord with Dr. Bigelow's conclusions, says: "This portion of the capsule, the Y ligament, is, manifestly, much the strongest, and is probably rarely torn asunder in any of the four classical dislocations, except the thyroid, in which it is, probably always, completely ruptured, as I shall have occasion to demonstrate in the course of the present paper. Its entire want of influence in the dorsal variety of dislocation I shall also be able to show by exhibition of a dissection of the parts. . . . I desire to direct

attention to another structure which plays an assisting rôle in holding the head of the femur down outside the ridge of the acetabulum in the dorsal dislocation. If, in an intact state of the muscles and the external portion of the fascia lata, the capsular and round ligaments be completely divided, and the head of the femur be dislocated upon the dorsum of the ilium, it will be found that the characteristic deformity of direction in the limb will be wanting, *i. e.*, the limb will be parallel with its fellow, on a line with the trunk lacking the inversion and adduction, but will be shortened the usual extent. If now the limb be placed in the position characteristic of dorsal dislocation in the living subject, and the reduction be attempted by the old method of extension and counter-extension, it will be found that the head is still held down firmly in its hooked position outside of the ridge of the acetabulum. It is thus held by the *fascia lata*, which in this position of the limb describes the outermost curve, and consequently is put upon the stretch and holds the whole trochanteric end of the bone pressed firmly inward.

"These figures," continues Prof. Gunn, "as is the case in all my illustrations, are made from a dissection of the parts, which dissection I also herewith exhibit. It is seen that the anterior and inferior portion of the ligamentous capsule is untorn, tense, and holds the dislocated head firmly hooked outside the dorsal portion of the rim of the acetabulum. while that portion of the capsule between the anterior inferior spinous process of the ilium and the anterior intertrochanteric line of the femur, which is reinforced and strengthened by the ilio-femoral fibres, is quite loose, owing to the approximation of these two points, in the shortened, adducted, and internally rotated state of the limb which characterizes this form of dislocation. Thus, this ilio-femoral portion of the capsule, in the dorsal dislocation, is entirely without influence, either in determining the deformity or in opposing our efforts at reduction. It is entirely to the anterior and inferior portion of the capsule that these influences are due."

Symptoms.—The average shortening is about one inch or one inch and a half, it does occasionally reach three inches. The thigh is rotated inward, adducted, and slightly flexed upon the pelvis. The great toe of the dislocated limb, when the patient stands erect (and in this position the examination ought, if possible, to be made), rests upon the instep of the foot of the sound limb, and the knee touches the opposite thigh near the upper margin of the patella. It must not be supposed, however, that the position of the limb is in all cases precisely such as I have described. Indeed, the degree of rotation, adduction, flexion, etc., will vary according as the head of the femur is more or less displaced, the capsule, including the ligaments, more or less

FIG. 438



Dislocation upon the dorsum ilii.

torn; or as it may be torn in its upper or lower margins, as the muscles may be actually rent asunder or only put upon the stretch, and perhaps also according to the amount of injury and consequent relaxation which they may have sustained from the shock. The thigh can be easily flexed; adduction is more difficult, and abduction is almost impossible, except to a very limited extent; the body of the patient is a little bent forward, the roundness of the hip is lost in consequence of the relaxation of the glutei muscles; the trochanter major is depressed, and approaches the anterior superior spinous process of the ilium; and if the patient is not fat, and swelling has not already taken place, the head of the femur may be felt in its new position rotating under the hand when the limb is turned inward or outward, but especially may it be felt when, by flexing or extending the limb, the head is made to move downward and upward, upon the dorsum ilii. This examination ought to be made, if possible, in the erect posture; after which, it will be well to place the patient alternately upon his back, upon his sound side, and upon his belly, until the diagnosis is rendered complete.

Sir Astley Cooper affirmed that the limb was sometimes found shortened in this dislocation to the extent of three inches. Liston, B. Cooper, Gibson, and others, repeat the affirmation. Chelius places the extreme of shortening at two and a half inches; Miller, at two inches; while Malgaigne declares that he has never seen the limb shortened more than half an inch, and that in some cases it is not shortened at all, and the very opposite opinions entertained by other surgeons he attributes to errors in the measurement. I am certain, however, that Malgaigne has fallen into some error.

The differential diagnosis between dislocation upon the dorsum ilii and a fracture of the neck of the femur may be briefly stated as follows. In fracture we may expect to find crepitus; the limb is in most cases mobile; the toes are generally turned out; the limb is shortened moderately or not at all; the patient is sometimes able to walk for a short distance; fractures of the neck of the femur generally occur in advanced life. In dislocation, crepitus is not often present, and only when a fracture co-exists; the limb is immobile, or nearly so; the toes are turned in; the limb is shortened more; the patient is unable to bear the weight of his body upon his foot for one moment.

Skey, however, says he has seen a patient with a recent dislocation, who walked one-quarter of a mile, to the hospital. I do not think that any other similar case is upon record.

Dislocations of the femur generally occur in middle life.

Norris, of Philadelphia, mentions an example of hip-disease mistaken for dislocation which ought to serve as a warning to prevent similar mistakes. A lad, twelve years old was brought to the hospital from a neighboring State, who a short time previous had been suddenly attacked with lameness in his right limb, and which, by his friends, was attributed to some injury received in play. Two physicians, who had been called to see the boy, pronounced him to be laboring under dislocation of the hip, and had made two strong efforts with the pulleys to reduce it: but after causing great suffering, they gave up all hopes of ever replacing the bone, and sent him to Philadelphia. The symptoms were plainly those of hip-joint disease in its early stage. The attitude was that assumed by those laboring under this affection; the leg seemed lengthened, but a careful

measurement showed that it was of the same length with the other; the buttock was flattened, and the motions of the joint were tolerably free but painful.¹

Keen,² of Philadelphia, gives the following guide to a differential diagnosis:

Fracture of Neck.

Old persons, as a rule.
In women more frequently.
Slight force.
Eversion of toes.
Shortening in both.
If you restore to position displacement recurs.
Usually crepitus.
Preternatural mobility.
Slight prominence of great trochanter.

Dislocation.

Adult middle life.
Either sex (men more frequently).
Severe force.
Inversion of toes (usually).
Shortening in both.
If you restore to position displacement does not recur.
No crepitus.
Preternatural immobility.
Great prominence of great trochanter.]

If the supposed dislocation occurs in a child, or in a person under ten years of age, we ought to take especial pains to ascertain that it is not a separation of the epiphysis.

Examples have occasionally been reported of "everted dorsal dislocations," in which most of the usual signs of a dorsal dislocation are present, except that the limb is everted, and sometimes slightly abducted. Bigelow attributes this condition to a rupture of the outer fibres of the ilio-femoral ligament, and he affirms that under these circumstances the limb may be found inverted, but it is also easily everted; the foot may be slightly everted, it may lie flat upon the bed, or it may even point backward. The treatment of the everted dorsal dislocation consists in reducing it first to an ordinary dislocation by flexion and rotation inward, aided by adduction, if necessary.

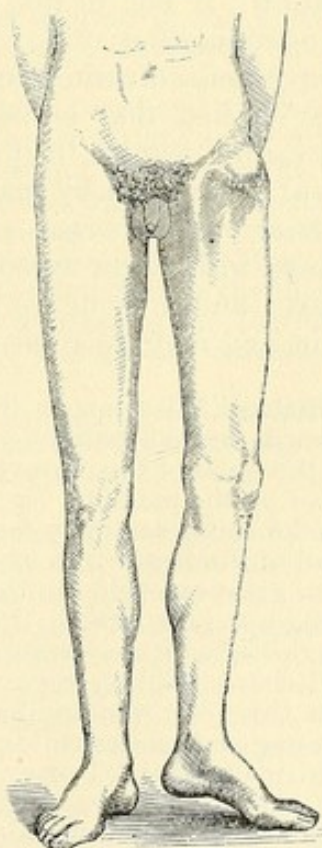
Prognosis.—In the large majority of cases the patients recover speedily, and in course of a few weeks, or months at most, the limb seems to be as sound and as useful as before.

Boyer says the limb remains always weaker than the other, the round ligament never uniting completely; and that inflammation of the cartilages and synovial glands may ensue, ending in caries of the joint. Such results have, indeed, been occasionally met with, nor are examples wanting in which more rapid inflammation, resulting in the formation of acute abscesses, has followed, but these are only rare accidents.

In one case reported from my clinic at Bellevue, the patient, aged 33, after I had reduced a recent dorsal dislocation by manipulation, walked on the fourth day; and on the seventh day he ascended five flights of stairs to the amphitheatre, walking without any halt. He declared, also, that he felt no soreness or lameness about the hip.³

Examples of non-reduction, however, from an error of diagnosis, or, what is more pertinent to our present purpose, from a failure to accomplish the reduction where the attempt has been made, are numerous.

FIG. 439.



Everted dorsal dislocation.
(Bigelow.)

¹ Norris, Amer. Journ. Med. Sci., vol. xxv. p. 280.

College and Clinical Record.

³ Reduction of a Dorsal Dislocation of the Femur. The Med. Record, Dec. 3, 1876, p. 780.

J. M., a German, æt. 19, related as follows: "When ten years old, I fell from a tree, a height of six feet, and dislocated my left hip. I was then living twelve miles from Heidelberg, and I was immediately taken there, but I did not see Mr. Chelius until the next morning. He took me to the University, and, before the medical class, attempted to reduce it, but he could not. During several weeks following, he tried six times, using pulleys, etc., but he could never succeed." On examination, I found the limb shortened two inches, the head of the femur lying upon the dorsum ilii; the knee was turned in, but the toes were inclined a little outward. He was able to walk rapidly, of course with a manifest halt, yet without pain or discomfort.

Treatment.—Regarding dislocations of the femur upon the dorsum ilii as the type of all the coxo-femoral dislocations, the remarks under this section may be considered applicable, with only certain qualifications, to all the others. The various methods of reduction which have been employed by surgeons may be arranged under two principal heads, namely, manipulation and extension. It is not possible, however, to classify rigidly the different procedures, so as to bring them under these two simple divisions, without some violence; since neither manipulation nor extension has usually been employed alone, but almost always some degree of extension has been recommended in connection with the manipulation; if not in the first instance, at least in the event of the failure of manipulation alone; while, on the other hand, extension is seldom if ever practised without manipulation. By these designations respectively, it is implied that either manipulation or extension has constituted the prevailing feature in the treatment.

(a) **Reduction by manipulation** dates from the earliest records of our science. Hippocrates says: In some the thigh is reduced with no preparation, with slight extension directed by the hands, and with slight movement; and in some the reduction is effected by bending the limb at the joint and making rotation.¹

Richard Wiseman, in 1676, speaks as follow: "If the thigh-bone be luxated inward, and the patient young and of a tender constitution, it may be reduced by the hand of the surgeon, viz., he must lay one hand on the thigh, and the other on the patient's leg, and having somewhat extended it toward the sound leg, he must suddenly force the knee up toward the belly, and press back the head of the femur into its acetabulum, and it will snap in. For there is no need of so great extension in this kind of luxation; for the most considerable muscles being upon the stretch, the bowing of the knee as aforesaid reduceth it; yet in rough bodies it may require stronger extension."²

Richard Boulton repeated, in 1713, almost the same instructions, affirming that this plan was applicable especially to dislocations inward, in the case of "young and tender children."³

In 1842, Daniel Turner declared that he had reduced three dislocations of the hip, one of which was a backward dislocation, by a method combining extension with manipulation, but alone "by the strength of the arm or without any other instrument." Extension and counter-extension being made by assistants, and "as soon as the surgeon perceives the bone moving out," says Turner, "let him take his opportunity, giving orders to the extenders below suddenly to lift up the patient's thigh toward his belly, pressing with his hands either to the right or left, as the situation of the same requires, and therewith force back its head

¹ Works of Hippocrates, Syd. ed., vol. ii. p. 643.

² Eight Chirurgical Treatises. By Richard Wiseman, Serjeant-Chirurgion to King Charles II. London, 1676. Book vii. chap. viii.

³ A System of Rational and Practical Surgery. By Richard Boulton. London, 1713, p. 346.

toward the acetabulum, whereunto it will, flipping over the tip of the cartilage, snap sometimes with a loud noise."¹

Thomas Anderson, surgeon, of Leith, in Scotland, was called, in Sept. 1772, to see a man who had dislocated his left femur into the foramen thyroideum. When he arrived four other surgeons were present, and prepared to use the pulleys, which they did in his presence several times, but to no purpose. After examining the limb carefully, "I was convinced," says Mr. Anderson, "that attempting the reduction in the common method, with the thigh extended, was improper, as the muscles were all put on the stretch, the action of which is, perhaps, sufficient to overbalance any extension we can apply. But by bringing the thigh to near a right angle with the trunk, by which the muscles would be greatly relaxed, I imagined that the reduction might more readily take place, and with much less extension. When I made this examination, he was lying on a table on his back. I raised the thigh to about a right angle with the trunk, and, with my right hand at the ham, laid hold of the thigh, and made what extension I could. From this trial I found I could dislodge the head of the bone. At the same time that I did this, with my left hand at the head and inside of the thigh, I pressed it toward the acetabulum, while my right gave the femur a little circular turn, so as to bring the rotula inward to its natural situation; and on the second attempt it went in with a snap observable to the gentlemen standing around, but more so to the poor man, who instantly cried out he was well and free from pain. His knees could then be brought together; the legs were of the same length, and the foot in its natural situation. The knees were kept together for some time, with a roller, to confine the motion of the thigh; and in three weeks he was at his work, without the least stiffness in the joint." Subsequently Mr. Anderson reduced, by a similar method, a dislocation upon the dorsum ilii in a child eight years old, and which had been out nineteen days.²

Says Pouteau, in a memoir on dislocations of the thigh upward and outward: "We observe, then, first, that the thigh ought to be flexed to a right angle with the body during the extension and counter-extension; second, that we ought to rotate the thigh from within outward, when the extension appears to be sufficient; third, that this position puts into relaxation, as much as possible, the triceps and gluteal muscles, which oppose the chief resistance to the extension, thus saving the patient from excessive pain; fourth, that the flexion of the thigh places the head of the bone in the best position for a return to the cotyloid cavity during extension; fifth, that feeble extension suffices for reduction, because all the muscles of the thigh are relaxed."³

On the 7th of January, 1811, Dr. Philip Syng Physick, of Philadelphia, reduced an outward dislocation of the hip, after extension had failed, by flexing the thigh to a right angle with the body, and then giving to the limb an "outward circular sweep."⁴

So early as 1815, and perhaps much earlier, Nathan Smith, Professor of Surgery in the New Haven Medical College, taught that the only correct mode of reducing a dislocation upon the ilium was to flex the leg upon the thigh, the thigh upon the pelvis, and then to carry the limb diagonally to the opposite side, whence it was to be brought outward and downward.⁵ Dr. Nathan R. Smith gave a more full account of his father's method, illustrating his views of the pathology of these dislocations, and the mechanism of their reduction, by several drawings. "The patient, being prepared for the operation by whatever means may be deemed necessary, may be placed in an attitude convenient for the operation, with the body securely fixed, by placing him in the horizontal posture, on a narrow table covered with blankets, and on the sound side. To the table his body should be firmly fixed, and this can be conveniently done by folding a sheet several times, lengthways—then applying the middle of the broad band thus made to the inner and upper part of the sound thigh—carrying its extremities under the table, crossing them beneath it, and then carrying

¹ The Art of Surgery. By Daniel Turner. London, 1742, vol. ii. p. 339.

² Anderson, Medical Commentaries, Edinburgh, 1776, vol. ii. pp. 261-4.

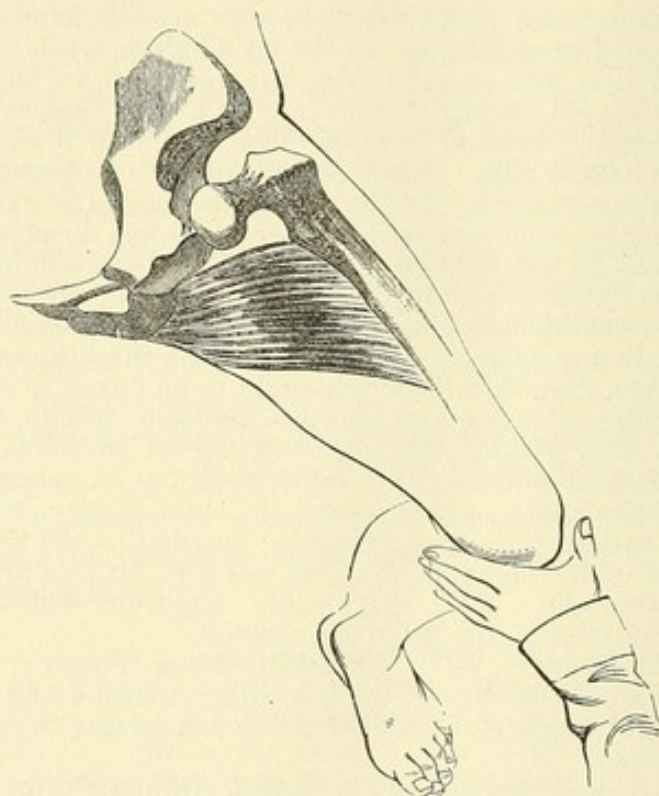
³ Vidal (de Cassis); from Œuvres posthumes de Pouteau, Paris, 1783.

⁴ Physick, Dorsey's Surg., 1813, vol. i. p. 242. Mem. of Nathan Smith, 1831, p. 172. Phelps's paper in Trans. New York State Med. Soc., 1856, p. 169.

⁵ Trans. N. H. State Med. Soc., 1854, p. 55.

them obliquely up and crossing them firmly over the trunk, above the injured hip. The ends may then be secured beneath the table. To support the trunk more firmly, a pillow may be placed on each side of it upon the table, and be included in the bandage. Should the operator design to employ any degree of extension, a counter-extending band may be placed in the perineum, and carried up to the extremity of the table, to be fixed to some more firm body, or held by the hands of assistants. The operator, now standing on the side to which the patient's back presents, grasps the knee of the dislocated member with his right hand (if the left femur be dislocated—*vice versa*, if the right), and the ankle with the left. The first effort which he makes is to flex the leg upon the thigh, in order to make the leg a lever with which he may operate on the thigh-bone. The next movement is a gentle rotation of the thigh outward, by inclining the foot toward the ground, and rotating the knee outward. Next the

FIG. 440.



Nathan Smith's method of reduction by manipulation. (From Smith's "Memoirs.")

thigh is to be *slightly* abducted by pressing the knee directly outward. Lastly, the surgeon freely flexes the thigh upon the pelvis by thrusting the knee upward toward the face of the patient, and *at the same moment the abduction is to be increased*. Professor N. Smith regarded the free flexion of the thigh upon the pelvis as a very important part of the compound movement. He believed that it threw the head of the bone downward, behind the acetabulum, where the margin of the cup is less prominent, and over which, therefore, the abductor muscles would drag it with less difficulty into its place. The operator may slightly vary these movements, as he increases them, so as to give some degree of rocking motion to the head of the os femoris, which will thereby be disengaged with the more facility from its confined situation among the muscles."¹

Dr. Luke Howe,² of Boston, who was a pupil of Nathan Smith's, gives the following account of the method practised by him successfully, about the year 1820, and which method, he says, was recommended by his preceptor: "The

¹ Medical and Surgical Memoirs, by Nathan Smith, late Prof. of Surgery, etc., in Yale College. Edited by Nathan R. Smith, Professor of Surgery in Univ. of Maryland. Baltimore, 1831, pp. 163-183.

² Boston Med. and Surg. Journ., May, 1840.

patient was permitted to lie on his back on the bed where I found him, the knee of the luxated limb turned in and over the other. I raised the knee in the direction it inclined to take, which was toward the breast of the opposite side, till the descent of the head of the bone gave an inclination of the knee outward, when I made use of the leg, being at a right angle with the thigh, as a lever to rotate the latter and turn the head of it inward. It then readily returned to its socket, with an audible snap. During this operation, the two assistants who had been placed to make the lateral extension and counter-extension, if ultimately required, were directed to draw moderately at their towels."

Kluge, in 1825, combined moderate extension with manipulation, by flexing both the leg and thigh, while at the same moment the thigh was abducted and the knee rotated inward.¹ Wathman, in 1826, directed that the limb should be seized by the knee and ankle and slowly lifted forward until it came to a right angle with the long axis of the body; when, if the outward "self-twisting of the thigh" occurs, "which cannot be prevented by fast holding," the movement of the head of the bone is declared, and it will only remain for the surgeon to let down the thigh gradually upon the bed so that the two limbs will come side by side, and the reduction will be accomplished.² Rust recommended also, in 1826, a similar plan, combining moderate extension by the hands, with flexion and abduction of the thigh.³ Colombot, whose opinions date from 1830, suggested that the patient should lay himself forward upon a bed or table, no higher than his hips, with the sound leg and foot resting upon the floor, and that then the surgeon seizing the foot with one hand, so as to flex the leg, should, with the other hand, exercise a moderate degree of extension, and at the same time move the limb to the right or to the left, backward and forward, in order to disengage the head of the femur; and, finally, that he should communicate to the thigh a sudden movement of circular rotation, either from within outward, or from without inward, as the surgeon may choose.⁴ Collin states that, in 1833, he had reduced four dislocations of the hip by a method very similar to this recommended by Colombot.⁵

Dr. Ingalls, of Chelsea, Mass., reduced a compound dislocation of the femur, in which the head of the bone rested upon the pubes, after an unsuccessful attempt had been made to reduce it by extension. "An assistant, taking the ankle of the dislocated limb in his right hand, and placing his left in the ham, bent the leg at right angles upon the thigh, and the thigh upon the pelvis, then lifting with a power little more than sufficient to elevate the whole limb, he carried it to its greatest state of abduction, at the same time rotating the femur inward, while Dr. Ingalls passed his thumb through the wound, and, pressing upon the head of the femur, directed it toward the acetabulum. At this moment he directed the limb to be forced toward its fellow, by which the reduction was effected with the greatest possible ease and elegance."⁶ Similar methods of reduction, with only such slight variations as scarcely deserve a special notice, have been suggested and practised from time to time by Palletta, in 1818;⁷ Desprès, in 1835;⁸ Vial, in 1841;⁹ Fischer, Mahr, and Clark, in 1849.¹⁰

In 1851 Dr. W. W. Reid, of Rochester, N. Y., published an account of the method practised by himself successfully in three cases of dislocation upon the dorsum ilii, the first of which dated from the year 1844. His method, as applied to a dislocation upon the dorsum ilii, consists in "flexing the leg upon the thigh, carrying the thigh over the sound one, upward over the pelvis as high as the umbilicus, and then abducting and rotating it."¹¹ Dr. Markoe, of New York, adopts the same procedure, except that when the limb has been sufficiently flexed and abducted, he directs that the limb shall be gradually brought down, and he affirms that it is during this last manoeuvre that he has usually found the bone resume its place in the socket.¹² Bigelow, of Boston, declares, as has already been stated, that in all the regular dislocations, that is to say, in all those

¹ Chelius's Surg., by South, Amer. ed., vol. ii. p. 241.

² Ibid., p. 239.

³ Ibid., p. 241, note by South.

⁴ Malgaigne, op. cit., vol. ii. p. 825.

⁵ Ibid., p. 823.

⁶ Ingalls, Bransby Cooper's ed. of Sir Astley's English ed., 1842, and Amer. ed., 1852.

⁷ Chelius's Surg.; note by South.

⁸ Malgaigne.

⁹ Ibid.

¹⁰ Dublin Med. Press, Dec. 3, 1851. New York Journ. Med., March, 1852.

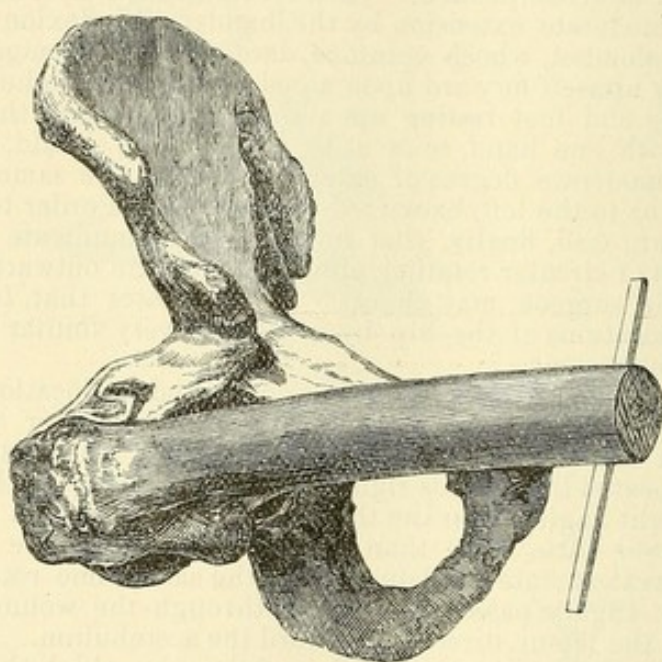
¹¹ Reid, Buffalo Med. Journ., vol. vii. pp. 139-143, Aug. 1851.

¹² Markoe, New York Journ. Med., January, 1855.

dislocations in which the ilio-femoral ligament is not torn, the thigh must be first flexed, in order to relax this ligament, and then reduction may be effected by extension directly forward, the thigh being at a right angle with the body, or by rotation. In some cases, where there is probably only a button-hole slit in the capsule, free circumduction may be required in order that the capsule may be torn more freely. His method of reducing the dislocation upon the dorsum ilii, is to flex the thigh upon the abdomen, abduct and then rotate outward; or, to flex, then adduct and rotate a little inward, to disengage the head of the bone from behind the socket, then abduct and pull directly upward. When necessary, circumduction is practised to lacerate the capsule more completely.

Prof. Gunn, of Chicago, says: "For the easy reduction of a dislocated hip or shoulder, the limb should be placed in, as nearly as possible, the same position as that which most frequently characterizes it at the instant of escape." And speaking especially of dislocations of the femur upon the dorsum ilii, he adds:

FIG. 441.



Relaxation of the ilio-femoral ligament by flexion. (Bigelow.)

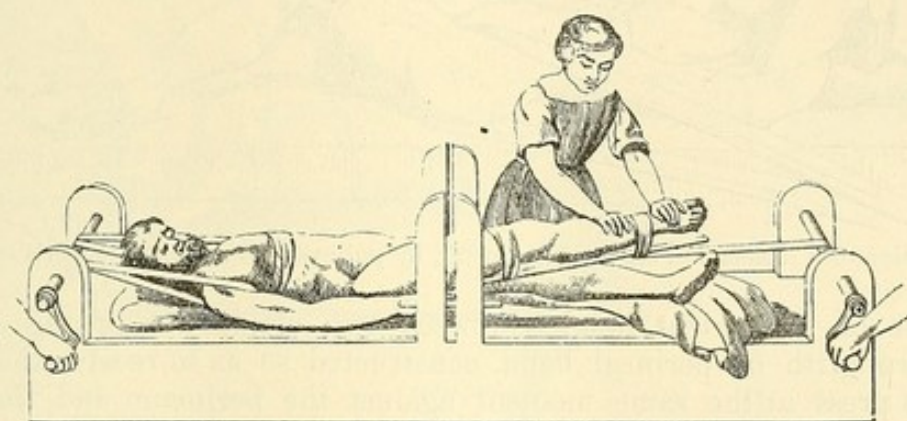
"If we now flex, adduct, and inwardly rotate to a still greater degree, we shall loosen the anterior and inferior tense untorn portion which is holding the head hooked outside the acetabular ridge, and then by a moderate amount of force we may draw the head into the socket. This is most conveniently accomplished by putting the patient on the floor on his back; an assistant fixes the pelvis; the surgeon grasps the limb, flexes and adducts it till it crosses the limb of the opposite side at a point as high as the union of the upper with the lower two-thirds of the femur; now rotating the limb inwardly, he will be able to lift the head into place by a moderate effort."

(b) **Reduction by extension** dates from a period equally early with reduction by manipulation. Hippocrates recommended, when other and gentler means had failed, to make extension and counter-extension; the extending bands being made fast above the knee and above the ankle, so as to distribute the points of pressure; and the counter-extending bands being secured around the chest under the armpits, and also, if thought necessary, in the perineum of the sound side.

Among the methods recommended and practised by Hippocrates, was sitting across the upper round of a ladder with a weight attached to the thigh of the dislocated limb; or suspending the patient from a sort of gallows with the head downward, and if the weight of the patient's own body proved insufficient, the surgeon might add his also; a method which Hippocrates characterizes as "a good, proper, and natural mode of reduction, and one which has something of display in it, if any one takes delight in such ostentatious modes of procedure."¹

With various modifications as to the position of the limb, and as to the points upon which the extending and counter-extending forces are to be applied, and with differently constructed appliances, surgeons have con-

FIG. 442.



Hippocrates's mode of reducing dislocations of the hip by extension.

tinued to employ extension down to this day. The great majority have regarded flexion of the thigh as essential to success; some holding the limb only slightly flexed, and others insisting that flexion should be increased to a right angle with the body.

The French surgeons, including Boyer and Vidal (de Cassis), prefer generally to apply the extending bands to the feet, in order that the muscles of the thigh may not be stimulated to contraction by the pressure of the bandages. Erichsen, and the English surgeons generally, make fast the lacq above the knee. The French, and most of the American surgeons, recommend the same; but Gerdy seeks to multiply the points of application, and for this purpose secures the extending band to the whole length of the leg, and to a small portion of the thigh above the knee.

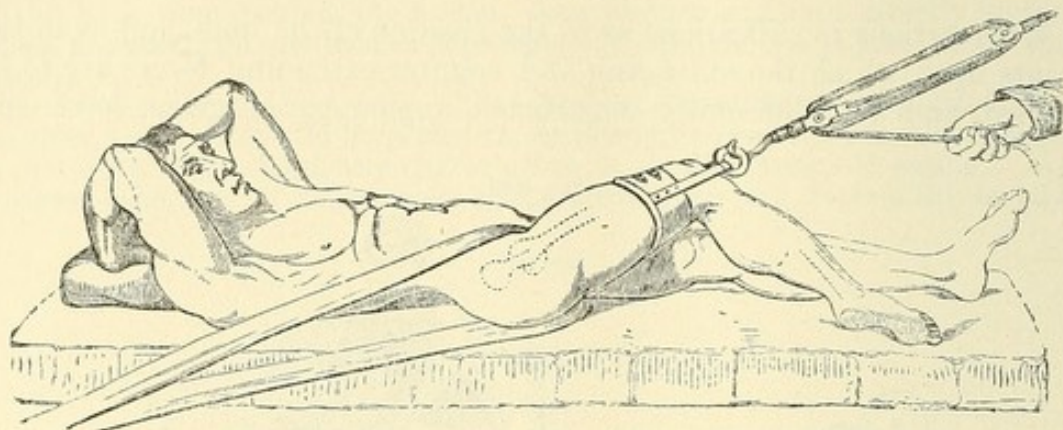
The counter-extending bands are now almost universally made to operate against the perineum of the dislocated limb, but Roux, following the practice of Hippocrates, places it in the perineum of the sound limb. Gibson recommends the same practice. Lizars recommends that sometimes the reduction should be attempted by simply placing the heel in the perineum and making the extension with the hands, very much as Sir Astley Cooper advises us to proceed in dislocations of the humerus. Morgan and Cock, of Guy's Hospital, have reduced six cases of dislocation of the hip-joint by placing the foot between the thighs, so that it pressed against the upper part of the dislocated bone, and thrust it away from the pelvis; extension and rotation of the limb being made at the same time by assistants.² Three of these were examples of dislocation upon the dorsum ilii, two upon the pubes, and one into the foramen thyroideum; and most of them had occurred in weak or elderly persons.

¹ Works of Hippocrates, Syd. ed., London, vol. ii. p. 641.

² Cock and Morgan, Chelius, op. cit., vol. ii. p. 242, note by South.

Ambrose Paré was among the first to recommend the use of pulleys for the reduction of dislocations. Most surgeons since his day have employed them for the purpose of making extension more energetic and steady, and that it might be longer continued. Sir Astley Cooper's plan of procedure is as follows: The patient is to be placed on his back upon

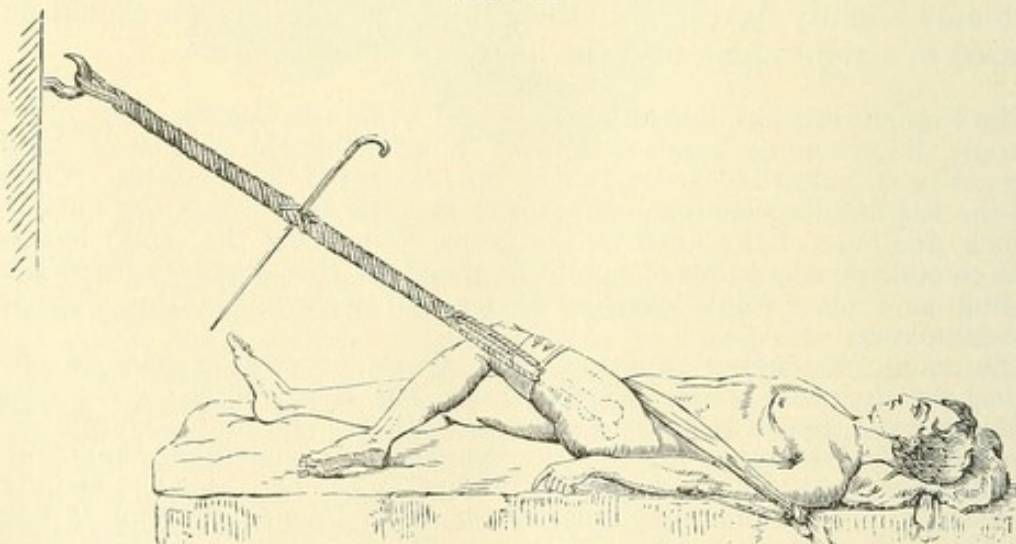
FIG. 443.



Reduction of a dislocation on the dorsum ilii, by pulleys. (Sir Astley Cooper's method.)

a table of convenient height between two staples; a strong padded leathern girth or perineal band, constructed so as to receive the thigh, and to press at the same moment against the perineum and the outer surface of the pelvis, is then applied and made fast to one of the staples situated behind the patient in the direction of the axis of the limb. A wetted linen roller is next to be tightly applied just above the knee, and

FIG. 444.

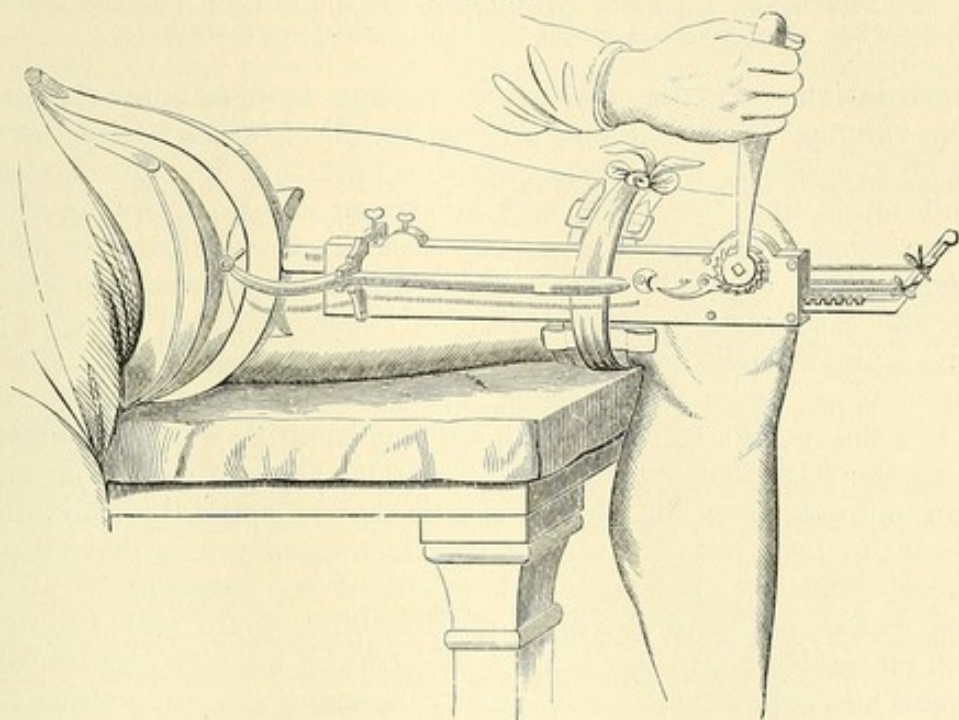


Reduction of a dislocation on the dorsum ilii, by the Spanish windlass. (Gilbert.)

upon this a leathern strap is to be buckled, having two short straps with wings at right angles with the circular part; or, instead of this, a round towel made in the knot called the clove-hitch. The knee is to be slightly bent, but not quite to a right angle, and brought across the opposite thigh a little above the knee. The pulleys being now attached, the extension is to be commenced.

A very simple and efficient mode of making the extension, if one has not the pulleys, is to employ for this purpose a small rope, the ends being tied together, and the rope being then doubled upon itself once or twice, so as to make four or eight parallel cords. The opposite ends of this bundle of ropes being made fast to the limb and the staple, the extension is made by thrusting a stick through its centre and twisting it. (Fig. 444.)

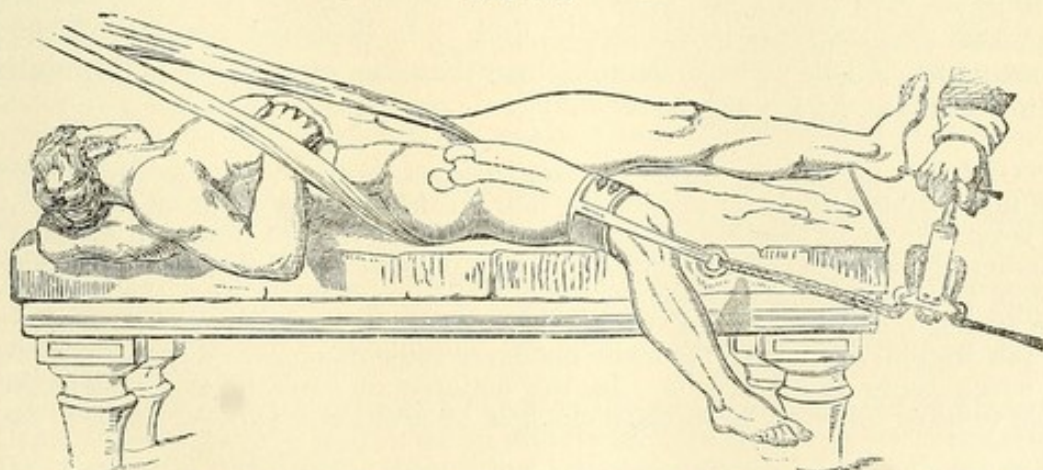
FIG. 445.



Jarvis's adjuster applied for reduction of a dislocation of the hip.

I have several times had occasion to resort to this plan; and indeed it has been for some time known and practised among surgeons in this country,¹ having

FIG. 446.



Bloxham's "dislocation tourniquet" applied for reduction of a dislocation on the pubes.

been first, according to Professor Gilbert, introduced by Fahnestock, of Pittsburg, Pa. It is usually known as the "Spanish windlass."

¹ Gilbert, of Philadelphia, note to Pirrie's Surg.; also Amer. Journ. Med. Sci., vol. xxxv., April, 1845.

Jarvis's adjuster, to which I have already made allusion when speaking of dislocations of the humerus, has been often used with success in dislocations of the hip as well as in dislocations of the shoulder.¹ Its power is equal to that of the pulleys, while the direction of the force can be varied with much greater ease.

Sédillot, a French surgeon, has suggested that when pulleys are used, we should measure the exact power employed in the reduction, by an ingeniously contrived apparatus called the dynamometer,² and which has been variously modified by Charrière, Mathieu, Robert, and Collin.³ Such an instrument might occasionally be useful in preventing the application of excessive force, especially when the patient is under the influence of an anæsthetic.

Appreciation.—Finally, without attempting to determine the precise relative value of these different procedures, all of which claim the testimony of experience, I am prepared to admit that no one of them is without merit, and that each may in certain cases possess advantages over the others. Precisely what the cases are to which each individual method may be especially applicable it would be impossible to declare unless the cases were actually before me; and even then it would probably be found difficult often to say which was the best until a fair trial of one or more, and a final success, had determined the question. The time has not yet arrived in which we may institute a rigid comparison between the relative merits of the two leading plans of reduction, manipulation and extension, for while it is true that reduction by manipulation has been practised from the earliest day, it is equally true that extension has been generally preferred and practised by surgeons in all ages. Indeed, it was not until Dr. Reid, of Rochester, again called the attention of the profession to this subject, illustrating his views by the results of several successful experiments and by ingenious arguments, that reduction by manipulation could be said to have been fairly introduced as an established method of practice.

The following summary of a paper prepared by myself, with the view of determining, if possible, the relative value of the two methods, and exhibiting an analysis of sixty-four cases in which manipulation was employed, will enable the reader to form some estimate of the difficulty in which this subject is involved; and if it does not actually decide a moot point, it will at least demonstrate that the method by manipulation is not without its hazards.⁴

"Of forty-one cases in which the fact is stated, twenty-eight were reduced on the first attempt, seven on the second, four on the third, and two on the seventh. In seven examples the head of the femur has been thrown from one position to another upon the pelvis, travelling from the dorsum of the ilium to the ischiatic notch, and from thence to the foramen ovale; or directly from the dorsum to the foramen, and back again; or in other directions, according to the character of the original dislocation; in some instances these changes being made as often as seven times in succession. In the majority of cases no evil consequences seem to have followed upon these changes of position. One of my own cases

¹ Crandall, Boston Med. and Surg. Journ., vol. xxxix. p. 77; Atlee, Trans. Amer. Med. Assoc., viii. p. 357, 1850.

² Amer. Journ. Med. Sci., vol. xv. p. 530.

³ Poinot, op. cit., p. 1038.

⁴ Reduction of Dislocation of the Femur by Manipulation. By the Author. Buffalo Medical Journal, Nov. 1857; Feb., March, June, 1859. With tables constructed by my very intelligent pupil, Lucien Damainville.

will especially serve to show with what impunity sometimes these changes may be made.

"J. C., æt. 28, was admitted to the Buffalo Hospital of the Sisters of Charity with a dislocation of the left femur upon the dorsum ilii, which had occurred six days before. No attempt had been made to reduce the dislocation. Five times in succession manipulation made by myself failed, leaving the head of the bone each time upon the dorsum ilii; the sixth attempt, made with the addition of moderate extension by the hands, threw the head into the foramen thyroideum. By reversing the movements, it was easily replaced upon the dorsum ilii. The seventh trial was made in the same manner, except that when I supposed the head of the bone to be opposite the lower margin of the socket I did not permit the limb to turn either outward or inward, but while lifting at the knee with my hands, with sufficient power to raise his hips from the table, I brought the limb down gradually to a line parallel with the opposite, and thus finally the reduction was accomplished. No pain or inflammation followed, and in two weeks he left the hospital; but whether he was able to walk or not at that time, I am unable to say."¹

The following cases have come to my knowledge: Dr. James R. Wood attempted, at the Bellevue Hospital, the reduction of a dislocation of the femur upon the dorsum ilii, of five months' standing, in a man 60 years of age. The patient was under the influence of ether. Manipulation alone was employed. Probably half an hour had been consumed in the various efforts, when at a moment when the thigh was being forcibly abducted, the neck was broken within the capsule, and very close to the head. I was able to feel the head of the bone distinctly, after the fracture, and to move it freely separated from the neck. Dr. David Prince, of Illinois, who was present at the time, informed me that he had himself fractured the neck of the femur in attempting the reduction of an ancient dislocation of the hip by manipulation.

In Markoe's paper,² several papers similar to my own are reported, in which the results have been equally fortunate; but the case mentioned as having been under the cure of Dr. Post, had a more serious termination. This patient, æt. 21, had a dislocation into the ischiatic notch, and on the same day the reduction was attempted by manipulation. On the first trial the head of the bone was thrown into the foramen ovale; and, after having been moved backward and forward between these two points several times, it was finally carried directly from the foramen ovale into the socket by manual extension applied in the ordinary way, but without pulleys. "In this case," says Markoe, "the cure was very slow, and he left the hospital with some degree of pain and swelling about the joint. I learned that an abscess formed in or about the joint, which was opened, and when I saw him, a year after, there was every appearance of seated morbus coxarius." In Case 14, of Markoe's paper, the thigh was broken at the neck after manipulation had been employed, but while extension was being made by the hands, united with "a lifting outward." Whether the fracture was due to the extension, or to the manipulation, seems not to be clearly determined. The dislocation had existed seven weeks when this attempt at reduction was made.

Dr. Bigelow has reported a case of dislocation upon the dorsum, of six months' standing, in a man 23 years of age, which he attempted to reduce, and caused a fracture of the neck of the femur. His account of the manner in which the accident occurred is as follows: "I flexed the limb once slowly upward upon the abdomen—a movement which was attended with a continued fine crepitation about the hip." Upon examination, the head of the bone was found to be separated from the neck.

Dr. Dawson has reported a case in which this accident occurred in his hands. Captain Williamson, a gentleman in middle life and fair health, was received at Dr. Dawson's clinic with a dislocation into the ischiatic notch of nine weeks' standing. He was placed under the influence of ether, and various methods of manipulation employed. At last "more force was used, the thigh was pressed forcibly across the abdomen," and this was followed by rapid circumduction.

¹ Buffalo Medical Journal, vol. xiii. p. 682.

² New York Journ. of Med., Jan. 1855.

At the sixth repetition of this manœuvre, the neck of the bone suddenly gave way.¹ Dr. J. S. Wight, of Brooklyn, broke the femur in an attempt to reduce a dislocation of four months' standing. The patient was 53 years old, and the head of the femur was thought to be in the ischiatic notch. Under ether the thigh was flexed upon the body, and then adducted with moderate force, when it broke with a loud snap just below the trochanter. The fragments subsequently united.²

I have succeeded in collecting sixty-two cases of attempts at reduction by extension; a great majority of which, we find, were reduced in the first trials; but five cases of recent dislocation were not reduced until after several attempts had been made. In five cases the femur was broken. The first occurred in St. Thomas's Hospital, London. B. W., æt. 40, was admitted with a dislocation into the ischiatic notch, of twenty-two weeks' duration. An attempt was made to reduce the bone by pulleys, in which the reporter professes to believe they were successful, but on the following day it was plainly enough not in place. Mr. Travers again resorted to extension, and while extension was kept up and the assistants were rotating the limb outward, the neck of the femur gave way.³ Malgaigne mentions a case in which, while he was himself directing the operation, the thigh was broken through its lower third. He was attempting to reduce the bone by extension, but it was not until he gave the signal for rotation outward that the bone gave way.⁴ Gibson says that Dr. Physick, at the Pennsylvania Hospital, while engaged in reducing a dislocated thigh by the pulleys, broke the femur in consequence of exerting too much force upon it in a lateral direction by an additional pulley; and that a similar accident is supposed to have happened to Drs. Harris and Randolph in the same hospital, in the year 1838, while using the pulleys upon a boy 12 years of age; for during the extension and counter-extension, at the moment of rotating the limb, and of drawing it forcibly outward by a towel, a sudden crack was heard.⁵ The fifth case is related by Sir Astley Cooper as having occurred at the Brighton Hospital, under the care of Mr. Gwynne; the dislocation was upon the dorsum ilii, and was supposed to have existed about one month. The neck of the femur was broken in the first attempt at reduction, and while the surgeon was making extension, with gentle rotation.⁶

Sir Astley says: "There are plenty of cases upon record, of fatal abscesses from violent attempts at the reduction of dislocated hips." I presume that this remark has reference to attempts at reduction by extension, since, in his day, this was almost the only mode in use among surgeons. He adds, moreover, that Mr. Skey has mentioned a fatal case of phlebitis following protracted extension of the thigh. Malgaigne has collected no less than eight similar examples, with several more in which serious consequences and even death followed promptly upon violent attempts at reduction by mechanical means.⁷

Marchand⁸ has reported three cases of paralysis ensuing upon attempts at reduction by extension; in one of which, however, some doubt remains as to whether it was due to the extension.

The head of the bone has been repeatedly thrown from the dorsum ilii into the ischiatic notch; and B. Cooper mentions a case in which the bone was carried from the foramen ovale into the ischiatic notch, from which latter position it could not afterward be changed.⁹

As to the relative chances of failure by the two methods, the testimony of the recorded cases is equally unsatisfactory. Of the failures by extension, the experience of almost every surgeon, the journals, and the treatises furnish a sufficient number of examples; while among the

¹ Dawson, *The Clinic*, Oct. 17, 1874. ² Wight, *Hosp. Gazette*, Sept. 13, 1879.

³ *London Med.-Chir. Rev.*, Nov. 1828, p. 239.

⁴ Malgaigne, *op. cit.*, vol. ii. pp. 146 and 830.

⁵ Gibson's *Surgery*, sixth ed., vol. i. p. 389.

⁶ Sir Astley Cooper on *Disloc.*, Amer. ed., p. 88.

⁷ Malgaigne, *op. cit.*, vol. ii. p. 164 et seq.

⁸ Marchand, *Thèse d'agrégation*, Paris, 1875, p. 76.

⁹ Sir Astley Cooper on *Disloc.* By Bransby Cooper, Amer. ed., p. 96.

sixty-four cases of attempts at reduction by manipulation collected by me, and, excepting the cases in which the bone was broken, only two were positive failures.

It is somewhat remarkable, however, that these two cases occurred in the experience of the New York City Hospital; and that they are taken from a total of fifteen, this being the whole number which had been treated by this method at the date of these observations, in the New York Hospital. One had existed one month, and, after repeated trials by manipulation and frequent changes of position, it was finally reduced by pulleys. The other, a dislocation into the ischiatic notch, had existed only a few hours. At least seven or eight trials were made to accomplish the reduction by manipulation, but without success. The first attempt by extension failed also, but in the second attempt the femur was kept at a right angle with the body, and the bone was soon brought into its socket.¹ We have in these two examples not only a record of failure by manipulation, but an equal record of success by extension; while, on the other hand, we find, in an analysis of the sixty-four cases, sixteen triumphs of manipulation over extension.

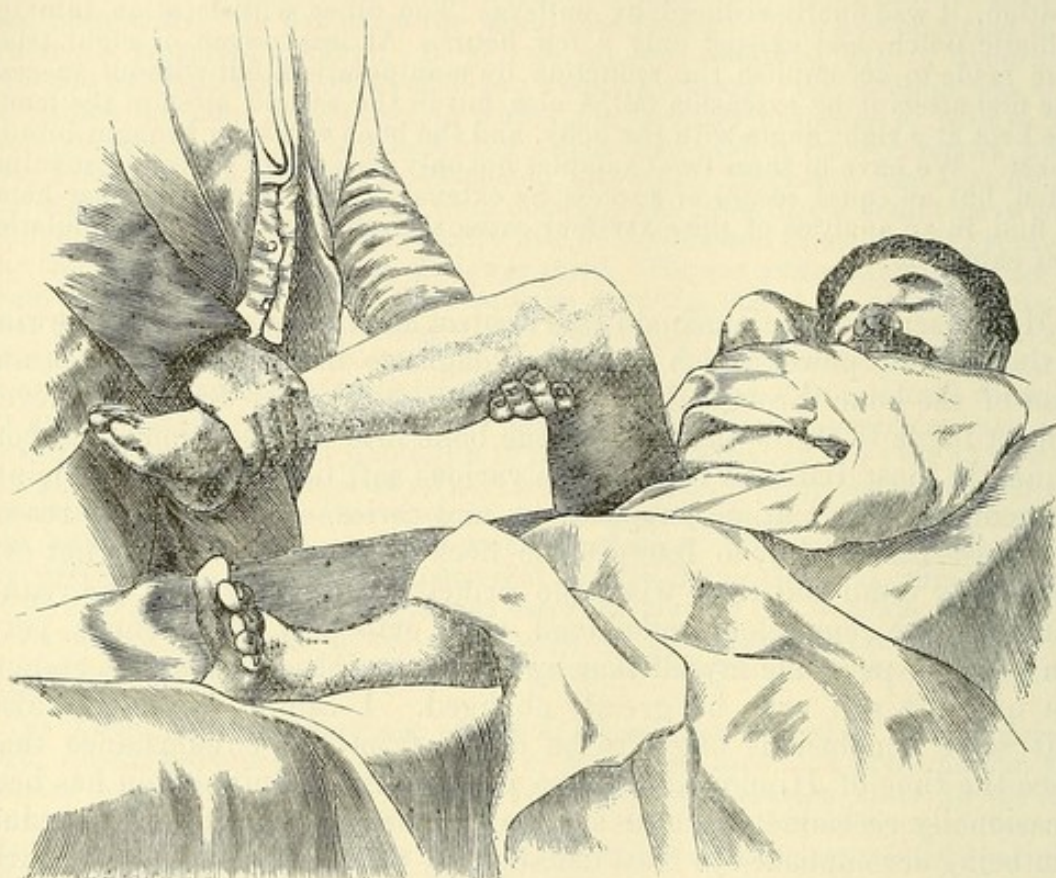
My present convictions upon this subject are that manipulation, owing to the greater power which may be brought to bear upon the neck and head of the bone through the action of the shaft of the femur as a lever, is most liable to throw the head of the bone into new positions, and consequently most liable to rupture the various soft tissues about the joint; to produce inflammation, suppuration, and caries. For the same reason it is most liable, also, to fracture the neck of the femur. It is not certain in my mind but that, when the principles which control the reduction are more completely understood, these evils may be lessened; yet I can scarcely persuade myself that by any future observations the state of the question will ever be greatly changed. I cannot but think, also, that some conclusions ought to be drawn from the circumstance that, since the time of Hippocrates to the present day, manipulation has been occasionally recommended and successful examples reported; the reduction being accomplished in most instances by processes identical, or nearly so, with those now adopted; yet generally the writers appear to have been ignorant of what had been done before, and, indeed, they have generally avowed their belief that the method suggested by themselves was altogether new and original. Possibly this slowness to establish, and total inability to sustain and perpetuate, a reputation was not the fault of the method, and had no relation to its failures. Until within a few years the number of surgical books, and especially of medical journals, was comparatively very small, so that valuable truths often died with their discoverers, or were known and remembered only by a few; but it is possible, also, that it has a deeper significance, and that it implies some defect in the procedure, or serious danger, in consequence of which it has from time to time lapsed into desuetude and finally into complete oblivion.

Method of Manipulation.—The rules which the author would give for the employment of manipulation are very simple. The patient being laid on his back upon a mattress, the surgeon, assuming that it is a dislocation upon the dorsum ilii, should seize the foot with one hand and

¹ Van Buren, New York Med. Times, Jan. 1856, p. 126.

the other he should place under the knee; then, flexing the leg upon the thigh, the knee is to be carefully lifted toward the face of the patient until it meets with some resistance; it must then be moved outward and slightly rotated in the same direction until resistance is again encountered, when it must be gradually brought downward again to the bed.

FIG. 447.



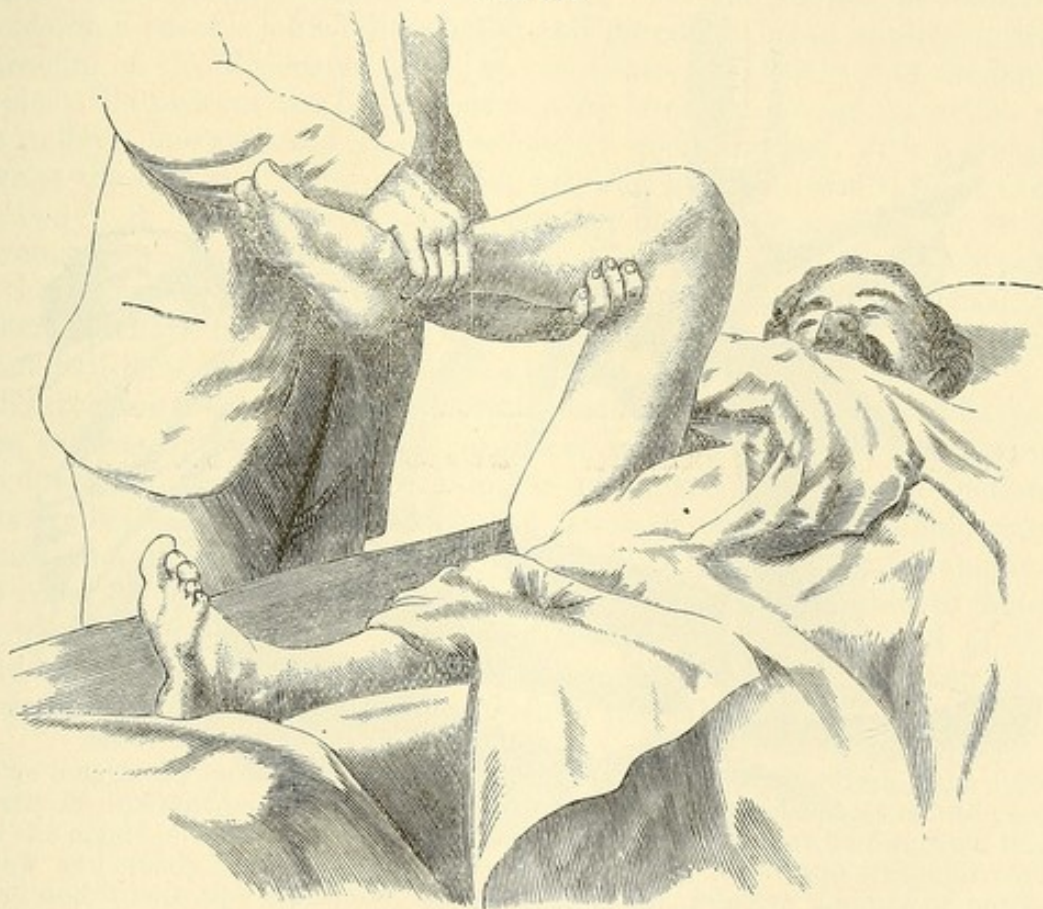The Author's method. First position.

I do not know that the whole process could be expressed in simpler or more intelligent terms than to say, that the limb should follow constantly its own inclination.

All writers have united in the necessity of flexion; and, indeed, with very few exceptions, the advocates of extension have insisted upon carrying the dislocated limb more or less across the sound one; or of making the extension at right angles with the body. They have also been nearly unanimous in their statements that the thigh should then be abducted and finally brought down. Nathan Smith has added the injunction to rotate the shaft of the femur outward, and to press gently upon the inside of the knee while the thigh is being flexed upon the body, so as to compel the head of the bone to hug the outer margin of the acetabulum and to prevent its falling into the ischiatic notch; a suggestion which has been erroneously interpreted by some writers to mean that he would carry up the limb abducted, a thing which is simply imply impossible until the reduction is accomplished. In adopting this practice, however, we must not forget the danger which we incur, when the limb is completely flexed, and the head of the femur is below the edge of the acetabulum, of throwing it over into the foramen ovale. Dr. Nathan Smith has also noticed the advantage which sometimes may be gained by giving to the limb at this moment a slight rocking motion.

These movements of the limb, with perhaps other slight modifications, such as lifting the knee moderately or forcibly when the bone refuses to mount over the margin of the acetabulum, pressing with the hand or foot upon the pelvic bones, and violent circumduction, are all which have been usually practised in successful manipulation. As a general rule, in the first trial, the knee must be carried only in those directions which offer no resistance, and these will be found almost always to be the same; the knee of the dislocated femur hanging over the sound one will be made easily to ascend to about a right angle with the body; we can then carry it outward a short distance, probably not more than four or five

FIG. 448.

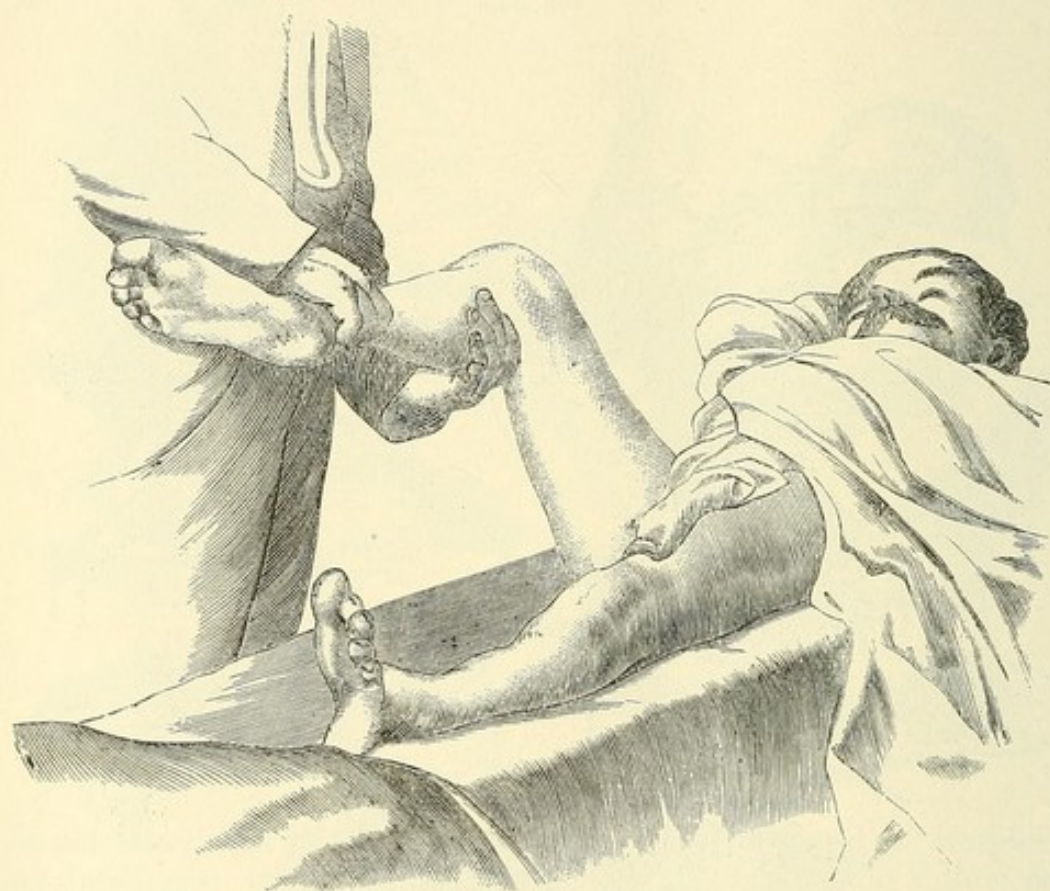


Second position. Not often required. Liable to cause secondary dislocation into ischiatic notch or foramen ovale.

degrees; at this moment, frequently, the thigh will begin to rotate outward of itself, and with considerable force, or, as Wathman says, "a self-twisting of the thigh occurs, which cannot be prevented by fast holding." When this action takes place the reduction is immediately accomplished; and it is, in fact, at this moment, before the limb begins to descend, that the bone most frequently resumes its socket. If it does not, then as soon as the limb begins to fall the reduction occurs, generally with a loud snap. It is pretty certain that this manipulation is to fail if the knee has descended more than a few inches without the reduction having taken place; and it will be better to repeat the manœuvre at once, rather than to bring the limb completely down.

Generally anæsthetics ought not to be employed, since the operation, if successful, is not usually painful, and we need that the patient should preserve his consciousness, in order to admonish us when we are using improper violence. It is probable, also, that the action of certain muscles sometimes affords material assistance in the reduction. If, however, the patient is very sensitive, or the parts about the joint are very tender, or manipulation without anæsthetics has failed, then certainly these agents may be properly and advantageously employed. If we propose to attempt reduction by extension, it is no longer necessary to resort to

FIG. 449.



Third position.

the lancet, antimony, and the hot bath, as preliminary measures, since the muscles can be at once overcome by the much more certain and more powerful agents, chloroform, ether, etc.

Method of Extension.—The method recommended by Sir Astley Cooper, and most often practised by surgeons of the present day, is essentially as follows: The patient is placed upon a bed of suitable height, reclining on his back, but partly over upon the sound side. Observing now the line of the axis of the dislocated thigh, one strong staple is to be secured into the wall upon one side of the room, and another upon the opposite side, both of which shall correspond as nearly as possible with the line of the shaft of the femur. The staple in front of the body will be higher than the bed, and the staple behind will be, in the same proportion, lower than the bed. The limb being stripped, two pieces of strong factory cloth, each about four inches wide and two feet long, should

be laid parallel with and on each side of the limb; the centre of each strip being about opposite that portion of the thigh which is just above the two condyles. Over the centre of these strips, above the condyles and patella, a strong roller, three inches wide, and at least three yards long, previously wetted in water, is to be turned as tightly as it can be drawn until the whole roller is exhausted; the extremity of the roller being made fast with a needle and thread rather than with pins. The upper ends of the side strips are then to be brought down, and tied to the lower ends, forming thus two lateral loops, upon which one of the hooks of the compound pulleys is to be made fast, while the other hook is secured to the front staple in the wall. Instead of these rollers we may employ, if we choose, a leathern thigh-belt. For the purpose of counter-extension a sheet is folded diagonally, and its centre being applied to the perineum of the dislocated limb, the ends are tied firmly into the back staple. To prevent the body from moving laterally, under the action of the pulleys, one assistant should be seated upon the bed, with his back against the side and back of the patient, and his right arm thrown over the body; it is well also to station another beside the sound limb, so as to retain it also in its place upon the bed. Underneath the upper part of the dislocated limb a strong and broad bandage should be placed, of sufficient length to tie over the neck of the surgeon when he is standing about half-bent over the body of the patient.

Everything being arranged, and all portions of the apparatus having been sufficiently tested to make sure that nothing will give way during the operation, the anæsthetic is to be administered, and as the patient falls gradually under its influence, the action of the pulleys should commence, and be slowly but steadily increased; a third assistant managing the rope, so as to leave the surgeon unembarrassed, and able to direct his whole attention to the position of the trochanter major and of the head of the femur. In order to this, he should place one hand upon each of these prominences, and watch carefully their descent.

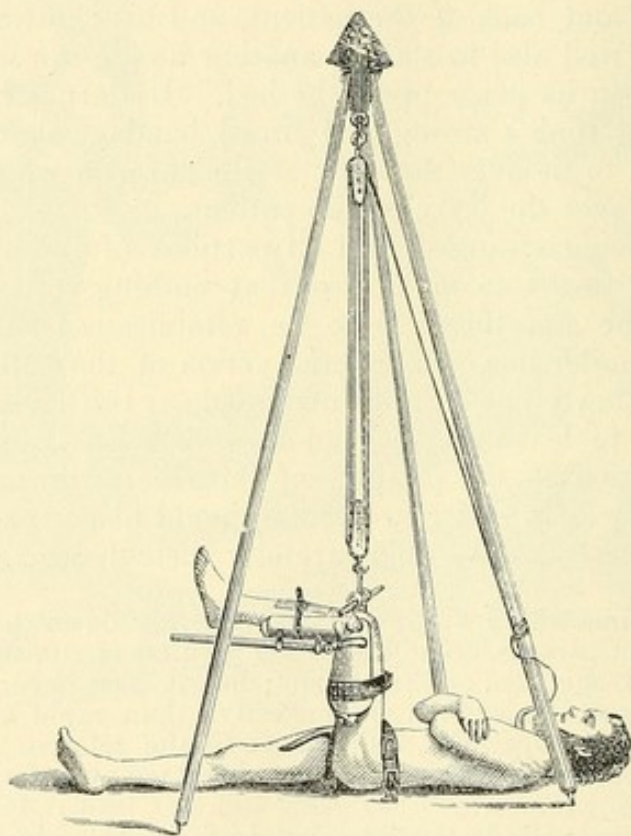
The length of time which will be required to bring down the limb must differ greatly in different persons, according to the peculiar circumstances of the case, and the condition, age, etc., of the patient; but it must never be forgotten that a slow and steady action is much more effective than rapid and irregular tractions, and it is in this especially, rather than in the relative amount of power, that the pulleys possess always so great an advantage over the hands.

When the surgeon finds that the head of the bone has nearly or quite reached the socket, if it does not take its place spontaneously, he may place his neck in the noose which passes underneath the thigh, and lift upward and outward, in order to raise the trochanter major, and thus enable the head to rotate toward the acetabulum. It is in this part of the manœuvre, and especially when at the same moment one of the assistants, after bending the leg upon the thigh so as to make of it a lever, has rotated the thigh outward, that the fracture of the neck has generally taken place; and we cannot be too cautious, therefore, particularly in old persons, not to bear very strongly upon the noose, nor to permit the assistant to rotate outward with great force. If the bone does not enter the socket, we may increase the flexion, or suddenly release the tension, or, in fine, again resort to manipulation alone. When

the reduction is accomplished, the patient should be laid upon his back, with the knees resting over a pillow, and tied together lightly with a towel or a strip of cotton cloth. In order also the more certainly to prevent a redislocation, the thigh of the dislocated limb should be gently rotated outward, by which the head will be pressed forward against the anterior portion of the capsule.

Such an accident, however, as a recurrence of the dislocation, in the case of the femur, is exceedingly rare; and I should have deemed it altogether impossible, except as the result of considerable violence again applied, had not at least two examples been reported to me upon very excellent authority. Malgaigne says he has himself seen an example of redislocation upon the *dorsum ilii*, occasioned by an untimely movement;¹ and Verneuil has seen, ten days after the reduction of a dislocation upon the ischiatic notch, the dislocation reproduced by a sudden effort of the patient to sit up;² indeed, it is when the

FIG. 450.



Tripod for vertical extension. (Bigelow.)

limb is in a flexed position that the accident seems most likely to occur. In these remarks I mean to except those cases in which the upper margin of the acetabulum is broken off, and the head of the femur has consequently lost its natural support in this direction. The possibility of this accident is also confirmed by the examples of "voluntary" dislocations, which I shall relate in the last section of this chapter.

Bigelow's Method of Lifting.—The method of extension recommended by Dr. Bigelow, namely, with the thigh at a right angle with the body, has already been referred to; and there is much reason to believe that, as a rule, it is preferable to extension as practised by Sir Astley Cooper. Nearly all surgeons, however,

¹ Malgaigne, *op. cit.*, tom. ii. p. 830.

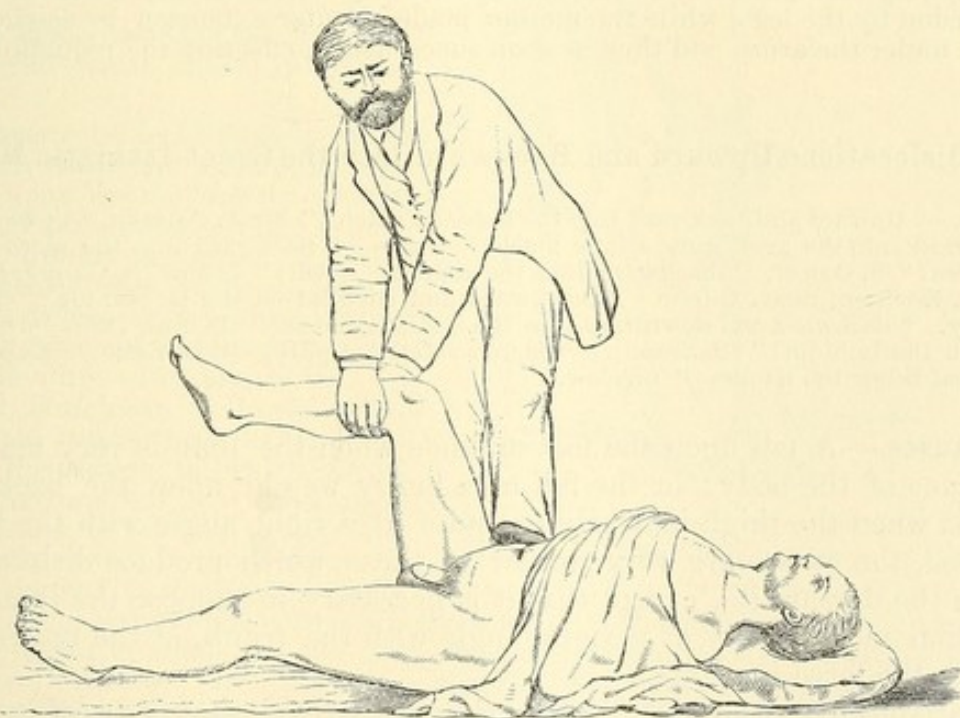
Ibid., p. 840.

have recognized the necessity of flexing the thigh in certain cases. Dr. Bigelow suggests that where greater force is required than can be obtained by the usual methods, a tripod should be employed, as shown in the accompanying woodcut.

[Bigelow¹ expresses himself thus: "If there is any single and best rule for reducing a recent dislocation of the hip, it is to get the head of the femur directly below the socket by flexing the thigh at about a right angle, and then to lift or jerk it forcibly into its place. The rule applies to all dislocations except the pubic, and even to that when secondary from below the socket. The reduction by the lifting method is usually instantaneous, and flexion is at the basis of its success. If after one or two trials it should appear that the hip cannot be jerked into place, let the rent in the capsule be enlarged a little by moving the flexed thigh, not up and down, but from one side to the other, so as to sweep the head of the femur across below the socket. No danger need be apprehended from this expedient of circumduction. The added injury is a very slight one. . . . Such additional laceration may sometimes advantageously occur without the knowledge of the surgeon during unsuccessful efforts to reduce the bone, especially in executing the manœuvres described in the rule: flex, abduct, evert."

The advantages of this method may be thus stated: Flexion relaxes the ilio-femoral ligament, and the relaxation may be further increased by slight adduction; then rotate very slightly inward, that is to say, move the foot away from the middle line while the knee is held steady; this disengages the head from behind the socket; slight traction in the line of the femur will then usually bring the bone into position; if more force is required, the surgeon may place his foot, covered with a stocking, on the anterior superior spinous process, to steady the pelvis while he raises the bent knee. (Fig. 451.)

FIG. 451.



Reduction by lifting.

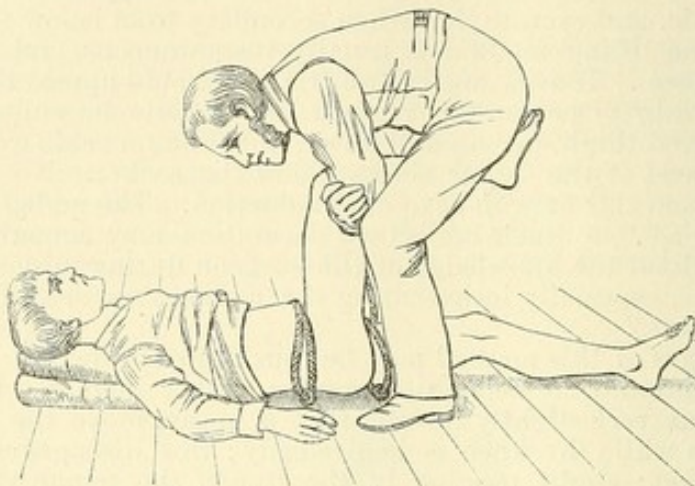
Dr. J. E. Kelly² fixes the patient in the recumbent position by straps or bandages around the hips and the board on which he lies; the thigh being bent at right angles with the body, the surgeon stands astride the leg facing the patient; stooping and passing his arms under the leg near the knee, the leg is brought against his perineum, and he is able to lift to great advantage. (Fig. 452.)]

¹ London Lancet, June 15, 1878.

² Dublin Journ. Med. Sci.

The following case, reported by Dr. Fanning, of Catskill, N. Y., illustrates the occasional necessity of resorting to extension, and is of special interest on account of the extreme youth of the patient. I have referred to the same case once before. A little girl, two and a half years old, was caught under a falling door; her parents suspected no injury beyond a severe bruise until ten days

FIG. 452.



Reduction by lifting. (Kelly.)

later, when they consulted Dr. Fanning. The left femur was then found to be dislocated upon the dorsum ilii. Dr. Fanning attempted first to reduce the dislocation by manipulation, but he failed. He then directed the father to make extension by the legs, while the mother made counter-extension by seizing the child under the arms, and thus he soon succeeded in effecting the reduction.

§ 2. Dislocations Upward and Backward into the Great Ischiatic Notch.

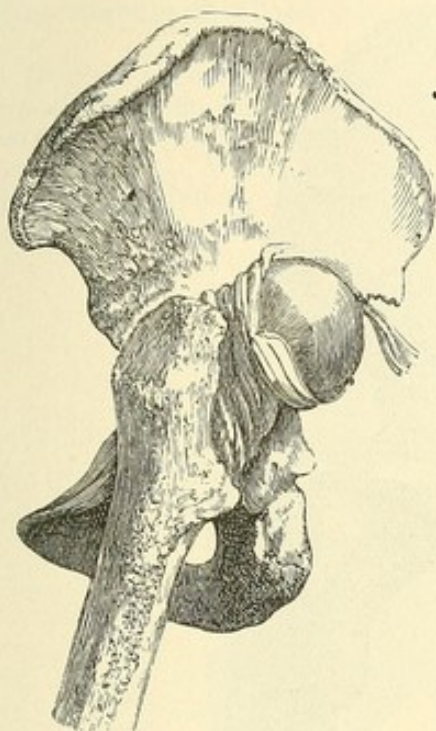
Syn.—"Upward and backward into the ischiatic notch;" Sir A. Cooper. "Upward and backward into the great sacro-sciatic notch;" Lizars. "Backward into the sacro-sciatic foramen;" S. Cooper. "Backward into the ischiatic notch;" Liston, B. Cooper, Miller, Pirrie, Erichsen, Skey, Gibson. "Downward and outward on the os ischium;" Boyer, Dorsey. "Backward and downward into the ischiatic notch;" Chelius, Petit, Duverney. "Upon the ischium;" Bertrandi. "Sacro-sciatic;" Gerdy. "Ischiatic;" Malgaigne. "Dorsal below the tendon;" Bigelow.

Causes.—A fall upon the foot or knee when the limb is very much in advance of the body; or the fall of a heavy weight upon the back and pelvis when the thigh is nearly or quite at a right angle with the body. Indeed, the causes are very similar to those which produce dislocations upon the dorsum ilii, except that it is necessary to suppose the limb in a position more nearly at a right angle with the trunk, at the moment at which the force is applied.

Pathological Anatomy.—Mr. Syme dissected the body of a man recently dead whose thigh had been dislocated into the ischiatic notch. He found the glutæus maximus nearly torn asunder, the head of the femur being embedded in its substance; the glutæus minimus, the pyri-formis, and the gemellus superior lacerated; the capsular ligament extensively torn close to the edge of the acetabulum, and the round ligament completely separated from the femur. The head of the femur was lying in the great ischiatic notch, upon the gemelli and the sacro-sciatic nerve,

behind the acetabulum and a little above it; being situated between the upper margin of the notch and the great sacro-sciatic ligaments.¹ (Fig. 453.)

FIG. 453.



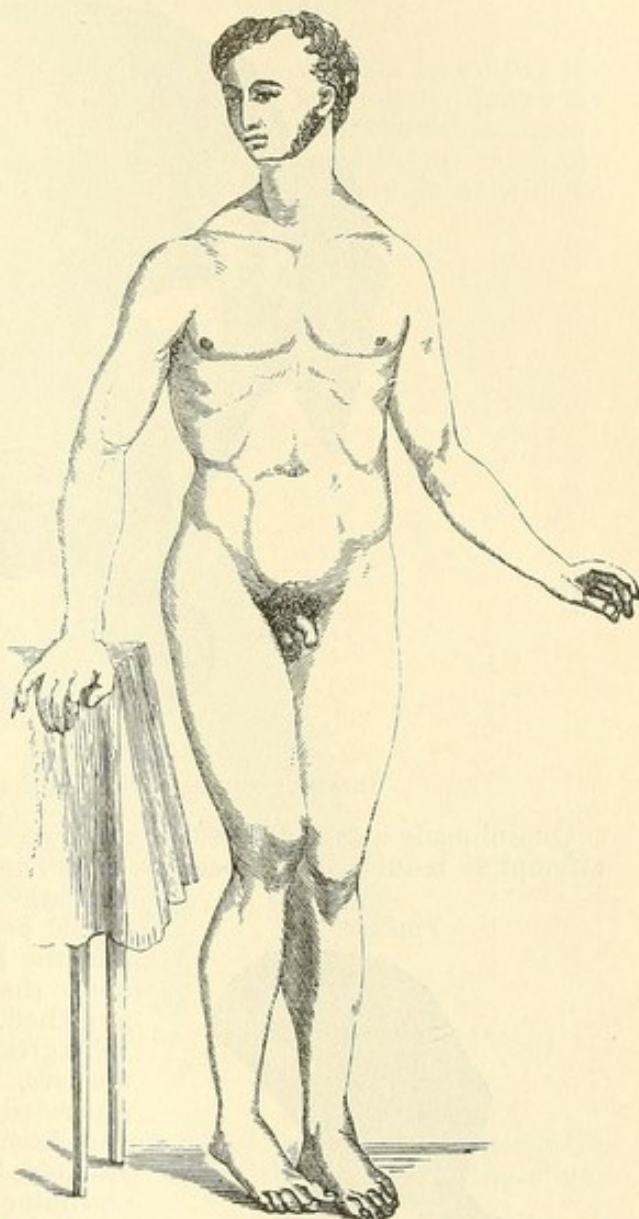
Dislocation upward and backward into the great ischiatic notch. (A. Cooper.)

Boyer considers this dislocation as only secondary upon a dislocation upon the dorsum ilii; but it is very certain that it often occurs as a primary accident. Not unfrequently, also, what was primarily a dislocation into the ischiatic notch, becomes subsequently a dislocation upon the dorsum ilii.

Dr. Hutchison, of Brooklyn, N. Y., has reported an example of this dislocation in which, death having occurred four days after reduction, he was able to ascertain the character of the lesions. I was present at this autopsy, and the lesions were found to be much the same as in the case related by Syme; but the glutæus minimus was not torn, and there was added a laceration of the obturator externus. Dr. Lente has reported one other dissection made after reduction.²

Dr. Bigelow speaks of a dorsal (upon the ilium) dislocation as sometimes occupying a position as low as the upper portion of the ischiatic notch; but the dislocation now under consideration he describes as that in which the head of the femur, having been driven from its socket downward and backward, is subsequently, in the attempt to straighten the limb, carried upward behind the socket until it is arrested by the strong tendon of the obturator internus, and

FIG. 454.



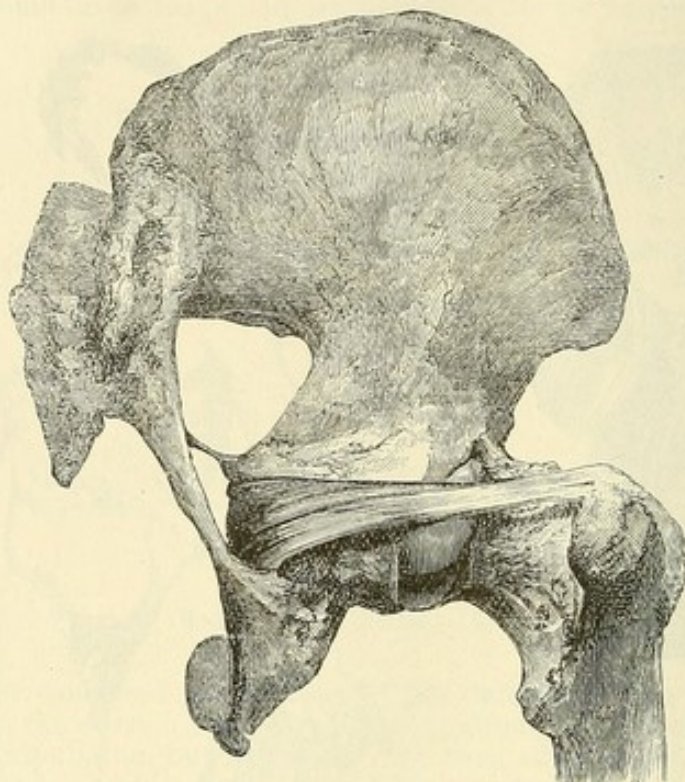
Dislocation upward and backward into the great ischiatic notch.

¹ Amer. Journ. Med. Sci., vol. xxxii. p. 460.

² Lente, New York Journ. Med., Jan. 1851.

the subjacent capsule. This is usually denominated "ischiatric;" but as it is both behind and below the tendon, Bigelow calls it "dorsal below the tendon."

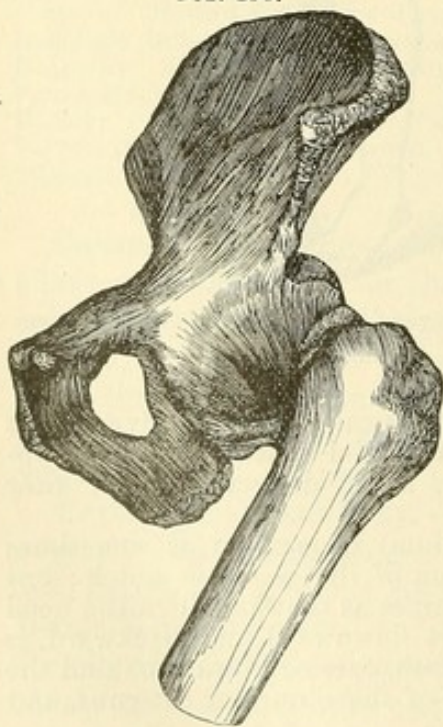
FIG. 455.



Internal obturator in its natural position. (Bigelow.)

Quain¹ made a careful dissection of a recent ischiatic dislocation, in which no attempt at reduction had been made. The head of the femur rested upon the ischiatic spine, and was separated from the pelvic bones only by the obturator internus and the gemelli. The pyramidalis, situated above the head of the femur, was moderately stretched. The gemelli and obturator internus were greatly stretched; which last-mentioned muscles, with the capsular ligament, alone separated the head from the cotyloid cavity, and from the surface of the innominatum situated behind this cavity. The external obturator and the quadratus were torn transversely. The capsule was detached from the cotyloid margin at its inferior and internal insertions, while its posterior and external portions were intact. The round ligament was torn from its insertion into the head of the femur.

FIG. 456.



Showing tense condition of anterior half of capsular ligament in "backward" dislocation. (Gunn.)

In a case reported by Scott,² the sciatic nerve was compressed between the head and the ischium.

In a case reported by Scott,² the sciatic nerve was compressed between the head and the ischium.

Symptoms.—The position of the limb is in some cases nearly the same as in certain dislocations upon the dorsum. It is shortened usually about half an inch, the thigh being flexed upon the body, adducted, and rotated inward; but the

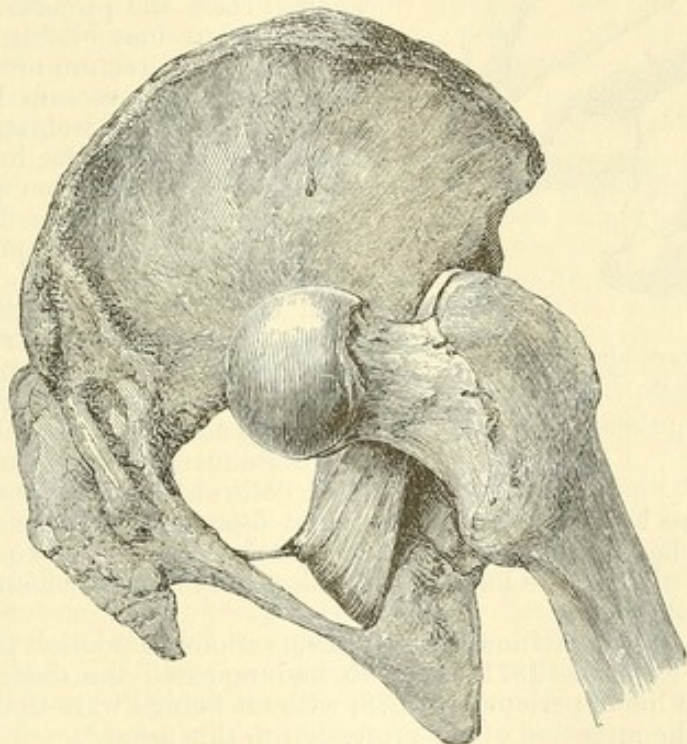
¹ Quain, Poinset, op. cit., p. 1054.

² Scott, Dublin Hosp. Rep., 1822, vol. 3, p. 389.

flexion is often less than in dislocations upon the dorsum, while, on the other hand, it is sometimes much greater. Generally it is such that, when the patient is standing, the end of the great toe of the dislocated limb touches the ball of the great toe of the sound limb.

Bigelow observes that the extreme flexion which is sometimes found to exist especially when the patient is in the recumbent position, is generally due to the arrest of the head of the femur by the internal obturator and the subjacent untorn capsule. When the patient rises, the weight of the limb may force the head up behind the tendon of the obturator; or if the limb is brought down

FIG. 457



Internal obturator in its new position. (Ischiatic) "Dorsal below the tendon."
(Bigelow.)

with force, the tendon and capsule may give way and the head may ascend to any point upon the outer surface of the ilium, and in this way an ischiatic may be converted into an iliac dislocation.

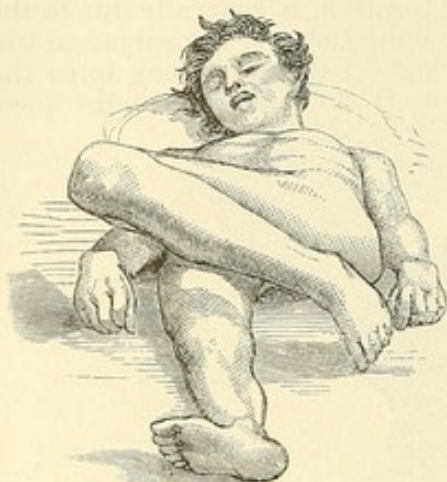The head of the femur is sometimes distinctly felt in its new position, especially when the limb is moved upward or downward. The trochanter major is approximated toward the anterior superior spinous process of the ilium.

Sir Astley Cooper remarks that this dislocation is the most difficult to detect, and Mr. Syme mentions a case in which the nature of the accident was overlooked by himself, and the thigh was not reduced until the thirteenth day;¹ and subsequently Mr. Syme has called attention to what he considers as one of the most important diagnostic marks—indeed, he says it is never absent, nor is it ever met with in any other injury of the hip-joint, "whether dislocation, fracture, or bruise;" this is "an arched form of the lumbar part of the spine, which cannot be straightened so long as the thigh is straight, or on a line with the patient's trunk. When the limb is raised or bent upward upon the pelvis, the back rests

¹ Amer. Journ. Med. Sci., vol. xviii. p. 242.

flat upon the bed; but so soon as the limb is allowed to descend, the back becomes arched as before."¹ This position, assumed by the back when an attempt is made to straighten and depress the limb, is due to the action of the *psaos magnus* and *iliacus internus*. But this can hardly be regarded as absolutely diagnostic,

FIG. 458.



Dislocation upward and backward into great ischiatic notch. "Below the tendon," when the patient is recumbent. (Bigelow.)

the two limbs are brought into a position of flexion, the thighs being at right angles with the body, the dislocated limb will appear one or two inches shorter than the other—that is, the knee of the dislocated limb will be on a much lower level than the other.²

Dr. W. Dawson, of Cincinnati, whose observations in relation to this new sign extended back as far as 1871, and who had repeated the observation several times, published his experience in 1878, without being aware that Dr. Allis had already called the attention of the profession to this point.³

I have seen two dislocations of this character which were not recognized by the surgeons at the time of the receipt of the injury, nor for some weeks afterward. One was a lad 12 years old. The accident had happened eight weeks before. His limb was shortened one inch; it was also forcibly adducted and rotated inward. Dr. Colegrove, a very excellent surgeon, had made a thorough attempt to reduce the dislocation with pulleys a few days before he was brought to me, and I did not deem it advisable to subject him again to the trial. Notwithstanding the dislocation, his limb was quite useful. The second was in the case of the boy seen by Dr. Sayre and myself, to which I have referred.

Treatment.—In employing *manipulation*, we may follow, with only a slight modification, the directions already given in dislocations upon the *dorsum ilii*. We find the head of the femur lower; consequently the extent of the circuit to be described in the manœuvre is diminished, but in other respects the processes are identical. We must not forget, however, that there is especial danger, while attempting to reduce this dislocation by manipulation, that the head of the bone will be thrown across into the *foramen thyroideum*.

¹ Amer. Journ. Med. Sci., Oct. 1843, p. 461, from Lond. and Edinb. Month. Journ., July, 1843.

² Allis, Phila. Med. Times, March 28, 1874.

³ Dawson, Archives of Clinical Surg., Jan. 1, 1878. Hosp. Gaz., May 16, 1878.

inasmuch as this same phenomenon will be observed in a degree, more or less, in a dislocation upon the *dorsum*, and in most cases of disease of the hip-joint. The inversion of the toes, immobility of the limb, and the absence of crepitus, are generally sufficient in themselves to distinguish it from a fracture of the neck. Dr. Squires, of Elmira, N. Y., suggests, also, that in ancient cases the projection of the head of the femur may be felt by passing the finger into the rectum or vagina. With my finger in the rectum I determined a dislocation into the ischiatic notch which had existed six months, in a boy 12 years old; and by exploration per vaginam I diagnosticated the same dislocation in a woman at Bellevue Hospital, which had existed four weeks.

Dr. Oscar H. Allis, of Philadelphia, has added another valuable means of diagnosis, namely, that, although the limb, when laid parallel with the other, or as nearly so as it is practicable to place it, and extended, will be found to be only very little shortened, if at all; yet, when

I have already mentioned one case occurring under the care of Dr. Post in the New York Hospital, in which the head of the femur, originally in the ischiatic notch, passed backward and forward between the ischiatic notch and the foramen thyroideum many times, and which, although the reduction was finally accomplished, was followed by morbus coxarius. Parker mentions a second case in the same paper,¹ in which his first attempt to reduce by manipulation carried the head of the bone into the foramen thyroideum; but the second attempt was successful. In Dr. Hutchison's case, to which I have already referred, the first attempt at reduction was made without an anæsthetic, and by manipulation after the method described by Reid. The first two attempts failed, and in the third, the limb being more abducted than before, the head of the bone was thrown into the foramen thyroideum. By reversing the movements, it was replaced in the ischiatic notch; and this change of position was made seven or eight times. The patient was now etherized, and the bone was lifted into its socket in the same manner which I have described in the case of Caswell. Malgaigne refers to a patient of Lenoir's, and to another of his own, in which the head of the bone was lodged under the margin of the acetabulum during the attempts at reduction.²

C. McC., æt. 21, a laborer, was caught between two cars, with his back resting against one car, and his right knee against the other, the right thigh being raised to a right angle with the body. As the cars came together he felt a "cracking" at the hip-joint, and found himself immediately unable to walk or stand. Two hours after the accident I examined the limb carefully, and made arrangements for the reduction with the pulleys, in case the attempt by manipulation should fail. The patient lying upon his back, I seized the right leg and thigh with my hands, the leg being moderately flexed upon the thigh, and carried the knee slowly up toward the belly, until it had approached within twelve or fifteen inches, when, noticing a slight resistance to farther progress in this direction, I carried the knee across the body outward, until I again encountered a slight resistance, and immediately I began to allow the limb to descend. At this moment a sudden slip or snap occurred near the joint, and I supposed reduction was accomplished; but on bringing the limb down completely, I found it was still in the ischiatic notch. I think the head had slipped off from the lower lip of the acetabulum, after having been gradually lifted upon it.

Without delay I commenced to repeat the manipulation, and in precisely the same manner. Again, at the same point, when the limb was just beginning to descend, a much more distinct sensation of slipping was felt, and on dropping the limb it was found to be in place and in form, with all its mobility completely restored. No anæsthetic was employed, and no person supported the body or interfered in any way to assist in the reduction. No outcry was made by the patient, yet he informed me that the manipulation hurt him considerably. The amount of force employed by myself was just sufficient to lift the limb, and the time occupied in the whole procedure was only a few seconds. After the reduction he remained upon his back, in bed, eleven days, in pursuance of my instructions. At the end of this time he began to walk about, but was unable to resume work until after eight weeks or more. It is probable that he could have walked immediately after the reduction, without much if any inconvenience, so trivial was the inflammation which resulted from the accident. He never complained of pain, but only of a slight soreness back of the trochanter major, near the head of the bone. This soreness continued several weeks, and was especially present when he bent forward. After the lapse of four months, when I last saw him, he occasionally felt a pain at this point in stooping, but the motions of the joint were free; he walked rapidly and without halt.

Perhaps in most cases, and especially when the head of the bone has not been carried by consecutive displacement upward until it rests fairly upon the lower portion of the dorsum ilii, the most important step in the manœuvre is to lift the bone toward the socket, by placing the arm

¹ Markoe's paper, N. Y. Journ. of Med., Jan. 1855.

² Malgaigne, op. cit., tom. ii. p. 839.

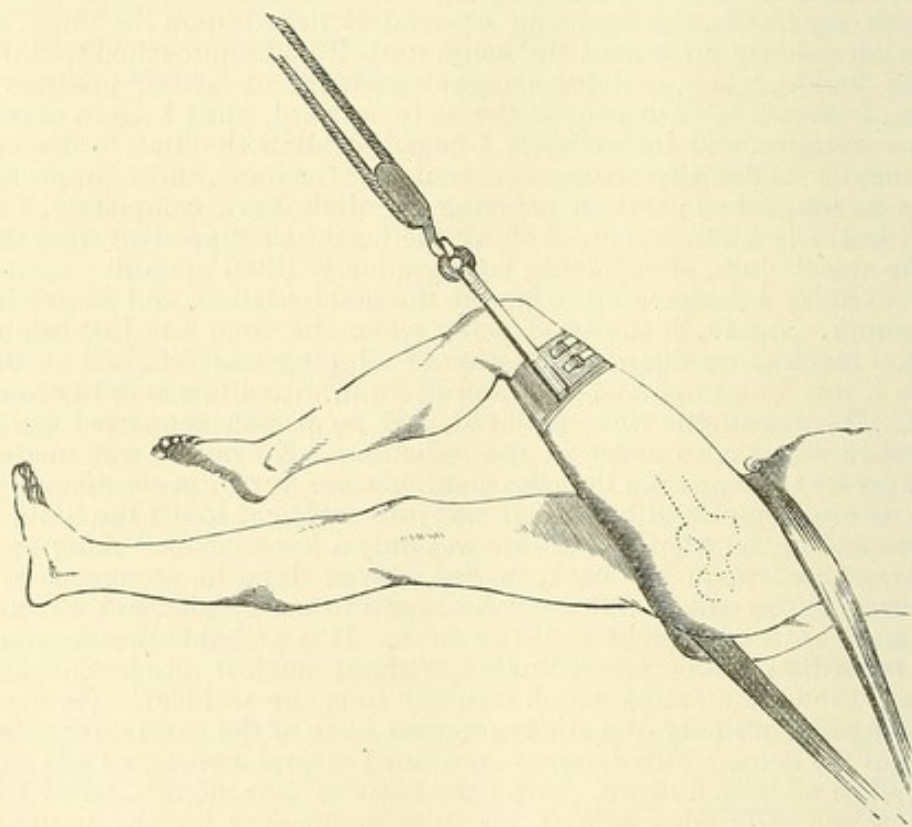
under the knee (the patient resting upon his back) and drawing directly upward.

Prof. Gunn, describing his method, says: An assistant fixes the pelvis while the surgeon flexes the thigh at a right angle with the trunk, and the leg upon the thigh; he then adducts, rotates inwardly, and draws the limb forward in the direction of extreme adduction, thus lifting the head directly into the socket. Essentially Prof. Bigelow adopts the same method.

If the reduction is attempted by *extension*, we ought to remember that the head of the bone lies more behind than above the socket, and that it is not requisite to carry it downward so much as forward; and especially that it must mount over the most elevated margin of the socket, in order to resume its position. The extension ought, therefore, to be made at a right angle with the body.

J. H., æt. 40, had a dislocation of the head of the femur into the ischiatic notch. He entered Bellevue Hospital about twenty hours after the accident. In the recumbent posture the limb was pretty strongly adducted and slightly rotated inward. It was shortened three-quarters of an inch. In the erect pos-

FIG. 459.



Reduction of dislocation upward and backward into the great ischiatic notch, by extension—
(Sir Astley Cooper's method.)

ture both adduction and inward rotation were very slight. Having etherized him, I made three separate attempts at reduction by manipulation, but failed. I then made extension in the following manner: The patient resting upon his back, I stood astride his body, and clasping my hands under the knee, I pulled directly upward, while an assistant held down the pelvis. I did not feel the bone resume its place, nor was I aware that reduction was accomplished, but

when I let the limb down the bone was found to be in its socket. Two or three minutes later, and before the patient had recovered from the effects of the ether, I raised the knee, to indicate to some young men, who had just come in, how the dislocation had been reduced, when it slipped out again, with a sudden jerk and a grating sensation. This sensation I had felt once or twice before while manipulating. It was scarcely as rough as the crepitus of a fracture, and it probably indicated that the cartilaginous margin of the acetabulum had been broken off. The limb was now brought down to the bed, and it was found to be in the same position as before reduction was attempted. Standing again over the patient, and placing my hand under the knee, I pulled upward, and the head resumed its place; this time with a sudden jerk and with the same rough sensation. The limb was then placed in the extended position and secured by a long splint, which was not removed until the eleventh day.

The facility with which the redislocation took place in the preceding case will sufficiently explain what happened in the following case on the tenth day after reduction, and on account of which I was subsequently consulted: W. M., æt. 18, was thrown from a wagon, dislocating his left femur into the ischiatic notch. Dr. Watson was consulted within three hours. Drs. Wood and Taffit were also present. Dr. Watson laid the patient on his back, and without anæsthetics reduced the dislocation by manipulation. The bone was felt distinctly as it slipped into its place, and the limb immediately resumed its natural position and length, as all the surgeons present affirm. He was soon out of the house on crutches, and on the eleventh day went in bathing. When he came out of the water he complained of his hip, and on the following day it was seen to be shortened. Subsequently it was examined by several surgeons, all of whom pronounced it dislocated. An attempt was then made to reduce the dislocation by Jarvis's adjuster, but without anæsthesia, as the patient refused to be rendered insensible. The attempt did not succeed.

Lente relates a case in which, extension being employed, the cord was suddenly cut while the limb was abducted and rotated outward, when the head of the femur left the ischiatic notch, and rose upon the dorsum ilii, assuming a position directly above the acetabulum, and below the anterior superior spinous process; and from which position it was subsequently, with great difficulty, returned to the socket.¹

§ 3. Dislocation Downward and Forward into the Foramen Thyroideum.

Syn.—"Downward into the foramen ovale;" Sir A. Cooper. "Downward into the obturator foramen;" Lizars. "Downward and forward into the foramen obturatorium;" B. Cooper. "Inward and downward into the oval hole;" Chelius. "Downward and forward into the foramen ovale;" Pirrie. "Downward and inward;" Boyer. "Subpubic;" Gerdy. "Ischio-pubic;" Malgaigne.

Causes.—In order to produce this dislocation the limb must be, at the moment of the receipt of the injury, in a position of abduction. Perhaps most often it is occasioned by the fall of a heavy weight upon the back of the pelvis when the body is bent and the thighs spread asunder.

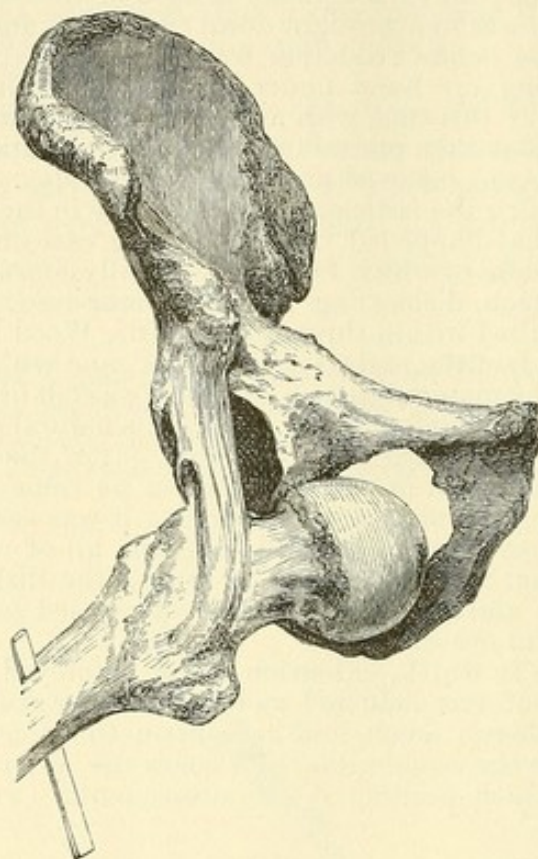
Pathological Anatomy.—The capsule gives way upon the inner side especially; the round ligament is torn from its attachment, and the head of the femur, pressing forward and downward, finds a lodgement upon or against the obturator externus muscle, over the foramen thyroideum.

Symptoms.—The thigh is apparently lengthened from one to two inches, abducted and flexed, the body being also bent forward or flexed upon the thigh. The dislocated limb is advanced before the other, and the toes generally point directly forward, but they may incline either

¹ Lente, New York Journ. Med., November, 1850, p. 314.

outward or inward. The hip is flattened or depressed; the long adductors are felt tense upon the inside of the limb; the trochanter major is less prominent than upon the opposite side; and the head of the bone

FIG. 460.



Relations of the ilio-femoral ligament to the thyroid dislocation. (From Bigelow.)

may sometimes be felt in its new position. The apparent lengthening of the limb alone is sufficient to distinguish this accident from a fracture of the neck.

I have said "apparent" lengthening, because in the position in which the limb is found, it is difficult to make an accurate relative measurement of the two limbs; and, indeed, Rivington,¹ of the London Hospital, could not in a case seen by him recognize any shortening, and in his experiments upon the cadaver he obtained a similar result. Holmes,² also, in a clinical lecture has stated that the lengthening is less marked in proportion as the abduction and outward rotation are greater.

In some cases the position of the head of the femur may be recognized by a rectal examination; or, in the case of females by a vaginal examination. The flexion and abduction are due in some measure to the tension of the psoas magnus and iliacus internus, and perhaps to a similar condition of other rotators and flexors; but, according to Bigelow, the ilio-femoral ligament offers the chief resistance, and constitutes the chief impediment to the restoration of the bone.

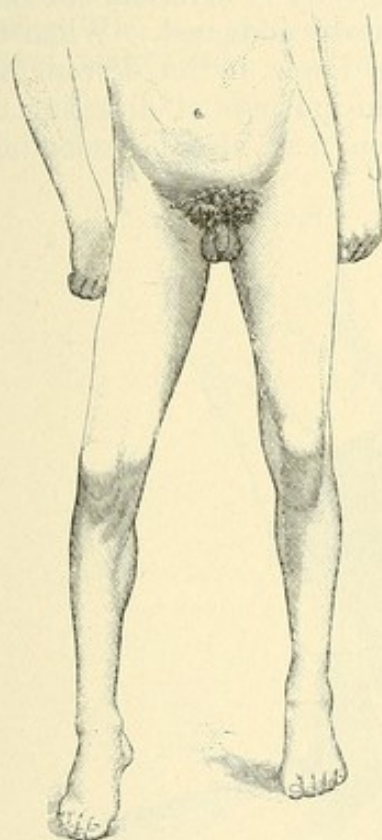
¹ Rivington, *The Lancet*, 1888, vol. ii. p. 321.

² Holmes, *Med. Times and Gaz.*, Oct. 27, 1877.

W. Taylor¹ has reported an example of compound dislocation upon the foramen ovale, in which reduction having been effected, it was, several weeks after the accident, followed by an abscess; but from which he eventually recovered with a tolerably useful limb, but not without some ankylosis.

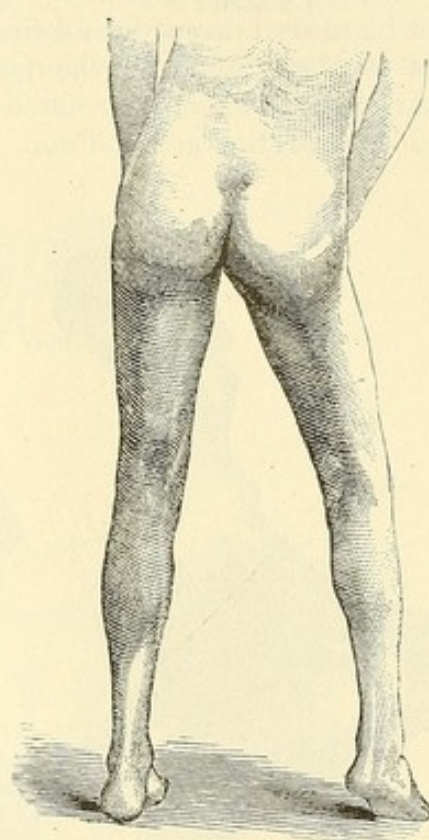
Says Prof. Gunn: "In the dislocation downward and forward over the thyroid foramen, the anterior and inferior portion of the capsular ligament must be torn asunder for the escape of the head; while from the extremely abducted state of the limb at the moment of the accident, the superior and posterior portion must be relaxed, and thus escape laceration.

FIG. 461.



(Anterior view.)

FIG. 462.



(Posterior view.)

Dislocation into the foramen thyroideum.

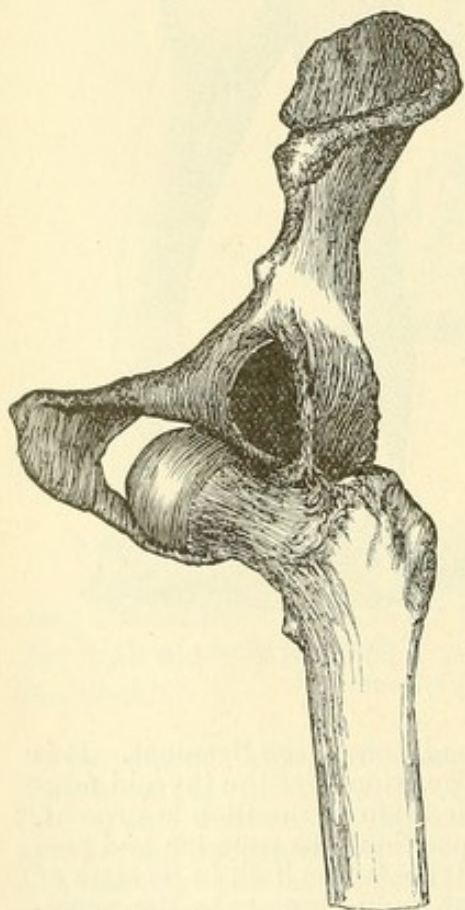
"Fig. 463 illustrates this dislocation and the condition of the ligament. It is seen that while the head of the femur occupies a position over the thyroid foramen, and while the characteristic deformity of direction in the limb is present, viz., a moderately flexed and slightly abducted position, the superior and posterior untorn portion of the ligament is tense and holds the limb in its state of slight abduction. The flexed position of the limb is due mainly to the necessarily tense condition of the psoas magnus and iliacus muscles. The characteristic position of the limb in this dislocation is inconsistent with the integrity of the ilio-femoral portion of the capsular ligament. The greatly increased distance between the anterior inferior spinous process of the ilium and the anterior inter-trochanteric line of the femur cannot be accommodated by anything less than the rupture of this portion of the ligament. The head of the femur *can* be placed over the thyroid foramen in the intact state of this portion of the ligament; but in order to accomplish this, the femur must be flexed to the right angle with the longitude of the trunk. This is illustrated in Fig. 464. An examination of this figure, or of the specimen which I herewith exhibit, will fully warrant the positive statement, that in the downward and forward dislocation, if the limb is found in the position generally characteristic of this form of

¹ Taylor, The Lancet, 1881, vol. i. p. 732.

the accident, the only untorn part of the capsule will be the upward and backward portion, as is illustrated in Fig. 464."

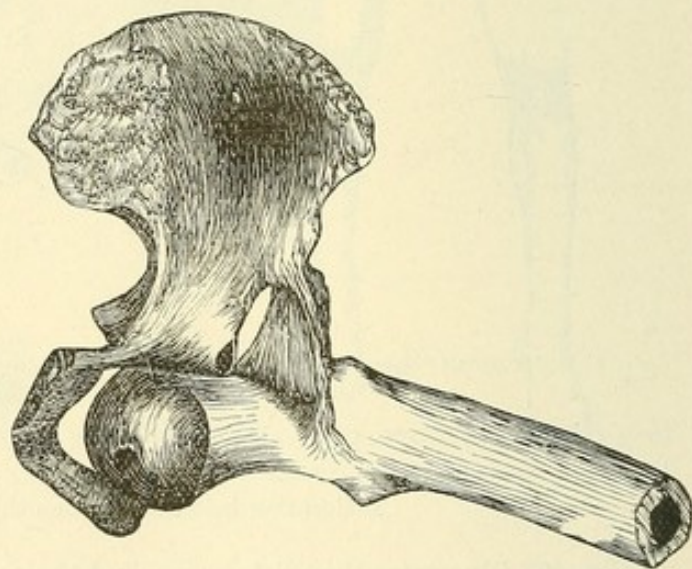
Treatment.—If we attempt to reduce by manipulation, it will be proper to follow the same rule which I have stated as applicable to dislocations backward, namely, to carry the limb, in the first instance, only in those directions in which it is found to move easily. Instead, therefore, of holding the leg in a position of adduction while the thigh is flexed upon the abdomen, it will be necessary to carry it up abducted; and when the further progress of the knee toward the belly is arrested, the limb must be moved inward, and finally brought down adducted. When the knee is about opposite the pubes, or a little lower, in its descent, the femur should be gently rotated inward, for the purpose of directing the head toward the acetabulum. The reduction may also be sometimes

FIG. 463.



Tense, untorn, upward and backward portion of capsular ligament in thyroid dislocation. (Gunn.)

FIG. 464.



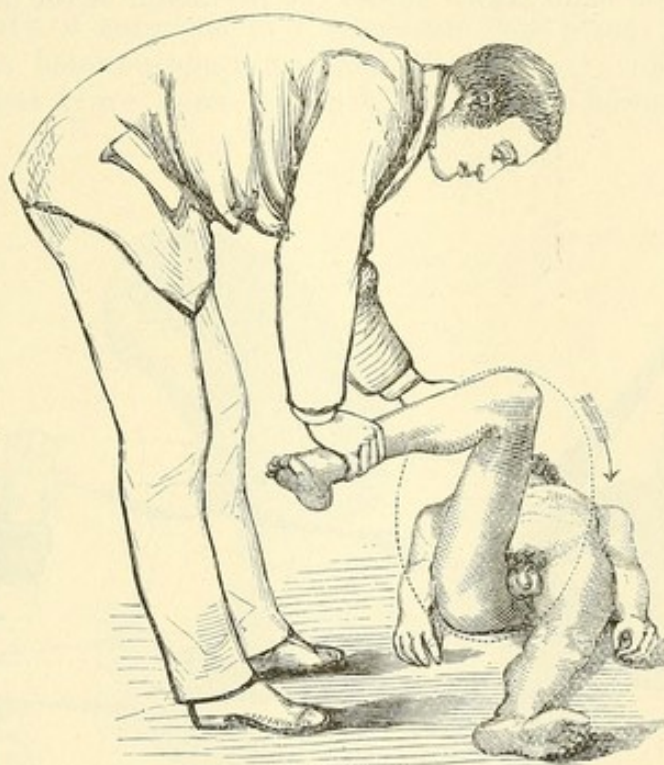
Illustrating what would be the degree of flexion in thyroid dislocation if the ilio-femoral portion of capsule remained untorn. (Gunn.)

facilitated by lifting the head of the bone with the aid of a band passed under the upper portion of the thigh and over the shoulder of an assistant; by giving to the shaft of the femur a slight rocking motion when it is about to enter the socket; by pressing with the hand against the head of the bone, and by lifting at the knee.

In one of the examples recorded by Markoe (Case 8), the reduction was accomplished in the second attempt, by rotating the thigh inward just as the thigh

had descended below a right angle with the body, in the manner which I have above directed; but in the second example (Case 9), a similar manœuvre carried the head across into the ischiatic notch, while the reduction was finally accomplished by rotating the thigh outward, and at the same moment adducting the limb strongly in a direction which carried the knee behind the other one. Markoe concludes that the latter mode is preferable, because it will throw the head of the bone a little upward as well as outward; in which direction it will find a more gently inclined plane toward the socket. He admits, however, that both methods may accomplish the same result. But I am quite certain that the method by rotation of the shaft of the femur inward is in general most likely to succeed. In this way also, I think, both W. H. Van Buren, of New York,¹ and R. L. Brodie, of the U. S. Army, were successful;² it is the method preferred by Bigelow, who also recognizes the propriety of making outward rotation when inward rotation fails. "Flex the limb toward a perpendicular, and abduct it a

FIG. 465.



Reduction of thyroid dislocation by manipulation. (From Bigelow.)

little to disengage the head of the bone; then rotate the thigh strongly inward, adducting, and carrying the knee to the floor." It is especially worthy of notice that Anderson, so long ago as 1772, in the case already quoted, practised successfully almost precisely the same method. In one example mentioned by Markoe (Case 7), it is pretty evident that the head of the femur was thrown into the ischiatic notch, by having flexed the thigh too much, so that "the knee touched the thorax." Indeed, it is questionable whether it will be best ever to bring the thigh much, if at all, above a right angle with the body, since any further flexion can only throw the head below the acetabulum, when in fact it is already too low.

N. S., a painter, æt. 33, fell from the second-story window upon a stone pavement, striking, as he believes upon the inside of his right knee. I saw him within an hour, and found the right tibia partially dislocated outward, the cor-

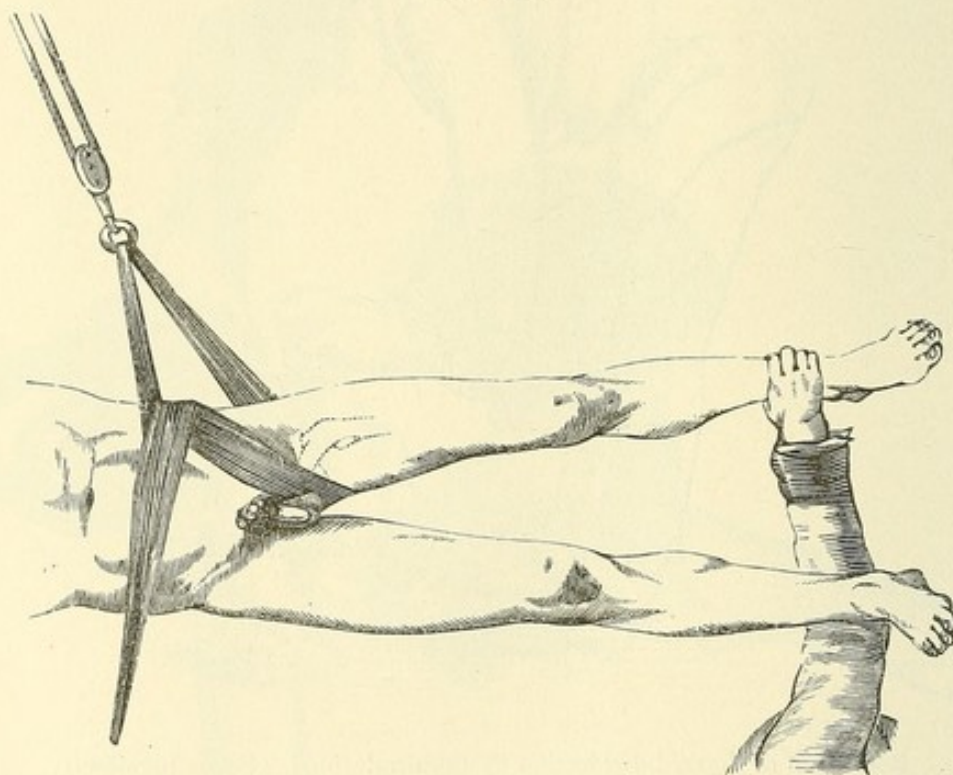
¹ W. H. Van Buren, New York Med. Times, Jan. 1856, p. 127.

² R. L. Brodie, Memphis Med. Recorder, Sept. 1857, p. 93; from Charleston Med. Rev.

responding patella dislocated completely outward, and the right femur in the foramen thyroideum. His thigh was forcibly abducted, slightly rotated outward, and lengthened, by measurement made from the pelvis to the ankle, one inch and a half. The distance from the anterior superior spinous process to the fold of the groin was ten inches, but upon the sound side it was only eight and a half. The head of the femur could be distinctly felt in front, just under the pubes. Having administered chloroform, I first reduced the tibia and the patella, then seizing the thigh and leg, I flexed the thigh upon the body, carrying the limb upward abducted until it was nearly or quite at a right angle with the body, then inclining the knee slightly inward, I brought it down again, and when the thigh had nearly reached the bed, it fell into its socket with a dull flapping sensation. In every step of the procedure I followed the inclination of the limb. The recovery was rapid and complete.

Sir Astley Cooper advises that the patient shall be placed upon his back, with his thighs separated as far as possible. The pulleys are to be made fast to a band drawn across the perineum of the dislocated limb,

FIG. 466.



Sir Astley Cooper's mode of reducing a recent dislocation into the foramen thyroideum.

in a direction upward and outward; while a counter-band is to be passed around the pelvis through the band attached to the pulleys, and secured to a staple, or delivered to assistants placed upon the sound side of the body. When everything is arranged, the pulleys should be acted upon until the head of the femur is felt moving from the foramen thyroideum; at this moment the surgeon must pass his hand behind the sound limb, and seizing upon the ankle of the dislocated limb, adduct it forcibly, thus converting the limb into a lever of the first order.

If the dislocation has existed some time, he recommends that this procedure shall be varied by placing the patient upon his sound side instead of his back, and attaching the pulleys perpendicularly over the

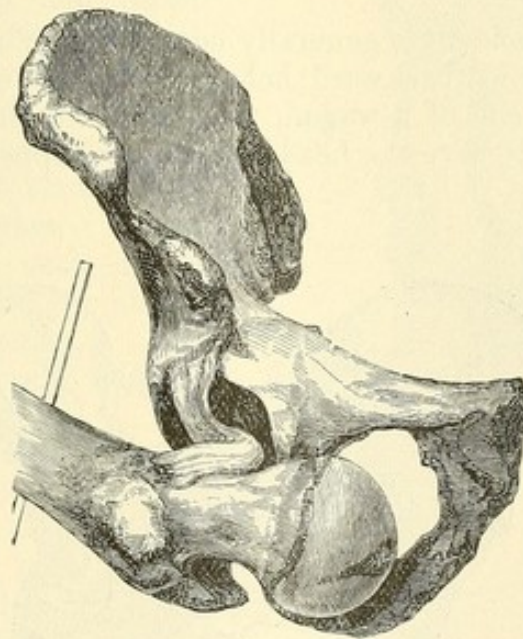
body. He especially cautions us not to flex the thigh during these manœuvres, lest we force the head of the bone backward into the ischiatic notch, whence he affirms that it cannot afterward be returned to its socket; but the experience of surgeons has since shown that this latter statement is incorrect, and that it may, in some cases, be afterward reduced, although it has fallen into the ischiatic notch.

Mr. Liston says that this accident happened to himself while attempting to reduce a dislocation of only a few hours' standing, in a young and powerful man, but he had no difficulty in returning it to its first position.¹

Brainard, of Chicago, reduced this dislocation, after both the compound pulleys and Jarvis's adjuster had failed, by placing between the thighs a piece of wood wrapped about with several layers of a wadded quilt, and making use of this as a fulcrum upon which the thigh operated as a lever. The legs were simply pressed together, care being taken to keep the knees straight.²

The majority of surgeons of the present day place the limb in the flexed position before attempting to make traction. This may be done with the patient lying upon his back, and by the hands, alone or with

FIG. 467.



Effect of flexion upon the ilio-femoral ligament in the thyroid dislocation. (From Bigelow.)

pulleys, or the patient may be placed in a sitting posture, and the extension made at right angles with the body. In all of these attempts to reduce by traction, measures must be taken to secure immobility to the pelvis.

A man, 40 years of age, was admitted to Bellevue, having a dislocation of the left femur into the foramen thyroideum, which had been caused six hours before. The limb was slightly abducted, and moderately flexed upon the pelvis, while he was lying upon the bed; the position being that represented in Fig. 457. There was a very marked depression in the situation of the trochanter

¹ Practical Surg., Amer. ed., p. 93.

² Brainard, Northwestern Med. and Surg. Journ., 1852.

major, and a fulness upon the inside of the limb, caused by the tension of the long adductors. The patient being under the influence of ether, the house surgeon, Dr. E. D. Hudson, first attempted, under my instruction, to reduce the dislocation by manipulation, flexion, and rotation, with adduction; but failing in this, a folded sheet was placed in the perineum corresponding to the dislocated limb, and committed to assistants, who were directed to pull upward and outward, the patient lying upon his right side, with his left thigh flexed to a right angle with his body. Dr. Hudson then passed a band under the upper part of the thigh and over his shoulders, lifting and pressing the knee forcibly inward at the same time. In a few seconds the reduction was accomplished.

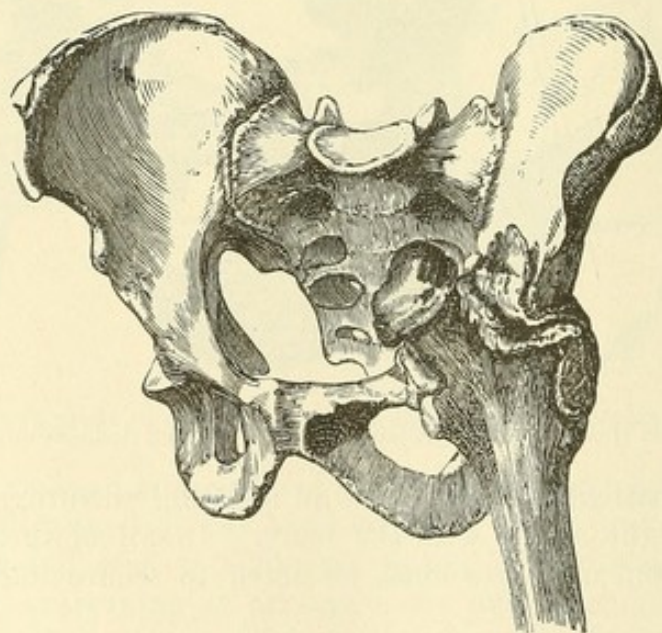
After the reduction is accomplished, the patient should be laid upon his back in bed, but instead of rotating the limb outward, as I have advised after a dislocation upon the dorsum ilii or into the ischiatic notch, it should be gently rotated inward, and the knees thus bound together.

§ 4. Dislocations Upward and Forward upon the Pubes.

Syn.—"Upward and forward on the horizontal branch of the share-bone;" Chelius. "Forward upon the pubes;" Pirrie. "On the body of the pubes, below the spine and transverse part of the bone;" Skey. "Sur-pubic;" Gredy. "Ilio-pubic;" Malgaigne.

Causes.—This accident is generally occasioned by a fall upon the foot when the leg is thrown backward behind the centre of gravity; as in a fall from the back end of a wagon, the foot being instinctively thrown backward in order to save the head; or it may happen to a person who,

FIG. 468.



Specimen of dislocation upon the pubes, in St. Thomas's Hospital. (From Sir J. A. Cooper.)

while walking, suddenly puts one foot into a hole, in consequence of which the pelvis advances, but the leg and upper part of the body incline forcibly backward. Occasionally it has resulted from a fall upon the back of the pelvis, or from a severe blow received upon the same part.

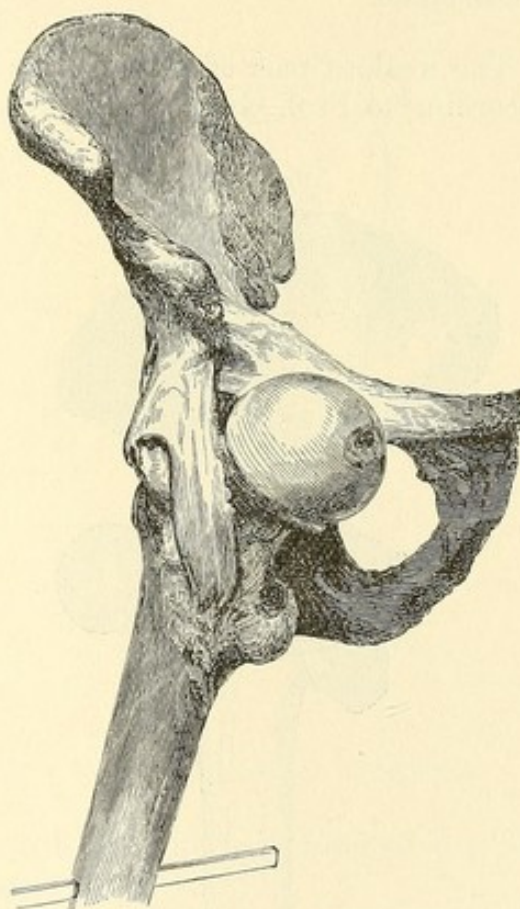
A patient was admitted, under the care of Dr. Ure, into St. Mary's Hospital, London, with a dislocation upon the pubes occasioned by swimming. His account of it was, that when in the act of "striking out" he felt a catch in the right groin which he thought was cramp, and that he was able to walk after the accident, but with a good deal of difficulty. The examination proved that he had a dislocation upon the pubes, which Dr. Ure easily reduced.¹

Pathological Anatomy.—Sir Astley Cooper dissected the hip of a person whose thigh had been dislocated upon the pubes for some time, the true nature of the accident not having been at first recognized. The acetabulum was partly filled by bone, and partly occupied by the trochanter major, both of which were much altered in their form. The capsular ligament was extensively torn, and the ligamentum teres broken off completely. The head and neck of the femur had torn up Poupart's ligament, so as to penetrate between it and the pubes, and lay underneath the iliacus internus and psoas muscles; the anterior crural nerve was lying upon these muscles, over the neck of the femur. The head and neck were flattened and otherwise much changed in form. Upon the tubes a socket was formed for the neck of the thigh-bone, the head being above the level of the pubes. The femoral artery and vein were to the inner side (Fig. 468).

The head of the femur may be found lying far forward upon the pubes (Figs. 472, 473), mentioned below; or it may lie further back, along the ilio-pubic margin, and rests below and in front of the anterior superior spinous process of the ilium. When the head rests directly below this process, the dislocation is considered anomalous or irregular, and this form will be considered hereafter as the "subspinous" dislocation.

In the accompanying drawing the relation of the ilio-femoral ligament of the head and neck of the femur is shown, when the head ascends moderately upon the pubes. The extreme displacement shown in the preceding illustration from Sir Astley Cooper is only possible where that portion of the capsule beneath the obturator internus is torn, and perhaps the obturator itself. According to Bigelow, the ilio-femoral ligament

FIG. 469.



Dislocation upon the pubes below the anterior inferior spinous process of the ilium. (From Bigelow.)

¹ Medical News and Library, vol. xvi. p. 1, from Lond. Lancet, Nov. 7, 1857.

and the psoas magnus and iliacus internus are then the only remaining causes of eversion.

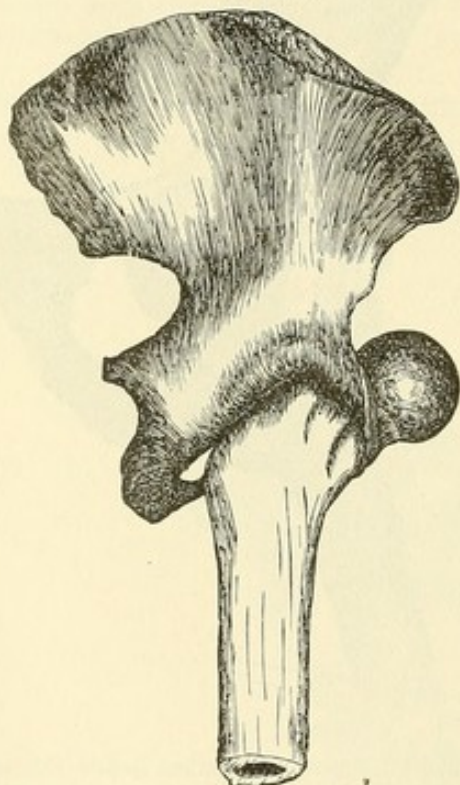
The femoral artery and vein are usually found upon the inner side of the head, but occasionally these vessels are in front of, and sometimes external to, the head.

In a case related by Goldsmith, of Louisville,¹ where the femoral artery was situated in front of the head, and the dislocation remaining unreduced, at the end of two months a diffuse aneurism having formed, the primitive iliac was tied, and the patient died on the fifth day. The autopsy revealed an opening in the artery through which the head of the bone had passed until it lay within the cavity of the aneurism.

Kronlein² reports a case of tearing of the femoral vein, in a case in which the leg had been thrown so violently backward that the heel touched the back of the shoulder.

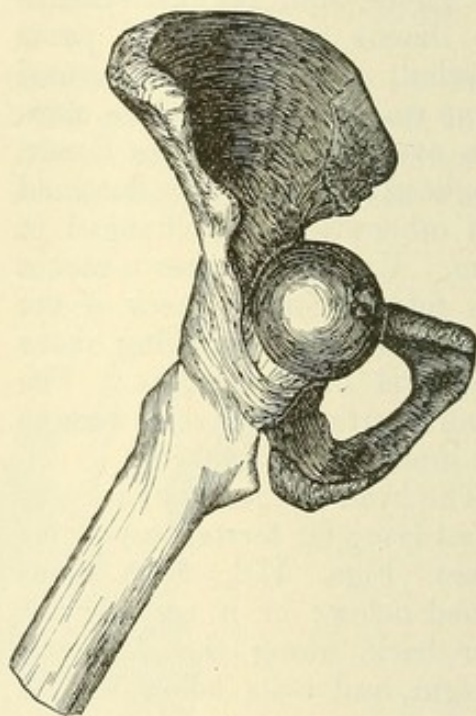
The weakest part of the anterior and upper portion of the capsule is, according to Prof. Gunn, "where it is not reinforced by the ilio-femoral

FIG. 470.



External view of pubic dislocation. Posterior border of the great trochanter occupying the acetabulum, pressing before it the posterior untorn half of capsule. (Gunn.)

FIG. 471.



Anterior view; showing continuity of structure between the ilio-femoral and inferior border of posterior half of capsular ligament. (Gunn.)

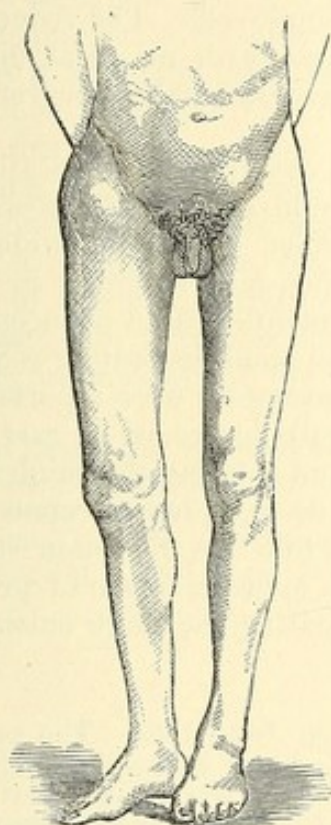
fibres. Through this the head escapes and rests in front of the body of the pubis, the posterior surface of the neck resting on the edge of the acetabulum, and the posterior border of the great trochanter settling somewhat into the socket. The portion of the capsule which remains untorn is the whole of the posterior half, and that part of the anterior

¹ Goldsmith, Amer. Journ. Med. Sci., July, 1860, p. 30.

² Kronlein, Poincet, op. cit., p. 1072.

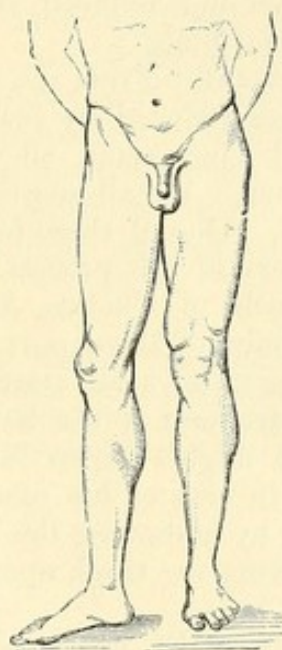
half covered and strengthened by the reinforcing ilio-femoral fibres. The posterior half is forced down into the acetabulum by the trochanter major, which encroaches upon that cavity." Being thus pressed into the acetabulum, this portion becomes "moderately tense, but it does not exert much influence on this dislocation in any way. On the contrary, the ilio-femoral portion of the capsular ligament in front, with the posterior untorn portion from below the cervix, holds the dislocated head in its luxated position. In this dislocation, the ilio-femoral portion of the

FIG. 472.



Ilio-pectineal dislocation. (Bigelow.)

FIG. 473.



Pubic dislocation. (Bigelow.)

capsular ligament, by its continuity with the inferior border of the posterior untorn portion, possesses its usual potency.

Symptoms.—The thigh is shortened sometimes, but not always; abducted, flexed slightly, rarely extended, and rotated outward. The trochanter major is carried back and lost, or nearly so, while the head of the bone may be generally felt like a round ball, lying upon or in front of the body of the pubes, in most cases outside of the femoral artery and vein. Larrey saw a patient in whom the femur was placed nearly at a right angle with the body; and Physick once met with a dislocation upon the pubes "directly before the acetabulum," in which the limb was not at all shortened, but, on the contrary, a very little lengthened.¹ Other surgeons have occasionally seen similar examples.

The differential diagnosis between a fracture of the neck of the femur and this dislocation may be thus briefly stated. In the fracture there is

¹ Dorsey's Surgery, vol. i. p. 238, 1813.

crepitus, mobility, slight eversion easily overcome, no abduction, the trochanter major rotates on a short radius, and the head of the bone cannot be felt. In this dislocation there is no crepitus, the limb is immobile, the eversion is extreme and not easily overcome, the thigh is often abducted, the trochanter major rotates upon a longer radius, and the head of the bone can generally be distinctly felt in its unnatural position.

Prognosis.—Sir Astley Cooper remarks that although this accident is easy of detection, he has known three instances in which it was overlooked, and he cannot but regard such errors as evidence of great carelessness on the part of the surgeon who is employed. The reduction has generally been accomplished, in recent cases, with no great difficulty; and when not reduced, the patients have occasionally recovered with very useful limbs.

Treatment.—From the several reported examples of dislocation upon the pubes reduced by manipulation, it would be difficult to draw any practical conclusions, since the methods have differed so widely from each other. I shall mention only four, which may be found in our own journals. One of these has already been mentioned in connection with the history of this process, as a case of compound dislocation reduced by Dr. Ingalls, of Chelsea, Mass.; and two examples were reported by E. J. Fountain, of Davenport, Iowa. Dr. Ingalls succeeded by carrying the limb into its greatest state of abduction, and rotating the thigh inward; the replacement of the bone being aided also by pressing upon its head with his fingers thrust into the wound; while Dr. Fountain succeeded equally in both of his cases, by an almost opposite mode of procedure, namely, by adducting the limb forcibly, rotating the thigh outward, and then flexing the thigh upon the body.

The first of Dr. Fountain's cases occurred in June, 1854. The patient, an adult male, had fallen from the second story of a house to the ground, fracturing his lower jaw and dislocating his left hip. The limb was a trifle shortened and the foot strongly everted. The prominence of the trochanter was lessened, and the head of the bone could be felt upon the pubes. Assisted by Dr. Arnold, he reduced the limb in the following manner: The patient was laid on the floor, and placed completely under the influence of chloroform. The dislocated limb was then "seized by the foot and knee and rotated outward, the leg flexed and carried over the opposite knee and thigh, the heel kept well up, and the knee pressed down. This motion was continued by carrying the thigh over the sound one as high as the upper part of the middle third, the foot being kept firmly elevated. Then the limb was carried directly upward by elevating the knee, while the foot was held firm and steady, at the same time making gentle oscillations by the knee, when the head of the bone suddenly dropped into its socket."¹ The time occupied was not more than thirty seconds, and the force employed was very slight.

The second case occurred on the 31st of October, 1855, in the person of an Irish laborer, the dislocation having been occasioned by falling with a horse while riding. The reduction was effected in about twenty seconds by the same process and without the aid of chloroform.

Dr. Henry, of New York, successfully reduced a dislocation of the femur upon the pubes after twenty-six days. The first attempt, made October 23d, was unsuccessful. The second attempt was made October 29th. After repeated trials, by forced abduction and circumduction the head of the bone was thrown into

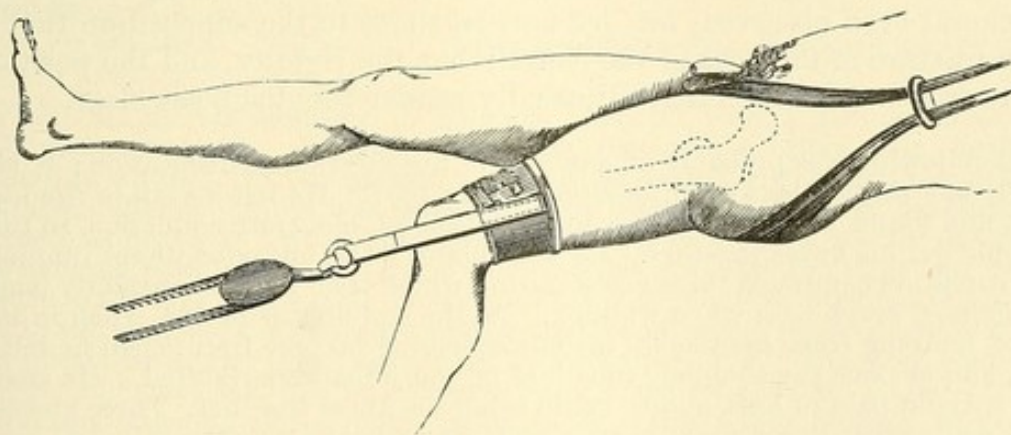
¹ Fountain, New York Journ. Med., Jan. 1856, p. 69 et seq.

the thyroid foramen, after which by abduction and extension it was conveyed into the acetabulum. He was dismissed cured in about three months.¹

It is probable that no one method will succeed equally well in all cases; but if the head of the bone, as in the case dissected by Sir Astley Cooper, has not only actually surmounted the pubes, but pushed itself fairly into the pelvis, then the limb ought to be abducted in the manner practised by Ingalls, and forcibly rotated outward, in order that the head may be thus lifted over the pubes; and subsequently it should be flexed upon the body, adducted, and brought down. But in this manœuvre we ought to be careful not to continue the rotation outward after the head of the femur has risen above the pubes, lest the head and neck should grasp, as it were, the psoas magnus and iliacus internus muscles, underneath which they have been thrust. On the contrary, it will be necessary at this point to rotate the thigh again gently inward, which, by compelling the head to hug the front of the pubes, will enable it, while the flexion is being made, to slide downward under these muscles toward the socket. If, however, the head of the bone has never risen upon the summit of the pubes, and is not actually engaged under the muscles which pass over it at this point, then the rotation outward will not be necessary in any part of the procedure.

Barron Larrey has reported a case of dislocation "before the horizontal portion of the pubes," which he reduced "by suddenly raising with his shoulder the lower extremity of the femur, while with both hands he depressed the head of the bone."² This case was attended with the unusual phenomenon of the thigh placed at a right angle with the body.

FIG. 474.



Reduction of dislocation upon the pubes, by extension.

If reduction is attempted by extension, the patient ought to be laid on his back upon a table, with the dislocated limb falling off slightly from its side. The extending band, made fast above the knee, should then be secured to a staple in the line of the axis of the dislocated thigh and, of course, below the table; while the counter-extending band, crossing under

¹ M. H. Henry, Amer. Journ. Med. Sci., Jan. 1875.

² Larrey, London Med.-Chir. Rev., Dec. 1820, p. 500; vol. i., first series, from Bullétin de la Fac. de Méd., No. 1.

the perineum, should be made fast in the same line, above the level of the table, and beyond the head of the patient. When extension is commenced, and the head of the femur has begun to move, the reduction may sometimes be facilitated by lifting the upper part of the thigh with a jack-towel or a band passed under the thigh and over the neck of the surgeon, as I have recommended in both of the backward dislocations. It may be found advantageous, also, to flex and rotate the limb after extension has brought the head near the socket.

§ 5. Anomalous or Irregular Dislocations.¹

1. Dislocations directly Upward above the Margin of the Acetabulum, and below the Anterior Inferior Spinous Process.

Syn.—"Sus-cotyloidiennes;" Malgaigne. "Subspinous." "Sixth dislocation;" Mütter

Malgaigne affirms that the head, in this dislocation, is situated external to the anterior inferior spinous process, and about one inch below the anterior superior spinous process.

It is in this position that the head of the femur is found in a specimen deposited in the museum of the Surgical Clinic of Bonn, by Kronlein. A new cotyloid cavity exists posterior to and on a level with the anterior inferior spinous process.² Blasius, of Halle,³ says that he has been able to reproduce this dislocation upon the cadaver by forced extension (dorsal flexion), combined with adduction and outward rotation.

The symptoms which characterize this accident are shortening of the limb, slight abduction and extension, with rotation upward. The eversion of the toes, together with the slight amount of shortening which has in general been observed, has led several times to the supposition that it was a fracture of the neck of the femur; but the rigidity, and the position of the trochanter and head will usually render the diagnosis clear.

The following was probably an example of the subspinous dislocation: B. M., æt. 51, was thrown backward, in wrestling, in 1851. He felt a snap in the hip-joint, and found his thigh placed in a position of moderate adduction, so that he could get his knees together. He was able to walk, but not without limping. This condition continued three years, during which time he was constantly lame, and suffered much pain when walking. At the end of this period, when in the act of jumping from his wagon, his horses having become frightened, he felt a snap, and at once the complete functions of the joint were restored. He could walk without pain or halt, and he could bring his knees together. Three months later, while ascending a flight of steps, carrying a heavy weight, his foot slipped,

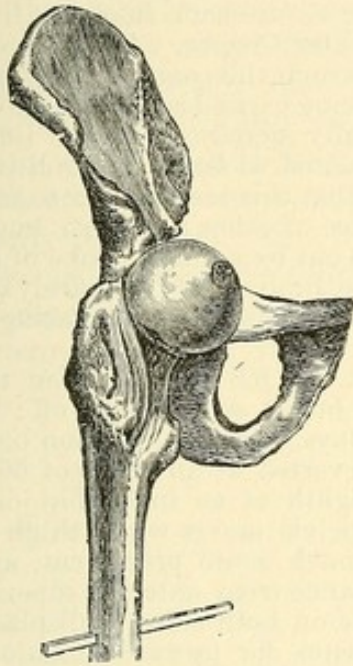
¹ Malgaigne, *Traité des Frac. et des Lux.*, tom. ii. p. 869 et seq. Samuel Cooper, *First Lines*, vol. ii. p. 391. Pirrie's *Surg.*, Amer. ed., 1852, p. 275. Skey's *Surg.*, Amer. ed., 1851, p. 110 et seq. Gibson's *Surg.*, sixth American ed., vol. i. p. 386. Guy's *Hospital Reports*, 1836, vol. i. pp. 79 and 97; 1838, vol. iii. p. 163. *London Lancet*, Lond. ed., 1848, vol. i. p. 184; 1840, vol. ii. p. 281; 1845, vol. i. p. 412; vol. ii. p. 159. *London Med. Gaz.*, vol. xix. pp. 657 and 659; vol. x. p. 19; vol. xxxiii. p. 404. *Medico-Chir. Trans.*, vol. xx. p. 112. Lente's paper on "Anomalous Dislocations of the Hip-joint," in *New York Journ. Med.* for Nov. 1850, p. 314 et seq. *Philadelphia Med. Examiner*, No. 51. *Amer. Journ. Med. Sci.*, vol. xvi. p. 14. *New York Med. and Phys. Journ.*, 1826, vol. v. p. 597. *New York Journ. Med.*, Jan. 1860, Dr. Shrady's case. *Dislocation of the Hip*, by Jacob J. Bigelow, M.D., 1869.

² Kronlein, Poincot, op. cit., p. 1076.

³ Blasius, *Archiv für klin. Chir.*, Bd. 16, Hft. 1, p. 207.

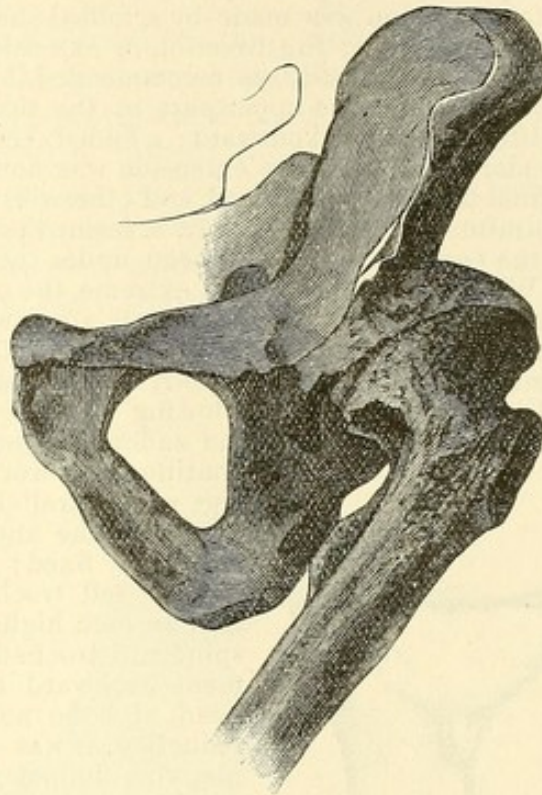
and the dislocation was reproduced, and in this condition it remained up to the period at which he consulted me, October, 1869. I found the thigh apparently elongated, but upon measurement it was found shortened half an inch. It was moderately abducted and rotated outward. All the motions of the joint were restricted. Although I feel very confident that the reduction could be again accomplished, the patient left without permitting me to make the attempt.

FIG. 475.



Subspinous dislocation; the Y-ligament stretched the neck of the bone which lies beneath it. (Bigelow.)

FIG. 476.



Subspinous dislocation. Kronlein's specimen.

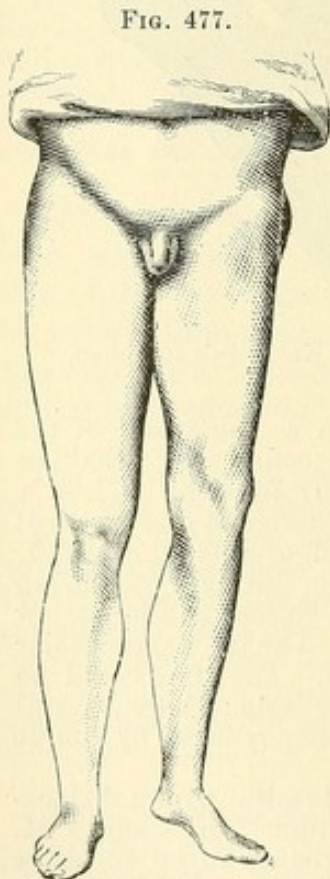
P. C., æt. 52, was admitted to Bellevue Hospital, with a dislocation of the right femur upward. He had fallen nine feet into a cellar. Dr. Erskine Mason, in whose ward the patient was received, called my attention to him a few hours after the injury was received. The limb was shortened one-fourth of an inch, as nearly as we could ascertain; strongly everted, or rotated outward, but hanging parallel with the other when he was standing, the right foot being a little in advance of the left. The head of the bone could be seen and felt below and to the inside of the anterior superior spinous process. The trochanter major was turned back, and there was a deep depression over it. The limb could be slightly adducted, but in all other directions it was immovable. After several ineffectual attempts at reduction, under ether, it was finally reduced by simple extension.

M. M., æt. 62, was admitted into the New York City Hospital with a dislocation of the left femur upward and forward upon the ilium. Dr. Charles M. Allin, one of the visiting surgeons, made some efforts at reduction on the same day, but failed. On the following day, in the presence of several medical gentlemen, including myself, Dr. Allin repeated his efforts more systematically, and was successful. Examining the limb while the patient was on his back, and under the influence of ether, preparatory to the operation, I found it shortened half an inch, strongly everted, and the thigh slightly flexed, but lying nearly parallel with the other. The thigh could be adducted quite freely, but in all other directions motion was more limited. With some difficulty it could be flexed to a right angle with the body. The head could be distinctly felt, but not seen, directly below the anterior superior spinous process; and from this

position it was occasionally moved, while manipulating, farther forward, but never fairly upon the pubes. The patient was a spare man, and not very muscular. The accident was caused by stumbling while ascending a flight of steps, and falling upon his knees and face. The skin over the spine of the tibia was much bruised and scratched. Dr. Allin made an attempt at reduction, 1st, by flexing the thigh at a right angle, and rotating outward forcibly. This was unsuccessful. 2d. By flexion and rotation inward. 3d. By extension in several directions by the hands, including vertical extension with the thigh flexed upon the body. 4th. Compound pulleys were attached to a lacque above the knee, and counter-extension was made by a folded sheet passed under the perineum, and secured to a staple; the direction of extension being a little back from the line of the axis of the body, as recommended by Sir Astley Cooper. A jack-towel was placed under the upper part of the thigh, by which this part of the limb was lifted upward and outward; a folded sheet also being carried across the pelvis to render it steady. The extension was now gradually increased, and the limb was from time to time rotated, and otherwise manipulated, so far as its condition of restraint would permit, until it seemed probable that this method was to fail also, the patient having now been under the influence of ether nearly an hour. 5th. While the extension was extreme, the cord was cut by a quick stroke of an amputating-knife; and immediately after, while the limb was lying paralyzed by the "shock," Dr. Allin seized the thigh, raised the knee a little, rotating it inward, when the head fell easily into its socket.¹

[Milner² reported the following case: A man, æt. 20, fell heavily upon the great trochanter; got up and suffered severe pain, but it soon passed off; he continued his work four days. On examination both legs were parallel; foot everted at an angle of 60°; leg short one and one-eighth of an inch; hip-joint absolutely fixed; whole pelvis moves when thigh is flexed; left trochanter much more prominent, and half an inch higher; distance from anterior superior spine and trochanter same on both sides as displacement backward compensates for upward luxation; head of bone nowhere felt. After many efforts at reduction, it was effected by following Busch's formula, viz., abduct the thigh, rotate it somewhat outward, and carry it into hyper-extension, then rotate rapidly inward and place it straight.

Barker reported a case of a boy, who fell at play with the right leg strongly abducted and somewhat flexed, and the left doubled up under him. He had little pain, but the deformity made his mother seek advice. Standing, the right thigh was strongly abducted; and, to bring the foot to the ground, the pelvis was tilted; thigh slightly flexed and foot everted; flattening in region of trochanter and obliteration of fold of nates; thigh rigid, and could not be flexed, adducted, or extended. Reduction was effected as follows: drew the limb gently downward on its long axis, adducted, flexed and then circumducted, continuing downward traction, and rotated inward.]



Appearance of a subspinous dislocation.

Other surgeons have met with examples of the subspinous dislocation in which the patients have been able to walk quite well immediately after the accident. Bigelow supposes that in these cases the upper portion of the capsule has been completely torn from the margin of the acetabulum, and that the head has been permitted to ascend until it was arrested by the under

¹ Brief report of same case, as a "suprapubic" dislocation, in Archives of Clinical Surgery, April 15, 1877, p. 38.

² St. Barth. Hosp. Rep., 1874.

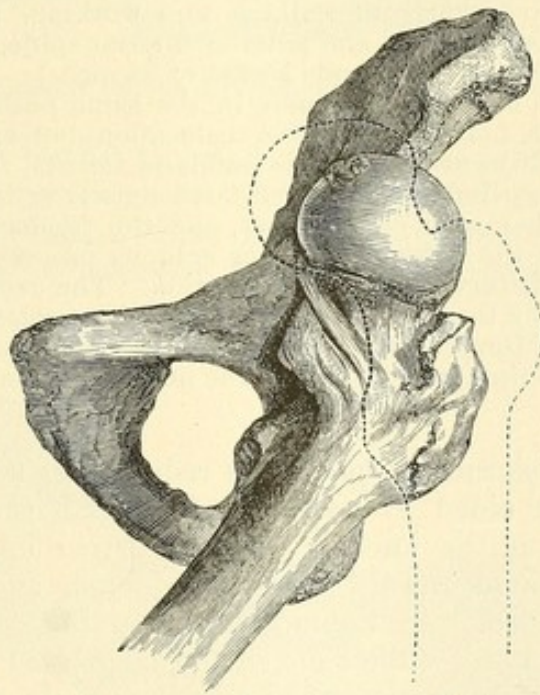
surface of the ilio-femoral ligament at the point where it rises from the anterior inferior spinous process of the ilium.

2. Dislocations directly Upward, between the Anterior Inferior and Anterior Superior Spinous Processes.

Syn.—"Supraspinous;" more appropriately, "Intraspinous."

Cummins reports a case which occurred in the practice of Gibson, of New Lanark, where the head of the bone was believed to be situated just above the anterior inferior spinous process and below the anterior superior spinous process; and also a little inward toward the pubes. The limb was shortened fully three inches; the toes everted; adduction and abduction were exceedingly painful and difficult, but flexion was more easily performed. The head of the bone could be felt in its new position, especially when the thigh was moved. At first it was supposed to be a fracture, but this error having been corrected, the surgeon proceeded to attempt reduction on the eleventh day. Extension was made by pulleys,

FIG. 478.



Supraspinous dislocation. (From Bigelow.)

and when the head of the bone had descended to the margin of the cavity, Mr. Gibson lifted the upper end of the femur by means of a towel, at the same moment pressing the knee toward the opposite thigh, and forcibly rotating the limb inward; by which means the reduction was accomplished.¹

[The following case of this form of dislocation appeared in my clinic several years since: The patient was a lady about 30 years of age and the mother of

¹ Cummins, Guy's Hospital Reports, vol iii. p. 163, 1838.

several children; she was short and stout, and apparently in perfect health. In walking the right limb was planted firmly and maintained in a nearly straight position, while the left limb made a half circuit around it. In standing the right limb was found to be about two and one-half inches shorter, and the right foot was fixed in a position of strong eversion. On examination, the head of the right femur was readily discovered between the anterior inferior and anterior superior spinous processes. Abduction and adduction were moderately free, but flexion was slight. The lady gave the following history of her case, which was confirmed by her mother: Four years previously, while in confinement, her physician, a large, stout man, had hastened the process by early rupture of the membranes, urging her to make great efforts, and during each pain pressing with both hands very firmly upon her right knee. She stated that at times the right thigh would be so flexed by his great pressure as to be forced violently against her body, causing acute pain at the hip. She suffered far more than in other confinements, but when it was over the limbs were placed side by side, and she was comfortable. Two or three days after, in attempting to change her position in bed, she was seized with violent pain in the right hip, and from that time she suffered almost constant pain in that hip for a year more. When she began to leave her bed, which she did not do for months, there was a gradual change going on in her right leg; it gradually became shorter, the foot became more and more everted, and at length she noticed a hard tumor forming outside of the inferior spinous process.

The case was clearly one of rupture of the capsule and primitive downward dislocation caused by the violent flexion and abduction of the thigh by the physician. Then followed a series of changes in the position of the head, caused by her daily voluntary efforts in walking and working, by which it passed upward between the acetabulum and anterior inferior spine, and finally became fixed between the two spines in a rude socket of its own.]

Lente has seen the head of the femur in the same position as in the case reported by Cummins, not as a primitive dislocation, but consequent upon an attempt to reduce a dislocation into the ischiatic notch. The shortening was about two inches; the limb very much rotated outward; the rotundity of the affected hip greater than that of the other, and the trochanter major one inch farther removed from the anterior superior spinous process. The head of the bone could be felt distinctly in its new position. The reduction was effected finally with pulleys, by the aid of chloroform, and by rotation of the limb in various directions.¹ Morgan also reports a case in which the head of the femur was above the acetabulum, and a little to the outside of the ilio-pectineal eminence.²

Some of these dislocations have been reduced by manipulation alone, or by manipulation aided by pressure. The limb should be seized in the usual manner, at the knee and ankle, carried up toward the face, abducted, then rotated inward, gently adducted, and finally brought down again to the bed. At the moment when the rotation and adduction commence, the head of the bone should be pressed toward the socket by the hands, and, if necessary, lifted a little over the margin of the acetabulum, by moderate extension at a right angle with the body. Others have been reduced easily by extension alone after a thorough trial of manipulation.

¹ Lente, *New York Journ. of Med.*, Nov. 1850, p. 314.

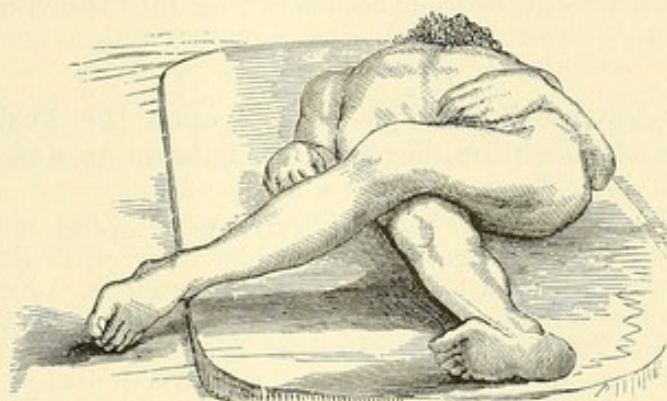
² Pirrie's *Surgery*, p. 276. See, also, *Phil. Med. Exam.*, No. 51, Mütter's paper.

3. Dislocations Upward upon the Dorsum Ilii, and near its Anterior Margin.

Syn.—"Anterior oblique;" Bigelow.

Bigelow, who regards as irregular only those dislocations which are accompanied with a complete rupture of the ilio-femoral ligament, but

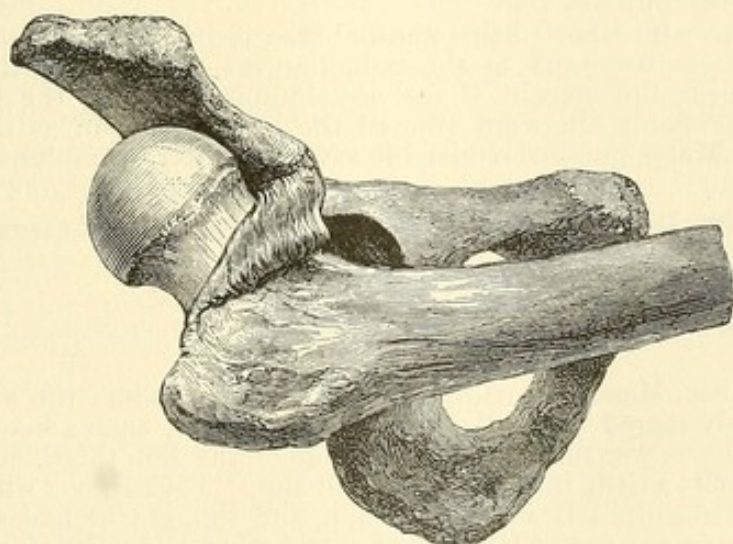
FIG. 479.



"Anterior oblique dislocation." (From Bigelow.)

whose classification in that regard I am not fully prepared to adopt, has, nevertheless, given us the most intelligible and most probable explanation of the mechanism of these irregular upward dislocations, and of several other forms of irregular dislocations. According to this writer,

FIG. 480.



Mechanism of "anterior oblique dislocation." (From Bigelow.)

the "anterior oblique dislocation," in which the limb is found greatly adducted, and at the same time strongly everted, is a regular dorsal dislocation, the head being advanced upon the dorsum to a point near the

anterior margin of the ilium. If now the limb be brought down, the neck of the femur will be made to bear against the outer fibres of the ilio-femoral ligament, and as these gradually give way the head will become more and more hooked over the remaining fibres of the ligament, and above the inferior spinous process ("supraspinous"); or, continued efforts being made to straighten the limb, the ligament will give way entirely, and the femur will assume the position indicated by the dotted lines (Fig. 473). He states that "the *anterior oblique* dislocation may be reduced by inward circumduction of the extended limb across the symphysis, with a little eversion, if necessary, to disengage the head of the bone. Inward rotation then converts this into the common luxation upon the dorsum."

4. Dislocations Downward and Backward upon the Posterior Part of the Body of the Ischium, between its Tuberosity and its Spine.

J. C. æt. 35, was admitted to the Pennsylvania Hospital, under the care of Dr. Hewson. The patient, a muscular man, had been crushed under a falling roof, and, as he thought, with his right thigh separated from his body. When received into the hospital, one hour after the accident, the right thigh was flexed upon the pelvis, and rested upon the left; the right leg was also flexed upon the thigh; the knee was below its fellow, the toes turned inward, and the whole limb shortened at least one inch. The head of the bone could be felt distinctly resting upon that portion of the ischium which lies between the acetabulum, the tuberosity of the ischium, and the spine. On the following day the muscles of the patient having been sufficiently relaxed by suitable means, the pulleys were applied; but, after a second attempt, some of the bands having given way suddenly, the pulleys were removed, when it was found that the reduction had been accomplished, although neither the patient nor his attendants had noticed the return of the bone to its socket. For several days there was entire loss of sensibility and motion in the leg, owing, probably, to the pressure which had been made upon the sciatic nerve; but these symptoms gradually disappeared, and at the time when the case was reported, about two months after the accident, he was walking with crutches.

Dr. Kirkbride, who reported this unusual case of dislocation, doubted whether the extension was necessary to the reduction, as the head of the bone was brought very near the margin of the acetabulum by lifting the thigh with a towel, and it probably afterward entered the socket as soon as the extension was relaxed.¹ Malgaigne has referred to several similar examples.

5. Dislocations Downward and Backward into the Lesser or Lower Ischiatic Notch.

Syn.—"Behind tuber ischii;" Gibson, S. Cooper. "Fifth dislocation;" Gibson.

C. L., of Lubec, Mass., was riding a spirited horse, when the animal, being restive, suddenly reared and fell back on his rider in such a manner that the weight of the horse was received on the inside of the left thigh, Mr. L. having fallen on his back, a little inclined to the left side. The surgeon who was immediately called recognized it as a dislocation, and thought he had succeeded in reducing it; but a day or two later it was seen by a second surgeon, who declared that it was still out of place, and repeated the attempt at reduction, but without success, as the result proved. Dr. John C. Warren, of Boston, was able to determine, as he affirms, the precise character of the accident. The limb was elongated, contracted, and the head could be felt in its unnatural position. By advice of Dr. Warren he was taken to the Massachusetts General Hospital, and

¹ Kirkbride, Amer. Journ. Med. Sci., vol. xvi. p. 13.

a persevering attempt was there made to reduce the bone, but with no better success than had attended the efforts previously made.¹

Mr. Keate has reported a case produced in a very similar way by a horse having fallen backward with the rider into a deep and narrow ditch; but the position of the limb was somewhat extraordinary, considering that it was a dislocation backward, the whole limb being very much abducted and the toes being turned outward, as if the head of the bone was in front of the tuber ischii rather than behind it. The thigh and leg were much flexed, and the whole limb was shortened from three to three and a half inches. The head of the femur could be distinctly felt "inferior to the ischiatic notch and on a level with the tuberosity of the ischium." In the first attempt at reduction the head of the bone was thrown into the foramen thyroideum, from which it was, however, after one or two more attempts by extension, and by lifting with a jack-towel, restored to the socket. Mr. Keate believes that the dislocation was originally into the foramen ovale, but that in the struggles made by the patient to extricate himself it was thrown backward into the position in which he found it.²

Mr. Wormald has reported a primitive accident of the same kind occasioned by jumping from a third-story window. The patient died soon after, and at the autopsy the head of the femur was found under the outer edge of the glutæus maximus, projecting through the torn capsule opposite the upper part of the tuber ischii. The shaft of the femur lay across the pubes, and the limb was considerably shortened and turned inward.³

6. Dislocations directly Downward.

Syn.—"Sous-cotyloïdiennes;" Malgaigne.

The following is one of several similar examples now upon record:

A man, æt. 50, was admitted into the London Hospital under the care of Mr. Luke. A dislocation of the left femur was easily diagnosed, but the symptoms were peculiar, inasmuch as the limb was lengthened one inch, without either inversion or eversion; yet the head of the bone could be easily felt, and was thought to be in the ischiatic notch. By manipular movements reduction was easily effected about an hour after the accident. The man subsequently died from the effects of broken ribs. At the autopsy, Mr. Forbes, the house-surgeon, before dissecting the parts, again dislocated the bone. This was done with ease, and it was clear that the original form of dislocation had been reproduced, as the bone could not be made to assume any other position. The head of the bone proved to be displaced neither into the ischiatic notch nor the thyroid hole, but midway between the two, immediately beneath the lower border of the acetabulum. The gemellus inferior and the quadratus femoris had been torn, the ligamentum teres had been wholly detached, and there was a laceration in the lower part of the capsular ligament.⁴

Dr. Blackman, of Cincinnati, informs me that, in January, 1859, he reduced a subcotyloid, incomplete dislocation, in a man æt. 70, by manipulation, Dr. Judkins lifting the thigh upward and outward by means of a towel, while Dr. Blackman first flexed and then abducted the limb.

¹ New York Med. and Phys. Journ., vol. v. p. 597, 1826. Letter to the Hon. Isaac Parker, etc., by John C. Warren, 1826. North Amer. Med. Journ., vol. iii. p. 169.

² Amer. Journ. Med. Sci., vol. xvi. p. 226, 1835, from Lond. Med. Gaz., vol. x. p. 19.

³ Wormald, London Med. Gaz., 1836.

⁴ Luke, Med. News and Library, vol. xvi. p. 34, March, 1858, from Med. Times and Gaz., Jan. 2, 1858.

7. Dislocations Forward into the Perineum.

Syn.—"Périnéales;" Malgaigne. "Luxations sur la branche ascendante de l'ischion;" D'Amblard. "Inward on the ramus of the os pubis;" Skey.

D'Amblard published an example of this accident in 1821, occasioned by a violent muscular exertion made by the patient in an effort to spring into his carriage, the symptoms attending which did not differ materially from those which were found to be present in the three following examples, except that in the first case the toes were turned slightly inward, while in each of the other cases they were turned outward.¹

Mr. E., æt. 35, a calker by occupation. The injury was received while at work under the bottom of a canal-boat, the boat being raised upon props three and a half feet long. The patient was standing very much bent forward, with his feet far apart, between which lay a piece of round timber one foot in diameter, when the props gave way, letting the whole weight of the boat upon himself and his companions. One of the workmen was killed outright. On extricating Mr. E. from his situation, the left leg and thigh were found extended at a right angle with the body, the toes turned slightly inward, the natural form of the nates was lost, and the head of the femur could be felt distinctly moving, when the limb was rotated, in the perineum, behind the scrotum, and near the bulb of the urethra. For the purpose of reduction, the patient was laid on his back upon a table, and the pelvis made fast by a muslin band. Extension, accompanied with moderate rotation, was then made in a direction outward and downward, bringing the head of the bone over the ascending ramus of the ischium, beyond which it was lying, into the foramen thyroideum; and from this position the bone was replaced in the acetabulum, by carrying the dislocated limb forcibly across the opposite one. The patient soon recovered the use of the joint.²

J. B., an Irishman, æt. 40, on entering the St. Louis Hospital, gave the following account of his accident, which had occurred six hours previously: He was engaged in excavating earth, and having undermined a bank, it unexpectedly fell upon his back while he was standing in a bent position, with his thighs stretched widely apart. The weight crushed him to the earth, breaking both bones of his right leg, the radius of the same side, and dislocating the left hip into the perineum. The thigh presented a peculiar appearance, being placed quite at a right angle with the body, but somewhat inclined forward. The part of the hip naturally occupied by the trochanter major presented a depression deep enough to receive the clenched fist; while the head of the bone could be both seen and felt projecting beneath the skin of the raphe in the perineum. Rotation of the limb, which was difficult and excessively painful, rendered the position of the head still more manifest. The patient had also retention of urine, occasioned probably by the pressure of the femur upon the urethra. Having dressed the fractures, Dr. Pope placed the patient under the full influence of chloroform, and then proceeded to reduce the dislocated thigh; for which purpose "two loops were applied, interlocking each other in the groin, and, using the leg as a lever, extension, by means of the pulleys, was made transversely to the axis of the body. A steady force was kept up for a short time, and the thigh-bone glided into its socket with a snap that was heard by every attendant and patient in the large ward."³

A man, æt. 22, was admitted to the Toronto Hospital, under the care of Dr. E. W. Hodder, having been injured by the fall of a bank of earth an hour before. The head of the right femur was found under the arch of the pubes,

¹ Malgaigne, op. cit., tom. ii. p. 876.

² W. Parker, New York Med. Gaz., 1841; N. Y. Journ. Med., March, 1852, p. 188.

³ Pope, St. Louis Med. and Surg. Journ., July, 1850; N. Y. Journ. Med., March, 1852, p. 198.

the neck resting upon the ascending ramus. The thigh formed nearly a right angle with the body, being strongly abducted, and the toes were slightly everted. On the following day, the patient being under the influence of chloroform, extension and counter-extension were employed in the direction of the axis of the femur, that is, nearly at right angles with the body, while, at the same moment, the upper portion of the femur was lifted by a round towel. By this manœuvre the head of the bone was carried into the foramen thyroideum. The force was now applied in a direction "more upward and outward; the ankle held by the assistant was drawn under the other and at the same time rotated." In a few minutes the complete reduction was accomplished. His recovery was steady, and three weeks later he was discharged, being able to walk very well with the aid of a cane.¹

§ 6. Ancient Dislocations of the Femur.

Sir Astley Cooper was of the opinion that three months after the accident for the shoulder, and eight weeks from the hip, may be fixed as the period at which it would be imprudent to attempt to make the reduction, except in persons of extremely relaxed fibre or of advanced age. At the same time, he was fully aware that dislocations have been reduced at a more distant period than that mentioned; but in many instances the reduction has been attended with evil results.

Later surgeons do not seem always to have correctly understood this remark, or, if they have understood, they have not correctly represented; since it has many times been affirmed of this surgeon, that he regarded reduction of the hip as impossible after eight weeks, and they have proceeded to cite examples which would prove that he was in error. But long before Sir Astley's day, Gockelius mentioned a case of reduction of the femur after six months, and Giulio Saliceto declared that he had reduced a similar dislocation after one year,² and Sir Astley says that he is "fully aware" of the existence of such facts or statements; yet with a knowledge of what has so frequently followed these attempts, he would not recommend the trial after eight weeks, except under the circumstances by him stated; and notwithstanding the number of these reported successes has been considerably increased in our day, I suspect that Sir Astley's rule will continue to govern experienced and discreet surgeons. Certain examples which have recently been published of successful reduction after six months by manipulation, if sufficiently verified, would encourage a hope that the period might be greatly extended.

The following case was published in the first edition of this treatise, but I regret to say that I am now unable to say from what source my information was then obtained, and communications addressed by me to gentlemen in Havana have failed to trace the case to its original source. A careful reading of the report must convey to the experienced surgeon a suspicion that it may not have been correctly diagnosticated, and that, if it was, its reduction may not have been thoroughly accomplished and permanently maintained.

A Chinese boy, aged about sixteen years, arrived at Havana on the 4th of June, 1856, suffering from a severe illness. When sufficiently recovered to rise upon his feet, it was ascertained that he had a dislocation of the left femur upon the dorsum ilii. The accident had occurred before leaving China, a period of more than six months. Deeming the use of anæsthetics improper, on account of the boy's feeble condition, these agents were not employed. Dr. Dupierris proceeded as follows: The body being held by two assistants by means of two bands, one of which passed beneath the perineum, and the other under the axillæ, traction was made upon the limb by two strong and intelligent assistants. The

¹ Hodder, *British Amer. Journ.*, March, 1861.

² Malgaigne, *op. cit.*, tom. ii. p. 185; from *Gallicinium Medico-practicum*, Ulm, 1700, p. 288.

movement of the head of the bone, resulting from this manœuvre, was very limited, even when the force was much increased; and the excruciating pain, which the patient referred to the iliac region, compelled him to desist. The following day he concluded to attempt the reduction by flexion. The patient being placed upon his back, and the trunk of the body made steady by assistants, with the left hand he grasped the upper part of the leg, placed the right hand upon the head of the bone in the iliac fossa, and then proceeded to flex the leg upon the thigh, and the thigh upon the pelvis. By this movement the great gluteal muscle was relaxed, and the head of the bone advanced, while with the right hand he directed the latter toward the cotyloid cavity. As soon as he judged the head to be immediately above the centre of the socket, he extended the leg, the thigh remaining flexed at a right angle; and then using the limb as a lever, he rotated it from within outward, and at the same time extended it by making a movement of circumduction in a similar direction. When, by these procedures, the limb was brought near to its opposite fellow, a snap audible to the assistants indicated the return of the head of the bone to its natural position; a fact which was further substantiated by the establishment of the original length and form of the member and the subsidence of the pain.

The case reported by Guyenot,¹ of a woman twenty-two years of age, in which Cabanis is said to have accomplished reduction after the dislocation had existed two years, was probably an example of chronic hip disease.

Nor is it proper to accept of the accidental reduction of the femur, reported to Sir Astley Cooper² by Mr. Cornish, as a well-authenticated case.

Dr. Lewis A. Sayre, in a paper read before the American Medical Association, has reported a case of *pathological* dislocation, into the ischiatic notch, of nine months' standing.³

The patient, Lieut.-Col. William A. Bullit, was wounded in battle, May 9, 1864, in two places, the first ball entering five inches below the anterior superior spinous process of the ilium, and remaining. More than five months after the injury he, for the first time, turned from his back to his side, and in doing so he felt "a slipping" of the caput femoris. This occurred almost daily for two weeks, when, dislocation being recognized, Dr. McDermott, assisted by Drs. Coolidge and Goldsmith, U. S. A., attempted to reduce it under ether, but failed. "In the latter part of February, 1865, four months after dislocation," another attempt was made to reduce it, under chloroform. The fact that this was not a traumatic dislocation, dating from the period of the original injury, is thus confirmed by Dr. Sayre, for it was already more than nine months since he had been wounded, but the dislocation had taken place only four months previous. At this time the attempt at reduction was made by Professor Cook, assisted by Drs. Force, Cox, Galt, and Garvin, all of Louisville, Ky. This attempt failed also. July 20, 1865, Dr. Sayre, in the presence of several gentlemen, including myself, the patient being under chloroform, forcibly broke up some adhesions and brought the limb, which was flexed upon the pelvis, down to a position nearly but not quite parallel with the other, and there secured it with a weight and pulley. There was no claim at the time, so far as I know, that a restoration of the bone to its socket had been effected. Some months later I saw this gentleman standing with a high heel under the boot corresponding to the lame leg, and I was then informed by Dr. Sayre, in reply to my inquiry, that the dislocation was not reduced, but that, as I could see, the position of the limb was greatly improved. In Dr. Sayre's report of the case he does not state when the dislocation was reduced, and certainly it was not reduced in my presence; and I have no reason to suppose that it was subsequently.

Dr. George E. Post, Missionary in Syria, and a Professor in the Protestant College, at Beirût, has reported a remarkable case of dislocation of both hips in a native girl, thirteen years old, "the result of a *vis a tergo*, applied six months previous" to her admission to the hospital. The force applied to her back caused her to fall forward, with a "twisting of the trunk to the right, and the

¹ Mém. de l'Académie Royal de Chirurgie de Paris, tom. cinquième, p. 803.

² Sir Astley Cooper, Frac. and Dis., 2d Lond. ed., p. 101.

³ Sayre, Case of Luxation of Femur into Ischiatic Notch, of nine months' standing, Reduced by Manipulation, Trans. Amer. Med. Assoc., 1866, p. 263.

lower extremities to the left." She was admitted Jan. 20, 1877. At this time it was ascertained that she had a dislocation not only of the left femur, but that there was a fracture of the neck also on the same side; the head had become necrosed, and there was a sinus communicating with the head as it lay upon the *dorsum ilii*. An incision was made, and the dead bone was removed. The ankylosed knee and thigh were then straightened by *brisement forcé*, the restoration being accompanied with a good deal of laceration. The left lower extremity was then committed to an assistant, while the requisite manipulations were undertaken to reduce the dislocation of the right hip. This was effected without pulleys, adding another to the many proofs that bone-setting is a matter of address and attention to anatomical relations rather than to force." The patient recovered after a prolonged confinement, and at the last accounts was able to walk with crutches, the function of the right limb being fully restored, and the left being shortened four and a half inches.¹

It is unnecessary to say that the mode of production of this double dislocation was extraordinary, and that the facility with which the right hip was reduced at the end of six months was equally extraordinary; and that for these reasons the distinguished operator owed it both to himself and to the profession to supply a more complete history of the case, symptoms, and treatment than he has given. In so far as the cause and the mode of reduction are concerned, I have given my readers all that the report contains.

The case reported by Bigelow, of reduction after three months, must be rejected also as a traumatic dislocation. Dr. Bigelow says himself that it was "perhaps connected with hip disease," as there was evidence of disease in the joint for some time prior to the accident which was supposed to have caused the dislocation, and its subsequent existence was demonstrated by sinuses which formed and opened in the groin. He had also had for a long time disease of the bone near the ankle.²

Dr. Brown's case of reduction of ancient dislocation of the femur in a child eight years old, cannot be considered in this connection, inasmuch as he states that the dislocation was probably caused by chronic rheumatic arthritis.³

In the accompanying table I have inserted such cases as have up to the present moment the best claim to be regarded as actual reductions of traumatic hip-joint dislocations after a period of eight weeks. Some of them, however remarkable they may seem to be, there exists now no satisfactory means of verifying or of disproving. Others, even among those reported by my contemporaries, are so briefly and imperfectly reported that they do not seem to me thoroughly established—certainly not by that sort of testimony which science demands where unusual and extraordinary facts are recorded. While estimating the relative value of the several methods of reduction, I have cited several examples of fracture of the neck of the femur in the attempt to reduce old dislocations. In some cases the results have been much more serious.

A man, 29 years old, was received at La Pitié, Paris, on the 13th of May, 1868, with dislocation of the hip of seven months' standing. M. Broca attempted to reduce it, using a force of 480 lbs. No reduction was obtained, and the patient insisted upon leaving the hospital five days afterward. A fortnight then elapsed, when he presented himself at another hospital, with the hip enormously swollen, and died the next day of peritonitis. The autopsy showed that the head of the bone lay in the ischiatic notch, that it was held firmly by bundles of the torn capsule, and that the cotyloid cavity was much shrunk. Pus was found in the

¹ Post, Med. Record, May 11, 1878, p. 366.

² Bigelow, Disloc. and Frac. of Hip, 1869, p. 111.

³ Spontaneous Dislocation on Dorsum Ilii; Reduction after several months. By Francis Brown, M.D., etc. A pamphlet. Boston Med. and Surg. Journ., Sept. 29, 1870.

TABLE OF TRAUMATIC DISLOCATIONS OF THE HIP, REDUCED AFTER EIGHT WEEKS.

No.	Operator.	Age of patient. Years.	Time after dislocation.	Form of dislocation.	Method of reduction.	Reference.
1	S. Nott,	33	56 days.	On dorsum ilii.	Extension.	Sir Astley Cooper, Disloc. and Frac., etc., 2d Lond. ed., p. 50.
2	Desprès,	48	66 days.	Foramen ovale.	Extension, with anæsthesia.	Bull. Soc. Chir., 1879, p. 142.
3	A. Crosby,	...	68 days.	Extension, with anæsthesia.	Trans. Amer. Med. Assoc., vol. iii. p. 356. An. 1850.
4	Pollock,	72	72 days.	Ischiatic notch.	Extension, with anæsthesia.	The Lancet, 1880, vol. ii. p. 130
5	Breschet,	...	72 days.	Brown, Boston Med. and Surg. Journal, Sept. 29, 1870.
6	Dupuytren,	23	78 days.	Dorsum ilii.	Extension.	Dupuytren on Diseases and Injuries of Bones. Lond. ed., 1847, p. 373.
7	Kimball,	...	3 mos.	Northwestern Med. and Surg. Journ., June, 1870.
8	Doutrelepont,	7	3 mos.	Dorsum ilii.	Extension.	Berliner klinische Wochenschrift, 1876, No. 31, p. 455.
9	Bayer,	...	3 mos.	Foramen ovale.	Manipulation.	Prager med. Woch., 1880, No. 30. (Poincet)
10	Blanc,	...	3 mos.	Journ. des Conn. Méd. Chir., 1870, No. 2.
11	Dupuytren,	25	99 days.	Dorsum ilii.	Extension.	Dupuytren, op. cit., p. 375.
12	W. L. Atlee,	...	4 mos.	Extension, with anæsthesia.	Trans. Amer. Med. Assoc., vol. iii. p. 357, An. 1850.
13	Williams,	8	5 mos.	Probably in ischiatic notch.	Anæsthesia.	The Lancet, vol. i. p. 665, An. 1862.
14	Bigelow,	7	5 mos.	Dorsum ilii.	Manipulation.	The Lancet, 1878, vol. i. p. 86.
15	MacGee,	...	5½ mos.	Manipulation.	American Journ. Med. Sci., January, 1871.
16	Gockelius,	...	6 mos.	Gallicinium Med.-pract., Ulm, 1700, p. 288.
17	Dupierris,	16	6 mos.	Dorsum ilii.	Manipulation.	
18	Blackman,	...	6 mos.	Western Lancet, April, 1856, p. 253.
19	Peltavy,	34	6 mos.	Foramen ovale.	Manipulation.	Wiener med. Wochenschrift, 1873, No. 47.
20	Bigelow,	27	8 mos.	Dorsum ilii.	Manipulation.	Bigelow on Dis. and Fract. of Hip, 1869, p. 55.
21	Carron du Villars,	...	8 mos.	Foramen ovale.	Extension.	Malgaigne, op. cit. vol. ii. p. 868.
22	Smyth,	27	9 mos.	Dorsum ilii.	Manipulation, with anæsthesia.	New Orleans Journ. Med., Jan. 1, 1869, p. 71.
23	Saliceto,	...	1 year.	Malgaigne, Fract. and Dis., Paris ed., 1855, vol. ii. p. 185.

capsule, in the iliac fossa, in the articular cavities, and had found its way into the peritoneum, through the obturator foramen.¹

The following case seems deserving of mention, for the reason that it is the first, so far as I am aware, in which an attempt has been made to reduce the dislocation after a subcutaneous division of the capsule: T. J., æt. 28, of Utica, N. Y., was sent to me by Dr. Jenkins, in January, 1869, having a dislocation of his left femur upward and backward upon the dorsum ilii. His account of the case was, that seven months before he was thrown in wrestling; a surgeon was called on the following day, and finding a dislocation, he placed him under the influence of an anæsthetic, and, as he supposed, reduced the dislocation by manipulation. The case did not come under the notice of Dr. Jenkins until a few weeks before he was sent to me, and although the character of the accident was recognized, no attempts were made at reduction. I found the limb rotated inward, adducted, and shortened two inches. Before the class of medical students at Bellevue, assisted by Drs. Sayre, Crosby, Howard, and others, I made an attempt, January 29th, to break up the adhesions and reduce the dislocation, the patient being fully under the influence of ether. We were able to move the limb quite freely in various directions; but after a trial of nearly an hour, we abandoned the attempt, having failed to accomplish reduction.

A few days later I applied extension, by means of adhesive plaster and a cord, with a weight of twenty pounds. This was continued unremittingly until February the 24th, when he was again placed under the influence of ether before the class. Assisted by Drs. Stephen Smith, Howard, Cross, and others, attempts were made to reduce the bone by manipulation, but without success. Believing now that the untorn portion of the capsule, and particularly the ilio-femoral ligament, constituted the chief obstacle to the reduction, I introduced a long, firm, but narrow bistoury, which I had had made for the purpose, just above the trochanter major, carrying its point inward until it touched the neck at the base of the trochanter. From this point, the edge of the knife being directed toward the head of the bone, I swept the point of the knife slowly along until the head was distinctly felt, the point touching the neck apparently in its whole length. This was accomplished without enlarging the external opening. While the incision was being made the limb was kept rotated outward, and abducted as much as was possible, and it was felt to yield distinctly, so that both rotation outward and abduction were more complete afterward than before. I then divided also the tensor vaginae femoris; and now the attempts at reduction were repeated, both by manipulation and extension, but without success.

The result of this attempt to reduce the dislocation by division of the ilio-femoral ligament, although unsuccessful, encourages a hope that it may sometimes succeed; and I shall not hesitate to repeat the experiment, if a favorable opportunity is presented.

In 1878, Dr. MacCormack, of London,² practised subcutaneous tenotomy of the muscles for the purpose of reducing a dislocation into the foramen ovale, which had existed two years. The patient was 19 years old. The section of the muscles gave no result; and Dr. MacCormack then exposed, by a free external incision, the articulation; and finding the socket was nearly obliterated he resected the head of the femur, and obtained a satisfactory result. In 1876, Volkmann,³ also, practised resection of the head of the femur, after having exposed the joint and divided the muscles extensively, in the hope that in this way he might effect the reduction; but in which case, as in the case of MacCormack, the reduction was even then found impracticable. The patient was a man, æt. 51, who had a dislocation into the perineum of about three months' standing, and which Volkmann had tried in vain to reduce by other methods. The head of the femur was found upon the dorsum of the ilium, to which point it had been carried by the previous manipulations. The head and neck were resected at a point below the trochanter, and the operation resulted in a complete recovery, and in giving to the patient a tolerably useful limb. M. Polail-

¹ New York Med. Record, Dec. 16, 1868.

² MacCormack, St. Thomas's Hosp. Rep., vol. ix. p. 101.

³ Volkmann, Ranke, Berliner klin. Wochenschrift, 1877, No. 25, p. 357.

lon¹ reports the case of a man, æt. 46, who had a dislocation upon the dorsum ilii. The dislocation had occurred more than six weeks before; and although repeated attempts were made to reduce the dislocation, commencing on the day following the accident, and by various methods, it still remained unreduced; but the head had been transferred from the dorsum to the foramen ovale, in which position it lay when M. Polaillon proceeded, with antiseptic precautions, to open the joint, and to sever the ligamentous and muscular attachments which prevented the return of the bone to its socket. Reduction having been effected, the wound was closed. The patient died on the fourth day, his death being caused, as it would appear, by septicæmic infection.

[Resection of the head of the femur, with proper use of antiseptic remedies, is now a very safe operation, and the surgeon who employs them intelligently need not hesitate to perform this operation when he deems it necessary. Nor would it be an improper procedure in obstinate cases to open the joint freely, divide obstructing tissues, and replace the head, as was done by Lister in old dislocations of the head of the humerus.]

§ 7. Partial Dislocations of the Femur.

Malgaigne declares that certain experiments made upon the cadaver led him, at one time, to the conclusion that all primitive dislocations of the femur were incomplete, and that the old complete dislocations found in autopsies have become so consecutively. Later observations have taught him to correct this error, yet he still finds "incomplete backward dislocations quite common, and incomplete dislocations in all the other directions much more common." I have more than once found occasion to call in question the accuracy of Malgaigne's views in relation to partial dislocations, the relative frequency of which, as traumatic accidents, he seems constantly disposed to exaggerate greatly. I cannot see the propriety of calling those cases partial dislocations, in which the head of the bone has fairly left the cotyloid cavity, and mounted upon its margin, even if it remains in this position without tearing the capsule; since the articular surfaces are now as completely separated as if the capsule had given way, and the head of the bone had escaped through the laceration. It is in fact a complete dislocation. But I doubt very much whether the head of the bone ever rests upon the margin of the acetabulum without tearing the capsule, unless it has previously undergone certain pathological changes, such as I have already described; at least I cannot hesitate to reject all those examples in which the head of the femur is supposed to rest upon the upper or outer margin of the acetabulum; and if I permit myself to speak of incomplete dislocations at all in this connection, I shall reserve the term for those rare cases in which the head of the femur becomes engaged in the cotyloid notch, after breaking down the fibrous band which, in the natural state, is continuous with the rim of the acetabulum.

Of this form of dislocation, I think I have met with two examples; one of which was in the person of a boy, whose thigh was reduced accidentally by his father; and the other occurred in a boy 15 years of age, residing at that time in Rutland, Vermont. He was brought to me on the 28th of May, 1842, by Dr. Haynes, of Rutland, at which time the dislocation had existed five years. His account of himself was that in walking upon a slippery floor, his left leg slid outward and backward in such a manner that when he fell it was fairly doubled

¹ Polaillon, Bull. Soc. de Chir. de Paris, 1883, Séance du 31 Jan.

under his back. On the tenth day following the accident he began to walk with some help, and he has continued to walk ever since, but with a manifest halt. Three months after the injury was received, it was first seen by several surgeons, who pronounced it a dislocation, and attempted reduction without mechanical aid, but were unsuccessful. When the young man was brought to me, the limb was neither lengthened nor shortened, but the thigh was forcibly abducted and rotated outward. It could not be flexed nor greatly extended. The head of the femur could be distinctly felt, as it lay anterior to the socket, but not sufficiently far forward to rest upon the foramen thyroideum.

J. C. Warren, of Boston, has reported a similar example in a child 6 years old, who was brought, April 21, 1841, to the Massachusetts General Hospital. Dr. Hale, who saw the lad at the end of two weeks, thought it a dislocation, but it had been treated by another surgeon as a case of hip-disease. The dislocation had now existed eight or ten weeks. The limb was a little lengthened, abducted, turned outward, and advanced in front of the body, with very slight motion of either flexion or extension, and almost no tenderness about the joint. Dr. Warren, also, was able to feel indistinctly the head of the bone "immediately external to, and in contact with, the insertion of the triceps and gracilis muscles." An attempt was made by manual extension and manipulation to accomplish the reduction, but without success.¹

It is probable that both the above cases, which I have described at length, were examples of partial dislocations; yet I cannot conceal from others a doubt which I actually entertain whether they were not, after all, only examples of hip-joint disease, arrested after having wrought certain slight pathological changes in the joint and the tissues adjacent. If, however, they were not examples of incomplete dislocation of the hip-joint, then I question whether any such cases have ever occurred as simple traumatic accidents.

§ 8. Coxo-femoral Dislocations, complicated with Fracture of the Femur.

Such complications are exceedingly rare, but it will not do to deny their possibility; although in some of the cases reported, the testimony is so incomplete as to leave a doubt whether the surgeons have not erred in their diagnosis.

James Douglas has reported a case of dislocation upon the pubes, complicated with a fracture of the neck of the femur, the actual condition of which was verified by an autopsy; the patient having died twelve years after the injury was received. The head of the femur still remained above the pubes, and was in no way connected with its neck or shaft. The upper end of the femur projected in the groin, lying upon the inside of the femoral artery and vein. Many other curious pathological changes had also occurred.²

The well-authenticated examples of reduction of the dislocation, where the femur was broken also, are still more rare; and several of the recorded examples which my researches have discovered, need additional confirmation.

John Bloxham, of Newport, in the Isle of Wight, claims to have reduced a dislocation of the femur on the pubes, which was accompanied with a fracture of the thigh a little above its middle. On the seventh or eighth day after the accident, "the patient was laid on his back upon the bed, and kept in that position by means of a sheet passed across the pelvis and fastened to the bedstead; another sheet was also passed over the left groin, and secured in a similar manner. The dislocated and fractured limb was then inclosed in splints, one of

¹ Warren, Boston Med. and Surg. Journ., vol. xxiv. p. 220.

² Amer. Journ. of Med. Sci., vol. xxxiii. p. 455, from Lond. and Edin. Month. Journ. of Med. Sci., Dec. 1843.

which extended up the back of the thigh as far as the tuberosity of the ischium. Pulleys, which were secured to a staple in the ceiling, placed at the distance of a foot to the right of a point vertical to the patient's navel, were then attached to a bandage fastened around the splints as high up as possible. The foot was raised with the knee extended, so as to bring the limb nearly to a right angle with the line of the tackle, when by drawing gradually on the cord, in the course of about ten or fifteen minutes the head of the bone was rendered movable, and was brought considerably more forward. I then began to press on the head of the bone, so as to push it downward, while the pulleys held it partially disengaged from the pelvis. In a few minutes the head of the bone passed over the ridge of the os pubis, and I then directed the foot to be raised a little higher, which by putting the glutei muscles more upon the stretch was calculated to render them more efficient in drawing the bone into its proper place. By this manœuvre, the head of the bone was drawn backward, and on the foot being more elevated and the cord slackened, it continued to recede from my fingers till the trochanter major made its appearance in the natural situation, and the reduction was found to be perfectly complete. Lest the head of the bone should slip backward on the dorsum ilii, I directed an assistant to apply firm pressure during the latter part of the process, above and behind the acetabulum. The apparatus was then removed, the thigh bound up in short splints, and the patient laid upon a double-inclined plane. No symptoms of inflammation appeared afterward about the joint. Passive motion was employed at the end of a week, and occasionally repeated during the whole reparatory process."¹ Without intending to question the accuracy of the statements in this case, which, in the main, seem to bear the marks of credibility, I must express my surprise that so little difficulty was experienced in the reduction if the femur was actually broken, no more, indeed, than is usually experienced when the bone is not broken; and that Mr. Bloxham was able to employ safely passive motion at the end of a week.

Charles Thornhill² relates a case of fracture of the femur through its upper third, in a man æt. 40, with dislocation into the ischiatic notch; which dislocation, he assures us, was reduced at the end of six weeks. But it is much more probable that, instead of reducing a dislocation, he refractured the bone. During more than one hour and a half, aided by pulleys, tractions and manipulations were made in almost every direction. The upper part of the thigh was lifted with all the strength of one man by means of a jack-towel; it was violently rotated, adducted, and abducted. Both the perineal and the knee band gave way, from the excess of the force employed; and, finally, the head of the femur resumed its place with an audible *crash*, after which the "limb was of nearly equal length with the other;" but there remained an "immense deposit" around the acetabulum.³

Malgaigne says that M. Étévé found a man with a dislocation of his left thigh backward, a fracture near its middle, a penetrating wound of the knee, and a fracture of the fibula in the same leg. Without delay he proceeded to reduce the dislocation by directing two assistants to support the body, three to support the leg, and two more to make extension from a towel tied not very tightly around the thigh above the fracture. The leg was then extended upon the thigh and the thigh flexed upon the pelvis until it was at a right angle with the body; and after a gradual extension had been made in this direction, M. Étévé pushed with all his strength the head of the bone into its socket. Of which case Malgaigne justly remarks that the "extension" practised by the surgeon was only imaginary.⁴ If the reduction was accomplished at all, it was by manipulation and pressure.

Finally, Markoe relates the case of a boy æt. 8, who was admitted into the New York City Hospital, on the 29th of June, 1853, with a compound fracture of the right thigh, a simple fracture of the left, and a dislocation of the head of the right femur upward and backward upon the dorsum ilii. When placed

¹ Lond. Med.-Chir. Rev., vol. xix. p. 420, Oct. 1833.

² London Medical Gazette for July, 1836.

³ Amer. Journ. Med. Sci., vol. xxv. p. 218.

⁴ Malgaigne, op. cit., tom. ii. p. 206; from Gazette Méd., 1838, p. 757.

upon the bed, the right limb lay obliquely across the abdomen of the boy, with the foot resting against the axilla of the left side. "The house-surgeon to whose care the case fell on admission, took the injured limb in his hands very carefully, carried it over the abdomen to the right side, and then abducted it and brought it down toward the straight position," during which procedure the head of the bone is supposed to have resumed its place in the socket.¹ Such is the account furnished of the symptoms and treatment of this extraordinary case; too meagre, certainly, to entitle it to much confidence, or to permit us to draw from it any practical inferences.

I have been unable to find any other examples of fracture of the femur complicated with dislocation; and, rejecting at least Mr. Thornhill's case as altogether incredible, the proper conclusion would be, that reduction is sometimes possible in recent cases, if the surgeon will resort promptly, before swelling and muscular contractions have taken place, to manipulation combined with pressure upon the head of the bone. Indeed, it is probable that pressure alone is the means upon which the success will finally depend. Richet says that he has several times dislocated the femur in the cadaver; and then having sawn off the head so as to represent a fracture, he has always been able to push the head of the bone easily into its socket.² By seizing the moment then when the patient is laboring under the shock, or by placing him completely under the influence of an anæsthetic, no resistance will be offered by the muscles any more than in the cadaver, and the reduction may, perhaps, be easily effected. I have no confidence that anything can be accomplished by extension; nor do I think it will be best to wait until the femur has united, since such delay will probably render the reduction impossible.

§ 9. Voluntary or Spontaneous Dislocations of the Femur.

Examples in which persons, having suffered no disease of the hip-joint, have been able voluntarily to dislocate the femur, have, from time to time, been recorded, but I am not aware that any dissections have ever been made in these cases. I shall, therefore, not attempt any explanation of the facts, but simply record them as matters of curious interest, and for the purpose of inducing others to make of them a subject of investigation.

Malgaigne remarks that "certain persons, without having suffered from any injury or disease of the joint, have the singular faculty of dislocating and reducing the femur voluntarily. Portal saw an example in the person of the Abbé of Saint-Benoit. Humbert mentions a surgeon near Troyes, who dislocated the femur up and down, and reduced it by the simple act of the muscles, without the aid of his hands. He reports at the same time, the curious history of a person endowed with the same power, who after a quarrel produced the dislocation, and then claimed damages, attributing the accident to the violence of his adversary." The same author speaks of cases reported by Coulson, Solly, and Stanley, and the one hereafter to be mentioned alluded to by Sir Astley Cooper, making in all seven cases. It does not appear, Malgaigne adds, that

¹ New York Journ. Med., Jan. 1855, p. 30.

² New York Journ. Med., March, 1854, p. 293; from *Bullet. de Thér.*

"this laxity impairs the functions of the limb; it is nevertheless a subject which demands to be better studied."¹

Sir Astley Cooper says, "I have received from Mr. Brindley, surgeon, of Wink Hill, an account of a dislocation of the os femoris, which the patient is able to produce and reduce when he chooses. The man is fifty years of age."²

Samuel Cooper speaks of this matter briefly as follows: "There are instances recorded of persons who could dislocate their thigh-bone spontaneously, and afterward replace it again without assistance. A gentleman, who attended my lectures, informed me of a person so circumstanced, and related some of the particulars to me. I suppose that, in such cases, there must be an unusual relaxation of the synovial membrane, a rupture of the ligamentum teres, and perhaps an imperfect state of the acetabulum."³

A case is related in an inaugural essay, by Dr. Lewis, of North Carolina, who graduated at the University of Pennsylvania in the spring of 1841."⁴

Dr. Bigelow has seen two cases, and reports a third from Prof. E. M. Moore, of Rochester. In the first of these the hip was at first dislocated by an accident; and in a few hours it was reduced by manipulation. Eight days after the accident, in attempting to walk, it was again partially dislocated, when the patient himself replaced it by pushing against it with the hand, and pressing with the other against the knee. Since then the man has been able to dislocate the bone backward upon the edge of the socket by muscular action, and to reduce it by throwing the leg out sideways. In the second case seen by Bigelow, "the phenomena are much like those just described." Dr. Bigelow regards them both as subluxations, and speaking of the first case, he says the limb "exhibits slight flexion, shortening, and inversion." Prof. Moore's case (Figs. 481, 482), is described as follows: J. B. Parker, private soldier, U. S. V., was skirmishing up a hill, May 13, 1864, and sprang suddenly back to avoid the gun of a comrade in advance. His left foot became entangled, and his weight dislocated the hip. He felt the injury, and supposed it out of joint. Some comrades put it in, and he immediately resumed his skirmishing, and marched seven miles, from 10 A. M. to 6 P. M. He rested at night, and went on duty the next day, sharpshooting and crawling all day. He continued this kind of duty nine days, and subsequently was on duty in other ways, and did not enter a hospital until the fifteenth day after the accident. When the case was reported to Dr. Bigelow, the man could dislocate the hip at any time by pressing the foot on the floor, to fix it firmly, contracting the adductors, and throwing out the pelvis, when the head "suddenly leaves the acetabulum, and goes on the dorsum." There is a slight inversion while the limb remains in this position. Dr. Bigelow thinks that this is also a subluxation.⁵

The following case was reported to me in 1865, by Dr. Forrest, of Portland, Maine, to whom the man presented himself as a "substitute," while Dr. Forrest was in the service of the U. S. Army. The application was rejected: W. G. Gliddon, æt. 37, farmer, says that he has been able to dislocate and replace the femur at the left hip-joint since he was a boy. It is not the result of any injury or disease, so far as he knows. He is in good health, and his muscular development is complete. He accomplishes the dislocation by throwing the weight of his body upon the left leg, and then contracting certain muscles about the hip. The reduction is generally more difficult than the dislocation, sometimes requiring the aid of his hand. When the head of the bone is out, there is a marked projection above and behind the trochanter major, apparently caused by the pressure of the head in this situation; the limb is very slightly if at all everted; while out of place it causes pain; and after a few repetitions the pain becomes so great as to compel him to desist. The limb was not measured while it was dislocated. When the limb is in position he does not walk lame."

¹ Humbert, *Essai sur less lux. spontanées du femur*, 1835, p. 35. From Malgaigne, *op. cit.*, vol. ii. p. 883. He also refers to *Gaz. des Hôpitaux*, 1841, p. 104.

² Brindley, *Sir Astley Cooper on Disloc. and Frac.* Preface to 2d Lond. ed., 1823.

³ Samuel Cooper, *First Lines*. New York ed., 1844, vol. ii. p. 385.

⁴ Gibson's *Surgery*, 6th ed., An. 1841, vol. i. p. 387.

⁵ Moore, Bigelow. *Disloc. and Fractures of the Hip*, by Henry J. Bigelow, 1869, p. 112.

Dr. Maurice Perrin¹ brought before the Surgical Society of Paris, in 1859, a man aged 22 years, who when 10 years old had suffered a dislocation of the right hip in consequence of a fall from a horse, in which his leg was caught in the harness, and his body suspended in a position of forced adduction. On the following day it was reduced. Two or three months later it was reproduced by a slight misstep. At a later period he was found to be able to dislocate and reduce the dislocation at will. When presented to the Surgical Society this fact was verified, and admitted by Chassaignac, Marjolin, Morel-Lavallée, and many others who were present.

FIG. 481.

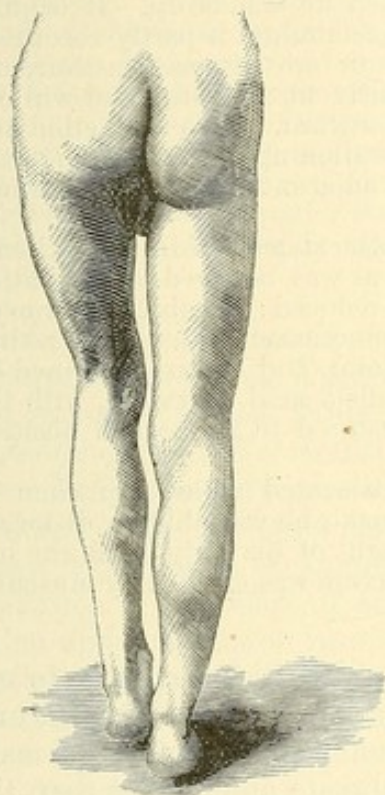
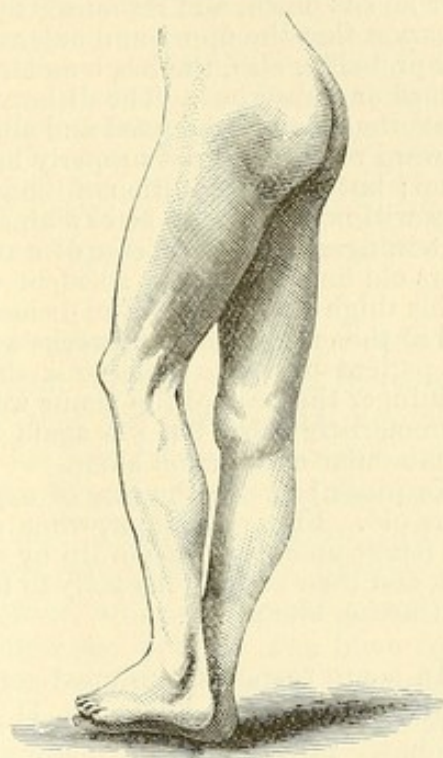


FIG. 482.



Voluntary subluxation upon the dorsum ilii. Case of Parker. (From Bigelow and Moore.)

The following case came under my personal observation: Dr. William G. S., æt. 24, received an injury on the outside of the right knee, in February, 1862, from the kick of a horse. There was no apparent injury of the hip. On the fourteenth day after the accident he rode forty miles on horseback, which was followed by some stiffness in the right hip. Two weeks later, in mounting his horse, he felt something slip in the hip-joint. From that day until this, a period of four years, he has been able to reproduce the same slipping voluntarily, and which phenomenon I recognize as a dislocation upward and backward. I have examined him more than once, and he has dislocated and reduced the dislocation in my presence repeatedly. Planting his right foot firmly upon the floor a little in advance of the left, with his toes turned out, he throws his weight upon the right leg by carrying his pelvis well over to the right, and then contracts powerfully the gluteal muscles. Instantly the head leaves the socket, and seems to mount upon the dorsum; the trochanter major becomes rotated inward, causing a slight inward rotation of the leg and foot. He can do the same when lying on his back, but not with the same ease. Reduction is accomplished without change of position, but by what precise manœuvre I have not determined. The reduction is more quiet, and less sudden, apparently, than the dislocation.

¹ Perrin, *Gaz. des Hôp.*, 1859, p. 367.

Both manœuvres are accompanied with some pain. He is not lame, nor does the dislocation take place without his volition. I have seen one case, also, which, although pathological in character, was nevertheless caused by an early injury, and as such may properly be noticed in this connection.

Dr. O. Gillett, æt. 65 (1867), of Westernville, Oneida Co., N. Y., was injured in his left hip-joint when 16 years old, by lifting a heavy weight. He felt at the moment something give way in the joint, and he has been lame ever since; at first he was quite lame, but after a time the soreness about the joint diminished, and up to within about three years the lameness was chiefly due to a lack of development in the limb. Since then the joint has again become tender, and during the last nine months he has been able to throw the head of the bone out of the socket, backward and upward. Indeed, the bone is dislocated whenever he sits down, and resumes its place again when he stands up. It is quite apparent that the upper and outer margin of the acetabulum is partly absorbed; and probably, also, the head and neck of the femur are in some measure deformed and absorbed. The dislocation is apparently incomplete; and while it exists the thigh is abducted and slightly rotated outward. This abduction and outward rotation do not properly belong to a dislocation upon the dorsum of the ilium; but as the condition of the joint and of the adjacent muscles is abnormal, they will not require to be explained.

Deininger¹ relates the case of a retired soldier, who stated to him that when 7 years old he met with an accident which caused, as was believed, a dislocation of his thigh backward. The dislocation was not reduced; an abscess formed; and at the end of fourteen weeks a spontaneous reduction ensued. After a time the patient began to observe a slipping of the joint, and when examined by Deininger the head of the femur was at each step dislocated backward, with the characteristic noise, but was again immediately restored to its normal position by muscular contraction alone.

Karpinski² reports the case of a man who had dislocated his left hip when 16 years old. Five years later, when seen by Karpinski, he was able to dislocate the femur upon the dorsum ilii by resting the weight of his body upon the left foot, and then turning his body to the left. Reduction was effected by muscular contraction alone.

In some respects the most remarkable example which has come to my knowledge is that of Charles H. Warren, the celebrated contortionist and acrobat. Having myself made a careful personal examination of the man, and having observed that he does actually sublunate other limbs than the thigh, it has seemed to me that it would throw light upon this somewhat obscure class of cases if I were to give his history briefly, and describe in detail all the phenomena observed by me. My examination of him was made in 1870, when he was thirty-one years old.

Mr. Warren was born in Schuylersville, Saratoga Co., New York, in 1848. His parents were healthy, and neither of the parents nor either of the five children, except Charles, possessed his peculiar muscular development or power of dislocating the bones. His maternal grandfather is said to have possessed a similar power, but in a much more limited degree. In his own case it was first noticed in his infancy, soon after he began to run about, that he would suddenly fall while running across the floor; and it was soon ascertained that he had been tripped up by the sudden displacement of his hip-joint, but the fall would restore it to place and he would get up and again run about. This is his own account of his case at this early period of life, and it may or may not be correct, as I am not informed that any medical man was ever consulted. His statement, however, finds a confirmation in the fact that an infant son of Mr. Warren, now dead, had the same peculiarity. He has also a little daughter, now living, in whom the same phenomenon, so far as the accidental dislocation of the hip-

¹ Deininger, *Deutsche Militar-Artzl. Zeitschrift*, iii. 2, p. 632, 1874.

² Karpinski, *Idem*, ii. 3, 1873, p. 157. (Poinset.)

joint is concerned, is manifested. He has had no other children, and his wife is a healthy and well-formed woman. In his own case this tendency to accidental and involuntary dislocation of the hip-joint only lasted two or three years after he began to run about. Since then, it only occurs by an act of volition and under the powerful contraction of the muscles. It is not even apt to occur during his performance of gymnastic and contortion feats. As a boy, Warren ran about as other children and at five years went to school, but when eight years of age he left home and joined a travelling circus. At eighteen he began to work at the trade of car-making, but soon returned to the circus.

Mr. Warren informs me that Walter Wentworth, a professional contortionist, now about forty-five years of age, and weighing perhaps 115 pounds, is probably more flexible than himself, but possesses rather less muscular power, yet he is very strong. John Santiago de Gibinois and George Mankin are probably as strong as himself; Lister, of the New York circus, now dead, was probably superior to anyone who has ever lived as a contortionist. The latter died at the age of forty-eight, and practised successfully his profession to the last days of his life. Yet not one of these men had the power of dislocating his bones which Warren possesses. It is clear, therefore, that we ascribe Warren's peculiar power in this respect to a congenital abnormality, namely, a great capacity and lengthening of the capsular structures, united with later muscular development from exercise. Warren is rather above the average height, slender, and well proportioned.

I have called attention to these historical details, because they seem to illustrate—*first*, that Warren had a congenital relaxation of the ligaments and capsules of the joints; and *second*, that his prodigious muscular development was the result of early and long-continued muscular exercise; while the daily practice of contortion maintained the ligaments and capsules in their original abnormal condition. There is, therefore, in this case a combination of anatomical conditions rarely met with, namely: a relaxation of one class of structures or tissues, and an unusual power of action and contraction in another. We often see persons who have congenital or acquired (pathological) relaxation of the articular ligaments, but this is associated in most cases with muscular weakness. So also there are frequent examples of great muscular power, the result of exercise, but the joints are compact also. None of them have the power of dislocating their bones by muscular action. The following are the results of my examination of Warren's voluntary dislocations.

Inferior Maxilla; Partial Dislocation Forward.—This is accomplished probably by the action of the external pterygoid muscles. There is nothing worthy of special note in this, inasmuch as the ability to displace the condyle to this extent is not very unusual. The condyle resumes its place the moment the action of the muscle ceases.

Clavicle; No Displacement.—He has no power to displace the clavicle at either articulation.

Scapula; Displacement of Lower Angle.—This displacement is very remarkable, the lower angle of the scapula being lifted upward and outward until it lies nearly on a level with the top of the shoulder, and is made to project far backward. We are enabled here to study carefully the mechanism of this displacement, an example of which is every now and then reported in the journals as a "dislocation" of the scapula. It has been ascribed variously to a partial paralysis of the latissimus dorsi, in consequence of which the somewhat feeble hold which it has upon the inferior angle of the scapula is relaxed, and it is unable to retain the

angle in its place; to a detachment of this muscle from the angle in consequence of some violence; to paralysis of the serratus major anticus; and by one writer, to paralysis of the rhomboid muscles. In the case of Warren, it is apparent that it is accomplished solely by the action of the rhomboideus major, which muscle he has the ability to call into vigorous activity, while he suspends the action of the rhomboideus minor, the serratus magnus, the latissimus dorsi and other muscles. We can even trace the fibres of the rhomboideus major as it lies in a state of contraction underneath the trapezius. When this muscle ceases to contract, the angle falls to its place spontaneously.

It is probable that as we see it presented occasionally in other persons, it is due most often to a paralysis of the serratus major anticus; possibly sometimes to a loss of power in the latissimus, and even occasionally to a disruption of the attachment of the latissimus; but it is impossible that it should be due to a paralysis of either of the rhomboids, as has been suggested. Of course I exclude from consideration, now, all those examples of scapular projections which are due to spinal distortions, and which are purely mechanical, and have therefore nothing in common with this case.

Head of the Humerus; Subglenoid Subluxation.—By the action, apparently, of the latissimus dorsi, aided, perhaps, by the lower fibres of the pectoralis major, Warren displaces the head of the humerus downward, until it rests upon the lower margin of the glenoid cavity, causing a very marked depression under the acromion process, and increasing the length of the arm, as measured from this process, about one inch. He soon becomes weary of holding it in this position, and then when he relaxes the muscles, the head rises to its socket without noise or sensation. His ability to perform this feat is equal in the two arms.

Elbow-joint.—The elbow-joint admits of a slight increase of lateral motion above what is usual, and the backward movement, or extension, is greater than is usual with adults; but he has no power to cause either a dislocation or subluxation at this joint.

Wrist-joint; Backward, Forward, and Lateral Subluxation.—By the action of the muscles alone he displaces the carpal bones backward or forward, causing in each case a partial dislocation. He cannot, however, cause a lateral dislocation without first grasping the wrist with the opposite hand—the wrist being grasped firmly by its radial and ulnar margins—when, by the action of the muscles, the carpus is thrown fully half an inch to either side. When the carpus is thrown to the radial side, the hand falls to the ulnar side; and the reverse happens when the carpus is thrown to the ulnar side. When the muscles are relaxed, the carpus resumes its position spontaneously, and without sound or sensation.

Phalangeal Articulations; Subluxations.—He is able to subluxate all the articulations of his fingers, including the thumb. The subluxations backward and forward are effected by muscular action, but the lateral dislocation only by the help of the other hand.

Hip; Apparently Complete Dislocation upon the Dorsum Ilii.—It is in the hip that the greatest scientific and surgical interest of this case centres. After a careful study of the phenomena accompanying certain

motions of the hip-joint in the person of Warren, I have felt compelled to accept of the theory that he causes a true and complete dislocation upon the dorsum of the ilium. We notice that while the patient is standing nude, his form is perfect, except that both feet turn out a little more than is usual with others. With a moderate effort of the muscles the head of the bone seems to move in its socket, and to be carried upward and backward upon the dorsum ilii. The change of position occurs suddenly, and is accompanied with a sensation to the hand as of a bone slipping suddenly into its socket—a sort of heavy thud. When he has dislocated his right leg, he stands upon his left leg, the right being lifted from the floor, the thigh a little flexed upon the body, the leg flexed upon the thigh, with the toes turned a little in. He says, that knowing that it ought to turn in a little more to represent the appearance which the limb usually presents in this dislocation, he sometimes, when exhibiting himself, turns it in more; but this is the position, only slightly turned in, which it naturally takes. Looking for the trochanter major, we find that it has been carried upward and backward full two inches. The head of the bone we are unable to find. It is very difficult to make a comparative measurement of the two limbs when one is thus displaced, but, so far as I can determine, the right limb is shortened at least one inch, probably more. Warren repeated the dislocation several times; the bone always returning quietly to its place after each displacement, without any sound or sensation like that which accompanied its displacement. The same experiment was made with the opposite thigh, and with the same results. Finally, he was laid upon the floor, upon a blanket, and he produced the dislocations equally, but apparently with little more muscular effort.

There seem to be but two possible explanations of the phenomena presented in the case of the femur: either they are produced by the trochanter rotating outward, and pressing firmly against the anterior margin of the glutæus maximus, until suddenly it becomes disengaged and slips under this muscle, while the head of the bone remains in its socket; or, there is a veritable dislocation of the head of the bone.

In favor of the first supposition it may be stated again, that when the displacement in the case of Mr. Warren has occurred, the trochanter major is removed backward and upward full two inches; it remains as prominent as it was before, and the head cannot be found; while in the usual dislocation upon the dorsum the trochanter turns forward, and is less prominent than it was before; and the head of the bone may usually be felt when there is no swelling. How then could this be a dislocation? Plainly only by supposing that there was such an abnormality of the joint—an almost total absence of the rim of the acetabulum in that direction—and perhaps such a broadening of the head, and shortening of the neck, as would permit the head, neck, and trochanter to be drawn up and back by the gluteal muscles, without changing the relations of the line of their common axis to the outer face of the pelvis; that is, without any inward tilting of the trochanter. This would assume the existence of anatomical conditions that are not proven, but only deemed possible.

If the limb is actually shortened, however, there must be a dislocation, and I think it is; but inasmuch as the accuracy of any measurements

under these circumstances might be fairly questioned, we shall for the moment dismiss this argument also.

There now remains only this important fact, that while the trochanter major is carried back, the toes are no longer very much turned outward, as they were before the displacement was made; nor do they point forward, but actually a little inward. So that in fact there is about as much inward rotation of the foot as we could have required to indicate an outward dislocation. But it is plainly impossible that the head of the femur should remain in its socket, while the trochanter is rotated outward two inches, and the knee, foot, and toes not accompany this outward rotation. Certainly it is impossible that the whole lower portion of the limb should rotate inward, as it actually does, while the trochanter is strongly rotated outward. These considerations, it seems to me, must exclude the supposition that there is here only a rotation of the trochanter outward, and a consequent muscular displacement.

Whatever difficulties there may be in the way of supposing that this is a dislocation, they are not insuperable if we assume the existence of some abnormality in the construction of the joint and of the neck. It is possible even, that what we believe to be the trochanter moved back is actually the head of the bone, and that it is the trochanter which is lost; for the change of position occurs so suddenly that neither by the sight, nor with the hands placed upon the trochanter, can we follow the change of position. I only discover, after a sudden commotion, that there is no longer a projection where the trochanter was felt, and which I marked with a pencil in order not to be deceived; and that there is a projection which resembles it precisely, so far as we can determine, two inches further back and upward. Possibly, I say, this new projection is really the head, somewhat changed from its normal form; but I do not think so. Perhaps nothing but an autopsy can determine this and other points connected with the case.

Knee-joint; Rotation and Subluxation.—Mr. Warren has no power to displace the knee-joint by muscular action; but seizing the leg while it is flexed, he can rotate the tibia laterally very freely, and cause the head of the tibia to project beyond the line of the articulation half an inch or more.

Patella.—He has no more power to displace this bone.

Ankle-joint.—With his hands he can abduct and adduct this joint almost to a right angle with the leg.

Tarsal Joints.—By the aid of his hands he can imitate the extremes of varus and valgus.

Phalanges of the Toes.—They are loose, but not so loose in their articulations as the phalanges of the fingers.

Adams,¹ of Glasgow, describes the case of a young man who, when 20 years of age, in trying to imitate an acrobat dislocated his thigh, which he reduced without assistance. After this he found himself able to dislocate either hip at pleasure. In order to accomplish this he raised the foot of the limb which he wished to dislocate, until only the toes touched the floor, and then suddenly flexed and adducted the limb. On ceasing the muscular contraction the bone returned spontaneously to its socket. This patient, who was examined three

¹ Adams, Glasgow Med. Journ., Oct. 1882, vol. viii. No. 4.

years after the original accident, was able also to displace voluntarily the inferior maxilla.

Chassaignac¹ furnishes an account of a vaulting mountebank, who had a congenital dislocation of both hips upon the iliac fossæ, which he was able voluntarily to convert into ischiatic dislocations.

CHAPTER XVIII.

DISLOCATIONS OF THE PATELLA.

§ 1. Dislocations of the Patella Outward.

Causes.—In the majority of cases this dislocation has been occasioned by muscular action; and especially is this liable to occur in persons who are knock-kneed, or whose external condyles have not the usual prominence anteriorly. It may be caused by suddenly twisting the thigh inward while the weight of the body rests upon the foot, and the leg is thus kept turned outward; or by falling with the knee turned inward and the foot outward. Occasionally it is the result of a blow received upon the inside, or upon the front and inner margin of the patella. In some persons there seems to exist a preternatural laxity of the ligamentum patellæ or of the tendon of the quadriceps extensor, which exposes the subject to this accident from very trifling causes.

Fergusson says he has known it to be occasioned by a child's stepping upon the knee of a person lying in bed; and Skey says he has seen two cases which occurred spontaneously during sleep. B. Cooper has seen a young lady who frequently dislocated her patella outward by merely striking her toe against the carpet, or in dancing. Boyer, Sir Astley Cooper, and others mention similar examples.

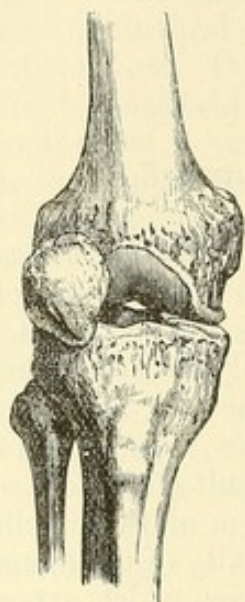
Pathological Anatomy.—Most frequently the dislocation is only partial, the inner half of the patella resting upon the articular surface of the outer condyle; and in consequence of the peculiar obliquity of these surfaces, together with the action of the vasti and rectus femoris, the outer margin of the patella becomes tilted forward. If the dislocation is more complete, this margin begins to fall over backward, as in the accompanying drawing (Fig. 483); and in more extreme cases the patella lies flat upon the outer side of the condyle, with its inner margin directed forward. When the dislocation is partial, it is probable that neither the capsule nor the ligamentum patellæ usually suffers much laceration; but in complete dislocations the capsule at least must have given way more or less.

Norris, of Philadelphia, reports a case of partial dislocation in which the complications were more serious. J. S., æt. 32, was admitted to the Pennsylvania Hospital, on the 27th of August, 1839, in consequence of injuries received a short time previous by having become entangled in machinery. In addition to

¹ Chassaignac, Bull. Soc. de Chir. de Paris, Séance du 28 Janv. 1853, p. 391.

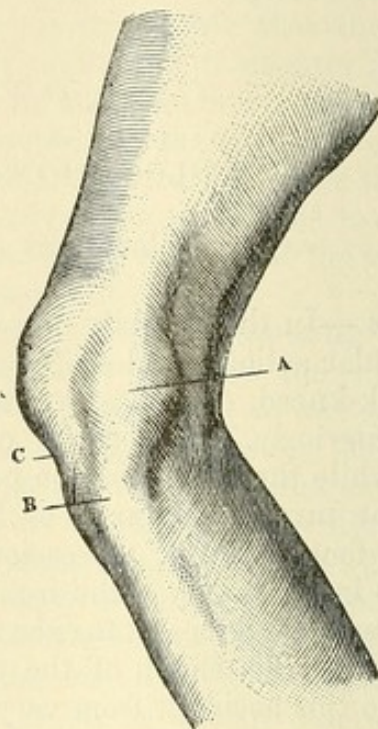
several fractures in other limbs, he was found to have a subluxation of his left patella outward, its outer edge being much raised, and resting on the side of the external condyle of the femur, while its inner edge was depressed, and firmly fixed in the hollow between the condyles. The internal lateral ligament of the knee was ruptured, allowing the head of the tibia to be moved considerably outward. A depression existed, also, between the tubercle of the tibia and the

FIG. 483.



Dislocation of the patella outward.

FIG. 484.



External appearances in outward dislocation.

lower end of the patella, at the middle and inner side of the knee, evidently produced by a rupture of the *ligamentum patellæ* in nearly its whole extent. There was almost no swelling, and the limb was moderately flexed. By firm pressure the patella could be restored to position, but as soon as the hand was removed it returned to its original position. At the end of two months "a good degree of motion existed at the knee-joint, which was in no way inflamed or painful."¹

M. Berger has gathered six examples of ancient complete dislocations outward, which have been examined anatomically, namely, two by Verneuil, two by Tainturier, and two by Philipeaux and Führer. In each of these examples the patella rested upon the tuberosity of the external condyle, which in two cases, of Philipeaux and Tainturier, had become articular, flattened, and covered by newly formed cartilage of considerable thickness. The patella was thickened and globular in the case of Verneuil. It was also rather triangular than rounded in the case described by Tainturier. In Philipeaux's case it was atrophied to about the size of a two-franc piece. The diarthrodial cartilages in one of Verneuil's cases, upon both the femur and tibia, were entire: the external condyle was flattened, and in consequence of the pressure the intercondyloidean space was diminished posteriorly. Tainturier has noted a sort of torsion of the femur from without inward. In two or three of these cases there was observed a laceration of the internal ligaments of the patella, and in one of Verneuil's cases the tendon of the *vastus internus* was torn also.²

Vesale,³ Textor père,⁴ Vering,⁵ Monteggia,⁶ Dupuytren,⁷ and Hamoir,⁸ have

¹ Norris, *Amer. Journ. Med. Sci.*, Feb. 1840, vol. xxv. p. 276.

² Berger, *Art. Rotule, Dic. Encyc. Sci. Méd.*, ser. 3, t. v. p. 343 (Poinot).

³ Berger, *loc. cit.*, p. 341.

⁴ *Ibid.*

⁵ *Ibid.*

⁶ Malgaigne, *op. cit.*, p. 906.

⁷ *Ibid.*

⁸ *Ibid.*

also observed cases in which the displacement interfered but little with the usefulness of the limb.

In a case seen, however, by Bérard, the patient had a dislocation of several years' standing, and there was partial ankylosis of the knee in a position of semi-flexion. Stromeyer and Hopfe have each met with a similar example.

Fowler¹ met with a case in a girl, æt. 21, which dated from her fifth year, and who was so much maimed that Dr. Fowler thought it proper, first, to divide subcutaneously the "patellar tendon," but without any satisfactory result. Eighteen days later he excised the patella. From the report of this case it must be inferred that her condition was not improved by this operation.

Symptoms.—The limb is slightly bent, but immovable; the breadth of the knee is considerably increased; the inner condyle projects unnaturally, and the patella is distinctly felt upon the outer side. If the dislocation is partial, the outer margin of the patella forms an irregular sharp ridge in front of the external condyle. If it is complete, the inner margin presents itself in front of the external condyle, and the outer margin looks backward. Usually the patient suffers great pain as long as the dislocation remains unreduced.

Watson, of New York, saw a case of complete dislocation of the patella outward in a fat young lady with lax fibre, and occasioned by dancing. He says the knee was slightly but firmly flexed. It was reduced by very slight pressure with the fingers, and although some inflammation with effusion into the joint ensued, the use of the limb was completely restored in a week or ten days.²

Prognosis.—Reduction is in general easily accomplished, but a redislocation is very prone to occur. In a few examples reported of a permanent dislocation, the patients have eventually recovered the use of the limb in a great measure. Boyer saw four cases of this kind, in three of which it existed in the left leg, and had remained from infancy. The patellæ were easily replaced, but unless confined they soon became displaced again; not one of them found it necessary to apply for surgical aid, as "they suffered no great inconvenience from the dislocation, and it exempted them from military service." After reduction very little or no inflammation usually follows.

Mr. Key has, however, narrated a case of death from suppuration in the knee-joint, following upon the reduction of an *inward* subluxation. The dislocation was produced by a fall while carrying a pail, and was reduced by very gentle pressure; but the patient, a girl æt. 20, although apparently in good health, was believed to be somewhat strumous.³

Treatment.—In order to relax completely the quadriceps extensor, by whose action chiefly the patella is held in its unnatural position, the body should be bent forward, while at the same moment the leg is extended upon the thigh and the thigh flexed upon the body. The surgeon will accomplish these indications in the most simple manner by placing the patient in a chair and then lifting the foot upon his own shoulder, as he kneels or sits before him. Sometimes the patella will resume its position at once when this manœuvre is adopted; but if it does not, slight lateral

¹ Fowler, The Lancet, May 6, 1871.

² Watson, New York Journ. Med., vol. i. p. 306.

³ Guy's Hospital Reports, vol. i. p. 260.

pressure, made with the fingers, will generally be found sufficient to accomplish the reduction.

A man, *æt.* 27, was sitting on a box, and in jumping off tripped himself with his right leg, causing a partial dislocation of the patella of the left leg outward. Half an hour after the receipt of the injury I found him sitting with the knee bent, and in great pain. The patella lay upon the outer half of the articular surface, with its outer margin a little tilted upward. Lifting the leg and thigh to a right angle with the body, and making very slight pressure upon the outer margin of the patella, it immediately resumed its place. Very little inflammation ensued.

In some instances, where other means have failed, the reduction has been effected by violent flexion and extension of the knee, aided by lateral pressure.

I have already mentioned, when speaking of dislocation into the foramen thyroideum, the case of N. Smith, in whose person I found at the same moment a dislocation of the thigh, a subluxation outward of the tibia, and a complete outward dislocation of the corresponding patella. This was occasioned by a fall from a height upon the inside of the knee. I reduced the tibia first, and then easily replaced the patella by lifting the leg and pushing with my fingers against its outer margin.

In many cases the patients themselves have reduced the dislocation immediately, and the surgeon is only consulted in relation to the after-treatment.

Liston says that this is so constantly the fact, or else such dislocations are really so rare, that it has never happened to him to have an opportunity of reducing any form of dislocation of the patella.

A young gentleman, *æt.* 25, called upon me in consequence of having discovered a floating cartilage in his knee-joint. His account of the matter was that on the 1st of February, 1858, he was kicked by a cow upon the outside of the right leg, about six inches below the knee, and that he immediately found the patella dislocated outward. After several efforts, he finally succeeded in reducing it himself. His knee soon became greatly swollen, so that for five weeks he was unable to walk, and he has been more or less lame to this time. Six months after the accident he discovered a floating cartilage on the inside of the patella, about one inch in diameter, which occasionally slips between the joint surfaces, and suddenly trips him up.

In 1870 M. Duplay¹ found in the Hospital Beaujon, a man, *æt.* 25, with an incomplete external dislocation of the patella, of recent occurrence, and which he was unable to reduce by any of the ordinary methods. Duplay then, the patient being chloroformed, introduced through the integument, and fastened firmly into the projecting portion of the patella a strong hook, by pulling upon which the bone was restored to position.

In a case of recent dislocation which proved to be irreducible, Moreau² opened the capsule and passed an elevator between the patella and the femur, but he was then unable to reduce the dislocation. "The consecutive accidents were formidable."

It seems proper to repeat here what has been said before, that the facts of modern surgery do not justify the assumption occasionally made by my contemporaries, that the knee-joint can be invaded with impunity,

¹ Duplay, *Bull. Soc. de Chirurg. de Paris*, 1870.

² Moreau, Poinot, *op. cit.*, p. 1121.

and that "formidable accidents" are not likely to ensue despite antiseptics, drainage, and the other appliances of modern surgery.

[The necessity of operative procedures for the restoration of a dislocated patella, must be left to the discretion of the surgeon in each individual case. While the warning here given, that the knee-joint cannot be invaded with impunity, is useful as a general statement, it should not prevent any operation—even the free opening of the joint antiseptically—necessary to the complete recovery of the functions of the articulation. No formidable accidents are likely to follow such an operation properly protected by antiseptics, drainage, and the other appliances of modern surgery.]

§ 2. Dislocations of the Patella Inward.

The existence of a complete inward dislocation has been denied by Nélaton, Streubel, and questioned by Malgaigne. One example of incomplete dislocation has been described anatomically by Key, and which has been already referred to as having terminated in death from suppurative arthritis. In this case there were found laceration of the outer portion of the capsule, and a partial rupture of the tendon of the vastus externus.

Causes.—They are occasioned generally by direct blows received upon the upper margin of the patella. The symptoms and treatment will be the same as in dislocations outward, except so far as these must necessarily vary from the opposite position of the patella.

§ 3. Dislocations of the Patella upon its Axis.

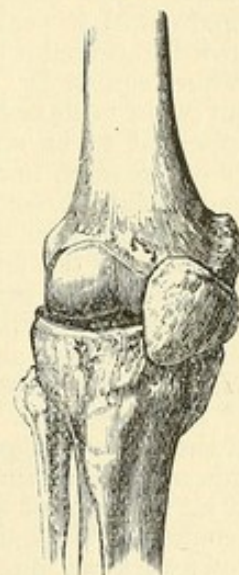(a) VERTICAL.

Syn.—"Semi-rotation;" Miller. "Luxation Verticale;" Malgaigne.

These accidents, of which I have found recorded about twenty-four examples—and one additional case has been seen by myself—seem to be the result of the same causes which produce lateral dislocations; and, indeed, they may be regarded as only exaggerated forms of incomplete lateral dislocations. In these latter accidents, as we have already noticed, the external or the internal margin of the patella, according as the subluxation is to the outer or inner side, is thrown more or less obliquely forward; a position into which it is carried partly by the peculiar form of the articulating surfaces, and partly by the action of the vasti and rectus femoris muscles. If now these muscles were to contract suddenly and violently, and the return of the patella to its normal position were prevented by the lodgement of one of its margins in the inter-condyloidean fossa, the other or free margin would be compelled to rise until it became perpendicular to the limb, or it might perhaps even become completely reversed.

Symptoms.—The signs of the accident are such as to render an error in the diagnosis almost impossible. The limb is generally found forcibly

FIG. 485.



Dislocation of the patella inward.

extended, occasionally it is in a position of moderate flexion, but the projection of the sharp border of the patella directly forward under the skin is itself sufficient to determine the true nature of the injury.

Treatment.—Reduction may be effected by the same manœuvres which I have recommended in lateral dislocations; but if these measures do not succeed, we may direct the patient to make a violent effort himself to flex and extend the limb, or the surgeon may force the limb into flexion and extension alternately, or he may rotate the tibia upon the femur, and then flex. Finally, he ought to make use of lateral pressure also, upon both margins of the upright patella, but in opposite directions.

In all cases it would be advisable to put the patient under the influence of an anæsthetic before attempting reduction.

In a case reported by Dr. H. Hunt, of Beloit, the reduction occurred spontaneously as soon as the patient was chloroformed, although it had resisted all the efforts previously made.¹

Watson, of New York, has related the following example of rotation of the patella upon its inner margin ("Luxation Verticale Externe," *Malg.*): H. B., aged about 35 years, of rather slender frame, while riding on horseback in a crowd, received a blow upon his knee from a horse ridden by another person. When seen by Dr. Watson, soon after the accident, the leg was perfectly straight, but could be flexed to about an angle of 140° without causing pain. "The patella appeared to be slightly drawn up, and it was twisted upon its axis, presenting its outer edge, in a prominent hard line, in front of the knee; its inner edge was resting either in the groove between the condyles of the femur, upon which its posterior face should naturally play, or in the small depression on the anterior face of the femur, immediately above this groove. The anterior surface of the patella was turned inward, its posterior surface outward, and it rested nearly at right angles with its natural position. Its upper and lower attachments were both preserved, and could be distinctly felt; and a sort of band appeared to pass from its under, or, as it now lay, its outer face inward to the deeper portion of the knee-joint. This band, as I conceived, was caused either by the tension of the capsular ligament, or by the rupture of its edge, as it passes from the outer side of the patella. The position of the bone was so well marked that no one at all acquainted with the anatomy of the part could mistake the nature of the accident. With the leg extended, and the anterior muscles of the thigh forced downward as much as possible, pressure was made upon the patella, with the expectation of forcing down its prominent edge. The effort was followed only by an increase of pain, the bone remaining permanently fixed. Another attempt was made to cant its posterior edge inward, and to bring its anterior edge outward, without pressing against the condyles of the femur, by forcing the head of a key against the posterior, now the outer, face of the patella (using this as a fulcrum), and pressing the prominent edge of the bone toward the outer condyle. This manœuvre gave him no pain, but was as fruitless in its result as the other. At length the knee was forcibly bent and immediately straightened again; and then, by canting the patella as before, and pushing it slightly downward and inward, it sprung with a sudden snap into its proper position."²

Dr. Joseph P. Gazzam, of Pittsburg, Pa., has met with a similar case: On the 10th of September, 1842, a man was thrown while wrestling, and immediately found himself unable to rise. Dr. Gazzam saw him about an hour after the accident, and found the patella of the right leg dislocated on its axis, and resting on its inner edge in the groove between the condyles of the femur. Dr. G. proceeded to attempt reduction, but failed, after having made repeated trials by lifting the limb toward the body and by pressure in opposite directions. In consultation with Dr. Addison, it was now determined to divide the ligamentum patellæ, which was done by introducing beneath the skin a narrow-bladed knife,

¹ H. Hunt, M.D., *The Medical Record*, April 1, 1873.

² Watson, *New York Journ. Med.*, Oct. 1839, p. 302.

and cutting close to the tubercle of the tibia. Again the attempts at reduction were renewed, but without success. The patella could be moved on its edge more freely than before the cutting, but resisted every effort to replace it. The patient was now bled in the erect posture, and until the approach of syncope, but to no purpose. On the following morning it was determined to adopt, with some modification, the mode practised so successfully by Dr. Watson. "The thigh was strongly flexed," says Dr. Gazzam, "on the pelvis, and the heel elevated. Then the leg was flexed steadily and forcibly on the thigh, and suddenly straightened. At the moment of straightening the leg, I pressed very strongly against the lower edge of the patella from without, with the head of a door-key well wrapped, while Dr. Addison pressed with both thumbs against the upper edge of the bone toward the external condyle. On the fourth trial this manœuvre succeeded, the bone springing into its place with a snap." Recovery was uninterrupted, and two or three months after, the patient had the complete use of his limb.¹

The following case is reported by Dr. S. F. Morris, New York:

"Mr. B., aged 27, of slender build, while playing at ball, in endeavoring to strike the ball had to jump up and turn partially round, when, on resuming his former position, he fell, his leg refusing to bend. He appreciated the nature of his injury, and, with the aid of the men in the store, endeavored to 'push it back.' Failing in this, surgical aid was sought, but, despite three attempts at reduction, the patella remained displaced. He was then taken to his home. I saw him about two hours after the accident. He complained of severe pain when any manipulation was made. The leg was perfectly straight. The patella was firmly wedged (its outer edge) in the inter-condyloid fossa; its anterior surface looking outward and slightly downward, its posterior face looking inward and upward. The prominence of the edge of the patella, thus twisting on its longitudinal axis, left no doubt as to the diagnosis. No attempt was made at reduction by me until the patient was etherized, when, assisted by Dr. C. M. Bell, of this city, it was easily performed in the following manner: The leg was raised from the bed, the thigh flexed upon the pelvis. Dr. Bell then placed his thumb, as a fulcrum, beneath the under (posterior) surface of the patella, and pressed on the upper (anterior) surface; at the same time I slightly flexed, then suddenly extended and rotated the leg inward. The patella immediately resumed its natural position."²

The following case is reported by G. P. Davis, M.D., of Hartford, Conn.: "A few weeks ago I was summoned to a nurse girl, who was reported to have 'put her knee out of joint.' On entering the room, I found the patient lying on her face, both legs extended, and the left foot pointing toward its fellow. On turning the patient upon her back, the left patella was plainly seen in a condition of 'vertical' displacement, *i. e.*, turned upon its inner edge, so that its upper surface looked toward the opposite knee. It was rigidly fixed, and the limb was entirely helpless. I learned that while sitting upon the floor, playing with the baby under her charge, she suddenly reached forward, at the same time twisting her body partly around, in order to seize the child, who was a little out of her reach, and who, she feared, was about to fall. She immediately became conscious that an accident had befallen her knee. The patient was etherized as she lay upon the floor. The whole limb was then elevated by an assistant, so as to relax the muscles in front of the thigh, and, by forcibly crowding down these muscles toward the knee with one hand, manipulating the patella at the same time with the other, reduction was effected with the utmost ease."³

Through the courtesy of Dr. A. R. Robinson and of Prof. S. B. Ward, of New York, I saw a case of "semi-rotation" of the patella. The accident had happened the day before, in the person of Susan N., æt. 31, a muscular Scotch woman, while wrestling. Dr. Robinson being called, attempted reduction by pressure and by other means, but without success. About seventeen hours after the accident I found her in bed with the left leg extended upon the thigh, and the patella standing upon its inner margin, which rested in the inter-condyloid

¹ Gazzam, Amer. Journ. Med. Sci., vol. xxxi., April, 1843, p. 363.

² Morris, The Med. Record, May 15, 1869.

³ Davis, The Med. Record, Dec. 1, 1874.

notch. The patella was not vertical, but leaned over toward the outside of the knee. While placing her under the influence of chloroform, she bent her leg to a right angle, but the patella continued to occupy its abnormal position. When completely under its influence, Dr. Ward extended and flexed the leg with no result. He then tilted the patella down until it lay flat upon the outer condyle (this was the position it took also when, being partially chloroformed, she flexed the leg); and after a second attempt, with moderate pressure against the outer margin of the patella, it suddenly resumed its position. None of the tendinous or muscular attachments were ruptured.

Dr. J. M. Boyd, of Thorntown, Indiana, reports a case of vertical dislocation, the patella resting upon its internal margin, in a negro 38 years old, and which was caused by muscular "spasms." Attempts were immediately made by a surgeon to reduce it, but without success. Subsequently Dr. Boyd tried also and failed; but at the end of two weeks the muscular spasms returned, and before Dr. Boyd could reach the house the bone had resumed its position spontaneously.¹ Malgaigne has reported, also, a case in which the reduction was accomplished spontaneously during an attempt made by the patient to walk. The same writer refers to a case reduced under the influence of chloroform. Mr. Flower records a similar case.²

In a case of the same kind,³ the reduction was found impossible, notwithstanding the surgeon finally had the temerity to sever completely the tendon of the quadriceps extensor and the ligamentum patellæ. Extensive suppuration followed, under which the poor fellow finally sank and died.

Dr. Dougherty, of Newark, N. J., has reported a case in which he succeeded in effecting reduction by pressure made with his hand while the limb was in an extended position, and without anæsthesia.⁴

Dr. Bradner, of Warwick, Orange Co., N. Y., reports a case occurring in a boy, æt. 9 years, caused by a fall in wrestling. The limb—the right—was slightly flexed. He describes the reduction as follows: "To relieve the strain upon the patella preparatory to reduction, I seized his ankle in my right hand, and raised it from the bed; then I placed my left hand over the patella and grasped the knee; then by depressing the knee forcibly with one hand, and raising the heel with the other, I found it a very easy matter to rotate the patella to its normal bed." The boy recovered at once the complete use of his limb.⁵

Dr. W. R. Cluness, of Sacramento, Cal., reports a case reduced by him in the extended position and by lateral pressure.⁶

In a case occurring in a lady, 36 years of age, solely from muscular action, the reduction was easily effected by Dr. Taylor, Assistant Surgeon U. S. A., by bending the knee as much as possible, and then suddenly straightening it, while at the same moment the patella was pressed firmly over.⁷

In two cases Cuynat⁸ has followed successfully the example of Moreau, already referred to in connection with dislocations outward, by introducing an elevator through an incision; and without any of the "formidable" accidents which ensued in Moreau's case.

(b) COMPLETE VERSION.

Syn.—"Renversement;" Malgaigne.

Complete version, like partial version, presents two varieties, namely, version *from without inward* and version *from within outward*.

In the earlier editions of this treatise, this dislocation is referred to as representing the most advanced or complete form of patellar rotation; but I have

¹ Boyd, Western Journ. Med., May, 1868, p. 275, and June, 1868, p. 341.

² Holmes's Syst. Surg.

³ Rust's Magazine.

⁴ Dougherty, The Med. Record, Dec. 30, 1876, p. 840.

⁵ Bradner, Ibid., Jan. 20, 1877, p. 46.

⁶ Cluness, Ibid., Jan. 27, 1877.

⁷ Taylor, Ibid., May 26, 1877, p. 336.

⁸ Cuynat, Recueil de Mém. de Méd. de Pharm. et Chir. Milit., t. 16, t. 18.

decided hereafter to speak of partial version (vertical) and complete version as two distinct forms.

Malgaigne¹ refers to a case reported by J. Sue in 1752, or version from without inward, which was not, however, complete, and which was unaccompanied with a rupture of the ligaments. Later, Bruyères is reported to have said to the Royal Academy of Surgeons that he had seen a complete version of the patella, and without rupture of the ligaments.

Castara² reports a case of complete version from within outward, in a girl of 17 years; the tendon and ligamentum patellæ were twisted into a cord. Reduction was easily effected by seizing the patella between the thumb and index finger, and by rotation from behind forward, and from without inward made slowly and gently.

Berger cites a similar case as having been published by Gaulke³ in a girl of 17 years, who had fallen from a horse. Gaulke, who did not see the case until after ten days, was at first unable to effect reduction, even when the patient was under the influence of chloroform. On the following day Gaulke procured a carpenter's wooden vice, and enclosing in its grasp the internal condyle and the outer margin of the patella, he succeeded, after several ineffectual efforts, in restoring it to position; but not without some laceration of the integuments. Recovery took place speedily, and without any inflammatory accidents.

§ 4. Dislocations of the Patella Upward.

Occasionally the ligamentum patellæ has been found so much elongated and relaxed, as to permit the patella to glide upward upon the front of the femur. Heister and Ravaton have each seen an example in which a displacement from this cause existed to the extent of three inches. It is much more common, however, to meet with this dislocation as a result of a rupture of the ligamentum patellæ.

On the 18th of Dec. 1850, D. M., æt. 50, was admitted to the surgical wards of the Buffalo Hospital of the Sisters of Charity. While at work on the same day, he had slipped and fallen, with his knee forcibly flexed under his body. I found the ligament of the patella torn asunder, and the patella drawn up two or three inches upon the front of the thigh. We applied at once the dressings used by me for a broken patella, and were able to bring the bone down completely to its place. Three weeks from the time of the receipt of the injury the dressings were removed, and the patella was found to be nearly but not quite in its original place. From this time we commenced to move the joint; in about ten days more he left the hospital, and I lost sight of him, so that I am unable to speak more definitely of the result.

Mrs. Fanny N., æt. 45, fell upon her right knee, causing a lacerated wound and a rupture of the ligamentum patellæ. Four years later, Oct. 28, 1880, I found the patella one and a half inches above its natural position. She was able to walk up and down stairs without difficulty, and while sitting she could lift the leg and straighten it upon the thigh perfectly.

The following case is unique: Miss M. E. B. was thrown in alighting from a stage, and, on consulting a druggist, was told that she had ruptured the ligamentum patellæ. Some time later, Oct. 20, 1880, she consulted me, when I found the lower edge of the left patella tilted forward, with a manifest depression below the patella caused by the absence of the anterior, or most superficial fasciculus of the ligament. The posterior fasciculus, attached to the posterior margin of the patella, could be distinctly felt, and seemed to be normal in length and breadth. In walking the knee is apt to give way suddenly, as happens when there is a floating cartilage in the joint. I directed her to wear an elastic knee-cap; but she omitted to do this except occasionally, and when she again

¹ Sue, Malgaigne, op. cit., vol. ii. p. 918.

² Castara, Malgaigne, op. cit., p. 921.

³ Gaulke, Deutsch. Klin., vol. ii. 1863.

consulted me, about one year later, there was no appreciable change in the condition of the limb.

In February, 1869, Dr. G. H. Smith consulted me in relation to a gentleman who had ruptured the ligament of the patella in both legs a little more than a year before by catching his heel in descending from a carriage, the ligaments giving way in the powerful muscular effort which he made to prevent himself from falling. Treated upon a single inclined plane in the same manner that I have recommended for a fractured patella, at the end of five weeks the patellæ were in place and the ligaments reunited. After walking about one month upon crutches he caught the heel of his right foot again, and again ruptured the ligament of the patella in the same leg. A similar plan of treatment failed to accomplish anything, and when he consulted me the patella was displaced three inches upward. He could raise the leg slowly to a position of extension while sitting, and was able to walk four or five miles a day.

Gibson has recorded a similar case, in which both patellæ were dislocated upward by a rupture of the ligaments, occasioned by the exercise of leaping. He recovered the use of his limbs almost completely.¹

[If the ruptured ligamentum patellæ fail of union, and the limb is thereby crippled, a union may be secured by free incision of the structures and sutures through the lower extremity of the patella, and the fibrous tissues remaining at the lower attachments of the ligament. A similar operation may be performed for rupture of the quadriceps tendon.]

(For examples of rupture of the quadriceps femoris, which some writers have incorrectly named Dislocations of the Patella Downward, see Velpeau's Surgery, 1st Amer. ed., vol. i. p. 422; New York Med. Times, April 6, 1861, p. 226, and two cases reported by myself in the same volume of the Med. Times; Demarquay, Mém. Rup. Tend. du Triceps, Gaz. Méd., Paris, 1842; Renouard, Arch. Gén. de Méd., sér. 4, t. xv. p. 101; Binet, Rup. Tend. Triceps et du Lig. Rotulien, Arch. Gén. de Méd., sér. 5, t. ii. p. 687, 1858; Adams, Case of Rupture of the Tendons of both Recti Fem., Lancet, 1861, vol. ii. p. 226; Lorinser, Wiener med. Woch., 1869, Bd. xix. S. 27; Berger, Art. Rotule, Dic. Enc. Sci. Méd., sér. 3, t. v. p. 330.)

CHAPTER XIX.

DISLOCATIONS OF THE HEAD OF THE TIBIA (FEMORO-TIBIAL).

Syn.—"Tibia upon the femur;" "dislocations of the leg"

IN consequence of the great size and irregularity of the articular surfaces between the tibia and femur, together with the remarkable number and strength of the ligaments which bind the two bones together, dislocations at this joint are exceedingly rare. They are known to take place, however, in four principal directions, namely, backward, forward, inward, and outward. A dislocation may also occur in either of the diagonals between these points, that is, antero-laterally or postero-laterally, or the tibia may be dislocated by rotation. Dislocations of the head of the tibia may be either complete or incomplete.

¹ Gibson, Surgery, vol. i. p. 395, 6th ed.

Velpeau found upon record thirteen examples of complete dislocations forward and eight backward, but not one of a complete lateral dislocation. Velpeau thought, also, that the antero-posterior dislocations were always complete, but Malgaigne has shown that this opinion is erroneous.

§ 1. Dislocations of the Head of the Tibia Backward.

The head of the tibia is felt in the popliteal space, and, if the dislocation is complete, the pressure upon the popliteal nerve becomes excessively painful. A marked depression exists in front, immediately below the patella, and especially upon the sides of the ligamentum patellæ; the condyles of the femur project strongly in front; the leg may be not at all (incomplete) or only slightly shortened, or the shortening may amount to one inch or more; and usually it is in a position of extreme extension, or thrown forward from the line of the axis of the femur; but its position has been found to vary greatly in different cases, the limb being sometimes very much flexed, and in others very slightly flexed or perfectly straight.

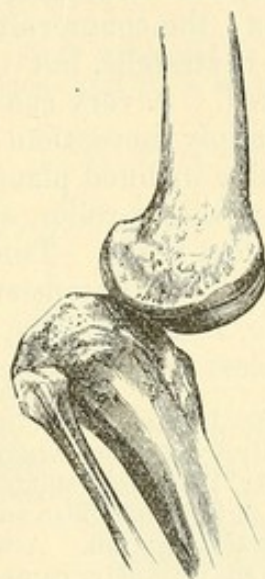Pathological Anatomy.—The posterior ligament of the joint is torn; the muscles of the ham are stretched; the popliteal nerves and vessels compressed; and the head of the tibia either rests partly upon the posterior half of the lower articulating surface of the femur (incomplete), or it passes up and rests only against its posterior articulating surface, which in this direction extends an inch or more upward. If the dislocation is complete, the crucial ligaments are also torn, and all the parts about the joint suffer extensive injury from stretching, laceration, or compression.

Prognosis.—If the reduction is promptly effected, the limb kept perfectly quiet a sufficient length of time, and in other respects properly managed, not much inflammation need generally be anticipated, and the limb may suffer in the end very little, if any, maiming.

Malgaigne has seen three examples of incomplete backward dislocations which were not reduced, and neither of the persons was very greatly maimed in consequence. One walked with crutches after three or four days, and with a cane after about five weeks. Another did not leave his bed under one month, and it was nearly one year before he could lay aside his crutches; but both of them were finally able to walk at least twelve leagues per day. Malgaigne informs us, however, that in a similar case seen by Lassus the patient was confined to his bed two years, although he finally recovered a tolerable use of his limb.

Treatment.—It will be proper, at first, to attempt the reduction by simple manipulation, as this is often found to succeed when the dislocation is recent and incomplete, and especially when the system is greatly depressed by the shock of the injury. If the dislocation is complete, however, we can hardly anticipate success without the application of

FIG. 486.



Complete dislocation of head of tibia backward.

some extending force. In the employment of manipulation we ought to be governed at first by the same rule which we have found so generally applicable in dislocations of the femur, namely, to carry the limb in those directions in which it will move easily, or without the application of much force. If this fails, we may at once resort to forced flexion alternating with extension; rotating or rocking the limb also occasionally from one side to the other, while at the same moment strong pressure is made upon the projecting bones at the knee-joint in opposite directions, or in the direction of the articulation. Finally, it may be necessary to resort to extension, made by means of a lacque, or by the hands of strong assistants, above the ankle, always at first in the direction of the axis of the tibia; the counter-extending band being applied to the perineum if the leg is straight, but to the lower and back part of the thigh if the leg is flexed. A very convenient mode of making extension, where we wish to apply more than usual force, is to lay the whole limb over a firm double inclined plane, or fracture-splint, securing the thigh to the thigh-piece with a roller, and making the extension with the screw attached to the foot-board. This method, however, while it enables us to use great force in the extension, prevents the surgeon from employing, at the same time, those flexions, extensions, and other manipulations, upon which success so often depends.

Dr. James Carmichael has reported a case in which reduction was effected easily by flexion, when traction failed.¹

Mr. Rose² has related a characteristic example of this accident, except that the patella had also suffered a lateral displacement, presenting the usual favorable termination. A woman was standing upon a low ladder when a carriage, driven furiously, came in contact with it, and precipitated her to the ground. Mr. Rose, who saw her almost immediately, found the tibia completely dislocated at the knee, the head being driven behind the condyles of the femur into the ham, with the patella thrown to the outside of the external condyle, and the leg in a state of fixed extension. Immediately, and without difficulty, the bones were restored by applying one hand to the patella, the other to the back of the upper portion of the tibia, and simultaneously pulling and pushing those bones toward their natural positions. The patient was then removed to a bed, and by the diligent use of antiphlogistic remedies inflammation was kept in check, and the case reached a favorable termination without one untoward symptom. After the lapse of only a few weeks she had completely recovered the use of the knee-joint.³

Dr. Walsham communicated a case to Sir Astley Cooper in which the dislocation was not only complete, but the tendon of the quadriceps extensor was ruptured. The leg was bent forward. The reduction was accomplished very easily by extension, made with the hands by four men, in the line of the axis of the limb. In about one month this man began to walk with crutches, but he was not perfectly recovered until after five months, at which time the crutches were finally laid aside.⁴

§ 2. Dislocations of the Head of the Tibia Forward.

The signs of this accident are the reverse of those which belong to dislocations backward. The patella, tibia, and fibula are prominent in

¹ New York Med. Gazette, Aug. 22, 1868, from the Lancet.

² Provincial Med. Journal, June 11, 1842.

³ Rose, Amer. Journ. Med. Sci., vol. xxxi. p. 216.

⁴ Walsham, Sir A. Cooper on Disloc., etc., 2d London ed., p. 188.

front, while the condyles of the femur may be felt behind, pressing strongly upon the muscles, nerves, and bloodvessels which occupy the popliteal space. In case the dislocation is complete, a shortening may exist to the extent of one or even three inches.

Dr. O'Beirne, of Dublin, has mentioned a case to Mr. B. Cooper in which the shortening was three inches and a half, and Mr. Mayo has seen one example in which the dislocated limb was "fully four inches" shorter than the other.¹

In consequence of the pressure upon the popliteal artery, the pulsations in the branches below are frequently interrupted, and in one instance this pressure was sufficient to produce finally a dry gangrene.

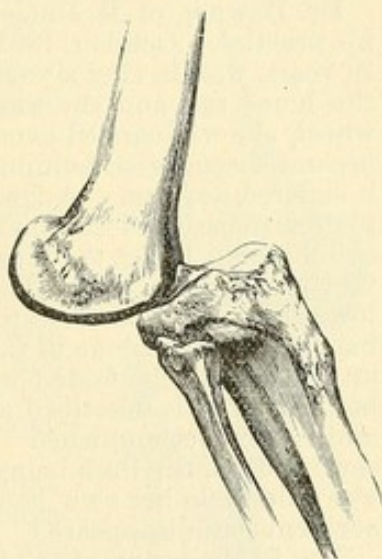
Dr. Gorde² relates a case occurring in a woman nearly sixty years old. This woman was returning home at night with a heavy burden, and in a state of intoxication, when she stepped into a ditch as deep as up to the middle of her thighs. The body was thrown forward by the fall, while the feet struck at the bottom of the ditch, the whole force of the impulse being sustained by the thighs. The lower end of the femur was found driven downward and backward, and lodged under the muscles of the calf of the leg; the limb being shortened three inches. Reduction was promptly effected, and without inflicting any pain of which the patient complained. In six weeks the patient was cured.³

Mr. Toogood has reported an example of complete dislocation in this direction, in which the appearance was so dreadful, that Mr. Toogood at first despaired of being able to reduce it; but by directing two men to make counter-extension while he made extension, the reduction was immediately effected. At the end of one month the patient was able to leave his bed; and sixteen years after, Dr. Toogood saw him walking "with very little lameness."⁴ Parker, of Liverpool, has reported another example, which was occasioned by the fall of a heavy spar upon a man's back, and the consequent violent bending of the knee under his body. In this case the limb was slightly flexed, and the patella was loose and floating. The reduction was effected without much difficulty by extension and counter-extension made by two men, while the operator, placing his knee in the ham of the patient, attempted to bring the leg to a right angle with the thigh.⁵

B. Cooper, Malgaigne, Little,⁶ and others, have recorded examples of this accident.

March 9, 1865, Hiram Wescott, of Sandy Cove, Nova Scotia, æt. 45, was caught by his sled, drawn by horses, in such a way that a beam pressed against the front and lower end of the femur while the heel was caught and arrested by a stump. The foot was thrown forward and the upper end of the tibia completely dislocated in the same direction. It was at once reduced by a person who was present, but on attempting to use the leg in walking it was redislocated immediately. Mr. J. H. Harris, medical student, found the limb soon after completely dislocated, with the leg thrown forward in the position of dorsal

FIG. 487.



Subluxation of the head of the tibia forward.

¹ B. Cooper's ed. of Sir Astley Cooper on Disloc., etc., pp. 214, 215.

² Bullétin de Thérapeutique.

³ Gorde, Amer. Journ. Med. Sci., vol. xvi. p. 225, May, 1835.

⁴ Toogood, Amer. Journ. Med. Sci., vol. xxxi. p. 465.

⁵ E. Parker, Ibid.

⁶ Little, New York Med. Times, Aug. 17, 1861.

flexion about 40°. The tendons of the hamstring muscles were not ruptured, but had slid forward past the condyles of the femur. There was no external wound. Reduction was easily accomplished by simple extension. Pasteboard splints were then applied. On the third day the knee was considerably swollen, and some ecchymosis existed about the popliteal region. On the fifth day these symptoms had much increased. Mr. Harris then applied extension to the foot, with the aid of adhesive plaster, pulley and weights, and by elevating the foot of the bed. The amount of extension employed was 9 lbs. This gave immediate relief to the pain, and was continued until the inflammation subsided. His recovery was steady, and in four months he walked with crutches or a cane.

In 1864 a similar dislocation was presented at the Brooklyn City Hospital, in which reduction having been practised, the patient died.¹

Dr. White, of Buffalo, invited me to see with him a lad, æt. 10, whose tibia had been partially dislocated forward eight weeks before, by a boy having hit the top of his knee with his head, while they were at play. His father, himself a physician, residing near town, reduced the limb very easily, by extension made with his own hands, and by pressing upon the projecting bones. Violent inflammation ensued, but at the time when I saw him, the knee was free from soreness or swelling, and the motions of the joint were nearly restored.

Dr. Downes, of McIndoe's Falls, Vt., gives the following account of a case in his practice. October, 1861, Mrs. H., a robust young married woman, aged about 20 years, was driving a young horse and holding her infant in her arms, when the horse ran and she was thrown out. One of her legs being caught in the wheel, she was carried over three or four times in its revolutions before she became disengaged, holding meanwhile upon her infant with such firmness that it suffered no harm. A few hours later Dr. Downes and Dr. Burton found a complete dislocation of the tibia and fibula forward, and the lower end of the femur could be felt under the muscles of the calf of the leg. The limb was shortened four inches and a half. The patella lay loosely in front of the femur, with its lower margin tilted forward. The patient was laid upon a bed, and a perineal band made fast to one of the posts, while a lacque was placed upon the foot and attached to a rope folded upon itself and forming a pulley or "Spanish windlass," such as is described at page 694. In this way the reduction was speedily and easily accomplished. Hot fomentations were subsequently applied for several days, the limb being kept perfectly at rest. In about three months she was able to do her own housework, and in a short time after all traces of her accident had disappeared.

The following account of a case was sent me by Dr. Alonzo Pettit, of Elizabethport, N. J.: J. McG., laborer, æt. 26, was sitting upon the platform of a freight car, with his feet upon the platform of the next car, his legs extended. The train slackening up at a station, before he had time to bend his knees, the cars came together and pushed the head of the left tibia upward upon the femur.

He saw him about half an hour after the accident, and found a complete dislocation of the head of the tibia, with the patella forward upon the femur. The leg was slightly flexed, and shortened two and a half inches. He succeeded in reducing it easily without assistance, or the use of anæsthetics, by grasping the leg with the left hand, the right being in the popliteal space, making moderate extension and flexion, and pressing upon the condyles of the femur.

§ 3. Dislocations of the Head of the Tibia Outward.

Occasionally, owing to a violent wrench of the knee-joint, the lateral ligaments upon one side or the other are ruptured, and consequently the joint surfaces separate somewhat from each other; or when the limb is moved, the head of the tibia may slide a little forward or backward, or to either side. These are not properly examples of subluxation; nor should we consider as belonging to this class the accident originally de-

¹ Yale, New York Journ. Med., vol. ii. p. 124, Nov. 1865.

scribed by Mr. Hey as an "internal derangement of the knee-joint," but which also by some writers has been termed "a subluxation of the knee." Of this latter accident I will take occasion hereafter to speak a little more particularly. In subluxation, properly so called, if the direction of the dislocation is outward, the outer condyle of the femur rests upon the inner articulating surface of the tibia, and if the direction of the dislocation is inward, the inner condyle of the femur rests upon the outer articulating surface of the tibia. The signs which characterize this accident are such as cannot easily be mistaken. The limb is not shortened, nor is there anything especially diagnostic in its position, since it has been found to be sometimes flexed, and at other times straight; but the strong lateral projections made by the inner condyle of the femur on the one hand, and by the heads of the tibia and fibula on the other, cannot fail to inform us as to the true nature of the accident. The treatment will not differ essentially from that which has already been recommended in dislocation of the tibia backward or forward. If any other expedients can prove useful, they must be left to the judgment of the surgeon whenever the exigencies of the case shall demand them.

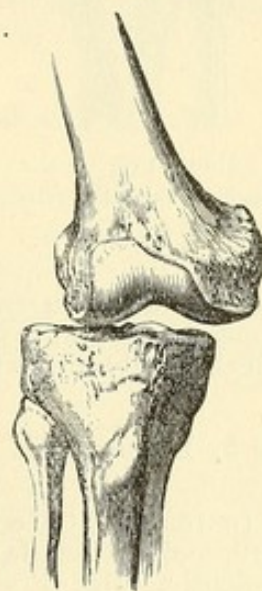N. S., in consequence of a fall from a window, had a dislocation of the right femur, tibia, and patella. The tibia was subluxated outward, and the leg was partially flexed upon the thigh, with the toes everted. By moderate extension, made with my own hands, united with alternate flexion and extension, the bone was easily and promptly restored to its place. Very little swelling followed the accident, and his recovery was rapid and complete.

A man was received into the North London Hospital, with a partial dislocation of the tibia outward, and although the knee was much swollen, the nature of the injury was easily determined. The knee was immovable, and the toes turned outward. Mr. Hallam, the house surgeon, reduced it by extension and counter-extension made with his own hands.¹

Mr. Pitt records a similar case in a young lady, produced by a fall down a flight of stairs. It was reduced easily by extension and counter-extension. Inflammation followed, but it was finally controlled, and she regained the use of her limbs.²

In one case of subluxation, mentioned by Sir Astley Cooper, and in a second recorded by Bransby Cooper, the recovery of the functions of the joint did not seem to have been so rapid; the joint remaining unstable and tender for a long time afterward.³

FIG. 488.



Subluxation of the head of the tibia outward.

§ 4. Dislocations of the Head of the Tibia Inward.

There is nothing peculiar in either the signs, conditions, or treatment of this accident, as distinguished from a dislocation outward, to demand a special consideration.

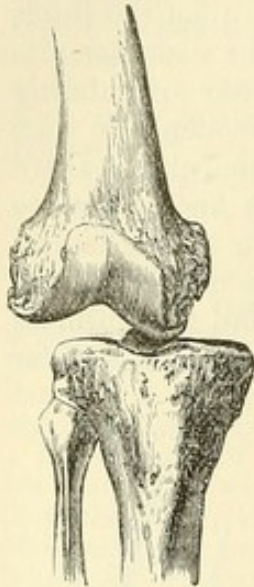¹ Hallam, Amer. Journ. Med. Sci., vol. xix. p. 251.

² Pitt, Ibid., vol. xxxi. p. 465.

³ B. Cooper's ed. of Sir Astley, op. cit., pp. 111-13.

Sir Astley Cooper has mentioned two cases of subluxation inward, and Mr. B. Cooper has added to these a third. Sir Astley remarks that in the first accident, the only one indeed which he had himself ever seen, he was struck with three circumstances: first, the great deformity of the knee from the projection of the tibia; second the ease with which the bone was reduced by direct extension; and third, by the little inflammation which followed. The second case of which Sir Astley speaks was communicated to him by a Mr. Richards. In this case the fibula was also broken, and the reduction was accomplished only after extension had been made by several persons for half an hour. The limb became excessively swollen, and remained so for many weeks. Eighteen months after the accident the knee continued somewhat stiff, and there was an unnatural lateral motion in the joint, from the injury which the ligaments had sustained. The patient referred to by Bransby Cooper had met with the accident by a fall upon the foot, with his leg bent under him; and a fellow-workman had reduced the bone by extension and pressure. Mr. Cooper thinks that not only the internal lateral ligament was torn, but also some fibres of the vastus externus and the crucial ligaments. Violent inflammation ensued, which did not permit him to leave the hospital until after about two weeks. Fergusson has seen two examples of unreduced subluxation inward, in both of which the patients had regained useful limbs.¹

FIG. 489.



Subluxation of the head of the tibia inward.

Malgaigne mentions that Boyer, Costallat, and Key had each seen one similar example; and he also enumerates two additional cases of complete dislocation attended with a protrusion of the bone through an external wound; in both of which the reduction was easily effected and the patients recovered.²

§ 5. Dislocations of the Head of the Tibia Backward and Outward.

In June, 1853, Henry J., of Dansville, N. Y., æt. 24, was thrown by an enraged bull, and his left leg, being caught under the knee by the horns, was twisted violently. Drs. Pryor, of Dansville, and Batton, of Burns, were called, and found the left knee completely dislocated; the tibia being displaced backward beyond the condyles of the femur, and also a little outward. The foot and leg were inclined outward. With the assistance of four men, extension and counter-extension were made in the line of the axis of the limb, and the reduction was easily accomplished. Pasteboard splints, bandages, etc., were applied to maintain the bones in place; but the swelling came on rapidly, and in the evening these dressings were removed. The limb was now laid over a double inclined plane carefully padded, in order to press the upper end of the tibia forward, as it manifested a constant inclination to become displaced backward. This apparatus was employed six weeks, with the exception of two or three days, during which the limb was laid upon pillows, but as the pillows did not sufficiently support the back of the tibia, the double inclined plane was resumed. After the removal of the plane, during seven weeks longer, an angular splint was kept closely applied to the back of the limb. Seven months after the accident, on the 23d of January, 1854, Dr. Robinson, of Hornellsville, brought the gentleman to me. I found the bones displaced backward about three-quarters of an inch, and half an inch outward, or to the fibular side. This was the position of the bones when he was sitting with his leg bent at a right angle with the thigh, but when he stood erect and bore some weight upon the foot, the outward displacement ceased, and the backward displacement only remained. It was very easy, however, in whatever position the leg might be, to push the bones forward by

¹ Fergusson op. cit., p. 284.

² Malgaigne, op. cit., tom. ii. p. 956.

the hands until nearly all deformity had disappeared. He could flex the leg to a right angle with the thigh, and straighten it completely, but he could not lift the foot and leg from the floor while sitting with his limb extended in front of him. He was unable to bear sufficient weight upon his foot to use it at all in progression, on account of the inability to fix and steady the limb, but not on account of any pain or soreness which it occasioned.

Thomas Wells, of Columbia, South Carolina, has described a similar accident, the tibia being dislocated outward and backward, which terminated fatally on the fourth day in consequence mainly of exposure, intemperance, and neglect to apply for surgical aid. The bones were never reduced, and the autopsy disclosed also a fracture of the internal condyle of the femur.¹

§ 6. Dislocations of the Head of the Tibia Forward and Outward.

Duvivier,² in 1828, treated an officer who had fallen from his horse, causing a dislocation of the tibia forward and outward, which was accompanied with a shortening of six inches. Reduction was effected, and at the end of a year the motions of the joint were only partially restored.

In a case reported by Wathen³ the reduction was easily effected, but inflammation of the joint ensued, and the cure took place with fibrous ankylosis.

§ 7. Dislocations of the Head of the Tibia Forward and Inward.

M. J. Cloquet⁴ met with an example of simple complete dislocation of the head of the tibia forward and inward, which had existed one year, and upon which the patient could bear the weight of his body. This latter circumstance led Malgaigne to express a doubt as to whether it might not have been only a subluxation; a supposition, however, which cannot be entertained if Cloquet was correct in saying that the limb was shortened one inch and a half.

Gerdy⁵ met with a case of complete dislocation, the limb being shortened half an inch, slightly flexed, and immobile. The popliteal artery was compressed. Reduction having been effected, the patient was able on the twenty-first day to walk very easily.

In a case reported by Sir Astley Cooper the dislocation was accompanied with a tearing of the integuments, and the limb was amputated. Dissection disclosed a large laceration of the vastus externus, and of the capsule and ligaments posteriorly. The lateral and crucial ligaments were unbroken.

In a case seen by Malgaigne⁶ the displacement was incomplete.

W. Mulligan⁷ reports a case of complete dislocation in the person of a man 26 years old caused by a direct blow upon the anterior and internal part of the thigh. The injury seemed simple and the integuments were intact. Reduction was effected easily by flexion, but it was then noticed that arterial pulsations in the foot had ceased, and a little later the appearance of gangrene in this portion of the limb rendered amputation necessary.

Treatment.—Malgaigne says "the dislocation may be reduced by direct extension, as in the case of outward dislocations, but it may be found a little more difficult; Gerdy employed three assistants, but I em-

¹ Wells, Amer. Journ. Med. Sci., vol. x. p. 25, May, 1832.

² Duvivier, Malgaigne, from Arch. Gén. de Méd., 1829, t. 20, p. 292.

³ Wathen, Poinset, Med. Times and Gaz., Nov. 23, 1872.

⁴ Cloquet, Dic. de Med., Art. Genou.

⁵ Gerdy, Arch. Gén. de Méd., 1835, t. 13, p. 163.

⁶ Malgaigne, op. cit., vol. 2, p. 959.

⁷ Mulligan, Med. Press and Circular, Sept. 15, 1875.

ployed only two. The pressure applied to the tibia by resting the femur upon the knee, did not prove to be sufficient," and it became necessary to employ a more solid resistance, and to substitute a block of wood for the operator's knee. Gerdy's case was a complete dislocation, while Malgaigne's was incomplete. Sir Astley experienced great difficulty in the reduction; and the dislocation having at once been reproduced, amputation was practised.

§ 8. Dislocations of the Head of the Tibia by Rotation.

Rotation sometimes accompanies either of the preceding dislocations; but I speak now of examples in which the dislocation is by rotation alone.

Malgaigne¹ has cited the following examples: In the case of Dubreuil,² which was presented in the service of Malgaigne himself, the leg was extended and rotated outward until the head of the fibula projected in the popliteal space, and the patella, dragged by the tibia, was completely dislocated outward. The dislocation was reduced two hours after the accident by a single assistant, who grasping the upper portion of the leg with both hands, made light traction and rotated the limb from without inward. Nineteen months after the accident the knee was stiff, painful, and incapable of supporting the body.

Boursier,³ of Bordeaux, published an example of this form of dislocation which occurred in a person *æt.* 19. When admitted to the hospital the leg was slightly flexed and rotated outward. There was no discoloration or swelling. The patella was lodged upon the external condyle. Attempts at reduction by extension and rotation were unsuccessful; but on placing the patient under the influence of chloroform the reduction was easily effected by the same manœuvres. Codman and Pétrequin have each reported one example of outward rotation seen in autopsies.

Malgaigne cites also a case reported by M. Paris⁴ of dislocation by rotation inward, the internal condyle of the tibia resting behind the internal condyle of the femur. Reduction was easily effected, but a chronic arthritis ensued.

§ 9. Internal Derangement of the Knee-Joint.

Syn.—"Slipping of the semilunar fibro-cartilages;" Hey. "Partial dislocation of the thigh-bone from the semilunar cartilages;" Sir Astley Cooper. "Subluxation of the semilunar cartilages;" Malgaigne. "Subluxation of the knee;" Erichsen. To these I think it proper to add, as giving rise to the same class of symptoms, "Floating cartilages in the knee-joint."

This accident is in no proper sense a subluxation of the knee. I should not make any farther allusion to it, were it not necessary in order to enable the student of surgery to distinguish between the phenomena which belong to it and those which belong strictly to subluxation of this joint.

Symptoms.—The patient is suddenly thrown to the ground while walking, as if by an instantaneous loss of power in the affected limb, this loss of control over the limb being accompanied usually with sharp pain, referred to the region of the knee-joint; or he trips his toe against some-

¹ Malgaigne, *op. cit.*, vol. 2, p. 962.

² Dubreuil, *Arch. Gén. de Méd.*, 1852, t. 30, p. 251.

³ Boursier, *Journ. de Méd.*, Bordeaux, Dec. 31, 1882, p. 225.

⁴ Paris, Malgaigne, from *Rev. Méd.-Chir.*, vol. 12, p. 174.

thing in his path, and the toes becoming everted, the leg suddenly gives way under him; in some cases it has happened when the patient was turning in bed, the weight of the bedclothes hanging upon the toes so as to occasion a strain and rotation outward at the knee-joint, or it follows upon a subluxation of the joint, as in one example which I shall presently relate; or it may result from forced flexion of the knee. If the patient is walking when the accident takes place, and he falls to the ground, he finds himself unable to move the limb, or to stand upon it; but by manipulation or extension, the difficulty is, in most cases, as easily overcome as it occurred, when immediately the motions of the joint become free, and he walks off as if nothing had happened. When the accident has once taken place, it is afterward exceedingly liable to occur from very slight causes, and eventually the knee-joint becomes tender and the capsule fills with synovia, indicating the existence of subacute synovitis.

A man, æt. 23, consulted me, on the 27th of October, 1858, in relation to the condition of his knee-joint. He stated that on the 13th of August, 1858, while standing with the whole weight of his body resting upon the left leg, a mate struck him on the inside of the lower end of the left femur. The blow was made with the palm of the hand, but with sufficient force to throw him down. It was immediately noticed that the tibia was partially dislocated inward at the knee-joint. The whole lower part of the limb was inclined outward. A person present in the room seized upon the foot and by extension easily brought it back to place; the bone resuming its position with an audible snap. After this he continued to walk about until night. Two days after, the knee had become so much inflamed that he was obliged to take to his bed, on which he was confined three weeks. Gradually the swelling subsided, and in about five weeks after the accident he began to walk on crutches. On the 23d of September he was walking in the store without crutches, when he suddenly felt a sensation of slipping in the joint, and he fell to the floor as if he had been tripped up. At the time when he called upon me, this had happened many times, but had never been attended with pain. The joint was filled with synovia, and tender, yet I could distinctly feel a hard body just to the inside of the ligamentum patellæ, and which moved freely under the finger.

Prof. Le Fort¹ has described this accident as it occurred in his own person, in consequence of a forced flexion of the leg. He was conscious at the time of a movement in the joint at the external part of the right knee, and when he arose he found the limb fixed in the position of flexion, and he was only enabled to straighten it by a violent muscular effort, the effort being accompanied by a violent pain, and a very loud crack, as if something which was displaced had resumed its place. Immediately all pain disappeared and the motions of the joint were restored. For several months the accident was repeated whenever the knee was much flexed; the phenomena attending the displacement being in each case the same as at first, he having always a distinct recognition of the movement of displacement, and always the voluntary straightening of the limb reproduced the crack, and caused the pain to cease. By avoiding the causes the accident ceased to occur; but after a time he failed to exercise the same caution, and the accident again occurred; but this time the displacement of the cartilage was backward instead of forward, as it had been previously, and the straightening of the limb caused an atrocious pain, which lasted, in some degree, more than eight days. He has since then exercised the same caution as before, and the displacement has not recurred.

Pathological Anatomy.—The same class of symptoms, with only very slight modification, belongs probably to several varieties of "internal derangement of the knee-joint;" and first it will be remembered that the

¹ Le Fort, Bull. Soc. Chir., Paris, 1879, July, 2.

semilunar cartilages upon which the margins of the condyles of the femur rest, are attached to the tibia by several ligaments; but when, from relaxation or a violent strain, any one of these ligaments becomes elongated or gives way, the portion of cartilage which it restrains is permitted to become partially displaced, and by interposing its thick margin between the deeper articulating surfaces the bones are separated and the muscles lose their control over the joint; second, these ligaments may not only yield, but a fragment of one of the cartilages may become actually broken off from the main portion; third, the femur may perhaps escape behind some portion of an interarticular cartilage, and thus, instead of the cartilage placing itself between the joint surfaces, the femur itself may have thrust it into this position; fourth, a cartilage, or some portion of a cartilage, may become hypertrophied, and thus give rise to the symptoms described; fifth, in other cases still, a bony, cartilaginous, fibrinous, or calcareous growth or concretion forming within the joint, and, if originally attached, becoming separated from the capsule, may move about more or less freely, and give rise to the same class of symptoms which I have described. This last variety has generally been described under the name of "floating cartilages;" but since these bodies are not always cartilaginous, and especially since they do not always by any means move so freely as to be properly designated as "floating," the term is less appropriate than that originally given by Hey, and which I have chosen to adopt.

Treatment.—For the purpose of obtaining immediate relief, it is generally sufficient to flex the leg completely and then suddenly extend it, or to combine this motion with a slight twisting or rocking of the knee-joint. Sometimes this experiment has to be repeated several times before it is completely successful, and in a few instances it has failed altogether. I think I must have met with ten or twelve examples in the course of my practice, and in no instance have the sudden flexion and extension of the limb failed to overcome the difficulty. As to the question of subsequent treatment, especially as to whether it is proper to attempt extirpation of the cartilages when they are found to be actually floating, or to make any other surgical interference, I prefer to leave its consideration to those general treatises upon surgery where it more properly belongs.

CHAPTER XX.

DISLOCATIONS OF THE LOWER END OF THE TIBIA (TIBIO-TARSAL).

Syn.—"Dislocations of the ankle-joint;" Chelius and others.

THE tibia may be dislocated at its lower end in four directions; namely, inward, outward, forward, and backward. Most of these dislocations complicate themselves with fractures of the fibula or of the tibia, or with fractures of both bones.

Dupuytren, Malgaigne, and a few other surgeons have reported examples also of dislocations forward and inward. Boyer, with a majority of the French writers, and several English and German surgeons, speak of these dislocations as belonging to the foot; consequently the outward dislocation of Boyer is the inward dislocation of Sir Astley Cooper, Malgaigne, myself, and others, who prefer to regard the tibia as the bone dislocated.

§ 1. Dislocations of the Lower End of the Tibia Inward.

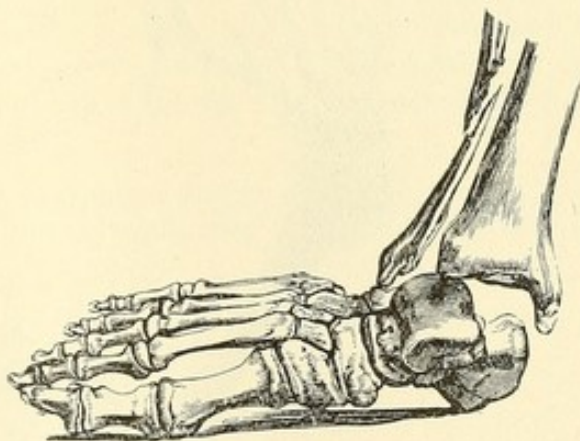
Syn.—"Inward tibio-tarsal luxations;" Malgaigne. "Dislocations of the foot outward;" Boyer and others.

Causes.—This dislocation is occasioned generally by a fall from a height, upon the bottom of the foot, the foot receiving at the same moment a sufficient inclination outward to determine the main force of the impulse toward the inner side of the ankle. It may be produced also by a blow received directly upon the outside of the leg just above the ankle, or by a violent twist or wrench of the foot outward.

Pathological Anatomy.—A large majority of those accidents which have been called inward and outward dislocations of the tibia, are merely examples of lateral rotation of the astragalus within the half ginglymoid and half orbicular socket formed by the lower extremities of the tibia and fibula; and true dislocations, either partial or complete, are at this joint and in these directions very rare occurrences. I shall continue, in accordance with the general practice of writers, to call them all dislocations, whether the astragalus simply rotates on its axis, or is displaced laterally and horizontally from the tibia.

In the most common form of the accident, then, when the foot is violently twisted outward, the astragalus becomes tilted upon its outer and upper margin in such a way that this margin slides inward and places itself underneath the middle portion of the lower articulating surface of the tibia; its upper and inner margin descends toward the extremity of the malleolus internus, and the outer surface of the astragalus presents obliquely upward and outward, instead of directly outward as it would do in its natural position. This cannot occur without a rupture of the internal tibio-tarsal ligaments, or a fracture of the malleolus internus, or both; indeed, a fracture of the internal malleolus is a very common circumstance in connection with this form of dislocation. Much more frequently, however, the fibula itself gives way at a point within from two to five inches of its lower extremity; or sometimes the fracture in the fibula occurs through that portion which forms the malleolus externus. For more particular information as to the causes and relative

FIG. 490.

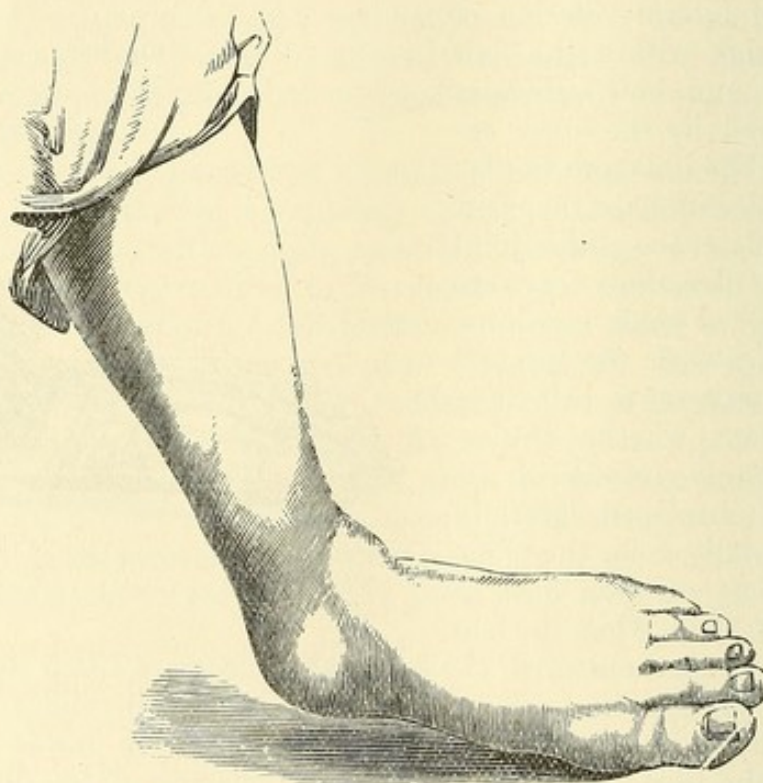


Dislocation of the lower end of the tibia inward (foot turned outward). (Pott's fracture.)

frequency of these fractures, I refer the reader to the chapter on fractures of the fibula.

Rarely it happens that, instead of this lateral rotation of the astragalus, there occurs a true lateral displacement of the tibia inward upon the astragalus, and the outer portion of the lower articulating surface of the tibia comes to rest upon the inner portion of the upper articulating surface of the astragalus; or it may slide completely off in the same direction; a result which is usually attended with a laceration of the muscles and integuments, converting the accident into a compound dislocation. In some cases this extreme displacement occurs without such laceration. In this form of the accident, the true lateral dislocation, the fibula may remain unbroken and undisturbed, the tibia merely having become displaced inward; or the fibula may give way also above the articulation, while the malleolus internus, and the internal lateral ligaments, are equally liable to rupture as in the other form of the accident. Sometimes, in addition to these complications, the lower end of the tibia is

FIG. 491.



Dislocation of the lower end of the tibia inward (foot turned outward).

found to be broken obliquely upward and outward from the articulating surface, leaving that fragment attached to the fibula which corresponds to the inferior peroneo-tibial articulation.

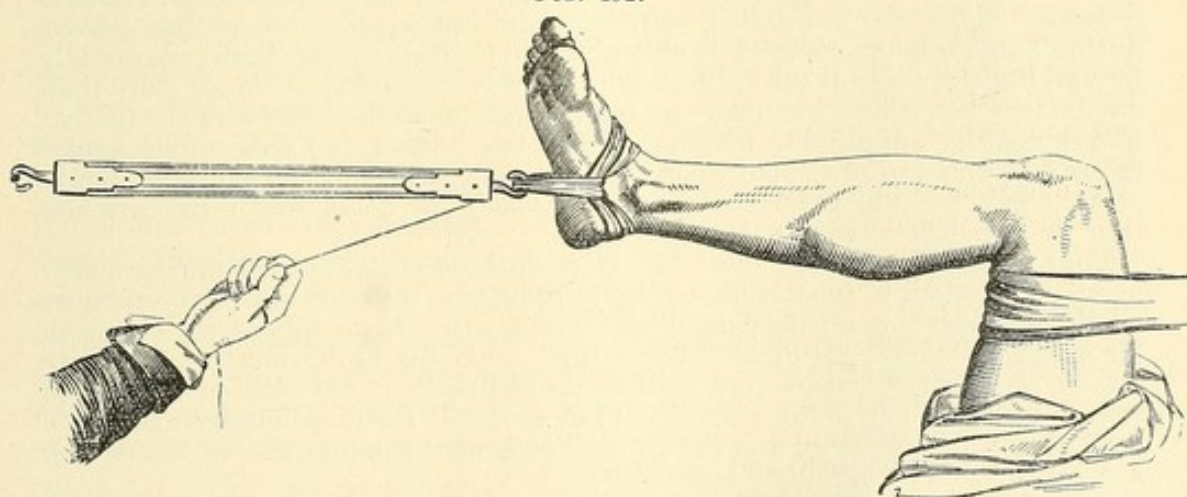
Symptoms.—The foot is more or less violently abducted, the sole of the foot presenting downward and outward instead of directly downward; the malleolus internus projects strongly at the inner side of the joint; and at the outer side there is a corresponding depression, generally most marked a little above the articulation near the point of fracture in the

fibula. The pain is very great, and the foot is immovably fixed so far as the volition of the patient can determine motion, but the surgeon can generally move it pretty freely, yet not without causing a great increase of the pain. When the dislocation is complete, and the fibula is also broken, the limb becomes slightly shortened.

Treatment.—When the accident is of the nature of a simple rotation of the astragalus upon its axis, the reduction is often accomplished with the greatest ease by seizing upon the foot and forcibly adducting it. Not unfrequently the patient himself, or some other person who is present, has effected the reduction before the surgeon is called. In other cases, and especially when it partakes of the nature of a true dislocation, much difficulty is sometimes experienced in the reduction. The surgeon ought then to flex the leg upon the thigh, in order to relax the gastrocnemii muscles, and holding the foot midway between flexion and extension, he should pull steadily upon it with his own hands, while an assistant makes counter-extension and supports the limb with his hands, grasping the thigh above the knee. At the same moment lateral pressure should be made upon the projecting bone in the direction of the articulation. It is of some use, also, occasionally to flex and extend the limb moderately, and to give to the foot a gentle rocking motion. If more force is needed, it may be applied by placing the limb over a firm double-inclined fracture-splint, and making the extension by the aid of a screw attached to the foot-board, as I have suggested in certain cases of dislocation at the knee. Or we may employ the pulleys after the manner represented in the accompanying drawing, Fig. 492.

C. S., aged about 30 years, while carrying a weight upon his shoulders, on the 6th of May, 1854, slipped upon the sidewalk, and fell, dislocating the left

FIG. 492.



tibia inward, and fracturing the fibula four inches from its lower end. I was in attendance soon after the accident occurred, and found the tibia projecting inward, with the other symptoms usually accompanying a simple rotation of the astragalus upon its axis. Seizing the foot with my hands and flexing the leg, while an assistant held the thigh and made counter-extension, I had scarcely begun to pull upon the foot before the reduction was effected. Dupuytren's splint was at once applied, and the subsequent inflammation was so trivial as scarcely to deserve notice. In six weeks the limb was sound, and free from all ankylosis.

In my report on dislocations, made to the New York State Medical Society for the year 1855, I have mentioned twelve similar examples, in addition to some examples of compound dislocations, all of which were easily reduced, but the results were not always so favorable.

If, as rarely happens, the tibia is broken obliquely into the joint, the complete reduction of the dislocated tibia may be found impossible, owing to the obstacle presented by the displaced fragment.

The following I am disposed to regard as examples of dislocation accompanied with fracture of the tibia within the articulation: Brockway, of Cortland, N. Y., aged about twenty-seven years, consulted me in relation to the condition of his foot. I found the tibia dislocated inward, and projecting more than an inch beyond the astragalus; the sole was turned outward, compelling him to walk upon the inside of his foot; the fibula was bent inward against the tibia, at a point about four inches above the ankle, which seemed to have been the seat of fracture of this bone. He stated to me, that immediately after the receipt of the injury, which was occasioned by a fall from a height upon the bottom of his foot, a surgeon made repeated and violent efforts to effect the reduction, but he had been unable to do so. Indeed, the bone had never been removed from the position in which it was at first placed.

J. B., of Erie Co., N. Y., æt. 31, fell under a rolling log, and dislocated his left tibia inward, breaking off the internal malleolus, and fracturing the fibula four inches from its lower end. An old and experienced practitioner was immediately called, who, with another surgeon, failed, after repeated efforts, to reduce the dislocation. I saw the patient, in consultation with these gentlemen, twenty-four hours after the accident. The foot and ankle were somewhat swollen and discolored. The lower end of the tibia projected so far inward as to threaten a rupture of the skin; the foot was strongly everted. We first flexed the leg upon the thigh, and made extension with our hands, in the manner I have already directed. This we continued several minutes; finally moving the limb in various directions, and adding forcible pressure upon the inside of the projecting tibia. We then placed the leg over a double inclined plane, and, securing it firmly in place, we attached a screw to the foot through a sandal and gaiter, and while the leg was well flexed upon the thigh, we renewed the extension and lateral pressure. This was continued, with the application of more or less power, during half an hour, meanwhile changing the position of the limb occasionally by varying the angle of the splint. Our efforts were prolonged in all more than one hour, when, as we had made no impression upon the bone, and the patient had repeatedly implored us to desist, the attempt was given over. The end of the tibia seemed to rest partly upon the astragalus, and the extension was plainly all that was demanded, but the obstacle was beyond doubt within the articulation, or rather between the tibia and fibula.

Four weeks after the accident, Mr. B. walked on crutches, and during a year he was compelled to use a cane, but since that time, a period of twelve years, he walked without any artificial support. For a year or two he felt a yielding in his ankle, as the weight of his body settled upon his limb; but this gradually ceased, and for some years past he has walked without any halt, and seems to step as firmly as before the accident. The foot still inclines outward; the tibia projects inward one inch, and the broken ends of the fibula can be felt resting against the tibia, where they are reunited.

I had occasion to amputate a limb for a compound dislocation inward, at the ankle-joint, and the possibility of this fracture was confirmed by the dissection. About one-third of the outer portion of the articular surface was broken off obliquely, and the fragment was lying so displaced that a reduction would have been rendered impossible.

Dr. Townsend, of Boston, has reported a case of compound dislocation, in which also amputation became necessary; and, with other injuries, the dissec-

tion showed a fragment from the outer margin of the tibia, one inch and a half long, and one inch thick at its widest part, with a very sharp point, displaced, and lying almost transversely over the astragalus.¹

In 1842, A. Berard,² in order to effect reduction, divided subcutaneously the tendo-Achillis, and at the same time the peroneus longus and brevis. Valentin³ reports a case of dislocation forward and inward, which had resisted all efforts. Traction made by three strong assistants, while the patient was under the influence of chloroform, and at two different days, had produced no result. Valentin divided the tendo-Achillis, and was then able to reduce the dislocation alone, and without the employment of excessive strength. The patient recovered with a restoration of the natural motion of the foot.

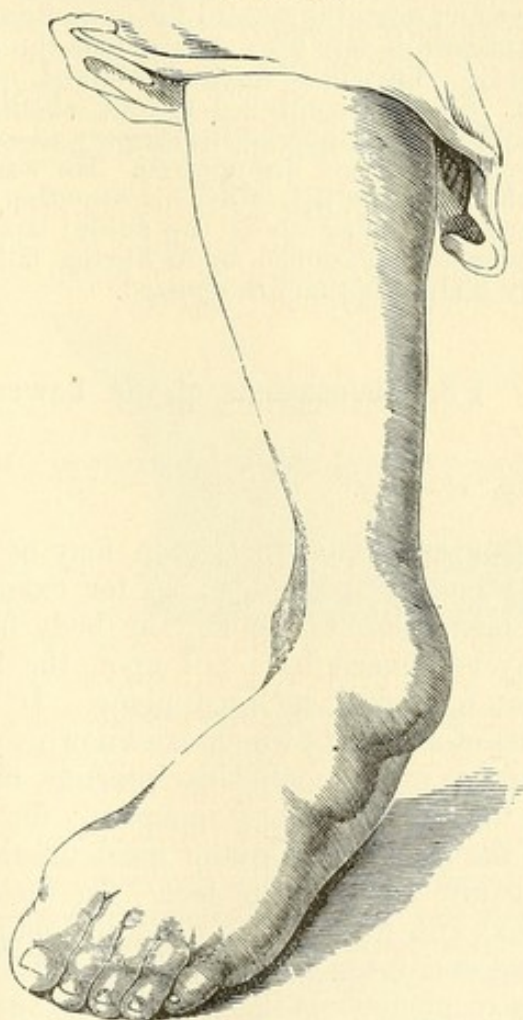
For a more full account of the prognosis and the general management of these cases subsequent to the reduction see the chapter on fractures of the fibula; and for the treatment of compound dislocations of the ankle-joint, see also the chapter on compound dislocation of the long bones.

§ 2. Dislocations of the Lower End of the Tibia Outward.

Syn.—"Outward tibio-tarsal dislocation;" Malgaigne. "Dislocations of the foot inward," of others.

The causes are the same or similar to those which are known generally to produce dislocations inward; only that the force of the concussion or the direction of the rotation must have been reversed. The external lateral ligaments, peroneo-tarsal, are either ruptured, or the lower portion of the fibula gives way, or both of these circumstances may have happened; while the internal malleolus may also yield to the shock and to the weight of the body now resting upon it. The nature of the accident may vary also in respect to the relative position of the articular surfaces; the astragalus may simply rotate on its inner and upper margin, or the tibia, with the fibula, of course, may actually slide outward until the lower end of the tibia more or less completely abandons the upper surface of the astragalus.

FIG. 493.



Dislocation of the lower end of the tibia outward (foot turned inward).

¹ Townsend, Mass. Hosp. Reports, Boston Med. and Surg. Journ., vol. xxxiii. p. 277.

² Berard, The Lancet, 1844, vol. i. p. 8.

³ Valentin, Thèse de Strasbourg, 1866, No. 970; Arch. Gén. de Méd., t. 1. 1867.

Treatment.—The modes of reduction, and the general principles of treatment, will not differ from those which I have mentioned as suitable for dislocations in the opposite direction. The examples which have fallen under my observation are not numerous, but the reduction has always been easily effected. Thus, a man, *æt.* 21, fell from a scaffolding, alighting upon his feet. He says that his left foot struck the ground obliquely, and upon its outer margin. I found the fibula projecting very strongly outward, evidently carrying with it the tibia; the malleolus internus was broken off, and the foot forcibly turned inward. Without either flexing the leg upon the thigh or calling to my aid any degree of counter-extension except what was made by the weight of the body, I grasped the foot and drew upon it gently, while at the same moment I rotated the foot outward. Immediately the bones resumed their places.

In June of 1846, H. W., *æt.* 38, consulted me in relation to his foot, which he said had been dislocated four weeks before. He had fallen upon the outside of his foot and turned it suddenly inward, so that when he looked at it he found the sole presenting toward the opposite side. Seizing upon it with both hands, he pressed it forcibly outward, and the reduction immediately took place with a snap. Very little soreness followed, nor was he confined to his house a single day. He had continued to walk about with only a slight halt in his gait, nor would he have thought it necessary to consult me at all except that the tenderness had not yet disappeared. He was not aware that the fibula had been broken also, until I called his attention to the fact. The fracture had taken place two inches above the ankle; and although it was already united, the depression occasioned by its having fallen in somewhat toward the tibia was very plainly felt and recognized.

§ 3. Dislocations of the Lower End of the Tibia Forward.

Syn.—"Forward tibia-tarsal luxations;" Malgaigne. "Dislocations of the foot backward," of others.

Causes.—This dislocation may be produced by a violent extension of the foot upon the leg; as, for example, when, the foot being engaged under a piece of timber, the body falls backward to the ground; or it may be caused by a fall upon the bottom of the foot, the foot resting upon a slightly inclined plane. It may be caused also by any of that class of accidents which are known to produce fractures of the fibula with fracture of the malleolus internus, or fracture of the fibula with rupture of the internal lateral ligament; for example, by a fall upon the bottom of the foot, or upon the inside of the sole, followed immediately by an outward twist of the foot. In these cases the dislocation of the foot backward, or, as it is generally found to be, the semiluxation, may be consecutive upon the accident, and the result only of contraction of the *gastrocnemii*. It may, therefore, occur immediately after the fracture has taken place, or not until after the lapse of several days.

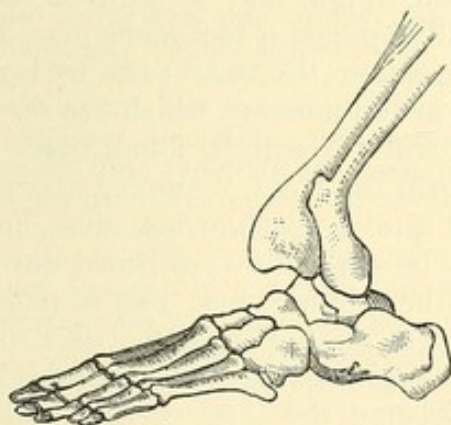
Pathological Anatomy.—The displacement may be very slight, so that the end of the tibia is only a little advanced upon the astragalus; or it may be such that the tibia rests one-half upon the naviculare and one-half upon the astragalus, or it may even desert the astragalus entirely. The fibula may at the same time be broken at any point, but it is generally broken two or three inches above its lower extremity. The malle-

olus internus is also sometimes broken, but more often the internal lateral ligament is torn. Still more rarely a fracture occurs through the posterior margin of the articular surface of the tibia.

Symptoms.—The length of the foot in front of the tibia is diminished, while the projection of the heel is correspondingly increased; the toes are turned downward and the heel drawn upward, and fixed in this position; the end of the tibia may generally be distinctly felt in front of the astragalus; the extensor tendons of the toes are sharply defined, while the tendo Achillis is curved forward and tense.

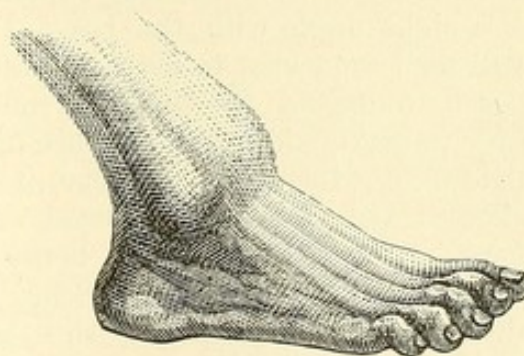
I presented to the New York Pathological Society a specimen obtained from the dissecting room of the Bellevue Hospital College. The history of the case was unknown. Before dissection the foot was observed to be turned outward, and shortened in front of the tibia, while there was a corresponding lengthening of the heel. The specimen, after dissection, disclosed a fracture of the internal malleolus half an inch above its lower end and a fracture of the fibula a little above its lower end. The tibia was displaced forward about three-quarters of an inch, so that only the posterior half of its lower end rested upon the articular surface of the astragalus, and at the point of contact with the astragalus a new socket was formed in the tibia, concave upward, half an inch deep, and presenting an appearance as if the posterior lip of the lower end of the tibia had been broken off and had become displaced upward. It was supported by a broad buttress of bone. It is not certain, however, but that this appearance was occa-

FIG. 494.



Partial dislocation of the tibia forward, with fractures of malleolus internus and fibula. Skeleton.

FIG. 495.



Appearance of a partial dislocation of the tibia forward, with fracture of the malleolus internus and fibula.

sioned solely by the long-continued pressure of the tibia upon the astragalus at this point. The fragments of the malleolus internus, and the lower fragment of the fibula, remained attached to their upper fragments and to the two sides of the astragalus in their normal positions, consequently each fragment was inclined downward and backward at an angle of 45° . The lower fragment of the fibula was driven upward, also, but both of the fractures were firmly united.

At the same meeting I reported the case of Mary Conlan, *æt.* 38, having been thrown, three days before, from a street-car. She could give no account of the manner in which she fell. I saw her November 16th. The limb was then much swollen, and I diagnosticated a fracture of the lower end of the fibula. (It had been supposed to be a mere sprain up to this time.) The limb was directed to be wet with cool water, and to rest upon a pillow. November 23d I found the lower end of the tibia displaced forward, and ascertained, also, that the internal malleolus was broken at its base. The dorsum of the foot, measuring from the

front of the tibia to the end of the great toe, was shortened half an inch. The heel was lengthened. There can be no doubt that in this case the dislocation occurred subsequent to the fracture, and that it was caused by the contraction of the *gastrocnemii*. I reduced the dislocation a day or two later, and maintained it in position by the method which I shall presently describe.

Dr. Voss reported to the Society a similar case which had come under his notice, and Dr. Buck remarked that he, also, had met with such examples.¹

Dr. Prince, of Illinois, has reported a case of this character which, remaining displaced, led to a prosecution for damages. A lady, æt. 40, met with an accident, August 31, 1863, which resulted in a fracture of the fibula near its lower end and a partial dislocation of the tibia forward to the extent of one inch. The toes were not pointed downward, but the foot had its natural angle with the leg. Nearly three months after the accident Dr. Prince, assisted by two other surgeons, broke up the adhesions, and reduced the bones to their natural positions.²

Treatment.—The reduction is to be attempted by flexing the leg upon the thigh, and making extension from the foot, while at the same moment pressure is made upon the front of the tibia and against the heel. When the bone begins to slide into place, the foot should be forcibly flexed upon the leg. A slight lateral motion or rotation in either direction may assist in restoring the bones to place. In general, the dislocation has been easily reduced, but in a majority of the examples recorded great difficulty has been experienced in maintaining the reduction; and in a few cases it has been found impossible to do so. In order to maintain the reduction, the leg, flexed upon the thigh, may be laid on its back in a box, and the foot supported firmly against a foot-piece placed at a right angle with the box. In this position the weight of the leg will tend somewhat to overcome the action of the muscles, which are disposed to displace the foot backward. Generally it will be found necessary to make additional pressure directly upon the front of the leg above the ankle, which, in order that it may not prove mischievous, must be effected with some soft material, and must be applied over a broad surface. Perhaps nothing will better answer these indications than to pass a cotton band, six or eight inches in width, through slits or mortises in the sides of the box, these slits being of a width equal to the width of the band and placed at a point sufficiently below the level of the spine of the tibia, so that when the band is made fast underneath the box, it shall press the leg firmly backward. To prevent the heel from suffering in consequence of this pressure, it also should be supported, or suspended by another band passing underneath the heel and fastened above to the top of the foot-board.

The plaster-of-Paris dressing, also, answers the purpose exceedingly well in these cases; indeed, as I have explained more fully in connection with the subject of Pott's fracture, I must regard it as the most effective means for preventing these accidents, as sequences of this fracture, and as the most certain means for retaining the bones in position, when, the displacement having actually occurred, they are again put in place.

¹ New York Journ. Med., April, 1866, p. 40.

² Cincinnati Journ. Med., April, 1867, p. 202. See also Todd's *Cyclopædia of Anat. and Phys.*; Adams on Ankle-joint, p. 160 et seq.

Dupuytren relates the following example of this accident: Pierre Froment, æt. 33, was carrying a heavy weight upon his back and had his right foot in advance, when by accident he came suddenly in contact with a beam placed across his path. Under the fear of being precipitated forward, he made a sudden effort to throw his body backward, by which he lost his balance, and fell with the point of the left foot inclined inward and forward, and his whole weight was thrown first on the outer side and then on the front of the ankle-joint. On examination, the leg seemed to be planted upon the middle of the foot; the toes were directed downward and the heel drawn up. On the instep there was a large bony prominence, over which the extensor tendons of the toes were stretched like tense cords. Behind the joint was a deep hollow, at the bottom of which the tendo Achillis could be felt forming a tense, resisting, semicircular cord, with its concavity directed backward. The fibula was also broken, the lower end of the lower fragment remaining attached to the foot, while the upper end of the same fragment was carried forward by the displacement of the tibia, so that it lay nearly horizontally, with its broken extremity directed forward. Dupuytren directed one assistant to fix the leg and a second to make extension from the foot, while Dupuytren himself, standing on the outer side of the limb, forced the heel forward and the tibia backward. The first attempt succeeded partially and the second completed the reduction. The limb was then placed in the apparatus employed by this surgeon for a fractured fibula, which I have before described, and laid on its outer side in a semiflexed position. The patient recovered rapidly, and in little more than a month he was able to walk.¹

But such fortunate results have not usually been observed; indeed, Dupuytren encountered much more serious difficulties in two other cases which came under his own notice, one of which he has himself recorded. This was in the person of a woman, æt. 48, who was brought to l'Hôtel Dieu in 1815, the accident having just happened from a slip in going down stairs. The fibula was broken, and also a fragment was broken from the tibia. The house surgeon reduced the bones, and placed the limb in the ordinary apparatus for broken legs; but on the following day Dupuytren found them redislocated, and laid the limb on his own splint, but the pressure requisite to keep the tibia in place soon induced sloughing, ulceration, and abscesses, and after four months' treatment, during which time the tibia had been repeatedly displaced, she left the hospital, able to use her limb, but with a certain amount of incurable deformity.¹ Malgaigne mentions the third example as having been seen by himself in Dupuytren's service in 1832, in which case the attempt to maintain the reduction by a tourniquet resulted in gangrene and finally the death of the patient.² Earle lost a patient after amputation made on the eighth day. The tibia could not be kept in place, and the amputation became necessary on account of the final protrusion of the bone through the integuments, which had sloughed.³ Reginald Harrison,⁴ who had seen three cases of this dislocation, practised section of the tendo Achillis for the purpose of maintaining the tibia in place, and with complete success.

§ 4. Dislocations of the Lower End of the Tibia Backward.

Syn.—"Backward tibio-tarsal dislocation;" Malgaigne. "Dislocations of the foot forward," of others.

More rare than the dislocations forward, Malgaigne has, nevertheless, succeeded in collecting five examples. They appear to have been produced, generally, by a cause the reverse of that which we have seen to produce in certain cases the preceding dislocation. Thus, while the dislocation forward is produced sometimes when the foot is in violent exten-

¹ Dupuytren, *op. cit.*, p. 276.

³ Malgaigne, *op. cit.*, p. 1044.

² Malgaigne, *op. cit.*, p. 1044.

⁴ Harrison, *The Lancet*, 1876, vol. i. p. 707.

sion, this dislocation has occurred, in at least two or three cases, when the foot was forcibly flexed upon the leg.

The symptoms are strongly marked and characteristic. The length of the foot from the tibia to the ends of the toes is increased one inch or more, the head being correspondingly shortened, or rather wholly obliterated; a portion of the articulating surface of the astragalus may be dis-

FIG. 496.

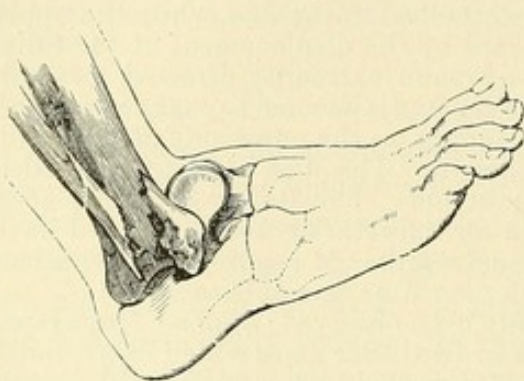
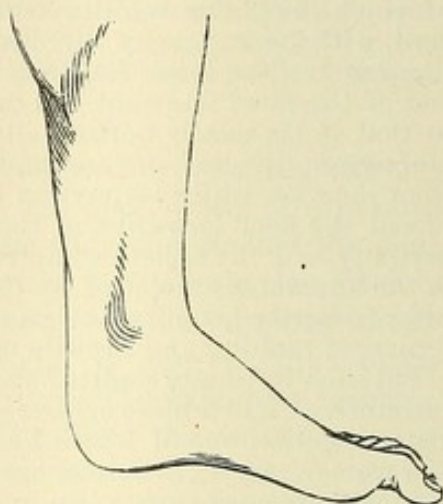


FIG. 497.



Dislocations of the lower end of the tibia backward.

tinctly felt in front of the tibia; the posterior surface of the tibia touches the tendo Achillis; the leg is shortened, and the malleoli approach the sole of the foot. In most cases one or both of the malleoli have been broken; and R. W. Smith, who has reported one of the examples alluded to, believes that the dislocation is never complete.

A similar case came under the observation of Dr. S. B. Ward, of Albany, N. Y., in November, 1882. The patient had fallen from a scaffold, and Dr. Ward found him with a fracture of the internal malleolus and a dislocation of the tibia backward, the signs of which were characteristic and marked. Reduction was easily effected, and was accompanied with an audible snap. There was no apparent tendency to a recurrence of the dislocation, and there resulted finally a complete restoration of the motions of the ankle-joint. Another case is reported by M. Poland, in Guy's Hospital Reports for 1855.

Reduction should be attempted by a method similar to that which has been recommended in all the other dislocations of the ankle, only with such modification as the peculiarities of the case must necessarily suggest.

CHAPTER XXI.

DISLOCATIONS OF THE UPPER END OF THE FIBULA.

Syn.—"Dislocations of the superior peroneo-tibial articulation;" Malgaigne.

SURGEONS have frequently described a condition of the peroneo-tibial articulation in which the ligaments have become relaxed, giving a preternatural mobility to the head of the bone. It is also not unfrequently displaced upward, in consequence of an oblique fracture of the tibia. I have myself seen several examples of both these accidents; but simple traumatic dislocations, which can only occur forward or backward, are very rare (Boyer¹ relates a case in which both the upper and lower peroneal extremities were dislocated, and the foot dislocated outward).

§ 1. Dislocations of the Upper End of the Fibula Forward.

Malgaigne has collected three examples of this dislocation, observed by Savournin, Jobard, and Thompson, respectively, uncomplicated with any other accident; and not, apparently, due to any abnormal condition of the ligaments; two of which, at least, seemed to have been produced by the violent action of the muscles which, arising from the anterior face of the fibula, traverse below the anterior surface of the foot. The third example, reported by Thompson, permits a doubt as to whether the displacement was occasioned by muscular action, or by a direct blow upon the part.²

The signs which characterize the anterior dislocation are the absence of the head of the fibula from its natural position, and its presence in front, near the ligamentum patellæ; the altered direction of the biceps flexor cruris muscle; and, in one case, considerable deformity in the shape and position of the leg has been observed.

Thompson and Jobard³ were unable to accomplish the reduction while the leg was extended upon the thigh, but succeeded readily after having flexed the leg. In Thompson's case the bone returned with a distinct *crepitus*. Savournin's case is related by Goyrand⁴ from memory. A woman, æt. 35, in falling caught her right foot, turning it violently inward. Savournin was called at once. He flexed the leg violently, in order "to relax the muscles going from the anterior face of the fibula to the dorsal surface of the foot," and then easily pushed the bone in its place with his fingers. The patient was kept in bed eight days, no dressings or splints being applied, and on the twelfth day she was dismissed cured. Malgaigne thinks that flexion of the leg, combined with flexion of the foot, would render the reduction more easy.

¹ Boyer, *Trait. des Mal. Chir.*, t. 4, p. 375.

² Thompson, *The Lancet*, 1850, vol. i. p. 385.

³ Jobard, *Rev. Med. Chir.*, 1853, t. 14, p. 114.

⁴ Savournin, Goyrand, *Clin. Chir.*, Paris, 1876, p. 111.

In whatever position the limb is placed, the surgeon must rely chiefly upon forcible pressure made with the fingers against the front and upper portion of the displaced bone.

Dr. J. Hawley, of Ithaca, N. Y., has furnished a brief account of a case which came under his observation: On the 29th of March, 1854, Bambak, while vaulting upon the parallel bars in a gymnasium, unintentionally made a complete somersault, and fell with his right foot upon the edge of a plank. Dr. Hawley, who was immediately called, found his right leg semiflexed and immovably fixed. The head of the fibula was plainly felt in front of its natural position, near the ligamentum patellæ. The patient was suffering the most intense pain. Extension and counter-extension were made, and while the doctor was pressing with both of his thumbs upon the head of the fibula, it went into its place with an audible snap. The relief was instantaneous. Complete rest was observed for a few days, while cooling lotions were constantly applied, and within a week he was able to attend to his usual duties.

§ 2. Dislocations of the Upper End of the Fibula Backward.

Sanson has recorded one example, in which the passage of the wheel of a carriage across the upper part of the leg, precisely on a level with the peroneo-tibial articulation, ruptured the ligaments which bind the fibula to the tibia, and caused a displacement, which, however, seems to have been spontaneously overcome. Nevertheless, there remained a preternatural mobility, permitting the fibula to be pushed easily backward or forward upon the tibia.¹

Sanson did not think that a permanent dislocation could be produced at this joint, but that the bone would be restored to its socket inevitably by the strong resistance offered by the aponeurosis attached to the head of the fibula; and Malgaigne seems not to have considered the case related by Sanson as a fair example of complete backward dislocation. It is my opinion, however, that, considering the nature and direction of the force applied, and the character of the symptoms present, it ought to be regarded as a complete backward dislocation; in which, however, the aponeurosis not being much disturbed, the bone was easily restored to its position and retained.

The first unequivocal case of this dislocation, unaccompanied by other complications, is related by Dubreuil.² A man, æt. 32, in order to save himself from falling, sprang suddenly, with his right leg in a position of extreme abduction, and at the same moment he experienced a severe pain in the region of the peroneo-tibial articulation. The head of the fibula was found to be thrown backward, and formed under the skin a marked prominence; the foot was thrown outward, and the whole outside of the limb became cold and numb. Dubreuil flexed the leg moderately, and pressing the head of the fibula from behind forward, the reduction was easily effected. On the following day, the limb having been straightened, the dislocation was found to be reproduced. It was again replaced, and the knee covered with a leather cap, secured moderately tight. After twelve days of complete rest, the knee was moved gently, and on the seventeenth day the patient walked with the help of a cane. For some time the leg had a tendency to incline outward; but in about three months the cure was perfectly established. It is probable that in this latter case the dislocation resulted from the violent action of the biceps flexor cruris. Such, at least, is the

¹ Sanson, Dict. de Méd. et de Chir. pratiques, p. 274, from Malgaigne.

² Dubreuil, Journ de Chir., 1844, p. 214, from Malgaigne.

opinion of both Dubreuil and Malgaigne, and I see no reason to question the correctness of their theory.

Erichsen mentions that a gentleman, 23 years old, fell in descending the Alps, with his leg bent forcibly under him, dislocating the head of the fibula backward. When seen by Mr. Erichsen it was found impossible to reduce it, owing to the tension of the biceps. He suffered no permanent inconvenience from the accident, except that this limb was a little weaker than the other, and he could not jump.¹

Another example has been reported by Dr. Joseph G. Richardson, resident physician to the Pennsylvania Hospital. John Dixon, æt. 9, fell five feet and struck upon the outside of the left knee. When admitted to the hospital, the leg was partially flexed and the toes a little everted, and he was unable to flex or to extend the limb completely. The head of the fibula was seen three-quarters of an inch behind its natural position, and the biceps was felt distinctly attached. There was no other lesion. The reduction was easily accomplished by pressing with the fingers upon the inner and back part of the fibula, thrusting it outward and forward. A compress and bandage were applied, and the limb placed at rest. The reduction continued complete, and after a few days he was permitted to use the limb.²

A boy, æt. 2 years, fell from a chair, and on examination two weeks later, the doctor found the head of the fibula displaced backward. It was easily replaced, and without pain; but some months later the surgeons in attendance were unable to retain it in place.³

Bryant says he has seen three examples of the backward dislocation, but gives no account of them.⁴

[§ 3. Displacement of the Head of the Fibula attended with Fracture.]

[Reference has been made, in connection with fractures of the fibula, to a fracture near the head, with several cases (page 463). A phase of that fracture is found in an accompanying displacement of the head of the fibula. The following case, reported by Dr. A. J. McCosh, of New York, illustrates this injury. A man, æt. 46, while in the act of lifting a horse's foot, the animal rolled over against the inside of his thigh, and as his leg slipped under the horse into a position of external adduction, he felt a pain and something give way on the outer side of his knee. On examination the smooth head of the fibula was not felt in its place, but at a point three-fourths of an inch above where it should be situated was distinctly felt a movable body of bony consistence about the size of a hickory nut; this mass could be easily grasped with the fingers, was movable laterally, could be pushed upward for a short distance, but could not be made to descend toward the foot; it was directly attached to the tendon of the biceps femoris muscle; below this was a depression of three-quarters of an inch, and then was encountered the upper end of a bone somewhat square and angular to the touch, which, on being traced downward, proved to be the fibula. It was evident that the injury consisted in a fracture of the upper end of the fibula, a fragment about three-quarters of an inch in length being drawn upward for a distance of one inch by the contracting force of the outer hamstring muscle. The upper fragment could not be brought directly down to the lower, but by flexing the knee to about 30° the separation was estimated at about half an inch. Union took place by fibrous tissue, and the patient was able to walk well, though the fragments separated three-fourths of an inch, and the upper fragment can be moved from side to side. There was no loss of sensation. Dr. McCosh reports a second case of fracture of the head in which the lower end of the small upper fragment appeared to spring away from the joint, and in order to bring the fractured surfaces together again pressure inward had to be made on the upper fragment.⁵

¹ Erichsen, *Science and Art of Surgery*, Amer. ed., 1873, vol. ii. p. 440.

² Richardson, *Amer. Journ. Med. Sci.*, April, 1863.

³ *St. Louis Med. and Surg. Journ.*, March, 1881.

⁴ Bryant, *Practice of Surgery*, Eng. ed. of 1872, p. 810.

⁵ *New York Med. Record*, Nov. 15, 1890.

Dr. R. F. Weir,¹ of New York, in an instructive paper, reports a case of fracture and displacement of the styloid process of the head accompanied by injury to the external popliteal nerve. The injury occurred while wrestling and was due to the action of the biceps muscle. The displaced fragment was not brought into contact with the fibula, but the patient recovered good use of the limb.]

CHAPTER XXII.

DISLOCATIONS OF THE LOWER END OF THE FIBULA.

Syn.—"Luxations of the inferior peroneo-tibial articulation;" Malgaigne.

EXCEPTING Boyer's case of dislocation of both the upper and lower ends of the fibula, already referred to, Nélaton relates the only example of a simple dislocation of this articulation of which I have any information. The patient who was the subject of this accident presented himself at the hospital under the care of M. Gerdy on the thirty-ninth day after the accident, which had been occasioned by the passage of the wheel of a carriage obliquely across the leg in such a manner as to push the malleolus externus directly backward. The lower end of the fibula was in almost direct contact with the outer margin of the tendo-Achillis; the outer face of the astragalus, abandoned by the fibula, could be distinctly felt in nearly its whole extent; the foot preserved its natural position; and he could walk pretty well, only that he was obliged to step with some care. M. Gerdy believed that the bone was too firmly fixed in its new position to be moved, and therefore made no attempt at reduction.

CHAPTER XXIII.

TARSAL DISLOCATIONS.

§ 1. Dislocations of the Astragalus.

Syn.—"Double dislocations of the astragalus;" Malgaigne.

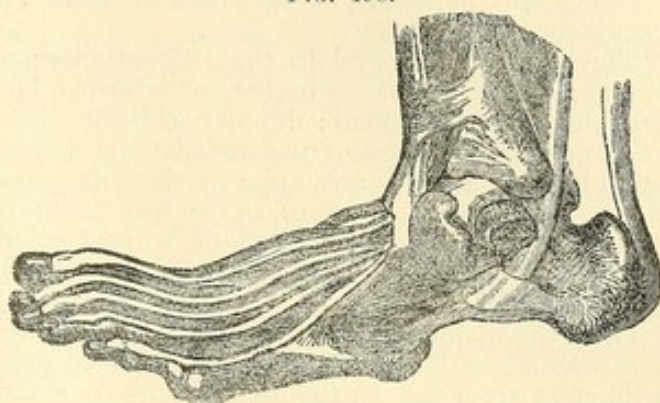
THE astragalus may be dislocated forward, outward, inward, backward; or it may be dislocated obliquely in either of the diagonals between these lines; it may be simply rotated upon its lateral axis, without much, if any, lateral displacement; and, finally, it has been occasionally driven between the tibia and fibula, tearing away the intermediate ligaments, and generally fracturing one or both bones of the leg.

Causes.—The causes which have been found chiefly operative in the

¹ New York Medical Journal, vol. xlvii. 1888.

production of this dislocation are very much the same as those which produce, under other circumstances, a dislocation of the lower end of the tibia. Thus, a fall from a height upon the bottom of the foot, accompanied with a violent abduction, adduction, flexion, or extension, may determine a dislocation of the astragalus inward, outward, backward, or forward. Sometimes it is accomplished by a mere wrenching or twisting of the foot in machinery, or in the wheel of a carriage, or by being caught between two irregular bodies. It may be produced also by a direct blow.

FIG. 498.



Dislocation of the astragalus outward. Anatomical relations.

Symptoms.—The great prominence occasioned by the displacement of the bone in either of these several directions, accompanied generally with more or less lateral deviation of the foot, is alone sufficient to indicate the true nature of the accident. In some cases, also, the foot is forcibly flexed or extended; the leg is shortened in consequence of the tibia having fallen down upon the calcaneum; the superincumbent skin and tendons are rendered tense; blood is effused, and swelling speedily occurs. In the backward dislocation, the position of the foot is not much changed, but the tibia being slightly carried forward, the length of the dorsal aspect of the foot is proportionately diminished. To be more precise, I shall quote at length from the careful analysis of this subject made by Poincot in the French edition of this treatise.

“The dislocation *forward*, which is very rare, is characterized by the prominence of the astragalus on the dorsal surface of the foot, at a point corresponding exactly to the space midway between the two malleoli, or to the dorsal surface of the scaphoid bone; that prominence is movable upon the foot and upon the bones of the leg.

“In the dislocation *forward and outward*, the most common of all, the foot is in a state of strong adduction, its extremity being directed inward, and its internal border being shortened and concave. The tibia rests upon the calcaneum, instead of the astragalus, and seems as if embedded in the soft parts; the fibula gives rise to a marked projection on the outside. Through the stretched integuments, in front and on the outside, the articular facetta of the astragalus can be recognized.

“When the dislocation has been produced *forward and inward*, the projecting astragalus is felt at that point; moreover, the foot is slightly abducted, with its external border elevated; but the characteristic sign consists in the change of direction taken by the astragalus, whose head is directed downward, its axis having thus become parallel with that of the tibia.

“The dislocation directly *backward* is characterized by the projection of the astragalus between the tibia and the tendo Achillis, which is pushed backward; in addition to this displacement backward, the astragalus undergoes a rotation in the direction of its transverse axis, which brings its superior surface forward and the inferior one backward. The tibia being slightly carried forward, the dorsal surface of the foot is shortened.

"In the dislocations *backward and inward*, or *backward and outward*, the projecting astragalus is felt behind the corresponding malleolus.

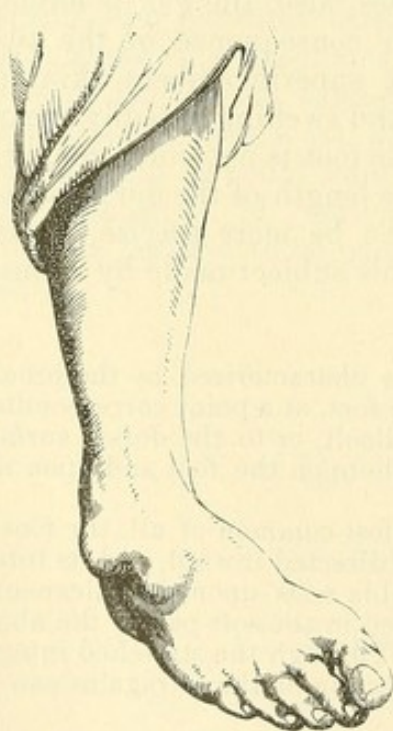
"The symptoms observed following a dislocation *inward* are: forced abduction of the foot; the existence, below the malleolus externus, of an enormous depression, into which the integuments may be pushed; the very marked projection of the internal malleolus, below which the facetta of the astragalus is felt directed completely inward.

"The signs are reversed in the dislocation *outward*, viz.: forced abduction of the foot; projection of the malleolus externus, below which is the facetta of the astragalus turned outward; depression below the malleolus internus.

"The clinical history of the dislocations *by rotation* or *by renversement* is too incomplete yet to give any hope of their diagnosis being established with precision. I will relate, however, in the way of information, what has been written by M. Delorme regarding the signs which, according to his statement, would enable one to diagnose the dislocations of the astragalus by *renversement* or *upside down*.

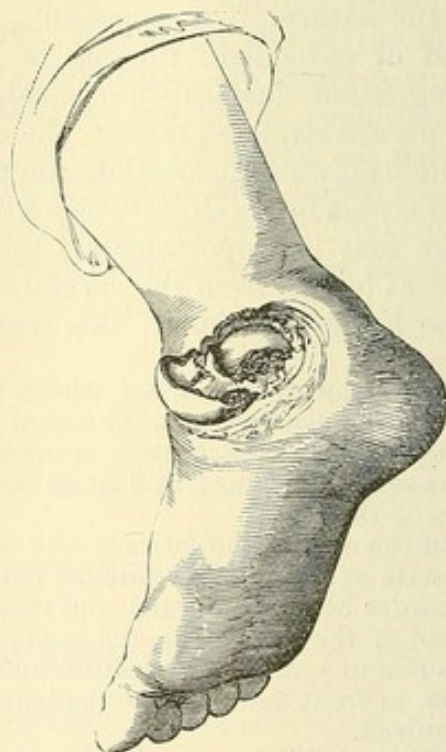
"If, in the dislocation without rotation, the two bony borders of the pulley of the astragalus be looked for, they begin to be felt very near the head, at 1 or 1½ centimetres from it. In the dislocations by rotation (of 180 degrees or by *renversement*), on the contrary, the projections by which the inferior and posterior articular surface of the astragalus is limited, and which were taken for the margins of the facet, are 3½ to 4 centimetres behind the head, two fingers' breadth, as Chassaignac has observed, who did not take advantage of this sign to establish his diagnosis.

FIG. 499.



Simple dislocation of the astragalus
outward.

FIG. 500.



Compound dislocation of the astragalus
inward.

"In dislocations without rotation, the interval separating the two bony margins of the facet of the astragalus is 3 centimetres, measured directly over the bone. It would exceed 3 centimetres, but would not reach 4, on a foot covered by the soft parts and swollen. In dislocations by rotation, the interval separating the projections which overhang the posterior articular surface of the astragalus is already 4 centimetres. The thickness of the soft parts and the swelling would increase it to nearly 5 centimetres.

"Finally, by careful search, it would not be more difficult to feel the depres-

sion of the articular surface, between the two projecting eminences of the inferior surface of the astragalus, than to feel the flat part of the superior surface, which is commonly recognized in the double dislocations without rotation. At any rate, establishing the absence of this surface would be the acquisition of a valuable sign."

Such are the symptoms which may ordinarily enable us to recognize the true character of these displacements when not much swelling exists, even though the skin is not broken and the bones are not exposed; but in a majority of the examples which have been seen, the integuments have been more or less extensively torn, exposing to the eye at once the naked bone, and thus removing all chance of error in the diagnosis.

Norris mentions a case seen by Hammersley, in which the astragalus was thrown completely out, and was subsequently found in the earth where the patient had received his injury. Inflammation, gangrene, and tetanus supervened, and the patient died on the seventh day.¹

Prognosis.—It will be readily understood that nothing short of very great violence could disturb and completely break up the connections of a bone so compactly and firmly seated as is the astragalus, and that, aside of any unusual complications, under the most favorable circumstances, intense inflammation must naturally be anticipated; and, with few exceptions, this has actually taken place. Even when reduction has been promptly and easily effected, inflammation, gangrene, and death have sometimes speedily ensued. But more often the reduction has been found to be exceedingly difficult or impossible, and complete removal of the bone or amputation has been immediately demanded. In a limited number of cases, on the other hand, the bone has been easily reduced, and recovery has taken place, with a tolerably useful limb; or resection has been practised with an equally favorable result; in still other cases the bone has been left protruding, and the patient has finally recovered so far as to be able to walk again, but in such a crippled condition as to render the achievement a very doubtful triumph of conservative surgery.

M. Poincot has attempted to decide, by means of figures, in what proportions these very opposite results are to be hoped for or feared. "Out of seventy-eight cases of simple double dislocation collected by M. Broca, he finds that nineteen were reduced. M. Dubrueil, since the date of publication of Broca's statistics, counted five reductions out of twelve cases of double dislocation without any primary wound. Beginning in 1864, when Dubrueil's statistics were published, I have been able to collect thirty-one cases of simple double dislocation, in which attempts at reduction were made, and which furnished nineteen successes. Twenty-one of the latter cases were published elsewhere: in that number reduction had been effected twelve times; of the nine other patients, one had suffered immediate amputation, and the last eight had been submitted, at least at the beginning, to the expectant treatment." According to Broca, the attempt at reduction failed in 54 cases out of 63. Poincot narrates briefly other cases collected by himself, and which have been reported by Guéniot,² Busch,³ Iverson,⁴ Gore,⁵ Üthoff,⁶ Ward,⁷ Fairbank,⁸ Hird,⁹ Landerer,¹⁰ Lloyd,¹¹ and F. H. Hamil-

¹ Norris, George W., Amer. Journ. Med. Sci., 1837, p. 383.

² Guéniot, Gaz. des Hôp., 1872, No. 94.

³ Busch (Madelung), Berliner klin. Wochen., 1873, 7 u. 8.

⁴ Iverson, Nordiskt Med. Ark., 1876, Bd. viii. Hft. 3.

⁵ Gore, The Lancet, 1880, vol. i. p. 625.

⁶ Üthoff, The Lancet, 1880, vol. i. p. 701.

⁷ Ward, The Lancet, 1880, vol. i.

⁸ Fairbank, The Lancet, 1880, vol. i. p. 745.

⁹ Hird, The Lancet, 1878, vol. i. p. 311.

¹⁰ Landerer, Centralb. für Chir., 1881, p. 609.

¹¹ Lloyd, The Lancet, 1882, vol. ii. p. 353.

ton.¹ "Out of the eleven preceding cases, therefore," says Poinso, "reduction was successful eight times; in the other three cases, extirpation of the astragalus had to be performed at a varying period following the accident. The three patients operated upon recovered in good condition. By adding our statistics to those of Broca and M. Dubrueil we reach a total of 121 cases of reduction, with 43 successes, making an average of successes of 35.5 per cent. I will call attention to the fact that our personal statistics, which are more recent than the two others, furnish an average of successes not below 61.2 per cent.

"In the fortunate cases, three times (cases of Crosse, Bryant, Moore) the reduction could not be accomplished until after the tendo Achillis had been divided; such was the case with Cock's patient, mentioned by Dubrueil. In two of the cases where reduction could not be effected, the surgeons (Busk, Cheevers) had not only divided the tendo Achillis, but also the tibialis posticus, the extensors of the toes, and the extensor proprius pollicis. Pichorel, of Havre, was not more successful, but he had only divided the tendo Achillis. Broca has reported four additional cases of tenotomy, taken from Chaussier, Despaulx, Solly, and from the clinic at Marseilles: reduction was only obtained twice. I will also state Shaw's case, recalled by Dubrueil, and in which the division of the tendon of the flexor longus did not effect the reduction. After all, tenotomy, practised in twelve cases, effected the reduction six times, thus giving an average of 50 per cent., which exceeds by 15.6 per cent. that furnished where attempts at simple reduction were made. With such results, one may be allowed to wonder why tenotomy is not resorted to more frequently in cases of irreducible dislocations.

"It is especially in the dislocations backward that failures at reduction have been most frequent: in twenty cases which we have been able to collect, reduction was effected only four times. The first one of those cases was reported by Malgaigne, without any author's name: the only indication as to its origin states that it was observed in 1839, in one of the hospitals of London; the displacement, which had occurred inward and backward, was reduced in ten minutes, by means of strong extension combined with lateral pressure. Erichsen, although insisting upon the extreme difficulties that are met with in the dislocations backward, declares that the surgeons of the University Hospital of London recently succeeded in a case which was complicated with a fracture of both bones of the leg. Erichsen advises the subcutaneous section of the tendo Achillis in cases where the ordinary procedures have failed. The third case was published in detail by Dr. Blatin, of Clermont-Ferrand: A man 50 years of age, robust and muscular, falling into a cellar from a height of several feet, dislocated the astragalus directly backward: the displacement was incomplete as to its relations with the articular ends of the tibia and fibula, complete as to its relations with the scaphoid and both articulations of the calcaneum. M. Blatin, in order to obtain the reduction, resorted to the following procedure: 'I made vigorous traction upon the calcaneum, in order to disengage that bone from the groove of the astragalus and so as to obtain sufficient room for the return of the astragalus. Then I extended the foot strongly upon the leg, in such manner as to disengage the hollow of the articulation of the calcaneum with the astragalus, and so as to use the posterior and superior portion of the calcaneum as a means of pushing the astragalus forward. . . . After the second attempt, the astragalus had resumed its normal position.' Finally, in 1875, Dr. Morgan stated, at the Pathological Society of London, that he had recently seen a case of dislocation of the astragalus backward, without fracture, where the reduction was easily effected.

"In eight cases out of fifteen, the results of which are known to us, failure at reduction did not deprive the limb of more or less usefulness. Lizars states that he saw a case of dislocation backward where, although all attempts at reduction had failed, the limb was saved, and afterward the patient could use it pretty well. Such was the result in a case in Mr. Liston's practice. Phillips has published two cases of dislocation backward which had resisted all efforts: the two patients walked easily, notwithstanding the persisting displacement; one of them wore a shoe cut behind in order to avoid pressure upon the projecting

¹ Hamilton, 5th ed. of this treatise, 1880, p. 774.

astragalus. A patient of Cheevers, to whom I have already alluded when speaking of tendinous sections, recovered notwithstanding the gangrene of the skin on a level with the astragalus; five months after, he walked pretty easily with a cane. In the two other cases, the dislocation had not been recognized in the beginning, and had been mistaken for a fracture; one of them has been reported by the author of this treatise.

"Dr. MacCormac, in 1875, presented to the Pathological Society of London a specimen of dislocation of the astragalus taken from a subject who had had the leg amputated for a chronic affection of the knee. The dislocation dated back two years, and had been treated for a fracture. The deformity was very slightly marked, and the patient walked easily with the aid of a cane. He could climb a ladder and walk on the scaffoldings. At the dissection, the head of the astragalus was found in place, but the body of the bone was displaced backward and adhered to the tendo Achillis; the other tendons passed on the sides of the dislocated portion of the bone. At the same meeting, Dr. MacCormac recalled a similar fact of Mr. Legros Clark, which dated back to 1863: the patient when seen again recently (1875), twelve years after, walked very well with his unreduced dislocation.

"But, in a certain number of cases, the expectant treatment resulted in gangrene of the skin over the projecting astragalus, and extraction of the bone had to be resorted to. Such was the measure adopted in two cases by Foucher, Buchanan, and Williams, of Dublin. In each case the operation was followed by success. In a patient of M. Pichorel, of Havre, two attempts at reduction and section of the tendo Achillis were followed by a purulent arthritis which required amputation. Immediate extraction of the astragalus, in dislocations backward, has only been practised twice, by Hulme, of Dunedin, and by Turner; the latter case being a compound dislocation. In both cases, the results of the operation were sufficiently satisfactory. The expectant plan of treatment, which has been relatively fortunate in dislocations backward, has only been followed by deplorable results in other displacements of the astragalus. Out of seventeen cases, I count only two successes; and out of the fifteen failures, there was one death by gangrene, nine consecutive extractions, and one amputation.

"The two successes belong to Dupuytren and Dr. Barton, of Philadelphia. I take from M. Dubreuil the very brief history of the first one of these cases: 'In a simple and complete dislocation outward, observed by Dupuytren, the bone could not be replaced: there occurred a superficial eschar which did not communicate with the articulation, and two months after the accident, the patient could use the limb very well.'

"In a patient of Dauvé, suffering with a dislocation of the astragalus forward and outward, with rotation on its antero-posterior axis, the pressure upon the integuments produced gangrene, and the exposed astragalus became necrosed. The result is not known to us, but the case may already be considered as one of the failures by the expectant plan. Two patients of Guthrie, in whom a similar displacement could not be reduced, could not possibly use their feet. A soldier, seen by Sir Wm. Fergusson, and who had a dislocation of the astragalus dating several years back, could only walk with the aid of a cane, and applied only the tip of the foot to the ground.

"Dr. Wilson, of Manchester, has reported a case of dislocation outward of two years' standing. The right foot turned strongly inward, it rested on the ground with its external border, the point d'appui being represented by the external borders of the calcaneum and of the fifth metatarsal bone. The patient could not use the foot. There existed at the external side of the dorsal aspect a voluminous projection; the integuments, at that point, would get inflamed on the slightest fatigue, and had ulcerated on several occasions. Wilson amputated the leg, and the patient recovered.

"The cases of secondary extraction have given one death, which occurred in the practice of Dr. Smith, of Leeds. A tall and robust gentleman dislocated the astragalus while jumping out of a carriage, on May 14, 1864. The skin sloughed, the bone became loose, and Mr. Smith extirpated it on the 14th of June. One month after, the patient died with eschars on the sacrum. The same surgeon scores three recoveries out of three operations which he performed, the patients

being able to use their limbs perfectly. An equally good result was obtained in the cases of Busk, Cruveilhier, Lallemand, Loewer, and Shillitoë.

"The dangers of the expectant method [except perhaps in the backward dislocation—H.] and the almost absolute necessity of resorting subsequently to extraction of the astragalus, have suggested to a certain number of surgeons the immediate performance of that operation. Such was the procedure which I adopted in a case mentioned above, in the chapter on Fractures of the Astragalus; I will recall the fact that the patient died after having undergone amputation of the thigh; the extirpation was incomplete, as I had left in place the head of the bone which had maintained its relations with the scaphoid."¹

George W. Norris, of Philadelphia, relates the following case, illustrating the imminent danger to which even the life of the patient may be exposed in those examples which are apparently the most simple: W. S., æt. 30, was admitted to the Pennsylvania Hospital on the 26th of September, 1831. An hour previous, while descending a ladder, he slipped and fell in such a manner as to throw the entire weight of his body upon the outer part of his left foot. The foot was turned inward, and nearly immovable; a slight depression existed immediately below the lower end of the tibia, and there was a hard rounded projection on the outer part of the foot, a little below and in front of the extremity of the fibula; the skin over this projection was not broken or excoriated, but reddened; there was no fracture of either bone of the leg. The symptoms rendered it plain that the astragalus was dislocated forward and outward. Dr. Barton, under whose care the patient was received, proceeded soon after to make attempts at reduction. The muscles of the leg were relaxed as much as possible, and extension made from the foot by seizing the heel and front part of the foot while an assistant made counter-extension at the knee. The bone was also pushed inward toward the joint by the surgeon. These efforts were continued for a considerable time, but had no effect in changing the position of the bone. Six hours afterward, Drs. Harris and Hewson being in consultation, the attempt was again made to accomplish the reduction, but without success; and the surgeons immediately proceeded to excise the bone. An incision was made parallel with the tendons, commencing a short distance above the projection, and extending down far enough to expose fairly the astragalus and its torn ligaments. The bone was then seized with the forceps and easily removed after the division of a few ligamentous fibres that continued to connect it with the adjoining parts. Very little bleeding occurred, only two small arteries requiring the ligature. After removal, it was discovered that about one-half of the surface which plays in the lower end of the tibia had been fractured, and that it remained firmly attached to the extremity of that bone. No attempt was made to remove this fragment, but, the joint being carefully sponged out, the sides of the wound were brought together and closed by sutures, adhesive straps, and a roller; after which the foot, placed in its natural position, was laid in a fracture-box. On the fifth day a slough began to form upon the outside of the foot, which was followed by suppuration at other points, and on the thirteenth day an opening was made to evacuate the pus near the malleolus internus. At the end of about eight weeks the fragment of the astragalus which had been suffered to remain was found to be carious, and it was removed; the heel also had ulcerated from pressure, and several other bones of the tarsus were discovered to be carious. Fifteen months later, this poor fellow was still in the hospital, suffering from hectic, with extensive disease in the bones of the tarsus and ankle-joint. Finally, amputation of the leg was practised by Dr. Barton, a few days after which the patient died.²

Norris mentions also two examples of simple dislocation of the astragalus at the Pennsylvania Hospital which came under the observation of Dr. Barton, in both of which the bone was left unreduced. In one case inflammation and sloughing soon effected a complete exposure of the protruding bone, but after a time the skin cicatrized. At the end of five months the patient walked and had good use of the joint, though great deformity of the foot existed, and he continued to be subject to ulceration of the newly formed skin on its outer part. In the other case gangrene supervened soon after the accident, and the patient

¹ Poinso, French ed. of this treatise, p. 1182 et seq.

² Norris, George W., Amer. Journ. Med. Sci., Aug. 1837, p. 378.

died. Norris adds that "the late Professor Wistar removed the astragalus in a case of compound dislocation, and the patient was cured with some motion at the joint." Dr. Alexander Stevens, of New York, made the same operation in a case of compound dislocation, and, after several months, he affirms that the patient "has recovered with very trifling deformity of the foot, and with a flexible joint. He walks with very slight lameness."¹

I am indebted to Dr. B. H. Hart, of Marietta, Ohio, for an account of the following case, and for the specimen: In June, 1853, T. W. was thrown from his carriage, alighting upon his left foot and causing a compound dislocation of the ankle-joint. Dr. Hart was immediately called, and found the bones of the leg thrust through the integuments on the outside, the malleolus internus broken, and the astragalus partially dislocated. After enlarging the opening in the integuments with a pocket-knife, the doctor was able to reduce the dislocated bones. It must be mentioned that this man weighed 225 pounds, and that in his fall he descended a precipice or bank thirty feet in height. Extensive supuration throughout the joint resulted, and some fragments of the bone came away; and on the thirty-third day Dr. Hart removed, without the aid of the knife, the entire astragalus. In three months the patient walked upon crutches, and in eleven months he could walk well without a staff, a slight motion having been preserved in the ankle-joint.

The dislocations backward, of which we have found recorded only twenty examples, have all, with but four exceptions, been left unreduced; yet in several instances the patients have recovered with pretty useful limbs. Such was the fact with Liston's, Lizars', and my own patients, and also with Mr. Phillips's two cases, to all of which I shall again refer. It must be noticed, however, that, in each of the cases mentioned as followed by a successful termination without reduction, the dislocations were simple.

Turner, of Manchester, has reported one example of compound dislocation outward and backward, in which, finding himself unable to effect reduction, he removed the astragalus, with a tolerably successful result.² Finally, a case was presented in one of the London hospitals in 1839, of a dislocation inward and backward, which was reduced in about ten minutes, by extension accompanied with lateral pressure.³

In September, 1870, I saw, with Dr. Sayre, in consultation, a subluxation of the astragalus forward and outward, in the person of Mr. Stewart, of this city, which had just occurred in consequence of an injury received in being thrown from a carriage. The dislocation seemed to be nearly but not quite complete, causing great projection and tension of the skin. Under the influence of chloroform, by extension and pressure, it was easily reduced by Dr. Sayre. In five weeks from this time he was able to walk, and soon after the restoration of the functions of the joint was complete.

Basil Norris, Surgeon U. S. A., in a paper read before the American Surgical Association in 1883, reports a case of dislocation of the astragalus forward and outward, caused by being thrown from a carriage, and alighting upon his foot. In less than an hour after the accident, under the influence of ether, it was reduced by Drs. Lincoln and Ashford, of Washington. The method employed was to draw the foot forcibly downward, while it was at the same time rotated outward. The first attempt was unsuccessful; but in the second, the extension being aided by direct pressure, the bone was at first partially restored to its position; the restoration being finally completed by continued extension, and by direct pressure upon the neck of the astragalus. No grave inflammatory accident ensued. The same paper contains communications from several surgeons reporting similar

¹ Stevens, *North Amer. Med. and Surg. Journ.*, Jan. 1827, p. 200.

² Turner, *Trans. Provin. Med. and Surg. Journ.*, vol. ix. *Essay on Dislocations of Astragalus*, with nearly fifty cases. For additional cases, see *Med. and Surg. Reporter*, Jan. 1867.

³ *London Lancet*, vol. ii. p. 559.

cases; only one of which, that of Dr. John Brinton, of Philadelphia,¹ had been previously reported.

In Dr. Brinton's case the astragalus was dislocated forward and inward, and the fibula was broken, but the integuments were not torn. Several ineffectual attempts at reduction were made on the same day by Drs. Brinton and Moss. A severe inflammation ensued, with other alarming symptoms, and on the fourteenth day Dr. Brinton practised excision. A portion of the os calcis subsequently became carious, and was removed, and he finally recovered with a tolerably useful limb.

A communication from Dr. J. W. S. Gouley, contained in the same paper, gives an account of a case of simple dislocation forward and outward which he had reduced. Reference is made also to other cases seen by Drs. Gouley, Vollum, and Agnew, but not with sufficient precision to render their repetition in this place useful.

Treatment.—Various attempts have been made by surgical writers to determine the line of treatment which should be adopted in these unfortunate cases, but with very unsatisfactory results, since they are far from having arrived at similar conclusions, nor have they been able always to settle the question definitely for themselves. The difficulty consists in the multiplicity and lack of uniformity in the complications which attend these accidents, rendering it impossible to establish a classification upon which a uniform treatment may be safely based. There are certain principles, however, which seem to be sufficiently settled to allow of an authoritative announcement; these may be briefly stated as follows: If the dislocation is simple, reduce the astragalus immediately, provided this is possible. If the dislocation is complete, and it cannot be reduced, even partially, except in cases of dislocation backward, proceed at once to resection or to amputation. In compound dislocations, resection or amputation affords the only safe resource. In all cases the inflammation is likely to be intense, in order to prevent which complication the surgeon must be unremitting in his use of the appropriate remedies.

The several indications and rules of treatment above enumerated I shall proceed to illustrate a little more fully. In a recent simple dislocation of the astragalus forward, the leg should be flexed to a right angle with the thigh, and, for the purpose of making extension, one assistant should take hold of the foot in both hands in the same manner that a servant draws a boot—that is, with the right hand grasping the heel, and the left placed upon the dorsum of the foot, near the toes. A second assistant should seize the lower part of the thigh, in order to make counter-extension, while the surgeon presses with the ball of his hand against the head of the astragalus, upward and backward. If these simple measures fail, the pulleys ought to be employed as a substitute for the hands in making extension. In applying the extension, the toes must be kept well down, and occasionally the foot should be moved gently from one side to the other.

An oblique dislocation must be reduced, if possible, to an anterior dislocation, before an attempt is made to carry the head of the bone back to its place, as by this mode the reduction will be greatly facilitated.

Lateral dislocations may be reduced by the same means; but if the astragalus is dislocated outward, the foot must be held forcibly adducted

¹ Brinton, *Photographic Rev.*, No. 2, Dec. 1870.

during the extension; and if it is dislocated inward, the foot may be held strongly in the opposite direction.

Lizars says that he has seen one case of backward dislocation, and that all attempts at reduction were unavailing. The limb was, however, preserved, and proved to be useful.¹ Liston was equally unsuccessful in a case which came under his notice.² Phillips has reported two cases, in neither of which was the reduction accomplished.³ Nélaton has seen a compound dislocation which he could not reduce.⁴ Mr. Erichsen, however, who believed that when dislocated backward it had not hitherto been reduced, declares that the surgeons at University Hospital have succeeded in one case recently, in which both the tibia and fibula were broken also.⁵ Mr. Erichsen suggests also that, in case of a failure by the ordinary means, we should resort to a subcutaneous section of the tendo Achillis. Mr. Williams, of Dublin, in a similar case, which had been left unreduced, was obliged finally to extract the bone, in consequence of the integuments having sloughed.⁶

In February, 1875, Mr. J. N. Hall, of Colorado, æt. 38, consulted me in reference to an injury to his foot sustained two years before. The foot had been caught between a couple of timbers and violently twisted inward. The nature of the accident was not at first recognized. I found the astragalus displaced backward as far as the posterior extremity of the calcaneum, causing the tendo-Achillis to curve backward; the astragalus was especially prominent on the inner side, posteriorly. The foot was at a right angle with the leg, and shortened in front three-eighths of an inch. The leg was shortened five-eighths of an inch. The foot was at times painful and numb. He walked very well with the aid of a cane. Of course, no surgical interference could be recommended.

Compound dislocations, and such as are otherwise complicated, demand of the surgeon immediate amputation or exsection, the latter of which ought to be preferred whenever the condition of the limb encourages a reasonable hope that the foot may be saved.

Dr. Grant, of Canada, has reported a case of success after reduction of a compound dislocation of this bone. The man was 35 years old, and in good health. Immediately after the accident the astragalus was found completely dislocated forward, and lying with its long axis placed transversely, so that the anterior extremity protruded through the integuments one inch on the outer side of the foot. There was no fracture. The first attempt at reduction, by extension and pressure failed; but in the second attempt moderate pressure, without extension, was successful. Suppuration ensued, and continued two months. At the end of eight months he walked without a cane; and at the date of the report the ankle was in all respects perfect.⁷

"In the dislocation by rotation, or renversement," says M. E. Delorme, "if the bone has been rotated upon its antero-posterior axis to the extent of 90 degrees, thus having brought its trochlear surface inward or outward, it is necessary, in order to effect reduction, that while pulling on the foot, the bone should be tilted, outward in inward dislocation, and inward in the external variety, which is done by pressing upon the margin of the facet which has become superior. In a case of dislocation by renversement, the surgeon must try first, by a tilting motion, to convert that

¹ Lizars, *System of Practical Surg.*, Edinburgh ed., 1847, p. 161.

² Liston, *Elements of Surgery*, vol. iii. p. 348.

³ Phillips, *Lond. Med. Gaz.*, vol. xiv. p. 596.

⁴ Nélaton, *Pathologie Chirurg.*, t. ii. p. 482.

⁵ Erichsen, *Science and Art. of Surg.*, Amer. ed., 1859, p. 270.

⁶ Williams, Erichsen, *op. cit.*, p. 271.

⁷ Grant, *Canada Med. Journ.*, Oct. 1866.

rotation of 180 degrees into one of 90; and then to press again upon one of the margins of the bone, in order to transform the displacement into an ordinary dislocation inward or outward."

When exsection is practised, and the bone is found to be broken, as it often is, all the fragments should be carefully removed, since they are certain to become necrosed if left in place. Nor ought the surgeon to hesitate to lay open freely the tissues in every direction, in order that he may accomplish this purpose; even the tendons lying over the protruding bone may be sacrificed unhesitatingly, since, after having been so severely bruised, stretched, and lacerated, they are pretty certain to slough. Indeed, the more freely the tissues are divided over the bone, the less will be the danger of inflammation, and the safer will be the life and limb of the patient.

The following case, reported by Dr. W. A. Gillespie, of Ellisville, Va., will illustrate the occasional value of exsection in compound dislocations: Mrs. A., aged about 50 years, fell from a horse on the 23d of May, 1833, dislocating both ankles. The dislocation of the right foot was accompanied with a dislocation of the astragalus outward, which projected through a very large wound in the integuments, and its trochlea was placed at an angle of about 45° with its natural position. Early on the following day it was removed by severing its few remaining connections, and the wound was immediately closed by stitches, adhesive plasters, and light dressings. From the moment of the receipt of the injury, and for several days afterward, she suffered excruciating pain in the limb, and on the third day tetanus was apprehended, but its full accession was prevented by the free use of opiates. The limb was suspended in N. R. Smith's fracture-apparatus; and as gangrene with hectic fever soon threatened the life of the patient, fermenting poultices were diligently applied, and the patient was sustained by wine, bark, and other tonics. Two months after the injury was received, the date at which the report is given, the wound had entirely healed, and her complete recovery was regarded as certain.¹

§ 2. Astragalo-calcaneo-scaphoid Dislocations.

It is perhaps quite as common for the astragalus to be dislocated from the scaphoid bone and calcaneum, while it retains its connections with the tibia, as to be dislocated from all these bones at the same time. This astragalo-calcaneo-scaphoid dislocation is that which Malgaigne has termed "subastragaloid." Produced by the same causes which determine true dislocations of the astragalus, it may occur in the same directions, and is liable to the same complications; nor will either the prognosis or treatment differ essentially from that which is recognized and established in the other accident.

As in dislocations proper of the astragalus, so also in this accident, opposite results have occasionally followed from similar modes of treatment. Dr. Detmold, of New York, stated in 1856 to the New York Academy of Medicine, that he had recently met with a dislocation of the astragalus in which the bone had retained its proper relations with the tibia, but not with the bones of the tarsus. The patient had fallen from a wagon and caught his foot in the wheel. Dr. Detmold made extension with pulleys, but could not effect the reduction. Subsequently he was obliged to remove the astragalus on account of the suppuration which followed and the consequent exposure of the bone. The wound did not

¹ Gillespie, Amer. Journ. Med. Sci., Aug. 1833, p. 552.

heal kindly, and at length amputation of the leg became necessary. Dr. Detmold concludes, from this example and others which have come to his knowledge, that if a similar case were to present itself to him again, he would amputate at once.¹

The following case, reported by Dr. Thomas Wells, of Columbia, S. C., is of unusual interest, as illustrating the danger of leaving the bone displaced, and also the benefit which may, even under the most unfavorable circumstances, result from its final removal: Dr. S., æt. 30, was riding in an open carriage, some time during the year 1819, when his horses became frightened and ran, and in leaping from his vehicle he struck upon his left foot, dislocating the astragalus from its junction with the scaphoid bone, upward and slightly outward. Several medical gentlemen made violent efforts to reduce the bone, but without effect. Inflammation and suppuration, accompanied by a high fever, soon followed, and the head of the astragalus, becoming carious, protruded through the skin. On the 18th of August, about seven months after the injury was received, he was still suffering from a copious discharge, pain, swelling, and general irritative fever, and it was determined to excise the bone, which was accordingly done by enlarging the wound and detaching its loose connections with the adjacent tissues. The astragalus extracted left a frightful wound, the foot seeming to be nearly separated from the leg. A hollow splint was adjusted to the inside of the foot and leg, so as to preserve the limb perfectly steady and in a proper direction; simple dressings were applied, and an anodyne administered internally. No accidents followed, and at the end of September the wound was healed, and the swelling of the parts had entirely subsided. One year after the operation he walked without the least difficulty, the ankle being then perfectly sound. The leg was shortened about one inch, and this deficiency was supplied by a thick heel upon his shoe.²

Examples might be cited illustrative of the value of early exsection where reduction could not be accomplished; but, after what has already been said upon the subject of dislocations of the astragalus, I shall not regard any farther reference as either necessary or useful.

If other principles of treatment are to govern the surgeon than those which I have already laid down they cannot here be stated. They are among those unwritten rules whose existence we cannot always recognize until the case arises to which they may apply. Yet, in the exigency supposed, they are as clearly defined, and as imperative, in the mind of the clever surgeon, as any of those laws which have been made the subjects of special record.

§ 3. Dislocations of the Calcaneum.

The calcaneum may, as a consequence of a fall upon the heel or of a direct blow, be dislocated outward from the astragalus alone or upward and outward from the cuboid bone at the same time. It has been found, also, according to Canton, at the same moment dislocated outward from the astragalus and inward upon the cuboid bone.

Chelius says he has seen an old dislocation of the calcaneum, produced in early life by pulling off a boot, from which there finally resulted a degeneration like elephantiasis of the leg, rendering amputation necessary.³

Of the two cases of dislocation outward of this bone mentioned by Sir Astley Cooper, the first, that of Martin Bentley, was occasioned by the falling of a heavy stone upon his foot; the integuments were not broken, and the position

¹ Detmold, New York Journ. Med., May, 1856, p. 383.

² Wells, Amer. Journ. Med. Sci., May, 1832, p. 21.

³ Chelius, System of Surg., Amer. ed., vol. ii. p. 354.

of the foot resembled a varus. "The dislocation was easily reduced, having bent the thigh and knee on the body and fixed the leg, by laying hold of the metatarsus and of the tuberosity of the heel-bone, and drawing the foot gently and directly from the leg, during which extension Cline put his knee against the outside of the joint, and the foot being pressed against it, the heel and the navicular bone readily slipped into their place, and the deformity disappeared." He was discharged from the hospital in five weeks, "having the complete use of his foot." In the second case, the dislocation, produced also by the fall of a stone upon the foot, was compound, and the patient, Thomas G., having been brought into St. Thomas's Hospital, the reduction was effected by extending the foot and rotating it outward. Six months after, when he left the hospital he was able to walk pretty well with a stick.

A. Dumas¹ relates an example of this dislocation outward caused by a piece of wood falling upon the internal side of the leg and foot. Jourdan, of Marseilles, in whose service the case was presented, reduced it easily by extension downward and outward combined with direct pressure. In another case reported by Dumas a man had been struck upon the posterior and external part of the heel and imprisoned by an anchor, in which condition of the limb the body was thrown to the left. Jourdan reduced the dislocation easily, as in the preceding case. At the end of a month the cure was complete. Dr. Edwin Canton² found in the dissecting-room of the Charing-Cross Hospital what he regarded as a traumatic dislocation outward upon the astragalus and inward upon the cuboid. Malgaigne and Poincot have accepted Canton's view of the case, but Polaillon could interpret it only as a pathological displacement. Hancock³ describes a specimen taken from an old man who had received his injury two years before death, causing a dislocation outward, which had not been reduced. Dissection showed that the calcaneum was slightly separated from the cuboid and more extensively from the astragalus, whose position in the articulation was completely changed. The astragalus, tibia, fibula, and calcaneum were ankylosed by bony callus.

§ 4. Middle Tarsal Dislocations.

The scaphoid and cuboid bones may be dislocated from the astragalus and calcaneum, constituting what is termed, by Malgaigne, a "middle tarsal" dislocation. It is probable that, to some extent, the same thing has occurred in many of those cases which are reported as simple dislocations of the astragalus or as dislocations at the astragalo-scaphoid articulation; but it occurs also occasionally in a degree so perfect and complete as to leave no doubt as to the true nature of the disjunction, and to entitle it to a separate consideration.

Mr. Liston mentions the case of a boy, æt. 14, who fell from a height of forty feet, striking, apparently, upon the extremity of the foot. The scaphoid and cuboid bones were found displaced upward and forward, so that the foot was shortened about half an inch and had a clubbed appearance. No attempt was made to reduce the bones, and he left the hospital in three weeks, able to stand on the foot.⁴

Sir Astley Cooper has recorded in more detail a similar example: A man received upon the top of his foot a stone of great weight. He was immediately carried to Guy's Hospital, and his condition is described as follows: "The os calcis and the astragalus remained in their natural situations, but the forepart of the foot was turned inward upon the bones. When examined by the students, the appearance was so precisely like that of a club-foot that they could not at

¹ A. Dumas, *Bull. Thérap.*, 1854, t. xlv. p. 550.

² E. Canton, *The Lancet*, 1847, vol. i. p. 506.

³ Hancock, *Anat. and Surg. Human Foot*, London, 1873, p. 216.

⁴ *Practical Surgery*; also *London Lancet*, vol. xxxvii. p. 133.

first believe but that it was a natural defect of that kind;" but, upon the assurance of the man that previous to the accident his foot was not distorted, extension was made, and the reduction was effected. He was discharged from the hospital in five weeks, having the complete use of his foot.¹

E. Delorme² mentions two cases observed by Thomas and Anger, respectively. In Thomas's case the foot had been traversed by the wheel of a wagon. Reduction could not be effected, and the patient died. The autopsy disclosed a displacement upward of the astragalus and calcaneum upon the second row of the tarsal bones. The scaphoid was broken, and one of its fragments protruded at the sole of the foot. The cuboid was only partially dislocated from the calcaneum. In Anger's case a man had fallen from a height, and the arch of the foot appeared a little flattened, but the displacement of the bones could not be made out. The patient having died of erysipelas, the autopsy revealed a complete dislocation of the astragalus and calcaneum forward upon the second row of the tarsal bones. The tubercle at the anterior portion of the scaphoid was almost completely torn away. Even after dissection it was found difficult to reduce the bones.

§ 5. Dislocations of the Cuboid Bone.

According to Piédagnel, quoted by Chelius, the cuboid bone may be dislocated upward, inward, and downward, but Malgaigne affirms that he has found no case recorded in which the dislocation has occurred alone, or unaccompanied with a dislocation of one or more of the other tarsal bones.

§ 6. Dislocations of the Scaphoid Bone.

Several examples are recorded of a true dislocation of the *os scaphoides*, in which the bone had abandoned both the astragalus on the one hand, and the cuneiform bones on the other.

Burnett has seen a dislocation of the scaphoid bone in which its connections with the astragalus were undisturbed, while at the same time it was completely separated from the cuneiform bones. By strong pressure exercised during several minutes, the *os scaphoides* was made to fall into its place. The dislocation was compound, yet the wound healed rapidly, and in a short time the recovery was almost complete.³

Rizzoli⁴ also reports an example of simultaneous dislocation of the astragalus and scaphoid in a direction "inward, upward, and forward," the injury being caused by jumping from a carriage. Rizzoli succeeded in effecting reduction with the aid of three assistants, by making counter-extension from the knee, the leg being in a position of semiflexion, while direct pressure was made upon the projecting scaphoid; Rizzoli himself seized the toes and the heel with his two hands, and made traction, bringing at the same moment the foot upward.

Garland,⁵ of Liverpool, saw a child, *æt.* 4, with a compound dislocation of the scaphoid forward, caused by a direct blow upon the top of the foot. The scaphoid was completely separated from the cuneiform bones. The reduction was effected not without much difficulty. When the child left the hospital there still remained some deformity, the foot being a little turned outward; and the arch of the tarsus being somewhat flattened.

Piédagnel mentions a case in which the scaphoid bone was broken longitudinally, and its internal fragment, constituting the largest portion, was displaced inward

¹ Sir A. Cooper on Disloc., etc., London ed., 1823, p. 376.

² Delorme, Thomas, and Anger. Poincot, *op. cit.*, p. 1210.

³ Burnett, Lond. Med. Gazette, 1837, vol. xix. p. 221.

⁴ Rizzoli, Clin. Chir. trad par Andreini, Paris, 1872, p. 146.

⁵ Garland, Anat. and Surg. of Human Foot, London, 1873, p. 234.

through a tegumentary wound. He was unable to effect reduction, and was compelled to amputate the foot.¹

Walker has reported an example of dislocation forward, occasioned by jumping upon the ball of the foot. The bone formed a marked projection upon the top of the foot, and a corresponding depression existed below. An attempt was first made to accomplish the reduction by simple pressure with the thumbs; but this having failed, the surgeon bent the extremity of the foot forcibly downward, and continuing to press upon the scaphoid, it fell into its position easily and with a distinct click. In about three weeks the patient was able to walk with only a slight halt, and no deformity remained.²

Robert W. Smith³ has also reported a case of ancient dislocation of the scaphoid upward, in a man who several years before had fallen from a horse, the foot being caught in the stirrup under the animal. The bone projected in front of the head of the astragalus: the sole of the foot was very much flattened, but walking was not at all interfered with.

§ 7. Dislocations of the Cuneiform Bones.

The cuneiform bones may be dislocated without having separated from each other, of which two or three examples are recorded, or, which is more common, the internal cuneiform may be dislocated alone. Sir Astley Cooper has twice seen this bone dislocated: once in a gentleman who called upon him some weeks after the accident, and a second time in a case which occurred in Guy's Hospital. In both instances the same appearances presented themselves. There was a great projection of the bone inward, and some degree of elevation, from its being drawn up by the action of the tibialis anticus muscle; and it no longer remained in a direct line with the metatarsal bone of the great toe. In neither case was the bone reduced. The subject of the first of these accidents walked with but little halting, and he believed would in time recover the use of the foot, so as not to appear lame. The cause of the accident was a fall from a considerable height, by which the ligament was ruptured which connects this bone with the os cuneiform, and with the os naviculare. The second case, which was in Guy's Hospital, happened by the fall of a horse, and the foot was caught between the horse and the curbstone.⁴

Villars⁵ met with an example of dislocation of the cuneiform internum upward and inward, which he reduced by extension, abduction, and pressure on the second day; at the end of two months the patient could walk easily. In a case reported by Meynier⁶ the dislocation of this bone was thought to be due to muscular contraction alone. The reduction was easily effected. Fitz-Gibbon⁷ reports a case of dislocation of the internal cuneiform downward and inward, from a direct blow. Reduction was easily accomplished by extension and direct pressure, and recovery took place without accident. Lemoine⁸ met with a similar case in which reduction attempted on the nineteenth day was found impossible. Four months after the accident the patient was able to walk, but not without fatigue. In a case of compound dislocation seen by Mr. Key, reduction was effected, and in two months the cure was so far completed that the patient

¹ Piédagnel, Journ. Univ. et Heb., tom. ii. p. 208.

² Walker, The Medical Examiner, 1851, p. 203.

³ R. W. Smith, Dublin Hosp. Gaz., 1855, vol. ii. p. 76.

⁴ Sir Astley Cooper, op. cit., p. 383.

⁵ Villars, Poulet, Gaz. Méd. de Paris, 1851, p. 757.

⁶ Meynier, Gaz. Méd. de Paris, 1851, p. 520.

⁷ Fitz-Gibbon, Dublin Journ. Med. Sci., 1877, vol. lxiv. p. 271.

⁸ Lemoine, Rev. Mens. de Chir., 1883, No. 2, 121.

walked with only a slight lameness.¹ Nélaton, in a similar case of compound dislocation, unable to reduce the bone, removed it completely, and the patient recovered.²

A dislocation of the sound cuneiform has been observed by Wm. H. Folker³ and by B. Anger.⁴ In Folker's case reduction was easily effected. In the case reported by Anger the dislocation was incomplete, not protruding more than one centimetre, but it could not be reduced.

Robert Smith has called attention to a species of dislocation of the internal cuneiform bone not before very accurately described; but of which he has presented two examples. It consists in simultaneous dislocation of the metatarsal and internal cuneiform—that is to say, the first metatarsal bone, together with the internal cuneiform, is dislocated upward and backward upon the tarsus, carrying with it also the four remaining metatarsal bones. In both of the examples seen and recorded by him the dislocations were ancient, and no account could be obtained of the precise manner in which the accidents had been produced. The feet were foreshortened to the extent of an inch or more in consequence of the overlapping of the bones, yet the heel in each case preserved its natural relations to the tibia, not being proportionally lengthened as is the case in dislocations of the tibia forward. The plantar surface of the foot was turned inward, and instead of being concave it was convex, both in its antero-posterior and transverse diameters. A transverse ridge on the top of the foot also indicated the line of the projecting bones. Both of these cases were verified by a careful dissection.⁵

Dupuytren has reported a similar case, occurring in a woman, æt. 39, who was brought immediately to Hôtel Dieu. She stated that in descending from the bridge of St. Michael, with a burden of two hundred pounds, she fell in such a way that the whole weight of the body was received on the right foot, and that, at the moment she made an effort to check herself in falling, she experienced severe pain in this part, and heard a very distinct snap; she was unable to raise herself from the ground. On the following morning Dupuytren reduced the bones with very little difficulty by extension, combined with pressure against the dislocated ends. The bones went into place with a loud snap, and in two or three months she left the hospital, with only a little lameness.⁶ Bryant has seen two cases of simultaneous displacement of the cuneiform internum and the corresponding metatarsal bone.

Mr. Smith, without intending to question the possibility of a simple dislocation of the metatarsal bones, of which, indeed, Malgaigne has collected a number of well-authenticated examples, is inclined to believe that, when a dislocation of the bones of the metatarsus is the consequence of a fall from a height, the individual alighting upon the anterior part of the foot, it is, in general, that variety which has now been described. And this aptness on the part of the cuneiform bone to maintain its connection with the first metatarsal bone, he would ascribe mainly to the fact that both the peroneus longus and tibialis anticus have attachments to each of the bones in question.

¹ Key, *Guy's Hosp. Rep.*, 1836, vol. i. p. 544.

² Nélaton, *Malgaigne*, op. cit., p. 1076.

³ Folker, *The Lancet*, 1856, vol. ii. p. 283.

⁴ A. Anger, *Traité iconographique des Malad. Chir.*, Paris, 1865, p. 356.

⁵ Robert Smith, *Treatise on Fractures*, etc., Dublin ed., 1854, p. 224 et seq.

⁶ Dupuytren, op. cit., p. 326.

Dr. Bertherand, of Algiers,¹ in 1856 reported a case of simultaneous dislocation of all the cuneiform bones, without separation from the metatarsal bones, caused by a fall upon the sole of the foot. The dislocation was not reduced, and was only seen by Bertherand two years after the accident occurred. The foot was atrophied; the tarsal and metatarsal articulations were ankylosed, and he walked entirely on his heel.

CHAPTER XXIV.

DISLOCATIONS OF THE METATARSAL BONES.

DISLOCATIONS of one or more of the metatarsal bones, at the points of their articulations with the tarsus, have been known to occur in almost every direction. They may be occasioned by crushing accidents, or more often perhaps they have been caused by a fall backward or forward, when the anterior extremity of the foot was wedged under some solid body and immovably fixed. They may be produced, also, by alighting upon the ball of the foot when falling from a height.

Mr. Robert Smith inclines to the opinion that this will, in general, only produce the species of dislocation which he has particularly described, and to which reference has been made in the preceding chapter.

The symptoms which characterize the dislocation of the whole range of metatarsal bones upward and backward will, when the dislocation is complete, resemble very much those which belong to the dislocation described by Smith. The dorsum of the foot will be shortened antero-posteriorly, the two arches of the foot will be lost upon the plantar surface, or even actually reversed, a ridge will traverse the back of the foot and a corresponding depression will exist underneath. In some cases, however, the dislocation is not complete, the articulations being only sprung, and then there can exist no foreshortening of the foot, and all the other signs will be less striking.

The diagnosis is generally very easily made out, if only a single bone is dislocated, unless, indeed, considerable swelling has already occurred.

Treatment.—The cases cited illustrate the difficulty which surgeons have experienced in the reduction of these bones, when a portion only is displaced: a difficulty which is probably due to the fact that it is almost impossible to make extension upon a single metatarsal bone. We might expect more from forced dorsal flexion, as advised in the case of the phalanges, and which was successfully practised by Shaw. Direct pressure upon the displaced head cannot be expected to accomplish much in these accidents, owing to the small amount of surface presented against which the force can be properly applied. If, on the other hand, all the bones are dislocated at once, the reduction is generally accomplished with ease by simple extension, combined with properly-directed pressure.

¹ Bertherand, Bull. Soc. de Chir. de Paris, 1856-57, t. 7, p. 361.

Bouchard and Meynier succeeded without difficulty in two cases of backward dislocation; Smyley was equally successful on the sixth day, in a case of dislocation downward. Laugier reduced an outward dislocation of all the bones by pressure and extension easily; and Kirk succeeded as well, in an example of the opposite character, all the bones being carried inward.¹

Mr. Sandwith has given us an account of a case which occurred in his own person, from the fall of his horse upon his foot. "I was instantly sensible," says Mr. Sandwith, "of the nature of the injury, and as soon as I was upon my feet, the metatarsus was found to be drawn upward, and obliquely outward upon the tarsus, by the action of the flexor muscles. On the removal of the boot, which was cut away, these were the appearances: The foot considerably shortened, the toes turned a little outward, and a hard swelling, bigger than an egg, upon the tarsus, with tumefaction of the integuments. The pain, which was great at first, was kept under by a warm fomentation. The reduction was easily effected by my friends Messrs. Williams and Brereton, and leeches and bread-and-water poultices prevented inflammation. For several nights the foot was violently shaken by spasmodic action of the muscles, but the parts preserved their relative situation; and although it was nearly a year before all lameness ceased, yet at the end of six weeks I was enabled to lay aside my crutches. For the ability to use the foot in so short a time, I was indebted to a contrivance which rendered the foot and ankle inflexible. Instead of an elastic sole to the shoe part of the apparatus, one of wood was procured, around the heel of which was nailed a piece of firm, unbending leather; this reached as high as the calf of the leg; three small straps with buckles held the leg *in situ*, and a broader one across the instep secured the foot. The comfort I experienced from this simple apparatus is my reason for describing it so particularly; it has since been found useful in various injuries of the foot and ankle."²

In one extraordinary case, however, Dupuytren was not so successful. P. E., æt. 24, fell, while drunk, into a ditch six feet deep, and alighted on the soles of his feet. The accident was followed by great swelling, and he did not suspect the nature of the injury, nor present himself at the hospital until three weeks after. Dupuytren then ascertained that he had dislocated the metatarsal bones of both feet. Several fruitless attempts were made to accomplish the reduction, but to no purpose, and in about two weeks he left the hospital.³

Mr. South says that, in 1835, a case was admitted to St. Thomas's Hospital, under Mr. Green's care, of dislocation of the last two metatarsal bones, occasioned by the falling of a heavy chest upon the inside of the foot. "Upon the top of the foot was a large swelling before and below the outer ankle, and behind it a cavity in which two fingers could be easily buried, in consequence of the bases of the metatarsal bones having been thrown upward and backward upon the top of the cuboid." The reduction was accomplished with much difficulty by continued extension, and as the bones resumed their places a distinct crackling was heard.⁴

Liston reduced a dislocation upward of the first metatarsal bone. Malgaigne mistook a dislocation of the fourth bone for a fracture, and did not attempt the reduction until the seventh day, when after five successive trials, the head entered with a noise into its cavity. In a dislocation of the second, third, and fourth metatarsal bones, he also failed to detect the true nature of the accident until the tenth day, when he proceeded to attempt reduction, but failed. Inflammation, suppuration, and delirium followed, and the patient died on the forty-first day. Tufnell failed in a similar case, although his patient finally recovered with a not very useful limb. Malgaigne failed to reduce the bones also in a recent case of dislocation of the first four bones, although he used chloroform and diligently tried various means. The same writer has seen one example of ancient dislocation, which was not recognized by the surgeon by whom the patient was first seen. Monteggia reports a case of dislocation of the

¹ Malgaigne, *op. cit.*, p. 1081.

² Sandwith, *Amer. Journ. Med. Sci.*, Nov. 1828, p. 216; from *London Med. Gaz.*, vol. i.

³ Dupuytren, *op. cit.*, p. 329.

⁴ South, *Note to Chelius*, vol. ii. p. 256.

last two metatarsal bones, which was not at the time recognized. On the tenth day swelling commenced, and soon after the patient died in convulsions.¹

Dr. W. C. Shaw, of Pittsburg, reports the case of a man 35 years old, who, falling from a height, "struck with all his weight upon a sharp edge of stone, striking upon the inner and under surface of the right metatarsal bones, dislocating the proximal end of the first metatarsal bone upward, and apparently carrying the second with it." After several ineffectual attempts at reduction made by himself and others, in which extension and direct pressure were employed, he succeeded finally by "bending the foot to an acute angle on the inner surface, approximating the articulating surfaces of the dislocated bones, and quickly extending the foot."²

CHAPTER XXV.

DISLOCATIONS OF THE PHALANGES OF THE TOES.

DISLOCATIONS of the toes are less common than those of the fingers, yet a considerable number of cases have been recorded by different surgeons. They are occasioned by blows received directly upon the ends of the toes; by the weight of the body brought to bear suddenly upon their plantar surfaces, as when a horseman springs in his stirrups, or by a fall, in consequence of which the rider hangs in his stirrup; by leaping, etc. They may be partial or complete; and in the latter case, a slight overlapping is generally observed. In a great majority of cases the direction of the displacement is backward, or with only a slight lateral deviation. Occasionally several bones are displaced at the same time, but usually only one suffers displacement. It is more common here to find compound and complicated dislocations than in the case of the fingers.

The position of the toes is not always the same in the same form of dislocations. Thus, in the dislocation backward, the toe is sometimes reversed upon the foot to nearly a right angle, and at other times it is found lying in the same axis as the metatarsal bone, or the phalanx, from which it is dislocated.

Some years since I reduced a backward dislocation of the first phalanx of the second toe in the person of L. B., æt. 60, who had fallen from a fourth-story window, striking upon his feet, and breaking both thighs. I did not discover the dislocation of the toe until sixteen hours after the accident. It was then lying parallel with the axis of the metatarsal bone, upon which it was slightly overlapped. The reduction was effected easily by pulling upon the last phalanx with my fingers, while at the same moment I pushed the head of the bone toward the socket. No swelling followed, nor has it troubled him at all since his recovery.

Dr. John H. Packard, of Philadelphia, informs me that in a dislocation backward of the first phalanx of the great toe, occurring in a very muscular man, the phalanges were found lying parallel with the metatarsal bone; and it was reduced easily by extension, while the patient was under the influence of ether.

Treatment.—With regard to the treatment, surgeons have experienced the same difficulty, in certain cases of dislocation of the great toe, as we

¹ Malgaigne, op. cit., p. 1077, et seq.

² Shaw, Pittsburg Med. Journ., 1882, p. 301.

have seen experienced in similar dislocations of the thumb. Occasionally, indeed, the reduction has been found to be impossible. The same doubts have existed also in relation to the causes of this difficulty, and in reference to the means by which it was to be overcome. I shall, therefore, refer the reader to the chapter on Dislocations of the First Phalanges of the Thumb and Fingers, for a more full consideration of this matter. In case the smaller toes are dislocated, the reduction is generally effected with ease, by simple extension, or by extension combined with pressure; sometimes, also, the bone will be more easily put in place by reversing the phalanx more completely, as I have advised in certain cases of dislocations of the fingers. If the skin is penetrated, it will often be found necessary either to amputate or to practise resection upon the exposed phalanx.

Sir Astley Cooper relates a case of dislocation of "all the smaller toes," from the metatarsus, which had not been reduced, and the subject of which was, in consequence, so much maimed that he was unable to labor. It had been occasioned by a fall, from a considerable height, upon the extremities of the toes. A projection existed at the roots of all the smaller toes, the extremity of each metatarsal bone being placed under the first phalanx of its corresponding toe. The swelling which immediately followed the receipt of the injury had concealed its nature, and now, several months having elapsed, reduction could not be effected. The only relief which could be afforded him, therefore, was in wearing a piece of hollow cork at the bottom of the inner part of the shoe, to prevent the pressure of the metatarsal bones upon the nerves and bloodvessels.¹

CHAPTER XXVI.

COMPOUND DISLOCATIONS OF THE LONG BONES.

Frequency of Compound as compared with Simple Dislocations.—Compound dislocations, as compared with simple, are of rare occurrence. Of ninety-four dislocations reported by Norris as having been received into the Pennsylvania Hospital for the ten years ending in 1840, only two were compound;² and of one hundred and sixty-six dislocations in my record of personal observation made in 1855, only eight were compound.³

Relative Frequency in the Different Joints.—In my own recorded cases just referred to four were dislocations of the tibia inward at the ankle-joint, one was a partial (pathological) dislocation forward at the same joint, one a dislocation of the astragalus, one a dislocation of the head of the humerus into the axilla, and one a forward dislocation of the radius and ulna at the wrist-joint. I have also met with several examples

¹ Sir Astley Cooper, *op. cit.*, p. 385.

² Norris, *Amer. Journ. Med. Sci.*, April, 1841, p. 335.

³ For most of these cases, see Transactions of the New York State Med. Soc. for 1855, article entitled "Report on Dislocations, with especial reference to their Results," by F. H. Hamilton.

of compound dislocations of the elbow and fingers. Both of the cases reported by Norris were dislocations of the thumb.

Sir Astley Cooper, speaking upon this point, says that the elbow, wrist, ankle, and finger-joints are most subject to these accidents; and that he has seen but two in the shoulder-joint, and one in the knee-joint. He had never seen a compound dislocation at the hip-joint, and he believed that it was "scarcely ever" so dislocated. Malgaigne says that a compound dislocation at the hip-joint has probably never occurred. Mr. Bransby Cooper has, however, reported in detail a very interesting case of this accident, communicated to him by Dr. Walker, of Charlestown, Mass., in which reduction was accomplished by *manipulation* alone, by Dr. Ingalls on the second day. The patient died at the end of about three weeks.¹ I have already, when considering dislocations of the femur downward and backward, referred to the case reported by Dr. W. Taylor, in which reduction having been effected recovery took place.

Among the cases of compound dislocation recorded by Sir Astley and Bransby Cooper, most of which were communicated to these gentlemen by other surgeons, forty-five were dislocations of the ankle, ten of the astragalus, four of the ulna at the wrist-joint, four of the thumb, two of the knee, one of the shoulder, one of the elbow, one of the radius and ulna at the wrist, one of the scaphoid bone, and one of the metatarsal bone of the great toe. Other writers have occasionally described compound dislocations of the clavicle, but I know of no record of a compound dislocation of the lower jaw.

Prognosis.—By most of the early writers these accidents, whenever they occurred in the larger joints, were regarded as nearly beyond the reach of art. Says Hippocrates: "In cases of complete dislocation at the ankle-joint, complicated with an external wound, whether the displacement be inward or outward, you are not to reduce the parts, but let any other physician reduce them if he choose. For this you should know for certain, that the patient will die if the parts are allowed to remain reduced, and that he will not survive more than a few days, for few of them pass the seventh day, being cut off by convulsions, and sometimes the leg and foot are seized with gangrene." Hippocrates adds: "But if not reduced, nor any attempt at first made to reduce them, most of such cases recover."² The same remarks are applied by Hippocrates to compound dislocations of the head of the tibia, of the lower end of the femur, of the wrist, elbow, and shoulder-joints; death occurring in all cases, as he believed, more or less speedily whenever the bones are reduced and retained in place a sufficient length of time, and "were it not that the physician would be exposed to censure," he would not reduce even the bones of the fingers, since it must be expected, he thinks, that their articular extremities will exfoliate even when the reduction is most successful. Hippocrates advised and probably practised resection in certain cases of these accidents.

Both Celsus and Galen adopt almost without qualification the line of practice laid down by Hippocrates, and affirm equally the danger and almost certain death consequent upon the reduction of compound dislocations in large joints.³ Celsus recommends resection in some cases. Paulus Ægineta, however, and after him Albucasis, Haly Abbas, and Rhazes, do not regard the rules established by Hippocrates, in relation to the non-reduction of the bones, as so imperative, nor the results of the opposite practice as so uniformly fatal. "Hippocrates

¹ A. Cooper, on Dislocations, etc., by B. Cooper, p. 59.

² Works of Hippocrates, Syd. ed., London, vol. ii. p. 634.

³ Paulus Ægineta, Syd. ed., vol. ii. p. 510.

remarks," says Paulus Ægineta, "in the case of dislocations with a wound, the utmost discretion is required. For these, if reduced, occasion the most imminent danger, and sometimes death, the surrounding nerves and muscles being inflamed by the extension, so that strong pains, spasms, and acute fevers are produced, more particularly in the case of the elbows, knees, and joints above, for the nearer they are to the vital parts the greater is the danger they induce. Wherefore, Hippocrates, by all means, forbids us to apply reduction and strong bandaging to them, and directs us to use only anti-inflammatory and soothing applications to them at the commencement, for that by this treatment life may sometimes be preserved. But what he recommends for the fingers alone, we would attempt to do for all the other joints; at first and while the parts remain free from inflammation, we would reduce the dislocated joints by moderate extension, and if we succeed in our object, we may persist in using the anti-inflammatory treatment only. But if inflammation, spasm, or any of the aforementioned symptoms come on, we must dislocate it again if it can be done without violence. If, however, we are apprehensive of this danger (for perhaps, if inflammation should come on, it will not yield), it will be better to defer the reduction of the greater joints at the commencement; and when the inflammation subsides, which happens about the seventh or ninth day, then, having foretold the danger from reduction, and explained how, if not reduced, they will be mutilated for life, we may try to make the attempt without violence, using also the lever to facilitate the process."¹

In the following quotations from three of the most celebrated writers of the last two centuries, we find but little, if any evidence that the opinions of the fathers upon this subject were not still held in general respect: "If the joint be dislocated, so that it is either uncovered, or a little thrust forth without the skin, the accident is mortal, and of more danger to be reduced than if it be not reduced. For if it be not reduced, inflammation will come upon it, convulsion, and sometimes death. 2. There will be a filthiness of the part itself. 3. An incurable ulcer, and if perhaps it be brought to cicatrize at all, it will easily be dissolved by reason of the softness of it; but if it be reduced, it brings extreme danger of convulsion, gangrene, and death."² "Si vero in magnis articulis tam valida fuit facta luxatio, ut ligamentis ruptis os articuli multum sit protrusum per integumenta, hæc pars ossis vasis privata moritur, citius autem si reponatur, quam si non reponitur; quare sola amputatio restat ad conservationem vitæ."³ Heister, who makes no allusion to this subject in the first edition of his great work, published at Amsterdam in 1739, adds the following remarks in his last edition, translated and published in London in 1768: "Dislocations attended with a wound, especially of the shoulder or thigh-bone, are of very bad consequence, and often endanger the life of the patient; in Celsus's opinion, whether the bones be replaced or not, there is generally great danger; and so much the more the nearer the wound is to the joint. Hippocrates has declared that no bones can be reduced with security, besides those of the hands and feet. See more on this subject in that passage of Celsus just now quoted, though I by no means recommend the following him implicitly."⁴

Such were the extreme views as to the fatality of these accidents, and of the feebleness of our resources, entertained by the ancient, and even by the more modern writers almost down to our own day; with only rare exceptions these limbs were condemned either to great and inevitable deformity, or to amputation. Nor, if we speak only of their fatality, have surgeons ceased to regard these accidents as among the most grave

¹ Paulus Ægineta, Syd. ed., vol. ii. p. 509.

² Chirurgeon's Storehouse. By Johannes Scultetus, of Ulme, in Suevia. London ed., 1674, p. 31.

³ Johannes de Gorter. Chirurgia repurgata. Lugduni Batavorum, 1742, p. 86.

⁴ General System of Surgery, by Dr. Laurence Heister. 8th ed. London, 1768, vol. i. p. 164.

See also, "De l'intervention Chir. dans les Lux. compliquées du cou-de-pied," by G. Poin-sot Paris, 1877.

with which they have to deal. The danger, according to Sir Astley Cooper, consists in the rapid inflammation of the synovial membranes, which is speedily followed by suppuration and ulceration, whereby the ends of the bones become exposed; and for the repair of which lesions great general as well as local efforts are required, and a high degree of constitutional irritation results. In addition to which circumstances, "the violence inflicted on the neighboring parts, the injury of the muscles and tendons, and the laceration of bloodvessels, necessarily lead to more important and dangerous consequences than those which follow simple dislocations."

The sources of danger enumerated by Sir Astley Cooper have been regarded as sufficient to account for their extraordinary fatality by the majority of those modern surgical writers who have alluded to the subject; but I must confess that to me they do not appear so. In compound fractures the mortality is far less; yet one might naturally suppose that when the sharp and irregular fragments are pressing into the flesh, among nerves and bloodvessels, the irritation and inflammation would be equal, if not more than equal, to the irritation and consequent inflammation produced by exposing a joint surface to the air; indeed, modern experience has sufficiently shown that these surfaces are much more tolerant of atmospheric exposure, and of the action of many other irritants, than surgeons formerly supposed. A clean incision into a large joint, which exposes the synovial membranes to the air, and which permits the products of inflammation to escape freely, is attended with much less danger than a small puncture which does not at all permit the air to enter, nor the increased synovia and the pus to escape. Very grave results sometimes follow from large wounds into large joints, but under judicious treatment such results are the exception and not the rule.¹ But Sir Astley evidently attributes more of the bad consequences to the exhausting effects of the efforts at repair, than to the immediate inflammation resulting from the exposure of the joint. It is pretty certain, however, that a majority of these patients die at a period too early to render this cause in any considerable degree operative.

As to the bruising of the "muscles and tendons, and laceration of bloodvessels," it cannot be denied that it must usually be greater than in "simple dislocations;" and I will not say that it is not in a given number of instances greater than in the same number of instances of compound fractures. The tissues have often been thrust rudely through by a large and smooth bone, and the tendons have been stretched violently or torn completely asunder; while occasionally large arteries, which are prone to hug the bones about the joints are lacerated and left to bleed. That the importance of these complications, however, may not be overestimated, I must state that Sir Astley Cooper himself has remarked how seldom, in compound dislocations of the ankle-joint, the large arteries are injured; that a tearing of the ligaments and of the tendons is almost as likely to occur in simple dislocations as in compound; and, indeed, that in neither case are the tendons usually ruptured, but only thrust aside. Moreover, the skin is often made to give way not so much from the pressure of the round head within, as from the equal pressure of some sharp angular body from without. In all these respects, there are many examples of compound fractures which possess not a whit of advantage; in which cases, nevertheless, the surgeon feels very little doubt as to the ultimate cure.

In short, the causes which, according to Sir Astley Cooper, determine the extraordinary fatality of these accidents, do not sufficiently differ from those which operate in compound fractures to occasion so great a difference in results, and the fatality of compound dislocations remains unexplained; or, if surgical

¹ Upon this point, see the very able article, entitled "Amputations and Compound Fractures," by John O. Stone, in the *New Journal of Medicine*, vol. iii. of 2d series, p. 316, Nov. 1849; and also a paper entitled "*De la conservation dans le traitement des fractures compliquées*," by G. Poincot, Paris, 1873.

writers have here and there intimated the true cause, they have failed to give it its proper place and value.

The cause of the greater fatality of compound dislocations over compound fractures is to be found in the simple fact that dislocations are generally reduced, and by splints or other apparatus successfully maintained in place, while compound fractures, as my statistical report of cases has proven, are not generally reduced completely, nor can they by any means yet devised, except in a few cases, be maintained in place if reduced. Broken limbs, whether simple or compound in their character, will in a great majority of cases shorten upon themselves in spite of the most assiduous and skilful attempts to prevent it.¹

In adults most bones break obliquely, and cannot be made to support each other, and even in transverse fractures the broken ends are generally small compared with the articular ends of the same bones, and afford a very uncertain and inadequate support for themselves; not to speak of the difficulty of once bringing their ends into exact apposition where the muscles are powerful, or where they lie embedded in a large mass of flesh so that they cannot be felt. While, on the other hand, dislocated bones, whether simple or compound, are capable, when restored to place, of supporting themselves; or with only slight assistance, their reduction may be maintained; it is also ordinarily a work of no great difficulty to reduce them. Herein, then, consists the most important difference between these two classes of accidents, which are in other respects so similar. In the one, the very nature of the injury prevents the complete reduction, and the consequent violent strain of the muscles, tendons, and other soft tissues; while in the other, the nature of the accident leaves it in the power of the surgeon to reduce the bones, and modern surgery has in a great measure sanctioned the practice of maintaining them in place, in defiance of the efforts of the muscles, and sometimes, no doubt, at the imminent hazard of the life of the patient.

Is it not fair to presume that tissues which have been stretched and lacerated, require rest in order that they may recover from the effects of their injuries? And if the soft parts are really more injured in dislocations than in fractures, does not the indication for rest become for this very reason more imperative?

The shortening of limbs after fractures, within certain limits and in certain cases, is a conservative circumstance rather than one which the surgeon should, in all cases, seek to prevent.

There is abundant evidence that the ancients had some knowledge of the value of rest to the muscles, tendons, etc., in the prevention of inflammation after compound dislocations, since they constantly urge the greater danger of reducing these dislocations, than of leaving them unreduced; and they do not hesitate to recommend that, in case violent inflammation supervenes upon the reduction, the bone shall immediately be again dislocated. Galen speaks very explicitly on this subject, and says that "the danger in reduction consists partly in the additional violence inflicted on the muscles, and partly in their being put into a stretched state, whereby spasms or convulsions are brought on, and gangrene as the result of the intense inflammation which ensues;" and Paulus Ægineta

¹ "Report on Deformities after Fractures." Trans. Amer. Med. Assoc., vols. viii., ix., and x.

remarks: "For these, if reduced, occasion the most imminent danger, and sometimes death; the surrounding nerves and muscles being inflamed by the extension," etc.

Treatment.—The alternatives which surgery presents for the treatment of these intractable accidents are as follows: 1. Reduction of the bone. 2. Non-reduction. 3. Amputation. 4. Tenotomy. 5. Resection and reduction. The questions for us to consider are, first, by which of these several methods is the life of the patient rendered most secure? and, second, when, of two or more methods, all are equally safe, by which will he suffer the least maiming or mutilation?

Reduction.—We have seen already how the old surgeons regarded the practice of reducing compound dislocations of the larger joints. It is not difficult, however, to find in the records of surgery numerous examples of successful terminations under this practice.

Dr. White, of Hudson, N. Y., has reported a case of this kind in which the dislocation was at the ankle-joint.¹ Pott says he has seen this practice occasionally succeed,² and Mr. Scott reported³ a case of compound dislocation of the humerus successfully treated by reduction. Sir Astley Cooper also records several cases of compound dislocations at the lower end of the tibia and fibula, successfully treated by reduction.

A careful examination, however, of those cases reported by Sir Astley as having been reduced without resection, and which resulted in cures, does not, in my opinion, leave much substantial evidence in favor of the practice; or perhaps I ought rather to say that it leaves only a qualified evidence of its propriety in certain cases. He has mentioned about sixteen of these examples, comprising dislocations of the lower end of the tibia, or of the tibia and fibula, outward, also inward and forward, all of which, save one quoted from Mr. Liston, have been reported to him by other surgeons, and not one of which had he ever seen himself. Many of the cases are reported very loosely, evidently in reply to circular letters, and from memory, without recorded notes, and by unknown, and in some sense, irresponsible surgeons. It is not always said whether the wounds in the soft parts were made by the protrusion of the bones, or by some external violence; yet this is certainly a very material point in determining whether reduction is to be followed by inflammation or not. The results, sometimes only attained after exposure to great hazards, are, after all, often sufficiently unfavorable.

It will be noticed, also, that, in Cases 152 and 153, the astragalus was comminuted and removed, either at first or at a later day; and in Cases 154, 155, 156, and 160, the tibia, and also probably the fibula, were broken, and it does not appear but that in consequence of this complication the limb became shortened, and the muscles were thus put at rest, very much as if the bones had been resected; and in one of the cases enumerated under 161, the lower end of the tibia spontaneously exfoliated. That a comminution or that any fracture of the astragalus, or of the tibia and fibula, should be regarded in these cases as rendering the accident less grave, can only be comprehended by a full appreciation of the value of relaxation of the muscles.

The few cases which remain after this exclusion do indeed illustrate how nature and skill may triumph over great difficulties, but nothing more. It is possible, also, that some of these examples of recovery after reduction may admit of an explanation entirely consistent with my own views of the true source of the danger in these accidents, if indeed they do not tend actually to confirm my doctrines. I have myself seen several

¹ White, Amer. Journ. Med. Sci., Nov. 1828, p. 109.

² Pott, Chirurg. Works, vol. ii. p. 243.

³ Lancet, March, 1837.

examples of complete recovery after reduction of compound dislocations at the ankle-joint, although resection was not practised; in one of which, all the tissues, or nearly all of which suffered any injury, were completely torn asunder, and therefore wholly removed from the danger of which I have spoken.

The example referred to is the following: J. B., *æt.* 30, was caught in the tow-line of a canal-boat, causing a compound dislocation of the right ankle-joint. I found the foot, immediately after the accident, thrown completely back against the lower part of the leg, the integuments in front of the joint, as well as all of the tendons and ligaments on this side, being completely torn asunder, while the tendo Achillis, and the tendons behind both of the malleoli, with the corresponding integuments, were uninjured. This immunity of the tissues behind the malleoli was due to the direction in which the foot was drawn, namely, directly backward. Everything which had suffered a strain being thoroughly severed, I did not hesitate to attempt to save the limb without resection. The reduction was accomplished very easily. The leg and foot were placed in a box filled with bran, and cool water dressings were applied to the portion which was exposed. On the twenty-second day the limb was removed from the bran to a pillow, the union being sufficient not to demand so much lateral support. He left the hospital, the wound having closed, but the ankle remaining swollen and stiff.

I have also seen two cases in which the foot has been nearly severed from the leg through the ankle-joint, by means of a "reaper." In each case the patient was standing with his back to the machine, and one of the blades cut horizontally from side to side, severing everything except about three inches of integuments in front, and the extensor tendons of the toes. In the first instance, having seen the patient, a gentleman nearly 60 years of age, within three or four hours after the receipt of the injury, I found him exceedingly exhausted by the hemorrhage. Both malleoli were cut off smoothly, the knife having severed the limb so exactly through the joint, as to have incised the cartilage of incrustation at but one or two points. Having secured the bloodvessels, I replaced the foot, and after a few days of attendance I left him in charge of Dr. Robinson, of Lancaster, N. Y., to whose diligence and skill the patient is no doubt mainly indebted for his recovery. After the lapse of nearly one year he was able, by the assistance of a shoe furnished with lateral supports, to walk very well. In the second case, which was only brought to my notice some months after the accident occurred, in consequence of a troublesome fistula near the ankle-joint, the recovery had been complete except that a small fragment of one of the malleoli was necrosed and required removal.

Dr. Hurd, of Niagara Co., N. Y., was equally fortunate in a case of compound dislocation of the shoulder-joint. This was in the person of G. T., *æt.* 30, who was caught in the gearing of a threshing-machine, which, having drawn him in with great force, dislocated the head of the left humerus downward through the integuments into the axilla. Reduction was accomplished according to the method recommended by Nathan Smith, by pulling from each wrist at right angles with the body, while the operator himself seized the naked head of the humerus with his left hand, his right resting upon the top of the shoulder, and pushed it into place. The time occupied in the reduction was about thirty seconds. The forearm was then suspended in a sling, and the venous hemorrhage, occasioned by a rupture of the subclavian vein, was arrested by compression. The tegumentary wound, between three and four inches in length, was subsequently closed by sutures, and cool water dressings were applied. On the fourth day the wound had united by first intention, and the man was walking about his room. In less than a month he was dismissed cured, and in the following harvest he was able to cut his own hay and grain, and to use his arm as before the accident.¹

Miller and Hoffman reduced successfully a compound dislocation of the knee,²

¹ Hurd, Buffalo Med. Journ., vol. ix. p. 119.

² Miller and Hoffmann, London Med. Repos., vol. xxiv. p. 346.

and Galli has communicated a similar case to Malgaigne.¹ Whether either of the last three mentioned examples admit of the same explanation as the preceding three, I am unable to say, but whether they do or do not, they are too exceptional in their character to prejudice materially the argument which I shall hereafter make in favor of resection.

It is not pretended that the few cases which I have mentioned in the preceding pages are all of the compound dislocations of the larger joints, successfully treated by reduction, which have been recorded; nor are they all which have come under my own observation; nevertheless, I repeat, success by this method has up to this moment, whatever plan of after-treatment has been adopted, been found to be the exception and not the rule. I speak now more especially of those dislocations of this class, which are rendered compound by the thrusting of the dislocated bone through the flesh, and which, in my experience, constitute by far the largest proportion of these examples.

Non-reduction.—While it is true that not many cases of compound dislocations, especially of the larger joints, can be found recorded as having terminated favorably after reduction, yet it will be very difficult to find an equal number of cases of compound dislocations, unreduced, which have terminated favorably. The fact is, no doubt, that at the present day very few surgeons would feel themselves justified in leaving a bone out of place unless they proceeded to amputate.²

I have reported a compound dislocation at the ankle joint, which, being unreduced, terminated fatally on the twenty-eighth day. This is the only example of a compound dislocation of a long bone, left unreduced, which has fallen under my observation; excepting, of course, those cases in which amputation was immediately practised.

The united testimony, however, of the old surgeons, who generally neither amputated nor adopted the method of resection, but who recommended and practised non-reduction, is, that it is much more safe to leave these bones unreduced, than to attempt immediate reduction; and I see no reason to doubt the correctness of their opinions in this matter. But whether it would be more safe to leave such limbs unreduced, or having practised resection to restore them, is another question, in which the advantage and comparative safety of the latter practice are too obvious to require explanation or defence.

Amputation.—Says Pott: "When this accident (dislocation of the ankle) is accompanied, as it sometimes is, with a wound of the integuments of the inner ankle, and that made by the protrusion of the bone, it not unfrequently ends in a fatal gangrene, unless prevented by timely amputation, though I have several times seen it do very well without." And Sir Astley Cooper, speaking of compound dislocations of the ankle-joint, remarks: "Thirty years ago it was the practice to amputate limbs for this accident, and the operation was then thought absolutely necessary for the preservation of life, by some of our best surgeons." Nor is it difficult to see by what reasoning surgeons of "thirty years ago" had fallen back upon this desperate remedy. Both reduction and non-

¹ Galli, Malgaigne, op. cit., tom. ii. p. 958.

² Transactions of the New York State Medical Society, 1855.

reduction having proven eminently hazardous, in the absence of perhaps both knowledge and experience in resection, they finally adopted the alternative of amputation, as that which after all must give to the patient the best chance for life; and were no other alternatives to be presented, this would be my choice in a large proportion of cases. It must not be understood, however, that amputation is an expedient wholly free from danger; or, indeed, that the chances of the patient are, in the average, very greatly increased by this practice.

Of thirteen amputations made for compound dislocations at the ankle-joint, in the Royal Infirmary at Edinburgh, only two resulted in the recovery of the patients.¹ Alluding to which, Mr. Fergusson remarks: "An amount of mortality which may well incline the surgeon to act upon the doctrine inculcated by Sir Astley Cooper" (to attempt to save the limb by reduction). But Mr. Fergusson has added a sentiment which accords very closely with my own experience and opinions. "I fear, however, that in the attempts which have been made to save the foot (by reduction), the results in all the cases have not met with the same publicity—that the instances where amputation has been afterward necessary, or where death has been the consequence, have not always been recorded; and, from what I have myself seen, I would caution the inexperienced practitioner from being over-sanguine in anticipating a happy result in every example."

Tenotomy.—As a means of overcoming the resistance of the muscles, and for the purpose especially of facilitating the reduction, tenotomy has been proposed; first by Dieffenbach in cases of ancient unreduced dislocations. But Wm. Hey, Jr., was the first to make a practical application of this suggestion in a case of compound dislocation. After cutting the tendo Achillis, the ankle being dislocated, the reduction was easily effected, but a strong tendency to displacement backward remained, and he was obliged afterward to cut the tendons of the tibialis posticus and flexor longus digitorum.²

This method, based in some degree upon a very correct notion of the principal sources of difficulty, I regard as in most cases totally impracticable, at least to any useful or adequate extent. In order to be efficient, usually, all the tendons passing the articulations must be cut, or nearly all of them; and I doubt whether the judgment of any discreet surgeon will ever sanction such an extreme measure. Nor do I think that in the point of view in which I am now considering this subject, having reference only to the question of danger, if the cutting of the tendons was sufficiently extensive to have any real effect in facilitating the reduction, the practice would be found to have any advantage over other methods known to be eminently dangerous. Certainly in no case would the surgeon, in my opinion, be justified in cutting any other than the tendo Achillis.

Resection.—Resection presents itself for our consideration as the only remaining surgical expedient. Most of the early writers understood the effects of a constant strain upon the muscles in increasing the danger of spasms, inflammation, and death; but in general they have suggested no remedy but non-reduction or amputation.

¹ Edinb. Med. Monthly, Aug. 1844.

² Hey, Trans. of Provinc. Med. and Surg. Assoc., vol. xii. p. 171, 1844.

Hippocrates, however, uses the following language, after speaking of resection of protruding bones in accidental amputations or in fractures of the fingers: "Complete resection of bones at the joints, whether the foot, the hand, the leg, the ankle, the forearm, the wrist, for the most part, are not attended with danger, unless one be cut off at once by deliquium animi, or if continued fever supervene on the fourth day." To which passage the translator adds the following note: "This paragraph on resection of the bones in compound dislocations and fractures contains almost all the information on the subject which is to be found in the works of ancient medicine." Celsus notices the practice of resection in compound dislocations very briefly as follows: "Si nudum os eminent, impedimentum semper futurum est; ideo quod excedit, abscindendum est."

Mr. Hey, of Leeds, was the first of modern surgeons who called especial attention to the value of resection in compound dislocations. Subsequently, Mr. Parks, of Liverpool, in an "Account of a New Method of Treating Diseases of the Joints of the Knee and Elbow," advocated the practice of resection in certain cases of diseases of these joints, but especially in "affections of the joints produced by external violence." M. Levéille, in France also, following, as he affirms, the guidance of Hippocrates, has advocated a similar practice.

Velpeau, Syme, Fergusson, Erichsen, Miller, Liston, Chelius, Lizars, Gibson, Norris, under certain circumstances, and especially where the bones cannot otherwise be reduced, and where the dislocations occur in certain joints, and especially the elbow and ankle-joints, recommend resection. To which names I may add that of Sir Astley Cooper, who has considered the subject, as applied to the ankle-joint, quite at length, and who says: "I have known no case of death when the extremities of the bone" (tibia, at the ankle) "have been sawed off, although I shall have occasion to mention some cases which terminated fatally when this was not done."

Why resection should diminish the danger to life, by placing at rest the injured muscles, has been already sufficiently considered; but it seems not improbable that, if the synovial membranes are actually more susceptible of violent and dangerous inflammation than the other tissues about the joints, then would this source of danger be removed just in proportion as the synovial membranes themselves are removed. Such, indeed, was the argument used by Sir Astley; and Mr. South, in a note to Chelius, when referring to this fact, has made the following statement: "In compound dislocations of the ankle-joint, with protrusion of the shin-bone through the wound, most English surgeons saw off the joint end, not merely to render reduction more easy, but also, according to Sir Astley Cooper's opinions, to lessen the suppurative process, by diminishing the synovial surface. This mode of practice is certainly not commonly followed in reference to other joints, and the younger Cline was always opposed to its being resorted to in dislocated ankle."

The following cases having occurred under my own eye, will serve to illustrate the value of the principle which I have been endeavoring to establish: S. A., æt. 24, was caught by the cable of a vessel, dislocating the left tibia at its lower end inward, and breaking the fibula two inches above the ankle. I was immediately called, and found the tibia protruding through the skin about three inches. The periosteum was torn up, and the cartilaginous surface of the end of the bone was roughened. His thigh was also severely bruised and lacerated, but the bone was not broken. Dr. Boardmann assisting me, we attempted to reduce the bones, but with our hands we found it impossible to do so. I proceeded immediately to remove about one inch and a half of the lower end of the tibia with the saw. The remaining portion was then brought easily into place, and the wound dressed with sutures, adhesive strips, bandages, and light splints. The wound in the leg healed kindly, with only a slight amount of inflammation and suppuration. Violent inflammation, however, occurred in the thigh, followed by extensive suppuration and sloughing. This, in fact, proved

to be by far the most serious injury, and that which most endangered his life and delayed his recovery. After about two months, the ankle was in such a condition as to require little or no further attention. The fragments of the fibula had shortened upon each other and were united, so that the tibia rested upon the astragalus. It was nearly two months, however, before he began to walk, owing to the condition of his thigh. Fourteen months after the accident he called at my office. He was then employed again as a sailor on board the schooner *Sebastopol*, and performed all the duties of an ordinary deck-hand. His leg is shortened one inch and a quarter; from which it seems that there has been some deposit upon the end of the bone, which has compensated for one quarter of an inch of that which I removed. The ankle is perfect in its form, being neither turned to the right nor to the left, and he treads square and firm upon the sole of his foot. There is considerable freedom of motion, especially in flexion and extension. Occasionally it becomes a little swollen and painful.

January 1, 1875, R. W., æt. 45, was admitted to ward 13, Bellevue Hospital, having just been injured by a street-car. She was in good health, but very fat, weighing 185 lbs. She was found to have a compound dislocation at the right ankle-joint—the tibia being thrust completely through the flesh—and also a fracture of the fibula. Dr. Lewis, the house surgeon, reduced the dislocation at once, and easily, and then sent for me. I advised an attempt to save the limb without resection, and by supporting the limb with the plaster-of-Paris dressing. This dressing was applied fourteen hours after the accident by Dr. Lewis, a window being made opposite the ankle. January 3, the window was enlarged. January 5, gangrene and phlebitis had occurred; fenestra again enlarged. January 7, entire splint laid open, and hot-water dressings applied. January 12, suspended limb. January 21, the condition of the limb very critical; and, in a consultation composed of the visiting surgeons, we were equally divided between amputation and resection. It was permitted, therefore, that I should choose my own course. I immediately resected two inches of the lower end of the tibia, and placed the limb again in a sling supported with compresses as means of lateral support, and warm-water dressings were continued. The subsequent progress of the case was very slow, and there were several smart attacks of erysipelas, so that her life was at times in danger; but finally all unfavorable symptoms disappeared, and on the first of May, the ankle was in perfect shape, admitting of some flexion and extension, and the wounds were almost completely closed. It is now apparent that a resection on the first day would have been the most judicious practice, but that even at a later day it saved her life.

In a case of compound dislocation of the upper end of the humerus, occurring also under my own observation,¹ in which reduction was followed by death, I have now much reason to believe that if I had practised resection before the reduction, my patient's chances for recovery would have been greatly increased; perhaps also the case of compound dislocation of the wrist-joint recorded in the same volume (p. 68), in which, having reduced the bones, I was subsequently compelled to amputate, may equally illustrate the hazard to which the practice of reduction without resection must often expose the patient. The same remarks I will venture to apply to the case of compound dislocation of the hip, of which I have already spoken as having occurred in the practice of Dr. Walker, of Charlestown, Mass. Had the head of the femur been resected before its reduction, I cannot doubt that the unfortunate man's chance for recovery would have been very greatly improved.

Thus, if we consider the question of the life of the patient only, the argument and the testimony seem to favor resection, in a great majority of cases of compound dislocations occurring in large joints, and in a considerable number of cases of similar accidents in the smaller joints. It is certainly more safe than non-reduction or reduction without resection, and it is probably quite as safe as amputation.

¹ Trans. New York State Med. Soc., 1855, p. 27, case 14.

Poinsot, who has collected 82 reported cases of immediate resection practised for compound dislocations of the ankle-joint, found 68 cures, 10 deaths, and 4 secondary amputations, of which latter one was cured, two died, and the result in the fourth was unknown.

But there is another question, which is, in my estimation, secondary to the one now considered, but which is often, in the estimation of the patient himself, of the first importance, namely, by which method will he suffer the least maiming or mutilation? This question I do not find it difficult to answer. Certainly it is not by non-reduction or amputation; and, putting tenotomy aside, it is now a question only between reduction without resection, and reduction with resection. These two methods, one of which experience has shown to be fraught with danger, and the other of which experience has shown to be relatively safe, are now to be compared in a point of view in which their antagonisms are perhaps less conspicuous, yet sufficiently marked.

First. In either case the inflammation consequent upon the injury may be violent, and the recovery slow and tedious. The same arguments, however, which I have applied to the question of the comparative danger of the two modes, must apply with nearly equal force to this question of maiming; since the amount of maiming must often be governed by the intensity and duration of the inflammation, and upon this point the testimony has been shown to be in favor of resection. Not only is the danger of maiming rendered more considerable by reduction without resection, because the inflammation is so much more likely to extend to the tendons and muscles, causing them to adhere to each other, and to become subsequently atrophied, a condition from which they often never completely recover; but also because the ligaments and capsules of the joints, with the synovial surfaces, are in consequence encroached upon, and the freedom of motion is ever afterward greatly restricted, if not completely lost. This marked impairment of the functions of the joint does not always happen, but it cannot be denied that it does generally. Indeed, it is by no means uncommon for these accidents to be followed, after ulcerations of the cartilage, by copious bony deposits in and around the joints. How is it, on the other hand, with these joints after resection? I have thus far heard of no cases in which complete ankylosis resulted; but in all considerable freedom of motion has returned, and in some the restoration in this respect has been nearly or quite as complete as before the accident.

Poinsot has also made a very careful *résumé* of the results of resection in regard to the usefulness of the limb. In forty-one cases where the patients have been seen after complete recovery there is not a single failure; only it is observed that in the case of Ollier, there existed a slight deviation of the foot backward, which was corrected by apparatus. In all of these cases the patients walked well, and were able to resume their previous occupations. A similar analysis made by the same writer, of examples treated by reduction and without resection, gave the following results: In nineteen of twenty-three cases, the patients could walk without artificial support; in one case the aid of a cane or of other support was required; three times the foot was ankylosed in a vicious position, and remained painful, and the patients were obliged to ask for surgical interference; in two of these latter cases amputation was practised, and in one resection, the resection restoring to the patient a useful limb.¹

¹ Poinsot, op. cit., p. 1238.

Kerr, of Northampton, says: "Several cases of compound dislocation of the ankle have fallen under my care, and it has been uniformly my practice to take off the lower extremity of the tibia, and to lay the limb in a state of semiflexion upon splints; by this means a great degree of painful extension and the consequent high degree of inflammation are avoided. The splints I used are excavated wood, and much wider than those in common use, with thick movable pads stuffed with wool. I keep the parts constantly wetted with a solution of liquor ammoniæ acetatis, without removing the bandage. In my very early life, upwards of sixty years ago, I saw many attempts to reduce compound dislocations without removing any part of the tibia; but, to the best of my recollection, they all ended unfavorably, or, at least, in amputation. By the method which I have pursued, as above mentioned, I have generally succeeded in saving the foot, and in preserving a tolerable articulation."

Sir Astley Cooper has made a valuable experiment to determine the condition of the new joint under these circumstances; and the vast number of examples in which resection has now been practised in cases of caries of the articulating surfaces, and their results, add still more substantial proofs as to the usefulness of the joints after such operations. "I made an incision upon the lower extremity of the tibia, at the inner ankle of a dog, and, cutting the inner portion of the ligament of the ankle-joint, I produced a compound dislocation of the bone inward. I then sawed off the whole cartilaginous extremity of the tibia, returned the bone upon the astragalus, closed the integuments by suture, and bandaged the limb to preserve the bone in this situation. Considerable inflammation and suppuration followed; and in a week the bandage was removed. When the wound had been for several several weeks perfectly healed, I dissected the limb. The ligament of the joint was still defective at the part at which it had been cut. From this sawn surface of the tibia there grew a ligamento cartilaginous substance, which proceeded to the surface of the cartilage of the astragalus to which it adhered. The cartilage of the astragalus appeared to be absorbed only in one small part; there was no cavity between the end of the tibia and the cartilaginous surface of the astragalus. A free motion existed between the tibia and astragalus, which was permitted by the length and flexibility of the ligamentous substance above described, so as to give the advantage of a joint where no synovial articulation or cavity was to be found. This experiment not only shows the manner in which the parts are restored, but also the advantage of passive motion; for, if the part be frequently moved, the intervening substance becomes entirely ligamentous; but, if it be left perfectly at rest for a length of time, ossific action proceeds from the extremity of the tibia into the ligamentous substance, and thus produces an ossific ankylosis."

Second. Is it not probable, moreover, since the limb can be retained in place so much more easily after resection, that it will actually, in a majority of cases, be found to have been retained in place more perfectly? Even after simple dislocations, especially in those occurring at the ankle-joint, great deformity and much maiming are the not unfrequent results, and that, too, when all diligence and care have been employed. It has been impossible always to maintain a perfect apposition in the articulating surfaces. How much greater must be this difficulty in cases of compound dislocations.

Third. The only argument which remains in favor of reduction without resection is the necessary shortening of the limb after resection. But this need seldom perhaps exceed three-quarters of an inch, and often not more than half an inch; an amount of shortening which, as I have had occasion to prove when treating of fractures, does not necessarily produce a halt, and which indeed is often not known to exist by the patient himself.

It is claimed that the experience of Heine, Langenbeck, Volkmann, Hueter, and other German surgeons, has shown that in a considerable number of cases,

when these resections have been made by the *subperiosteal* methods, no shortening whatever has resulted.¹

Fourth. It must not be inferred that the author intends to recommend resection as a universal practice in cases of compound dislocations of the long bones. He has only sought to determine in a general manner its relative value as compared with other modes of procedure; and especially has it been his intention to bring more prominently into view the importance of rest and relaxation to the muscles, as an element in the treatment most essential to success. To declare its special application to cases would demand a treatise more elaborate than it was proposed to write. If, however, one were to speak of the individual bones only, there seems sufficient authority in the facts and arguments already presented, to conclude that resection is applicable to certain compound dislocations of the clavicle, humerus, radius, and ulna, fingers, femur, tibia, fibula, and toes; in short, to a certain proportion of all these accidents occurring in the long bones of the extremities. If an attempt is made to save the limb without resection, it is scarcely necessary to say that the success will depend, in a great measure, upon the care, attention, and skill bestowed upon the treatment. The limb must be maintained in a position of rest, combined with moderate elevation; and warm-water or other suitable dressings assiduously applied; including a judicious employment of antiseptic precautions and of drainage.

[It is necessary to emphasize the concluding words of the above text, recommending "a judicious employment of antiseptic precautions and of drainage." The question of the method of procedure in any given case of compound dislocation must be greatly influenced by the certainty that suppuration will not be present as a complicating condition. The treatment by reduction, if undertaken with the thorough employment of antiseptics, is deprived of nearly all these dangers. Resection performed antiseptically is an entirely safe operation. While, therefore, the dangers of both reduction and resection, performed without antiseptic precautions, are not overstated by the older authorities, both operations are now entirely practicable if the usual antiseptic remedies are employed.]

Of the several methods of treatment given, there can be no doubt that reduction is preferable provided it is equally safe. As the use of antiseptics removes the principal element of danger, reduction should, therefore, be the treatment pursued ordinarily. Resection should be resorted to only in cases in which the bones or other structures have been so much injured as to endanger the integrity of the joint, or in which reduction is impossible without excision. Amputation should be reserved for those cases in which the destruction of the vessels and nerves is such as to involve the loss of the extremity.

The rule of practice should be as follows: 1. Determine the amount of injury which the structures about the joint have sustained. If the vessels and nerves are so far uninjured that the limb can be saved, determine upon reduction or resection. 2. In either case, cut away tissues so bruised or torn that death is likely to ensue. Disinfect all the exposed surfaces with hot sublimate solutions (1:4000), the water being injected forcibly with a bulb-syringe. The solution should be of a temperature of not less than 130° to 140°, or so that the hand can scarcely be retained in it. If of the proper temperature the irrigated tissues will be changed to a dull gray color. The greatest care is necessary to force this solution into every part of the joint, and among the tissues. 3. Reduction or resection should now be effected with little strain upon the tissues. 4. Ample drainage should be provided, the drainage-tube or tubes extending to every

¹ On Subperiosteal Resection of the Tibio-tarsal Articulation. By Achilles Rose, M.D., New York. The Medical Record, July 3, 1875.

recess. 5. The wound should be closed by the union with suture of all divided tissues which can be brought into easy apposition. 6. Antiseptic dressings, enveloping the parts sufficiently, should be applied; and to maintain rest a plaster-of-Paris dressing may be required, as at the knee or ankle.

These dressings should not be changed for three or four weeks, unless there is evidence of disturbance in the wound. The tubes should be removed in four or five days by opening fenestra where they are located.]

CHAPTER XXVII.

CONGENITAL DISLOCATIONS.

CONGENITAL Dislocations are generally, in some sense, pathological, or are accompanied with such essential modifications of the anatomical structures as to separate them entirely from ordinary traumatic dislocations, which alone constitute the proper subjects of consideration in the present treatise. In relation to congenital dislocations, we shall find it necessary to establish systems of etiology, symptomatology, prognosis, and treatment, having very few points in common with traumatic dislocations. Exceptions to this rule will occur, in examples of intra-uterine traumatic dislocations, existing at birth without either original or accidental malformations of the articulations, or of the adjacent muscular, tendinous, or ligamentous structures; yet only in sufficient numbers to warrant the intrusion of the subject in this place.

It is probable that congenital displacements may occur in all the articulations of the skeleton; and in most of them their existence has been already established by dissections. Until within a few years, however, the attention of surgeons has been almost entirely directed to congenital dislocations of the shoulder and hip.

Hippocrates, in his treatise "De Articulis," speaks expressly of dislocations of the hip occurring in the mother's womb, comprising them under the same order with the different varieties of club-foot. Avicenna and Ambrose Paré have each mentioned congenital dislocations of the hip; but the first to record an example with any degree of accuracy was Kerkring; in which case, death having occurred during infancy, he was able to verify his opinion by an autopsy. Chaussier has reported, in the *Bulletin de la Faculté et de la Société de Médecine*, An. 1811 and 1812, the case of an infant, upon which he discovered, at birth, two dislocations, one at the scapulo-humeral articulation, and the other at the coxo-femoral. In 1788, Palletta, of Milan, published, under the title of *Adversaria Chirurgica*, a collection of observations, in which, among other things, he has described certain congenital malformations of the hip-joint; and in 1820 he published another work, entitled *Exercitationes Pathologicae*, where he enters into a more complete exposition of the nature and causes of these deformities. In 1826, Dupuytren read, before the Academy of Sciences, a memoir upon the lameness produced by the original displacement of the femur; and in the *Leçons Orales*, published in the collections of the Sydenham Society, may be found a full record of the views and observations of this distinguished surgeon. The writings of Dupuytren seem, more than anything previously written, to have directed the attention of surgeons and pathologists to this interesting subject, and to have given a new impulse to investigation.

From this time various treatises have been written by eminent surgeons, many of which are characterized by profound thought, careful investigation, and practical experiment. Among those who have furnished us with elaborate treatises, or with more precise practical information upon this subject, the following names deserve to be especially mentioned: Breschet,¹ Caillard-Billionnière,² Lehoux,³ Sandiforte,⁴ Bouvier,⁵ Sédillot,⁶ Wrolik,⁷ Guérin,⁸ Parise,⁹ Pravaz père,¹⁰ Carnochan,¹¹ Robert Smith,¹² Delpech,¹³ Heine,¹⁴ von Ammon,¹⁵ Pravaz fils,¹⁶ Hueter,¹⁷ Dollinger,¹⁸ Grawitz,¹⁹ Kirmisson,²⁰ Kronlein,²¹ Gerdy,²² Polinière,²³ Jalade-Lafond,²⁴ Humbert and Jacquier.²⁵

Etiology.—If we analyze the various opinions of authors as to the causes of congenital dislocations, we shall find that they are so far susceptible of classification, as that they may be arranged under the three following divisions:

First, the physiological doctrines; according to which congenital dislocations are due to an original defect in the germ, or to an arrest of development.

Second, the pathologic doctrines; which refer them to some supposed lesion of the nervous centres, to contraction or paralysis of the muscles, to a laxity of the ligaments, to hydrarthrosis, or to some other diseased condition of the articulating apparatus.

Third, the mechanical doctrines; which recognize no intra-uterine dislocations except those which are strictly traumatic, the causes being understood to be the peculiar position of the foetus in utero, violent contractions or the constant pressure of the walls of the uterus, falls and blows upon the abdomen, and unskilful manipulation of the child in delivery.

Hippocrates says that the several bones of the extremities may be disarticulated during intra-uterine life by falls or blows, or by injuries of any kind, inflicted directly upon the abdomen of the mother. Ambrose Paré, while admitting the efficiency of the several causes named by Hippocrates, believed also

¹ Breschet, *Répertoire d'Anatomie et de Physiologie*. Gaz. Méd., Paris, 1834, p. 218.

² Caillard-Billionnière, *Thèse Inaugurale*, 1828.

³ Lehoux, *Thèse Inaugurale*, 1834. Paris.

⁴ Sandiforte, *Thesis*, sustained before the Faculty of Med. of Leyden, 1836.

⁵ Bouvier, *Malad. Chron. de ap. Locomot.*, Paris, 1858.

⁶ Sédillot, *Journ. de Connais. Méd.-Chirurg.*, 1838.

⁷ Wrolik, Amsterdam, 1849, quoted by Pravaz.

⁸ Guérin, *Recherches sur les Luxations Congénitales*; par Jules Guérin. Paris, 1841.

⁹ Parise, *Archiv. Gén. de Med.*, 1842.

¹⁰ Pravaz père, *Traité Theorique et Pratique des Luxations Congénitales du Femur, suivi d'un Appenice sur la Prophylaxie des Luxations Spontanées*; par Ch. G. Pravaz. Lyons, 1847.

¹¹ Carnochan, *A Treatise on the Etiology, Pathology, and Treatment of Congenital Dislocations of the Head of the Femur*; by John Murray Carnochan. New York, 1850.

¹² R. Smith, *A Treatise on Fractures in the Vicinity of Joints, and on Certain Accidental and Congenital Dislocations*. Dublin, 1854.

¹³ Delpech, *Orthomorphie*, Paris, 1829, t. 2.

¹⁴ Heine, *Spont. und Congen. Lux.*, Stuttgart, 1842.

¹⁵ Von Ammon, *Die Angeborenen Chir. Krankheiten der Menschen, etc.*, Berlin, 1842.

¹⁶ Pravaz fils, *Lux. Congen. du Femur*, Lyon, 1847.

¹⁷ Hueter, *Klin. der Gelenkkrankheiten*, Leipzig, 1870-71.

¹⁸ Dollinger, *Arch. f. klin. Chir.*, Bd. 20, 1887.

¹⁹ Grawitz, *Virchow's Archiv*, Bd. 74, Hft. 1, p. 1, 1878.

²⁰ Kirmisson, *Rev. Men. de Chir.*, 1878, p. 498.

²¹ Kronlein, *Die Lehre von der Lux.*, Deutsche Chir., v. Billroth u. Leucke, 1882.

²² Gerdy, *Rap. sus deux Mém. du Pravaz, etc.*, Lyon, 1840.

²³ Polinière, quoted by Pravaz.

²⁴ Jalade-Lafond, *Deform. du Corps Humain, etc.*, Paris, 1829.

²⁵ Humbert and Jacquier, *de Lux. Spont. ou Symptomatiques*, Paris, 1835.

that the contractions of the womb, and violence employed by the accoucheur, were occasionally adequate to the production of the same result. He taught, moreover, that the position of the fœtus itself might favor the displacement; and that, in some instances, an articular abscess, insufficient depth of the socket, with a laxity of the ligaments, were competent to determine the expulsion of the head of the femur from its natural position. Sédillot regards a softening and relaxation of the ligaments as the most frequent cause.

Parise and Malgaigne are disposed to attribute a majority of these cases to hydrarthrosis, or water in the joints. Says Malgaigne: "For myself, after having long meditated upon this subject, I have come to think that inflammation of the joints enjoys a grand rôle, both in coxo-femoral dislocations and in many others, and even also in various congenital malformations generally ascribed to arrest of development." This writer admits, however, that it will not do to generalize too much in this matter, and that the etiology of congenital dislocations is probably as complex as that of dislocations after birth. Dupuytren thought forced flexion of the thigh in utero would explain the congenital dislocations of the hip; while Roser¹ attributes it to forced adduction.

Chaussier seems to have regarded muscular contraction, or the occurrence of an intra-uterine convulsion, as the cause of the example of congenital dislocation of both humerus and femur seen and recorded by him. Since whom Guérin has greatly extended the application of this doctrine, having embraced in the same etiologic formula all or nearly all congenital dislocations. Guérin ascribes to muscular contraction in one form or another, and to corresponding muscular paralysis, not only dislocations of the femur and other long bones, but also club-foot, torticollis, and various other deviations of the spine. He affirms, moreover, that he has established incontestably the dependence of this abnormal state of the muscular system upon the absence or disappearance more or less complete of corresponding portions of the central nervous systems.

Breschet and Delpêch maintained similar views, especially in relation to the dependence of the several varieties of club-foot upon some morbid condition of the cerebro-spinal axis. While Carnochan remarks as follows: "It appears most in accordance with science to refer the muscular spasmodic retraction, upon which congenital dislocations of the head of the femur from the cotyloid cavity depend, to a perverted condition of the excito-motor apparatus of the medulla spinalis, and more especially of that portion of it which is in direct relation with the reflex-motor nervous fibres, distributed to the pelvi-femoral muscles surrounding, and in connection with, the ilio-femoral articulation."

Verneuil regards paralysis of one group of muscles as the direct cause; in consequence of which the normal action of the opposing muscles tends to displace the bone; whilst Reclus² applies the same theory to congenital dislocations of the femur. In effect, therefore, both Verneuil and Reclus refer the abnormalities in question to the nervous centres.

Palletta ascribes these deformities solely to an original defect of the germ; and Dupuytren also declares that, in the case of a congenital dislocation of the hip, the causes are coeval with the earliest organization of the parts, and that the displacement is due rather to a defect in the depth or completeness of the acetabulum, than to accident or disease.

Dollinger adopts essentially the same theory, attributing the imperfect formation and shallowness of the cotyloid cavity to an arrest of development, and to a premature ossification of the Y-shaped cartilage which unites its three portions. Grawitz, also, recognizes arrest of development as the essential cause, but in the seven specimens he has examined he has not found premature ossification of the cartilage.

Breschet and Delpêch, both of whom, as I have already stated, refer them to some morbid condition of the cerebro-spinal axis, imagine that in consequence of this morbid condition of the nervous centres, there exists an arrest of development in the bones, muscles, ligaments, sockets, and, in short, through all the apparatus of the joint which is the seat of the deformity.

¹ Roser, *Arch. f. Klinik Chir.*, 1879, Bd. 28, Hft. 2.

² Reclus, *Rev. Mensuelle de Chir.*, 1878, p. 176.

After a full and careful consideration of this subject, I am prepared to admit the occasional agency of all the causes enumerated, and the probable concurrence of two or more in many instances; nor do I see the propriety of rejecting, as Malgaigne has done, all that large class of malformations which seem to depend upon an arrest of development, or those which appear to be due mainly or solely to intra-uterine paralysis, of both of which many examples have been reported.

As illustrating the relation which arrest of development sustains to this class of deformities, I may refer to the facts of hereditary transmission, and to the frequency with which other forms of imperfect development are associated with congenital dislocations. Cruveilhier¹ and Voss² have referred to examples in which the dislocations were accompanied with other malformations; and Grauwitz found this coincidence in seven examples seen by him, while Paré, Palletta, Schreger, Dupuytren, Robert Bouvier, and Stromeyer have noted the marked influence of heredity. Kronlein mentions two infants, a brother and sister, in both of whom there existed a congenital dislocation of one hip; and also the case of a boy, who was one of seven children, and whose grandmother presented the same malformation.

§ 1. Congenital Dislocations of the Inferior Maxilla.

Malgaigne says: "We know of no congenital dislocation of the jaw;" we are "not to accept the pretended dislocation observed by Guérin upon a *déréncéphalous* infant." The example recorded by Robert Smith he rejects also, declaring that he does "not comprehend how one can see in it a dislocation." For myself, I know of no reason why we should not take "seriously" the case mentioned by Guérin, since, so far as appears in his very brief report of the same, it might have been a true dislocation. The specimen was before the Academy, and if Malgaigne, from a personal examination, had become satisfied that a dislocation did not exist, he ought to have so informed us. But since he does not speak of having made it the subject of special examination, I shall feel compelled to accept of it as reported by Guérin. As to the objection offered to Mr. Smith's case, namely, that "aside of the complete absence of its history, the subject did not present the characteristic signs of dislocation, and the dissection discovered neither maxillary condyle nor glenoid cavity," I must reply, the dissection seems to me to have furnished such evidence that the deformity was congenital as to render its history unnecessary; the signs were characteristic, not indeed of a traumatic dislocation, but of a congenital dislocation, such as may be supposed to have been the result of an arrest of development, or of an original aberration of the germ. The following is a summary of the very complete account of this case given by Robert W. Smith (Fig. 501):

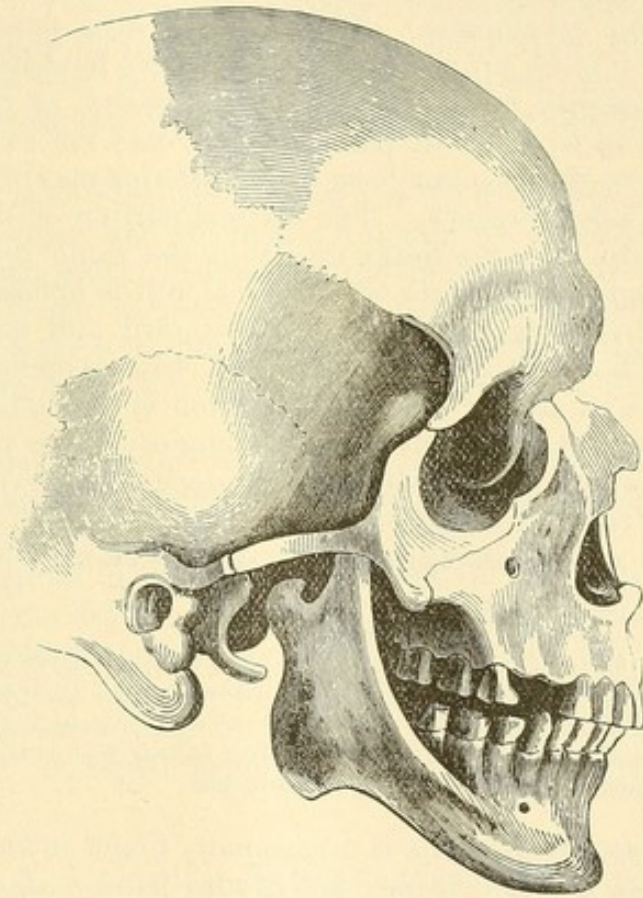
On the 5th of May, 1840, E. L., æt. 38 years, an idiot from infancy, died at the Hardwick Hospital, in consequence of gangrene of the lungs. While making the autopsy, a singular deformity of the face was discovered. The right and left sides seemed as though they did not belong to the same individual, the left being in every respect more fully developed. Upon removing the integuments, the muscles of the right side were found to be much smaller than those

¹ Cruveilhier, *Trait. d'anat. path.*, Atlas, liv. ii. pl. 2, fig. 23.

² Voss, *Inversio Vesicæ Urin.*, og lux. fem. con. hot samme individ., Christiania, 1857.

of the left, and especially the masseter. These latter having been removed also, the condition of the right temporo-maxillary articulation was carefully studied. When the mouth was closed, the external lateral ligament, instead of being directed backward, was seen descending obliquely forward, to be attached to a very imperfectly developed condyle situated at least one-quarter of an inch in front of its natural position. There was neither an interarticular cartilage nor cartilage of incrustation, the joint surfaces being invested by a thick periosteum alone; nor was there any distinct capsular ligament. Nearly the whole of the right side of the inferior maxilla was smaller than the left. The condyle was short and curved, being directed nearly horizontally inward, and resembling much more

FIG. 501.



R. W. Smith's case of congenital dislocation of the inferior maxilla.

the coracoid process than the condyle of the inferior maxilla. The coronoid process was very small and thin; and the sigmoid notch could scarcely be said to exist. The articular eminence of the temporal bone was absent, there being in its place nearly a flat surface destitute of cartilage; which surface presented upon its inner side a shallow and semicircular sulcus where the hook-like condyle of the lower jaw had played. The malar, superior maxillary, and sphenoid bones of the right side had also suffered corresponding changes of form and relative size. The motions permitted in the lower jaw were more extensive than those which it enjoys in its normal condition, that is, upon the right side the ramus could be moved very freely forward and backward, while upon the left, the condyle underwent a species of rotation upon its axis. During life the patient was observed to be constantly performing this motion, and the right side of the face was continually affected with spasmodic twitches. When the mouth was closed, the front teeth of the upper jaw projected beyond those

of the lower, and when opened the deformity was in all respects greatly increased.¹

Mr. Smith expresses his dissent from the views maintained by Ribes, namely, that the formation of the glenoid cavity is consequent upon the growth of the condyle, and that, were this process not formed, there would not exist either a glenoid cavity or an articular eminence. It is true that neither the glenoid cavity nor the articular eminence is found in the foetus. Until the seventh month of intra-uterine life there exists at this point of the temporal bone only a plane surface, and the glenoid cavity with its corresponding eminence is developed in proportion to the growth and development of the condyle. But Mr. Smith justly observes that although the development of the condyle does precede that of the glenoid cavity, "it by no means follows that the formation of the latter is due to the pressure of the former." The cavity, or rather the transverse eminence in front of the plane surface, does not exist in foetal life, because, owing to the peculiar form of the inferior maxilla at this period, its existence is not necessary. The vertical portion of the jaw (vertical only in the adult) is in the foetus nearly in the same line with the axis of the shaft, and consequently when the mouth is opened by the action of the muscles, the condyles are pressed upward and backward instead of upward and forward, as in the adult. A displacement forward cannot therefore very well occur; and the protection of the articular eminences is not required. As age advances the angles of the jaw increase, the portions upon which the condyles rest become more vertical, and finally a displacement forward would occur whenever the mouth was well opened if the articular eminences were not present to afford a sufficient protection in front.

In the case of E. L. the foetal condition of the bones upon one side remained during life, there being neither cavity nor eminence, and the condyle itself being only imperfectly developed; but the angle of the jaw had assumed the form which belongs to the adult, and the ascending ramus was vertical, consequently the condyle became somewhat displaced forward.

Chronic rheumatic arthritis is occasionally found in the temporo-maxillary articulation of old persons; and it may be important to distinguish it from congenital dislocation, with which, owing to the absorption of the articular eminence, and the consequent displacement of the condyle, it might possibly be confounded.

Says Mr. Smith: "In a majority of instances, this remarkable disease attacks those of advanced age, and is symmetrical; but occasionally it occurs during the period of adult life. In the latter case it is generally more rapid in its progress, is accompanied by greater pain, and is more liable to implicate the neck of the condyle, and the ramus of the jaw."

When the condyle is implicated it becomes enlarged, and can be felt beneath the zygoma, in front of the meatus externus. The lymphatic glands of this region are sometimes enlarged, and the progress of the malady is attended with a constant but not generally severe pain. The

¹ Robert Smith, *op. cit.*, p. 283.

deformity of the face varies according as one or both articulations are affected. When the malady is confined to one joint, the chin is thrown slightly forward, but chiefly to the opposite side, and when both are implicated, the chin is simply advanced so that the teeth project beyond those of the upper jaw. As the disease progresses, the glenoid cavity enlarges by absorption, and at length a considerable portion of the whole of the articular eminence disappears and the jaw becomes gradually displaced through the action of the external pterygoids. The disease does not extend in the temporal bone beyond the articulating surface of the glenoid cavity. The condyle assumes a variety of forms, sometimes being greatly enlarged in all its diameters, while its upper surface may be flattened or conical. The articular cartilage disappears; but Mr. Smith has never yet found any foreign bodies in the joint, and in only one instance have the surfaces been polished or eburnated as we often see in examples of chronic rheumatic arthritis occurring in the hip, knee, and other joints.

The following is an excellent summary of the diagnostic marks between congenital, accidental, and rheumatic dislocations, given by this writer:

"1. In the congenital dislocation, the mouth can be freely opened and closed; in chronic rheumatism, these motions can be performed, but not without uneasiness to the patient, an uneasiness which sometimes amounts to severe pain; in dislocations from accident, the mouth cannot be closed.

"2. An involuntary flow of saliva accompanies the accidental dislocation alone, although in some cases of chronic rheumatism there is an increased secretion of that fluid.

"3. In congenital dislocation, the teeth of the upper jaw project beyond those of the lower; the reverse is observed in accidental dislocation and in chronic rheumatism.

"4. In congenital dislocation there is no fulness in the cheek, such as the coronoid process produces in cases of accidental dislocation, and the condyle is not enlarged, as in some instances of chronic rheumatic arthritis."¹

§ 2. Congenital Dislocations of the Spine.

Of the subluxation occipito-atloidean, Guérin gives: "First. Backward, an exaggerated flexion of the head upon the front of the neck and chest, with a commencement of sliding backward of the occipital condyles upon the articular facets of the atlas. Here are two examples in foetal anencéphalous monsters. Second. Forward. Those who follow my consultations can recollect having seen last year an infant, about two or three months old, who offered a remarkable example. The head was exactly applied against the posterior part of the neck and upper part of the back. There was probably a sliding of the condyles forward, with elongation of the anterior ligaments."² The existence of the first of these varieties has since been denied by Guérin himself;³ and it will be noticed that he only speaks of the second as a *probable* subluxation

¹ R. Smith, op. cit., p. 292.

² Guérin, op. cit., 1841, p. 29.

³ Ibid., op. cit., p. 32.

forward. Neither of them can, therefore, be regarded as established. Guérin further remarks that he has observed sublaxations in the other regions of the spinal column many times; and he showed to the Academy a foetus in which the spine presented, besides the occipito-atloidean displacement, a series of angular flexions in the antero-posterior direction, with sliding of the articular surfaces.

In attempting to appreciate the value of Guérin's observations upon this point, it must be remembered that he regards all cases of congenital torticollis, and other deviations of the spine, as examples of sublaxation; and, in some sense, I think the theory of this distinguished surgeon may be regarded as correct. The amount of articular displacement between each of the adjacent vertebræ may be very inconsiderable in any such case, yet, however trivial, if it exceeds the limits of natural motion, it may properly enough be regarded as the commencement of a dislocation.

§ 3. Congenital Dislocations of the Pelvic Bones.

Bassius speaks of a diastasis of the sacro-iliac symphysis in newly-born children, and infants; but, according to Malgaigne, his account of these cases is not such as to warrant any conclusions as to the true nature of the displacements.

Congenital exstrophy of the bladder is accompanied always with a deficiency of the central and upper portions of the pubic bones, the result manifestly of an arrest of development; but these cases, of which I have seen several examples, are not properly examples of congenital dislocations, but only of diastases, the separated portions remaining in their normal position with reference to each other, except that they are not prolonged sufficiently to meet in the median line.

Guérin declares, however, that he has seen congenital displacement, or overriding of the iliac bone upon the sacrum, accompanied with coxo-femoral dislocation and curvature of the spine. The same writer mentions an example, in a foetal monster, of diastasis of the pubic bones and of the sacro-iliac symphysis, accompanied with a turning out of the pubes upon the external face of the ischium.¹

§ 4. Congenital Dislocations of the Sternum.

Seger alone has reported one example of dislocation of the xiphoid cartilage from the sternum.

A woman in the fifth month of pregnancy fell and dislocated her shoulder. Just four months after this she was brought to bed with an infant, well formed, except that, soon after it was born, the ensiform cartilage was observed to be remarkably movable, especially when the child hiccupped, to which it was very subject. The cartilage was separated from the sternum by the breadth of the little finger. No treatment was employed; the cartilage gradually became restored to its place, and in about one year it was firmly united to the sternum.²

¹ Guérin, *Gaz. Méd.*, 1851, p. 227.

² Seger, *Ephem. Nat. Curios.*, 1677, from Malg., *op. cit.*, p. 410.

§ 5. Congenital Dislocations of the Clavicle.

Malgaigne says that a congenital dislocation at the sterno-clavicular articulation has never been observed; but Guérin declares that he has established the existence of three varieties, namely:

1. A dislocation of the sternal end of the clavicle inward and forward; this extremity of the clavicle lying in front of the sternal fourchette. In illustration of which he presented to the Academy a plaster cast of a girl eight years old, in whom the displacement existed upon both sides.

2. Inward and upward. Observed by him in a girl eight years old; but which displacement took place only when the arm was moved, and through the contraction of the sterno-cleido-mastoideus muscle.

3. Backward. Of which he presented two examples in the corresponding sides of a foetal monster.

Shaw¹ reports a case of congenital dislocation of the sternal end of the clavicle upward in a girl two and a half years old.

I have already referred to Fergusson's case of dislocation of the sternal end of the clavicle forward, which occurred during birth. The end rested in front of the sternum, and could be pushed into its place with great ease; but when left alone it immediately slipped out again. Nothing was done; a new joint formed, and the child afterward possessed as much power in the one arm as in the other.²

Nadaud³ also met with a dislocation of the sternal end forward in a newly-born child which had been delivered rapidly by the breech. The arm was immobilized by a sling, and the cure took place without deformity.

Guérin says that he has seen a dislocation upward and outward at the acromial end of the clavicle in a fœtus of three months. And I have mentioned, in the chapter on Traumatic Dislocations of the Bones, one case seen by me at the end of the fourth week of life.

In regard to the treatment of either of these displacements of the clavicle, I need only remark that a reduction ought to be attempted; and, if practicable, without much confinement to the little patient, it should be maintained until the bones have become fixed in their natural positions. It is quite probable that this can never be accomplished, at least perfectly; but it will nevertheless be proper always to make the attempt.

§ 6. Congenital Dislocations of the Shoulder.

Guérin affirms that he has established the existence of three varieties of congenital scapulo-humeral dislocations, namely:

1. Dislocations of the head of the humerus downward; of which variety he presented to the Academy a plaster cast taken from a boy ten years old. The displacement existed in both arms, but was much more pronounced in the right than in the left arm. It was due wholly to paralysis of the muscles about the joint, and to elongation of the capsule.

¹ Shaw, New York Med. Record, Aug. 18; Virchow und Hirsch's Jahresbericht für 1877, p. 338.

² Fergusson, System of Surg., 4th Amer. ed., 1853, p. 203.

³ Nadaud, Bordeaux Médical, 1874, No. 42.

2. Downward and inward; complete upon one side and incomplete upon the other, in the same person. The head of each humerus was applied against the ribs, and the arms maintained in an abduction almost horizontal, under the influence of the retraction of the deltoid muscles. "The same case," Guérin remarks, "has been confirmed by Roux."

3. Subluxation upward and outward; seen on both sides in a foetal monster, which was offered to the Academy for examination; and in one arm of a youth fifteen years old, of which Guérin presented a plaster cast. "It is characterized by a sliding of the head of the humerus in the direction indicated; this sliding being favored by a corresponding displacement of the coracoid and acromion processes."¹

Malgaigne, who regards "all luxations in consequence of paralysis as essentially posterior to birth," will not admit the first example mentioned by Guérin; but, as I stated before, the objections made by Malgaigne have failed to convince me of the propriety of rejecting all of this class of reported examples. Of the second case, mentioned by Guérin as having been confirmed by Roux, Malgaigne declares that he has consulted Roux upon this matter, and that he affirms that "he has never seen a congenital luxation of the shoulder."

Robert Smith has met with but two of the forms of congenital dislocation of the humerus described by Guérin, namely, that in which the head of the humerus is displaced forward, and that in which it is displaced backward. Of the first variety he has seen several examples.

The first was in the person of A. S., æt. 29 years, who presented both a dislocation of the head of the humerus under the coracoid process of the left scapula, and pes equinus in the foot of the left leg. The muscles of the arm and shoulder upon that side were feeble and greatly atrophied. The humerus was shortened; its head being of the natural size and form, but when the arm hung by the side it dropped so far from its socket as to permit the thumb to be placed between the head and the acromion process. By pressing the humerus forward, the finger could be placed in the outer part of the glenoid cavity; and although the head could be moved about thus freely, it seemed naturally to occupy only the anterior half of the glenoid fossa.

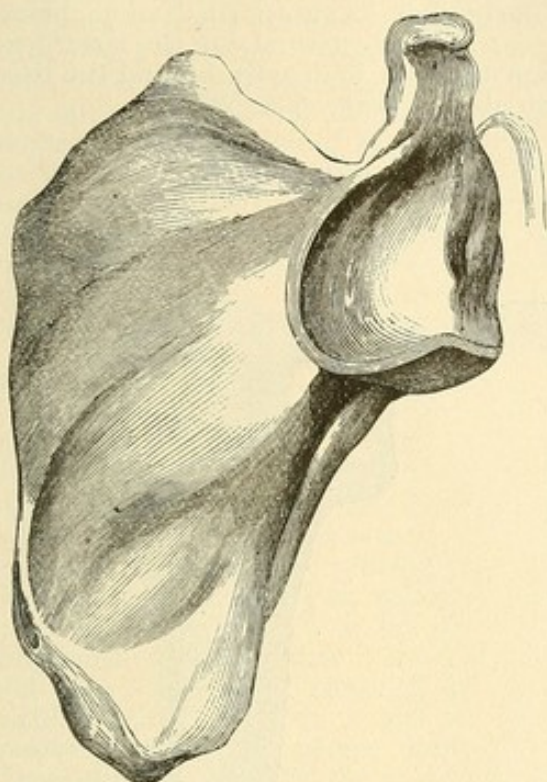
Robert Smith's second example of subcoracoid congenital dislocation was presented in the person of Mr. H., æt. 20, the condition of whose left shoulder resembled almost precisely that of Mr. S. "The deformity had existed from his birth, but became much more obvious and striking as he increased in age and stature."

In the third example the child had attained nearly the age of one year before the condition of the limb attracted attention, which was then excited, not by the deformity of the shoulder, but by the atrophied condition of the muscles of the arm. The child had never complained of pain about the joint, nor had he ever met with any accident. No doubt this was also an example of paralysis, and it is not improbable that it was congenital, but the evidence upon this point is not very conclusive. When seen by Mr. Smith, he was nine years old, the shoulder and arm presenting the same appearance as in the other cases mentioned.

The fourth was also subcoracoid and symmetrical, the same deformity existing in both shoulders. This was in the person of a female, æt. 21, who had been for many years a patient in a lunatic asylum, and who died of chronic inflammation of the meninges of the brain. Mr. Smith, who himself made the autopsy, first noticed the condition of the left shoulder. The muscles were atrophied; the head of the humerus could be felt lying under the coracoid process; the elbow projected from the side, but could be readily brought into contact with it. The right shoulder presented the same appearance, but the deformity was somewhat less, and the head of the humerus was not so directly underneath the coracoid process. From the external appearances presented by

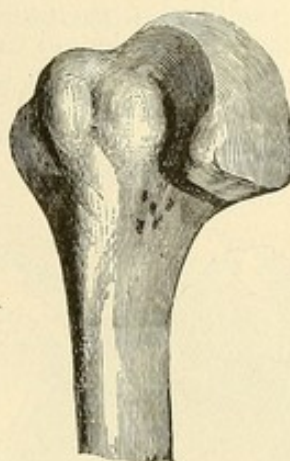
¹ Guérin, *op. cit.*, p. 30.

FIG. 502.



Double congenital subcoracoid dislocation; left scapula. (R. W. Smith.)

FIG. 503.



Left humerus of same case.

capsular ligament, which ligament included also that small portion of the original socket which remained. The head of the humerus was changed in form, being oval, and fitted, in some measure, to both the old and new sockets, upon which it seemed to rest alternately. Upon the right side, although the condition of the bones was somewhat different, the characteristic features of the deformity were similar (Figs. 502, 503).

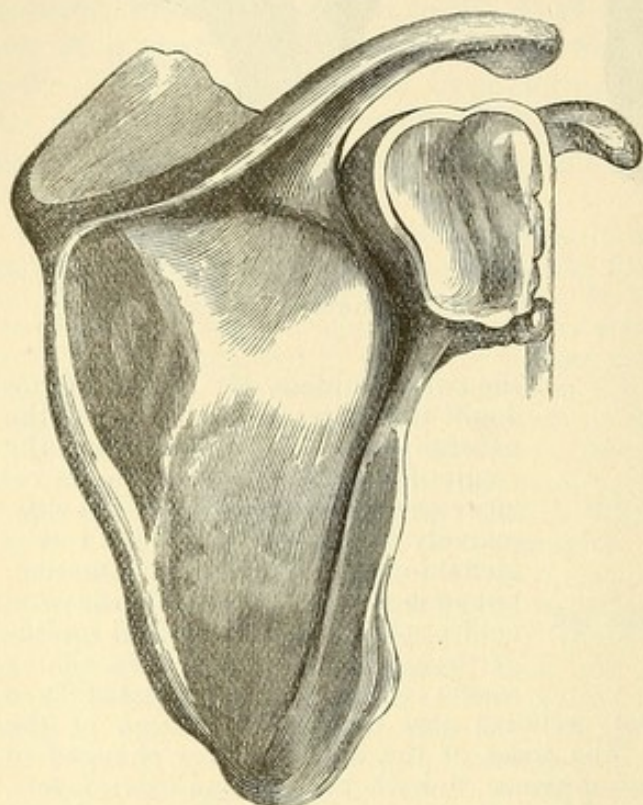
Malgaigne, who quotes Mr. Smith as saying that these dislocations must have been congenital, and for no other reason than because they were symmetrical, has scarcely done this author justice. Says Mr. Smith: "The position of the glenoid cavity, the remarkable form of the head of the humerus, the presence of a perfect glenoid ligament, the absence of any trace of disease, and the existence of the deformity upon each side, *all* indicate the original nature of the malformation."

The only example of backward dislocation seen by Mr. Smith was also symmetrical, and seems to be equally well authenticated. This was in the person of a woman named Doyle, æt. 42, a lunatic also, who died February 8, 1839, in Dublin. She had been a patient in the lunatic asylum fifteen years, and was subject to severe epileptic convulsions, which ultimately proved fatal. Mr. Smith made the autopsy on the day following her death. The convolutions of the brain were small and atrophied, as is frequently observed in idiots. The two shoulders resembled each other so perfectly, both in external appearance and in their anatomy, that Mr. Smith has only found it necessary to describe particularly the condition of one. The coracoid process was remarkably prominent, but the acromion was not so prominent as in accidental dislocations of the shoulder. The head of the humerus could be seen and felt distinctly moving with the shaft, upon the dorsal surface of the scapula. On removing the integuments, muscles, etc., no trace of a glenoid cavity was found in its natural situation; but upon the external surface of the neck of the scapula was a well-formed socket, which received the head of the humerus. This socket was covered with a cartilage of incrustation, and surrounded by a perfect capsule. The tendon of the biceps arose from the top and internal margin of the socket.

the two shoulders, Mr. Smith did not doubt that these deviations from the natural state of the parts were not the result of violence. Proceeding to remove the soft parts upon the left side, scarcely any trace was found of a glenoid cavity in its natural situation, but immediately underneath the coracoid process, upon the costal surface of the scapula, was formed an oblong socket completely surrounded by a

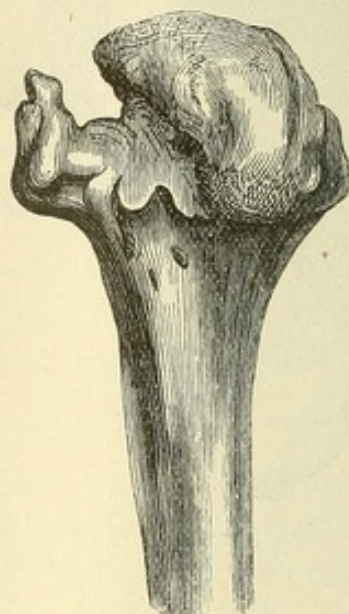
The form of the acromion process was changed; the capsule smaller than natural; the head of the humerus irregularly oval, its anterior half alone being in contact with the glenoid cavity; the great tubercle natural, but the lesser was elongated and curved, forming a process of an inch in length, around the base of which the tendon of the biceps muscle played¹ (Figs. 504, 505).

FIG. 504.



R. W. Smith's case of double congenital backward dislocation.

FIG. 505.



Right humerus of the same case.

Gaillard² relates the case of a female child whose left arm was discovered to be deformed a few days after birth, and the elbow separated from the side. Later, the arm was found to be nearly immovable, and only at the end of four years was the dislocation recognized; but no attempt at reduction was then made. When sixteen years old, she was seen by Gaillard, who found the head of the humerus in the infraspinous fossa. The scapula, clavicle, and arm were preternaturally small; the forearm, although well developed, could not be completely extended nor supinated. Despite these unfavorable circumstances, Gaillard determined to make an attempt to accomplish the reduction. Four times in the space of eight days he submitted the arms to extension made at right angles with the body, by means of sixteen-pound weights, the extension being continued from twenty to twenty-five minutes, and occasionally his own exertions being added to the weights. On the fourth attempt the head of the bone was drawn gradually forward, and by a rotary motion it was finally made to slip into its socket; but became immediately displaced. The next day Gaillard reduced it anew, and retained it in place one hour. Six days later it was again reduced, and, by the aid of bandages, permanently retained in place. The slight pain and swelling which followed soon disappeared; and, by the aid of careful exercise, at the end of two years the arm had increased in length, and the patient could use the arm and hand so much better than before, as to encourage a hope that the recovery would be complete.

¹ Robert W. Smith, *op. cit.*, p. 266.

² Gaillard, *Mém. de l'Acad. de Méd.*, 1841, from Malgaigne, p. 569.

Aristide Rodrigue,¹ of Holidaysburg, Penna., gives the following brief account of a case of intra-uterine dislocation of the shoulder, complicated with a fracture of the forearm: "The woman, when about four months gone with child, fell on her left side, striking a board, and felt herself much hurt at the time; at the full period she was delivered of a full-grown large boy with the following deformity, dislocation of the humerus into the axilla; fracture of both bones of the forearm of left side, lower third. Dislocation could not be reduced; union of the bones of the forearm by ossific matter complete; bones passing each other, and hand at an angle of about 40°; the child did well otherwise; now, four years old, strong and healthy; humerus has grown nearly apace with the other; forearm has not, and remains short and deformed as at birth; the hand is of the same size with that of the sound side."²

I was asked to examine the arm of J. H., æt. 7 years, May 12, 1878, who had a subspinous dislocation of the left humerus. The parents stated that the birth of the child was premature, and that he was delivered with forceps, and as a head presentation. On the following day a swelling was noticed over the shoulder. On examination I found the head of the humerus resting upon the dorsum of the scapula below the spine. The scapula is smaller than the opposite scapula, and the arm is one and a half inches shorter than the other. The coracoid process is very prominent, and the humerus somewhat rotated inward. He uses the arm nearly as well as the other, and in this respect it is yearly improving. It is difficult to say positively whether this was strictly a congenital displacement, or whether it was caused by some violence employed in the act of delivery. Jenni³ has recorded an example of congenital dislocation into the axilla of the left arm in a girl six years old. The child at birth occupied a position across the pelvis, demanding the intervention of the accoucheur. From the time of birth the arm hung inert beside the body. Both the left arm and forearm were somewhat smaller in diameter and shorter than the same portions of the right. Jenni reduced the dislocation ten times in succession, but it was as often reproduced. He then applied a plaster dressing, and left it on fifteen weeks, when he substituted a roller bandage, which was permitted to remain some time, after which the dislocation was not reproduced.

Küster,⁴ in a case of double congenital dislocation seen in a child one year old, and whose arms were seriously maimed in consequence, proposed to open the articulation and restore the bone to place. We are not informed whether he carried his intention into effect.

§ 7. Congenital Dislocations of the Radius and Ulna Backward.

It is not uncommon to meet with a slight subluxation backward of these bones in feeble and newly-born infants; which condition is probably due to a relaxation and elongation of the capsule. It is characterized by a preternatural mobility of the joint, and especially by the circumstance that the limb is capable of abnormal extension, or flexion backward, as it is sometimes called. Guérin has seen this condition more advanced, the bones of the forearm having actually overlapped somewhat upon the lower end of the humerus, so that the articular surface of this latter presented itself in the fold of the elbow. This was especially observed in a girl of 14 and a boy of 13 years, and also in the two arms of a foetal monster.⁵

Chaussier relates that a young woman, at the commencement of the ninth month of pregnancy, perceived suddenly movements of the fœtus so violent that

¹ Amer. Journ. Med. Sci.

² Rodrigue, loc. cit., Jan. 1854, p. 272.

³ Jenni, Corresp. Blatt für Schweiz. Aerzte, No. 19, p. 580, 1er, Oct. 1879.

⁴ Küster, Berliner klin. Wochenschrift, No. 1, p. 9. 6 janv. 1879.

⁵ Guérin, op. cit., p. 31.

she almost lost consciousness. These movements were repeated three times in the space of six minutes, after which everything returned to its natural order, and the accouchement took place naturally and at the usual term. The infant was pale and feeble, and presented a complete backward dislocation of the radius and ulna.¹

§ 8. Congenital Dislocations of the Head of the Radius.

This dislocation has been reported by Dupuytren, Cruveilhier, Sandifort, Adams, Dubois, Verneuil, Deville, Robert Smith, Guérin, and Hayem, most of which were in the direction backward, some outward, but only one of them forward; some were double, the same deformity being presented in both arms, and others were single. In a few examples the dislocations were complicated with a consolidation of the radius to the ulna, and in others with a deficiency of the ulna or with some deformity indicating its congenital origin. Of the symmetrical or double dislocation backward Dupuytren furnishes the following example, presented to him in 1830, by M. Loir:

"The abnormal position which the head of either radius had assumed was at the back part of the lower extremity of the humerus, beyond which it extended for the space of at least an inch. This disposition of parts was absolutely identical on the two sides, and had all the characters of a congenital affection."²

In January, 1866, J. F., æt. 19, was admitted to the Bellevue Hospital, laboring under a general scrofulous cachexy, in whose person I found a congenital dislocation of the heads of both radii, outward. The dislocations are complete. The ulna are in place and of natural form, but their articulations at the wrist are loose. The remark applies to all other joints in the body. The power of pronation and supination is unimpaired, as well, also, as the power of flexion and extension.

In the example of outward dislocation mentioned by Deville, there was an almost complete absence of the ulna, the head of the radius mounting upward more than three centimetres above the level of the articulation.³

Guérin, who has described an example of a forward dislocation, says it was observed by him in a girl of 7 years, and that it was symmetrical. The two radii lay in front of the humeri, near the coronary fossæ.⁴ Hayem⁵ has also reported an example of double forward dislocation, which he believed to be congenital.

§ 9. Congenital Dislocations of the Wrist.

Guérin gives three forms of this dislocation. First, a dislocation forward, characterized by a sliding of the wrist before the bones of the forearm, and by the projection posteriorly of the lower ends of the radius and ulna; seen in an infant of six months, and in two adults. Second, backward and upward; seen in a child of six years, and accompanied with an incomplete paralysis of all the muscles of the forearm and hand. Third, backward and outward; in a girl of 14 years, accompanied with incomplete paralysis.⁶ Guérin has also seen three examples of dislocation outward in foetal monsters, and one of dislocation inward, as the

¹ Chaussier, from Malgaigne, *op. cit.*, t. ii. p. 268.

² Dupuytren, *Injuries and Dis. of Bones*, p. 117.

³ Deville, *Bulletin de la Soc. Anat.*, p. 153.

⁵ Hayem, *Bull. Soc. Anat. de Paris*, 1864, p. 56.

⁴ Guérin, *op. cit.*, p. 31.

⁶ Guérin, p. 717.

result of arrest of development. Robert Smith believes that the case of simple dislocation of the wrist or of the carpus forward, mentioned by Cruveilhier in his *Anatomie Pathologique*, was an example of congenital dislocation; and he relates two other cases equally remarkable which came under his own observation.

One was in the person of D. O'N., a lunatic and epileptic, who died when 36 years old. Both upper extremities were deformed from birth; the right presenting an example of dislocation of the carpus forward, and the left of dislocation of the carpus backward. The dissection showed that there had been an arrest of development, especially in the bones of the forearm and carpus. The second was in the person of a young woman who died of phthisis in the Richmond Hospital; the right wrist presenting an example of congenital dislocation of the carpus forward from arrest of development also.¹

Marrigues describes a very singular congenital displacement which he found upon a newly born infant. The radius and ulna were widely separated below, and in the interspace was lodged the whole of the first range of the carpal bones; the hand being strongly turned inward.²

§ 10. Congenital Dislocations of the Fingers.

Chaussier found in a foetus the last three fingers of the left hand dislocated at the metacarpo-phalangeal articulation. The thighs, knees, and feet were also dislocated.³

A. Bérard speaks of an incurvation backward of the last two phalanges of the fingers as having been occasionally seen in newly born children of the female sex; and Malgaigne adds that he has himself seen a woman who had, from birth, all the *phalangettes* carried backward to an angle of 135° , leaving the heads of the phalanges projecting forward under the skin.⁴

Robert has seen, in a girl 6 years old, a congenital lateral dislocation of the *phalangette* of the index finger, which was inclined outward at an obtuse angle. The external condyle of the lower extremity of the proximal phalanx was slightly atrophied, and the internal presented a corresponding projection. Robert cut the internal lateral ligament by a subcutaneous incision, but without any favorable result.⁵

§ 11. Congenital Dislocations of the Hip.

Dupuytren thought that double dislocations of the hip-joint, as congenital accidents, were more common than single dislocations, but in the experience of Pravaz the rule has been reversed, he having met with but four double dislocations in a total of nineteen.

They have been noticed much oftener in females than in males. Of forty-five examples mentioned by Dupuytren and Pravaz, only seven or eight were males. The following table, constructed by Poincot from statistics gathered by Drachmann, Pravaz, and Krönlein, respectively, ought to be accepted as conclusive

¹ R. Smith, op. cit., pp. 238, 251.

² Marrigues, Malgaigne, from Journ. de Méd., t. ii. p. 31, 1775.

³ Chaussier, Malgaigne, op. cit., t. ii. p. 751.

⁴ Bérard, Malgaigne, op. cit., p. 773.

⁵ Robert, from Malgaigne, op. cit., p. 773.

evidence that unilateral dislocations are more frequent than bilateral, and that these deformities are much more frequent in females than in males; while as regards its occurrence in the right or left limb, no marked preference exists for either.

Observations.	Limits of observation.	Males.	Females	Unilateral.			Bilateral.
				Left.	Right.	?	
A. G. Drachmann (77)	1865-1880	10	67	24	24	...	29
Pravaz (107)	1863-1878	11	96	27	29	...	51
Krönlein (90)	1875-1880	14	76	32	22	5	31
		35	239	83	75	5	...
		274		163			111

Congenital dislocations of the femur may be complete or incomplete. Of the complete dislocations, four varieties have been noticed.

Upward and backward, upon the dorsum ilii. This variety is by far the most common.

Upward and forward; the head of the femur resting upon the eminentia ilio-pectinea.

Downward and forward into the foramen thyroideum; of which variety Chaussier alone mentions one example; but Delpech found in an infant, born paralytic, the head of the femur lodged habitually *near* the foramen thyroideum.

Directly upward; seen by Guérin, Pravaz, and others; the head of the femur being placed immediately without the anterior inferior spinous process of the ilium.

Guérin has observed, moreover, a single variety of subluxation; characterized by the incomplete displacement of the head of the femur in the direction upward and backward, so that it rested upon the edge of the cotyloid cavity: "observed often in newly born children, and with those in whom the muscular dislocations are effected spontaneously after birth."

In March, 1865, I saw a child who was born in 1860, with dislocation of both knees and both hip-joints. The legs at the time of birth were doubled forward upon the thighs, the heads of the tibias resting upon the front of the femurs, one inch above the condyles, the thighs being at right angles with the body and the feet touching the abdomen. The knees were drawn closely together. The dislocation of the heads of the femurs was not at this time recognized. By constant pressure Dr. Palmer had succeeded, at the end of one year, in restoring the legs to position, the thighs remaining flexed; but when two years old she began to walk, with her body bent forward. The displacement of the hip-bones was then first discovered. When four years old the sartorius and tensor vaginæ femoris were severed, but with very little benefit. At the time of my examination she was five years old. The thighs were still flexed and adducted; by pressure upon the knees the femurs could be slid upward and backward upon the ilium one inch; on rotating the femurs the trochanters were observed to move upon a very short radius, indicating the entire absence of head and neck. She walked with the gait peculiar to these conditions.

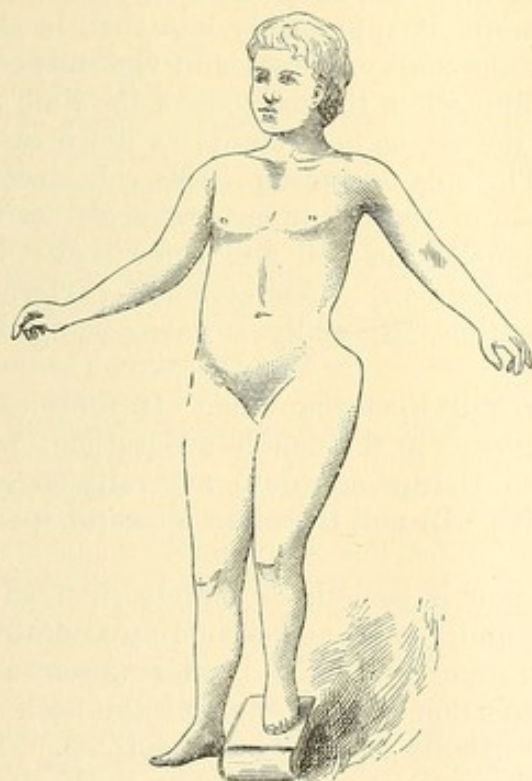
Both Delpech and Guérin have called attention to two varieties of what the latter terms pseudo-luxations; of which the first simulates a dislocation upward

and backward, and the second a dislocation downward and forward. In these examples, the extreme adduction or abduction of the thighs might lead to a belief that the bones were dislocated, when in fact the abnormal position of the limbs is due only to muscular contraction, without actual articular displacement.

In the remarks which follow I shall have special reference to that form of congenital dislocations of the femur in which the head of the bone rests upon the *dorsum ilii*, as being that which will be presented in a vast majority of cases, and which, characterized by the same general phenomena, may be regarded as typical of all the others.

Symptomatology.—First. When the dislocation is double. In these examples the deformity is often found to be absolutely symmetrical; the opposite limbs being of precisely the same length, and in the same relative positions; a circumstance which, when it exists, may render the diagnosis more difficult, or may cause it to be for a long time entirely overlooked. It is in such cases especially that the deformity is not usually discovered until the child begins to walk.

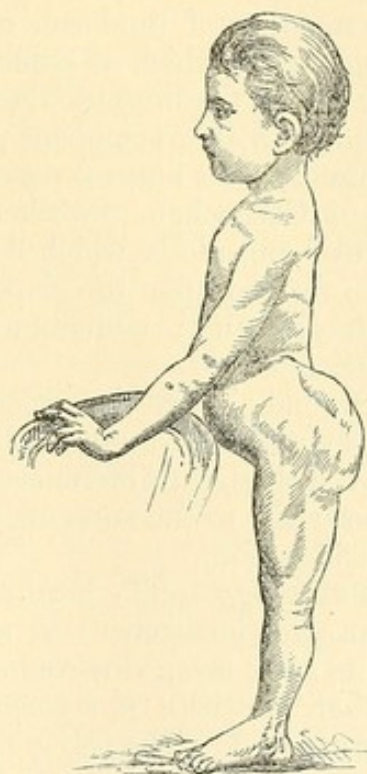
FIG. 506.



Single.

Congenital dislocations of hip.

FIG. 507.



Double.

The first circumstance which would naturally arrest our attention, if the person who is the subject of this double dislocation is stripped and placed erect before us, is the great apparent length of the arms and of the body in comparison with the lower extremities. We may next observe that the great trochanters are carried upward and backward, so as to make a remarkable projection in this direction; the lumbar portion of the spinal column is thrown very much forward and the dorsal portion backward. The thighs incline inward, so as almost to cross each other; the whole of the lower extremities are imperfectly developed and feeble;

the toes are generally pointed directly forward, or they may be noticed to turn inward (Figs. 506, 507).

When the person stands, and his limbs are not in motion, the heel is usually brought down fairly to the floor; but in walking, and especially in the attempt to run, he touches only the balls and toes of his feet. "When they are about to walk," says Pravaz, "we see them lift themselves upon the points of the feet, to incline the superior part of the trunk toward the member which is about to support the weight of the body, and to lift the other from the ground with an effort, in order to carry it forward. At this moment one of the trochanters, that which corresponds to the column of sustentation, appears to approach the iliac crest more nearly than when the patient is standing upon his two feet." In consequence of which mobility of the thigh-bones the patient assumes a peculiar waddling gait which is not only ungraceful, but exceedingly fatiguing. The difficulty of progression is, however, very variable in different persons. Sometimes the patient requires no aid whatever, and at other times he cannot walk without assistance. Generally it increases with age. It is especially deserving of notice that in rapid progression the mobility of the heads of the femurs is appreciably less than in slow progression, which is explained by the more constant and vigorous contraction of the muscles about the joint, when the motions of the limb are rapid. In the recumbent posture, the thighs may be drawn down easily to almost their natural positions. The only exception to this rule, according to Carnochan, "is when the head of the femur has escaped from the natural capsule in which it was originally inclosed, and a new socket has been formed upon the dorsum of the ilium." Abduction is performed with difficulty; adduction and rotation, especially inward, being less restricted.

Second. When the dislocation is only upon one side. In these cases the symptoms are essentially the same as in the double dislocation; with only such slight differences and peculiarities as would naturally suggest themselves to the surgeon, and which will not, therefore, demand special consideration.

Pathology.—The head of the femur is sometimes merely changed in form and consistence, the neck also undergoing corresponding alterations in its size, form, direction, etc.; at other times the head is absent altogether, and with it a considerable portion of the whole of the neck has disappeared. The pelvic bones are usually more or less deformed. The acetabulum may be entirely deficient, or it may present itself as an irregular bony protuberance, without cartilage, fibro-cartilage, or ligaments. Sometimes it exists as an oval or triangular cavity, which is expanded at its superior and posterior margin into a distinct fossa, where the head of the femur, descending from the dorsum ilii, occasionally rests. A new cavity is formed usually upon the side of the pelvis, which is shallow and without an elevated margin, or it may be deeper and more complete in its construction by the addition of an osseous border. In either case the new socket is often lined with a true periosteum and synovial membrane; but not unfrequently it is unprotected by any soft tissue, the surface being hard and polished like ivory.

The head of the femur, having escaped from its original capsule,

through a button-like opening, rests in this socket constantly. In still other examples the head of the femur remains within its capsule, and may be observed to play backward and forward between the two sockets; or the head and neck being absorbed, and the capsule remaining entire, the latter is converted into a long, narrow sac, somewhat contracted in its centre; or finally into a firm ligamentous cord, which being attached to the stunted upper extremity of the femur, limits its motions in the direction of the crest of the ilium. In this case no new socket is formed. A portion of the pelvi-femoral muscles are contracted, in consequence of an approximation of their points of origin and insertion, and remaining in a state of comparative, if not absolute, inertia, they become atrophied, or pass into a condition of fatty degeneration; while other muscles, in consequence of the increased labor which they have to perform, become hypertrophied, or degenerate into a fibrous tissue.

Treatment.—The treatment of this deformity has been the subject of much discussion from an early period, but as yet no definite method has been established. Dupuytren studied the treatment quite thoroughly, and his observations are important. He says:

“When we call to mind the natural proneness which the heads of thigh-bones have to ascend to the external iliac fossæ, and that this tendency is partly due to the superincumbent weight of the body, and in part to muscular action, a just conception may be formed of the indications on which the employment of palliative remedies should be founded. The object should be to relieve the lower limbs of the superincumbent weight on the one hand, and on the other to moderate the muscular action. Both of these indications are in part fulfilled by repose; and the attitude most conducive to this effect is the sitting posture, in which the weight of the upper part of the body is not transmitted to the lower extremities, but is centred in the tuberosities of the ischia. Therefore, laboring persons afflicted with this infirmity should be recommended to adopt a sedentary occupation, as a calling which requires much standing and walking about would dangerously aggravate their deformity. Yet one would scarcely be willing to condemn such individuals to perpetual repose; and to avoid this it is necessary to discover some means for diminishing the inconveniences which attend the upright posture, the act of walking and other exercises. Experience has taught me hitherto but two methods of obtaining this important object: the first consists in the daily employment of a perfectly cold bath, in which all the body should be immersed for the space of three or four minutes, the head being protected by an oiled-silk cap; the water may be fresh or salt; and the only precautions necessary to take are to avoid bathing when the body is in a state of perspiration, or when the catamenial discharge is present. These baths have a local, as well as general, tonic effect. The second method consists in the constant use, at least during the day, of a belt, which embraces the pelvis, fitting closely over the great trochanters, and keeping them at a constant height, so as to bind the parts together, and prevent that continual unsteadiness of the body which results from the loose connections of the heads of the thigh-bones. For the proper fulfilment of these indications, certain precautions are necessary in the construction of this cincture; in the first place, it should occupy the narrow interval between the crest of the ilium and great trochanters, completely filling this space, and therefore being about three or four fingers' breadth, according to the age and size of the patient. It should further be well padded with wool or cotton, and covered with doeskin, so that it may not abrade the parts to which it is applied; and there should be a piece let in on either side, so as to receive and support the trochanters without entirely covering them; it should be buckled behind, and padded straps be carried under the thigh, and across the tuberosity of the ischium, on either side, to prevent the zone from slipping up. I do not mean to assert that I have ever succeeded in completely getting rid of

the inconveniences of congenital dislocations of the thigh-bones, but I have prevented their increasing, and have rendered supportable what I could not cure. The testimony of some patients to the value of this treatment has been of a most unequivocal character; for being worried by the pressure of the belt, they have laid it aside, but have speedily restored it again, as they found that without it they had neither a sense of firmness in the hip nor confidence in walking."

In relation to which opinions the same excellent writer subsequently made the following candid admission: "I at first thought that no benefit would be derived in these cases from the employment of continual traction on the lower extremities, for reasons already stated; but the experiments of MM. Lafond and Duval tend to throw some doubt on the correctness of this conclusion. These distinguished practitioners tested the influence of extension, in their orthopædic institution, on a child eight or nine years of age, who was the subject of double congenital dislocation of the hip; after the uninterrupted employment of this treatment for some weeks, I satisfied myself that the limbs had resumed their natural length and direction; but I was not a little astonished to find that after extension had been persisted in for three or four months continuously, the greater part of the beneficial results remained for several weeks undiminished. It would be idle, it is true, to generalize on this single case; but as an isolated example of the utility of extension it is interesting, and it may be the forerunner of more important results."¹

Since which time Humbert and Jacquier, who, as well as Duval and Lafond, confined themselves to the treatment of deformities, claim to have met with equal success in the management of these cases by extension alone; and, still more lately, Guérin, of Paris, and Pravaz, of Lyons, by the adoption of the same general principle more or less modified, have added new triumphs and greatly enlarged its application. Other surgeons have confined their efforts to the reduction of the dislocation, and they have, consequently, abandoned all those cases in which, owing to the complete absence of the natural socket, or to the want of sufficient mobility in the limb, the reduction was deemed impossible; but Guérin has gone a step farther, and has sought to establish a new socket upon some point of the pelvic bones as near as possible to its natural articular fossa.

"The means which I adopt," says Guérin, "are based upon a recognition of the processes which nature employs for the attainment of the same purpose, and of which mine are but an imitation. I have shown that the essential condition of the formation of artificial cavities is perforation of the articular capsule, and the placing in contact of the luxated extremity with an osseous surface, and that the condition of the maintenance of this abnormal rapport is the intimate adherence of the borders of the rent with the circumference of the new cavity. Now it appeared to me that art could realize, in all points, the conditions which preside at the spontaneous formation of artificial joints. To this end I commence by practising under the skin, and at the point corresponding to that where it is most convenient to fix the luxated extremity, scarifications of the capsule, down to the bone to which it is attached. By this means the dislocated extremity is placed in immediate contact with the bony surface upon which it reposes. It makes upon this point a beginning of the work of organization resulting from the adhesion and fusion of the scarified points with the corresponding points of this surface. Then, in order to circumscribe and imprison the luxated extremity, in this place of election, I practise all about deep scarifications, which tend to excite the same work of organization and to establish fibro-cellular adhesions between the incised borders of the capsule and the contiguous bony surfaces. Finally, when the fibro-cellular adhesions are supposed to be sufficiently solid to resist the movements of the new articulation, I pro-

¹ Dupuytren, *op. cit.*, pp. 176-178.

voke, little by little, the development of the cavity destined to embrace the luxated extremity by the means which Nature herself employs in analogous circumstances; that is to say, by circumscribed and frequent movements of this articulation."¹

The treatment ought to be commenced as early as possible, no examples of success having been recorded in persons over fifteen years of age; while the youngest child whose treatment is reported as successful was three years of age. For the purposes of making the requisite extension, and of maintaining the bone in place, Pravaz (who does not, however, adopt Guérin's practice of establishing for the head of the bone a new socket, but only seeks to reduce and maintain it in its old socket) has invented several forms of apparatus adapted to the different stages of progress in the treatment. Heine, of Cannstadt, Guérin, and others, have also suggested special contrivances for the same purpose; but no surgeon who understands fully the principle upon which the cure is supposed to be accomplished, will be at loss for apparatus suitable for making the necessary extension, or for maintaining the reduction when once it has been effected.

The length of time required for the completion of a cure, where a cure is possible, must vary according to the age and health of the patient, and according to the pathological condition of the joint, and may be found to extend from a few months to one or more years. It is unnecessary to say that where the accomplishment of the cure demands a period of several years, the treatment must be intermittent and greatly varied, so as to suit all the changing circumstances in the condition of the patient.

Finally, if after a fair trial we fail to accomplish a cure, or if the condition of the child will not warrant even the attempt, we ought as far as possible to seek to prevent an increase of the deformity by such means as our ingenuity may suggest, or by such judicious appliances and general management as we have seen recommended by Dupuytren.

South says that he has seen one case of double dislocation in which the walking was at first extremely difficult, but from the fifteenth year and onward the patient so improved that at the twentieth year scarcely any trace of the peculiar gait could be discovered.²

[In addition to the methods of treatment above mentioned, resection has been successfully performed by Rose; Margary deepened the acetabulum by chiselling, and then replaced the head, but his patient died of pyæmia; Paoli deepened the cavity and diminished the size of the head with the effect of reducing the shortening by nine and a half centimetres. The most successful treatment recently instituted is that of Dr. Buckminster Brown,³ of Boston, who kept up continuous traction for thirteen months with the effect of quite restoring the form and walk of the patient.]

§ 12. Congenital Dislocations of the Patella.

Palletta found a dislocation in the cadaver which he supposed to be congenital.⁴ Michaëlis has reported two cases; one in a young man of

¹ Guérin, *op. cit.*, pp. 81-83.

² South, Note to Chelius, *op. cit.*, vol. ii. p. 245.

³ Brown, *Boston Med. and Surg. Journ.*, June 4, 1885.

⁴ Palletta, *Exercitationes Pathologicæ*, p. 91.

seventeen years, and the other in a girl of fourteen, each of whom affirmed that it had existed from birth.¹ Both of these examples presented themselves at the hospital on account of hydrarthrosis of the knee-joints, and Malgaigne, who had himself seen a similar case, is disposed to regard them all as examples of pathological rather than congenital dislocations. Périat reports a case in which the dislocation was only produced by walking, and in relation to the authenticity or pertinence of which Malgaigne seems also to entertain a doubt.²

South says that he has seen a congenital dislocation of both legs, in an aged man. The patellæ rested entirely upon the outer faces of the external condyles, leaving the front of the knee-joint completely uncovered. When the limbs were extended the patellæ could be easily made to resume their natural positions, but on the patient's making the slightest movement they were again displaced. The knees were very much inclined inward, the feet outward, and his gait was difficult and unsteady.³

Dr. Samuel G. Wolcott, of Utica, N. Y., informs me that he has under observation a case similar to the one reported by South, in a healthy and otherwise well-formed and well-developed boy, æt. 4. "When the legs are flexed the patellæ slip outward upon the external condyles of the femurs, and on extending the legs the patellæ resume their positions in front of the knee-joints. This occurs at every step he takes. The knees are strongly inward, and the feet outward. His step is very insecure, and if accidentally he hits his feet or legs against anything in walking, he invariably falls."

The most remarkable example, however, has been reported by Dr. E. J. Caswell, of Providence, R. I., inasmuch as no less than five members of the same family have double congenital dislocations of the patellæ. The man who was the subject of Dr. Caswell's special examination is 43 years old, and possessed of a good constitution. The patellæ lay upon the outer condyles, and are movable, performing their functions nearly as well as if placed in their proper positions. He walks without difficulty upon level ground, or upon an ascending plane, but great caution is required in descending. The right patella is longer and less movable than the left, and the muscles of both of his lower extremities are small. "In addition to his labor as an operative, he cultivates a small farm." Dr. Caswell examined his son and found the same malposition, but less marked than in the case of the father. The father then stated that his own father, his sister, and the son of his half-brother by the same father, had a similar deformity.⁴

Servier⁵ relates a case of congenital dislocation of the patella associated with other deformities, and both the father and the brother had dislocations of the patella. Zielewicz⁶ has collected eight cases of congenital outward dislocation. To these examples P. Berger⁷ has added three others. Holthouse⁸ mentions a case seen by himself, and Lannelongue⁹ reports a similar case.

§ 13. Congenital Dislocations of the Knee.

The head of the tibia has been found, at birth, dislocated forward, backward, inward, outward, inward and backward, outward and backward, and simply rotated inward. Most of these dislocations were in-

¹ Michaëlis, *Rev. Méd. Chir.*, tom. xv. p. 65.

² Périat, Malgaigne, *op. cit.*, tom. ii. p. 932.

³ South, *Note to Chelius*, *op. cit.*, vol. ii. p. 247.

⁴ Caswell, *Amer. Journ. Med. Sci.*, July, 1865.

⁵ Servier, *Gaz. Hebd. de Méd. et de Chir.*, Avril 5, 1872.

⁶ Zielewicz, *Berliner klin. Wochens.* t. 6, p. 25, 1869.

⁷ P. Berger, *Art. Rotule*, *Dict. Enc. Sc. Méd.*, 3d ser., t. 5, p. 360.

⁸ Holthouse, *The Lancet*, Aug. 24, 1872, vol. ii. p. 258.

⁹ Lannelongue, *Bull. Soc. de Chir. de Paris*, 1880, p. 236.

complete; and of them all, the dislocation forward has been observed much the most often. A subluxation forward of the head of the tibia has been seen by Guérin in a foetal monster, accompanied with extreme retraction of the extensor muscles of the leg.¹ Cruveilhier has dissected a foetus affected with a similar subluxation.² In these examples the displacement forward at the articular surface was but slight, and the anterior flexion of the limb inconsiderable; but when the dislocation is complete, or nearly so, the deformity is in all respects very much increased; as the following examples will illustrate.

Dr. D. H. Bard, of Troy, Vermont, has reported an example of complete anterior dislocation of the tibia, seen by himself, in a newborn infant. The leg was found drawn forward upon the thigh at an acute angle, so that the toes pointed toward the face of the child, and the bottom of the foot was directed forward. By the application of moderate force, the limb could be straightened and even flexed completely. These motions inflicted no pain. It was especially noticed that in bringing down the leg from its position of extreme anterior flexion (extension) more force was required in the first part of the manœuvre than in the last; and that if, having brought the leg down, it was left to itself, it immediately resumed the abnormal position, moving at first slowly, but after a time much more rapidly. The limb was confined by bandages for a short time, and it did not afterward show any disposition to return to its unnatural position. The child did well, and when it began to use its legs, no difference could be discovered between them.³

J. Youmans, of Portageville, N. Y., reports a similar case which occurred in his own practice. A healthy woman was delivered, on the 16th of August, 1859, of a full-grown female child, whose left knee was so completely dislocated that the toes rested upon the anterior part of the thigh near the groin. Dr. Youmans immediately took hold of the limb and brought it to its natural form, but as soon as he relinquished his hold, it flew back to its original position. Having again straightened the leg it was retained in place easily by two pieces of whale-bone tied upon each side of the thigh and body. Some soreness and swelling ensued, and it was some weeks before the splint could be safely removed. At the time of the report, October 11, 1860, the child was using the limb with as much freedom and dexterity as other children of her own age. In the report particular attention is called to the disposition on the part of the limb to resume its unnatural position with a spring, showing contraction of the anterior muscles of the thigh; to the fact that the patella of this knee was smaller than the other, and that the skin on the front of the knee was wrinkled as it is usually back of the knee in fat children.⁴

I have mentioned a case of congenital forward dislocation of both tibiæ which came under my observation, in the section on congenital dislocations of the hip, and I have recently seen a case of congenital subluxation of both tibiæ backward, occasioned by contraction of the hamstrings. Section of the muscles restored the bones nearly to their normal position.

Chatelain was consulted in relation to a similar case, in which the restoration of the limb to its natural position was also easily effected, and by means of three metallic splints, applied during about fifteen days, the cure was consummated. Chatelain directed, however, that the leg should be kept flexed upon the thigh eight days longer.⁵

Kleeberg found a child with the leg so much flexed forward (extended) upon the thigh that the popliteal region became the lowest point of the limb; in front and above the articular extremity of the tibia could be felt, and the condyles of

¹ Guérin, *op. cit.*, p. 33.

² Cruveilhier, *Atlas de l'Anat. Patholog.*, 2e livr., pl. 2.

³ Bard, *Amer. Journ. Med. Sci.*, Feb. 1835, p. 555, from *Boston Med. and Surg. Journ.*, Nov. 26, 1834.

⁴ Youmans, *Boston Med. and Surg. Journ.*, Oct. 25, 1860, vol. lxiii. p. 250.

⁵ Chatelain, *Bibliothèque Méd.*, tom. lxxv. p. 85.

the femur made a corresponding projection behind into the popliteal space. This was plainly an example of complete dislocation; and, contrary to what was observed in Bard's case, flexion of the limb backward was difficult and painful. The treatment was commenced by securing the limb in a straight position by means of a splint and roller; subsequently, Kleeberg carried the limb back to an obtuse angle, and finally, it was kept eight days in a position of extreme flexion. A complete cure was said to have been accomplished in about two weeks.¹

Richardson and Porter² report a case of congenital dislocation of the tibia forward, in which the leg was carried to a right angle with the thigh. Reduction was easily effected and maintained by a roller. The cure was effected in about fourteen days. They report also another case, in which the anterior hyperextension was such that the leg could be laid upon the thigh. The cure was effected in ten weeks by the same means.

Bertin³ found a child at birth with a displacement similar to the second example seen by Richardson and Porter, and in whom, under the use of massage and bandaging, all traces of the deformity disappeared in fifteen days. At the end of seven years the cure remained complete.

In a case seen by Motte,⁴ where the heel touched the corresponding shoulder, the leg turned on its axis, the reduction was easily effected, and being maintained by a bandage, the cure was effected in about fifteen days. After three years no traces of the deformity existed, and the functions of the limb were perfectly restored.

Moos⁵ saw in a child two and a half years old, a congenital displacement, in which the leg was extended forward to a right angle with the thigh. The dislocation had been reduced when the child was six weeks old, but in spite of an apparatus continuously applied, there still continued a tendency to subluxation forward, the knee inclined backward and the foot was everted.

Guéniot⁶ communicated to the Surgical Society of Paris two examples of congenital incomplete forward dislocation of the tibia. In both cases a cure was speedily effected by very simple means. At the same séance Guéniot presented a case observed by Périer, almost precisely analogous with those seen by himself, but in which case, in spite of apparatus, the deformity persisted at the end of about six weeks, and without manifest improvement.

Guérin has seen a subluxation backward, accompanied with a slight rotation of the head of the tibia outward, in a girl fourteen years old; and which, he affirms, was congenital, characterized by a permanent flexion (backward) of the leg upon the thigh, and a sliding of the condyles of the tibia backward. This girl was under Guérin's treatment, but with what result is not stated.⁷ Chaussier found both tibiae displaced backward in an infant otherwise deformed.⁸ Robert speaks of an example of lateral subluxation in a man, which had existed from birth. The right knee was thrown inward, and the left outward.⁹ Guérin "operated" publicly upon a child, two years old, who had a congenital dislocation of the head of the tibia backward and inward, accompanied with a slight rotation of the leg inward.¹⁰ In what manner he operated, and with what result, he does not inform us. The same writer speaks of a subluxation backward and outward, with rotation in the same direction, a deformity which, he affirms, is very frequent, and which appears especially after birth, although the causes which produce it have given their first impulse during intra-uterine life. The case quoted from Robert, by Malgaigne, as an example of dislocation inward, seems to have been rather a case of semi-rotation of the articular surfaces, the inner condyle being thrown back into the popliteal space, while the outer condyle still retained its natural position.

¹ Kleeberg, Malgaigne, op. cit., p. 983.

² Richardson and Porter, Boston Med. and Surg. Journ., Sept. 16, 1875.

³ Bertin, Union Méd., 14 Oct., 1880.

⁴ Motte, Bull. Acad. Royale de Belgique, 3d Ser., t. 10, No. 2.

⁵ Moos, Archiv für klin. Chir., Bd. 17, Hft. 3, p. 492.

⁶ Guéniot and Périer, Bull. Soc. de Chir. de Paris, 1880, pp. 442-683.

⁷ Guérin, sur les Lux. Congén., p. 33.

⁸ Chaussier, Malgaigne, op. cit., p. 884.

⁹ Robert, Malgaigne, op. cit., p. 985.

¹⁰ Guérin, sur les Lux. Congén., p. 33.

§ 14. Congenital Dislocations of the Tarsal Bones.

Under this general term may be included all those varieties of subluxation of the several bones which compose the tarsus, and which are known as examples of talipes or club-foot; such as tibio-astragaloid dislocations, astragalo-scaphoid, calcaneo-astragaloid, calcaneo-cuboid, etc.

Although these deformities may properly enough claim a place in a chapter on congenital dislocations, they have so long been the subjects of special treatises as to justify their exclusion from the present volume.

§ 15. Congenital Dislocations of the Toes.

Observed occasionally at the metatarso-phalangeal articulations; the articular facets of the first phalanges suffering a subluxation upward, or laterally upon the corresponding metatarsal bones.

Guérin has noticed especially a congenital lateral subluxation of the great toe.¹

¹ Guérin, *op. cit.*, p. 34.

INDEX.

PART I. FRACTURES.

- A** BSCCESS of the sternum, 165
 Acetabulum, 343
 Acromion process, 199
 Allis, carrying function of humerus, 257
 treatment fractures of condyles, 258
 relaxation of fascia, 374
 Amesbury's thigh splint, 389
 Anæsthetics, use of, in diagnosis, 44
 Anaplasty in fractures of the septum narium, 101
 Anatomical neck of humerus, 207
 Anchor splint, 121
 Ankylosis after Colles's fracture, 284
 after fractures of elbow, 262
 after fracture of patella, 440
 of knee, 524
 Apparatus immobile, 66
 Arteries, ruptured, 73
 Arthritis, chronic, 365
 Arytenoid cartilages, fractures of, 139
 Astragalus, 491
 Asymmetry of long bones, 388
 Atlas, 159
 Atrophy, 37
 surgical neck of humerus, 219
 neck of femur, intracapsular, 355
 tibia above tubercle, 459
 Axis, 156
 and atlas, 160
- B** ADLY united fracture of radius, 263
 Barton's bandage, 126
 fracture, 279
 Base of acetabulum, 343
 of condyles of femur, 419
 of condyles of humerus, 237
 Bauer's wire splints, 486
 Bavarian splint, 480
 Bean, lower jaw apparatus, 123
 Bending of bones, 83
 Bigelow, stellate fracture of radius, 275
 rim of acetabulum, 349
 Body of the scapula, 194
 odies of the vertebræ, 147
 Bond's elbow splint, 243
 radius splint, 287
 Bones, repair of, 46
 badly united, 73
 delayed union, 74
 fibrous union, 74
 non-union, 74
 Boyer's thigh splint, 390
 Brainard, perforator, 81
 Bryant, ilio-femoral triangle, 387
 Brown, anchor splint, 121
 Buck, lower jaw, 119
 thigh splint, 394
- C** ALCANEUM, 493
 Carpal bones, 329
 Cartilages of the ribs, 171
 Cervical vertebræ, bodies of five lower, 151
 axis, 156
 atlas, 159
 atlas and axis, 160
 Children, fracture of femur, 415
 Chronic rheumatic arthritis, 365
 Clavicle, 173
 immediate dressing, 58
 partial fractures, 193
 dressing for children, 193
 Cline, trephining vertebræ, 145
 fracture of atlas, 159
 Coccyx, 351
 Colles's fracture, 271
 double, 271
 Comminuted fracture, 72
 Common signs of fracture, 42
 Compound fractures, 72
 forearm, 328
 thigh, 418
 patella, 457
 Condyles of humerus, 247
 internal, 255
 external, 259
 base, 237
 base and between condyles, 244
 of femur, 422
 external, 422
 internal, 424
 occiput, 140
 base, 419
 between condyles, 425
 Congenital, 39, 227, 458
 Coracoid process, 203
 Condyle of occiput, 140
 Coronoid process of ulna, 310

Cotyloid cavity, 343
 Crandall, extension, fracture of leg, 484
 Cricoid cartilage, 140
 Crosby, femur, external condyle, 422

DANIELS'S fracture-bed, 408
 Deformities of legs, 490
 correcting, 470
 Delayed or non-union, 74
 Denticulated fractures, 36
 Dextrine, 67
 Diagnosis, general, 41
 Dislocation of humerus, diagnosis, 220
 Displacements, varieties, 44
 Dorsal vertebrae, 151
 Dressing, immediate, 56
 Drill, Brainard's, 81
 Dieffenbach's, 80
 Drilling in non-union, 80
 Dugas, dislocation of humerus, 220

ELBOW splint, Physick's, 242
 immediate care, 58
 Kirkbride's, 242
 Rose's, 242
 Welch's, 242
 Bond's, 242
 the author's, 243
 Embolism, venous and fatty, 55
 Emphysema in fracture of ribs, 171
 Epicondyle of humerus, external, 254
 internal, 247
 Epiphyseal separations, 37
 acromion, 200
 humerus, upper end, 213
 lower end, 238
 olecranon process, 310
 femur, upper end, 357
 lower end, 427
 trochanter major, 381
 tibia, 459
 Epiphyses, sternum, 161
 scapula, 201
 humerus, 214
 radius, 301
 ulna, 312
 os innominatum, 335
 femur, 353
 tibia, 458
 fibula, 462
 Epitrochlea, 247
 Esmarch, double inclined plane, 405
 Etiology, general, 37
 Exciting causes, general, 38
 Experiments on bending, 83
 on partial fractures, 89
 External epicondyle of humerus, 254
 condyle of humerus, 259
 femur, 422
 Extension of thigh, 394, 413
 in fracture of vertebrae, 155
 vertical, 418

FASCIA, relaxation of, 374
 Fatty embolism, 55
 Felt splints, 65
 Femur, 352
 immediate dressing, 59
 absorption of neck, 364
 neck, within capsule, 354
 without capsule, 370
 within and without capsule, 377
 anatomy of, G. K. Smith, 363
 differential diagnosis, 373
 trochanter major and base of neck, 454
 epiphysis of trochanter major, 456
 shaft, 382
 lower third, 419
 measurement of, 386
 in children, 415
 external condyle, 422
 internal condyle, 424
 between condyles, 425
 base and between the condyles, 425
 delayed and non-union, 428
 separation of lower epiphysis, 427
 Fibula, 462
 Fingers, 332
 Fissures, 93
 cartilage, 95
 neck of femur, 353
 treatment, 95
 Forearm, 321
 immediate dressing, 58
 Four-tailed bandage for broken jaw, 127
 Fox apparatus, 189
 Fractures, 35
 delayed union, 74
 general etiology, 37
 general semeiology and diagnosis, 41
 general prognosis, 51
 general treatment, 55
 heredity, 38
 immediate dressings, 58
 incomplete, 83
 partial, 86
 treatment, 92
 repair of, 46
 Fracture-beds, 408
 Daniels, 408
 Burgess, 408
 Crosby, 409
 Fracture-box, 487

GANGRENE, after use of immovable
 apparatus, 69, 397, 417
 after fracture at base of condyles of
 humerus, 241
 after fracture of forearm, 323
 patella, 429
 arm and thigh, 298, 397, 399
 Garretson's bandage, 126
 General division of fractures, 35
 etiology of fractures, 37
 semeiology of fractures, 41
 prognosis of fractures, 51
 treatment of fractures, 55

Gibson, inferior splint, 125
 splint for femur, 368
 Gilbert, apparatus, 483
 Glenoid cavity of scapula, comminuted, 198
 Gordon's splint, 293
 Gout, cause of fracture, 38
 Granger, fracture of epicondyle, 249
 Greater tubercle of humerus, 212
 Growth, arrest of, 230
 Gum-shellac splints, 65
 Gunshot fractures, 498
 treatment in, 502
 Gutta-percha splints, 55, 66

HAMMOND, jaw splint, 123
 Hartshorne, Edward, clavicle, 184
 Hays, radial splint, 287
 Head of radius, 263
 and anatomical neck of humerus, 206
 Head and neck of humerus, longitudinal fracture, 212
 Hereditary fragility, 38
 Hogden's fracture-cradle, 504
 wire suspension splint, 393
 Humerus, 205
 carrying function, 257
 immediate dressing, 58
 anatomical neck, 207
 head and neck, 206
 tubercle, 211
 longitudinal fracture of head and neck, 212
 surgical neck, 213, 218
 upper epiphysis, 213
 differential diagnosis, 220
 shaft, 227
 lower epiphysis, 238
 base of condyles, 237
 with splitting of condyles, 244
 condyles, 247
 internal epicondyle, 247
 external epicondyle, 254
 internal condyle, 255
 external condyle, 259
 delayed union, 229
 Hyoid bone, 131

ILIUM, 340
 Immediate care, 56
 Immovable apparatus, 70
 patella, 453
 leg, 476
 thigh, 400
 dangers of, 70, 399, 476
 Impacted fractures, 37
 head and neck of humerus, 208
 neck of femur within capsule, 356
 without the capsule, 360
 radius, 275
 Incomplete fractures, 83
 Inferior maxilla, 111
 Interstitial absorption of femur, 364
 Internal condyle of humerus, 255
 Internal femur, 424

Interdental splints, 121, 123
 Intra-uterine fracture, 39, 227, 458
 Ischium, 339

JAW, lower, immediate care, 57
 fracture, 111
 upper, fracture, 104
 Joint, aspiration, 448
 fracture in, 459

KINGSLEY, fracture of lower jaw, 124
 Knee, immediate dressing, 59

LARYNX, fracture of, 135
 Lansdale, patella, 451
 Levis, hooks for patella, 444
 Liston, thigh splint, 385
 leg splint, 485
 Lower jaw, 111

MALAR bone, 102
 Malgaigne, fracture of patella, 443
 of leg, 489
 Malleolus internus, 459
 Many-tailed bandage, 60
 Mason, ossa nasi, 99
 Maxilla, superior, 104
 inferior, 111
 Measurement of bones, 51
 of humerus, 236
 of thigh and leg, 386
 Metacarpus, 329
 Metatarsus, 496
 Metallic splints, 62
 Mollities ossium, causes of fracture, 38
 Monahan, fracture of astragalus, 492
 Moore, Colles's fracture, 276
 head of humerus, 216
 fracture of clavicle, 185
 Morbus coxæ senilis, 364
 Muscular action, cause of fracture, 39

NASAL bones, 96
 Neck of femur, 353
 within capsule, 354
 prognosis, 362
 without capsule, 370
 Neck of humerus, anatomical, 206
 surgical neck, 218
 Neck of lower jaw, 112
 of radius, 365
 of scapula, 198
 Nerves, causing fractures, 38
 Non-union, 74
 clavicle, 180
 femur, 428
 fibula, 466
 humerus, 229
 lower jaw, 117
 patella, 442
 ribs, 169
 tibia, 461
 tibia and fibula, 472

Nose, fracture of, 96
septum of, 100

OCCIPUT, condyle of, 146
Odontoid process of axis, 157
fractures of, 156
mode of death, 159
Edema after removal of dressings, 53
Ogston, fracture femur, 378
Olecranon process, 302
epiphyseal separation, 310
Ossa nasi, 196
Otis, hooks for patella, 445

PALMER'S thigh splint, 393
Paralysis after fracture of spine, 172
humerus, 230
inferior maxilla, 115
clavicle, 180
internal epicondyle of humerus, 252
base of condyle, 240
upper end of fibula, 466
Partial fracture, 86
Patella, 429
etiology of, 432
anatomy and pathology of, 433
immediate dressing, 59
mode of union, 436
treatment of, 443
wiring in fractures, 445
Pelvis, 335
immediate dressing, 57
traumatic separations, 336
Phalanges of fingers, 332
toes, 498
Phelps, Charles, on patella, 445
Pick, fracture femur, 378
Pilcher, Colles's fracture, 282
Pins in non-union, 81
Plaster-of-Paris, 70
Prognosis, general, 51
464 Pubes, 336
Pulmonary venous embolism, 55

RADIUS, 263
Radius and ulna, 321
Refracture of badly united legs, 490
Repair of fracture, 46
Resection for badly united fractures, 490
Rheumatic arthritis, chronic, 364
Rhinoplasty, 101
Ribs, 167
immediate dressing, 57
cartilages of, 171
Rim of acetabulum, 346
Rodet, neck of femur, 355
Roller, 60
Rose, elbow splint, 242

SACRUM, 349
Sacro-iliac symphysis, 350
Salter's cradle for leg, 487
Sayre, L. A., clavicle, 187

Scapula, 194
body, 194
neck, 198
acromion process, 199
coracoid process, 203
epiphyses of, 201
Scraping in non-union, 80
Sculptetus, bandage, 61
Semeiology, general, 41
Senn's dressing, 378
Septum narium, 100
Seton in non-union, 80
Setting bones, 60
Seutin, dressing, 66
Shaft of humerus, 227
from muscular action, 227
femur, 382
radius, 269
ulna, 317
Shellac splints, 66
Shoulder-joint; differential diagnosis, 220
Side splints, 65
Sling for broken jaw, 127
Smith, E. P., radial splint, 288
Smith, N. R., fracture of femur, 391
Spine, immediate dressing, 57
Spinous processes, vertebræ, 140
ilium, 340
Splint, Bavarian, 480
Splints, 63
Starch bandage, 66
Sternum, 161
diastasis, 161
Styloid process of radius, 300
of ulna, 321
Surgical neck of humerus, 218
Swing-box for leg, 486
Symphyses of pelvis, 336
of pubes, 336
sacro-iliac, 350
Symphysis pubis, separation of, 336
Syphilis, cause of fracture, 38

TARSUS, 491
astragalus, 492
calcaneum, 492
Tenotomy in fractures of olecranon, 309
Thomas, wiring jaw, 120
Thyroid cartilage, 138
Thyroid and cricoid cartilages, 139
Tibia, 457
Tibia and fibula, 470
Toes, 498
Trader's suspension apparatus, 487
Transverse processes of spine, 142
Treatment of fractures, general, 55
Trélat's hooks, 444
Trephining for fracture of vertebræ, 145
Tripolith, 68
Trochanter major, 379
fracture of, 380
through, 379
separation epiphysis, 381
Tubercles of humerus, 211, 212
Turner, patella splint, 452

ULNA, resection of, 314

Ulna, 302
shaft, 317
coronoid process, 310
olecranon process, 302
styloid process, 321

Upper epiphysis, humerus, 213
femur, 381

Upper maxillary bones, 104

VAN WAGENEN'S suspension apparatus, 479

Venous embolism, 55

Vertebral arches, 43

Vertebrae, 140
operations on, 146
spinous processes, 140
transverse processes, 142
vertebral arches, 143
removal of, 146

Vertebrae bodies, 147
lumbar, 149
dorsal, 151
cervical, 151
axis, 156
atlas, 159
axis and atlas, 160

WACKERHAGEN'S splints, 479
Water-beds, 154

Wire-beds, 154

Wire-splints, 62

Wire rack for fracture of leg, 488

Wiring patella, 445

Wooden splints, 63

Wrist, 329

ZUCKERKANDL, epicondyles, 251
Zygomatic arch, 109

PART II. DISLOCATIONS.

ANÆSTHETICS, 518

Ancient dislocations, 511
inferior maxilla, 520
spine, 531
clavicle, outer end, 554
humerus, 582
head of radius forward, 616
radius and ulna backward, 631
femur, 735

Ankle-joint, 770

Anomalous dislocations of the hip, 726

Anterior oblique dislocations, 731

Astragalus, 783

Atlas, dislocations of, 538

Axillary artery, rupture of, 588
vein, rupture of, 590

BICEPS, rupture or displacement of, 596

CALCANEUM, dislocation of, 795

Carpus, 652
backward, 655
forward, 657
congenital, 830

Carpal bones among themselves, 661

Carpometacarpal articulations, 663

Cartilages, of ribs from sternum, 542
of ribs, upon one another, 543
in knee-joint, 768

Clavicle, dislocations of, 544
sternal end forward, 544
sternal end upward, 548
sternal end backward, 550

Clavicle, dislocations of, acromial end
upward, 552
acromial end downward, 559
under coracoid process, 560
both ends, 561
congenital, 825

Clove-hitch, 517

Compound pulleys, 518

Compound dislocations of long bones, 803
reduction in, 808
non-reduction in, 810
amputation in, 810
tenotomy in, 811
resection in, 811

Congenital dislocations; general observations and history, 817

general etiology, 818
inferior maxilla, 820
spine, 823
pelvic bones, 824
sternum, 824
clavicle, 825
shoulder, 825
radius and ulna backward, 829
head of radius, 830
wrist, 830
fingers, 831
hip, 831
patella, 837
knee, 838
tarsus, 841
toes, 841

Coxo-femoral dislocations, 678

ancient dislocation of elbow, 637

Cuboid, dislocations of, 797

Cuneiform bones, dislocation of, 798

DIRECT causes of dislocations, 513
 Dislocations, 511
 Division and nomenclature, 511
 Double dislocation of lower jaw, 519

ELBOW-JOINT, 631
 Everted dorsal dislocation, 687
 Exciting causes, general, 513
 Extension by a twisted rope, 694

FEMUR, dislocation of, 678
 dislocation on dorsum ilii, 681
 reduction by manipulation, 699
 reduction by extension, 712
 dislocation into ischiatic notch, 706
 below the tendon, 709
 dislocation into the foramen thyroideum, 713
 dislocation upon the pubes, 720
 anomalous dislocations, 726
 downward and backward upon the body of the ischium, 732
 downward and backward into lesser ischiatic notch, 732
 behind the tuber ischii, 732
 dislocation directly up, 729
 directly down, 733
 forward into perineum, 734
 ancient dislocations, 735
 partial dislocations, 740
 with fracture, 741
 in children, 679
 congenital, 831
 voluntary, 743
Fibula, upper end forward, 781
 backward, 782
 displacement with fracture, 783
 lower end, 784
 "Fifth" dislocation of femur, 732
Fingers, dislocations of first phalanx, 675
 second and third, 676
 congenital, 831
Foot, dislocation outward, 785

GENERAL division, 511
 direct or exciting causes, 513
 predisposing causes, 512
 prognosis, 516
 pathology, 515
 treatment, 516
 symptoms, 513

HEAD upon the atlas, 540
Hip, congenital dislocations of, 831
Humerus, dislocations of, 563
 double, 594
 downward, 564
 forward, 594
 fracture in reduction, 591
 with fracture, 592
 backward, 601
 upward, 606

Humerus, dislocations of—partial, 612
 ancient, 582
 accidents during reduction, 588
 rupture of axillary artery, 588
 rupture of axillary vein, 590
 rupture of artery and vein, 590
 cerebral congestion, 591
 injury to axillary nerves, 591
 avulsion of arm, 591
 inflammation, 591
 congenital, 825
Humero-scapular dislocation, 563
Hyoid bone, dislocation of, 527

Ilio-femoral ligament, 684
Ilio-pubic dislocation of femur, 720
Indian "puzzle," 674
Inferior maxilla, 519
 double dislocation, 519
 single dislocation, 524
 congenital dislocation, 820
Internal arrangement of knee-joint, 768
Ischio-pubic dislocation of femur, 713
Ischiatic dislocation of femur, 706

JARVIS'S adjuster, 695
Jaw, lower, 519

KNEE, slipping of cartilages, 768
Kocher's method, 581

LIGAMENTUM patellæ, rupture of, 759
Long bones, compound dislocation in, 803
Long head of biceps, displacement of, 613
Lower jaw, 599
 double dislocation, 519
 single dislocation, 524
 simulating luxation of, 526
Lumbar vertebræ, 529
Lunare, 663

MAGNUM, 662
 and cuneiform, 662
Maxilla, inferior, congenital, 820
Metacarpus, 663
Metacarpo-phalangeal articulation, 665
Metatarsus, 800
Middle carpal dislocation, 663
 tarsal dislocation, 784

OCCIPITO-ATLOIDEAN dislocations, 540

PATELLA, outward, 751
 inward, 755
 on its axis, 755
 upward, 759
 downward, 760 (note)

Patella, spontaneous, 750
 congenital, 837
 Pathology, general, 515
 Pelvis, congenital, 824
 Peroneo-tibial, 831
 Phalanges, 667
 toes, 841
 Pisiform, 662
 Predisposing causes, general, 512
 Prognosis, general, 516
 Pseudo-luxations of inferior maxilla, 526
 Pulleys, 518

QUADRICEPS, rupture of, 760

RADIUS, head dislocated forward, 616
 backward, 621
 outward, 624
 downward, 626
 congenital, 830
 Radius and ulna, backward, 631
 congenital, 829
 outward, 640
 inward, 646
 forward, 649
 Radius forward and ulna backward, 651
 Radio-carpal articulation, 652
 Radio-ulnar articulation, inferior, 658
 Ribs from vertebræ, 541
 from sternum, 542
 one cartilage upon another, 546
 Rupture of quadriceps femoris, 760
 Rupture of biceps, 612
 Rupture of ligamentum patellæ, 759

SACRO-SCIATIC dislocation, 706
Scapoid, dislocation of, 797
 Scapula, voluntary, 747
 Shoulder, dislocations of, 563
 Single dislocation of lower jaw, 524
 "Sixth" dislocation of femur, 726
 Spine, 528
 Spontaneous or voluntary dislocations, 743
 Sternum, 551
 congenital, 824
 Subcoracoid dislocation of humerus, 594
 Subclavicular dislocation of humerus, 594
 Subcotyloid dislocation of femur, 733
 Subluxation of the jaw, 526
 Subglenoid dislocation of the humerus, 564
 Subpubic dislocation of femur, 713
 Subspinous dislocation of humerus, 601
 Symptomatology, general, 513

TARSUS, 784
 astragalus, 784
 astragalo-calcaneo-scaphoid, 794
 calcaneum, 795
 middle tarsal dislocation, 796

Tarsus, os cuboides, 797
 os scaphoides, 797
 cuneiform bones, 798
 congenital, 841
 voluntary, 750
 Tendons, dislocation of, 613
 Thigh, 678
 Thumb, first phalanx, 667
 backward, 667
 forward, 674
 second phalanx, 676
 Tibia, dislocation of upper end, 760
 backward, 761
 forward, 762
 outward, 764
 inward, 765
 backward and outward, 766
 forward and outward, 767
 forward and inward, 767
 by rotation, 768
 congenital, 838
 lower end inward, 771
 outward, 775
 forward, 776
 backward, 779

Tibio-tarsal dislocations, 770

Toes, 802

 congenital, 841

Treatment, general, 516

Tripod for vertical extension, 704

Twisted-rope extension, 694

ULNA, upper end backward, 629
 inward, 631
 lower end backward, 659
 forward, 660

Unilateral dislocation of lower jaw, 524

VERTEBRÆ, 528
 lumbar, 529
 dorsal, 530
 six lower cervical, 532
 atlas upon axis, 538
 head upon atlas, 540
 congenital dislocations, 823
 Voluntary and spontaneous dislocations, 743
 inferior maxilla, 747
 scapula, 747
 humerus, 748
 wrist-joint, 748
 phalanges of fingers, 748
 hip-joint, 748
 knee-joint, 750
 ankle-joint, 750
 tarsal joints, 750
 patella, 750

WINDLASS for extension, 694
 Wrist, 652

Y-LIGAMENT, 684

