

**Lectures on operative surgery of the eye, or, An historical and critical inquiry into the methods recommended for the cure of the cataract for the formation of an artificial pupil, &c.; &c.; &c; : containing a new method of operating for cataract by extraction, which obviates all the difficulties hitherto attendant on that operation : being the substance of that part of the author's course of lectures on the principles and practice of surgery which relates to the operations on that organ / by G.J. Guthrie.**

### **Contributors**

Guthrie, G. J. 1785-1856.  
Francis A. Countway Library of Medicine

### **Publication/Creation**

London : Burgess and Hill, 1830.

### **Persistent URL**

<https://wellcomecollection.org/works/zr2e9ty2>

### **License and attribution**

This material has been provided by This material has been provided by the Francis A. Countway Library of Medicine, through the Medical Heritage Library. The original may be consulted at the Francis A. Countway Library of Medicine, Harvard Medical School. where the originals may be consulted. This work has been identified as being free of known restrictions under copyright law, including all related and neighbouring rights and is being made available under the Creative Commons, Public Domain Mark.


You can copy, modify, distribute and perform the work, even for commercial purposes, without asking permission.



Wellcome Collection  
183 Euston Road  
London NW1 2BE UK  
T +44 (0)20 7611 8722  
E [library@wellcomecollection.org](mailto:library@wellcomecollection.org)  
<https://wellcomecollection.org>













Digitized by the Internet Archive  
in 2011 with funding from  
Open Knowledge Commons and Harvard Medical School

LECTURES  
ON THE  
OPERATIVE SURGERY OF THE EYE.

G. J. GUTHRIE, F.R.S.

THIRD EDITION.

LONDON:

JOHN WOODHEAD, 15, N. B. ROAD, ST. MARK'S.

PRINTED BY J. WOODHEAD, 15, N. B. ROAD, ST. MARK'S.

LECTURES

ON THE SURGERY OF THE EYE

LECTURES

ON THE

OPERATIVE SURGERY OF THE EYE



**Lectures**  
ON THE  
**OPERATIVE SURGERY OF THE EYE;**  
OR, AN  
HISTORICAL AND CRITICAL INQUIRY INTO THE METHODS  
RECOMMENDED FOR THE CURE OF  
**CATARACT,**  
FOR THE FORMATION OF AN ARTIFICIAL PUPIL,  
&c. &c. &c.

CONTAINING  
A New Method of Operating for Cataract by Extraction, which obviates all the Difficulties  
hitherto attendant on that Operation:

BEING  
THE SUBSTANCE OF THAT PART OF THE AUTHOR'S  
**Course of Lectures**  
ON  
THE PRINCIPLES AND PRACTICE OF SURGERY  
which relates to  
THE OPERATIONS ON THAT ORGAN.

BY  
**G. J. GUTHRIE, F.R.S.**

PROFESSOR OF ANATOMY AND SURGERY TO THE ROYAL COLLEGE OF SURGEONS,  
SURGEON TO THE WESTMINSTER HOSPITAL,  
TO THE ROYAL WESTMINSTER OPHTHALMIC HOSPITAL,  
&c. &c. &c.

---

THIRD EDITION,  
*WITH SEVEN EXPLANATORY PLATES.*

---

LONDON:  
BURGESS AND HILL, GREAT WINDMILL STREET.

SOLD BY  
MACLACHLAN AND STEWART, EDINBURGH, AND  
FANNIN AND CO., DUBLIN.

1830.

Reviews

ON THE

# OPERATIVE SURGERY OF THE EYE

OR, AS

HISTORICAL AND CRITICAL INQUIRY INTO THE METHODS

RECOMMENDED FOR THE CURE OF

## CATARACT,

### FOR THE FORMATION OF AN ARTIFICIAL PUPIL.

By

JOHN

A New Method of Operating for Cataract by Extraction, which operates all the difficulties  
formerly attendant on that operation


28.2.191

THE EDITION OF THAT PART OF THE AUTHOR'S

OF

OR

THE PRINCIPLES AND PRACTICE OF SURGERY



JAN 28 1921

LIBRARY

TREATISE OF ANATOMY AND SURGERY IN THE ROYAL COLLEGE OF SURGEONS

FORWARD TO THE ANATOMICAL MUSEUM

TO THE ROYAL ANATOMICAL MUSEUM

By

THIRD EDITION.

WITH NEW EXPLANATORY PLATES.

LONDON:

BURGESS AND SONS, GREAT WINDMILL STREET.

SOLELY

MAGNAN AND FLEMING, EDINBURGH, AND

LAMBIN AND CO., DUBLIN.

1890.



TO  
THE PATRONS,  
PRESIDENT, VICE-PRESIDENTS,  
AND  
GOVERNORS  
OF THE  
**ROYAL WESTMINSTER INFIRMARY**  
FOR THE  
CURE OF DISEASES OF THE EYE,  
TO  
WHOSE KINDNESS AND LIBERALITY THE INSTITUTION IS INDEBTED FOR  
ITS SUPPORT,

THIS WORK

*Is Respectfully Inscribed,*

BY THEIR  
VERY OBEDIENT AND HUMBLE SERVANT,

*G. J. Guthrie.*





## PREFACE

TO

### THE FIRST EDITION.

---

PREVIOUSLY to the year 1817, no lectures were delivered in Great Britain on the Diseases of the Eye, unless the concise observations, which were made in the schools of anatomy, on some of the operations, be considered as such. The consequence was, that a knowledge of these complaints was not presumed to form a part of the education of a surgeon; and the public, in applying for relief to those gentlemen who made this branch of the profession their only occupation, encouraged rather than repressed a propensity to idleness, which so frequently induces mankind to neglect that which does not appear to be immediately necessary, or which is not directly required. The various casualties of a protracted war, in distant climates, which rendered it imperative on many of the physicians and surgeons of the army and navy to pay greater attention to the diseases of the eye, together with the impulse given by the application and success of the late Mr. Saunders, gradually, however, began to cause some change in the ideas of medical men; and, at last, to convince many of the propriety of



their acquiring a knowledge of these diseases by the same means, and in the same manner, as were found essentially necessary in the study of medicine and surgery in general. In order to remove some of the difficulties which impeded the progress of practitioners, and to render an acquaintance with these complaints more easily attainable by students, Lectures on the Anatomy and on the Diseases of the Eye were commenced by Dr. Forbes and myself, shortly after our appointments as Physician and Surgeon to the Royal Westminster Infirmary for Diseases of the Eye, which, whilst they were separated from our respective courses of Lectures on the Principles and Practice of Physic and Surgery, were yet founded on the same principles, and on the same general reasoning, and were elucidated by examples drawn from other parts of the body. The following observations form a part of the Lectures which were allotted to me, and are now published at the urgent desire of a great body of students, who were solicitous to have an opportunity of reviewing those opinions more at leisure, and of referring to them when they might stand in need of assistance. They felt the want of a work, which, whilst it noticed the doctrines and practice of the several writers on the subject, should yet state the facts, and impartially discuss the opinions of each, so as to obviate the necessity for purchasing several books on the same subject, merely because each author has chosen to recommend only his own practice or methods of operating. In the observations I have found it necessary to make for this purpose, I have avoided as much as possible entering into controversy; and where I



have thought it right to combat the opinions of either the dead or the living, I have endeavoured to do it with liberality. Where I have differed with my contemporaries, I have frequently done so without any direct reference to them; and if I could have devised the means of explaining myself in an intelligible manner in all cases without it, it would have been peculiarly agreeable to me to have availed myself of it.

A knowledge of the diseases of the eye cannot be acquired from lectures alone, or by reading; it is necessary to study them by diligent examination, and an attentive observation of the individual who is the subject of them. This can only be done at an hospital or an infirmary, where the opportunities are numerous; but then a competent acquaintance with them may be obtained in a few months, and with very little comparative labour. The diseases are nearly all open to inspection, most of the changes are under observation, and the effects of disease may almost always be predicted, if they cannot be prevented.

Public opinion, which on medical subjects is generally erroneous, although for the most part founded on professional authority, is in no instance more injurious than in relation to the eye. It pronounces it to be an organ of a very delicate nature, exquisitely sensible, requiring the greatest delicacy of touch, and the utmost nicety of management; which opinion some oculists formerly found it convenient to support, and which the public may still continue to believe without any great disadvantage; but students in surgery must be taught otherwise. They must learn, that the eye is not a



delicate organ; that it will suffer more comparative violence, with less injury, than any other of importance in the whole body; that, so far from being exquisitely sensible, it is, when exposed in a healthy state, nearly the reverse, only becoming permanently so on the occurrence of inflammation; and that the ablest and most successful operators are neither the most gentle nor the most tender in their proceedings. The opinion of the exquisite sensibility of the eye has arisen from the pain which is felt on the admission of a small piece of dirt, or a fly, between the eyelids; but this occurs from a wise and preservative provision of nature, on account of the insensibility of the eyeball itself. Let the eyelid be raised, and the same piece of dust applied to the surface of the eye, no pain, and scarcely a sensation, will be produced: remove the piece of dirt, turn out the lid, and whilst it is retained everted, place the piece of dirt upon it, no greater sensation will be induced than is felt when it is applied to the eyeball. The inference is, that both surfaces, when touched separately, are nearly insensible to this species of irritation. But let the same piece of dirt be put between the eyelid and the eyeball, and the sensation produced is exquisitely painful. To give rise to this sensation it is necessary that the two surfaces should come in contact, and that the foreign body be grasped between them. If this were not the case, an irreparable injury would often occur to the transparent part of the eye before it would be observed; and if the raising of the lid and the separation of the surfaces did not nearly annul sensation, an operation could not be performed for cataract; for, who could bear



quietly the sensation which must arise from pushing a needle into the eye, if it were analogous to that arising from a fly or a dry solid substance between the eye and the lids? The experiment may be tried in a very simple and conclusive manner by any one on himself, by merely keeping the lids apart by an effort of the will, when the end of the finger may be placed boldly on the eyeball without any inconvenience. Inflammation, by enlarging the vessels, gives rise to pain in the same way, and the sensation is at first as if some extraneous matter were interposed between the lids.

In regard to the difficulty supposed to attend the performance of operations on the eye, it partakes of the same error, and has been supported for the same reasons. The sensibility presumed to exist in the organ, naturally led to the conclusion, that the operations required to be performed upon it must be difficult of accomplishment; and the science of optics, in showing the beautiful arrangement of its structure and the complexity of its functions, induced a belief that the slightest alteration in its composition must be fatal to its mechanism: but this is not found to be the case. Few persons can, however, duly estimate the liberties that may be taken with the eye until they have seen several operations performed, when the false ideas they have imbibed will be completely removed, and new feelings will arise, in admiration of the benignity of the Creator, who, in rendering the eyeball nearly insensible, enabled it, in its quiescent state, to undergo those operations



which are frequently necessary for the recovery of sight.

It has also been supposed, that there is a peculiar tact, or something indefinable, required in the hands of the surgeon, to enable him to operate with advantage, and that the performance of operations on the other parts of the body unfits him for those on the eye: that this may be the case in London, I do not mean to dispute, and I have no wish that the public should change its opinion; but students must not suffer themselves to be deceived. The surgeon who can perform an operation, with that precision which enables him to lay bare and avoid a part, the division of which would cause the death of the patient, possesses coolness enough to operate upon an eye, the loss of which is comparatively of little consequence. The capability of dissecting within an eighth of an inch of the death of a patient, or more frequently of his future discomfort and misery, is only acquired by habit, or, in other words, by practical labour and study. A knowledge of the different operations on the eye must be acquired in the same manner. A student, having the advantages of a cool head and a steady hand, will, with a due share of study, perform an operation on one part of the body just as well as on another. He may never perform them well on any part, but that is dependent on other causes, which would not be removed by his confining himself to one operation. Practice for such persons will do nothing; for a man who can perform other operations well, it will do every thing. There are



a great many surgeons in Europe, there are but few good operators, and principally for want of opportunity; for no man can know what he is capable of doing until he makes the experiment. If he cannot operate well himself, he may still, by a knowledge of disease, prevent the necessity of its being done by others.

The Lectures on the Anatomy, and on the remaining Diseases of the Eye, will follow the completion of a work in which I have been for some time engaged, on the Diseases of the Urethra.

2, Berkeley Street,  
Berkeley Square,  
Aug. 1, 1823.

a great many answers in 1846, there are but few  
 good operators, and principally for want of oppor-  
 tunities for no longer continuing with the capable of  
 doing well, the makes the experiment. If he cannot  
 operate himself, he may not be a knowledge of  
 disease, prevent the necessity of his long days by  
 others. THE LECTURE ON THE THEORY OF THE  
 THE LECTURE ON THE THEORY OF THE REMAINING  
 Diseases of the eye will follow the completion of a  
 work in which I have been for some time engaged, on  
 the repeating this work, I only find it ne-  
 cessary to state that there is no other book  
 existing containing so much information as the  
 work of which it is the present one.  
 The principal part of the work is made in the  
 names of the students of the Royal College  
 of Physicians in London, and the names of the  
 authors of the various parts of the work are  
 from the originality of many of them, they will  
 attest the correctness of the whole.

Printed by J. G. & J. H. B. 1847



## CONTENTS.

---

### ON THE INVERSION OF THE EYELIDS.

DIFFERENT names used to designate it, Page 1. Three states of derangement, 2. Opinions of Winslow, Albinus, Scarpa, 2. Of Ætius, Paulus Ægineta, Gleize, Jæger, Demours, and Boyer, 3. Symptoms, 4. Causes, 8. Opinion of Mr. Ware, 9. Mr. Crampton, 9. Of the author, 10. Conclusions, 15. Methods of operating, 15. Of Hippocrates, 15. Galen, Antonius Musa, Ætius, Celsus, 16. Paulus Ægineta, Rhases, Bartisch, Verduin, Heister, 17. Maitre Jan, St. Yves, Gendron, Dionis, Janin, Gleize, Wenzel, Boyer, Demours, Scarpa, Monteggia, 18. Baratta, Quadri, Helling, Bëer, Langenbeck, Weller, Schreger, Beclard, 19. Bëer and Jæger, 20. Saunders, 24. Observation on Saunders and Jæger, 25. Mr. Crampton's method, 26. Mr. Travers's, 28. Method of cure by the sulphuric acid, 30. Mode of operating, in severe cases, on the upper eyelid, 31. On the lower lid, 35. Subsequent treatment, 36. Cures, 37.

### ON THE EVERSION OF THE LIDS.

More rarely met with as affecting the upper lid, 41. The appearance and symptoms depend on the nature and causes of the disease, 42. Ectropium of four species, 42. Well known to the ancients—Hippocrates, Celsus, Aëtius, 43. Antyllus, Albucasis, 44. Platner, Thevenin, Heister, Maitre Jan, Dionis, Junker, Severinus, Bordenave, St. Yves, 45. Symptoms of the first kind, 46. Scarpa only considers two kinds of disease, 49. Not always accompanied by the tumefaction of the conjunctiva, described by him, 51. Indications of cure of this species, 52. Use of the sulphuric acid, 53. Caution to be observed in its continuance, 54. Causes of inversion, 54. On the second species, 54. Description from Dr. Vetch, 54. The appearance of the eyelids differs from that of the third species, 57. Treatment of Demours, 57. The German ophthalmologists,



58. Sir W. Adams, 59. Remarks upon his operation, 60. Rejected in the second species, approved of in the third, 63. On the third species, 63. Method of cure by Bordenave and Dzondi, 65. Indications of cure, 66. Principles, 67. Conclusions on the operation, 69. Subsequent dressing and treatment, 69. Fourth, or paralytic species, 70. Cases, 71. Eversion of the upper lid, 75. Sometimes a natural defect, 75. When incurable, 75. Less susceptible of relief when caused by abscess, 76. When partial, to be cured by the same means as the first and second species of eversion of the lower lid, 76. Scarpa's case, arising from a fungous excrescence, 77. Remarkable case of eversion of the upper lid, caused by the cicatrix of an ulcer, cured by operation, 78. Professor Walther's operation and case, 79. Remarkable case of Mary Harrop, 80. Lagophthalmus from partial paralysis, 80. Dr. Monteath's remarks, 83. Mr. Shaw's, 84.

#### ON THE RELAXATION OF THE UPPER LID.

Mostly a symptomatic disease, 85. Accompanied by paralysis, as a consequence of apoplexy, 85. In few cases relievable by a surgical operation, 87. Dependent on various causes, 88. Cases from relaxation, atony, and palsy, 88—90. Galvanism, electricity, moxa, 91. Schmidt's opinion, 92. Particular cases, 93—99. Cure by caustic, 99.

#### ON THE COHESION OF THE EDGES OF THE EYELIDS.

Perfect or imperfect, 100. Seldom perfect; the conjunctiva, as a sero-mucous membrane, not admitting of a complete union, 101. Causes, 101. Bœer's opinion, 102. Important distinction to be made as to the part from whence the adhesion arises, 103. Seldom curable when it commences at the angle of reflection, 103. Methods of cure proposed by Celsus, Paulus Ægineta, Fabricius, Hildanus, 104. By Bœer, 105. Treatment recommended, 106.

#### ON WOUNDS OF THE EYELIDS.

Simple wounds neither dangerous nor difficult of cure, 108. One or more sutures frequently required, 109. Union of a divided lachrymal canal seldom accomplished, so as to continue pervious, 109. Wounds of the forehead often productive of deformity, and occasionally of blindness, 110. Vision sometimes affected in an unaccountable manner, 111. Opinions of Bœer and Weller, 112. Their accuracy suspected, 113. Scarpa's opinion, 114. Symptoms dependent on injury of the supra-orbital nerve, 116. Treatment, 116. When followed by inflammation, 117.



ON TUMOURS, OF VARIOUS DESCRIPTIONS, AFFECTING THE EYELIDS:  
HORDEOLUM, CHALAZION, GRANDO, &c.

The eyelids are very liable to be the seat of them, 119. Hordeolum, symptoms of, 119. Treatment, 121. Chalazion, &c. 121. Treatment, 122. Escharotics do harm, 122. Phlyctenulæ, treatment of, 122. Ptilosis, or falling out of eyelashes, 123. Encysted tumours, 124. Simple kind of, 124. Operation, 125. Atheromatous, 126. Operation, 127. Caustic, inapplicable when large, 128.

ON THE ENCANTHIS.

Not frequent in this country, 128. Symptoms, 129. Suppuration of caruncle, 129. Excrescence of a large size, 130. Opinion of Scarpa, 131. Sometimes of a cancerous nature, 131. Treatment of simple inflammation, 132. Mulberry excrescence to be cut off, 133. Operation of Purmannus, by ligature, 133. By the knife, 134. Scarpa's proceeding, when large, 134.

ON THE PTERYGIUM.

Appearances of pterygia, 135. Diagnostic marks, 136. Supposed cause of formation, 137. Scarpa's opinion very doubtful, 138. Not the consequence of chronic inflammation, 139. Difference between nebula and pterygium, 140. Cure is by operation, 140. Scarpa's method, 141. Bëer's, 141. Operation, 142. True pterygium very rarely malignant, 143. When malignant, part or the whole of the eye to be removed, 144. Small bulby tumours, 144. Papula of the conjunctiva of Bëer, to be removed by scissors, 145. Not by escharotics, 145.

ON THE REMOVAL OF EXTRANEOUS SUBSTANCES FROM THE EYE,  
AND ON INJURIES OF THE EYEBALL.

Situation of the extraneous body has great influence, 146. When on the conjunctiva lining the lid, or in the angle of reflection, 146. When it sticks in the cornea, 147. Mode of examination, 147. Consequence of the accident, 148. Method of removing a substance sticking in the cornea, 149. Wounds of the cornea, 150. A portion of the iris, in certain cases, to be cut away, 151. Lens removed, 151. Protruded iris to be returned, 152. Blows on the eye, 152. Injuries from shot, 153. By chemical substances, 154. Treatment, 155.



ON TUMOURS WHICH ARE FORMED WITHIN THE ORBIT, AND ON  
PROTRUSION OF THE EYEBALL.

The consequence of a particular indefinable action, 156. Almost always encysted, 156. Abscess, 157. Inflammation and suppuration within the orbit, 157. Tumours within the orbit, 158. Case by Richerand, 158. Contents of such tumours, 159. When causing exophthalmos, 160. Dr. Monteath's case, 160. Removal of deep-seated tumours sometimes fatal, 161. Langenbeck's cases, 161. Of a cartilaginous nature, 162. Exostosis very rare, 164. Protrusion of the eyeball, 165. When the consequence of injury, 166. Opinions, 166. Schmidt on exophthalmos, the consequence of a hydatid of the lachrymal gland, 167. Case of aneurism of the ophthalmic artery, 169.

ON THE EXTIRPATION OF THE LACHRYMAL GLAND.

Lachrymal gland little susceptible of derangement, 169. Opinions of Messrs. Todd, Schmidt, B  er, Desault, Boyer, Warner, 169. Demours, Guerin, Richerand, 170. Symptoms of scirrhus, 170. Mr. Todd's case and operation, 171. Mr. O'Beirne's case and operation, 174.

ON THE ALTERATIONS OF FORM OF THE ANTERIOR PART OF THE  
EYE.—STAPHYLOMA.

Staphyloma divided into total and partial, spherical and conical, 176. The first, or most simple kind, apparently overlooked by B  er and Richter, 177. Second kind, 178. Opinions of German writers, 178. Of Angeli and Scarpa, 179. Peculiarity of the structure of the cornea in infants, 179. Thickness of it in infants resists disease, 179. Small pox most frequently causes staphyloma, from ulceration, 180. Purulent ophthalmia in infants less dangerous than in adults, 181. Cause of staphyloma, 181. Natural cure, 182. Manner of accounting for staphyloma doubtful, 182. Partial staphyloma the result of ulceration, 183. Operations by caustic and the knife, 184. Escharotics recommended by Richter, B  er, and Vetch, 184. The intention misunderstood by Scarpa, 185. Reasons for his mistake, 185. Operation by the knife preferred, 186. Mode of operating, 187. Treatment, 188.

ON THE EXTIRPATION OF THE EYEBALL.

Does not arrest fungus h  ematodes of the eye, 189. Symptoms of, 189. Scarpa's conclusions, 190. First operation done by Bartisch, 191.



Different methods since his time, 191. Operation described, 192. After-treatment demands attention, 193. Case requiring great depletion, 193.

## ON CATARACT.

Opinions of Galen and the ancient Greek and Roman physicians and surgeons, 194. Seat of vision supposed to be in the lens, 194. Seat of disease in an adventitious membrane, deposited from the aqueous humour, 195. Kepler first proved the crystalline body to be unfit to retain or reflect light, 195. To be merely a double convex lens, 195. First noticed professionally in 1707, by Maitre Jan, 196. Distinction then made into true and false cataracts, 197. A variety of appellations, 198. Cataracts termed ripe and unripe, 198. These terms defective and illusory, 199. The hardness of a cataract not dependent on its age, 199. Nor colour, 199. Length of existence equally illusory, 199. Greater or less defect in vision, not more certain, 199. An important distinction between idiopathic or constitutional, and local or accidental cataracts, 199. The constitutional form cannot be prevented, 199. Affects persons of all ages, and infants before birth, and all temperaments, 200. Scrofula does not give rise to it, 200. Nor syphilis, unless the part suffers from inflammation, 200. Rheumatism and gout, 201. On hereditary predisposition, 201. Influence of the constitution, 202. Prognosis in constitutional cataract, of one eye escaping, unfavourable, 202. The reverse in local or accidental cataract, 202. On the sympathy between the eyes, 203.

*On the Symptoms and Appearances common to the various Kinds of Cataract.*

The general symptoms resemble each other in all cases, 204. Are external or visible, internal or occult, 204. Internal symptoms, 205. External symptoms, 206. Appearance of the iris, 207. Motions of the iris influenced in three ways, 208. Susceptibility of the iris for light, 209. Sympathy of the iris with the retina, 211. With the other eye, 214. Scarpa and Sir W. Adams on the diagnosis of the consistence of cataracts, 217. Colour of cataracts, 217.

*Diagnosis of Muscæ Volitantes.*

Their nature, 218. Are never fixed, 218. Causes, 220. Principal diagnostic sign is their mobility, 220. Mode of demonstrating the existence of the liquor Morgagni, 220. Incurable, 221.



*Diagnosis between incipient and confirmed Amaurosis and Cataract.*

The spots are fixed, 221. A part of an object only seen, 221. Flashes of light, appearance of brilliant colours, 221. Cornea at first scarcely altered, 222. Appearances of the iris, 222. Of the cloudiness or opacity, 222. General symptoms, 222.

*Diagnosis between Glaucoma and Cataract.*

Symptoms of glaucoma, 223. Sufficiently diagnostic, 223. An elongation of the pupil considered an important diagnostic sign of glaucoma in Germany, but is not so in Great Britain, 224. Observations on the German theory of arthritic inflammation, 225. Critical remarks on inflammation of the iris and of the choroid, 227.

*On the Causes of Cataract.*

Age an occasional cause, 229. Beer enumerates many very disputable causes, 229. Professor Walther's opinions relative to inflammation, 230. Delpech, 233. Syphilitic inflammation a cause of cataract, 235. Observations on the cure of incipient cataract from inflammation, 236.

*On the Classification of Cataract.*

Two classes; the true, and the false or spurious cataracts, 236. The first class contains three genera, 237. Complicated cataracts, 237. The first genus, or of lenticular cataracts, contains four species: the hard, the fluid, the soft, the caseous, 237.

*On the Diagnosis of hard Cataract.*

Mode of examination, 238. Use of the belladonna, 239. Nomenclature of the Germans in relation to the motions of the iris, 239. Appearances of the opacity, 239. Colour of a hard cataract, 240. Hard cataract generally small, 241.

*On the Diagnosis of capsular Cataract.*

Arises in all probability from an action of a peculiar kind, 241. Appearances of the opacity, 241. Anterior capsular cataract, 242. Posterior capsular cataract, 243. Opinions of B  er and Mr. Travers, 243. Complete capsular cataract, 244. Secondary capsular cataract, 245.

*On the Diagnosis of capsulo-lenticular Cataract.*

Diagnosis intimately connected with that of soft, fluid, and caseous



cataracts, 245. A fluid cataract, 246. *Cataracta morgagniana*, 246. *Cataracta fluida dura*, 247. *Cataracta capsulo-lenticularis cystica*, or encysted, or hydatid cataract, 247. *Cataracte tremblante*, capsulo-lenticularis; tremula or natalis, 248. On the soft, gelatinous, or flocculent lens, 249. *Cataracta marmoracea* and fenestrata, 250. *Cataracta stellata*, punctata, dimidiata, centralis, quadrata, innominata, &c. 251. *Cataracta arida siliquosa*, 252. *Cataracta gypsea*, 253.

*On the Diagnosis of Cataracts of the second Class, or false, or spurious Cataracts.*

When the cataract does not exist as an independent disease, but is complicated with inflammation of the surrounding parts, it is a false cataract, 253. *Cataracta capsulo-lenticularis lymphatica*; spuria purulenta, 255. *Pyramidata*, 256. *Grumosa*, 256. *Trabecularis*, or cum zona, or balkenstaar, 257. *Cataracta capsulo-lenticularis, cum bursa ichorem continente*, 258. *Cataracta capsulo-lenticularis arborescens, dendritica, or choroidalis*, 258. *Cataracta capsulo-lenticularis, choroidalis, or pigmentosa*, 259.

*On the Cure or Removal of Cataract.*

Cure often considered practicable in the incipient stage, 260. Injury of the capsule of the lens, 261. M. Gondret, method of cure of, supported by cases, 262. Author's remarks, 265. Meaning of ripe and unripe cataracts, 266. Proper period for operating, 267. Preparation insisted upon by some, neglected by others, 267. Any other disease to be removed previously to operating for cataract, 268. Propriety of operating where only one eye is affected, 269. Opinions of Sabatier, Maitre Jan, St. Yves, Wenzel, Richter, Travers, 269. Remarks on Mr. Stevenson's opinions, 275. Cases against, 277. Cases in favour of, 278. Concluding observations, 279.

*On the Operations for Cataract.*

Works of Celsus give us the first description of this operation, 281. Two methods of the Hindoos, 282. Of the Arabians, 285. Of Rocho Mathioli and Freytag, 285.

*On the Operation by Displacement.*

Divided into operations posterior and anterior to the iris, 286.

*On the Operations posterior to the Iris.*

Simple depression, 287. Divisible into three stages, 287. First stage,



287. Second stage, 288. Third stage, 288. Observations on the three stages, 289. On the ciliary processes, 291. The operation condemned, 294. Operation of Scarpa, 294. Observations upon it, 297. Reclination, or the operation of Willberg, 299. Advantages and disadvantages of each considered, 300. Hyalonyxis, of Dr. Bowen, 300. Observations, 303. Mode of proceeding in case the nature of the cataract should have been mistaken, 304.

*On the Operations anterior to the Iris.*

Reclination through the cornea principally supported by Langenbeck, 306. Operation, 306. After-treatment, 308. Hæmorrhage a rare occurrence, 309. Violent vomiting, 310. Generally dependent on injury of the retina, 311. Rising of the lens causes irritative inflammation, 311. To be again depressed, 312. Case of Michael Moody, 312. Amaurosis, 313.

*On the Operation by Extraction.*

Attributed to Daviel, 314. Known to Rhazes, Antyllus, Lathyrion, Haly, Avicenna, St. Yves, 314. Case by Mery and Petit, 315. Platner, Chandler, 316. Operative process, 318. Remarks on the first stage, or the punctuation of the cornea, 321. On the completion of the incision, 323. Form of the incision, 325. Division of the capsule, 328. Shape of the hook or needle, 328. Abduction of the lens, 330. Difficulties attending it, 331. Use of the curette, and admission of air, 332. A peculiar method of proceeding by Bæer, 333. The large hook recommended in particular cases for the removal of the lens, 333. Loss of the vitreous humour, 334. Mode of proceeding in such cases, 335. Irregular union of the flap, 335. Protrusion of the iris, 337. On the incision of the cornea upwards, 339. On the double knife of Jäger of Vienna, by Loudon, 343. Its qualities doubted, 344. A new knife recommended by the author, 344. The principle of using it diametrically opposite to that of all others, 345. Presumed to be a great improvement, 346. After-treatment, 346.

*On the Operation for the Division or Breaking up of the Cataract.*

Of two kinds, 350. Posterior to the iris: anterior to the iris, or through the cornea; the keratonyxis, 350. On the operations posterior to the iris, 350. Pott, Hey, Scarpa, Saunders, Sir W. Adams, 351. Operative process, 352. Remarks on the introduction of the needle, 353. On the division of the lens, 354. When the lens is too hard for division, 354. When the vitreous humour is thinner



than usual, 355. When the lens is in a gelatinous state, 356. Secondary capsular and adherent cataract, 357.

*On the Operations anterior to the Iris.*

The keratonyxis, noticed by Mayerne in 1690, 358. Removal of the lens by absorption, by Barbette, 359. Operation of Gleize, 359. Of Conradi, of Saunders, 361. Langenbeck, Buckhorn, Walther, Reisinger, and the German school, 362. Mode of operating by puncture of the capsule, 362. By division through the cornea, 364.

*On the Operations for Capsular Cataract.*

Operation for cataracta arida siliquosa, or coriaceous capsular cataract, 364. Operation for secondary capsular cataract, 368.

*On the compound Operation of Displacement and Extraction.*

Mr. Gibson's method, 369. Mr. Travers's, 371. Sir W. Adams's, 374. Deviations from these methods recommended, 379. Objections to the operations generally, 381. These operations ought not to be practised but in two cases, 385. De Wenzel's method also condemned, 385.

*On Congenital Cataract.*

Objections to the term by the German ophthalmologists, 386. Discrepancy of opinion between Messrs. Saunders and Gibson, 387. Two particular species of congenital cataract indicated, 389. The proper period for operating, 389. Great merit attributed to Mr. Saunders, 391. Manner of securing the child for an operation, 392. Processes recommended, 393.

*Concluding Observations on the Advantages and Disadvantages attending the various Modes of operating, as applicable to the different Species of Cataract.*

No operation applicable to every species of cataract, 393. Operative process to be regulated by the general principles of surgery, 394. On extraction, as applicable to hard cataract, 394. Only proper under particular circumstances, 395. Difficulties attending its performance, 395. Observations on them, 398. Displacement may be performed in every case in which extraction is proper, 403. Other cases enumerated, 403. Objections to it, 404. On the pain and vomiting, 405. On a wound of the annulus gangliformis and ciliary processes, 406. Principle of the operation of Scarpa and of reclination, 408. On the rising of the displaced lens, 408. On



the *elastic* cataract, 409. On the disorganization of the vitreous humour, 411. Operation adapted to this state, 415. On the advantages of reclinatio through the cornea over that through the sclerotica, 416. Order of operations for *hard* cataract, 416. Division only applicable to *soft* cataracts, 417. Advantages of division, 418. Disadvantages, 418. Observations on the disadvantages attending it, 419. The preference given in Germany to division through the cornea, doubtful, 420.

ON THE OPERATION FOR THE FORMATION OF AN ARTIFICIAL PUPIL.

On the different methods of restoring vision, 421. First, By division of the iris (coretomy), (iridotomy), 421. Second, By excision of the iris (corectomy), (iridectomy), 422. Third, By separation of the iris (coredialysis), (iridodialysis), 423. Fourth, By excision and separation combined, 424. Fifth, By making an opening in the sclerotica, 424. Sixth, By separation and division of the iris through the sclerotica, 424. History of the operation for artificial pupil, 424. Mr. Cheselden's method, 1728; Morand's, 425. Janin's 1st, 426. Sharpe's, 427. Janin's 2d, 428. Gendron's, 430. Guerin's, 430. Wenzel's, 430. Richter's, 431. Pellier de Quingsy's, 431. Plenck's, 431. Assalini's, 431. Buzzi's, 432. Forlenza's, 432. Arneman's, 433. Travers, one of his methods, 433. Jurinne's, 433. Gleize's, Demours', Scarpa's 1st, 434. Schmidt's, Sabatier's, Maunoir's, 436. Scarpa's 2d, 437. Donegana's, 440. Gibson's, 441. Sir W. Adams's, 442. B  r's, 445. Reisinger's, 449. Himly's, 459. Buckhorn's, Richerand's, Flajani's, 460. Walther's, 461. Langenbeck's, 461. Frattini's, 464. Gr  fe's, 464. J  ngken's opinion, 465. Wagner's method, 465. Embden's, 465. Dzondi's, 466. Zeng's, 467. Schlagintweit's, 467. Faure's, 467. Montain's, 468. Muter's, 468. Ryan's, 469. Quadri's, 470. Preliminary observations and classification, 471. On the proper size and form of an artificial pupil, 471. Places of election for its formation, 471. A sound part of the iris to be selected, even if less favourable from position, 472. The central part frequently unsound, 473. Operation not to be performed when one eye is sound, 473. Operation doubtful where the vision of the other eye is impaired, 474. The ciliary processes offer an impediment to the entrance of light, 475.

*Classification.*

Divided into three classes, 475. First class divided into two sections, *a* and *b*, 476. Second class, no division, 476. Third class, eight



sections, *a* to *h*, 476. Closure of the pupil not the principal point, 477. The practitioner will gain great assistance from his acquaintance with other diseases, 477. Operation useless when closed pupil is combined with amaurosis, glaucoma, varicosity, dropsy, or atrophy of the eyeball, 478. The most favourable appearances of the eye for operation, 478. Favourable after the operation for cataract by extraction, 478. Unfavourable after the operation for cataract by depression, 479. General convexity of iris unfavourable, 479. Opinions as to the membrane of the aqueous humour, 479. Nature of alterations of colour of the iris, 481. Closed pupil combined with amaurosis, 481. Closed pupil resulting from inflammation after an injury on the forehead, 482. Closed pupil resulting from the passage of musket balls behind the eye, 482. The iris thin, with lens adherent, 482. The iris puckered and fleshy, the vessels of the eye varicose; *Cirsophthalmia*, 483. Closed pupil combined with glaucoma, 483. Closed pupil with increase or diminution of the eye, 483. Closed pupil with dissolution of the vitreous humour, 483. Opinions of B  er, &c., 484. In such cases, the history of material importance, 487. A particular motion of the iris, 487. Before an operation is attempted, the eye must be free from inflammation, 489. Attention must be paid to the constitution, 489.

*First Class.*

*Section a*, 490. Closed pupil, without a lens, favourable for the operation for division (*coretomia*), 491. Especially after extraction of the cataract, 491. Method of operating by division, 492. Reasons why the iris is not always easily divided, 493. Sometimes cannot be divided, 495. In such cases, *coredialysis* recommended, 495. A spontaneous separation of the iris from the ciliary ligament never closes, 496. If two openings be made in the iris, they must be laid into one, 496. Sometimes the iris is very distensible, 496. The manner in which the knife is made to act on the iris, 497. The iris becomes flaccid from the escape of the vitreous humour, 498. *Section b*. Closed pupil with adherent lens, 498. The operation to be performed according to the nature of the case, 498. When the consequence of neglected inflammation, 498. Operation when the pupil is not less than one line in diameter, 499. Operation when the pupil is more contracted, 500. After the iris is divided, the lens is to be cut up, 500. The capsule prevents the retraction of the fibres of the iris, 501. The capsule alike the cause of reunion of these fibres, 501. Remarks on the interposition of a portion of the lens between the divided edges of the iris, 501. Sometimes



advantageous, sometimes the reverse, 501. May be the cause of inflammation, and not to be attempted, 501. Generally acts on the capsule, and not on the iris, 502. If the lens be found too hard, the remaining steps of the operation to be deferred, 502. Two-thirds at least of the iris must be divided, 502. The incision will yet often be too small, 502. Opinion of Sir W. Adams, 502. Objections to it, 503. In such cases, the operation with the scissors, or the core-dialysis, to be preferred, 504. Opinions of Maunoir and Scarpa on this point, referred to, 504. Objections to these opinions, 505. Objections of Scarpa to the operation of division by the knife, examined, 506. Objections of Sir W. Adams to the operation with the scissors, examined, 506. The author's opinion on these points, 507. In a case in which the lens is very hard or ossified, the scissors to be preferred, 512. The lancet-edged scissors recommended, as made by Mr. Stodart, according to the suggestion of Dr. Wollaston, 512. Operations on an adherent capsule, 512. When coriaceous, by opening the cornea and extracting it with hook or forceps, 513. When the pupil is closed by an adventitious membrane, Scarpa's needle may be used, 513. Operation attempted for the formation of an artificial pupil, by inducing inflammation on the iris, whilst the pupil is dilated, 513.

*General Treatment after the Operation.*

Twofold, to prevent, and to subdue inflammation, 514. Inflammation always to be expected, 514. Preparation before the operation, 515. Great reliance to be placed on blood-letting afterwards, 515. On the utility of mercury in iritis, 517. Equally valuable when occurring from a wound, 517. On local blood-letting, 517. The utility of the antimonium tartarisatum, in nauseating doses, 517. The inutility of this medicine, in active internal inflammation of the eye, when it produces incessant vomiting, 518. Pain not constantly present in inflammation of the eye, running on even to suppuration, 518. Treatment of the wound in the cornea, 519. Patient generally obliged to wear glasses, 519.

*Second Class.*

*Section a*, 520. The most favourable for the operation of excision (corectomia), 521. Method of performing it, 521. The opening in the cornea to be made with a rip, 521. Mr. Gibson's opinion, 521. Sir W. Adams's opinion, 522. Professor B  er's claim stated, 525.




*Third Class.*

*Sections a and b*, 525. The results of inflammation and ulceration, 526. Kinds of ulceration observed in this state of disease, 527. Observations on ulceration of the cornea, 527. Protrusion of the iris, not often the consequence of rheumatic inflammation, 527. On the treatment of interstitial abscess, 528. Use of the argenti nitratum, 529. An operation not to be attempted until the ulcer has healed, 530. Operation by the knife when the iris is attached by a point, 530. Operation by the scissors, 530. *Section c*, 531. Opinions on the part secreting the aqueous humour, 531. Operations for the relief of the derangement noticed in this section by Himly, Demours, Scarpa, &c., 533. *Section d*, 534. Excision usually recommended, 535. Separation at the ciliary ligament oftentimes more advisable, 535. Mr. Gibson's opinion, 535. His operation not advisable when the whole of the pupillary margin is attacked, 538. Operation by the scissors, 538. If the lens should become opaque, 539. The opinion of Mr. Cheselden considered as to this state of disease being combined with a diminished lens, 539. *Section e*, 541. This morbid state the result of inflammation, 541. Often causing staphyloma; mode of removing it, 541. Operation often useless, sometimes successful, 541. To be done with the scissors or single-edged knife, 542. Cases, 542. *Section f*, 542. Three operations recommended, excision, a vertical separation, and the coredialysis, 542. Excision in some cases prohibited, 543. A vertical division of the iris, inferior as an operation, and equally dangerous as the coredialysis, 544. *Section g*, 544. This state of eye admits only of one operation, the coredialysis, 544. Method of operating, 544. The iris, when separated, to be drawn out and cut off, 545. *Section h*, 545. Autenrieth's proposal to open the sclerotica, for the formation of an artificial pupil, 545. Beer's case and failure, 546. Author's case and opinion, 546.







## LECTURES

ON

## THE OPERATIVE SURGERY

OF

## THE EYE,

&c. &c.

### ON THE INVERSION OF THE EYELIDS.

THIS disease consists in an inversion or irregular direction of one or more of the eyelashes; either alone or accompanied by an alteration of the natural curvature of the eyelid, in consequence of which the edge of the tarsus is directed inwards, and great irritation ensues from the unusual friction of the hairs on the eyeball. It was called Trichiasis, Trichosis, by the ancients, from *τριξ*, pilus, a hair, and *στιχος*, versus, ordo; the disease being partial: Distichiasis, Tristichiasis, when there appeared to be a double or a treble range of hairs: Entropeon, Entropium, from *εν*, in, and *τρεπω*, verito, to turn, there being an alteration in the curvature of the tarsus; and Phalangosis, from *φαλαγξ*, acies quævis: Ptosia\*, when supposed to de-

\* "Trichiasim Græci vocant quam sanè sub pilis naturalibus in palpebris alii exorti, et intro nuentes, tunicas pungunt, et oculorum fluxiones concitant. Dicitur etiam trichiasis, quum ipsæ palpebræ laxatæ sunt, aut ipsarum extremitas intro nutat, ut pili non facile appareant, nisi quis distendat ac disparet palpebras. Vocant autem medici palpebræ laxationem phalangosim, aut casum. Pilorum vero subcretionem, duplicem pilorum ordinem hoc est distichiasim." *Ætius*, Tetrabibli 2, sermo iii, cap. lxvi.



pend on relaxation of the skin of the eyelid, the *Inversio Palpebrarum* of the Latins.

Some confusion has taken place in the proper application of these names to the different states of disease they were intended to designate; but the complaint is essentially the same under whatever name it may be characterized, differing perhaps only in degree. The principal distinction seems to have been made with reference to the derangement, as depending, 1st, on a false or irregular direction of the eyelashes; 2dly, on an augmented growth of them, forming, as was supposed, a double or a treble row; 3dly, on a vicious inclination of the edge of the eyelid, accompanied by either of the previous states of derangement of the eyelashes.

That the natural direction of the eyelashes may be changed, either separately or conjointly, has never been disputed; but that an extraordinary growth should take place, or a new row of hairs be formed, has frequently been questioned and often denied. That the eyelashes are not arranged in one regular row, as has been presumed, was long since remarked by Winslow and Albinus, who demonstrated, that, although their roots appear to be placed in one line, still the hairs themselves seem to form two, three, and in some cases even four rows, not partaking, however, of any regular order, although, for the most part, having the same general direction, outwards; but which inclination, as well as the arrangement of the roots of the hairs, may be so apparently changed by constant misdirection inwards, as to assume the appearance of an additional row; which opinion will be more readily entertained, if the patient should happen to have naturally thick eyelashes. Scarpa\* considers the idea of a morbid growth as purely imaginary. In this opinion I perfectly accord, conceiving the turning in of the cilia to be a secondary and not an original complaint; a consequence of disease and not a cause, which seems to be sub-

\* Scarpa, Treatise on the Diseases of the Eye, by Briggs, second edit. page 80.



stantiated by the fact, that children are seldom or never born with this unnatural distribution; but that it occurs at a subsequent period of life, and after sufficient irritation has taken place in the part to account for this derangement. I have operated successfully on a child of ten months old; and this case strongly supports my opinion, as the child remained well after the lid was restored to its natural state, which would not have been the case if the hairs had originally been placed in an improper direction.

Gleize\* mentions two cases in which the eyelashes seemed to form four rows of hairs, and were troublesome from infancy.

Dr. Hosp, in an inaugural Dissertation, lately published at Vienna, and dedicated to Dr. Jaeger, the son-in-law of Beer, and whose practice it recommends, supports, however, the opinion of *Ætius* and *Paulus Ægineta*, of a double or præternatural row of hairs, called *pseudocilia*, arising from too luxuriant a growth; he says, "these spurious hairs do not turn from their regular situation from any disease in the part, or defect in the hairs, but from too luxuriant a growth, and truly spontaneous generation, being a *morbosæ vegetationis progenies*†."

Demours‡ maintains this opinion also, and says he has seen it twenty times in persons who were afflicted with it from their birth. But Boyer§ denies it, and supports the idea of *Scarpa*, of its being an accidental occurrence from continuance of disease; and that no distinction should be made between *trichiasis* and *distichiasis*.

My remarks do not, however, apply to the circumstance, which has been frequently observed and is well established, of one or more hairs growing from a part in which they are not usually situated, such as the *conjunctiva*, *caruncula lachrymalis*,

\* Gleize, *Nouvelles Observations pratiques sur les Maladies de l'Œil*. 1812, Orleans.

† Hosp, *Dissertatio medico-chirurgica*. Viennæ.

‡ *Dictionnaire des Sciences medicales*, article *Trichiasis*.

§ Boyer, *Traité des Maladies chirurgicales*, tome v, page 290.



cornea, or sclerotica. I lately removed from an infant three hairs, growing from the conjunctiva, near to its reflection from the eye to the external angle. The bulbous roots of these hairs, congregated together, formed a small tumour, which was easily seized by the forceps, and cut out by the scissors. It was congenital, and gave rise to symptoms resembling those of entropium. Dr. Monteath\* mentions a case, in which one exceedingly strong hair grew out of the conjunctiva, lining the lower tarsus. It was directed perpendicularly to the bulb. The natural cilia were of a light colour, the pseudocilium of a jet black, and double the strength of the others. These are evidently of a different description, and an accidental occurrence or sport of nature; but a partial change in the cilia, from a dark to a lighter colour, may be frequently observed, where the disease has been of long continuance; as well as an increase, both in the length and thickness of the hairs which are or have been inverted. These cilia will occasionally deviate considerably from the regular line, and turn in on the eye, after the cure of the general inversion has been accomplished. But those, which may be called pseudocilia, by way of distinction, are by no means a new growth, although differing in colour and in strength from the old ones; but new hairs, growing from the old bulbous roots, which have been altered in their direction, most probably by some injury inflicted on them in the evulsion of the original hairs.

The symptoms arising from the inversion of a single hair are very distressing, and sometimes give rise to acute inflammation; more frequently, however, when neglected, it becomes the cause of the inversion of the neighbouring cilia, and, by the gradual propagation of disease, to that of the whole lid. And although it may be confined to one eye in the first instance, still, from the sympathy which exists between them in every part, the other, in most cases, sooner or later becomes affected; being another confirmative proof that the

\* Monteath's Translation of Weller, page 115.



complaint is a symptomatic and not an idiopathic disease; the inversion taking place in the second eye evidently as a consequence of sympathetic inflammation.

The first effect of an inversion of one or more hairs is the inflammation of the conjunctiva lining the palpebræ and covering the ball of the eye, which soon increases and becomes more than usually painful from the interposition of the hairs augmenting the sensibility of the part, and giving rise to a constant desire to move the lid, which motion essentially aggravates the complaint, whilst the pain it causes prevents its completion. The intolerance of light is considerable, the flow of tears copious, and, in the first instance, hot. The skin below the eye becomes red and excoriated. The head ache is severe, and the sufferings of the patient are without intermission; the general health becomes materially deranged; and it is recorded that one person, aware of the cause of his misery, cut away with his own hand the edge of the tarsus, as well as the offending hairs. The inflammation of the conjunctiva is communicated to the cornea, which becomes opaque, and frequently falls into a state of ulceration, whilst that portion of the conjunctiva which covers it, is always more or less abraded, or opaque. The acute stage of the disease seldom continues so long as to destroy the eye, but gradually degenerates into a chronic state, subject to frequent excitement on the slightest exposure or irregularity. These relapses terminate in some instances, although rarely, in the loss of vision; but in general the result is ulceration of the cornea, followed by opacity and thickening of the conjunctiva: the eyelids are contracted. The secretion of the meibomian glands is early augmented in quantity and vitiated in quality, agglutinating the eyelashes to each other, and collecting to such a degree during the night as to close the eyes, and render considerable ablution necessary before they can even be examined. In this state, and nearly blind, the unfortunate sufferer tries to open the eyelids just sufficiently to enable him to guide himself from place to place. He endeavours to see,



not by moving the eye in the usual manner and directing it towards the object to be viewed, but by moving the head so that the eye may be opposed to the object, with as little motion as possible either of it, or of the eyelid. This frequently gives to the patient the appearance of a wry neck; and in children or very young persons, where the head inclines to the shoulder, and the shoulder is raised to support the head, permanent contraction of these parts, or distortion of the spine, may actually take place.

The conjunctiva lining the palpebræ is found in very different states; sometimes villous, or granulated, and occasionally even fungous. In general, if the disease be of long standing, it is considerably thickened, always altered in its texture, contracted in its extent, and roughened on its surface; but by no means showing that granulated or fungous state which is so commonly observed, and which is so important a feature in chronic inflammations of the membrane, unaccompanied by entropium. I am disposed to say, that the constant pressure of the tarsus on the eyeball is incompatible with that completely granulated state of the conjunctiva to which I have alluded, and which remark would seem to be confirmed by the fact, that more simple and less continued means are necessary for the restoration of the conjunctiva, after the proper operation has been performed, than would be required in a case of chronic inflammation of equal standing without any inversion of the lid.

When the disease has existed for a considerable time, the integuments become of a redder colour than natural; the folds of skin, usually observed at the upper part of the lid, disappear; it is altogether thickened, and the cartilage assumes a vicious or unnatural curvature, which is most observable at the inner angle: this, with the contraction of the conjunctiva at the commissures, and a slight ulceration or excoriation, which frequently takes place at the outer canthus, prevents the separation of the eyelids from being accomplished without considerable pain. The constant effort at nictitation, or wink-



ing, which prevails from the commencement of the disease, and the increase of sensibility of the parts, augment the size and power of the orbicularis muscle; and that portion, which runs upon the edge of the eyelid, and has been described as a distinct muscle, appears more particularly affected by it; so that the patient is capable of opposing a greater resistance to the forcible turning out of the lid, than is usually experienced in a healthy state. This increase of power is, however, frequently observed in cases of chronic inflammation, unaccompanied by entropium. In cases where the disease has been attempted to be relieved or cured by the evulsion of the hairs, or by the burning of their roots, after the tarsal cartilage has obtained a vicious direction inwards, there is this peculiarity in the appearance of the eyelid; that the cilia are scarcely, and sometimes not at all, perceptible, unless on a careful examination, and even then occasionally requiring a magnifying glass, when the remains of those which have been broken, or the strong stiff stumps of others sprouting forth, may be observed on the edge of the lid, and which, from the vicious inclination of the tarsal cartilage, must cause great irritation to the eye. In these cases the means of cure have added to the complaint, and rendered it more difficult of accomplishment, whilst the unnatural curvature of the lid will readily distinguish it from any scrofulous affection, in which the cilia are wanting.

This sketch of the disease, in its worst stages, is by no means overcharged: the unfortunate sufferer may exist with it for years, enduring more or less of misery, until he be relieved by the efforts of art; or the cornea, as Mr. Saunders\* has observed, thickens and indurates in an extraordinary degree, assuming a shining white appearance, like a macerated ligament; and then the patient's repose is found in the insensibility of the new-formed substance.

These observations have reference principally to the inversion of the upper lid, but they also apply generally to that

\* Saunders on the Eye, page 75, edited by Dr. Farre.



of the lower lid, which sometimes exists conjointly with that of the upper, aggravating in every respect the disease. But when it occurs in the lower, without any affection of the upper lid, it is not quite so troublesome a complaint, being more manageable by artificial means, although, if neglected, rendering the patient's life equally uncomfortable.

The causes of this disease must necessarily be various, and sometimes dissimilar; from that state in which a single hair turns in and irritates the eye, to a complete inversion of the whole lid. A single hair sometimes takes a wrong direction after it has attained a certain length, and irritates the eye, so as to render it very uneasy, without any perceptible cause, which can be discovered on a careful investigation. A general officer, a friend of mine, has one hair which turns in, without any obvious cause, after having attained nearly its natural length; and as the removal of it is sufficient to relieve him from all inconvenience, he is contented with its occasional extraction. Ulceration occurring on the edge of the tarsus, or conjunctiva lining it, or immediately implicating the roots of any of the hairs, frequently gives rise to inversion of the cilia, when cicatrization takes place; but this applies to a partial rather than to a general inversion. In the same manner, small encysted tumours, situated near the margin of the lids, frequently displace the cilia immediately near them; and after they have been removed, the derangement of the lashes may remain, unless means be adopted to cause the cicatrix to draw the lid outwards rather than inwards. A want of cleanliness is by no means the least cause of a partial inversion; I am, indeed, inclined to believe, that it is one of the most frequent, if not the most important; and more especially when there is an increased and vitiated secretion from the meibomian glands or conjunctiva tarsi, by means of which the hairs become matted to each other, and turned in upon the eye; giving rise to an increase of all the symptoms, which again in turn lead to further mischief, and establish that as a permanent derangement, which was at first merely an accidental occurrence.



Complete inversion of the lid, or entropium, is, however, a consequence of chronic inflammation, and may therefore take place at every age, in every habit, and in every situation of life; but naturally prevails most among the poor, from want of cleanliness. In the lower lid it may occur before the inflammation has completely passed into the chronic state, in consequence of the swelling of the conjunctiva, and the oedema of the integuments, causing the edge of the lid, which is confined by its attachments, to roll inwards.

Mr. Ware\* has conceived, "that when trichiasis affects the upper lid, it must be owing to a relaxation of the levator palpebræ superioris, and a contraction of the superior part of the orbicularis; whereas, in the case of a trichiasis affecting the lower lid, it can only arise from a relaxation of the skin and a contraction of the inferior part of the orbicularis. And as in these two cases the causes of the disorder are very different, they will in consequence require a very different treatment." But later observation has disproved these opinions of Mr. Ware, the proper operation being in both cases alike in principle, and nearly so in execution; whilst a relaxation of the lid, without inflammation of the conjunctiva, has been found incompetent to its formation.

Mr. Crampton has not only pointed out the principal cause of the disease, *viz.* the contraction of the angles of the lids; but has nearly indicated the proper method of cure. He first demonstrated, that the levator palpebræ superioris was not inserted into the upper or convex margin of the tarsal cartilage, as was previously supposed, but into the parts connected with it and the conjunctiva†; in consequence of which he

\* Ware on the Ophthalmy, 2d edit. page 93.

† Crampton's Essay on the Entropeon, page 28. He says, "That it is not inserted upon either margin I ascertained by the following dissection: I raised the conjunctiva of the upper eyelid: beginning at the inferior margin of the tarsus, and continuing my dissection beyond its superior or semicircular edge, I found that the tendon of the levator remained attached to the conjunctiva upon one side, and to the integument of the eyelid upon the other. The levator palpebræ, there-



lays considerable stress on the contraction and thickening of this part of the membrane being a principal cause of the inversion, and therefore recommends its division; but in this I cannot coincide, and suspect it has not the influence he attributes to it in the formation of this disease, and therefore conclude, that the subsection, or division of it, which he recommends, is at least unnecessary, if not injurious.

The eyelids, in all their component parts, are more or less engaged in every case of inversion of the lids, but in different proportions at different periods of time, and in different ways, according to the activity or nature of the preceding or accompanying disease. In the most severe cases affecting the upper lid, the disease is generally the consequence of acute, followed by chronic inflammation, during the formation and continuation of which, a thickening and contraction of the conjunctiva takes place more or less, in *every direction* in which it is loose, but more particularly towards the external and internal angles, and by continuity of parts to the cellular texture, by which it is attached to the ligament supporting and maintaining the eyelids in their proper situation. This ligament may be considered as a process of the epicranium, or as arising from all the edge of the orbit, and forming, more particularly with the conjunctiva at the external canthus, a very strong fold, which whilst it unites and confines the tarsal cartilages, maintains the proper opening of the eyelids. This is much more acute at the outer than at the inner angle, and the thickening of this part, and consequent contraction of the aperture, appears to be greater than usually takes place at the inner angle, where the ligamentous structure is weaker, apparently from the additional fore, is not inserted into the tarsus, but merely connected with it by means of the attachment of this last to the conjunctiva, and to the integuments." — It would have been more correct to have said, that the muscle is inserted into the conjunctiva, and into the process of the epicranium, or broad ligament suspending the tarsal cartilage, to the upper edge of which the ligament is affixed. The integuments and orbicularis muscle are external, the levator palpebræ muscle is internal to this ligament. — G. J. G.



support derived from the insertion of the tendon of the orbicularis muscle, and where a more obtuse angle of union or larger opening is necessary from the situation of the lachrymal apparatus. The consequence of this contraction at the angles or commissures of the lids, and more especially the outer one, is a diminution of the size of the opening, which may be observed in all cases of chronic inflammation, with or without inversion. It takes place in acute inflammation as a voluntary act, to exclude the light, and is continued subsequently from contraction of the parts, until relaxation ensues from the subsidence of disease: when the eye, which had previously been considered by the patient and his friends to be smaller than the other, re-assumes its natural appearance. This contraction of the angles frequently diminishes the aperture between the lids to one half its natural size, and is very inconvenient to the surgeon when examining their inner surface, as it renders the inversion of the upper lid a difficult operation, which in a state of health is accomplished with the greatest facility; the fold of the conjunctiva, and the ligament forming the angle, yielding in the one case readily, whilst they resist powerfully in the other.

The conjunctiva lining the cartilage of the upper lid is also thickened, showing a villous, and occasionally a granulated surface; but neither a villous nor a granulated surface, lining or superior to the tarsal cartilage, and which latter state of disease is scarcely ever to be seen, have any influence in shortening the eyelid, or more especially in turning the edge of it inwards, as Mr. Crampton supposes\*; because, 1st, in the

\* He says, "From the very lax state of the conjunctiva, which is necessary to admit of the free motion of the eye in every direction, it would follow, that in every sudden motion of that organ upwards and backwards the membrane would be thrown into irregular folds, which by falling upon the cornea would at once obstruct the movements of the eye and interfere with vision. But this is obviated by the nice adjustment of the levator palpebræ to the conjunctiva; for at the same moment that the 'attollens oculi' acts in rolling the eye upwards, the 'levator palpebræ' contracts, in order to remove the eyelid from before the axis of vision, and draws back with it the loose



worst cases of a granulated, or more properly fungous state of the conjunctiva, we often find that there is no inversion of the upper lid, but frequently rather a tendency to slight eversion. 2dly, That as the conjunctiva of the tarsus is firmly attached to it, the action of the levator palpebræ must be on the whole and not on the edge; and the experiment of holding the eyelashes of the upper lid between the finger and thumb, and drawing the eyelid gently downwards, whilst the patient rolls the eye upwards, is by no means conclusive, as Mr. Crampton supposes; for the orbicularis is acting all the time to shut the eye, and the natural elasticity of the cartilage is also acting to bring it to its proper situation, precisely in the same manner and with the same consent that the rectus superior and the levator palpebræ act together when the eye is rolled upwards.

conjunctiva upon which it is inserted, and the tarsus with which it is connected. Thus, by one contraction of this muscle the eyelid is raised and the loose conjunctiva is lodged in the triangular space, which I before described as contained between the roof, the orbit, and the superior surface of the globe of the eye. But should the conjunctiva by any means become so contracted in its extent as to confine the free motions of the eye, it must necessarily follow, that upon rolling the eye upwards and backwards the yielding margin of the eyelid upon which the conjunctiva terminates will be drawn inwards upon the eye. When the contraction increases (and we know that a disposition to contract is common to all secerning membranes), so that the folds are not only obliterated, but that the internal membrane becomes actually shorter than the internal integument; the margin of the tarsus, deriving no support from without, and constantly acted upon from within, readily yields and becomes permanently inverted.

“Although this may happen independent of the action of the levator palpebræ and orbicularis palpebrarum muscles, it is easy to conceive that their contraction must operate in increasing the disease. And first with respect to the levator palpebræ: I have only to remind my readers of the attachment of its fibres to the conjunctiva, and of this last to the tarsus, to make it at once evident, that every contraction of the muscle, by drawing backwards and consequently tightening the conjunctiva to which it is attached, must operate forcibly in increasing the inversion of the cartilage.”



The inversion of the edge of the lid appears more clearly to depend on the contraction of the angles, the undue action of the orbicularis muscle, and particularly that part of it called the musculus ciliaris, as well as on a vicious curvature of the cartilage; which deformity is proved to exist by the fact, that if the cartilage be cut completely from its connection at each angle, its superior attachment remaining entire, the inversion will be removed, as far as the vicious curvature will permit.

The extreme pain (on motion), hitherto supposed to depend principally on the contracted and diseased state of this part of the conjunctiva, cannot fairly be attributed to it, unless it also attends the same state of disease without entropium; and as this is known not to be the case, the supposition is evidently erroneous. The increase of pain must therefore be attributed to the irritation excited by the hairs which are pressed against the highly sensible conjunctivæ on any attempt at motion.

It may be fairly objected, that if a granulated and diseased state of the conjunctiva takes place without any signs of inversion, contracted angles and a diminished aperture are frequently observed without entropium; which is so far true, inasmuch as inversion does not always occur, but there is invariably an evident tendency to it; and in cases of long standing this is accompanied by a commencing alteration in the curvature of the cartilage; and it is upon due consideration of these circumstances I have said inversion does not depend upon one but on several causes, which lead to the same point, although acting variously and at different times. In the lower eyelid, inversion takes place very readily, although there is no levator palpebræ, or muscle directly corresponding to it; there is frequently little or no apparent alteration in the appearance of the conjunctiva, and certainly not sufficient, when the lid is depressed, to warrant the conclusion that the contraction or derangement of it has drawn the edge inwards. On the contrary, in nine out of ten of these cases, it is evident that the inversion has been occasioned by a relaxed and



oedematous state of the integuments, occurring during inflammation, accompanied by a contraction at the external angle, which thereby shortens, and binds the edge or upper part of the lid across the ball of the eye, whilst the swelling draws the under part directly outwards, and, on the slightest motion of the orbicularis, alters the natural direction of the part, and turns the edge of the eyelid inwards. The proof of this is, that a simple perpendicular incision at the external angle, which divides the stricture, restores the part to its natural situation, and cures the disease. In the upper lid, the swelling and relaxation of the integuments have not so much influence, from the greater extent of the lid; but the contraction, shortening, and binding of the lid upon the ball of the eye, are materially assisted by the action of the orbicularis, which in many instances is really spasmodic. This spasmodic contraction of the eyelids, during inflammation, is often so great, especially in children, that it is with considerable difficulty the eyes are examined, and in many instances is so complete, that the eyelashes cannot be seen until the lids are partly separated. Partial inversion, in such cases, is very common, but is in general removed by the subsidence of the inflammation, and the consequent cessation of the spasmodic action of the orbicularis, provided the curvature of the tarsus has not been altered. I have several patients in these states at present, and there is little wanting but an accidental inversion of one or two of the eyelashes to cause a complete entropium. This frequently takes place in poor persons, who attend very little to cleanliness; but with the rich, and those in better circumstances, it is not a common occurrence; whence the remark, that entropium is a disease which seldom affects the rich, although it prevails among the poor. If the eyelashes happen to be long and thick, and the secretion from the meibomian glands considerable and viscid, or allowed to remain, the disease is almost inevitable; whence its prevalence among the lower Irish, who are exposed, in their mud cabins, to the smoke of wood fires, which, although it may be nearly innoxious to them from



habit in a state of health, is highly irritating in a state of disease. Some persons have supposed that there may be a shortening of the cartilage itself in these cases; but that is impossible; and I have never found it even softened, which Scarpa conjectures may sometimes occur. My observations on this disease have then led me to the following conclusions:—

1. That the derangement of the eyelashes, constituting trichiasis, is frequently the consequence of disease; but seldom or never arises from unnatural formation, or from an accidental or too luxuriant growth of the cilia.

2. The relaxation of the integuments, or a partial paralysis of the levator palpebræ, in a natural and otherwise healthy state of the eye and eyelids, are not primarily concerned in the formation of entropium, and never alone give rise to it; although, if other derangement take place, they may (by removing some power of resistance to it) assist in its more complete formation.

3. That, in a general or complete inversion of the edge of the tarsus of the upper lid, the swelling of the external parts, and the spasmodic action of the orbicularis palpebrarum, first tend to the formation of the disease, which is completely established by the contraction of the angles of the lids and the accidental inversion of such hairs as become stiff and matted by the vitiated discharge from the meibomian glands and conjunctiva.

4. That the change in the curvature of the lid takes place principally from the contraction of the angles, whilst under the influence of the orbicularis, and not from the contraction of the conjunctiva, corresponding to the superior broad ligament, which supports the tarsus, and maintains the shape of the upper eyelid.

These conclusions do not, of course, apply to such partial cases of trichiasis as result from the formation of a cicatrix, tumour, or other direct and obvious cause, to which I have already alluded.

There are few diseases in which so little alteration in the



methods of operating has taken place since the time of Hippocrates\*. He recommended a ligature to be passed through a fold of skin, by means of a needle, which was then to be tied and allowed to remain until it ulcerated its way out; if this was not sufficient, the same operation was to be repeated. Galen attributes to Heraclidus of Tarentum the introduction of adhesive plaisters to glue the hairs to the lid; and to Antonius Musa, physician to Augustus, the use of a paste, composed of alum and vitriol, to destroy the offending hairs. Celsus† recommends two more violent methods. The first was burning the roots of the hairs with a red-hot needle until they were destroyed and subsequently dropped out. The second was to raise and cut off a fold of the skin, bringing the edges of the wound together by ligatures, not exceeding three in number. A scarification was then to be made in the eyelid (upper) under the roots of the eyelashes, that, being raised from the inferior part, they might point upwards. Ætius introduced or recommended several remedies, now of no importance, to prevent the regrowth of the hairs after they had been pulled out. The sixty-seventh chapter of his work contains a list of them, and among others the blood of a frog, and the remains of a burned lizard. The sixty-eighth is full of agglutinative remedies, by which the hairs may be fastened to the external skin; and, lastly, as a radical means of cure, in addition to the removal of the fold of the skin, described by Celsus, he advises a division of the conjunctiva, above the roots of the hairs, from the

\* Hippocrates, by Vander Linden, page 321, vol. ii. "Ad trichiasin, id est pilos pungentes in palpebris enascentes. Immissum in acum foramen habentem filum, in summa supernæ palpebræ margine deorsum versus perpunctione facta trans mitte, et aliud itidem sub hoc inferne trajice: extenta fila consue et deliga, donec decidant: et siquidem satis habuerit, bene est; sin minus, et quid defecerit, rursus eadem facito."

† Celsus, De Re Medica, lib. viii.

‡ Ætius, Tetrabibli 2, sermo iii.



outer to the inner angle, and even a second incision in inveterate cases, in the same direction, but nearer to the edge of the lid\*.

Paulus Ægineta†, in addition to a similar surgical operation, recommends the application of a caustic externally, composed of two parts of quick lime to four of soap. He does not, however, notice it as a new method, but rather as one well known; and not only gives a caution, that too much skin may not be destroyed, and a lagophthalmia, or shortening of the lid, take place, but in the next chapter specifies the mode of obtaining relief, when such an effect shall have been produced.

Rhases‡, after enumerating the usual methods, directs the tarsus to be cut off in inveterate cases, but does not describe the operation. The invention of an instrument, or forceps, for compressing a fold of the skin of the eyelid, and thereby causing its eversion, is also attributed to him.

Bartisch§ and Verduin|| improved upon this instrument, so as to render it more convenient to the patient during the time it was necessary to be worn, before the removal of the portion of skin it enclosed was accomplished.

Heister¶ informs us, that Cortumius, in his Dissertation

\* “Eversa palpebra, subsectionem intrinsecus faciamus, ultra pilos præter naturam exortos, quo ipsi ad naturales foras tendant. Aliquando vero in ipsos pilos præternaturales, si penitus insiti fuerint subsectionem facimus, ut succedens cicatrix ipsos rursus enasci prohibeat. Nihil autem vetat etiam duas subsectiones facere, unam ultra pilos præter naturam exortos, quo extremitatis palpebræ fiat resiccatio: alteram super ipsos præternaturales pilos. Sit autem profundior subsectio, adjuvat enim refractionem et palpebræ levitatem: et ab altero extremitatis sine marginis palpebræ termino usque ad alterum procedat.”

† Paulus Ægineta, liber vi, cap. ix. Quomodo Palpebræ Medicamento urantur.

‡ Rhases, De Re Medica, lib. ix, cap. xxvi.

§ Bartisch, Medic. Oculorum, page 181.

|| Verduin, Morbi Oculorum, page 211.

¶ Heister's Surgery, part ii, page 392.



de Trichiasi, addressed to Professor Gaelicke, 1724, proposed the use of the potassa fusa, for the destruction of the edge of the lid, rather than resort with Rhases to the removal of it by the knife.

From this period until the present time, little attention seems to have been paid to the disease. In France, Maitre Jan\*, who published in 1702, doubts whether the operations described by Celsus, Paulus, and Ætius, were ever practised; although he informs us that the inhabitants of Alexandria, in Egypt, among whom trichiasis was very common, were in the habit of applying a red-hot plate of gold to the edge of the lids, in order, by the formation of a cicatrix, to prevent or cure the disease; he contents himself, however, with recommending the removal of the hairs, and a mild treatment of the eye. St. Yves† advises the removal of a fold of skin; and from him to Gendron‡, Dionis§, Janin||, and Gleize¶, down to Wenzel\*\*, Boyer††, and Demours‡‡, no alteration seems to have taken place in this practice, with the exception perhaps of the proposal of Professor Beclard, noticed by the latter, of dividing the edge of the eyelid perpendicularly, which gives rise, he observes, to a slit resembling a species of hare-lip, an infirmity much less troublesome than the original complaint. The Italians have added little or nothing to our knowledge. Scarpa§§, who has done so much in the improvement of the treatment of

\* Maitre Jan, *Traité des Maladies de l'Œil*, 2d edit. 1712, 602.

† St. Yves, *Nouveau Traité des Maladies des Yeux*, Paris, 1722, 102.

‡ Gendron, *Maladies des Yeux*.

§ Dionis, *Cours d'Opérations de Chirurgie*, Demonstrat. 6.

|| Janin, *Maladies de l'Œil*, Paris, 1772.

¶ Gleize, *Nouvelles Observations*, &c. Orleans, 1812.

\*\* Wenzel, *Manuel de l'Oculiste*, 2d edit. Paris, 1808.

†† Boyer, *Maladies Chirurgicales*, 1818.

‡‡ *Dictionnaire des Sciences Medicales*, art. Trichiasis; Paris, 1812.

§§ Scarpa on the Diseases of the Eye, by Briggs, 1818.



other diseases, contented himself with the operation of removing a portion of the skin of the eyelid. Monteggia\* advises either the knife or caustic for the same purpose. Baratta†, who published at Milan in 1818, follows the directions of Scarpa; and Quadri‡, of Naples, did the same, until he became acquainted with the use of the sulphuric acid, as recommended by Helling.

The German ophthalmologists, as they term themselves, although aware of the almost incurable nature of the disease by the means usually adopted, have not suggested any other, but the total removal of the part; for, although the introduction of the sulphuric acid by Helling, in 1814, may be considered as, and is actually, an improvement, still it is but an improvement on the caustic used by Paulus Ægineta, and cannot be considered as a new method. Beer§ recommends the evulsion of the hairs in the slighter cases, although he admits he never effected a cure by it, but in children; whilst in the more severe and intractable ones he advises the removal of a fold of skin, and the use of sutures. Langenbeck|| is of the same opinion, but insists on the removal of the sutures at the end of twelve, or, at most, twenty-four hours, in order to prevent suppuration. Weller¶ says, if there be a deranged form of the edge of the eyelid, a radical cure will rarely be practicable, in which opinion he is supported by Beer, and confines his advice to the occasional removal of the offending hairs. Schreger\*\*, in one instance, cut out a triangular piece of the eyelid, and with it the disease, leaving,

\* Monteggia, *Instit. Chirurg. seg. 1, p. iii, cap. 3.*

† Baratta, *Osservazioni pratiche, &c. Milani, 1818, page 112.*

‡ Quadri, *Annotazione pratiche sulle Malattie degli Occhi, Napoli, 1819.*

§ Beer, *Lehre von den Augenkrankheiten, Wien, band ii, p. 114.*

|| Langenbeck, *Neue Bibliothek, band i, p. 415 et seq. 1818.*

¶ Weller, of Berlin, 1819, translated by Dr. Monteath, of Glasgow, 1821.

\*\* Schreger, *Chirurgische Versuche, band ii, p. 253, Neue Methode die Trichiasis zu Operiren, Nuremberg, 1818*



however, a deformity greater than that noticed by Beclard. Lastly, Dr. Jaeger, the son-in-law of Beer, recommends the removal of the edge of the eyelid, including the cilia; but as Dr. Hosp, to whom I have already referred, gives a detailed account of the operation, I shall extract it from his pamphlet\*, more especially as Dr. Jaeger sent it to me as containing the most correct statements of the practice pursued at Vienna. He says, "The patient being seated, and the upper eyelid raised by an assistant, a thin plate of horn, affixed to a handle, is to be placed underneath, and the lid being stretched over it and steadily secured, the surgeon is to make an incision from one angle of the eye to the other, about one line at least above the origin of the cilia which have deviated from their natural direction, in order to cut above, but as close as possible to their roots; he then separates the parts down to the edge of the cartilage, leaving it entire. Taking hold of the extremity of the divided part with a forceps, having an eminence on one blade and a hole to receive it in the other, he separates it by repeated slight touches of the knife, and thereby removes the external edge of the lid, with the roots of the cilia, as far as the tarsal cartilage, leaving, however, the punctum lachrymale entire, and, as far as is possible, the excretory ducts of the meibomian glands. If any of the inverted hairs remain, they must be removed, and cold water carefully applied to the part; under the use of which it heals in a few days, and, as far as our observation has hitherto gone, without a bad symptom. If any of the bulbs of the cilia should have been overlooked, the new hairs will show themselves on the third or fourth day, like black spots on the surface of the wound, when they are immediately to be destroyed by caustic." He then relates the following cases, which I think it right to insert, as they are illustrative of the practice of Beer, and prove the insufficiency of Helling's method of cure by the sulphuric acid, whilst they are confirmative of that of Dr. Jaeger.

\* Hosp, *Dissertatio medico-chirurgica, sistens Diagnosin, et Curam radicalem, Trichiasis, Distichiasis, nec non Entropii. Viennæ.*



"Gargasch Ursala, a girl, 20 years of age, of a sound constitution, had enjoyed good health until she was seventeen years old, when she was attacked in both eyes by catarrhal inflammation, which, partly from want of care, partly from improper treatment, continued increasing for the space of three years, so that at last she could not walk without a guide.

"Having applied, on the 2d of May 1816, to the celebrated Professor Beer, the following appearances were remarked :—

"The skin, as far as the edge of each eyelid, was swelled and red; the margins of the palpebræ were turned towards the bulb of the eye; the cilia, glued together by mucus, lay upon the conjunctiva, irritating the eye. By raising the integuments of the upper eyelids, the cilia for the most part were drawn outwards, and on everting the lid, a contraction of the inner edge was observable. In the right eye, opacity of the cornea with thickening of the conjunctiva of the bulb (*panniformis*). The same appearances were observable in the other eye, but the symptoms were more aggravated, and the opacities of the cornea were leucomatous. The intolerance of light and discharge of tears were equal in both eyes, whilst the light was so much diminished, that the patient could only perceive larger objects very obscurely.

"After due consideration of the means of cure, it was resolved to try the method of Helling; and the concentrated sulphuric acid was applied on the upper lid of the left eye, by means of a pencil made of asbestos, and the usual phenomena were observed after this operation. On the following day the patient felt relived, and the improvement was progressive for several days, when the cilia were found to turn outwards, so as not to molest the eye, as the edge of the eyelid had returned to its proper position.

"On the 12th of May, a stronger caustic was applied in the same manner to the upper lid of the right eye, which proved more efficacious than in the left; for, the next day, the cilia



for the most part turned outwards from the bulb of the eye, and the edge of the lid had resumed more of its natural position.

“ During the following days, the cilia seceded more and more from the eye, the opacity of the cornea diminished, and in the same proportion the sight improved.

“ On account of the first application not being sufficient, sulphuric acid was again applied to the left eye, and the common integuments of the lid were so shortened by the action of the acid, that the patient could not exactly close the lids; yet the cilia did not altogether cease to molest the bulb of the eye, though the sight continued to improve, particularly in the right eye, but more slowly and less perfectly in the left, on account of the specks on the cornea.

“ At the end of two months her sight was so far restored that she could walk alone, and was then dismissed the hospital on condition she should attend daily for inspection. But soon after the girl had been dismissed, it might be observed by any one, that the continued action of the orbicularis muscle had overcome the mechanical resistance opposed to it by the cicatrix, and the integuments being thereby lengthened, the edges of the eyelids turned more to the bulb of the eye, and the cilia began again to irritate the conjunctiva, by which the original disease was re-established, but in a slighter degree. The means adopted not having proved effectual, whilst the integuments were still so contracted that the eye could not be properly closed, and the conjunctiva was seen during sleep, Dr. Jaeger, on the 16th of September 1816, performed his operation by excision of the cilia, on the upper lid of the left eye, and a few days afterwards on the right, with such success, that little treatment was necessary, and the patient recovered without much deformity, and has enjoyed the best sight for nearly two years.

“ In the course of eighteen months after the operation, the integuments of the eyelid became so much lengthened that she could perfectly close her eyes.



“Spriller Theresiæ, of Lower Austria, 26 years of age had been operated upon five years before her present application, by the celebrated Professor Beer, for entropium; and a portion of the integuments was removed from each of the four eyelids, by which a cure was effected, and she was dismissed. She had been, however, but a few weeks at home, when the hairs began again to turn in, the conjunctiva became in consequence inflamed and thickened, and the sight so defective, that at the end of the fifth year she again returned to the hospital. That the cause of the inversion was to be sought for in the alteration or corrugation of the tarsus, and not in the relaxation of the integuments, was obvious, from the circumstance of their still being very tense. Taught by experience, we were persuaded that a radical cure was only to be effected by the excision of the roots of the cilia, which operation Dr. Jaeger performed on the 13th May 1818, on the upper lid of the right eye; and on the 18th and 24th, on the remaining palpebræ. Little or no inflammation succeeded; the conjunctiva rapidly recovered; and, on the last day of the month, the patient was discharged, cured.”

This operation of Dr. Jaeger's, I think it proper to observe, differs but little from that which Mr. Saunders recommended, and which is described page 24, and was published many years before Dr. Jaeger first performed it.

In Great Britain and Ireland few improvements were attempted to be made until we come to Mr. Crampton, who published in 1806. Mr. Ware\*, after recommending the use of sticking plaister in slight cases, and the removal of a fold of skin in others more severe, adds, that if these methods prove unsuccessful, no other way remains of obtaining relief but by enlarging the circumference of the ciliary edges; which, he says, may be done by an incision at the outer angle, or by a complete division of the tarsal cartilage at its middle. He does not appear to have performed either of these operations; and if he had, they would not have suc-

\* Ware's Observations on the Ophthalmy, &c. 1805, page 96.



ceeded. He relates, however, a case that was operated upon (the 41st) by Mr. Bromfield, in a different manner, and which is a remarkable instance of incorrect reasoning on the cause of the disease, and on the effect of the operation. He supposed it to depend on a relaxation of the levator muscle, and therefore cut down upon it, and applied a hot iron to its insertion, in order to make it contract, which he imagined he had effected; whilst in fact he was doing nothing more than causing a general contraction of the parts by the actual cautery.

Mr. Saunders\* conceived, that "such a vicious bending of the tarsus took place, that every attempt at re-establishing its original position must be fruitless;" and although he considers Mr. Crampton's operation as highly successful, and "unexceptionable in the earlier period of the disease, before an unconquerable inclination of the tarsus towards the globe is produced," still he thought, that in "this ultimate and inveterate state of the disease, in which the contraction is often consequent on the cicatrization of the tarsus itself, it is altogether inexpedient." He goes on declaring any operation then known but the extirpation of the tarsus to be ineffectual, and concludes with the following description of it: "A piece of thin horn, or a plate of silver, having a curvature corresponding with that of the eyelid, is to be introduced, and its concavity turned towards the globe, within the eyelid, which is to be stretched upon it. An incision is to be made through the integuments and orbicularis palpebrarum down to the tarsus, immediately behind the roots of the cilia, and should extend from the punctum lachrymale to the external angle. The exterior surface of the tarsus is then to be dissected until the orbital margin is exposed, when the conjunctiva is to be cut through directly by the side of the tarsus, which must now be disengaged at each extremity—the only caution necessary being to leave the punctum lachrymale

\* Saunders, Treatise on some practical Points, &c. by Dr. Farre, page 12



uninjured. Nothing can be more simple than this piece of dissection; and if any embarrassment arises, it is from the bleeding of the ciliary artery, which must necessarily be divided; and this hemorrhage renders it somewhat difficult to observe the punctum, when one wishes to divide the tarsus by the side of it. If the operation itself be simple, the subsequent treatment is still more simple than the operation. In a word, no dressing is necessary, and it is only advisable to cover the eye, to conceal a disagreeable object from the patient's friends. In a few days an union will have commenced between the section of the integuments and conjunctiva, and the elevation of the skin will go on like that of the original eyelid, less complete indeed, but sufficiently so to leave the pupil clear during a moderate elevation of the eye. In all the patients on whom I have operated, a fungus of considerable size has sprouted from the centre of the section. This must of course be managed by caustic or the knife; and the latter is to be preferred, because it excites no subsequent irritation."

I have seen five persons on whom this operation has been performed, and in two of them by Mr. Saunders. In all the deformity was considerable, and the relief obtained only partial. One of these people is attending at the Infirmary at the present moment. Sixteen years ago he suffered from inflammation of both eyes, which terminated in entropium. The operation of removing the edge of the tarsus was performed six years afterwards by Mr. ———. The consequence has been, that the conjunctiva has remained in a state of chronic inflammation and thickening, the cornea is opaque and white, and nearly impervious to light. He does not suffer so much pain as he did before the operation, but the deformity is considerable, and he has been rendered nearly blind, and very miserable.

The operation of Dr. Jaeger being similar, the same objections of permanent deformity and imperfect cure apply to both; and a mutilation of this nature can indeed only be tolerated by comparison with the misery arising from the disease.



Mr. Saunders admits this; and Dr. Jaeger, I presume, must do the same, and only adopts it because he is unacquainted with any operation that will always succeed without a mutilation of the part. What Mr. Saunders says, that no operation known previously to his time, not even that of Mr. Crampton, invariably succeeded, may be true; and therefore he conceived it to be an incurable disease, and to be relieved only by the excision of the part: but as the alterations I have made in Mr. Crampton's method render it in my opinion equal to the cure of every stage of the disease, and as so many more cases of it have come under my observation, and have been cured by the operation I recommend, since the publication of the first edition of this work, I feel myself bound to add, that any surgeon who shall mutilate his patient, without having previously tried it, and failed, will be liable to the severest reprehension.

Mr. Crampton gives his method, in the case of Catherine Roache, page 63, operated on 29th of May 1802. "Having seated her with her back to a window, that she might open her eyes with greater ease, and her head being supported on the breast of an assistant, I raised the upper eyelid by means of the first and second fingers of my left hand, while I passed a very narrow slightly curved and sharp pointed bistoury between the eye and the eyelid at its external angle. I then pushed out the point of the knife so as to divide the internal connecting ligament of the tarsus and the external integument obliquely upwards. This incision was about three lines in length. I then made a similar incision at the internal angles, completely dividing the superior branch of the tendon of the orbicularis palpebrarum\*. The eyelid immediately felt unconfined, and its margin could with ease be turned outwards; however, I thought it necessary to divide the contracted conjunctiva; this was effected by running the knife along the

\* "The duct leading from the superior punctum lachrymale is divided in this part of the operation; but its division is attended with no bad consequences, as the new orifice remains pervious, and performs the function of the punctum lachrymale."



internal membrane of the eyelids, beginning at the external, and terminating at the internal angular section. As soon as the bleeding ceased the parts were washed and dried, and a suspensorium palpebrarum was applied in the manner described\*.

“ The first dressings were worn for thirteen days ; they then became loose and were removed, but the margin of the eye was completely restored to its proper position. However, three or four hairs that seemed to grow within the natural arrangement of the cilia, still rubbed against the cornea, and kept up a great degree of irritation. They were repeatedly extirpated, and various applications were tried to prevent their return ; but they increased in number and strength after every operation. This determined me to take some decisive step. Upon examining the tarsus minutely, I perceived a slight depression on its external edge, immediately over the inverted hairs, and a corresponding cicatrix on the

\* “ The suspensorium, with some trifling alterations in shape, differs very little from the elevator of Pellier. It is to be applied in the following manner : as soon as the tarsus is completely liberated at each of its extremities and along its entire length, the patient should be desired to look upwards, while the eyelid should be gently raised by the fingers of the surgeon ; the convex part (c) of the instrument should then be pushed gently backwards, between the roof of the orbit and the superior surface of the globe of the eye : the legs A A should then be laid upon the forehead, previously guarded with a thin compress, and the whole should be retained in its situation by a strap of linen covered with carpenter’s glue, and a calico bandage brought twice round the head ; the whole secured to a light cap by a few pins. As the legs of the instrument have a considerable curvature outwards, so as scarcely to touch the forehead, except at their extremities (bb), I usually allow the patient himself to perform this part of the operation ; telling him only to draw the bandage so tight as to sustain the eyelid, and turn its margin outwards without pressing upon the globe of the eye.” He considers that this instrument acts by forcibly pressing the parts into their natural situation, and retaining them there, until, by an alteration in their structure, they are enabled to perform their original functions.



internal membrane. I performed the operation in the manner described. The portion of the tarsus that contained the inverted hairs was supported in its proper position by a suspensorium palpebrarum, for almost three weeks, and the woman was perfectly and permanently relieved from her painful disease. In the month of February, 1804, she was examined by Dr. Stokes, Mr. Dease, and Mr. C. Roney."

Mr. Crampton's operation, then, as above described, appears to have succeeded perfectly in his hands; that it has been found insufficient in that of others is equally certain, arising, I believe, from the unequal effect produced by the suspensorium, and from its not acting in a sufficiently powerful manner, in the inveterate curvatures of the cartilage, on its bent extremities; and from his attention not having been directed towards them, and the establishment of a countervailing force; all of which indications are necessary to be, and are, I believe, fulfilled in the worst cases by performing the operation in the manner I shall point out.

If a hair turns inwards without any discoverable cause, I coincide in the directions given by Mr. Travers\*, "that it must be kept plucked, until, by the improved condition of the hair gland, under the means used, the disease is removed." He further adds, "if a case occurs in which the vitiated site or curvature of one or more cilia does not admit of correction, the corresponding follicle should be obliterated by repeatedly touching it with a fine caustic pencil." This method is also often effectual; but the application of the argenti nitratum, or any other caustic pencil, however finely cut, is frequently inefficient, and is apt to give rise to greater inconvenience from the cicatrices which may be formed from its use. When two or three hairs turn inwards in this manner, and continue to do so after repeated evulsion, the cause should be more narrowly inquired into. If a tumour be perceived, or excrescence, or irregularity, it must be removed; and while the operation is performing, the offending hairs should be cleared

\* Travers's Synopsis of the Diseases of the Eye, 1810, page 254



to the bulb, and this part destroyed by a gentle application of the caustic. This latter part of the operation may even be done in difficult cases in which no tumour exists; but where two or three hairs only turn in, with an irregularity of that part of the tarsus or contraction of the conjunctiva lining it, which may be perceived on turning it out, by a peculiar whiteness and thickening of the part, the operation described by Mr. Crampton ought to be preferred: "Let the eyelid be well turned outwards by an assistant; let the operator then with a lancet divide the broad margin of the tarsus completely through by two perpendicular incisions, one on each side of the inverted hair or hairs; let him then, by a transverse section of the conjunctiva of the eyelid, unite the extremities of the perpendicular incisions. The portion of the cartilage contained within the incisions can then, if inverted with care, be restored to its original situation." He further suggests the propriety of completely insulating, in difficult cases, a small portion of the margin of the tarsus, leaving it connected to the eyelid by the external integument only; and in all cases advises that the portion included between the incisions should be raised above the level of the ciliary margin of the tarsus, and retained in that situation by strips of adhesive plaister, or by the suspensorium palpebræ; but I have found both the plaister and the suspensorium insufficient, and recommend, when the tarsus has been divided, that a needle and thread be passed through the skin, close to the ciliary margin, and the thread fastened to the forehead by sticking plaister, by which the part may be suspended. This effectually answers the purpose; and if it appears to be restored to its proper place on the first dressing, the ligature may be removed; but I think it better to let it ulcerate its way out, by which a small cicatrix ensues, that tends to consolidate the part and give permanency to the cure.

In cases of chronic inflammation, where there is a commencing but incomplete general inversion of the cilia, the cure of the inflammation will be sufficient to restore the conjunctiva



to its natural state, and the cilia to their original direction, without any especial means being employed for the cure of the commencing inversion; but when this proceeds too slowly, the application of the sulphuric acid, recommended by Helling and Quadri, should be resorted to, and will always be found sufficient. Indeed, in many cases in which there is little incurvation of the cartilage, and a moderate contraction of the angles, it will supersede the operation to be hereafter described. Quadri\*, who has written a quarto in praise of this method, and which he also liberally attributes to Helling of Berlin, applies it in the following manner:—

1. A small quantity of concentrated sulphuric acid is to be applied, by means of a piece of smooth solid wood, to the centre of the affected part of the lid, and rubbed along on an oval space, a little exceeding in length the part on which the inverted hairs are situated, and from three to four or six lines in width, according to the inveteracy of the disease. The part ought to be wiped dry after the acid has been applied about ten seconds, in order to prevent any of it from getting into the eye.

2. The application of the acid is now to be repeated, taking care that it may approach the edge of the lid, and touch the parts immediately over the inverted eyelashes; and it is to be continued or repeated a third or a fourth time, until the contraction of the parts draws the hairs from within outwards, or to their natural situation; when the operation is completed, and the part ought to be again thoroughly dried.

Quadri recommends, however, that the cilia be collected in three or four places, and tied together by pieces of silk, which may be afterwards attached to the forehead by means of sticking plaister, thus raising the lids upwards. But as he loosens these ligatures on the third day, and as the effect intended to be produced principally takes place after that period, in the contraction and cicatrization of the parts on the sepa-

\* Quadri, *Malattie degli Ochi*, &c. Napoli, 1819, page 68.



ration of the eschar produced by the sulphuric acid, I do not perceive their utility, whilst they are certainly very inconvenient.

Where patients will not submit to an operation by the knife, this is perhaps the next best means of cure; it causes, however, more deformity, is less certain, and does not succeed in severe and inveterate cases.

The operation I recommend, as equal to the cure of the worst cases, is to be performed in the following manner:—The head being properly supported, the eyelids are to be gently separated; the patient is to be desired to refrain from making any effort whatsoever, and the surgeon is to wait until he sees that the lids are perfectly quiescent. A small narrow knife, or one blade of a blunt-pointed scissors, is then to be introduced close to the external angle, and a perpendicular incision made, of from a quarter, to half an inch in extent, or of a sufficient length to render the eyelid quite free; the quiescent state of the lids, and especially of the orbicularis muscle, enabling the surgeon to cut closer to the angle than he otherwise could do, and thus to divide the ligament, or at least the extremity of the cartilage. Another incision is to be made, in a similar way, at the inner angle; this should not include the punctum lachrymale, but be external to it, as I have never found it necessary to divide it; for, although the tears may continue to pass through the lateral canal into the sac, when the punctum has been included in the incision, they do not do so with equal freedom, and there is some observable deformity. The length to which the perpendicular incisions at both angles ought to extend, must now be decided upon by the appearance of the part; they must be continued, if necessary, by repeated touches with the scissors, until that part of the eyelid containing the tarsal cartilage is perfectly free, and is evidently not acted upon by the fibres of the orbicularis muscle, which lie upon it. This frequently causes the incisions, and especially the internal one, to be longer than is usually supposed to be necessary. The part included in the



incisions is now to be completely everted, and retained by the fore finger of the operator's left hand against the brow of the patient; when, if any lateral attachment be observed, acting upon, and drawing, or confining the lid, it is to be divided, which is in fact still elongating the incision. On letting the eyelid fall on the eye, the edge of the tarsus and the hairs will frequently appear in their natural situation, in consequence of the relaxation of the angles, which bound them down; but if the tarsal cartilage has become altered in its curvature, this will be immediately perceived; it will turn inwards at its ciliary edge, and be completely bent at its extremities, more especially at the inner one, where it is more powerfully acted upon by the *musculus ciliaris*. On desiring the patient to raise the lid, he readily attempts it, but the action of the levator, in such cases of vicious curvature, causes the cartilage partly to resume its situation\*; and, on examination, the curve will be observed to be so permanently vicious for about an eighth of an inch at each extremity, and especially at the inner, that it cannot be easily induced to resume its actual situation. When this is the case, the cartilage is to be divided, exactly at the place where it is bent, in its length, and in a direction at a right angle with the perpendicular incision†. The portion thus slit is only connected with the common integuments of the eyelid; and although this incision does not exceed one-eighth of an inch, at both extremities, and in general is only necessary at the inner, it enables the surgeon more readily to remove the altered curvature of the part. Mr. Crampton recommends that the two inner points of the perpendicular incisions should be now united

\* This would seem quite in favour of Mr. Crampton's opinion, that the levator palpebræ acted on the ciliary edge of the cartilage, in consequence of the contracted state of the conjunctiva. But I have shown that the conjunctiva is often much more contracted, thickened, and diseased, without any such result taking place; and I attribute it to the elasticity of the cartilage, causing it, on any motion, to resume its former curvature.

† See Plate I.



by the subsection of *Ætius* and *Paulus Ægineta*, that is, by a division of the conjunctiva, which he supposes to be in a contracted state; but I have always found this division to be useless, and even injurious. It is useless, because it has no influence on the part, for a simple division of that kind unites or fills up in a very short time; and it is injurious, because, if made across the cartilage, it is apt to form a ridge or cicatrix which irritates the eye, and of which, among others, I have seen one particular and incurable instance. The operation being thus far accomplished, a fold of skin is to be cut away from that part of the eyelid included between the incisions; three or four ligatures are then to be introduced, and the divided parts, from which the fold has been removed, are to be neatly brought together by the ligatures, each of which ought to be twisted, and then fastened to the forehead by several short slips of sticking plaister, the ends being turned over the plaisters near the hair, and retained in that situation, to prevent their slipping. In raising the fold of skin, care should be taken to do it regularly with the fingers; it is also essential to the success of this part of the operation that it be done as close as possible to the margin of the eyelid. It may then be grasped by the forceps of *Beer*\*, which have transverse pieces, slightly curved for the purpose at their extremities, and close with a spring. The piece thus included, which need not be large, may be cut away at one or more strokes of a large pair of curved or straight scissors. The ligatures should be inserted first at each angle; and when the vicious curvature is considerable, I not only pass it through the skin, but take care that *the internal* one shall include, at its lower part, the *outer edge* of the margin of the eyelid, which, from its firmness, retains that ligature much longer than those which are passed through the skin only, and

\* To the forceps used by *Beer* and *Langenbeck*, *Messrs. Everill* and *Mason* have adapted the spring used by *Gibson* for his artificial pupil forceps, which causes them to secure the raised fold without pressure by the operator.



tends to prevent the possibility of a relapse. The ligatures thus placed are to be equally drawn up on the forehead, until the eyelid is *completely everted*, when they are to be fastened as directed. In order to prevent any attempt at union but by granulation, or a filling up of the incision, the edges are to be slightly touched with the *sulphas cupri*; the eye and eyelids are now to be carefully cleansed; a piece of lint, spread with the *unguentum cetacei*, is to be placed upon them; a small compress is to be put under the edge of the eye-bone and orbit; a retaining bandage covers the whole, and completes the different steps of the operation. When the disease is not considered of an inveterate nature, the ligatures may be introduced through the fold of skin, without cutting any portion away. They give little additional pain, and are infinitely more effectual than any other suspensorium with which I am acquainted, but they ought to be assisted by strips of adhesive plaister placed between them\*. The operation, accomplished with all the care I have described, will still fail, if equal attention be not daily paid to the subsequent dressing, on which, indeed, more depends than on the operation itself; so much, indeed, that I am disposed to consider inattention to it the most certain cause of failure. In more than one hundred operations that I have performed, I have never known inflammation or other bad consequences ensue. The patient is to be kept perfectly quiet until the next morning, when the bandage and lint are to be removed, the eye carefully fomented and cleansed with warm water, and the dressings replaced. On the second day, great attention must be paid, that the ligatures keep the lid sufficiently raised;

\* In order to ascertain how much skin ought to be cut away, the operator should first raise a fold with his fingers, and desire the patient to open the eye. If the fold be correctly made, the eyelid will be raised very readily to its proper distance; if the fold be too small, the eye will not be sufficiently exposed. In raising the fold of skin, more should be taken from the centre than from the extremities, so that, when it is removed, the wound may be of an oval shape.



and if any union has taken place by adhesion at the angles of the incisions, it must be broken through with the probe. On the third day, the plaisters, attaching the ligatures to the forehead, will in general require to be exchanged. The ligatures themselves must be supported by straps of plaister placed vertically between them; the edges of the incisions should again be touched with the *sulphas cupri*, or separated by the probe. The great art of the cure now consists in causing the incisions to be filled up by granulations only, so that the eyelid may be lengthened as much as possible, which can only be effected by a continuance of the means indicated. In a few days more, and especially by the continued elevation of the lid, the ligatures cut their way out, during which period the eyelid is gradually lowered, and by the time the incisions have filled up, it will have resumed its natural situation, and the cure will be completed. There will, in general, be an indentation in the ciliary margin of the tarsus, where the incisions were made, but this is sometimes scarcely or not at all perceptible, and never detrimental. If the patient should have kept the lids closed at the commencement of the operation by the action of the orbicularis, the first incision may not have been made as close as might be desired to the angle of the lids; and in this case a hair or two at that part may not afterwards obtain quite its, or their original direction, and cause some inconvenience; but this does not often happen, as these hairs are usually carried clear of the eye.

The operation on the under eyelid is analogous to that on the upper, but is less severe, as the parts are more simple. It consists, in inveterate cases, of a perpendicular incision made with the scissors at the outer angle, and carried downwards to such extent as will perfectly relieve the inversion. This incision, by dividing the fibres of the orbicularis at that part as well as the conjunctiva, renders the muscular fibres powerless; and when it is properly made, the patient is incapable of moving the lid. One ligature is now to be inserted at the margin of the lid, and the threads fastened below the



jaw by sticking plaister, so as to keep the eyelid everted. The edges of the incision are to be touched with the sulphas cupri or the argentum nitratum to prevent union, and care must be taken daily that the part fills up by granulation. If any union should have taken place from the ligature slipping, it must be broken down by the probe. In the very worst cases, the inner angle is to be divided and treated in the same manner, the integrity of the punctum lachrymale and lateral canal being observed. In more recent and less severe cases, the simple division of the outer angle will be sufficient without any ligature, care being taken to prevent a too rapid union. I rarely recommend the use of the acids on the lower lid, as the operation is so very slight, that the most timid need not fear it. Mr. Saunders notices an inversion of the lower lid, arising, as he supposes, from a thickened state of the conjunctiva where it is reflected from the eyelid to the ball of the eye, and forming a roller at that part, over which, by the strong contraction of the orbicularis, the eyelid is turned and lodged between the projecting conjunctiva and the eye. If this be neglected, he says, it thickens and indurates to a very great degree; and he recommends its removal, and the subsequent application of a compress to carry the orbital edge of the tarsus inwards. I object to this operation as likely to give rise to a subsequent inversion, as well as to cure it, and have either not met with the case as described by Mr. Saunders, or have found the more simple operation I have described equally successful.

The subsequent treatment of the eye is much less than might be supposed; the principal cause of irritation being removed, *viz.* the inverted hairs, the inflammation gradually subsides, the conjunctiva assumes from day to day a more natural appearance, the opacities of the cornea diminish, and such alterations only, as are found to be permanent after the cure of chronic inflammation from other causes, remain as indelible marks of previous disease. Mild stimulants, such as the solutio opii Battlei; the liquor plumbi subacetatis; the vinum



opii, made without spices; the tinctura ferri muriatis, diluted with two parts of distilled water; the solutio argenti nitratis, of from two to four grains, to an ounce of distilled water, are the best applications after the incisions are healed. Where the conjunctiva is thickened, or granulated, or fungous, the latter solution dropped into the eye twice a day is very useful; and in more inveterate cases, a saturated solution of the sulphas cupri in distilled water applied with a camel's hair brush, and well washed off with plain water, is often of essential service. In every case, some mild ointment should be applied to the edges of the lids at night, and any secretion, which may have arisen and become hard, should be removed by the aid of warm water in the morning. Indeed, the lids, whilst any vitiated secretion remains, should be carefully examined *every* morning, and great attention paid that any hair, which has changed its direction from having been clogged by the discharge, be replaced in its situation, or pulled out, if it appears to resume its place with difficulty. The best ointments are, the ung. cetacei, the ung. zinci oxydi, the ointment of Janin, the ung. hydr. albi gr. 2 ad 3j, the ung. hydr. nitr. et oxydi rubri, six times reduced with the ung. cetacei, assisted during the day by the occasional use of any of the mild astringent lotions.

By the means, then, which have been thus fully described, I have reason to believe that a disease, which has been an opprobrium to surgery since the time of Hippocrates, may be always cured, under whatever name or description it may be included; and the six following cases will, I trust, be sufficient to remove any doubts, which may remain even in the minds of the most incredulous, whilst they will also justify the prolixity of detail which has preceded them.

#### CASE I.

Robert Baldwin, of the 1st battalion 79th regiment, was admitted into the York Hospital on the 2d of December 1816, with entropium of the upper lids of both eyes. He stated, that in September 1801 he was affected by inflamma-



tion whilst in Egypt, which continued until he went to Minorca in the succeeding year, when the hairs turned inwards, and have continued to do so ever since. The eyelids are nearly closed. He is incapable of opening the right, but has more power over the left; when the lid of the right eye is raised for him, he can discern objects, and can see to do his duty as a drummer with the left, although with great distress. The conjunctivæ are inflamed and thickened, but not granulated; the corneæ are nebulous; the secretions increased in quantity and vitiated in quality, so as to glue the eyelids together during the night. The operation recommended by Mr. Crampton was performed on the right eye, and great attention was paid to supporting the lid. On the 17th January there is the following remark by my assistant: "The operation has succeeded in a very great degree: previously to its performance he had not the least power of raising the upper eyelid, consequently had no vision of the eye. The cilia were also turned in on the eyeball, they are now nearly natural, and he has so far the power of elevating the upper eyelid, as to be able to see objects distinctly: he says, the eye is much easier." On the 28th the lid at the external angle had turned again so much inwards, that another incision was made at that part; and in order to prevent its closing, a small piece of lint was introduced between its edges; but this being found ineffectual, a fold of skin of the eyelid was cut off on the 6th of February, and the lid raised by attaching three ligatures uniting the incised edges of the wound to the forehead. These ligatures slipping, a smaller portion of the skin of the eyelid was removed on the 15th February, which proved effectual. The same operation was performed on the left eye on the 18th, and on the 2d March I find the following remark: "The eyes are perfectly easy; the eyelashes turned out, and no deformity. 9th. Confined in the black hole for a misdemeanor; and on the 13th discharged cured, but recommended to the Chelsea Board for a pension."

This case is remarkable for the length of time it had existed, the complete formation of the disease, the misery the



patient had endured, and the relief he obtained. It is equally valuable as proving the fact, that granulated lids are not a necessary consequence of ophthalmia acquired in Egypt.

## CASE II.

John Towers, formerly a corporal in the Life Guards, suffered an attack of purulent inflammation in both eyes in September 1815, which, after causing the loss of sight from ulcerations of the corneæ, gave rise to inversion of the lower lid of the left eye, for which in 1816 an operation was performed by the gentleman under whose care he had been, and which consisted in the removal of a fold of skin, and the insertion of ligatures to draw the edge of the tarsus outwards. In 1817 he was taken into a public institution by the same gentleman; but, having refused to submit to further treatment, was discharged. In 1818 he put himself under the care of a non-professional person, but without advantage. In 1819 he tried another oculist of eminence, who relieved him from time to time by extracting the hairs of the upper lids, which had turned in for some time; and in June 1820 he applied to me at the Royal Westminster Infirmary for Diseases of the Eye. The edges of the eyelids as well as the eyelashes were completely inverted; the hairs were uncommonly long, thick, and strong, and apparently in three or four rows; the discharge of matter was considerable, and kept the hairs constantly matted together; the irritation was very great; the corneæ were staphylomatous and opaque; the conjunctiva was thickened and granulated, not only where it lines the lid, but partially where it covers the eyeball: the poor man was altogether in a most deplorable state. The operation I have recommended was done on the left eye, with as little delay as possible; and, on the right eye, in the September following. In both cases they have proved eminently successful; the vitiated curvature of the tarsi has been completely removed; the cilia have reassumed their natural direction, and are a good instance of the luxuriance of eyelashes, which, when inverted, give rise to the opinion of a double or treble row, which was



supposed to be the case by every one who saw him. The opacities of the corneæ now prevent his seeing; but he lives in a comparative state of comfort and happiness, without any deformity, and with scarcely any appearance of an operation having been performed, even to an experienced eye. There is, however, occasionally an irregular hair, which turns inwards and requires to be eradicated.

### CASE III.

Susan White, aged 52, living at No. 5, Hudd's Court, Hanway Street, Oxford Street, had been blind twenty-three years of the right eye, when she applied at the Royal Westminster Infirmary for Diseases of the Eye, in April 1818. I found on examination that the principal complaint was an inversion of the eyelashes, which were turned directly on the eyeball; the tarsal cartilage was curved completely inwards; the aperture formed by the opening of the lids was so much contracted as not to allow of their being forcibly separated to half their usual extent; the conjunctiva was red and thickened, the cornea muddy and opaque, the discharge viscid, the irritation considerable. The operation was done immediately, and the relief was almost instantaneous; no inconvenience nor bad symptom followed, and the result was so complete and so perfectly successful, that the good lady considers a miracle to have been performed upon her as creditable to me as useful to herself, and is therefore a privileged person to send all the poor she meets with to the Infirmary, and when she attends in person to claim as early attention to them as she pleases.

### CASE IV.

A child, ten months old, was brought in the arms of its mother to the Infirmary, with an inversion of the hairs of the upper lid of the left eye, which she said she had observed from its birth. The eyelashes were long; and as the cartilage was little altered in its curvature, they did not turn so directly inwards and upwards, as inwards and downwards. They were always matted together by the discharge from the eye, and the conjunctiva was inflamed and villous. The ope-



ration was performed in the usual manner, with the exception of the removal of the fold of skin of the lid, for which I substituted three ligatures to keep the lid properly raised. The cure was complete, without deformity, small marks only remaining where the ligatures had been introduced.

#### CASE V.

A poor woman, 75 years of age, applied to me at the Infirmary in 1819, on account of entropium of both eyes. The operation was performed in the usual way, little or no inconvenience ensued even at her advanced age, and the cure was complete.

#### CASE VI.

An elderly woman applied at the Infirmary, in 1821, with an inversion of the lower lid of both eyes of some years standing, for which she had unsuccessfully undergone four different operations on the right eye, the cicatrixes of which were very obvious. She was effectually cured in a fortnight, by the method described.

The same result has followed in so many other cases, in which the operation has been performed since the first edition was printed, that it is considered nugatory to give any additional instances of its success, and the only precaution which the practice of others seems to render it necessary to add, is, that the perpendicular incisions be not carried to too great an extent but be confined nearly to the width of the extremity of the cartilage in order to prevent a puckering of the lid, which will sometimes take place, if these incisions be unnecessarily prolonged. I have never had occasion to exceed one third of an inch, and I do not believe that a further division of the part can have a beneficial effect.

---

#### ON THE EVERSION OF THE EYELIDS.

THIS disease consists in a turning outwards, or an eversion, of the upper or under lid; but is rarely met with as affect-



ing the superior palpebræ, whilst it is altogether less frequent than the opposite state of disease, or the inversion of the eyelid. It is called *Ectropeon*, *Ectropium*, from *εκ*, out; and *τρεπω*, to turn. *Eversio palpebrarum*, by the Latins.

The appearance of the part, as well as the accompanying symptoms, depend entirely on the nature and causes of the disease, differing from each other in a remarkable manner, according to the difference of cause, which also influences, indeed imperatively regulates, the method of cure. In consequence, however, of inattention to this important fact, operations and remedies have frequently been recommended, which are in no way applicable to one kind, although they may be essentially serviceable in another. In order, then, to elucidate this subject, I have thought it advisable to consider *ectropium* as of four different species, or produced in four different ways :—

1. As depending on chronic inflammation, accompanied by contraction of the skin and of the integuments of the lid; but without any marked cicatrix.

2. As depending on acute inflammation, or immediately following it, with relaxation or swelling of the conjunctiva.

3. As depending on the contraction occasioned by a cicatrix, on the healing of a wound, on, or in, the immediate vicinity of the eyelid.

4. On paralysis.

This disease, in whatsoever way it may be induced, is never productive of so much distress to the patient as the inversion of the lid. It is in general a complaint of inconvenience, and of annoyance from its unsightliness, rather than of constant pain; and as the eye is seldom much implicated by it, unless it be of long standing, or of great severity, the sufferer, if a poor man, is capable of following his occupation for months and even years, before the extension of the disease to the eyeball causes a sufficient obstacle to prevent it. At first there is merely a dropping (*stillicidium*) of the tears, and an increased and vitiated discharge from the irritated glands of the eyelids; this is accompanied by excoriation and redness



of the skin of the cheek, and is followed by a slight defect in vision, resulting from the thickened secretions which pass over the cornea, as well as from the greater exposure of the conjunctiva covering it. The conjunctiva of the eyeball is not always inflamed, neither is that lining the eyelid necessarily thickened, unless in certain states, to be hereafter described: whilst in others, the eyeball may not only be inflamed, but, in a subsequent stage, the cornea may be rendered opaque, and the conjunctiva, covering it thickened, dried, and withered, so as totally to alter the natural appearance of the eye. The conjunctiva, forming the fold between the eyeball and the lower lid, may be so swelled and thickened as even to form an almost horny substance between them; whilst, in other cases the whole of the conjunctiva palpebræ may protrude, so as to hide the ball of the eye, and present a most hideous object to the spectator; a good representation of which has been given by Dr. Vetch in the fourth figure of his second plate.

This disease was well known to the ancients: Hippocrates\* has alluded to one cause of it, *viz.* a fungous state of the lids, when he directs the thickened part to be removed, as quickly as possible, with a knife, and the cut surface to be burned with a moderately hot iron, taking care to avoid injuring the hairs. Celsus†, considering it as a consequence of the removal of too much skin in the operation for the cure of entropium, says, "that when too much of the eyelid is wanting (alluding to the upper), there is no remedy for it; but if a small part only, then it may be cured by making an arched incision, with the ends upwards, a little below the eyebrow, but not so deep as to injure the cartilage:" the cure is then to be completed by granulation.

Ætius‡ directs from Antyllus, that the fungous flesh be removed from the inner part of the lid, and the wound afterwards healed by astringents; but if the case is a more

\* Hippocrates, De Visu, page 353.

† Celsus, lib. vii, cap. 7.

‡ Ætius, Tetrab. 2, sermo iii, cap. 61, 62.



inveterate one, that the following operation be practised :  
 “ Two incisions are to be made on the inside of the everted lid, of the shape of the Greek letter  $\Delta$ , the apex of the angle being towards the cheek ; the portion of the eyelid thus cut through is now to be removed with the subjacent part, the lower lid not being cartilaginous (the skin being left entire). The edges of the wound, thus made, are now to be brought together by a suture placed near the margin of the lid, by which the incurvated and everted lid is restored to its place. But if a cicatrix be formed externally, from any cause whatsoever, this is to be taken hold of with a hook ; and a needle armed with a double thread being passed through it, the whole is to be cut away. The edges of the wound are to be kept asunder by dressing it to the bottom with lint, supported by compress and bandage ; and attention is to be paid to promote this object, by the best mild surgical means, as something is gained in the turning of the lid inwards from the increase of flesh in the external wound.”

This, it will be observed, is a great improvement on the method of Celsus ; and although *Ætius* and *Antyllus* are both wrong, in supposing the lower eyelid to have no cartilage, we cannot well understand what is meant by the operation, unless we suppose that they cut out a portion of it, and contracted the lid by the insertion of the suture. He afterwards says, “ If the eversion has been caused by a growth of flesh at the greater angle of the eye, it is to be removed, by which the eyelid will be restored to its proper situation.” He adds, “ It is necessary for us to know, that an eversion of the upper eyelid is incurable\*.”

*Albucasis*†, in the twelfth century, did not improve

\* It is somewhat remarkable, that, in the “*Précis historique de la Doctrine des Auteurs sur l'Opération qu'ils ont proposé pour remédier au Renversement des Paupieres*,” attached to *M. Bordenave's Mémoire sur le Renversement des Paupieres*, no mention is made either of *Ætius* or of this operation.

† *Albucasis*, *Chirurg.* part ii, cap. xiv.



on the incision Celsus recommended to be made externally, in cases of eversion from a wound, further than to direct that its shape should depend on the size and situation of the cicatrix.

Roland, in the thirteenth century, in order to prevent the union or filling up of the wound thus made, recommended a piece of lead, of a proper form and size, to be placed in it and retained for eleven days in that situation, by means of four threads passing from each of its edges into the neighbouring skin: a method, the recollection of which, as far as concerns the lead, was retained and revived centuries afterwards, by Platner\*, Thevenin†, and others, whilst the method of keeping it in its situation was forgotten.

Heister‡ only adds to the semilunar incision of Celsus, by directing three to be made instead of one; the inutility of which had been demonstrated by Maitre Jan§, in 1707: this induced Dionis|| to recommend two incisions, one, the thickness of a crown, above the other; and Juncker¶, finding two insufficient, added a third.

Marcus Aurelius Severinus\*\*, a Roman surgeon, celebrated in his day for having placed a ligature on the femoral artery, appears to have been the first who revived the idea of removing a portion of the swelled and diseased conjunctiva from the inside of the lid, and by which he says he restored the eyelid of a Capuchin friar nearly to its natural state, after it had been pronounced incurable by the surgeons of Naples.

Bordenave††, in cases of eversion depending on a

\* Platner, *Institutiones chirurg.* s. 581.

† Thevenin, *Traité des Opérations de Chirurgie*, chapitre 49.

‡ Heister, *General System of Surgery*, 1763.

§ Maitre Jan, *Maladies de l'Œil*, chapitre 20 et 21.

|| Dionis, *Course de Chirurgie*, sixieme Demonstration, page 453, 2d edit. 1716.

¶ Juncker, *Conspect. Chirurg. Tabulæ* 87.

\*\* Severinus de *Medic. Efficac.* part ii, cap. xxxiii, de Ectropio.

†† Bordenave, *Mém. de l'Acad. Royale de Chir.* tome xiii, page 156. 12mo.



thickened state of the conjunctiva of the lower lid, recommends with St. Yves\* the application of the lapis infernalis, so as to produce a slight eschar, which should destroy by degrees the swelling; or the repeated scarification of the part, which he seems to prefer to the caustic; and, lastly, the removal of a portion of the conjunctiva, in the whole length of the lid. This operation, which he particularly recommends in the more simple cases, he expressly declares to be insufficient when the complaint has arisen from the contraction of a cicatrix from a wound of the external parts; and his Memoir is indeed written to prove the necessity which exists for the removal both of the cicatrix and of the internal fold or swelling of the conjunctiva, in order to effect a permanent cure.

Bordenave's Memoir appears to have regulated the practice in this branch of surgery nearly to the present day, although cases have not been wanting to prove, that even these means have been found insufficient for the cure of every species of the complaint.

The first kind of disease, or that which is dependent on chronic inflammation, usually takes place after the long continuance of that form of it, which has obtained the name of lippitudo, and prevails more or less in almost every case of it of long standing, both in the child and the adult. In this complaint, which begins as an inflammation of the meibomian glands, extending to the conjunctiva palpebræ and the edges of the eyelids, we find, after a time, that the disease assumes a chronic form; the itching and pain diminish; the redness of the conjunctiva subsides; it becomes smoother, of a yellower colour, and the vessels are more distinctly marked; small ulcerations have formed at the roots of the hairs; the edge of the lid becomes thicker and of a more shining reddish colour than natural, and is also excoriated in various parts; the eyelashes have mostly fallen out; the secretion from the meibomian glands is considerably augmented in quantity and altered in quality, it exudes and passes over the edge of the eyelid with tears, which the

\* St. Yves, *Traité des Maladies des Yeux*, chap. x, 1774.



irritation of the eye, from any exciting cause, produces in greater quantity than can be carried off by the puncta lachrymalia. In poor persons, this matter dries and forms crusts at the roots of the hairs, glues the eyes together during the night, and is a constant source of irritation to the skin of the eyelid and cheek. These parts become in turn excoriated, are frequently studded with small spots of ulceration, and the skin loses in consequence its natural pliability, becoming hardened, irritable, and contracted. If the eye be examined when in this state, the remaining cilia of the lower lid will be found to turn downwards, and the edge of the eyelid within the hairs, and where the ducts of the meibomian glands open, will be so much turned outwards as to show the reddish yellow conjunctiva lining the palpebra, and giving the peculiar appearance to the eye, which characterizes this complaint. If the eye be irritated by a high wind or exposure to cold, the tears stand upon the edge of the lid, or fall over, constituting what is often called a blar eye. This partial, or rather commencing eversion of the eyelid is only so far a necessary consequence of the disease as it depends on the excoriation, contraction, and hardening of the skin, the result of the passage of the vitiated secretions over it, and which, by drying on it, increase the irritation. That this is the cause of the eversion is demonstrated by the simple experiment of pressing on the skin so as to draw it downwards, or increase the contraction, when the eyelid becomes immediately everted. That this artificial assistance is merely adding what occurs when the disease is in a more advanced stage, is proved by the fact of the eversion being more complete when the contraction is greater; and after it has proceeded so far as to turn the cartilage outwards, the firmness and elasticity of which opposes at first a powerful resistance, the complete eversion is promptly effected; for the external contraction is now only opposed by the ligaments uniting the extremities of the tarsal cartilages to the angles of the eyelid, which have been gradually yielding, and are no longer capable of offering any effectual



counterpoise to the increasing power acquired by the contracting skin. That this view of the subject is correct, I am in the habit of proving almost every week at the Infirmary, by contrasting the different stages to the gentlemen attending; when that, which may not be so apparent on the inspection of a single case, is clearly demonstrated on the examination of several. The altered appearance of the skin is also strongly confirmative of the opinion. In the first state of the first species, it is only rough, hardened, and slightly contracted. In the second, it is more contracted and apparently deficient in quantity; the lid can, however, be restored to its natural position by pressure made with the finger at the external angle. In the last stage, however, or that of complete eversion, the deficiency of skin, from its contraction, is so evident as not to be overlooked, and the eyelid cannot be restored to its situation by the finger in many instances, whilst it is accomplished with difficulty in all.

The edge of the lower lid is not straight when in its natural situation, but has a gentle curvature corresponding to the eyeball, which becomes more apparent, and is perhaps slightly increased, when completely everted, from being drawn downwards in the centre; and from the inferior ligament and the conjunctiva offering less resistance at that part than at any other: whilst at the angles the alteration is infinitely greater, so much so, that at the outer angle, the eversion does not gradually commence, but is suddenly effected, as if the ligament at that part was twisted rather than stretched. It is usual to consider this disease as dependent on an elongation of the tarsus: which, if it mean the tarsal cartilage, or that part of the lid which receives its shape or form from it, and on the outer edge of which the hairs are situated, is incorrect; the structure of the cartilage not admitting of such extension, and the only part which can be elongated is that portion of the eyelid, at the two extremities of the cartilage, which unite it to the upper lid, and form the inner and outer angles. This union, which is a ligamentous one, is so very short at



the outer angle, as to admit of little stretching; and we find accordingly, that when complete eversion takes place, it is effected by a twisting at this part, rather than by an elongation. The cartilage, however, in consequence of the unnatural direction it has been forced to take, assumes a different or vicious curvature, which is more or less observable according to the length of time the disease has existed. It is this alteration of curvature which causes the lid to stand out from the eye, and appear to be elongated, when the eversion is suddenly overcome by operation or otherwise, and has therefore led to what I conceive to be, in the two first species of this disease, an error; *viz.* cutting out a portion of the lid, and forcibly altering, by ligature, the curvature of the part, instead of leaving this process to the efforts of nature, assisted in a gentle manner by art. That these are sufficient, in the more simple states of disease, is proved by the fact, that a too long continuance of the means employed will ultimately give rise to a disease of an exactly opposite nature, a case of which I shall hereafter relate.


Scarpa\* says, "With regard to the causes, therefore, there are two distinct species of this disease; the one arising from a preternatural tumefaction of the palpebra, which not only separates its edge from the eyeball, but also presses upon it in such a degree as ultimately to evert it; the other, produced by a shortening of the skin covering the eyelid, or that of the neighbouring parts, by which the ciliary edge is, in the first instance, separated from the ball of the eye, and afterwards gradually turned outwards together with the whole of the eyelid." This latter species would seem to be that I have been alluding to; but after describing the first species, he goes on and says, "The second species of eversion, or that occasioned by a shortening of the skin which covers the eyelid or surrounding parts, is not unfrequently a consequence of contractions produced by the confluent small-pox in the integuments of the face, near the eyelids, or in those of

\* Scarpa's Treatise, by Briggs, page 113.



the eyelids themselves; of deep burns, accidentally inflicted on them; of the extirpation of cancerous warts or encysted tumours of the eyelids or circumjacent parts, where a sufficient quantity of skin has not been saved; of the malignant carbuncle; and, lastly, of lacerations of those parts, attended with considerable want of substance. Each of these causes is sufficient to produce such a contraction and shortening of the integuments of the eyelids, as to draw them towards either of the arches of the orbit, and consequently to separate them from the eyeball, and cause an eversion of their edges. This effect no sooner takes place than it is succeeded by another, no less inconvenient, the tumefaction of the internal membrane of the eyelid, which also greatly contributes to complete the eversion. For the internal membrane of the eyelid, though slightly everted, being incessantly exposed to the contact of the air, and continually irritated by extraneous substances, in a short time swells, and is elevated in the form of a fungus; a part of which, by degrees, covers a portion of the eyeball, the other presses the eyelid outwards, and produces so considerable an eversion of it, that its edge is not unfrequently brought in contact with the margin of the orbit. This second species of the disease is attended with the same unpleasant effects as the first; to which it may be added, that when either form of the disease has been of long standing, the fungous tumefaction of the internal membrane of the eyelids becomes indurated, coriaceous, and almost callous.

“Although the internal membrane of the eyelid, in both these species of eversion, appears equally tumefied, yet the surgeon may easily determine to which of the two species the disease belongs. For, in the first form of the disease, as I have stated, the skin of the eyelid, or surrounding parts, is not disfigured with scars, and the everted eyelid, on being pressed upon with the point of the finger, would rise again without difficulty, so as to cover the eye completely, if this carnous substance were not interposed; while, in the second species of eversion, besides the evident scars and contractions





which are seen upon the skin of the eyelid or neighbouring parts, if an attempt be made to restore the eyelid to its situation, it either does not yield so as to cover the eyeball entirely, or it can only be reduced to a certain extent; as from the edge of the eyelid having formed an adhesion to the arch of the orbit, in consequence of a very considerable destruction of the integuments, it does not admit of being removed in any degree from its unnatural position.

“ From comparing, therefore, those two species of eversion, it must be evident that a perfect cure of this disease cannot be effected equally in both forms of it; and that the latter species, in some instances, is absolutely incurable. For as the treatment of the first species of eversion, which depends only on a morbid tumefaction of the internal membrane of the palpebræ, merely consists in removing that which is superfluous, the art of surgery possesses many efficacious means, perfectly adequate to accomplish this object. But in the second species of the disease, in which the principal cause consists in the loss of a portion of the skin of the eyelid or surrounding parts, which no artifice hitherto known can restore, a complete cure of the disease cannot be obtained. The surgeon must be therefore content to remedy, as far as possible, the evils attendant on it, and that in a more or less satisfactory manner, according to the greater or less destruction of the integuments; and to abandon as incurable those cases in which the edge of the eyelid is found to be united to the arch of the orbit.”

This quotation proves that Scarpa was not aware of, or did not think it necessary to notice, that species which I have just described; but my object in referring to his work is not directed to this point, but to that part of his statement in which he says, “ this effect (the eversion) no sooner takes place, than it is succeeded by another no less inconvenient, the tumefaction of the internal membrane of the eyelid, which also greatly contributes to complete the eversion,” &c. &c. That this is not a constant occurrence, I have no hesitation in affirming,



and that it is, on the contrary, a rare one in the species I have referred to; a fact, which, while it shows the propriety of the division I have made, is also of importance, as it influences materially the mode of cure; and the first four cases to be related are incontrovertible proofs establishing the correctness of my opinion. In denying, then, the fungous state of the conjunctiva, I by no means intend to imply that it retains its natural characters without alteration. I have, on the contrary, noticed its primary changes; and I have now to state, that as the eversion takes place, the exposed and everted conjunctiva becomes thickened, of a more general yellowish red colour, but not granulated, and is constantly bedewed with the tears and vitiated secretions of the adjacent parts. The thickening is not such, however, as to enable an operator to remove it with a knife or scissors, or to render such proceeding necessary, for it subsides with the removal of the complaint. According to the views I have given of this species of disease, the indications of cure are two; 1st, to relieve the contraction of the skin externally; 2d, to restore and retain the lid in its proper situation, until the unnatural curvature of the cartilage has been overcome, and the chronic inflammation removed; when the cure will be completed. The first indication is in some measure fulfilled by washing the external parts with warm water, so as to leave the skin as clean as possible. It is then to be carefully dried and repeatedly anointed with the unguentum zinci oxydi, for three or four days, so as to form a covering, which will protect it from the matters which usually pass over it. It is necessary here to bring to our recollection, that the skin is merely contracted from irritation; and is disposed, from the inherent properties of our nature, to resume its natural appearance on the subsidence of the cause of irritation. It is in a different state from that forming the cicatrix of an ulcer; which, although it be called skin, is in reality only a smooth membrane, in some respects resembling it, but possessing neither its furrows, nor, of course, its great exten-



sibility, whilst it is equally destitute of the elasticity depending on continuity of structure. The skin, thus situated and relieved from irritation becomes softer and more pliable, ceases to contract, and, if it does not even relax, is at least in a favourable state to yield to a mild extension. This is accomplished, and with it the second indication, by the application of the sulphuric acid of the shops, in the following manner: The lid having been previously cleansed, so as to prevent its slipping, the conjunctiva is to be gently wiped dry, and everted as much as possible, so as to show the part where it begins to be reflected over the eyeball. The upper eyelid ought to be a little raised by the finger of an assistant, and the patient should be desired to look upwards. The blunt end of a common silver probe is then to be dipped into some sulphuric acid, and rubbed with its side flat upon the conjunctiva so that every part may be touched by the acid. The round point of the probe should be carried as far as where the reflection to the ball begins, but that part of the conjunctiva which covers it should be preserved inviolate. The punctum lachrymale, caruncle, and semilunar fold, are also to be avoided; but the external angle, as well as every other part, must be carefully rubbed. The effect of the acid will be observed by the conjunctiva turning white where it has been touched by it; and in order to prevent the acid from affecting the eyeball, a stream of water should now be directed over the eyelid by an elastic gum syringe. If the acid should not appear to have turned the conjunctiva sufficiently white, it may be repeated with the same precautions; and if the patient washes the eye afterwards in cold water, no inconvenience will result, the pain is comparatively trifling, and very few persons complain of it. The application of the acid should be repeated every fourth day; and when applied in the manner directed, it does not cause a slough, but a general contraction of the part, which is, however, only perceptible after two or three applications, by its effect in inverting the lid, which gradually begins to take place.



After six or eight applications the cure will be more than half accomplished, and in most cases of this species of eversion, the thickening of the conjunctiva will have subsided; if the operator should have become bolder in the use of the acid, slight ulcerations may be produced, but these are favourable to the completion of the cure. The ung. zinci oxydi is to be constantly applied to the skin, and the ung. hydr. nitrati, diminished in strength by the admixture of the ung. cetacei, in the proportion of four or six parts to one, to the edge of the lids and roots of the hairs every night, so as to produce a moderate sensation of smarting.

The immediate effect of the acid is not confined to, neither does it cease in four days, but remains for a much longer period; so that if the use of it be continued until the eyelid be entirely restored to its proper situation, the continuance of its action in producing contraction will cause an inversion of the eyelid, of which I give an instance in Case III, and whence the precaution now to be observed, of a longer interval between the applications of the acid, after the lid has two thirds recovered from the state of eversion, in order to prevent such an accident taking place. The occurrence of it is, however, a valuable fact, as it proves the efficacy of the practice, and the power of a remedy, which if it be capable, when too frequently or too violently applied, of causing an inversion of the eyelid, must, if correctly employed, be sufficient to restore it to its natural state.

After the eversion is cured, the complaint which first gave rise to it may in part remain, and must in that case be treated by a continuance of the ointment to the edge of the lid, or of the ung. hydr. nitrico-oxydi, or such gentle stimulants as usually remove the disease, which is frequently accomplished almost as soon as the restoration of the lid.

The second species, or that which is dependent on acute inflammation, or immediately following it with relaxation or swelling of the conjunctiva, may arise during the continuance of the acute stage. Dr. Vetch\* has given so able a descrip-

\* Vetch on Diseases of the Eye, 1820, page 228, et seq.



tion of one kind of it, occurring from a violent attack of purulent ophthalmia, that I have great satisfaction in transcribing it; he says, "When the external œdema of the eyelids begins to subside, the granulated state of the palpebra loses that counterpoise, which the swelling afforded to it, and the action of the orbicularis muscles now forces it outwards. If the protrusion is not immediately returned, the upper part of the eyelid and the retroverted cartilage have the effects of a ligature to the parts protruded; and as the swelling increases, the stricture becomes still stronger by the natural but ineffectual efforts of the muscles to bring the tarsus into its proper position. The tumour of the part is therefore occasioned by strangulation, and the hypersarcosis belongs to the surface only. When the surface is thus kept in contact with the air, the granulations become larger, harder, and more sulcated. In this state the surface may be pared off for weeks, or months, without any other effect than a temporary relief, by unloading the vessels, while the pain of the operation occasions great straining to the eyelids, and consequent increase of the strangulation, which forms the basis of the disease; while the operation, itself is liable to produce a diseased state of the surface, much more difficult to heal than the natural state of the granulations. Although it is of the utmost consequence to remove the disease as speedily as possible, in order to save the cornea as far as we can from the effects of the preceding ophthalmia, yet I conceive it is better for the patient to leave nature to herself, than interrupt her progress by the treatment I have mentioned. The proper method of curing the disease is simple and the effect immediate.

"I take the opportunity, which this exposed state of the surface of the palpebræ presents, of beginning the cure of the granulations and the general villosity, by a very light and careful application of argenti nitrati. The everted portion is then to be returned, and secured in its place with a compress and straps of plaister or bandage. Every time the



eye is cleaned, the same things are to be repeated ; in the course of a few days the tendency to protrude will disappear, and at the end of a fortnight the patient will have so far recovered the use of the muscles of the part, as to be able by their means alone to raise or open the eyelids at pleasure ; whereas, if attention is not given to relieve the strangulation, which takes place every time the membrane protrudes, it becomes a disease of many months duration, and the eye may be destroyed in consequence, although it might have escaped the violence of the acute stage of the preceding ophthalmia." In figure the 2d, plate 3d, of his work he gives the representation of a very bad case, which by this treatment was cured in a fortnight.

This result of acute purulent inflammation does not always take place where even ectropium is a consequence. I have seen three different cases of what was considered gonorrhoeal ophthalmia, in which, during the swelling and protrusion of the ball of the eye, the lower lid became everted, apparently from the pressure of the eye first turning the upper edge of the lid outwards whilst the fibres of the orbicularis muscle, acting perhaps in an equally powerful manner below, pressed the under part inwards ; the natural elasticity of the narrow cartilage doing the rest, the eversion became complete in twenty-four hours. In these cases no thickening or granulation of the lid took place on the subsidence of the acute inflammation, and the eyelids were soon restored to their natural situation, by the means adopted for the removal of the chronic inflammation, *viz.* scarifications and mild astringents.

In young children an eversion of one or both lids is not an infrequent occurrence during the purulent inflammation of these parts, more especially on any attempts being made to examine the eyes whilst the child is crying, which generally gives rise to it in consequence of the pressure of the orbicularis muscle on the lids in the act of separating them. This eversion, which is more common to the upper lid, can always be relieved



at the moment, by taking hold of the eyelid at each angle with the finger and thumb, and turning it inwards, whilst, or after it has been drawn downwards; but if it has remained some time in that state, inflammation takes place from the partial strangulation on the part, and it can only be reduced on the subsidence of the inflammation, which scarifications and mild astringents materially assist.

In these cases, as well as in the first species, and frequently in the second, the appearance of the eyelid is very different from the remainder of the second, and all of the third: the tarsal cartilage is completely turned outwards; whilst in the others it is not so much turned out, as bent, and the edge drawn downwards.

The observations of Demours\* apply to the disease as described by Scarpa, which I have already quoted page 49. In that state of it which Dr. Vetch has noticed, and in its subsequent stages, he describes his method of treatment in the following words: "St. Yves always succeeded by applying a solution of the nitrate of silver, which method I have adopted when the conjunctiva is not much thickened; but when it is more so, I remove it in the following manner: the eyelid being completely everted and steadily retained in that situation, I first cut along the inferior edge of the part to be removed, and finish the incision from above; the blades of a pair of flat curved scissors are then to be introduced into each incision, and the part enclosed between them cut off. In its worst stage," he adds, "I make use in general of a mixed treatment, by removing in the first instance, as much of the thickening of the part as I can, and then applying the nitrate of silver; after which, at the end of eight or ten days, I return to the knife, and again apply the caustic. On other occasions, I remove at once as much of this flesh as possible, by Guillemeau's method †, only substi-

\* Demours, *Traité des Maladies des Yeux*, page 98.

† Guillemeau, *Traité des Maladies de l'Œil*, sect. iv, chapitre ix, says, "If the superfluous flesh is of long standing and has become



tuting a hook, and afterwards resorting every second day to the use of the caustic ;" which method, he says, he thinks more simple, and preferable to that of Sir W. Adams to be hereafter mentioned.

The German ophthalmologists seem to have confined themselves to nearly the same mode of treatment. Beer recommends in the first instance mild astringents; and if they should be found ineffectual, and the conjunctiva has become thickened, and the derangement of long standing, scarifications with the knife, and the subsequent use of the lapis infernalis, rubbed on the part with proper precautions. At page 137, noticing more particularly this second kind of eversion accompanied by a thick and hardened swelling of the conjunctiva, he directs it to be laid hold of with a hook and cut off with a knife, in the same manner as Demours, taking care to avoid the cartilage. To complete the cure he recommends the use of the tinct. opii simp. (Thebaic tincture); and, if that should not be sufficient, recourse is to be had to the lapis infernalis.

Weller\*, who professes his work to be a compendious account of whatsoever is known in Germany on the diseases of the eye, delivers his sentiments to the same effect: "In order to heal the ectropium sarcomatosum, when the disease is as yet recent, streak the still sensible fungus daily with tinct. opii simplex, to which is afterwards added æther sulphuricus; then proceed to the use of weak salves, with red precipitate; exchange them afterwards for the lapis infernalis, and lastly for butter of antimony, in using which, the parts must be previously scarified, if they be entirely insensible. If the fungous conjunctiva be hard, horny, insensible, and of long standing, the hard swelling is to be drawn out as much as possible from the tarsus, and cut away, without how-

hard, it must be cut away by introducing a thread under it by means of a needle, and then, after raising the part, removing it at one or more strokes of the knife or scissors, taking care not to injure the eyelid."

\* Weller, by Monteath, page 122, vol. i.



ever wounding the latter. The eyelid immediately unites in its natural position, inflames gently, and heals in a few days."

Sir W. Adams\*, having found that the methods then known for the cure of ectropium were insufficient to effect it in his practice, was induced to try a new method, by cutting out a portion of the eyelid, in the shape of the letter V, in similar cases to those we are now considering, as well as in those of the third species; and of which he relates four successful cases, all of the second species; the first dated November 1808.

"On first adopting the operation, about to be described, I employed a very small curved bistoury, the point of which I carried along the inside of the eyelid and its outer angle, downwards and outwards, as far as the point of reflection of the conjunctiva would admit. I then pushed it through the whole substance of the everted eyelid and its integuments, and cut upwards through the tarsus, making an incision nearly half an inch in length. With a curved pair of scissors I next snipped off a piece of the edge of the tarsus about the third of an inch in width; and afterwards I removed, with the same instrument, the whole of the diseased conjunctiva, to prevent it from mechanically irritating the eyeball. After the profuse hæmorrhage had ceased, I passed a needle and ligature through the whole substance of the two divided portions, and brought the raw surfaces as accurately into contact as possible. Finding, however, that too much integument had been left at the lower part of the incision, which formed a small knob after the wound had cicatrized, I substituted, in subsequent operations, in preference to the scalpel, a pair of straight scissors, with which I cut out an angular piece of the lid, resembling the letter V. This prevented the formation of the little protuberance, but the incision did not heal at its upper part by the first intention. It was, however, essential that this process should, if possible, be accomplished, since, independent of the delay that was thus produced in effecting the

\* Adams's Practical Observations on Ectropium, &c. 1814.



cure, the space between the two disunited edges of the lid became filled up by granulations, which in some measure conduced to the reproduction of the disease. As the frequent motion of the eyelids, however, seemed to oppose the greatest obstacle to the adhesive process, by preventing the divided surfaces being accurately retained in contact, I left about a quarter of an inch of the lid adjoining its external angle, and, after shortening it as much as was necessary, brought the two edges into juxtaposition, in which situation it was retained by means of a suture, which completely answered my expectations. I have not specified the length of that portion of the lid necessary to be removed, since this depends on the degree of elongation and consequent eversion, and must therefore, in a great measure, be left to the judgment of the operator. It may not, however, be here improper to caution the surgeon against too much shortening of the parts; as, in this case, they could not be brought into contact without stretching them to such a degree as to produce ulcerations, thereby detaching the ligature before an union is effected. On the other hand, if too small a portion of the diseased parts be removed, so that the least eversion in the centre of the lid be suffered to remain, chronic inflammation will be likely to ensue, and the vessels, becoming turgid, will, by their weight and distention, again produce a morbid elongation of the tarsus, that must finally terminate in a recurrence of the disease. By an attention to these circumstances, none of the patients on whom I have operated for this malady have ever been subjected to a relapse. It has often surprised me, that this simple operation, which has proved uniformly successful with me, should not have occurred to Professor Scarpa; or, so far as I have been able to discover, to any other of those ingenious practitioners who have professedly written on the subject."

This operation is founded on the idea of the eyelid being elongated beyond the power of recovery, either by the assisted or unassisted efforts of nature, and therefore requiring to be



shortened to restore it to its proper length. This supposition, in regard to the two first species, is certainly erroneous; for four fifths of the eyelid cannot be elongated, and the remaining fifth part is only so partially stretched, in these cases, as not to form an irremediable obstacle to the retention of the part in its natural position. That it does not do so, I have given a positive proof, in showing that the opposite state of disease may be readily induced; and Beer, whose authority must be decisive, at page 137 of his first volume, when on this subject, gives an express caution not to apply the lapis infernalis too frequently, or an inversion of the lid will be the consequence. According, then, to the principles which regulate the practice of surgery in all other cases of disease, this operation ought not to be performed in either of the two first species, as the same effects may be produced by more simple means; with little pain, without one day's confinement, and certainly with less deformity (even if it be merely temporary), inasmuch as there will not be an external incision. In this opinion I am not singular; for Mr. Samuel Cooper has quoted, in his Dictionary of Surgery, the following observations of Mons. Roux on this subject: "What Sir W. Adams says, with a view of enhancing the value of his own method, about the frequent recurrence of ectropium, when the conjunctiva is simply cut out, is a gratuitous assertion, contradicted by experience. I have already, in a great number of cases, undertaken the cure of ectropium in the common way: the operation always succeeded as much as the degree or other circumstances of the disease allowed; and I have not yet observed an instance of a relapse."

It will be admitted by every one, that, as the second species of eversion essentially consists in a fungous or granulated state of the conjunctiva, with, for the most part, a swelling, either sensible or insensible, at the angle, where the membrane passes from the eyelid to the ball of the eye, and which is even said to be, with a contracted state of the external skin, in some cases the cause of the eversion; the indi-



cations of cure must be, first, to remove the diseased growth or state of the conjunctiva; secondly, to restore the lid to its natural situation.

In order to accomplish the first indication, recourse must be had to the knife, the scissors, or such remedies as, acting partly as caustics, partly as stimulants, gradually restore the conjunctiva to its natural state. When this membrane is either fungous or granulated, I may, I believe, say, without entering into particulars, that it is now very generally admitted that the knife and scissors are the most objectionable means of cure, and are nearly, if not altogether, abandoned; which at once establishes the propriety of the practice of the ancients, by stimulants and caustics; and, among our contemporaries, of Beer and Scarpa in particular. I am, however, disposed to prefer the use of sulphuric acid, every four days, and a gentle application of the sulphate of copper, daily, or every second day, to the means recommended by either of them; and I have no hesitation in affirming, that the cure effected by these means, in addition to those minor remedies I have already noticed for the cure of the first species, will be complete and permanent. This point being settled, the only remaining question for consideration is, whether the cure can be accomplished in less time by the operation of cutting out a portion of the eyelid, than by the treatment more usually recommended. To judge only from the statements and cases which have been published, the answer would be decidedly in the affirmative, as they would lead to the belief that every thing was done by the scissors, both in relation to the cutting out of the angular portion, and the removal of the fungous or granulated state of the conjunctiva. But we have the authority of Sir W. Adams for believing, that the method of removing a granulated surface of the eyelid by the scissors, as recommended by Mr. Saunders, is incompetent to the purpose, more especially in the lower lid; and he introduced a knife in order to supersede the scissors, which knife has properly yielded to the use of es-



charotics. On these points, and on the incompetence of the scissors, I perfectly agree; and therefore draw what I conceive to be a correct inference, that, if the scissors are not competent for the purpose intended at one time, they are equally unfit, in the same kind of case and under similar circumstances, at another. When the fold of conjunctiva is the principal cause of eversion, and has become hard or horny it ought to be removed by the scissors, and a compress and bandage should be applied over the eye; but as the scissors never cut away the whole of a granulated surface, it must be subsequently restored to its natural state by the operations of nature, either alone or assisted by stimulants or caustics, in the same manner as in the preceding states of disease; which fact being understood, places the two methods on a par. If there be, however, no fungous conjunctiva lining the cartilage, and merely a hardened swelling or fold at its angle of union with the eyeball, then the operation will be more advantageous in regard to time.

If, in judging this operation by the general principle of surgery, I have been obliged to reject it in the two first species of this complaint, I by no means wish to condemn it in all; and I have now to show, in the third species, in what way it may be highly useful.

This third species, or that which is caused by a contraction occasioned by a cicatrix on the healing of a wound in the immediate vicinity of the eyelid, has always been considered as a very intractable complaint, and only curable when the eversion was not complete, and the cicatrix not extensive, nor firmly attached to the bone beneath.

In this species, the appearances and actual situation of parts differ materially from the other two, and are influenced by different circumstances. It is well known, that the first step towards the cure of an ulcer or wound is the drawing in of the surrounding parts, in a manner commensurate with the growth of the granulations, which are to fill up the vacuity that has been made by the progress of the



ulcer; and by the time cicatrization has taken place, the cicatrix bears no proportion to the size of the original wound. But this process of contraction does not stop here; it continues after the ulcer has healed, especially in loose parts; and, in burns of the neck, it is capable of drawing down and fastening the chin to the breast. This diminution in the quantity of new-formed parts continues until there is little left to mark where the solution of continuity existed; but this little does not resemble the original structure: it is firmer, harder, more stringy, and somewhat resembling the nature of ligament. The cure has been effected at the expense of the surrounding parts, which if loose, as in the neck or in the eyelid, may be drawn in to a very considerable extent. In consequence of a knowledge of this fact, our attention, in cases of burns in the neck, should be invariably directed to the position of the head, which must be kept backwards until long after the wound has healed, in order to counteract, as much and as mechanically as possible, this tendency to contraction, and to force nature to form more new skin, or a larger cicatrix, which she is always very unwilling to do, and is often indeed incapable of doing. The same thing takes place on the eyelid; and if an ulcer be allowed to heal quickly, eversion, in a greater or less degree, is an invariable consequence. In the first and second species, the operation of this cause is slight and on the edge of the eyelid, or cartilage; in the third, it is greater and on the whole external surface of the cartilage, which is turned downwards, whilst the eyeball is more exposed; the whole of the conjunctiva of the under lid is distinctly seen, and forms something resembling an inclined plane from its angle of reflection over the eyeball, outwards and downwards. The deformity is more striking. In the second and third species, the conjunctiva always forms more or less of a sulcus, or hollow, with the eyeball at the angle of reflection: in the third, this part is fully exposed, the conjunctiva is drawn downwards; the tears always flow



over the cheek; the curvature of the tarsus is altered; the ligaments are more stretched, and the elongation of the eyelid becomes more apparent; the conjunctiva is sometimes fungous, or granulated, and occasionally but little affected, or altered, but in many instances it assumes a lippitudinous appearance; the cicatrix is hard, and, for the most part, firmly attached to the cheek bone.

It was for the cure of this species of the complaint that Bordenave, whose memoir I have already noticed, recommended the double operation of the removal of the cicatrix and of the fold of the conjunctiva; and, although he did not succeed in effecting a perfect cure, still he so much relieved his patients as to render his method deserving of the greatest attention: it will, however, be observed, it was only returning in some measure to the practice of the ancients. That it was not sufficient is attested by the subsequent observations of Scarpa and Beer, who declare this species, in severe cases, to be incurable; and that the German ophthalmologists have not hitherto done much towards relieving it will be proved by the following summary of a case from Professor Dzondi, of Hallé, who was also so good as to inform me when in England, that no better method had been adopted in Germany.

“ William König, a tanner, applied for assistance in consequence of an eversion of the lower lid, the result of an erysipelatous inflammation, followed by abscess, which took place below the eye; the cicatrix was attached to the cheek-bone, and drew the eyelid downwards, so that the conjunctiva lining the lid formed an inclined plane from the eyeball downwards and outwards; the tears continually ran over the cheek. Professor Dzondi, having first attempted to loosen the attachment of the cicatrix to the cheek-bone, by gently stretching it every day, in which he met with little success, proceeded to the division of these attachments by a curved incision (following the course of the orbit) down to the bone to which they adhered; and on cutting through and separating all the points of attachment, the eyelid could be



replaced in its natural situation, the edges of the wound being half an inch asunder. The lid being returned to its place, the wound was dressed from the bottom, with an ointment composed of equal parts of the ung. cantharidis and the ung. resinæ flavæ, for the space of two months, when the granulations, being perfectly healthy and above the level of the surrounding skin, were slightly touched with the potassa fusa, and the sore was then allowed to skin over, which it did in nine days, leaving a cicatrix somewhat larger than half the surface of the wound. This, and the subsequent contraction of the cicatrix, again drew the lid down, so that the eversion was only half cured, the tears still ran over occasionally, and the lids would not meet. The cicatrix having been unavailingly stretched every day for ten weeks, the operation was repeated, and the wound again kept open for two months, which nearly but not completely effected a cure; still rendering a third operation necessary. This he was persuaded to submit to, and at the end of several months the eversion was perfectly removed."

This case corroborates, in the strongest possible manner, the observations I have made on the appearances and nature of the disease, as well as on the manner in which cicatrization is accomplished, whilst it also shows that the usual processes of nature may be sometimes interfered with successfully by art, although only with the greatest labour. I believe this to be one of the most severe cases in which the disease has ever been completely removed by the excision of the cicatrix and the filling up of the wound by the formation of new matter.

To effect a cure of this species of eversion, the indications are two in number: first, to remove the cicatrix of the old wound, with the strong membranous threads which attach it to the bone beneath; and then, secondly, to give such permanent support to the eyelid as will enable it to resist the contractile power of the granulations during the cicatrization of the wound below.



The first indication is to be fulfilled by a single or double incision, from a little below the external to the internal angle of the eye, following the curve of the eyelid and of the orbit, as far and as deep as may be found sufficient for the removal of the cicatrix and of the cellular attachments to the bone beneath, which will be found exceedingly strong and firm, and sometimes requiring a dissection completely upon, or even within the edge of the orbit. These adhesions are to be taken away if possible, for if only cut through they will reunite with greater firmness. The lid may then be raised to its proper situation, and every thread of cellular membrane, which seems to draw it downwards in the slightest degree, must be divided.

The second indication was formerly attempted to be accomplished by supporting the eyelid by sticking plaisters placed across it, which answer very well until the cicatrization begins; but then they cease to offer a sufficient counteracting power, from the yielding nature of the parts to which they are attached; and the eyelid and the sticking plaisters are drawn down together. What is wanting, then, is evidently an opposing force, or counteraction, in a different direction, which shall be competent to prevent the contraction of the granulations in the wound, and the drawing in of the surrounding skin, which I have already shown, in the instance of burns in the neck, may be done by great care and attention in keeping the head backwards.

This opposing force was sought for by Bordenave, in the removal of a fold of the conjunctiva from the inside of the lid; but has seldom or never, in cases of severity, been found sufficient; and when both operations were repeated and assisted in every way, as in the case of Professor Dzondi, they were only effectual with a submission to pain and inconvenience, which can scarcely be expected from any person.

The removal of an angular portion of the lid, as proposed by Sir William Adams, and more especially in addition to the removal of the horizontal fold of conjunctiva, gives the



opposing power required, in a degree quite sufficient to restrain the cicatrizing process from drawing the surrounding skin downwards, and a cure is therefore speedily and effectually accomplished. The removal of a V-like piece from the eyelid, and the approximation of the edges of the wound by sutures, shorten the part considerably and bind it over the eyeball: they alter the vicious curvature of the cartilage, and bring it nearly to a straight line, the object formerly desired to be obtained by the application of plaisters. This straightening of the eyelid, which is effected in cartilaginous, ligamentous, and comparatively unyielding parts of the eyelid, is also permanent for a period equal to the contractile power *inherent* in the skin and granulations for a *certain* time after the cicatrix is completed; and therefore, the powers being equal, or rather against the cicatrix, the healing of that part is rapidly effected by the granulations filling up the wound, and the skinning process covering it in, by the formation of a new membrane, and not at the expense of the surrounding old skin.

That the effect is produced by shortening the eyelid beyond, and not by merely restoring it to its natural state, is proved by the fact, that the eyelid, in its natural state, never offers a resistance equal to withstand the cicatrizing process below; of this, the disease itself is proof, as it could not otherwise have occurred; and therefore restoring it to its natural state only will have no influence in promoting a cure, further than is gained by the cicatrization in a different direction. That this is the true principle on which the operation can be supported will, I believe, be conceded by all those who are capable of estimating the value of opposing powers; and in performing the operation, it must be borne in mind by the surgeon, who will therefore cut out just as much as will bring the eyelid into this state, and yet not cause so great a separation of the edges of the wound, that the sutures cannot bring it together, without such a degree of extension as will prevent the union of



the parts by the adhesive process. This portion to be removed may be taken out as far inwards as the middle of the tarsal cartilage when necessary, of which Case the Sixth is an example; but it is in general more advantageously done nearer to the external angle, and the quantity to be removed will not, I believe, or as far as I know, ever exceed one quarter, and seldom more than an eighth, or from that to three-sixteenths of an inch. The depth of the incision must be in proportion to the width of the part removed at the ciliary margin of the lid, in every case however extending beyond the cartilage.

The operation for the third species consists, first, in the removal of the adhesions which the cicatrix has formed to the cheek-bone, with the whole or such part of the cicatrix as can be with propriety taken away; secondly, in the cutting out of an angular portion of the eyelid, near the external canthus; thirdly, in the removal of the diseased fold of the conjunctiva (if there be any), by a horizontal stroke of the scissors, assisted by the forceps; fourthly, in the application of two sutures, to bring the divided edges of the eyelid together; one close to the margin of the lid, the other near the point of the angle below; these are to be drawn just so tight as to bring the parts in close apposition, when they are to be cut off close to the knots, and supported by slips of sticking plaister; fifthly, in the dressing of the wound made by the removal of the adhesions to the bottom with very fine lint, and applying a bandage over the whole.

The subsequent dressings require attention. The object intended by the sutures will almost always be effected by the third day, when the edges of the angular wound will be seen to adhere, and the sutures are really of no further service, whilst a retention of them in the part would lead to ulceration. They are therefore to be cut and the threads removed, which will allow the openings made for their reception to close. Strips of adhesive plaister should be



applied in their place, and a small compress, to give additional support to the part. If the edges of the lid should not have perfectly united, a small notch will remain for a short time, which will be gradually filled up. If the lower part or apex of the angular piece should not have been consolidated by adhesive inflammation, it will fill up by granulation, which may be assisted after a time, or any fungus repressed, by gentle touches of the *argentum nitratum*.

The wound made by the removal of the cicatrix, or of the points of attachment to the cheek-bone, is to be kept open after the first dressing, by an ointment composed of equal parts of the *ung. lyttæ* and of the *ung. resinæ flavæ*, and it is not to be allowed to close until the granulations have reached the level of the surrounding parts; during the process of cicatrization, the eyelid must be carefully supported by strips of sticking plaister.

Slight inflammations, accompanied by pain, may, although in general they do not, take place: in such cases the compress and bandage, placed over the eye to complete the dressing, ought to be kept wet with cold water, and a cathartic should always be administered on the morning subsequent to the operation. Poultices should be avoided, particularly in the third species, as they tend to promote supuration and prevent adhesion. One operation will not at all times succeed, the cure will not be complete, or perfect, although the deformity will have been in a great measure removed, in which case the division of the cicatrix everting the lid must be again had recourse to, and I have had to repeat this even a third time in a very severe case, but have never failed in effecting a cure.

The fourth species, or that which is dependent on paralysis, is of course only to be treated effectually by such general means as may remove the original disease; which, unless in young persons, is seldom effected. Under this species, and partly connected with it, is classed that affection



of the lower lid of old people, which is termed the ectropium senile, consisting of a gentle turning out of the edge of the eyelid, and a chronic state of inflammation of the membrane lining it. The lid is not closely applied to the eye, and the tears occasionally run over it. Operative surgery is scarcely applicable to this state, as it will not effect a perfect cure; relief may however be obtained from the use of gently stimulant ointments and collyria. If the complaint increase, two or three applications of the sulphuric acid will afford relief, and so will the incision of any portion of the conjunctiva that may be swelled and hardened, and is a source of irritation.

### CASE I.

#### *Of the First Species.*

A young man, 26 years of age, applied at the Infirmary, in 1820, for eversion of the lower lids of both eyes, the consequence of a lippitudinous affection of long standing, and repeated attacks of inflammation: the conjunctiva was only slightly thickened. The sulphuric acid was applied in the manner formerly directed, for the space of a month, and the eversion was completely cured. The lippitude was also greatly relieved, and nearly disappeared under the usual remedies. In a similar case, about the same time, a cure was nearly effected by the same means, when the patient considered himself sufficiently well to go to work, and ceased to attend; a circumstance which in many similar affections too frequently takes place at public institutions.

### CASE II.

#### *Of the Second Species.*

A poor man applied to me, in 1816, in consequence of chronic inflammation of the right eye, accompanied by a granulated state of the lids, and a partial eversion of the lower one. At that time we were trying the efficacy of the acids, at the York Hospital, in the cure of this fungous



state of the membrane, and I applied the nitrous acid in this case with complete effect, as far as relates to the eversion. The diseased appearances of the conjunctiva, and the chronic inflammation of the eye, were afterwards removed by gentle but repeated applications of the sulphate of copper, and a weak solution of the argenti nitratum.

### CASE III.

#### *Of the Second Species, followed by Inversion.*

A middle-aged woman came to the Infirmary, with eversion of the lower lids of both eyes, which were in a granulated or fungous state; I commenced with the right, and applied the sulphuric acid two and three times a week until the eversion was scarcely perceptible; but being desirous of effecting a perfect cure, it was applied with a little more severity, and the consequence was, that an inversion took place: I promised to cure this as soon as the reinstatement of the other lid should be effected; but when that began to take place, fearful, I presume, of its following the same course, she ceased to attend.

### CASE IV.

#### *Of the Third Species.*

A middle-aged woman applied to me, in 1818, with eversion of the lower lid, the consequence of a cicatrix a little below the edge of the orbit on the outside, and to which it was attached. The eyelid could not be restored to its place by pressure: the conjunctiva was not thickened. The operation was performed by dividing the cicatrix, and separating the adhesions, which were but slightly attached to the bone, and then removing about the eighth of an inch of the eyelid, near the external angle, by a double incision meeting in a point below, at the depth of about three-eighths of an inch. The edges of the cut thus made, were brought together by two sutures, and healed in three days,



when the sutures were withdrawn. The wound made by the removal of the adhesions to the bone healed in the space of a month, and the cure was completed.

### CASE V.

#### *Of the Third Species.*

Joseph Geoffry, Royal African Corps, was admitted, labouring under ectropium of the left inferior eyelid, occasioned by a sabre wound received ten years ago, which divided the orbital ridge of the superior maxillary and malar bones, and partially the nasal bones. The ciliary margin of the lid is held down by a firm cicatrix to the lower margin of the orbit, especially towards its inner angle; and he suffers a great deal of inconvenience from the dust and wind, as well as from the tears flowing over the lid: conjunctiva not thickened.

The operation for ectropium was performed on the 9th of April, by detaching the everted margin of the lid from its adhesions, cutting out a triangular portion of the tarsus near its centre, and then bringing the divided edges together by means of two sutures. Great difficulty was encountered in dividing the adhesions, from their very firm nature, and the depth at which they existed within the margin of the orbit, and also from their being situated very close to the lachrymal sac, which required the dissection to be performed with great care to avoid wounding it; this was however effected. The wound was then filled with lint, supported by adhesive straps, and the whole covered with simple dressing and a bandage.

April 12th, the wound of the tarsus united, and the transverse one, granulating freely, has had no pain since the operation. The sutures were removed, and the wound filled with lint and supported by straps.

16th. The wound filling rapidly with healthy granulations, and the lid now retains its natural position.

20th. The wound very nearly healed.



27th. Discharged ; the wound healed, and the eyelid perfectly retained in its natural situation.

John Smith, 22d Foot, admitted, labouring under complete eversion of the lower lid of the left eye, occasioned by an extensive wound he received fourteen years ago, by the wheel of a cart passing over the side of his head, and fracturing the frontal bone and the external margin of the orbit. The edge of the everted tarsus adheres to the malar bone by a firm cicatrix, and the muscles of the cheek exercise great power in drawing it downwards whenever the lower jaw moves. He has been in this state fourteen years, and suffers much inconvenience from it.

23d. The operation for ectropium performed by making a free horizontal incision beneath the whole ciliary margin of the lid, and thus detaching it from its firm adhesion to the malar bone ; after which a triangular piece was cut out of the centre of the tarsus, and the lips of the wound brought together by two sutures. The lid was then retained in its natural position by adhesive straps and a bandage.

25th. The dressings removed this morning, the granulations of the horizontal wound healthy ; has experienced no pain since the operation.

27th. The wound of the tarsus perfectly healed ; the sutures removed ; granulations spring up rather too abundantly from the horizontal incision beneath the orbit, and were therefore touched with the sulphate of copper.

March 6th. The wound nearly healed.

10th. Discharged ; the lid perfectly restored to its natural position.

For these two cases I am indebted to the records of Chatham Hospital, and they are highly creditable to Staff Surgeon Melin, whose attainments, in this and every other branch of his profession, cannot be too warmly commended.



In the case of a Medical Student, an engraving of whose eyelid is given, plate iii, the removal of the deformity was so effectual, that on his return to the country his friends did not know him.

The eversion of the upper eyelid, called *Lagophthalmos* by the Greeks, from *λαγως*, a hare, and *οφθαλμος*, an eye; the *oculus leporinus*, or hare's eye; is a much less common disease than the eversion of the lower lid, which is in itself by no means of frequent occurrence. It is sometimes observed in a slight degree as accompanying the eversion of the lower lid; but it usually takes place in consequence of the contraction which occurs on the formation of a cicatrix, or from an abscess within, or a disease of the edge of the orbit. I have seen it happen from the loss of the upper lid, consequent on destructive ulceration. It is said, by the older authors, to occur from a habit acquired by infants in their cradles, of looking continually upwards; but this I have never seen. A short eyelid is said to be sometimes congenital; and, lastly, an incapability of closing the eyelid may arise from partial paralysis, or *staphyloma*.

The effects accruing from the eversion of the upper lid are analogous to those of the lower, and lead in the same manner to the loss of sight. In the case alluded to above, in which the lids were lost by a destructive ulceration, the conjunctiva covering the eyeball had become so thick and semi-transparent as to resemble gold-beater's skin, through which the patient could just see sufficiently to guide himself about. It fell into wrinkles on every motion of the eye, and its continuity over the cornea was remarkably well shown. It was nearly insensible to all moderate stimuli.

The attempts made to effect a cure in this disease do not always succeed. When it takes place as a natural defect, it is of course incurable; and those authors, who mention its occurrence as a consequence of infants having been allowed



to look upwards in the cradle, only recommend that the eyelid should be bound down until the complaint be removed.

When the disease is dependent on a cicatrix or abscess, it is less susceptible of relief, in consequence of the greater looseness of the skin of the upper lid, which causes it to be completely drawn up to the eyebrow when cicatrization takes place. I have now under my care a gentleman, who has suffered for several years from an eating ulcer of the cheek, nose, and forehead, surrounding the eyelid; which it became necessary to destroy in order to prevent its further extension to the rest of the face, and render him incapable of following his business. This I have effected, and nearly removed the whole of the disease; but on the cicatrization of that part over the edge of the orbit and of the surface of the lid, a complete eversion took place; the edge of the lid adheres to the integuments covering the edge of the orbit, and, as the eye is lost, I have not made any attempts to remove it. This case shows the powerful influence of cicatrization, and should be a caution in regard to the use of caustics for the cure of inversion.

I have had two cases of this complaint under my care, accompanied by and depending upon disease of the bone at the edge of the orbit, originally caused by an abscess. In both I tried, by means of an incision, to detach the parts, and to keep them asunder a sufficient length of time to produce granulations, and a new but elongated cicatrix. In this I succeeded at first; but the disease of the bone, not having been cured at the same time, caused the eyelid to return nearly to its former state.

When the lagophthalmos is partial, and has accompanied eversion of the lower eyelid of the first or second species, it is to be cured by the same means and at the same time. When it has taken place in consequence of inflammation, followed by a fungous excrescence of the conjunctiva, either



from common causes or from the presence of a concealed foreign body, that part must be removed by a stroke of the scissors or the scalpel, aided by the forceps; and if it should be then found that the lid cannot be readily retained in its place, the V-like piece ought to be removed, one or more sutures inserted, and a proper compress and bandage applied.

Scarpa has recorded one of the best cases I am acquainted with of this nature, and I therefore transcribe it.

“A boy, 10 years of age, in the beginning of October 1790, having lain during the night in a sheet upon which ears of corn had been thrashed, awoke in the morning with the lids of his left eye swollen and painful. Notwithstanding the use of emollient topics, an abscess formed in the upper eyelid, which burst below the supercilium towards the temples, and left an opening which could not be healed by any methods of treatment which were employed. In process of time, the upper eyelid began to be turned outwards, and its internal membrane to swell and protrude, and to increase the eversion of it prodigiously.

“Towards the middle of June 1791, about eight months from the first appearance of any disease, the fungous excrescence, formed by the internal membrane of the eyelids, covered a considerable part of the upper hemisphere of the eyeball, and the eversion was so considerable, that the margin of the lid, especially towards the temples, was almost close to the eyebrow. The eyelid, however, readily yielded on being pressed upon with the point of the finger, and appeared as if it would have descended and covered the eye, had it not been for the intervention of this fungous substance, formed by its internal membrane: as the fungus was dry and indurated, I ordered that a bread and milk poultice should be applied upon it for twenty-four hours; I then removed the whole of it with the curved scissors at one stroke, carefully avoiding the superior lachrymal punctum.



“After the extirpation, it was discovered that there was a piece of wheaten straw, almost an inch long and half a line thick, contained in the fold of the fungus. The whole of the superfluous part of the internal membrane being now removed, the eyelid descended over the eye, so as to cover it conveniently. The operation was not followed by any unpleasant symptom, and ten days afterwards the child left the hospital, so far cured that no defect remained except a small elevation of the eyelid, near the external opening where the abscess had burst.

“As there can be no doubt that the piece of straw had prevented the ulcer of the eyelid from healing during eight months after the bursting of the abscess, it is singular how such an extraneous body could have been forced through the internal membrane of the eyelid, without the child having been awaked by it.”

The operation required for the cure of eversion of the upper eyelid, caused by the cicatrization of an ulcer, is so analogous to that of the lower lid, that I need not enter into further detail; and shall describe the manner of proceeding in the following curious case.

Henry Puchet, aged 21, when half a year old, was scalded by some boiling water on the forehead, which caused an ulceration of considerable extent, the cicatrix being now rather larger than a crown piece, and situated upon and above the outer part of the left eyebrow. On the cicatrization taking place, the skin of the eyelid was drawn upwards, and with it a part of the tarsal cartilage, which is completely bent in its vertical diameter, so that the inner half remains in its natural situation, whilst the outer half is completely everted, the conjunctiva being a little thickened, the eyeball of course very much exposed, and giving rise to considerable deformity. The cicatrix had no attachment to bone, but merely to the tendinous parts beneath, and was moveable with them. I performed the operation on the 31st December, by making



an incision along the lower edge of the cicatrix, and continuing the dissection until the lid was perfectly relieved from its attachments; the cartilage had, however, no disposition to resume its natural state, but remained bent as before this part of the operation was attempted. I therefore removed a V-like portion of it, within a quarter of an inch of the outer angle, and brought the parts together by suture; and in order still more to correct the vicious curvature of the cartilage, a ligature was introduced through the edge of the lid and fastened below the chin. This was removed, as well as the suture, on the fourth day, when the operation appeared to have succeeded. The wound made on the eyebrow and lid was dressed with the ung. lyttæ and ung. resinæ flavæ from the first, and granulations soon rose above the surrounding level. On the completion of the cicatrization the lid became again everted in a slight degree, rendering a second division of the cicatrix necessary, which effected the removal of the deformity.

Professor Walther\* has lately effected a cure of an eversion, nearly of a similar nature, but affecting both lids, by a different method of operating, which will be best understood by relating the case.

“An Officer received an oblique wound on the left temple, near the external angle of the eye. A portion of the integuments and of the orbicular muscle of the eye were lost. The wound healed in a short time, and left an ugly, rugged, and prominent cicatrix, corresponding to the outer edge of the orbicular muscle. The outer angle of the eye was drawn towards the temple, and was at least six lines from its natural situation. It had entirely lost its angular form, and was now rounded.

“In consequence of the displacement of the angle of the eye, the eyelids were thrown outwards. The conjunctiva was

\* Journal für Chirurgie und Augenheilkunde von Græfe und Walther, band ix, stück 1.



much inflamed. When the patient applied to me, there was not only considerable deformity, but he complained of a painful feeling from the stretching of the parts towards the temple. He could not perfectly close the eyelids. When he attempted to do so the parts closed from the middle to the internal angle; but from the middle to the external angle a separation still remained. The opinions of many surgeons had been taken, and it had been suggested to divide the cicatrix, probably with the view of restoring the parts to their natural situation during the healing of the wound. This proposal I rejected, as I could not anticipate any favourable result from its being carried into effect.

“ I recommended the patient to submit to an operation, by which the lids might be united together in such a manner as to form a new external angle in its natural situation. When the eyelids were wide open, I could, by pressure with my thumb and finger towards the temple, place them in contact, for the space of five or six lines from the outer angle, without diminishing the natural aperture of the eye, and while the parts were kept in this position all deformity was removed. The patient had a mirror placed before him, and was extremely anxious for such a restoration of the parts. Some apprehensions, however, were to be entertained on account of the eyelashes and the Meibomian glands. If the former were plucked out, their subsequent growth might very possibly prevent the union of the wound which must be made.

“ It was also a question to determine what would become of the secretion from the latter. If it were constantly poured out after the operation, a union of the parts would be prevented. I did not feel capable of satisfactorily resolving these doubts in my own mind. The operation, however, was determined on. The cilia were removed the day before the operation entirely from both lids, as far as it was intended to make the incision, by means of a pair of tweezers. The patient being conveniently seated, I drew forth the tarsus of the under eyelid, with a pair of forceps applied near the part



where the division was to begin, and with a narrow-bladed probe-pointed bistoury I removed the tarsus by a steady stroke of the instrument, carrying the incision about one line beyond the external angle. About one-third of the whole length of the tarsus was removed in this manner. The same operation was then performed upon the upper eyelid, the two incisions running towards the temple in an angular direction. The hemorrhage was trifling. Two ligatures were used, which were passed quite through the substance of the upper and under eyelids. Upon the interval between the ligatures a strip of adhesive plaister was applied. The edges of the wound joined each other accurately, and the motions of opening and shutting the eye did not disturb the parts which were divided. On the second day considerable inflammation arose. Both eyelids swelled very much on their external halves. The patient complained of a good deal of pain. These symptoms were relieved by appropriate treatment. On the fifth day suppuration took place where the ligatures had been introduced, and they were removed. From this time all unpleasant symptoms ceased, and the wound was perfectly united throughout its whole extent. The deformity was entirely removed. The external angle of the eye was now in its natural situation, and the divisions between the lids were equal on both sides. The motions of the lids were perfectly free. The cicatrix from the operation was not visible.

What was now become of the secretion from the Meibomian glands, the excretory ducts of which, or at least their openings, had been removed in the operation, and were now enveloped within the cicatrix?

The secretion must have ceased, as no appearance of it was to be discovered. Perhaps the structure of the glands might have been changed by the inflammatory action, and their secretions consequently suspended. At all events this case proves, that the commonly received doctrine of *Hordeolum* and *Chalazion* is incorrect. If these swellings arose from the stoppage of the mouths of the excretory ducts of the Meibo-



mian glands, in this patient, there should have been a row of them along the parts which had been divided. It is a still more difficult question to determine, why the cilia did not grow again, as their roots must have remained after the operation. If we consider how rapidly the cilia grow, like mushrooms, when they have been removed for Dystichiasis and Trichiasis, and how obstinately their growth continues in such cases, and how seldom they can be perfectly destroyed, the effect of the present operation must appear the more remarkable. I offer the following physiological speculation as an explanation.

The openings of the small canals in the skin, through which the hairs grow, were removed, and the canals themselves included within the cicatrix which united the eyelids after the operation. The roots of the hairs must have been remaining in the back part of the canals, which were thus included in the cicatrix. It would appear, therefore, to follow, that the influence of the atmospheric air upon the roots of the hairs is necessary for their growth, and that the latter must be in contact with the former. Plants, we know, will neither grow nor germinate without the influence of the air. Hairs, also, usually grow only upon the external surface of animal bodies, which is exposed to the atmosphere. The occasional appearance of hairs in certain enlargements, &c., cannot disturb the general physiological conclusion. The facts above narrated may perhaps suggest a new mode of radically extirpating the cilia in cases of Trichiasis and Dystichiasis. It would only be required to find some application, which would prevent the admission of the air into the small canals from whence the cilia shoot, or to arrive at the same effect by any other means, and the subsequent growth of the cilia would be prevented after they were once removed. I flatter myself that the operation I have described will be worthy of imitation.

From badly healed wounds, the external angle of the eye may be sometimes displaced; such an occurrence, however, is not unusual when ulceration has taken place in the adjoining



parts. In two cases of this kind I have, within a short time, had an opportunity of repeating the same operation."

The following case corroborates some of the preceding observations of Professor Walther.

Mary Harrup, 32 years old, applied lately at the Infirmary on account of a union which had taken place between the edges of the eyelids of the left eye, to the extent of one-third, at its outer angle, and which she stated to have been caused by a burn she received when four months old. There was scarcely a mark of a cicatrix, and it looked like a congenital malformation, the shape and edges of what ought to have been the rima palpebrarum, or opening of the lids, being very distinctly seen through the skin which united them. I divided the adhesion by the scissors, until the separation of the lids seemed perfect; no dressing was applied, save at the angle, which was also slightly touched with the sulphate of copper to prevent reunion. The cure is complete, and it now remains to be seen whether the cilia will grow, or not.

Dr. Monteath has, in his translation of Weller's *Manual of the Diseases of the Eye*, the following remark on the subject of partial paralysis, which is very creditable to his judgment and discrimination. He says, "I have frequently met with lagophthalmus, occasioned by a temporary palsy of one half the face, produced by exposure to a current of air. I have seen this disease continue from two weeks to twelve months, during all which time the eye could not be closed, on account of the paralysis of the orbicularis palpebrarum. I have accurately noted a number of these cases, and feel convinced that cold is the invariable cause, producing at first an inflammatory swelling and diminution of the caliber of the aquæductus Fallopii, causing consequent pressure on the trunk of the nerve. Pain radiates from the ear along all the branches of the nerve for some days; it then ceases, and perfect semifacial palsy follows. This disease is soonest overcome by antiphlogistic treatment for the first few days, then by applying a semilunar-shaped blister around the ear, and rubbing the paralyzed parts with stimulating liniments. The



only description of this affection I have met with is in Duncan's *Annals of Medicine* for 1800. The paper is entitled, *De Paralyti Musculorum Faciei Rheumatica*, by Nicolaus Friedreich. The affection might be mistaken, by a careless observer, for palsy dependent on the state of the sensorium, and I have even seen it treated as such by a medical man of the first eminence in his profession."

Mr. Shaw\* has made some observations connected with this subject, which deserve attention, as leading to a greater discrimination between partial paralysis of the face, depending on a local cause, and on an affection of the brain. To the former he attributes the greater number of these complaints, and more particularly those which are accompanied by inability to close the eyelids. Another great object of Mr. Shaw's remarks is to prove, that when the portio dura of the seventh pair of nerves is affected locally, no alteration is observable in the functions influenced by the fifth pair. In *lagophthalmus*, which depends in these cases on an affection of the portio dura of the seventh pair, the sensibility to external stimuli of the parts of the face suffering from paralysis remains entire, as dependent on the fifth pair. The actions of the muscles connected with respiration, laughing, and sneezing, are suspended, whilst those (the voluntary actions) which are influenced by the fifth pair continued unimpaired. The patient can pass a morsel of bread from the cheek of that side into the mouth by the action of the buccinator; he can hold a tobacco-pipe in the same corner, by the action of the orbicularis oris; by tickling the inside of the nose, the symptoms of sneezing become evident; but snuffing up hartshorn, on the same side, produces no effect, the sensation necessary to cause sneezing by inhalation being under the influence of the seventh.

\* Mr. Shaw "On Paralysis of the facial Nerves," in the *Journal of Science, Literature, and the Arts*, for April 1822; and "On partial Paralysis," in the 12th volume of the *Transactions of the Medical and Chirurgical Society*.



In lagophthalmus from a local cause, there will not be any other paralytic affection; the head will remain unimpaired: and it is useful to contrast with this statement the fact, that where the paralysis is dependent on derangement within the head, the eyelid is almost invariably closed, constituting a state of relaxation, or of Ptosis. The treatment must be then in a great measure local. Cupping on the temple of the same side, to the amount of twelve ounces, or from that to sixteen ounces, followed up by repeated blisters behind the ear, and cathartic remedies, will in general effect a cure. Stimulants to the part seem to be of use as the complaint is subsiding; and when the disease has existed for three or four months, it is seldom curable.

#### ON THE RELAXATION OF THE UPPER LID.

A FALLING down or relaxation of the upper eyelid, without any inversion of the cilia, or inflammation, occasionally takes place; but it is for the most part a symptomatic disease, is frequently accompanied by hemiplegia, or more partial paralysis, and is often a consequence of apoplexy. It is by some said to be congenital. Its occurrence is also attributed to the long-continued use of emollient applications, in persons of a phlegmatic temperament, to an atony of the levator palpebræ, or to a paralysis of it as one of the consequences of an injury to the optic nerve, or to the ophthalmic branch of the fifth pair of nerves. Scarpa conceives that it may arise temporarily from an irregular spasmodic action of the orbicularis palpebrarum.

It has been termed *Atoniatoblepharon*, from  $\alpha$  privative; *τονος*, tone; and *βλεφαρον*, palpebra: also *Ptosis*, from *πιπτω*, *cado*, to fall.

The effect of this complaint is the partial deprivation of sight, from the incapability of raising the lid; and, from the enumeration of the causes, it is obvious that very few cases can be relieved by a surgical operation. In all those, which depend on hemiplegia, or more partial paralysis, and which



constitute by much the greater number of persons affected by it, the treatment, it is evident, must depend on general means. It is the same when caused by an injury of any of the nerves of the eye or orbit, and is only to be relieved by a surgical operation when really the consequence of a relaxation of the skin and integuments of the lid from previous distention, and combined with atony of the levator palpebræ, or when it is congenital. The operation, which has been found useful, is that which has been so constantly recommended for trichiasis; viz. the removal of a fold of skin from the eyelid, whereby a diminution of the length of the integument takes place, counterbalancing the relaxation which had previously occurred. This cannot, however, act on the levator palpebræ, if that muscle be in a state of atony, unless by taking off some additional weight, or rather by facilitating the motion of the part; when, therefore, that muscle is really affected, the complaint can only be partially cured; whilst in simple cases of relaxation from over distention the operation will always prove successful; and on reference to the cases related by authors, they will be found to have been of this nature. When the operation is likely to be successful, the raising the fold of skin, which ought to be removed, will be sufficient to enable the patient to open his eye, so as to correspond with the other; and a greater or less quantity should be cut away, according as it is found to answer this purpose; and, if the patient be directed to look the operator steadily in the face whilst he is sitting immediately before him, the quantity to be removed will be easily ascertained. In trichiasis, the skin removed should always be immediately from over the tarsal cartilage, whilst in a case of pure relaxation it should be in that folding part of the integuments above the upper edge of the cartilage, or nearer to the eyebrow. Scarpa\* considers sutures unnecessary, and advises the edges of the wound to be brought into contact and retained by means of strips of adhesive plaister; but especially by applying a compress upon

\* Scarpa, on the Relaxation of the upper Lid, page 100.



the supercilium, and another upon the inferior edge of the orbit, and over these a uniting bandage. I am disposed, however, to insist on the use of sutures, and I have reason to believe they assist materially in effecting a more perfect cure. If the atony of the levator palpebræ should depend on mere debility from inaction, the suspension of the lid will be sufficient, with the attempts at motion of the patient, to effect a cure, which will also be assisted by slight stimulant applications; but if, on the contrary, there be a real paralysis of this muscle, I do not see how the operation can do more than raise the eyelid to a certain extent, so as to remove a part of the deformity, and the cure of the paralysis must be attempted according to the nature of the immediate cause. Indeed, in such a case, the operation should follow rather than precede the general treatment.

When the difficulty of raising the lid is caused by an œdematous swelling of it, or by a morbid thickening, the result of more acute inflammation, it will, in most instances, be gradually relieved by the efforts of nature, or these may be assisted by cold or gently stimulating applications, increasing the strength and varying the quality of the stimulus as the part becomes accustomed to it, or seems to remain stationary under its application. A dry clear air, and proper diet, will essentially promote recovery; and friction of the eyelid at night with a warmed flannel, and the shower-bath in the morning, will often be found useful. Cantwell, in the *Philosophical Transactions*, mentions a case of this kind recurring every night, with a discharge of white matter, which was cured in a few days, by the use of the cold bath to the neck and back part of the head. In these cases the state of the eye itself will always be a strong indication of the nature of the disease, inasmuch as it is generally sound in those which are curable; whilst it is for the most part the reverse, and showing some internal derangement, in those which are, on the contrary, incurable.

In order to arrive at correct indications of cure, it is ne-



cessary to consider a relaxation, or a falling of the lid, to be dependent on various causes, and to occur under very opposite states of disease. It may be congenital, as in Case the 1st. Dependent on atony of the lid generally, but principally of the integuments, as in Case the 2d. On paralysis, as in Cases 3 and 4.

### CASE I.

#### *Of Congenital Relaxation of the Lid.*

In the year 1820, a child of two years old was brought to the Infirmary, with the right eye nearly closed from the falling down of the lid, which its mother observed shortly after its birth. The cilia were not inverted. It appeared on examination, that by pinching up a fold of the skin, the lid could be raised nearly to a level with the other; and I thought it advisable to remove this portion, which could at most do no harm if it did no good. It succeeded, however, in removing nearly the whole of the deformity, although the child neither shut nor opened it with the same facility as it did the other.

### CASE II.

#### *Of Atony of the Lid.*

A soldier applied to me at the Infirmary, for a relaxation of the upper eyelid, the consequence of long-continued inflammation; which had, however, in part subsided, so as to leave only a slightly granulated state of the conjunctiva of the lid. As there was no appearance of other complaint, but the swelled and partly oedematous state of the integuments, I removed just such a portion of them as enabled the man to keep the eyelid sufficiently elevated when I held it in my fingers, which perfectly succeeded. Scarpa relates a very analogous case, but more marked and equally successful.

### CASE III.

#### *From Palsy.*

Stephen Woolger, aged 30, states, that in the month of January he suffered an attack of palsy, which caused a falling



down of the upper lid of the left eye, a drawing outwards of the corner of the mouth of the right side, weakness of the right arm, great drowsiness, faltering in his speech, and dimness of sight. For this he was bled and cupped without any apparent relief, but he afterwards recovered under the use of brisk purgatives. A month had scarcely elapsed when he was attacked a second time, and was restored to health by the same means. In the beginning of August he experienced a third attack, more severe than any of the preceding, and he applied to me on the 14th of that month. The left eyelid nearly covered the eye, the left corner of the mouth was drawn down, he spoke in a scarcely intelligible manner, and with great stuttering: he was obliged to be led to prevent his falling: vision very indistinct. I directed twenty ounces of blood to be taken from the arm, which relieved him greatly; he could shortly after move the eyelid a little, and the mouth partly resumed its natural direction. Eight grains of calomel and six of the compound extract of colocynth were given immediately, and half a drachm of jalap and one drachm of cream of tartar were ordered to be taken at night, and a blister to be applied to the nape of the neck. The purgatives having failed to produce an effect, they were repeated on the subsequent day, and fourteen ounces of blood were taken from the temple on the 16th by cupping. On the 20th, the drowsiness continuing, he was bled to fainting, twenty ounces being taken away; and the purgatives were repeated. On the 23d he could raise the lid, which had hitherto covered the eye, although vision was still very indistinct, and the speech but little amended. The purgatives were repeated, and another blister applied to the nape of the neck. They were repeated on the 26th, and on the 30th he was altogether better. The purgatives were continued every other day until the 10th of September, when he thought himself well, with the exception of a slight faltering in his speech. On the 15th of September he was able to go to work, his eyelid quite natural, and vision only impaired when any object was



brought close to the eye: there remained scarcely any stuttering, or impediment in his speech, and he walked well. I recommended him to have either a seton in his neck, or an issue in his arm, and to take some purgative medicine every two or three days; but he neglected to do either, and will in all probability suffer a relapse.

#### CASE IV.

##### *From Palsy.*

An elderly gentleman, who was under my care for a derangement of the urinary organs, and whose general state of health was failing, suffered, in the course of two days, a considerable loss of recollection, was apparently dull of comprehension, and became very deaf: he lost the power of raising the right eyelid, which nearly covered the eye, and altogether appeared incapable of supporting himself in the erect position. An attack of apoplexy or hemiplegia seemed to be hourly impending. I bled him instantly to the amount of twenty-four ounces, which afforded almost instantaneous relief. He was well purged, and cupped the subsequent evening on the nape of the neck. The eyelid quickly resumed its natural situation, and by a continuance of the means indicated, he was relieved from all apprehension of palsy.

In many instances the connection between the internal derangement of the head and the relaxation of the lid is not so marked, and these cases are of most frequent occurrence. The patient complains, that he cannot raise the eyelid, and consequently cannot see, but says he has nothing else the matter with him; and although a close investigation may satisfy the medical practitioner, that there is a tendency to congestion, still the patient is unaware of any other derangement than that which he considers local. These cases have invariably yielded to a very moderate abstraction of blood, purgatives, and blistering. The blisters should be applied in turns behind the ear and on the temple of the affected side; and I con-



sider them as by far the most important part of the treatment, superseding, in this particular class of cases, the administration of mercury (which, when continued to salivation, does no good, but generally harm), the insertion of setons, &c., of which the following case is a sufficient example.

A gentleman in the city suffered an attack of this nature, being also subject to Epilepsy. He was bled, purged, his mouth made sore by mercury, and a seton was placed in the neck, but without advantage. It was proposed again to affect his mouth by mercury, which caused him to apply to me. I directed a course of blistering behind the ear and on the temple, with warm purgatives, and in three weeks he was able to return to his business, and has since continued well.

Galvanism and electricity have been recommended I think in a too general way in this complaint: I have seldom seen them useful, and never alone effect a cure. The application of the moxa ought to be confined to such cases as evidently depend on partial paralysis of the nerves supplying the eyelid, in which I have seen it do a great deal of good. It is not however a remedy deserving of the extravagant praises it has received from Baron Larrey, whose method of using it I have followed in these and other complaints for the last ten years, but not with a similar success. It may be applied over the supra and infra-orbital nerves of the fifth pair, before the mastoid process, and in the course of the superior branches of the portio dura of the seventh pair; which will also exert some influence on the communicating branches of the third of the fifth pair.

In these cases, or species of disease, there is little or no pain in the part, neither is there any intolerance of light when the eyelid is raised by the finger; but in many, which are certainly symptomatic, and in others occurring from doubtful causes, the falling of the lid is accompanied by a very acute and darting pain in the forepart and side of the head, whilst the eye bears the admission of light with great difficulty.



Professor Schmidt\*, in a work published at Vienna in 1801, and reviewed by Professor Himly†, gives a good description of this complaint, as dependent on paralysis, and notices a particular spasmodic affection, which he calls blepharospasmus. "This disease," he says, "consists in an involuntary and continued contraction of the upper and lower eyelid; the patient being unable to raise the lid, even when aided by a moderate external power. The eyelids generally press upon the eyeball, which yields to the pressure, and appears to be pushed backwards into the orbit. The skin of the lid covering the orbicularis palpebrarum is laid in folds, and over the eyebrow it appears hardened, or as if almost knotted, from the contraction of the corrugator supercilii, and the hairs of the eyebrow stand on end, as in frowning. The skin covering the forehead and the muscles of the neck, and especially the former, appears to be in convulsive motion, the patient making involuntary efforts to draw the eyelid upwards by the occipito-frontalis muscle, which acts as an antagonist to the orbicularis palpebrarum. If the eyelids are forcibly drawn asunder, the eye appears dull, the pupil somewhat dilated, the iris sluggish in its motions, and vision is considerably impaired. Some days previously to the occurrence of the spasm, the patient generally complains of headach on the side affected, which extends to the ear, and gives rise to deafness."

The method of cure recommended is the same in both diseases, *viz.* the application of the potassa fusa, on the space between the mastoid process and the ascending branch and angle of the lower jaw. After the slough has separated, the ulcer is to be dressed with a stimulating ointment, and kept

\* J. A. Schmidt. Ueber eine neue, &c. und des anhaltenden Augenliedkrampfes. In dem Abhandlungen der K. Konigl. Med. Chir. Jos. Acad. zu Wien. Band. ii. s. 365, 1801.

† Himly und Schmidt, Ophthalmologische Bibliothek. Jena, 1804, b. ii. stuch 3.



discharging for three or four weeks after the cure has been effected, when it may be allowed to heal.

Schmidt relates three cases, which were cured by this method: the first, of blepharoplegia, which was cured in thirty days, many other means having previously been employed without success. The second, of the disease particularly described, which occurred for the sixteenth time in the same individual, and which ceased a few days after the caustic had been applied. The third case resembled the first.

The two following cases are instances of the symptomatic species of disease to which I have alluded, one being of a mild, the other of a very severe and obstinate nature. The difference between them, and indeed all others which have occurred to me, and the case drawn by Professor Schmidt, consists in the constant acute and darting pain in the forehead, particularly over the brows, and in the course of the supra-orbitary nerve, as well as in the superior branch of the portio dura, which he does not appear to lay much stress upon, or indeed to notice, further than as a headach preceding the falling of the lid. The peculiar knotted or hardened appearance of the skin over the corrugator supercilii muscle I have not observed, but the remaining symptoms and appearances correspond with my observations in cases otherwise apparently similar.

## CASE V.

### *From Amenorrhœa.*

A young woman, 19 years of age, applied to me in consequence of a deranged state of health, accompanied by a falling down of the upper lid, which was also slightly oedematous; her whole appearance was evidently chlorotic, the catamenia having been wanting for several months; the bowels were extremely irregular: she suffered from occasional pains in the head, and thought her sight defective. Purgatives were first had recourse to alone, and were afterwards continued, in combination with the tinct. ferri ammon. She



recovered her health in the course of three months, and with it the power of raising the eyelid; to which, and the parts adjacent, she latterly applied an embrocation composed of the liquor ammoniæ and the spiritus rosmarini, and she thought with advantage.

### CASE VI.

Mary Ann Cameron, aged 18, applied at the Infirmary, June 20 (1826), in consequence of defective vision of the right eye, inability to raise the lid, which seemed to be spasmodically pressed against the eyeball, pain over the eyebrow, in the eye, and extending outwards from it over the side of the head; there is some intolerance of light, and the attempt to look at any thing always increases the pain. The eye seems to have sunk in the orbit, and the pupil is a little dilated. She had suffered more or less from this complaint for seven years, but it had been greatly aggravated during the last two months. Her bowels had been kept in a regular state; she had taken different medicines, tried change of air without effect, and had menstruated twice at irregular periods, without perceiving any beneficial change. She was subject to Hysteria. On her application at the Infirmary, she was bled from the jugular vein to 16 ounces, and again from the temporal artery, without any benefit. She was then cupped to the amount of 20 ounces, which nearly removed the pain, and rendered her freer from it than she had been for seven years. The bowels were daily purged with the sulphate of magnesia. At the end of two days the pain returned. Calomel, leeches to the temple, and venesection to syncope, were now had recourse to, with only temporary relief, although she was frequently, during the subsequent day, in a state of syncope from the loss of blood. Two grains of calomel, and a quarter of a grain of antim. tart. were given three times a day, or as often as the vomiting resulting from it would admit, and were continued for several days, without any advantage. Her head was now shaved: the liquor ammoniæ was rubbed twice a day over it; and it was kept cold with



water frequently applied, which seemed to remove a weight from the head, and gave her some relief. This continued only for a short time, [although the pain did not recur of so violent a nature : she was twice bled at short intervals, and the tinct. lyttæ was ordered for several days, in doses from ten to fifteen drops three times a day, which did not affect the bladder, nor produce any sensible alteration in her complaint.

July 20. The tongue is always clean, pulse regular, and her appetite good, although she lives very abstemiously, never eating meat. The catamenia, since her treatment began, has been regular, but she considers she had passed her period. The pain shifted a little to the opposite side, but was removed by the loss of 12 ounces of blood by cupping on the temple of the side affected.

July 24. Last evening she was attacked with sickness and vomiting, which lasted for an hour or two. This was followed by hysterical fits of some violence, which continued through the night, and left her quite weak.

July 27. During these few days, the pain over the eyebrows is much less severe. On one occasion, after the sickness and hysteria had been troublesome, and when perfectly free from a fit, she found an utter inability of speaking ; this, however, continued only for a few hours. The sickness and hysteria went off, but the pain over the eyebrow returned, and it increased and continued ; still it was much less severe than it had been previously to her coming to the Infirmary. About the time of her being attacked with hysteria (a few days back), a temporary dysuria took place, which was relieved by warm fomentations to the region of the bladder. The catamenia has not yet appeared again. She is now ordered to take guttas x tinct. lyttæ ter. die. The pain has shifted back again, from the left to the right eyebrow, its original seat of attack.

July 29. She had two slight attacks of hysteria on the evening of the 27th, and soon after she recovered she found herself perfectly free from the pain over the eyebrow, which has



not since returned. Very early on the morning of yesterday (28th) she again found an utter impossibility of using the organs of speech: she says she had not the power of elevating her tongue to the roof of her mouth. From some uneasy sensation, which she felt in the oesophagus at the moment, it is probable this was a symptom of hysteria; though the sensation was not like globus hystericus, which she had been much troubled with (and consequently well acquainted with) for some years back.

August 1. She has passed the three last days free from pain over the eyebrows, with the exception of some slight return once. She has had one return of hysteria, affecting the oesophagus and the organs of speech as before, but which continued for a short time only. She has continued the tinct. lyttæ, and has had a blister behind each ear. The tinct. lyttæ has hitherto produced no strangury. The sickness and vomiting, which occurred about ten days ago, have not returned.

August 3. Has had no pain over the eyebrows, nor any sickness nor vomiting; but she has had an attack of pain in the head. This she attributes to the blisters, which seemed to give more than ordinary pain, that in the head soon following. She has continued the tinct. lyttæ, and has experienced some trifling sensation of heat in the urethra. Her appetite and general health are good. Her pulse and tongue have on all occasions been favourable. Her bowels are regular. Since the blisters have had their proper effect, and have been removed, the pain in the head has left her. She has had one slight return of difficulty or inability of utterance.

August. 5. Has continued the tinct. lyttæ. No return of the pain over the eyebrows; nor of any other symptom, except a slight and temporary difficulty in her speech.

August 8. Still goes on well. No return of pain over the eyebrows, nor of the affection of the organs of speech; but a symptom of another kind has shown itself. She was seized with a sensation resembling the falling and noise of waters within the head. This was preceded by con-



siderable diminution of vision, was followed by a fainting fit, and, after she recovered, the noise in the head went off again. This affection of the brain in a new form did not bring back the pain over the eyebrows. Within the last two or three days, the ung. antimon. tart. has been rubbed upon the scalp; it has produced inflammation and soreness, but no pustules: appetite good: bowels rather lax *without* opening medicine. Has continued the tinct. lyttæ.

August 10. No return of pain over the eyebrows, but some troublesome symptoms of hysteria have again appeared. Ordered to take the pil. aloes c. myrrh daily, as amenorrhœa continues, and to go on with the tinct. lyttæ.

August 15. Still free from pain over the eyebrows; the amenorrhœa and hysteria the same. Ordered the following pills: R. Ferr. sulphat. gr. xij, pilul. aloes c. myrrh. 3ss. pil. galban. comp. 3j. ext. hyoscyam. 3ss. ft pilul. xxiv, cap. ij, noct. et mane c. haust. (cyath.) infus. pulegii.

19. Menstruation has returned, she is much better in every respect, and quite free from the pain, for which she applied to the Institution. After this she continued in the house a short time (during which she was now and then somewhat troubled with hysteria) and was then discharged, perfectly cured. This case was taken by Mr. Cox.

In the three following cases the complaint seemed to depend on some derangement within the head.

A young woman applied to me in the year 1818, with symptoms entirely resembling those last described; they had come on slowly, but increased gradually until the pain became excruciating, in the forehead, over and in the eye, and towards the side of the head. The intolerance of light was such as hardly to allow of the lid being raised. The eye seemed to be pressed back in the orbit by the pressure of the lid, which was a little swelled and resisted the attempt to raise it. Her health was otherwise good: the catamenia regular. Large bleedings, the regular exhibition of drastic, alternating with mild purgatives, a caustic issue kept open for two months before the mastoid process, mercury, repeated blisters, iron in va-



rious preparations, colchicum — all failed to effect a cure, although almost every thing caused some relief. At the end of nine months' rigid treatment the disease gradually subsided, and she perfectly recovered, rather as the consequence of the whole, than of a particular remedy or method of treatment.

A young woman, 20 years of age, presented herself at the Infirmary, with the same set of symptoms as in the preceding case, with the addition of a sensation of weight in the head, sometimes rendering her lethargic. Large bleedings, cathartics, blisters, were tried in vain: she gradually got worse, and seemed passing into a state of coma, from which she was only saved by the loss of a very large quantity of blood. The pain now became less severe, and by a frequent repetition of the bleedings, in small quantity at a time, and by due attention to her general health, she gradually recovered.

In the third case, the patient, a young lady, suffered precisely in the same way; the disease remaining, however, rather more stationary after it had attained its acme of pain, until symptoms of approaching apoplexy made their appearance. This was prevented by the abstraction of 40 ounces of blood: but as her mother had died of this disease, it was considered the most important, and she was delivered over to the care of a physician, under whom she recovered, principally by small and repeated bleedings, with other general but simple measures.

I had lately under my care a groom, who was sent to me by his master, on account of a pain in his forehead, which had been pronounced rheumatic, and treated as such in vain by several eminent practitioners. It affected the forehead, the side of the head, and the region of the frontal sinus of the left side, in a manner similar to the cases related above: the difference between them was, that the pupil in this case was in its natural state, both as to size and motion, although vision was defective. The eyelid fell a little, and there was an unusual intolerance of light when the pain was most severe; which in all these cases is often increased by paroxysms. He had suffered, more or less, for seven years, but was yet capable of doing his work, although in an inefficient manner. When



he first came under my care, bleeding, cupping, and the colchicum, combined with mercury, seemed to give him great relief, and he looked forward to a cure; he again, however, deteriorated; fever made its appearance, with evident affection of the head; this was relieved for a time, but the general state of febrile excitement did not diminish: some severe rigours were followed by great exhaustion, a slight squint of the eye of the affected side, and great difficulty of speech, although he remained perfectly sensible, and capable of moving every limb. He gradually recovered his speech in a few days, and thought himself so much better as to have himself supported in an arm chair eight hours before he died, which appeared to take place from exhaustion: while sitting in the chair he conversed with me in his usual natural manner. Mr. Thomson opened the head next morning, in the presence of Mr. Sheldon and myself, and found an abscess in the anterior lobe of the left hemisphere of the brain, containing at least two ounces of pus; the dura mater formed the anterior boundary of the sac, and a slight puncture through the anterior portion of the lateral sinus opened the back part of the abscess. The under surface of the cerebrum, and the whole of the cerebellum, were covered by a thick layer of matter, not to be distinguished from pus, deposited between the brain and pia mater, and external to it; the membrane being evidently in a state of inflammation. The orbital plate of the frontal bone, on which the anterior part of the abscess rested, was diseased, and almost removed by absorption, as if nature was endeavouring to find an exit for the matter of the abscess. The loss and the subsequent recovery of speech, and the defective vision of the eye of the affected side, deserve, among other important points, particular attention.

The practice which Schmidt recommends, and seems principally to rely on, of caustic issues, has not merited the same eulogium from me which it has obtained from him. In two cases in which the complaint was of a less severe nature, and the pain more in the course of the superior branch of the



portio dura, he succeeded, in combination with other general remedies; but in the more complicated cases to which I have alluded, and in others which I have not mentioned, they have totally failed.

These cases are more common than is generally supposed: they seem to prevail principally among females, and I have three at present under my care. One a female living in Chapel Street, Grosvenor Place, who has been for several months a patient at the Infirmary, and has tried, in vain, all and every of the remedies that have been mentioned, and many others besides, is now getting well by the gradual subsidence of the disease, although a month ago she could scarcely allow any part of the left half of her body to be touched without shrinking, from pain.

---

ON THE COHESION OF THE EDGES OF THE EYELIDS,  
OR OF THE INNER PART OF THE LID, TO THE  
BALL OF THE EYE.

The adhesion of the edges of the eyelids to each other, so as to obliterate the opening between them, is a complaint mentioned by authors under the name of *Ancyloblepharon*, from *αγκυλη*, a hook; and *βλεφαρον*, the eyelid; but very rarely seen. I have, indeed, a suspicion that it never takes place from disease, although it may be congenital, and that the division noticed by Beer, into perfect and imperfect, is unnecessary; the latter species being the only one ever met with, as an opening always exists at the inner canthus, through or into which a probe may be introduced. The adhesion of the lids to each other can only occur under particular circumstances, *viz.* when the edges are deprived of their natural covering by excoriation, in consequence of inflammation, and are kept in apposition, either from inability to open the eye, or from improper bandaging. When the eyelids are thus situated, it is possible they may adhere in particular parts by the usual process of adhesion, which implies the deposition of



lymph agglutinating the two surfaces to each other, notwithstanding the passage of the natural secretions over them, and which must form an insuperable obstacle to a perfect union in the whole of their extent. The cause, whatever it may be, which gives rise to this union of the edges of the lids, often acts at the same time on the eyeball, an union takes place also between the eyeball and the inside of the lid, which is called Symblepharon, from *συν*, together; and *βλεφαρον*, the eyelid; and constitutes a complaint not unfrequently met with and of a very intractable nature. This is also divided by Beer into perfect and imperfect; the former implying a general adhesion of the two surfaces, the latter an union in particular parts; the one being incurable, the other, in many instances, admitting of relief although very seldom of cure. This complaint has also been called Symblepharosis, Prosphysis, Enothes. The structure and properties of the conjunctiva, as a sero-mucous membrane, and especially that part of it lining the eyelids, do not admit of adhesion taking place between its surfaces whilst they remain entire, whatever degree of inflammation may be excited on them. In consonance with this opinion, we never find that union of these parts occurs in any of the inflammations arising from other than mechanical causes, unless ulceration has previously taken place; a provision which Nature has made for the preservation of vision, which would otherwise be lost in every severe case of inflammation. The causes, then, of these adhesions are generally to be found in the application of such substances as abrade or destroy the conjunctiva covering both surfaces; such as melted lead or other metals, the mineral acids, quick lime, and scalding water; they also occur from burns, and from wounds affecting both surfaces. Either of the substances enumerated getting between the eyeball and the lid, certainly abrades the surfaces of both, whilst it generally gives rise to ulceration, and often to sloughing of the cornea, when the termination is usually fatal to the eye. In all these cases the inflammation which takes place is severe,



and from the cornea being implicated, the intolerance of light is so great as to prevent the patient, when neglected or improperly treated, from attempting to open the eye; and the abraded or ulcerated surfaces are kept for an indefinite time opposed to each other. At a period which cannot be precisely indicated, means of union are offered by the inner surface of the eyelid; and, if I may use the expression, are accepted by the surface of the eyeball; for I am of opinion, that the whole of the matter supplied to effect the union is furnished from the vessels of the lid; which hypothesis seems to be confirmed by an examination of the substance connecting these parts in the slighter and relievable cases, which is always found to partake of the nature of the lid, and perhaps of the conjunctiva of the eyeball, but not of the cornea; and which may account for the fact, that I have never met with any difficulty in effecting a permanent separation of such partial adhesions from the cornea, whilst it is next to impossible to do so by any means we are at present acquainted with, when union has taken place between the conjunctiva lining the lid and that covering the sclerotica alone. In the year 1815, a soldier of the 95th regiment was examined at York Hospital, on his discharge, when a long and narrow adhesion of the skin of the edge of the lower lid of the left eye was observed to pass up as far as the centre of the cornea, apparently possessing the properties of true skin. It occurred from some lime getting into his eye; and when the inflammation had subsided, and he attempted to open it, this adhesion was found to have taken place. He suffered no uneasiness from it, but its whiteness gave him a very peculiar appearance: he would not let me remove it.

Beer\*, and his abridger, Weller†, say, that the prognosis is more favourable when the union is effected, in either complaint, by the formation of a particular (new) membrane be-

\* Beer, *Lehre von den Augenkrankheiten*, &c. page 126, s. 108 2 band. Wien, 1817.

† Weller, *Manual of the Disease of the Eye*, by Dr. Monteath.



tween the parts, in consequence of the greater facility it affords in effecting the separation; but unless they mean merely the elongation of the adhesions from mechanical causes, I do not understand them, and I presume they cannot intend to imply any thing else; for the union of parts is, I conceive, always accomplished in the same way, although this difference may subsequently take place; that the adhesions, when partial, are elongated by the motions of the eye and eyelid, in the same manner as those which are framed between the membrane covering the lungs and that lining the chest, whilst the more general adhesion of the surfaces remains permanently fixed.

In these partial adhesions, a very important distinction ought to be made as to their nature, and the part from whence they take their origin, for much mischief may be committed by improper interference. When the adhesion begins at, is continuous with, and arises from that part of the conjunctiva which is reflected from the lid to the ball of the eye, so that on raising the eyelid a broad attachment is perceived, restraining the motions of the eye, it ought not to be meddled with for it may be increased, but it will never be diminished. This is a fact which cannot be too strongly impressed on the minds of students, inasmuch as the appearances are such as to offer the best hopes of success, whilst experience proves to us their delusive nature. Nothing seems more easy than to divide the adhesion, and to keep the parts asunder until each side shall heal, but nothing is found more difficult; for, although they may seem to cicatrize separately, still the contraction attendant on cicatrization draws them together, as it takes place, and re-establishes, if it does not increase, the original complaint.

When the attachment takes place, by one or more narrow slips of communication, an amelioration may frequently be effected, by the simple operation of dividing the attachment close to the eye, and cutting it away from the lid; but if it arises from the angle of reflection, it will require repetition, great care in the treatment, and will not be quite successful. When, on the contrary, the adhesion takes place at such



distance from the angle of reflection of the conjunctiva as will admit the passage of a large probe between them, an operation will succeed in effecting a cure.

This complaint was well known to the ancients, and would indeed seem to have been more common with them than with us. Celsus\* recommends the introduction of a flat probe under the eyelids, by means of which they are to be forcibly separated; but if they adhere to the white of the eye, then the separation is to be effected with a knife. He adds, "I do not remember an instance of one person cured by this method." Meges also says he tried many ways, but never succeeded, for the eyelid always adhered again to the eye.

Paulus† directs that a flat probe be introduced between the lids, or that they should be raised with a hook, and the adhesion divided with a knife. Aëtius echoes Paulus; and Fabricius‡, ab Aquapendente merely desires the knife to be curved, made smooth on the back, and the point to be covered with a small ball of wax, to enable it to pass between the lids with more facility.

Hildanus§ describes a different method of proceeding in the following case: "A young nobleman received a wound from a sword, in the year 1593, which extended from the left ear as far as the eye, the upper eyelid being divided and the cornea injured, although superficially. In consequence of the parts having been firmly bound down by bandage, union took place, so that the patient was prevented from opening his eye, and was not altogether free from pain. To remove this deformity, a bent probe was gently introduced from the inner angle, until it appeared at the outer; a piece of waxed silk being then fastened to the end of it, the probe was withdrawn, carrying with it the silk, the ends of which were tied under the eye, having attached to them a small piece of lead,

\* Celsus, De Re medica, lib. vii, cap. vii.

† Paulus, De Re medica, lib. vi, cap. 15.

‡ Fabricius, ab Aquapendente, de Chirurgicis Operationibus, cap. 8.

§ Hildanus, Observat. Chirurgic. Centuria 5, Observatio 7.



of about a drachm weight. This moved during the day, according to the motions of the head, but was taken away at night to prevent inconvenience, when the eye was lightly covered up. A collyrium was used three or four times a day, for eight or nine days, when the silk cut its way out and liberated the eyelid. The sight of the eye was, however, found to be impaired in consequence of the cicatrix on the cornea, but the motions of the eye and eyelid were perfectly restored to their natural state."

When the edges of the eyelids adhere partially to each other, the separation may be accomplished by introducing a flat probe beneath them, and then dividing the adhesion upon it with a common scalpel. The wounds thus made should be slightly touched with the sulphate of copper, frequently washed with warm water, and afterwards smeared with some ung. zinci oxydi.

Beer recommends the operator, in such cases, to depress the lower lid, by taking hold of a cross fold of skin with the fore finger and thumb of his left or right hand, as the case requires, whilst an assistant draws the upper lid outwards and upwards in the same manner. A small blunt-pointed bistoury is to be introduced at the inner canthus, and made to cut its way slowly out towards the outer angle, without injuring either eyelid. If the adhesion be through the medium of a membrane, then the incision is to be carried along the edge of the upper lid, and the membrane attached to the lower lid must be cut away with the scissors. He also advises that the patient should sleep soundly the night before, so as to be able to remain awake the night after the operation.

When the eyelid adheres to the ball of the eye, several important considerations present themselves and require attention. If the inflammation which gave rise to the adhesion was violent, the eye may have been so much affected by it as to be useless, even if the operation for separating the lid should prove successful, which would then be unnecessary. When the eyelid is allowed to fall over the eye in its natural



state, light and shadows can be very readily perceived, and this faculty should continue where the eyelid adheres to the eyeball, unless the union has taken place immediately in front of the pupil, when an operation can never be successful in restoring vision, although it may in part remove deformity, for the cicatrix formed on the cornea, after the separation of the adhesion, will still continue to impede the passage of the rays of light. If the eyeball should, on a careful examination, be found larger or smaller, harder or softer, than natural, it indicates, in such cases, a derangement generally destructive of vision, and therefore forbids an operation. If the adhesion of the eyelid to the ball be general, no operation at present known will succeed; it is only therefore when the eye is sound, and the adhesion partial and not covering the pupil, that an operation should be attempted. The extent of the adhesion may be ascertained by drawing the eyelid from the eye with the finger and thumb, whilst the patient rolls the eye as much as he can, when the parts adhering to each other will be sufficiently marked. In those cases which are likely to be successful, the introduction of a probe *around* the adhesion, and the effecting of which can alone warrant any operation, will clearly demonstrate its limits, as in the case related by Hildanus.

Beer\* recommends, in cases of partial union of the eyelid to the eyeball, that the separation should be effected with a round-pointed, thin, and elastic scalpel; which, after the first incision, ought to be used so as to tear rather than cut through the adhesion; but he admits that success is doubtful, that a repetition of the operation will often be necessary; and in one particular case, in which he succeeded, he was obliged to repeat it four times.

I have already expressed my opinion as to the impropriety of interfering with these adhesions, when they are broad, and proceed from the reflection of the conjunctiva from the eyelid to the eyeball; when this union is, however, narrow, and the

\* Lehre von den Augenkrankheiten, B. 2, 129.



adhesion has become elongated so as to assume the form of a band or bands, having distinct formations and attachments they may be cut away with partial success, but will seldom be completely removed; and this partial success will only be attained after two or more operations, which are to be accomplished in the following manner: the eyelid, if the lower one, and such adhesions are usually formed in it, is to be drawn outwards, so as to give a full view of the membranous band attaching the parts to each other, which is then to be divided close to the cornea, and down to the reflection of the conjunctiva, by one snip of a pair of scissors. The eyelid being now completely drawn outwards, the portion of the membrane which remains attached to the conjunctiva is to be carefully raised with a forceps, and cut away in like manner with a pair of scissors. In order to prevent adhesion, the cut surfaces of the eyelid should be lightly touched with the sulphate of copper, and the patient should frequently roll the eye and move the lid for the first twenty-four hours, during which time it may be washed with the decoctum papaveris albi. The attention must now be directed to the healing of the part next the cornea, and the edge of the lid, whilst it should be prevented as much as possible at the angle between the eyeball and eyelid; in other words, the wound should be induced to heal downwards rather than upwards. There is never any difficulty in clearing the cornea; but it is very much the reverse with the conjunctiva beneath it; for, although the cicatrization may be nearly accomplished, with little appearance of adhesion, still, on its becoming complete, a contraction takes place, which in a great degree restores the appearance of the previous attachment. By a repetition of the operation, some further advantage may be gained; but I believe I may say, the parts are never restored to their natural state, although the deformity and inconvenience may be almost entirely removed.

I have succeeded in several instances in separating attachments of this kind, and in the manner I have recommended,



where the adhesions had extended nearly as far as the centre of the cornea; but in every case a second, and in some a third operation was necessary to effect a cure.

When the adhesion is partial, and a probe can be passed around it, the prospect of success is greater, in whatever part it may be situated. The division of it is to be effected with a knife, either close to the cornea or the eyelid, and the whole of the adventitious parts removed with the scissors. The tearing of the adhesion by the elastic scalpel of Leber, as recommended by Beer, possesses no advantages, as it scarcely influences or prevents in any way the reunion of the cut surfaces, which is much more effectually hindered by touching the bleeding surface of the eyelid with the sulphate of copper, and by taking care to keep the parts in frequent motion for the first twenty-four hours. The introduction of foreign substances between the eyelids always does harm.

---

#### ON WOUNDS OF THE EYELIDS.

THE operations, which have been directed to be performed for the removal of the diseases already noticed, will show, that wounds of the eyelids are neither dangerous nor difficult of cure; and that they merely require to be treated by those simple rules, which regulate the practice of surgery in other parts. In consequence of the constant motion of the eyelid, and of the deficiency of a point against which pressure can be made, penetrating wounds, whether horizontal or perpendicular, will, *generally*, require the insertion of one or more sutures to retain the edges exactly in apposition, assisted by strips of sticking plaister, a compress, and the due application of a bandage, to ensure the perfect immobility of the part. I have shown, in the method of cure recommended for entropium, that a simple perpendicular incised wound will heal without difficulty or deformity, by merely keeping the parts in contact; yet, if the wound should happen to be more extensive than is alluded to in these cases, one or more



sutures will be highly serviceable. When the division is horizontal, the eyelid should be raised and supported against the edge of the orbit by proper pressure, made by compress and bandage; or, if the wound be of greater extent, the silken threads forming the sutures should be fastened to the forehead, as in the cure of entropium, for the first forty-eight hours, after which they should be cut out, and the eyelid again supported by sticking plaister, compress, and bandage.

When the lachrymal canal is divided, I doubt very much if union ever takes place in such a manner as to render it pervious; and although Professor Schmidt\* and Mr. Mac Kenzie† seem desirous that we should believe in this process, I confess I am rather sceptical on the subject. These gentlemen advise in such cases (I presume of injury of the upper lid), that means be adopted to keep the eyelids apart, or, as it is termed, open, for at least twenty-four hours, as the edges of the incision are then in contact, but are separated by every motion of the lid. To effect this, they recommend that one or more slips of plaister should be applied, of sufficient length to extend from the cheek or the temple, and then drawn over the wound, and fixed to the nose or forehead, and the patient is desired to close his lids as little as possible; but this direction he cannot obey in the manner intended; and I therefore advise, notwithstanding the prohibition of Schmidt, that recourse should be had, in severe injuries, to a suture, with sticking plaster, compress, and bandage, to fix the eyelid in its proper situation. Schmidt says he used them, in two instances, and had to make up by sticking plaisters for the time lost by the sutures; but I am fully persuaded he used them improperly, for the adhesive plaister is always required in combination with them; and his observation, as to the deficiency of room at the inner angle

\* Schmidt, Ueber die Krankheiten des Thräennorgans. Wien, 1803, p. 218.

† Mac Kenzie's Essay on the Diseases of the Lachrymal Organs. London, 1819.



of the eyelid for the insertion of a stitch or suture, confirms me in this opinion. When the sticking plaister is alone relied upon, it sometimes fails from getting wet and losing its agglutinative properties.

Wounds penetrating the upper eyelids in a horizontal direction may also injure the eyeball, and if the wound be deep, the eye will in all probability be lost; but if it be slight, cicatrization will take place, and a scar only remain, marking the situation of the injury. In such a case, the elevation of the upper lid necessary to bring the parts in perfect contact, will effectually prevent the coalition of the wounded portion of the lid with that of the eyeball; but if the wound should be in a perpendicular direction, that in the lid will remain opposed and in contact with the wound in the eyeball and if passive motion be not early given to the lid, a union, or symblepharon, might be the consequence. Sometimes a fissure remains at the edge of the lid, termed a coloboma; but this very rarely happens, unless a portion of the lid has been cut away, and the sutures have failed in procuring union. In such a case, the two edges of the little fissure ought to be refreshed, as it is termed by the French, by removing the skin covering them with a sharp knife or lancet-edged scissors, when the sides of the fissure are again to be brought together by a suture; which, as in all other cases, should be inserted completely through the lid, and removed early, as in the operation for the third species of entropium. If the slit or fissure is small, callous, and of long standing, I recommend, with Demours, that all operative methods should be avoided; but if it be merely a slight defect of union, it may be aided at the moment, and be gradually induced to fill up by gentle applications of the *argentum nitratum*.

Wounds of the eyelids are very seldom productive of defective vision, or amaurosis, unless some injury has at the same time been done to the eye itself.

Wounds and injuries of the forehead are often productive of deformity, and sometimes of blindness, and consequently



demand considerable attention. In cases of incised and lacerated wounds, attended with extensive solutions of continuity, recourse should always be had to one or more stitches or sutures, whenever the common sticking plaisters do not keep the parts in complete apposition; and this rule should not be departed from; for, if the incision be a horizontal one, near, or upon the eyebrow, which is commonly the case, and the suture be neglected, an irregular cicatrix, as well as a slight falling of the lid, is very apt to ensue; and much less inconvenience will arise from the suture than from the suppuration which will certainly take place if union be attempted without it. In cases of bruises, burns, or scalds, followed by loss of substance, even of the skin and cellular texture alone, great care should be bestowed so as to prevent the drawing in of the surrounding parts in the process of cicatrization, or some deformity will follow, as in the case of Henry Puchet, page 78; which can only be done by delaying the cicatrization, so as to encourage the formation of new skin, and by counteracting the contracting process by opposing powers, mechanically applied in the shape of agglutinative plaisters, compress, and bandage. These observations as to the use of sutures apply also to non-penetrating wounds of the cheek, even when they do or do not appear to implicate the eyelid.

Vision is sometimes affected by these wounds in a manner that would appear unaccountable if we were not acquainted with the subtlety of nervous sympathy. The relation of the numerous cases I have met with of this nature would rather gratify curiosity than answer any useful purpose — from the wind of a cannon ball (as it is said) to the prick of the point of a sword. It appears to me, however, from a due consideration of them, that defective vision, or a total deprivation of sight, rarely takes place, unless the injury immediately affects a branch of a nerve, of such magnitude as to be usually demonstrated in a common anatomical dissection. These wounds or injuries are either situated, for the most part, on the forehead towards the nose, implicating the supra-orbital branch,



and the nasal branch of the first division of the fifth pair of nerves, or immediately below the eye, affecting the infra-orbital branch of the second division of the same nerve. It is not necessary that any injury should have been inflicted on the eye itself, and the absence of all appearance of it at the moment, independently of the patient's own knowledge on the subject, sufficiently attests the fact, that the amaurotic affection is the result of sympathy, and not of direct injury to the eye. In some instances, the deprivation of sight would appear to be simultaneous with the receipt of the blow; in others it comes on more slowly, during the process of healing, and is seldom complete; whilst in a third set, it only commences after the cicatrization is fully accomplished.

When the deprivation of sight is instantaneous, I suspect, notwithstanding any opinions to the contrary, that the eye itself has suffered from the general concussion. When there is an evident derangement of it, such as an extravasation between any of its tunics, the fact cannot be doubted, and the treatment has no immediate connection with the wound of the forehead, although the termination, under any kind of management, will, for the most part, be fatal to vision.

Beer\* and Weller† place great reliance on the appearance of the iris, as indicative of the manner of the derangement; that is, whether it has arisen from sympathy with the supra-orbital nerve, or from a direct affection of the eye. They consider a contracted pupil to indicate concussion of the eye; a dilated pupil, a laceration of the supra-orbitary nerve — inferences which do not accord with my experience, inasmuch as the appearance of the eye has been more natural in the amaurosis from sympathy than from direct injury. In some cases of perfect blindness no symptom of disease could be detected, although the defect of vision could not be doubted. The passage in Weller, which gives a compendious statement of the opinions of Beer, is as follows: "The amau-

\* Beer, *Lehre von den Augenkrankheiten*, s. 190 et seq. band 1.

† Weller's *Manual*, by Dr. Monteath, vol. i, page 75.



rotic blindness is to be ascribed to a weakness of the eye, produced by concussion, when there is no remarkable contusion or laceration in the site of the branches of the superciliary nerve, and when the iris of the half, or entirely blind eye, is perfectly motionless and extended in a high degree, in consequence of which the pupil is much contracted. If there be, moreover, an extravasation of blood in the chambers of the eye, or even, without this, if there be a deep pressing pain in the whole eye, and such a degree of sensibility that the eyeball cannot bear the least touch, and if at the same time the vision be so destroyed as merely to leave the smallest sense of light, the surgeon will not err if he declare an actual laceration of the retina, and prognosticate an incurable blindness. The appearances are very different in the eye when only a contusion, laceration, and imperfect division of the greater branches of the superciliary nerve have suddenly produced the amaurosis; for even when the eye is blind, it yet retains in such a case a more or less distinct sensation of light; and although the iris be even motionless, yet the pupil is found not only very unusually dilated, but the iris much narrower towards the canthi than above or below, so that the pupil appears like that of ruminating animals, and the pupillary edge of the iris seems so reclined backwards, that the small circle of the iris is no longer observable."

"If the amaurosis be the product of a contusion combined with dilaceration of the superciliary nerve, the above enumerated characteristic symptoms will be found mixed, only the iris will have nearly vanished."

This account of symptoms is so foreign to my observations, that I can only reconcile it by supposing, that they are taken from a very advanced period of the disease, long after the accident had occurred, and that they are rather the consequence of internal derangement in the eye, from low, irregular action, than the sudden result of sympathy.

When complete blindness takes place as the immediate consequence of a blow on the eye or on the forehead, and con-



tinues without amendment for several days, it has hitherto, I believe, been found incurable. When there is a partial blindness, so that the patient sees with only half or a part of his eye, the injury has been direct to the organ of vision, and is sometimes in part relievable. When the defect of sight comes on slowly some days after the injury, the case is less desperate, although a cure is equally uncertain; the complaint may be arrested, but is seldom entirely removed. If internal inflammation, either in its acute or chronic form, supervene, no hope should be entertained of the affected eye, and the other will be in considerable danger; for, although the sympathy existing between the eyes is not great in consequence of a purely local nervous injury; it is as much to be feared when excited by local inflammation, as it is admitted to be by general nervous derangement.

When the injury committed on the forehead is sufficiently severe to affect the brain as well as the supra-orbitary nerve, it may not only give rise to symptoms indicating inflammation of the brain and its consequences, but to a derangement of the nervous system of the eyes, which may show itself in an amaurotic affection of both. I consider an amaurosis from injury to be much on a par with cataract from injury, and often occurring without affecting the other eye; whilst both diseases, when caused by internal derangement, seldom exist long alone.

When the defective vision follows a wound on the forehead, the only hope of relief that we are at present acquainted with lies in a free incision made down to the bone in the direction of the original wound; and even of the efficacy of this I am sorry I cannot offer testimony from my own practice, having failed in every case in which I tried it. Scarpa, on this subject, says, "Of the numerous cases of amaurosis of this kind, I do not know that any one has been cured, except that related by Valsalva in his Dissert. 2, s. 11." Beer, however, speaks positively of success having attended his practice, and I therefore transcribe the passage: "My experience authorizes



me to say, that much may be done in these cases at the moment, which, if neglected, cannot be repaired at a subsequent period. If the defective vision commences during the cicatrization, it will proceed to complete amaurosis, in consequence of the nerves, which are already half torn and irritated, being still more injured and stretched by that process, unless the operation is quickly resorted to, of completely dividing the supra-orbitary nerve, near where it passes out of the orbit, through the supra-orbitary foramen, to be distributed on the forehead; after which the patient will soon recover his sight, of which fact I am positive from the result of several operations. This practice is to be followed, whether the blindness is immediate, or only takes place during cicatrization, or after the healing of the wound\*." He subsequently says he was led to adopt this practice in consequence of the queries of Richter on this subject, in the three hundred and twenty-fourth section of the second volume of his *Rudiments of Surgery*; that he was always disappointed when he used emollient or oily applications, frequently lost a great deal of precious time in their employment, and had at last to have recourse to the operation, which, he again repeats, never failed him.

In all cases of wounds of the forehead, which are accompanied or followed by any defect in vision or amaurosis, the surgeon should endeavour to ascertain whether it has been caused purely through nervous sympathy, injury of the eye itself, or by general concussion of the head. It will also be necessary to observe whether the amaurosis, subsequent to the commencing cicatrization, be a consequence of nervous sympathy alone, or of a low irregular vascular action of the internal part of the eye, which can be readily ascertained to be going on from its symptoms and appearances, whilst the pure nervous derangement is only discoverable by its effect in destroying vision. The object of this particular inquiry is to regulate the practice to be followed, and particularly in relation to that recommended by Beer; for every wound of the

\* Beer, *Lehre von den Augenkrankheiten*, band 1.



forehead, implicating the fifth pair of nerves, does not cause amaurosis; whilst many cases of defective vision, accompanied by wounds, are dependent on other injury than that committed on the forehead.

According to my observation, the eye, when amaurotic through injury of the supra-orbitary nerve (and I have had many opportunities of examining officers and soldiers, who have lost the sight of one eye, in consequence of injuries of this nature), often shows little or no derangement of structure, the iris preserves more or less of its natural motions, and the information we acquire is from the patient's declaration of his loss of sight, which is generally unaccompanied by pain. When amaurosis is the consequence of a direct injury to the eye itself, there are, for the most part, positive marks of the injury having been inflicted upon it, which cannot be mistaken; such as extravasations in, or lacerations of some of the internal parts. The motions of the iris are greatly impaired, the pupil is dilated, the pain is considerable. When the amaurosis is the consequence of concussion or of derangement within the head, such as extravasation of blood or deposition of matter, the eye of the side opposed to the injury is most frequently affected, when both are not equally implicated, which state will be easily recognized by those conversant with injuries of the head, by whom alone they should be treated.

Wounds of the forehead should be managed according to the principles of surgery applicable to wounds of the head in general. If loss of sight should have immediately followed the injury, an incision should be made down to the bone at the part affected, so as to render it a clean incised wound, whether it were before a contused or a lacerated one, which should then be dressed simply, and suppuration encouraged in a moderate degree, by the application of a poultice. If the amaurosis should only appear after cicatrization has commenced, the same kind of incision should be made on that side of the wound nearest the supra-orbitary foramen. If



these should be found of no avail after a few days, the operation of dividing the nerve, just above where it passes out from the orbit, should be attempted, as a last resource; and those who consider that this operation fulfils the intention better than dividing the branches, which are irritated at the part itself, will have recourse to it at once in the manner recommended by Beer, which will certainly be preferable when cicatrization has nearly or completely taken place, and a new wound must in any manner be made. When the injury has been inflicted upon the eye, and the amaurosis is complete, or commences slowly, or after a few hours begins to subside, a division of this branch of the fifth pair of nerves must be useless, and may do mischief. In this case, independently of any considerations which may arise from injury committed within the head, recourse must be had to general bleeding; cupping on the temple of the affected side; a regular drain by the application of four or six leeches near the eye, every day, or second day; purgatives; abstinence; and, if applications are made to the eye, I consider the decoctum papaveris albi, used warm, the best local remedy. At a subsequent period, stimulants, galvanism, electricity, or the moxa may be useful, if a partial restoration of vision be effected. If signs of active inflammation take place, the depletory means must keep pace with them; but when the low irregular action occurs, to which I have alluded, dependence must be placed on local bleeding, blisters behind the ear, a caustic issue above it, and mercury given in such manner as to affect the mouth quickly.

When amaurosis is followed by inflammation, the complaint is of a much more serious nature than when it is apparently a nervous derangement alone, and not so much on account of the affected eye, which will be entirely lost, but from the great probability of the other eye being attacked by internal inflammation, even if it should not become amaurotic. I have had several cases of this kind under my care. In one, the wife knocked her husband down with a frying-pan, which blow



ruptured the iris : in another, the husband knocked the wife down with a pair of bellows, and ruptured the cornea and iris. Low inflammation, with amaurotic amblyopia, took place in both cases in the other eye ; the man lost both his eyes ; the woman was less unfortunate. The pain experienced in affections of this nature is not so much felt in the eye as it is in the different branches of the supra-orbitary nerve near the nose over the forehead, and round the side and even back of the head, showing that the sympathy is as complete between the eye and the nerve, when the former is suffering from internal inflammation, as between the nerve and the eye, when the affection of the nerve is the cause of amaurosis.

A third case, of a mixed nature, deserves attention. A gentleman, when pheasant shooting, was accidentally shot in the face by his companion ; seven of the shot struck the forehead and side of the head, and one was supposed to have passed into the orbit by the side of the eye : complete blindness was the immediate consequence, from which he gradually in part recovered, but not so as to be able to distinguish a letter in an octavo volume, although he could perceive the lines. The small holes made by the shot soon healed. In this state he came under my care ; the eye being to all appearance just as sound as the other, not painful, and he only suffered inconvenience from one of the shot on the forehead, which was pressed upon by his hat. He considered his vision to be more defective at intervals, from a black cloud passing over the eye, which he described as descending from the outer corner of it. This cloud, in the course of his treatment and consequent improvement, diminished so as to come over the eye only after he had read a whole page of an octavo volume ; and when the amendment first began to take place, he could enable himself to see for a minute or two, by first turning the eye quickly outwards and then inwards, when it became momentarily clear. In this case, I removed the shot which caused uneasiness, drew blood from the temples by cupping, had recourse to purgatives assisted by alteratives



and abstinence, and subsequently stimulants applied around the orbit, under which treatment he recovered.

The physiologist will not fail to connect these pathological observations with the opinion of Majendie, that the integrity of the fifth pair of nerves is essential to vision.

---

ON TUMOURS, OF VARIOUS DESCRIPTIONS, AFFECTING THE EYELIDS: HORDEOLUM, CHALAZION, GRANDO, &c.

THE eyelids are very liable to become the seat of small tumours, of various descriptions, some apparently the product of acute inflammation; others, of an unhealthy character, and also the consequence of an irregular and scarcely perceptible action, which is, for the most part, only an object of attention when the small tumour is accidentally discovered by the finger passing over the part in which it is situated.

The Hordeolum, or, *κρίθη* of Hippocrates, is an inflammatory tumour, resembling a boil, and partaking very much of its external characters, situated in general on the edge of the eyelids, and seldom attaining the size of a grain of barley before it suppurates and breaks. It is said, by most authors, to prevail in persons of a scrofulous, cachetic habit, but I have seen it very frequently in young persons under the common English name of sty, without being able to discover any peculiarly unhealthy diathesis in the habit. The inflammation, which gives rise to it, begins generally in the cellular texture covering the tarsal cartilage, occasionally in the skin, but rarely, if ever, as has been supposed, in a Meibomian gland. It commences with a burning sensation, accompanied by an itching of the edge of the lid, which, on examination, appears red, and slightly swollen; this swelling soon becomes more painful, and assumes the form of a small hard tumour, of a dark red colour, which, as it increases, becomes more oval, elevated, and shining. The pain is greater than might be expected from so small a tumour, is increased on moving the lids, and even extends to the eyeball. When the inflammation affects the edge of the eyelid, it often extends a little way on the



conjunctiva: the secretion from the Meibomian glands is increased and becomes more glutinous. In persons of an irritable habit, slight restlessness and other symptoms of fever ensue. When this inflammation is not arrested, the redness is augmented in intensity, and assumes a darker brown colour, the tumour increases in size and appears more conical, and the weight as well as the pain of it is complained of by the patient. At this period the swelling becomes softer and appears to point, the apex of the tumour becomes of a straw colour, the skin soon yields, a whitish matter is discharged, but the tumour does not subside; a portion of the apex seems to have been destroyed, and the fluid part of its contents to be evacuated; but the cellular texture, in which the inflammation had its origin, remains in a state of slough, to be discharged, as in all other unhealthy inflammations or furunculi, by a subsequent process of separation, during which the little tumour gradually softens, and on the removal of the slough, which may be assisted by pressure, slowly heals. The resolution of these tumours is seldom accomplished, and ought not to be attempted where the inflammatory action is acute, for it never succeeds. When several of them follow each other in rapid succession, the later ones seldom go on to suppuration, but remain as small troublesome points of inflammation, which often continue for weeks or months, and are best left to themselves, attention being paid to the patient's diet and general health. The resolution of the more active tumours may be attempted by iced water, or vinegar and water, constantly applied, but which ought to be omitted if the pain be found to increase, and a small warm poultice substituted, which will assist in promoting the suppurative process. The abscess should not be opened, but ought to be allowed to discharge itself by ulceration, and the poultice should be continued until the slough is discharged and the hardness of the tumour has subsided. If the whole of the slough should be long in separating, Scarpa recommends that it should be touched with the point of a camel's hair brush previously dipped in sulphuric acid, in order to destroy it completely, and to hasten



the actions in the parts beneath. If the tumour should continue hard, Beer\*, in order to prevent the formation of a chalazion, recommends the use of roasted onions, or a poultice of cicuta and camphor.

The slight swelling and redness of the lid, which frequently remain, will be gradually removed, and the disposition to a return of them perhaps prevented, by any mild astringent lotion, such as the *lotio zinci sulph. gr. ij ad f℥ iv.*; the *lotio plumbi subacet. dil. &c.* Strict attention should also be paid in children to the state of the bowels, to regularity in diet, to exercise, and to clothing.

When the inflammation which gives rise to the hordeolum does not proceed to suppuration, the commencing swelling soon degenerates into a hardened tumour, which has been called chalazion, grando, lythiasis, tophus, porosis, &c. is sometimes very troublesome, occasionally dangerous, and generally requires an operation for its cure. It is commonly a small fleshy tumour, but is sometimes found to contain calcareous matter, when it obtains the name of lythiasis, which may be situated on the outer or inner side of the eyelids, and seldom exceeds the size of a hazel-nut. The chalazion is not usually attended by pain, and is not even red, unless it be immediately under the skin. When it takes place in the lower lid, it is more perceptible on the inside, and in the upper lid its site is often clearly seen through the cartilage on everting it, when it offers nearly the same appearance as an encysted tumour.

The removal of this swelling may be occasionally effected, when it is small, by gentle friction with any smooth solid substance, such as an old woman's gold ring, which has long obtained credit for this service, and sometimes by stimulant applications, which, whilst they induce inflammation and suppuration, occasionally bring on unhealthy action, and give rise to sores of a malignant character. When a chalazion becomes troublesome from its size, it should be removed by making an

\* Beer, band i, s. 335.



incision through the skin over it, in the direction of the eyelid, of sufficient extent to expose the tumour, which should then be raised with a hook, and cut off with the scissors, care being taken not to injure the cartilage, or the edge of the lid; and if a portion should adhere to either, it must be left, and will be destroyed by the suppuration which will ensue. Escharotics generally do mischief, and ought, therefore, to be avoided, as capable of giving rise to cancerous ulceration in persons of a cachectic habit. Professor Beer seems to consider this as a common occurrence in Germany; but in this country, where the practice of surgery is in general much better understood, and relief is speedily obtained, such a change is very rarely or never observed. When it does take place, it will, I suspect, be only symptomatic of a cancerous diathesis, which has already shown itself by local derangement in those parts most liable to it, and the appearances of its commencement on the eyelid can neither be mistaken nor cured.

Little tumours frequently occur on the edge of the eyelids, between the eyelashes, containing a whitish, fatty, or chalky matter; these should be touched with the point of a lancet, and their contents squeezed out. Small vesicles, containing a colourless fluid, often appear on the edges of the lids, and have been called hydatids, *phlyctenulæ*. They are sometimes stationary for years, at others become troublesome, and are surrounded by a small circle of inflammation, during the continuance of which the cuticle hardens and forms an inconvenient tumour. These should be removed by cutting them off at their base by the scissors, when the part heals under the use of any mild lotion to keep it clean. If the upper part only of the vesicle be cut away, it is apt to form again.

Warts, *verrucae*, are common to the eyelids of both old and young, occurring sometimes with a broad base, at others with a narrow neck. In young persons they may always be removed with safety, either by a ligature or the scissors,



where the base is small; or by the use of any of the caustics where it is larger: in elderly people, or those of a bad habit of body, they should not be meddled with, but with the greatest caution; for, although they may show at first no signs of a malignant nature, they will frequently do so after a very moderate degree of irritation. Whenever, then, any thing is done, it should be by way of complete extirpation, which will be the best mode of proceeding, if yet in time, when from any accident they have become painful and irritable. Under any circumstances the patient should be desired to rub them as little as possible, although it should allay the itching which frequently accompanies them. After many of the preceding complaints, as well as in other chronic affections of the lids, a thickening or callosity of the edges of the lids, with a loss of the cilia, sometimes remains, which has been dignified by the formidable names of ptilosis, from *πτίλος* bald, and pachytes, pacheablepharosis, pacheablephara, from *παχὺς* thick, and *βλεφαρον* the eyelid. The falling out of the eyelashes is a very common occurrence after acute inflammation; but new ones generally spring forth from the old bulbs, although never with the same luxuriance or beauty. When their loss has arisen from long-continued chronic inflammation, some derangement takes place at their origin, and the future growth of them is prevented. I am not acquainted with any applications that will induce them to reappear.

When the thickening or callosity of the edges of the lids has taken place from the formation of several small tumours, and from the operations necessary for, and the inflammation consequent on their removal, as well as from a disposition in the part for the regrowth of them, which is shown by slight inflammations which do not proceed to any direct formation, a cure is seldom completely effected; and the amelioration which does take place is as much the effect of time as of treatment. In persons of a scrofulous habit, a slight thickening of the lids, with redness of their edges, and a partial loss of the eyelashes, will often continue through life, with little inconvenience; in old people, the thickening of the lid will



sometimes give rise to a dropping of the tears over the cheek ; but I have never seen it degenerate into scirrhus, as Beer would intimate it sometimes has done. The ung. hydrargyri nitrati, vel nitrico oxydi, more or less reduced, are the best applications in all these cases, both to reduce the thickness of the lids, and to remove the chronic inflammation, or slight ulceration, which may exist on their edges, together with strict attention to the general health of the patient and the state of the digestive organs. Græfe, of Berlin, recommends a poultice, made of equal parts of the powder of the leaves of henbane and hemlock and linseed meal, boiled together with a sufficiency of water to make a poultice, to be used warm. Beer advises the adoption of some camphor sprinkled on it until the parts become irritable, and then to have recourse to the stimulating ointments, beginning with the weaker ones ; but this mode of practice is troublesome, and does not, in my opinion, deserve to be imitated.

Encysted tumours occur so very frequently in the eyelids, that I am induced to consider them as more common to these than to any other parts of the body ; and although little attention is now paid in surgery to the old distinction, drawn from their contents, of melicerous, steatomatous, and atheromatous tumours\*, which can only be certainly ascertained after they have been opened, I shall not reject it in considering the mode of removing them by operation, as the method in one kind (the atheromatous) ought to be regulated by the nature of the contents, which require the removal of the sac, whilst in the others it is merely a matter of choice or of indifference, the removal of the sac not being absolutely necessary to effect a cure.

The most simple kind of tumour forms immediately under the skin of the lid, elevates the part, and causes it to look like a little flat wart. Of these I have removed thirteen in succession from the same eyelid of a child, without the slightest inconvenience resulting from it. An incision is to be

\* Melicerous, from μέλι, honey, and κέρος, wax ; steatomatous, from στέαρ, suet ; atheromatous, from αθηρωμα, pap, pulse.



made across the centre of the little tumour to its middle; the contents are then to be squeezed out by pressure, made at the base by the nails of the two thumbs, and the cure is completed in twenty-four hours. The tumour will be found, in general, to have consisted of a substance resembling a little brain in appearance, but harder, sometimes attaining almost a cartilaginous firmness, although seldom exceeding the size of a small pea. When these tumours are situated under the orbicularis muscle, they have no distinctive external character, and may still be removed in the same manner; but if they adhere to the tarsal cartilage, the eyelid should be everted, when the projection of the tumour will be perceived through it, into which an incision is to be made, and the contents are to be pressed out in the same manner. This method of removing tumours through an opening in the cartilage is never attended with any inconvenience, and ought always to be adopted when the appearance of the inside of the eyelid is changed from its natural colour to a semitransparent yellowishness, showing the firm attachment of the tumour to the cartilage, even if it do not indicate its partial removal by absorption. The head being firmly held, the eyelid is to be everted, and retained in that situation by the fore-finger of the left hand; the surgeon makes an incision a little longer than the projection of the tumour, with a small sharp-pointed knife, the hand being unsupported, in order to avoid an accident from the starting of the patient. When the cartilage is divided, the tumour appears, and a touch of the knife discloses its nature, whether fleshy, fluid, or otherwise. If fluid, the contents escape, and the operation is completed by introducing the blunt end of a common probe into the sac, and moving it about in every direction, so as to empty it completely, and at the same time to excite inflammation. This should be repeated every day, for three, four, or five days, at the end of which time the sac will have become consolidated, and the opening in the cartilage nearly closed. The little remaining tumour or hardness soon disappears, never to



return in the same place from the same cause. If, on the incision being made through the cartilage and capsule, the tumour should be found of a fleshy or steatomatous nature, it can by pressure be made to protrude, when it may be raised with a hook, and cut off with a pair of scissors at its base. If the whole of the capsule should not be removed, the probe should be used as in the previous case for several subsequent days. If the tumour should be of the brainlike form first described, it will be easily squeezed out, and the sac will require scarcely any subsequent treatment.

These tumours seldom cause any pain in their formation, although they become inconvenient from their size, and occasion some deformity. When they are attached to the skin, and especially those of the melicerous or steatomatous character, they often give rise to inflammation and ulceration, when the cure is spontaneously effected by the discharge of the contents of the tumour and the suppuration which ensues. This effort of nature should be imitated in similar cases by making an opening into the tumour, and keeping up a slight suppuration by the use of the probe, or by a gentle application of any escharotic. If a slight fungus should spring up, which sometimes takes place, it ought to be touched with the *argentum nitratum*. In this manner I have removed perhaps five hundred tumours of the steatomatous and melicerous kind, as well as others of an anomalous nature, with complete success.

Whilst the last-described tumours affect for the most part the immediate vicinity of the tarsal cartilages of both lids, the atheromatous ones are usually situated at some distance from them, although more generally in the upper lid; they occur equally without pain, but feel rounder, more elastic, and deeper seated; they roll more readily under the finger, and seldom adhere to the skin so as to cause inflammation, unless of long standing, or when they have been irritated. If a small opening be made into one of these tumours, and pressure is applied, the contents are readily made to pass out



in the shape of a tape-worm, and resembling the *medullary* matter of the brain. It is, however, secreted very rapidly, not only by the whole sac, but even by a part of it, which renders the removal of the whole of it necessary to prevent a recurrence of the complaint. If the tumour be small, an incision should be made over it, extending beyond it each way, and the skin separated, so as to allow the tumour to rise on pressure. The sac, which is usually rather thick, should now be raised with a hook and carefully dissected out. If the tumour be large, an incision should be made directly into it, so as to allow the contents to escape; or if the operator should have fairly divided it, unconscious of its nature, the two sides of the sac may be laid hold of with the forceps and dissected out, which will be assisted by making pressure below the tumour, so as to press the inside of the sac upwards and outwards: if any portion of it should remain, it ought to be touched with the *argentum nitratum*, or other caustic, and the wound should not be allowed to close until every appearance of a further secretion from the sac has ceased.

The atheromatous tumours are sometimes found to contain hairs, as Beer and Sir Astley Cooper\* have already remarked, which, however, differ from those which are produced in other parts where they usually grow, by wanting both a bulbous root and a canal.

I have never thought it necessary to follow the advice of Beer, who recommends that these tumours should be moved about for several days previously to the operation, in order to lengthen their attachments; and although I have known erysipelas produced by removing encysted tumours from the scalp, I have never seen any inconvenience result beyond a slight swelling after their removal from the eyelids, unless they adhered to the periosteum of the orbit, but then they more properly belong to the class of tumours arising from the orbit.

\* Sir A. Cooper on Encysted Tumours, in Cooper and Travers's Essays, part ii, page 224.



When these tumours do not exceed the size of a filbert, and they are rarely half as large, no deformity beyond a slight scar ought to ensue; but if they have been treated by escharotics, which they never should be, then any kind of deformity, common to the eyelids, may readily take place. Demours\* recommends, in cases of encysted tumours, where persons will not submit to the knife, that a small drop of nitrous acid be applied to the surface of the tumour, by means of a straw or a fine point of hard wood, and repeated daily until it penetrates into the tumour, which is then to be emptied, and the acid applied to its internal surface, until suppuration is fully established, when it may be allowed to heal. If the tumour be small, no bad consequence will result from this practice; if it be large, it will be apt to cause some deformity, and it ought not to be adopted. When the sac of an atheromatous tumour has not been entirely removed, I have applied the acids with success; but I prefer, even for this purpose, the *argentum nitratum*, cut into a fine point. These observations do not refer to deep-seated tumours of the orbit.

---

#### ON THE ENCANTHIS.

This disease takes its name from its situation, and not from any peculiarity in its appearance, being derived from *εν*, and *καυθος*, the angle of the eye, and consists in an enlargement of the *caruncula lachrymalis*, implicating the *valvula semilunaris*, extending, when of an inveterate nature, along the edge of either eyelid, and advancing as far forward on the conjunctiva as the cornea. It is usually the consequence of neglected or ill-treated inflammation of the *caruncula lachrymalis*, is by no means of frequent occurrence in this country, in any form, and is very rarely seen to assume a scirrhus or cancerous character. I have never met with it in this state.

When inflammation attacks the *caruncula lachrymalis* alone,

\* Demours, *Maladies des Yeux*, tome i, page 127.



it in general takes place in consequence of direct injury to the part; such as a blow or cut, or from some sharp or solid substance being driven into, and remaining in it. When this last accident happens, the foreign body may almost always be perceived and easily removed, by which further inconvenience will be avoided. If this should have been neglected, or the inflammation have arisen from any other cause, the caruncle swells, becomes painful, of a darker red, the semilunar fold thickens and enlarges, so as to show its shape distinctly, whilst it approaches nearer to the cornea; the eye feels as if an extraneous substance were included between it and the lids, the motion of which augments the pain; the tears become hot and run over the cheek, instead of passing through the puncta lachrymalia and the lateral canals, which are pressed upon, if not implicated in the disease, whilst the enlargement of the caruncula and valvula semilunaris causes them to deviate from their natural direction. Towards the termination of the fourth or sixth day, suppuration takes place in the enlarged caruncle, a yellowish and more prominent spot is perceived, which either yields of itself or may be opened with the lancet, so as to allow the escape of the contents of the abscess, when the pain is relieved; but the increased secretion from the conjunctiva generally remains, of a viscid nature, and, with that from the Meibomian glands, often glues the eyelids to each other during the night. The inflammation is more or less general over the whole surface of the conjunctiva, and sometimes gives rise to pain in the eye, as well as over the orbit near the nose. If the inflammation should subside without the formation of an abscess, a slight defect in carrying off the tears alone remains for a short time, and gradually subsides. Should the inflammation have been more severe, it may degenerate into a chronic state, the valvula semilunaris as well as the caruncle become slightly enlarged, and the weeping of the tears continue. In general, this degree of inflammation does not give rise to a regular permanent enlargement, but to the formation of small fleshy excrescences, like warts,



which give to the part, when the eyelids are closed, a fringed-like appearance, the form of disease which is usually observed in this country, causing some deformity, whilst it is attended by a *stillicidium lachrymarum* and irritation at the corner of the eye.

When the inflammation has proceeded to suppuration, and the abscess has burst, a fungus sometimes springs from the surface of the sac, or from the ulcerated edges of the part, which assumes different characters. Under more favourable circumstances it heals in the usual manner, the enlarged caruncle gradually returns to its natural shape and size, and no inconvenience ensues. When the caruncle has suffered much from the formation of matter, it may become distorted in shape or diminished in size; in either of which cases the tears run over the cheeks, and cause an incurable disease called *Rhyas*, *rhæas*, from *ῥυαῖς*; a disorder Aëtius describes as a *naturalis carnis in angulo decrementum*, arising also from an incautious removal of the caruncle in any operations in the inner angle of the eye.

Sometimes the excrescence, instead of taking on the fringed-like form above described, assumes more of the solid appearance of a mulberry, and may attain a considerable size, when neglected. The ancients all notice an operation for this complaint, as if it were of more frequent occurrence in their days than in ours; and it is probably more common in southern than northern latitudes, for Scarpa gives a description of the advanced stages of the disease (which have certainly not been so often seen in England as to allow any one to describe them), as if he had often seen them. He says, "When the excrescence has acquired a considerable bulk, a part of it presents a granulated appearance, while the rest is smooth, and of a whitish or cineritious colour, streaked with varicose vessels, which occasionally advance so far upon the conjunctiva covering the eyeball on the side next the nose, as to reach the part where the cornea and sclerotica unite. When the excrescence has arrived at this advanced state, it



not only constantly involves the *caruncula lachrymalis* and semilunar fold, but the internal membrane of one or other of the eyelids, or of both: besides the attachment, therefore, which the encanthis has, in such cases, to the *caruncula lachrymalis*, semilunar fold, and conjunctiva of the eyeball, it is observed to give off a firm and projecting appendix or process along the internal surface of the upper or lower eyelid, in the direction of their edges; or the centre or body of the encanthis is, as it were, divided near the cornea, into two appendixes or processes, resembling a swallow's tail, one of which extends along the upper eyelid, covered by its margin; the other runs along the internal surface of the lower eyelid, concealed also by its margin, from the internal towards the external canthus of the eye."

"The body of the encanthis, or that middle portion of the excrescence, which extends from the *caruncula lachrymalis* and semilunar fold inclusively, upon the conjunctiva of the eyeball, almost as far as the junction of the cornea and sclerotic coat, is sometimes as prominent as a hazel or chesnut, at other times it is of this size but depressed, and as it were flattened. The central part of the excrescence, however, preserves the granulated appearance which it had at first, while one, or both appendixes, which are continued upon the internal surface of either or both eyelids, present, as I have said, rather the aspect of a lipomatose (fatty) than a granulated substance. If the eyelids are everted, these appendixes or processes of the encanthis make an elevated projection, and when this takes place in both eyelids, on their being everted, these appendixes form nearly a ring, which is closely applied upon the eyeball. This disease was known and successfully treated by Fabricius Hildanus\*, who has applied to it the term *ficus scirrhusus ad majorem oculi canthum*."

"The encanthis, as well as the pterygium, sometimes assumes a cancerous malignity, which is characterized by the dark red or leaden colour of the excrescence; its extraordi-

\* Hildanus, Centur. 1, Observat. 2.



nary hardness ; the lancinating pains, which accompany it, extending to the forehead, the whole of the eye, and the temples, especially after it has been even slightly touched ; by its disposition to bleed, and by its ulcerating in several points, from which a fungous substance is thrown out, discharging a thin and very acid humour. This worst species, or rather degeneration of the encanthis, admits only of a palliative treatment, unless the total extirpation of it should be attempted, together with all the parts contained in the cavity of the orbit ; the success of which must be very doubtful."

Beer\* reiterates and confirms this statement of Scarpa, with the addition, that the neighbouring bones soon become implicated in the disease ; and Gleize† says he has seen several such cases prove fatal.

The treatment of simple inflammation of the caruncula lachrymalis must depend upon the nature of its more obvious cause ; and as it most frequently arises from the presence of an irritating substance, the part itself, as well as the inside of the eyelid, should be carefully examined, and every extraneous substance removed. Dr. Monteath says he has seen it originate twice from a loose eyelash sticking in the superior punctum lachrymale and irritating the caruncle. When no immediate exciting cause can be discovered, several leeches should be applied in the neighbourhood of the part, and one should certainly be placed on the inside of the lower lid, close to the inflamed caruncle, the bleeding from which should be encouraged by repeated fomentations with warm water ; and I would advise a repetition of the leeches until it is evident, that the progress of the inflammation towards suppuration cannot be prevented, when a light poultice of bread and water should be had recourse to until the abscess is duly formed. I do not coincide in the opinions of foreign writers, who recommend cold water and cold applications, generally, instead of the more

\* Beer, *Lehre von den Augenkrankheiten*, band 2, page 188.

† Gleize, *Nouvelles Observations pratiques sur les Maladies de l'Œil*, page 291.



active practice I have advised ; and which may perhaps be one cause of the great frequency of the disease abroad, compared with its occurrence in England. When suppuration has unfortunately taken place, the treatment should still be, in the first instance, of the mildest nature, followed up by slight astringents ; but if these should not be found sufficient to prevent the appearance of the fringed-like or fungous growth alluded to, recourse must be had to the infusum sabinæ, the sulphas cupri, and the argentum nitratum. The Germans recommend that they should be sprinkled with a powder composed of sacchar. alb. 3ij, aluminis usti gr. xv, zinci sulph. gr. iv ; but in this I place little comparative confidence.

When the fringed-like excrescences, or the more solid mulberry growths, are not the sequelæ of abscess, but the products of inflammation, which has not attained to suppuration, they should be at once cut off with the scissors, and the parts from whence they sprung touched a day or two after with the sulphate of copper, by which treatment I have never failed to effect a cure, taking care, however, to continue the latter part of the treatment until every vestige of the disease was removed ; which should also be done in every case, whatever course the complaint may have taken.

When the encanthis is not of an inflammatory nature, and the excrescence is of a large size, it has been recommended to remove it by a ligature placed around its base. Purmannus relates an instance, in his *Chirurgia Curiosa*, of a tumour of this nature of the size of the fist, which he removed by ligature, and afterwards destroyed its root by caustic ; but this practice should not be imitated, being likely in many cases to bring on irritation, which might have a dangerous tendency ; for there cannot be tumour at this part, which ought to be meddled with, which may not be much more effectually removed with the knife ; and although Pellier\* met with one case out of several which was followed by a dangerous hæmorrhage,

\* Pellier, *Recueil d'Observations sur les Maladies de l'Œil*, Part ii, Observation 118.



I doubt very much whether this would have proved so to a surgeon of the present day.

When an encanthis of this description is to be removed, the eyelids should be fully separated, and the head firmly secured by proper assistants; the tumour should then be raised by the forceps and cut off with the scissors, great care being taken to leave the caruncle itself uninjured, or at most to take away as little as possible of its substance, in order to avoid the *stillicidium lachrymarum*, which inevitably follows its destruction or removal. The eye should be carefully washed clean, and a compress wetted with cold water applied over it by means of a bandage sufficiently tight to keep it in its place. The subsequent part of the cure should be managed as before directed.

When the encanthis is very large and inveterate, with one or two appendixes extending along the inside of the upper or under eyelid, Scarpa advises the following method of proceeding, which appears to me deserving of imitation. "The patient should be placed in a chair, and the upper eyelid everted by an assistant, so that one of the processes of the encanthis may project outwards. This being deeply divided in the direction of the edge of the eyelid, by means of a small bistoury, and then taken hold of and drawn out by the forceps, should be entirely separated from the internal surface of the upper eyelid longitudinally, proceeding from the external towards the internal angle of the eye, as far as the body or middle portion of the encanthis. The lipomatose process, situated upon the internal surface of the lower eyelid, should be separated in the same manner. The body of the encanthis should be afterwards elevated by means of the forceps, or, if this is not practicable, by a double hook, and then, partly by means of the curved scissors, completely detached from the subjacent conjunctiva which covers the eyeball, from the semilunar fold and *caruncula lachrymalis*, penetrating more or less deeply into the substance of the latter, as the firmness and depth of the roots of the disease may render it necessary; for it must be openly avowed, that in the treatment of the inveterate and



very large encanthis, which is deeply rooted in the caruncle, it is not always in the surgeon's power to avoid the substance of that part so carefully, that when the wound is healed some defect may not remain from the weeping of the eye."

The continental writers are disposed to consider that syphilis has a tendency to induce encanthis to assume a cancerous character; but as there is no deficiency of the one, whilst the other is happily a rare disease in this country, either in its benign or malignant form, there is reason to believe that those inferences as to the syphilitic virus are as badly founded in this complaint as in most others to which the same train of reasoning is applied.

---

### ON THE PTERYGIUM.

This word, derived from πτερυξ, a wing, is used to designate a disease of the conjunctiva, consisting in an alteration of a portion of that membrane, of a triangular or pyramidal shape, the apex of which is turned towards or is implanted on the cornea, whilst the base originates at the circumference of the eye, or more properly at the reflection of the conjunctiva from the lids to the eyeball. This disease most frequently occurs at the inner canthus, is less common at the external one, and is seldom observed to take place in the superior or inferior parts of the conjunctiva covering the ball of the eye. In some very rare cases, they have been observed to arise from these four cardinal points at once, and occasionally one or more have been seen in both eyes at the same time. The appearance of the pterygium varies. When it resembles a thin veil, is of a greyish colour, and semitransparent, having a few vessels running in straight lines upon it, it is called a membranous pterygium, or pterygium tenue, or ungula. When it is thicker, opaque, more shining, raised in appearance above the surrounding conjunctiva, supplied by more blood-vessels, and of a redder colour, it is termed pterygium crassum. The pyramidal form of the diseased part of the membrane is dis-



tinctly marked on every side, the apex advancing gradually from the circumference of the eye to the centre of the cornea, beyond which it seems incapable of proceeding, no one having hitherto been known to pass over to the opposite side, although the points of two opposing pterygia have frequently met at that point, and, for a time, entirely obstructed vision. These pterygia seem to be so totally dependent on an alteration of the conjunctiva alone, rather than on a conjoint one of it and of the sclerotica or cornea, that even a greater laxity of union takes place between the conjunctiva and sclerotica in its course over the latter, so that the whole of it may be readily grasped by the forceps, and raised from either the sclerotica or cornea without inconvenience to the patient. When the apex of the pterygium has extended over the cornea, it is separated from that part, is raised above its natural level, and scarcely adheres to it but at its junction with the healthy conjunctiva. This mobility of the pterygium on the sclerotica is a diagnostic mark of the disease, distinguishing it from all excrescences of these parts which may in some measure resemble it; and when opportunities of examining its nature have offered, by dissection after death, they have confirmed the preceding observations. When the patient turns the eye towards the part from whence the disease originates, the part it occupies seems to fall into slight folds, and may then be more easily raised by the forceps. When the eye is rolled in the opposite direction, the pterygium is rendered more tense, seems to be put on the stretch, and some of the membranous bands composing it become more shining and distinct. A pterygium forms without pain, and rarely gives rise to it; many persons have been for years unconscious of its existence, until at last its infringement on the cornea has caused some indistinctness of vision; for which, or the slight deformity it occasions, surgical assistance is at last required. When the disease takes place in its most usual situation, at the inner angle, it would seem to arise from the semilunar fold, and sometimes even from the caruncula lachrymalis; but a closer



examination will show, that the parts are only connected with it by contiguity of situation, not by continuity of disease. The progress of this complaint, from its commencement to its termination at the centre of the cornea, is often very slow, sometimes from one to ten years; and occasionally, after having advanced to any given point, more especially the edge of the cornea, it subsequently remains stationary. Its progress in general is slowest after it reaches the cornea, and it scarcely interferes with vision until it has advanced over it to about half a line from the edge of the pupil, when moderately dilated. When the pterygium is thin it usually retains a membranous character; when thicker, it becomes fleshy, or even seems to contain a substance resembling fat; and, in some cases of long standing, it has been described as assuming a coriaceous appearance, or even resembling parchment or cartilage; but none of the latter species have ever fallen under my observation.

This disease may appear at any age; it has been seen in young children immediately after birth; it is, however, most common about the middle and latter periods of life.

The peculiarity of manner in which a pterygium proceeds to its complete formation has attracted much attention. Scarpa has ventured to give the following solution of this difficulty, which, although it may appear sufficiently plausible, is yet so unsatisfactory, that the problem is still open for the exercise of further ingenuity.

He says\*, "It is worthy of observation, that whether the pterygium be great or small, and in whatever part of the circumference of the eyeball it is formed, it constantly retains its triangular figure; its base being situated upon the white of the eye, and its apex upon the cornea. The constancy of this fact ought to be referred, in my opinion, to the adhesion of the lamina of the conjunctiva becoming stronger, in proportion as it advances from the circumference towards the centre of the cornea. For, in consequence of such structure

\* Scarpa, by Briggs, page 236, second edition, 1818.



and different degree of cohesion which actually exists in the sound eye, it must necessarily follow, in the first place, that the progress of the pterygium ought to be, in every case of such disease, much slower upon the cornea than upon the white of the eye: secondly, that from the greater resistance which it always meets with, in proportion as it extends towards the centre of the cornea, it must, from mechanical necessity, assume a triangular form, the base of which corresponds to the white of the eye, the apex to the centre of the cornea."

Forestus\* has particularly remarked the constancy of this phenomenon; and, speaking of the pterygium, he adds, "*Non co-operit oculum nisi in forma sagittæ.*"

This method of accounting for the peculiar formation of a pterygium seems to me, however, to be very much at variance with the idea he entertains of the cause of its occurrence, and which he attributes to the continuance of chronic inflammation. He says, "The chronic varicose ophthalmia, with relaxation and thickening of the conjunctiva, the nebula of the cornea, and the pterygium, differ from each other only inasmuch as they are greater or less degrees of the same disease: for all the three consist in a varicose, relaxed, and atonic state of a certain portion of the conjunctiva. In the chronic varicose ophthalmia, the preternatural fulness and nodosity of the veins, as well as the flaccidity and thickening of the conjunctiva, are confined to the white of the eye. In the nebula, particular branches of varicose veins are continued in a dilated and knotty state, to a certain extent, upon the fine lamina of the conjunctiva, which covers the external surface of the cornea; and in the pterygium, in addition to this varicose state of the vessels, there is a preternatural thickening of the thin lamina of the conjunctiva covering it, upon which the small varicose veins are situated. Hence it is that the pterygium appears at first to be a new membrane formed upon the cornea, whereas it is nothing more than the fine lamen of the conjunctiva, forming its natural external covering, which, in

\* Forestus, *Opera Medica*, lib. ii, observ. 6.



consequence of the chronic ophthalmia, has degenerated from a transparent into a thick and opaque tunic, interwoven with varicose vessels. In cases of pterygium, therefore, the disease is not a new production formed upon the eye, but an alteration of some one of the fine and transparent membranes which cover it; and a convincing proof of it, as will be afterwards shown, is, that the incipient pterygium may be cured in the same manner as the nebula of the cornea; that is, not by detaching it from the surface of the cornea, but merely by extirpating it at the part where the cornea and sclerotica unite, in the manner employed for destroying the communication between the minute ramifications of the varicose veins of the conjunctiva and their trunks, from the former of which the nebula is produced and nourished."

From very great experience in the treatment of chronic inflammation, as well as from the observation of several of my friends, who have examined the pensioners discharged from the army in consequence of diseases of the eye, I feel myself entitled to doubt the correctness of this opinion, and to affirm on the contrary, that a true pterygium is very rarely the consequence of chronic inflammation, whilst an essential difference exists between those *nebulæ* of the cornea which simulate the appearance of pterygium, and the true disease itself. In certain individuals, for the most part of a phlegmatic habit, several varicose vessels frequently remain after the chronic inflammation has almost entirely subsided: these run from the circumference of the eye to the cornea, upon which they can be clearly discerned ramifying in a diseased conjunctiva, not, however, in the well-defined triangular form of a pterygium, but in an irregular shape, the cornea on which they are placed, as well in the immediate vicinity, if not to a greater extent, showing evident signs of derangement, in its alteration of colour and transparency; whilst, in the pterygium, the cornea, that is not covered by it, is totally free from disease. When these varicose vessels have given rise to a nebula, or thickening of the conjunctiva of the cornea, it is always irregular,



never of the spear-formed shape of the pterygium, and is sufficiently distinct in appearance to excite a doubt on a cursory inspection as to their identity. In these cases the progress of the disease, from the commencement of that stage which in any way resembles pterygium, is in an inverse direction, *viz.* from, rather than towards the cornea. I have now under my care a case of this description, which has deceived the younger students of the Infirmary. The opacity of the conjunctiva of the cornea is of an irregular semicircular form, without a pointed termination, and scarcely admitting of being elevated from the cornea; the vessels supplying it pass from the inner angle, and the conjunctiva in which they run has assumed a shining fibrous appearance, very much resembling that observed in pterygium. The width of the origin and termination is nearly equal. It resembles the thin pterygium in its external characters, but differs from it in the deficiency of width at its origin or base, and the irregularity and size of its termination. It began also on the cornea, and then became more evident in the conjunctiva, and is a result of chronic inflammation; whilst a true pterygium forms insensibly without any preceding disease.

The cure of the well-formed pterygium should always be accomplished by its removal. The pterygium tenue may be sometimes cured, when the patient is very much afraid of an operation, by slight scarifications and stimulants. The scarifications ought to be made by raising the pterygium with the forceps, and cutting across it in two or three places. After the second day, the *solutio argenti nitratis*, or the *vinum opii*, or a solution of the *carbonas potassæ* in distilled water, in the proportion of twenty grains to an ounce, or other remedies used for the removal of leucomatous affections of the cornea, may be resorted to; but the cure by these means occupies a great deal of time, is often not complete, and the patient frequently is obliged to submit to the operation after a delay of several months to no purpose.

The cure by operation consists in the removal of the diseased part, and is perfect, as far as relates to the termination



of the disease; but a slight defect remains on that part of the cornea where the apex of the pterygium was situated. This arises from the cicatrix which takes place where the conjunctiva was removed, and which is in fact an indelible mark or nebula, although much less than the extent of surface exposed by the operation; so that if the pterygium extended to the distance of two lines on the cornea, the mark caused by the healing of the part would not exceed one line in length. In the same manner a cicatrix is generally observable on the white of the eye, but this very much depends on the manner of operating. When the pterygium arises by a broad basis from the inner angle of the eye, and the whole of it is removed, a ridge or small band very generally forms during the process of cicatrization in the central line of the exposed surface, from the inner angle to the edge of the cornea, which, by communicating with the semilunar fold of the conjunctiva or *caruncula lachrymalis*, impedes the lateral motions of the eye, and also attracts the attention of the bystander. In order to avoid this inconvenience, Scarpa proposed, "in the treatment of pterygia, which have a very extensive base upon the white of the eye, to divide them from the apex only as far as the part where the cornea and sclerotica unite, and then to separate them at their base by a semicircular incision, including about a line in breadth of the substance of the conjunctiva, in a direction concentric to the margin of the cornea." He directs this to be done by raising the pterygium in a fold with the forceps, then separating it at the apex from the cornea with the scissors, and turning it back towards the base the distance indicated, *viz.* one line from the cornea, when it should be cut off by another stroke of the scissors.

Beer recommends that the pterygium should be raised near its basis by the forceps, and cut through at that part by a sharp knife passed underneath it. The upper and under edges are to be cut towards the apex with a pair of curved scissors; it is then to be carefully separated from the cornea, so that no portion of it may remain. He says he has cured, in the course



of thirty-two years, three hundred and seventy-six pterygia, for the most part by this operation, and therefore justly considers it to be a mere local disease. The objection which Scarpa makes to the removal of the whole of a pterygium, when the base is extensive, I have found valid in practice, although Beer does not seem to have bestowed upon it the attention it deserved. I have, therefore, of late years taken what I conceive to be a middle course between the two, removing half of the pterygium from the apex towards the base, which I have never found to fail; for, although some appearance of disease continued for a time where the portion which was left remained, this gradually subsided, or entirely disappeared, and never gave rise to a re-formation of the disease.

The operation should be performed in the following manner: —

The patient being seated lower than the operator, ought to rest his head against the breast of an assistant, who elevates the upper eyelid, and fixes the eye with the fore and middle fingers of one hand, whilst he depresses the lower eyelid with the other. The surgeon should then desire the patient to turn the eye outwards, if the pterygium arise from the inner canthus; and, whilst it is thus on the stretch, take the opportunity of grasping it between the points of the forceps, about two lines from the cornea, and then raise it from the sclerotica, until he has room to pass an iris, or spear-pointed cataract knife, underneath it and to the inside of the forceps, when it is to be cut through from within outwards. The extremity of the pterygium being still held by the forceps, will allow the operator to cut it off close to the cornea, with the same knife or by the curved scissors, which will be more easily effected and more completely done. If any portion of the edge of the pterygium should have been left after this operation, it must be removed by the scissors, or it will keep up for several days the subsequent suppuration, and the eye should be washed with warm water until the bleeding ceases, when a compress and-bandage should be applied, so as to keep the eyelids



closed, but not to press on the eye. The eyelids should be carefully washed clean night and morning, or oftener if it be found agreeable to do so; but the eye should be opened to examine the wound, only so far as will show that the conjunctiva is not highly inflamed, or that chemosis has not taken place. On the fifth day the eye should be examined, when the divided surface of the sclerotica will be found covered with a yellow-coloured deposit resembling mucus, whilst the surrounding edge of the conjunctiva is irregular, red, and inflamed. This gradually diminishes, the wound contracts, and a new membrane is formed on the part, which, after a time, becomes less opaque, and assumes more and more the natural appearance of the conjunctiva. This process of cicatrization, which goes on from two to three weeks, requires no assistance from art, and should not be interfered with by any application, unless it appears that some irregularity or elevation is about to take place, when this spot should be lightly touched with the sulphate of copper or the argenti nitratum. When the fungous elevation has been small and well defined, I have removed it with advantage by a snip of the scissors. When the cicatrization is nearly completed, mild stimulants should be dropped into the eye, to remove the chronic inflammation which may remain, and to assist in the absorption of the base of the pterygium, which is almost entirely effected, so as in time to be scarcely, if at all observable.

In the case alluded to above, of *nebulæ* simulating the appearance of incipient pterygium, I contented myself with dividing the part, close to the junction of the cornea with the sclerotica, by raising it with the forceps and cutting it across with the round-pointed scalpel. This will in general be sufficient to put a stop to its progress, and the nebula gradually diminishes; a slight opacity only remaining where it was situated on the cornea. If the divided part should reunite too soon, a small piece must be cut with a pair of scissors, which will always be effectual in removing it.

The true pterygium very rarely assumes a malignant cha-



racter; if, however, it should do so, either from accidental circumstances or improper treatment, it will retain, of all its external characters, only its triangular form; the termination of its sides in the surrounding conjunctiva will not be so well defined; red vessels will be observed passing from a distance into it; its colour will have changed to a darker red; it will be found to adhere firmly to the cornea and sclerotica beneath, so as not to be raised from them as in the true benign pterygium; it bleeds on being slightly touched, and is always attended by pain, sometimes of a lancinating nature, which shoots through the eye deep into the head, and indicates the presence of a cancerous disease, which can only be cut short by the removal of this part of the eye, as in the operation for staphyloma, accompanied by a varicose state of the vessels of the anterior part of the eyeball. This method of cure must also be adopted in excrescences of a similar nature, whether they assume the form of a pterygium or not: if the disease be farther advanced, the whole of the contents of the orbit will require to be removed.

Sometimes a small deposition of matter takes place near the edge of the cornea, giving rise to an appearance somewhat resembling a pterygium, differing a little in regard to the formation of the apex and the extent of base, and supplied with blood from the sclerotica rather than the conjunctiva, which is readily perceived from the vascular appearance of it immediately surrounding the part. At an early period they are moveable, and I have always then removed them with success. The hæmorrhage is greater than in a common pterygium, evidently from the sclerotic coat, and it should be encouraged by the aid of warm water. The subsequent treatment was conducted in the usual manner; the cicatrix always remained, however, of a dark colour; and if the disease had been allowed to go on, I have little doubt but it would have become of a dangerous or even malignant character.

Small oval substances, of a dirty yellowish colour, and resembling fat in appearance, are occasionally formed near the



edge of the cornea in persons somewhat advanced in life; they do not often grow to a large size, and are removed only on account of the unsightliness of their appearance. They remain indeed for the most part stationary, after having attained the size of the half of a grain of barley, and seldom encroach on the cornea so as to affect vision. They should never be meddled with but when they can be completely removed by the forceps and scissors.

Fleshy and even cartilaginous tumours have been known to form in the cellular texture beneath the conjunctiva; and, in some very rare cases, from the surface of the conjunctiva itself. These should be removed as early as possible, and the cure conducted in the most simple manner. If the part shows no tendency to heal, the surface may be gently excited into action by slight touches of the *argentum nitratum*.

Beer\* has described an affection of the conjunctiva which I have never seen, or at least have known it only as a small tumour, not uncommon to the eyelids generally. He calls it papula of the conjunctiva, occurring in the shape of a small, pale red, hard, and itching tumour, of the size of a pin's head, on the lower lid, near the semilunar fold or membrane; if rubbed or irritated, it acquires the size of a pea in the course of three days, and may, by improper treatment, such as the application of escharotics in cachectic persons, become carcinomatous. He says he has seen it only in chlorotic young women, and that on the return of the menses it subsides and disappears. The proper treatment is to raise it with a hook, and to cut it out with a knife or scissors, as may be most convenient.

I have removed, in three instances, a small fleshy tumour, from which several hairs grew, from the conjunctiva at the outer angle of the eye, without leaving any deformity, and without trouble. In both they were congenital, and were productive of the same uneasiness as an ectropium.

\* Beer, *Lehre von den Augenkrankheiten*, band 2, s. 675.



ON THE REMOVAL OF EXTRANEOUS SUBSTANCES  
FROM THE EYE, AND ON INJURIES OF THE EYE-  
BALL.

ALTHOUGH the eye is well protected by the eyelids and the cilia against the entrance of any extraneous substances, which are propelled towards it with a moderate degree of force, they offer a very insufficient defence against those which proceed with greater velocity; and foreign bodies are therefore frequently found between the eyelids, adhering to their inner surface, and causing great irritation as well as injury to the eyeball. The entrance of any extraneous matter is immediately perceived, not only by direct sensation, but in consequence of the motion of the lids, which, by passing over the part affected, increases the pain; and, if the foreign body be small and moveable, generally removes it from the surface of the eye, whilst, by its adhesion to the inside of the lid, it becomes a more constant source of irritation. The situation of the offending substance has great influence on the symptoms which follow. When the extraneous body is lodged in that part of the conjunctiva which lines the tarsal cartilage, it is rubbed against the cornea by every motion of the lid, the sensation is acute, and the general inflammation of the conjunctiva, and, in succession, of the cornea, is certain, unless the cause be removed. The symptoms attendant on this state come on much more rapidly and severely when the upper eyelid is affected, in consequence of its greater latitude of motion; but if the offending cause should have lodged in the conjunctiva, nearer the part where it is reflected over the ball of the eye, and especially in the upper lid, then, as it scarcely comes in contact with the globe of the eye on the movement of the lid, the irritation which ensues is merely that which arises from the local injury inflicted on the particular portion of the conjunctiva affected by it; the symptoms are those of low inflammation, which degenerate into a chronic state, and give rise to fungous excrescences from the conjunctiva,



frequently including in their growth the extraneous matter, and thus concealing the cause of the derangement.

When a solid substance sticks in the cornea, or the anterior and most prominent part of the sclerotica, over which the tarsal cartilage passes in winking, more severe symptoms ensue; but if the foreign body should stick in the sclerotica, at a part which is not pressed upon by the tarsal cartilage in winking, the symptoms are frequently so slight as only to cause an inconvenience scarcely amounting to pain. I lately removed a small piece of the husk of a grass seed from the sclerótica at the upper edge of the cornea, in the eye of a young medical student, which had been lodged there for sixteen months. It had merely given rise to a little occasional irritation, which was augmented on his taking cold; and three or four red vessels running from the spot were then increased in size. It had caused a small depression, in which it was lodged, but whence it was easily removed, and all inconvenience immediately subsided. A knowledge of the comparative impunity with which such substances may be retained in the folds of the conjunctiva, especially of the upper lid, will cause a closer investigation to be made of this membrane, when the origin of the chronic inflammation, for which relief is desired, is attributed to an injury or accident of this nature; and if any fungous excrescence is perceived, it should be removed to its base by the scissors, in order that no extraneous matter may be concealed within it; for the records of surgery afford numerous examples of this fact, and several cases have occurred to and have been happily cured by myself; the cure, indeed, after the removal of the exciting cause, being accomplished in almost every instance by the unassisted efforts of nature.

Whenever the admission of any irritating matters between the eyelids is suspected, they should be carefully examined; the lower one offers no difficulty, the upper lid should be everted in the following manner. The patient should be



placed on a chair, lower than the surgeon; who, taking hold of four or five of the cilia in the centre and close to the edge of the eyelid, gently draws them downwards and outwards from the ball of the eye. A probe, or other small round or blunt instrument, is then to be placed horizontally across the lid, immediately above the upper edge of the tarsal cartilage, when by raising the cilia, which have been already grasped by the fore-finger and thumb, the eyelid may be turned out over the probe; the offending matters will be in general found adhering to the everted surface. If the patient be desired to look downwards with the other eye, the whole of the conjunctiva may be readily examined\*.

When a small fly, or any substance which is not sufficiently pointed to stick into or fast to the conjunctiva, gets between the lids, there is an action set up in the orbicularis muscle for its removal, which, together with the flow of tears, will frequently be successful, provided the person will remain perfectly quiet, and not strain the eye; at the end of a few minutes it will be found at the edge of the lid, and may be readily removed by a bystander.

If the substances propelled be solid, and driven with great violence, they may penetrate the conjunctiva, and stick in or pass through the cornea or sclerotica. If the impelling force be sufficient to cause them to adhere to the part against which they impinge, they will in general be found imbedded in it; and when the cornea suffers, which is usually the case, the little extraneous body will often be observed to be so far below the surface, as to be out of the way of friction from the passage of the eyelid over it; the inflammation which ensues is then from the irritation of the cornea in particular, and not from the conjunctiva generally. If no assistance be obtained,

\* When surgical aid is not at hand, I have seen ladies in the country slightly raise the eyelid in the same way, and introduce the tip of the tongue underneath it, by which a foreign body may be often brought out. The sensation is peculiar, but not unpleasant.



the results of such a trivial accident may be fatal to the eye, and in the most favourable cases suppuration must ensue, when the extraneous matter is washed away with the discharge by the tears; sometimes, a layer of new-formed matter is deposited from the cornea upon it, and by being enclosed, it becomes ultimately harmless, although giving rise to some deformity.

There is never any difficulty in discovering a foreign body implanted in the cornea, and it ought always to be removed, in the following manner, as soon as perceived. The operator, standing behind the patient, supports his head against his own breast while he elevates the eyelid, and maintains it against the edge of the orbit, with the fore and middle fingers of the left hand, fixing the eyeball with the extremities of them at the same time. If the eye be very unsteady, an assistant should depress the lower lid, and fix the eye in the same manner from below, if the operator is not capable of doing it himself. Having selected a sharp firm cataract needle, he should first touch the cornea with the side of it, to accustom the patient to the sensation it produces, and then introducing the point below the foreign body, raise it from its situation, and remove it from the eye. This proceeding will frequently require repetition before it succeeds, and in some instances it has very much the appearance of digging the extraneous substance out of the cornea, in consequence of the tenacity with which it adheres. It is a very common accident with smiths, but seldom gives rise to inconvenience, as I have rarely seen a patient twice after the bit of iron was removed, although it had actually required to be dug out of the cornea. A slight opacity is generally observable afterwards in a certain light; but I have not always been able to discover it, unless the speck of iron had remained imbedded in the cornea for several days, and ulceration had commenced. When this is the case, the eye will be very irritable, the patient can scarcely bear to have it examined, and the eyelids seem



to close spasmodically: this is best relieved by the removal of the cause, and it is a waste of time to have recourse to poultices or narcotics, as some foreign authors have recommended.

There is a case at the Infirmary in which a small piece of iron has been driven through the centre of the cornea, and is seen sticking in the lens, which is opaque. In another instance, three different grains of gunpowder pierced the cornea, and were implanted in the iris; but in neither would it be advisable to interfere. If the offending body should, however, be larger, and likely to excite more active inflammation by its presence, it should be removed by an incision in the cornea; this I have twice been under the necessity of doing with perfect success, and it is not attended by any difficulty, for the aqueous humour does not escape through the opening, which has already been made in the cornea, unless it be of such a size as to render another unnecessary.

I have three children now under my care, each of whom run a fork through the cornea and iris into the lens, which became of course opaque. By bleeding and strict antiphlogistic means, and an early use of the belladonna, I have preserved a good pupil in two of them, and the lens has been absorbed to an extent that enables them to see objects distinctly. In the third case the injury to the cornea being greater, the aqueous humour drained away, the iris adhered to the edges of the wound, the pupil closed, and as an operation would not give the child useful vision, I have refrained from attempting it.

Wounds of the cornea made by sharp cutting instruments, and of small extent, unite without difficulty, and leave no mark. If the wound be of larger dimensions, it heals with a little elevation or irregularity, and a trifling scar remains. If union should not take place, and the parts be kept in apposition, the opening in the cornea being small, and near the sclerotica, the elasticity of the cornea will prevent the escape of the aqueous humour, whilst the cornea seems nearly insensible of the injury, unless pressure be made, when the aqueous



humour escapes. But if the wound be more extensive, as in the extraction of the cataract, and union does not take place, the slower process of suppuration naturally ensues; the aqueous humour drains away between its edges, the cornea remains flattened, and becomes opaque for some distance from the incision; the cut edges thicken, a yellowish lymph seems to be deposited upon and between them, adhering and hanging down in flakes, through which the aqueous humour percolates, until, by the advancement of the process of cicatrization, the edges of the wound are brought into contact, unite, and render the passage impervious. The cornea then assumes more of its natural form, the opacity is in part removed, and the scar marking the cut or ulcerated surfaces alone remains. If the iris should have fallen forwards, and have passed into the wound, from the draining of the aqueous humour through it, the consequences may be fatal to the eye from general inflammation. If it should already adhere to the edges of the wound and not protrude, interference would be improper: an irregularity of the pupil will be the result. Should the iris protrude through an accidental opening of this kind, I recommend that it be cut off with a pair of scissors, and that the *argentum nitratum* be immediately applied, under which the cure will be rapidly effected. I have had many cases of this nature under my care at the Infirmary, in which the happy effects of this method of proceeding have been fully illustrated.

When this proceeding is not adopted, much time is lost, great pain endured, and more deformity ensues; for the cornea at last throws a layer over the protruded iris, which, uniting with it, leaves a larger and more indelible cicatrix.

When the injury of the cornea and iris is attended by a displacement of the lens, so that it protrudes into the pupil, or has passed into the anterior chamber, it should be extracted by making an opening into the cornea of sufficient extent to allow of its being seized and drawn through it by a hook. This practice is imperiously necessary in persons advanced in



life, on account of the hardness of the lens, whilst in children it may be dispensed with when evidently soft, and in the anterior chamber. The consequence of its remaining and distending the pupil, when hard, will be general inflammation and suppuration of the eyeball.

When the iris has merely protruded, without being injured, through an opening in the cornea, which is not attended by any loss of substance, it may be made to retire, shortly after the receipt of the injury, by closing the eyelids and rubbing the eye gently, and then suddenly allowing a bright light to fall upon it. If this should not be sufficient, a small flat probe ought to be introduced under the cornea, when any aqueous humour which fills the protruded part of the iris, and causes it to resemble a bag, will drain off, and allow the iris to recede. If a portion of the iris, retina, or any other of the internal structures of the eye, should hang out of the external wound, it must be removed with the scissors, so as to offer as little obstacle as possible to its cicatrization. When extravasation takes place in the eye, whether it be accompanied by a wound or not, the under part of the cornea should be opened to allow of its evacuation; and although the eye will seldom be saved, yet much suffering may be avoided by decided measures, and among them the prevention of inflammation must be considered as the most important.

A blow on the eye will frequently give rise to an extravasation of blood beneath the conjunctiva, which will be absorbed, if in moderate quantity, under the use of cold and weak spirituous lotions, preceded by general and local blood-letting, as the urgency of the case may require; but if the blood thrown out should distend the conjunctiva considerably, an incision ought to be made into it, to allow of its removal. If the conjunctiva should have been torn, and left in a lacerated and ragged state, these parts may be removed with advantage by the scissors.

Blows on the eye, inflicted with pointed although blunt instruments, such as a foil or a small stick, often give rise to



a separation of the iris from the ciliary ligament, in consequence of which two openings are found capable of transmitting light to the retina ; but the natural one, or the pupil, generally closes from the inflammation which ensues from the injury, whilst that part of the iris which is detached from its ciliary connection remains stationary : a peculiarity occurring only when the separation is effected by a blow ; for when it is accomplished by a surgical instrument it is seldom permanent, the iris gradually returning to its natural situation ; to prevent which, it is necessary to cut off a portion of it, and therefore to perform the operation through the cornea. I have seen one case in which the separation of the iris from its ciliary attachment seemed to be spontaneous and permanent ; the patient declaring he never suffered either an injury or an operation. Amaurosis is, however, the consequence most to be dreaded in these cases, accompanied by severe and sometimes excruciating pain in the course of the branches of the supra-orbitary nerve, over which depletion and evacnants have no influence. If severe vomiting should occur immediately after the receipt of the injury, it will be best relieved by moderately large doses of calomel and opium, remedies which are often found to allay nervous irritation in a pre-eminent manner, when united, without altogether depriving each of its peculiar efficacy by the combination.

Accidental injuries from small shot striking the eye, when parties are out shooting, are of frequent occurrence, and are often followed by amaurosis, even if the structure of the eye should be apparently uninjured. When the shot does not penetrate the sclerotica, this effect must be produced by concussion, if the loss of sight be immediate. In some cases, the patient may recover in the course of a few hours, but restoration seldom occurs if it be protracted beyond this period, and no amendment takes place. The prognosis will be favourable, after an accident of this nature, in proportion as vision is uninjured, and the motions of the iris are unaffected. If the shot penetrates the sclerotica, suppuration of the eye-



ball will in all probability occur ; I have, however, seen a small musket-ball lodged in the back part of the eye without such a consequence ensuing. If the shot should stick in the sclerotica or cornea, or be seen in any situation from which it can be readily removed, it ought to be done as quickly as possible.

The observations I have already made, page 113, on injuries of the ciliary nerves, apply here, in an equally forcible manner ; and if reference be made to the consultations of Demours, in his second volume, it will be found, that in nearly all the cases referred to by him, in which the injury to the eye had been caused by a small shot impinging against it, the functions of the iris were impaired, being confirmative of my opinion, that no reliance can be placed on a dilated state of the pupil, as an indication of primary affection of the supra-orbitary nerve.

In all these accidents the surgeon should never forget, that his first object is to prevent inflammation from passing beyond those bounds which are essential to the restoration of the part to its natural state ; if this cannot be accomplished by the most active means, which should be invariably employed from the moment of the injury, they must be continued in order to relieve pain, and prevent, if possible, a further extension of disease ; and although the patient should be debilitated by them, recourse must yet be had to general and local bleeding, the use of mercury and of counter-irritants, if the other eye should be attacked by internal sympathetic inflammation.

Injuries are often committed on the eyeball by substances which act chemically ; such as quick lime, escharotics in general, the mineral acids, melted lead, boiling water, &c. which not only produce inflammation, but frequently destroy the texture of the part to which they are immediately applied. When the injurious matter is conveyed in a solid form, yet capable of being dissolved by the tears, the removal of it is a point of great importance ; and this should be accomplished, as in the case of a piece of caustic getting into the eye, by



forcibly opening it, or by everting the lid, and removing it with the point of any instrument which may be at hand. When the extraneous body is in the form of powder, or in very small pieces, it cannot be effected in this manner, and it becomes desirable to float the extraneous substances from between the lids by the sudden application of a fluid, which in the case of quick lime ought to be oil, and not water, as the solution and decomposition of the lime by the water would do considerable mischief. I have never seen a patient sufficiently early after the accident to render him this service, either with oil or water, and I suspect the theory of the application of the oil to be the best part of it. I should not hesitate, when oil was not at hand, to open both eyelids forcibly, and cause a strong stream of water to pass between them, so as to carry away the lime without giving it time to do mischief; the eyelids should afterwards be everted, and the same operation continued until every particle of lime or mortar be removed. If the lime has rested long enough on the part to which it was applied, it invariably produces a slough, and will always give rise to severe inflammation, both of which must be treated in the usual way. Should the eye have been injured by the explosion of gunpowder, all the grains which can be observed unburned and sticking on the conjunctiva or eyelids are to be picked out with the point of a needle, and a poultice applied to facilitate the solution of the particles which remain. If the eye should be scalded by boiling water, a vesicle is formed, as in other parts, and inflammation ensues, which must be treated accordingly. The vesicle turns generally white, bursts, loses its shape, and is gradually thrown off like a slough from any other cause, frequently leaving behind it a chronic state of inflammation, of an intractable nature. I have a case now at the Infirmary, of several months standing, in which a slough separated from nearly the whole of the cornea, in consequence of turpentine getting into the eye, and being neglected. The cornea is now nearly transparent, and



there are great hopes of a cure being effected ; but the sufferings of the patient have been great.

In all these cases, the treatment, after the removal of the offending cause, should be that of inflammation generally, and the applications should never be of an astringent nature until it has assumed the chronic form. It should also never be forgotten, that in these injuries, which may be considered as purely external or chemical, the internal parts of the eye are only affected in a secondary manner, and amaurosis never takes place as a primary symptom. Whenever, then, an amaurotic defect of vision accompanies a chemical injury of any kind, whether it arises from a coup de soleil or other cause, the external or chemical affection must be considered as the least important injury ; and although inflammation must be prevented or subdued, still the principal treatment must be subsequently directed to the nervous derangement, on the principles adapted for the relief of amaurosis from such particular causes ; but it will in general be unavailing, and the surgeon will do well if he can prevent suppuration and the consequent loss of the form of the eye.

---

#### ON TUMOURS WHICH ARE FORMED WITHIN THE ORBIT, AND ON PROTRUSION OF THE EYEBALL.

TUMOURS arising within the orbit are generally the consequence of particular indefinable actions, to which they owe their origin, and their contents must therefore be frequently of an anomalous nature ; partaking, however, for the most part, of those characters which are usually met with in similar textures of the body. They are, I believe, almost always encysted, although the sac may be exceedingly delicate. Sometimes, when the swelling is the result of acute inflammation, the abscess is formed with great pain ; and when measures are not taken early for the discharge of the matter, its undue retention may give rise to very serious consequences ; but it



finds its way in general to the surface of one or other of the lids, and its evacuation, either spontaneously or artificially, leads to a subsidence of the symptoms, as well as a return of the eyeball to its natural situation, if it should have been protruded from the orbit by the size of the tumour. The pain, in these cases, is deep-seated and distressing, always accompanied by fever, and occasions considerable alarm from the swelling of the parts and the commencing protrusion of the eyeball. The upper lid swells, becomes red, œdematous, and immovable; the conjunctiva inflames, and a viscid watery discharge takes place, which requires to be frequently removed. The eyeball is but little affected, otherwise than by its displacement from the increasing size of the abscess, which at last points and bursts. If the formation of matter cannot be prevented, the free discharge of it should be assisted by keeping the external orifice freely open, until the sac of the abscess has gradually contracted and closed. Where sinuses form, leading into the orbit, the orifices should be dilated, and their internal surfaces induced to take on a healthy action by stimulant applications in the form of injections, or by the insertion of substances which may exercise a gentle pressure upon them, such as prepared sponge, catgut, &c. If the abscess should have formed in the cellular texture and parts surrounding and supporting the eyeball, the cure will be effected without any deformity; but if it should be connected with the periosteum lining the orbit, it will frequently be found to give rise to very troublesome consequences, and often to deformity, by causing an eversion of the lid affected by the disease. A case of this kind I have already alluded to, when on the subject of ectropium.

Inflammation and suppuration within the orbit are sometimes followed by much more serious consequences, implicating the eyeball, and even the life of the patient. I once saw a case of this kind in a soldier, who was wounded at the battle of Albuhera, by a bayonet, which penetrated into the orbit without injuring the eye. The symptoms which ensued



were trifling, until the patient contrived, three days afterwards, to absent himself for twenty-four hours and get drunk. On his return, the eyeball was protruded, the lid could not be raised so as to expose the eye, which was highly inflamed; chemosis had taken place, vision was indistinct, the iris was discoloured, the pupil contracted, the pain was excruciating, both in the eye, which felt as if it were too large for the orbit, and all over the forehead and temple of that side; flashes of light, of various colours, darted through the eye, in consequence of the surrounding pressure upon it; the swelling increased, the patient became delirious; and an abscess burst in the upper eyelid on the fourth day, without any alleviation of the symptoms. He soon afterwards became comatose, and died, I have little doubt, from the formation of matter within the head. The eye had previously been lost by the sloughing of the cornea. In some cases, this fatal termination is said to take place in a different manner, by the destruction of the bones of the orbit, and consequent communication with the cavity of the skull; but this I have never seen.

Tumours form within the orbit more commonly without these violent symptoms, and with little or no apparent inflammation, even when their contents are fluid and accompanied by pain. One of the best cases of this nature, with which I am acquainted, is related by Richerand\*. "A shoemaker, 45 years of age, had the left eye nearly protruded from the orbit in consequence of the gradual formation of a tumour between the inside of the eyeball and the bone. No inflammation took place, although the exophthalmia was attended by pain. The eye was not increased in size, though pushed outwards and deprived of sight. The patient having consented to an operation for the removal of the tumour, I divided the external commissure of the eyelids, and cut through the conjunctiva at its angle of reflection from the eyelids above and below to the eyeball; but being desirous of

\* Richerand, *Nosographie Chirurgicale*, tome ii, page 126.



ascertaining the nature of the swelling previously to its removal, I plunged the point of the bistoury into it; this was immediately followed by the discharge of between two and three ounces of a fluid resembling the white of an egg. Satisfied that the exophthalmia was caused by the pressure of this, which was proved to be an encysted tumour, the eye having been partly restored to its place on the diminution of the swelling from the evacuation of its contents, I gave up the idea of extirpating it, and merely placed a compress and bandage upon it. The inflammation was considerable, but was mitigated by bleeding in the foot; the sac suppurated, and the patient was cured after the excision of some little excrescences, which formed on the conjunctiva connected with it."

These tumours sometimes contain a compact fatty substance, at others, a mixture of a liquid and a cretaceous matter, or a limpid and sanious fluid, and are in general as large as a pigeon's egg\*. When, from their situation, they project above, below, or to one side of the eye, and can be in part exposed by everting and raising, or by depressing the lid, the operation should be performed by dividing the conjunctiva immediately over the tumour, when it may be made to protrude by external pressure; it should then be seized with a double hook, in order to give a more steady hold, and dissected out; which, if it be merely an adipose tumour, will be readily effected by a few touches of the knife.

When the tumour is hard, or of an anomalous character, it generally arises deeper in the orbit, and, in advancing to the surface, displaces the eye, so as to cause considerable deformity, and frequently to destroy vision; although a much greater protrusion and displacement of the eye will frequently occur, without any defect of sight, than could have been previously supposed. Tumours are rarely found to take their

\* Scarpa, by Briggs, chap. xix, page 441.



origin from the posterior part of the orbit, so as to protrude the eye before, or with them, the exophthalmos being generally accompanied by a displacement to one side, which renders it more hideous. In these cases it must be first ascertained whether the tumour can be removed without injuring the eye, and that point being decided in the affirmative, the operation is to be done in that way which will give the greatest facility to its execution, and cause the least subsequent deformity. If it tend towards the external canthus, and has displaced the eye inwards, the outer commissure should be divided, and room obtained in this way to raise the lid, so as to allow it to be dissected out. If the tumour should be, on the contrary, towards the inner angle of the eye, that part should not be enlarged on account of the lachrymal apparatus, and the operation must be done by cutting through the eyelid, in the direction of the line of the orbit, which method will succeed when the tumour is small; or by fairly dividing the eyelid in a perpendicular direction through the tarsal cartilage, by which each part may be turned outwards, and the eyeball and the anterior part of the tumour be fully exposed. Dr. Monteath\* relates the history of a case in which he performed the operation in this way, on account of an encysted organized tumour, of the size of a plum. The eyelid reunited perfectly, and regained nearly its natural power and extent of motion. When the first incision has been made in either of these ways, the tumour should be laid hold of with the hook, and carefully dissected out with the scissors, or small knife; and if any portions of it should remain, which may be ascertained by examination with the finger, they should be carefully removed by the hook and scissors. The after-treatment must depend on circumstances: if the tumour has been completely removed, the healing process may be allowed to go on as speedily as possible; but if any portion of the cyst or sac should have been

\* Weller's Manual, by Dr Monteath, vol. i, page 195.



allowed either designedly or accidentally to remain, the external opening should be kept in direct communication with it, until the wound fills up from the bottom.

The more severe operation of extirpation is usually accomplished without any particular hæmorrhage, and not requiring surgical interference. The inflammation which ensues is often considerable, and must be subdued by the usual means. If the tumour should have adhered to the periosteum, this ought, if possible, to be removed with it. In these cases the inflammation sometimes assumes an erysipelatous character, and extends over the head in the usual manner; but this will only modify the treatment so as to render it consistent with the nature of erysipelas; whether it be accompanied by inflammatory or irritative fever\*, the local applications should always be warm. The removal of a tumour attached to the periosteum, and occasionally without any such adhesion, is often attended by dangerous consequences, especially in persons of unhealthy constitutions. Langenbeck† relates a case of this nature which proved fatal. He removed a steatomatous tumour from the orbit of a man forty years of age, with the greatest facility, and with every prospect of success, the eye having been replaced in its situation. On visiting him two hours afterwards he appeared to sleep soundly, which induced him to retire without disturbing the patient; but on seeing him again in two hours, and examining him more closely, he observed that his mouth was open and his features distorted, and was told that he had been very uneasy and had pulled off the dressings. The sound eye was half closed, and he did not reply when spoken to. The dressings were replaced, he was bled largely, and evacuations were procured from the bowels, but he gradually got worse, became restless towards evening, comatose at night, and died

\* See the observations on Erysipelas in my Treatise on Gun-shot Wounds, &c.

† Langenbeck, Neue Bibliothek, band 2, stuch 2, p. 238, s. iv. Ein Beytrag zu den abnormen Metamorphosen in der Orbita, &c.



in the morning. On dissection, the bones of the orbit were found uninjured, the tumour had been completely taken away. The surface of the brain and its membranes appeared healthy, but discoloration and other signs of inflammation, with a purulent exudation, were observable upon that portion of the brain lying on the orbital plate of the frontal bone. It was subsequently discovered that the man was addicted to drinking rum, and had been drunk the night before the performance of the operation.

When the tumour is posterior to the eyeball, or connected with it, it can scarcely ever be removed, unless the eye be extirpated at the same time; and, as its nature can seldom be ascertained previously to the operation, the removal of the whole will in general be the most advisable proceeding; this step will also be the less regretted, as the eye will, in most instances, be either useless or disorganized.

When a tumour forms beneath the periosteum, and in enlarging causes the eye to protrude, it is always a very dangerous disease: I have not met with an instance in which a cure has been effected. Mr. Travers says he has seen several such cases; and in one, in which it was of the hardness of cartilage, he succeeded in scraping it away from the bone; but as he soon lost sight of the patient, he was uncertain as to the permanency of the cure. The prospect in all of them is very unfavourable, as the bone is generally implicated in the disease, and an operation should seldom or never be attempted when their termination backwards cannot be distinctly ascertained, and not even then if they appear to be remaining stationary. When they are connected with disease of the frontal, sphenoidal, or ethmoidal sinuses, or with polypi of the nose, which have forced their way into the orbits, an operation offers the only, although a doubtful, remedy. Langenbeck met with the following interesting case: "The patient, twenty years of age, had received, when nine years old, a blow from a ball, on the side of the nose and eye of the left side, giving rise to a swelling, which disappeared in the usual



manner. Two years afterwards he began to suffer from pain in the eye, and observed a prominence at the inner angle. When I saw him, the eyeball was of its natural shape, vision unimpaired, the iris correct in all its motions. The eyeball was pressed outwards and downwards by a considerable swelling at the inner canthus, which had quite the appearance, and was in the situation, of a very dilated lachrymal sac, but larger. It was easily perceived to be of a different nature, not being diminished on pressure, neither could the contents be made to regurgitate through the puncta lachrymalia, and the tears continued to pass regularly into the nose. The voice was altered, and resembling that which is observed in people suffering under polypi in the nose. The swelling felt as if it contained a fluid, and was bounded next the nose by a sharp bony edge, in the situation of the nasal process of the superior maxillary bone; but as it was not covered by a bony plate, it was difficult to ascertain its origin. The eye was displaced outwards and downwards, and the tumour extended from the inner angle of the eye upwards to the frontal sinus, which I conceived to be the principal seat of the disease, from the circumstance of having extracted an hydatid from this part half a year before, which had protruded the external layer of bone forming the sinus, and pressed down the orbital plate of the os frontis to such a degree as to displace the eye and cause it to protrude, so as to be on a level with the point of the nose. On perforating the frontal sinus, I found it two inches and a half in depth. The patient recovered. In the present instance I determined on attempting the removal of the tumour; and in order to avoid injuring the lachrymal sac or ducts, I made an incision close to the sharp bony edge of the swelling, from above downwards, and on dissecting back the soft parts, a white shining sac appeared beneath, which conveyed to the touch the sensation of fluctuation. On opening it, a grayish white tough matter was discharged; and on introducing my finger, it passed into the nose, and downwards to the palate or floor of the nostril, a depth of three inches. On



turning my finger upwards, I found it could not enter the orbit on account of the bony side of that cavity, formed by the papyraceous portion of the ethmoid bone, preventing it. This part of the orbit and the lachrymal sac were carried towards the eyeball by the tumour, and caused its displacement outwards. The fore-finger readily entered the frontal sinus. The cyst was a sac formed separately from the membrane of the nose, and prevented the discharge of its contents into it, of which about as much as would fill a teacup, of the same grayish white colour and tough consistence, was removed. This tumour must have forced its way into the orbit, between or at the junction of the ethmoid and lachrymal bones, with the nasal process of the superior maxillary bone, or the greater part of this process must have been absorbed, which appears to be the most probable: the patient recovered."

Exostosis from the bones of the orbit is very rare; I have seen only two instances of it, both from the frontal bone. In one case, the disease attained the size of a large marble, when it became stationary. In the other, it was much larger, and a portion of it had been ineffectually removed by the hot iron, which only added to the inconvenience, without giving any relief. If an operation be considered advisable, a small chisel or saw would, in my opinion, offer the best chance of success, used with great care, as in other parts of the body.

There is, however, a case on record\* of an exostosis of the os planum, and of the internal angular process of the os frontis, which had increased to the size of an egg, so as to displace the eye outwards, and cause it, as it were, to hang down on the cheek. M. Brassant removed it by the application of caustic. This caused an exfoliation of a considerable portion of the tumour, the eye returned to its place, and the cure was completed.

\* Mémoires de l'Académie Royale de Chirurgie, tome v, p. 171, in 4to.



A protrusion of the eyeball not only accompanies tumours, when of a large size, but takes place from other causes. It is called *exophthalmia*, from *εξ*, out; and *οφθαλμος*, the eye: *ophthalmoptosis*, &c.

The simplest form of this disease is when the protrusion takes place in consequence of inflammation, which, on subsiding, has left an induration of the cellular texture behind, or around the eye, causing it to project; and if this displacement continues, the tears run over the cheek, the eyelids can no longer close, the conjunctiva becomes irritable, headaches supervene, with insomnolency, fever, and great anxiety. Sometimes the patient continues to see when the eye is forced nearly out of the orbit; and when vision has been lost, it has been subsequently restored on the replacement of the eye. In the case related by Dr. Brocklesby\*, of a tumour removed from the orbit by Mr. Bromfield, which had protruded the eye, sight was partially restored four months after the operation, and from that time the patient found it gradually improve. St. Yves† gives the history of a similar case, in which vision was perfectly restored. Langenbeck, in the memoir already quoted, relates the case of a woman, forty years of age, from whose orbit he removed a steatomatous tumour, attached to the eye and its muscles, and which had not only caused the eye to project considerably, but had also deprived it of sight, although no disorganization was perceptible; yet, on the removal of the tumour, the woman recovered her sight so as to see small objects perfectly well before she left the hospital.

When the *exophthalmos* is caused by indurated cellular texture only, the consequence of inflammation, it may in general be removed by alteratives, by the establishment of a drain in the neighbourhood of the part, by attention to the state of the bowels, and by good air and exercise. If the swelling should degenerate into a scirrhus tumour, extirpa-

\* Medical Observations and Inquiries, 4th volume, page 371.

† St. Yves, *Traité des Maladies des Yeux*, ch. xxi, p. 147.



tion of the whole contents of the orbit offers the only, although doubtful, chance of safety.

Exophthalmos is frequently the consequence of injuries of the orbit, and the treatment of them is to be conducted on the usual principles of surgery; the only peculiarity, of which some further knowledge ought to be acquired, is, that the eyeball is capable of being restored to its situation, and of retaining it, even with a restoration of sight, after an injury or partial evulsion, which would at first appear to preclude all hope of saving it. The most remarkable instance of this kind is related by Covillard, a surgeon of Montelimard in France, in which the eye was driven out of the orbit by a blow from a racket ball. When he arrived, a relation of the patient had just taken up the scissors to divide the attachments by which it was still retained in the head; this he prevented, and having replaced the eye, effected so perfect a cure, that the patient suffered no alteration or diminution of sight. Maitre Jan having expressed his doubts as to the correctness of the statement, Louis\*, who enters fully into the whole story, endeavours to prove the possibility of its occurrence, and cites a similar case from the observations of Lanzwerde of Cologne, as having occurred to Spigelius. Notwithstanding these authorities the cases must be exaggerated; for, conceding that the eye might have been forced out in the manner related, the ball must have committed such injury, by the direct blow upon it, as to cause considerable internal derangement. They establish, however, this fact, that the eye ought to be restored to its place after almost every wound that can happen to the orbit, provided its structure be uninjured and the optic nerve sound. The cases I have noticed prove, that the eye can be restored to the due exercise of its functions after a very great degree of displacement has taken place. That related by Dr. Hope, in the *Philosophical Transactions* for

\* Louis, *Mémoire sur plusieurs Maladies du Globe de l'Œil*, &c. en *Mém. de l'Académie de Chir.* tome v, page 115, 8vo. edit. 1819.



1744, is very interesting, inasmuch as it was found necessary, on restoring the eye to its place after the extirpation of the tumour, to retain it there by means of a compress and bandage, which were gradually tightened, until the eye became fixed in its proper situation: a practice which it will be advisable to imitate in every case, with due precautions in relation to the pressure proper to be made beyond that caused by a mere retaining bandage.

Schmidt\* relates the history of two cases of exophthalmos, from an hydatid of the lachrymal gland. In the first, the patient died. The second, a young woman, applied to him in consequence of great pain in the side of the head and eye, which, after a few days, became intense, and was accompanied by such a violent inflammation as to protrude the eyeball from the orbit. In this state he first saw her; the eye was greatly enlarged, the cornea had sloughed, the iris was covered by organized warts like excrescences; pain was felt deep in the orbit, and was much increased on pressing the eye towards the lachrymal gland, in the situation of which a firm, resisting, and fluctuating tumour could be felt. He supposed the disease to have been caused by this tumour, which he considered to be an hydatid in the lachrymal gland, and recommended his colleague, Dr. Ruttorffer, to open it, which he did, by passing a small flat trocar below the eyelid into the tumour, when more than an ounce of a clear tear-like fluid was evacuated from it. A discharge of the same nature continued for several days; but the headache diminished considerably from a few hours after the operation, and the eye began to return to its natural situation. On the fourteenth day, a small white piece of membrane being perceived in the opening of the wound, it was taken hold of by the forceps, and the sac which contained the fluid was drawn out. In another fortnight the woman left the hospital well, but the eye was lost.

Aneurisms within the orbit give rise to exophthalmia,

\* Schmidt, Ueber die Krankheiten des Thränenorgans, page 54.



with excruciating suffering. There are two cases recorded of that disease called aneurism by anastomosis, in both of which the carotid artery was tied with complete success; the first by Mr. Travers\*, the second by Mr. Dalrymple† of Norwich. The first sensations experienced by the patients of commencing disease were a sudden snap in the orbit, followed by pain, and accompanied by a whizzing noise in the head. In a few hours, a copious effusion of a limpid fluid took place into the eyelids, the pain increased in severity, so as to become intolerable. The eye soon began to protrude, and a tumour became perceptible, in both cases evidently of an aneurismal character. The pain was now accompanied by a noise in the head, which one patient compared to the blowing of a pair of bellows, the other to the rippling of water, and both the pain and noise were insupportable, when the head fell below the natural level.

I have seen one case of true aneurism of the ophthalmic artery, of both sides, which terminated fatally. The symptoms were similar to those above mentioned, but no tumour could be perceived; the eye was gradually protruded until it seemed to be exterior to the orbit, but vision was scarcely affected. The hissing noise in the head could be distinctly heard, and was attributed to aneurism. On the death of the patient, an aneurism of the ophthalmic artery was discovered on each side, of about the size of a large nut; the vena ophthalmica cerebialis was greatly enlarged, and obstructed near where it passes through the foramen lacerum orbitale superius, in consequence of a great increase of size the four recti muscles had attained, accompanied by an almost cartilaginous hardness, which had been as much concerned in the protrusion of the eye as the enlargement of the vessels. The disease existing on both sides, prevented an operation on the carotid being attempted, to which indeed the patient would not have submitted.

\* Travers, in *Medico-Chirurg. Transactions*, vol. ii, 1811.

† Dalrymple in ditto, vol. vi, 1815.



## ON THE EXTIRPATION OF THE LACHRYMAL GLAND.

THE lachrymal gland is less susceptible of derangement or disease than any other part of the body equally complicated in its structure, or varied in the exercise of its functions. It is seldom the seat of inflammation, whether acute or chronic, and has been rarely the subject of surgical operation. Mr. Todd, in an excellent memoir on the diseases of the lachrymal gland, published in the third volume of the *Dublin Hospital Reports*, admits the accuracy of a similar statement; yet, from having seen several instances of disease in this part, supposes that they take place more frequently than has been suspected. In this opinion I cannot coincide, having met with but one case of suppuration, and none of scirrhus, in nearly twelve thousand patients, of all ages, who have attended the Infirmary to which I am surgeon. I have seen these diseases at other places and at different periods, but consider them, and especially scirrhus, to be upon the whole complaints of infrequent occurrence. Neither Schmidt nor Beer, who admit and describe in an admirable manner the symptoms of inflammation, appear to have often seen the gland in a scirrhus state. Schmidt\* says he never met with a case of scirrhus of the lachrymal gland but in connection with carcinoma of the eye; and both he and Beer consider an operation useless. Desault† conceived it only took place as a consequence of cancer of the eyeball. Boyer‡ says he never saw it, and had only read of one case in which it had been extirpated with success. Warner§ says he has seen, “a few times, the lachrymal gland so much enlarged and altered from its natural texture, as at length to evade every kind of aid but that of extirpation, which operation he had successfully performed.”

\* Schmidt, Ueber die Krankheiten des Thränenorgans, page 130.

† Desault, *Œuvres Chirurgicales*, tom. iii, *Mémoire sur le Cancer*.

‡ Boyer, *Traité des Maladies Chirurgicales*, tome v, page 288.

§ Warner's *Description of the Human Eye*, page 27.



Demours\* says he has seen several cases of it, and that they are attended by great danger. He also quotes one from Boerhaave, of a woman in the town of Delft, in whom it grew to a prodigious size; but he does not give an instance in which the operation for its removal was performed. Richerand† says, "Scirrhus enlargements of the lachrymal gland are more frequently met with in the dead body than seen in the living in practice. Guerin extirpated one that had attained so great a size as to conceal the globe of the eye, which might have been supposed to form a part of the swelling, if the phenomena of the disease had not rendered it probable that the eye was only covered by it. Guerin removed the gland with such dexterity that the rectus externus muscle was not injured." This operation, he adds, is perhaps the only one of its kind, and that he was not acquainted with another instance of its removal, in an isolated state of scirrhus, or without carcinoma of the orbit.

The symptoms of scirrhus are at first obscure; a slight uneasiness is felt at the outer part of, and within the upper edge of the orbit, which is sometimes attended by a sudden discharge of tears from the eye, more particularly when this uneasiness amounts to pain, and is increased by paroxysms: flashes of light are subsequently perceived in the eye, and about the same time the enlargement of the gland is observed. This is soon followed by displacement of the eye inwards, with more or less of direct protrusion. As the gland enlarges it becomes irregular and knotty to the touch, the eyelid is stretched over it, the conjunctiva falls into a state of low chronic inflammation, and the lower eyelid is everted. The pain is, in this stage of the disease, very severe and lancinating, principally at night. The eye continues to protrude until it appears to rest upon the cheek. In some cases vision is totally destroyed, in others it is only impaired, in a third set

\* Demours, *Traité des Maladies des Yeux*, tome i, page 490.

† Richerand, *Nosographie chirurgicale*, tome ii, page 33, 4me edit. 1815.



the patient sees objects double, and in one instance I saw the eye greatly protruded without any defect of sight. The changes in the structure of the eye may be scarcely observable, or the reverse.

Mr. Travers \* removed this gland, in a state of true scirrhus, from the orbit of a middle-aged man, with success, and the patient was in good health a year afterwards. Mr. Todd † performed the operation under the following circumstances: "Jane Worthington, æt. 70, admitted into the Richmond Surgical Hospital, 26th August, 1821. The lachrymal gland forms a large irregular tumour, which occupies the upper part of the orbit, and projects more than half an inch beyond the superciliary ridge. It is covered by the superior palpebra, which is stretched upon it, thus rendering the knotty eminences on its surface very conspicuous. The tumour is extremely hard, and moveable to a slight extent, in a transverse direction only. Some, who have carefully examined it, are of opinion that it adheres to the roof of the orbit.

"The globe of the eye is not enlarged, but it has been protruded by the tumour, and is so low upon the cheek, that the cornea lucida is nearly on a line with the edge of the ala nasi. The inferior eyelid is everted, and appears dragged down with the globe; its conjunctiva is much thickened, particularly in the line of its fold; there is chemosis and considerable turgescence of the superficial blood-vessels of the eye.

"The transparency of the cornea is but slightly obscured; and although vision is destroyed by the pressure of the tumour and the extension of the optic nerve, yet there is no apparent disease in the interior of the eye. The pains are severe and lancinating, and extend from the tumour to the globe, accompanied with a sense of heat, and a frequent discharge of scalding tears.

\* Travers, Synopsis of the Diseases of the Eye, page 228.

† Dublin Hospital Reports, vol. iii, page 419.



"The sufferings of the patient are more severe at night, and she is almost entirely deprived of sleep; notwithstanding which her general health is not much impaired, and her appetite for food is good.

"The disease is attributed by the patient to a blow which she received on the eye about seven years ago, since which period she has been subject to a frequent discharge of tears from the eye; but suffered no other inconvenience until a year ago, when the tumour began to project under the temporal extremity of the eyebrow. At first she had no pain or headache; but as the tumour increased, these symptoms set in, and they are now so severe, that she is anxious to undergo any operation which holds out a prospect of relief.

"August 29th. In consultation this day with Mr. Carmichael, it was determined that an attempt should be made to extirpate the diseased gland alone, and in the event of that being found impracticable, either from extent of attachments or of deep-seated disease, the expediency of removing all the contents of the orbit was fully acceded to; the intense sufferings of the patient, the probable nature of the disease, and the useless state of the eye, appearing to render this an indispensable alternative.

"30th. I performed the operation this day, in the following manner:—

"The patient having been placed on her back on a table, with her head a little elevated, and secured by my assistants, a transverse incision was made through the integuments, nearly parallel to the superior margin of the orbit, from one extremity of the tumour to the other; and having cut through the orbicularis palpebrarum and the ligamentum tarsi, I exposed, by a careful dissection, the entire of the anterior surface of the tumour. The diseased gland was then found firmly wedged into the orbit, and it was not without difficulty that the handle of the scalpel was introduced between it and the superciliary ridge, to detach the former from the orbital process of the frontal bone. The surface of the gland next



the eye was irregularly lobulated, and the lobes had insinuated themselves amongst the muscles and other contents of the orbit, so as to render their disentanglement extremely difficult and hazardous; however, by cautiously tearing their cellular attachments with the end of my finger, the handle of the knife, and the blunt extremity of a director, and by cutting on my finger, with a probe-pointed bistoury, some firm membranous bands, which could not be easily broken, I succeeded, in the course of a few minutes, in extracting the entire tumour. On a careful examination, no further disease could be detected in the orbit; and as no bleeding occurred, the globe of the eye was gently pressed towards its natural situation, the wound dressed, the parts supported with a compress and bandage, and the patient laid in bed, with strong injunctions to observe the strictest quietness.

“The diseased gland was found, on examination, much larger than a walnut; it presented on the surface which had been turned towards the eye three considerable eminences, or lobes, with deep fissures between them; it was almost as firm as, but more elastic than cartilage. A section of the gland exposed several small cartilaginous cysts, which contained a glairy fluid, and the interspaces consisted of a firm fatty substance, traversed by a few membranous bands.

“In two hours after the operation an alarming hæmorrhage took place; this, from the great depth at which the wounded vessel was situated, and the extensive extravasation of blood into the loose cellular tissue of the orbit, was with difficulty suppressed by Mr. Benson, the resident pupil in attendance, making pressure with his finger. Dossils of lint were then introduced into the wound, and the bleeding did not recur. The patient passed a tranquil night, and for the first time for many weeks enjoyed refreshing sleep.

“On the following day, the appearance of the eye and surrounding parts was by no means encouraging; the globe was protruded from the orbit as much as before the operation,



by large coagula, which occupied the situation of the tumour; the eyelids were affected with an extensive ecchymosis, they were as livid and as cold as if in a state of gangrene, and the cellular tissue of the conjunctiva was distended with effused blood in all its dilatable parts. Notwithstanding these untoward occurrences, the patient had experienced much relief from the operation; she was free from acute pain, and the constitutional excitement was inconsiderable.

“ In the course of a few days the coagulated blood contained in the orbit began to dissolve, and suppuration was soon established. From that period the globe of the eye was observed to return slowly into its natural situation, and the conjunctiva and skin of the eyelids to assume their healthy appearance.

“ On the twelfth day after the operation, the improvement in the position of the eye was quite evident; but it was found impossible to prevent the eversion of the lower eyelid, in consequence of a thickened fold of the conjunctiva, which extended between it and the globe. To this fold the nitrate of silver had been frequently applied without any benefit; I therefore removed it by excision, and was immediately enabled to replace the lid, which showed no further tendency to become everted.”

The following case occurred to Mr. O'Beirne, formerly of the Royal Artillery, and now surgeon to the Charitable Infirmary, Jervis Street, Dublin, to whose ability, zeal, and experience I have often, in the course of the late war, been greatly indebted.

“ Thomas Cooke, of Longford, aged twenty-two years, strong and athletic, was admitted into the Infirmary on the 21st of December 1820, with considerable deformity and imperfect vision of the right eye. The globe projected more by its semi-diameter than the sound eye, yet it was covered almost entirely by the upper eyelid, which hung loosely over it, as if paralysed; the pupil was dilated and insensible to



light, the cornea lucida was turned towards the nose, and the puncta lachrymalia were patulous.

“ The upper and outer part of the orbit was occupied by a tumour, the outline of which could not be distinctly traced ; but to its growth were attributed the protrusion of the eye, impaired vision, &c. The patient suffered considerable pain of the right side of the head and face, and much irritation and watering of the eye were produced by cold air, or particles of dust. All objects appeared to him doubled ; and in walking or endeavouring to reach any object, his hand or foot generally fell short of it, so much so as to prevent him from working even as a labourer. About two years before his admission, he perceived, for the first time, sparks, and occasionally mists before his eyes, with sharp intermitting pains in that side of his head and face ; and, in about a year, a slight prominence and inversion of the globe were observed ; from that period the symptoms have gradually proceeded to the state described above.

“ On the 23d, it was decided, in consultation, that the tumour should be removed ; but it was not even suspected that the lachrymal gland was the part affected.

“ The operation was begun by an incision being made through the integuments of the upper eyelid, which extended from the inner to the outer angle ; the orbicularis palpebrarum being next divided, some portions of adipose substance which presented were removed. I then introduced my finger, and at once discovered that the disease was an enlarged and indurated lachrymal gland. The anterior surface of the tumour was exposed by dissection, and it was finally removed by cautiously working with the nail of the little finger, for it was not considered safe to introduce a knife into the back of the orbit.

“ On the tumour being removed, the pupil instantly recovered its contractile power, and the globe retired nearly to its natural situation ; vision too was improved, but not perfectly restored. Scarcely any hæmorrhage ensued, and the



wound was dressed simply. With the exception of a slight erysipelas of the scalp, which yielded to the usual remedies, the patient's recovery was uninterrupted, and the wound was completely healed on the fourteenth day after the operation. At that time vision was perfect, all pain and uneasiness, either from the disease or the operation, had subsided, and the eye occupied its proper place. The upper eyelid, however, having continued so much relaxed as to obscure a great part of the cornea, a camel's hair pencil, dipped in sulphuric acid, diluted in three parts of water, was drawn in the line of the cicatrix ; in a few days the black mark sloughed, and the subsequent cicatrization of the ulcer contracted the lid to its natural state, and the patient was discharged cured."

These cases establish, in an incontrovertible manner, not only the fact of a scirrhus of the lachrymal gland existing as an isolated disease of the orbit, but also prove, that the extirpation of it may be safely and successfully accomplished. The method of doing it is so clearly described by both, that it would be an injustice to Mr. Todd and Mr. O'Beirne, as well as a matter of supererogation, to repeat it.

---

#### ON THE ALTERATIONS OF FORM OF THE ANTERIOR PART OF THE EYE.—STAPHYLOMA.

THIS disease takes its name from its supposed resemblance to a grape, σταφυλη ; and consists essentially in a protuberance of the anterior part of the eyeball, particularly of the cornea, which has become opaque, is a consequence of acute inflammation, and assumes various appearances, all bearing a general resemblance to each other. They are divided into total and partial, spherical and conical. When the cornea is enlarged, and projects in an equable manner, it is called Staphyloma totale sphæricum ; but if the central point be advanced, in addition to the general projection, it obtains the name of Staphyloma totale conicum. When only a part of the cornea



projects, it is called *Staphyloma parziale*, which is sometimes found superadded to the total spherical staphyloma. It is a disease common to all periods of life, is said to prevail in children, is most frequently caused by the purulent ophthalmia and the small pox, and has been more often seen during the last two years than for several preceding, in consequence of the greater prevalence of this disease. Scarpa\* considers it to be an extraordinary circumstance, that it never occurs during the eruptive or suppurative stage of that disorder, but on the desiccation, and even after the crusts have desquamated; but if he had reflected a moment on the cause and course of the complaint he would have perceived, that the ulceration and sloughing of the cornea, caused by the variolous pustule formed upon it, were slower in their progress than the same processes in the skin; and that the staphylomatous projection was a consequence that could scarcely appear at so early a period as the usual time of incrustation, or even desquamation.

When the cornea does not project between the eyelids so as to prevent their closing, it causes but little inconvenience to the patient, and is only unpleasant from the deformity it occasions. The first and most simple kind of staphyloma is of this nature, and appears to have been overlooked by both Richter and Beer in the definitions they have given of the disease. It occurs after or during a long-continued inflammation of the eye, which has principally affected the conjunctiva and cornea, during which the latter becomes opaque, loses its natural appearance, projects, and becomes more spheroidal, the conjunctiva covering it is thickened, and red vessels are to be observed on its surface; the iris may be partly discerned in its natural situation through the semi-opaque staphyloma; the anterior chamber contains a larger quantity than usual of the aqueous humour, and the projecting cornea has the greatest resemblance to an equal portion of a white grape. This state of the eye is irremediable.

\* Scarpa, by Briggs, page 392.



There is a good illustration of this disease in the person of William Jackson, who occasionally attends at the Infirmary. When he first presented himself for advice, the eyelids were enormously thickened in consequence of a granulated and fungous state of the conjunctiva; the eyeball appeared to be a red fungous mass, in which the cornea was not distinguishable: he was perfectly blind. In the course of twelve months' treatment, the eyelids have been reduced to their natural state, the conjunctiva covering the eyeball has a more healthy appearance, the cornea is now well defined, semi-transparent like horn, and the patient can see, so as to avoid large objects in his way, with the left eye. The cornea of this eye projects in a spheroidal form, and the anterior chamber is increased in size. The disorganization having proceeded further in the right eye, renders it entirely irrecoverable.

The second kind of staphyloma is that which has been described by Scarpa, Richter\*, and Beer†, and in the abridgment of the works of Beer and Schmidt, by Weller. By the German writers, staphyloma is supposed to depend on an external and internal swelling of the cornea, the consequence of inflammation, accompanied by a corresponding swelling and projection forwards of the iris, which adheres to the cornea, constituting the first step in its formation: for its completion, they suppose that the secretion of the aqueous humour in the posterior chamber must continue unimpaired, when the cornea yields to the pressure, enlarges, and becomes staphylomatous; a total staphyloma depending upon a general adhesion of the iris to the cornea, a partial one on a portion of the iris being alone adherent. When the iris adheres generally to the cornea, without implicating the lens and its capsule, they suppose the staphyloma will be necessarily spheroidal, from the equable distention caused by the aqueous humour; but that when the posterior part of the iris adheres to the capsule of the lens, causing a destruction of both the anterior and the posterior

\* Richter, *Observat. Chirurgic. Fascicul. 2.*

† Beer, *Lehre von den Augenkrankheiten*, band 2, page 211.



chambers of the aqueous humour, with a consequent deficiency in its secretion, a conical cornea will be the result. This reasoning does not appear to me to be in any way conclusive, or consistent with fact.

Angeli\* and Scarpa† have proved, that the cornea of infants is, in its natural state, much more pulpy in its texture, whilst it is nearly twice as thick as in adults, which necessarily implies a comparative diminution of the size of the anterior chamber of the aqueous humour. "Such also," adds Scarpa, "is the natural softness, flexibility, and succulency of the cornea in infants at an early age, that when separated from the rest of the eye in the dead subject, and rubbed between the fingers, it loses at least one half of its bulk and thickness, which does not take place in adults." When inflammation occurs in the cornea of infants, this texture readily admits of the admission of a considerable quantity of adventitious matter, without permanent injury to its structure, rendering it perfectly white and opaque, in a manner which if it were to occur in the eye of an adult would leave an indelible leucoma. This peculiarity in the cornea enables us to account for the almost perfect recovery which frequently takes place in cases of purulent inflammation of infants, after the cornea has been of a marked ash colour, and attended by ulceration. The thickness of the cornea, and the consequent diminution of the anterior chamber, which seem to offer a more favourable opportunity for the iris to adhere, are not the cause of the great prevalence of staphyloma among children, as Scarpa has supposed; this is to be sought for in the period of life at which persons are subjected to the small pox by the will of their friends, and it having been almost universally during infancy, young children were therefore more liable to staphyloma from a variolous pustule forming upon the cornea. The thickness of the cornea should rather be regarded as a means offered by nature for resisting disease, than of assisting in

\* Angeli, *Commentatio medica de Oculo*. Erlangæ, 1802.

† Scarpa, by Briggs, page 355.



its formation, which appears to me to be proved by the fact, that the remark of the greater prevalence of staphyloma in children has not been correct for the last twenty years, since the general introduction of vaccination, whilst it must be admitted with great regret, by every surgeon of every hospital or public charity in the kingdom, that, during the last few years, infants have suffered considerably from it in consequence of the greater prevalence of the small pox. The reason why the inflammation of small pox causes staphyloma more frequently than any other inflammation is, not that there is any thing specific in it, but that it goes on to ulceration, and a state of ulceration of the cornea is necessary in almost every instance for the production of that kind of staphyloma of which we are now treating, and which Richter and Beer suppose to depend on the mere swelling, approximation, and adhesion of the cornea and iris. The anterior surface of the iris and the internal membrane of the cornea are not prone to adhere to each other, they are almost incapable of effecting it by the adhesive inflammation, and, in order to accomplish it, the inflammation must proceed beyond that point. So long then as ulceration does not take place and penetrate the cornea, will an infant, in almost every case of violent purulent ophthalmia, be free from danger of staphyloma; and as often as a varolous pustule forms on the cornea will an infant, in consequence of its ulceration and sloughing, be in danger of staphyloma. The thickness of a staphyloma which has been formed in infancy is readily accounted for, and so is the general adherence of the iris to it. For the opposite reason, a staphyloma formed at adult age is generally thinner and harder; whilst in children it is thicker, more spongy, and softer, but becoming occasionally, with time, hard and almost cartilaginous.

The purulent ophthalmia, which formerly prevailed to a considerable extent in a part of the army, gave rise to many total staphylomatous formations; but, I have reason to believe, not in one single instance, unless sloughing or ulceration of the cornea had previously taken place. The purulent oph-



thalmia, when it attacks a child, is always a mild disease, compared with its state when it attacks its nurse, who may have acquired it from the infant. The succulency of the texture of the cornea, in the infant, enables it to support the inflammation and its consequences for many days with little detriment, whilst the firmer and more compact cornea of the adult sloughs from its circumference. The exposed iris, in the adult, is by degrees covered with a layer of matter, adhering to it and somewhat resembling the cornea, of which it seems to be an imperfect formation; through this the patient can often distinguish light and objects for a time, but it soon becomes irregularly obscured, the conjunctiva which is formed upon it is thick, opaque, and firm; red vessels wander upon its surface; the iris can sometimes be seen attached to the inside of the new-formed cornea, and very frequently a point will be observed to project, to become thin, to resemble a small staphyloma seated upon a larger one, and at last to burst and discharge a quantity of aqueous humour, with a partial subsidence of the projection. —*RHEXIS OCULI*.

In the infant or very young person, the cornea seldom sloughs so completely as in the adult, and it also possesses in them a power of reproduction, which causes it to resemble in thickness, although not in transparency, the original state of the cornea. Hence the greater thickness and pearly opacity of a staphyloma in children. I have known this reproductive power so great as to cause a second staphyloma in a child, larger than the first, after nearly the whole of the cornea had been removed by incision.

The gradual projection of the cornea is supposed to depend on the pressure or impulse given by the continuance of the secretion of the aqueous humour posterior to the iris; whilst the attendant absorption of it is diminished in consequence of the abolition of the anterior chamber by the adhesion of the iris to the cornea. This supposition, which appears at first to be plausible, admits, however, of considerable doubt; for we seldom find, that after the staphyloma has attained a



certain size, it continues to increase, which it ought to do if the cause remained in activity. The desire of obtaining relief does not arise from the pain or inconvenience caused by the projection, further than that the inability to close the lids gives rise to irritation, keeps up chronic inflammation, and therefore causes pain as well as deformity. The operations now in use for its cure do not, in many instances, destroy the secreting apparatus, which they ought to do on this presumed hypothesis, whilst they certainly tend to diminish the absorbing surface; I therefore am disposed to believe, that nature is in general capable of regulating the secretion according to the absorption, unless when some particular impulse is given to the former, as in the commencement of the formation of a staphyloma, or as frequently takes place at a subsequent period, when the eye becomes irritable from any cause whatsoever, which may give rise to it, and that the disease takes place in consequence of increased secretion, rather than from deficient absorption; nothing being more common than to see eyes in which the anterior chamber seems to be obliterated by the iris lying directly against the cornea, without any apparent attempt at the formation of a staphyloma.

The cure which nature endeavours to effect of this disease is by thinning one particular part until at last it bursts, and the aqueous humour is evacuated; but this bursting has been caused by progressive absorption, which, on that event taking place, if not at an antecedent period, becomes the ulcerative; the ulcer remains for several days, a drain is established, inflammation is excited, under which, in my opinion, an alteration takes place in the actions of the secretory apparatus, by which the secretion is diminished. The eye becomes smaller, the ulcer heals, but the eye still decreases in size; showing that the absorbent are superior to the increasing or secreting powers. If the ulcer and inflammation be more extensive, suppuration takes place internally, and the eye sinks.

The manner of accounting for the formation of a conical total staphyloma appears to me to be also defective; for in



the disease which is called conical cornea, every part except the cornea seems to be in state of health. In this disease the cornea loses its spherical appearance, as a segment of a circle, and assumes the form of a pointed cone, from the apex of which the light is reflected so powerfully as to present to a spectator the appearance of a luminous spot, which when once seen can never be mistaken. I have two cases of this kind under my care at the Infirmary, one in a young, the other in a middle-aged man; both eyes are affected in each, without any other appearance of disease save that of a very slight increase of vascularity. The cornea in such cases is decidedly thinner than usual, and if irritation takes place upon it, the apex of the cone becomes opaque, and causes it to represent in shape a conical total staphyloma. The cause of these two complaints cannot, then, be so essentially different as the German hypothesis would lead us to believe. The alteration of shape is incurable, but the defect of sight may be partially relieved by using a deep concave glass; which appears to me to answer better than an operation for the destruction or depression of the lens, which may not be, and has not always been successful when attempted in such cases.

A partial staphyloma is, I believe, always the result of ulceration of the cornea, through which the iris protrudes, and from which it obtains a thin covering. This becomes opaque, and of a pearly colour, and the iris can be seen firmly adhering to its internal surface; in which state it is merely a leucoma. If the irritation of the eye continues, or a new one be set up, the increase of aqueous humour causes a pressure which the newly formed part is incapable of resisting; it yields accordingly to the distending power from within, and in protruding gives rise to a partial staphyloma, or projection of a part of the cornea, which is generally below a line drawn horizontally through its centre. It is almost always very thin, but in some particular cases, where it does not yield to the pressure, or is not destroyed by art, and the increased secretion of



the aqueous humour ceases, it gradually becomes thicker and of a more pearly appearance.

The operations for the cure of staphyloma are effected in two ways: one by the caustic, the other by the knife. The caustic is only applicable to cases of adult subjects (very rarely of young ones), in which the cornea forming the staphyloma is thin, and the sclerotica is nearly, or quite free from disease. The operation by the knife is required in young, or in old subjects, where the staphyloma is evidently thick and hard, and the anterior part of the eye in a more or less varicose state.

The use of escharotics, and especially of the lunar caustic, for the cure of staphyloma, is attributed to Richter\*, and they have been strongly recommended by Beer†, who praises the butter of antimony for this purpose; and by Dr. Vetch‡. Scarpa§ seems to have misunderstood the intention with which it was used, and therefore to have employed it ineffectually. He says, "In recent cases of staphyloma, Richter proposes to produce an artificial ulcer upon the base of the tumour of the cornea, by means of the reiterated application of the argentum nitratum, or the antimonium muriatum, and to keep it open by the repeated use of these caustics; in order to evacuate, by means of this small cauterization, the thick and tenacious humour which is the immediate cause of the opacity and preternatural tumefaction of the cornea. The author asserts, that he has frequently obtained a diminution of the staphyloma by means of this small drain made in the substance of the cornea; and in one particular case, that he has even restored the transparency of the cornea: an instance of a cure which has always appeared to me one of the most ex-

\* Richter, *Observat. Chirurgic.* Fasc. 2.

† Beer, *Lehre von den Augenkrankheiten*, band 2, s. 67.

‡ Dr. Vetch, *A Treatise on the Diseases of the Eye*, page 58 et seq.

§ Scarpa, by Briggs, page 402.



traordinary and wonderful of the many which are found recorded on the diseases of the eyes; particularly as it was completed in fourteen days. *Ter repetita operatione, quarto scilicet, septimo et decimo die, ne vestigium quidem morbi die decimo quarto supererat.*

“I am sorry to be obliged to declare, that although I have frequently adopted this method of treatment, in the recent staphyloma of infants, and that with the fullest confidence of success, not only from a persuasion that this plan of treatment proceeded from certain and evident premises, founded on the nature of this disease when recent, and in subjects of an early age, but because, in so doing, I was guided by one of the most authentic writers in surgery; yet I have never had the gratification to obtain such success, with regard to restoring the transparency of the cornea, as to be in any degree compared with that obtained and recorded by Richter.”

It will be seen from this quotation, that Scarpa implies a doubt, almost amounting to disbelief, of the fact stated by Richter; yet nothing can be more correct, provided it be understood, that the small ulcer penetrates the substance of the cornea, which Richter evidently intended, although it may not be clearly expressed, and which Scarpa did not, therefore, understand. In selecting young subjects for this practice, he was also in error, from the thickness of the cornea, which, while it prevents the caustic from quickly penetrating into the anterior chamber, causes it to produce a severe general inflammation of its substance, and of the eye generally: reasons which render it a particularly improper remedy in cases which occurred in childhood and have continued to manhood; as it almost always causes great inflammation, and long-continued and excruciating pain, generally terminating in suppuration. The lunar caustic, which is the best of all the escharotics that have been recommended, should be reduced to a very fine point, and applied with a steady hand to the most prominent part of the staphyloma for the space of a minute, if the patient is sufficiently steady, and it ought to be repeated every second



day until it has penetrated the cornea, which will in general be accomplished on the second application, if the first should not have been found sufficient. The caustic which has been dissolved during its use will do no harm; but to be secure, the eye may be washed with a little warm water. On the separation of the slough, an irregular, small, but penetrating ulcer remains, through which the aqueous humour percolates until the opening closes, which it does in a few days, with a very moderate degree of inflammation and little pain. By this period, the anterior part of the eye will have become so much flattened, that although it prevented the closure of the eyelids previously to the operation, it now offers no such obstacle, and the cure is equally certain and effectual, although less formidable, than if the operation had been done by the knife.

When the staphyloma is firm and thick, as in young subjects, or where it has existed in an adult from childhood, its removal by the knife should always be preferred. The operation was well known to the ancients. Celsus\* describes it, and gives some very excellent precepts for its performance, which were subsequently neglected. The principle on which it ought to be done is well understood; the mode of doing it varies according to the state of the part.

When the eyeball is sound, and a total spheroidal staphyloma is the only morbid formation to be perceived, the deformity and inconvenience it occasions will be obviated in the best and safest manner by cutting off only such part of the cornea as projects beyond its natural situation, and without interfering with the crystalline lens or its capsule. When this portion of the cornea has been removed, with such part of the iris as may be adhering to it, the lens and its capsule will be perceived, either opaque or transparent, but perfectly exposed. It remains in this state for some days; but in general, between the seventh and tenth day, a thin layer is spread over it from the surrounding cornea, which is at

\* Celsus de Re medica, lib. vii, cap. 7.



first partly transparent, in a short time after the anterior part of the eye becomes consolidated, but perfectly flat and somewhat less than natural, being in the best state for the application of an artificial eye. If the cornea be conical, and the lens be advanced into the projection; or if the same thing should happen in a spheroidal staphyloma, or the capsule of the lens be injured in the operation, either by the point of the instrument or undue pressure by the hand of the surgeon or assistant in fixing the eye, the discharge of the lens will follow the completion of the incision in the cornea; a circumstance which causes a greater diminution of the eyeball. The vitreous humour need not be purposely evacuated, although its accidental escape is of no consequence, further than as the globe of the eye is thereby considerably lessened, and sometimes entirely sinks in the orbit.

The operation is to be performed in the following manner: the patient's head being secured, and the upper lid properly raised, either by Pellier's speculum or the finger, the eye should be steadied by a gentle pressure, or, in a conical staphyloma, by a hook, whilst the operator passes a broad spear-pointed cataract knife across the centre of the staphyloma, and carries it downwards, or upwards until rather more than one half of it is cut through by the passing out of the knife. Without allowing the eyelid to fall, the operator should raise the flap with the forceps, or desire it to be done by an assistant, if he should prefer elevating the lid himself; and then cut through the portion of the cornea remaining to complete the circle, with the scissors; when the operation will be finished, and the lid may be allowed to drop. The patient should be desired, if an adult, to be as quiet and as steady as possible; for the slightest irregular pressure or exertion will cause the escape of the lens, and perhaps of a portion of the vitreous humour, which indeed, in children, can seldom be avoided.

If the constant irritation should have caused a varicose state of the anterior part of the eye, as shown by the bluish



leadens appearance of the sclerotica, which seems to be penetrated close to the cornea by many tortuous dark red vessels, accompanied, in its more advanced state, by a bulging out of particular parts in this same situation, the anterior portion of the eye ought to be removed, and with it the vessels which are in a varicose state. This operation is to be done in a similar manner, although further back towards the centre of the eye, when the whole of its contents will be evacuated. In these cases a weeping venous hæmorrhage frequently takes place, and will continue for hours; it is seldom or never dangerous, unless the opening into the eye has been small, and the choroid coat and the retina, together with any coagulum which may form, close it up, when the bleeding continuing internally, and being only partly discharged, causes pressure and gives great pain. This will be remedied by removing the coagula, by cutting away any portion of the membranes which may fill up the opening, and by the application of cold. I have seldom applied any dressing but a light compress and bandage; if much tumefaction appeared in the lids, attended by pain, I have occasionally had recourse to a poultice. The upper eyelid should not be raised for five or six days, as it causes irritation, and the eye does not require examination whilst it can be cleansed without it. As the process of cicatrization proceeds, a small fungous-like granulation will sometimes appear in the centre, and require to be lightly touched by the *argentum nitratum*.

I have performed the operation many times, in all these different ways, and always with success.

---

#### ON THE EXTIRPATION OF THE EYEBALL.

THE extirpation of the eye is an operation sometimes necessary, in consequence of a cancerous affection of its appendages, of fungus hæmatodes of the eyeball, and of tumours which implicate any part of it in such a manner as to render the removal of the whole necessary.



It is not my intention now to enter into the consideration of cancer and fungus hæmatodes as affecting the eye or eyelids, but merely to point out such states or stages of those diseases, in which the operation may be done with some probability of success, and the best manner of doing it.

The observations already made on the subject of the extirpation of the lachrymal gland, when in a scirrhus state, prove, that the presence of this disease within the orbit ought not to forbid the operation if the eyeball should be similarly affected; for, although it may offer less chance of success, still the extirpation of the whole of the contents of the orbit, under such circumstances, has frequently been followed by the happiest results. If other cancerous appearances should take place in a different part of the body, an operation would be useless. It offers little or no chance of success when the habit of body seems to be bad, and to be affected by the existence of this disease. It would be improper to attempt it when the eyeball is immoveably fixed in the orbit.

In regard to fungus hæmatodes of the eyeball, it may be considered as a fatal disease; inasmuch as the removal of the eye has not, I believe, hitherto succeeded in arresting its progress, when it has been so fully formed at the bottom of the eye as to show distinctly its nature. It prevails in children, mostly under twelve years of age. The first sign of the disease is the loss of sight, soon followed by an appearance at the back of the posterior chamber, resembling burnished or polished iron, and accompanied by a dilatation and immobility of the pupil, by an enlargement of the vessels of the conjunctiva and sclerotica, and by pain in the eyeball. By degrees, an amber or greenish coloured irregular spot is seen to arise from it, resembling a small mass of coagulable lymph, which may be mistaken for a partial opacity of the vitreous humour. This fungus gradually increases; and at this period the extirpation of the eye offers little or no chance of success, but will rather accelerate the death of the patient, as the disease has



extended along the optic nerve, and will re-appear after the eye has been removed.

The following observations of Scarpa deserve attention, I have therefore thought proper to transcribe them.

“ 1. The fungus hæmatodes, formed within the eyeball, is a disease altogether distinct from the carcinoma, which attacks the external parts of this organ ; whether the first be regarded as a modification of the second, or not.

“ 2. The fungus hæmatodes attacks the internal part of the eyeball, in children under twelve years of age more frequently than in adults.

“ 3. The complete extirpation of the eye for the cure of the fungus hæmatodes, although performed on the first appearance of this disease, under the form of a yellowish spot, is useless, and rather accelerates the death of the patient.

“ 4. The exterior fungous excrescence of the eye, commonly called carcinoma, on the contrary, makes its appearance on the conjunctiva and anterior hemisphere of the eye.

“ 5. The exterior fungous excrescence of the eye, while it is soft to the touch, flexible, and pulpy, although accompanied with symptoms similar to those of carcinoma, is not actually so ; nor does it become malignant and strictly cancerous, until after it has become rigid, hard, coriaceous, warty, and in every respect scirrhus.

“ 6. The inveterate fungous excrescence, hard to the touch in all its parts, covered with ulcerous warts, which has involved the whole of the eyeball, optic nerve, and surrounding parts, rendered the bones of the orbit carious, and contaminated the lymphatic glands behind the angle of the jaw and in the neck, is incurable.

“ 7. The partial or total extirpation of the eye, on the contrary, is attended with success whenever the operation is performed before the fungous excrescence, exterior to the eye, has passed from the state of softness to that of scirrhus, verrucous, and carcinomatous hardness.”



The first account we have of an operation for the removal of the eyeball is to be found in a Treatise on the Diseases of the Eye, by Bartisch, published at Dresden in the year 1583\* ; who performed it with an instrument resembling a spoon having a cutting edge, with which he scooped it out. Thirteen years afterwards Hildanus, having occasion to extirpate an eye, discovered the inconveniences arising from the spoon of Bartisch, by trying it on animals, and invented a slightly curved knife with a blunt extremity, which he used with great success. We find, however, Job à Meékren, a Dutch surgeon, a hundred years afterwards, using the spoon of Bartisch, in preference to the knife of Hildanus. Tulpius, and Plempius, rejected the operation altogether. Bartholin mentions a case in which, by the advice of Walæus, a cancerous eye was torn out with hooks, the patient appeared to be doing well for the first three days, but then died suddenly after a slight convulsion. Muys† restored the operation by the knife. Bidloo relates the history of four successful cases, in which the knife was used conjointly with the scissors. La Vaugyon, the first French surgeon who mentions the operation, in 1696, does so merely to proscribe it ; in which opinion he was followed by Maitre Jan, and even by the celebrated Dionis. St. Yves notices it in a cursory manner ; but it was reserved for Louis to give a complete history of the operation, to indicate the necessity for doing it, and to show the advantages resulting from it. He recommended it to be done with a knife and a pair of scissors curved on the side or back. Desault first advised the division of the external commissure, in order more effectually to expose the tumour, and in this I coincide ; for the orbicularis muscle contracts so strongly, in many cases, as to diminish the natural aperture very considerably, and thereby materially impedes the progress of the operation. It always heals without difficulty. In

\* See "Extirpation de l'Œil, Histoire de cette Opération," vol. v, page 131, of the "Mémoires de l'Académie de Chirurgie."

† Muys, Praxis Medico-chirurg. rational. decad. 12, observ. 1.



order to steady the eye, and to enable the assistant to move it in every direction, a hook or a ligature must be passed through the eye. Beer\* recommends a hook or tenaculum; but it appears to me that a ligature, made of three threads and passed through the cornea, answers better, as it is more out of the way. This ligature is for the purpose of moving the eye in every direction, except drawing it out of the orbit, which must be carefully avoided, until the optic nerve is divided, as serious consequences may ensue from dragging upon it in an irregular manner.

The patient being seated below the operator, or placed on his back, and his head being firmly secured, the upper eyelid should be raised by an assistant, whilst the surgeon passes the ligature, by the aid of a needle, through the cornea, or even the anterior part of the eye, when the needle should be cut off, and the upper lid allowed to fall. The surgeon should now cut through the external commissure down to the edge of the orbit, with a small straight but rather long and pointed scalpel, and then divide the conjunctiva and fat around the eyeball, beginning at the under part, to prevent the blood from above impeding the operation. The complete division of the outer angle of the lids down to the bone, facilitates this part of the operation materially, as it allows the lower lid to be readily everted, and depressed by the fore-finger of the left hand of the operator, thereby preventing its being injured, which is very likely to be done, unless great care be taken to avoid it, by making the fore-finger act as a director. The eyeball may then be drawn gently forwards, or outwards, to offer a greater facility to the remaining steps of the operation, which consist in cutting deeply into the orbit with a pair of scissors, curved as directed on the back. In order to repress the hæmorrhage, or rather to prevent its impeding the operation, an assistant should wash away the blood, by means of water injected into the wound by a syringe; and, when the eye is removed, the operator must carefully examine the orbit with the finger,

\* Beer, band ii, s. 193.



to ascertain that no diseased part is left, and that the lachrymal gland has been removed. The hæmorrhage is not to be dreaded; and unless the patient is very weak, it is much better to let it cease under the use of cold water, than to fill the orbit with sponge or lint, neither of which can be of any use, unless they make compression, which is improper, if it can be avoided.

I have performed the operation five times, with little loss of blood, save in the last case, in which the hæmorrhage continued so long, that it became necessary to fill the orbit with sponge to suppress it. The patient recovered without a bad symptom.

The eyelids are to be closed, the external commissure, which has been divided, is to be supported by a strip of sticking plaister, and a light compress and bandage are then to be placed over the orbit. The patient should be put to bed, and an opiate given shortly afterwards. When the eyelids are diseased, and the extirpation of the contents of the orbit is still considered advisable, they must also be removed.

The after-treatment requires attention. The patient should be confined to bed until the inflammatory symptoms which may arise have been subdued, and suppuration has been freely established (when any sponge introduced into the orbit for suppressing hæmorrhage will be easily removed), and should on no account be allowed to go into the open air, until considerable progress has been made towards the completion of the cure. When symptoms of inflammation come on with great severity, they must be met by the usual corresponding means. In one case these were so violent as to render it necessary, during the first three days, to take away two hundred and fifty ounces of blood. The pain in the head was not, however, removed, although it changed its character: instead of being a throbbing pain, attended by a sense of fullness and tightness around the head, as if it were compressed or bound by an iron ring, or a hard rope, and accompanied by delirium, it became a sharp darting pain, fixed within the centre of the head, unattended by delirium, but rendered more



sensible on the slightest motion. The pulse diminished in strength and became softer, although equally frequent. It now appeared to me to depend on nervous irritability rather than on inflammation; and that narcotic remedies were indicated rather than further depletion; a drachm of the tincture of opium, given in an ounce and a half of the camphorated mixture, procured the patient some rest, and relieved the pain, which slowly subsided. The cure was soon afterwards completed without further accident.

#### ON CATARACT\*.

THIS disease has, from the earliest ages of medicine, been considered as an opacity in the internal transparent part of the eye, by which the rays of light are impeded in their passage to the seat of vision. Later observation has confirmed the fact, whilst it has at the same time proved the fallacy of the opinions entertained on the subject; and anatomy, in demonstrating the real nature and seat of the disease, laid a more solid foundation for surgical practice, and has enabled us to adapt it to each particular case with a certainty of success, almost as regular in the present day as it was doubtful in the hands of our predecessors.

Galen, and the ancient Greek and Roman physicians and surgeons after him, supposed the immediate seat of vision to be in the crystalline lens, and that through the diseases of this part sight was irremediably lost. When they saw this substance apparently lose its transparency and become white, when they perceived the opacity, from its vicinity to the pupil, either to be in the lens or immediately before it, they were confirmed in their idea; but when they saw from the rude operations then performed, and which were occasionally successful, that sight was sometimes restored, they soon found the

\* Γλανχωμα of Hippocrates; Καταρακτα, Τρόχυμα, of Galen; Suffusio of the Romans; Gutta opaca of the Arabs.



impossibility of maintaining the opinion of the lens being at the same time the seat of vision and of the disease which obscured or destroyed it; for they were fully aware, that during the operation something was removed from the axis of vision and depressed below the pupil. The restoration of sight satisfied them it could not be the lens; they referred not to anatomy, or to the examination of parts similarly diseased, to ascertain the fact; but by an effort of genius, which is always more ready to create than to observe, they relieved themselves from the difficulty, by supposing an adventitious membrane was formed by a deposition from the aqueous humour occupying the space behind the pupil, and forming as it were a veil before the lens. This supposition, which appeared capable of removing every doubt and of satisfying the most scrupulous inquirers, received so much additional support from the operations performed on what we now call capsular cataracts, and especially those formed after accidents in which a thickened membrane appears very obviously to be depressed, that it was considered and received as an established fact by succeeding ages.

The revival of learning, and the encouragement given to the liberal arts and sciences, could not fail to have a particular influence on the science of optics and the arts connected with it. These were cultivated more by philosophers than by professors of the healing art; it is to them principally that our additional knowledge in this branch of science is to be attributed; and it was among them that the first objections originated against the lens being the seat of vision. Kepler, in the year 1604, proved by experiments, that the crystalline lens, being a diaphanous body, was unfit to retain or reflect light, and that, so far from possessing the attribute of vision, it was only to be considered as a double convex lens, peculiarly adapted for conveying the rays of light in their passage through it to a focus or point at the bottom of the eye. The knowledge thus communicated was but slowly acquired by professional men, and more slowly applied to the considera-



tion of disease. The surgery of the eye was principally in the hands of persons who considered themselves only competent to understand one subject, and it was not to be expected they should attend to any collateral branches, which might even, in throwing light upon the object of their pursuit, bewilder the trifling powers of mind they acknowledged themselves to possess. The real nature and seat of cataract was only known to a few, who scarcely practised in this branch of surgery; and although it was privately noticed and publicly announced so early as the year 1651, it only became currently recommended in books treating professedly on the subject in 1707, when Antoine Maitre Jan announced the fact rather as a discovery of his own than as one that he was about to confirm by his observations; although he even supports his opinion by the following quotation: "*Plempius, a celebrated physician of Amsterdam, gave me the following explanation of the uses of the crystalline, in the fourteenth chapter of the third book of his Ophthalmographia, in which he says, 'Dicam ne vero etiam omnibus inopinatum quidpiam? aio enim vero crystallinum non nobiliori in oculo fungi officio, quam aqueum. Et exempto crystallino, oppletoque loco ab humore vitreo visionem nihilominus celebratum iri: verum non tam distinctè, quam nunc; confusa enim esset in retiformi pictura, nisi alio situ, quam quem nunc obtinet, retiformis locaretur.'*" This learned man was, however, unacquainted with the fact, that the crystalline could be depressed; for, in alluding to cataract, he adopted the ancient opinion, and could only have formed his own from an attentive consideration of optical phenomena, and not from practical experiment." The manner in which he became acquainted with the fact carries with it such evidence of its truth, that I will acquit myself towards his memory by giving it in his own words: "Having been informed the night before the death of a poor man in the hospital, that he had a cataract in one of his eyes, I removed the eye a short time after his death, and carried it home. On opening it, I observed that this cataract



occupied the place of the crystalline, and appeared to be that body itself; and, on scoring it with the point of the scalpel, it was distinctly proved to be the crystalline, but entirely altered in its substance. To determine the fact, I broke it up between my fingers, and it exactly resembled in appearance a healthy crystalline which had been infused in any liquor." He afterwards gives another case, on which he had previously operated with success, and in which he found, on examination, the crystalline lodged behind the inferior part of the iris; his attention having been first drawn to the subject in the year 1682, in consequence of observing a large, round, white, and solid body rolling under his needle, in an operation for depression, when he had only expected to find a thin membrane. The works of Brisseau (in 1709), Heister, St. Yves, Petit, and Daviel, in succession, completely established in surgery what Maitre Jan had advanced, and the different denominations which cataracts have since received followed, as soon as it was known what parts were concerned in the disease.

We find accordingly the distinction into true cataracts, or those which admitted of depression when that operation (then the only one) was resorted to, of whatever consistence they might be found to be; of false cataracts, when not admitting of perfect depression, and vision was not restored by the operation; and of doubtful cataracts, when the appearances partook of the nature of both. These were again subdivided according to the particular qualities or appearances they were supposed or found to possess. Thus we read of the hard or horny, the cheesy, the flocculent, the fleecy, the milky, the black, the stony, among the true cataracts; of glaucoma, protuberance of the crystalline, the tremulous or shaking cataract, and the abscess of the crystalline, among the false cataracts; of dryness of the crystalline and attachment to its capsule, of increase of size of the crystalline with thickness of its capsule, of a tendency to abscess or ulceration, among the doubtful cataracts. We find, besides these, a variety of other appellations, such as cataracts from forcible displacement of



the crystalline by external injury ; of spotted cataracts ; congenital cataracts ; membranous cataracts, from the formation of a new membrane behind the pupil ; the filamentous cataract ; barred cataract ; the starry or membranous cataract of the posterior capsule of St. Yves, or of the anterior capsule ; the interstitial cataract, or of the humour of Morgagni ; and the secondary cataract, or opacity of the capsule after previous operation ; the partial, or incomplete, when only a portion of the membrane is concerned ; lenticular, when the lens alone was supposed to be affected ; mixed, when the lens and capsule were diseased with diversity of substance ; complicated, when other parts were also implicated ; adherent, where the cataract adhered to the iris ; hereditary cataracts, where transmitted or common in families ; elastic cataract, dependent on thickness of the capsule and soundness of the vitreous humour ; and of encysted or hydatid cataracts, of a spherical form, in which a fluid is contained in an entire and opaque capsule, the lens being dissolved or absorbed ; capsulo-lenticular cataracts, when the capsule is opaque as well as the lens ; and the appearances the capsule sometimes assumes, have caused the later German ophthalmologists to add the distinguishing names of marbled or variegated, window or latticed, stellated, central and dotted, according as they considered they resembled the things which are understood by these different designations ; conical or pyramidal, when the protrusion of the cataract into the pupil affected that form ; siliquose, or husky, when it had a resemblance to a dried pea-shell ; purulent, or putrid, when accompanied by a small cyst of purulent matter ; and, lastly, the arborescent, dendritic, or choroid cataract, so named from a portion of the pigmentum nigrum adhering to the capsule of the lens, and on a casual or distant inspection, giving to it that blackness of appearance usually indicative of transparency.

Cataracts have also been termed ripe or unripe, with reference to their consistence and the proper period of operation ; but these terms are defective and illusory. By the



ripeness of a cataract it was intended to express that state in which it had attained a sufficient degree of firmness to admit of depression, or subsequently, of extraction as a solid body, or with little soft surrounding substance, or accompaniments. It was considered to be in a state of maturity when of a pearly colour, when the patient was only able to distinguish between light and darkness; after which period it was again supposed to become old, adherent, and complicated. By the unripeness of a cataract was understood its soft, incipient, or recent state, when the patient could still see objects in a moderate light, and when the lens was not sufficiently firm to admit of depression or extraction, without breaking up under the instrument; in which case it was generally of a whitish or milky colour. This opinion, founded on the hardness or softness of the cataract, as dependent on its duration or colour, is contradicted by experience; for cataracts of fifteen or twenty years' duration, and of a pearly colour, have been extracted perfectly soft; whilst others, of one year's standing and of a milky colour, have been found hard. Neither is the relative state of blindness, under these particular circumstances, a more just criterion; patients having been found almost entirely blind with a soft cataract, whilst through a hard one they could still distinguish objects and colours.

There is, however, a very important distinction, which is frequently neglected, between idiopathic or constitutional, and local or accidental cataracts; not, as in the previous case, referring to the change which has taken place in the structure or appearance of the lens, or to the manner of operating, but to the comfort and happiness of the sufferer. The idiopathic or constitutional disease affects in general both eyes, the local or accidental being more often confined, under proper management, to the organ which has been injured either by external violence or active inflammation.

The constitutional form of cataract is a disease we have it not in our power to prevent, not only from insufficiency of means, but from our being perfectly unaware of its approach-



ing commencement, until our attention is drawn to it by the symptoms attendant on its progress. It affects persons of all ages, but is more prevalent among elderly and old people, males rather than females, and is found in the foetus before birth. It occurs alike in persons of all temperaments, and has not been found to prevail in those of any known constitution, disposition, or idiosyncrasy; neither has previous disease any influence on its formation, unless where it has affected the part directly, or the eye generally, by particular and direct sympathy. Scrofula and syphilis have each been considered as assisting in its production; but I have not observed it, neither is it now generally believed to be the case, unless under the circumstances to which I have alluded, when the disease is no longer idiopathic. Scrofula, in the early part of life, affects the eyelids and the cornea with a peculiar kind of inflammation, which, from its characters and from general considerations of temperament and appearance, we usually call strumous; but this is rarely propagated to the interior of the eye; and the most careful investigators into this subject have not been able to discover, after the most extensive observation, that persons who have suffered from scrofula, or were still supposed to be liable to it, or even had a predisposition for the disease, were more subject to cataract than those who were considered free from it. Syphilis affects the iris with an inflammation, conceived by some persons to be peculiar to the disease, and, by contiguity, causes an adhesion to the capsule of the lens, producing opacity; but this is an immediate derangement of the part, the effect of which we can predict, and which occurs alike from inflammation not presumed to possess any specific character. It has never been shown, neither has any evidence been adduced to prove the fact of persons being more liable to cataract who had even suffered severely and frequently from syphilis; on the contrary, the general and equal appearance of cataract among females of all ranks in society, and the little comparative difference of its occurrence between the sexes, even including



the direct syphilitic affection, must be satisfactory to every reasonable man, that syphilis has no share in the production of cataract as a constitutional disease. Rheumatism and gout have both been supposed, and are now frequently considered to have some influence in the formation of cataract, but I place no reliance on this opinion; and admitting, as I do, their capability to cause disorganization when the inflammation attacks the eye, I deny their possessing any other power in promoting the appearance of opacity of the lens or its capsule; for repeated and careful investigation has not proved that cataracts are more frequent in persons who have suffered from gout and rheumatism than in those who have been exempt from these diseases.

The existence in some people of an hereditary predisposition for cataract, as well as for amaurosis, appears well ascertained; but we can in no way account for it any more than for predispositions for other diseases with which we are acquainted: it is fortunate, however, that the transmission from parent to child by no means seems so direct, or so regular as in several other complaints, especially as in consumption, gout, or scrofula; for, considering the numbers of persons suffering from cataract, but few instances are recorded of its prevailing in families to such an extent as to render it remarkable. Like other diseases, it may originate in one branch of a family, and affect in succession three or four generations, without attacking another branch springing from the same original root; in others, after continuing through two or three generations it ceases to afflict them; and sometimes it attacks only the males, whilst the females are exempt, or vice versâ. In amaurosis, I have seen the same thing occur; and in one instance, all the females of a family were attacked at a certain age, whilst the males remained exempt. Janin mentions a whole family of six persons suffering from cataract; and Morgagni, Petit de Lyon, Richter, Stevenson, Saunders, all attest the fact; and as far as observation has hitherto gone, the cataracts, when congenital, generally preserve the same



character, being all either capsular, lenticular, white, dark coloured, &c. ; and we find that the children are, for the most part, affected in a succession of pregnancies, rather than by intervals, after the irregularity has once occurred.

The influence of the constitution in the formation of idiopathic cataract is beyond our means of detection; we can only acknowledge the fact of such an influence existing, and observe the effect, which is *in general* not confined to one, but extending to both eyes, and with such regularity, that few people, who suffer from this complaint in one eye, escape, after a time, the disease in the other; the period between it, in both, is various; occasionally it commences at the same time, although in general one eye is first affected, the other subsequently following the same course; more rarely the second one becomes affected after a considerable interval; whilst few persons live to an extreme old age, having had a cataract in one eye, without having it also in the other. The prognosis, then, in constitutional cataract, as to the probability of one eye escaping, the other being affected, is extremely unfavourable.

The reverse holds good in local or accidental cataract, and this might reasonably be expected from a consideration of the causes which produce the disease. In constitutional cataract, the cause, whatever it may be, we must suppose, consistent with our general belief on these points, to act on both eyes nearly at the same time, whether it be through the medium of the nervous or sanguiferous systems; whilst, from local or accidental circumstances, it may be more particularly directed to one. In local or accidental cataract there is no general predisposition; indeed, there may be so little injury committed, that the organ would seem to be almost unconscious of it\*. If inflammation follow the injury, there may

\* If a fine round-pointed needle be introduced through the cornea and the capsule of the lens punctured, the lens will become opaque without any apparent internal inflammation. This has occurred in evacuating the aqueous humour, yet no increase of inflammation ensued.



be, and there generally is, great sympathy between the eyes ; but this, in many cases, only shows itself by an increase of sensibility, although, occasionally, it soon amounts to direct inflammation, which has even been known to alternate from one eye to the other for several times in succession. But this is a sympathy resulting from and terminating in inflammation. If the sympathy be moderate, the symptoms of inflammation will be trifling and apparently external ; if more intense, the proper tunics of the eye may be implicated, and cataract and closed pupil, or rupture of the eye, the result ; but in this instance cataract is produced by extension or intensity of inflammation, which is always capable of doing it ; but it has rarely been observed, that a person having received an injury of the lens of one eye, should have the sound one immediately, or even shortly (within the usual acceptation of direct sympathy), affected by opacity of the lens alone, without accompanying signs of inflammation, or in the same manner as the disease appears in one eye after the other has been affected by the constitutional disease.

I am fully sensible of the great sympathy which exists between the eyes after an injury has occurred to one ; I am quite aware that it is a very common circumstance for the second eye to be lost after the first has been destroyed by external violence ; but this is a sympathy of inflammation attacking the proper coats of the eye, which ought always to be expected, may frequently be prevented by proper treatment, and generally cured even when it does take place.

When consumption occurs from constitutional causes, or with strong hereditary predisposition for the disease, on dissection, we find the lungs on each side affected, tubercular, and suppurating ; while, in general, on one there are several vomicae, or abscesses, denoting a greater extent of mischief. Rarely indeed is one lung to be met with free from disease, when the patient has been destroyed in consequence of the formation of matter in the other. On the contrary, when a



healthy person, free from any predisposition for consumption, suffers an injury of the lung on one side, in consequence of which matter forms and he is ultimately destroyed by it, it is frequently found, on dissection, that the other lung is perfectly sound. I examined the body of a soldier, who died at the York Hospital, who had received an injury in the chest with a lance at Waterloo, which caused the destruction and absorption of the left lung, the pleura costalis having attained the thickness of an inch, the whole of the cavity on that side being full of pus. The right lung was perfectly sound.

Observation has confirmed in regard to local cataracts what reasoning had presumed; persons have been found to suffer from them for years without the other eye being affected; and I suspect that in most cases where cataract is formed early in life, and continues without implicating the other eye, it has been of this nature; I therefore consider there is a great probability of the sound eye escaping the disease.

#### ON THE SYMPTOMS AND APPEARANCES COMMON TO THE VARIOUS KINDS OF CATARACT.

The general symptoms of cataract, both in the idiopathic and accidental diseases, resemble each other at one period of the complaint, yet are of course essentially different in the first instance. In the accidental formation of cataract they are well remarked and defined, as being principally *external*, or *visible* to our senses. In the idiopathic cataract they are at the same period of formation, and for a considerable time afterwards, for the most part *internal* or *occult*, being invisible to observers, and dependent upon the patient's own perceptions, until such time as a change in the structure and transparency of the lens or its capsule has taken place, which may be discovered on a careful inspection.

When persons are about to suffer from idiopathic cataract, they generally complain of a little weakness of sight, which renders them unable to see objects at as great a distance as



formerly; this in a short time increases, so as to render near ones more confused, a greater degree of attention is required to fix and distinguish them accurately, and even then they appear through a mist, or as if seen through a transparent yet turbid fluid, or a glass which has been breathed upon. This indistinctness of vision is constant; no change or rubbing of the eye or motion of the head gives relief, while the patient remains exposed to the same degree of light; but on darkening the room the sight is in some cases, and especially at an early stage, considerably improved, although there is still a central cloud or smoke which cannot be overcome. This advantage is gradually lost in a moderate light, and the patient finds that he is obliged to bring every object nearer his eye to distinguish it correctly, whilst it is often more readily seen from one side than when placed in the axis of vision: he sees best in twilight, when the pupil is most dilated, especially if the opacity be central; and, for the same reason, vision is improved by turning the back to the light; or, in the early stages of the disease, by using clouded glasses, which act in the same manner. On looking at a lighted candle, the flame does not appear as clear and distinct as usual, but seems as seen through a mist and surrounded by a halo, or burr, as it is sometimes termed in the North of England; which, when the disease is not complicated with an affection of the retina, is always white or clouded white, and not of various colours, especially either red or blue, or intermixed with what the patient terms flashes of light. This white halo becomes also broader, and the object more indistinct, as it is further removed from the eye. These defects increase with greater or less rapidity, the form of objects is lost, their shadow can, however, be observed between the eye and the light, and the patient is at last only able to distinguish between light and utter darkness, or he may be entirely deprived of every sensation, without having suffered any pain. These essential internal signs are frequently accompanied by others which are not so diagnostic, and which more often appertain to other diseases



or derangements. There is frequently an appearance of black specks, of dust, flies, or cobwebs floating before the eyes; flashes of light sometimes dart across them; the candle seems surrounded by burning circles or rings, of divers colours; or a dull pain is felt above the orbit, or at the bottom of the eye; but these symptoms are rather dependent on derangements of the retina or other parts of the eye than of the lens itself; they are not essential to cataract, are with dulness of vision incidental to many complaints, and indicate, when accompanying cataract, the existence of other disease.

The essential external signs of cataract are infinitely more decisive, inasmuch as many of them are peculiar. In constitutional cataract they may, I believe, be said invariably to follow the internal ones, and the indistinctness and dulness of vision have existed some time before an alteration of structure can be detected in the eye, rendering the diagnosis difficult in many cases, at an early period, between cataract and the mild incipient amaurosis. In a short time, however, the change becomes apparent on a careful examination, a slight general haziness or muddiness may be discovered, which is often of a deeper shade towards the centre in the situation of the lens, giving the back part of the pupil an appearance as if seen through an opaque or muddy substance. The iris is sometimes slightly dilated in a moderate light, compared with the healthy eye of another person; the pupillary edge, especially where the disease is a soft cataract, puts on a darker appearance, as if it were surrounded by a narrow black ring, which is in fact the posterior edge of it, pushed forward in consequence of the increasing size of the lens. If the dilatation be increased to its full extent, by the application of the extract of belladonna, an internal blacker circle will be seen to surround the turbid or muddy part behind the iris, and the patient sees better for a short time than he did previously to its application. The partial loss of transparency soon increases to a state of opacity, proceeding, for the most part in the same manner, from the centre progressively to the



edge of the lens ; the jet black colour of the pupil is lost, and the space behind the iris is occupied by an opaque body of various shades of colour, from grey to silvery or dead white, to yellow, brown, or a shade approaching to dirty black.

In other cases, the commencement of the opacity is not perceived in the centre, which is perfectly or nearly transparent ; but two or three spots may be discovered, in various parts, of a different colour to the rest, and partaking generally of a white colour, and the opacities of which are only made perceptible by the transparency of the rest of the lens, which enables the observer to see between them to the bottom of the eye. These sometimes give rise to certain *fixed* specks or objects, noticed by patients in the early stage, as remarkable even before the general dulness of vision : they soon increase in size and opacity, the whole lens or its capsule partakes of the derangement, and the same appearance is produced behind the pupil as in the former instance. In local cataract these appearances are co-eval with or precede the internal symptoms.

The appearance of the iris is of considerable importance, both as to diagnosis and prognosis : it frequently suffices to distinguish the constitutional from the local cataract, and to mark the complication of disease which may render an operation unadvisable, useless, or improper. The association or sympathy between the eyes is so strong, that the motions of the iris of one eye involuntarily follow those of the other ; and if we examine the affected eye, whilst the healthy one is exposed to the same light, we shall have, in all probability, an action of the iris sympathetic with that of the healthy eye, rather than dependent on its own susceptibility for stimuli ; whence the rule of covering the sound eye under any examination or performance of operation on the diseased. The iris is usually described as a curtain placed before the retina, possessing muscular or contractile powers, for the purpose of dilating or contracting the pupil, and having its sensibility for stimuli so harmonized with that of the retina, that it con-



tracts or dilates according to the greater or less degree of intensity with which light is thrown on that membrane. The great contraction of the pupil in a very vivid light, its proportionate dilatation in partial darkness, together with its general state of immobility and dilatation, when the retina is altogether insensible, seem to demonstrate its use, and have given rise to the opinion, that the motions of the iris were regulated by the susceptibility of the retina for external impressions, and that the state of the iris, when uninfluenced by sympathy with the sound eye, was an index of the state of the retina; that a motionless and dilated iris indicated an unsusceptible retina; a moveable and contracted iris, a healthy state of that membrane; the intermediate actions pointing out different shades of derangement. If this opinion had been found critically correct, it would have been an invaluable test of the state of the retina, and a certain guide as to the expediency of operating in many complicated cases; but unfortunately this is not the case, for although the motions of the iris do accord with the susceptibility of the retina, whilst both are in a healthy state, they differ materially when either membrane is diseased. We find, for example, that in many cases of complete amaurosis, the motions of the iris continue, on exposure to the light, as if influenced by it, and independently of any sympathy with the retina; whilst, in mydriasis, the pupil remains nearly immoveably dilated, although the retina is perfectly sound and exposed to the strongest light.

The motions of the iris are influenced in three ways essentially differing from each other; one by the direct stimulus of light, and two by sympathy, first, with the retina of the same eye; and, secondly, with the iris of the other eye: all of which deserve particular consideration.

The susceptibility of the iris for light seems, during health, to be on a par with that of the retina; and in sleep light is excluded from the retina and the iris by the closing of the eyelids, and the pupil is partially dilated; if a strong light be thrown on the eyelids, the pupil contracts, the retina be-



comes sensible of the stimulus, and the person frequently awakes. Under disease, the susceptibility of both may be increased or diminished; but whether it be in excess or by diminution, it may be accounted for by the different origin of the nerves of these parts, which seems to point out the reason why there should be frequently two different states of susceptibility, one set being diseased and the other not, or only in an inferior state of derangement. The sympathy of susceptibility is, however, infinitely greater between the retina and the iris than between the iris and retina, whether it be from what is professionally termed sympathy, or from parity of disease affecting the origin, or referred to the sentient extremities, of both sets of nerves; the healthy state of the iris *generally* being a good, although not an unerring index of the healthy state of the retina; whilst a diseased state, or loss of function of the iris, by no means indicates, although it may lead to a suspicion of, a diseased state of the retina. I some time back operated for artificial pupil on the right eye of a man who had been blind twenty-two years; no light being transmitted to the retina, and yet at the end of that time it retained its susceptibility for impressions, and the patient can now see to read very well.

It is on the integrity of the healthy susceptibility of the iris for light, and not of the retina, that the contraction and dilatation of the pupil depends in cases of cataract; that a patient suffering from incipient cataract sees best towards evening, or in a moderate light, in consequence of the dilatation of the pupil allowing the rays of light to pass on to the retina through the edge of the lens, which is not so opaque as the centre, and is exposed by the enlargement of the pupil. It is in consequence of the light passing through this edge obliquely, that persons suffering from cataract often see better when they place objects to one side. We endeavour to produce this effect by the application of the belladonna, which causes the pupil to dilate, and allows the transmission of light in the same manner to the retina, which, in general, remains unaffected by it; for, if it were equally under the influence of



the application, the patient would not see although light fell on the retina. I have met with several instances of persons using belladonna for months with evident advantage; but still it is a fact equally deserving attention, that in some instances the belladonna seems from the first to paralyze the retina as well as the iris, the sight being either destroyed or rendered much more indistinct until the effect of it had ceased. When given internally and in large doses, it not only influences the motions of the iris, the ciliary and the optic nerves, rendering vision very indistinct, or even destroying sight, but all the nerves of the face connected with the organ of vision; whence its efficacy in some cases of *tic douloureux*, as well as in other painful affections of parts around the orbit, and of the body generally, when applied externally in the form of plaister; a practice I have adopted for the last nine years at the Infirmary, with great success.

The motions of the iris are not, however, to be disregarded, as indicative of the state of the retina. A proper degree of sensibility generally implies a correspondent state of the retina, and the ready and quick contraction of the pupil, on any sudden exposure to light, is a favourable sign; whilst immobility of the pupil does not deprive us entirely of hope, operations having been performed with a restoration of sight, after this symptom had been present. It is usually supposed, that the round form of the cataract, in preventing the ingress of light to the retina, may in these cases be the cause of the immobility of the pupil; but as I have considered the iris as having a sensibility of its own, independent of the retina, although generally sympathizing with it, we cannot include this as a sufficient cause. The immobility of the iris may, however, be dependent on the form and state of the lens, although not on its permeability by light; and this is an object of great importance, and requiring the closest attention. The motions of the iris may be prevented, and it may remain fixed and dilated, or fixed and contracted, in consequence of adhesions formed between it and the capsule of the lens; or it may be fixed and dilated, in consequence of pressure



from the lens and parts behind. The diagnosis in these cases is of consequence, and may in general be duly formed by a little attention. In the natural and healthy state of the eye there is a space between the capsule of the lens and the posterior part of the iris, which has received the name of the posterior chamber of the aqueous humour, by which fluid it is filled. This space is demonstrated in the dead body by freezing the eye, when the layer of aqueous humour between the capsule and the iris is readily perceived. Into this space the needle is first passed in the operation for cutting up a cataract, and into it the iris is folded towards its greater circumference, when dilated. The distance between the capsule of the lens and the iris is perhaps better estimated by repeated observation on the human body, in health and under disease, than by measurement.

When the iris is insensible from deficiency of susceptibility for light, whether natural, or acquired by sympathy with the retina, this space is preserved; the distance between the edge of the pupil and the lens is perceived, and appears to be more or less natural according to the state of dilatation, which must be taken into consideration. If the belladonna be applied, the pupil becomes fully dilated, and the capsule exposed in nearly all its extent; it is often long in returning to its natural state, and it is even possible the pupil may remain partially dilated, but always preserving its circular form. If the immobility of the pupil depend on adhesion between the capsule of the lens and the uvea, or posterior part of the iris, it may be suspected from the diminution of the natural space between these parts, by the irregular appearance of the edge of the iris, and by that of the capsule of the lens; it will be proved, and the attachments shown, by forcibly dilating the pupil by the application of belladonna. Immobility of the iris, and especially in the contracted state, is generally the consequence of previous inflammation; it is therefore a local disease, and implies nothing with relation to the retina beyond what we may calculate upon as the effect of inflammation. The iris is generally irregular and puckered; there is no space



between it and the capsule ; the one adheres to the other ; the capsule is always opaque and white, although in a greater or less degree of intensity ; and on the continued application of the belladonna, the iris becomes more irregular, if it yield at all, and then shows more marked points of attachment. If the iris be not contracted, or even if it be rather dilated, it always shows the edge of the pupil of a darker colour ; and, on the application of the belladonna, it dilates and becomes irregular at the points of attachment, which are then conspicuous. In cases of cataract of long standing, it is possible that adhesions may be formed between the capsule of the lens and the iris, from the simple increase of the lens causing it to press against the iris, or from slight irritation ; but in these cases the pupillary edge will seldom or never preserve its natural colour, although it may remain unaltered in shape, whilst the iris may be very sluggish or nearly motionless ; but the fact of attachment may be readily proved by the application of the belladonna, and a surgeon is highly reprehensible who does not dilate the iris by it some time before he operates, even if he be certain there is no attachment, because it is the only way in which he can acquire a full view of the surface of the cataract, and in many cases obtain information as to its nature.

Immobility and dilatation of the iris, when not of the first kind, in which the size or depth of the posterior chamber is obvious, may arise from the pressure of the lens behind without any attachment to the iris. In this case the cataract is immediately in contact with it, sometimes even appears to protrude through it, the black ring round the pupil is well marked, and on examining the eye from one side, the iris may also appear protuberant, its natural plane surface is lost ; when the true state of the case is evident, the application of the belladonna will cause a dilatation of the pupil, but it may not be able to return completely to its former state of contraction from the continued pressure of the lens.

Immobility of the iris is not a sign in cataract of paralysis of the retina, especially where there are attachments to the capsule of the lens ; because there is a local cause for its re-



maining immoveable ; but, where the space of the posterior chamber is entire, or the iris does not seem to be dilated by the pressure of the lens, it is a most unfavourable symptom, and when combined with a total impossibility of distinguishing the shadows of bodies, or of light from darkness, it nearly amounts to a prohibition of the operation, which ought on no account to be performed, if it be accompanied by pain in the eye, orbit, or forehead, or with flashes of light shooting through the eye, which indicate amaurosis, or approaching disorganization. When the immobility of the iris only marks its want of sensibility, and the patient can readily distinguish light from darkness, there is good authority for performing the operation ; and it is right to attempt it, where the patient has suddenly been deprived of that power from inflammation, because it may have occurred in consequence of adhesions. But if it have suddenly occurred, the pupil remaining of its natural size, or being dilated, there is little or no hope of success, and particularly if both eyes are affected.

Dilatation of the pupil may occur as an idiopathic disease, or not symptomatic of any affection of the retina, which remains in all its integrity of power, when it is termed mydriasis. The iris is completely dilated and insensible to any degree of light, the pupil remaining clear ; sometimes a slight haziness may be distinguished behind the seat of cataract, apparently in the vitreous humour, disappearing or changing its situation according to the different motions of the eye, and depending on the refraction of light, and not upon any opacity of the lens. The free access of light causes great inconvenience ; objects are seen invariably smaller and in a very confused state, except in the shade and in partial darkness ; but if the natural contraction of the iris be imitated by placing an opaque body close before the eye having a very small hole cut in it, sight is then restored, and the functions of the retina seem unimpaired, which is perfectly diagnostic of the disease from amaurosis. In mydriasis, the pupil momentarily contracts on the application of stimulating substances,



such as a strong infusion of tobacco, by electricity, or by rubbing the eye forcibly; which does not occur in amaurosis: and in mydriasis the disease has not been observed but in one eye at a time, whilst in amaurosis both are for the most part affected.

The second sympathy of the iris, or with the iris of the other eye, often exists when that with the retina and its susceptibility for the stimulus of light are destroyed. I have a good instance of this in the left eye of a man, who has suffered a severe attack of choroid inflammation. He is completely blind, so as to be incapable of distinguishing light from darkness; the iris is slightly discoloured, the pupil is black and of a moderate size, and remains unaffected by the stimulus of light when allowed to fall upon it alone, although it is enlarged or diminished according to the motions of the iris of the opposite eye. When the sound eye is covered, the pupil of the diseased one is immediately dilated to a moderate extent, and remains in that state, and immoveable, even under the influence of the full glare of the sun. But if the sound eye be uncovered and exposed to the same degree of light, both pupils are instantly contracted. If a cataract were to be formed in this case, the state of the iris might escape detection, unless carefully inquired into when the sound eye was closed.

The iris must also be examined as to the correctness of the manner in which its motions of contraction and dilatation are performed. In the natural state of the eye, the iris is a perfect plane, not protruding forwards or slanting backwards, and is without folds or plaits. A deviation from this appearance indicates derangement, in consequence of pressure from behind, or of its own structure, either of which may influence the mode of operating, as will be hereafter mentioned. The plane of the iris is preserved by a due degree of pressure before and behind, anteriorly by the aqueous humour supported by the cornea, and posteriorly by the quantity of the aqueous humour contained in the posterior chamber sup-



ported by the peculiar firmness of the crystalline lens. In this space the iris moves, displacing from one part to another the aqueous humour, as it either dilates or contracts; but this is accomplished with such precision, and the balance of pressure appears to be so little disturbed, that the iris performs these motions without any vacillation apparent to our sight, a fact of great importance as a diagnostic sign of a lenticular cataract; for it appears that it is mainly on the presence and consistency of the lens that the equilibrium of pressure depends, and not on the fulness of the eye; for the increase of aqueous, or of vitreous humour, the lens being removed, or even dissolved in its proper capsule, will not answer the purpose, the iris obtaining under these circumstances a tremulous motion, indicating the absence of the lens. This circumstance is frequently attributed to dissolution of the vitreous humour, which is also capable of giving rise to it; but I am satisfied it is not the most common cause in cases of cataract; for, in all those on which I have operated with restoration of sight, when this sign was present, I have found the cataracts to be capsular, the lens having been absorbed or become fluid. In these cases previous pressure on the eye with the point of the finger had convinced me, by the resistance it met with, that the vitreous humour was of a proper consistence; and in two cases in which I operated by an opening in the cornea, a sufficient quantity of the vitreous humour escaped in removing the capsule to enable me to ascertain the fact, and to convince me of the propriety of the opinion I have formed as to the cause of such appearance. In all cases of cataract, then, pressure should be made on the eyeball with the finger, to ascertain the degree of consistency of the vitreous humour; if thin and watery, the eye will yield to it, and the iris will acknowledge the pressure in a very decided manner, when the disease is advanced to the tremulous state I have alluded to, and which is best seen under general motion of the eye exposed to great variations of light and shade\*.

\* These remarks on the motions and sympathies of the iris have formed a part of my lectures, and have been publicly delivered at the



The information now to be gained from an examination of the cataract itself is of great importance, its situation with regard to and influence on the iris having been previously estimated. It must be borne in mind, that, independently of those complications in which disease first begins in the vitreous humour or deep-seated parts of the eye, and which have particular symptoms, the disease may begin and consist in an opacity of the lens of the anterior or posterior capsule, of each alone, or of all of them in different states of combination. The distance from the iris to the bottom of the eye, to the posterior capsule of the lens, and the thickness of the lens itself, must be computed by the surgeon whilst examining the eye; and if the pupil has been dilated, by attending to the general appearance of the whole, he will readily ascertain the existence, the seat, and the extent of the opacity, and consequently of the disease. He should at the same time endeavour to ascertain the changes of structure, or quality, which have taken place, from the appearances which the part has put on, and which is the most difficult discrimination of the whole. Scarpa, whose accuracy, fidelity, and extent of observation, during more than half a century, few will doubt, says, page 319, "It is not equally easy to pronounce concerning that which regards the other part of the diagnosis, that is, whether the cataract be hard or soft, caseous or fluid; and whether, together with the opacity of the crystalline lens, the capsular membrane which envelops it be also opaque. All that has hitherto been written and taught upon this subject has not that degree of certainty which can serve as a guide in practice; and the most experienced oculist of the present day is not able to determine with precision what the nature and consistence of the cataract is, upon which he proposes to operate; nor whether the capsule be yet transparent or not, although the lens

Infirmaries twice every winter for the last nine years, independently of the necessary recurrence to them on many other occasions, in pointing out the symptoms diagnostic of cataract from other diseases. The Baron Larrey in France and Mr. Shaw in London have since published a part of them as peculiar to their observation.



be evidently opaque." In this opinion he is supported by all the oculists in Europe, with the exception of Sir W. Adams \*, who, in commenting upon this observation, says, "In this opinion the learned Professor, I must observe, is certainly mistaken; for, although I admit that no verbal or written description can convey to an inexperienced practitioner an accurate idea of the various kinds and shades of cataract, yet repeated observations will teach it to such an extent, if the operator has sufficient opportunities for making them, that an oculist of just and accurate observation will rarely be deceived in his opinion of the nature of the cataract upon which he is about to operate." It is a distinction without a difference. Scarpa does not deny advantages to be acquired in discrimination from repeated observation; he simply states that *precision* is not attainable; Sir W. Adams allows that errors may occur, although "rarely." If there be a difference, which I do not perceive, the members of the profession, to whom both gentlemen are well known by their publications, must rely upon the opinion of him in whom they place most confidence, and which accords most with their own observation. Scarpa, however, page 337, thinks much corroborative information may be obtained from the state of the patient's general habit, and considers it as a well-established fact, "that in persons of an unhealthy habit of body, the cataract is generally soft and caseous."

The true state of the question seems to be, that although there are characteristic marks by which certain kinds of cataract may be always distinguished, there are still some which may be mistaken; and he who attends most, not only to individual signs, but to the general aspect and the assemblage of symptoms and appearances, will, in all probability, although sometimes in error, still for the most part judge correctly of the nature of the disease.

Cataracts have been described of various colours: yellow, blue, brown, black, of a pearl, iron, silvery or milky colour, speckled, striated, barred, &c. Of these, as two great out-



lines, the pearl-coloured, yellow, and brown, may be considered as indicating a hard cataract ; while the white, milky, or striated, rather point out a soft cataract ; but the milky colour of a cataract is by no means a test of its solidity ; many, perfectly white and supposed to be soft, having, after extraction, been discovered to be hard ; and the pearl-coloured, on the contrary, have been found to be soft. Neither does the colour after extraction always correspond with the colour observed before the operation, being sometimes much darker. The size of the cataracts is a better sign of their nature than their colour, it having been found, that the smaller the lens and the darker its colour the more solid was its substance, except, perhaps, where there appears to have been some defect of organization or growth from early life ; in which case a soft bluish white cataract, with a striated capsule, will often be observed, when the pupil is fully dilated, to be seated on the vitreous humour, and surrounded by a black transparent ring, the consequence of the deficiency of size of the lens and its capsule. The larger and more protuberant the lens, pressing forwards even into the pupil and against the iris, the greater is the certainty of its being soft.

#### DIAGNOSIS OF MUSCÆ VOLITANTES.

By *muscæ volitantes* are understood a variety of appearances moving before the eye, such as small threads or filaments assuming the form of worms, zigzags, or spots of greater or less dimensions, but generally small ; little globules or webs, or luminous spots sometimes surrounded by a halo, which always move before the eye, and are never FIXED.

These are most readily seen on raising the eye quickly from the ground towards the sky, when they appear to ascend whilst the eye is in motion, and to descend on its becoming fixed steadily upwards, as if they had been disturbed from, and were returning to their original situation below the axis of vision. Of the different kinds of *muscæ volitantes*, the filamentous



particles, turning and twisting in various directions, are the most common ; two or three of which are generally more conspicuous than the rest, although accompanied by an infinity of others less distinguishable, intermingled with small globules, which fall like a fine mist when the eye has been gently raised and fixed on a white wall, or on the sky on a clear day. The filamentous particles, being apparently the lightest, descend the last, assuming the appearance of twisted semi-transparent tubes, or worms, spotted in different places.

In the evening, or by candlelight, these spots are scarcely to be observed ; they are not very perceptible in a room which is rather dark, are but imperfectly seen when looking at the flame of a candle, and but feebly marked when the eyes are raised to the sky, with the lids shut, on a fine clear day. They appear much more brilliant on a clear or bright day, when the lids are half closed ; they are also very distinct on a misty day, or when attention is paid to them in light reflected from water or snow. These spots always appear to sink below the axis of vision by their own weight when the eye is simply turned upwards ; and this opinion seems to obtain great support from their falling and collecting, as it were, into a focus in the axis of vision, when this point is made the most dependent by bending the head forward and looking on a white sandy soil. In this way the patient can readily examine them ; or by lying down in the open air and looking at the sky, with the head and eyes turned back, they will be found to ascend and lodge themselves in what is the upper, but, in that position, the most dependent part of the eye.

If a filament is examined, by placing before the eye a sheet of paper on which a strong light is thrown, when it appears to be about the sixth of a line in diameter and an inch long, it will be magnified to two lines in diameter and a foot in length if examined against a white wall twenty or thirty feet distant ; so that it seems, to a certain extent, to be magnified according to the distance from the object against which it is



inspected. But it is not every one who is able to make these observations, and few can cause the appearance of the spots at pleasure, until they have been long accustomed to their casual production.

These phantoms have been attributed to an insensibility of some fibre of the optic nerve \*; to a varicose state of the vessels of the retina †. Others, satisfied that if they depended on either of these causes, the spots must be FIXED, or always seen in one place, have attributed them, with La Hire ‡ and Le Roi §, to some defect in the aqueous humour; and others, with Morgagni ||, have supposed the yarose, in some instances, from an inspissated portion of the tears and lachrymal secretion adhering to the cornea in their passage over the eye. The latter opinions are, however, subverted by the simple fact, that, in some very rare cases, these spots increase, forming a mist, which becomes less and less moveable, and are at last followed by opacity of the lens. In others, these spots may be seen for several years, whilst a portion only of the lens becomes opaque, either in its posterior half or in parts; and the integrity of the aqueous humour in these cases has been demonstrated by puncturing the cornea and evacuating that fluid, without any amelioration of these symptoms.

From a consideration of these circumstances Demours ¶ has concluded, and with a great probability of truth, that these appearances arise from small portions of the humour Morgagni, which, without losing their transparency, have acquired an increase of density, weight, and refractile power\*\*.

\* Willis, *Cerebri Anat.* cap. 21.

† Pitcairn, *Theoria Morborum Oculi*, page 14.

‡ La Hire, *Mémoires de l'Académie*, tome ix, page 571.

§ Le Roi, *Histoire de l'Académie*, Année 1760, page 53.

|| Morgagni, *Animadvers.* 75, de *Causis Punctarum*, &c.

¶ Demours, *Traité des Maladies des Yeux*, page 409 et seq.

\*\* The existence of the humour Morgagni may be demonstrated in the eye of a sheep, in the following manner: cut away the cornea, remove the iris to one side, and wipe the capsule of the crystalline



The principal diagnostic mark of these appearances is their *mobility*, which distinguishes them in a very decided manner from the fixed spots often perceived in the eye, and which depend on opacity of the lens, or a defective state of the retina. *Muscae volitantes* are incurable, seldom pass a certain point, and when the patient is assured of their not proceeding further, appear to be lost sight of, and to give no inconvenience, unless when the attention is directed to them. They are very rarely followed by cataract or amaurosis, and it is a great consolation to the patient to be assured that they are not dangerous.

#### DIAGNOSIS BETWEEN INCIPIENT AND CONFIRMED AMAUROSIS AND CATARACT.

The incipient amaurosis is occasionally accompanied by some of the symptoms attributed to *muscae volitantes*; but one or more of the spots will in general be found to be fixed, of a darker colour, and permanent, whilst a general indistinctness of vision takes place and increases. This is in other persons only discoverable at first, after a steady application of the eye to a particular object, when the sight is suddenly found to fail altogether, but returning again after resting the eye; or the patient describes himself to have suffered the loss of half of his sight, so as to be able to see only the half of an object; both of which states are for the most part accompanied by more or less pain in the forehead, temple, or eye. These changes are sometimes periodical. The sight is not improved by the use of spectacles, or by the application of the belladonna, seldom by viewing an object sideways, or to the right or left of the direct axis of vision, which it is in the early stages of cataract. Flashes of light, or white and brilliant circles, or

dry. Then plunge the point of a lancet into it, and a small drop of this humour will flow out, although it appears to lose its fluidity in some instances after death, and to diminish in quantity as we advance in years.



luminous spots, equally indicate amaurosis; and the change in the colour of the flame of a candle from white to yellow, or red, or green, is also demonstrative of that state; in which the patient occasionally sees, when the eye is closed during the night, luminous circles of different colours. The halo which is observed to surround the candle in cataract, of a white clouded colour, is, in amaurosis, of a bright yellow, or red, or green, the colours being more confused as the object is more distant. The cornea, in the incipient amaurosis, is scarcely altered from its natural state; but, at a later period of the disease, it evidently loses its perfect transparency and clearness, and becomes rather turbid or dull in appearance. The iris is at first sluggish in its movements, or the pupil has even begun to be dilated; at which period little or no change can be observed either in the lens or vitreous humour; but as the disease advances the pupil becomes more dilated, the edge of the iris loses its regularity, the pupil is no longer round, but irregular, or angular and fixed. In that form of amaurosis, in which the actions of the iris and the motions of the pupil remain unaffected, no opacity is perceived behind the pupil which can be mistaken for cataract. The cloudiness which occurs in amaurosis is always distant from the iris, and is for the most part accompanied by a general change in the appearance of the lens and vitreous humour, which no longer seem to be of a perfectly jet black colour, but are changed so as to allow the bottom of the eye to be seen through them, of a pale greenish or horn colour, giving to the whole somewhat of the same hue. The cloudiness observed behind the pupil is deep-seated, and on a careful examination in every direction, particularly sideways, may be observed to have a concave appearance, dependent on the form of the posterior part of the eye. If a particularly opaque spot can be observed, when the pupil is completely dilated, it will appear of a greenish or reddish-green colour, but not grey as in cataract; and by changing the position of the eye, it will be found to change its place also, being caused by the refraction of light, and not by any



permanent opacity. The eye will frequently be softer than natural, in which case the motions of the iris may be tremulous; the vitreous humour will then be thinner than usual, or even be dissolved.

If these symptoms have been preceded by great and protracted excitement of the nervous system, followed by general debility and languor of the whole body, and especially of the digestive organs; or are the consequence of the abuse of spirituous liquors; or occur after epilepsy or internal inflammation of the eye; or follow injuries of the supra-orbitary nerve; the disease is more marked and less curable.

#### DIAGNOSIS BETWEEN GLAUCOMA AND CATARACT.

The disease termed glaucoma consists essentially in an alteration of the component parts of the vitreous humour, accompanied by derangement of structure of the hyaloid membrane, of the retina, and tunica choroidea, the vessels of which are always more or less in a varicose state. The lens is generally at last implicated, although the disease may exist for a considerable time without any visible alteration in it. It is never primarily affected. When the disease is fully formed, so as to be confounded with cataract, or to render a diagnosis necessary in order to prevent a useless and dangerous operation, the symptoms are as follow. The eye has a general unhealthy appearance, arising from a turbid state of the cornea, which has lost its brilliancy, although in no one part has it become opaque. The sclerotica does not preserve its natural appearance, being either more of a bluish or yellowish colour, whilst several tortuous dark red vessels may be observed, especially on the under and upper part of the eye, which do not run on to the cornea, but penetrate the sclerotica at a distance not exceeding the eighth of an inch from it, and sometimes less, giving rise, when they are numerous, to the appearance of a white ring or circle situated between them and the cornea. They are varicose vessels, coming from within



the eye, and intimately connected with varicosity of the vessels of the choroid coat ; and as that state of disease increases, they assume a darker red or blue colour, become larger and more tortuous, often communicating with each other where they penetrate the cornea, forming also a sort of vascular ring, exterior to the bluish-white one already noticed. If the eye is examined by the touch, it will be found rather firmer or harder than natural.

The iris, if only one eye is affected, differs a little from its natural colour : if formerly blue, it has now become grey ; a black iris changes to a dirty brown, but this alteration is of no consequence compared with the state of the pupil, which is dilated, unless inflammation of the iris, which is not an essential characteristic of the disease, has been superadded to it. The dilatation of the pupil is always accompanied by a marked irregularity of its edge, sometimes rendering it angular, whilst it is always perfectly fixed or immoveable, and occasionally drawn to one side, sometimes to both, rendering the pupil oval\*. The patient cannot distinguish light from darkness. The diagnosis of a disease that cannot be relieved by operative surgery is now sufficiently established, and no man of the slightest pretension to discrimination ought to be deceived by the appearance of a lenticular opacity behind the iris, which can or does only appear after these previous symptoms have become most marked or apparent. With their commencement a change may be observed behind the iris ; the pupil, instead of looking of a brilliant black, seems dull, and the distance to the posterior part of the eye may be esti-

\* The elongation of the pupil towards the canthi is considered, by the German ophthalmologists, as a very important diagnostic sign of glaucoma : it appears to me to be only an accidental occurrence. In the same manner, they supposed a drawing of the pupil upwards and inwards towards the nose to be a diagnostic symptom of syphilitic iritis, which is not the case in England. The eyes of the good people of Great Britain and Ireland seem rather repugnant to such minute arrangement.



mated, and its concavity observed. This concave appearance soon becomes of a dull yellowish colour, tending to green, loses the transparency it possessed, becomes turbid, but evidently confined to the back of the eye, so that the thickness of the lens in situ may be accounted for anterior to it. As the disease advances, and the other symptoms become more marked, the greenish yellow colour increases in intensity, and the space occupied by the lens now becomes gradually implicated by it, the lens swells, presses the iris forwards into the anterior chamber, and a cataracta glaucomatosa is completely formed. In many instances the lens never becomes so opaque as to give rise to the appearance of cataract. In some rare cases, the opacity of the lens is so entirely free from any glaucomatous tint, and even possesses so perfect a character of a striated opaque lens, that if the appearance of it alone were to guide the judgment of the surgeon, the disease would be pronounced to be "cataract." The internal symptoms accompanying such cases are, however, so marked as to prevent error, even if the external ones have been mistaken. The patient cannot distinguish between light and darkness. This capability was lost under symptoms of amaurosis, of flashes of light of various colours in the eye; and, above all, the progress of the disease has been, and in all probability continues to be, marked by pain, of a severe and often excruciating nature, not only as affecting the eye, but the forehead and the side of the head. The disease may have come on slowly, it may have developed itself under an attack of acute inflammation, or it may have appeared suddenly; but in whatever way it may take place, it is seldom long before it is augmented by the supervention of very severe pain and inflammation. This the German ophthalmologists are pleased to pronounce to be arthritic, or gouty, upon no sound principle that I can discover, unless it be, that when persons are subject to gout, and suffer an attack of internal inflammation of the eye, it often assumes particular characters, which, when they appear in other individuals, are therefore denominated gouty, although



no such predisposition has been before or since observable in them ; which fact they admit, as well as another, that the inflammation is sometimes, in gouty persons, of a healthy character. The inflammation is really an unhealthy disorganizing inflammation, not necessarily dependent upon or connected with gout, and is more or less immediately dangerous to vision, according to the part of the eye it attacks. The consequence of viewing it as a gouty inflammation alone has been, that they have been obliged to consider it as affecting two classes of people, one of meagre irritable habits, the other of a flabby and relaxed fibre, or, as they term it, a pastose individual, in order to account for the different symptoms which take place ; but the truth is, that the symptoms depend not alone upon the nature of the inflammation or the habit of the patient, but on the part that is affected : for instance, they say in the *iritis arthritica* of meagre irritable people\*, “that the iris becomes immoveable, and changes, when it was previously blue or grey, into a greenish colour ; and when brown, into a reddish colour. The pupil acquires an angular shape, contracts, and remains, as in pure *iritis*, in its proper position behind the cornea. The pains increase, and after every attack of pain and fever, the pupil contracts more and more, and at the same time a web-like vegetation of lymph forms in it, which at length totally destroys vision.” In flabby callous patients it has the following modifications : “In place of the pupil contracting, it always expands and assumes an oval form, as in ruminating animals, because the radiated fibres of the iris contract towards the canthi, particularly towards the internal one. At the same time the pupillary edge of the iris is so turned towards the lens, that the small circle of the iris entirely disappears. The pains now increase, become more severe, tearing and piercing as if the eyeball would burst ; a symptom that the vitreous membrane is also affected with inflammation, which is soon sufficiently indicated by it and the

\* Weller's Manual, by Dr. Monteath, vol. ii, page 224 et seq.



vitreous humour becoming opaque. This opacity, which gives the appearance of a greyish green colour in the bottom of the eye, announces the approach of glaucoma. If the lens also take a share in the disease, it grows opaque, acquires a sea-green colour, and forms a cataracta viridis; better named by Beer, cataracta glaucomatosa, and appears to swell out, either alone or with the vitreous humour, and press towards the iris. In the mean time the pains progressively augment, the varicosity of the eyeball increases, the sclerotica and choroidea often form partial adhesions, terminating in nodulated swellings; the cornea acquires a dull, and as it were a cadaverous appearance, after which the vision is entirely destroyed, though the patient believes he still has occasional sensations of light." The symptoms are here minutely detailed, but in no case are they dependent on inflammation of the same parts, modified by habit; on the contrary, in the first example, the iris only is inflamed, as remarkable by its symptoms, and not the choroid coat or hyaloid membrane. In the second example, the tunica choroidea is the part affected, with the hyaloid or vitreous membrane, whilst the iris is scarcely implicated. In the desire to account for the altered appearances the disease puts on, in different persons, by difference of habit, and to form a sufficient diagnosis between them, other and more important principles have been overlooked, not unobserved, inasmuch as they have been fairly related. If the inflammation had attacked the same parts in each individual, the symptoms would in all probability have resembled each other, or if they had changed places or persons they would equally have assumed the same appearances. In the second example, the pupil was dilated because the choroid coat was inflamed, not because the individual was of a relaxed or flabby fibre, or callous as to sensibility; and the same thing would have taken place in the first example if the choroid had been equally affected.

When the choroid coat is inflamed, without the iris being equally affected, the iris merely changes colour, and the pupil



is dilated ; but these symptoms proceed no farther. If the iris be alone affected, it changes colour, the pupil contracts, adheres, and lymph is generally deposited ; it is probable the choroid partly changes colour also, but this cannot be seen. When both choroid and iris are inflamed, the choroid obtains the mastery, and, in consequence of the pressure from behind, the pupil is always more dilated than it would have been if the iris had been alone inflamed. It is always sufficiently so to mark the fact. Two persons who have suffered from pure choroid inflammation are now attending at the Infirmary, on whom these points have been so fully and so clearly proved as to satisfy all those who have seen them. Vision is sometimes totally lost, and is always materially affected, both during and after every severe attack of this nature, although not always irrecoverably so in cases of pure inflammation.

The whole of the symptoms, as well as the histories of those diseases which are likely to be complicated with cataract, and prevent the success of the operation, having been duly investigated, and none of them being found to be present in so manifest a manner as to mark the complication ; reference must again be made to the state of the retina, and if the patient can in any way distinguish light from darkness, there is sufficient reason for trying the operation ; for, if it does not succeed, it will probably do no harm. There is a chance of sight on the one hand, a certainty of blindness on the other.

#### ON THE CAUSES OF CATARACT.

The causes of cataract are enveloped in considerable obscurity, which is not likely to be dissipated until the nature and formation of the lens is better understood ; some surgeons, at present, considering that it is formed by deposition from the liquor Morgagni, which is supposed to be secreted from the internal surface of the capsule ; whilst others conceive that it is supported by vessels of its own, entering at its circumference through the capsule, rendering it an organized



body, and therefore subject to the changes incidental to such parts; a supposition which, although it will enable us to account for many circumstances attendant on this disease, and appears to be nearest the truth, requires yet to be satisfactorily proved.

Among the occasional causes of cataract, age seems to be a very prominent one, inasmuch as this disease prevails most among elderly persons; yet as only a few are affected by it, and many live to extreme old age free from it, there must be some more immediate cause superadded than that which can be supposed to depend on defective or deficient circulation.

Professor Beer\* enumerates a variety of exciting causes; which, however, appear to me as referrible to amaurosis, and many of them may be doubted as applicable to cataract, such as the fumes arising from concentrated acids, alcohol, or naphtha. For instance, he says, sect. 56, that a woman, fifty-two years old, having exposed her eyes for a quarter of an hour to the fumes arising from some concentrated acids, had a cataract formed in a few hours, depending on an opaque state of the liquor Morgagni, on which he operated next day, and found the lens hard, and both it and its capsule transparent. That there was cataract I have no doubt, but that it occurred from the particular exposure alluded to I do not believe; for work-people, who are frequently exposed in this country under similar circumstances, do not suffer in the same way. Great stress is laid by him on misuse of the eye, such as the employment of it on minute objects in a room lighted up by a strong reflected light, particularly when the abdomen is pressed against the table, so as to obstruct the free circulation of the blood, and to cause an irregular distribution of it to the head. In admitting this as a cause, it is proper to add, it more frequently gives rise to amaurosis. Working on minute objects with the head in a depending position, may, by acting in the same manner, prove equally prejudicial. Strong and long-continued action of the direct

\* Beer, *Lehre von den Augenkrankheiten*, band 2, s. 51 et seq.



rays of the sun upon the bare heads of persons working in the fields, combined with the bent position of the body; hard labour near great fires, as in glass-houses, furnaces, &c. &c. are also mentioned as causes promoting the formation of cataract in old age; to which must be added, the abuse of spirituous liquors.

The too sudden darting of a strong direct light upon the eye of a new-born infant, or delicate child, is said to be capable of giving rise to cataract, in consequence of inflammation, which, by affecting the capsule in particular, often remains incomplete. Lastly, cataracts are supposed by Beer to arise from a slow insidious inflammation affecting the lens and its capsule.

“Professor Walther\* has repeatedly observed inflammation in the capsule, and pointed out cases of it to his pupils, who after having been once accustomed to such examinations, have readily distinguished it themselves. It usually occurred in men about the middle of life, and of a slightly cachectic disposition, and was always preceded by a string of various local affections, which had often commenced with itch, gout, or catarrhal affections. The disease occurs oftener in light eyes than in dark, and is always accompanied with a slight change in the colour of the iris and form of the pupil, the first becoming a little darker, and the pupil slightly oval, and drawn upwards and inwards to the root of the nose. The motions of the iris are at first more lively and extensive to partial variations of light, but subsequently they become more sluggish. The pupil is habitually smaller than in the sound state, and there usually exists a black ring of irregular breadth all round its edge, produced by a real eversion of the uvea, that is, the pupillary edge of this projects beyond the same edge of the real or anterior membrane of the iris.

“Along with these symptoms, a number of red vessels now appear in the pupil itself, the largest of which are visible to the naked eye, which has been accustomed to such investigations, but the greater number are only distinguishable with the aid of a sextuple magnifying

---

\* *Abhandlungen aus dem Gebiete der practischen Medicin, besonders der Chirurgie und Augenheilkunde. Von Ph. F. Walther. Landshut. 1810.* But for the quotation, see the sixth number of the *Quarterly Journal of Foreign Medicine and Surgery*, which also contains an account of, and critique upon, the ophthalmic part of the work.



glass. What to the first appears merely a red point, assumes, under the glass, the appearance of a most delicate tissue of vessels. The lenses used for such microscopical examination of the living eye should have a very short focus, and the patient ought to be so placed with respect to the light, that the parts within the pupil be well illuminated, and not shaded by the glass or head of the examiner. In order to have the pupil as large as possible, the other eye should be kept closed during the examination, and a little of the solution of the extract of belladonna may be dropped between the eyelids an hour previously. And in inflammation of the capsule of the lens, the sensibility not being much increased, the patient can bear examination of the eye in a strong light, and with dilated pupils, without much uneasiness.

“The red vessels observed in the pupil during inflammation of the capsule always constitute a sort of vascular wreath, situated at about a quarter of a line’s distance from the pupillary edge of the iris; this wreath forms a concentric circle with the pupil, and is found on examination to consist, not of a circularly disposed vessel or vessels, but of a number of vascular arches, similar to those formed by the arteries of the palm of the hand and joint of the knee. To this vascular wreath there run in a radiated form, as to a common centre, numerous vessels from the periphery of the anterior capsule. Some vessels seem to extend from the pigmentum of the uvea into the capsule, and might lead us to suppose that all the vessels seen in the pupil are merely prolongations of those on the posterior surface of the iris. This, however, is not the case; sometimes there are no such vessels present; where they are, it is only after the disease has lasted some time that they appear; whilst, at other times, vessels are seen prolonged from the capsule into the uvea, reciprocally as those of the latter into the former. Besides, these prolonged vessels are observed to have an oblique direction with respect to the axis of the eye, and they never are the largest trunks, which we see come from the edge or circumference of the capsule. The vessels going between the iris and capsule never arise from the very edge of the former, but at a little distance from it on the posterior surface, so that nearly a line’s breadth of the pupillary portion is free from these vascular sproutings.

“From the vascular wreath we have described, vessels are seen spreading towards the centre of the anterior capsule, and there again forming clusters and arches; and although the connection between the vessels seen in different parts of the pupil seems interrupted at some points, yet there is no doubt it holds good universally, although from the extremely minute size of the vessels they cannot be distinguished.



“Posterior to the red vessels seen in the capsule, there appears in some cases a network of more delicate vessels deeper seated, developed in the lens itself, the larger trunks of which are not always derived from the circumference of that body, but evidently come from its posterior surface directly forwards, and then divide into branches.

“This vascular connection between the lens and its posterior capsule Professor Walther considers to be entirely morbid, and to be effected as an inflammation of the pleura, through the medium of a new-formed membrane, situated upon the posterior capsule, connecting it with the lens; and through the medium of which, vessels shoot into it, giving rise to inflammation, suppuration, or other alteration of its structure.”

Professor Walther, in endeavouring to account for congenital cataract, or that which is discovered at the birth of the infant, supposes that it has not been formed in consequence of disease, a turbid state of the lens being natural to the foetus, and that it remains so in consequence of a check being given to the development and progressive metamorphosis of the embryo, the continuance of which would have brought it to its healthy state. He forms this supposition on the grounds, that it is scarcely possible to conceive such processes taking place in the foetus as would render a lens, previously clear and transparent, opaque. This idea, although it may be correct, does not seem to me to be sufficiently satisfactory, inasmuch as the changes required to cause an alteration in the composition or structure of the lens do not appear to require a labour, which nature is not at any period capable of undergoing and supporting. It accords, however, with my observation, that the lens and capsule, in one species of these cataracts, in which the capsule is thick and striated, and the lens soft and semitransparent, never increase in size in the same proportion with the rest of the eye; and when the pupil is dilated to its utmost extent by the belladonna, the small opaque lens may be seen well defined and seated on the vitreous humour, surrounded by a black ring, pervious to light: this is the transparent vitreous humour itself, which



cannot be seen when the cataract has been formed in the adult, in consequence of the size of the lens, unless the eye is also amaurotic or glaucomatous, and the iris has nearly disappeared; in which state there is now a person attending at the Infirmary, the lens being of a dark brown walnut colour, the vitreous humour black, vision being destroyed. This kind of congenital cataract evidently arises from a defective formation, and not from a loss of the life of the part. Delpech\* supposes that cataract is a perfect spontaneous necrosis, or death of the lens and its capsule, and in this he is correct, so far as relates to the occasional dissolution of the lens; but the processes by which the necessary changes are effected are so different, as well as the results which subsequently take place, from necrosis of any other parts of the body, that the analogy can only be received as an hypothesis unsupported by facts; and, in the particular kind of congenital cataract above alluded to, contradicted by facts, the patients oftentimes going through life without any further change taking place in the lens or capsule, and having very useful vision for all *common* purposes as journeymen or labourers.

That the occasional causes which have been enumerated are capable of assisting in the formation of cataract, seems to be too well established to be a matter of doubt; but it is very different with the conjectures which have been made as to the immediate state of the part, or of its vessels, which give rise to it. Inflammation, being the common preceding and accompanying cause of most of the morbid changes which take place in the human body, is of course referred to as the cause of cataract; and Walther, in the quotation given, describes the symptoms and appearances which lead to its formation; but no one accustomed to see diseases of the eye can fail to perceive, that he is alluding to one kind of cataract, and that his remarks are totally inapplicable to all. The disease he notices is certainly inflammation of the capsule of the lens,

\* Delpech, article "Cataracte," Dictionnaire des Sciences Medicales.



but it is an inflammation communicated to it by contiguity of parts, not arising specifically in it. The first symptoms enumerated, "of a change of colour in the iris, and of the form of the pupil, which becomes slightly oval, and drawn upwards and inwards to the root of the nose," mark the complication of disease, and show that it is not of that nature which gives rise to true cataract, in which there is neither alteration of the colour or shape of the iris or pupil. If a doubt, however, could remain of the different nature of the inflammation, the following account of the termination of it would be decisive, inasmuch as it bears but a slight resemblance to the manner in which a pure capsular cataract is formed.

"At the apparent terminations of several of the vessels in the capsule, we distinctly perceive small knotty pieces of a whitish grey semi-transparent substance, evidently coagulable lymph, the presence of which effusion serves to disclose the manner in which inflammation of the lens and capsule produces opacity of these parts. The anterior capsule, where the vessels are very numerous, sometimes assumes a peculiar velvety flocculent grey or brownish appearance, which has led some to the idea that a flake of the pigmentum of the iris or choroid has been detached and become adherent to the capsule of the lens, and which has led to the cataracta choroidea of Richter. But this is a mistake; we never find that a piece of the pigmentum has been detached, even when the greatest violence has been offered to the eye, the corpus ciliare lacerated, and blood effused into the chambers of the eye and under the conjunctiva. And even supposing it detached, would it become adherent to the capsule, instead of floating in the aqueous humour and being absorbed? The brownish spots on the anterior capsule are in some cases occasioned by the effusion of lymph, and by the extreme terminations of the vessels; and our author has several times in this kind of cataract, which is not at all rare, observed, with the aid of a magnifying glass, the vessels of the capsule and their prolongation into the spots mentioned. In other cases, the capsule had been previously united to the uvea by partial adhesions, and being separated either by the more lively motions of the iris, or by the application of mechanical violence, part of the pigmentum of the uvea had remained attached and adherent to the anterior surface of the capsule \*."

\* Quarterly Journal of Foreign Medicine, No. 6.



The inflammation of Walther is then merely, as he indeed describes it, an unhealthy inflammation communicated to the capsule of the lens from the surrounding parts, which, if it be allowed to go on to its spontaneous termination, would implicate the whole so much as to render the disease of a complicated nature, and would therefore form what is called a false cataract.

Syphilitic inflammation of the eye, or of the ciliary processes, or simple iritis, are capable of giving rise to cataract precisely in the same way; but in a more marked or decisive manner. In all these cases the capsule of the lens is inflamed, vessels appear on its surface, it becomes turbid, opaque, and is often covered with a deposition of lymph, so as to render it perfectly white, or grey, or brown. Yet in many instances all these appearances may be completely removed, and the part restored to its natural diaphanous state, showing that the lens had not been affected. If the lens should, however, have been implicated, then the opacity is permanent, and the lens often adheres to the capsule, which is a very unusual circumstance in the true cataract. If the inflammation should have been less violent, although more permanent, the capsule remains partly or entirely opaque, yet the lens continues transparent, as has been often proved by operation; a circumstance which, I believe, never occurs in the true capsular cataract of adults, the lens always partaking of the disease. When the inflammation is less permanent, although perhaps equally violent, an opaque spot or mark, of greater or less extent, will often remain during life on the capsule, without the slightest change, a circumstance equally inapplicable to true capsular opacity. In the cataracta choroidea of Richter, the posterior part of the iris often adheres so completely to the capsule of the lens, that a space as large only as the size of a small pin's head remains transparent in the centre, yet continues so for life, which no one will say it is probable it would do, or even for one year, if the opacity of the rest of the capsule had not arisen from common inflammation.

When authors write, and persons speak, of having cured



the incipient stages of cataract, they rarely allude to true cataract, but to those states of inflammation I have endeavoured to bring under consideration, which are accompanied by opacity of the capsule, and which are sometimes permanent, but more frequently transitory. It is a fact, which I wish to impress on the minds of students, that those inflammations of the iris and ciliary processes, which are active in their nature, and quickly cause a deposition of lymph, and in considerable quantity, are the most easily removed, and the capsule of the lens thereby restored to its natural state, unless the disease has been too long neglected; whilst those inflammations of the same parts which are slow in their progress and cause the deposition of a small quantity only of lymph, scarcely perceptible but from its effects, in attaching the iris to the capsule of the lens, are very difficult of cure, and generally leave some defect. In the former cases, when neglected, the disease terminates in cataract, with an adherent iris, and possibly a closed pupil. In the latter, the pupil becomes irregular, is attached to the capsule of the lens, which becomes opaque in points, and may be completely so. The eye is likely to become amaurotic, or glaucomatous, from repeated recurrences of the inflammation, if that which has already taken place has not been sufficient for the destruction of vision.

If inflammation be the cause of pure lenticular or capsular cataract, it is an inflammation *sui generis*, depending on the peculiar structure or organization of the parts, and the progress of which is not likely to be better known to us, until this peculiar structure or organization shall have been more fully investigated.

#### ON THE CLASSIFICATION OF CATARACT.

Arrangement being necessary in order to simplify the consideration of the diagnosis of cataract, as well as of the methods of operating which result from it, I have adopted that which appears most efficient and least troublesome, and have



therefore divided them into two classes: first, the true; secondly, the false or spurious cataracts.

The first class, or the true cataracts, containing three genera, or all those, of whatsoever description they may be, which have been caused by derangement or disease of the lens or its capsule, or by both; but unconnected with any perceptible derangement or attachment to the iris or adjacent parts.

Three genera.

1. Cataracta lenticularis, or lenticular cataract.
2. Cataracta capsularis, or capsular cataract.
3. Cataracta capsulo-lenticularis, or capsulo-lenticular cataract.

The second class, or the false cataracts, containing all those previously noticed, or otherwise, which are combined or connected with derangement of the iris or adjacent parts, as a consequence resulting from inflammation.

The term *complicated* may be retained to mark the presence of other and more important diseases, such as amaurosis, glaucoma, cirsophthalmia, &c.

The object of this division being also to show those cataracts which are relievable or removable by the usual known operations for that disease, and which are enumerated in the first class, or true cataracts, and those which require a different and more complicated operation, and are enumerated in the second class, or false cataracts.

#### ON THE DIAGNOSIS OF CATARACTS OF THE FIRST CLASS.

The three genera of the first class are intended to distinguish the disease, as existing in the lens alone, or combined with opacity of its capsule; or in the capsule only, the lens having been removed by operation or absorption. The first genus, or of lenticular cataracts, is divided into four species. 1. The hard; 2. The fluid, which is almost always combined with opacity of the capsule; 3. The soft; 4. The caseous.



## ON THE DIAGNOSIS OF HARD CATARACT.

On proceeding to the examination of a person nearly blind, it is always advisable to look at the eyes in the first place, in order to ascertain whether an opacity really exists behind the iris or not; after which the surgeon may continue his investigation of the appearances, or inquire into the history of the symptoms or illness which led to it. This may indeed be done at the same time, and frequently with advantage. He should ascertain whether the opacity commenced and proceeded to its completion without pain, either in the eye or forehead, and with little or no increased sensibility to light; what degree of light, and of the shadows of objects passing before the eye, the patient is capable of perceiving; the manner in which the complaint came on; the diseases to which he is liable, and whether he is hereditarily disposed to them or otherwise; and whether an attack of any of them, especially of gout, rheumatism, erysipelas, or fits, be impending. These questions being answered favourably, seem to imply the existence of a true cataract, which opinion will be confirmed by examining the eye by the touch, in order to ascertain that it possesses its natural firmness, and by seeing that the sclerotic is free from disease or varicosity of its vessels, that the cornea is pellucid, and that the iris is not only plane and of its natural colour, but that the pupil possesses its regular motions, when exposed to the influence of light, as described from page 208 to 215. The state of the lens itself next demands attention, and it ought to be examined first by a direct front view, whilst the iris is under inspection, and subsequently sideways, in order to discover how far it has interfered with the posterior chamber of the aqueous humour, whether it retains its proper distance from it, or presses forwards or recedes from the pupil; which investigation may be assisted by moving the head in a corresponding direction. The extract of belladonna, dissolved in water to the consistence of cream, may be rubbed on the forehead and eyebrow; or a little,



more diluted, may be dropped into the eye, under the influence of which, in the course of an hour or two, the pupil becomes fully dilated\*; or, if otherwise, the application may be repeated once or twice in a day, for further examination on the subsequent morning. The pupil will now be either fully dilated, or the points of its adherence will be clearly demonstrated, by their remaining fixed whilst the rest of the pupil yields, the salient points being thereby exposed; or the pupil will remain permanently fixed, showing the attachment of the whole internal surface to the capsule of the lens; or it will remain immoveable, whilst the distance between it and the opacity can be distinctly perceived to be as great or even greater than natural, the iris inclining backwards, under which circumstance it will in general be tremulous. These parts, as well as the surface of the lens, are now to be examined with a magnifying glass best suited to the eye of the surgeon.

When the eye is sound and the lens is perfectly hard, the following essential symptoms will be perceived, or ascertained. The cornea is pellucid, the iris plane, healthy in colour, and the pupil regular in its motions and appearance. The opacity, or lens, is of a grey or amber colour, verging to yellow or a brown walnut hue, and is said to be sometimes black. When of a grey or amber colour, the centre of it seems more dense in appearance, or of a deeper shade of colour, constituting what has been termed *cataracta centralis*. The opacity is at a distance from the iris, and, on viewing it sideways, this can be distinctly perceived, as well as an appearance of the

\* The Germans, conceiving that the motions of the pupil depend rather on an erectile state of the part than on muscular action, or referring rather to the iris generally, to the whole rather than a part, as is often done in England, call the dilatation of the pupil contraction of the iris, and the closing or contraction of the pupil an expansion or dilatation of the iris; to which terms, as referrible to the pupil or to the iris, attention must be paid, or their meaning, when applied to both, is directly the reverse of each other.



surface resembling a fine polish, which it loses if the capsule be opaque. The distance of the opaque lens from the iris causes a slight narrow shade, of a darker colour, to be thrown upon it, or on the side next the light, when it falls upon it obliquely, which cannot be seen when, from the size of the cataract, it touches the iris. In the formation of this disease, the central opacity can be perceived long before the whole lens has partaken of it; the patient therefore sees best in the evening, or when the pupil is dilated, or when an object is placed to one side: a symptom which is common in amaurotic persons, and therefore not diagnostic of cataract, but only, when that disease is ascertained, of a particular kind of it: the patient is seldom perfectly blind. When the whole of the lens is opaque, the centre is of a deeper colour, brighter or clouded white specks are never observed in it, and it has always the same appearance.

When the opacity does not commence in the centre, it usually occupies three different parts, corresponding to the three portions in which the lens may be divided by boiling or charring it, the division between them being semi-transparent and of a different colour\*. The lens is small and hard, particularly so in the centre.

When the lens is of a dark or black colour, it has been mistaken, and the disease supposed to be amaurosis; the diagnosis will be found in the lively motions of the iris, the absence of the brilliancy of the black colour of the pupil in its natural state, and by the figure of the person examining the eye not being reflected from it. The history of the case ought to induce suspicion, and if the pupil be dilated, I conceive all doubt must be cleared up, and the disease be distinctly evident.

When the opacity begins far back in the lens, all the symptoms of hard cataract may be present, and the patient be nearly blind, yet the anterior part of it scarcely partakes of

\* In the third plate I have given an engraving of the appearance of a lens of this description, in an amaurotic eye.



the disease, and the opacity is seen at a distance, its surface showing what may be compared to a thicker coat of polish. In such cases the lens is generally found to be very hard, but thinner than natural.

When a hard cataract is of a white colour, it has been compared to a white cornelian; this does not tend to a bluish tint, has always a dense appearance, implying a solid body, and a fine smooth or polished surface; it is not in general of a dead white colour, neither is it clouded or speckled; marks which are indicative of a soft cataract.

It is necessary to remark, although a hard cataract preserves its natural size, or is even less, and therefore at a distance from the iris, that a soft cataract is not always protuberant.

#### ON THE DIAGNOSIS OF CAPSULAR CATARACT.

When the capsule loses its transparency by that slow and equal process which characterizes the formation of cataract, and causes it to be termed an insidious disease; it is in all probability from an action of a peculiar kind, which we are disposed to consider as inflammation. The patient does not complain, but he sometimes, although not always, feels at first that he cannot bear a strong light, and does not see so well; this greater excitability subsides, and vision becomes indistinct. The opacity is evident in the pupil, the lens can be seen, sooner or later, to be affected behind the capsule, is for the most part soft or caseous, and but rarely hard or lenticular, when the complaint begins in this manner. The appearance of the capsule is that of a fine semi-transparent membrane, or of the silk which is termed white persian in this country, drawn perfectly tight over any white or colourless substance, which peculiar shade is best seen by allowing the light to fall obliquely upon it, and it does not possess that transparent polish which has been attributed to the lenticular cataract. It is not always of an equal hue, but seems to be sometimes veined of a different shade of colour. In other instances, the appearance of



the capsule is best represented by what is called silver paper, which jewellers use as the envelope of ornaments in gold or silver; sometimes also called tissue paper. Frequently the commencement of the opacity can be observed very distinctly from its edge, in several stripes or points of a much whiter colour, shining like spermaceti, or mother of pearl, passing on, but in a less defined manner, to the centre of the pupil, and giving it a marked character, always readily distinguishable. Sometimes these spots or striæ begin at the circumference, at nearly equal distances, and remain stationary for years. But when this is not the case, and the disease increases rapidly, the capsule often thickens, depositions seem to take place in it, and upon its surface, causing it to assume various appearances, to which the German authors have given names, but which are perfectly useless\*. The opacity seldom begins in the centre: is never uniform. When the capsule is alone affected, which it seldom is for any time, the opacity does not necessarily approach to, and therefore does not alter the appearance, or interfere with the movements of the iris. These observations apply particularly when the affection of the capsule is concomitant with that of the lens. In many cases, however, although the capsule is but slightly affected, it will be perceived to be nearer the iris than is natural, the posterior chamber being partly abolished. When the lens is implicated, it generally becomes soft, and then the pupillary edge of the iris may be perceived to have taken on a black colour, which is most perceptible when the iris is blue. This black rim or edge must not be considered as a diagnostic sign of capsular opacity, although it may accompany it, for it appears under other circumstances, and is peculiarly characteristic of an enlarged lens. The motions of the iris now become sluggish. When the anterior part of the capsule only appears to be affected, it is termed *anterior capsular cataract*. When the posterior part is supposed to be alone affected, it obtains its

\* See Cataracta capsulo-lenticularis, page 237.



name from it; and when both are diseased, the capsular opacity is said to be perfect or complete.

The *anterior capsular cataract* so soon becomes a capsulo-lenticular cataract, and must always be treated as such, that any further diagnosis is unnecessary. In the adult, the lens does not in general undergo any diminution in size; but, for the most part, an increase in consequence of becoming opaque and soft, or caseous. In infants it is frequently the reverse, only small portions, or a piece of the lens remaining, the rest being fluid. When the capsule is rendered opaque in consequence of an injury which cuts or ruptures any part of it, it thickens, becomes leathery, and has been called *cataracta arida siliquosa*. It is one of the consequences of a capsulo-lenticular cataract.

The *posterior capsular cataract* is a rare disease. It is proper, however, to understand by it an opacity which begins in that part, and remains stationary a sufficient length of time to enable the surgeon to observe its progress; and not to include those opacities which begin at a considerable depth, and proceed rapidly to a completely-formed cataract. Beer, whose accuracy as to facts ought to be doubted with great caution, says, "The lens is much more rapidly implicated, and becomes sooner opaque than when the anterior capsule is affected:" an observation which is quite the reverse of the opinion my experience has led me to form on this subject, and which coincides with that of Mr. Travers\*. So far from the complaint being one which proceeds with rapidity, it is generally the reverse; the patient complains for months, and even years, of indistinctness of vision†, which is usually relieved or assisted

\* Travers's Synopsis of the Diseases of the Eye, page 209.

† I know three persons, who have each had this complaint, in one eye, for several years, and latterly without any increase of the disease. In a fourth case, which I supposed to be of this nature, I operated at an early period, with the hope of arresting or preventing the progress of the disease in the other eye, and found the opacity to be in the pos-



by the use of a magnifying glass. On looking into the eye, a muddiness can be observed in the situation of the lens, but more deeply seated, so that the thickness of the lens may be estimated anteriorly to it; and on examining it sideways, or from the side of the eye, it has a concave, yellowish, turbid appearance, generally accompanied by lines, which can be often distinctly perceived, crossing it, but seldom intersecting each other. These appearances may be irregular, but they do not resemble the chalk white, or shining light-coloured spots observed on the anterior capsule. As the lens becomes opaque, they are of course lost in the general opacity; and, as it is usually hard, it assumes the characters indicating this state, and the opacity of the posterior capsule can only be ascertained after the operation, if the previous stages of disease have not been known to the surgeon. Beer says he could not make a satisfactory drawing of this disease, and it must be difficult to represent the appearances incidental to it, although they are easily recognised on a careful inspection. Is it possible to reconcile the difference of opinion between Beer, Mr. Travers, and myself, by supposing the hyaloid membrane to be more particularly implicated, or rather the seat of the opacity in the disease we describe?

The *complete capsular cataract* possesses no signs by which its character can be ascertained. It is a capsulo-lenticular cataract, or the lens is deficient and the capsule has shrunk. If the surgeon has seen its commencement, and that it began from behind, he may know the fact; but it is not demonstrated by the abolition of the posterior chamber of the aqueous humour, nor by the immobility of the pupil, nor by the convexity of the iris from the pressure of the lens, as all these signs may be present in a case of large soft cataract, without any affection of the posterior capsule.

terior layer or layers of the lens, and not in the capsule: a circumstance which has led me to doubt the accuracy of the diagnosis, if not the fact of the disease existing alone as an opacity of the posterior capsule.



When the anterior or posterior parts of the capsule become affected, or remain opaque after operation, the disease is called *secondary capsular cataract*.

#### ON THE DIAGNOSIS OF CAPSULO-LENTICULAR CATARACTS.

As the fluid, the soft, and the caseous cataracts are for the most part attended by opacity of the capsule of the lens, although they may commence and in some cases continue without it, the diagnosis of these species is dependent in a great measure on this circumstance.

When the lens and the liquor Morgagni alter from their natural state, and the former becomes fluid, both are more or less opaque, and the change is usually effected with some increase of size of the part, so that the convexity of the lens is more marked; it occupies the whole of the posterior chamber of the aqueous humour, presses forwards, and appears to touch the iris, the appearance of which is always convex, and corresponding to the surface of the lens, the extent of which may frequently be calculated from the projection of the iris. The pupil undergoes a slight change, with reference to the appearance of its edge, which becomes black, or is surrounded by a black ring, and is slightly dilated by the pressure from behind; the black edge or ring being a portion of the uvea, or posterior part of the iris, which is pressed forwards and rendered evident from the same cause. The motions of the pupil, under the influence of light, are slower and less lively than natural, or than in the other eye, if it be not affected; and if the belladonna be applied, the subsequent return of the size of the pupil to its usual state requires a longer time for its accomplishment than if the lens was perfectly healthy. The opacity is close to the edge of the pupil, and the convexity of it is perceptible, sometimes giving rise to the idea of an actual projection into it. There is not of course a shadow thrown from the iris upon it, as these parts



are nearly on a level. These essential signs indicate a cataract larger than the common size ; and as large cataracts are almost invariably soft (although small ones are not always hard), it may be fairly concluded, that a cataract which possesses or is accompanied by these characters is soft. The actual appearance of the opacity will in many cases point out its nature provided the capsule has not become completely opaque or thickened, which must necessarily preclude further observation.

A fluid cataract is generally of a colour resembling skim milk, or milk and water, or even less distinctly of a white, although clouded, as if of unequal density. When the pupil is dilated, and the eye put into quick motion, or the eyelids are rubbed sharply over it, this cloudiness will appear to change its situation, to vary from time to time, to render the whole surface of the opacity of an equal colour, whilst it again becomes apparent after the eye has been a short time at rest ; when, in some cases, a separation and subsidence of the denser parts may be distinctly perceived, forming a whiter layer at the lower portion of the opacity, the upper part being still opaque, but less deeply coloured. This examination requires of course a little time, and the patient can, in some instances, himself perceive the difference in the two layers of opaque matter. The cataract does not from the first possess the polished surface always to be observed when the capsule is diaphanous ; and although it may remain perfectly transparent, still it very seldom is so, and the fine tissue-like appearance of the capsule will be readily discovered, by placing the patient in any position in which the light shall not fall directly on the eye. At the commencement of the disease the patient can see tolerably well, but when completely formed, the faculty of distinguishing light from darkness, and the shadow of objects, alone remains.

The *cataracta Morgagniana*, lactea, or puriformis, of foreign authors, is of this kind, and does not appear to deserve consideration as a distinct genus. It has been so named by



them from the supposition, that the disease essentially consists in an alteration of the humor Morgagni, by which it becomes opaque, as the consequence of chemical injury, among which Beer particularly mentions the sudden exposure of the eye to the fumes arising from acids at the moment of the oxydation of metals, which must be a very doubtful if not an improbable cause; for, if it were indeed capable of giving rise to the disease, it can only do so through the medium of the capsule, which is, in my opinion, always the primary seat of the complaint. The lens now becomes affected, may be dissolved or rendered gelatinous, or part of it may remain hard, giving rise to that most barbarous of all the names invented for cataracts, the *cataracta fluida dura*, or fluid hard cataract; a term intended to designate the consistence of a cataract, the nature of which can scarcely ever be discovered, and never satisfactorily known until after it has been proved by the operation. The existence of a portion of the lens in a hard state is not discoverable behind an opaque capsule and a quantity of milky fluid; and, although it may be suspected, the distinction and the name are both useless.

The *cataracta capsulo-lenticularis cystica*, or *encysted* or *hydatid* cataract, is a very rare disease, and seems to belong to the fluid cataracts. It is said to be the consequence in general of a blow on, or of a concussion of the eye\*, by which the lens, enclosed in its capsule, is loosened at the time of the accident from its connections with the surrounding parts, in consequence of which the capsule becomes opaque, and the lens is dissolved. The character of the opacity is that of a snowy whiteness, evidently depending on a thickened capsule, which is sometimes as thick and as tough as leather; in one instance Beer met with it one line in thickness. If absorption of the lens should take place, it becomes the coriaceous or siliquose cataract; if it is merely dissolved, it presses forwards

\* Beer, Lehre von den Augenkrankheiten, band 2, s. 20.



against the iris, and its spherical form and fluid contents may be shown by bending the head forwards, when it advances into the pupil, and again recedes on the head being thrown backwards. When the operation of extraction is performed, the cataract rolls out of the eye on the division of the cornea being completed. Richter\* mentions a case of this kind, in which it resembled a sac full of a whitish fluid. Beer says, when put into water, the sac appears globular; but when placed on the hand, it lies flat, and resembles a bag half filled. It is frequently accompanied by amaurosis, and sometimes by a dissolution of the vitreous humour. From the tremulous appearance, which, under such circumstances, it often puts on, it has been termed "*cataracte tremblante*," *cataracta capsulo-lenticularis tremula*, or *natatalis*. I doubt the correctness of the opinion that attributes the formation of this species of cataract to a separation of the lens and its capsule from all its vital connections, because such a separation is not necessary to account for the opacity of the capsule, and that the alteration of the lens from a solid to a fluid state, when contained in its capsule, seems to me to be a process which is not likely to be carried on under such circumstances; for, when the lens is depressed, enveloped in its capsule, into a dissolved vitreous humour, it remains moving about in it, diminishing, but not increasing in size, and not changing to a fluid state. Lastly, Richter†, in the account he gives of the case alluded to, by no means implies that it was separated from its connections; on the contrary, he says he had recourse to pressure until the cataract sprang suddenly out, and with it at least one-third of the vitreous humour. I have never had an opportunity of verifying the fact, inasmuch as I have not met with any such case on dissection; and I do not consider the operation by extraction to be so well adapted to it as that by division or rupture of the capsule: I have never performed

\* Richter's Treatise on the Extraction of the Cataract, page 101.

† Ibid.



it\*. If inflammation should have caused adhesion between the capsule and the iris, it becomes a false cataract, and the operation assumes a different character to that adopted for true cataract.

A *soft, gelatinous, or flocculent* lens is sometimes seen without any affection of the capsule, especially in the latter species; but in general the capsule partakes of the opacity, and often in a manner sufficiently remarkable to give a name to the peculiarity. When the capsule is not affected, the lens is generally of a dead white colour, and flocculent in appearance, conveying to the eye the idea of softness, in opposition to that of density or solidity, which is entertained from the examination of a hard lens. There is a fine polish on the surface, instead of the membranous shining appearance of a semi-opaque capsule. When the lens is of a gelatinous substance, it often assumes a semi-transparent grey colour, or the bluish green appearance of deep sea water: the capsule has the membranous appearance I have described, as resembling thin silk stretched over it, and is occasionally semi-transparent, or partly unaffected, in spots or lines. I have now four cases before me, in different persons, and I cannot give a better description of a disease, which no one will, however, afterwards fail to recognize, when once it has been seen.

When the capsule of the lens has undergone a further change, as it frequently does, and has become thicker, either wholly or in parts, and the lens has obtained greater consistency, the difference of colour between them can often be easily perceived. The chalky yellowish white of the lens may be seen covered in parts, by the mother of pearl colour of the capsule. This appearance of the capsule again often covers

\* De Gravers, in his Treatise on the Eye and Ear, mentions two cases in which the cataracts came out on the completion of the section of the cornea, and preserved an hydatid form. I have seen the same thing in two operations for the cure of staphyloma, in different persons, verifying the fact of the spontaneous separation of the capsule of the lens from the hyaloid membrane.



a lens of a whiter colour; and sometimes whilst the whiter circumference of the lens marks its softness, the darker centre indicates a hardened nucleus. The sensation of light is very obscure, the lens is always large, presses against the iris, obliterates the posterior chamber of the aqueous humour, renders the iris convex, and causes the black ring around the pupillary edge to be very evident\*. The motions of the iris are slow, and the pupil, after having been dilated by the belladonna, returns to its former size with great difficulty, and sometimes, although rarely, never becomes so small as before.

The alteration on the surface and the thickening of certain parts of the capsule have given rise to appellations, which it may be considered necessary to know, although they are of no utility in practice; provided it be understood, that whenever these appearances originate from, or have been dependent upon inflammation, as indicated by alteration in the form of the pupil and attachment of the iris to the capsule, the disease becomes a false cataract.

When the chalk-white depositions, or thickening of the capsule, assume the variegated appearance of marble, it has been termed *cataracta marmoracea*. This name would, however, be more useful, if it were commonly intended to designate also a hardened state of the capsule, which often accompanies this marmoraceous appearance, and in which calcareous matter is deposited, in spots or scales, amounting, as has been sometimes supposed, to the formation of bone†. When these striæ in the capsule happen to cross each other in a particular manner, and something resembling the bars of a window-frame, the term *cataracta fenestrata*, or window or lattice capsulo-lenticular cataract, is applied to it; but it yet remains

\* This black ring must not be mistaken for a blacker and wider circle, seen round a small lens when the pupil has been dilated — as has been done.

† Dr. Monteath relates the history of a case, in which he extracted a bony cataract, the size and shape of the lens, with success, which had been pressing against the iris, and had caused great pain to the patient. Vol. ii, page 22.



to be settled by the learned, whether it be the cross bars alone that are entitled to this appellation, or whether lines running in parallelograms or lozenges are to be included in it or not: it having been decided, that when they run in a radiated direction, the proper name is *cataracta stellata*, or stellated; and when the striæ are so incompletely formed as only to appear in dots, it should be called *cataracta punctata*; but if they happen to run into each other, and form a white spot on one half of the capsule, whether to one side or the other, it ought to be called *cataracta dimidiata*\*. Here, however, another difficulty remains for consideration; it being evident, although a spot occurring in the centre of the capsule, whilst the rest of it remains tolerably clear, may entitle it to the appellation of *cataracta centralis*; that if one fourth of the capsule only be affected, neither *punctata* nor *dimidiata* will apply to it; and it appears to me, unless one be forthwith coined, such as *quadrata*, it will, like many other parts of the body similarly situated, be obliged to take that of *innominata*.

Cataracts accompanied by any marked alterations of the capsule, such as are or may hereafter be described, will for the most part be found to be soft; and the practical rule to recollect is, that in whatever way the operation be performed, the destruction of the capsule must be a principal object of attention.

When the capsule of the lens is wounded or ruptured in such a manner as to prevent union of the divided edges from taking place, the lens is gradually absorbed, the capsule thickens, resembles white leather or parchment, is frequently as tough, shrinks, and the anterior, in uniting to the posterior capsule, often in the adult, encloses a small piece, or remaining nucleus of the lens, which renders the central part of it thicker and more dense in appearance. This, which is called *cataracta*

\* It has been urged as a reproach to British surgery, that it was not aware of the difference between *cataracta punctata* and *dimidiata*.



*arida siliquosa*\*, or dry-bulled, or coriaceous cataract, generally takes place after an accidental injury, although it may occur after the operation of the keratonyxis. In the former case, the cicatrix in the cornea will be visible, the pupil is for the most part irregular, and the edge of it attached to the capsule. I have never known it occur in the adult, unless as a consequence of an operation, or from injury; but so far from the capsule being loosened from its connections, or any diminution of cohesion having taken place between them, as Beer would seem to imply; there is generally a much firmer attachment between the thickened capsule and the zona ciliaris, or zinnii, than is met with in a state of health; the surrounding parts appearing to partake of the opacity and toughness, to nearly the same extent as the capsule, and rendering a separation of them very difficult of accomplishment. In children and in adults the opacity is always situated at a distance from the iris, even if it be attached to it at a particular point, which it most frequently is; the motions of the rest of the pupil are perfectly free, and the depth of the posterior chamber of the aqueous humour can be readily estimated, by looking at it from the side at which the iris is attached. The cataract is of a dead white colour, yet shining like the smooth surface of kid gloves, exhibiting in some parts a more dense appearance than in others: it is always irregular, uneven, or flat; but never convex on its surface, and when recurring after operation, frequently separated in parts from its natural attachments. From the depth at which the opacity is generally situated, the shadow thrown upon it by the iris is in such cases always broad. In infants the colour of a cataract of this description is said, by Beer, s. 22, to differ, and to be of a white or light grey, but never of a clear white colour; and in some cases of adults, when the bright white of the capsule is intermixed with spots of a dirty yellow colour, it has obtained the name

\* Schmidt, *Ueber Nachstaar und Iritis nach Staar Operationen*, page 19. Vien. 1801.



of *cataracta gypsea*, or gypsum cataract, from its supposed resemblance to that substance. Schmidt conceived, that when this cataract took place in infants, it occurred from a rupture of the capsule, or a separation or loosening of its cohesion from its vital connections, in consequence of convulsions; and that it was a mistake to consider it as congenital. This opinion of Schmidt may be, and has been doubted, with correctness; for many children have had such cataracts without having convulsions, and very few that have had the most violent convulsions suffer from cataract. Schmidt and Beer both state that this cataract is more common among children; in this country the fact is certainly otherwise, unless in cases where a direct injury is committed on the part itself by a penetrating wound, when the nature of the injury is no longer problematical. When it takes place as the consequence of a blow on, or concussion of the head, it must be from inflammation, which also accounts for the fact, that in such cases vision is generally very defective, if not entirely destroyed; whilst in many cases, occurring from direct injury, it is as perfect as in any other case of cataract after the operation has been successfully performed.

#### ON THE DIAGNOSIS OF CATARACTS OF THE SECOND CLASS, OR FALSE, OR SPURIOUS CATARACTS.

When the opacity, constituting true cataract, no longer exists as a single independent disease of the lens and its capsule, but is connected from the first with, or has been subsequently implicated by inflammation of the surrounding parts, it becomes a false or spurious cataract; the essential signs of which are, adherence of the iris or edge of the pupil to the capsule of the lens, obliteration of the posterior chamber, accompanied by discoloration of the iris, and thickening of the capsule and depositions upon its surface, the result of inflammation. A slight adhesion of a point or part of the edge of the pupil does not render a true cataract a false one; it only



requires particular attention in the method of operating; but a greater degree of adhesion, which can only be the result of inflammation, precludes the performance of the usual operations for cataract, renders another of a different or complicated kind necessary, and constitutes it a false or spurious cataract. Under this head, and for these reasons, I include several of the capsulo-lenticular cataracts of foreign authors; such as the *cataracta lenticulo-capsularis lymphatica; spuria purulenta; pyramidata; grumosa; trabecularis*, or *cum zona*, or *balkenstaar* of Beer and Schmidt; the *cataracte barrée* of the French; the *cataracta capsulo-lenticularis cum bursa ichorem continente* of Schmidt; the *putrida* of Schiferli; and the *cataracta lenticulo-capsularis arborescens*, or *dendritica*, of Schmidt; the *choroidalis* of Richter; or *pigmentosa* of others.

The history of a case of false cataract is very important, as it will frequently point out its nature, and, with the appearances of the part itself, indicate what probability there is of success attending an operation for its removal. A false cataract being the consequence of injury or of inflammation, its formation has been attended by more or less pain, which is frequently violent, and often followed by extinction of sight. In all such cases, the iris, the choroid coat, and the retina will have become diseased, and it may be readily complicated with amaurosis, glaucoma, or cirsophthalmia, the symptoms of which will be in general sufficiently evident. Those which are deduced in amaurosis from the state of the pupil, and the susceptibility for light, must be defective, inasmuch as the iris is attached to the capsule of the lens, which is itself thickened and nearly impermeable to light. Shadows of objects passing between the eye and the sun, on a clear day, can be observed in most persons whose eyes are not amaurotic. The pupil, in the majority of these cases, is diminished in size, the edge of it firmly attached to the capsule of the lens, and although a part of it is visible, the opening would be too small for correct vision, even if the opacity could be removed. They come, therefore,



under the consideration of those states of the eye which require an operation for *closed* or for an *artificial pupil*.

In other cases the pupil is not contracted, yet the iris is adherent either wholly or in great part, the edge of the pupil being irregular, and nearly if not entirely destitute of motion, constituting what is called the *adherent* or *concrete cataract*, a disease which equally requires a modified operation; and under every circumstance forbids that of extraction. The whole of the first kind, or false cataracts with diminished and adherent pupil, having been referred to the consideration of the diseases of the iris, requiring the operation for closed, or for an artificial pupil, there remain for consideration such cases of false cataract as have been noticed with an irregular but scarcely diminished pupil. The first class includes the *cataracta lymphatica* and *spuria purulenta* of Beer, with what propriety will be perceived by a simple enumeration of the principal symptoms: inflammation of the iris, and of the lens and its capsule, effusion of lymph, diminution of the size of the pupil, attachment and irregularity of the pupillary edge of the iris, with loss of motion of this part, partial or total deprivation of sight, not only as dependent on the filling up or closure of the pupil with lymph, but on the derangement which may have been caused to more important parts. The lymph, effused into and behind the pupil, may form a delicate net-work, or a thick web, deviating from a snow white to a yellowish white colour. From the edge of the pupil, dark brown spots may sometimes be seen extending towards its centre, which are merely spots of lymph coloured by the pigmentum nigrum, and which are becoming vascular by means of vessels passing from the posterior surface of the iris: the lens may be transparent. The only difference between the lymphatic cataract and the spurious purulent is, that in the former the lymph deposited on the capsule is more clear or semi-transparent, and therefore exhibiting more of a membranous appearance; whilst in the spurious purulent cataract a greater quantity of lymph is thrown out, intermingled, as



Beer supposes, with points of purulent matter, so as to give it a light yellow tinge and an irregular appearance: lymph has also been deposited in the anterior chamber. The distinction between these diseases is only in degree, and may be compared to the state of persons having the gout, one with small chalk-stones, the other with larger ones. They are not worthy of distinct names: in both an adventitious membrane is formed, which is the product of inflammation. The first has not a better right than the last to the name of membranous cataract, which Beer was also disposed to bestow upon it, and both require the same operation for the relief of the patient.

The *cataracta capsulo-lenticularis pyramidata* of Schmidt and Beer, is neither more nor less than the same disease in a more advanced degree, lymph filling up the pupil, advancing into the anterior chamber, and causing the iris to be pressed forwards in the same manner. Beer's account of it, s. 21, is as follows: "It is the result of a violent inflammation of the eye, which more particularly affects the iris and the capsule of the lens, and is not a common occurrence. It is distinguished by a white, almost shining, rounded, and more or less projecting substance, which appears behind the pupil and pushing through it, arising from the centre of the capsule of the lens, to which the pupil, rendered immoveable and irregular, adheres. The great increase of this new-formed part sometimes carries the iris forwards, so as to cause it to touch the cornea, and sometimes even it adheres to it."

The *cataracta grumosa*, of Beer, is equally a product of inflammation of the same parts, and is dependent for its distinction on the accidental effusion of a little blood, and is totally unworthy of further consideration. Beer says, s. 27: "It is the least common of false cataracts; like the other two, is invariably the product of inflammation, and has its basis in the deposition of coagulable lymph, into which blood is deposited, or by which it has been enclosed, when it has been effused as the consequence of an injury, or during the progress of neglected inflammation. When the blood has been



extravasated from injury, and partly absorbed, the surface of the capsule of the lens exhibits the appearance of a red net with silvery white strings passing through it; the pupil, although irregular, is seldom much narrowed; the iris nearly or completely immoveable. The patient can occasionally distinguish objects, but always in a trifling degree. When it has taken place from neglected inflammation (or hypopium), the opacity behind the pupil is of a very thick white colour, studded with red or brown spots, very irregular in their appearance, and projecting through the pupil into the anterior chamber. The pupil is contracted and angular, the iris is adherent to the capsule, and the eye is nearly insensible to light." He adds, that it may be easily confounded with the *cataracta spuria purulenta*, and that the difference is only to be discovered by a good magnifying glass; he has omitted to add, that, when discovered, it is a distinction of no real or practical utility, and only tending to render that confused which is otherwise exceedingly simple.

The *cataracta capsulo-lenticularis trabecularis*, or *cum zona*, of Schmidt and Beer, or *balkenstaar*, is equally the consequence of violent inflammation, and is only distinguishable from any other case of adherent iris and irregular and diminished pupil, by the circumstance of its having a bar or mark across it, either perpendicularly, horizontally, or in any other direction, which is of a whiter colour than the rest of the capsule, generally thicker, and sometimes even cartilaginous. The diminished pupil, the firmly adherent iris to every part of the capsule, the almost entire loss of the perception of light, not only indicate the nature of the complaint, but show the impropriety of attempting one of the usual operations for cataract, especially that by extraction. Beer says, in one case, which he examined after death, the inner end of the bar, firmly attached to the iris, reached over the ciliary processes to the ciliary ligament; and although he extracted the lens from both eyes, in a boy who suffered from this disease, it offers no proof of the propriety of the practice.



The *cataracta capsulo-lenticularis cum bursa ichorem continente*, or that which is accompanied by a cyst or sac of purulent matter, as described by Schmidt and Beer, is also a result of inflammation, although a very rare disease, and generally occurring in persons of a weak and unhealthy constitution. It is distinguished, according to them, by a deep lemon colour, by a heavy motion of the iris if the pupil be not immoveable, by the extinction of the posterior chamber of the aqueous humour, slight convexity of the iris, trivial perception of light. The small sac of purulent matter is generally found between the posterior part of the capsule and the lens, and may sometimes, according to Schmidt, be taken out entire by the forceps, together with the capsule. Beer has seen this bag of matter, in one case, formed between the anterior part of the capsule and the lens. Mr. Travers\* has seen one case, something of the same kind. Sir W. Adams† mentions another which occurred in his practice. In both these cases the lens was absorbed, the pupil became contracted, the iris adhered in every part, the thickened capsule alone remained: a termination always to be expected when matter forms within the capsule of the lens.

The *cataracta capsulo-lenticularis arborescens, dendritica, or choroidalis*, is described by Schmidt and Beer to arise universally from a severe blow or percussion of the eye, with or without a wound, by means of which a portion of the dark covering of the uvea is separated from it, and remains attached to the capsule of the lens, giving rise to the arborescent appearance seen in the stone called *dendritis*. The patient, immediately after the accident, complains of a sensible diminution and indistinctness of vision. A casual observer, on examining the eye, will not perceive this change; but a more minute inspection, especially with the aid of a magnifying glass, will render this appearance manifest on the surface of

\* Travers's Synopsis of the Diseases of the Eye, page 206.

† Sir W. Adams's Practical Inquiry into the Causes, &c. page 29.



the yet transparent capsule. If the lens and capsule be loosened from their connections, inflammation takes place, the parts are rendered indistinct, and the disease no longer possesses any distinctive characters. But if inflammation should not arise, the iris remains free, the pupil moveable, the light clearly distinguishable, whatever changes may take place in the lens and its capsule. The streaks, or spots of pigment, sometimes change their forms, but never entirely disappear, although they may not be firmly attached to the capsule, as may be demonstrated when such cataracts are operated upon by extraction. A disease more truly deserving of the name of *cataracta capsulo-lenticularis choroidalis*, or *pigmentosa*, much more frequently arises in a very different manner, without any blow on, or concussion of the eye, and in consequence of a low or anomalous inflammation of the iris, which is attended by a gradual closure of the pupil, nearly to a point; but which point, or part of the capsule, remains more or less transparent, and is seldom so opaque as to prevent the person from seeing objects with the aid of spectacles. On the subsidence of the inflammation, the iris, by the natural efforts of the part, or under the influence of the belladonna, is drawn towards its outer circle or circumference, and the pupil is apparently enlarged; but the uvea, in retracting, does not keep pace with its anterior part, or leaves attached to the capsule of the lens so considerable a portion of its pigment, as to prevent the passage of the rays of light through it; whilst the pupil, at a distance, seems to be of its natural size and blackness; but a minute inspection shows the peculiar nature of the disease, and that the pupil is in fact nearly closed. There are several cases of this kind now attending at the Infirmary; but the operation for closed pupil, by division (the only proper one), is not advisable so long as they can see sufficiently for the common purposes of life. This derangement is more frequently caused by rheumatic inflammation of the eye affecting the internal parts than by any other.

The second class of false or spurious cataracts, in which



the pupil remains rather dilated, the iris adhering to the capsule of the lens, the opacity of which appears complete, is of a more doubtful nature as to the probability of the restoration to sight of the patients than the first; inasmuch as the inflammation has been more certainly general, and the dilated state of the pupil has been caused by the pressure from behind, as noticed page 228. All those symptoms indicating amaurosis or cirsophthalmia are to be particularly attended to, and if an operation be attempted, it should not be by extraction.

#### ON THE CURE OR REMOVAL OF CATARACT.

The cure of cataract, in its incipient stage, has been often considered practicable, and the methods or means of doing it have been frequently recommended by different authors; which, whilst they induce us to place some confidence in an opinion so often repeated, lead us, after almost constant disappointment, to suppose they must be mistaken in the cases they considered as incipient cataracts, and that they were not constitutional or idiopathic, even if they were strictly local.

There cannot be a doubt that persons, who have had opacities behind the iris perceptible to the eye of an observer, have been cured under a course of medicine, of various kinds; but it is indisputable that these cases are very rare, even in the hands of those who place confidence in the opinion: and it is possible that the opacity had arisen from slight depositions in the capsule, the result of simple inflammation, rather than from any opacity of the crystalline itself; for we know that opacities, or rather a haziness of the capsule, caused by inflammation of the iris extending to it, may almost always be relieved under the treatment proper for the cure of iritis. That opacities in the capsule remain stationary for a series of years is well known; and I am disposed to believe, that where medicines have been given in such cases, they have obtained more credit than they deserved for arresting



their progress, and that most of the cases reported to have been relieved or arrested have been of this kind; whilst those that have been cured have not been opacities of the lens itself, but of its capsule: or if they were lenticular cataracts, they were caused by external violence, and disappeared in consequence of their dissolution and absorption in the aqueous humour, the opacity of the lens having been the result of a rupture of its capsule. Mr. Ware, who at one time supposed incipient cataracts might be cured by spirituous applications, and particularly the sulphuric æther, latterly abandoned the opinion; and it would seem, from a note in the third, that the cases he published in the first and second editions of his work on cataract, and which followed an external injury, were of the latter description.

When an injury is inflicted on the eye by any substance which penetrates the cornea, and opens the capsule of the lens without displacing it from its situation, it gives rise to the formation of a capsulo-lenticular cataract, which is usually a soft one, and readily removed by absorption, provided the opening in the capsule does not close, which would put a stop to this process, or cause at least a change to take place in the nature and appearance of the cataract, rendering the capsule, in the generality of cases, harder, tougher, or leathery, or, what is termed by Schmidt and Beer, siliquose. If the wound in the capsule should have been of greater extent, the capsule yields, and either shrinks or is itself absorbed, so as to leave the pupil perfectly clear, and in this way give rise to the opinion of a cataract having been cured by the external remedies applied to the eyelids, or eye. Upon this fact the operation (the keratonyxis) through the cornea for the opening of the capsule and the consequent removal of the opaque lens was founded, and is liable, as will be hereafter explained, to the same difficulties; for if, in any way in which the operation be done, whether accidentally or purposely, the lens be displaced, it presses on the iris, as a large solid body, and fre-



quently causes inflammation, closure of the pupil, and other deformity, which is often irremediable. When a cataract has been already formed, and from some accidental violence the capsule is ruptured, the cure may be completed in the same manner, and be attributed to the use of remedies which have been perfectly inert.

In doubting then that the removal of a well-formed opacity of the lens can be accomplished by external applications, or internal remedies, it is also proper to confirm the opinion, that opacities of the capsule may be sometimes arrested, frequently diminished, and sometimes removed, by a due appropriation of these means; but even in these cases, I believe, it is principally such opacities as are the consequence of common inflammation that are amenable to their influence, or the true idiopathic cataract, in an incipient state.

M. Gondret\* asserts, however, and supports his opinions by the relation of several successful cases, that he has been enabled to remove opacities, at an early period of their existence, by a combined internal and external treatment. The two following cases are the best, and show the means employed.

M. Pepin, fifty-nine years old, of a good constitution, after an attack of fever, with determination to the head, perceived, for the first time, a black spot floating before his right eye. Six months afterwards, clouds, precursors of cataract, appeared before the left eye. During the winter of 1819 and 1820, he suffered, for thirty nights, insupportable pain in the right temple, followed by an attack of inflammation of the left eye, which was removed by the application of leeches. In January 1822 the pains in the right temple returned, and were removed by opium. In April 1822, he came under the care of M. Gondret, who gives the following statement of his case. He has entirely lost the sight of the left eye, which has been cata-

\* *Memoire sur le traitement de la Cataracte* by L. F. Gondret, &c. &c. Paris, 1825.



ractous for the last four years: the right eye has a greyish spot in the centre of the lens, characteristic of commencing cataract. The patient can hardly read for a short time without inconvenience, sometimes he can scarcely see at all. The threads or spots, which he first perceived nine years back in the right eye, are now more numerous. The pupils are moderately dilated, and little moveable.

April 4, 1822, a caustic issue was made on the sinciput by the ammoniacal pomatum.

May, 1822. The cloud which appeared to cover the right lens is less apparent, vision is a little stronger, the filaments remain. An electric stream, produced by means of a Voltaic trough of thirty plates, and directed between the superciliary nerve and eye-ball of the right side rendered vision for a moment clearer; but the nerves received from it a general shock, which remained until next morning.

June 1, 1822. The right eye is perfectly clear, sight stronger.

July, 1822. The cloud in the right lens has returned, and vision has deteriorated. The caustic issue is very superficial, and is reduced in size to between three and four lines in diameter. I increased its size, and made it deeper by the ammoniacal pomatum.

August, 1822. The opacity of the lens has disappeared, vision is always good, the dead white appearance of the cataract of the left eye has changed to a greyish tint.

June, 1823. The right eye is in its natural state, the filaments or threads are greatly diminished, vision is good. The lens of the left eye becomes more and more of a dark grey colour. The sight of this is confined to the perception of light.

August, 1825. The cure remains complete of the right eye. The opacity of the left is scarcely visible, but there is no improvement of sight.

CASE II. J. J. Henriet, aged seventy, has cataracts in both eyes. In the left the cataract is complete, and vision is lost.



In the right eye the opacity is perfectly visible, although not to so great an extent as in the left ; sight has sensibly diminished for some months.

October, 1822. I made a caustic issue with a red-hot iron, at the desire of the patient, on the sinciput, and kept it open for four months. The Voltaic electricity was frequently employed, as well as an ammoniacal collyrium, taking care to keep the bowels open by some laxative remedy when necessary. The opacity of the right lens has gradually disappeared, and sight has been entirely restored. The benefit obtained from the treatment in the left eye has not been permanent, such as a diminution of the opacity of the crystalline, and an improvement in vision.

August, 1825. The patient is now seventy-two years of age ; two years have elapsed since the treatment was discontinued, the cataract has not returned in the right eye, and the sight is good.

CASE III. Madame Leleu, sixty-six years old, was sent to me by Dr. Dutremblay ; and Dr. Bessiere, who happened to be in my room at the moment, perceived, as well as myself, a cataract in each eye, of a blackish grey colour. The patient could not see an object at some paces distance, and believed she saw a thick fog before her eyes, which diminished in density, at times, towards evening. She saw her way with difficulty. She considered her complaint to have begun between three and four months back.

The caustic issue having been made on the sinciput by the ammoniacal pomatum, and having been cupped on the neck from time to time, she found the fog had become clearer at the end of six weeks ; vision was more distinct. The opacity had diminished in both eyes.

February 19, 1825. The fog had disappeared, and in its place the patient perceives filaments like flies, floating before the eyes. The cataracts are scarcely visible.

April, 1825. The cataracts have disappeared ; vision is



good; and she is only troubled by some *muscæ*, which still appear to float before the eyes\*.

Majendie, in a note at the end of the memoir, says, "in the observations of M. Gondret, one may find the application of my experiments on the fifth pair of nerves. In acting on this nerve, may we not be able to modify the nutrition of the eye, which is evidently connected with the integrity of the fifth pair? If defective action be the cause of opacity, why should not a state of excitement remove it? There is nothing certain on this point, but the inquiry deserves the attention of physiologists and surgeons."

The first case is not one of pure cataract; and if the others had been like it, the reputation of the practice for the cure of cataract could not have been maintained. The two last cases are, however, unobjectionable, provided no mistake has been made, and establish the fact of the possibility of removing an opacity of the lens without an operation. Gondret admits, that when the disease is fully established, the means recommended are not sufficient, but the precise state at which the removal of the opacity is likely to be accomplished is not ascertained; and therefore the practice may be tried in all incipient cases.

I have been in the habit of making caustic issues on the top

\* The following are the formulæ sent to me by M. Gondret.

POMMADE AMMONIACALE.

R<sub>x</sub> D'axonge de porc..... 3 vij  
 De suif de chandelle ..... 3j  
 Faites à peine liquifier l'axonge, melez avec le suif  
 liquifié à part; ajoutez d'ammoniaque liq. à 25°  
 Reaumur ..... 3j

m. f. l. a.

COLLYRE AMMONIACAL.

R<sub>x</sub> D'axonge de porc à peine liquifié ..... 3 vij  
 D'huile d'amandes douces..... 3j  
 melez; ajoutez  
 D'ammoniaque liq. à 25° Reaumur..... 3j

m. f. l. a.



of the head and on the temples for several years past, and of continuing them for months, as the students attending at the Infirmary can testify, in cases resembling the first, and with considerable success. This treatment has been combined with galvanism, alteratives, and strict attention to the general health, and to any prevailing diathesis, such as gout, rheumatism, &c.; but I have never seen a distinct well-formed cataract removed by it. Patients have often improved in sight, their pains have ceased, the eyes have re-assumed a natural appearance, or the alterations of structure have not extended; and so far this may be considered a cure. I have several cases now under treatment, and I shall be very glad to find that a greater extension of the practice, in cases of incipient cataract, will lead to a more favourable result than has hitherto been attained in this country. Admitting, as I do, that an operation on one eye is certainly capable in some instances of causing the removal of a commencing opacity in the other; it is reasonable to suppose that some means may yet be found of effecting this object in a certain and more satisfactory manner. Incipient cataracts ought not, therefore, to be left until the opacity is complete, but should be submitted to a treatment adapted to the age and habit of the patient.

When the cure of cataract is effected by the removal of the opaque lens and its capsule, the patient will be obliged to wear convex glasses to compensate for their loss, but vision will nevertheless remain defective, although equal to the performance of all the common offices of life, including a moderate degree of reading or writing. By the cure of cataract by operation, the restoration of the patient to his former state is not implied, and ought not to be so understood.

The terms ripe and unripe, mature and immature, which were formerly used with reference to the state of solidity or softness of the lens, and which are therefore now rejected as illusory, have been applied latterly in a different manner, that is, with reference to the state of vision, which is no longer supposed to be dependent on the hardness or softness of the opaque lens, but on the degree of opacity; the term unripe



being used when the patient can still see to distinguish objects sufficiently for the common purposes of life; ripe, when he is nearly blind, so as to be able only to see the shadow of any thing passing before the eye. These words must always, from their usual acceptation, cause an impression, relating more or less to the time which the opacity has existed; and are, in my opinion, equally improper and unnecessary as when applied to indicate the consistence of the cataract, and ought to give place, as they have done in this country, to the terms fitness or unfitness, proper or improper, for operation.

The proper period for operating is a subject of great importance, and involving several considerations. The age and state of health of the patient first deserve attention; for, although operations have often been successfully performed at and after eighty years of age, which therefore appears to offer no obstacle to it; the state of health may forbid the attempt. It should be what is usually considered good for the period of life, and the person should be free from any inflammatory disease; if liable to gout, rheumatism, or erysipelas, the operation should be done after a fit of either, and not when one is impending, or likely to occur on the application of any exciting cause. In persons subject to dyspepsia, hypochondriasis, and hysteria, it will be proper to strengthen the patient for two or three weeks previously to the operation by a generous diet and stomachic bitters and corroborants, such as the infusion of quassia with sulphuric acid, the sulphate of quinine, or a scruple of the radix valeriana sylvestris, two or three times a day\* in an infusion of the cinchona. Scarpa says, the less timid and nervous the patient is, the milder are the symptoms consequent on the operation. It may be added, the less irritable the patient is, the better will he be able to bear the means of cure necessary to be resorted to, should these symptoms unfortunately become severe.

A course of preparation has been insisted upon by some authors, and has been as much neglected by others: perhaps

\* Scarpa, Diseases of the Eye, page 336.



both have erred from not duly considering the real state of their patients respectively, but blindly following, in all cases, a mere routine of practice, which, while it might be useful to some, was equally detrimental to others. Preparation ought to be regarded with relation to the system generally, or the part locally, and should be regulated according to the state of both, so that the patient may be in the best possible condition to support the actions which may be induced by the operation; and, when too strongly excited, the means necessary for their repression. Inflammation of the internal tunics of the eye is to be avoided, or speedily repressed, because there is not only an immediate danger awaiting its effect on their organization, but also on their function, for vision may be very much impaired while the structure is apparently but little altered. The operation inflicts an injury on the internal parts in every way in which it can be done, and its effects ought to be obviated as much as human foresight will permit, particularly as we have it in our power to choose the period for its performance. If the patient be of a good habit of body, of a middle age, not inclined to indulge either in great eating or drinking, and not prone to inflammatory affections, all that is required by way of preparation will be to open the bowels gently, and to abstain from animal food for a few days, previously to that fixed on for the operation. If the patient be of a rigid fibre, inured to hardships, and in high health, blood should be taken from the arm, and abstinence more rigidly enforced. If he be the reverse, a gentle cathartic will alone be necessary.

If the eye or its membranes be in a chronic state of disease, it should if possible be remedied, and any minor operation be performed, such as for pterygium, ectropium, &c. before that for cataract is attempted. Derangement of the lachrymal passages is not a sufficient cause for preventing the operation, it only precludes the mode by extraction, if it can be accomplished in any other way; for the tears, finding an obstacle to their transit to the nose, regurgitate upon the eye, and interfere with the union of the incision. If, from the hardness of the cataract or other cause, extraction be the only mode of



operating considered advisable, one eye should be done first, and the patient be made to lie on the opposite side, so as to favour the passage of the tears into the nose or over the inner angle of the eye.

The eyelids are frequently, in elderly people, in a state of chronic irritation, slightly tumefied, looking red on inspection, causing a watery appearance of the eye, independently of disease of the lachrymal passages, and accompanied by a secretion of mucus, in a greater or less quantity, which incrusts on the lid about the roots of the eyelashes and glues them together in the morning; sometimes there is only a weeping of the eyes, with great relaxation of the fold of the conjunctiva, passing from the lower lid to the sclerotica. In this case, a slight touch of the *sulphas cupri*, every other morning, will soon give tone to the parts; whilst, in the former, relief will be more readily obtained from the *ung. hydr. nitr.* diluted with three or even six times its weight of the *ung. cetacei*, according as it excites irritation, gently rubbed every night on the edge of the tarsus within the cilia, whilst a drop of the *tinct. ferri muriatis*, diluted with three times its weight of water, may be instilled into the eye every morning. This application I have found of essential service in many chronic states of disease of the eye; it is useful in most cases in which the *liq. plumbi* or the *vinum opii* are considered serviceable, and in some it has been found more useful; a solution of the sulphate of zinc in water may be used with advantage, until the conjunctiva assumes its natural appearance, and the eyelids have recovered their usual softness and flexibility.

Pregnancy is usually considered as a state unfavourable to the operation; and during which it ought, if possible, to be avoided.

When only one eye is affected by cataract, the propriety of operating on it is a question on which much contrariety of opinion has been maintained, both on account of the utility as well as expediency of doing it, and the reverse; one party\*

\* Sabatier, *Medecine opératoire*, tome iii, page 5.



contending that the operation, if successful, only confused the sight through the irregularity of the foci of the two eyes; and that, if unsuccessful, it might cause an affection of the sound eye through sympathy of inflammation; whilst the deformity produced by a failure of the operation would be greater than the defect which appeared from the presence of the cataract. The other party\* maintained, that, when the cataract was successfully removed, the eye gained a power of accommodating itself, so as to cause, after a short time, little or no inconvenience from the difference of focus, especially in persons who had been previously myopic; and that, although reasoning might be against them, facts were in their favour. Secondly, That the removal of the cataract from one eye prevented its formation in the other, and that they did not advise the performance of the operation unless there was every reason to expect a fortunate result.

Maitre Jan†, so far back as 1685, appears not to have had any hesitation on the subject, and relates several cases in his work, in which success seems to have crowned his efforts. St. Yves‡ does not seem to have doubted the propriety of it. Richter§ at first supported this opinion, but afterwards doubted its correctness. Wenzel|| strenuously advocated it, and makes mention of several successful cases of it in his work. I have performed the operation several times myself, both satisfactorily and the reverse. St. Yves¶, however, relates a case which alters the question materially, by adding another and very important reason for operating. It is of a person, who, having sustained an injury on one eye, which caused the formation of a cataract, began to suffer from amaurosis in the other. The operation for the cataract having been performed

\* Wathen on Cataract, page 57.

† Maitre Jan, *Maladies de l'Œil*, edit. 2, page 196.

‡ St. Yves, page 261. 1722.

§ Richter's *Treatise on the Extraction of the Cataract*. 1791.

|| Wenzel, by Ware. 1791.

¶ St. Yves, page 261. 1722.



under these circumstances, the amaurotic affection in the other eye began to subside, and, in the course of a year, was completely removed by the unassisted efforts of nature.

Mr. Travers\* says, "It often happens, that a patient has a full-formed cataract in one eye, which presents the signs of amaurosis, and an incipient cataract, or one as much advanced as the other, which is at present free from these symptoms. In this case, the cataract of the latter should be removed without delay." In this opinion I am disposed to coincide, from the high estimation I entertain of the talents of its author. I have operated in two different instances on the left eye for soft cataract, combined with complete amaurosis, when the right eye was sound, and with all the success I expected, *viz.* the restoration of the appearance of the eye, an object of consequence to my patients; who, being upper servants, found that the deformity the disease occasioned was an obstacle to their getting places. The operation had no effect on the sound eye; and, as amaurosis often becomes stationary under proper treatment, it would not be easy to decide how much was attributable to the operation, how much to the general treatment.

Mr. S. Cooper is of opinion, that the reason assigned for not operating when only one is affected, *viz.* that one eye is sufficient for the necessities of life, is but of a frivolous description; and that the other objection, as to the foci of the two eyes not being the same, and therefore causing confused vision, is a gratuitous supposition inconsiderately transmitted from one author to another†. Mr. Travers‡ considers these objections altogether subordinate, and not deserving of attention; on which point I cannot coincide, however great my respect for both of them; for, independently of other considerations, and allowing, as Mr. Travers says, that the defect of an equal focus may always be remedied by glasses, it

\* Travers's Synopsis of the Diseases of the Eye, page 314.

† Cooper's Surgical Dictionary, article Cataract, page 197.

‡ Travers's Synopsis, page 512.



appears to me that a person had better be blind of one eye, seeing well with the other, than to be obliged to carry a glass before the affected eye, to enable him to avoid having confused vision with the other. That the inconvenience arising from the loss of sight of one eye is scarcely felt, must be acknowledged by every one conversant with diseases of the eye, for many persons are only made acquainted with their loss by some accidental circumstance, which induces them to depend on the blind eye, which they then find, to their great surprise and alarm, to be utterly deficient. That the sphere of vision laterally is diminished by the loss of one eye, cannot be doubted; but an operation seldom enlarges it in such a satisfactory manner as to render it worth undergoing the risk attending it; and admitting that the eye has the power of accommodating or adjusting itself, after a time, to the alteration which has taken place, no one will venture to contend that direct vision will be improved by it, although it may be urged that it is not much impaired by it, even without a glass. I have, however, met with several cases in which great inconvenience was sustained from the confusion of vision caused by a successful operation; and in one instance the patient, a workman on minute objects, applied to me to put out the eye, or at least to destroy the sight he had obtained through the operation. I have no hesitation in declaring it as my opinion, that, as far as the improvement of sight is concerned, the operation should not be attempted on one eye whilst the other remains sound. If the sight of that one should become deranged, from the commencement of cataract or any other cause, the objection is of course completely obviated. In local or accidental cataract I do not believe the presence of an opaque lens in one eye has any influence on the other, neither does the removal of it prevent the formation of an opacity in the other at any subsequent period. The only reason there is for performing an operation is to remove the deformity, and to restore that intelligence of countenance which is much diminished by the pre-



sence of the opaque lens. If the patient has lately had inflammation of either eye, and especially if it has alternated, as it is frequently observed to do, the performance of an operation which might re-excite dormant sympathies would be manifestly improper, until a considerable time had elapsed, so as in all probability to allay this increase of sensibility; for we frequently see that inflammation will be produced at one period from a very trifling cause, whilst at another and subsequent one, great liberties may be taken with impunity. In forming our decision, much will depend upon the nature of the cataract; if it be simple, and will admit of removal without difficulty, the operation in all probability will succeed; for, in the healthy state, one eye seldom sympathizes with the other, unless considerable inflammation be induced.

Another question has arisen as to the propriety of performing the operation on both eyes at the same time, which has been as much disputed as the other; one party strongly enforcing it, the other decrying it. Scarpa\* says, "In cases of cataract in both eyes, I have learnt from experience that it is not advantageous to operate upon them immediately one after the other; but that it is better to wait till the first is well, before the operation is attempted upon the other; the delay makes little difference in the time required for the cure of both. Upon this point I have had frequent occasion to remark, that the symptoms of the second operation, whether on the same eye or upon that which has not been operated upon, are constantly less considerable than those of the first operation." And, "I have frequently seen, in women subject to hysteria, and in hypochondriasis, after the easiest and most successful depression of the cataract in one eye, convulsive symptoms excited, either general or confined to the head and the eye which had been operated upon; and these, in some cases, so violent as in a short time to leave the pupil dilated and immoveable, with almost total insensibility of the optic

\* Scarpa, by Briggs, page 356.



nerve of that side; while in the same patient, when the other eye has been operated on, two weeks afterwards, it has not been followed by any remarkable accident."

Beer\* adopts a middle course; he says, "When cataracts are completely formed, and every thing promises a favourable result, both eyes may be operated upon at the same time; which ought not to be done when any circumstances are present which render the event doubtful, so that if the first operation should fail, the patient will have one eye left for a more favourable attempt." In this opinion of Beer I most cordially concur, with this addition, that if any accidental circumstance should take place during the first operation, rendering its success doubtful, the second should be delayed to a future opportunity. The only good argument which can be adduced in favour of the practice is, that the same treatment, the same time and confinement, answer for both, which in delicate nervous people is an object of importance, as the general health might be injured by the repetition of them under unfavourable circumstances. If the patient be subject to gout, rheumatism, or erysipelas, or is of a bad habit generally, one eye only should be operated upon. If I were the subject of this disease myself, I should choose to have one eye operated upon first, and the second done at a subsequent period.

There are, however, other circumstances which influence and ought to decide this point, as well as the exact period for operating; these are the state of the opacity and of vision. When the lens has become so opaque as to prevent the patient seeing sufficiently to find his way about, and he can only distinguish the shadows of objects, it is in a fit state for operation, inasmuch as no deprivation of light can take place through an unsuccessful result; and, what is of much more importance, there is less liability of inflammation ensuing after an operation on a cataract which is completely formed, or, as it has

\* Beer, *Lehre von den Augenkrankheiten*, b. 2, page 350.



been termed, become indurated, than after the removal of a lens the opacity of which is only commencing, and through which the patient can still see. These circumstances are so well known as to cause, in general, the delay which is usually recommended, until the patient can no longer see sufficiently for the common purposes of life. I have, indeed, heard of a person sitting down and writing several letters, to inform his friends that he was going to be operated upon next morning, on both eyes, for cataract; but in such a case, I should conceive, that the want of judgment and discrimination, in both surgeon and patient, must have been mutual.

It frequently happens that the cataract is completely formed in one eye long before it impedes vision in the other, so as to prevent its being of service. In such a case I would advise the patient to submit to his disease, keep his health in a good state, and have the operation done on the eye first affected, as soon as the other became nearly unserviceable, so that he might perhaps have the good fortune of never being completely blind. The operation may be done at a very advanced age, with every prospect of success.

The advocates for the performance of an operation on one eye, whilst the other remained sound, have asserted, that the removal of a cataract from one eye will prevent its formation, or give rise to its disappearance if forming, in the other, as stated page 269. Mr. Stevenson has lately revived this opinion\*, and strongly recommended the practice, conceiving, that if this advantage could be obtained, it would counterbalance any inconvenience that might arise from the dissimilarity of the focus of vision of the two eyes. Mr. Stevenson's book does not appear, however, to be written for professional readers, who cannot derive indeed any precise information from it, on account of the manner in which the criticisms on the different operations are mingled together, and the general inapplicability of them, or of the observations to the professional

\* Stevenson on the Nature and Symptoms of Cataract, &c. 1826.



points in dispute. As far as I am capable of understanding them, it appears that Mr. Stevenson supposes—

1. That the removal of a cataract in one eye by operation will be the cause of the disappearance of any opacity which may be commencing in the other; or, if it should not have commenced, will prevent its appearance.
2. That the operation to effect this removal of the cataract may *always* be done by puncturing the lens, or by the absorbent practice, to the rejection of the methods by extraction and depression.
3. That the operation ought to be done at the earliest possible period of time after the opacity is fairly perceived to exist.

The idea, that the removal of a cataract in one eye would prevent the formation of an opacity in the other, does not belong to Mr. Stevenson, and must have had some previous foundation in observation: yet the general failure of the operation to effect this specific purpose prevented its reception, and gradually gave rise to the opinion that it had no such influence. Mr. Stevenson has the merit of reviving the idea; and I am satisfied, that in *some* instances he is correct in this first assertion, “that the removal of the cataract in one eye by operation will cause the disappearance of an opacity which may be commencing in the other.” I am led to this conclusion from having seen it in a sufficient number of instances to establish the fact. In compliance with the rule I have laid down, of never allowing a patient to become blind before an operation is performed on one eye, unless circumstances should prevent it, and also for the purpose of ascertaining what advantages would result from the practice, I have rarely, I may indeed say I have never declined operating on one eye in a case of idiopathic cataract, when the patient has wished it, and the other eye has been affected. I have therefore operated on a considerable number under these circumstances; and as far as *any* benefit has been derived from the operation, in relation to the sound eye, it has been



very limited. In most of these cases, the patient has seen a little better, but the opacity has afterwards gone on increasing until the patient became blind. I saw a gentleman last year, on whom the late Mr. Phipps had operated by extraction on the right eye thirty years ago. He could see, he says, at that time, very well with the left, but it gradually got worse after the operation had been done on the other, until the cataract became completely formed, and vision was destroyed. He sees so well with one eye, that he will not have an operation performed on the other. I operated eight years ago on the eye of a gentleman under similar circumstances: the cataract in one eye rendered him completely blind; the lens of the other was unsound, but he could still see for common purposes. The operation was so successful, that a mark of where it had been done could scarcely be discovered by an experienced eye. It did not prevent the cataract in the other eye from rendering it useless, but he saw so well with one that he would not submit to another operation.

I operated, in January 1822, on the right eye of a gentleman, for soft cataract, by breaking up the lens, and sight was restored. The other eye seemed perfectly free from opacity at the time; but he returned to me in the month of December of the same year, with a cataract distinctly perceivable in it, which he said he considered, from the defect of sight, to have been forming between three and four months.

Sarah Mitchell, wife of the master tailor of the 3d light dragoons, was admitted into the Infirmary with a well-marked cataract of the right eye, principally affecting the posterior capsule. I operated on it, by breaking up the lens and capsule, in June 1823. She was delivered of a child, on the 28th of December, affected with cataracts of both eyes, which were successfully operated on in July 1824, at which period a cataract of a similar nature to that she had in her right eye, and which I had removed, was well formed in the left: she saw, however, so well with the one which had been operated upon, that she preferred delaying the operation on the other until it might be necessary.



These four cases, selected from a great number, prove the fact, that the most successful operation on one eye will not prevent, at all times, the formation or the completion of the opacity in the other.

A poor woman, now living at North End, Fulham, was admitted into the Infirmary with a soft cataract of the right eye, and an affection of the capsule of the left, resembling that depicted plate iii, fig. 8. I operated on the right eye, by the compound operation of displacement and extraction, recommended by Sir W. Adams, and in a very successful manner. A foreign surgeon, who came occasionally to the Infirmary, went into the ward, and, contrary to the express orders for regulating the affairs of the charity, examined the eye very roughly on the second day, gave the woman great pain, which she had not before experienced, and was the cause of suppuration taking place, with the loss of the eye. Some months after she called at the Infirmary, as she generally does three or four times a year, and on dilating the pupil of the remaining eye I found, that all the opacity I had before observed had disappeared, she declared her sight had improved, and that she saw quite well. The loss of the one eye had certainly led to the removal of the opacity of the other.

I operated on the right eye of a patient at the Infirmary, of the name of Thomas, nearly two years ago, by extraction, the lens being hard and the capsule affected. The capsule of the left eye was distinctly opaque at its circumference, as in plate iii, fig. 8. On examining the eye lately, having previously dilated the pupil by the belladonna, the capsule was free from opacity.

I have seen the same disappearance of an incipient opacity in two other cases, and in one of these I had reason to suspect a commencing opacity of the lens. My observation has not however led me to remark the removal of a well-formed opacity of the lens, evidently of a hard or indurated nature, as a consequence of an operation on the other eye. Dr. Bowen relates the case of Padre Bora of Rome, seventy-one years of age, on whom he had operated for soft cataract of the left eye



with an incipient one of the right. The operation was successful, and was followed by the disappearance of the opacity in the other. Dr. Bowen gives it as his opinion\*, that "many a man would have prevented a cataractous companion by an early operation on the first formed." He recommends, as will be hereafter noticed, the absorbent practice, and the operation by depression, or, as he terms it, hyalonyxis.

It is not possible to say what influence an operation may have in preventing the formation of a cataract in the other eye, where no signs of its occurrence were previously observable; but it is very desirable to ascertain, if possible, in what cases, and at what period of the progress of each kind of cataract, the operation is likely to be attended with the desired result. The cases of failure I have related and alluded to fully establish the fact, that it is not always successful, whilst those in which it succeeded prove, that it may sometimes effect the removal of an opacity in the other eye. I believe that it will not succeed in cases in which the lens is alone affected, and of course of a hard or indurated nature; that it is more likely to be of use where the capsule seems to be the part first implicated, and then only in an early stage, whilst it often fails of causing any favourable result at whatever period the operation may be attempted.

In regard to the second supposition, "that the operation to effect this removal of the cataract may *always* be done by puncturing the lens, or the absorbent practice, to the rejection of the methods by extraction and depression," there cannot be the slightest doubt of it being most unfounded: indeed Mr. Stevenson must be aware, that when the cataract is a hard or indurated one, the absorbent practice will not only not succeed, but will in general be followed by the most unfortunate result. I shall therefore presume, that he limits the expression to the earliest period, at which the formation of a

\* Bowen, Practical Observations on the Removal of every Species and Variety of Cataract, 1823.



hard lenticular cataract can be perceived. I am not prepared to say, that at this period the absorbent practice may not succeed, but this I know, that long before the hard lenticular cataract is completely formed, long before the patient has ceased to see objects at a few yards' distance, the lens is too hard to be broken up by the knife, and that at this period the operation by the absorbent practice is neither the safest nor the best. In cases of soft cataract the absorbent practice is at all times the best; but on these points I beg to refer the reader to the following parts of this work, in which these subjects are particularly noticed.

The third supposition, "that the operation ought to be done at the earliest possible period of time after the opacity is fairly perceived to exist, is the only one to which I can assent; for if the operation is likely to be followed by success, and not to meet with an insuperable impediment from the peculiar nature of the cataract, it can only be at the particular period of commencement. The patient must then be made aware of a fact, that from the moment the needle enters the capsule of the lens, the opacity of that lens will rapidly increase, and in a few hours will induce perfect blindness, which can only be removed by the absorption of the lens and a successful result of the operation. Surgeons must not either forget, that by far the greater number of cataracts have made considerable progress before they are discovered to exist; and in many cases the cataract of one eye has gone on nearly to blindness before it is discovered.

I shall conclude by observing —

1. That the particular operation recommended by Mr. Stevenson is inapplicable in by far the greater number of persons afflicted with cataract, as they are usually met with, and when attempted will in general be followed by an unfavourable result.
2. That it is an excellent operation in all cases of soft or fluid cataract.
3. That Mr. Stevenson is correct in maintaining, that an



operation in one eye is capable, in certain cases, of causing the removal of a commencing opacity in the other.

4. That the kind of operation to be selected must depend on the nature of the cataract.

5. That Mr. Stevenson's proposition, of operating at the earliest possible period at which an opacity can be perceived, is deserving of a further and more extended trial.

#### ON THE OPERATIONS FOR CATARACT.

The operation for cataract has, like every other in surgery, undergone a great variety of changes, not only in the mode of performing it, but in the instruments by which it is accomplished. If we refer to the writings of the ancients, as well as to the traditional authority of the nations of the East, we shall find that operations were practised by them for the removal of the cataract from the axis of vision by depression; and that some had been bold enough to attempt it by extraction. Their opinion of the cataract being simply a thickened membrane deposited from the aqueous humour, rather induced them to abstain from extraction, and the difficulty they must have met with in accomplishing the operation, when they did attempt it, was an additional reason for rejecting it; and although traces of it may be discovered in the records of the ancients, they are merely references to the operation as to what had been attempted, rather than as the examples which it was recommended to be adopted.

Celsus is the first of either the Greek or Roman authors whose works have come down to us, containing a description of the operation for cataract, and it is remarkable, that whilst he speaks of it as one well known, he gives directions that may be considered valuable even at the present moment. He says, "After the needle has been introduced, it is to be inclined towards the cataract, which is to be depressed below the pupil. If it remains in that situation, the cure is accomplished; but



if it rises up, it is to be cut in pieces, that it may the more readily be disposed of\*."

There is reason to believe that this operation was practised in India by the Hindoos, at a period anterior to the time of Celsus, and a description of their method of operating has been given by Dr. Scott†, and by one of the assistant surgeons on the Bengal establishment; the latter of which is extracted, as being the most precise, although it differs from the other as far as regards the use of charcoal, which is not mentioned. This gentleman says‡: "A few days ago, while visiting at the house of a friend near Calcutta, I found a native old woman about to submit to the operation in the right eye, at the hands of a native, who had before performed it on the left eye of the same patient, with every success that could be desired. The instruments which he employed were very similar to those employed by Dr. Scott; and consisted of a lancet, of nearly the common shape, and a copper or brass probe, or needle, having the extremity of a triangular shape, for the length of about three-eighths of an inch. The point of this instrument is made very blunt, as also the corners, and the triangular part is tapered and rounded off to a narrow neck, which joins it to the handle-part of the instrument, about three-fourths of an inch from the point. The operator commenced by covering the blade of his lancet with a thread, which he wrapt around it, to within about one-eighth of an inch of the point, to prevent its penetrating farther than he wished into the eye; and in the same manner he wrapt a thread round the fine neck of the brass probe, about three-fourths of an inch from its extremity. The precise extent of the instrument that was covered by the thread, the operator seemed to regard as a matter of much importance, adjusting and re-adjusting the thread, according to a measure marked by two cross lines on the inside of his left little finger. This part of

\* Celsus, De Re medica, cap. vii.

† Scott, in Journal of Science and the Arts, No. III.

‡ Asiatic Magazine and Review, No. I, for July 1818, page 59.



the business he went through with many gesticulations, which he no doubt considered as highly necessary to ensure success to his operation.

“The patient was now seated upon the ground, on which the operator also placed himself directly opposite to her. I remarked to him, that as he was to operate on the right eye, a position behind the patient would be more favourable; but he observed that it was the same to him, as he could perform equally well with the left, as with the right hand. He then caused the woman, over whose left eye a fillet had been gently tied, to take hold of his cumberbund, or girdle, with both her hands; I stood behind her and secured her head, by placing the occiput between my knees, and holding my right hand upon her forehead. The operator then opened the eyelids, which he secured with the fore and middle fingers of the right hand, and without the assistance of any other speculum, easily succeeded in keeping the eye open. The patient was next directed to look upwards and inwards to the nose; and upon her doing so, the operator, with a lancet in his left hand, thrust the instrument into the eye as far as the thread would permit it to go. The incision was made at about the distance of a line beyond the side of the cornea, towards the external angle of the eye, and about one-eighth of an inch below the horizontal line passing through the middle of the pupil; and, as it appeared to me, was performed rather with a steady than a very delicate hand. Immediately on perforating the sclerotica, the lancet was withdrawn, and the eyelids shut; when I remarked, that not a drop of blood, or humour, or scarcely any tears followed the incision. In the course of a few seconds, the eye was again opened, and the operator proceeded to use the brass probe, already described. So very slight was the wound which the lancet had inflicted on the eye, that he was at first at a loss to discover it, and pressed the probe on a small vein, which he mistook for it, until I observed that the opening was lower down; accordingly the operator continued pressing the probe along the ball gently until he



found the wound, into which he introduced it, with a cautious boring motion of the instrument. When it had fairly entered the eye, he turned the thick end of it downwards to the cheek, and by this means elevated the point in a slanting direction, until he saw that it touched and raised the junction of the cornea and sclerotica, at the upper and inner corner of the eye. The triangular swelling of the probe was thus placed along the upper and back parts of the lens in its capsule; a small dossil of cloth was now introduced betwixt the handle-end of the probe and the cheek, on which the probe rested, and by this means the point was prevented from pressing on the cornea or sclerotica. The eyelids were again shut, and the probe left in this manner in the eye; and I remarked again, that neither blood, humour, nor any tears followed this part of the operation. A little lighted charcoal (a ball of gool on a common chillum) was now brought to the operator; who, opening the eyelids, applied it pretty close to the eye, for a few seconds. On removing the chillum, the operator took the probe in his left hand, and drawing it out a very little, elevated the handle, and began to press the triangular point upon the upper and back part of the lens and capsule, in order to depress them. At this part of the operation, the lens and capsule were brought to bear upon the inner side of the iris so closely, that not only the pupil, but almost the whole extent of the iris, became perfectly white; but from the light in which the patient was placed, I could not distinguish whether or not this appearance was produced by the dilatation of the pupil. The steadiness of the operator's hand and countenance made it also impossible for me to conjecture what degree of force he used to detach the lens; but, in his first attempt, he failed in accomplishing this, by the pressure which he judged it proper to employ. On finding he had not succeeded in depressing the lens, he again introduced the dossil of cloth betwixt the cheek and the handle of the probe, shutting the eyelids, and allowing the instrument to remain a few seconds suspended in the eye, as before. He then



brought the charcoal again within a little of the eye, which he had opened, when I remarked that the pupil had contracted to a very small point. He now made a second attempt to depress the lens, in the same manner as before, and with the same want of success: again all things were put in the same order, and, after a few seconds, the hot charcoal was re-applied, and a third attempt was made at depression. In this the operator succeeded; and slowly and steadily pushed down the lens to the very bottom of the eye. For a few seconds he kept the probe resting upon it. After it was fairly depressed, he questioned the patient, whether she had recovered the use of her eye, which, I may observe, had been completely lost. She replied she had; and not only saw him and the other people about her, but on his holding up his fingers, she told how many and what they were, and also discriminated and named several objects that were held up at different distances, and this she did as easily and accurately as any person could do, and seemingly without pain, although the lens, and most probably the capsule too, had been torn away, and the instrument still remained in the middle of the eye.

“The operator now gradually raised the probe, until he got it as nearly as possible into the position in which it had first entered the eye, and then gently withdrew it in the same direction in which he had introduced it. The eye was then moistened with a wet cloth; and both operator and patient said it would be quite well in a few days. I left the woman walking about in a verandah.”

The method of performed the operation recommended by the Arabians, by Avicenna and Rhazes, accords with that of Celsus. Albucasis\*, indeed, proposed to introduce into the eye a hollow needle, in the shape of a canula; and, by sucking at the extremity, forcibly extract the cataract.

Rocho Mathioli†, surgeon to Charles Ferdinand, Archduke of Austria, advised the introduction of a gold wire, en-

\* Appendix, varior. Instrumentorum.

† Scultetus, *Armam. Chir.*



closed in a canula, to seize the cataract, and by gently moving it, to extract it on the point of the wire. Albinus\* conceived this could be best accomplished by an instrument resembling a small forceps. Freytag† recommended its extraction with a needle bent like a hook; but it does not appear that any of these methods were successfully practised, even if they were ever actually attempted. In the year 1651, it was demonstrated that the crystalline lens was the seat of the disease; and we find, that, after that period, the different attempts which were made for its removal from the axis of vision, were by depressing it below the edge of the pupil. The immediate situation of the lens, or the part in or to which it was to be removed, have undergone some alterations, more especially by Scarpa and the German practitioners, which will be particularly described.

#### ON THE OPERATION BY DISPLACEMENT.

This operation has been usually called that of couching, or by depression; and whilst there was but one mode of doing it, the term depression was sufficiently comprehensive, and was not to be misunderstood; but since several methods have been recommended, not only differing essentially from each other in the operative process, but in the manner of displacement and the subsequent position of the lens, it is advisable to have a term for the operation generally, which may not interfere with and lead to a false conception of each kind of operation individually. I have therefore selected the "operation by displacement," as expressive of the fact, without suggesting any precise ideas of the process by which it is accomplished; and this I consider the more necessary from perceiving, that, in several works on this subject, authors, in recommending one, or objecting to another method of operating, have argued more against what it suited their own purposes to refute, than what was actually acknowledged to be

\* Heister, Instit. Chir. pagin. 480. 4to.

† Thèse soutenue à Strasbourg en 1721.



the practice or the fact, at the period in which they wrote. Thus, in inquiring into the merits of the operation by displacement, if we were only to notice the advantages and disadvantages which have been said to accrue from the ancient operation of couching or depression, we should be as far from a real estimate of the fact as we well could be in any inquiry bearing a strong resemblance to truth and impartiality, but in which neither were observed. To obviate this, I divide the operation of displacement —

First, Into operations posterior to the iris : —

1. Simple depression ; 2. Depression of Scarpa ; 3. Reclination of Willberg and Beer.

Secondly, Into operations anterior to the iris : —

Reclination through the cornea.

#### ON THE OPERATIONS POSTERIOR TO THE IRIS.

1. Simple depression. This operation consists in dislodging the opaque lens from its natural situation, and placing it in the vitreous humour, so far from, and under the level of the pupil, that it may no longer impede the passage of the rays of light, or prevent vision, and is the simplest operation of the three.

It is fairly divisible into three parts ; 1. The introduction of the needle ; 2. Placing it on the anterior surface of the lens ; 3. Removing the lens out of and below the axis of vision.

The patient is to be placed and the eye fixed in the manner recommended for extraction, the pupil having been previously dilated by the belladonna. The small spear-pointed needle is to be held steadily but lightly, like a writing pen ; the little finger resting on the cheek-bone or side of the orbit, so as to give due support to the hand, and prevent the needle from entering violently, or going too far, if the toughness of the sclerotica should require a considerable degree of pressure to be made. It should penetrate the sclero-



tica about a line and a half from the edge of the cornea (not nearer than a line, nor farther than one and a half), and half a line below its horizontal diameter, to avoid the long ciliary artery; the point being directed towards the centre of the eye\*, so that it does not enter directly on the lens and change its position, pushing it towards the nose; one flat surface of the needle should be upwards, the other downwards†. The triangular point of the needle is to penetrate in this direction, until the neck of the instrument has entered the wound. The first step of the operation is then completed, and the second begins with a double motion of the needle, which requires a little dexterity. The direction of the point of the needle is to be changed from the centre of the eye towards the nasal edge of the pupil, which can only be done by carrying the handle backwards towards the temple, and as it approaches this new direction it is to be turned so far (a quarter of a circle forwards) on its axis, that the flat surface, which at the commencement of the operation was upwards, may now be turned towards the operator. It is in fact in the position it would be in if it had been introduced in the manner more commonly adopted, and it is to be passed on in its new direction, until its point and flat surface are seen advancing behind the temporal edge of the pupil. It is to be carried on in the posterior chamber, between the iris and the cataract, until the point has fairly passed the nasal edge of the pupil. One flat surface is towards the cornea, the other pressing on the cataract. The second stage is now completed.

These two stages are equally applicable to the operation of reclination through the sclerotica, and the knife or needle is in the same situation as it would be in for the division or breaking up of a soft cataract, save that it is not quite so far across the lens towards the opposite side.

The third stage commences by a double motion, resembling

\* Hey's Surgery, page 63. Beer, Leitfaden, s. 88.

† Warner, page 95.



that of the second ; the handle of the instrument is to be depressed, so that the point of the needle may be elevated to the upper edge of the cataract, on which the broad flat surface of the instrument must be placed, by giving it a quarter turn backwards on its axis. The posterior flat face of the needle, which pressed against the face of the cataract, is now on its upper edge, and the needle is (excepting the elevation of its point) in the same situation as when it was first introduced. The third stage is now completed by raising the handle, and firmly depressing the cataract downwards and a little outwards. The handle of the needle should not be raised above the horizontal position, but it should be kept there steadily for a few seconds, to prevent the lens rising again, when the point is to be gently raised. If the lens remains depressed, the object of the operation is completed, and the needle is to be withdrawn in the same manner as it was introduced, only with the motions in an inverse order. If the lens rises up after the instrument, the depression must be repeated, and again a third or fourth time, with a longer interval between each attempt, until it can be lodged below the level of the pupil.

The needle to be used in this operation is called Beer's, of which a plate is given ; it is the spear-pointed needle formerly used, but made smaller and rounder at the neck. On the sides of the handle corresponding to the flat surfaces of the needle, a small piece of ivory should be inlaid, to mark them and prevent error. It is introduced with the flat surfaces upwards and downwards, that there may be less danger of injuring the long ciliary artery and the ciliary nerves. It is directed backwards to prevent its doing mischief, if it pass too forcibly into the eye, as it would then merely penetrate the vitreous humour ; and also to avoid the lens ; whilst at the same time it prevents the point of the instrument being turned or broken, which will often happen from a sudden motion of a fold of the conjunctiva, when the point is allowed to fall on the eyeball in an oblique direction forwards. The ob-



ject is to pass the needle through the coats of the eye, *viz.* the conjunctiva, the sclerotica, the choroidea, the insensible retina, the hyaloid membrane, and a little way on into the vitreous humour, so that the neck of the instrument may turn in the slight opening made in these parts without materially separating their edges. It is passed into the sclerotica a line from the cornea, that the roots of the ciliary processes may not be injured; and it should not exceed the distance of a line and a half, and never two lines, or the sensible retina will be injured; the medullary or sensible portion of this membrane not extending so far forwards as the insensible or membranous portion of it.

The instrument is now to change its position: instead of passing behind the lens, it is to be directed before it, and the flat surface placed against its anterior face. To effect this it is obvious two parts are exposed to injury, the ciliary processes and the lens itself. Beer and the oculists of the German school would seem desirous of persuading us, that this second motion of the needle can be accomplished without injury to either; but I am satisfied, that however possible it may be to do it, still it is never done. When the double motion has been given to the needle, it is, previously to pressing it on, parallel to the iris, and its point is between the edge of the lens, covered by its capsule, and the anterior circular edge of the ciliary processes. The point of the needle in its progress, so as to be seen behind the pupil, must either raise or penetrate a portion of the processes, or pass through the edge of the lens. Of the two injuries, the piercing of the lens is by far the most important, not as to the injury done to the part, for that is of no consequence, but as it impedes, and in many cases effectually prevents the completion of the operation, by precluding the possibility of depressing the cataract. To enable the operator to depress and leave the lens in any given situation, it is absolutely necessary that it should have no sort of connection with the needle by which it is depressed, or it will, in consequence of this connection,



follow the needle when it is elevated, and resume nearly its original situation. The same thing occurs, only in a more remarkable manner, in the operation for cutting up the cataract. If the needle, in passing the front of the lens, has been entered too far back, it passes through the edge of the cataract, and, to use a homely expression, pierces it like a fowl on a spit. When the edge is turned towards the lens to cut it in halves, and force is used for that purpose, the cataract recedes from the pressure of the shaft of the instrument; but the edge does not cut, and the operator soon perceives that the lens follows the motion of the instrument, that it is actually spitted upon it, that he can do nothing with it, and must withdraw the needle for the purpose of reintroducing it, clear of the lens. In some instances, if the very edge of the lens only be pierced, it will yield to a turning motion of the needle, but this is not to be depended upon; the knife must be withdrawn and reintroduced, when the lens, separated from its attachments, will be found to roll or turn round it, can be depressed but with difficulty, and seldom or never cut up, if that be the operation attempted. I consider it then a point of great importance, and fully established in this operation, that the lens is on no account to be pierced, and that this object (the integrity of the lens) is to be obtained, *if necessary*, at the expense of the ciliary processes.

That the ciliary processes are parts of great importance in a healthy state of the eye, cannot be doubted, from an examination of their structure and distribution; but that a principal part of their utility terminates with the removal of the lens, is, I think, almost equally well demonstrated in many cases of operation, especially by division, where they must have sustained considerable injury, and yet the vision of the patient has been as good, and continued so, as in any other case of cataract after operation. I have seen this very often, I have done it repeatedly, and therefore affirm it as a fact; but it is not a lesion of the functions of the ciliary processes that is, we are told, principally to be dreaded from wounding them, but



instant hæmorrhage into the chambers of the eye, obscuring the view of the parts through the pupil, preventing the completion of the operation, or rendering it necessary to finish it as it were in the dark, and incurring the risk of a great and destructive inflammation. If this were actually a fact, I am not certain which of the two injuries would be the worst; but I have no hesitation in saying that these dangers are imaginary, not real, that the ciliary processes may almost always be cut or divided without fear of their bleeding; I have cut them repeatedly without this or any bad effects whatsoever, either at the moment or at any subsequent time. The ciliary processes are certainly the most vascular parts of the eye; but the vessels are proportionately small, and bleed but little on being injured, if they are perfectly healthy. If they are in a state of derangement, and especially if they have suffered from inflammation, or are varicose, there can be no doubt but they will then throw out blood in sufficient quantity to be troublesome, but seldom to produce the very serious bad effects enumerated. I have strong reason for believing that the hæmorrhage is very rarely productive of mischief, not even if the operator has negligently cut the long ciliary artery, or the vessels are varicose. The testimony of all authors who have written on the subject is satisfactory as to the fact, but by no means of the frequency of its occurrence, and the best proof we have to the contrary is, that when little attention was paid to prevent these processes being injured, bleeding into the chambers was not more frequently observed than at present. The state of the ciliary processes, in health, may aptly be compared to the iris; and no one will dispute, that in very many instances the iris may be divided, or even a piece cut out, without any bleeding ensuing; whilst in others it can hardly be punctured without considerable hæmorrhage taking place. That the former is the healthy state of the iris is, I apprehend, not likely to be controverted. I wish then to be understood, as not recommending the ciliary processes to be divided, but that the needle should be intro-



duced as nearly as possible between their anterior edge and the capsule of the lens, without injuring either; but that care must be taken to preserve the integrity of the lens, even at the expense of the ciliary processes; and that in most cases they may be injured in a reasonable degree with impunity.

The third stage of the operation commences by placing the flat surface of the needle on the upper edge of the lens; but how is this to be accomplished from before, without touching the ciliary processes running towards this part? It may be done by dissection, I admit; but that it is done by the generality of operators, or in those operations which have proved perfectly successful, I cannot allow, and therefore believe I have additional reason for supposing they will suffer considerable disturbance without material injury. The flat surface of the needle being placed on the upper edge of the cataract, a question naturally arises, how far or how low is it to be depressed, in a perpendicular direction, or a little inclined outwards? Beer says, only until the handle of the instrument is brought into the horizontal position, that the lower edge of the lens may not press upon the retina; but then the upper edge is only half a line below the lower edge of the pupil, and, by pressing against the iris, will excite inflammation, and ultimately terminate in closure of the pupil. Two great evils are then impending, like Scylla and Charybdis, one of which it is not easy to avoid; and perhaps they are only to be avoided in hard lenticular cataract, by the fortuitous circumstance of the lens being small. If the lower edge of the lens descend perpendicularly, and the pressure be continued much below the lower edge of the pupil, it will be pressed between the retina and choroidea, either of which may be torn or bruised; and if amaurosis does not immediately follow, vision is soon impaired or destroyed, and the eye diminished in size, from the low inflammation which takes place on these membranes. If it be not sufficiently depressed, but allowed to touch the posterior part of the iris, it will irritate that mem-



brane as well as the ciliary processes, and equally cause the loss of the organ through low inflammation and amaurosis, even if it does not immediately produce a closure of the pupil and wasting of the eye.

From a due consideration of these two circumstances, with the almost impossibility of avoiding them both, I have no hesitation in condemning this method of operating, as one which ought not to be practised in any case of hard cataract, although it has the sanction of Beer, for such as are of small dimensions. For it appears to me, that the operation as preferred by Hey, Scarpa, Willberg, &c. is infinitely better, even in this particular case, which, it will be admitted, is rather estimated than precisely ascertained, and therefore liable to error.

Scarpa\* says, "With respect to the hard consistent cataract, it should be observed, that the word depression, used in the schools of surgery to express the manner in which this operation is executed, readily produces in the mind of the student an erroneous idea, that this merely consists in pressing the opaque crystalline with the needle, from above downwards, until it descends below the pupil. If this were the case, as there is not a sufficient space for firmly lodging the crystalline lens between the corpus ciliare and the iris, it would constantly follow, that, immediately after the operation, the cataract would rise up again, either entirely or partially, opposite the pupil. But the word depression, in this case, has a much more extensive signification than that which is commonly given to it. It includes two motions which the surgeon makes with the needle; one of which pressing down the opaque crystalline, the other burying it in the vitreous humour, by carrying it from before backwards, out of the axis of vision. By this precaution only is the opaque lens prevented from rising again, and in this sense only ought the

\* Briggs's Translation of Scarpa on the Diseases of the Eye, page 320.



term depression of the cataract to be explained and understood."

The needle Scarpa recommends is a very fine one, moderately curved at the point. "The curved extremity of this needle is flat upon its convex surface, sharp at the edges, and has a concavity, consisting of two oblique planes, forming a slightly elevated line in the middle, which is prolonged as far as the extreme point of the instrument, similar to the curved needle for stitching wounds. The handle is marked in the direction corresponding to the convexity of the curved point."

For the operation, the pupil having been previously dilated by the belladonna, "The surgeon should place his patient on a low seat, at the side of a window which has a northern aspect, so that the light coming from it may only fall upon the eye which is to be operated on laterally. The other eye being covered, although affected with cataract, the surgeon ought to place himself directly opposite the patient, upon a seat of such a height, that, when he is prepared to operate, his mouth should be on a level with the patient's eye. And, in order to give his hand a greater degree of steadiness in the several movements which the depression of the cataract requires, the elbow should be supported upon the knee of the same side, which, for this purpose, he should raise sufficiently by resting his foot upon a stool, or, if necessary, also by placing a small hard pillow upon his knee. An able assistant, situated behind the patient, with one hand fixed under the chin, should support the patient's head against his breast, and with the other, placed on his forehead, gently raise the upper eyelid by means of Pellier's elevator, carefully observing to gather the eyelid against the arch of the orbit, without pressing upon the globe of the eye.

"Supposing then the eye to be operated on is the left, the surgeon, taking the curved needle in his right hand, as he would a writing pen, with the convexity of the hook forwards, the point backwards, and the handle in a direction parallel to the patient's left temple; should rest his fingers upon the



temple, and boldly perforate the eyeball in its external angle, at rather more than a line from the union of the cornea and sclerotica, a little below the transverse diameter of the pupil, gradually moving the extremity of the handle of the needle from behind forwards from the patient's temple, and consequently giving the whole instrument a second motion, until its bent point has entirely penetrated the eyeball, which is effected with the greatest readiness and ease. The operator should then conduct the convexity of the needle upon the summit of the opaque crystalline, and by pressing upon it from above downwards, cause it to descend a little, carefully passing the point, at the same time, between the corpus ciliare and the capsule of the crystalline lens, until it be visible before the pupil, between the anterior convexity of the capsule of the lens and the iris. Having done this, he should cautiously push the hook, with its point turned backwards, towards the internal angle of the eye, passing it horizontally between the posterior surface of the iris and the anterior convexity of the capsule, until the point of the needle has arrived as near the margin of the crystalline and capsule as possible, which is next the internal angle of the eye, and consequently beyond the centre of the opaque lens. The operator then inclining the handle of the instrument more towards himself, should press the curved point of it deeply into the anterior convexity of the capsule and substance of the opaque crystalline, and by moving it in the arc of a circle, should lacerate the anterior convexity of the capsule extensively, remove the cataract from the axis of vision, and lodge it deeply in the vitreous humour, leaving the pupil perfectly round, black, and free from all obstacle to vision. The needle being retained in this position for a short time, if no portion of opaque membrane appear behind the pupil, which would require the point of the instrument to be turned towards it, in order to remove such obstacle (for, with respect to the crystalline, depressed in the manner now described, it never rises again), the surgeon should give the instrument a small degree of rotatory motion,



in order to disentangle it easily from the depressed cataract, and should withdraw it from the eye in a direction opposite to that in which it had been introduced, that is, gently inclining and turning the handle towards the patient's left temple."

Such are the words of Scarpa. It appears to me, in analysing this operation, that the needle should be introduced from a line and a half to two lines from the cornea, that it may the more readily pass into the vitreous humour behind, without touching the lens, until the point of the needle, with the convexity turned forwards, has been placed upon the summit of the opaque crystalline. To do this, the point of the needle must be elevated, passed over the edge of the lens, raising up the anterior edge of the ciliary processes before it, and passing in front of the capsule, through the opening thus made by laceration. Some nicety is requisite in doing this; and although the lens be slightly depressed before the needle passes between the "corpus ciliare and the capsule of the crystalline;" still I am of opinion that the corpus ciliare will in general be injured to a certain extent, which I mention, although of little consequence, because this operation is supposed to be done without it. At this point, an error of importance may be committed. If the operator slightly depress the lens, to be enabled to pass the needle over the edge of it, and then through the capsule (which may be done), without injuring the corpus ciliare, he may perhaps not pierce the capsule, but finish the operation, leaving it unbroken, if still transparent, and, from the disturbance it has suffered, to form a secondary membranous cataract. This inconvenience will be avoided by attending to the appearance of the convex part of the needle. When perfectly uncovered, or really in front of the capsule, it shines through the aqueous humour and cornea as it would through water, whilst, if covered with the capsule, the brilliancy of the steel is diminished, in a manner that cannot be mistaken again, when it has once been perceived; the instrument will also be confined in its motions in pushing it forwards into the anterior chamber, and the tissue-like appearance of the capsule may be observed with facility. When a doubt



even exists on this point, the operator ought to turn the needle so as to bring the point forwards, and by rotating it a little, he will directly see whether it is covered by capsule or not. Having satisfied himself that the needle is free, the point is to be turned backwards, and carried on horizontally between the iris and the anterior hemisphere of the capsule towards the internal angle of the eye, when it is to be pressed into the capsule and lens, and both depressed into the vitreous humour. The capsule being torn in the first instance, to allow the needle to be placed in front, is again pierced on the lens in the act of depressing it; the double puncture and the subsequent laceration must then destroy a considerable portion of it, and almost entirely prevent the occurrence of secondary membranous cataract. The last step of the operation is termed that of depression, but it is not a pressing of the lens downwards, so as to place it on its edge, that is intended to be expressed by the words "moving it in the arc of a circle," but simply, having firmly fixed the needle near the internal edge of the cataract, that it be carried from before backwards, downwards, and outwards, so as to lodge it deep in the vitreous humour, in the space between the insertions of the rectus inferior and rectus externus muscles, the anterior surface of the cataract looking upwards, the posterior one downwards. In this manner the lower ciliary processes are uninjured, and the tearing up of the retina and choroidea is avoided. The needle should be retained for a short time, to allow the vitreous humour to close in over the lens, which, on the other hand, settles in its new situation; and when the needle has been loosened by a gentle rotatory motion, and raised to a level with the pupil, any opaque membrane which may appear should be destroyed by moving the needle backwards and forwards until the pupil assumes the deep black colour of velvet. If the lens should follow the needle, it is generally in consequence of some attachment of its capsule at its lower edge to the iris, or zona ciliaris, which must be separated, and the cataract again depressed as before; and if, after repeated trials, the operator should be foiled, he has the satisfaction of



knowing that the lens is at such a distance from the iris as will not give rise to inflammation, and that he will have an opportunity in a few days of making another attempt, without endangering the eye. If, in the act of removing the lens, the pupil becomes of an oblong form, and this increases as the depression proceeds, "it is a certain sign that the capsule of the crystalline is adherent to some part of the posterior surface of the iris, and more precisely at the part where the pupil is elongated." This attachment is to be broken through by the point of the needle, when the pupil will become circular, and the lens remain depressed. If the lens follow the motions of the needle, and nearly recover its natural situation, the instrument must be withdrawn and reintroduced farther back, when the lens will readily be separated and depressed.

An operation similar to this has received the name of re-clination from Willberg, Beer, and the oculists of the German school, to distinguish it from simple depression, and prevent error by a mistake in the term employed. The needle is to be introduced precisely in the same manner as in other cases of depression, until it reaches the fore part of the cataract; when, instead of depressing the handle of it so as to place the point on the edge of the lens, the point is to be kept exactly in the front of the capsule, towards its upper edge; when, by pressing on it, and by bringing forward the handle in a diagonal line, obliquely upwards and forwards, so that the point of the instrument may press the cataract backwards, downwards, and outwards, it may be placed in the space between the under and outer straight muscles. The anterior face of the cataract looking upwards, the posterior downwards, the upper edge backwards, the lower edge forwards, having been pressed through the posterior capsule, and lying as it were on a layer of the vitreous humour, the external membrane of which separates it from the retina; of course, in a dilated state of the pupil, it is barely out of sight, and in some cases not actually so, although it does not interfere with the axis of vision.

The disadvantages and the accidents attending these two



operations being those of depression generally, may be of course considered together ; the advantages of each are, in Scarpa's opinion, that greater facility is afforded in rupturing the capsule and depressing the lens by a curved than by a straight needle, which, however, appears to be counterbalanced by the greater nicety required in introducing it, and in again removing it from the depressed lens, without at the same time elevating it from its position ; in reclination, that the operation is more simple, therefore more easily accomplished by a beginner, and the needle, having a sharp spear point, more readily divides any attachment, or acts upon a soft lens ; while, from the size of the point, it generally acts with as much certainty as the curved needle, without any of its disadvantages, except in the instance of its having pierced and as it were spitted the lens. Reclination is not however quite so certain in its result as Scarpa's depression.

Dr. Bowen, in a work actually printed and published in Paris in October 1823, although sold with London on the title-page, claims the following improvements on the operation of depression as recommended by Scarpa.

1. That the pupil is to be dilated by the belladonna previously to the operation.
2. That the needle is to be entered at the distance of three lines and a half from the cornea.
3. That by this process the lens is more readily and safely depressed, and the capsule more effectually removed. He terms it *Hyalonyxis*, from *ἵαλος*, glass (the vitreous humour being so termed from its resemblance to glass), *νυσσω*, I pierce ; and performs the operation in the following manner.

#### HYALONYXIS, OR VITREOUS OPERATION.

“The patient being seated, so that the superior part of the head does not reach higher than the superior part of the sternum of the operator, he takes his needle, previously besmeared with oil, as a pencil or writing pen, placing the weight of his hand on the cheek of the patient ; this produces



two very considerable advantages; first, it steadies the hand; secondly, in the event of the patient's moving, the hand preserves its relative position with respect to the eye, so that any movement of the patient's head can be of no importance to the surgeon. The patient being directed to turn the eye towards the nose, the needle, with its convex\* surface forward, corresponding with the iris, is boldly introduced into the globe of the eye through the sclerotica, three lines or three and a half from the transparent cornea, and a line below the transverse diameter of the pupil, to avoid wounding the ciliary artery, which pursues its course to the iris between the sclerotic and choroid coats, along the middle of the external convexity of the eyeball: if introduced at or below this point, you avoid all effusion of blood. The instrument passes into the vitreous humour, posterior to the lens and its capsules. The point of the needle is then brought forwards, from inclining the hand to the temple, and penetrates the posterior capsule.

“Should the lens be soft or fluid, the needle passes through its centre on its passage to the interior chamber: if solid, the instrument should be directed to its superior part, and by gently elevating the handle, the lens will be sufficiently depressed to allow the instrument to pass between it and the ciliary processes: it is then to be carried through the anterior capsule and pupil (which latter has been previously dilated with the belladonna) into the anterior chamber, without any risk or danger of wounding either ciliary ligaments, iris, or ciliary processes. The object the operator has in view is the laceration and removal of a large portion of the anterior capsule; that is to say, of greater extent and diameter than the pupil in its natural most dilated state; this is effected by three or four circular movements of the point of the needle, which should invariably be done. If the capsule be trans-

\* To avoid still more the wounding of the ciliary nerve or artery, the needle may be introduced with its cutting edge corresponding with the iris; and after having entered the eye, to be turned round with its convex surface forwards, and continued as we have here described.



parent, the inexperienced operator will scarcely be sensible of effecting any good, or change, by this circular movement of the needle.

“The correspondence in transparency and colour of the capsule to the aqueous humour is so similar, and the former so delicate, that no resistance of the needle is sensible to the fingers, when in reality the point is breaking down and removing from the axis of vision the membrane, so frequently the cause of secondary cataract.

“When the capsule is opaque, the effects of the needle are of course evident; the transparent or opaque portions should be conducted backwards and downwards with the lens, and buried in the vitreous humour, below the margin of the iris, and as much as possible removed from the front of the pupil. On retiring or withdrawing your instrument, a circular movement is similarly made with the point, for the purpose of removing every portion of the posterior capsule, which is also liable to opacity; so that a communication is completely established between the aqueous and vitreous humours. The anterior capsule, lens, and posterior capsule are now removed, so that the utter and total impossibility of secondary membranous cataract forming must be evident.

“Such is the operation for a solid cataract, enveloped by its capsule; but the lens we usually meet with, at least seven in ten cases, is either fluid, semi-solid, or curdy. When the instrument therefore penetrates the anterior capsule, and the operator commences his delicate circular movement, the aqueous humour becomes clouded or discoloured, which is the passage of the parts of the diseased lens into the anterior chamber, where its absorption is more rapid than in the vitreous humour.

“The views of the operator are the same; instead of quickly finishing the operation, the solid particles of the lens should be removed, by several movements of the needle, as much as possible from the axis of vision, either by depressing them into the vitreous humour, or bringing them into the anterior



chamber. The free movements of the needle, and the removal of the capsule into the vitreous or aqueous humour, as we have above described, ensure the success of the operation.

“The great desideratum in all fluid cataracts is the laceration and removal of the capsules from the axis of vision; for in all cases, when a free communication is once established between the aqueous and vitreous humours, absorption goes on, and your cure is almost certain.”

If Dr. Bowen had published his book at Paris in French, or at Naples in Italian, the improvements claimed by him might in either place have been valid. The first edition of my work was published in the beginning of 1823, and in that I had recommended the use of the belladonna to dilate the pupil, previously to any of the operations within the eye, without conceiving it to be any thing novel, having practised it for years\*. The introduction of the needle at three lines and a half behind the cornea, is returning to the practice of the ancient surgeons, as may be seen in the plates attached to their works, and is unnecessary. I had also shown that it was not followed by the bad consequences apprehended.

The description of the operations by displacement, whether of Scarpa or of Willberg and Beer (a method I had adopted long before I had seen even an extract from the works of the latter), is infinitely shorter than that of extraction, requiring less apparent care in its performance, less manual dexterity, and hardly demanding that more than one object should be attended to at the same time; there are, however, some inconveniencies and accidents attending its performance which it is desirable to avoid. I have already noticed the error of spitting the cataract with the straight, or pushing it inwards with the curved needle; when spitted, the needle has been entered too far before it is turned forwards, and it is best to withdraw it in the first instance, and to reintroduce it to a less depth, so that it may pass in front of the lens without meeting with re-

\* Vide pages 281 and 377 of the first edition.



sistance, or pushing it a little forwards, both of which are signs of its having taken an improper direction. If the curved needle has been introduced too near to the cornea, and too directly upon the lens, it pushes it towards the nose, displaces it from its situation and attachments, and may be the cause of injury to the ciliary processes ; the lens is depressed with greater difficulty, and is more liable to give rise to secondary membranous cataract, from the capsule not being so readily lacerated as on the surface of the lens in situ. When this motion of the lens inwards is perceived in introducing the needle, it ought to be withdrawn in a slight degree, and directed more towards the centre of the vitreous humour ; and if that be not found sufficient, it must be re-entered a little further back. The first puncture need not prevent the continuance of the operation.

It may possibly happen that the nature of the cataract has been mistaken ; or the operator, being in doubt, has chosen to make the experiment of depression. In either case, the surgeon must not lose his presence of mind ; on finding that the needle passes through the cataract, in every direction, without apparently making any impression upon it, he must be prepared for such an occurrence, and act accordingly. If the curved needle has been used, further attempts are not to be made to lower the cataract, but the needle is to be brought through the centre of it, with the convex part forwards ; the point is to be then turned forwards and backwards, the needle rotated on its own axis, and the point made to describe a circle as large as the pupil, and immediately behind it, so that the capsule may be fairly torn in shreds in this part, and the aqueous humour allowed free access to the opaque lens, which will soon begin to disappear. The lens, however soft, should be as little displaced as possible in an accidental case of this sort, to prevent its falling forwards and irritating the iris ; which part having been dilated by the belladonna, should be kept in that state until the inflammation has subsided. A case of this kind will often require a second operation for the complete removal of the lens. If the spear-pointed needle has



been used, and the lens be discovered to be soft, the point of the needle is to be made to act on the centre of the capsule, in the same manner and with the same subsequent precautions.

In other cases, the lens will often be solid, the capsule thin, and the lens reclines easily, or with so little pressure, where the straight needle is used, that this membrane will be merely slit by it; great attention must be paid to this circumstance, the point must be directed towards the pupil, and moved backwards and forwards, as well as a little upwards and downwards, to destroy the capsule; but in this, as well as in every other instance, the needle should be used gently, and not with too much irregular freedom.

The lens, in some instances, is imperfectly solid, so that, on pressure being applied, it separates into two or more pieces. The surgeon has here the choice of depressing them separately; or if small, which is much better, of pushing them into the anterior chamber.

I have already said, that if the lens be spitted, it will not, cannot remain in the situation in which it is intended to place it; but sometimes this rising of the cataract depends on its retaining some attachments, as Warner, Scarpa, Hey, &c. have noticed. Warner recommends raising it up with the needle, so as to cut them; but I believe this will be best effected by carefully ascertaining the point of attachment, cutting it with the point of the needle, and again depressing it. In all these manœuvres, the operator must always recollect, that it is the flat surface of the lens, and not the edge of it, that is to be laid against the bottom of the eye.

#### ON THE OPERATIONS ANTERIOR TO THE IRIS.

The reclinacion of the lens, by introducing the needle through the cornea and anterior to the iris, is an operation which has resulted from the practice of perforating the cornea for the purpose of puncturing the capsule, or breaking up the lens, in order to effect its removal by absorption. The operation of reclinacion through the cornea, has been principally



introduced and supported by Professor Langenbeck\*, of Gottingen, and is to be performed in the following manner: The pupil having been previously dilated to its utmost extent by the application of the belladonna, the patient is to be seated, and the eyelid secured in the usual way; the small curved needle, of which a drawing is given, held in the manner of a writing pen, is now to be introduced at the middle of the lower part of the cornea, the concave part being upwards, the convex downwards, and pushed quickly but steadily through the anterior chamber, until it touches the lens. This part of the operation will be assisted, and the point of the instrument more readily and certainly introduced at the precise spot intended, if the operator fixes the eye with the fore-finger of the left hand, immediate below this part, so as to be able to allow the needle to pass along, and to be supported by the nail in its passage into and through the cornea. The convex part of the needle, which is turned towards the cataract, is now to be passed upwards and placed against its upper edge and face, when the handle is to be raised so as to cause the point to pass backwards and downwards, carrying with it the cataract, which is in this manner reclined; the lower edge being forwards, the upper backwards, the anterior surface upwards, the posterior downwards. If the opaque lens should not be out of sight, it is to be depressed by lowering the point of the instrument, which should be kept steadily upon it for the space of a minute, and then gently raised, when, if the lens should not follow, it is to be withdrawn, and the eye closed, when the operation is completed. If the lens should rise and follow the needle into the axis of vision, the same proceeding for its depression must be repeated, under the same circumstances as in reclinacion or depression, behind the cornea; but if it be observed, that in consequence of the softness of the lens, the point of the instrument has sunk into it, a

\* Prüfung der Keratonyxis einer Methode den grauen Staar durch die Hornhaut zu recliniren, &c. Gottingen, 1811. Neue Bibliothek für die Chirurgie, 1. b. 1815.



rotatory motion must be given to it, between the finger and thumb, to extricate it previously to depressing the handle of the instrument, in order to withdraw it, which must be repeated until it is effected, and the lens remains reclined, although it will not always be depressed so deeply as not to be visible when the pupil is dilated. This operation is evidently adapted for hard cataracts only; but if a mistake should have been made, and the cataract be found to be so soft as to allow the needle to pass through it, the capsule must be torn in every direction, and as much of the substance of the lens brought forward into the anterior chamber as can be effected; the remainder will be removed by absorption: but in such a case, a second operation will in all probability be necessary. The pupil must be kept dilated, in all these cases of depression or reclination, until every sign of inflammation has disappeared; and, although an irregularity of it may sometimes take place as a consequence, it will be attended by a moderate degree of dilatation, whilst the same quantity of inflammation, in an undilated state of the pupil, would cause as great an irregularity with a corresponding degree of contraction. In performing this operation, as in that for puncturing or breaking up the lens, the keratonyxis, to be presently described, two great evils are to be avoided, the loss of the aqueous humour through the opening in the cornea, and pressure on the edge of the iris by the instrument, in depressing the lens after it is reclined. The first may be prevented by using an instrument properly made; the second will be best avoided by entering the needle at such a distance from the union of the cornea and the sclerotic as will allow it to pass clear of the edge of the dilated pupil in the act of depressing the lens, and yet not so high up as to be in the axis of vision, when the pupil is restored to its natural state; for a small white spot, or cicatrix, usually remains, marking the place where the needle passed through the cornea.

The after-treatment is the same as in the operations posterior to the iris.



## AFTER-TREATMENT.

After the operation has been completed, examinations for the purpose of ascertaining whether or not the patient can see are useless and improper. As the needle is withdrawn, the eyelid ought to be allowed to drop, and need not be reopened. A compress of folded linen should be placed over the eye, after it has been properly dried, and both eyes covered with a bandage, to prevent the admission of light, for a spasmodic action of the muscles might be induced from sympathy with the motions of the sound eye, and the cataract be displaced from its new situation. The patient should remain perfectly quiet in a dark room, and, if possible, for some hours in a sitting posture; no motion should be allowed to the head; the patient should be fed for three or four days on spoon victuals, such as light puddings, and the same precautions taken to obviate inflammation as in extraction. The eye may be opened on the third or fourth day, with the back turned to the light; when it will be found more or less inflamed, and must be treated according to circumstances. In general the patient will be able to distinguish objects at this period, although light will appear of different colours, and in most instances, a green silk shade may now be substituted for the bandage.

Sometimes a slight ecchymosis will be observed at the spot punctured by the needle, arising from a small blood-vessel having been injured, which appears alarming to the patient's friends, and occasionally gives a slight uneasiness to the eye, when the lid is passed over it; but it is in reality of no consequence, and disappears in a few days, without any application.

When it has been necessary to use the needle with freedom to lacerate the capsule, depress the lens, or separate its attachments, the edges of the puncture made by the needle in the coats of the eye do not always unite, and a slight protrusion takes place, which is either the vitreous humour and its pro-



per membrane, or, when the opening is too near the cornea, is caused by a protrusion of the choroid coat, connected with the ciliary processes and the iris, and gives a slight uneasiness in moving the eye, whilst it keeps up an action at the part, and red vessels are seen running on the conjunctiva and even sclerotica. In general it subsides gradually, and at last disappears, without the aid of any remedy, in much the same manner as a small protrusion of the iris through the cornea, and is often followed by the same irregularity of the pupil. If, however, it should subsequently prove troublesome, as an exciting cause of inflammation, a few drops of the *vin. opii* may be employed, or the *guttæ argenti nitratis*; or, if very rebellious, the *argent. nitratum*, in the shape of a fine pencil, may be applied to it, and a drop of oil put between the lids, to prevent inconvenience.

Having combated, and I trust effectually, the dread frequently entertained of hæmorrhage into the chambers of the eye, as a general result of a wound of the ciliary processes, whilst I admitted that bleeding did sometimes occur from a wound of these parts, when in a varicose or deranged state, it is necessary to mention, that it may also occur from separating the attachments of the lens to the iris, previously to or in the act of depressing it; but this hæmorrhage is rarely of importance, it may be sometimes even foreseen, and hardly ever prevents the completion of the operation. If the long ciliary artery be wounded, the blood frequently escapes by the side of the needle, but the bleeding is rarely so profuse as to oblige the operator to withdraw the needle before the lens is depressed, or sufficiently removed from the iris to prevent mischief. The blood thus thrown out will in general be absorbed without giving any trouble. If it be in greater quantity\*, filling up the anterior chamber, it ought to be evacuated by a small opening in the cornea, and the antiphlogistic system should be strictly pursued.

\* Beer, vol. i, page 223.



These perceptible accidents may be accompanied or followed by others, less obvious, but of infinitely more importance, as being dependent on more concealed and intricate causes. Of this number is violent vomiting, either coming on immediately or a few hours after the operation. This symptom, noticed by all the authors who have written on the subject, is properly attributed, by Heister \*, to nervous irritation; not arising, as he supposes, from consent of parts alone, but from more tangible injury to the ciliary nerves, in penetrating the choroidea, or to the retina, from the lens pressing against the external tunics. It may also arise, *it is said*, from the needle being entered too far back (beyond two lines), by which the sensible retina may be injured; or by the point of the needle penetrating or overreaching the lens, in depressing or retaining it in a state of reclination, so as to wound the retina. The occurrence of vomiting is at any period unfortunate, as it may, from the exertion and shock, cause the lens to reascend, and, in addition to the injury already committed, prove a source of greater mischief, by irritating the iris. Vomiting is, however, by no means so common an occurrence as it was formerly, since the parts to be avoided are better understood, and the operation of simple depression abandoned. It not only arises from consent of parts, or sympathy, but from direct communication with the great sympathetic, in the manner Ribes † has demonstrated. If the ciliary nerves only have been wounded, or otherwise injured, inflammation of the iris is likely to be the consequence, requiring active antiphlogistic remedies, combined with mercury, as soon as this state is perceived, whilst the irritability of the stomach should be allayed by opium ‡, saline draughts, camphor, and subsequently valerian, &c. as in cases of nervous irritation. In this case, the vision of the patient, if properly and actively treated, will not be ultimately much or at all impaired. If, on the contrary, the

\* Heister, part ii, page 436, 4to. 1763.

† Ribes, Mémoires de la Société d'Emulation, vol. vii.

‡ Warner, page 97. 1775. Beer, Leitfaden, s. 96.



vomiting has been caused by an affection of the sensible retina, either from the point of the instrument or the pressure of the hard lens, it is likely to be more or less accompanied by pain, and attended by a greater or less defect of vision, or even perfect amaurosis. I will not assert that this is absolutely diagnostic of the nature of the injury; but in those cases which have come under my observation, or in which I have been consulted, there could be little doubt of the fact of the defective sight, and the constant pains having originated from pressure on or laceration of the retina. Wenzel says, page 33, "Those persons who have undergone the operation of couching, sometimes feel constant pain in the eye as long as they live. These pains are probably occasioned by the injury which the retina sustains, in consequence of its pressure between the choroides and the depressed crystalline. I have had an opportunity of dissecting and examining the eyes of two women, after their decease, who suffered unceasing pain from the time of the operation; and in both these cases, the depressed crystalline was deposited on the retina, in the way I have mentioned." Daviel\* says, in regard to his post mortem examinations, "and I have also found the crystalline lodged between the retina and choroides, and these two membranes torn in several places." In these cases, although acute inflammation may be subdued, a low irritative inflammation will continue, be productive of great pain, and in all, probably, give rise to a closure of the pupil, with secondary cataract, or terminate even in suppuration of the organ. The antiphlogistic regimen, alteratives, or nervous medicines, can only be palliative, they cannot cure; and the only hope of relief depends on our being able to move the lens from its situation: the vomiting sometimes does this, and gives us a hint not to be neglected; occasionally it rises spontaneously, and we find it recommended to shake the head violently, with the hope of obtaining the same object. If these fail, I should have no hesitation, in an extreme case, of

\* Daviel, Mémoire, dans l'Académie Royale de Chirurgie, page 337, 12mo. edit.



introducing a needle, for the purpose of raising it, considering any evil more bearable than loss of sight, when accompanied by extreme pain, and that relief ought to be sought for at any risk.

When the rising of the lens produces, somewhat in the same manner, low irritative inflammation of the iris, from pressing against it, and this pressure continues, as is observable from the situation of the cataract, it is not only useless but dangerous to delay reintroducing the needle, and removing the lens to a more harmless situation. The idea of operating on an eye in a state of irritative inflammation will be, I am aware, alarming to many; but it must be recollected that it will be ultimately lost, unless relief be speedily obtained. We read indeed of cataracts redescending spontaneously after they had risen up from their new situation; but such things are not to be depended upon; and as to the solution of the cataract, the eye will be lost before half of either of these objects can be accomplished. The increase of inflammation, which will ensue, will change the character of the complaint, and render it amenable to vigorous treatment, by bleeding, mercurials, and counter-irritants, while the removal of the irritating cause will permit our remedies to act with effect. The belladonna should in these cases be applied every night around the eye, not only to relieve pain, but to keep the pupil dilated.

If the irritative inflammation should be, however, so great as to deter the surgeon from this early reintroduction of the needle, he must wait for a more favourable opportunity of doing it; the relation of the following case will be more explanatory and satisfactory on this subject than any detail I can give. Michael Moody, 64 years old, applied at the Infirmary three years back for a well-formed hard cataract of the right eye, and a commencing opacity of the lens of the left. The eyes being sunken, I decided on operating by depression, which was accomplished apparently with success. The subsequent inflammation did not subside at the usual period, but increased, and was accompanied by pain around the orbit,



in the forehead, and side of the head : the sclerotic coat showed signs of low irritative inflammation, the iris slightly changed its colour, the pupil gradually contracted, and vision was again lost. I took a favourable opportunity of freedom from pain, to perform the operation for artificial pupil by division, which succeeded, the pupil under the influence of the belladonna became a large one, and I could see the depressed lens a little behind and below it : vision was again restored in part. The pain returned however with equal violence : he suffered several attacks of irritative inflammation, the cornea became muddy, and he was again deprived of sight. I now determined on removing the lens from its situation, which operation I effected with Scarpa's needle, and depressed the lens further back downwards and outwards, but out of sight. The pain ceased, the cornea cleared up, and he now sees very well with a cataract glass. The other lens has become quite opaque. In these and similar cases of pain, opium, and belladonna applied around the orbit and on the side of the head give great relief : and whenever an operation is followed by pain, warm fomentations containing these narcotics in considerable quantity should always be had recourse to, in combination with the treatment already described.

Amaurosis may occur without any vomiting, and with little pain ; in these cases the retina has been injured ; the eye diminishes in size from the secretion of the humours being imperfect, a slight blush of inflammation is observable on the sclerotica for a considerable time, the pupil begins to diminish from low inflammation : it appears cloudy, as if a thin network were drawn behind it, which gradually becomes more opaque ; the cornea shrinks and flattens with the general diminution of the eye ; the iris, for the most part, becomes corrugated, convex, immoveable, and insensible to any degree of light ; or if it be moveable, it is merely a vibratory motion, dependent on disorganization of the vitreous humour, where the pupil has not closed.



## ON THE OPERATION BY EXTRACTION.

The introduction of the operation for removing a cataract by extraction is justly attributed to Daviel, a French surgeon, who first seems to have practised it in a regular manner, and to have supported his proceedings by an appeal to public opinion\*. The mere opening of the cornea for this purpose was not a new discovery. Rhazes† says, that, about the end of the first century, Antyllus opened the cornea, and drew the cataract out of the eye with a fine needle; in which practice he was followed by Lathyron. Haly‡, the Arabian, also notices, in his works, the operation by extraction and depression. Avicenna§ expressly says, that considerable danger attends this mode of operating, in consequence of the humours of the eye escaping, when the cataract is hard. These observations were, however, forgotten or neglected, as the opinion gained ground of the cataract being formed by a membranous deposition from the aqueous humour; a doctrine which led to a variety of methods for its removal, by hooks and wires. The certainty, subsequently acquired, of the lens being the seat of the disease, induced surgeons to take more decided measures for its removal; and when by accident it had passed into the anterior chamber, through the pupil, the old operation of opening the cornea was once more had recourse to. St. Yves has a chapter on this subject, the twenty-first, in which the method of performing this operation is clearly expressed in the following words:

“When the operation of removing the cataract, which has thus passed into the anterior chamber, is to be performed, the patient must be seated on a chair, with the eye fairly opposed

\* Daviel, “*Sur une nouvelle Méthode de guérir la Cataracte par l'Extraction du Cristallin*, 1747. In *Mémoires de l'Académie Royale de Chirurgie*, tome ii. Paris, 1753.

† Rhazes, lib. ii, c. 3, f. 41. Venet. 1529.

‡ Haly, Persa, *Practic.* lib. ix, c. 28, f. 163, c. ed. Venet. 1492, fol.

§ Avicenna, *Can.* lib. iii, tract. 4, cap. 20.



to the light; the lids are to be kept open with the thumb and fore finger of the right hand, and the cornea is to be opened with a fine cutting lancet, commencing a little below the level of the pupil and continuing it across to the opposite side, so as to leave only half a line on each side of the lower half of the cornea undivided\*. Through this opening a fine curette is to be introduced; and, by passing it behind the crystalline, its extraction is to be accomplished. The eye is to be dressed in the usual manner, and the patient placed on his back in bed, with his head a little raised. Although I have done many of these operations, I shall only relate one example of each of three kinds of these cataracts.

“The first was done in 1707, before M. Mery, of the Royal Academy of Sciences, on a merchant of Sedan, who came to Paris on account of a shaking cataract, which had passed through the pupil into the anterior chamber. It pressed so much on the iris, that it caused a very considerable pain in the head, and had deprived him of sleep for three months. I had never heard of such an operation; but considering that I did not hesitate to open the cornea, to evacuate the matter of an abscess lodged behind it, I conceived I might do the same thing for the evacuation of a solid body, and I operated in the same manner. On examining the substance thus extracted, it was found to resemble plaster; I afterwards placed the patient on his back, and M. Mery and I found the next morning that he slept well, which he had not done before for a long time, that the wound was cicatrized, and the aqueous humour which had been lost was completely restored.

“The second case occurred in 1708, to the celebrated surgeon M. Petit, in a priest, whose crystalline, which had been depressed some years before, passed, in consequence of sudden exertion, through the pupil, and lodged between the

\* If the lower half of the cornea be estimated at  $\frac{6}{12}$ , he directs  $\frac{5}{12}$  to be divided: in extraction, according to received opinions, nearly  $\frac{7}{12}$  would be divided. Daviel acknowledges this operation as the parent of extraction.



iris and the cornea. M. Mery and myself were present at the operation. M. Petit having first pierced the cornea with a needle, cut it open with a lancet, and withdrew what we discovered to be the crystalline. This gentleman was soon well, and I saw him in Paris more than a year afterwards, when he could read perfectly well with a cataract glass.

“My third, was the case of a poor man, who lived in the Rue Cassette, Fauxbourg St. Germain, and had been wounded in the eye, in consequence of which the crystalline was separated from its attachments, and passed through the pupil into the anterior chamber, between the iris and cornea. Having made an incision in the cornea, I drew out the lens, which was partly soft, partly stony; but as it adhered to the cornea, I was obliged first to detach it, and also to cut with a pair of scissors another attachment, which it had with one of the ciliary fibres, of some length. The operation succeeded perfectly, and the patient was soon well.”

St. Yves, then, so far back as 1707, pointed out the proper course to be followed when an *entire* lens had accidentally passed into the anterior chamber of the aqueous humour; he does not, however, appear ever to have met with this state of derangement as an immediate cause of depression; and it is not likely he should, for, at and before the period in which he lived, the needle was always placed on the upper margin of the cataract, which was merely depressed below the pupil; and if it did revolve, it was again depressed; and if at last it remained undepressed, it was still in a very unfavourable situation for passing through the pupil, which would in all probability be in a state of contraction, as a consequence of the irritation to which the iris had been exposed.

To these cases of St. Yves and Petit, the operation of extraction owes its origin. Daviel\* says, “A hermit of Aquilles, in Provence, having unsuccessfully undergone the operation for cataract in the right eye, came to Marseilles,

\* Daviel, in Mémoires de l'Académie Royale de Chir. 12mo. edit. page 372, vol. v.



and entreated me to operate on the left, which I did ; but not more fortunately than on the other. Having made use of a common needle, cutting on both edges, I was not only unable to depress the cataract, but several broken pieces of the lens passed into the anterior chamber, which also became so filled with blood that I could not see my needle, and was obliged to withdraw it, without having finished the operation. This determined me to follow the example of Petit\*, and open the transparent cornea, in order to evacuate the blood and fragments of the cataract, which had passed into the anterior chamber, which I accomplished by introducing a half-curved needle into the chamber, enlarging the wound on the cornea with a pair of bent scissors, and evacuating the contents. The pupil appeared clear, and the patient immediately perceived every object presented to him ; but as the eye had suffered much from the previous steps of the operation, this also was unsuccessful, from suppuration destroying the eye." This operation made considerable impression on his mind, and the following one, confirming the opinion he had long entertained, gave origin to the operation of extraction on the one hand, whilst it is almost a counterpart of several operations since recommended as new. "On the 8th of April, 1747, I was applied to by a patient, in whose eyes the cataracts seemed to be good, and favourable for operation. I began with the left eye, in which the cataract appeared to me to be the most solid, yet I found it impossible to depress it ; the pupil appeared clouded after the operation, and the patient could not distinguish objects in the slightest degree. Having no better success on the other eye, I decided on opening the cornea, as in the preceding case of the hermit ; I dilated the opening, raised the flap of the cornea with a pair of forceps, and with my small spatula (flat needle) I drew out from behind the pupil the different portions into which the crystalline had been broken by the first operation. This extraction was followed

\* Mémoires de l'Académie Royale des Sciences, année 1708.



by the expulsion of a part of the vitreous humour, which had been injured by the needle in the first instance; but this was not followed by any bad symptom, the patient saw very well, and was soon after cured." He subsequently says, "This case decided me on never again operating but by an opening of the cornea, whereby I might draw the opaque lens from its seat through the pupil into the anterior chamber, from whence it might readily be removed." Those who preferred the operation by depression were not, however, unmindful of the advantages to be derived from the removal of the lens through an opening in the cornea, under particular circumstances.

Platner says\*, if during the operation the lens have passed into the anterior chamber and remain, exciting pain and inflammation, an incision must be forthwith made in the cornea, and the lens extracted through this wound, either with a forceps or a little hook.

Chandler† expressly notices the received opinion, in the following words: "It is said, that the cataract sometimes passes through the pupil and gets into the anterior chamber of the eye, in which case the lower part of the cornea is ordered to be divided, and the cataract extracted."

#### OPERATION BY EXTRACTION DOWNWARDS.

The position of the patient necessarily depends on the operator's capability of using both hands with equal dexterity; for, if he confine himself to the right alone, he must materially alter the position of the patient when the right eye is to be operated upon, or adopt a different mode of proceeding. This appears so great an inconvenience to foreign authors, that they are disposed to consider a surgeon to be deficient in his profession who does not possess an equal degree of dexterity with each. There can be no doubt as to the greater appearance of it displayed by him who is thus gifted; but when we consider

\* Institut. Chirurg. 8vo. edit. page 779.

† Chandler's Treatise on the Diseases of the Eye, page 170. 1780.



that very few possess this happy talent, or are capable of acquiring it, even when they have been long practised in the use of a variety of instruments; and when we reflect on the errors which may possibly have been committed in endeavouring to attain it, we may, perhaps, be less disposed to value it at so high a rate; and our regret will be lessened when we find, that by altering the position of the patient, the eye can be readily submitted to the right hand of the surgeon, which is usually, from the customs of society, more certain in its motions than the left. The left eye should be operated upon with the right hand, and if the operator be ambidexter, the right eye with the left hand, or the position must be changed. For the left eye, the patient should be seated on a low stool or seat, the back of which, if a chair, should not be so high as to prevent the assistant's readily moving the head in every direction. He should be placed immediately before a light that is not very bright, that the pupil may not be too much under its influence. It should fall directly upon the eye, and not be allowed to enter from any other part, so that there may be as little reflected light as possible, to interrupt distinct observation during the several stages of the operation. The surgeon should be seated on a stool, and raised so much higher than the patient, that his breast becomes parallel with the patient's head, which allows him the free use of his arms, without raising them above their usual line of action, or inducing fatigue, and enables him at the same time to observe every part of the operation from above downwards. The legs of the operator are to be placed on each side of the patient, and the right foot raised by a stool to such a height as will enable the surgeon to rest his elbow on his knee, whilst his knife is on a level with the eye, and in this manner (if he requires it) give him support during the first steps of the operation. The assistant, who should be duly instructed in his duty, now presses the patient's head gently against his breast, where he fixes it firmly, but tenderly, by placing his right hand under the chin, if it be the left eye that is to be operated upon, having pre-



viously covered the other eye with a bandage. He then lays his left hand flat on the forehead, so that the points of the fore and middle finger pass beyond the edge of the upper eyelid. The lid is to be raised with the point of the fore finger, and fixed with the assistance of the other, by pressing the tarsus against the upper edge of the orbit; but neither should press on nor disturb the ball of the eye, unless where the assistant is *perfectly* acquainted with his business, and where the eye is very unsteady, when he may *lightly* help to fix it, by the slightest possible pressure on the upper part, until the knife is introduced, when even this light pressure should be removed. In doing all this, however, the greatest care should be taken that the cilia are not bent inwards by the pressure of the finger, or displaced, and left on the eyeball as a cause of irritation, which may readily be done if attention be not paid to prevent it. The surgeon draws down the lower lid with the fore finger of the left hand, which gently touches the conjunctiva, whilst the point of the middle finger, placed over the caruncula lachrymalis in the same manner, prevents, in a great measure, the eye from rolling inwards, and this gentle pressure may be continued until the knife has pierced the cornea on both sides, or the punctuation, as this is termed, has been completed, when it must be removed as unnecessary and injurious\*. Taking the knife in the right hand, in the same manner as he would hold a pen, he supports his hand as in writing, by separating the little finger from the others, and resting it on the edge of the orbit.

The operator now waits patiently until the eye ceases to roll, or he touches the cornea gently with the flat surface of the knife, until the eye appears perfectly quiet, when the point is to be entered one line from the union of the cornea and sclerotica, and rather above the horizontal diameter.

\* No greater pressure can be admitted with safety; and the specula of Beranger, Guerin, Pope, Petit, Le Cat, Poyer, Pellier, Pamard, Rumpelt, as well as those of more modern invention, are all abandoned as worse than useless.



In the directions given by different oculists for this the first step of the operation, there is great discrepancy of opinion as to the distance from the sclerotica. Wenzel directs the puncture to be made a quarter of a line from the union of the cornea and sclerotica; Ware, the twentieth part of an inch, or something more than half a line; Mr. Wardrop, one line; and Beer, at the distance of one-eighth part of a line. The intention of all is the same, *viz.* that it may be as near as possible to, but at the same time at such distance from the cornea, as will allow the point to penetrate it readily, and pass into the anterior chamber, near to, but without touching the iris; which will readily account, according to the different states of that membrane, for the difference of estimation of the distance. It is desirable that the incision be near the sclerotica, that the opening in the cornea may be as large as possible, and the knife is directed to be introduced above the horizontal diameter, to secure a division of fully one half its circumference, according to Beer; of nine-sixteenths, by Ware and Wathen.

All the operators of the present day recommend the incision to be made, as I have described it, in the lower or in the upper half of the cornea. The De Wenzels, who were celebrated for their success in operating, insisted upon its being made to the outside, obliquely from above downwards towards the inner angle. De Wenzel says, page 105, "If the section of the cornea be made in the oblique manner, as I have above recommended, not only many inconveniences will be avoided, but many advantages will often be obtained. In the first place, the operator will escape the danger of unnecessarily wounding the adjacent parts, such as the caruncula lachrymalis, the angular vein, the nose, and the tunica conjunctiva. These accidents are very likely to happen when the incision is made horizontally; that is, in a line with the great and small angles of the eye; and more especially in those cases where the eye is drawn inward, which is frequently the case when the patient is much agitated. In the next place, by this mode of making the section through the cornea, the operator will prevent the too hasty effusion of the aqueous humour. This is an important point, since, whenever it happens, the iris, getting before the edge of the knife, is in danger of enveloping it; and in this case, unless the mode of liberating it which I have indicated, by gently rubbing the cornea, be adopted, it is almost impossible to avoid wounding this membrane. Again, by this mode of operating the incision of the cornea may be made larger than by any other, and the passage of the crystalline through the incision being hereby facilitated, the irritation, which a difficulty of extracting it might occasion, will be avoided. But another, and one of the greatest advantages arising from this oblique



mode of making the incision through the cornea is, that the wound will afterwards be nearly covered by the upper eyelid; and its lips being thus kept in close contact, their reunion will be promoted, the cicatrix be made less apparent, and the danger of a staphyloma, after the operation, be diminished. When, on the contrary, the section of the cornea is made horizontally, if the upper lid becomes swelled, it will press against the superior part of the cornea, and retract or elevate the upper lip of the wound. And if at the same time the lower lid press the inferior lip of the wound inward, it will separate this lip still further from the superior, and often insinuate itself into the intermediate space. The air also, getting between the lips of the wound, will dry them, render them callous, impede their reunion, and consequently deform the cicatrix, and produce a train of accidents which too often terminate in a staphyloma. The last advantage I shall mention as arising from this oblique mode of dividing the cornea is, that the vitreous humour is less likely to escape through a wound thus made than when the incision is made horizontally."

The only real advantage gained by this mode of opening the cornea is avoiding the danger of the flap being raised by the under lid; and where the operation is done on an eye where the lids are naturally contracted, and not admitting to be opened wide, even Beer\* directs that the opening should be made in this manner, to prevent the lower edge of the incision, which must lie under the under eyelid, being raised, and a difficulty of healing and a large scar taking place. If the forehead project, or the eye be sunk, it is obvious that the incision cannot be made in this manner, without great danger of the point of the knife, from its obliquity, cutting the iris; and I believe this projection of the forehead to be the reason that has given the general preference to the horizontal mode of incision; for, if there be, in addition to that, a sunken state of the eye, or contracted lids, the operation of extraction is contra-indicated. I always operate on the right eye by making the incision in the upper half of the cornea.

The point of the knife having penetrated the cornea, the handle is to be slightly depressed towards the temple by an *almost* imperceptible motion of the fingers, and pushed forwards, steadily, neither too slowly nor too quickly, across the anterior chamber, with the under side of the blade near to and parallel to the iris, neither turning the edge inwards nor outwards, until the point shall fairly have passed out through

\* Beer, vol. ii. page 108.



the cornea, exactly opposite to where it entered, at the same distance from the sclerotica, and without the slightest pressure having been made upon it downwards. The punctuation of the cornea, as it is called, is now completed; and all pressure on the eye, either by the fingers of the operator or assistant, must be removed\*.

If the knife be entered at too great a distance from the sclerotica, and the point not fairly directed into the anterior chamber, it may be passed across the cornea, between its lamina, and the section of the cornea apparently completed without the anterior chamber being opened into, or in so trifling a degree as to render the passage of the lens through it impracticable. As most of the difficulties and unpleasant consequences, which occur in extraction, depend upon errors in the first stages of the operation, it is of the first importance that the proper method of entering the knife is attended to; and that the operator is satisfied, that the point is fairly in the anterior chamber; but as the point, if carried on in the same direction, might injure the iris, the slight motion backwards of the handle is given to place it in a parallel direction to the iris: this motion is however so imperceptible as scarcely to be perceived by a spectator, and if the operator is certain of penetrating the cornea properly it may be altogether dispensed with, for when overdone it tends to facilitate the loss of the aqueous humour. The point is rather carried higher than lower than the horizontal diameter of the cornea to ensure the division of one half of it. It is neither turned inwards nor outwards, that the angle of incision at the point of entrance may not be changed, the aqueous humour evacuated, and the iris thrown forwards, which would be the consequence of any alteration in the direction of the edge of the knife. Once entered, the point must not be in the slightest degree withdrawn. It is carried steadily across the anterior chamber for the same reason; but on its arrival at the internal part of the cornea, on the opposite side, a degree of resistance will be experienced from the inner membrane of the cornea, which is sometimes sufficient when the point of the knife is too flexible to turn it inwards, and by causing it to follow the con-

---

\* Beer divides the operation into three stages; first, the incision of the cornea; second, the opening and destruction of the capsule; third, the removal of the lens. The first stage he divides into four parts: first, the entering of the knife; second, passing it across the anterior chamber to the point of exit; third, its exit; fourth, the completion of the incision.



cavity of the cornea, pass into the iris at the ciliary ligament, or at its junction with the sclerotica, and prevent the due punctuation of the cornea. To avoid this evil, the knife, when it is on the point of reaching the inside of the cornea, should be pressed on with more force and quickness than it was carried across the anterior chamber, and thrust, as it were, through the cornea, rather than allowed to bend. This, if it be of a moderately good temper, it will be found sufficient to accomplish. During the whole of this process, particular care must be taken that the knife does not cut downwards, and leave room for the evacuation of the aqueous humour. If the operator cannot force the point of the knife through the opposite side of the cornea, he must withdraw it, and postpone the operation; or, if he be accustomed to difficulty and perfectly steady, he may bring it out lower down, which can always be done, and enlarge the incision with the blunt knife or scissors.

The operator has now three different things to attend to in the progress of the incision to its completion; first, that the iris does not fall forward below the edge of the knife; secondly, that the knife does not take an improper direction; and, lastly, that the point does not injure the internal angle of the eye.

The point of the knife having been made to pass through the cornea, it is to be pushed steadily on until the edge of the knife passes below the pupil; the handle of the knife is to be pressed slightly towards the temple, to raise the point and prevent its pricking the conjunctiva or interior angle of the eye; and now the edge of the knife is to be directed downwards, to complete a semi-circular section of the cornea, preserving the same distance in every direction from the sclerotica. The instant the knife begins to cut downwards, the aqueous humour escapes through the opening it makes in descending, and the iris, deprived of support, may fall forwards, so as to be in a situation to be cut by the knife in its further progress. If this should happen, the operator must rub the cornea gently with the point of the finger, which causes a contraction of the pupil and consequent drawing back of the iris, when he must complete the operation\*; but if the iris again fall forward, before this be accomplished, he must keep the finger on the cornea until it is effected, by which all danger of the iris suddenly protruding will be avoided. In addition to the difficulty of transfixing the cornea, already noticed, the division of the lowermost portion will sometimes be found difficult, from the peculiar

---

\* Mr. Ware says this is the most important direction given by the Baron de Wenzel in his whole book.



toughness and hardness it has acquired. The steady and equable pressure of the knife may here be assisted by opposing the nail of the fore or middle finger, as a counter-resisting point on which the incision may be slowly completed. The instant the knife has passed so far through the cornea, that the edge is below the pupil, and the danger of cutting the iris is obviated, the assistant should permit the upper lid to drop; and if the surgeon does not see distinctly, he may depress the lower eyelid very gently with the fore finger, until the incision is completed, when the patient should be allowed a few moments to recover himself. It is, however, a preferable mode of proceeding not to complete the incision all at once, but to withdraw the knife quickly, when the cornea is so nearly divided that only a sixteenth part, or from that to an eighth part, remains to be cut. The division of this portion is to be effected by introducing the small blunt or round-pointed knife, as soon as the eye has recovered from the effort it usually makes after the first incision.

In completing the incision, the eye is almost invariably perfectly steady, provided the cornea has been properly transfixed; but if the point of the knife be permitted to prick any part of the internal angle of the eye, a sudden start or involuntary motion is the consequence, and may be destructive of success; hence the precaution of bringing the point outwards, by slightly depressing the handle. If the iris be cut, great inflammation will follow, and probably failure of the operation, independently of the greater chance of a sudden evacuation of the vitreous humour, and an increase of difficulty in removing the lens. When the incision is completed at once, it should be done slowly, with an uninterrupted and steady motion forwards and downwards, more especially if there be any involuntary or spasmodic twitching of the eye, as the muscles now begin to act more powerfully in all cases, and their effect on the internal parts seems in some degree obviated by the resistance afforded by the knife, and would appear to be entirely frustrated by completing the division by a second incision as above described. The incision of the cornea cannot however be always accomplished by a *steady* forward downward or upward motion of the knife, in which case a little sawing motion must be given to the knife to enable it to cut freely.

Much difference of opinion has been entertained as to the form of the lower part of the incision; most surgeons recommend it to be attempted in the manner I have described, when the cicatrix will not cause a much larger scar than the opacity observable in the alterations of structure common in old people, and called *arcus senilis*, which hardly appears to injure vision. If the knife, however, in passing



out, be allowed to take a slanting direction, the cicatrix or opacity is much greater, and it has in some cases been so extensive as to render the operation nearly useless. This arises from having entered the knife too far from the sclerotica, when a small segment of the cornea only can be divided, which the operator perceiving, tries to prevent, by directing his knife to the inferior point of union of the cornea to the sclerotica, thereby cutting between its lamina, and increasing the extent of the future opacity without augmenting the size of the opening into the anterior chamber; or, having entered the knife properly, he has not been able to cut the cornea at an equal distance all round, but has slanted it a little forwards, and then downwards, producing the same effect as in the former instance. If, on the contrary, the knife slants a little backwards, the sclerotica or the iris may be cut, and the eye lost from excessive inflammation. This must be avoided; yet the Baron Wenzel \* preferred dividing the cornea close to the sclerotica; for, perceiving a drop or two of blood to follow such mode of division generally, he conceived it tended to prevent subsequent inflammation, and therefore adopted it; it is, however, more dangerous than useful, and tends to weaken the attachment of the iris to the ciliary ligament, whence it loses its support, and, falling forwards into the wound, giving rise to a protrusion of the iris between the edges of the incision, with subsequent great irregularity of pupil, or of at least a union of the iris with the divided part of the cornea.

Mr. Wardrop, with the view of obviating these difficulties, recommends the performance of the operation in the following manner: "Having previously oiled the knife, to make it cut more keenly, its point is to be thrust through the cornea, a little above its transverse diameter, and one line from its margin, in a direction as if it was to pass through the pupil, or nearly perpendicular to the spherical surface of the cornea. When it reaches the plane of the iris, the blade is to be moved a little upon the incision which is already made, as a fulcrum, so that the point is elevated and turned towards the opposite side of the cornea. It is then to be carried forward and a little obliquely downward, so that the cornea is again punctured at its transverse diameter, and at the same distance from the sclerotic coat at which it had been entered on the opposite side†. By these two incisions the blade has cut perpendicularly, or very nearly so, to the spherical surface of the cornea, and the gradual thickening of the knife, by filling up the wound as fast as it is made, prevents the aqueous humour from escaping. The eye is now completely secured

---

\* Page 100.

† The punctuation is completed.



by the knife, and the incision is to be finished by turning round the blade on its axis, thus keeping the edge turned outwards in such a manner, that the remaining part of the incision is a straight line, and, therefore, nearly perpendicular to the lamellæ of the cornea. If none of the aqueous humour has escaped before the last step of the incision is begun, it is sometimes necessary to withdraw the knife a very little, to allow a drop of it to escape, before the knife can be turned on its axis."—"The incision should be made so that the inferior edge of the wound is half way between the circumference of the cornea and edge of the pupil, supposing the pupil to be in a moderate state of dilatation. If it be made nearer to the sclerotic coat, then the advantage to be expected from this mode of operating will be lost; and, on the other hand, if it be made at too great a distance from the sclerotic coat, and consequently too near the pupil, the iris will be apt to fall forwards, and a portion of it pass through between the lips of the wound."—"In making the incision of the cornea in this manner, another circumstance also particularly deserves notice, which is, that on giving the knife the motion round its axis, after having punctured both sides of the cornea, there is a great risk of the iris turning over its cutting edge, some of the aqueous humour having generally by this time escaped. An operator who meets with this for the first time is apt to think a wound of the iris inevitable; but if he cautiously stops the progress of the knife, and presses the iris from its edge, by sliding the point of his fore-finger over the cornea, the incision may be completed with perfect safety."

Mr. Wardrop recommends having the eyeball properly fixed before attempting to introduce the knife, and supposes the five following advantages to accrue from his method of operating.

1. That a large portion, or ring of the cornea, is left attached to the sclerotic coat, and must form, from its thickness, a complete support to the iris.

2. That as the incision is throughout nearly perpendicular to the lamellæ of the cornea, the length of the incision of the internal layer will be greater than when it is made in the usual manner, and equal to that of the external one, consequently the lens will be more easily extracted through it.

3. The upper edge of the internal incision is also further below the edge of the pupil.

4. As the flaps are very small, the edges thick and not easily moveable, or apt to be caught by the motion of the eyelids, the lips of the wound are not liable to be displaced, and consequently the wound has a much better chance of uniting by the first intention.



5. The cicatrix which remains is scarcely perceptible, and cannot be distinguished when the cornea is looked upon in a direction perpendicular to its surface.

Of these advantages, the fourth I consider as the only valid one, and it is counterbalanced by the diminished size of the opening; so that, upon the whole, although the operation may be and is successful in the hands of Mr. Wardrop, still, from what I have seen, I do not consider it generally as more easy of performance, or more successful in its results, than the one usually recommended.

The patient having a little recovered, the surgeon, in all ordinary cases, now takes entirely upon himself the charge of the eye, and gently raises the upper lid with the left hand, whilst he slightly depresses the lower lid with the middle finger of the right, and introduces the hook or lance-pointed needle, for the division of the capsule. In doing this he should see the pupil distinctly; the point of the instrument should be passed under the flap, directed towards the interior angle, and carried upwards towards the centre of the capsule, the edge turned towards it, and several slight tears or cuts made into it in different directions, so that it may be cut in pieces, when the hook is to be withdrawn as introduced. During this part of the operation a bright light should not be allowed to fall on the eye, or the pupil will contract\*.

The introduction of the lance-pointed sharp instrument is owing to Beer. In most operations the capsule is extracted or completely destroyed, but in some it remains behind, either only torn or very partially destroyed on its anterior surface; which, if it be already opaque, or become so from subsequent inflammation, soon reunites and forms a dense white substance, obscuring and tending to cause a contraction of

---

\* The hooks sold in the shops were totally incompetent to accomplish the purpose intended, and those who used them must have altered them after they came into their possession, or suffered much inconvenience. I have taken some pains to correct this little irregularity, and to have the point of the hook placed at a right angle with the shaft of the instrument, so that when it is turned towards the capsule, it may penetrate it without difficulty. This trifle constitutes, nevertheless, one of the greatest improvements in the instruments sold for the operation of extraction hitherto made.



the pupil. The patient sees but indistinctly ; a secondary cataract, as it is termed, is formed, and requires another operation. To avoid this, we find many authors recommend an examination of the eye after the lens has been extracted, for the purpose of removing such membrane, if it exist, with the forceps, and by so doing they frequently cause a protrusion of the vitreous humour, and lay the foundation for subsequent high inflammation, irregularity of the pupil, and ulceration and opacity of the cornea, not to mention suppuration of the eye ; and sometimes even failing in the removal of the capsule, after this mischief has been excited. The best way of avoiding a capsular or secondary cataract, or the necessity for attempting its removal, is by taking care to divide the centre of it in the first instance, in the manner recommended. The pieces of capsule, cut or torn in this way, are either evacuated, ultimately absorbed, or shrink up out of the sphere of vision ; but even if any should be observed hanging in the pupil, none, or but very careful attempts should be made to extract them, unless the greater part of the capsule remain in a thickened state, when it should be taken hold of with Gibson's spring forceps, and removed in a very gentle manner, by turning the instrument between the finger and thumb until its attachments are separated.

The division of the capsule and the removal of the lens are two important stages in the operation, and every precaution, however trifling, should be attended to. During the division of the cornea, a clear steady light has been allowed to fall on the eye, and although its rays have not passed on to the retina, they cause a contraction of the pupil ; and whilst the iris is thus in part prevented from falling forward, under or before the edge of the knife, it aids in supporting the lens in situ against the efforts frequently made by the muscles compressing the eyeball. The object now to be attained is exactly the reverse ; it is a dilatation of the pupil, not its contraction, an effect hardly to be attained whilst the iris continues under the same influence, unless it be opposed by a counteracting power, that of pressure, which is highly mischievous. In a contracted state of the pupil, the capsule is but slightly exposed, and a very small part is only torn or cut by the instrument employed for this purpose ; which is also more liable, however delicately or dexterously it may be used, to bruise and injure the edge of the iris, proving an additional exciting cause of inflammation. Therefore, when the surgeon raises the lid, he should take care to see the pupil distinctly before he introduces the instrument for dividing the capsule ; and if the pupil be not moderately dilated, he should interpose a curtain before the window, sufficiently thick to break the rays of the light, without impeding distinct vision



on his part, when the object of dilating the pupil will be effected, and due facility afforded for cutting up the capsule, and for evacuating the lens.

If the light has been well regulated, and the capsule properly torn or cut, the lens will frequently follow the needle out of the eye, when a few moments of rest should be allowed. If it does not appear to be beginning to do so, the operator must endeavour to ascertain the cause, and especially to discover if it is dependent on any fault of the operation. If the incision of the cornea is not large enough, it must be increased with Daviel's scissors, or with a small knife, rounded at the point for the purpose. If the capsule has not been sufficiently divided, it must be now done; but if these important points have been duly completed, the operator must then assist in the expulsion of the lens; first, by giving or allowing motion to the eyeball, by which a gentle pressure is made on it; and, lastly, by increasing it with the point of the finger. In the first instance, he directs the patient to move the eye a little quickly upwards, by which the lens is frequently observed to move from its natural situation forwards, and at last, by the gentle pressure of the lid and muscles, to be protruded. If this should not succeed, the point of the fore-finger should be pressed gently on the lower part of the eyeball, and the pressure increased until the inferior edge of the lens is seen to rise, when it is to be continued in a steady gentle manner, until the greater part is expelled. The evacuation of the lens at this period may be assisted by the scoop, and the falling of the lid ought to be simultaneous with its expulsion.

If the previous steps of the operation have been well performed, yet the lens does not pass readily out, Beer \* directs the operator to make a little pressure, and continue it until the under edge of the cataract rises up and shows a black semicircular edge between it and the iris; when, without increasing the pressure, which would evacuate the vitreous humour, and without diminishing it so as to allow the cataract to sink, he must introduce

---

\* Beer, page 115.



David's spoon behind, and extract it. He acknowledges some vitreous humour must be lost, but thinks not quite so much as if the hyaloid membrane burst of itself from pressure. I recommend the patient to be placed on his back, and the hook to be used at the moment the curette is usually applied. Cases in which this accident occurs are in general, from the first, not proper cases for extraction, and they are rarely met with unless this operation has been improperly chosen.

The principal thing likely to impede the due evacuation of the lens, is too small an opening of the cornea. If attention be paid during an operation in which a difficulty of this kind occurs, it will be seen, that by the natural pressure and continuity of parts, as well as from the escape of the aqueous humour, the iris and cornea are in contact; and, from this latter not being sufficiently divided, it still affords nearly an equal degree of support to the lens, and prevents the under edge from turning forwards. Let this equable support be a little removed, and the rising of the lens will be very observable; but when the incision is increased to its proper extent, the lens is perceived to protrude with evident facility. If the attention be directed to the angles of the incision and the elevation of the flap, the reason of this facility, and the necessity of a certain extent of opening, will be obvious. I use the term extent of opening in contradistinction to extent of incision, which may be destructively great, and the serviceable opening yet too small; for it is evident that a whole circle of the cornea may be removed, yet the opening may not be equal to the size of the lens, whence the precautions insisted upon in making the first incision, and, in my opinion, the destructive effects following too large an incision, as inflammation, sloughing of the cornea, &c. noticed by Macnevin\*. If the pupil be contracted under the influence of light, and the lens forced through it, as I have seen it done, by pressure with the handle of the instrument, not only does inflammation ensue, but the vitreous humour frequently follows, nay sometimes precedes the expulsion of the lens. In no operation should any thing be effected by force which can be accomplished by art; the surgeon should always assist rather than violate nature, and he is perfectly inexcusable who does not avail himself of the means so amply afforded him by a judicious regulation of the admission of light.

Sometimes, after the section of the cornea has been completed, the pupil evidently contracts, and the lens remains in situ; in this case the opening in the cornea is usually too small, and must be enlarged;

---

\* Vide Edinburgh Medical and Physical Journal, vol. iv, p. 285.



but if the cataract advances and the narrowness of the pupil continues, the incision being perfect, it most probably arises from the sudden loss of the aqueous humour, and you must cover the eye and wait a few minutes for the dilatation of the pupil.

The curette, or scoop, is an instrument recommended by most authors to be used for removing any pieces of the lens, which may be detached in its passage through the pupil. Beer says \*, if the surface be soft or scabrous, some small portions will be detached by the edge of the pupil, and the operator should be ready with the curette to assist in their expulsion, that they may not fall into the posterior chamber. As soon as the great diameter has passed, and it is evident that some pieces must or will fall off, he introduces the curette at the under and outer corner, upwards, in order to push the pieces out, taking care that the wound is opened as little as possible, that the admission of air may be prevented: a circumstance on which the German surgeons lay great stress, although I am disposed to consider it of very little importance, as an exciting cause of inflammation. It is advanced, I conceive, merely as being consonant to their general opinions of the admission of air into shut sacs or cavities being a great cause of inflammation, on which opinion I cannot place any reliance, for precisely the same kind of reasoning, *viz.* that I do not consider it a great exciting cause in any healthy state of cavity or sac; and when I refer to the cases recorded by Wenzel and others, where fifteen and even more minutes have been taken up in removing these floating portions of lens and capsule, during which time air was freely admitted, without any great inflammation ensuing, I am the more confirmed in my opinion, and would rather attribute the subsequent inflammation to the repeated introduction of the instruments than to the admission of air.

Ware † is equally positive on the necessity of removing these small portions, although he admits that a rupture of the hyaloid membrane, and the escape of a portion of the vitreous humour, is the general consequence of the introduction of the curette, giving rise of course to a greater and more permanent inconvenience; and this, although he gives a case, page 298, in which, after a lapse of five weeks, these portions were all absorbed. If the capsule be divided thoroughly before any attempt be made for the removal of the lens, any opaque portions which remain will certainly be absorbed, and they should not be interfered with, unless they intervene or are likely to pass between the edges of the incision; and under any circumstance, in which it

---

\* Sect. 105, band 2.

† Ware, page 295.



may be considered advisable to introduce a curette or forceps, I strongly insist on the patient being placed on his back, when the danger will be considerably diminished.

If secondary cataract should still form, it must be treated as described under that head.

Beer\* recommended, in 1799, the following method of extracting a cataract, of a medium consistence, being neither hard nor soft, by which lens and capsule may be removed at the same time; he acknowledges that it requires great care, and I am so satisfied that it is one of those alterations which neither will nor ought to be adopted, that I only notice it from the great authority from which it proceeds. He directs the lance-pointed needle to be thrust into the centre of the lens, the flat surfaces being up and down; the lens is to be moved suddenly though slightly upwards and downwards, to detach it in that direction: the instrument is then to be turned so that the sides may be turned outwards and inwards, and the motions to be repeated to detach the cataract sideways. The needle being quickly withdrawn, frequently brings with it the lens and capsule, leaving the pupil quite black. If it should not come out, the more usual proceeding is to adopted.

In some rather rare cases, the lens, although opaque, is greatly diminished in thickness, so as not to exceed half its natural size; a circumstance which may be suspected, previously to the operation, by the unusual distance at which the opaque body seems to be situated from the iris; and in two cases of this description, which came under my care, the black vitreous humour appeared under the edge of the opaque lens, which seemed then to fall downwards, as if verging to the bottom of the eye. The slightest degree of pressure, in this stage of the operation, does harm, as it causes the rupture of the hyaloid membrane and the evacuation of the vitreous humour, whilst it rather impedes than assists the discharge of the lens. The operator must here act in a decided manner, by introducing the large hook usually attached to the end of the handle of the curette, underneath and behind the lens, which is to be in this way hooked by it and brought out of the eye. This is necessarily attended by the loss of a part of the vitreous

\* Beer, 109.



humour, but which is often found to be of little importance. The last case of this kind I have met with was in the person of Mr. Smith, who fills the office of a coal-meter on the Thames. On completing the incisions of the cornea, and rupturing the capsule of the lens, it became necessary to make a slight degree of pressure on the eye, when the vitreous humour appeared at the under edge of the lens, a portion of it was evacuated, and the lens sunk. Knowing that the consequences to the eye would be fatal if it were allowed to remain, I introduced the hook in the manner described, nearly to the bottom of the eye, fished it up, and extracted it. This gentleman has been able to do his duty perfectly well with that eye, so well indeed as to make him decline any operation on the other.

The operation being finished, and the lid having fallen, it is on no account to be raised for the purpose of ascertaining that the patient can see, but simply to enable the operator to observe whether the pupil is regular, and if the edges of the incision are in contact: which is best effected by making the patient turn his eye upwards.

In spite of all the care the operator can bestow it will sometimes happen, that, on the completion of the incision, the lens and the principal part of the vitreous humour shall be suddenly evacuated, and the eye partly collapsed; this is always an unfortunate circumstance, but is not necessarily a fatal one: I once saw this happen to both eyes of a lady in the hands of a very able operator, the lens appearing to be almost seated on the vitreous humour after its evacuation, yet she subsequently saw very well. I have seen, in other cases, considerable portions of the vitreous humour escape, and no bad symptoms ensue; and I am satisfied, that a larger rather than a less evacuation, if a portion must be lost, is the least detrimental of the two, as there is then less tendency to inflammation, or to a subsequent protrusion on any little irritation. The loss of a considerable portion is never the immediate cause of blindness, it is the inflammation which ensues



that is destructive of vision, and this occurs principally from a portion of the glutinous vitreous humour sticking about the edges of the incision, preventing the adhesive inflammation and consequent union of the cornea, and causing the suppurative, which extends itself to the internal parts of the eye from the iris, which is coevally affected. Whenever, then, an evacuation or protrusion of the vitreous humour has occurred, or seems likely to take place, the patient ought to be laid on his back, on the mattress on which he is to remain; and before the upper lid is finally closed, the iris should be restored to its natural position by the help of a small gold probe, if it will not return to it by gentle friction, so that the pupil may assume nearly its natural form. The edges of the incision are to be cleansed with the same instrument, so that as little as possible of the vitreous humour may be allowed to remain between them; and although the eye may be exposed to more light than is desirable, it may in part be useful, by causing a greater contraction of the pupil, provided it does not call the muscles into action. If one-fourth of the vitreous humour be lost, the sight will scarcely be impaired. If the loss amount to half, the patient may not see so well, and the result will be doubtful; but if a greater quantity escape, the collapse of the eye is often, indeed generally, fatal to the organ. The subsequent antiphlogistic treatment will be infinitely more severe, and the attention and confinement considerably greater.

If the flap of the cornea be properly adjusted, the union will be complete, and with little additional matter or opacity, the whole assuming nearly its natural convexity; but if the position of the flap be irregular, the posterior edge of it may adhere to the anterior edge of the cornea, and irregularity ensue, both at the part and in the general shape of the whole, which will project more at the point of union, whilst the upper part will be proportionably flattened. The inflammation will be greater, as well as the deposition of lymph, and the consequent opacity; for the edge of the flap of the cornea



must be rounded off by the deposition of lymph and the action of the absorbents: red vessels will be seen running on the sclerotica, constituting, for some time after the usual term of cure, a kind of chronic inflammation, which is to be treated as such; and after the intolerance of light has ceased, and the tears run cold, the *vinum opii*, the *argentum nitratum*, the *tinct. ferri muriatis*, will be found the best applications, with the *ung. hydr. nitr.* properly diluted, to subdue the chronic state of irritation likely to ensue on the lower lid.

If the two posterior edges of the cornea only adhere, and the anterior ones are not in contact, lymph is thrown out and adheres to them, the edges look thickened and white, and the cure may be equally prolonged; but sometimes the aqueous humour, being rapidly secreted, and not meeting with sufficient resistance, presses forward the newly united part behind the lymph, in the form of a partially transparent bladder, resembling what has been termed a protrusion of the membrane of the aqueous humour, which is sometimes seen to occur after an ulcer has nearly penetrated the substance of this part, before the ulcerative absorption ceased to be active. The pressure of this protrusion is felt, and produces uneasiness and even pain; the flow of tears is, however, less; of aqueous humour, none; the chamber, on examination, is full; the cornea is not collapsed; the pupil is circular, or but little irregular, so that the iris is evidently not implicated. This protrusion is likely to increase rather than to diminish, the parts not being able to recover themselves unless action be induced in them. A simple puncture, which relieves distention, is not sufficient to do this, and may be detrimental, for, on the evacuation of the aqueous humour, the iris is apt to fall forward; and, from the draining of the fluid, to be drawn into the little sac, and form a protrusion, with adhesion of the iris. The under portion of the protruded part should be cut away, with a pair of fine scissors, so as to excite sufficient inflammation to induce the cut surfaces to adhere, and efface the weaker part. After this operation, the eye



should be bandaged up, and treated as in the first instance for ten days. It must not be concealed, that there will be a much greater mark of cicatrix than in the more favourable termination to the operation.

If the flap of the cornea has been irregularly placed, or any portion of the vitreous humour has lodged between the edges of the incisions, so as to cause a continued drain of aqueous humour, or the iris has not been replaced, by gently touching the cornea, or stimulating it to contract by a little exposure, or even by replacing it with a probe if necessary, a protrusion of the iris may be, and an adhesion of it to the edges of the incision will be the consequence, with great irregularity and drawing down of the pupil, as a permanent defect, independently of the danger resulting from inflammation of the iris and of the internal parts of the eye. The restlessness of the patient, or unnecessary attempts to open the eye or move the lids, may equally be the cause of these accidents; if it be merely adhesion of the iris to the edges of the incision, an increase of inflammation is the only symptom; but if the iris protrude through the incision, it gives the sensation of a foreign body, and the flow of tears is considerably increased. In this case the eye is in great danger, and it is usually recommended that the lids should be opened in a mild light, and if adhesion should not have taken place as well as protrusion, it is said, that by gently rubbing the cornea it may be induced to retract; but if it should adhere, then nothing ought to be done, beyond keeping the eye constantly closed, and treating it as for high inflammation with protrusion of the iris after ulceration. To these precepts I do not assent, for I have found, in such cases, that the best method of treatment is to cut off the protruded portion of the iris with the scissors, provided it be sufficiently prominent to allow of its being done with facility, and afterwards to touch the part gently, but steadily, with the *argentum nitratum*; a mode of proceeding which ought always to be followed in similar cases of protrusion of the iris from ulceration of the cornea.



The usual practice of turning the patient's back to the light, for the purpose of presenting various substances to him to ascertain whether or not he can see, is a very idle and very injurious curiosity\*, tending always to a protrusion of the vitreous humour, and the evil consequences resulting from it; for no person can see an object, even in a state of health, without fixing or adjusting the eye, which is principally done by the muscles, and of course by a certain degree of pressure. The care which ought to be taken to cut up the capsule, renders an examination on that account unnecessary, and I prefer leaving any loose pieces of the lens, to extracting them by the introduction of an instrument, unless it can be done with great facility. The lid should only be raised (the eye being protected from a bright light) to enable the operator to see that the pupil is regular, and that the iris is not implicated in the edges of the wound. The eye ought then to be turned a little upwards, that the lid may completely cover the cornea, and prevent any motion of the flap. Inversion of the lower lid, in ever so slight a degree, or a very protuberent eyeball, which acts nearly in the same manner, and irregularity of the cilia, producing the same effect, or a very short upper lid, generally forbid the operation of extraction downwards, from the interference produced by the lid on the edge of the incised cornea. When the eye is in the natural state, nearly all the motion of the lids belongs to the upper, and in a state of rest the edge of it descends below the inferior margin of the cornea, the concavity of the tarsus corresponds with the convexity of the eyeball, and from the smoothness of both parts, motion is effected when the cornea has been divided, without affecting the line of incision, provided it has been properly adjusted. The due support of the upper lid is therefore invaluable, and the patient should keep his eyes rather above the horizontal line of vision to obtain it; for, if the edge of the lower lid should, by any accidental movement, raise the flap of

---

\* Abucasis, on this point, says, "*Methodus medendi certa clara et brevis, &c.*" Liber ii, p. 67. "*Præparetur infirmo lectus aptè factus in quo dormiat super dorsum suum in domo tenebrosa, et prohibeatur ab omnibus motibus, et a tussi, et præscribe cibum ei quo lenitur natura ejus, et non moveat caput suum dextra, neque sinistra omnino, et sit ligamentum secundum dispositionem suam usque ad diem tertium, deinde solve illud in domo tenebrosa et experire visum ejus, et propone illi res videndas, deinde reduc ligamentum usque ad diem septimum. Et non oportet ut facias illud post incisionem et curam statim.*"



the cornea, very serious inflammation will in all probability ensue. The lower lid is always to be depressed on every examination of the eye, and any loose or inverted lash carefully removed.

The bandage is to be applied as follows: an elastic network nightcap, which fits the head closely, is to be put on, if it has not been done previously to commencing the operation, which some operators prefer, having a piece of a roller fastened by its middle, to the centre of the nightcap behind. A small piece of lint, on which some ung. cetacei has been spread, is to be applied over the closed eyelids, a compress of fine linen or unwrought cotton is to be placed over it, and another over the opposite eye, when each end of the roller is to be brought forwards, made to secure the compress of its own side, and then passed over to the other.

#### ON THE INCISION OF THE CORNEA UPWARDS.

If the surgeon be ambidexter, he may perform the operation in the same manner on the right eye as on the left; but if this should not be the case, the patient must be placed on his back on a table, or on a mattress, or a firm bedstead with a head, or a high backed chair, so that the operator can stand behind without inconvenience; either of which situations will be found more comfortable to the patient, if the operation should be a little prolonged by any accidental cause, than sitting in a low chair and leaning the head backwards. The head being duly supported, the operator raises the upper eyelid himself, fixes the eyeball and lower lid, or an assistant depresses the lower lid, if necessary; the incision is then to be made with the same precautions as in the other method, the knife being held a little differently, the cutting edge being towards the finger instead of the thumb; the little finger towards the temple instead of the cheek. There is, however, infinitely less danger of wounding the iris, and gravity considerably favours the retention of the vitreous humour under circumstances in which it would otherwise escape. These advantages are so manifest, that I recommend young operators



always to place the patient on his back for an operation on the right eye; and even for the left, if they are at all doubtful of their own steadiness; for, although the erect position is certainly more favourable for the evacuation of the lens, it is not in that stage of the operation that the greatest difficulty is met with, or the greatest error is generally committed, but in making of the incision of the cornea.

When the operation is to be performed on the right eye, and the upper lid is elevated by the left hand of the operator, there is an evident facility afforded for opening the cornea upwards; the right hand and the knife are exactly in the position in which they are usually placed, and the incision is more likely to be made with regularity and precision. But independently of the advantages to be derived from position, we find oculists recommending this operation from its intrinsic merit, and they will be allowed to be great, and deserving strict attention, when it is known that it is the operation which Mr. Alexander generally prefers on both eyes, in all cases where it is not specially contra-indicated. The Baron de Wenzel, *secundus*, says \*, “When a cicatrix or opacity exists in the lower or external lateral side of the cornea, no new cicatrix will be added in this part of the operation; and a cicatrix in the upper and inner side of the cornea will neither interfere with the pupil nor afford any obstacle to the sight. In those cases, again, where the cornea is small, I have remarked that the lens is constantly large, and in them it is necessary to make a free incision, in order that it may come through it easily. Now, if the incision be here made outwards and downwards, the stretch upon the iris will be so great, when the lens comes through the pupil, that the iris will unavoidably be engaged in the section of the cornea, and a staphyloma be produced; the reduction of which afterwards is often difficult. But if the incision be made upwards and inwards, the upper lid will entirely cover the wound, and it will be found to heal without any accident.”

\* Mr. Ware's Translation, page 162, third edition.



When on the operation, by the usual mode of incision downwards, I noticed the unpleasant consequence of the incision being improperly made, *viz.* a very disagreeable opacity, not only vitiating the appearance of the eye, but frequently injuring and even proving destructive of vision. This will of course be avoided by cutting the cornea upwards. In the next place, the lens and vitreous humour are not so likely to be expelled by any spasmodic action of the muscles of the eye, as when this expulsion is favoured by gravity and the non-resistance of the parts immediately opposed to them. Thirdly, the operation is not more difficult of performance than the incision downwards, and is less liable to accident. It must, however, be acknowledged, that if subsequent accidents should occur, such as protrusion of the vitreous humour and iris, or derangement of the edges of the incision, the eye cannot be so readily opened to inspect or attend to them. If the iris happen to be implicated in the edges of the incision downwards, or united to them from any cause, the pupil becomes irregular, is of course drawn downwards, and more or less diminished in size; the sight of the patient is not, however, proportionably diminished, for the pupil is still in a very favourable situation for distinct vision, unless the cornea has become opaque, and no further assistance from operative surgery will in general be required. But if any of these accidents should cause a corresponding effect in the operation upwards, vision may be less distinct, for not only would the cicatrix of the incision be covered by the upper lid in the natural state of the eye, but the pupil is also drawn upwards, and the patient would be always obliged to look downwards, to enable him to distinguish objects distinctly. Fortunately these accidents and this derangement of the pupil are not so likely to occur as after the operation downwards on the right eye; and taking into due consideration the facility of giving relief, if they should occur, I still recommend it as the preferable operation on the right eye, in all cases where it is admissible; and it is equally so on the left, where any spasmodic motion of the eye



is expected, the operation of depression contra-indicated, or the success of the usual operation at all doubtful.

In performing this operation on either eye, the upper lid should always be raised by the operator, who will stand behind or to the side of the patient, and keep the head steady at the same time, in the position most convenient to himself, whether it be on a chair or in bed, which latter I consider the safest. The incision must be made with the same precautions and in the same manner as in the operation downwards, save that the knife should be entered below the horizontal diameter, so as to make its exit proportionately above on the opposite side, by which the entrance of the hook for dividing the capsule will be much facilitated, and less danger accrue of the flap being caught by the falling of the upper lid. If the opening, made with the usual precaution, be not considered sufficiently large, it must be increased, which can be readily done by the blunt-pointed bistoury, or the round-pointed knife, and with much less risk than in the operation downwards. The capsule is to be opened in the manner already directed; the evacuation of the lens solicited as in extraction downwards, with this exception, that when gentle pressure is necessary, it ought to be made from above, which causes the upper edge of the lens to move forwards rather than the lower, but which protrusion is also much regulated by the want of resistance opposed to it. The rest of the operation is to be completed with the usual precautions; but the attention must be particularly directed to the falling of the lid, in doing which the eye should be turned a little upwards, so that the lid in touching may not displace the edge of the incision, but fall a little below, and of course rather support than derange it. Previously to this being done, the state of the pupil should be carefully examined, and if it be not circular, slight friction should be made with a piece of fine linen, or cotton, on the outside of the fallen lid, for the space of a minute or more, which will often be found effectual in causing it to assume its proper form. If insufficient, the irregularity will



have arisen, in all probability, from some portion of lens, or congealed blood, which presses against the edge of it, and which the curette will remove; but if it should have occurred as a consequence of a rupture of the hyaloid membrane, and a loss of part of the vitreous humour, it will scarcely ever be quite restored to its circular form.

In order to avoid some of the difficulties attendant on the division of the cornea, Dr. F. Jäger, of Vienna\*, has proposed a double knife, one rather smaller than the other, attached by a button screw, yet capable of sliding upon it by pressure with the thumb, for the purpose of completing the incision of the cornea, when the punctuation is completed by the larger and lower one. It is to be introduced in the same way as Beer's knife, not parallel, but nearly perpendicular to the cornea; and afterwards carried across the eye, exactly like the single knife, with the blunt edge, or back, following an ideal line drawn directly from one side to the other, and with the external side of the fixed blade parallel to the iris, at the usual distance from the junction of the cornea with the sclerotica. When the point of the greater knife has transfixed the cornea at the inner side, pressure is to be made on the button-head with the thumb; the smaller knife is, in consequence of the pressure, pushed forward, while the greater keeps the eye steady, until the operation is finished. A needle is then introduced to lacerate the capsule, and the operation concluded by gentle pressure on the ball, if necessary, to displace the lens from its situation.

"In employing the double knife we may use it as we would a Beer's knife. After the counter-punctuation is made, we have a support for the ball in the greater knife, while the cut is performed by the smaller. There is no necessity for dragging forward the eye to enable the operator to complete the incision."

The advantages, above described, have not all been observed in the trials I have made with the instrument, and I

\* See Loudon's Short Inquiry into the Principal Causes of the Unsuccessful Termination of Extraction by the Cornea. London, 1826.



suspect they will be found to be more specious than real. I am not, however, as yet competent to give a decided opinion either for or against the affirmative one of Jäger, or of our author, Mr. Loudon.

In denying however to this instrument the merit which has been attributed to it, I am willing to concede that of its being the foundation for the construction of another, which I believe to be more perfect—to be capable not only of preventing nearly all the difficulties and dangers which occur in the extraction of the cataract, but of obviating them when they have occurred, either from accident or from any defect in the operator. It is a double instrument, one part being a cataract knife of the shape of Wenzel's, the other a silver blade of the same form, but larger and blunt. (See Plate 6.) The sharp steel knife is attached to the silver blade by a button-screw in the handle, which admits of the knife being pressed forward in the same manner as Jäger's; whilst it is so nicely and closely fitted to the silver blade as to form one instrument, neither the point nor the edge catching when the finger is pressed along it. An opening is to be first made in the cornea, with a common large Wenzel's knife (which I prefer to Beer's); and of such a size as to admit the double instrument, being the first step of the punctuation: the knife being withdrawn the aqueous humour escapes, and the iris is pressed forwards against the cornea, the eyelid being allowed to fall over it. If any protrusion of the iris should take place at the opening in the cornea, the protruded part will return to its place on gently rubbing the eyelid with a silk handkerchief, a piece of sponge, or the finger. The eyelid is now to be raised, and the double instrument introduced at the opening, the silver blade being next the iris. The silver point being larger than the steel one, easily raises the cornea and presses back the iris; so that by alternately raising and depressing the point of the instrument, it is readily carried across the eye in front of the iris and pupil, until the silver point touches the inside of the cornea, either immediately opposite the point of entrance, or as much above or below as the operator may think fit. The thumb which has hitherto



been resting on or near the button screw is now made to press it forward, and to protrude in consequence the sharp steel blade through the cornea, when the instrument readily cuts its way out, and completes the section of the cornea.

The principle on which this instrument is used is diametrically opposed to all others. The great object of Wenzel, Beer, and Jäger, and of all operators, is to prevent the evacuation of the aqueous humour, until the knife has passed across the eye through the cornea at the opposite side, and has begun to cut its way downwards. The great object of this method is to evacuate the aqueous humour, as a preliminary step to the operation, and to bring the eye to that state which renders the operation recommended by those surgeons impracticable. The great difficulty they have to encounter is the falling forward of the edge of the iris, at the moment the aqueous humour is evacuated, and the necessity which then arises for bringing the knife out before the incision is completed, or of wounding the iris. It is true, rubbing the cornea, as directed by Wenzel, will sometimes cause the iris to move from before the edge of the knife, but this is only when the punctuation has been well made; for it will not always do it, and the knife must then be withdrawn, and the incision completed with the scissors or blunt-pointed knife, the edge of which often injures the iris, and always cuts with difficulty; so that three or four cuts will be required, leaving the general edge of the cornea uneven and indisposed to adhesion. In my operation, the double instrument not being introduced until the eye is quiet after the first attempt made upon it, the iris has little disposition to fall forward, as it is termed, or turn upon the edge of the knife, because this movement of the iris is caused by the evacuation of the aqueous humour; and when it is disposed to do so from other causes, it is prevented by the blunt or silver blade, which keeps it back in its place. The unsteadiness of the patient's eye only delays, but does not otherwise interfere with the success of the operation, neither does the toughness of the cornea, both of which are often serious impediments in the usual



method of extraction, as preventing the perfecting of the incision by a single introduction of the knife, and rendering the use of the round-pointed knife necessary to enlarge the opening to a sufficient size for the passage of the lens through it. In the common method of operating it is dangerous to complete the operation by one incision, on account of the spasmodic action of the muscles, which often expels the lens and vitreous humour with great violence. By my method, this sudden spasmodic action has had time to subside, with the evacuation of the aqueous humour, by the formation of the first opening and the subsequent falling of the lid, and the operation may therefore be completed at once with little or none of this danger. Upon the whole, I consider that this instrument simplifies the operation in a remarkable manner, and renders one of the most difficult operations in surgery, one of very easy performance.

#### AFTER-TREATMENT.

The patient should be put to bed with as little movement of the head and body as possible; and if the incision has been made upwards, or with the patient lying on his back, it may be done at once in bed. Light is to be excluded from the room, and no noise made in the vicinity, which may cause starting or sudden alarm. The great objects sought are to promote and obtain union of the incised parts of the cornea, with as little inflammation as may be necessary for its accomplishment. The general knowledge of the operator of the science of medicine, of the human constitution in all its varieties under disease, and of the effects of remedies on these varieties, will here be his best guides; and, possessing them, he will save many eyes which in other hands would be lost. He must estimate every thing, and act accordingly. As a general rule, blood-letting will be necessary, but this is not to be directed by a certain measure, but according to circumstances, which every well-educated man will understand, and which it is not necessary here to describe. In healthy persons (and extraction should not, if possible, be the operation selected for any



others), the inflammation will be in general rather more than is necessary, and frequently in excess; and as blood-letting is the only remedy now available, I generally direct the abstraction of a quantity of blood a few hours after the operation, whether pain come on or not; and I do this the more willingly as I seldom have recourse to it as a preliminary or preparatory step to the operation. If I could exactly ascertain the moment when action had commenced and gone on sufficiently to enable the vessels to perform the office required of them, I would then abstract blood with the view of preventing its increase, because I should feel confident that such abstraction, after an injury, would not be attended with any improper diminution, although it might prevent any augmentation of inflammation; but this precise moment cannot be ascertained: if we wait for the recurrence of pain, we have delayed longer than is advisable, and *its total absence is not a positive criterion to determine us in refraining from the operation.* From four to eight hours after the operation, unless pain has come on sooner, I direct blood to be drawn from a large orifice, yet so as to avoid causing fainting or sickness; the quantity to be regulated, as in other complaints, according to the state of the patient. If pain should come on afterwards or continue, the bleeding is to be repeated; and if a few hours have elapsed without amendment, it must be repeated, with the understanding that the occurrence of syncope is only a guide where a quantity of blood has been drawn, for fainting after the loss of six ounces of blood is by no means likely to be followed by the same beneficial effects as after sixteen or six-and-twenty; and inflammation after extraction must be suppressed at an early period, if it be intended that the operation should be successful. This must be left, however, to the judgment of the practitioner, who will not forget that bleeding to a great extent, in the early stage of inflammation, does not produce that irritability and debility which follow the abstraction of the same quantity at greater intervals, at a later period; and whilst he regards it as his sheet anchor, he will not neglect other important aids. The bowels having of



course been opened before the operation, I am not desirous that any action should be brought upon them for the first twenty-four hours after it, as the necessary and irregular motions of some patients might tend to displace the edges of the cornea ; but at the end of that period there can be no objection to cathartic medicines ; and I prefer, in common cases, the saline aperients ; but where much inflammation is expected, I think it advantageous to resort to calomel, in a fair dose, according to the usual custom or habit of the patient : to women from three to five grains, to men from four to seven, combined with the opiate confection ; and if the inflammation continues, it may be repeated in doses of two grains, with one quarter or one half grain of opium, three times in twenty-four hours, or even every four hours, so as to produce the constitutional effect of the mercury with such rapidity as may be thought necessary ; for, if the inflammation continue long and run high, the iris and the internal parts of the eye will become affected, and no medicine has a better effect in suppressing it than mercury. If the sensation of sand in the eye, or irritation, be great, the lower lid should be depressed very carefully with the finger, to prevent the possibility of the edge being inverted ; and as the operator will have taken special care that no hair was left inverted or loosened during the operation, so as to irritate the eye, he may be easy on that point. The discharge of tears will be great, in general in proportion to the inflammation, and the scalding or the subsidence of heat in them are good criteria of the increase or decline of it. The moistening and drawing down of the lower eyelid will also facilitate their evacuation, and therefore afford relief ; especially if there has been any previous disposition for increased secretion from the meibomian glands ; which will be augmented by the inflammation, and cause the lids to stick together, so that the exit of the tears will be prevented, the lids distended, and pain and tension ensue, until it be evacuated by moistening and drawing down the lower lid, which must be done frequently, until the edges of the incision have united, when the lids must be treated as for chronic inflammation.



The eye which bears the light without inconvenience immediately after the operation, does not long continue to do so ; the increase of action necessary to promote union, and for the most part more than sufficient for that purpose, is accompanied by increase of sensibility ; there is some intolerance of light, and pain on exposure, which point out to us the impropriety of opening the eye, in addition to other reasons which have been noticed, until the second day, when the edge of the incision only, if it has been made in the lower part of the cornea, need be examined. If it be found regular, the operator ought to be satisfied ; if it be affected in any of the modes above described, he will proceed accordingly. After this period it may be more extensively examined ; but it must be borne in mind, that inflammation is often late in coming on, that it is frequently the third or fourth day before it actually appears to any extent, and therefore an unnecessary exposure is likely to be highly detrimental, as it may much increase what would in itself have been but trifling. The eyelids should be gently cleansed every morning with warm water, the lower lid being depressed to allow of its more ready accomplishment. On the third day the bowels should be again acted upon ; and, if free from pain, the patient may be allowed to sit up on the fourth day, for a short time ; and on the fifth, the eye may be fairly examined, but with great precaution, in a dull light, and even with a shade ready, to prevent the too sudden influx of it to the eye. During this period nothing but gruel, tea, arrow-root, and panada ought to be allowed ; but after it the patient may be permitted to increase slowly his diet, and to cover the eye with a shade during the day, instead of the bandage, and to look at large objects ; but he should never fatigue the eye. If low inflammation should continue, a blister to the nape of the neck will be of essential service, and the local applications, after leeches have failed, or ceased to benefit, may be gradually made stimulating, and the eye treated as for chronic inflammation, by scarifying the lower lid, the *liq. plumbi*, the *vin. opii*, &c. &c.



ON THE OPERATIONS FOR THE DIVISION OR BREAK-  
ING-UP OF THE CATARACT.

These are of two kinds—

I. Posterior to the iris.

II. Anterior to the iris, or through the cornea. The keratonyxis.

I. *On the Operations Posterior to the Iris.*

The operations for the removal of a cataract, by breaking or cutting up the lens in its place, have grown out of the operations of depression, and are only applicable to those, whose consistence is soft, and which are easily divided by a sharp-edged needle. When depression was the operation generally selected, the impracticability of depressing an opaque lens was often felt, in consequence of the needle passing through its substance in every direction. This circumstance, although long known and lamented, was not always found to prevent a cure; for although the pupil could not be rendered clear in the first instance, it subsequently became so by what was supposed to be a subsidence of the broken pieces, but which is now known to be a removal in consequence of absorption. Mr. Pott\* seems to have been the first who distinctly ascertained this fact, and established a method of proceeding upon it. He says, “I have sometimes, when I have found the cataract to be of the mixed kind, not attempted depression, but have contented myself with a free laceration of the capsule; and having turned the needle round and round between my finger and thumb, within the body of the crystalline, have left all these parts in their natural situation; in which cases I have hardly ever known them fail of dissolving so entirely as not to leave the smallest vestige of a cataract. In a few instances, where I have had fair opportunity, I have pushed the firm part through the pupil into the anterior chamber, where it has always gradually and perfectly dissolved and disappeared, not producing pain or trouble while such dissolution was ac-

\* Pott's Chirurgical Works, vol. iii, page 156.



completing." Mr. Hey\*, who was a great advocate for depression, adopted nearly the same method of proceeding, and recommended a needle for the purpose, which is, however, too large to be generally used with safety. Scarpa† deviated in such cases from the operation already described in page 295, for hard cataract, by breaking up and pushing as much of the divided lens and its capsule into the anterior chamber as he could, with his curved needle. Mr. Saunders‡, whose views had been successfully directed to the management of congenital cataract in children, tried several methods of proceeding, both posterior and anterior to the iris: first, by breaking up the lens and pushing it into the anterior chamber of the aqueous humour; and, latterly, by merely opening the centre of the capsule, and allowing the lens to remain in situ until removed by the absorbent process. Further experience has not decided in favour of the latter method, and I consider the former to be the better operation, as facilitated by the use of the two-edged needle, recommended by his pupil Sir W. Adams§. This gentleman's method of proceeding is as follows: "Having secured the eye by making a gentle pressure with the concave speculum, introduced under the upper eyelid, I pass the two-edged needle through the sclerotic coat, about a line behind the iris, with the flat surface parallel to that membrane; it is then carried cautiously through the posterior chamber, without in the slightest degree interfering with the cataract or its capsule. When the point has reached the temporal margin of the pupil, I direct it into the anterior chamber, and carry it on as far as the nasal margin of the pupil, in a line with the transverse diameter of the crystalline lens. I then turn the edge backwards, and with one stroke of the instrument cut in halves both the capsule

\* Hey's Observations on Surgery, page 61.

† Scarpa on the Diseases of the Eye, by Briggs.

‡ A treatise on some practical Points relating to the Diseases of the Eye, by the late J. C. Saunders, by Dr. Farre, chapter vi, on the Congenital Cataract.

§ Sir W. Adams's New Operations for the Cataract, page 255.



and cataract. By repeated cuts in different directions, the opaque lens and its capsule are divided in many pieces, and at the same time I take particular care to detach as much of the capsule as possible from its ciliary connection. As soon as this is accomplished, I turn the instrument in the same direction as when it entered the eye, and, with its flat surface, bring forward into the anterior chamber, as many of the fragments as I am able; by these means the upper part of the pupil is frequently left perfectly free from opacity. By cutting in pieces the capsule and lens at the same time, not only is capsular cataract generally prevented, but the capsule is also much more easily divided into minute portions, than when its contents have been previously removed.

“The needle which I employ in this operation is eight-tenths of an inch long, the thirteenth part of an inch broad, and has a slight degree of convexity through its whole blade, in order to give it sufficient strength to penetrate the coats of the eye, without bending. It is spear-pointed, with both edges made as sharp as possible, to the extent of four-tenths of an inch. Above the cutting part, it gradually thickens, so as to prevent the escape of the vitreous humour.”

In performing the operation for dividing or breaking up a soft lens (and it should never be attempted on a hard one), the operator may use either hand, in which case the lids should be elevated by an assistant: or he may sit behind the patient, as in extraction, which I prefer, and raise the lid and fix the eye himself, a speculum being necessary only in children. The needle being held in an easy manner, is now to be introduced, half a line below the centre, and at the distance of a line from the cornea, the pupil having been previously dilated by the belladonna, with one flat side backwards, the other forwards, the point being directed towards the vitreous humour rather than on a level with the iris, in order to prevent its being injured by any irregular motion of the eye. The *point* of the instrument having pierced the coats of the eye, the handle is to be depressed just so much as will direct the point of the needle into the posterior chamber of the aqueous



humour\*, when it is to be carried on between the iris and the capsule of the lens until it passes across the dilated pupil, and the point is observed to be behind its nasal edge. The needle is now to be turned between the finger and thumb a quarter of a circle, so that the *upper* edge of the needle may be placed against the lens enveloped in its capsule; when by a steady pressure, accompanied by a slight withdrawing motion of the needle, they are each to be divided into two parts, as nearly as possible in halves.

The needle is introduced a little below the central diameter, in order to avoid the long ciliary artery, and more particularly for the purpose of placing the edge of the needle on this precise line, within, or on the surface of the capsule, which would not be done if the point of the instrument were entered at this spot externally, for half the width of the needle would be above or below the central line of the lens, according to the manner of turning it on the quarter turn being made. When the edge of the needle is in contact with the capsule in its central line, or transverse diameter, a moderate pressure causes the needle to sink into the lens through the capsule, provided they be not firm, or tough, and their complete division may be effected by it alone; but if the cataract be of a firmer consistence, pressure will have the effect of carrying the lens backwards into the vitreous humour, but not of dividing it; a drawing motion being necessary to make the sharpest razor cut the hand: hence the necessity of the double movement of the instrument.

If the lens should yield to the needle, and be completely divided, by its passing through it, an important part of the operation is accomplished, and it is to be completed by bringing the needle back in the incision it has made, in order that it may be repeated in the upper and lower portions of the lens and capsule, until they appear to be divided into small pieces, when the flat side of the needle is to be turned towards the operator, and as many as possible of these pieces are to be pushed into the anterior chamber through the dilated pupil. When this is accomplished the operation will be completed, if the pupil be clear and transparent; but as this can seldom be so perfectly attained, and some portions of the lens and its

\* See particularly the remarks on this subject, page 289.



capsule will remain behind the iris, the surgeon must move the needle freely upwards and downwards, or in such direction as he may conceive will more effectually destroy the capsule.

When the needle is introduced and placed upon the anterior surface of the capsule of the lens, its point ought to be beyond, or at least as far as the nasal or inner edge of the lens itself; and, in some instances, will be under the inner or nasal edge of the pupil. When the needle is brought back after the first division of the lens, care must be taken that its point is sufficiently withdrawn to be distinctly seen clear of this part, or it may be injured. The temporal edge of the pupil may also be wounded at the same moment, in placing the edge of the knife on the lens, for the subsequent division of it, unless the flat side of the needle be turned towards the iris as it passes out of the first incision and over the surface of the capsule to the place where it is intended to make the second, when it is again to be turned on its edge; which precaution is the more essential, as the lens may be large and pressing against the iris, or the pupil may not be completely dilated.

The degree of force necessary to divide the lens is sometimes so great, that, before the division takes place, the lens is seen to pass backwards into the vitreous humour; which, from the pressure thus made upon it, offers a resistance, which enables the cutting edge of the needle to divide the cataract, on which it again resumes its situation; and a nearly equal degree of difficulty is experienced in cutting up the remaining portions, which, indeed, in some cases is scarcely effected, and a half or a quarter of the lens is brought at once into the anterior, or left in or depressed in the posterior chamber of the eye. In other cases, the solidity of the lens is such as to resist the pressure made by the knife, it is consequently carried back into the vitreous humour, past even its centre, when the reaction of this humour, pressing unequally against the upper or under half of the lens, causes it to turn over or under the needle, whereby it is separated from its capsule and all its attachments or support, and is loose in the posterior chamber of the eye. All further attempts to divide a lens, floating as it were in the vitreous humour,



would be futile, for it turns round the needle whenever pressure is made by its edge. In such a case the surgeon has a choice of two modes of proceeding; either to depress the lens or to place it whole in the anterior chamber, and then extract it. The depression is to be effected by what is termed reclin<sup>a</sup>ation, that is, the lens is to be placed on its flat surface, and in this manner depressed below the level of the pupil, and retained in that situation until it remains stationary. It will frequently, however, rise so much as to be seen, although it may not impede vision, and, being separated from its capsule, it will gradually be removed by the absorbents\*. When the removal of the lens is preferred, the needle is to be carried behind it, by means of the flat side of which it may in general be readily pushed whole through the pupil into the anterior chamber of the aqueous humour, from whence it ought to be extracted†.

The great necessity which exists for placing the edge of the knife on the exact central line or diameter of the lens, in the first instance, will now be duly appreciated, as the only manner in which a sufficient resistance can be obtained from behind, by causing the pressure to be diffused over a larger surface, *viz.* that occupied by the whole posterior face of the lens. If the edge of the knife or needle be placed above or below the central line, the lens begins to turn over or up, almost as soon as the pressure is applied with sufficient force to carry it backwards, and in this way it often slips at once through the pupil into the anterior chamber.

If this operation has been attempted upon an eye in which the vitreous humour is not perfectly sound, and this state is not always discoverable; or upon one which is in a dissolved, or, as it is often termed, fluid state, the division of the lens will not always be effected, although it be sufficiently soft to cut readily if the vitreous humour were more healthy. The lens, separated from its capsule, will sink as it were, or be

\* See the observations on the operation for cataract by displacement, page 287.

† See the observations on the compound operation for cataract by displacement and extraction, page 366.



depressed of itself; or, if it should admit of a partial or complete division, the pieces will disappear in the same manner. In some instances, the eye will remain clear, and the pupil transparent; in others, the whole lens, or the pieces, will be observed to have risen and to be floating in the vitreous humour; but they subsequently disappear, unless the lens has been removed, enveloped in its capsule, under which circumstances it shrinks and becomes rounder, but never is removed by the absorbents. If the vitreous humour be found in a dissolved state, the lens should not be extracted: the surgeon has then no choice of proceeding, reclinacion is his only resource.

When this operation is attempted upon a lens which is in a very soft or gelatinous state, none of the difficulties enumerated are to be met with, but others occur equally deserving of attention. The size of the lens, which causes it to press against the iris, not only renders the passage of the needle between these parts more difficult of accomplishment, but exposes the iris to greater danger of being wounded. The gelatinous state of the lens allows the needle to pass through it in every direction with the greatest facility; but its non-resistance renders the removal of it into the anterior chamber of the aqueous humour equally difficult. The object of the surgeon, when operating in this manner, ought to be, to effect the destruction of the anterior part of the capsule, in order to expose the lens to the action of the aqueous humour, the first effect of which is to harden and render it more solid, previously to its removal by absorption; a circumstance which, whilst it facilitates any further operation, may prove immediately injurious, by irritating the posterior surface of the iris. To prevent this, and indeed to give to this operation, as in all others of the same kind, the best chance of success, the pupil should not only be fully dilated previously to the operation, but retained so for several days afterwards, or until any inflammation, which may arise, has subsided: pressure on, or friction against the iris will be avoided, and, what is of as



much consequence, the divided portions of the capsule cannot adhere to the posterior part of it, whilst a greater opportunity will be given for the removal of the whole by the action of the absorbents, and a repetition of the operation be perhaps obviated. In such cases a second, and sometimes even a third operation will be necessary, before the pupil can be perfectly cleared, and these will be most frequently required when the capsule has not been fully divided, more especially towards its centre, and when the pupil has not been kept dilated. In the first operation, the attention of the surgeon must be directed towards the destruction of the centre of the capsule, as well as the breaking up of the gelatinous substance of the lens; and after the knife has sunk through and completely across its surface in several directions, the instrument should be withdrawn, so that the point may be directed upon and a little beyond the central part of the capsule, which, by repeated motions of the edge of the needle, upwards and downwards, and backwards and forwards, is to be destroyed. In a second operation, the attention will in general be required more to the separation of the adhesions which the capsule may have formed to the iris, than to protruding the portions of the lens which remain into the anterior chamber; and as the capsule thickens and becomes tougher with age, the sooner the operation is repeated, after the inflammation has subsided, where it is likely to be necessary, the more easily will this part be again cut up and separated from any attachments it may have formed. Sometimes, by a repetition of these operations, the whole of the lens will be removed, yet a considerable portion of capsule will remain in a thickened state, demanding then a different mode of proceeding, and constituting a *secondary capsular cataract*.

When in any of these cases, or indeed of cataract generally, a portion of the iris adheres to the capsule of the lens, the disease obtains the name of an *adherent*, or *partially adherent* cataract, whether hard or soft. If the adhesion be general, it must have taken place as a consequence of inflammation; and the pupil will, in almost every case, be so much



diminished in size as to render an operation for closed pupil necessary, which state of eye will be subsequently treated of; but when only a small portion of the iris adheres to one side, whilst the remaining part of the pupil is dilated by the application of the belladonna, the operation must be begun by introducing the two-edged cutting needle in the manner already described, and carrying it over the surface of the lens until the point reaches the part of the iris which is adhering to the capsule; this adhesion is to be separated by a gentle insinuating motion of the needle, which, when it is observed to pass freely between the iris and the lens, may then be turned, so as to complete the remaining steps of the operation, either by division or by displacement, or, if under fitting circumstances, by the compound operation of displacement and extraction, either of which I prefer, as completing the operation, to withdrawing the needle, and after the inflammation arising from its introduction has subsided, attempting another operation for the removal of the lens. In all cases the application of the belladonna will be essentially necessary to maintain the pupil in a dilated state; but if the lens be left in situ, it will frequently be incompetent to prevent a partial if not a complete reunion of the separated parts, the presence of the lens causing a greater degree of inflammation than would otherwise have taken place.

## 2. *On the Operations anterior to the Iris, or through the Cornea. The Keratonyxis.*

The remarks already made, pages 285 and 314, on the earlier methods of operating, show that the opening of the cornea for the purpose of removing the whole or a part of the lens and its capsule, was well known to the ancients. The mere puncturing of the cornea, for the purpose of removing the lens by depression or dissolution, is of later origin. The first operation, for the latter purpose alone, that I am acquainted with, is noticed by Mayerne\*, in 1690; who, after

\* Mayerne (Theod. de) Praxis medica ad Exemplar Londinense, 1690, impressum novissimè recusa, &c. Genevæ, 1692. Page 100.



giving an account of a case in which a spontaneous displacement of the opaque lens took place, and the patient recovered his sight, says, "*Mulier Angla, oculista, vidente my Lord Rich filio Comitis Warwick, acu aperuit corneam supra pupillam, et humorem aqueam exhaustit sive affluere sivit, qui turbidus et obscurior factus, visionem imminuerat, ita ut æger quasi per velum se omnia confusè cernere crederet. Post humoris effluxum oculus concidit, applicata remedia, imperata quies in tenebris; prospectum inflammationi. Aliquot post diebus postliminio succrescente humore aqueo, qui est excrementitius, non pars corporis, et qui reparari potest; intumuit, sive repletus oculi globus; punctura ejus occlusa et consolidata nulla remanente cicatrice. Restituta visionis acies, et perfectè curatus fuit æger.*"

The fact of the lens, when broken up or injured, disappearing, apparently by dissolution, was, however, previously known; and although the honour of the discovery is not directly attributable to any one, Barbette\*, without laying claim to it as his own, testifies to the fact in the following words: "*Licet cataracta non satis intra pupillæ regionem sit depressa, dummodo in particulas sit divisa, perfecta visio intra sex aut octo septimanas sæpissime redit, licet tota operatio absque ullo fructu peracta videatur; quod aliquoties experientia edoctus loquor.*" Gleize†, 1786, having commenced an operation by extraction, was prevented from completing it by a sudden movement of the patient's head; instead of enlarging the opening by the scissors, the idea came across his mind that he could introduce a needle through the opening he made in the cornea, and depress the lens; he tried, and effected it. This induced him to invent a new method of operating, which he describes as follows, and published in 1786: "Two hours previously to the performance of the operation, two or three

\* *Chirurgia Barbettiana*, pars i, cap. xvi, 1672.

† Gleize, *Nouvelles Observations pratiques sur les Maladies de l'Œil*, 1812. Page 118.



drops of a solution of the extract of belladonna, in the proportion of three grains to a drachm of water, are to be dropped upon the cornea, and the eyelids are to be allowed to close. The pupil being in consequence dilated, I make an opening in the side of the cornea, and then divide the capsule of the lens in a circular manner with the spear-pointed needle, depressing at the same time the lens below the pupil. If it is hard, and completely separated from its capsule, it cannot reascend; but if it be of a soft or mixed consistence, attempts ought to be made to bring it out of the eye by slight but repeated pressure, or by the assistance of the curette, in order to avoid the delay attendant on its dissolution, which sometimes requires from twenty to thirty days, or even longer. When some flocculent or detached portions of the opaque body remain in the anterior or posterior chambers, they are naturally dissolved by the aqueous humour. If the capsule is so altered as not to appear susceptible of being torn, it must be extracted by a pair of fine forceps, introduced through the opening in the cornea, which ought to be at least three lines in extent."

Conradi\*, of Nordheim, improved upon this operation of Gleize's, insomuch as he omitted all the ulterior parts of the method, after opening the cornea and the capsule of the lens with a lance-shaped knife, leaving the subsequent removal of the cataract to the efforts of nature. Beer†, about the same time, made trial of a similar method on twenty-nine cases, but not with a satisfactory result. The operation was, however, repeated in different parts of Germany, and received several important additions from Dr. Buckhorn‡, such as the division of the lens as well as the capsule, and the bringing forward of the pieces into the anterior chamber, and who

\* Conradi, in Arnemann's Magazine für die Wundarzneykunst. Göttingen, 1 theil, p. 95. 1791.

† Jaeger, Dissertatio de Keratonyxide, page 18. 1812.

‡ Buckhorn de Keratonyxide, Halæ, 1806; & Die Keratonyxis, eine neue gefahrlosere Methode den grauen Staar zu operiren. Magdeburg, 1811.



bestowed upon it the name of keratonyxis, from *κερας*, a horn; and *ρυξις*, a puncture.

About the same time, in England, Mr. Saunders, with only the observations of Pott, Gleize, and Conradi before him, perfected a similar operation, and applied it in a particular manner to congenital cataract; and it is to be regretted that his efforts for the improvement of this part of surgery should have been overlooked by the Editors of the Quarterly Journal of Foreign Medicine and Surgery, in the sketch given by them of the history of division through the cornea, in their 4th Number for August 1819.

Langenbeck, conceiving that the two-edged or lance-shaped needle but imperfectly fulfilled the objects required from it, invented a curved one with a cutting edge (see Plate IV), for the purpose of more effectually dividing the lens and its capsule, and with which he says he has been particularly successful; finding with it not only a greater facility in dividing the parts, but of bringing the pieces into the anterior chamber\*. The operations for the destruction of the capsule and the dissolution of the lens, by means of an opening through the cornea, are of two kinds, although very similar to each other. The first is that of Conradi, Beer, and Saunders, for destroying a central portion of the capsule equal to the size of the pupil, with or without a very gentle opening of the texture of the lens. The second is that of Buckhorn, Langenbeck, Walther, Reisinger, and others of the German school, in which the whole of the lens is broken up and the capsule destroyed; the pieces being brought into the anterior chamber of the aqueous humour, instead of being left in situ posterior to the iris.

In both these methods the belladonna should be applied the day before and on the morning of the operation, that the pupil may be completely dilated, and a few drops of a solu-

\* Langenbeck, C. J. Prüfung der Keratonyxis, &c. Göttingen, 1811.



tion, in the proportion of five grains of the extract to a drachm of water, should be dropped into the eye, half an hour before its commencement, in order to prevent a contraction of the pupil during the operation, which otherwise sometimes takes place. For the first operation, or that of merely opening the capsule, a very small fine spear-pointed needle, such as is recommended by Professor Walther, of Landshut, and which resembles that of Beer in every thing, save in being smaller, is to be passed into the cornea, about the eighth of an inch from the temporal side, or at the same distance from its inferior edge, the eye having been previously fixed in the usual manner. When the point of the needle has arrived at the centre of the dilated pupil, it is not to be plunged in the lens, but is to penetrate the capsule with a very gentle motion of the point of the instrument, and which motion is to be repeated, working in a lateral direction with the point and shoulder of the needle, until a portion of it is destroyed, in a circumference which does not exceed the natural size of the pupil. Having acted upon the centre of the capsule, the needle may be gently sunk into the substance of the lens, and its texture moderately opened. The needle is then to be withdrawn. If the needle is properly made, the neck, or part beyond the point, fills up the opening in the cornea, in a manner sufficient to prevent the aqueous humour flowing out, yet not so closely as to hinder its being turned on its axis. If it should be badly made, and the aqueous humour escapes in consequence, or from undue pressure in fixing the eye with the finger or speculum, the progress of the operation will be impeded, and, what is of more consequence, as likely to give rise to inflammation, the lens is removed from its situation by the sudden loss of it, rises from its seat, tears the capsule to a greater extent than is intended, presses against the iris, which is rendered thereby convex, and carried forwards against the cornea. If the lens is very soft, no great inconvenience may ensue; but if it be more solid, or caseous, inflammation of the iris and sloughing of the cornea is not an



uncommon result, constituting, in my opinion, the greatest objection to this operation; for, as one operation will seldom be successful, a second and a third will be required upon a lens, which, in consequence of the opening of its capsule, has become more solid, and at last, as the capsule yields, any irregular motion of the head may give rise to a partial displacement of the lens, although the aqueous humour has not been evacuated. It is to avoid this, if possible, that the direction is given to work gently upon the surface of the capsule, so as to cut or scrape it away, but not to raise it with the instrument; an error, to avoid which great care should be taken, as leading inevitably to partial displacement and consequent inflammation. In addition to this danger and inconvenience, resulting from the repeated operations required, a capsular cataract, or the presence of a portion of the capsule in the pupil, is not an unfrequent occurrence, demanding another operation for its removal, even if the lens should have entirely disappeared. From the consideration of all these circumstances, I am not disposed to recommend this operation as one to be preferred for the removal of a cataract, although I have found it useful as a preliminary step where the cataract has been very soft and large, pressing against the iris and rendering it convex. A slight opening in the centre of the capsule gives rise to a diminution of the size of the lens, and at the same time causes it to become more solid; bringing it then in the course of a month or six weeks to that state in which division by the posterior operation ought to be accomplished with facility. If in any case of cataract the lens should, on the introduction of the needle for this operation, be found to be hard, it should be immediately withdrawn, and the part allowed to recover itself. If the lens should have been in the slightest degree displaced, it must be immediately either depressed or extracted. The occurrence of inflammation must be treated in the usual manner, and the pupil should be kept in a dilated state, if possible, until every symptom of it has subsided.



The method of operating by division through the cornea is to be accomplished as follows. The previous steps of the operation having been attended to in the same manner, the curved cutting-edged knife, held like a writing pen, is to be introduced at the inferior part of the cornea, at such a distance from the edge of it as will allow the instrument to pass into the dilated pupil without injuring the iris, yet so far from the centre of the cornea, that the small cicatrix which ensues may be below the lower edge of the pupil in its natural state. The concave part of the instrument being upwards, the convex part downwards, the knife being introduced (see the observations on reclinatio*n*, page 291), supported on the nail of the fore finger, is to be steadily carried on to the upper part of the lens, into which it is to be sunk, and by repeated cuts the anterior capsule is to be divided, and with it the substance of the lens itself: this being accomplished, the broken portions of the lens are to be brought forward with the flat side of the knife into the anterior chamber. Care must be taken not to injure the iris in these different movements; and when the knife is withdrawn the belladonna should be applied, so as to keep up the dilatation of the pupil until all symptoms of inflammation have subsided; when, if at the end of four or five weeks' rest the pupil does not begin to clear, the operation may be repeated; more especially if any portions of the capsule are observable, as, the longer they are allowed to remain, the firmer and more difficult of removal they become.

#### ON THE OPERATIONS FOR CAPSULAR CATARACT.

An operation for capsular cataract alone, necessarily implies the previous removal of the lens, either by absorption or by operation. When the lens is gradually removed by absorption, as it frequently is in the infant, or in consequence of a direct injury by which the capsule is partially torn, it shrinks, recedes from the pupil, assumes a dead white appearance, and is called *cataracta arida siliquosa*; for the diagnos-



tic appearances of which see page 252. The removal of the capsule when in this state from the axis of vision is difficult of accomplishment, and is seldom effected by one operation. The attempt to cut it in pieces always fails, in consequence of the toughness of the capsule, and the non-resistance of the vitreous humour, which allows it to be carried almost to the bottom of the eye, from whence it springs back uncut the instant the knife or needle is removed; if a cut be made into it, or it be partially torn, the resistance becomes less; and if completely separated, it never remains depressed. Scarpa recommends that it should be torn, or separated by his needle, and the pieces or the whole capsule then pushed into the anterior chamber through the pupil; but this is difficult of accomplishment, and when done, the capsule is not always removed by the absorbents, but shrinks, or rolls up, and remains, not only obstructing vision, but deforming the appearance of the patient by the peculiarity it gives rise to in the eye. In four persons, who had each been operated on five times by different operators, I have successfully removed this capsule by an incision in the cornea. I have now a patient under similar circumstances, who has been operated on six times by one gentleman; and in the first case of this kind which came under my own care it required five operations before I could get the capsule sufficiently into the anterior chamber, from whence I was afterwards obliged to extract it by a sixth. In consequence of these and other circumstances, I now recommend that the capsule be first separated as much as can be conveniently done from its attachments by one operation posterior to the iris with the needle, and then extracted at a subsequent period, through a small opening in the cornea; for a repetition of the use of the needle will be attended by the same difficulty, and at last recourse must be had to evulsion and removal through the cornea. The eye being fixed, Scarpa's needle, or one (which I prefer) less bent, being slightly curved towards the point, and cutting on both edges, is to be introduced and brought in front of the



capsule in the usual manner. It is then to be carried to the opposite side, the pupil having been previously dilated by the belladonna as much as possible, and the capsule is to be separated from its attachments: by working with the edges and points of the needle it will give way in parts, under gentle pressure; but other points of attachment of great firmness will remain, appearing to resist almost any degree of pressure that can be applied by either the cutting edge or point of the needle. As much, however, as can be done consistent with the safety of the eye under such circumstances, is to be attempted for the purpose of loosening or separating the capsule; and if this should be happily effected, it may be pushed into, if it cannot be thrust through, the pupil. The inflammation which may ensue having subsided, the second operation is to be performed in a few days in the following manner: the patient must be placed on his back, and the external part of the cornea opened for near one-fourth of its extent, but where the transparent cornea is large, one-fifth will be sufficient; for, if room be not given for the easy introduction of the instruments, the irritation in passing them in will be the cause of a greater subsequent opacity of the cornea than the mere size of the incision can possibly be, whilst the chance of a protrusion of the vitreous humour will be rather diminished than increased; for if the opening be sufficiently free, the flap rises, and there is no pressure on the ball of the eye; but if the opening be confined, it is the sclerotica that yields, and the vitreous humour is compressed. Two instruments ought now to be at hand, a small but sharp hook, and a pair of spring forceps serrated within the points. I generally first employ the hook by passing it into the pupil and under the capsule, which being pierced upwards is to be drawn steadily but not forcibly out of the eye; sometimes it will yield, and the operation is almost immediately completed; at others it may be drawn just without the cornea, and its attachment divided with the scissors; or it may be so tough that the hook will not take sufficient hold, and slip, or bring away only a



piece. I then try the forceps, which are to be introduced shut until they reach the capsule, when the blades are to be opened, and made to close on as much as possible of the membrane intended to be removed; the spring will now keep the blades together, and prevent the capsule slipping from the points of the forceps, which are serrated within. If the forceps be now drawn out, it is evident the capsule must come with them; but in doing this, the surgeon will sometimes perceive that he turns the hyaloid membrane on its axis, or that he pulls it so much towards him, that the vitreous humour is compressed against the side of the sclerotica and bursts from its cells, a portion being evacuated; for the hyaloid membrane in many cases of this kind becomes exceedingly dense and strong, much beyond what might be conceived from an examination of its healthy structure. The capsule should not then be forcibly torn out, but the forceps turned on its axis, by which means the capsule is wound round the blades of it, the evulsive force is more equally divided on the surface of the hyaloid membrane and is more easily regulated. If this operation fail, the scissors must be introduced, and the attachment divided as close as circumstances will admit. Proceeding in this way, and with due caution, greater liberties may be taken with the eye than could be supposed, and with perfect safety; for the inflammation, if any follow, is very manageable by simple means.

The reason for recommending the first operation by the needle, instead of proceeding at once to the removal of the capsule, is, that it renders this latter operation more safe, and therefore endangers the eye less, whilst it also enables it to be done with greater facility. If the centre of a coriaceous capsule of this kind should happen to be torn, the shreds of it float on the vitreous humour, which is frequently in a state of partial dissolution, and cannot be removed by the needle by any operation posterior to the iris. The attempt at drawing them through the cornea is not always successful, from the necessity which exists for a repetition of the operation on each sepa-



rate piece, during which the vitreous humour escapes in considerable quantity, and the resistance within the eye becomes less; so that, if the attachment be very strong, great mischief may ensue. The loss of a portion of the vitreous humour at one introduction of the hook or forceps is of little consequence, if the capsule be extracted at the same time.

When the opacity of the capsule is the result of a previous operation for the removal of the lens, it obtains the name of *secondary capsular* or *membranous cataract*, and may be of its *anterior* or *posterior* parts, or both combined. When it takes place as a consequence of extraction, the capsule usually adheres to the whole of the edge of the pupil, and is for the most part so thin as to be readily torn by the point of the needle, for which purpose I have found Scarpa's the best. It is to be introduced in the usual manner until it can be seen behind the capsule, when the point of it is to be turned forwards, and the capsule freely lacerated; any shreds which remain attached to the edge of the pupil, may be again torn, if they appear likely to float into the axis of vision; but when the capsule is thin, they shrink up and offer no impediment to the passage of the rays of light, although the pupil will in general be fixed, from this as well as other adhesions that the iris will in all probability have formed.

The same proceeding may be followed where the capsular opacity has followed the operations for division, and has not become *siliquose* or *coriaceous*, provided the pupil can be largely dilated by the belladonna. If this cannot be accomplished, in consequence of the adhesions formed between the iris and the capsule, the point of the slightly-curved needle must first be carried to these points of adhesion, in order to separate them previously to lacerating the capsule. Such parts of it as may not be separated from the iris, yet are torn from the centre by the needle, usually shrink up, as in the previous case, and give the patient no inconvenience, more especially if the belladonna be applied immediately after the



operation, so as to stretch and keep the pupil as much dilated as possible.

When the capsule is not *siliquose* or *coriaceous*, yet apparently too much thickened to be easily lacerated, it often yields to the pressure at its ciliary attachment, rather than be cut or torn by the needle at its centre. When this is, or is likely to be the case, the operator should detach it in every part, save that near which the needle entered, and endeavour to depress it, which may sometimes be effected. If it succeed, the capsule shrinks up and remains as a small rounded body behind the iris, and out of the axis of vision, adhering near that spot at which the needle entered, and where it was not separated from the surrounding parts. If this attempt should fail, and the capsule floats again into the axis of vision, it ought to be removed, as in the first instance, through an opening in the cornea.

An opacity in the posterior capsule, the consequence of an operation, will be most easily removed by Scarpa's needle; when it takes place, the lens being in situ, the proper operation is that by displacement, by which an opportunity is afforded for the free laceration of the capsule, an operation which cannot be accomplished so readily nor so safely by that of extraction.

#### ON THE COMPOUND OPERATION OF DISPLACEMENT AND EXTRACTION.

The different methods of proceeding that have been adopted on this principle seem to owe their origin to the operations recorded by St. Yves\* and Gleize†. The late Mr. Gibson‡, of Manchester, recommended that the needle should be introduced behind the iris and the capsule, and the texture of the lens freely opened; and that, as soon as the eye had recovered from the operation, an opening should be made in

\* St. Yves, page 302. 1722.

† Gleize, page 118. 1812.

‡ On Artificial Pupil and the Extraction of soft Cataracts. 1811.



the cornea, for the extraction of the soft cataract, with a curette; Mr. Gibson did not recommend it for hard ones, as he thought the usual operation of extraction preferable. In May, 1812, Sir William Adams published his first work on the Diseases of the Eye, in which he recommended that every lenticular cataract, of whatever consistence, should be cut up, by particular methods adapted to each kind, and the pieces placed in the anterior chamber for solution and absorption; and on this operation of Mr. Gibson's he makes the following remarks: " \* The exposure of the opaque crystalline to the action of the aqueous humour, by freely lacerating the capsule and loosening the texture, or entirely cutting to pieces the lens, is now generally acknowledged to be the only operation applicable to the condition of infancy: but in adults, many practitioners of eminence still contend for the superior advantages of extraction, or depression; while others, like Mr. Gibson, partly taking advantage of the solvent power of the aqueous humour, have recourse to a method compounded of both. Were we ignorant of the powerful hold which habit has even on the most enlightened minds, it would create surprise that any one should be found to contend for operations exceedingly difficult to be performed, and in which parts essential to vision may be irreparably injured, or the eye itself entirely destroyed by the most expert operator, in preference to one easy of execution, almost uniformly successful, which appears pointed out by nature, and where she herself so materially aids the cure. When this operation becomes better known, I however flatter myself, that every remaining objection must give way to its superior merit." A little after he says, " There are two kinds of case, however, in which the operation of Mr. Gibson will prove useful, provided the patient possesses a sufficient degree of self-command to keep the eye steady without the aid of a speculum. The first is where a portion of the capsule is wholly detached from the ciliary

\* Adams on the Diseases of the Eye. 1812.



processes, and floats about in the vitreous humour in the axis of vision. The second, where the lens has fallen into the anterior chamber, unbroken; in which case, as will be hereafter stated, the nucleus will produce constant irritation in the eye." In 1814, Mr. Travers published a paper on cataract in the fifth volume of the *Medico-Chirurgical Transactions*. He says, page 404, "Circumstances unfavourable to the operation of extraction are occasionally combined with forms of cataract, to which it is otherwise well adapted. One of the most formidable of these, as it appeared to me when I commenced the practice, was the convexity of the iris, and consequent narrowness of the anterior chamber, where the lens was bulky and of firm consistence. It is evident, that this figure of the iris will either materially limit the section of the cornea, or expose the iris to be wounded in the section. Frequently meeting with this difficulty, induced me to vary the mode of operating thus: I first employed the belladonna to dilate the pupil, and then introducing a small spear-shaped needle behind the iris, I slit the capsule down the front of the lens perpendicularly, and repressed with my needle the superior margin of the lens, by which pressure its inferior margin was raised, and easily tilted over the edge of the dilated pupil into the anterior chamber; here I left it resting against the cornea, and withdrew my needle. The eye was then closed and a napkin thrown over it. After a minute or two, the upper lid was gently raised, and I made my section boldly upon the lens, in conformity to the surgical practice of cutting upon an extraneous body, previously secured. By the interposition of the lens the iris was effectually protected, and the cataract readily escaped as soon as the section was completed. This operation, which it will be seen differs from that of extraction as hitherto done, chiefly in having its stages reversed, I performed several times without difficulty, and with good success; the patients had no more than ordinary inflammation, and recovered excellent vision. But in the progress of my experience, I found the pupil vary



in its extent of dilatation under the influence of belladonna; and where the external lamellæ of the opaque lens were soft, as in the mixed cataract, I found them separate under the pressure of the needle, which increased the difficulty of throwing the nucleus, as it sunk away from the pupil, into the anterior chamber. To remove the fragments of the cataract, it appeared superfluous to make the entire section of the cornea; I therefore carried the knife only half across the chamber, and withdrew it. The fragments floating in the aqueous humour, were at once evacuated with it; and upon introducing the scoop, and gently depressing the outer margin of the pupil with the back of it, the remaining portion was readily conducted along the groove, as the contents of an abscess follow the director. The success of this operation, obtained more than once, under circumstances nearly similar; the clearness of the pupil, and the perfect state of the iris; furnished a suggestion not to be overlooked, and led to what I am disposed to regard a material improvement in the operation for soft cataracts. I began my operation, having previously dilated the pupil, by the quarter section of the cornea, dipping the point of the knife into the pupil, and freely lacerating the capsule before withdrawing it. The fluid cataract was instantly evacuated with the aqueous humour. The flocculent cataract frequently passed out entire, taking an oblong shape; and the soft caseous cataract piecemeal, through the hollow of the scoop, on gently depressing the margin of the pupil and sclerotica.

“If the pieces were not all evacuated, the introduction of the capsule needle was found sufficient to clear the pupil, or they disappear in a few days by absorption. The operation may be performed experimentally on the dead eye, and will be found to admit of the easy escape of the lens piecemeal.

“One advantage of this operation over that which invites the solution of the cataract is too obvious to require pointing out. Such an operation effects the object, which, on an average, requires two or even three of the latter. Its greater



simplicity and superior safety to that of extraction, as commonly performed, appeared to me so decided, that I anxiously endeavoured to substitute it in cases of hard cataract. The first stage of the operation, in this case, consisted in dividing the lens by the needle, introduced through the sclerotic tunic: the second after a pause of two or three minutes, of the section of the cornea, to the extent required for the extraction of the fragments by the scoop, which was introduced with its back to the iris, and very gently pressed upon the outer margin of the pupil. I soon found, however, that the firm lens could not be reduced to fragments, without a greater exertion of force, and the continuance of it for a longer time than was consistent with the safety of the organ; and being inelastic, that it would not in any degree alter and accommodate its figure, and therefore required a section somewhat exceeding in extent its greatest diameter. And though the use of a larger and more powerful instrument might enable the operator to cut it in pieces; not to speak of the extent of injury which the use of such an instrument inflicts; the complete escape of the aqueous humour, which follows its removal, and the consequent collapse of the cornea and iris, render the section of the former impracticable. Even if this were not the case, if the firm cataract were divided and subdivided, I greatly doubt if the pieces of a lens, of this consistence, would be extracted with facility through a simple incision of the cornea; and with the operation by which it is removed entire, this would certainly not admit of a comparison.

“The operation which I have described is similar to that performed and recommended in cases of soft cataract, by the late ingenious Mr. Gibson, Manchester; whose death, like that of all young men, ardent and able to improve their opportunities of information, must be regarded as a serious public calamity. Mr. Gibson’s proposal was to extract the soft cataract through a large puncture or small incision of the cornea, having broken it in pieces by a former operation with the needle. But I do not find this previous measure neces-



sary. This texture of cataract yields at once to the point of the knife or the curette. I have detailed the progress of observation, by which I arrived at the operation, and had not recollected, until reminded by a friend, that a similar plan had been adopted by Mr. Gibson. I am very happy to do him the justice of acknowledging his priority, and am every way gratified to discover, that although our observations were independent of each other, they conducted us to similar conclusions."

In 1817, Sir William Adams published his work, entitled, "New Operations for the Cataract," in which he abandons the operation for hard cataract, noticed page 367, and introduces others, the principal of which he describes in the following manner, at pages 138 and 283.

"The eye is first prepared for the operation by the application of belladonna, a very weak solution of which I employ over night. I prefer doing this, in consequence of finding it advantageous, while making the opening of the cornea, that the pupil should resume its natural size, as soon as the opaque lens has been placed into the anterior chamber, which could not be the case were the solution of belladonna to be made strong, and applied but a short time before the operation. The first part of the operation should be conducted precisely as if the cataract were of the soft kind, by introducing the two-edged needle through the sclerotica, a line behind the iris, with its flat surface parallel to that membrane. Its point is then to be directed through the posterior chamber, on a line with the transverse diameter of the opaque lens, when its edge should be turned backwards, and a complete division of the capsule and lens be attempted, in the manner which will be hereafter more particularly described. If, upon trial, the lens be found too hard to admit of an immediate division, the point of the needle should be withdrawn a little, and then carried something below the line of the transverse diameter of the cataract, when, upon making pressure with its flat surface against the latter body, it becomes dislocated, and the upper



part tilts forwards, through the pupil, into the anterior chamber; after which, without any difficulty, it may be entirely carried through the pupil and with its posterior part turned forwards. When this is effected, the operator, with the point of the needle (taking care, however, not to wound the iris), should lacerate, or cut in pieces, the remaining part of the capsule, throughout the whole extent of the circumference of the dilated pupil\*, by which means secondary cataract is certainly avoided, unless an adventitious membrane be formed, in consequence of inflammation. Having accomplished this important part of the operation, the needle is to be withdrawn, when the operator should proceed to extract the opaque body.

“The patient should now be laid down on a table on his back, with the head somewhat raised, which is a far preferable position to his sitting in a chair, whereas the latter position is the best for executing the primary part of the operation, namely, the bringing the opaque lens into the anterior chamber. The operator then makes an opening in the temporal margin of the cornea with a lancet, or double-edged extracting knife†. This opening is enlarged, both upwards and downwards, with a small curved knife, in shape and size similar to the probe-pointed knife, described by Barón Wenzel, with the button removed, until it is made sufficiently large to admit of the free passage of the lens; through which a small hook is introduced, with its flat surface between the anterior part of the iris and the posterior part of the lens, which should be carried to the centre of the pupil; the curved point is then turned forwards, and the cataract laid firm hold

\* “In the majority of instances, I believe, the capsula propria is brought into the anterior chamber with the cataract, in which case, of course, the process of the vitreous tunic, which lines the fossula of the vitreous body, is the membrane which is destroyed with the needle.”

† “This method of opening the cornea is very similar to that formerly described by Daviel.”



of, when it is extracted without any difficulty. By this means the cataract is extracted, without any pressure being made upon the ball, and through an opening much smaller than what is required in the usual operation of extraction. Should the cataract separate while in the act of extraction, which is sometimes the case if it be brittle, the fragments may be extracted separately, either with the hook or a small scoop. I am not, however, very solicitous to remove every fragment of a cataract, for, if some of them are so small as to elude the hook or scoop, I allow them to remain, as they are sure to sink to the bottom of the anterior chamber, where they usually dissolve before the opening in the cornea has healed sufficiently to admit of the eye being used; and as the opening\* is made vertically, at the outer margin of the cornea, they do not interfere with its healing, as would be the case were the section of the cornea made in the usual manner.

“ The first step, it will be recollected, is to introduce the two-edged needle behind the iris, in the manner recommended for soft cataract, and, having ascertained that the lens is too solid to admit of division, the point of the instrument is to be carried above, in order to detach the connection between the ciliary processes and capsule, after which the opaque lens may be readily passed through the dilated pupil into the anterior chamber. If, however, there be observed an escape of the vitreous humour by the side of the needle, it may be concluded that it is either partially or wholly disorganized; in which case the surgeon should at once bring the cataract into the anterior chamber, by pressing upon it below its transverse diameter, when the upper edge will tilt forwards through the pupil, and can be easily brought into the anterior chamber; whereas, if it be at first entirely separated from its ciliary attachment, it becomes spontaneously depressed, and cannot afterwards be extracted without hazarding the total destruction of the eye.

\* “ I have employed the word *opening* of the cornea, instead of *section*, as the former, I think, gives a better idea of the manner in which I effect this step of the operation, than the latter.”



It has been already stated, in the short history given of this operation, that, on my first adopting it, I effected the section of the cornea (after having brought the cataract into the anterior chamber with the needle by carrying the knife across it) in the usual manner. The consequence, however, of so doing, was, from the knife being carried so near to the iris, in order to make the section of a sufficient size, to force back the cataract through the pupil into the vitreous humour, which, being in a disorganized state, in two instances in which I performed this step of the operation, the cataract immediately and spontaneously sunk to the bottom of the eye, and produced gutta serena in one, and in the other suppuration, and a total destruction of the organ. In a third instance, the cataract became hid behind the iris, and the coats of the eye collapsed from the abundant escape of the fluid vitreous humour; but I was fortunately enabled afterwards to extract it with a hook.

“ These accidents induced me to adopt my present mode of opening the cornea, which, it will be recollected, consists in cutting behind the cataract, that is, between the cataract and the iris, whereby, instead of the lens being forced back through the pupil, as in the former method, it is actually prevented from taking such a course, during the accomplishment of this step of the operation, by the point of the knife with which the enlargement of the opening is effected. In doing this with the blunt-pointed curved knife, after the puncture has been made with a lancet, or two-edged knife, there is no fear of wounding the iris, if proper caution is used; and the size of the cataract being seen, and its exact consistence ascertained, the surgeon will have no difficulty in making the enlargement of the requisite size, and can afterwards extract the cataract with facility by means of a hook. If, in doing this, the cataract should break in pieces, these pieces must be separately extracted with the scoop, or such other instrument as is well adapted to that purpose. It is not, however, necessary to be very particular in extracting all



these portions, as, the section of the cornea being made vertically, the lower part of that tunic is left whole, and some of these fragments may remain without doing injury, until they become dissolved and absorbed.

“ In extracting the cataract with a hook, care must be taken not to entangle it in any manner with the iris, as it would in that case detach that membrane from the ciliary ligament, and, very probably, cause thereby a total failure of the operation. It is also necessary for the surgeon not to attempt the extraction of the cataract while there is any protrusion of the iris, as it would carry the protrusion still further before it, and in this manner, very probably, detach the inner part of the iris from the ciliary ligament. The protrusion should be returned by gentle frictions of the lid with the finger, or by the forked instrument already mentioned.

“ In this method of performing extraction, no degree of pressure is at all necessary, and should therefore be avoided, both by the surgeon and his assistant; and if at any time previously to the introduction of the hook for the extraction of the cataract, a protrusion of the iris or vitreous humour occur, from any involuntary spasm of the muscles of the eye, the lids should be instantly closed, and the operation concluded as soon as the spasm has subsided.”

The difference between the operations of Mr. Travers and Sir William Adams is this, that Mr. Travers recommends the lower edge of the lens to be brought first through the pupil, and consequently the convex side of the lens to be opposed to the concavity of the cornea, *i. e.* retaining their natural aspects to each other; and that the incision for its subsequent removal should be in the lower half of the cornea, according to St. Yves, &c. Sir W. Adams advises the upper part of the lens to be tilted forwards into the anterior chamber, and the posterior part of the lens to be placed in contact with the cornea, *i. e.* with their natural aspects reversed; the incision for its subsequent removal to be made in the external



or temporal part, as Daviel, Wenzel, Gibson, &c. had previously recommended.

Mr. Travers acknowledges, as above quoted, that his operation is similar to that performed and recommended by Mr. Gibson for soft cataracts, and admits his priority. Sir William Adams, page 126 et seq., overlooks Mr. Gibson and this acknowledgement of Mr. Travers altogether, and claims priority in the invention of the operation. The discussion is too long for insertion here, but I may be permitted to refer to it as a remarkable instance of the mutability of, and little reliance there is to be placed on, what are termed medical facts and opinions. On the 25th of July, 1812, Sir William Adams published his first work, containing his unqualified disapprobation of Mr. Gibson's compound operation of extraction and depression, except in two cases, in which he admits it may prove useful, under certain provisions\*. Yet he says, in his work published in 1817, it was in the month of June 1812, he first practised an operation of the same nature, liable to every objection he had made against that of Mr. Gibson, and which he had expressly condemned.

In performing this operation for *hard* cataract, the following deviations from the method recommended by these gentlemen should be adopted.

First, That the needle should be entered half a line below the central transverse diameter of the eye, and the lower edge should be turned towards the lens instead of the upper, as directed page 350 for soft cataract, by which the long ciliary artery is avoided, and the lens more readily tilted forwards into the anterior chamber.

2dly, After the lens has been pushed into the anterior chamber, the needle should be moved upwards and downwards behind the iris, in order to destroy such portions of the capsule as may not be lacerated by the passage of the

\* Vide page 367.



lens through it, no proof of the capsule passing with the lens into the anterior chamber having been hitherto exhibited.

3dly, When the preceding steps of the operation have been accomplished, time should be given for the pupil to become contracted, which will require in general at least *five* minutes. If the section of the cornea be attempted before the pupil has returned to its natural state, the return of the lens through the pupil may be expected ; or, if this should be avoided, the removal of the lens will be followed by the evacuation of a part of the vitreous humour.

4thly, When the pupil has become contracted to its natural size, the vertical section or opening of the cornea *may* be made at once, with great advantage, taking care that the point of the knife passes between the lens and the iris rather than between the lens and the cornea. For, when the opening in the cornea is made by several introductions of the knife, the iris is apt to protrude and to be injured, giving rise to inflammation, facilitating the expulsion of the vitreous humour, and laying the foundation for injury with the hook in the abstraction of the lens, and for a future protrusion. If the iris should by accident be caught by the point of the hook and injured, the protruded part should be cut off by the scissors.

This operation has been recommended for the purpose of obviating the difficulties which have been met with, and are attributed to extraction—

First, By placing the lens in the anterior chamber, previously to opening the cornea, whereby the sudden expulsion of the cataract and vitreous humour will be avoided, as well as the consequent irregularity of the pupil and protrusion of the iris.

2dly, By making the opening in the cornea no larger than is necessary to extract the lens, additional safety will be acquired, and no danger of wounding the iris will occur.



3dly, No deformity will ensue from the cicatrix in the cornea, and the patient will be less liable to accident during the first days of the treatment.

4thly, Cases may be operated on with safety in which great risk would ensue if done in the usual manner.

To place the lens in the anterior chamber, it is necessary that an additional wound be made in the eyeball, and that, including the extraction, no part or tunic of the eye remains uninjured except the sensible retina. The sclerotica, the choroid, the insensible retina, the ciliary processes, the hyaloid membrane, the posterior capsule of the lens, and the vitreous humour behind it, are wounded in addition to the parts affected in extraction, *viz.* the cornea and anterior capsule; the pressure on the iris, as will be hereafter explained, is nearly the same in both. In the successful operation for cataract, great stress is laid by its advocates on the advantage of none of these parts being injured; and the disadvantages and dangers attending the operation are said to be compensated by the sound state of the eye which the patient subsequently enjoys, and which is dependent on their integrity. I believe that this is really true, although, perhaps, something exaggerated; for few can conceal from themselves, that the greater part of those who have undergone the operation for soft cataract by the posterior operation, have had all these parts injured; and yet, where the inflammation has been manageable, they have enjoyed as good sight and as much soundness of eye as those who have suffered extraction. This injury alone is not then of such importance as we are taught to believe; but when conjoined to pressure on the iris, and an opening in the cornea, it may readily become formidable, the inflammation excessive, and lastly, not accomplish the object for which the double operation was recommended; *viz.* principally that of preventing an effusion of the vitreous humour, and subsequent inflammation and its sequelæ.

The hyaloid membrane being cut at the entrance of the knife, and lacerated in a space equal to the size of at least half the



lens in tilting it into the anterior chamber, the vitreous humour is only prevented from starting forwards by the pressure of the aqueous humour; it is precisely in the same state as when the hyaloid membrane has been wounded in extraction; and it is acknowledged, that if any pressure be applied in this case, whilst the cornea is open, it must be evacuated; it is then only retained by the pressure of the aqueous humour, or when this is evacuated and the patient is in the horizontal position, by its own gravity, and the valve which the cornea makes on the pupil. If pressure be applied on the one hand by any spasm of the eye, and this valve be removed, a propulsion of it must take place, and the dangers resulting from it are as great, if not greater, from a small, than from a larger quantity, not exceeding one-fourth of the whole. If the pupil does not contract after the lens has passed through it, the danger will be considerably increased, and the expulsion of a part will be almost certain if the anterior chamber be not sufficiently large to contain the lens without its pressing backwards and distending the iris, or pressing on the vitreous humour. The shape of the lens renders it particularly likely to do this; for the convexity of it is no longer turned towards the cornea but backwards, the flat side of the lens forwards, so that an anterior chamber which will contain a lens in its natural position in a state of simple application against the iris, but without pressure, cannot do this in its reverse position, without as much of the convexity of the lens passing backwards into the pupil, as there is space between the flat surface of the lens and the inner membrane of the cornea. The pupil, in a case of this kind, cannot contract; and when an additional irritation is brought upon the eye by the introduction of the hook, and all counter-pressure of the aqueous humour and of the valve made by the cornea removed by the passing out of the lens, the vitreous humour follows it. The very act of lacerating the capsule and hyaloid membrane (for it is next to impossible to do one without the other), after the lens has been pushed forwards, greatly facilitates this accident; and I have no he-



situation in saying, that if the pupil does not contract fairly behind the lens, it is nearly inevitable. When describing the different steps of the operation, I have insisted strongly on the contraction of the pupil, as a *sine quâ non*, before proceeding to the extraction of the lens; to allow of this, the anterior chamber must be large, and the compound operation can only then be attempted with safety as far as regards the loss of a part of the vitreous humour, under the same circumstances in which extraction can be done with equal safety. It is advanced, that the expulsion of the vitreous humour does not take place, or is at least prevented by this operation. I grant that the sudden propulsion of the lens and vitreous humour is prevented, but not the subsequent loss of a quantity capable of producing as much inconvenience; but this sudden propulsion of the vitreous humour is an uncommon occurrence in a proper case for extraction, just as much so as in the compound operation; whilst the loss of a small quantity, in a more doubtful case, is more certain in the compound operation, and the chances of inflammation, from the double operation, much greater.

Great stress has been laid on the opening of the cornea being small; on its being made at several attempts, at least three; and on the impossibility of the iris being wounded; on the irregularity of the pupil, and chance of protrusion of the iris, being less. I have already shown, that opening the cornea by several introductions of the instrument, causes, at each attempt, a spasmodic effort, by which the vitreous humour may be discharged, or the iris be injured, and have recommended it to be done at once whenever the anterior chamber is sufficiently large to admit of it. The danger of wounding the iris in extraction is an exaggeration, from considering what happens in improper cases, not what occurs in such as are properly selected for it; and although authors of approved merit notice this as a difficulty, it is to be remembered they extracted in every case, fit or not fit, and overcame, or tried to do so, by dexterity, when they should have succeeded by



judgment. From what has been said it will appear, that irregularity of the pupil will almost invariably follow a loss of the vitreous humour, although it is not a necessary consequence of it; and although a protrusion of the iris may not perhaps be quite so frequent as in the old operation of extraction, an attachment of the iris to the edge of the incision, where there has been a slight loss of the vitreous humour, will be more so.

The deformity which sometimes occurs after the operation, from the cicatrix, is certainly avoided in a greater degree by the compound operation, as well as the liability to subsequent protrusion of the iris, and irregularities of union of the edges of the incision; but it must be recollected, that these seldom occur where the operation has been well performed, the incision of the cornea made upwards, and in a proper case.

It is further said, that this operation may be done with safety in cases in which it could not be done without risk by the usual method. A convex iris and a small anterior chamber have been considered to constitute one kind, and a fluid vitreous humour another. I have shown, that a small anterior chamber is unfavourable to this operation, in as great a degree as to the old method, and a fluid state of the vitreous humour is not less so than it is to the operation by a section of the cornea upwards; it must not be forgotten, it is acknowledged, that, in cases of this description, the small opening made behind the iris, in an operation for artificial pupil, is competent to drain, and frequently does drain the eye: if this be the case, what can be expected to happen when an additional opening is superadded, but, in all probability, a failure in removing the lens, which repasses into the posterior chamber, and subsequent inflammation, with a closed pupil and loss of vision?

The great advantages said to be derived from this method of operating dwindle down to nothing, when carefully examined; whilst the disadvantage of increased inflammation from the double operation is almost always present, and invariably so if



any accident occur during its performance. In any given number of cases, more eyes will be and *have been* lost from the compound than from the simple method of extraction. In two kinds only is this operation decidedly advantageous: 1. Where there is an attachment of the iris to the lens, which renders its detachment necessary; 2. Where, on attempting to cut up a lens, it is found too hard; or in depressing it, it rolls round the needle, or has accidentally fallen into the anterior chamber: and in no other cases should a compound operation, according to any of the methods recommended, be performed.

Dr. Wenzel\* has suggested an operation upon the same principle, and to be performed in the following manner: "The pupil being dilated by belladonna, the needle for division is to be passed through the cornea, and such a division of the anterior hemisphere of the capsule performed as constitutes the second period of the operation of division through the cornea. Favoured by the dilatation of the pupil, the division of the capsule will be executed in this manner to its complete extent, and without any risk of injuring the iris; whence the dangers of secondary cataract, and of iritis, will be greatly lessened. On the following day, the pupil having contracted to its natural size, the incision of the cornea is to be performed in the usual manner. Then moderating the light to which the eye is exposed, the same gentle degree of pressure is to be made upon the lower part of the eyeball, which is exercised during the third period of the operation, as usually performed. Under this pressure the cataract will advance through the pupil and make its exit through the cornea. In this method of operating, the lifting of the flap of the cornea, and consequent admission of the atmospheric air into the aqueous chambers, which take place in the second period of the ordinary

\* Wenzel, Ueber den Zustand der Augenheilkunde in Frankreich; nebst kritischen Bemerkungen über denselben in Deutschland. Nürnberg, 1815. Also the 4th number of the Foreign Journal of Medicine and Surgery, page 411.



operation, are avoided." The performance of the whole on one day does not render the suggestion deserving of imitation, and this, like most of the other compound operations, can only be regarded as an exertion of the imagination, the mention of which may prevent others from following in the same course.

#### ON CONGENITAL CATARACT.

By the term congenital cataract is understood those affections of the lens and its capsule which are coeval with, and are generally supposed to precede, the birth of the infant. Schmidt, Beer, and the ophthalmologists of the German school, are, however, disposed to believe, that, in many instances, cataracts usually considered as congenital are really only the consequence of a rupture of the capsule during the violent convulsions which sometimes occur shortly after birth, and are included among congenital cataracts from a want of due discrimination. This supposition seems to have arisen from the circumstance, that they are often found to be capsular, and of the species called *arida siliquata*, in which the lens has been removed by absorption, a circumstance which it is supposed can only occur in the adult in consequence of a wound or injury committed on the capsule, by which the substance of the lens is exposed to the action of the aqueous humour. From a consideration of this fact, and presuming that the diseases of the lens and its capsule were regulated by the same laws in the infant as in the adult, Schmidt was led to the conclusion, that a rupture of the capsule must take place, in order to admit of the formation of the disease; and as no other cause could be found, he fixed upon those violent convulsions which sometimes occur shortly after birth, and which he considered sufficient to occasion the rupture of the capsule, from the undue pressure made upon the eye by the irregular action of its muscles. In admitting this as a cause, which it possibly may be, it must not be overlooked, that very few children have had cataracts, who have suffered



from violent convulsions, and that very many have had cataracts of this nature who did not suffer shortly after birth from violent convulsions, or even from any kind of perceptible convulsions.

The observations made on the subject of congenital cataract by several authors, and particularly by Gibson and Saunders, show that changes take place in the appearance and characters of the cataracts of infants, which are uncommon with reference to adults, and would lead to the suspicion, that time is capable of effecting changes in them, the possibility or probability of which we are led to deny, with respect to adults. This cannot be illustrated in a more remarkable manner than by contrasting the statements of Gibson and Saunders, as to the results of their experience with relation to the nature of congenital cataracts generally. Gibson\* says, "Although I have met with cataracts in infants hard enough to bear depression, yet *I never met with a simple membranous cataract*, though this is no uncommon occurrence in patients at the age of eight or ten, as well as in adults who have been blind from birth. Within a few weeks I have operated upon three patients, about ten years old, who had simple membranous cataracts in both eyes; and I am strongly of opinion, that at any earlier period these cataracts had been of the milky kind; and that the fluid having been absorbed, the opaque capsule, which originally contained it, now formed the membranous cataract." Mr. Saunders, in a table of the appearances of congenital cataract, in forty-four instances, which is published in his work edited by Dr. Farre, page 159, marks eighteen cases of "opaque and thickened capsule, the lens being completely absorbed, or the remains of it being thin and squamose." And he subsequently declares, that the capsule is the principal difficulty in the way of effecting a cure. This discordance of opinion, and even of facts, may, however, be reconciled. Mr. Gibson lived in Manchester, a small

\* Gibson on the Use of the Couching Needle in Infants, in the Edinburgh Medical and Surgical Journal for 1811, vol. vii, page 399.



town when compared with London, and saw, in all probability, all the children in it who were blind from congenital cataract a short time after their birth, and before the lens could be absorbed, or the capsule could become arid or coriaceous. Mr. Saunders, on the contrary, living in London, had children brought to him, as his reputation as an oculist extended, from all parts and of all ages, inasmuch as they were not at that time operated upon until after they were twelve or fourteen years old, when, as he says, the cataracts had become capsular or membranous. His words, at the commencement of the sixth chapter, are precise: "The efforts of nature in disease are seldom stationary, and even when they fail to accomplish the cure, the correctness of the intention may be clearly discerned: thus, in the congenital cataract, after the crystalline lens is converted into an opaque substance, it is gradually absorbed; and, in proportion to the progress of absorption, the anterior lamella of the capsule retires upon the posterior, until they form one membrane, which is white, opaque, and very elastic. This is the conversion of the lenticular into the capsular cataract: all that is capable of being absorbed, nature herself removes, and she only fails to accomplish her purpose because the capsule cannot be destroyed by this process." The discrepancy between the statements of Messrs. Gibson and Saunders can then be fairly and, I think, satisfactorily accounted for; but the fact of a capsulo-lenticular cataract becoming, in a few years, an arid or siliquose capsular cataract, is not readily explained on the principle Mr. Saunders has laid down, inasmuch as only a part, and not even the majority of congenital cataracts, follow that rule, which he seems to consider as a law of nature. The German ophthalmologists have the analogy of the adult in their favour; and if the cause assigned for the rupture of the capsule appeared to be sufficient to accomplish it, I should be disposed to consider with them, that the disease was not congenital, but an accidental formation shortly after birth. A greater number of observations, and those more correct, can alone elucidate this



ma ter, and establish or disprove that as a fact which is at present an hypothesis. That a great majority of congenital cataracts are, at an early period, fluid, or soft, or mixed, will not be disputed; that very few are found sufficiently firm to depress, is an acknowledged fact; and that, at the end of a few years, most of them are found to be capsular, accords with the observation of our ablest and most attentive surgeons. There are, however, at least two kinds of capsulo-lenticular cataracts, which do not appear to undergo any change with time. One is the central capsular cataract, described by many authors: the other is that species I have alluded to, page 218, in which the lens is evidently smaller than natural, as if it had ceased to increase in size from the commencement of disease; the peculiarities of which are, the smallness of its size, which gives rise to the appearance of a black ring around it, when the pupil is fully dilated, and through which the patient sees more distinctly, its striated appearance indicating an affection of the capsule, which, with its bluish-white colour and rounded shape, would imply also a soft cataract (see plate iii, fig. 9). I have operated on several cases of this kind, and have invariably found a thickened and rather tough capsule, more thick, however, than tough, and a lens more or less soft, but always easily divisible by the knife. They have generally required more than one operation, the capsule being difficult of management from its thickness.

As far as my observations extend, cataracts in infants have always been capsulo-lenticular, or more or less accompanied by an opacity of both lens and capsule, the lens being either fluid or soft, so as to admit of division by the knife, never so hard as to require depression. The appearances dependent on these states in no way differ from those observable in adults, and recourse may therefore be had to their diagnostic symptoms in order to distinguish them.

The proper period for operating has been, and even remains, a disputed point, not as to the propriety of doing it at an early age, or within the first three years, that being fully established;



but as to the best part of that time, some surgeons recommending six months, others from twenty months to three years. It would appear, however, from due consideration, that no definite period ought to be fixed to regulate every case, much being dependent upon circumstances, and especially on the health of the infant. This necessarily implies that it should not be teething, and the child ought to be sufficiently strong to be able to bear some little inconvenience; it is, however, a fortunate circumstance, and which must not be forgotten, that inflammation very rarely follows the operation for cataract in infants, whether the division or rupture of the lens and its capsule be accomplished either anterior or posterior to the iris; or at most to such a degree as to require more than the application of one or two leeches. If the child be healthy at three, four, and certainly six months, and without any sign of being about to cut its teeth, the operation ought to be performed with every hope of success; at a later period, it can seldom be done until after fourteen or sixteen months, with the same advantage; wherefore the reason some surgeons have selected from the eighteenth month to two years of age, from which time to three years it is presumed the child will be stronger, and up to which it is supposed little change will have taken place in the nature of the cataract. The rule to serve as a guide for selecting the period of operating must be the state of health of the infant, and even if the operation be delayed until the end of the third year, little or no inconvenience is found to arise from it, further than that the child acquires the power of retracting the eye within the orbit, which renders the operation less simple, and obtains an irregular rolling motion of the eye, which it does not readily lose; not to include the disadvantages it labours under, in point of recreation and education, and of the greater resistance it can offer when under the operation.

Congenital cataracts appear sometimes in several infants of the same family, occasionally, in a succession of pregnancies;



at others, only among the males, or females, or alternately : but these latter instances of peculiar predisposition are of less frequent occurrence.

To Mr. Saunders the merit is unquestionably due of establishing, if not of introducing, the practice of operating upon children in early infancy. The peculiarity of his situation in the metropolis, in bringing before him a greater number of cases, many of from five to ten years of age, induced him to form an opinion of their being principally capsular, and that the capsule offered the greatest obstacle to success in the operation for their removal. His attention was therefore principally drawn to this point, and his operations, whether anterior or posterior to the iris, were all directed to the destruction of the capsule as their principal object, which induced him to recommend, in capsulo-lenticular cataracts, the anterior operation, or through the cornea, the keratonyxis, performed as directed at page 362. My experience leads me, however, to prefer the posterior operation, or behind the iris, performed as directed page 352. When the cataract is fluid and the capsule opaque, I recommend the same kind of operation, making use of Scarpa's, or the curved, instead of the straight two-edged needle, which offers a greater facility in destroying the capsule ; this being frequently obscured by the escape of its contents, which are often of a milky appearance, the diffusion of which through the anterior chamber renders the motions of the needle less perceptible. The complete dilatation of the pupil yields so large a sphere for its action, that an error can scarcely be made by any one accustomed to its use ; and if, after the opaque fluid has been removed by absorption, the capsule should not appear to have been sufficiently destroyed, the operation for capsular cataract must be had recourse to, as described page 364. It has been said, that the effusion of this fluid into the anterior chamber of the eye from within the capsule, sometimes excites a hazardous inflammation, and it has therefore been recommended to puncture only the anterior lamella of the capsule,



and, after discharging its contents, to desist from all further efforts against the capsule; but as the fluid will have just the same opportunity of doing mischief, provided it has the power, I do not perceive what advantage can be gained, by deferring that to a future opportunity (*viz.* the destruction of the capsule), which is not supposed to have a particular influence in causing the inflammation. I may perhaps be permitted to doubt the correctness of this opinion, and my observations induce me to advise a different mode of proceeding.

In all these operations, on infants as well as on adults, the pupil should be dilated previously to the operation, and kept in that state by the daily application of the belladonna until every symptom of inflammation has subsided.

In performing operations on children, it is necessary they should be completely under control, for which purpose several assistants are necessary. The child is to be laid on its back on a firm table, with a pillow under its head, which is to be securely held by one assistant, in such manner as not to interfere with the position the operator may choose to place himself in. A folded sheet having been placed over the body, legs, and arms, is to be fastened under the table, and a second assistant prevents the body and legs from moving, in which he is materially aided by the sheet. The third assistant depresses the lower lid of the right eye with his fore finger, and receives at the same time the chin of the child between his thumb and fore finger, as in a crutch, by means of which the motion of the head on the chest is prevented, which the child attempts, in order to extricate itself, and which, if not guarded against, may give rise to injury to the iris during the operation: with the other hand he prevents the extrication of the arms from beneath the sheet. The eyelids must be elevated by a speculum, and that which is called Pellier's is the best, being the most easily introduced, and the most serviceable and retentive, when properly employed. When the right eye is to be operated upon, the surgeon sits or stands behind the



patient, and holds the speculum with his left hand, the needle with the right, the light falling on the eye across the nose. Previously to introducing the needle, a gentle pressure is to be made upon the ball of the eye by the speculum, which, whilst it elevates the lid, at the same moment fixes the eye. If the first attempt should not be sufficient, from the irregular action of the muscles, the pressure must be taken off and again applied until the eye can be duly fixed in a central position, when the needle is to be entered, and the operation completed according to the directions which have already been referred to, pages 352—364. When the left eye is to be operated upon, the surgeon should stand or sit before the child, by which he will have the advantage of operating with the right hand. An assistant may elevate the lid, or the operator may do it himself. In infants, both eyes may be operated on at the same time; no preparation will be necessary, further than a dose of castor oil the day before, which ought to be repeated the morning after the operation; one or more leeches may be necessary, but a troublesome degree of inflammation is a rare occurrence in children; and although those of two and three years old will sometimes cry for a few hours afterwards, they generally seem to have lost all remembrance of the operation, as well as all inconvenience arising from it, on the third day, when a shade may in general be advantageously substituted for the bandage.

#### CONCLUDING OBSERVATIONS,

##### ON THE

ADVANTAGES AND DISADVANTAGES ATTENDING THE VARIOUS MODES OF OPERATING, AS APPLICABLE TO THE DIFFERENT SPECIES OF CATARACT.

In considering the advantages or disadvantages resulting from any or all of the different operations for cataract, it is absolutely necessary to recollect, that no individual operation is applicable to every species of the disease; that each kind



requires an operation for its relief or cure, sometimes of a particular nature, and differing essentially from that which is found most advantageous in another. To collect then all the objections which can be urged against any of the operations, from a consideration of every case of cataract to which it is and is not applicable, is merely to confuse the subject; and when this is done, it is for the purpose of recommending some particular mode of proceeding, rather than to regulate these operations by the general principles of surgery.

Cataracts may, for this purpose, be arranged in three classes; the hard, the soft, and the capsular; the hard admitting only of extraction and displacement; the soft, seldom of displacement, or of extraction, but usually of division; the capsular, neither of displacement, extraction, nor division, purely considered as such, but by laceration and removal of the opaque body from the axis of vision by different operations; which, although they may partake of the nature of all, are yet not precisely either. All intermediate states of disease, such, for instance, as the caseous and the fluid cataracts, admit of some slight deviations from these rules, but are still regulated by the same principles.

The operation of extraction, or the removal of the opaque lens and part of the capsule from the eye, is a radical cure of the complaint, as it cannot possibly return. It is performed in a very short space of time, and, when completely successful, causes the least disturbance to the internal parts of the eye, and is the most certain of all the methods recommended for restoring vision in this disease. Possessing these advantages, it is not surprising that it should have been generally adopted, that it should have frequently been found to fail, that it should have been disregarded by some, repudiated by others, extolled by a third party, and at last, from greater attention being paid to the causes of failure, as well as to the varieties of the disease, more justly estimated by all. These causes of success, as well as of failure, have been found to depend not only upon the operator, and upon the mode of



operating, but especially upon the good or bad selection of the cases for it. It has been proved, that dexterity in operation and precision in the performance of it, will enable a surgeon to do more in every operation than can be done by another who does not possess these qualities in an equal degree; but it has been no less proved, that certain states of disease are better adapted for one operation than another, and that each variety of cataract is not favourable for the operation of extraction, displacement, or division. The greatest attention has been and is paid to this subject by every man of judgment and honour; and, supposing an equal degree of dexterity in the performance of all, the choice of the operation depends, 1st, upon the nature of the disease; and, 2dly, on the state of the parts implicated by the operation; for the nature of the disease may forbid one operation, which would be selected by a consideration alone of the state of the parts implicated in it; and the nature of the disease may recommend an operation, which the state of parts forbids. From a careful consideration of these points, separately and collectively, it is fully established, that, as far as regards the nature of the disease, extraction is only necessary or proper where the lens has become hard, inasmuch as the removal of the cataract can be more safely accomplished, where it is soft, or fluid, or capsular, by the operation of division or laceration, and the subsequent process of absorption. For the diagnosis of hard cataract, see page 238; and the operation by *extraction*, performed as directed pages 318 and 344, is only proper in addition to these appearances:

1. When the eye is of its natural firmness to the touch.
2. When it is not so sunk back in the orbit as to render the division of the cornea difficult.
3. When it is not the reverse, very protuberant; for, when the eye is full, the under eyelid is found to press against and raise the edge of the incision. This inconvenience is, however, obviated by making the incision upwards.
4. When the eyelids open well and are not contracted,



which contraction may be a natural formation, or the consequence of chronic inflammation, as the same inconvenience arises from the under lid.

5. When the lids are free from œdema, the conjunctiva, meibomian glands, and lachrymal passages, are free from irritation or inflammation; for the increased secretions will cause considerable pressure on the eye and prevent vision.

6. When the cilia are straight and the eyelid is perfectly regular; for, if they are in the slightest degree inverted, they will irritate and produce the worst effects.

7. When the cornea is transparent, and has not been lately subject to inflammation.

If the cornea has suffered much from disease, and especially if it has been in an inflamed state, or changed in colour, or having red vessels running into it, it is not only very liable to slough or run into ulceration, but it does not even cut like a sound cornea; for, instead of the edges of the incision lying flatly opposed to each other, that of the flap will frequently curl up like horn before the fire, and suppuration will be the inevitable consequence.

8. When the anterior chamber is of fair dimensions, and the iris plane, not convex.

I consider inattention to these two points, or at least an undervaluing of them, the principal reason why extraction frequently fails. A hard cataract is most commonly found in old persons, although it does not follow that old persons should have hard cataracts; but old persons generally have a flattened cornea, with great diminution of the anterior chamber, and an iris, which is, to a greater or less extent, a little convex, or deviating from the planicity natural to it in middle age, and in health. In many of these cases the extracting knife cannot be readily entered at the proper distance from the edge of the cornea, carried fairly in front of the iris to the opposite side, and brought out at the same distance from the sclerotica. The knife comes out short of this distance, and the incision has to be enlarged; the iris falls forward, and is frequently injured; in short, the foundation is laid for every kind of mischief. When, then, the operator is not certain of being able to make his incision or punctuation in the manner to be directed, the operation by displacement may become the most eligible.

9. When the iris is dilatable. If the pupil will not dilate



on the application of belladonna, the cataract is adherent, and the operation of extraction should not be attempted; but the belladonna will almost in all cases indicate the points of adhesion.

10. When the pupil is not in too great a state of dilatation, as it would lead, in all probability, to a protrusion or evacuation of the vitreous humour.

11. When the iris is healthy in appearance, and its motions are (however free or sluggish they may be) perfectly *steady*; for, if there be any vibratory or tremulous motion of the iris, there is in all probability either a very dissolved state of the vitreous humour, or a mistake in the diagnosis, the cataract being capsular instead of lenticular.

12. When the eye seems free from other derangement or disorganization, such as varicosity of the vessels, or glaucoma. A suspicion of its being complicated with amaurosis, from defect of nervous energy, does not forbid extraction.

13. When the patient is healthy and not subject to an habitual cough, not labouring under chronic inflammatory disease, especially gout or rheumatism, as it is apt to supervene on the common inflammation, and give rise to suppuration, or disorganization of the eyeball.

14. When the patient has sufficient control over the motions of the eye to be able to keep it steady; and when, above all, it is free from spasmodic or convulsive twitchings; to which may be added, that those symptoms which forbid operation generally, more especially forbid extraction.

From a review of these requisites, it may be supposed that few cases will occur in which extraction can be with propriety attempted, but this supposition would be by no means correct; it may be safely performed in nearly every case of hard cataract; the only point to be attended to is, not to select it when another operation will answer the purpose better. Surgery is the art of assisting nature, and we should endeavour to follow in her footsteps with gentleness, not to lead them by violence.



The dangers and disadvantages of extraction have been greatly magnified by those who oppose the operation with the view of preferring another; and those who have recommended it with equal ardour, as preferable to all others, have been forced to acknowledge many of the dangers cited by their opponents, simply because they thought fit to perform it in cases where it was not really applicable, rather than adopt another which might in any way detract from the reputation of their favourite. Since the operations on the eye have been more carefully studied, surgeons have no longer thought of adapting an eye to an operation, but an operation to the eye; consequently the different operations are more generally performed than formerly, and practitioners value themselves not on being able by superior dexterity to overcome difficulties which are obvious, but, by superior judgment, to adapt the operation to the state of disease, so that these difficulties may be avoided.

Having pointed out under what circumstances only the operation should be attempted, the difficulties attending its performance will be greatly diminished; they may be enumerated under the following heads.

1. Difficulty of making the section.
2. Escape of the aqueous humour and injury of the iris.
3. Sudden expulsion of the lens and vitreous humour.
4. Irregularity of the pupil and protrusion of the iris.
5. Deformity of the cicatrix.
6. Closure of the pupil and secondary cataract.
7. Inflammation and suppuration of the eye, with their sequelæ.

The difficulties said to be experienced in making the section of the cornea, are attributable, in my opinion, to the patient's eye being so unsteady that it cannot be fixed in the manner I have recommended, to the eye being sunk, the cornea flat, or the iris convex, so that the anterior chamber is considerably diminished in size; all or any of which circumstances ought to forbid the operation of extraction by the *usual*



methods: but if the operator be not inconvenienced by any of these circumstances, there can be little or no difficulty in making the punctuation of the cornea; the aqueous humour will not escape before the proper period, the incision will rarely be interrupted by the iris, but be complete in every way, and the subsequent stages of the operation will not be impeded by the errors of the preceding part of it. I consider a proper section of the cornea to be as much dependent on the part as on the operator; an improper evacuation of the aqueous humour, on both. If the eye is in a fit state for the operation, the knife correctly made, and entered at the distance of about or near a line from the sclerotica, the undue evacuation of the aqueous humour ought not to take place, provided the operator and the patient are both steady, and the falling forward of the iris will consequently be avoided. If the aqueous humour should escape before the punctuation is completed, or the knife has been completely passed across the anterior chamber, it will often be better to withdraw it than to proceed; for, although rubbing the cornea will cause the iris to fall back from before the edge of the knife, it will seldom remove it sufficiently from before the point to prevent its being cut; the operator being sensible of this, and not liking to be foiled, brings the knife out much farther from the sclerotica than he would do, and lays the foundation for every other kind of mischief; or he pushes on the knife in despair, wounds the iris, and probably destroys the eye\*. If the knife be withdrawn, a mere puncture of the cornea has been made, which heals in twenty-four hours, and in twenty-four more the operation may be again attempted, if necessary†. If the punctuation has been completed, and the iris then falls forward, by gently rubbing the cornea to remove it, or if the iris again fall forward, when the friction ceases, by keeping the point of the finger upon it until the section be nearly completed,

\* Richter, page 33. Bischoff on the Extraction of the Cataract.

† Wathen's Dissertation on Cataract, page 101.



injury may in general be effectually prevented\*. As to the point of the knife being carried behind the nasal edge of the pupil, or being made to pierce it near its junction with the sclerotica, it cannot possibly happen in a case fit for the operation, unless the light fall upon the eye in an improper manner, so as to obscure the view of the iris, or the operator himself has bad sight, or is very unsteady. Neither ought the iris to be wounded in a case where a slight enlargement of the opening of the cornea is necessary, as a blunt-pointed instrument is used for the purpose. I consider then, and I think with justice, these difficulties to be attributable not so much to the operation, but to the performance of it in a case to which it is not adapted.

The sudden expulsion of the lens and of a part of the vitreous humour is an accident peculiar to this operation, and is one of the defects which cannot always be obviated, being in some measure dependent on natural causes. To take off the pressure of the cornea from the iris and prevent its acting like a valve on the pupil, it is necessary that one half of the circumference of the cornea should be divided; the contents of the eye are then left without adequate support, and if any exertion be made, may be expelled in proportion to the propelling force. This accident has been frequently observed to occur where the eye is very protuberant, and therefore more exposed to irregular pressure, which renders it necessary to make the section of the cornea upwards in all such cases, by which this inconvenience, as well as the raising of the flap by the lower eyelid, will be avoided. It more often follows a spasmodic affection of the lids, or eyeball, or where the patient has not a perfect control over the motions of the eye; and directions are given, by several authors, how these difficulties are to be encountered. Richter, Wenzel, Ware, Bischoff, Wathen, Demours, are particular in remarking them; but as

\* Ware's Note on Wenzel, page 106.



these difficulties in fact forbid the operation by extraction, it would be a matter of supererogation to quote these observations. A fluid state of the vitreous humour (improperly so termed) occasionally exists with a cataract, and a part of it will in all probability be lost, either on completing the section of the cornea, or on the extraction of the lens ; but this state may generally, indeed almost always, be known or sufficiently ascertained previously to the operation being commenced. It is generally known by the peculiar softness and flaccidity of the eyeball to the touch, sometimes attended by a diminution in its size ; it is in this case the consequence of inflammation, the iris will be more or less discoloured, and a vibratory motion will be observed in it ; or, if in a less degree, the eye may retain its size, but will yet be soft, and the vibration may be more slight, yet obvious on careful inspection. This state equally forbids the operation. Undue pressure is an accident against which proper care alone can preserve the patient ; it seldom, however, is a cause of accident, from the great attention which is bestowed to prevent it, on the part of the surgeon and assistant ; and if the directions I have given be observed, in completing the incision and in promoting the expulsion of the lens, it will seldom happen. Mr. Ware\* attributes the discharge of the vitreous humour, on some occasions, to the operator's having pierced the lens at its lower part, and the posterior capsule also, whilst attempting to destroy the centre of the anterior one ; but if the directions I have given be observed, this will not happen ; and as to making pressure with the handle of an instrument until the lens starts out, I can only say it is a very dangerous mode of attempting it, even in very skilful hands. Upon the whole it must be admitted, that the discharge or loss of a part of the vitreous humour is an accident that will sometimes happen ; but, fortunately, it is not one, when the eye is properly treated, of such importance as has been supposed.

\* Ware's Inquiry, third edition, page 273.



Irregularity of the pupil is not of much consequence, as it does not materially impair vision; a protrusion of the iris is, for the most part, the result of the errors previously alluded to, and both of them principally arise from the discharge of a part of the vitreous humour. The danger resulting from it may then, in almost all cases, be avoided by following the rules laid down in page 320 et seq.

A protrusion of the iris ought never to take place in the first instance, as it may always be restored by gentle friction on the cornea, or by the aid of a probe, as already directed; but it may happen at a later period, from the fourth to the sixteenth day, and is then to be treated in the same manner as from other causes.

The deformity arising from the cicatrix, when the operation is well performed and in a proper case, is so trifling as not to be a detriment to the patient: if improperly done, it may be to the extent of destroying vision.

Closure of the pupil and secondary membranous cataract will be both exceedingly rare where the operation has been done according to the directions given, unless inflammation has been allowed to run too high; when they may probably occur to a greater or less extent; but then the eye will be in a state admitting of relief by the operation adapted to such particular cases.

Inflammation of the eye to an improper or uncontrollable degree seldom occurs where the operation has been properly chosen and as well performed; it may, however, take place, but it can and ought in all cases to be subdued, so as to prevent suppuration and loss of vision. That these occur in some instances must be acknowledged, but it is in those cases, I believe, where accidents have happened, and in which extraction should not have been performed.

Amaurosis is sometimes found to follow the operation of extraction, and it cannot be denied, that such an occurrence may happen or follow after it and every other operation; but, in my opinion, much less often than after any operation of



depression. It has been attributed to the loss of the vitreous humour, and the sudden collapse of the eye injuring the retina; but this must be an error, if the eye recover afterwards its natural size, for we find a loss of the vitreous humour is not generally a cause of amaurosis, unless it is followed by great inflammation. Therefore, when amaurosis does follow extraction, I consider it to have been caused by subsequent inflammation of the internal parts of the eye.

Having then enumerated the disadvantages to which the operation of extraction is liable, and considered them as principally arising from its being badly done, or in improper cases, it is but fair to state, that when a fault is committed, it is less capable of correction, and if an error or an accident of importance occur, it is impossible to repair it. If the operation fail in the first attempt, a second is not admissible; but when successful, it is so in an eminent degree, and leaves the eye in a more perfect state than by any other operation.

The operation by displacement may be performed in every case in which extraction ought to be attempted, and can be done in several in which extraction, according to the preceding observations, would be improper. The disadvantages by displacement follow the operation, those of extraction rather accompany it. It may be done,

1. When the eye does not appear perfectly firm to the touch, and the surgeon is doubtful of its being a fit case for extraction.

2. When the eye is so deep in the orbit as to render the division of the cornea difficult.

3. When the eyelids are contracted or diseased, when the lachrymal passages are affected, which circumstances positively forbid extraction, but need not prevent displacement, after a little attention to the alleviation of such symptoms as are remediable.

4. When the cornea is opaque in parts, and not likely to heal if an incision be made into it.



5. When the anterior chamber is nearly abolished from the flattening of the cornea.

6. When the pupil is not sufficiently dilatable, or is in the opposite state, too much dilated; or when the iris is in a vibratory state, indicating, in most cases, the absorption of the lens or the derangement of the vitreous humour.

7. When there are doubts as to the healthy state of the eye, and the chance of an operation is desired.

8. When the patient is in a doubtful state of health, and subject to gouty or rheumatic inflammation.

And, lastly, when he has not sufficient control over the eye to keep it steady, or it be subject to spasmodic or convulsive motions. It being understood, that those symptoms which forbid operation generally, equally forbid that by displacement.

From this statement it may be concluded, that the operation by displacement is admissible in every case of *hard* cataract, in which an operation is advisable; and it is an inference legitimately deduced by its supporters, as far as it bears upon the operation only; but it is also necessary to take the consequences into consideration, to enable us to decide whether it be the preferable mode of proceeding under all circumstances; for, although simplicity is a great merit in an operation, the result is the principal object which regulates our preference. It is objected to the displacement of the opaque lens by the advocates for extraction, and principally by Wenzel\*, that it causes great pain and vomiting, and often leads to suppuration of the eyeball, from injury of the ciliary vessels and nerves; circumstances which have, however, little or no foundation in fact, when the operation is properly performed, and are not deserving of attention. The other two objections of De Wenzel, viz. the occurrence and continuance of constant and violent pain after the operation, and the ascension of the lens, are entitled to great consideration, as they are really the essential objections to the operation.

\* See Mr. Ware's translation, page 32.



The pain and vomiting have been supposed to be caused by a wound of the ciliary nerves, but I believe very unjustly, and that, in whatever manner they occur, they are entirely dependent upon some derangement which has taken place more immediately within the eye. The whole array of dangers, so frequently displayed as arising from a wound of the conjunctiva and sclerotica, the choroidea and retina, the ciliary vessels and nerves, by the introduction of a needle in a proper manner, is purely imaginary, inasmuch as the consequences said to be derived from them do not take place in practice, although they appear in books. For instance, it is said the wound of the sclerotica by the needle may frequently be compared, from the severity of its effects, to the pricking of an aponeurosis, an accident which commonly produces extensive suppuration. The fact is, that the pricking of an aponeurosis seldom produces any inconvenience, and rarely suppuration, much more an extensive one, as is well known, or ought to be, to every surgeon; and a simple wound of the sclerotica, from a well-made needle, will not be followed by it once in a hundred times. A wound of the ciliary processes, or of the long ciliary vessels, is also said to be attended by instant and occasionally profuse bleeding into the chambers of the aqueous humour, so as to obscure completely the field of the intended operation, which must therefore either be left unfinished or hurried over in the dark. Upon this statement I have merely to remark, with all due deference, that it will be found, when examined practically, not only to be destitute of foundation, but to be actually the reverse of fact; and I do affirm, and am ready to prove, that the ciliary processes do not bleed when cut in an eye that is sound, with the exception of the lens being opaque; that no bad consequence arises from their being cut, and that an operation is rarely performed posterior to the iris without one or more of them being divided. I admit, that in some few cases of diseased iris and adjacent parts, blood may be effused into the chambers of the aqueous



humour; but this state may in general be easily distinguished; and it never takes place from the division of one, two, or three of the ciliary processes, when these and the adjacent parts are in a state of health.

A wound of the annulus gangliformis, or of a ciliary or iridal nerve, is also said to give rise to paralysis of the iris, withering of the eyeball, and other most lamentable consequences; a wound of the sensible retina, to violent and continued vomiting, ending in amaurosis: the space of *one line* in the sclerotica is marked out as a distance which must not be exceeded, and the boundaries of it are said to be beset with monsters more direful than the Scylla and Charybdis of the ancient poets; monsters which will, however, be found to have only an equally poetical existence: for a wound of the annulus gangliformis rarely gives rise to any inconvenience, a ciliary or iridal nerve may be cut with impunity, and the sensible retina may be punctured without any injury resulting from it. I by no means wish to be understood as authorizing any negligence, or the intentional injury of these parts, but merely as denying that the consequences are in general such as they are said to be, and as stating, that if an operator should have accidentally injured any of these parts, he may still hope no permanent inconvenience or detriment will ensue. I have known violent and long-continued pain affect the eye, and by sympathy the side of the head, after an operation upon portions of an opaque capsule, where the lens had been previously removed; and have lately had a case of this kind under my care, in which the inflammation of the eye itself was apparently slight. It was, however, sufficiently marked to show that it was a low internal inflammation. In this case the mischief could scarcely be attributed to the lens, but to the injury committed on the parts to which the capsule was attached, considerable comparative violence having been necessary to destroy those portions which impeded distinct vision. A low but slight iritis ensued, the pupil became fixed,



but not contracted; a vibratory motion can now be observed in the iris, the vitreous humour appears to be altered from its natural state, but vision is good. The mischief here arose not from the wound of a single ciliary process, or of a ciliary nerve, but from low inflammation affecting all the parts, the consequence of violence offered to them generally, and constituting a very different kind of disease to that which these authors allude to, as dependent alone upon nervous irritation. The same symptoms would in all probability have taken place if the needle had been introduced through the cornea, instead of through the sclerotica; and this I consider myself authorized to assert, from having seen them.

These objections, which I consider then to be perfectly invalid, so far as relates to the mere wounding of these parts, and as not even occurring when the operation is properly performed, are not intended to apply to that kind of displacement which is called reclinacion through the cornea, in which they are not presumed to be injured; but the only real objections to displacement, *viz.* the injury done to the internal parts by the depression, and kept up by the presence of the lens, as well as that arising from its ascension, are equally applicable to all.

The injury committed by the lens, according to the old method of depression, occurred in consequence of its lower edge forcing up the retina and injuring the choroidea in the conveyance of the whole below the level of the pupil; whence the rule not to raise the handle of the instrument above the horizontal line, in order to prevent the opaque lens being carried too far downwards, so as to injure the retina and choroidea. In following this direction, the cataract was seldom entirely removed from the axis of vision, or it ascended so as to become visible, whilst at the same time it irritated the iris and the ciliary processes, giving rise to inflammation, which so frequently terminated in closed pupil, or in the disorganization of the eye, as to render the operation most unsafe, and ultimately to lead to its abandonment.



The operation of Scarpa and the method by reclination (see page 295 et seq.) have for their basis this principle ; that the lower edge of the lens must not be forced down so as to injure either the retina or the choroidea, but that the lens must be placed on its flat side, the lower edge being turned forwards, or towards the iris, although deeply lodged at the same time in the vitreous humour, where it gives rise to no inconvenience, and whereby the injury alluded to as committed on the retina and choroidea by the old mode of depression is avoided. It is not only then unfair, but unprincipled, to advance objections against one operation, because they may be fairly urged against another. I do not mean to say, that when a rash or ignorant man puts a needle into an eye, he cannot do mischief; but only to observe, that any evil such a person may commit is foreign to this inquiry.

The return or partial rising of the lens, is a circumstance much to be dreaded, and upon which the principal objection to the operation is founded. If it did not take place, the re-clination of the lens, either from behind or before the iris, would be as perfect an operation as can well be devised, but unfortunately this is not the case; it does not remain in the place in which it is deposited by the needle, but rises up, not to its natural situation, but so as to be in general visible behind the pupil. It is only, however, when it comes forwards and presses against the iris that it causes irritation; for if it be seen situated deep in the vitreous humour, even in the axis of vision, it is not found to give rise to inflammation. If the pressure of the lens on the iris be combined with some previous injury of the retina or tunica choroidea, the result is usually fatal to the eye, and without such combination, the consequences are generally sufficient to render the operation abortive. The ascension of the lens may take place at any period of time; it commonly does so immediately, or in a day or two after the operation; for, if it occur at a later period, it is in general the consequence of a violent blow or a concussion of the eye, which displaces it from its situation. In-



stances are recorded of this occurring after a lapse of even thirty years; but in these cases the lens must have been depressed, enveloped in its capsule, which defended it from the action of the absorbents, for, if a lens be divested of its capsule, it is removed in a comparatively short space of time\*. Much unnecessary discussion has taken place upon this point, and upon the greater solvent power of the aqueous humour over the vitreous humour; but the fact is, that when mischief is done from the presence of the lens, it is during the first days and weeks of its displacement, when it could not in its hard and entire state be removed by either. Scarpa, one of the greatest advocates for displacement, denies the frequency of this occurrence altogether; and although I am disposed to place the greatest reliance on his assertion, I cannot admit the fact, and must therefore attribute the success of his practice to a greater degree of dexterity or of good fortune than is enjoyed by most others. The cause of the return of the lens from the place in which it has been deposited has been warmly disputed. In many instances there can be little doubt of its taking place in consequence of a portion or part of the capsule retaining its attachment to the zona ciliaris, or zinnii, at the place where the needle is entered, and which is not sufficiently upon the stretch to yield when the lens is displaced. This I consider to be the case in those cataracts which are termed *elastic*, and are acknowledged by all authors

\* Beer seems to have been of a different opinion: he says, that, in his examinations, whenever the lens was hard, whether with or without a capsule, he found it a little lessened, but with no sign of maceration. In one instance he removed a lens which had been depressed thirty years before, by Hilmer, and had risen again in consequence of a blow on the temple, and passed readily, when the pupil was dilated, from one chamber to the other; when extracted it appeared cartilaginous and almost bony. In another case, he removed a lens after it had been displaced for fourteen years, with little diminution. He therefore declares he will not believe in the fact of the dissolution of a hard lens until he sees it. Beer, Lestfaden, s. 97.



to consist principally of a tough and thickened capsule, which when not containing an opaque and hard lens, constitutes a species of disease foreign to the present question, and therefore forming no part of the inquiry as to the manner in which ascension of a hard lens takes place. Gibson\* conceived, that, in these cases, the whole vitreous humour moved with the cataract under the depressing power of the needle, forming part of a revolution of a spherical body, which again returned to its natural situation when the pressure was removed. But this is merely an unsupported hypothesis, which a little consideration of the relative situation of the internal parts of the eye must immediately show to be inconsistent with future vision, or the safety of the organ. The opinion, founded in like manner on the great strength and elasticity of the cells and membrane of the vitreous humour being sufficient to prevent their being ruptured, and the lens being depressed, and that their resiliency carried it back to its place, is equally an hypothesis unfounded on any known fact, and may be disproved by the most common anatomical investigation; for in no instance has the lens been shown fairly depressed, without the tunica hyaloidea, and the cells of the vitreous humour, being torn or materially injured, and the humour itself displaced. It does not appear to me necessary, however, to attribute any uncommon power to the vitreous humour, or more than can be fairly deduced from its external characters and consistency. The opaque and hard lens, a substance of greater specific gravity than the vitreous humour, is forced into it, and ought therefore, it is supposed, to remain stationary in the situation in which it may happen to be placed. It is forgotten, that the resistance of every part of the vitreous humour is entire to the introduction of a foreign body, except that part which has been injured in its passage; and that when a general pressure is applied, by any motion of the eye-

\* Gibson on Artificial Pupil, page 120.



ball to the whole, the lens, although heavier and firmer than the humour generally, will naturally take that direction (because it cannot yield equally to the force applied) in which the resistance is least. It ascends then nearly in the reverse way to its descent, but not frequently in so precise a manner as to occupy its former situation, although it interferes with vision; gravity and the previous displacement of the vitreous humour preventing such an occurrence, as well as the injury committed on the surrounding parts, by which it was retained in its natural position; a circumstance to which the possibility of performing the operation a second time is due; for if the lens happens to return more nearly to its proper place, it falls forwards against and gives rise to inflammation of the iris and to all the disasters to which the operation by displacement is liable. Another objection urged against any operation by displacement is, that when a hard and solid cataract, whether its capsule be lacerated or not, is depressed into a disorganized vitreous humour (which may be suspected from the softness of the eye and the vibratory motion of the iris), it will remain so long undissolved, unless the nucleus be divided, until, by its weight and pressure on the retina, it causes gutta serena; or, by its rolling about, from the motion of the head, and the continual friction on the retina or iris, it occasions such severe pains and inflammation, as to defeat the purpose of the operation, by producing a closure of the pupil, or a suppuration and sinking of the eye.

In regard to what is termed a disorganized or fluid state of the vitreous humour, there appears to me also to be some misconception; for, as far as I can collect from the writings of authors, it is supposed that the difference or derangement depends on the vitreous humour having lost a part or the whole of its consistency, and become a watery fluid, losing the capability of resistance it previously possessed, arising from its density and visciditv; and that an opaque lens displaced into it, sinks on account of its greater specific gravity,



whilst it would have required force to depress it, if the humour had retained its due consistency: in the same manner as an egg will float on water sufficiently impregnated with salt, whilst it sinks in brine of a less degree of saturation. From the experiments of Ribes, we have reason to believe that it is not so much the quantity of albumen contained in the fluid that gives the consistency to the vitreous humour, but the septa of the tunica aranea, or hyaloidea, which form its internal cellular structure. Two-thirds of the fluid itself will drain away in an aqueous form, when the eye is properly suspended for the purpose, and the remainder is not particularly inspissated; the change then does not appear to me to depend so much on any alteration which has taken place in the fluid part of the humour, except in colour, which is slightly yellower; but in the cellular structure, which has been removed by the action of the absorbent vessels, or dissolved by the vitreous humour itself, in consequence of some change in its nature, the result of inflammation. Without accounting for the fact, there is sufficient reason for believing it, from the great discharge of fluid, which takes place on making an opening into the sclerotica, and from the free motion of an opaque lens when displaced into the vitreous humour in such a state of disorganization.

The free unchecked movements of the opaque lens, in every direction, its submission to the laws of gravity and motion, prove that it is not confined by any cellular structure, and demonstrate most satisfactorily, in my opinion, that no such structure can exist. The lens then is unconfined, unimpeded, obedient to every impulse communicated to it, is seldom at rest on any one part, and presses on that but lightly. It is asserted that this pressure is still the cause of amaurosis, and of the pains in the head, &c. which authors have mentioned as following the operation of displacement; but most of these authors have given us dissections, in which it is proved that they depended on injuries directly committed



on the retina during the operation, and do not attribute them to the floating lens. That amaurosis should accompany this state of eye cannot be surprising; that it should come on after an operation is less so; it is known to occur as well after extraction as depression.

That the opaque lens, moving in every direction on the slightest impulse, is not the cause, in the greater number of cases, of amaurosis, or of the severe pains, &c. which authors have enumerated, is proved very satisfactorily, by a consideration of the simple fact, that in those cases in which the lens seems to have the most motion, and in which the vitreous humour appears to be most disorganized, the patients are in general not amaurotic, neither do they suffer from the pains, &c. alluded to. In many cases which I have seen, this fact was well exemplified, and it is supported by the testimony of several authors. A question arises here which involves another fact, Does this state of vitreous humour necessarily imply a detachment of the lens from its situation? Scarpa\* seems to think that a dissolution of the vitreous humour necessarily implies a complete destruction of its membranes. It appears to me, that the investing membrane of the vitreous humour, or tunica hyaloidea, is the last to be destroyed, and may subsist after its anterior structure has been dissipated, so that the lens may remain in situ for a certain time, or until touched, when it sinks below the pupil, on the slightest pressure, which it would ultimately have done, from the detachment of its capsule, if left entirely to itself. It must also not be overlooked, that the lens, in this state of eye, has been frequently found to be absorbed, and a coriaceous capsule remains, requiring to be extracted. In its natural state, the separation of the lens and capsule is the last thing effected, and an operation may be desired a short time previously to this taking place. It is a state obviously un-

\* Scarpa's Letters, 3d number of the New Series of the Edinburgh Journal, July 1819.



favourable and improper for extraction, on account of the facility afforded for the escape of the vitreous humour. It is pronounced dangerous by displacement or depression, and the compound operation of displacement and extraction has been recommended, but only where division cannot be accomplished; both of these operations I consider as nearly impracticable. The disorganization of the vitreous humour being first assumed as a fact, a change in the structure of the eye is necessarily inferred as a consequence, which change is essentially the removal of all resistance greater than that of water in an uncompressed state (marked by the softness of the eye) from behind the opaque lens; which is (if not nearly absorbed and the cataract essentially membranous) retained in its situation by the slightest possible adhesions around its circumference, and which frequently give way to the weight they sustain, whilst at its back part the tunica aranea is absorbed, or is so delicate as to yield to the most gentle pressure. This slight attachment, then, prevents the lens from falling forwards, and retains the capsule and lens in situ until the progress of disease and disorganization shall have caused them to detach themselves as it were by the weight of the lens, and to fall down to the bottom of the eye. That this is the fact is, I think, evident, from the circumstance, that if the lens be absorbed and the capsule left, it is never precipitated, and cannot be depressed; and that it is so I am positive, from having been several times obliged to perform an operation for its removal. But what happens to the posterior part of the capsule? It loses its thin inner lamen of the tunica hyaloidea, which separated it from the vitreous humour, by the same action which removed or destroyed the membranous septa of it in the vitreous humour; or suppose, to avoid a misunderstanding, that it even remains in its natural state, the consequence must be, that the slightest touch on any part of the lens sends it into the thin vitreous humour and to the bottom of the eye. It may be argued, that the tunica hyaloidea behind the posterior



capsule is thickened and strong; but this is disproved as a fact, from the operation by extraction being found inadmissible, in consequence of the vitreous humour, in its fluid state, running out after the lens; the membrane being found either entirely wanting, or so thin as not to be able to withstand the slightest shock, or resist the pressure of the vitreous humour. If the membrane were thicker and stronger than usual, the operation by extraction must be in direct proportion so much the more safe, as the principal objection to it would be removed.

There being then no additional support gained to the lens from behind, from any thickening of the tunica hyaloidea; but, on the contrary, a great diminution of it; in what manner can the opaque lens be divided, or even tilted into the anterior chamber for extraction? It is an acknowledged fact, that when an attempt is made to divide a lens of moderate consistence, it cannot be done unless it be firmly supported in its situation by its capsular attachments, and by the resistance afforded by the healthy vitreous humour. In the disorganized state, neither the posterior capsule nor vitreous humour offer any resistance, as proved by the lens being precipitated at the first touch of the needle. It is then clearly demonstrated, that, in this case, the lens cannot possibly be cut, neither can it be tilted into the anterior chamber; it must therefore be nearly impracticable to operate, either by division, or by the compound operation of displacement and extraction.

In such a state of eye, what operation can be performed? I know of none but displacement. I approve of the principle of displacement and extraction, but I deny its practicability. The displacement then should be performed with Scarpa's curved needle; if the lens sinks on being touched, it must be left, and the pupil kept in a dilated state, with the hope of its passing through into the anterior chamber, when, like a lens that has started up, it may be extracted, as St. Yves, Janin, &c. have long since directed. If the lens can be caught with



the hook, when the cornea is opened, without injuring or distressing the eye, it may in like manner be extracted; but if this cannot be done, the patient must remain content with the occasional interruption to vision, experienced from the rolling of the lens in front of the pupil. I have had several cases of this kind at the Infirmary, and in no instance was any further inconvenience ever experienced.

The advantages of reclination through the cornea over that through the sclerotica, are supposed to be, that the injury committed on the cornea is of less importance than when the needle penetrates through the sclerotica, that the whole of the internal parts of the eye are avoided by the anterior operation, and that the operator can see every motion of the needle from its commencement. The disadvantages are, that the lens cannot be so well nor so steadily depressed, that the neck of the needle in doing it is apt to press on the iris, however well dilated the pupil may be, and give rise to inflammation, and that from the lens not being so well depressed after it is reclined, it is prone to advance and to press on the iris with its lower edge, thereby, in some instances, causing irritation, low inflammation, and subsequent closure of the pupil.

Having already declared, and being at all times ready to show, that the evils said to arise from penetrating the sclerotica are greatly exaggerated by most authors; the principal advantage which is supposed to result from penetrating the cornea, *viz.* the absence of inflammation, does not compensate for the greater difficulty experienced in sufficiently reclining the lens; and as a subsequent, a more important, and more dangerous inflammation is likely to arise from this cause, I do not consider reclination through the cornea entitled to a preference over reclination through the sclerotica. There can, however, be no comparison between reclination through the cornea and the old operation of depression.

In relation to *hard cataract*; I am disposed to place the operations in the following order, subject to a due consideration of the different states of eye requiring them: 1. Ex-



traction; 2. Reclination through the sclerotica, or posterior to the iris; 3. Reclination through the cornea, or anterior to the iris; abandoning altogether all the operations, either by puncture or by division of the lens, and only admitting of a compound operation, commencing by displacement and ending with extraction, when the lens has accidentally fallen forwards into the anterior chamber, during the performance of the previous steps for its reclination.

The operation by division is only applicable to *soft* cataract, or one which can readily be divided by the knife, introduced through the sclerotica or cornea. If the nucleus of a caseous or soft cataract be large and hard, extraction is much more likely to answer than division, and becomes therefore the preferable operation. The advantages arising from the operation by division, result entirely from the consistency of the opaque lens and capsule admitting of their being cut in pieces by a knife or needle, within the eye; and to apply this operation to a case in which this cannot be accomplished, is deviating not only from the principles of surgery, but of common sense.

The advantages of division in all cases of *soft* cataract are:

1. The facility with which the operation is performed.
2. The capability of doing it in all cases in which extraction or the operations by displacement are recommended.
3. The avoiding those dangers which are admitted to attend extraction, and also displacement, from injury of the retina in the act of depression.
4. The total removal of the lens and its capsule by absorption.

The disadvantages attending it are:

1. That it can or ought to be done only in cases of *soft* cataract.
2. That it frequently requires to be repeated, and therefore occupies a longer space of time than the other operations.
3. That if the diagnosis is bad, it may be begun in a case



in which it cannot succeed, when recourse must be had to depression or extraction.

4. That it is occasionally attended by severe inflammation, giving rise to amaurosis.

5. That vision is not so perfect as after extraction.

The advantages are sufficiently remarkable to require no elucidation; the disadvantages demand some comment.

The inconvenience resulting from the operation being applicable to *soft* cataracts only, is, that when the lens is found harder than is expected from its exterior appearance and diagnostic symptoms, it yields to the knife with great difficulty; sometimes can only be divided into two parts, and at others, instead of yielding to the knife, turns round it, and is so separated from all its attachments as to be incapable of being acted upon by it. The principal object of the operation is to cut or break up the opaque lens into small pieces, so that they may the more readily be dissolved by the aqueous humour, or acted upon by the absorbents; whilst, at the same time, the smallness of their size may prevent pressure and consequent irritation of the adjacent parts. The directions given, page 353 et seq. have this manifestly for their object; and the removal of the pieces from their natural situation into the anterior chamber of the aqueous humour, is not so much to facilitate their absorption as to prevent irritation from the pressure, occasioned by their divided state, on the iris when in the posterior chamber. When, therefore, from the hardness of the lens, it can only be divided into two parts, or is displaced whole, the operation is in the first instance likely to be disadvantageous, and in the second has failed, and another must be resorted to. When the lens can only be divided into two parts, these must, if possible, be brought through the pupil into the anterior chamber; for, if they be left long behind it, they will press on the iris, and before a sufficient diminution in their size can have taken place to render them harmless, they will have caused an irritation on the iris



capable of doing considerable mischief. If both pieces are brought into the anterior chamber, they are also likely to cause irritation on the iris, although not to the same degree; and it will frequently be advisable to remove them by a small opening in the cornea, which ought always to be done shortly after the displacement, when the lens has passed whole, from its resisting the knife, through the pupil into the anterior chamber. If a half or the whole of a hard lens cannot, under these circumstances, be brought through the pupil, they must be carefully depressed or reclined below the axis of vision. If they are sufficiently removed from the iris, they will disappear in due time, without causing further inconvenience.

The first and third of the disadvantages attending this method of operating, may be obviated in a great measure by care and attention during the operation; and although the case may not turn out quite so fortunate as might have been anticipated, yet the eye will seldom be lost, or vision be materially impaired. It is usually under these circumstances that the fourth disadvantage, of severe inflammation, is experienced; but this, to say the least of it, does not occur more often than in the operations by extraction and displacement, and can almost invariably be safely subdued, provided the lens has not been allowed to remain behind, irritating the iris.

The third of the disadvantages alleged against division, *viz.* the necessity which sometimes exists for its repetition, including the time which is occupied in the cure, is only to be balanced by the greater safety of the operation. It generally occurs in consequence of the defective division of the capsule; and if due pains be taken to effect this object, a second operation will not often be necessary, and rarely a third.

In regard to the fifth disadvantage said to attend the operation, *viz.* that vision is not so perfect as after extraction, I can positively affirm that it is not founded in fact, and my observation induces me to conclude, that in two completely successful cases, vision is as good in one as in the other.



The operation by division through the cornea is said by its advocates to possess certain advantages over that performed through the sclerotica; and, principally, that it secures a more complete laceration of the capsule, whilst it is not attended with the same injury to the internal tunics of the eye and the vitreous humour. This, as far as regards the laceration of the capsule, may perhaps be true; but I do not understand how a lens, although soft, yet of a tolerably firm consistence, can be cut in pieces without injury to the vitreous humour; and as I do not consider this injury, or that to the internal tunics of the eye, to be of the consequence attributed to it, whilst a mistake, in regard to the consistence of the lens, would be attended by very unpleasant results, I cannot give that preference to division through the cornea, which it obtains, I believe, at the present time in Germany. In cases even of fluid capsulo-lenticular cataracts, of large size, I prefer, perhaps from prejudice, the posterior operation of Scarpa.

The observations made on the operations for capsular cataracts, page 364, may be referred to, as not requiring further comment.



ON THE  
OPERATIONS FOR THE FORMATION  
OF AN  
ARTIFICIAL PUPIL.

---

THE different methods of restoring vision, in every case in which the defects requiring it exist in the lens or its capsule, are denominated "Operations for Cataract." When the disease is not confined to these parts, but is combined with derangement of the structure and function of the iris, so as to produce a complete obliteration, or partial closure of the natural pupil, sufficient to prevent vision; the modes of affording relief are usually termed in this country "Operations for Artificial Pupil."

There are four successful methods of forming an artificial pupil<sup>a</sup>, and two which are doubtful; all subject to particular modifications.

1. By division of the iris, either through the sclerotica, or through an opening in the cornea, called by foreign authors Coretomia<sup>b</sup> (properly) Corotomia<sup>c</sup>, Coretotomia<sup>d</sup> (less correctly). Iridotomia<sup>e</sup>; being the operation invented by Cheselden<sup>f</sup>, recommended by Morand<sup>g</sup> and Sharpe<sup>h</sup>, and after-

<sup>a</sup> Called by continental authors, especially Wagner and Langenbeck, Coremorphoseos. *Κόρη* (pupilla), et *Μορφωσις* (formatio).

<sup>b</sup> By Himly, from *Κόρη* (pupilla oculi), et *Τομή* (sectio).

<sup>c</sup> By Bëer.

<sup>d</sup> By Schmidt.

<sup>e</sup> By Wagner, *Commentatio de Coremorphosi*. Göttingæ, 1818. From *ἰρις ἱριδος* (iris), et *Τομή* (sectio).

<sup>f</sup> Cheselden, *Philosophical Transactions*, 1728.

<sup>g</sup> Morand, *Eloge de M. Cheselden*, in *Mémoires de l'Académie de Chirurgie*, tome ii, 4to.

<sup>h</sup> Sharpe's Surgery.



wards abandoned. Having been denied by Lassus<sup>a</sup>; supposed by Cloquet<sup>b</sup> to have been merely a division of the membrana pupillaris; and again restored by Sir W. Adams<sup>c</sup>, being effected through the sclerotica. Recommended by Janin<sup>d</sup>, Guérin, Richter<sup>e</sup>, Pellier<sup>f</sup>, Plenck<sup>g</sup>, Bëer<sup>h</sup>, Maunoir<sup>i</sup>, et Jurinne<sup>k</sup>, Faure<sup>l</sup>, Flajani<sup>m</sup>, Montain<sup>n</sup>, Gleize<sup>o</sup>, Ryan<sup>p</sup>, through the cornea.

2. Excision of the iris. When a portion of it is cut out through an opening in the cornea, which may be done by several methods, called by continental authors Corectomia<sup>q</sup> (properly), Coretonectomia (less correctly), and Iridectomy, being the different operations recommended by Wenzel<sup>r</sup>, Ware<sup>s</sup>, Gendron<sup>t</sup>, Demours<sup>u</sup>, Bëer, Sabatier<sup>v</sup>, Arneman,

<sup>a</sup> Lassus, Pathologie Chirurgicale. Paris.

<sup>b</sup> Cloquet, Jules, Mémoire sur la Membrane Pupillaire, &c. Paris, 1818.

<sup>c</sup> Adams, W., on Artificial Pupil, &c. 1812.

<sup>d</sup> Janin, Mémoires sur l'Œil. Lyon, 1722.

<sup>e</sup> Richter, Anfangsgründe der Wundarzneikunst, b. iii.

<sup>f</sup> Pellier de Quingsy, Mémoires sur les Maladies de l'Œil. Montpellier, 1783.

<sup>g</sup> Plenck de Morbis Oculorum, 1777.

<sup>h</sup> Bëer, Ansicht der Staphylomatösen Metamorphosen des Auges, &c. Vienna, 1806, Lehrbuch von den Augenkrankheiten, 1817.

<sup>i</sup> Maunoir, sur l'Organisation de l'Iris. Paris, 1812.

<sup>k</sup> Prof. Jurinne, of Geneva.

<sup>l</sup> Faure, Observations sur une Pupille Artificielle. Paris, 1814.

<sup>m</sup> Flajani, Collezione di Osservazioni, t. iv.

<sup>n</sup> Montain, Journal de Medecine, par Leroux. Paris, 1817.

<sup>o</sup> Gleize, Nouvelles Observations Pratiques sur les Maladies de l'Œil, et leur Traitement. Orleans, 1812; 1st edit. 1786.

<sup>p</sup> Ryan on Artificial Pupil. Dublin Hospital Reports, 1818.

<sup>q</sup> Himly, Corectomia, from *κῆρη* (pupilla), et *ἐκτομή* (exsectio).

<sup>r</sup> Wenzel on Cataract.

<sup>s</sup> See the late Mr. Ware on Cataract.

<sup>t</sup> Gendron, Louis Deshais, Florent, Traité des Maladies des Yeux, 1770.

<sup>u</sup> Demours, Traité des Maladies des Yeux, t. iii. Paris, 1818.

<sup>v</sup> Sabatier, Medecine Opératoire. Paris, tome iii.



Saunders, Forlenza<sup>a</sup>, Benedict<sup>b</sup>, Gibson<sup>c</sup>, Muter<sup>d</sup>, Travers, Sir W. Adams<sup>e</sup>, Quadri, Ryan.

3. The separation of the iris. — When the iris is separated from its attachment to the ciliary ligament in any part of its circumference, with or without strangulation of the separated portion in the external incision, whether by operation through the sclerotica or through an opening in the cornea, called by continental writers, principally in Germany, *Coredialysis*<sup>f</sup> (properly), *Corodialysis*<sup>g</sup>, *Coretodialysis*<sup>h</sup> (less correctly), and *Iridodialysis*<sup>i</sup>, being the different operations recommended by Schmidt<sup>k</sup>, Scarpa<sup>l</sup>, Assalini<sup>m</sup>, Buzzi<sup>n</sup>, Quadri<sup>o</sup>, Himly<sup>p</sup>, Bëer, Buckhorn<sup>q</sup>, Bonzel<sup>r</sup>, Langenbeck<sup>s</sup>, Richerand<sup>t</sup>, Frattini<sup>u</sup>,

<sup>a</sup> Forlenza, of Naples, *Considerations sur la Pupille Artificielle*. Strasbourg, 1805.

<sup>b</sup> Benedict, *De Pupillæ Artificialis Conformatione Libellus*. Leipsic, 1810.

<sup>c</sup> Gibson on Artificial Pupil, 1811.

<sup>d</sup> Muter on Cataract and Artificial Pupil, 1811.

<sup>e</sup> Sir W. Adams on Artificial Pupil, 1819.

<sup>f</sup> By Himly, from *κῶρη* (pupilla); et *διάλυσις* (dissolutio).

<sup>g</sup> By Bëer.

<sup>h</sup> By Schmidt.

<sup>i</sup> By Wagner.

<sup>k</sup> Schmidt, 1802, in Schmidt and Himly's *Ophthalmologischer*, Bib. band 2, stück 1.

<sup>l</sup> Scarpa, 1801, on Diseases of the Eye, 1st edition; 2d edition, 1819, by Briggs.

<sup>m</sup> Assalini, *Ricerche sulle Pupille Artificiali*. Milan, 1811.

<sup>n</sup> Buzzi in Assalini.

<sup>o</sup> Quadri, *Annotazioni pratiche sulle Malattie degli Occhi*. Naples, 1818.

<sup>p</sup> Himly, in Himly and Schmidt's *Ophthalmologischer Bibliothek*, band 3, stück 2.

<sup>q</sup> Buckhorn, *Dissertatio de Keratonyxide*. Halle, 1806.

<sup>r</sup> Bonzel, of Rotterdam, in Hufeland's *Journal der Practischer Heilkunde*, stück 2, 1815.

<sup>s</sup> Langenbeck, *Neue Bibliothek für die Chirurgie, &c.* 1 vol. 3d part and 4th part, sect. 2, p. 676. Goettingæ, 1819.

<sup>t</sup> Richerand, *Nosographie Chirurgicale*. Paris.

<sup>u</sup> Frattini, *sulla Maniera di formare la Pupille Artificiali*. Parma, 1816.



Reisinger<sup>a</sup>, Graëfe<sup>b</sup>, Walther<sup>c</sup>, Wagner, Embden<sup>d</sup>, Dzondi<sup>e</sup>, Zengs<sup>f</sup>, Schlagintweit<sup>g</sup>.

4. Separation and excision combined. The iris being first separated from the ciliary ligament, and a portion of the separated part removed through an opening in the cornea, being the operation recommended by Assalini and Reisinger.

*The hitherto unsuccessful methods are:*

1. Removing a portion of the sclerotica and choroid coats, close to the cornea, where that part is perfectly opaque, so as to allow the rays of light to pass into the eye. Autenrieth<sup>h</sup>.

2. Separation and division of the iris, through the same opening in the sclerotica. Donegana<sup>i</sup>, with excision. Muter.

The idea of forming an artificial pupil owes its origin to Mr. Cheselden, previous to whose time, a closed pupil was considered irremediable. The information we derive from Cheselden himself, is to be found in the Philosophical Transactions for 1728. But he does not seem to have performed the operation on the person whose history he relates, but rather to have added to it an account of a particular operation, which he considered worthy of record, yet not sufficiently important to become the subject of a separate memoir; and from inat-

<sup>a</sup> Reisinger, Darstellung, &c. und einer leichten und sicheren Methode künstliche Pupillen zu bilden. Augsburg, 1816.

<sup>b</sup> Graëfe das Coreoncion, von Ch. Jüngken. Berlin, 1817.

<sup>c</sup> Walther, Merkwürdige Heilung, eines eiterauges nebst Bemerkung über die Operation des Hypopyon.

<sup>d</sup> Embden, De Raphiancistro, &c. &c. Goettingæ, 1818.

<sup>e</sup> Dzondi, Kurtze Geschichte des Klinischen Institutes für die Chirurgie, &c. Halle, 1818.

<sup>f</sup> Zengs, Darstellung blutiger heilkundiger Operationen, 2d part. Wien.

<sup>g</sup> Schlagintweit, Ueber den gegenwärtigen Zustand der kunstlichen pupillenbildung in Teutschland. Munich, 1818.

<sup>h</sup> Autenrieth in Ephemeridibus Tubingæ. Wagner, Foreign Medical Journal, No. IV.

<sup>i</sup> Donegana, Ragionamento sulla Pupille Artificiali. Milan, 1809.



tention to this circumstance, several errors of considerable magnitude have been made. He describes the operation in the following words, with reference to a plate: "C is a sort of needle with an edge on one side, which, being passed through the tunica sclerotis, is then brought forwards through the iris a little farther than E. This done, I turn the edge of the needle, and cut through the iris as I draw it out." In this case the opening was made in a line with the transverse diameter of the iris; but in cases complicated with cataract, he recommended it to be made a little above or below (as Sharpe did after him), with the view of avoiding the lens, which he supposed to be smaller than in a transparent state, and so adherent that it could not be detached from the iris, without exciting too much inflammation; an opinion adopted possibly from generalizing too much, and which a wider range of experience, had he lived, would doubtless have induced him to alter.

Morand says, that Cheselden had not sufficiently detailed his method of operating in his paper in the Philosophical Transactions, and gives the following description of it as he saw Mr. Cheselden perform it in London. "He made an incision in the middle of the iris with a kind of needle, larger and less pointed than that for cataract, and having but one cutting edge: this he plunged into the sclerotica about half a line from the cornea, and made it traverse the posterior chamber of the aqueous humour, until it had reached as far over as two-thirds of the iris, when he turned the edge of the instrument towards that membrane, so as to cut into it, and, in withdrawing the knife, to divide so much of it in a horizontal line as to leave an artificial pupil of an oblong form, more open in the middle than at the two ends, resembling the pupil of a cat placed horizontally, instead of being, as in that animal, vertically."

The remarks of Morand naturally excited the attention of many scientific men, and from the obscurity of Cheselden's account of his own operation, several of them believed that



it was but an operation for cataract done with a different instrument. This appears to have been the opinion of Voltaire<sup>a</sup>, Buffon<sup>b</sup>, Le Cat<sup>c</sup>, Smith<sup>d</sup>, and Haller<sup>e</sup>; but Janin thought that Morand had noticed an operation he had seen done, rather than that he alluded to Mr. Cheselden's paper in the Philosophical Transactions, and therefore performed the operation in the following manner.—“After the usual preparations, the patient being placed opposite the light, as in the operation for cataract, and the lid elevated by an assistant, I plunged the flat and cutting edge needle of Mr. Cheselden, half a line from the edge of the cornea into the sclerotica; when it had passed in as far as two-thirds of the posterior chamber, I carried the point *forwards* (*en avant*) through the iris, and when about the length of a line of the needle was visible in the anterior chamber, I prolonged the incision in withdrawing the instrument. It was not possible to see what sort of a pupil I had made, in consequence of an effusion of blood into the anterior chamber.” No bad symptoms supervened, but the edges of the incision, if one was made, were found re-united when the eye was examined. In a second case operated upon in the same manner, no blood was effused, and Janin saw that he had made an incision of two-thirds of the extent of the iris, although the edges of it were but little separated from each other. As the person saw in a confused manner, he introduced a needle, and separated the edges of the incision to a greater distance, which perfectly succeeded, and the patient's vision was improved. The usual treatment was pursued, and when the eye was opened, the edges of the incision were found united.

Such was the result of Janin's operations, which induced

<sup>a</sup> Voltaire, *Elémens de la Philosophie de Newton*, vol. xiv, 4to. 1771, page 190.

<sup>b</sup> Buffon, *Histoire Naturelle*, 1<sup>re</sup> édition, vol. vi.

<sup>c</sup> Le Cat, *Traité des Sens*.

<sup>d</sup> Smith, *Treatise on Optics*, vol. ii in 4to.

<sup>e</sup> Haller, *Elementa Physiol.* vol. v.



him to reject the method altogether. It appears to me, however, that he did not perform exactly the operation Cheselden recommended; for, as far as I can understand the description given by him or Morand, the knife was passed behind the iris for the distance of two-thirds of its diameter, instead of before it, and the edge then turned forwards instead of backwards.

Sharpe's account of the operation is more precise. "In doing this operation, the patient must be placed as for couching, and the eye kept open and fixed by the speculum oculi, which is absolutely necessary here, for the very reason I would discard it in the other (cataract); since the flaccidity of the membrane from the issue of the aqueous humour, would take away its proper resistance to the knife, and make it, instead of being cut through, tear from the ligamentum ciliare; then introducing the knife, in the same part of the conjunctiva you wound in couching, insinuate it with its blade held horizontally, and the back of it towards you, between the ligamentum ciliare and circumference of the iris, into the anterior chamber of the eye, and after it is advanced to the farther side of it, make your incision quite through the membrane; and if the operation succeeds, it will, upon wounding, fly open, and appear a large orifice, though not so wide as it becomes afterwards.

"The place to be opened in the iris will be according to the nature of the disease: if the membrane itself be only affected with a contraction, the middle part of it, which is the natural situation of the pupil, must be cut; but if there be a cataract, the incision must be made above or below the cataract, though I think it more eligible to do it above."

"The contracted iris, from a paralytic disorder, is so often complicated with an affection of the retina, that the success is very precarious in this case. This operation, by what I have seen, has answered best in adhesions of the crystalline humour, though, to speak truly, but very seldom even there. As I would not mislead any one who shall prac-



tise an operation not yet much known in the world, I do confess, that either the danger of the iris separating from the ligamentum ciliare, or of the wound not enlarging sufficiently, do upon the whole make the event very doubtful. I once performed it with tolerable success, and, a few months after, the very orifice I had made contracted, and brought on blindness again. Since it has been discovered by the extraction of the crystalline, that a large wound may be made through the cornea without any bad consequence, I should imagine this operation would be much improved by introducing the knife perpendicularly through the cornea and iris, and cutting both at the same time, so that the incision of the iris should be exactly in the same part, and of the same dimensions, as by the other method."

From a careful consideration of these different statements, we can, I think, only come to the conclusion, that Cheselden attempted several ways of operating (as he did for the stone), and that the methods described by himself, Morand, and Sharpe, were perhaps those he followed at the different periods in which each wrote, or had an opportunity of seeing him operate; and the operation Sharpe recommends is precisely the same as the one Sir W. Adams has since revived, save that he did not repeat his incision in the iris.

In consequence of the constant failures of these methods, Janin proposed and performed another in the following manner. "I opened two-thirds of the cornea with Baron de Wenzel's knife, and then raised the flap with a curette held in the left hand, whilst I introduced under it a pair of curved scissors, the lower branch of which was pointed; having plunged this into the iris about a line from its inferior edge, and on the side nearest to the great or nasal angle, I directed the point of the scissors upwards about half a line to the inside of the ancient pupil, and made my section by a single stroke; the wound forming an artificial pupil in the shape of a crescent, the convex part turned towards the temple, the concave towards the nose, being in length about two lines and



a half." No accident supervened, and the lady, the subject of the operation, saw extremely well with cataract spectacles for four years afterwards, while she remained under his observation.

Accident demonstrated to Janin the necessity of further varying the mode of operating. In the year 1768, a young peasant was brought to him, seventeen years of age, who had been blind seven years, in consequence of a blow. On examination Janin found, "that the iris was imperforated, the globe natural in shape, the conjunctiva without any inflammation, the eye free from pain, and the patient capable of distinguishing light and darkness, as well as the shadows of bodies which were moved between him and the light, which decided me to attempt an artificial pupil.

"As soon as the section of the cornea was completed, I wished to make the vertical incision, and had introduced the under or sharp-pointed blade of the scissors for the purpose; but on attempting to close them I felt a resistance as if they included between them a stone, and therefore presumed that the lens was ossified. I withdrew the scissors, with the hope of being able to make the incision towards the lesser or outer angle, but on attempting it I experienced the same resistance.

"After a little consideration, I determined to make a circular incision in the iris, which I effected with a pair of curved scissors, removing a portion of the iris which adhered to the anterior part of the capsule, and the lens, which was not only opaque, but ossified in all its extent.

"I could not see at the moment what state the artificial pupil was in, from the quantity of blood which was extravasated, as well behind as before the iris. The patient was bled several times, and little inflammation ensued; on the 40th day, however, he could not bear the light." Janin perceived that the cause of this was the too great size of the pupil, and endeavoured to remedy it, by causing his patient to use, instead of a glass, a card (convex without, concave



within) painted black, and having a small hole cut in the centre, of the size of the natural pupil; by the aid of which, he was enabled to use his eye with effect in a strong light.

Gendron recommended the operation to be commenced as for cataract, and the iris to be divided with the same instrument as was used for cutting the capsule.

Guerin, with the view of preventing the closure of this newly-formed pupil, which frequently took place, recommended a crucial incision to be made, and the edges or points to be removed by the scissors. But Monteggia and Scarpa affirm, that even when this was done, the closure of the pupil was not always prevented.

Wenzel senior recommended that the operation should be begun as for extraction, but "when the point of the instrument has arrived at about the distance of half a line from the centre of the iris, it must be plunged into this membrane to about the depth of half a line; and by a slight motion of the hand backwards, it must be brought out again, about the distance of three quarters of a line from the part in which it entered. Then pursuing the incision as it is before described in common cases of the cataract, the section of the iris will be completed before that of the cornea, and will present a small flap nearly a line in diameter. This section of the iris, like that of the cornea, will be in the form of a semi-circle. A small scissors is then to be introduced under the flap of the cornea, and the divided portion of the iris is to be cut clean off. By this method an artificial pupil will be made, which, in consequence of the sudden and equal contraction of the divided fibres, sometimes proves to be almost round; and, after this operation, we may rest assured that the pupil so formed will never close again.

"It may sometimes happen, in consequence of the contraction of the fibres of the iris, that it will be difficult to perceive and cut off the divided flap of this membrane. With a little attention and dexterity a small portion of it, however, may almost always be engaged between the points of the



scissors; and this portion, whatever it be, should be removed."

Richter and Pellier de Quingsy recommend the operation to be begun as for cataract; but instead of cutting the iris at the same time as the cornea (which was found to be difficult and frequently impracticable, or rendering the success of the operation very doubtful), to make an incision into the centre of it with a sharp knife of such dimensions as might be required, and through it, if necessary, to extract the lens. Richter even directs, that if the cornea should be leucomatous, this part should be cut in order to spare that which is transparent. Plenck advises an operation nearly similar to that of Wenzel.

Assalini states, that in the year 1786 he conceived the idea of performing the operation for artificial pupil, by detaching the iris from the ciliary ligament, which he had readily accomplished in various experiments on dead bodies; to effect this, he contrived a pair of forceps, of which one blade resembled Cheselden's iris knife with a blunt point, the other limb being very fine and exquisitely sharp pointed, which was united to the knife blade by a joint, forming a pair of forceps, kept in close contact by a spring\*. The apices of this instrument were dentated on the inside, so as to close most accurately by the force of the spring; so that having laid hold of the iris with this instrument, he was able to detach it with great facility from the ciliary ligament without lacerating it.

Accordingly, in the year 1787, he performed the operation in the following manner on a young woman, blind from infancy, with two milky and capsular cataracts. "Having placed the patient in a horizontal position, I made with great ease the incision in the cornea in both eyes; I lacerated the capsule of the crystalline lens, on which there issued a little caseous matter, and the capsule remained attached to the iris: I endeavoured to extract it, but without success; and I was obliged to have recourse to my pincers.

"Having pushed the apex of this instrument into the

\* Like Gibson's forceps.



centre of the capsule, I separated the blades, and perforated it with that to which the spring was attached. I then carried on the instrument, still open, to the margin of the iris, and closed it (by liberating the spring), so as to grasp the capsule, which was firm like parchment; but by means of efforts, at first gentle and afterwards more forcible, I detached, instead of the crystalline, a third part of the iris from the ciliary ligament, thus producing an artificial pupil of an oval form and considerable extent." The operation was conducted on the right eye in the same way, excepting that the artificial pupil was made smaller, which the operator had reason to regret, from the imperfect vision enjoyed by the patient in that eye some years afterwards.

Buzzi of Milan performed the operation for the artificial pupil in the year 1788, in the following manner.—On a patient remaining blind after the operation for cataract, "I penetrated," says he, "into the posterior chamber with a lancet-formed needle, pushing it on through the upper part of the iris within the distance of a line of the closed pupil; after having passed the needle in a direction parallel to the anterior surface of the iris, I depressed its point; and at the same time pushing it towards the centre of the vitreous humour, I detached with some force a third part of the circumference of the iris at its superior margin." He adds, that "great celerity is required in doing this, as the discharge of blood from the lacerated vessels of the iris fills the anterior chamber, and may not only prevent the operator from seeing what he is doing, but may even render the operation fruitless."

Forlenza of Naples makes an incision, as for the operation of cataract, of two-thirds of the transparent cornea, raises up the flap, and laying hold of the iris with a delicate forceps with a double hook, draws it out, keeping it equally tense in all parts, and cuts off one-third of it with a pair of fine straight scissors, after which he proceeds to extract the crystalline lens and its capsule. In a case of closed pupil com-



bined with cataract, the iris being convex, and in contact with the surface of the cornea, he makes a puncture of a line in length, with a cataract knife, and then introduces a blunt-pointed needle between the iris and cornea, and by pressing it forward, and turning it in various directions, he separates the iris from the cornea, and then withdraws the needle: at the same opening he introduces a narrower knife, and finishes the incision as in the case of cataract.

On other occasions, having separated the iris from the cornea with the needle, and having fixed the iris in its position with it, he introduces a cataract knife on the opposite side of the cornea, and thus divides it as in cataract, the iris being kept back by the needle. He afterwards cuts a portion of the iris, as has been described, and extracts the lens and capsule even when transparent.

Arneman is said to have recommended the removal of a circular piece of the iris, with a pair of curved scissors, after the manner of Janin's operation above described. To effect this, one-half of the cornea must be opened, principally from the side, and a hook introduced to gather up the portion of the iris intended to be cut out with the scissors, which should in this case be blunt-pointed and straight. This method enables the operator to make a certain and central pupil; and I have seen two excellent pupils which had been made in this way by my friend Mr. Travers, and which do great credit to his dexterity. Professor Jurinne of Geneva seems, from the report of Maunoir, to have also practised an operation of this nature; and Gleize prefers one nearly like Janin's to all others.

Demours gives his method in the following case\*: "Mons. Sauvages, of Ham, in the year 1793, when twenty-two years of age, suffered from repeated and violent attacks of ophthalmia, with abscess in the cornea, which ulcerated through, so as to cause the evacuation of the aqueous humour

\* Demours, in the *Journal de Medecine redigé par Sedillot*, Juin, 1800.



on several occasions, and were followed by complete opacity of the cornea of the right eye and of four-fifths of that of the left. The iris of each was convex, touching the internal surface of the cornea; the anterior chamber, and the aqueous humour usually contained in it, being consequently wanting. The patient remained in this state four years, perfectly blind, when I proposed to make an artificial pupil at the upper and outer part of the eye close to the sclerotica, where the cornea remained transparent. On the 15th of April, 1797, I plunged a cataract knife through the cornea into the iris close to the sclerotica, taking the precaution to make the opening in the iris a little lower than that in the cornea, in order to prevent the inconvenience which might result to vision from the cicatrix. Into the opening I introduced one of the blades of a very fine pair of scissors, which penetrated a little way into the vitreous humour. The other blade was pushed between the iris and the cornea, which at this spot was only touching, but not adhering to it. I then cut off a small flap of the iris nearly of the size of a sorrel seed, at two strokes of the scissors, and vision was immediately restored."

In his *Traité des Maladies des Yeux*, published in 1818, he says, "M. Sauvages continues to see very well with the eye operated on, has not had a relapse of inflammation for twenty years, and is living at Ham."

Professor Scarpa, having observed that the edge of the iris was occasionally separated from the ciliary ligament by blows and other injuries, and that this was accomplished with less violence than would be requisite to tear the iris, leaving an artificial pupil, through which the patient frequently saw very well, conceived the following method of operating. "The patient is to be seated and secured as in the operation for extracting a cataract: then with a straight needle, such as I adopt, the sclerotica is pierced in the external angle of the eye, about two lines from the union of that membrane with the cornea. The point is next advanced as far as the



upper and internal part of the border of the iris, on the side next the nose; in this situation, close to the ciliary ligament, the needle pierces the upper part of the internal margin of the iris, until its point is just visible in the anterior chamber of the aqueous humour. This step of the operation requires attention, because this part of the anterior chamber is very narrow, and if the point of the instrument advances ever so little before the iris, it must penetrate the substance of the cornea. As soon as the needle is visible in the anterior chamber, it must be pressed upon the iris from above, downwards, from the internal towards the external angle of the eye; as if it were intended to carry the instrument parallel to the anterior surface of the iris, in order that a portion of its border may be detached from the ciliary ligament. The point of the needle must then be depressed, in order to press it upon the inferior angle of the rent, which may be enlarged at pleasure, by drawing the iris towards the temple, and directing the instrument from before backwards, in a direction parallel to the anterior surface of that membrane, and the greater axis of the eye.

“ Having produced this separation, if no opaque body appear in the bottom of the eye, the needle may be withdrawn. If, however, any portion of opaque capsule, which had remained after the depression or extraction of a cataract, should appear near the pupil, this opaque portion being broken down with the point of the needle, must be conveyed through the artificial pupil, and deposited in the anterior chamber of the aqueous humour; or, as we have before shown, these membranous flakes may be left to be gradually dissolved and absorbed along with the aqueous humour, which is incessantly replenished.”

In the second edition of his work, published in 1818, page 368, he abandons the operation above described, for the following reasons, and recommends the one invented by Maunoir, to be hereafter noticed.

“ Experience,” he observes, “ to which all theory is sub-



ordinate, has since convinced me, that independently of the mode of operating which I proposed being inapplicable, of which I was aware, to the greater number of complicated cases of closure of the pupil, I was also mistaken with regard to the most material point of the operation, that is, the permanency of its success; as I have since found that the marginal pupil, or opening, which is formed by the detachment of the greater circumference of the iris from the ciliary ligament, from being oval, becomes, in process of time, *filiform*, and consequently useless." The principal and indeed sufficient objection to the operation of Janin.

In 1801, John A. Schmidt, of Vienna, proposed two operations. In the first, he opened the cornea and introduced a hook into the anterior chamber, with which he took hold of the iris, and separated nearly one-third of it from its attachment to the ciliary ligament. In the second, he introduced a needle, curved at the point, through the sclerotica, and carried it behind the iris, in front of the lens, if present, or, if removed, in front of the hyaloid membrane, until it reached that part of the iris intended to be separated. The iris was then to be transfixed about the fourth part of a line from the ciliary ligament, the point of the needle appearing in the anterior chamber; and by now giving it a motion downwards and backwards, the iris was to be separated from its attachment, to the extent which might be considered necessary.

The idea of separating the iris from the ciliary ligament, seems to have originated with Schmidt and Scarpa nearly at the same time, and without any communication with each other. The only difference between them seems to have been in the shape of the needle, Scarpa's being less curved at the point, and narrower.

Sabatier recommended an operation of the same nature as the Baron de Wenzel's.

Professor Maunoir, of Geneva, in his first Memoir on Artificial Pupil, gives the following method: "1805 — I begin by making an incision in the cornea, as much as possible on



the external side (whether there be an opacity at that part or not), about the length of three lines, and at the distance of one line from the sclerotica. This incision should have a curvature parallel to the circumference of the cornea, and in general it will not differ from that which should be made in the operation for cataract, except that it ought to be much less.

"I finish the operation with a pair of scissors, with very thin and narrow blades," when united, Scarpa says, not thicker than a common probe, "the blades being about seven-tenths of an inch long, and bent so as to form at the joint an angle of 140 degrees. The extremity of the superior blade, which is to pass between the iris and cornea, is blunt or round pointed; the inferior blade is very sharp at the point on the inside, and for a line on the back at the point, which is intended to penetrate the iris. This blade should also be a little shorter than the other.

"These scissors are to be introduced flat, until the point reaches the part of the iris where the incision ought to begin: the scissors are then to be turned, the handles raised, and the blades slightly opened, sufficient pressure being applied to force the point of the inferior or sharp blade through the iris, under which the blade is to be carried on transversely as far as the incision is intended to be made. The scissors are then to be sharply closed, and the iris will be divided."

In the first operation, in March 1802, he performed the single incision, which succeeded; but in the second, in July 1802, he found it made only a division of the iris, without effecting a sufficient separation for the purposes of vision. He says, in this case, "I cut about the length of a line of the external circumference of the iris, which left, however, a simple slit, which, on withdrawing the scissors, appeared only as a black line. I reintroduced the instrument and repeated the stroke, but in a different direction, although near to the former one, so as to make a triangular incision between them, at the point of which the two incisions met in the natural



situation of the pupil, the base being at the incision in the cornea. The triangular flap thus made, retracted upon itself towards its base, so as to leave an artificial pupil near the centre, not of a triangular form, but rather assuming that of a parallelogram."

Scarpa, in the last edition of his work, adds to this account of Maunoir's operation by himself, two additional methods on the same principle, but deviating a little according to the circumstances of the case.

1st. "The contraction of the natural pupil is sometimes occasioned by the iris and pupil being stretched towards some point of the cornea. This happens, in general, in consequence of prolapsus of the iris through ulcers of the cornea, or after the incision made in this membrane for the extraction of the crystalline lens. This affection is most frequently accompanied with partial opacity of the cornea around the part occupied by the proidentia of the iris, as well as of the capsule and lens: at other times, however, these internal parts preserve their natural transparency, notwithstanding the deviation of the natural pupil. In the latter case, which is precisely that now under consideration, the pupil, removed from its situation, is not in reality obliterated, but merely very much contracted, and incapable of admitting the quantity of light necessary for vision, especially if the cornea opposite to it is slightly opaque.

"To remedy this morbid state, it is necessary to have the scissors of Maunoir made with the points of both blades terminating in a button. A small incision being made in the cornea at the most commodious part, according to the rules before laid down, and the scissors introduced, closed, an attempt is to be made to free the adhesion which the iris has contracted to the cornea by them; and if this be effected, the natural pupil in general recovers its former situation and size; but, if the adhesion of the iris to the cornea is very firm, the operation is to be completed in the following manner.—One



of the blades, by means of the small button, is introduced within the contracted natural pupil\*, and conducted behind the posterior surface of the iris, until the other blade, defended in the same manner, has reached the confines of the cornea with the sclerotica. The iris is then to be divided in the form of the letter V, without at all injuring either the capsule or lens, both of which have preserved their transparency.

2. "Where the lens is supposed to be opaque and hard, the capsule tough and adherent to the iris, he proceeds as follows: An incision of moderate size should be made in the cornea, either at the lower part, or a little inclined towards the nose or temple, if the partial opacity of the cornea render it necessary, and, if possible, without making use of a speculum oculi of any kind. With the sharp-pointed blade of the scissors, the iris should be perforated at a small distance from its great margin, that is, nearly opposite the external wound, and pressing it further inwards than usual, towards the longitudinal axis and bottom of the eye, at once pass it beyond the opaque capsule and the crystalline lens, if it is found there. Both the blades having reached the side opposite to that which they entered, all the parts should be divided at one stroke, that is, the iris, the opaque capsule, and the crystalline; and without delay, after the first incision, a second should be made diverging from the first, so as to leave a large aperture in the iris in the form of the letter V. Through this large opening in the iris are immediately discovered the broken portions of capsule and opaque crystalline. If the portions of the lens are firm, by a slight pressure on the eyeball they will advance and pass through the new triangular pupil into the anterior chamber of the aqueous humour, from whence they may be extracted in the same manner as is practised in the cataract. For this purpose, where the lens is broken into fragments, a smaller incision in the cornea is requisite than

\* This mode of operating is equally applicable to cases of simple contraction of the pupil, unaccompanied with prolapsus of the iris and opacity of the capsule and lens.



where the extraction of the crystalline lens is to be made in its entire state. If, however, the crystalline is soft or caseous, the removal of the divided portions of it may be facilitated by means of the small scoop, or of the eyed forceps of Maunoir, similar to those used for the polypus, but of extreme fineness. In the same manner, with regard to the capsule, the fragments of it may be detached and extracted by means of a very fine hook, or the forceps just mentioned. The portion of capsule which may have adhered to the small triangular flap in the iris, will form no obstacle to vision; as, in consequence of its adhesion to it, it will retire with this divided portion from the apex to the base of it. Whenever the crystalline, notwithstanding the opacity of the capsule, has preserved its entire transparency, the extraction of the pieces of it will require greater attention than when it is opaque, in consequence of these portions of it being confounded with the substance of the vitreous humour.

“ Notwithstanding the utmost care, it is not uncommon, after the operation now described is completed, and the consecutive symptoms have ceased, to find some fragments of the capsule or crystalline, or of both, concealed in the posterior chamber, appear opposite the new pupil. In this case, it will be proper to introduce a fine curved needle through the sclerotic coat into the eye, and by this means completely detach the particles of capsule, if they are still adherent to the iris; and either alone or with the fragments of the crystalline press them through the new pupil into the anterior chamber of the aqueous humour, where, being liquefied by the solvent power of this humour, they finally disappear by absorption.”

Donegana, in order to render the artificial pupil, formed by a separation from the ciliary ligament, more permanent, proposed to unite to it a slight division of the transverse diameter of the iris, the result of which would be a triangular instead of an oval opening, the base being at the ciliary ligament, the apex towards the centre of the iris. For this purpose he had a curved needle, made of a falciform shape, one, or the under,



edge being very sharp, which he used either through the sclerotica or cornea, as appeared most convenient; and after separating the iris from the ciliary ligament, he effected, with the cutting edge of the instrument, the proposed division of the iris. In a few instances he appears to have had some success, but those who have attempted to cut the iris in any operation, after it has separated from the ciliary ligament, know, that it is hardly possible to effect it; and that an operator will, almost to a certainty, completely separate, rather than divide the iris, by a continuation of the attempts at division, after separation has commenced.

In 1811, the late Mr. Gibson, of Manchester, published his methods of making an artificial pupil; the principal of which he describes in the following words: "The first step of the operation is to secure the eyelids, as in the operation for extracting a cataract. A puncture is then to be made in the cornea, with a broad cornea knife, within a line of the sclerotica, to the extent of about three lines. All pressure is now to be removed from the eyeball, and the cornea knife gently withdrawn. The consequence of this is, that a portion of the aqueous humour escapes, and the iris falls into contact with the opening in the cornea, and closes it like a valve. A slight pressure must be made on the superior and nasal part of the eyeball, with the fore and middle finger of the left hand, till at length, by an occasional and gentle increase of the pressure, or by varying its direction, the iris gradually protrudes, so as to present a bag of the size of a large pin's head. This protruded portion must be cut off with a pair of fine curved scissors, and all pressure at the same time removed; the iris will then recede within the eye, and the portion which has been removed will leave an artificial pupil, more or less circular.

"It sometimes happens that the whole breadth of the iris, to the border of the natural pupil, is protruded and removed in this way. This I consider as rather an advantage, because it ensures a large pupil, though generally one which is oblong



in its shape. I have found, however, the mere circumstance of shape to be of little consequence in this operation, and always to be sacrificed to the object of size. It may also be remarked, that the opening has no disposition to close, when, in forming the artificial pupil, the border of the natural pupil is divided.

“ It occasionally happens also, that as soon as the knife is removed, the muscles of the eyeball act with violence, and project a small staphyloma or bag of the iris through the incision. If this bag be not large enough to form the new pupil, the iris must be further protruded by gentle pressure.”

Sir Wm. Adams, in the year 1812, revived the operation of Mr. Cheselden, which had been entirely abandoned. He was induced to do so from having effected an opening in an opaque capsule, by turning the edge of the cataract needle backwards; from which he was encouraged to hope he might be able to cut the fibres of the iris in the same manner. Fortunately, the first case which presented itself was very favourable for the attempt, and he succeeded in making a division of the iris exactly in its centre; “ the radiated fibres immediately retracted, and formed an opening of a large size, nearly circular, and quite clear.” The eye was amaurotic, and the patient was not therefore benefited. In the next case on which he operated, he perfectly succeeded, and, after some alterations in the shape of the needle, he perfected his operation as I have described it in his own words\*, with the exception of having made the artificial pupil too large; but which error he has corrected in his last work on the same subject. In cases where the opacity was more considerable, he recommended the following operation, page 41; “ but when there is not above a line of the circumference of the cornea remaining clear, I then introduce the knife, though in a similar manner, at the external and upper part of the eye, in order to prevent the escape of the aqueous humour before

\* See my observations in this work on the first class of diseases.



the operation is completed, and make a perpendicular incision through the outer margin of the iris, opposite to and extending the whole length of the remaining clear part of the cornea. This operation much resembles that recommended by Professor Scarpa for artificial pupil, with this difference, that the instrument is introduced through the coats of the eye in a different part, and the fibres of the iris are divided, instead of being detached from its ciliary ligament. But if, as has happened in some of these cases, the iris separates from its ciliary attachment, my operation becomes similar to that of Scarpa. Sometimes there is only a small protrusion of the iris, which adheres afterwards to the cornea, causes the edge of the pupil to be of an irregular form, and prevents its expansion beyond the limits of the cicatrix, by which vision is either partially or wholly obscured. In this case, if the disease is uncombined with any other morbid affection of the pupil, and the cicatrix is not of a large size, the operation should consist in introducing the artificial pupil knife through the cornea, a little anterior to the iris, and carrying its point on to the adherent part, which should then be divided with the cutting edge of the instrument."

In continuation he says: "It often happens that the cicatrix in the cornea is so large as to reach beyond the utmost extent of dilatation of the pupil, even when under the influence of the belladonna. Yet, if the whole surface of the cornea is not obscured, an attempt may then be made either to open a new aperture in the iris opposite to the remaining unobscured part, according to the plan proposed by the late Mr. Gibson of Manchester, or to drag the natural pupil on one side. In cases of this kind, I, however, very much prefer the latter plan, because, in the operation recommended by Mr. Gibson, the incision made in the cornea must be of such extent as probably to produce a considerable opacity in the portion of it which still remained transparent; and this objection, which is candidly acknowledged by Mr. Gibson, page 99 of his valuable *Observations on Artificial Pupil*, I



saw very strongly exemplified in the case of Mr. Rushton, of Liverpool, who had been operated on by that distinguished surgeon. The artificial pupil, which was of a small size, was seated quite at the bottom of the external margin of the iris; others, which the patient informed me had been made above it, having been successively obscured by as dense an opacity as that which originally affected the centre of the cornea; and this opacity encroached even upon that part opposite to the upper portion of the pupil still remaining. In this operation of Mr. Gibson's, it is true, there is little risk of injury to the crystalline lens or its capsule; but the preservation of the lens can be of no advantage, if the inflammation occasioned by the incision made in the cornea be such as to render the whole portion of that coat opposite to the artificial pupil, opaque. Upon the authority of Mr. Gibson's publication, I made trial of his operation in two or three instances; but the unfavourable result induced me wholly to abandon it, and to substitute for it the following operation. To this I was led by Miss Russell's case, by which it appeared to me that the original pupil might be so much dragged to one side (without any risk either to the transparent lens or its capsule) as to be made subservient to vision by a very simple operation, namely, that of making an opening in the cornea of so small a size as neither to risk opacity nor to require the removal of any part of the iris. The unavoidable diminution which (after Mr. Gibson's operation) must occur in the size of the newly-formed pupil, when the natural one is much dilated, can never take place by pursuing this plan first recommended. I first fix the eye with a speculum, and then enter my closed pupil knife through the cornea about a line anterior to the iris, and make the opening somewhat longer than the width of the instrument. Through this the aqueous humour will make its escape, and be followed by a part of the iris. If the iris does not protrude sufficiently from the pressure of the speculum to extend the edge of the natural pupil as far as the puncture in the cornea, I lay hold of it with a



pair of small forceps, and gently pull it out, using great caution not to employ so much force as to rupture it. Having in this manner dragged the outer edge of the pupil a little through the puncture, I do not cut off the protruded part, but suffer it to remain strangulated, which prevents it from again returning within the cavity of the eye. The puncture heals, and it includes the protruded part of the iris, which is shortly removed by a very weak solution of *argentum nitratum* dropped into the eye two or three times a day. Care should be taken to make the incision no larger than just sufficient for the iris to protrude, in order to avoid the opacity which would be likely to ensue were it of a larger size, and also to prevent the iris receding when the cornea is again distended by the regeneration of the aqueous humour."

In his last work on Artificial Pupil, published in 1819, he appears to have abandoned the operation of dragging the natural pupil to one side, and to have adopted that of Gibson, using the forceps instead of the hook, as will be noticed when on the subject of the operation by excision.

Professor Bëer of Vienna says, 1806, 1817, "The methods of operating may be classed under three principal heads—*Corotomia*, *Corectomia*, *Corodialysis*."

"The first has been very properly laid aside for a considerable time, because it is only applicable in a very few cases, and may now be fully dispensed with, in consequence of the adoption of the other two methods. Yet it sometimes happens that the operator, instead of separating the iris from the ciliary ligament, tears it, and thus accidentally performs *corotomia*. Yet no expert oculist, no man well versed in the art of operating, will have the least hesitation in preferring *corodialysis* to *corotomia*, when he is perfectly at liberty to make a choice, provided *corectomia* is not in some measure contra-indicated.

"Agreeably to rule, the artificial pupil should always be formed near the inner angle of the eye, in the neighbourhood of the natural pupil. Yet frequently the operator is



forced to make it towards the inferior, templar, or upper region, when the cornea is not staphylomatous: and the surgeon may, in these cases, think himself very fortunate to find a convenient place anywhere, on which he can operate with the requisite certainty.

“Corectomia is preferable in all cases where the lens is healthy, with the following exceptions. When the transparent part of the cornea is so circumscribed that a competent opening cannot be made in it to enable the operator to seize the iris with the hook or forceps, and to cut out a sufficiently large piece towards the ciliary ligament. Corectomia is also to be resorted to, when we are certain that the lymph coagulated in the posterior chamber after extraction, does not extend beyond the small ring of the iris, and is not connected with any opacity of the remaining capsule of the lens. The former may be ascertained from the natural colour and form of the larger ring of the iris; the existence of the latter may be suspected from the very imperfect perception of light, with respect to its particular modifications.

“The excision of the iris requires an incision at least one line in length, but which must run along the sclerotica, as near as possible to the edge of the cornea, that the operation may not be useless from subsequent opacity. In the second part of the operation, the act of excision may be attended by three different circumstances. When the iris is in no way improperly adherent to the cornea, it will be immediately protruded through the incision, by the gush of aqueous humour from the posterior chamber of the eye; of which the operator must instantly avail himself, by laying hold of the prolapsed part with a small cataract hook, and cutting it off as close as possible with a pair of Daviel's scissors; when the remaining part of the iris will immediately shrink back behind the cornea, and a well-formed pupil will be evident. Or, when the iris is adherent, except at that part where the pupil is to be formed (which may be discovered by viewing the eye laterally), the operator, after having made the inci-



sion, must introduce the small hook sideways, so as not to hook either the iris or the cornea, and then, by an oblique direction of it, endeavour to lay hold of the pupillary edge of the iris, and drawing it out, cut it off, as before directed; by which he not only increases the size of the natural pupil, so that it now extends behind the transparent part of the cornea, but greatly augments the power of vision, because the rays of light will fall more upon the centre and less upon the edge of the crystalline lens. Thirdly, and finally: the iris may be connected by its pupillary edge to the cornea, even at the place where the pupil is to be formed. In this case it must be laid hold of by the hook near its larger ring, or, if that tears out, a pair of fine-pointed and indented forceps are to be introduced, and the iris thus torn is to be drawn out if possible and the piece cut off; but if it cannot be drawn out, the piece seized by the forceps must be cut off within the edge of the incision; because a perseverance in the attempt to draw the iris more forcibly out, will tear it in all probability, in a manner highly prejudicial to the success of the operation. The healthy lens and capsule can never be injured, provided the patient is steady and the operator sufficiently dexterous. The latter method, *viz.* with the forceps, must at once be resorted to, when we wish to form an artificial pupil, after a previous extraction of the cataract; but this is only practicable when the capsule is not adherent, and when there is but a small quantity of coagulable lymph in the posterior chamber, and not then extending beyond the smaller circle of the iris towards the ciliary ligament.

“The separation of the iris from the ciliary ligament is only indicated, first, when, after an extraction or reclamation of the cataract, the lymph thrown out in the posterior chamber, in consequence of inflammation, extends towards the ciliary ligament, far beyond the smaller ring of the iris, which may be ascertained with tolerable accuracy, from the alienation of the colour of the larger ring of the iris, and a somewhat imperfect perception of light: secondly, when we



have to deal with a secondary capsular or capsulo-lenticular cataract, which is adherent to the iris; or with an opacity of the pupil, resulting from the deposition of matter or blood; and with which there is sometimes a distinct perception of light, and no symptoms decidedly unfavourable to the operation: thirdly and finally, when the cornea is so marked by the cicatrixes of ulcers, or is incurably opaque, and to such an extent, that it cannot properly be opened with the knife, so as to enable us to undertake the operation of excision.

“ In the two first cases, in order to perform corodialysis quickly and successfully, Schmidt's lancet-shaped curved needle (supposing that the pupil is to be made towards the inner angle of the eye) is to be introduced into the anterior chamber, a good half line from the outer edge of the cornea, the convexity of the needle being turned towards the iris. It is then to be carried, without touching either the cornea or iris, to the inner edge of the cornea, when the point of it is to be pushed so deeply into the iris, within the distance of the eighth part of a line from its outer margin, that it may be firmly hooked. A double motion is then to be executed with the handle of the needle; for the handle is to be raised, so as to press the point of the needle into the iris and vitreous humour, whilst the needle is at the same moment to be withdrawn, but not entirely out of the eye. The point of it is now to be loosened from the iris, and the eye examined, to see whether the separated iris does not again return towards the ciliary ligament, which is unfortunately but too generally the case. If the iris shows the least disposition to return, or if the pupil thus made be too small, the iris is to be again laid hold of with the point of the needle, at the upper or lower angle of the new pupil, and the operation of separation is to be repeated; when the artificial pupil will certainly appear, and remain, as large as can be wished. But if the coagulated albumen and lymph in the posterior chamber of the eye really extend to the ciliary ligament, the iris may be stretched and pulled about in an incredible manner, but can



never be separated; and the attempt at making an artificial pupil will not succeed, unless by a fortunate accident the iris and the pseudo-membrane which is behind it should be torn asunder, and give rise in this manner to a pupil of sufficient dimensions. In the third case, Schmidt's needle must be introduced into the eye through the sclerotica, as in the reclamation of the cataract, and carried on, with its concave surface turned to the iris, towards that part of the ciliary ligament where the pupil is to be formed. It is then, as recommended by Schmidt, to be pushed from behind forwards into the iris, about the eighth part of a line from the ciliary ligament, in order to lay hold of, and to separate it sufficiently by one or two attempts, which is exactly the reverse of the method recommended in the former cases. In either instance the lens, whether transparent or adherent, will naturally be displaced at the moment of separation by the double movement of the needle, and consequently be so far out of the limits of the artificial pupil, that it can never be injurious to vision, even on its becoming opaque at a subsequent period, which will and must inevitably be the case.

"It is now no longer to be doubted from recent experiments made upon persons totally blind, that coredialysis, performed with Reisinger's hooked forceps, has in many cases great advantages over this method; but whether it is such as to deserve a place in this work as a prototype of operative proceeding, must be decided by further experience." Since the publication of the book in 1817, from which this extract is made, Professor B  er has written a very interesting paper in the *Austrian Medical Jahrbuch*, giving an account of a number of cases in which he had successfully employed the method of Reisinger.

Reisinger, in 1816, published a method of performing the operation of separating the iris, strangulating it afterwards between the edges of the cornea; to effect which he uses a very fine double hook, which, by a slight pressure of the finger and thumb, is made to resemble a single one; and



Bëer appears to have reported so favourably of it, that I have thought proper to use the author's own words in describing it.

“ The operation must be begun near the outer edge of the cornea, and if possible *three* lines (one quarter of an inch) distant from that part of the iris which is to be separated. For, if the anterior chamber of the eye be opened at a greater distance from the spot where the separation of the iris is to be effected, the iris would be loosened too largely to form a good protrusion, the pupil would be inconvenient from its size, and the injury too considerable. If the iris should adhere strongly, the tension will become too great in consequence of the increased distance of the prolapsed part, and it is therefore apt to be drawn back ; but, on the other hand, if the incision is begun too near the spot where the separation of the iris is to be effected, a subsequent opacity of the cornea may injure the artificial pupil.

“ The incision in the cornea ought to be one and a half, or at most two lines in length, and it is important that it should not exceed that size, or the prolapsed part cannot be sufficiently strangulated. A larger incision, in addition to the *procentia iridis*, may occasion an opacity of the cornea, which it will be very difficult, and often impossible, to remove.

“ After the incision in the cornea is completed, the eye should be allowed to close for a moment, to afford it rest, and prepare it for the subsequent proceedings, unless it has been previously fixed by an instrument.

“ The operator should hold the hooked forceps nearly in the same manner as the cataract knife, the points of the hooks downwards, the thumb resting on the flat side of the shank which is facing the operator, and the first and second finger on the flat side of the opposite shank, so that the point of the second middle finger may reach the end of it. The handle must rest against the *radial* side of the first joint of the first finger, the little finger serving to steady the hand.



“ The instrument is now to be drawn along the edge of the cornea, pressing gently and steadily with the convexity of the united hooks against the small incision, in order that the edges of the wound may be gently opened, and the closed forceps insinuated into the anterior chamber; then glide the instrument with the convexity of the hooks against the inner surface of the cornea, as far as the spot where the iris is to be separated, taking care, however, to bring the hooks as near as possible to the ciliary edge of the iris. The forceps are now to be turned, so that the points of the hooks may be directed towards the iris; then let the instrument be opened, so that the two hooks may be at least one line, and not more than two lines asunder; press the convexity of the hooks against the ciliary ligament, sink the points into the iris and close the forceps, at the same time gently drawing them towards you: by these motions, which must be almost simultaneous, the iris is steadily seized and easily separated. The closed forceps are now to be further drawn out of the eye, the convex edge of the hooks being carefully turned towards the inner surface of the cornea, to avoid pricking it: in this manner a considerable part of the iris will be separated, and a triangular pupil formed, of the size of at least one quarter of the iris, and which will reach the middle of the eye. Should the iris not be properly laid hold of, slip off the hooks, or be torn, the same movements of the instrument must be repeated.

“ The handle of the forceps is now to be depressed, and as the convexity of the hooks glides out at the upper angle of the incision, withdraw the forceps together with that part of the iris which has been laid hold of, so as to produce a pretty considerable procidentia iridis; then open the pincers so as to free them from the protruding part of the iris. Should the hooks whilst withdrawing catch in the cornea, they must be pushed back a little, and the proceeding just now detailed gone through again; or the convexity of the hooks may be brought out at the lower angle of the incision, by turning the



instrument on its axis and lifting the handle. The eye should now be immediately closed to assist the strangulation of the prolapsed iris, by the pressure of the eyelid. After a few minutes the eye is to be opened, to ascertain the state of the prolapsed part; and should it have disappeared, the instrument must be reintroduced to draw out the separated part of the iris, unless the extravasation of blood should cause too much obscurity.

“If the prolapsed portion of the iris should recede, it will generally happen from the incision having been made too large. In this case it may probably be advisable to cut off the part of the iris which has been separated, and which must again be drawn out; and so combine coredialysis with corectomia, to ensure an artificial pupil of a proper size.

“If the regular application of the hooked forceps should not produce a perfect separation, but rather tear the substance of the iris, which can but seldom happen, and only when it is greatly altered in structure; the portion of the membrane which has been drawn out will in all probability be too small to remain fixed and strangulated in the wound of the cornea, and may therefore easily recede. In such a case the pupil will be too little, and in general soon filled up by the subsequent effusion of lymph, for which reason I here prefer the excision of the protruded part of the iris. If the larger ring of the iris should exhibit a particularly morbid and altered appearance, or if the separation have previously been attempted with the needle or single hook, and failed in consequence of tearing the membrane; it will be proper to lay hold of a broader portion of the iris with the forceps, to ensure at least the removal of that part of it, although the separation from the ciliary ligament should have succeeded.

“When the combination of excision with separation of the ciliary ligament is indicated, as in the foregoing cases; and the unsteadiness of the eye renders it necessary to use an

\* This should always be done. G.



instrument to fix it; then an able assistant, who is to elevate the upper eyelid, must be entrusted either with the cutting off of the protruding part of the iris, or rather with the task of steadying the eye, by a hook inserted in the conjunctiva scleroticæ.

“ When there is considerable tension of the fibres of the iris, on account of a previous protrusion, either through an incision in, or from a fistulous opening of the cornea, the formation of a prolapsus may be quite dispensed with; and a separation effected to a considerable extent, by the hooked forceps, will be sufficient to form a pupil of a proper size; for the tense fibres will recede, and cannot again lessen the pupil; we at the same time avoid the probable danger of extending the partial opacity of the cornea and the closure of the pupil, which the prolapsus might produce.

“ When an incurable opacity extends over two-thirds or three-fourths of the cornea, but at the same time leaves an anterior chamber from two to three lines distant from the ciliary edge of the iris, then observe the rule of forming the incision in the cornea two or three lines from that spot where the iris is to be separated; and the incision may be made partially or wholly in the opaque part of the cornea. In this case, if the opacity has but lately taken place, and if a general disposition to such a morbid change is strongly marked in the cornea, a combination of excision with separation appears to be indicated; for the protruded iris would be apt to give rise to a dangerous extension of the opacity.

“ When the cornea is opaque, to within a very small distance of its edge, and is adherent to the iris as far as the transparent part, the coredialysis, agreeably to Schmidt's method, has hitherto been considered the safest operation, and excision very properly rejected, in consequence of its injuring the transparent part of the cornea too much (even if the incision should principally extend into the sclerotica), without being able to remove the lens, which is generally opaque.

“ Yet if we consider that the very small pupil formed by



Schmidt's method, even when successfully accomplished, is very apt to be obstructed on its outer edge by the ciliary processes, which lie behind the iris, and cannot be properly destroyed by the needle; and towards its inner edge by the separated iris itself, which, from its intimate adhesion to the cornea, cannot be properly removed; perhaps the following method of operating may be thought more effectual. If an opaque or transparent lens should still exist behind the iris, I propose, in the first instance, to introduce a keratonyxis needle through the cornea and iris, below the middle of the cornea, so that its convex surface may lie upon the centre of the lens, in order either to depress it or cut it to pieces. Then to make an incision one half or two lines in length with a cataract knife through the cornea and adherent iris; to introduce the hooked forceps through this opening into the posterior chamber, and lay hold of that part of the iris corresponding to the transparent part of the cornea, and draw it out of the posterior chamber of the eye, and either by tearing or cutting it off remove it entirely: at the same time the ciliary processes will be so destroyed that their remains will certainly recede from the artificial pupil; and the injury of the iris can scarcely deserve to be taken into consideration, as it will have already lost its importance in such an eye.

“Should the case require the formation of an artificial pupil on the outer side of the eye, the anterior chamber still existing within two or three lines of the ciliary edge of the iris, which is to be separated, then my operation might be effected by using the hooked forceps over the nose, provided a prominent eye and flat nose favoured the attempt; which would also be made more easy by the assistance of an instrument to steady the eye. But if this is rendered difficult by the eye lying deep, as well as other unfavourable circumstances, particularly when the anterior chamber is too much contracted by the cohesion of the cornea and iris, the lens and capsule being supposed to be in a healthy state; a small incision should be made in the cornea near the edge of the sclerotica, to enable the operator to lay hold of



as much of the iris as possible, in order to draw it out and cut it off; but should the capsule and lens be positively opaque, then it is necessary to proceed in regard to the cataract in the manner above directed, or to have recourse to the coredialysis, agreeably to Schmidt's method, with one of Himly's curved needles. If the natural pupil is in a healthy state, but covered by an incurable opacity of the cornea; or if there is about a quarter of the cornea transparent near the outer angle of the eye, the lens and its capsule being transparent, the cornea should be opened near the edge of the sclerótica by a puncture with the knife one line and a half in length, the outer pupillary edge of the iris drawn out without injuring the lens or capsule, and cut off with a pair of scissors; for a prolapsus would in this case increase the opacity. By this means the new pupil will be as near as possible in the middle of the eye. If the pupillary edge should not be sufficiently visible to enable the operator to lay hold of it with safety, and without injuring the capsule, then the operation may be undertaken, after having moderately dilated the pupil by the hyoscyamus.

“ But as long as there is sufficient space for an artificial pupil on the inner corner of the eye, that spot should invariable be chosen (*cæteris paribus*); for experience has shown, that a pupil on the inner side of the eye is most favourable to vision.

“ When, from a previous operation or otherwise, a softness of the ball of the eye is evident, with a closure of the pupil, but without any other unfavourable symptoms, or such as contra-indicate the formation of a pupil, the hooked forceps will still be applicable; but only in cases where a transparent lens can be left uninjured in its proper situation, or where we are certain of being able to close the small wound in the cornea immediately by the artificial prolapsus of the iris. In every other case, it will be advisable to attempt the coredialysis agreeably to Schmidt's method, in order to avoid a considerable and very injurious loss of the vitreous humour,



which cannot be so great through a puncture of the sclerotica. Yet the more important *lesion* of the sclerotica, choroidea, &c. together with the morbid state of the eye, and its liability to injury, ought previously to be well considered.

“ When the lens and its capsule are in a healthy state, great care must be taken, in using the hooked forceps, that the convexity of the little hooks may not be removed from the interior surface of the cornea, in introducing or withdrawing the instrument; and equal attention must be paid in laying hold of the iris, to avoid a lesion of the lens or its capsule, and the danger of a cataract, which would be the consequence; and should a subsequent opacity of the capsule or lens take place, this cataract must be put aside, either by reclinatio*n* per scleroticam (and the more easily, as, from the size of the artificial pupil, the operation of the needle is visible), or depressed, or destroyed by the keratonyxis; for pressure on the pupillary edge of the new immoveable pupil, or on the iris, which has lost its original value, cannot be attended by any essentially bad consequences.

“ When an opacity of the capsule or lens exists, many difficulties may occur, which must be met by means equally diversified. If we find a cataract where the natural pupil is obscured by an opacity of the cornea, and if no adhesion, of any consequence, of the capsule with the iris is discovered by the external and strong application of the belladonna; a keratonyxis needle should be introduced through the cornea in the usual manner into the middle of the pupil (pressure on the lower pupillary edge is here to be disregarded), and the cataract depressed or destroyed. If the artificial pupil is to be formed on the inner side of the eye, let the small incision in the cornea be now made, which may include the previous opening of the needle; then with the hooked forceps separate the iris from the ciliary ligament, and cut off the protruded part of it with the scissors. But when the artificial pupil must be formed on the outer side of the eye, then the separation and excision effected with the hooked forceps, as de-



cribed page 425, are to be resorted to. Perhaps it might be more advantageous to undertake the keratonyxis and the excision of the iris at two distinct periods, by which the eye would be spared; but if the opacity of the cornea has lately taken place, or if we perceive an evident disposition in it to enlarge after a fresh lesion, then an attempt at coredialysis agreeably to Schmidt's method, either on the inner or outer side of the eye, would be preferable. Should we find the capsule diseased and adhering to the pupillary edge of the iris or uvea, which may be discovered by the application of the belladonna, then reclinacion through the sclerotica, or Schmidt's coredialysis, will afford the best prospect of success; should the attempt fail, the hooked forceps may be tried, as the cataract has at least been dislodged.

"When the lens and capsule, or even the pseudo-membrane of a lymphatic cataract, is so adherent to the pupillary edge of the iris, that the visible surface of the cataract has a diameter of at least one line, there is reason to hope that the natural pupil may be restored. A moderately bent depressing needle should be introduced through the sclerotica, and moved as in reclinacion; when the central piece of the capsule or the pseudo-membrane will in general be separated from the pupil to which it adhered; but should this fail, which will chiefly happen in cases of fluid cataract where the capsule has grown into the pupil, then endeavour to push the point of the needle (the convexity turned backwards) at the outer edge of the pupil, through the capsule into the anterior chamber of the eye; turn the needle on its axis, in order to sink the point at the inner pupillary edge into the posterior chamber of the eye, and thus hook round the cataract or lymphatic concrement by a movement towards reclinacion, by which this substance is frequently separated from the pupil. If this operation succeed, the belladonna should be immediately applied to prevent the bad consequences of an iritis. Should this attempt at restoring the natural pupil fail, carry the point of the needle (which is already in the anterior chamber of the eye) as far as



the ciliary edge of the iris, press it into this membrane, and endeavour to effect its separation by moving the point of the needle backwards and downwards; should the object not be attained even by these means, the hooked forceps must be employed (after the reaction has subsided), for the lens will already have been depressed, and will be ultimately absorbed. In every other kind of cohesion of the pupil with the capsule or with coagulated lymph, the attempt at restoring the natural pupil is contra-indicated.

“When we are fully convinced that a capsular or lenticular cataract exists behind a pupil which is completely closed, and appearances indicate the application of the hooked forceps, make the incision in the cornea in its proper place, introduce a keratonyxis needle through it, and perforate the iris, so that the convex surface of the needle may be directed backwards; then depress the lens, withdraw the needle, and by means of the hooked forceps form the artificial pupil. The lens and its posterior capsular membrane will either be depressed or cut in pieces, and the anterior capsule, which in such cases is generally intimately connected with the uvea, will be removed together with the iris by the forceps. The wounding of the iris is a matter of minor consideration in the formation of artificial pupils, and the injury it sustains from the needle will be but inconsiderable; therefore this operation is preferable to reclination through the sclerotica, which is apt to occasion much more important lesions, the operation of which under these circumstances is very uncertain. But if the existence of a cataract connected with an opacity of the pupil is not ascertained, which it is often difficult to do, nothing should be undertaken against the lens or capsule for fear of injuring them if they should be in a healthy state; and the operation ought to be confined to the formation of a pupil by the hooked forceps: it is even to be hoped that a cataract adhering to the uvea may be drawn aside with the iris by their operation, and that when a lasting connection of the iris with the cornea has been effected by means of a prolapsus, the



cataract adhering to the iris will never be able to resume its former place and injure the new pupil. If, however, after the formation of the pupil, there should be a cataract preventing vision, or should the lens subsequently become opaque, it will be easier to remove the cataract after the irritation occasioned by the operation has completely subsided; for, by means of the vicarious pupil, the operator will see what he is about. If the artificial pupil is sufficiently large, the keratonyxis may be undertaken with advantage. But should the pupil be small, or the cataract adhering to the iris, it will be proper to prefer depressing through the sclerotica, in order to render the operation more certain, and to avoid the possibility of the opacity of the cornea covering the small pupil."

Professor Himly, that he might render the operation of separating the iris from the ciliary ligament, practicable in cases in which it had hitherto appeared inadmissible, improved upon it in the following manner.

1. When only a small portion of the cornea remained transparent at the external angle of the eye, but still admitting of the formation of an artificial pupil behind it; he invented a needle, which by being bent so as to receive the nose in the curvature, might be used over it and entered at the inner angle of the eye, thereby avoiding all injury to the transparent part of the cornea.
2. When the cornea is nearly or altogether transparent, he uses a needle, which, as far as regards the point, holds a middle place between those of Schmidt and Scarpa. This is introduced through the cornea into the anterior chamber, until it reaches the ciliary edge of the iris, into which the point is pressed and the iris separated in the usual manner.
3. When the structure and situation of the iris is altered, so that it becomes convex and nearly in contact with the cornea, the point of the needle is very likely, when pushed through it from the posterior chamber, to puncture the cornea; to avoid this, he directs the needle to be passed through the sclerotica at the external angle, and the point



made to perforate the iris immediately at its attachment to the ciliary ligament, when by insinuating the instrument sideways, between the iris and the cornea, room may be gained to complete the operation.

4. When the iris is so completely in contact with the cornea, that the point of the instrument cannot pierce it without wounding the cornea, he performs an operation at two different periods, leaving a proper interval between them. First, he removes the lens by depression, by which a sufficient opening is made in the natural place of the pupil to allow the aqueous humour to pass into the anterior chamber, and press back the iris into its proper situation; which being accomplished, he effects, in the second instance, the operation of separation (coredialysis).

Buckhorn, Richerand, Flajani, and others, have given their sanction to the anterior operation, as described under the second head; but I have reason to believe that Professor Himly did not find it generally answer his expectations, for the pupil closed after a certain lapse of time; and he latterly performed the operation of separation of the iris from the ciliary ligament, from behind, having passed the needle through the sclerotica; or, after the method of Langenbeck, through the cornea, strangulating a portion of the iris between the edges of the incision, to prevent a closure of the pupil. Himly has also recommended the operation of drawing the natural pupil to one side with a hook, strangulating the iris, in the same manner as has been recommended by Sir W. Adams, although he has not acknowledged his authority.

Flajani is said, by Scarpa, to have made an artificial pupil by dividing the iris crucially with a double-edged needle, introduced through the cornea, which he presumes to have been perfectly transparent, and unaccompanied with opacity of the lens or capsule. But Scarpa disapproves of the operation, and very properly remarks, that when the needle is introduced into the anterior chamber of the aqueous humour, and has perforated the upper part of the iris, a vertical division of



this membrane can only be made by pressing the instrument from above downwards, and withdrawing it at the same time from the eye; in consequence of which the iris is carried forwards by the pressure of the needle towards the concavity of the cornea. In the second stage of the operation, or in making the transverse incision in it, as the aqueous humour is almost entirely discharged, it is very difficult to replace the sharp and pointed needle a second time in the anterior chamber, where the iris is nearly in contact with the cornea; and still less, after this is accomplished, can the instrument be moved in a transverse direction, so as to divide this membrane crucially, through its whole diameter.

Professor Walther (late of Landshut, 1815) opens the cornea for about two lines and a half, with a small cataract knife, either in a straight or in an oblique direction, from the transverse diameter of the cornea, downwards or upwards, as the case may require. Through this opening the iris protrudes, if it be not too strongly attached. If it should not protrude, but lie against the wound, he seizes it with a pair of forceps, and cuts it off.

The advantage or peculiarity of Walther's method is that of making a large opening.

He also practises, in some instances, the operation of separation, to which he seems particularly to have been led from a consideration of the following case. A patient came to him with a leucomatous affection of the cornea, preventing vision, to which were superadded, inflammation of the internal parts of the eye, and an effusion of lymph, for the evacuation of which, an opening in the cornea became necessary. Through this opening the iris protruded, and drew the pupil opposite to a transparent part of the cornea, through which the patient immediately saw. He allowed the iris to remain protruded, and in this way a cure of both complaints was effected.

Langenbeck, in a memoir in his new *Bibliothek für die Chirurgie*, 1st volume, 3d and 4th part, sec. 2, p. 676, notices the formation of an artificial pupil, and has also invented



an instrument for effecting the separation of the iris. It consists of a silver tube, having a very small gold one affixed at one end, into which is inserted a small hook, which is moved backwards and forwards by a spring in the silver tube, but confining the motion of the hook to two lines. A very small opening is to be made in the cornea, in order that the iris, when brought out, may not recede. The hook enclosed in the golden tube (to prevent its bending from its tenuity) is to be directed to the spot where the iris is to be laid hold of; the hook is then to be pushed out by the spring, to the extent of one line, which will be sufficient to enable it to penetrate the iris. As soon as the hook is affixed, it is to be allowed to recede to its usual place in the golden tube, drawing with it the iris, which will be caught between it and the end of the tube, something in the manner of a pair of forceps. As soon as the hook begins to recede, a small black spot will be seen at the edge of the iris, from its incipient separation; and care should be taken to insert the hook at, or even under the edge of the sclerotica\*, and as near as possible to the ciliary processes. The hook must recede gradually, the finger being kept steadily on, and moved slowly with the knob regulating the spring in the silver tube. As the chance of tearing off a part of the iris is proportionate to the distance it has to be drawn out, the opening is to be made as near as possible to the spot where the separation is to be effected, taking care that the pupil shall be large enough, so that the prolapsed iris, and subsequent opacity of the cornea, cannot obstruct the entrance of the rays of light. The great advantage of this instrument, in Langenbeck's opinion, is, that the separation is effected by means of the spring, which is more gentle and gradual than when accomplished by the finger alone, so that if a commencement of the separation can be obtained, the completion of it is certain, without any risk of tearing the iris. As soon as the hook has receded to the golden tube, carrying

\* The iris, before it is attached to the ciliary ligament, extends a little farther outwards than can be seen through the cornea. G.



with it the iris, the whole instrument is to be gently withdrawn, moving it slowly up and down, in order to loosen the upper and lower attachment of the iris; for this membrane may be torn, if there has been much previous inflammation, or if direct force be employed in withdrawing it. The instrument always keeps its hold as firmly as the best forceps, and with much more advantage, for it occupies less space, and enables the operator to make the incision in the cornea small, on which the correct strangulation of the iris depends. In all his operations, the capsule of the lens has never been injured by this instrument, which he considers another advantage, and he conceives that it may be used through the sclerotica, without rendering the lens opaque, as by the methods of Scarpa and Schmidt. He thinks it a better instrument than that of Reisinger, because there is much less risk of injuring the lens, from the hook being smaller; and also, because it may be held much steadier, from its acting in conjunction with the golden tube, like a forceps: and as it is not necessary to introduce it so deeply as the hooked forceps, it is less likely to injure the lens. I prefer Reisinger's instrument.

When the cornea is transparent only at the outer edge, he sometimes performs excision. When there is an opacity of the cornea opposite the natural pupil, he has proceeded as follows. The cornea being opened near the edge of the sclerotica, the iris protruded, which protrusion being laid hold of with the hook, he drew out the pupillary edge, and strangulated it; but the iris again receded on the patient's moving his eye, which rendered it necessary to repeat the operation. If the iris will not protrude in such cases, the hook must be introduced, to lay hold of its pupillary edge, and to draw it out; and Langenbeck thinks there is more danger of inflammation and effusion of lymph, and subsequent closure of the pupil, after excision, than after strangulation, which is his reason for preferring it\*. He thinks this operation ought to

\* This is found to be an erroneous opinion. G.



supersede that of excision, in every case in which the natural pupil remains; but is diminished in consequence of some adhesion to, or of opacity of the cornea, preventing the passage of the rays of light.

Professor Langenbeck formerly directed the operation to be done without strangulating a portion of the iris in the wound of the cornea, in which he was supported by Bonzel, of Rotterdam, who recommends it to be done in the same manner, first fixing the eye by means of a hook in the conjunctiva; but, from finding that the artificial pupil thus made frequently closed again, he has latterly performed it as above described.

Frattini, of Parma, 1816, considers coredialysis through the anterior chamber as preferable to all the operations hitherto proposed, but recommends it to be done in the following manner; "After having opened the cornea, the handle of the needle is to be a little depressed, so that the point may be kept clear of the iris, and by carefully insinuating it in this way, alternately raising and depressing the handle, it is to be carried on to within about a line from the greater circumference of the iris, either at its superior or inferior part. The point of the needle is then to be pushed into the iris, just as far as will be necessary to enable the operator to detach it from the ciliary ligament, not by drawing the iris outwards, but by gently moving the instrument from above downwards, and vice versa, until the object be accomplished.

Gräefe, of Berlin, who also considers coredialysis to be the preferable operation, performs it, however, with an instrument of his own invention, a fine double hook, provided with a sliding sheath, steadied by a ring, and so constructed, that it will slide forwards or backwards, exposing or sheathing the point of the instrument at pleasure. The cornea being opened, the sheathed instrument, which he calls a coreoncion, is to be introduced flat, the point directed downwards, and carefully carried on by gentle motions, until it reaches that part of the ciliary margin of the iris which he intends to separate.



The sheath is then to be slid back, the double hook exposed, and pressed into the iris, when the sheath is to be again advanced, leaving the double hook to grasp the iris and ciliary processes in the same manner as a forceps: he then separates them from their attachment, by gently drawing the instrument outwards, by repeated efforts. Jüngken\* wishes to divide the merit of this mode of operating between Langenbeck and Gräfe; but Langenbeck says Jüngken saw him do it long before Gräfe; and Langenbeck's is certainly the better instrument.

Wagner, in an inaugural thesis, published at Göttingen in the year 1818, from which I have derived much useful information, describes an invention of his own, which he has used frequently with success on animals and on dead bodies, although never on man; but which I think complex, and therefore objectionable. It acts much like the instrument of Gräfe, being a double curved needle, so constructed, as, when closed, to resemble a single one. It is to be introduced closed, through the cornea; and when it has reached that part of the iris to be separated, it is allowed to open to a certain distance, which has been adjusted beforehand by a spring and screw; it is then to be pressed open into the iris, and again closed, so that a portion of the iris is included between the needles, as by the double hook, when the separation is to be performed as usual. He thinks the lens should always be first removed by depression, when the operation is performed through the sclerotica, the point of the instrument being subsequently directed forwards through the iris, instead of backwards, to effect the necessary separation.

Dr. Embden, 1818, says, these operations through the cornea ought not always to be resorted to, although most authors have approved of them; and recommends an operation through

\* Vide Das Coreoncion ein Beitrag zur Künstlichen Pupillenbildung, von Ch. Jüngken. Berlin, 1817, in Commission bey Liebeskind. Additional account in Langenbeck, Neue Bibliothek, 2 band, 1 stuch, part 3.



the sclerotica, with an instrument of his own invention, called raphiancistrum, from *ραφιον* (acus) et *ἄγκιστρον* (hamulus). In cases where the opacity of the cornea, and the adhesion of the iris to it, is so great, that the more usual modes are not sufficient, the instrument is to be introduced at the distance of a line from the cornea into the sclerotica, so that one side is upwards, the other downwards: on the left eye, the hook side upwards, on the right eye, the hook side downwards; and, to facilitate the introduction of the hook, the instrument must be pressed in the opposite direction. After the instrument is introduced, the lens is to be depressed, and the hook advanced one line beyond the point of the needle, by means of the knob in the handle; the ciliary edge of the iris, near the inner angle, is to be hooked with it, and drawn into the wound of the sclerotica, the handle of the instrument being first carried towards the temple, until the point of the needle appears in the wound, when it is to be directed towards the nose, and the hook brought out of the wound with the iris attached to it. Dr. Embden thinks this mode of operating through the sclerotica as effectual as Langenbeck's through the cornea.

Professor Dzondi, of Halle, performs the separation of the iris by means of an instrument in the shape of a forceps. The blades are a little bent towards their points, the one broad, grooved, and rounded off; the other pointed, not rounded but flat on the inner side, grooved, and a little shorter than the other, so that, when the forceps is closed, the point projects. The pointed blade is to be thrust through the iris, and by closing the forceps that membrane is grasped. (Langenbeck.)

Professor Zengs, of Vienna, says, "Many recent attempts, made by Dr. P. Jäger, have proved that the membrane of the iris may be separated from the ciliary ligament by a single hook, properly introduced, with greater facility than by the double hook of Reisinger, &c. In all my attempts to introduce any instrument, in the shape of forceps,



into the anterior chamber, in order to separate the iris, experience has taught me, that the anterior chamber is frequently too small, and the iris too near the cornea, to admit of the operation being performed with such an instrument. However, M. Reisinger's invention will do him great honour, and may be applicable in certain cases."

Schlagintweit, of Munich, 1818, has also invented an instrument for the separation of the iris, which he terms an *iriankistron*\*, which he uses in the following manner. After making an opening in the cornea, less than a line in length, the operator takes the *iriankistron* with the point downwards, the fore-finger on the knob of the silver ring, and introduces it closed into the anterior chamber of the eye, carrying it on towards the inner edge of the cornea. He then, by a gentle pressure on the knob of the ring, draws back the forceps blade, and presses the hook still further into the eye. The handle is then to be turned a quarter of a turn, so that the point of the hook may be directed to the iris, when, by a gentle effort, it is to be fixed into it. The forceps blade is now to be pushed forwards again, and the iris thereby pressed into the hollow of the hook. The instrument is now to be withdrawn with a gentle rotatory motion, by which the iris will be gradually separated, and drawn into the opening in the cornea. A sufficient prolapsus iridis being thus obtained, the operator opens his instrument, raising the handle at the same time towards the temple, when he again depresses it obliquely, and disentangles the hook.

The inventor had not tried his instrument on a living subject at the time he wrote, but says he always succeeded with it on dead bodies, and on animals.

Faure, 1814, invented an instrument, not for the separation, but for the division of the iris, being a very sharp pair of scissors, acting by a spring, whilst the extent of the opening is regulated by a screw. The cornea being opened, the

\* Vide Plate V.



scissors are introduced, closed; and, on being opened, one branch is passed through the iris; and in this manner a sufficient opening is made without injuring the lens, which in certain cases may be readily accomplished.

Montain, 1817, invented two instruments, one a pair of scissors, the other a knife, both to be used through the cornea, but neither possessing any peculiar advantages.

Muter, in 1811, published the following method of operating. "The border of the iris, towards the external angle of the eye, is the most convenient part to be operated upon; and we shall at present suppose this to be the situation in which the artificial pupil is to be formed. In this operation, the eye must be steadily fixed, the greatest precision being necessary.

"The operator taking a very fine thin couching needle, pierces the sclerotica immediately behind its junction with the cornea, in the line of its transverse diameter: the point of the needle should barely puncture the inner coat of the eye, lest it wound the capsule of the crystalline. The needle should be entered as if it were the intention of the operator to push the margin of the iris off from the ciliary processes. The sclerotica being thus punctured, the couching needle is to be laid aside for the iris scissors, which are so constructed that the blades, when open to the distance of about half a line, are parallel to each other, to the extent of four lines.

"The point of one blade is rounded off and blunt, the point of the other is sharp and thin, similar to a spear-pointed couching needle. They open by a spring, and, like the forceps, have only one long handle. The blunt-pointed blade is to be entered into the puncture of the sclerotica, the other blade will be opposite the margin of the cornea, through which it is to be pierced. The points of both blades being then directed forwards, till opposite the margin of the pupil, the border of the iris will be included between them. The points should now be turned towards the lower margin of the pupil, and closed, by pressure with the fore finger on the



short handle; an incision of the whole breadth of the border of the iris, beginning in the line of its transverse diameter, and extending to the lower margin of the pupil, will thus be made. The points being now allowed to be opened by the spring, are next to be turned towards the superior margin of the pupil, and again closed; another incision of the whole breadth of the border of the iris will be made, beginning in the line of its transverse diameter, and extending to the superior margin of the pupil.

“Thus will a triangular portion of the exterior border of the iris be removed. The scissors being withdrawn, the small hook is to be introduced, and the divided portion extracted through the incision.

“During this operation, the aqueous humour will not be evacuated until the scissors are withdrawn, consequently they can be used with the greatest precision, the parts of the eye retaining their natural tension and situation.

“The incision thus made will not exceed two lines in extent; and, if proper care be taken in piercing the cornea, and in closing the scissors, it will not be in the least ragged, but the lips clean and smooth cut. Although a portion of the exterior border of the iris is most conveniently removed, yet the superior or inferior border may also be removed in a similar manner. The incision will be sufficiently large to permit the extraction of the divided portion of the iris, and as it extends but a very little way into the cornea, not more than a line, cannot be the cause of any cicatrix to obscure the artificial pupil.”

Dr. Ryan, of Kilkenny, 1818, has no operation peculiar to himself, but appears to perform either that of Mr. Gibson or of Mr. Cheselden, improved by Sir W. Adams, as the case may require. In adopting these methods, he does not blindly follow the opinions of their inventors, but thinks and acts for himself, in a manner which the favourable result of his cases shows to be highly creditable. The following passage is a good epitome of both: “Many reasons have been assigned



for the frequent failure of the operation, but the chief cause has probably been overlooked. According to my view of the matter, disappointment has arisen chiefly from our not having adapted the most appropriate operation to each particular case: nothing can tend to counteract our endeavours more completely than a prepossession in favour of any one mode of operation, or an adherence to the rules laid down by any writer, however high his reputation. For example: I cannot coincide with Sir W. Adams, in the view which he has taken of the cause of the failure of Cheselden's operation, which he has of late revived. His method of introducing the knife, or the double-edged needle (for it appears to me a matter of indifference to which the preference is given), is unquestionably a great improvement\*: but I have never found it necessary to place any portion of the lens, or its capsule, between the edges of the newly-formed pupil. I cannot discover any advantage in this step; and, from analogy, I am led to consider these parts as extraneous substances, which would be likely to produce inconvenience when fixed between the edges of the newly-formed pupil. Indeed this operation is not that which is most generally applicable; it is not only ill adapted to the cases for which he recommends it, but would be highly injurious in many of them."

Professor Quadri, of Naples, has performed this operation in twenty-two instances, in the clinical school of surgery of that city, in the year 1816, on persons of every temperament, whether scrofulous, scorbutic, or syphilitic, between the ages of seventeen and fifty-five, and at every season of the year. In fifteen cases the operation was attended with success; with great relief in six; and failed totally but in one, from amaurosis. He frequently dilated and enlarged the remaining vestige of the natural pupil, contracted in some cases nearly to obliteration. He performed the operation on seven persons on both eyes at the same time. He makes the aperture of

\* Dr. Ryan seems to have forgotten, that it is Mr. Sharpe's method; see, in page 427, the quotation from his work.



the dimensions of from one to two square lines. When the state of the cornea leaves a choice to the operator, he prefers the inner portion of the eye to the outer, as affording greater benefit to the patient; and he makes the pupil a little below a line drawn horizontally through the centre of the eye.

#### PRELIMINARY OBSERVATIONS AND CLASSIFICATION.

The object of the formation of an artificial pupil is to admit the rays of light to the retina, with as little injury as possible to the remaining parts of the eye. To effect this, an opening must be made in the iris, of an extent equal at least to the natural size of the pupil, when moderately dilated; for, if it be less, there will not be sufficient room for the rays of light to act with effect on the retina, in a moderate light; and it must not be forgotten, that the artificial pupil never acquires the motions of dilatation and contraction, so eminently useful in the natural one. It should not, on the other hand, be too large, because it would prove detrimental to vision, by admitting too many rays of light to the retina\*. It should resemble the natural opening in form, as nearly as possible; for there cannot be a doubt of the advantage derived in man from a circular pupil, where the axis of vision is directly forwards; and although an artificial one is seldom made in a circular form, and in the centre of the iris, still that process will be the best, the result of which most nearly resembles the natural state.

When an artificial pupil cannot be made in the centre of the iris (from whatever cause), the other parts of it are eligible in the following order: 1st, The inferior part of the iris inclining inwards; 2d, The internal, a little below the transverse diameter of the eye; 3d, The inferior and external: the upper part being the least eligible, from the eyelid cover-

\* When the pupil is too large, it seems to have the same effect of confusing vision, as in the disease termed Mydriasis, which is an unnatural dilatation of the pupil. In both cases the patient's vision is much improved by looking through a small hole in a card or glass.



ing that portion of the cornea in the natural state of the eye. The lower and inferior parts of the iris are to be preferred, for the following reasons; because the line of vision being through that part, the eye is less removed from its natural axis, and consequently less squinting is occasioned than when vision is acquired in any other direction; and, if both eyes are operated upon, the axes of vision are made more nearly parallel. A decided preference of a position, not higher than the centre of the iris, is founded upon the natural position of by far the greater number of objects of vision, which it is essential for a person to see, being viewed forwards or downwards. In general, however, the selection of the place in which the iris is to be perforated, depends more on the transparency of the cornea, than upon the choice of the operator.

It may be useful to remark, that a small artificial pupil, at the lower part, is infinitely more valuable than a large one at any other, which, in the natural state of the eye, is covered by the lid, or much out of the axis of vision. If the pupil be made quite on the nasal side of the eye, the field of vision is less extensive in proportion as it is distant from the inferior margin of the cornea; and, although this objection cannot be urged against the pupil made towards the temporal side, still there is a defect frequently observed, if the pupil be small, and near the ciliary margin of the iris, from the patient's turning the eye a little inwards, to allow the rays of light to fall more on the central part of the retina; and this is even accompanied, in some instances, by a corresponding motion of the head, when the person is desirous of submitting any thing to accurate inspection.

If the state of the cornea will permit it, a sound part of the iris should be selected in preference to that which is apparently unhealthy; for the iris, when sound, seldom bleeds, and is not liable to inflammation when injured, or divided with a cutting instrument; in its natural condition, indeed, it has but little sensibility, and is therefore not very susceptible



of pain; but, with an unhealthy iris, we find the reverse to be the case; when wounded, it bleeds copiously, is prone to inflammation, which terminates not unfrequently in suppuration, or the deposition of lymph: and it is manifest, that the occurrence of either may eventually destroy the eye, or render the operation unavailing, by filling up the aperture made to serve as a pupil, with a deposition of lymph, or even by the formation of an adventitious membrane behind it.

The central part of the iris frequently appears unsound, whilst it is more healthy at its outer or inner margin; in which case one of these places should be selected for the operation, notwithstanding the rule which has been stated.

The external and internal margins of the iris, immediately on a line with the central transverse diameter, are particularly unfavourable for the operation of separating the iris from the ciliary ligament (coredialysis), on account of the long ciliary arteries entering at these parts, and causing by their division a greater hæmorrhage, if the iris is diseased, and frequently a higher degree of inflammation, than would otherwise occur; which dangers are augmented by the more firm attachment of the iris at this part, and the greater force necessarily employed for its separation.

The operation for artificial pupil should not be recommended where one eye is sound; for, as the axis as well as the power of vision will be different, it is likely, in most instances, to be prejudicial rather than serviceable. If the lens and capsule be perfectly transparent, and the pupil can be made at the inferior and internal part of the iris, observing an axis parallel to that of the sound eye, no inconvenience may perhaps ensue, as has frequently been noticed to be the case where the pupil has been drawn a little to one side, in consequence of a slight attachment of the iris to the cornea.

It is a question of some moment to decide, whether the operation ought to be performed or not in those cases, wherein vision has been totally lost in one eye, and materially



impaired in the other; and the decision should rest with the patient rather than with the surgeon, even where the prognosis is favourable; for, if the patient still enjoys sufficient power of vision to enable him to guide himself, the surgeon would be more than hardy who could put that portion of the faculty of sight in jeopardy, by attempting an operation which may fail in the best hands. In such circumstances the operation should not be attempted upon any grounds, unless the case is so simple as to require only an opening in the cornea and the removal of a portion of the iris, for the purpose of enlarging the natural pupil. If the patient cannot see sufficiently well to guide himself, the conditions are very essentially altered; since an unsuccessful operation involves the loss of very little, whereas much is to be gained by the successful issue of it. Where opacities in the centre of the cornea occasion the impediment to vision, it is prudent to dilate the pupil beyond the edge of the opacity by the daily application of the belladonna, which may possibly enlarge the sphere of vision so as to supersede, in a doubtful or dangerous case, the necessity of an operation.

I am perfectly aware, that in many cases of this kind an operation may be followed by the most brilliant success; but it is not to be denied that total blindness has been produced by this operation in many instances; simple, therefore, as it may appear, it ought not to be practised without the free concurrence of the patient, unbiassed by the language of authority, founded solely upon a fair and true statement of all he has to hope for, or to apprehend from its consequences.

The artificial pupil, as I have already stated, ought to be made as nearly as possible in the centre of the iris, in order that the rays of light may impinge upon the retina after passing through the crystalline lens, as in the sound state of the eye. It is also necessary on account of the ciliary processes, which are opaque bodies, surrounding the capsule of the lens, lying on, and attached to the zona ciliaris, and situated immediately behind the greater or outer margin of the iris. If, then, the



opening in the iris be small and directly in front of these processes, the patient ought not to be able to see, unless they become transparent, or have been removed by nature or by art. If they have not been removed, they in general retract or withdraw themselves from their attachment to the zona ciliaris towards the ligamentum ciliare; in consequence either of the injury the iris has received at its junction with the ciliary ligament, or from their being incapable of bearing the stimulus of light, or from some cause with which I am unacquainted. It must not, however, be overlooked, that in cases where a partial separation of the iris takes place from a blow, or from the attempt at dividing the centre of the iris with a knife, the restoration of vision, through the artificial pupil thus accidentally made, does not generally follow. X

CLASSIFICATION OF THE STATES OF THE EYE REQUIRING THE OPERATION FOR THE FORMATION OF AN ARTIFICIAL PUPIL.

The morbid affections of the eye, which render it expedient to perform an operation, in order to produce an artificial pupil, for the transmission of the rays of light to the retina, though many and various, may nevertheless, for the sake of arrangement, be comprehended under three general classes, namely:

1st. Those morbid states of the eye which depend on derangement of the structure and function of the iris, or of the crystalline lens and its capsule, the anterior chamber of the aqueous humour preserving its natural dimensions, the central part of the cornea remaining transparent.

2d. Those morbid states of the eye which depend on derangement of the structure of the cornea, the anterior chamber being nearly or quite natural in its dimensions; the iris, the crystalline lens, and its capsule, being healthy.

3d. Those morbid states of the eye which depend on any combination of the two preceding states of disease, or



with a diminution of the anterior chamber of the aqueous humour.

*In the first class are included —*

- a. Those cases in which closure of the pupil has taken place, in a greater or less degree, after the operations of depression, reclinacion, extraction, or by division of the crystalline lens, with or without the formation of an adventitious membrane, or deposition of coagulable lymph; the capsule having been destroyed or not.
- b. All cases of false cataract, of whatever description, wherein the lens, or its capsule, adheres to the posterior part of the iris, with diminution of the area of the pupil; the principal cause being inflammation of the iris, whether simple, or dependent on general derangement of health, syphilis, or rheumatism; the iris being more or less of its natural colour and structure, but plane on its anterior surface.

*In the second class are included —*

- a. Those cases in which the cornea is rendered partially opaque (leucoma), in consequence of ulceration, operation, or other cause, preventing the transmission of light, or impeding it so much as to render vision indistinct; but in which the anterior chamber, the lens and its capsule, remain unimpaired.

*In the third class are included the following cases —*

- a. A slight attachment of the iris, drawing the natural pupil to one side, with diminution of its size, the lens and capsule being transparent, the cornea opaque at the point of attachment.
- b. The same, with opacity of the lens and capsule.
- c. When the iris is convex, but not adhering to a transparent cornea, the pupil nearly closed, the pupillary edge of the iris firmly adherent, the anterior chamber considerably diminished or nearly destroyed.
- d. The state c combined with opacity of the cornea, and attachment of the iris, including the natural pupil.



- e. The state *d* combined with a staphyloma of the cornea, in a greater or less degree, the lens being present, or having been removed.
- f. Either or all of the three last varieties of disease, combined with central opacity of the cornea, so dense and large as to leave only a narrow transparent ring, the aqueous humour not being entirely wanting.
- g. The states included in *f*, the iris in contact with the cornea, a segment of a narrow ring at the edge being alone transparent, and the anterior chamber obliterated.
- h. Other anomalous states, not included in the above, but requiring some modification in the mode of operating.

The formation of an artificial pupil necessarily implies some derangement of the iris, the result of inflammation; for the closure of the pupil, the consequence of a collapse of the eye from a discharge of the humours, or from atrophy, does not admit of relief. In the arrangement I have chosen, and in all the varieties of disease enumerated, I wish it particularly to be understood, that the simple closure of the pupil is by no means the principal point demanding attention; for the estimate made of the actual state and appearance of the eye, connected with the previous history of the complaint of which the closure of the pupil has been the result, ought chiefly to regulate our decision.

From the knowledge which every practitioner ought to possess of the effects of disease on the system generally, and especially of what are called constitutional and specific diseases, such as scrofula, rheumatism, gout, syphilis, or irritative inflammation in unhealthy constitutions, he will gain considerable information, both in distinguishing and treating every complaint of the eye. This knowledge will enable him to discriminate the different shades of disease one from another, and prevent his forming erroneous conclusions. The mere inspection of the eye will give him a general idea of the nature of the previous inflammation; a more



minute one will point out the immediate local derangement; and the history of the previous and subsequent constitutional as well as local symptoms, will enable him to draw an accurate conclusion; and not only form a good prognosis as to the result of an operation, but, what is of more consequence, will prevent his committing, through ignorance, irreparable mischief.

If the deranged state of the iris, requiring the formation of an artificial pupil, be combined with amaurosis, glaucoma, varicosity, dropsy, or atrophy of the eyeball, an operation must be useless, and in most cases even highly injurious, because the inflammation following the injury will be very apt, in the four last cases of complication, to excite malignant actions, not easily to be suppressed, and even frequently destructive.

A natural state of the iris, as far as regards its colour and apparent structure, with the exception of the derangement of the pupil, unattended by any other external or internal local morbid appearances or symptoms of constitutional disease, with a tolerably accurate perception of light from darkness, is most favourable for operation; for these appearances imply, that the inflammatory affection, which caused a closure of the pupil, was not particularly severe, was in all probability neglected, and did not extend to the more internal parts of the eye.

A closed pupil after the operation of extraction (when performed in a proper case for that operation) offers in general a favourable prognosis; for the inflammation was in all probability simple, and arising from protrusion of the iris, or of the vitreous humour; and the iris will in general, by its otherwise apparently healthy structure, indicate the fact, which will be confirmed by the history of the inflammation. It is far otherwise after the operation of depression or reclinacion, except where the closure of the pupil has arisen from general high inflammation, which may even then have been productive of irremediable derangement. For, when it has taken



place from an imperfect depression, or from constitutional predisposition for rheumatic, gouty, or irritative and unhealthy inflammation, the prognosis is less favourable, because the more internal parts of the eye have, in all probability, been irrecoverably implicated in the disease.

A general convexity of the iris, which otherwise retains a healthy appearance, may not indicate any posterior disorganization, but rather a continuance of healthy action in some parts behind it. The membrane lining the transparent cornea has been called the membrane of the aqueous humour, on the supposition that it alone secretes that fluid; but this has by no means been demonstrated, whilst there are many facts leading to a contrary opinion; for, although some may be secreted in the anterior chamber, the principal part of this fluid passes from the posterior to the anterior chamber, through the pupil keeping up an equal pressure on both sides of the iris. If the pupil be closed completely, and the posterior secreting organs of the aqueous humour remain in activity, the fluid thrown out behind the iris not being able to pass through, presses it against the cornea, and gives it the convex shape alluded to. The pupil, in a case of this kind, will appear completely closed or filled up by a membranous substance; but appearances here are deceitful, for, from the subtilty of the aqueous humour, the pupil may seem to be closed, when it is not actually impervious to this fluid, and vice versâ. Bëer and Himly incline to the opinion I have stated, and the mode of obtaining relief favours it remarkably. It is by first making a small opening at the place of the natural pupil (perhaps removing the lens by depression), when the aqueous humour gets before the iris, and if it be not attached to the cornea, presses it back, and gives room for a subsequent enlargement of the pupil.

I have had many cases under my care, demonstrating the fact in a very marked manner. In one, the woman had suffered from inflammation of the iris before she came to me; at the termination of which the belladonna had been applied to dilate the pupil, which it would appear to a casual observer



to have done; but, on a more minute inspection, it was evident, that, although the pupil was of a tolerable size, as far as regards the edge of the iris, which was also immoveable, yet, in retracting, it had left behind it the pigmentum nigrum attached to a layer of coagulable lymph, which still closed the pupil, with the exception of an exceedingly small point, through which the communication was kept up between the anterior and posterior chambers of the aqueous humour. The best idea I can give of this state is, that it conveys the appearance of the iris, properly speaking, having retracted, leaving the uvea behind it. I operated on this disease (*cataracta choroidalis*) by separating the attachment of the iris, cutting into the lens, which was soft, and dilating the detached pupil by the belladonna. During the operation, which was accomplished with difficulty, from the softness and toughness of the iris, the aqueous humour escaped by the side of the knife, and the iris was pushed forwards against the cornea, by the pressure of the lens and parts behind. The lens being soft, I did not fear ulceration from its pressure; but it effectually prevented communication between the two chambers, and no aqueous humour appeared in the anterior chamber, although little or no inflammation followed, until the lens began to dissolve, when the iris gradually and slowly receded. If the lens had been hard, it must have been removed, either by depression or extraction, as it would have caused ulceration from pressure.

Against the opinion of Ribes\*, Edwards†, and Majendie‡, that the aqueous humour is secreted behind the iris, Cloquet has brought forward a very strong fact, viz. that a fluid, resembling in every respect the aqueous humour, has been found in the anterior chamber, before the membrana pupillaris had yielded in the slightest degree; demonstrating then (if the fact be correct), that some fluid is secreted before

\* Mémoires de la Société Médicale d'Emulation, tome viii, 2d part.

† Edwards, Mémoire sur l'Anatomie de l'Œil. Paris.

‡ Majendie, Précis élémentaire de Physiologie, tome i.



the iris, even if, as is supposed, the greater portion may come from behind the iris.

If the colour of the iris be altered, with little or very slight convexity, and no appearance of derangement of its structure, the change of colour will depend, in all probability, on the effusion of coagulable lymph behind it; and the alteration of colour will be confined to the central part, or in a space not extending beyond the size of the crystalline lens, and generally less; the pupil will appear to be closed, although not completely contracted. In such a case, if there be any perception of light, and no pain or uneasiness, the operation may be successful. A greater convexity of the iris will only show a more perfect closure of the pupil. But if the iris be diseased, the prognosis is bad; and if a blue iris be changed to green, or a brown one to a dove colour, there is but little hope, for the eye will in general be found either soft or hard, amaurotic or varicose.

The iris may show little or no sign of derangement, beyond some change of colour, yet the retina may be perfectly insensible (amaurotic), and the operation useless. In a case of this kind, the eyeball, on pressure, will generally be softer than natural; and the history of the case will materially assist us in forming our prognōsis, as well as the patient's want of perception of light and darkness, or his incapability of distinguishing the shadow of an object interposed between him and the light; for, if he cannot distinguish day from night, the prognosis is bad; if he has scintillations, or flashes of light of different colours in the eye, it is worse; and if it be accompanied by pain, even at intervals, or varicosity of the vessels, an operation ought not to be attempted. The want of power to distinguish night from day, the pupil being closed, is not a sufficient reason for conceiving the retina to be paralysed; and, if the eye is otherwise healthy, an operation should be attempted, for it has proved successful in many such cases, the patient slowly recovering useful vision; and,



if unsuccessful, it removes all doubt, and no bad consequences are likely to follow.

A closed pupil, resulting from inflammation, after a severe injury on the eye, including the forehead, and the lesion of the first branch of the fifth pair of nerves, is a case in which nothing can be expected; amaurosis being almost certain. The prognosis is equally bad in all cases of closed pupil, resulting from the passage of musket-balls behind, or lodging and pressing on the eye; for, in every case in which I have removed a ball from behind, or from the side of the sclerotica, the eye has been amaurotic. It is not so, however, when the other eye becomes affected, as the closure of the pupil is the consequence of simple sympathetic inflammation affecting the iris, which ought to be prevented, or at least cured by the most active antiphlogistic and mercurial treatment. In all acute cases of iritis, bleeding from the temporal artery is of as much use as mercury; it frequently renders its operation more rapid and certain, and, in healthy persons, should never be omitted. In all such cases, an attack on the sound eye may be expected, and the surgeon should be on the watch to meet and subdue it. The sympathetic inflammation is more to be dreaded than the occurrence of sympathetic amaurosis, one being generally the forerunner of the other.

The iris is occasionally so thin, and altered in appearance, as to show a solid yellow lens adherent to its posterior surface, in which case absorption has taken place from pressure, the iris having been in part disorganized by the previous inflammation, which has also, in most instances, affected the retina. If there be no other unhealthy appearance, an operation may be attempted, at the desire of the patient; but it will in all probability be unsuccessful. If the cornea be implicated, I think the prognosis better than if it be transparent, for then there is a greater likelihood of the more internal parts having been less affected.

If the whole of the iris be diseased and convex, it becomes



in parts puckered up and fleshy, bleeding on the slightest incision; it is of a dark blue dove colour, although sometimes a little lighter, the hollows between the elevations being more transparent, as if the iris was thinner at these parts, or the pigmentum nigrum was, as in the former case, partially or totally wanting. The general appearance of the eyes does not, however, mark the case less than that of the iris; it is altogether unhealthy. The sclerotica is of a leaden blueish colour; two or three vessels, of a brick-red colour, are seen pursuing a tortuous course nearly to the edge of the cornea, which part itself does not retain its natural brilliancy. The eye is generally harder than usual; if it should be much so, and the sclerotica, at the insertion of the recti muscles, especially the superior, the externus and internus, appear more discoloured, the varicose state of the vessels of the choroid coat is distinctly marked; but if a bulging out of the sclerotica is perceptible at these parts, the blue colour of the choroid shining through its attenuated substance, the eye being of a flinty hardness, the state of cirsophthalmia cannot be mistaken. The eye is completely disorganized, and an operation must be highly injurious, and not unfrequently fatal.

Glaucoma cannot be very evident with a closure of the pupil, further than as it is generally accompanied by internal derangement of the eye, showing itself by external appearances; such as a dull cornea, unhealthy-looking sclerotica, tortuous brick-red distended vessels, advancing nearly to the edge of the cornea, leaving a blueish white ring around it; scintillations of light, without any perception of light and shade. The eye may be soft from disorganization of the vitreous humour.

If the eye be of increased dimensions, an operation is forbidden; and if it be considerably diminished, it is equally contra-indicated.

From the observations which have been already made, disorganization, or dissolution of the vitreous humour (syn-



chisis), indicated principally by softness of the eyeball, will appear to be a frequent accompaniment of closed pupil. It is so, because closed pupil is an effect of inflammation, and so is the disorganization of the vitreous humour, in an eminent degree. I do not intend to say it is the only cause, for I know it may take place in cases where the previous occurrence of inflammation is not admitted, and no traces of it can be perceived. Bëer says, on this subject, although he does not peremptorily maintain it, that dissolution of the vitreous humour is either an effect of syphilitic inflammation of the eye, when traces of it may be observed, or the consequence of the excessive and improper administration of mercury, particularly calomel, in persons who have long suffered from syphilis, and have contracted a mercurial diathesis or habit; or, where it had been in the same manner given to persons of an excessively weak and cachectic habit, and more or less inclined to scurvy.

I ought to enter here into a discussion, as to what is or is not syphilis, before I express my doubts as to the accuracy of Bëer's conclusions on this subject, for he may very readily consider certain inflammations to be syphilitic, which we do not believe to have that character, and consequently he is so far correct; but in waving the discussion, in this place, where it would be obviously improper, we shall still very nearly approximate in opinion, if I admit, what I am most ready to concede, that the inflammation, in such cases, is not always a simple inflammation, but generally of an unhealthy character.

In regard to its being the effect of mercury, the difficulty is equally great, in deciding what is due to the mercury, what to the constitution; for, in thousands of persons, no such effect takes place; and I certainly have seen many cases in which the alteration could not reasonably be attributed either to syphilis or the improper exhibition of mercury.

This fluid state of the vitreous humour has been long known, especially as existing with cataract, where it could



not have been the result of inflammation, and has not been considered as forbidding even the operation of extraction. The Baron de Wenzel has a chapter in his book on this very point, and gives the cases of two persons, from whose eyes he extracted three cataracts, the vitreous humour being in this state; and who saw as well afterwards as persons usually do after an operation for cataract; although, in one case, three-fourths of the whole quantity had been lost during the operation.

In general, when the vitreous humour is disorganized, the power of vision is not so good as De Wenzel mentions. Bëer says, it is either very weak, and the patient far-sighted, or else it is reduced to a trifling and imperfect perception of light, if not to blindness.

The subject seems to admit of very little discussion, for it is an acknowledged fact, that in no part of the human body could any other structure be employed with the same advantage as that which nature has adopted; if a disorganized state of the vitreous humour would have answered, even as well as the healthy state, there can then be no doubt but it would have been substituted for a structure which is infinitely more complex; and it follows of course, both according to the laws of nature and the laws of optics, that vision cannot, in any case, be as good as when the vitreous humour is sound. The truth lies between the two extremes, and the state of vision depends on the nature of the derangement previously affecting the eye. When the dissolution takes place without inflammation, or such appearance of its principal phenomena as entitle us to adopt that term for the morbid affection, the vitreous humour retains its transparency; and vision, although certainly more impaired in the most fortunate case of operation for artificial pupil, than in an equally fortunate case of cataract, is still good, and enables the patient to see very well with the help of a proper glass. But if inflammation should have preceded, and have been, as far as we can judge, the apparent cause of this change in the vitreous humour, it



will, in all probability, according to the nature and severity of the inflammation, not only have lost its consistency but its transparency, changing to a straw or yellowish colour, and even to a yellow, light green, or brown. The change to a straw colour is common to old age, but the other states are always the result of inflammation, and vision is exceedingly defective, if not entirely destroyed. It is not the change of colour, however, which entirely prevents vision, for this defect often accompanies a transparent state of the vitreous humour; but the amaurotic state of the retina, as a sequela of the original complaint. A deranged, if not a diseased state of the retina, is always to be feared in cases of closed pupil, when the vitreous humour is suspected to be fluid, although one is not a necessary accompaniment of the other, further than that inflammation is shown to have been in actual contact with, and in all probability to have been communicated to the retina or adjacent parts, capable of acting upon it. Whether the retina can or cannot bear a degree of inflammation with impunity, which causes disorganization of the vitreous humour, I am not capable of deciding; but I know, that inflammation of the retina, or choroides, frequently destroys vision: and in a case where the previous existence of general inflammation is tolerably evident, from the closure of the pupil and flaccid state of the eye; what proportion of it has fallen to the lot of each part, no one, I believe, will attempt to demonstrate. A diseased state of the retina generally implies a disorganized vitreous humour, although a disorganized vitreous humour does not always indicate a diseased retina.

At page 412, when considering the merits and demerits of the different operations for cataract, combined with this state of the vitreous humour, I have given it as my opinion, that the disorganization principally consists in a removal of the membranous septa of the hyaloid membrane, rather than in a very material change in its constituent parts. B  er admits, that, in all these cases, the hyaloid membrane be-



comes particularly thin and crisp, so as to be readily ruptured, on the application of the slightest exciting cause. I conceive that the hyaloid membrane itself actually undergoes the same process of dissolution, especially at its anterior and inner part; and that the lens, enclosed in its capsule, sinks at last to the bottom of the eye, from the dissolution of the hyaloid membrane depriving the capsule of its principal attachments.

In such a case of closed pupil, the history of the disease, and the appearance of the diseased eye, will materially assist us in forming our prognosis. If the inflammation, which closed the pupil, was moderate, simple, and in a healthy constitution; the iris good, the eyeball not diminished in size, although soft to the touch; and if the patient can distinguish light from darkness, the prognosis is favourable, for the retina is in all probability unaffected, the vitreous humour transparent. If the eyeball be diminished, the danger of amaurosis is much greater, although not certain; and, according to the appearance of the other parts of the eye, the prognosis may, in the same manner, be formed. It may, however, happen, that the vitreous humour and the retina may be both diseased, and accompanied by closure of the pupil, without any flaccidity or diminution of the eye; it may be even firmer than usual; but then the surgeon must be suspicious of a varicose state of the organ, and turn his attention particularly to the symptoms of that state, which have been already enumerated.

When the disorganization of the vitreous humour takes place, without a closure of the pupil, and with or without the appearance of a cataract, a due discrimination of the nature of the disease is of the greatest importance, especially if there be a cataract, and an operation has been proposed. The particular symptom, to which I wish to attract attention, is the state of the iris. The appearance of it at first sight is nearly natural; the pupil is very sluggish in its motions, sometimes slightly irregular, yet sufficiently obedient in most instances



to the belladonna, applied in the usual manner; but it has acquired a motion it does not possess in a healthy state of the eye, a vacillating motion backwards and forwards, such as a rag would have, if agitated in a glass globe not quite full of water; or as some have compared it to the unsteady motion of a well-poised magnetic needle; which is perceived on making the patient move the eyeball rapidly, and which, when once seen, can never be mistaken. When combined with softness of the eyeball to the touch, it is perfectly diagnostic of a disorganization of the vitreous humour; when the eyeball retains its firmness, without symptoms of varicosity, and a cataract is present, it marks it to be capsular, or fluid.

I know but of one apparently healthy eye, in which the iris has this motion to a certain extent, and I admonished this person, that if he should ever suffer from cataract, he ought not to have it extracted.

The fact which I wish to be adduced from this digression is, I apprehend, of some little importance, *viz.* that the iris will frequently retain this intestine kind of motion, although the pupil be closed, and more especially if the lens should have fallen back into the vitreous humour. I have a case now under my care, in which it is exceedingly well marked, whilst the other symptoms are equally demonstrative of the nature of the morbid affection.

But it will sometimes happen, that with exactly the same appearances to our senses, one eye shall be found to be good, the other the reverse; and that which seems to be the best, will be the most injured by disease.

I have lately seen a young lady who became blind from closed pupil, the result of inflammation of the iris, when a girl, and who, after the disease had existed seven years, had the operation performed on both eyes, for artificial pupil. In each, the lens separated with its capsule, and sunk to the bottom of the eye: the eye which appeared the best, and of which most hope was entertained, was found perfectly amaurotic. With the other, the patient sees very



well; and, after a lapse of five years, the lens enveloped by its capsule, but shrunk, irregular, and more spherical than usual, is seen moving towards the cornea from the bottom of the eye, on every sudden motion of the head. The eye is very soft, the vitreous humour perfectly transparent, the iris a mere ring around the inner edge of the ciliary ligament. The lady is subject to headaches, frequently severe; and she always feels, on a sudden motion of the head, the sensation of something moving in the eye. This case I consider a very valuable one, for it shows, that, after simple inflammation of the iris, ending in cataract and closed pupil, the retina may be healthy or unhealthy, the eye which was considered to offer the best prospect of a favourable result, being in this case the worst. That softness of the eye to the touch implies merely a disorganization of the vitreous humour; which, as it is a general accompaniment of disease of the retina, renders the healthy state of that membrane doubtful: it also shows, that in performing an operation in such cases, it is not possible to extract the lens, unless it accidentally slips into the anterior chamber, as it usually sinks to the bottom of the eye, from whence it must be fished up with a hook: and, that the lens remaining in this state, in a disorganized vitreous humour, does not cause all the mischief generally attributed to it\*.

Finally, In no case should the operation be attempted where the eye is not perfectly free from inflammation of every description, especially from all trace of that which caused the closure of the pupil: a well-regulated local treatment will then be often required, previously to the performance of an operation to remove a chronic state of irritation, which frequently remains after the principal disease has been removed. The state of the constitution will demand fully as much of our attention, for no man, in the slightest degree acquainted with the practice of surgery, can be ignorant of the influence it

\* See page 412 et seq.



exerts upon local injuries, and how much the success of surgical operations depends upon the soundness of the constitution. A correct medical treatment will often be absolutely necessary to re-establish the health of the patient, and any predisposition to derangement should be studied, as well as his actual state of disease; for a person predisposed to rheumatic or gouty inflammation should not be operated upon, whilst a fit of the latter is impending, or even expected; or the state of the weather, the season, or any premonitory signs, render the prospect of an attack of rheumatism probable; for, in such cases, the operation would be liable to excite in the eye an inflammatory action of the character to which the patient is predisposed, and which would in all probability prove fatal to vision. In the same manner, persons suffering from a syphilitic, mercurial, or generally cachectic habit, should be, as nearly as possible, restored to their natural state of health, before the operation is attempted.

#### FIRST CLASS.

*Those morbid states of the eye which depend on derangement of the structure and function of the iris, or of the crystalline lens and its capsule, the anterior chamber of the aqueous humour preserving its natural dimensions, the central part of the cornea remaining transparent.*

SECTION a. — *Those cases in which closure of the pupil has taken place, in a greater or less degree, after the operations of depression, reclinacion, extraction, or by division of the crystalline lens, with or without the formation of an adventitious membrane, or deposition of coagulable lymph: the capsule being destroyed or not.*

The most favourable cases for the operation of artificial pupil by division (coretomy), are those contained in section a of the first class, in which the closure of the pupil is the result of inflammation, consecutive to the operation of extraction. They are so because the inflammation has occurred in



an eye in general free from disease, from its having been, for the most part, confined to the iris, and from its being frequently on the stretch, from some slight attachment to the lower and inner edge of the cornea.

When the operation of extraction has been successfully performed, it will be recollected, that the anterior capsule of the lens ought to have been cut in pieces, so as to offer no point to which the iris can adhere: it must then be in consequence of a very high degree of inflammation, or in a very neglected case, that an adventitious membrane can form behind the pupil, so as completely to prevent the passage of light to the retina; for the iris rarely closes in a case of this kind to a point; and if the inflammation does cause the formation of a new membrane, through the deposition of lymph, it may be removed with the needle, without dividing the iris, nearly as in a case of secondary capsular cataract. But more frequently, the closure of the pupil demanding the formation of an artificial one has been caused by inflammation, the consequence of pressure on the iris, in the passage of the lens through the pupil; in which case the capsule of the lens will seldom have been completely destroyed, and the pupil will adhere to it. The iris may become attached to the inner edge of the incision in the cornea, or probably in part protruded through it, giving rise to inflammation of the iris, and subsequent closure of the pupil. In the first two instances the iris is perfectly plane, and its fibres hardly on the stretch. In the two latter, the iris is protuberant at the lower place of incision, the pupil drawn towards it, and the fibres much on the stretch in the opposite direction. If the depth of the anterior chamber is unimpaired, or diminished only in a trifling degree, the operation by division is, in all, the most applicable. Mr. Cheselden, it would appear, intended it for these particular states, and from endeavouring to extend its application to others, it seems to have fallen into disrepute; for, at that time, the solubility of the lens in the aqueous humour was unknown, its extraction not practised, and the sufficient en-



largement of the wound in the iris, by repeated attempts with the knife, not insisted on, from the fear of evacuating the vitreous humour. As I have stated, in the history of the operations, Sir William Adams has the merit of reviving it; and I think it due to him to describe it in his own words.

“The patient being seated as in the operation for cataract, and the eye being steadied, either by the finger of the assistant, who supports the upper lid, or by the gentle pressure made by my concave speculum, the iris scalpel already described, with its edge turned backwards, must be introduced through the coats of the eye, at their external part, about a line behind the iris, and in the transverse diameter of the latter membrane\*. The point of the instrument should then be made to penetrate through the iris into the anterior chamber, in a line with its central diameter, and somewhat less than one-third of the width of that membrane, from its ciliary margin. The iris scalpel is then to be carried cautiously through the anterior chamber, towards the inner canthus, keeping its edge in contact with the iris (in order to prevent the point from piercing the internal part of the cornea), until it has traversed more than two-thirds of the width of the iris, when it should, with great care, be drawn backwards, almost out of the eye, making the most delicate pressure with the edge of the instrument against the iris, lest it should be detached from the ciliary ligament. If the division of the iris is not effected to a sufficient extent, during the first effort, the iris scalpel should be again carried forward, and withdrawn in a similar manner.

“This is to be repeated as often as may be necessary to

\* Before the eye is fixed, the patient should be desired to turn the eye slightly towards the nose, which trifling obliquity enables the knife to be passed in front of the iris with more facility. It should also be introduced half a line below the transverse diameter of the eye, on account of the ciliary vessels; and the iris scalpel employed should be the smallest that can be made, consistently with the service required from it. G.



effect a division of the iris to the extent of a third part of its diameter. In my work, published in 1812, I directed that two-thirds at least of the extent of the transverse diameter of the iris should be divided, in order to guard against the supposed disposition in that membrane to reunite; but that abundant experience of the favourable results of this operation, which has since occurred in my practice, has convinced me that no such apprehension need be entertained, and that a division of one-third the extent of diameter of the iris is sufficient. Indeed, so far is there from being a disposition in the newly-formed pupil to close again after it has been once established, that the very reverse is the case; for the radiated fibres subsequently contract in a greater degree, from delay; whereby the artificial pupil is proportionably enlarged. In the species of case now under consideration, an almost immediate contraction of the radiated fibres of the iris usually takes place, after that membrane has been divided, which produces a new pupil of a sufficient size for all the purposes of vision."

The operation, as it is here described, offers no difficulty, until the attempt be made to cut the iris by withdrawing the knife. The description of the division of the iris, by the most delicate pressure; or, fibre after fibre; or, by a pressure equal to the weight of a drachm, which have been given, are perhaps intelligible to a general reader, but are not sufficiently precise for the medical student who intends to perform the operation. This does not arise so much from a deficiency of terms, as from the state of the iris being essentially different in different instances; so that out of six or eight cases, apparently similar, in no two will the iris be divided with the same degree of pressure or facility; the appearance of the pupil, from an incision of equal extent, being probably different in all. In some cases, the iris will yield and separate to the most delicate pressure of the knife, and the pupil appear to be instantaneously formed. This is often the case when the pupil has closed after the operation of extraction, where the



capsule of the lens has been removed ; it is generally so when there is a slight attachment of the iris to the inner edge of the incision, which puts its fibres on the stretch, and renders them sufficiently tense to resist the pressure of the knife, and yet yield to its edge. In these cases, the iris is but little altered from a healthy state, or perhaps in a slight degree at its centre, and the circular fibres once divided, the superior and inferior radiated ones separate the edges of the incision to a reasonable distance. I would describe them, as cases in which the iris gives way to a delicate pressure, yielding fibre after fibre in such rapid succession as to render the division almost simultaneous, but proceeding no farther than the extent of the incision. In many cases of closed pupil, when the preceding inflammation has been so violent as to alter the structure of the iris, rendering it much thinner than natural ; and more often, when accompanied by amaurosis ; the iris does not only give way to moderate pressure, but yields to the most delicate touch, flying, as it were, before the knife in every direction, so that all that remains to be seen of the iris is a small ring, forming nearly a complete circle at the junction of the cornea and sclerotica, exposing a more or less clear vitreous humour, perhaps containing a floating and diminished lens, or an opaque capsule behind. I believe, in this kind of case, the capsule of the lens does not adhere to the posterior part of the iris ; and I have seen the same thing take place where the iris was so thin that a solid yellow lens could be distinctly seen behind it. The iris flew to the ciliary ligament, the lens sunk to the bottom of the vitreous humour ; or, in a less marked case of general derangement, the diminished lens remained supported by its lower attachment. In the greater number of these cases, the iris is evidently more or less changed in structure and appearance ; frequently it is of a dove blue colour, but not puckered, and but little irregular.

Opposed to this state is the closed pupil, the result of inflammation from an injury, where the lens has been absorbed, and the capsule firmly adherent to the iris ; or, in some few



cases, from specific inflammation, as of gout, rheumatism, or syphilis. In these instances, the anterior capsule, or both anterior and posterior, are thickened and firmly attached to the iris, the fibres of which have no longer any power of action; there is but an indistinct perception of light, and the smaller circle of the iris is in general more discoloured, indicating a greater deposition of lymph behind it. In a case of this kind, the knife will not penetrate the iris and adherent capsule by any force; for, if it be increased, so as to render it effectual, the iris will be torn from the ciliary ligament; it will give way rather at its circumference than at its centre. When pressure is applied, the iris, it is true, yields to the knife, but it is not divided; if the pressure be increased, the knife is seen to carry the iris before it, deeply backwards to the centre of the eye, and when it is withdrawn this impression remains on the iris as a permanent mark, but without any perfect division having been effected. A case of this kind presented itself to me some years ago, in a woman, on whom this operation had been attempted. The mark of the knife, with a corresponding depression of the iris, remained in its transverse diameter, but no opening had been made. I repeated the operation, but with an equal want of success, and the woman refused to allow of an attempt at division with the scissors, which would, in all probability, have succeeded.

The proper operation for such a case is the coredialysis, or separation at the ciliary ligament; for the formation of a triangular opening by the scissors would not be easily accomplished to a sufficient extent; and the simple division of the central part of the iris would, in general, be ineffectual, in consequence of the thickened capsule preventing the necessary retraction of the fibres of the iris. In cases where the capsule has become thickened after extraction, the same difficulty is experienced, but in a minor degree, and the iris is pressed so far back, before it is cut, that if practitioners are not made acquainted with the fact, they will fail from not



applying a sufficient degree of pressure. It is at this moment that the iris may yield at the ciliary ligament, which must put a stop to all further attempts to divide it, as they will only increase the separation. But, in a case of this kind, when once the iris has yielded at the ciliary ligament, its separation should be assisted by gentle pressure, until a sufficient space has been obtained for a new pupil; the operator, in consequence of the accidental separation, changing his mode of proceeding, and adopting that which B  er and other continental surgeons think the best. There is one thing of importance to be recollected, which is, that a spontaneous separation, as it may be termed, of the iris from the ciliary ligament, never closes, whilst it frequently does so when purposely effected, unless a portion of it be cut away, or it be strangulated in the opening in the cornea; the difference being, I conceive, dependent, in the first instance, on its being a complete separation of the border of the iris; whilst, in the latter, it is, in many instances, a rupture within the border, which, therefore, renders the excision or the strangulation of it, in a wound of the cornea, necessary, to prevent its reunion.

If an opening should be made with the knife, and another by the separation of the iris, so as to make two pupils, and thereby confuse vision, they must be laid into one, at a subsequent period, by a stroke of the scissors, after having made an opening in the cornea.

In other cases, the cellular structure of the iris seems increased in quantity, and becomes tougher and more distensible, so that the knife, on entering at the temporal angle, may pass over towards the nasal angle, carrying the iris with it, without completely dividing it; and repeated attempts, in the same line of incision, will be necessary, before it can be sufficiently cut to effect an artificial pupil of proper dimensions. If the vitreous humour be thin or disorganized, it will escape so rapidly, during these reiterated attempts, that the eye will become flaccid; for it must also be known, that if



the knife be withdrawn nearly from the eye, after the first attempt on the iris, and a second and third be made, the opening in the sclerotica is increased, sometimes even to nearly double its original size, and the evacuation of the vitreous humour becomes proportionably more rapid. This loss will, however, be of little consequence, provided the artificial pupil has been made, as it will shortly be reproduced; and the operation is followed by less inflammation, from the flaccidity of the eye admitting of greater vascularity, without a corresponding degree of tension.

The division of the iris is by no means a certain operation, as far as regards the quantum of pressure to be applied; it must also be borne in mind, that steady pressure does not cause a knife to cut, unless it be accompanied by a slight motion forwards or backwards. Every knife requires to be drawn along a part, to effect a division; and this saw-like action is the more necessary in proportion to the want of resistance behind. In dividing the iris, it must not be forgotten, that it is for this reason the knife is directed to be withdrawn nearly to the point, by a double motion of pressure backwards, and removal outwards; and, in doing this, attention is necessary to a third circumstance, that the back of the knife be constantly kept in contact with the sclerotica, next the cornea, which acts as a fulcrum, or point of support, and prevents the opposite part of the sclerotica from being cut, at least in any great degree. In other words, the knife is to act as much as possible without increasing the external opening.

In making these repeated attempts on the iris, the edge of the knife should always act on the same line, so that the iris may not be cut in two parallel lines, which may always be managed without difficulty, yet one part may yield more readily than another, and two pupils may be formed in the same direction, separated only by a narrow slip, not easily divided when the iris is flaccid. This once occurred to me, and rendered a second introduction of the knife necessary; but, if a considerable quantity of the vitreous humour should



have escaped during these repeated movements of the instrument, the iris will have become so flaccid, from the want of posterior support, that it cannot be cut, although it may be torn from the ciliary ligament, and the surgeon must abstain from further proceeding, until the eye shall have again become firm from the reproduction of the humours, when he may complete his operation.

**SECTION b.**—*Containing all cases of false cataract of whatever description, wherein the lens, or its capsule, adheres to the posterior part of the iris, with diminution of the area of the pupil: the principal cause being inflammation of the iris, whether simple or dependent on general derangement of health, syphilis, or rheumatism, the iris being more or less of its natural colour and structure, but plane on its anterior surface.*

The presence of the lens, in addition to a diminution or obliteration of the pupil, renders an operation more complicated, but not at all times more difficult. The lens may be of its natural size, transparent or opaque, hard or soft, the capsule simply opaque, or thickened, tough, slightly or strongly adherent, or remaining in situ, the eye soft, the vitreous humour disorganized. The iris may be discoloured, and the lens, of a yellow colour, solid, and even shining through it.

The operation must be performed according to the nature of the case.

When inflammation of the iris is neglected, or improperly treated, a deposition of lymph takes place behind it, upon the capsule of the lens, uniting it to the uvea, contracting the size of the pupil, and preventing the passage of the rays of light through the crystalline lens to the retina, forming what is called *cataracta lymphatica*\*; if blood be intermixed with it, *cataracta grumosa*: and the lens may be, in either

\* See page 255 et seq.



case, opaque or transparent, although it is generally soft, and easily separable into pieces, or from the iris. If the inflammation of the iris has been violent, and neglected in the first instance, the pupil will frequently close nearly to a point; and if the belladonna is applied at a subsequent period, the iris seems to retract, leaving a portion of the uvea, or pigmentum nigrum, attached to the lymph adherent to the capsule of the lens, so that the pupil will, on a casual inspection, appear to be of its natural size, whilst it is in fact nearly closed. In many cases, the eye will have become amaurotic, whilst in others the patient can see, although imperfectly, through a very small opening; the lens, in both instances, being generally transparent. *Cataracta choroidalis* of Richter.

In the cases to which I am alluding, the diameter of the pupil is not less than one line, in some instances more; and although the edge of the iris is adherent, so as to render it immoveable, still the lymph, deposited behind it, seems to be laid upon the capsule of the lens, rather than to form one part with it: the iris itself, even in its smaller ring, is hardly, if at all discoloured; or, a slightly greenish tinge may be discovered in one which is naturally blue, and a deeper tinge of colour in one that is usually brown.

In such cases, the motion of the iris appears only to be prevented in consequence of its attachment; and the objects of an operation seem to be the separation of the attachment, and the removal of the opaque parts. This may be accomplished by the introduction of a needle behind the iris, so as to divide its attachments; and subsequently to open into the texture of the lens; for, as the passage of the needle behind the iris necessarily renders the lens opaque, if it be transparent, the removal of it becomes necessary to vision. In this operation, the iris need not be cut, unless at a part where it may be too firmly attached to be separated, and the belladonna must be applied immediately after the operation, to dilate the pupil, and separate it more permanently from the parts behind; in which state of dilatation it must be



retained until the lens is dissolved. In some cases, the iris, although separated, will still be immoveable, from the cohesion of its fibres one to another, from the effusion of coagulable lymph in its posterior part, although this may not be strongly indicated by a change of colour. If, after the iris be detached, the pupil is likely to be too small, the point of the needle must be advanced through the pupil, and the inner edge of the iris divided, as far as may be necessary, to ensure a pupil of a proper size. In some instances, as well as in others of the subsequent cases, the operation may require repetition, to effect the complete removal of the lens. Scarpa, in his Letters, published in the Edinburgh Medical and Surgical Journal (vide No. 60), does not admit that such a state of eye exists, in which the adherent cataract can be separated, and the natural pupil remain of sufficient magnitude for useful vision. The dilatation of the iris by the belladonna, after the operation, in these instances, removes the difficulty, and the division of the inner, or even of the outer edge, obviates, I conceive, his principal objection; and the practicability of the operation is proved in the case related page 480.

In cases where the pupil is more contracted, so as not to leave an opening of a line in diameter, and where there is every appearance of a more firm attachment to the capsule of the lens, the operation by division may be attempted, whether the lens be opaque or transparent, soft or more solid; but it is fortunately, in most instances, soft and easily divided. The operation is to be begun and continued as in page 492, until the iris is about to be divided, when the operator must proceed by making the opening into it larger than when the lens has been removed, as it is more likely to close at its angles.

The lens is at the same time to be cut into, and as soon as the opening in the iris is sufficiently formed, to be cut in pieces in every direction, and as much of it as is possible brought into the anterior chamber. The complete division of the lens into small pieces will seldom be effected at the same time as



the artificial pupil is made, so that one operation may suffice for both; but a second will generally be necessary to complete the destruction of the lens, which may be done with the needle, as in soft cataract, provided the pupil has been made sufficiently large. The principal object of the first operation is to make an artificial pupil, and to open the texture of the lens. The iris, if the lens be hard, is readily divided, but the cut edges do not always separate, in consequence of an attachment behind, which must, if possible, be destroyed, the incision enlarged to at least two-thirds of the extent of the iris, and the edges pushed asunder by the side of the knife; the capsule being alike the cause of the non-retraction of the fibres of the iris and of their reunion. The lens, which has been in part cut up by these different motions of the needle, is now to be more separated in its texture, and brought forwards, so that what remains behind (if in any quantity) may be more exposed to the action of the aqueous humour. At this period of the operation Sir W. Adams particularly insists on a portion of the lens being cut off and placed as a plug or wedge between the edges of the incision, in order to prevent their reunion by the first intention, until all disposition for it has ceased; he also thinks, that the fragments or portions so interposed tend to promote a contraction of the radiated fibres, whilst the artificial pupil is made to assume a transversely oblong shape.

On this subject I have to remark, that if the fragments be not attached to some portion behind the iris, they will not readily remain in the desired position, but fall forward into the anterior chamber from the usual law of gravity; and in fact, the accomplishment of this part of the operation is in most cases as much an act of necessity as of choice; the opened texture of the lens hanging out in considerable portions. As to the utility of a part of the lens acting in the manner of a plug or wedge, it is, in some instances, extremely questionable, whilst in others it may be advantageous. If the iris has been readily divided, and has retracted with



little adhesion, to a sufficient distance, mechanical irritation is injurious; for so far from tending to promote a contraction of the radiated fibres, as is supposed, it has and must have a contrary effect; being another cause of inflammation and its sequelæ, and such a manœuvre should not, therefore, be attempted\*. But if the edges of the iris cannot separate to a sufficient distance, from the firm adhesion they have to the capsule behind, the adhesion must be divided as I have directed, by gentle pressure with the edge and side of the knife, and the interposition of a plug or wedge will be highly serviceable; but the plug does not here act on the iris, but on the edges of the capsule, which are not irritable, and to which it is attached, and which can generally be seen of a whitish appearance, extending beyond the edges of the fibres of the iris, and protecting them from injury. In dissenting, then, as to the manner in which the fragments act on the iris and capsule, and their advantage in all cases, I agree in the opinion as to their utility in the particular cases and in the manner alluded to, and which cases are not infrequent from the disease being a consequence of inflammation.

If the lens be found too hard to admit of division, the operator will do well to defer the remaining steps of the operation until a subsequent period.

According to the directions which have been given, the central third of the iris, or very little more, is to be divided in a favourable case for an artificial pupil. Where the lens is to be cut up, a larger opening must be made; and if the capsule be thick and firmly adherent, it must be further extended; yet if the lens be so solid as not to admit of division, this opening will even be too small to allow of its extraction. The incision of the iris must then be increased so as to exceed the diameter of the lens, which is to be pushed into the anterior chamber. On this point Sir W. Adams simply says†, “But if the lens be found too hard to admit of division, or

\* Vide Dr. Ryan's observations on the subject, page 441.

† Page 38.



if it should separate from its adhesion to the iris, before the operator is enabled to effect that important object, he should at once bring it through the new pupil into the anterior chamber; and, after making a sufficient opening in the cornea, extract it with a hook."

The directions given here are explicit, but are by no means readily executed. I have shown that the pupil must be divided, at least to the extent of the diameter of the lens, which is contrary to the first principle of the operation; but even then the lens cannot come through, unless the fibres of the iris retract very considerably, which they cannot do if they are attached to the capsule or lens. If the capsule be thick and the attachment strong, the extraction of the lens is out of the question, for the slit in the iris will not be equal to the thickness of the lens, even if its edge be turned upwards; and as to forcing it through after it has been dislocated, it is not to be accomplished with safety to the organ. It frequently requires a little trouble to effect it in a dilated state of the natural pupil, and surely it must be considered impracticable in a narrow artificial one. Indeed the lens once dislocated will sink of itself; and although it may be moved behind the iris, it will never be brought through it, especially if the vitreous humour be in any degree disorganized, in which case there is little or no resistance. It is true, in some instances, the iris immediately covering and adherent to the lens will separate with it on being touched; in which case it is virtually in the anterior chamber and may be extracted, provided it does not sink to the bottom of the eye; but that eye will yet be useless, because it must be amaurotic. In another case where the iris flies to the ciliary ligament, a hardened lens may be found behind, in some rare instance, and may be pushed forward; but it will sink directly on the patient's being placed on his back, and the extraction will become unadvisable, even if practicable.

I am ready to admit that a case may be met with, in which, after the artificial pupil has been made, by the intro-



duction of a knife behind the iris, the hardened lens may be pushed through it by the same instrument into the anterior chamber, and then extracted; but I have no hesitation in saying the instances must be very rare, and that the operation by extraction performed in this manner does not apply or succeed in one case in a hundred; and, therefore, should never be attempted, where the lens is presumed to be hard and firmly adherent.

If the solidity of the lens be inferred, extraction through an opening in the cornea and iris, or the coredialysis, are alone to be considered admissible. In the first method the operation for artificial pupil should be attempted anterior to the iris. The patient ought to be placed on his back, and an incision of one-third at least of the circumference of the cornea be made at the external edge of it, to allow of a ready entrance to the different instruments. The iris is next to be divided, and it may be done in several ways; by the introduction of the sharp blade of a pair of scissors through it and below the lens, so as to cut both at one stroke; the divided lens is then to be extracted by a hook, or a blunt-pointed knife may be introduced under the cornea, and its edge turned towards the iris, which is to be cut across by withdrawing it, and with as little derangement as possible to the parts beneath; the lens is then to be hooked and extracted. But one cut with the knife or one stroke of the scissors will not always be effectual, as in Professor Maunoir's case of the Marquis de Beaumanoir (vide *Medical and Chirurgical Transactions*, vol. vii, part 2d), in which a second and diverging cut was necessary to make a good pupil, and afford room to extract the lens.

The operations on the iris with the scissors of the Professors Maunoir and Scarpa are given in their own words from page 436 to 440, to which I refer. The points considered by them as fundamental in their methods are, first, that the internal parts of the eye, and especially the annulus gangliformis, are uninjured: secondly, that the opening in



the iris is made at a distance from the wound in the cornea, and the newly-formed pupil is therefore not liable to obstruction from any opacity which may arise in consequence of the wound in the cornea: thirdly, that the lens is removed by extraction, instead of being left an irritating substance, to be dissolved by the humours and ultimately absorbed. Against these advantages are opposed, the greater liability to inflammation from a large opening in the cornea, the difficulty of cutting the iris in a flaccid state, even with a pair of scissors, the possible escape of the vitreous humour; and to these have been added the difficulty of cutting a hardened lens with a pair of scissors. Professor Scarpa, in enforcing the use of the scissors, objects to that of the knife; Sir William Adams objects as strongly to the scissors; but I do not conceive that either views the question without prejudice, or confines his objections or arguments to the points of the greatest importance. The object of each seems to be, to prove that the operation he recommends is the best in all cases, without admitting that, in some instances, the operation of his opponent may be preferable; arguments and objections are then brought forward upon points to which they have not sufficient reference, and each operation is condemned generally, because it is not perfectly successful in cases to which it is not applicable, or in which the same objections may be urged against any other. Viewing the subject as I have endeavoured to do, and concluding that operations are to be adapted to eyes, and not eyes to operations, and attributing to each morbid state of eye that operation which appears most applicable to it, much of the difficulty will vanish.

Professor Scarpa, in his last work on the Diseases of the Eye, 1819, by Briggs, page 372, and in the 60th number of the Edinburgh Medical and Surgical Review, enumerates all his objections, as if they could occur in every case; whereas it will be seen from what I have already said on the subject, that they cannot possibly occur in many. There is one objection, however, advanced by Scarpa, which is a very fair



one: it is the difficulty and danger which he says Sir William Adams confesses to attend his operation, and the great dexterity and delicacy of hand, which he considers necessary to enable an oculist to perform it correctly. Scarpa then reasons naturally enough, that if these requisites be necessary in a greater degree than in any other kind of operation on the iris, those operations are preferable which require only the usual degree of both. It is not surprising then, that on every point connected with this operation he should magnify the danger and difficulties attending it.

To Scarpa's first objection, that the knife cannot be passed in front of the iris when it is convex, the answer is, that in such a case the operation is not applicable. As to the second, that the iris may separate at the ciliary ligament during the operation; we must acknowledge its correctness, although it seldom happens in a well-selected case, and advantage can even then be taken of it. With respect to the third, the difficulty experienced in dividing the iris "fibre after fibre," so as not to leave an irregular pupil, I refer to my observations on the different states of the iris, and the mode in which it is divided, page 492 et seq.

The fourth objection is a well-grounded one—the difficulty of disposing of a hard lens, even if the iris be cut, without a repetition of operations, which are always more dangerous behind the iris. The answer is simply, that in such a case, the operation by division through the sclerotica, although practicable, is by no means the most applicable.

Sir William Adams, page 91 of his last work on Artificial Pupil, acknowledges that Professor Maunoir's methods of operating with the scissors are highly ingenious; and he further adds, "I have no hesitation in offering a decided opinion, that they are superior to all other methods of forming an artificial pupil, by effecting an opening in the cornea, which had preceded them." He objects to them, however, for the following reasons (page 92 et seq.):—

"First: When the closure of the pupil results from the



operation for cataract, it frequently happens that the vitreous humour is so morbidly fluid, that the entire discharge of it would certainly ensue, were Professor Maunoir's method of making a double incision of the iris commonly practised.

"This diseased change of the vitreous humour has frequently occasioned its escape so abundantly through the puncture of the coats of the eye, by the side of my smallest-sized iris scalpel, as completely to occasion their collapse. Now, although this fluid will generally be reproduced, yet if atmospheric air be admitted into the posterior cavity of the eyeball, it will generally give rise to violent inflammation and suppuration, terminating in a total destruction of the organ.

"Every surgeon, at all conversant with ophthalmic surgery, must be aware, that these accidents are far more likely to occur when the cornea has been opened, and a large artificial pupil formed in the manner recommended by Professor Maunoir, than when the iris scalpel is employed in the manner I have described and recommended."

These objections do not rest on matter of opinion but of fact; and it then becomes a question, whether a greater loss of vitreous humour is sustained, in consequence of an opening through the cornea, than through the usual opening in the sclerotica, and whether air is admitted by one opening and not by the other?

As far as my observation has enabled me to form an opinion, I have no hesitation in saying it does not accord with that given by Sir William Adams.

In operating with the scissors, the patient is laid upon his back, the eyelids are separated, and after the cornea is opened, little or no pressure is required to be made on the eye; the scissors can be readily introduced beneath the flap of the cornea, and the first cut is made in the iris, before a drop of fluid vitreous humour escapes. If the opening in the cornea includes one-third of its circumference, which is the greatest extent of opening required, the flap is easily raised, no pressure is made on the sclerotica, and the vitreous



humour which escapes is not forced out by the pressure of the instrument, but by the action of the muscles of the eyeball, the effect of which is counteracted by the remaining two-thirds of attachment of the cornea, and by the recumbent position of the patient. When once the scissors are fairly introduced beneath the flap of the cornea, the eye becomes in general sufficiently steady to permit the operator to use them with effect, although some, and often considerable difficulty will occur, as in the other operation, from the flaccidity of the iris. But as there is no pressure directed backwards, the vitreous humour does not escape in such quantity as has been or might be supposed *à priori*. Sir William Adams distinctly admits, that by his operation the vitreous humour frequently escapes so abundantly through the puncture in the coats of the eye as completely to occasion their collapse; now, nothing more can possibly happen by the other method; and I assert without fear of contradiction by those who have performed the operation, that so much as is here described to have escaped, will never be lost through an opening in the cornea, the remaining part of the operation being confined to the division of the iris and crystalline lens; and as it is acknowledged that the loss of half the vitreous humour is not followed by unpleasant consequences, the objection, if correct, is, after all, of little weight; and I am satisfied, that, in most instances, the quantity lost will not be greater in one operation of this particular kind than in the other; and the objection is at least equally applicable to both operations.

In consequence of the loss of the vitreous humour, he conceives that atmospheric air will be admitted into the posterior cavity of the eyeball, and give rise to violent inflammation and suppuration, terminating in a total destruction of the organ. This occurrence he considers more likely to take place in Maunoir's operation than in his own, and advances it accordingly as an objection to the operation. Bëer, and the continental surgeons in general, are very much afraid of the ad-



mission of air into any of the cavities of the body; but in Great Britain surgeons do not dread it, provided the parietes of the cavity be in a natural and healthy state; and in regard to the eye it is manifest, that when an opening is made, so that the vitreous humour runs freely out and the coats of the eye collapse, there must either be a vacuum formed within the eye, or some atmospheric air must take the place of the humours; for the term collapse of the eye is only a figurative expression. I do not see that any other inference can be drawn; and as the state of collapse is the same in both cases, it may be fairly concluded that the state of eye in regard to the presence of atmospheric air is pretty much the same in both instances; but as the question admits of decision by matter of fact, it is unnecessary to refer to opinion; and as no other person will assert that the operations of Maunoir and Scarpa with the scissors, have been more frequently followed by suppuration than those which have been done by the knife, it is evident, that until this assertion be proved, neither of the objections are of any force. So far, indeed, from a dissolved state of the vitreous humour being likely to lead to suppuration of the eye, after an opening has been made in the cornea, it appears to me, that the reverse is nearer the truth, and that this accident is more likely to occur when the vitreous humour is sound; for we know, that operations for cataract are much more frequently followed by inflammation and suppuration, if a small portion of healthy vitreous humour be protruded, and in part retained between the edges of the incision, than if a greater quantity in a more fluid state be lost. In such cases, it is not the admission of air, which causes the mischief, but the propagation of ulcerative inflammation from the edges of the cornea, which ought to have united by the adhesive inflammation. The admission of air then, I consider as equal, in a surgical point of view, on both sides.

To the second objection, that, considering the permanency of the two kinds of pupils as equal, still the prefer-



ence is to be given to the shape, size, and situation of that made by the knife, I fully agree; and in a case where both operations may be performed, in other respects indifferently, I prefer, on this account, the operation with the knife.

The third objection is, that if the lens or capsule be very hard, indurated, or ossified, a delicate pair of scissors cannot divide them. "In this case," he says, "they must be extracted whole and entire, which will occasion not only a considerable degree of injury to the iris, by the separation of the adhesions existing between them, and by forcing the lens through the newly-formed pupil; but the cornea likewise will require to be opened full one half of its circumference, as in the common operation for extraction of the cataract, in order to admit of their free passage. Now it must be obvious, that the danger of a copious escape of the vitreous humour, even should it be in a healthy state, is here very great, while, if it be in any degree disorganized, its total discharge, and a consequent loss of the organ, is inevitable."

A reply to this objection can only be made by acknowledging, in the first instance, the difficulty in its fullest extent in an extreme case of this kind; and then by inquiring how the difficulty would be lessened by instituting in the place of the scissors, the knife; and to this inquiry no man of any experience will reply, otherwise than that the difficulty, instead of being lessened, is infinitely increased; and that, although the chance of success with the scissors be small, there is hardly a probability of it with the knife; and in some cases, as where the iris is convex, the knife cannot be used, whilst the scissors are yet applicable.

Supposing that the scissors are too weak to divide the lens, which is but a gratuitous supposition, never actually realized in practice, it is difficult to conceive what the knife can accomplish; indeed, it is utterly impossible that it can make any impression where the scissors have failed. Supposing, however, for the sake of argument, that the knife can be brought in front of the iris, it may make a mark



upon it; but where the indurated capsule and lens adhere so firmly as is presumed to be the case, it cannot separate them; admitting still, that, after great labour and repeated efforts, during which the dissolved vitreous humour runs out, the hardened and ossified lens and capsule are separated, what is to be done with them? are they to be left to roll about in the cavity of the eye? or, are they to be pushed through the newly-formed pupil, and extracted? If left to roll about, the eye must indisputably be lost, according to Sir William Adams's own doctrine, and according to fact, in such cases. As to partially detaching a hardened lens, it is out of the question; for, unless it be removed from the iris, the operation is unavailing, and will end in the destruction of the organ. A capsule may, perhaps, be depressed, and a shrunk lens may be superadded to it; but a hardened lens and indurated capsule, adhering in the manner described, cannot be so treated; and if they could, the irritation arising from them would prove destructive. As to extracting them, as Sir W. Adams recommends, it must be accomplished with less probability of success than if the cornea had been opened as the first step of the operation: indeed, the whole of the third objection to the use of the scissors applies to the use of the knife, and in a much stronger manner; for it is one operation superadded to another, and the patient has to encounter the dangers of both. The same injury must be sustained, from separating the adhesions to the iris, and forcing the lens through the newly-formed pupil; the same-sized incision must be made in the cornea, and the danger of the escape of the vitreous humour must be as great, unless it has already run out. In investigating closely the operations recommended by Scarpa and Sir W. Adams, and the arguments advanced on both sides, the only essential difference that I can perceive between them in a case of hardened or ossified lens and indurated capsule is, that by the double operation of Sir W. Adams, an additional wound is inflicted on one of the most delicate parts of the eye, and a greater



liability for inflammation and suppuration incurred, than if one operation alone had been attempted; and this without any evident advantage. I apprehend, then, that although the scissors be bad, the knife is a great deal worse; and that if an operation must be done by either, the scissors are infinitely to be preferred. In such cases the continental surgeons recommend the coredialysis, and I believe they are often correct in their recommendation.

If scissors be used in any case, the operator should always endeavour to make his pupil on that side of the centre of the eye which is opposed to his incision in the cornea. In using them, the salient angle at the joint, or the convex side of the scissors, should be upwards, the patient always being placed on his back. There is an inconvenience, however, to which scissors, as they are usually made, are liable, and that is, they bruise rather than cut: this Mr. Stodart has endeavoured to obviate by giving to each blade, at the suggestion of Dr. Wollaston, a lancet edge; so that they divide the part without bruising, and with great precision.

If the lens has been removed or absorbed, the closure of the pupil may be accompanied by an unusually thickened state of the capsule. If the capsule should adhere strongly to the iris, it will be cut with it, as I have already mentioned, and its edges must be pushed asunder, and any portion of the capsule, which may be detached, carried forward into the anterior chamber. If the capsule be less firmly adherent, it must be detached and brought forwards, or separated from above and depressed below the lower edge of the pupil, where it will generally remain; or if it float a little at first, it will soon shrink and disappear from the axis of vision.

If the capsule be but slightly attached to the iris, and still thin although opaque, it will be sufficient to lacerate it in every direction, opposite to the artificial pupil, and the remnants will in like manner disappear.

If the capsule, on the contrary, remains in its natural situation, and is much thickened, an attempt to lacerate it



will not succeed; if it be detached from above, after much trouble, it will not remain depressed. It is then in that state which has been called *cataracta arida siliquosa*; for the diagnostic symptoms of which see page 251, and for the method of removing it page 364 et seq.

Lastly. After the operation for cataract has been performed by extraction, the edge of the pupil sometimes adheres to the inner edge of the incision, without any portion of the iris having been protruded; the natural pupil is, in such a case, reduced in size to nearly a small pin's head; and if any opaque capsule remain behind, vision is almost entirely prevented. In some instances of this kind, the pupil, although almost closed, is still dilated by the application of the belladonna, at every point save the one at which it is attached, and nearly in the same manner as it would be if no such attachment had taken place. In one case which came under my observation, I presumed, that if inflammation could be induced in the iris when the pupil was in a semi-dilated state, the consequent effusion of lymph in its cellular structure would agglutinate the fibres one to another, whilst under the influence of the belladonna; and on this effect ceasing, a permanently enlarged pupil would remain. In this presumption there was nothing new; for, if the belladonna be applied in a case of inflammation of the iris, before the inflammatory action be sufficiently subdued, this permanently dilated state of the pupil may be constantly expected; and if its application be, on the other hand, too long delayed, a permanently contracted state of the pupil will be the correspondent result; of which facts I have had instances in the person of a young man, in whose right eye the pupil is permanently dilated, whilst in the left it is contracted; the reason I have stated; and as he was treated for this disease by a very able practitioner, there can be no suspicion of want of ability in his previous management. In the case in question, I could not effect artificially what is not easily prevented from happening naturally; for, although I lacerated the capsule,



and then punctured the iris in four different and opposing points, whilst in a dilated state, and although I repeated it twice, I could not make it inflame; and the man received so much benefit from the partial removal of the capsule, that he would not let me repeat that, or the common operation of division, which would certainly have succeeded.

#### GENERAL TREATMENT AFTER THE OPERATION.

The treatment after an operation on the iris is of as much importance as the operation itself, and is twofold; to prevent inflammation, and to subdue it, if it should occur. If inflammation be allowed to take place, or cannot be prevented, a failure may be expected, and the eye left, in all probability, in a worse state than it was previously to the performance of the operation. As far as my observation has carried me, or as I have been able to obtain information, sufficient attention is not paid to prevention in the first instance, any more than after the different operations for cataract; and inflammation is allowed to establish itself before means are employed for its prevention: an error of very great magnitude, which should be carefully avoided.

According to the principles which have been laid down, the eye ought not only to be in a sound state, exclusive of the closure of the pupil, but the constitution of the patient should be good, and his general habit healthy, before an operation should be attempted. In a case of this description, inflammation may or may not supervene, from the injury inflicted on the iris; but it is to be expected as the natural result of a wound in the human body, and therefore to be guarded against; for, if it should take place, the artificial pupil may be obliterated, by a closing of the divided fibres of the iris, or filled up by the effusion of lymph; whilst the power of vision may be destroyed by the extension of inflammation to the more internal parts. According to the view entertained at present of the human frame, in health, and labouring under disease, surgeons are not disposed to resort to violent mea-



sures, such as great depletion, purging, or starving, by way of preparation, but merely remove any obstruction, or forbid any irregularity of conduct, which might prove prejudicial if inflammation should occur. The patient is then only placed on low diet, the bowels gently opened, and he is removed from all the exciting causes of irritation for a few days previous to the operation. Blood-letting was formerly resorted to, with a view of reducing the powers of the system, and consequently of preventing inflammation; but the quantity abstracted was seldom more than a few ounces, and was, in my opinion, rather detrimental than beneficial, exciting rather than allaying any disposition to irritation, by creating a greater degree of anxiety in the mind of the patient, without having any decided effect on the sanguiferous system. Instead of drawing blood before the operation (except in plethoric persons), the surgeon should abstract it afterwards, in a sufficient quantity to have a marked effect on the action of the heart and arteries; and if it can be done at the moment when the local irritation is about to affect the general system, the advantage of it will be considerably greater. As a general rule then, yet admitting of particular exceptions, according to the judgment of the surgeon, founded on his knowledge of the human body in health and under disease, the patient should be bled largely after any of the operations for the formation of an artificial pupil; and the quantity ought to be regulated by the constitution of the patient, his disposition to inflammatory action, or the appearance of any of the symptoms of inflammation. After all the different operations, the patient feels that something has been done to the eye, although the actual pain, on many occasions, is but trifling, and soon subsides, leaving the eye easy, or with some sensation of stiffness; in others the pain continues more or less acute, does not subside, but gradually gives rise to other concomitants of inflammation of the eye, such as heat, swelling, and increased secretion of hot tears, with an addition of pain not confined to the eye, but extending to the brow and side of the head, de-



monstrating the presence, and the rapid increase of inflammation.

The pain, in some instances, is severe during the operation, in others trifling; and it is in general desirable to ascertain whether this will increase or diminish, before recourse is had to the great remedy, bleeding, in order that the quantity to be abstracted may be regulated according to the idea entertained of the state of the constitution. I usually, therefore, wait from three to six hours (unless the pain increase), before I direct blood to be taken away; which is then done in almost every case, whether for the sake of precaution or necessity, to the amount of fourteen ounces; in some instances, to twenty-four, or from that to thirty ounces. If it be simply by way of precaution, a vein may be opened in the arm; and if from necessity, from the arm and temporal artery at the same time, or nearly so, in order to produce, with as little delay as possible, a decided effect on the sanguiferous system, and especially on the eye. The first bleeding, when a precautionary one, may be moderate; when a necessary measure, it ought to be effectual; and if syncope be occasioned by the loss of blood, and not by the alarm of the patient, it is so much the better. The pain will not always immediately subside, although it may be diminished, and will, in a short space of time, almost entirely disappear, proving the efficacy of the means adopted. But if the diminution of the pain is only temporary, and after a few hours begins to increase, recourse must again be had to bleeding, regulated according to the patient's constitution; and if this should not be sufficient to arrest the progress of the disease, it must be immediately treated as a case of iritis, and mercury administered in such a manner as to affect the system as rapidly as possible. If, however, the abstraction of blood has been judiciously directed, recourse to this unpleasant remedy will seldom be necessary; but where, unfortunately, the loss of blood is not capable of putting a stop to the inflammation, then the medicine should be administered in doses of two or three grains of the



sub-muriate of mercury, combined with one of the pulv. antimonialis, and a quarter of a grain of extr. opii, every three or four hours, until the mouth becomes sore, or the disease is arrested. A solution of opium, combined or not with mercurial ointment, ought to be used externally. The eye should be kept dry and warm, and the belladonna only applied when the inflammation is subsiding.

On the utility of mercury, in cases of idiopathic or symptomatic iritis, so much has been written, that it is unnecessary here to add to it\*; but the great utility of mercury in inflammation of the iris, resulting from wounds, has not, I believe, been either noticed by authors or generally understood. It is not, however, more valuable in one case than in the other; and the use of it should never be neglected, when bleeding is insufficient for the suppression of the inflammation, which will, in all probability, prove destructive to vision.

Local blood-letting, by means of leeches, is not of so much value, in active inflammation of the iris, as is supposed; because the blood drawn relieves the vessels affected but in a very slight degree, and has no effect on the system at large, unless it be carried to excess, when it is more troublesome, and, in that case, more detrimental to the system than general blood-letting. By opening the temporal artery, I consider that I am relieving locally as well as generally, and therefore this method of abstracting blood is usually to be preferred. Cupping on the temple will often relieve symptoms of a less urgent nature, and prove more advantageous in the less active forms of the disease.

During the first period in which we are endeavouring to prevent or reduce inflammation, recourse may be had with great effect to the antimonium tartarizatum, in nauseating doses: one drachm of the liq. antimon. tartar., or 1-8th, or

\* See especially Saunders on the Diseases of the Eye, edited by Dr. Farre, and Mr. Travers's Essay on Iritis, in Cooper's and Travers's Surgical Essays, part 1st.



1-4th of a grain of the powder, may be given every hour, according to the susceptibility of the patient, so as to cause considerable nausea, or even, at first, a slight vomiting, when the dose must be diminished; for, as to excessive vomiting being serviceable in active inflammation of the internal or more important parts of the eye, or even the ophthalmia improperly called Egyptian, it is, to say the least of it, an error. It has done harm in every fair case in which it has been tried; and the surgeon who wastes that time, so precious to his patient, in the use of means so totally inadequate to effect a cure, will have reason to regret his deviation from the beaten paths of sound medical science.

After the great inflammatory symptoms have subsided, leaving, however, a considerable degree of irritation, blistering on the nape of the neck, and the other usual means recommended in cases of inflammation of the iris, will be found of great service.

In directing blood-letting as a general remedy in all cases of operation, in which the constitution of the patient does not forbid it, I have been also very much actuated by the circumstance of inflammation sometimes running even to supuration of the internal parts of the eye, without causing so much pain as to attract particular attention. Richter gives an instance of this kind, and I have also seen four of the same nature, rendering it then absolutely necessary not to trust to the non-appearance of symptoms, especially in those cases where precautionary depletion cannot with propriety be resorted to; but to examine the eye from the first day of the operation, and carefully mark any appearances on the conjunctiva, particularly those indicative of chemosis. If inflammation be present, we acquire, in the certainty of it, a knowledge of the greatest importance; and if it be absent, the gentle raising of the lid, in a moderate light, sufficient to enable us to ascertain the fact, can never do any mischief.

I am the more particular on this point, because the fact is



not generally known, and is therefore frequently overlooked by those who consider pain as the essential sign of inflammation.

If the cornea should have been opened, and some degree of opacity ensue, a solution of the *argentum nitratum*, beginning in the proportion of four grains to the ounce of distilled water, and increasing it to eight grains, will be found, as well as the other applications usual in such circumstances, of essential service in removing it.

If the patient should, some days after the operation, suffer from an attack of erysipelatous, rheumatic, unhealthy, or other inflammation of the eye or iris, it must be treated as an idiopathic or symptomatic case of the same nature, occurring independently of the operation.

During the first days of the treatment, the patient should be confined to bed, the eyes lightly covered, so as to exclude the light, and the diet be strictly antiphlogistic; but as soon as all danger of inflammation is past, the eye may be gradually accustomed to the light, the shade left off, and the patient allowed to return to his usual habits.

If the iris has become more vascular than usual, a greater or less quantity of blood may be effused, especially in the operations by excision or separation, which will in general be absorbed; but if it be in greater quantity, puncturing the cornea, and evacuating it and the aqueous humour, will rapidly tend to remove it. In a complicated operation, such an occurrence may prevent its completion.

The power of vision, resulting from the different operations, must of course vary exceedingly, both as regarding the state of the eye and the particular method of operating. After division of the iris, the patient must wear a cataract glass, on account of the lens having been removed. After excision, this is not always necessary, and the patient recovers good sight without it; although, in the first instance, a convex glass will be useful, and where the pupil is made towards the margin of the iris will be absolutely necessary, until the re-



tina has become accustomed to the unusual stimulus of light. The same thing occurs after the operation by separation from the ciliary ligament; but, in many cases, the retina will be found nearly insensible in the first instance, and only slowly recover itself. In one case, in which I operated after the patient had been twenty-four years blind, he saw immediately after light was admitted to the retina, and wrote me a letter a very few days afterwards. In another case, after twenty years of blindness, the patient has recovered so as to walk about with ease, but he can only just discover the large letters of a printed book. In some instances, the first admission of light gives pain, whilst in others it excites only pleasing and joyful sensations.

#### SECOND CLASS.

*Those morbid states of the eye which depend on derangement of the structure of the cornea; the anterior chamber being nearly or quite natural in its dimensions: the iris, the crystalline lens, and its capsule, being healthy.*

SECTION a.—*Those cases in which the cornea is rendered partially opaque (leucoma), in consequence of ulceration, operation, or other cause, preventing the transmission of light, or impeding it so much as to render vision indistinct; but in which the anterior chamber, the lens, and its capsule, remain unimpaired.*

The nature of the case is explained in the description already given; it is a derangement of the cornea alone, the consequence of ulceration or cicatrization, in almost every instance; although it occasionally occurs from a deposition of lymph between the laminae of the cornea, which has become organized; the opacity not admitting of removal in either instance, and occupying so much of the centre of the cornea as to prevent the passage of the rays of light to the retina, rendering vision exceedingly defective, and for the most part useless, the patient only seeing in an imperfect manner side-



ways, and generally receiving considerable benefit from the application of the belladonna, so much so, as, in some instances, to induce the sufferers to decline any operation.

This is the most favourable case for the operation of excision, and in no instance should any other operation be attempted. The principle of it is to make an opening in the cornea, through which the iris may immediately protrude, and be readily cut off, which may be effected with almost a perfect certainty of success, by attending to the following directions.

The patient is to be placed on his back, and the eyelids secured by the fingers of an assistant; an opening is then to be made in the most favourable part of the cornea, with a cataract knife, or other sharp instrument, immediately before the junction of the cornea and sclerotica, and at a sufficient distance from the iris, which is to be carefully avoided. This opening ought to be nearly three lines in extent, and made with a rip, so that the aqueous humour may be suddenly evacuated and bring a portion of the iris with it, which it will almost invariably do. This portion is to be seized by the forceps, and cut off by the scissors, when the operation is completed.

In making the opening in the cornea, I generally attempt a complete punctuation by not using too broad a knife, by which I avoid accident from the point of the instrument, and prevent the escape of the aqueous humour, but with a sudden gush; but I by no means consider it as actually necessary, for the knife may be introduced by a steady hand, and made to cut a sufficient portion of the cornea in the same manner, or with a rip, without making the punctuation.

Mr. Gibson\* says, "All pressure is now to be removed from the eyeball, and the cornea knife gently withdrawn. The consequence of this is, that a portion of the aqueous humour escapes, and the iris falls into contact with the opening in the cornea, and closes it like a valve. A slight pressure

\* Gibson on Artificial Pupil, page 40.



must now be made upon the superior and nasal part of the eyeball, with the fore and middle fingers of the left hand, till at length, by an occasional and gentle increase of the pressure, or by varying its direction, the iris gradually protrudes so as to present a bag, of the size of a large pin's head."

Sir W. Adams\* says, "On withdrawing the point of the knife, the aqueous humour escapes, and the iris and cornea come into contact with each other. If the iris does not spontaneously protrude, which it usually does, the assistant should make a slight degree of pressure upon the eyeball, for the purpose of occasioning it to do so."

By making the opening in the cornea, in the manner I have recommended, the iris will almost invariably protrude, and without the slightest danger, and nearly in a sufficient quantity for excision, unless it have some internal attachment. If the iris should not protrude, pressure must be made as directed by Mr. Gibson, with gentleness and caution (lest the capsule of the lens be ruptured, or the lens displaced), until the iris appears between the edges of the opening in the cornea, when it is to be seized by the blunt round-ended forceps, and drawn out with equal care, until a sufficient quantity be protruded, so that the edge of the natural pupil may be included in the incision. This, however, can seldom be judged of, but from the size of the portion of the iris which is protruded; for, the cornea being flaccid and in part opaque, and the iris irregular from the protrusion, the edge of the pupil cannot always be distinguished, especially if it happen to be just at the edge of the incision: and time would be badly spent in making search for it; for, if the protruded part be of the size of a large pin's head, the edge of the natural pupil is almost to a certainty included, and to some extent.

In every case of this kind where the iris is free, it may be made to protrude by the measures directed; but where the

\* Sir W. Adams on Artificial Pupil, page 44.



iris is attached, it may be necessary to use the forceps, or hook, or resort to the methods recommended in the different sections in the third class.

In his last publication, Sir W. Adams claims the merit of an improvement, for directing the edge of the natural pupil to be always removed, and attributes to Mr. Gibson's operation the defect of "causing the patient to have two small pupils: namely, the remaining portion of the natural pupil and that which has been newly formed." At page 90, he makes a reference to Mr. Gibson's work, which he thinks demonstrative in his favour; but he has not quoted the whole passage, which is as follows, page 40.

"It sometimes happens that the whole breadth of the iris, to the border of the natural pupil, is protruded, and removed in this way. This I consider as rather an advantage, because it ensures a large pupil, though generally one which is oblong in its shape. I have found, however, the mere circumstance of shape to be of little consequence in this operation; and always to be sacrificed to the object of size. It may also be remarked, that the opening has no disposition to close, when, in forming the artificial pupil, the border of the natural pupil is divided.

"It occasionally happens, also, that as soon as the knife is removed, the muscles of the eyeball act with violence, and project a small staphyloma, or bag of the iris, through the incision. If this bag be not large enough to form the new pupil, the iris must be further protruded by gentle pressure."

At page 47 he says, "The permanency of the artificial pupil appears to me to depend principally upon the size of the opening, and healthy state of the iris and contiguous parts of the eye, at the time of the operation. When the artificial pupil has been made almost as large as the medium size of the natural one, and especially when the part of the iris removed has included its border, I have never seen any disposition in the opening to close. When, however, a more narrow slip has been removed; when the iris, from previous inflammation,



has become more vascular than natural, or when it is complicated with adhesion to the capsule of the crystalline lens; in such cases, its closure has occasionally taken place."

In the case of Captain F., page 61, in which the iris was adherent, so far from being content with a small pupil, he says, "A degree of pressure was then made, in the manner already described; but only a small bag of the iris could be protruded, which was cut off with the curved scissors. The hook was next introduced, flat and with its point downwards, until it laid hold of the inner rim of the iris, which was gently drawn out in sufficient quantity to be cut off with the curved scissors. The new aperture, thus formed in the iris, was irregular in shape, but formed an excellent artificial pupil."

I consider it demonstrated from these passages, and particularly the last, that Mr. Gibson wished the edge of the natural pupil to be removed, whenever it could be safely accomplished, in the opinion of the operator: he did not recommend it always to be done, because he knew it could not always be effected, when it was not free; and so far from the principle of his operation tending to the formation of two pupils, I have no hesitation in saying, that, in my opinion, it is precisely the reverse. I admit, that, in certain instances, two pupils may be formed; and that in some of Mr. Gibson's cases two pupils were formed; but this occurred from the inner edge of the iris being strongly adherent; and consequently not capable of being protruded either by pressure, the hook, or the forceps. The error was not so much in the mode of doing the operation, as in adopting it in a case to which another was more applicable. The fault is not then in the operation, but the operator. Mr. Gibson stands precisely in the same situation as Mr. Cheselden. They both invented or practised operations highly successful in certain cases, but which, when resorted to indiscriminately, were found frequently to fail, and were either undervalued or hastily abandoned.

It is not even just to attribute the merit of this operation



to Mr. Gibson; for although I firmly believe he was not acquainted with Professor Bëer's mode of operating, there cannot be a doubt that Bëer opened the cornea, drew out the inner edge of the iris with a hook, and cut it off with scissors, whilst Mr. Gibson was a student. Still the operation was made known to us in this country by Mr. Gibson; and he used both the hook and forceps; the latter being made with a spring and handle. Professor Walther, late of Landshut, did also, in 1815, inculcate the same doctrines.

The only addition made to the operation, since the time of Mr. Gibson, is that of using a pair of common round-pointed forceps, with a handle attached to them, for drawing out the iris, instead of the spring forceps, or hook, which he recommended; and the operation performed in the manner directed is the safest, whilst it is, at the same time, the most simple that can be done on the eye, for the attainment of so important an object as the formation of an artificial pupil.

#### THIRD CLASS.

*Those morbid states of the eye which depend on any combination of the two preceding states of disease, or with a diminution of the anterior chamber of the aqueous humour.*

SECTION a.—*A slight attachment of the iris, drawing the natural pupil to one side, with diminution of its size, the lens and capsule being transparent, the cornea opaque at the point of attachment.*

SECTION b.—*The same, with opacity of the lens and capsule.*

These varieties of disease are the result of inflammation, which has terminated in ulceration or sloughing of the cornea, but principally the former; and occurs, for the most part, in the more acute or chronic forms of disease; the ulceration, which gives rise to either, being of the acute kind; and when occurring in a chronic case, is in general the consequence of its becoming changed, through the application of some irritating cause, which gives to the inflammation an activity it did



not before possess, and which the powers of the part are unable to sustain. The appearance or nature of the ulceration seems to depend much upon the activity of the inflammation, and the relative power of the part; which also regulate, in an equal degree, the healing process; and the nature of the ulceration frequently determines that of the derangement of the iris.

Independently of other peculiarities, I have been able to observe three leading points of distinction in ulceration of the cornea, as connected with attachment of the iris to the cornea.

Where the ulceration proceeds deep into the substance of the cornea (however it may originate), bearing the true characters of an active ulcer in other parts, and filling up by the deposition of lymph and cicatrization of the part, leaving an indelible opacity or scar.

Where the ulceration possesses a certain degree of activity; but instead of penetrating, like the former, in a hollow cup-like manner, spreads more extensively, removing only one or two of the outer laminae of the cornea; and healing with a slight muddiness of the part, through which the colour of the iris is perceptible. In the circumference of the cornea, this kind of ulceration, after the activity of acute inflammation has been subdued, often assumes, at a late period, the form of a groove; the discharge being frequently ichorous.

A chronic kind of ulceration, sometimes beginning acutely, in which the superficies of the cornea seems to be sliced smoothly off, giving to that part the appearance of a gem which has been cut by the artist; which cut surface frequently remains for months unaltered, impairing vision from the different refraction of light, but not on healing becoming opaque: in young persons sometimes, indeed frequently, regaining the natural level of the cornea, without causing any opacity.

The morbid state of the iris in question is one frequent result of the two first kinds of inflammation, seldom or never of the third. In children and young persons of a strumous habit, inflammation of the membrane lining the inner surface



of the cornea, said to be reflected over the iris in a more attenuated state, frequently gives rise to the appearance of a lardaceous ulcer on the cornea; in the same manner, I conceive, as irritation of the urethra, or of the rectum, induces abscess in perinæo, or by the side of the gut, constituting fistula in ano, without any continuity of ulceration, until after the external part has yielded, and the ulcerative process has extended inwards. This ulcer does not commonly penetrate the cornea, even if neglected, but fills up in some cases by the deposition of lymph; in others by leaving an opaque flat surface; it may, however, penetrate through all the lamina of the cornea, as far as the inner membrane, which protrudes through the opening, giving rise to what is termed a protrusion, or hernia of the membrane of the aqueous humour, or ceratocele. This protrusion may, in general, by proper treatment, be forced to recede without bursting; it occasionally, however, yields, the aqueous humour is evacuated, and the iris more or less drawn into the opening. If the case be very successfully treated, the iris will appear (after the ulcer has in part filled up, and the anterior chamber been re-established) to point towards the ulcer, as if attached by a thread, which pointing or elevation of the iris will slowly recede to its natural state without leaving any irregularity. But, if the ulcer should have made further progress, the iris will adhere to the cornea at that part, in a greater or less degree; and the pupil be distorted, as well as considerably diminished in size, although the lens may remain uninjured.

In adults this alteration of structure is principally caused by ulceration, the consequence of active and violent inflammation; whether idiopathic, purulent (ophthalmo-blenorrhœa of continental authors), or gonorrhœal; and is generally preceded by the formation of an interstitial abscess, or by sloughing of the cornea. It is not often observed as a consequence of rheumatic inflammation, where the pustule preceding the ulceration more commonly contains at first an ichorous fluid, and the ulceration is superficial.



An interstitial abscess, or the formation of matter between the layers of the cornea, is the most formidable disease affecting that part, and has been hitherto the least understood. Nature, in depositing matter, seems to be conscious of her own incapability to remove it by absorption, and therefore endeavours to provide an exit for it by ulceration. This action, if it were set up only on the external surface of the cornea, would be competent to the object intended; but, unfortunately, the same disposition seems to take place on the inner membrane, only with less activity. The whole cornea loses somewhat of the brilliancy of its appearance, and is surrounded by a zone of red vessels, whilst the conjunctiva is sometimes highly inflamed. The matter deposited forms a yellowish spot in the cornea, the surface of which appears abraded, indicating the commencement of ulceration. The iris at this period has undergone a slight change of colour, the pupil is contracted in size, and a yellowish line will be perceived at the lower part of the anterior chamber of the aqueous humour, caused by some tenacious matter, which has fallen down from the inside of the cornea, opposite the interstitial deposition, at which part ulceration has also commenced. As the disease advances the pain becomes greater, not only affecting the eye, but the forehead towards the nose, and the temple; the interstitial deposition is augmented, with enlargement of the opacity of the cornea; the ulceration of which is increased, the quantity of matter in the anterior chamber becomes greater; lymph is deposited in the contracted pupil and on the surface of the iris. The patient either sees very indistinctly, or vision is lost. Under these circumstances the ulceration penetrates the cornea; the contents of the aqueous humour are evacuated through a considerable opening, into which the iris falls, and from which it is protruded. The evacuation of the contents of the anterior chamber gives a temporary relief, but the pain soon returns from the irritation on the surface of the ulcer and of the protruded iris; the prolapse of which is gradually increased until the pupil is



implicated in it, or the ulceration or sloughing of the cornea has left the iris completely exposed; in which case the eye is lost. In the previous state, an operation for the formation of an artificial pupil may, perhaps, be subsequently attempted.

Baffled in almost every case I had treated by the methods usually recommended, I had recourse to the consideration of those principles by which the practice of surgery is regulated in other cases; which indicated to me the propriety of assisting nature in the evacuation of the interstitial deposit, rather than allow her to effect it by ulceration and the destruction of the part; I therefore opened the substance of the cornea, as far as the abscess, so as to allow the matter to be discharged, which frequently took place with evident good effect. The surface thus exposed did not, however, in general, heal in the manner of a common abscess, but became irritable, and the ulcerative action not only continued, but increased until it implicated the whole of the cornea. To this surface I applied the *argentum nitratum* with the best effect; it destroyed the irritable part, relieved the pain, and, contrary to the opinions entertained by British physiologists, caused a diminution to take place in the inflammatory action, which seems, in these cases, to be very little affected by the abstraction of blood, unless accompanied by the local treatment described, when it becomes an efficient remedy. Bleeding, the opening of the abscess, the application of the caustic, have, however, little influence on the inflammation which has extended to the iris; for which, if it be severe, mercury will be very beneficial, with the subsequent employment of the *belladonna*. I have not found the *cinchona* of use until after the disease had been subdued. The opening of the cornea and the evacuation of the aqueous humour are of no service, inasmuch as they have no influence on the disease which is going on into the cornea, whilst it often is the cause of ulceration taking place at the part where the puncture has been made. When a small cup-like ulcer is formed on the surface, and appears disposed to penetrate the cornea, the *argentum*



nitratum cut in the shape of a fine pencil, so as to fill up the ulcer by a momentary application, as Scarpa has recommended, will be found the most efficient remedy hitherto devised\*.

When protrusion of the iris has taken place, the ulcer must not only be healed, but the original disease cured, before an operation to relieve the iris can be thought of, and the nature of it must be regulated by the extent of the leucoma of the cornea, the attachment of the iris, and the dilatation of the pupil, as well as by the state of the lens and its capsule, which may have become opaque from continuity of inflammation.

When the iris is attached only by a point, and vision considerably impaired, the lens remaining transparent; a small cataract knife should be entered at the external edge of the cornea, and carried across the anterior chamber to the spot where the iris adheres, in order to cut it across by a gentle motion of the knife forwards, if the case will admit of it, so that the aqueous humour may not be evacuated until its division be completed, when the knife is to be quickly withdrawn. The pupil, relieved from the restraint under which it laboured, will now be dilated by a slight application of the belladonna, the aqueous humour will be replaced in two or three hours, and the small portion of the iris remaining attached to the cornea, will gradually disappear. If this separation of the attachment of the iris to the cornea should not be found effectual, a larger opening must be made in the cornea, a pair of scissors blunt at both points introduced, and the edge of the natural pupil divided towards the nose, so as to enlarge it sufficiently for the purposes of vision, the operator

\* The importance of the subject has caused this digression. The efficacy of the practice, an outline of which only is given, will, I am sure, live in the recollection of all those students who have attended the practice of the Infirmary for the last year, during which period several cases of this nature have been in attendance, as remarkable for the extent of disease, as for the success which has attended their treatment.



being particularly careful not to injure the capsule of the lens; or if there be an opacity of the cornea at that part, the outer edge of the iris must be drawn out with a blunt hook, and a part cut off. In most cases, however, where the pupil cannot dilate, on the removal of the attachment, the inflammation which caused the deposition of lymph in its structure, so as to prevent its natural motions, will, in all probability, have extended to the capsule of the lens, when the operation by division must be resorted to, as in section *a* of the first class; but then the attachment to the cornea should not be divided, in the first instance, as it will facilitate the division of the iris, from the resistance it offers to the knife.

SECTION *c.* — *When the iris is convex, but not adhering to a transparent cornea, the pupil nearly closed, the pupillary edge of the iris firmly adherent, the anterior chamber considerably diminished or nearly destroyed.*

This state of eye is not very common, because it depends, or seems to depend, on causes which are not usually present; and of these, in an especial manner, on a perfect closure of the pupil, either by its contraction, or the addition of some substance which completely closes up the communication between the anterior and posterior chambers of the aqueous humour.

The aqueous humour being poured into the posterior chamber, necessarily passes through the pupil to get into the anterior chamber; and a constant change is going on from the motion of the iris, which is perpetually moving in it whilst we are awake, and the eye is exposed to the light. When the pupil becomes closed from inflammation, the communication may be altogether cut off, or a sufficient opening may be left to allow of the passage of this aqueous fluid, although not very discernible by the eye. In the first case the iris becomes convex, from the aqueous humour collecting behind it and pressing it against the cornea. In the second, it retains



its situation, in consequence of the communication keeping up sufficient pressure on both sides of this membrane.

This explanation does not, however, account for the commencing convexity of the iris, which can often be observed when the pupil is certainly not closed, and where the posterior pressure cannot be supposed to exist; and in other instances the pupil appears to be so thoroughly closed by an adherent opaque lens, that it can hardly be supposed to be pervious even to water, yet the iris preserves its natural position, and the anterior chamber contains the usual proportion of fluid. If, on the other hand, the aqueous humour be supposed to be secreted by the membrane lining the cornea, the difficulties are not diminished, for it is necessary to account for the non-secretion of the fluid. If the cornea be punctured and the aqueous humour evacuated, the contents of the eye are pressed forward by the recti muscles, the iris becomes convex, and lies against the inner surface of the cornea, but the secretion of the aqueous humour goes on, and in less than three hours the anterior chamber will again be full. Let this operation be performed from the sclerotica, either in the attempts to make an artificial pupil or to cut up a cataract, the lens in both instances being loosened in its capsule so as to press on the iris, the result of almost any number of hours will be different. The iris will become convex, as in the former instance, yet no more fluid will appear in the anterior chamber; the iris will not fall back, but remain convex. The difference is dependent on the state of the lens; if it be hard, its pressure on the iris will cause it to inflame, and the cornea to slough at its circumference. Should it be very soft, it may remain and be slowly dissolved, with only a moderate degree of inconvenience. If the operator should be so unfortunate as to meet with a hard lens, in a case of this kind, he must re-introduce a needle and depress it; there is no alternative. But why is not the aqueous humour secreted, as in the former case, during the first three hours in which no inflammation takes place?



When the lens has been cut up, this does not occur, neither does it if the iris be divided and the lens remains in situ.

Be the cause what it may, practical observation has taught us, that if an opening be made in the iris, so as to re-establish the communication between the two chambers, the iris will in general fall back to nearly its natural situation, provided the posterior chamber has not been destroyed by inflammation, in which case the eye will frequently be so much disorganized as to be useless. The operative process for the relief of this kind of derangement may be of three kinds: first, by depressing or cutting up the lens, and making an artificial pupil; or, secondly, by opening the cornea, making an artificial pupil and removing the lens; thirdly, by the co-redialysis. Himly is the inventor of the first; Demours of the second, supported by Maunoir and Scarpa; the later German authors, of the third.

The two first methods of operating in the pure case described, in which the cornea is transparent, are both good; the first making, however, a central pupil, the other a lateral one. The first should be particularly regulated by the appearance of the iris, and the cause of the closure of the pupil. If the lens be supposed to be hard and strongly adherent, it is liable to accident in the detachment and removal, causing inflammation, and possibly suppuration or amaurosis; independently of a second operation being always required to enlarge the pupil. In such a case, I conceive the second or third methods the more eligible. If, on the contrary, the patient be young, the iris healthy, the pupil of a line in diameter, and the lens in all probability soft, and attached through inflammation of no distant occurrence, the first or Himlyan method should be had recourse to. The needle, sharp at both edges for a short distance, is to be entered as for the depression of the cataract, and insinuated between it and the iris, and in this manner the lens is to be detached; or, if too adherent, the point of the needle must be passed at the external side between it and the iris, so as to open a chan-



nel of communication; and, if possible, a part of the texture of the lens is to be broken up; this will, in cases which have been properly chosen, be generally accomplished, although with more or less difficulty, and some of the separated portions be absorbed, so that by a second operation the pupil may be opened a little more. The iris, in these cases, is not very sensible, unless the disease has occurred from specific or unhealthy inflammation, and the subsequent symptoms are not very acute. If by these operations the iris has resumed more or less of its natural appearance, although the pupil has not been sufficiently re-established, the opening may be enlarged by the usual operation by division, as in other cases of the same kind, the principal complication having been removed.

When the second method is adopted, the operation practised by Demours, page 433, may be tried, if the lens is supposed, from the appearance of the iris, to be small; or if an opening made in this manner does not seem likely to be sufficient, the more serious operation of Maunoir and Scarpa should be attempted, and there will be much less difficulty met with than might have been expected, in passing the blunt-pointed blade of the scissors between the iris and cornea, provided the external opening has been made sufficiently large.

SECTION d.—*The state last described (c) combined with opacity of the cornea and attachment of the iris, including the natural pupil.*

In the former section the operator had a choice of three operations, all of which, in many cases, were applicable to the state of derangement, although, in several, one or other of them might be found more eligible. The attachment of the central part of the iris to the cornea, and the probable opacity of the cornea at that part, as in the present instance, makes an essential difference in the state of derangement, and in the method of operating. The operation usually recom-



mended is that of excision (corectomia), but it does not appear to me to be always the most applicable. The central division of the iris by the knife would be of course useless, if practicable, and the operation by the scissors is not likely to be much more successful. It is a case, in my opinion, peculiarly adapted for the operation of separation at the ciliary ligament, for a pupil may be made opposite the transparent part of the cornea, as large as it will permit to be useful, and the incision being made in or near the opaque part, will add nothing to the opacity or deformity. Mr. Gibson has noticed this state of eye, in recommending his third method of operating by excision, which consists in opening the cornea, and separating or cutting across the adhesions of the iris to the cornea with the knife, at the same time the incision is made in the cornea, and then drawing out the iris, a portion of which is to be cut off with a pair of scissors. He says, page 66, "The point of the cornea knife is to be passed through the cornea in the usual way, and is to be directed to those adhesions, the division of which will most effectually tend to render the iris free, for the subsequent part of the operation. Care must, at the same time, be taken to avoid undue pressure upon the eyeball, that the aqueous humour may not escape before that object is accomplished; for otherwise the cornea and the adherent iris will become flaccid, and the adhesions be much more difficult to separate."

"Having separated some part of the iris from its connection with the cornea, and consequently made an aperture in it, the next step will be to remove a portion of it, in a convenient situation. If the iris appear sufficiently loose, the hook may be first introduced through the puncture in the cornea, and a gentle attempt be made to draw out a sufficient portion from the eye, to be cut off with the curved scissors. If this be found impracticable, the iris must be removed, within the eye, by means of the iris scissors."

"In using these small scissors, they are to be introduced shut and flat through the aperture in the cornea; and



at the place where the artificial pupil is to commence, a small opening is to be made with them in the iris. Through this opening, the blade of the scissors, which is attached to the long handle, and has a blunt point\*, is to be conducted between the iris and the crystalline lens, by opening the scissors a little. The other blade is to be passed between the inner surface of the cornea and iris, until their points reach a little beyond the border of the iris, where it has been separated from its adhesions. This portion of the iris is then to be divided; and the flap thus formed may generally be removed by another snip or two with the scissors. By this means an artificial pupil, of a triangular or oblong shape, will be made, which may easily be enlarged by the use of the scissors, if it should appear too small.

“To the permanent success of this operation, I always consider it of consequence that a portion of the iris should be removed. For, although the mere division of the iris appears to afford a sufficient aperture during the operation, yet this is only temporary, since it arises from the aqueous humour having been evacuated, by which the lens and vitreous humour loose their support anteriorly, and are pressed forwards so as to distend the new opening. Hence it happens, that the edges of the iris frequently return to their former situation, when the eyeball has become plump; especially if the border of the iris has not been divided. The only case in which I now depend upon a simple division of the iris is, where this membrane, after the operation for extracting a cataract, has formed a large staphyloma, and has, in consequence, been enveloped by the incision of the cornea to such a degree, that during the healing process the uppermost part of the pupil is at length dragged down to the lowest part of the cornea. By this means all useful vision is destroyed, and the iris is put upon the stretch. When, in such a case,

\* When an opening has been formed in the iris, previous to the introduction of the iris scissors, it will be advisable to use a pair blunted at both points.



an horizontal incision is made in the iris, the aperture will remain permanent, because its fibres had previously received all the extension of which they were susceptible.

“ It occasionally happens, in this operation, that particular circumstances may induce the surgeon to postpone its completion. If, for example, an attempt to draw out the iris with the hook should prove ineffectual, and the division of the adhesions with the iris scissors should appear in the least likely to injure the lens or its capsule, in consequence of the aqueous humour having escaped; the best plan will be to postpone the operation until the eye has recovered from the effects of the puncture. The cornea will then be plump, and the adhesion of the iris may be divided more completely by the cornea knife, so that the operation may be safely completed with the iris scissors.

“ In cases of this kind, the iris is sometimes more vascular than usual, and the effused blood so much obscures the part to be divided, that the operator cannot act with any certainty. This state of the iris, therefore, furnishes another reason for postponing the completion of the operation, until the absorption of the effused blood has taken place. All attempts, however, in such cases, sometimes prove ineffectual.”

After relating a case, illustrative of his manner of proceeding, he adds, “ Although the iris was drawn out with the most perfect ease, in this and two or three similar cases, yet in the majority of instances I have been unable to effect this, and have in consequence used the iris scissors.”

I have transcribed this statement of Mr. Gibson's, because it is highly honourable to his character as a surgeon and a man; neither increasing nor diminishing the difficulties of the operation; and whilst he shows the state of eye to which it is applicable, he endeavours to forewarn the student of the obstacles which he may have to encounter to a successful issue of it; he also very clearly shows, that it was always his intention to remove, if possible, the pupillary margin of the iris;



and how far, and in what cases, he considered a transverse division of the iris likely to be successful.

In the latter part of section *b* I have recommended an operation similar to that just described by Mr. Gibson; but then the iris must only be slightly attached to the cornea, and the separation of this attachment requires little more to be done to effect a competent pupil. In a case of attachment of the iris to the cornea, even at its central part, its external or internal pupillary edge remaining free, the operation by excision will often, with the help of a blunt hook, be perfectly successful. But, if the whole pupillary margin of the iris be firmly attached to the cornea, the anterior chamber will in general be considerably diminished; the knife will be passed with some difficulty to the adhesion, which will be increased on attempting to separate them, and cannot always be accomplished. In many cases, even if effected, the iris will be found very intractable, not readily drawn out with the hook, and if the lens and capsule should not be opaque, the repeated attempts at separating the adhesions, and drawing out the iris, will cause them to become so, and frustrate the operation. I cannot then recommend this method, unless the adhesion be slight, the edge of the iris free, and the lens and capsule transparent.

The operation, as performed with the scissors, may be attempted in the manner advised by Demours, as opposed to Maunoir and Scarpa, and described page 433; and the blunt-pointed scissors may be again introduced, and the artificial pupil enlarged towards the centre of the iris; but I think the operation of separation at the ciliary ligament, with excision of a part of the iris, is the most applicable to this peculiar state of eye. If, in any of these operations, the lens should be found opaque, it may be either extracted by enlarging the external opening, or the capsule may be ruptured, its texture opened into, and allowed to remain in situ, for absorption. If it should become opaque in consequence



of the operation, its texture may be opened in the same manner, by a fine needle introduced through the cornea or sclerotica, and the lens allowed to remain in like manner, for absorption.

I have thought proper to include a peculiar morbid state of the eye in this section, because the cornea is affected in it, as well as the iris. It is the state alluded to in page 427 ; in which Cheselden and Sharpe recommended the incision in the iris to be made a little above or below the transverse diameter of the eye, in order to avoid the lens, which they supposed to be smaller in the opaque than in the transparent state. I have there said, that this opinion was probably adopted from generalizing too much ; and that, had Cheselden lived, a wider range of experience would have induced him to alter it ; for he must have discovered, that, although this might be the case in some instances, still they were but in a very small proportion to those in which the lens was of a natural size. This opinion of Cheselden, repeated by Sharpe, has been pronounced to be erroneous, and it has been said, that he could not make an aperture in any part of this membrane (the iris), which would not be obstructed by the opaque lens. Cheselden was, however, right, and it is the opinion of later authors that is erroneous ; for, although a contraction or closure of the pupil commonly arises from inflammation of the iris, and not from any disease of the lens ; still, when once that inflammation is established, that man is more than hardy who will say where its effects shall terminate ; the lens may then be diminished in size, or it may have been originally preternaturally small ; the capsule and hyaloid membrane may be opaque, and the cornea may or may not be implicated ; but I hold it to be a fact of some importance, that the chance of the more internal parts of the eye being sound is greater in a case of closed pupil, after inflammation of the iris, complicated with derangement of the cornea, than when the external tunics have been unaffected ; because the unfortunate termination has been, in all probability, the result of neglected ra-



ther than of obstinate disease. The state alluded to by Mr. Cheselden will, I think, in general be found of this description; the cornea is for the most part opaque, particularly at the centre, the pupil closed, the lens diminished in size, and appearing through the iris, which is attached to the central opacity of the cornea, the aqueous humour keeping the outer circle of the iris nearly in its usual situation, which membrane, excepting where it is attached to the lens, preserves its natural appearance. The principle of any operation which can be recommended, must be to make an opening above or below a lens, under such circumstances; for, any attempt to remove a lens so firmly attached, would, in all probability, be unsuccessful, and must be useless from the opacity of the cornea. When the only transparent part of the cornea is at the upper part, the iris must be separated from the ciliary ligament, or divided at that part, as Mr. Cheselden recommended. That the operation is practicable, and that a person suffering from such derangement should not be abandoned, or this morbid state denied, or treated as fabulous, and that Cheselden's opinion was founded on fact, I have a living instance in proof, in the person of a young woman, who applied to me at the Infirmary for advice. Twelve years ago she suffered an attack of inflammation, from which she lost one eye, and the sight of the other. Three years afterwards, when Assalini was in this country, he attempted an operation on the eye, which retained its natural shape, but without success, and she remained blind. Two years afterwards she placed herself under the care of Mr. Alexander, who, by an operation on the same eye, restored her to a degree of sight, which is to her inestimable; but for the improvement of which she afterwards applied to me, and received considerable benefit.

The central part of the cornea is opaque, the rest not transparent, but clouded; the disk and surface of the lens is seen attached to the iris, which is adhering to the opaque part of the cornea; the greater circle of the iris is nearly natural, and immediately above the upper edge of the lens, precisely



at the spot Mr. Cheselden has mentioned, a small but good artificial pupil has been made, through which she sees sufficiently well to guide herself about with ease. I have performed the operation five times since the publication of the first edition of this work, and in three instances with success.

SECTION *e.*—*The state d, combined with a staphyloma of the cornea, in a greater or less degree: the lens being present, or having been removed.*

In this morbid state of eye, the whole derangement is the consequence of inflammation terminating in ulceration, or sloughing of a part of the cornea; the upper part or side of which often remains thin and transparent, and an artificial pupil may be made in it, of some use to the sufferer, if he should be blind of both eyes.

In adults, the staphylomatous affection is frequently not so much dependent on the derangement and thickening of the cornea, as on the protrusion of the iris taking place through an opening in it, the consequence of sloughing, but which proclivencia iridis is subsequently covered over by an opaque layer proceeding from the cornea, giving to the eye the appearance of a partial, rather than a complete staphyloma. In this case, the upper third of the cornea is, for the most part, tolerably if not entirely transparent, the iris is seen through it with its fibres fully on the stretch, closely applied to its internal surface, without any interposition of aqueous humour. In most of these cases the eye may be amaurotic, and an operation useless; but it is not so in all, and an operation should be attempted if the patient be blind of the other eye, merely on the chance of giving relief. I some years ago operated in a case of this kind on a poor man, a patient at the Infirmary: a puncture was made in the cornea with a sharp-pointed instrument, sufficiently large to admit a common cataract needle, with only one cutting edge and a round blunt



point; this being passed flat in front of the iris, and between it and the cornea, nearly to the opposite side, the edge of the instrument was turned to the iris, and an attempt made to cut it, which did not, although repeated, completely succeed, two small openings being made. The wound in the cornea was now a little enlarged, and Mr. Stodart's lancet-edged scissors introduced, with which an opening was completed, of sufficient size; the vitreous humour, in a healthy state, now pressed in between the edges of the incision of the iris, which separation I encouraged as much as possible, with the side of the knife. The patient said he saw well, and that his eye had been rendered very useful to him. This operation I have since repeated several times with equal success.

SECTION *f.*—*Either or all of the three last varieties of disease, combined with central opacity of the cornea, so dense and large as to leave only a narrow transparent ring, the aqueous humour not being entirely wanting.*

This state of eye is generally the consequence of acute inflammation, which has terminated in ulceration or sloughing of the cornea and protrusion of the iris; the only part of the cornea which remains transparent, being at the edge, and the only part of the iris perceptible being little more than that which covers the ciliary processes. A permanent opening is to be made in this part, if possible without injuring the cornea; and that operation seems *à priori* to be the best, which will enable the operator to do this with the least danger and the least inconvenience to the patient. Excision has been recommended by Mr. Gibson, a vertical division by Sir William Adams, and separation at the ciliary ligament by the continental authors.

The nature of the inflammation which caused the derangement, as well as the existing state of the eye, are both objects of inquiry and strict observation. If the in-



inflammation has been simple, and run its course in a short time, its sequelæ having assumed their present appearance with as little inconvenience as possible, without leaving any chronic inflammation or irritation of the eye and its appendages, or any morbid vascularity of these parts, the prospect of success is favourable: whilst it is the reverse in the proportion in which any of these symptoms prevail. It is particularly so if the iris appear morbidly vascular, or the only remaining transparent part of the cornea should seem to be softer, less transparent, less colourless, or more vascular than natural; for, in this case, the cornea is disposed to become opaque from previous disease, and any opening that may be made in it will cause a general muddiness of the transparent part, not easily dissipated, and seldom so completely as not to leave some permanently additional opacity. The operation by excision, which is in some instances practicable, is quite prohibited in a case in which there is any tendency to a disease of this nature; for, although a competent opening in the iris may be effected, yet the small puncture in the cornea will cause that part to become more or less opaque, and will, by preventing the passage of the rays of light to the retina, render the operation unavailing; and a repetition of it would add still further to the evil.

If, on the contrary, the eye has entirely recovered from the inflammation which caused so much mischief, no appearances of chronic irritation remaining, the transparent part of the cornea looking perfectly healthy, and the iris evidently separated from it by aqueous humour, the operation of excision may be attempted, and it will sometimes succeed, although it will much more frequently fail. When it does succeed, the pupil will always be small, and vision by no means good, although certainly very useful.

The operations done in this way have not proved so satisfactory as could be desired; and upon the whole, I can only recommend this method, in cases where, from the state of the



constitution, unhealthy or excessive inflammation might be expected from the separation of the iris at the ciliary ligament, which appears to me to be the preferable, although the most dangerous operation.

A vertical division of the iris is by no means applicable, in my opinion, to this state of disease; it is not easily effected, does not make so large or so good an opening as is made by the separation at the ciliary ligament, and is equally liable to cause inflammation: I know that it may be done, but I do not think it less dangerous, and it is certainly less advantageous to the patient, than the coredialysis.

SECTION *g*.—*The states included in f; the iris in contact with the cornea, a segment of a narrow ring at the edge being alone transparent, and the anterior chamber obliterated.*

This state of derangement explains itself, and there is but one method of operating which offers to the sufferer a chance of relief, and that is the separation of the iris from the ciliary ligament, at whatever part the cornea may be transparent.

The cornea is to be opened by a perpendicular incision, to the extent which may be considered necessary for the easy introduction of the coreoncion of Langenbeck; for which instrument see Plate V, figures 1, 2, 3, 4, or the hooks of Reisinger\*. This opening may be made, if necessary, in the opaque part, and the instrument is to be introduced through it, and insinuated between the iris and cornea until it reaches the edge of the iris as seen through the cornea. The operator has his thumb on the knob of the coreoncion *b*, figure 4; and the hook, which is projected at *c*, fig. 2, is retracted to the edge of the gold tube marked *b*, so that the point of the hook rests against the edge of the tube, and cannot catch

\* See his operation page 449, substituting excision for strangulation of the iris.



the iris, either on introducing or withdrawing it. The point of the hook being turned towards the iris (which has been previously ascertained by its correspondence with the knob in the shaft of the instrument regulating it), is to be projected a little, and affixed by pressure into the iris: the operator now allows the knob, regulating the hook, to recede slowly, and he will perceive that the iris has begun to separate; which separation is to be completed by withdrawing the whole instrument from the eye, bringing with it the iris grasped between the hook and the end of the gold tube; as if held in a pair of spring forceps. The portion of iris external to the cornea is to be cut off with the scissors, and the remaining part returned into the anterior chamber, so that it may not prevent the union of the edges of the cornea. The strangulation of the portion of the iris brought through the opening of the cornea gives rise to inflammation, is not necessary, and ought not to be practised.

The operation performed in this manner will, I conceive, supersede every other method hitherto adopted for the core-dialysis; even at the upper part of the eye, where the iris is not likely to return to the ciliary ligament, if the separation has been completely effected. In using these instruments in a case where the lens is transparent, all injury to it from the points of the hooks must be prevented, by turning it slightly on its axis after the separation has commenced, by which the lens will be completely avoided.

*SECTION h. — Other anomalous states, not included in the above, but requiring some modification in the mode of operating.*

In this section may be included that state of eye, in which the cornea has become entirely opaque, so as to preclude the possibility of making an artificial pupil in the iris, which in all probability is closely attached, if not adherent to the cornea in almost every part. It is a case hitherto supposed to be hopeless. Professor Autenrieth, of Tübingen,



conceived, however, that it might be possible to make an artificial pupil through the sclerotica, by which a certain degree of vision might be obtained. He made the experiment on dogs, and says he succeeded; upon which authority Bëer tried it in one case, on a person whose cornea was completely opaque, but failed. I have also tried it in three instances, but with an equal want of success. The operation which is called scleroticectomy by the Germans, has been made the subject of a treatise at Tübingen, by L. Schmidt, and is to be attempted in the following manner:

A curved needle with a cutting edge is to be passed under the sclerotica close to the cornea, with the convex part towards the eye, and made to cut itself out, by which a small flap is made in the sclerotica, which is to be enlarged by the blunt-pointed iris scissors, until an irregular triangular opening is made, nearly of the size and shape of the artificial pupil in fig. 4, Plate I. The choroid coat must next be removed to the same extent as the sclerotica, and in doing it care must be taken not to injure the hyaloid membrane. As the wound heals the sclerotica closes in; and in those cases I have seen the new-formed substance was so opaque, as to prevent any benefit resulting from the operation, which cannot, in my opinion, be ever attended with success.

THE END.








Fig. 1.

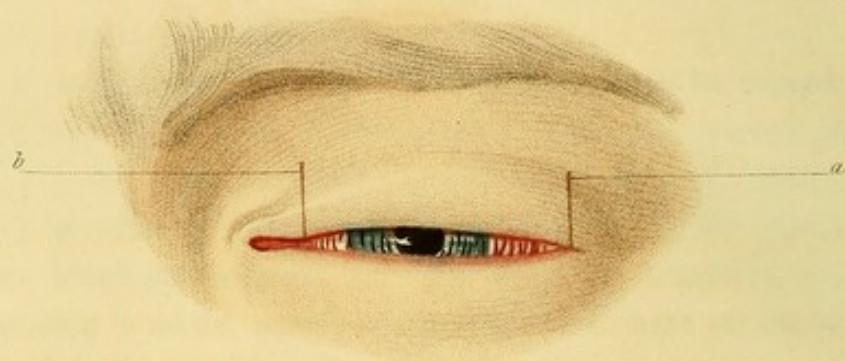
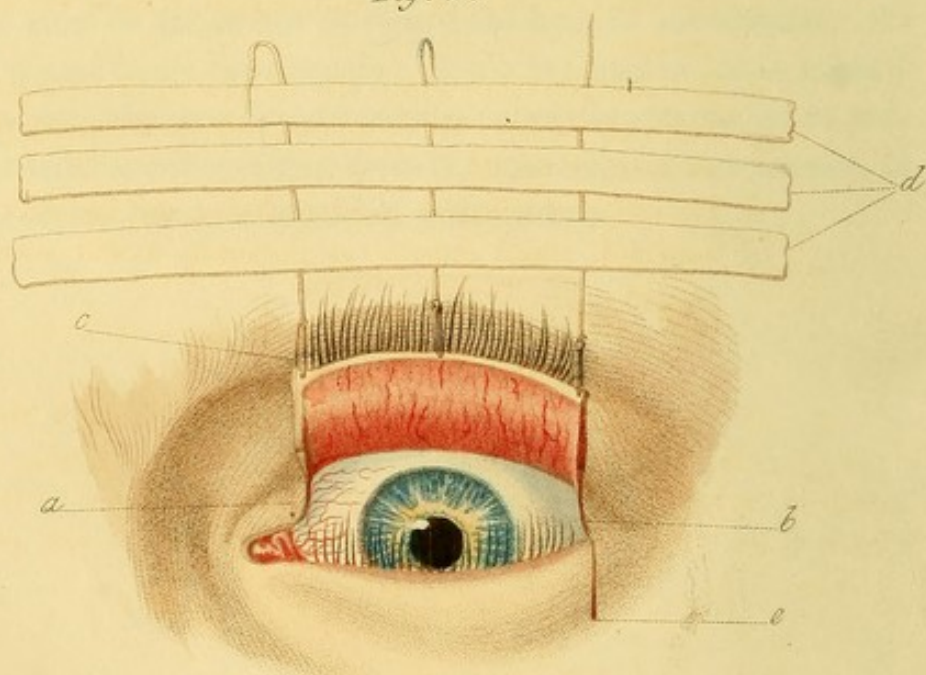


Fig. 2.



Drawn by Mulready.

Eng<sup>d</sup> by L. Stewart.



## EXPLANATION OF THE PLATES.

---

### PLATE I.

Fig. 1. The eye partially opened, the cilia of both lids inverted.

- a. b.* The lines of incision at the outer and inner angle, not exceeding one-third of an inch in length.

Fig. 2. Represents an eye in which the upper eyelid has been operated upon for inversion.

- a.* The inner incision, close to the punctum lachrymale, which is marked by a black spot, and which incision need never exceed one-third of an inch in length.
- b.* The outer incision, of the same length, close to the external canthus.
- c.* The ligatures supporting the lid against the eyebrow, and more particularly the inner one, which is passed through the edge of the lid.
- d.* The strips of adhesive plaister affixing the ligatures to the forehead, which must be as numerous as will answer the purpose.
- e.* The line of incision, in a case of inversion of the lower lid.

Mr. Crampton informs me, that, in cases of inversion of the lower lid, he has succeeded in effecting a cure by making pressure, below the lid, by an instrument placed on the nose, and fastened at the back part of the head, resembling almost in every respect a pair of spectacles.



## PLATE II.

Fig. 1. Represents a case of eversion of the second species.

Fig. 2. Represents the appearance of the eyelid in the case of Henry Puchett, page 78, which was perfectly cured.

Figs. 3 and 4. Represent the appearances of an eversion of the third species, in the eye of Joseph Geoffry, page 73, before and after the operation. The two yellowish spots on the sclerotic, in fig. 4, are intended for the oval substances alluded to page 144.

Fig. 5. Represents a thin membranous pterygium.

Fig. 6. A fleshy pterygium.



Fig. 1.

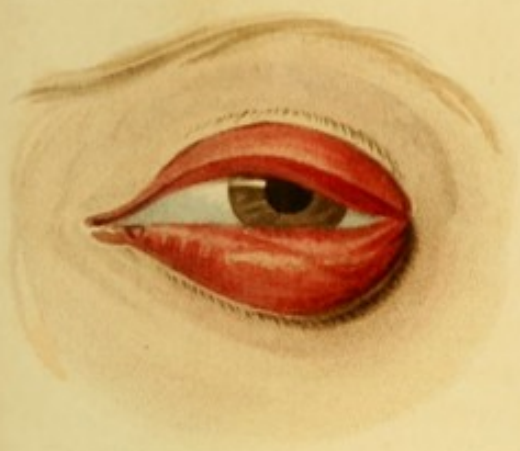

Fig. 2.

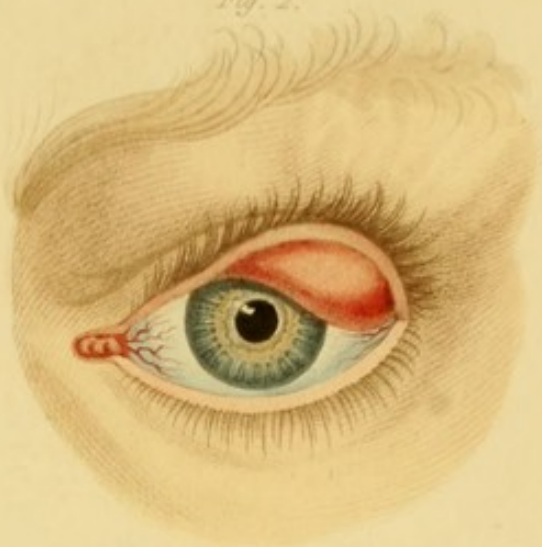

Fig. 3.

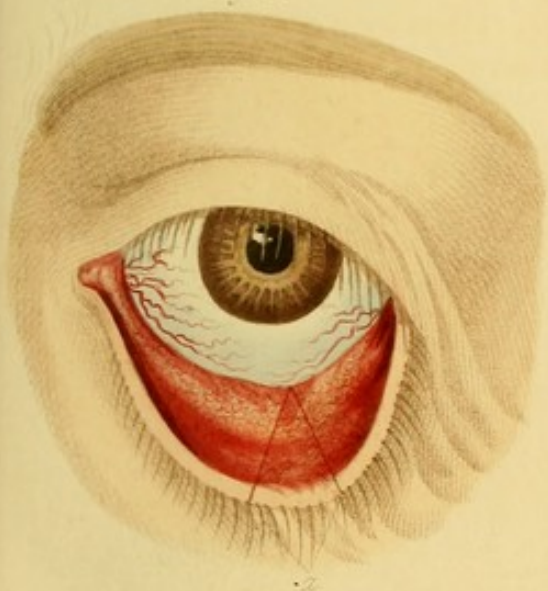

Fig. 4.

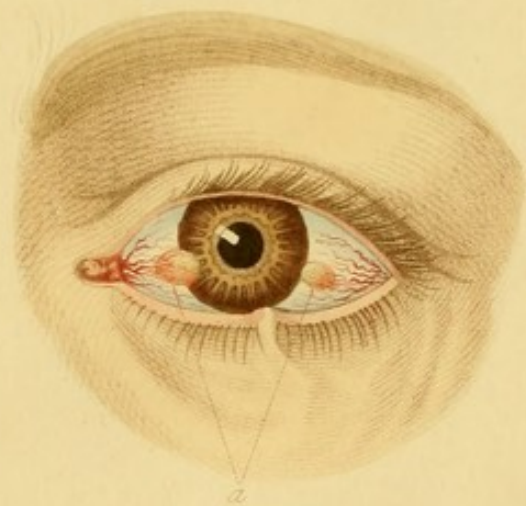


Fig. 5.

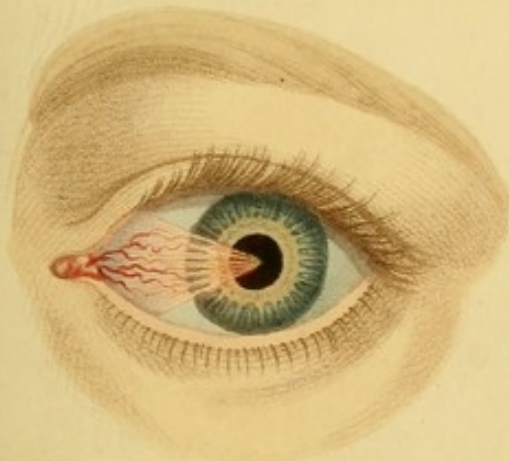
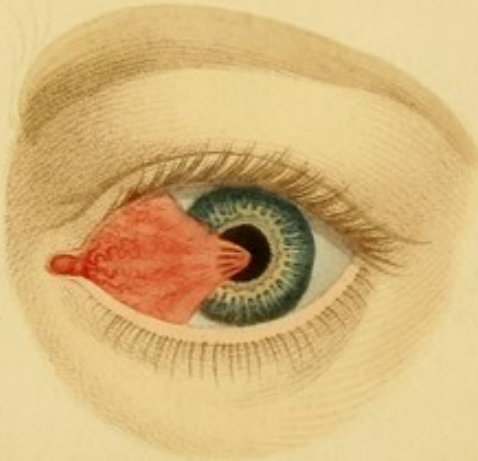



Fig. 6.



Engraved by I. Stewart.












Fig. 9.

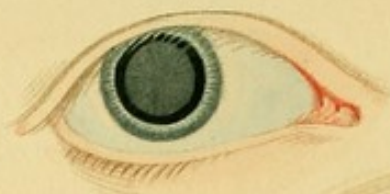

Fig. 2.

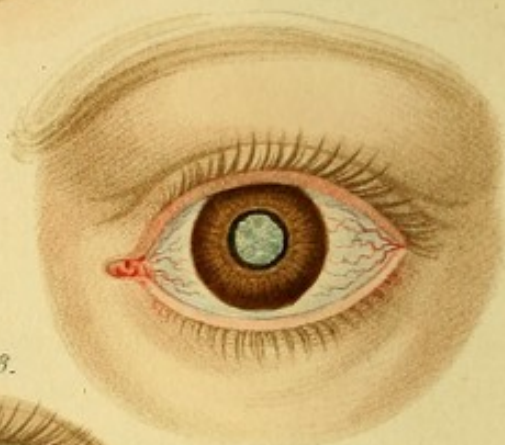

Fig. 8.

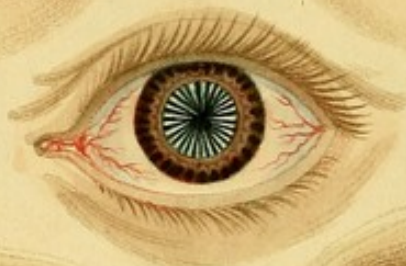

Fig. 4.

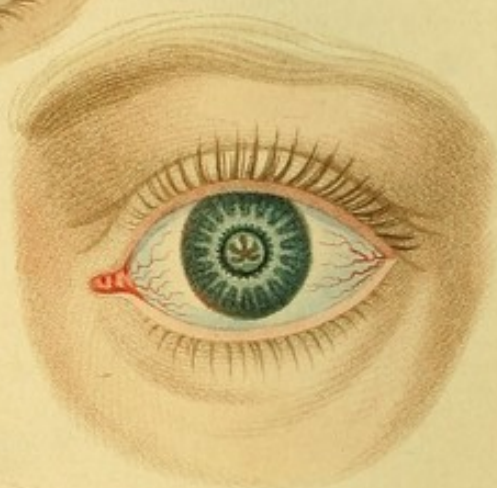


Fig. 7.

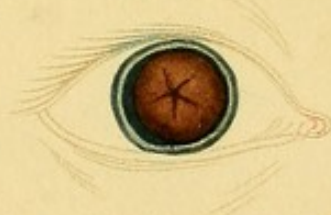

Fig. 6.

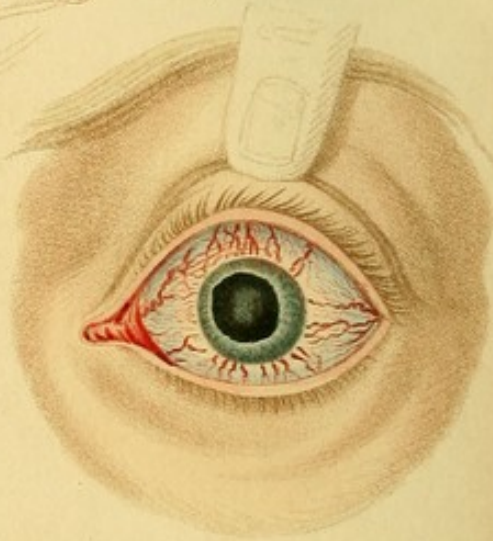


Fig. 1.

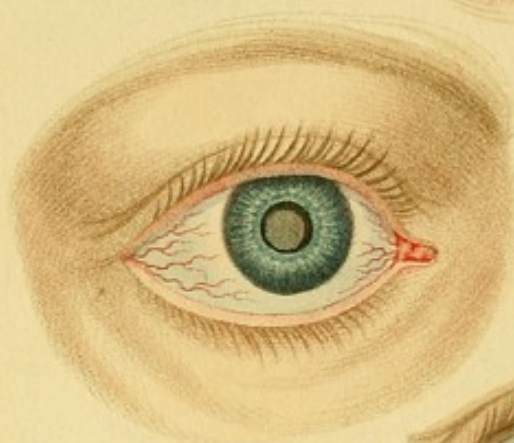

Fig. 3.

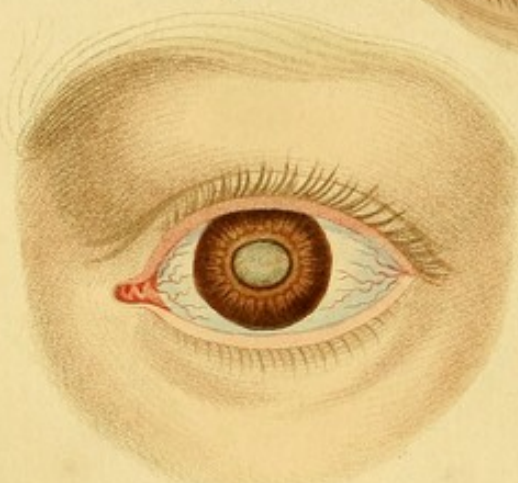
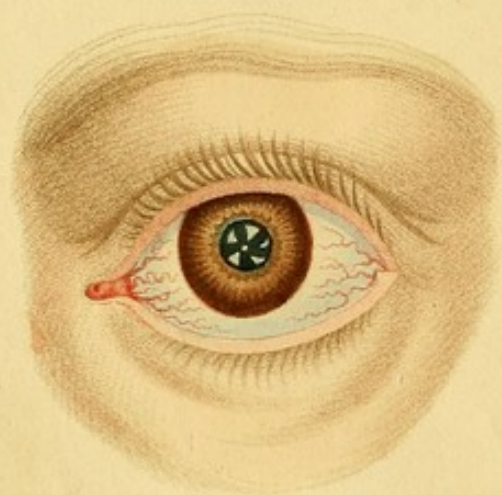


Fig. 5.



Engraved by L. Street.



## PLATE III.

Fig. 1. Represents a hard lenticular cataract, of a grey colour. The shadow thrown upon the lens by the iris, in consequence of the light falling upon the eye over the nose, is strongly marked, but extends rather too far outwards. The lens is supposed to be distant from the iris.

Fig. 2. Represents a soft capsulo-lenticular cataract, of a large size, pressing into the pupil, indicated by the black ring around it, formed by the posterior edge of the iris, or the uvea, a little advanced in consequence of the pressure from behind. The lens being supposed to be nearly if not quite in contact with the iris, no shadow is cast upon it. The capsule is striated.

Fig. 3. Represents a fluid cataract, in which the capsule is slightly affected; sometimes called *cataracta Morgagniana*. The opaque spots are not stationary; the thicker portions descending when the eye has been some time at rest. The dark ring around the pupillary edge is marked, showing that the cataract is nearly in contact with the iris.

Fig. 4. Represents an arid siliquose, or coriaceous capsular cataract, described page 251, and which, when once seen, can afterwards scarcely be mistaken.

Fig. 5. Is intended to represent two affections of the capsule, a central opacity, which sometimes exists alone, and several opacities of the capsule commencing from the circumference, the pupil being a little dilated by the belladonna.

Fig. 6. Represents a strongly marked case of glaucoma, described page 223, the lens being scarcely affected.

Fig. 7. The other eye, of the same person, in which the lens is of a mahogany colour, the iris a mere ring, as perceptible through the cornea.

Fig. 8. A capsular cataract of a peculiar appearance, the lens remaining sound.

Fig. 9. The congenital cataract described page 389, being a small opaque capsule and lens, with a black circle of vitreous humour around it; the pupil being dilated, as seen in the eyes of Mr. Farnsworth, 70, Clarendon Place, Somers' Town.



## PLATE IV.

Fig. 1. An artificial pupil of a large size, formed by dividing the iris with the knife (coretomy), in which the capsule and shrunk lens remain attached to the lower edge of the newly formed pupil.

Fig. 2. The appearance of an artificial pupil formed in the eye of a man, at the Infirmary, who had been twenty-four years blind of both eyes. The capsule was thickened and adherent to the iris, which accounts for the narrowness of the pupil; the lens was opaque. He saw extremely well.

Fig. 3. Taken from Scarpa, to show an artificial pupil formed by the scissors; the opening in the cornea being marked by a line, the segment of a circle.

Fig. 4. The appearance of a good-sized pupil made by excision of a portion of the iris.

Fig. 5. A separation of the iris from the ciliary ligament, the consequence of a blow.

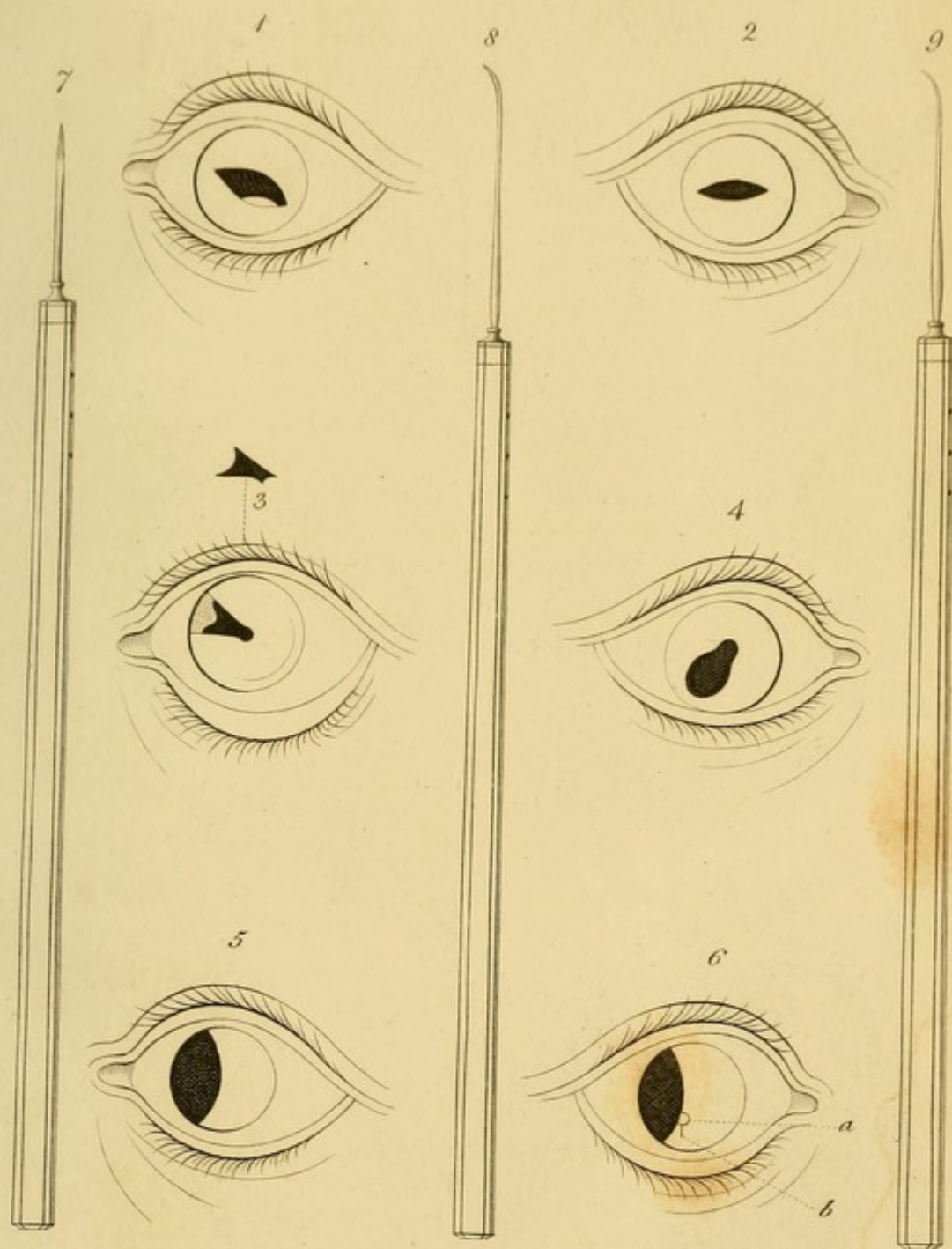
Fig. 6. This separation imitated by art. The letters *a* and *b* being intended to give an idea to the student of the place where the opening is to be made in the cornea.

Fig. 7. The double-edged cutting needle for the division of a soft lens, posterior to the iris.


Fig. 8. Langenbeck's knife for the breaking up of a soft lens through the cornea.

Fig. 9. The curved needle used in reclinatio through the cornea, being nearly similar in curvature to that of Scarpa.






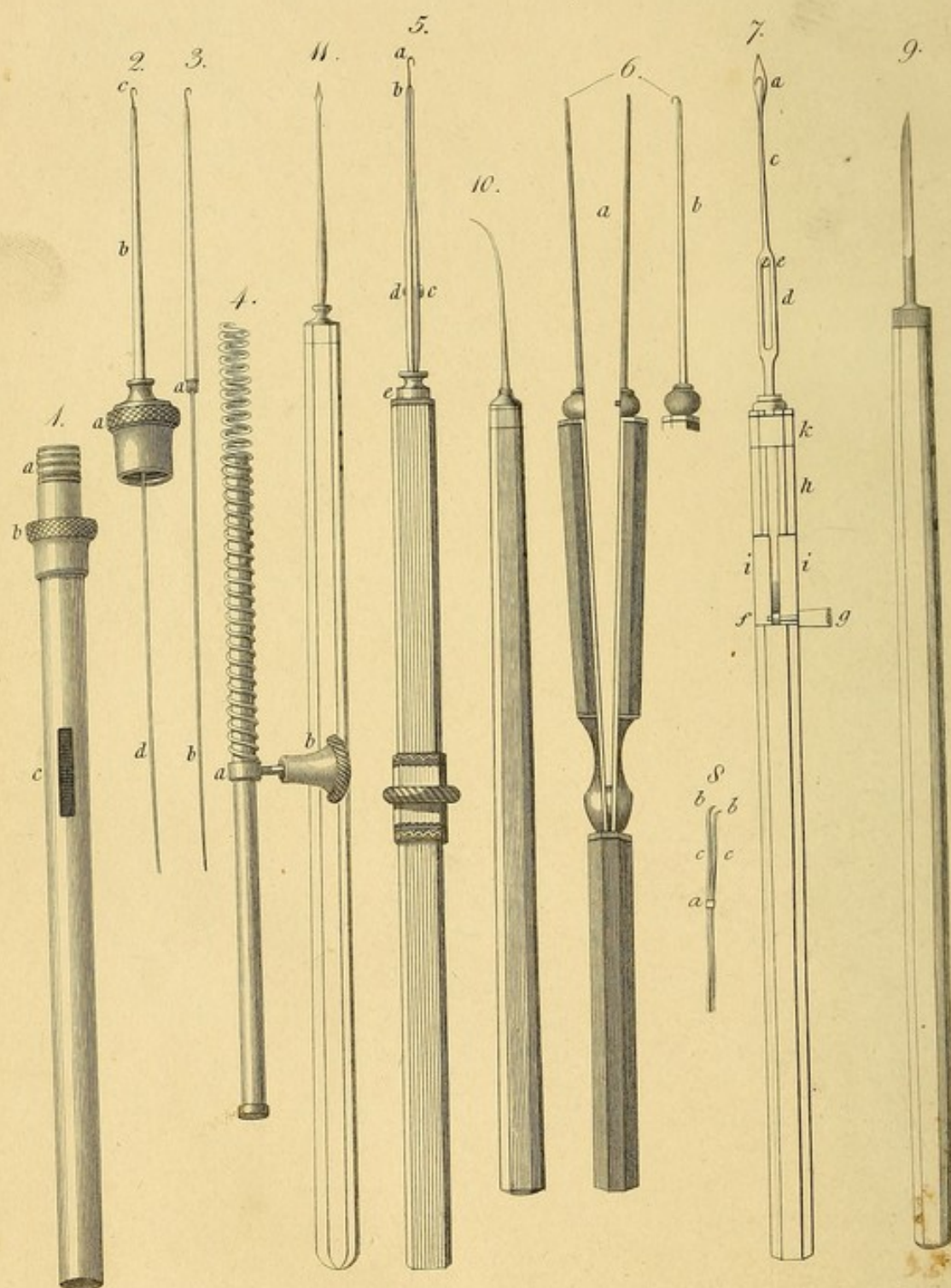












Engraved by J. Stewart.



## PLATE V.

Figs. 1, 2, 3, 4. The Coreoncion of Langenbeck in four parts, to show its mechanism.

Fig. 1. The shaft of the instrument :

- a.* The screw worm to which the cap or end fig. 2 is affixed.
- b.* The projection or ring against which the finger rests to steady the instrument.
- c.* The opening in the shaft to admit the motion forwards and backwards of the knob *b*, fig. 4.

Fig. 2. *a.* The end of the instrument which fits on to the screw in the handle *a*, fig. 1, and containing the hook.

- b.* A fine gold tube only large enough to receive the hook.
- c.* The hook, which can be projected for two lines only.
- d.* The shaft of the hook, by which it is affixed in the spiral wire, fig. 4.

Fig. 3. This figure shows the golden tube and hook separated from the handle or shaft of the instrument.

- a.* The joining of the golden tube.
- b.* The hook and shaft.

Fig. 4. The spiral spring made of wire, which is received into the shaft of the instrument, fig. 1.

- a.* The ring in which the moveable knob *b* is affixed, after the spring has been introduced.

Fig. 5. The Iriankistron of Dr. Schlagintweit.

- a.* The hook.
- b.* The slider, making, when pushed forwards to the hook, a kind of forceps.
- c.* The screw, which being put through a small groove in the slider, and fastened to the neck of the hook at *d*, admits of the slider's or forceps' blades being pushed forwards or drawn backwards to the extent of the groove or hollow that the neck of the screw plays in.
- e.* The ring or joint which unites the different parts of the instrument.



Fig. 6. *a.* Dr. Reisinger's double-hooked forceps.

*b.* A single limb, side view.

Fig. 7. Dr. Embden's Raphiaukistron.

*a.* The straight cataract needle, in the shape of a lancet, on the surface of which the hook lies. The instrument is delineated in the state in which it is to be used.

*c.* The hook and needle fitting so closely as to form but one shaft.

*d.* The opening in the broad part of the neck of the hook.

*e.* The screw, by which the hook is so connected with the needle as to admit of its being moved backwards and forwards.

*f.* The end of the neck of the hook, provided with a hole, into which the knob *g* is received.

*h.* The part of the neck of the hook which lies in a hollow of the handle.

*i. i.* A flat surface in the handle, which is as deep as the hollow, in order to allow the knob to be fixed on either side.

*k.* The ring under which the neck of the hook may be freely moved.

Fig. 8. Gräefe's Coreoncion, or double-hooked forceps.

*a.* The moveable ring which closes the hooks.

*b. b.* The two hooks.

*c. c.* The two shafts or limbs of the hooks.

Fig. 9. The iris scalpel, of the middle size of the shops, being the largest which should ever be used in the operation for dividing the iris; pointed, but cutting only on one side.

Fig. 10. A curved needle for capsular cataract, alluded to page 362.

Fig. 11. Bëer's lance-pointed needle, for the displacement of the lens.








Fig. 1.



Fig. 2.


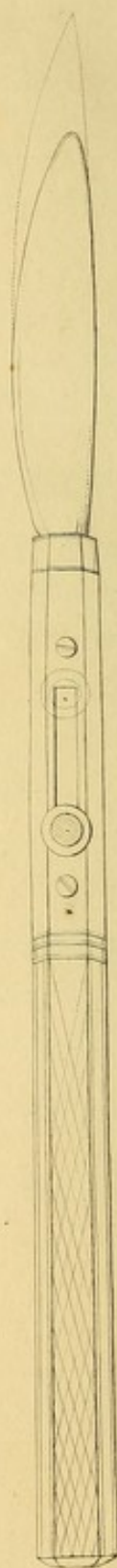


Fig. 3.





## PLATE VI.

Fig. 1. Mr. Guthrie's double knife, one blade of silver, one of steel.

This sketch shows the steel knife guarded by the silver blade, which projects beyond it.

Fig. 2. The steel blade detached.

Fig. 3. The knife with the silver blade uppermost, the steel blade projected in outline beyond it.



## PLATE VII.

Fig. 1. A case of inversion of the under eyelid, cured by operation.

Fig. 2. Ditto of the upper eyelid.

Fig. 3. A case of glaucoma combined with cataract.

Fig. 4. A peculiar ring of opaque capsule remaining after the operation for the removal of the lens by the keratonyxis. The portion of capsule surrounding it being transparent.

Fig. 5 and 6. The two eyes of Mary Keely, the Nurse at the Infirmary, which have been operated on for Artificial Pupil.

Fig. 7. A fungoid tumour of the eye, rendering extirpation necessary ; noticed page 193, and divided in halves.

*a.* The optic nerve.

*b.* A yellow soft cheesy substance.

*c.* The remainder of the tumour, of a black colour and soft.

The disease appeared to have begun in the retina.





Fig. 1.

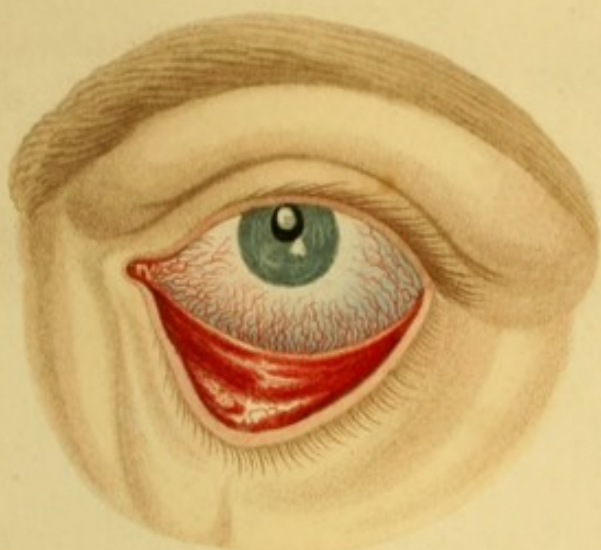


Fig. 2.

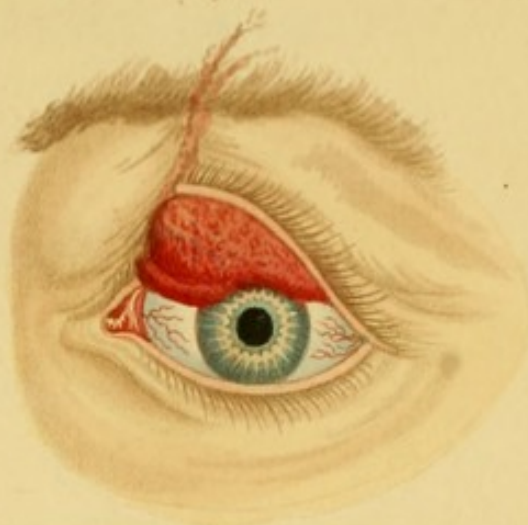

Fig. 3.

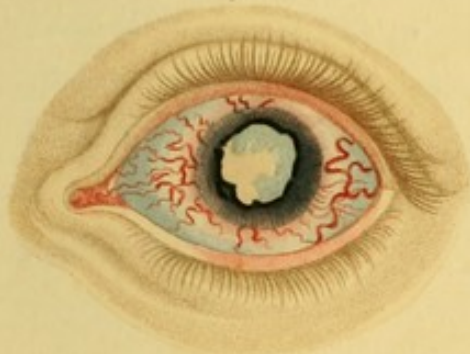


Fig. 4.

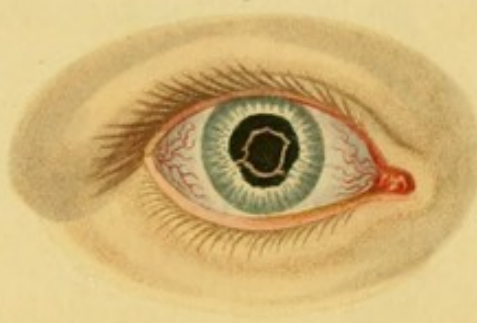


Fig. 5.

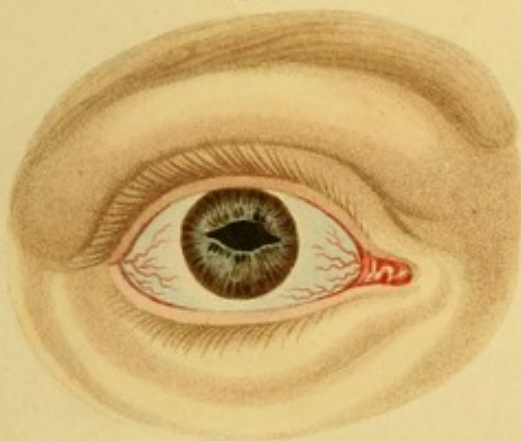


Fig. 6.

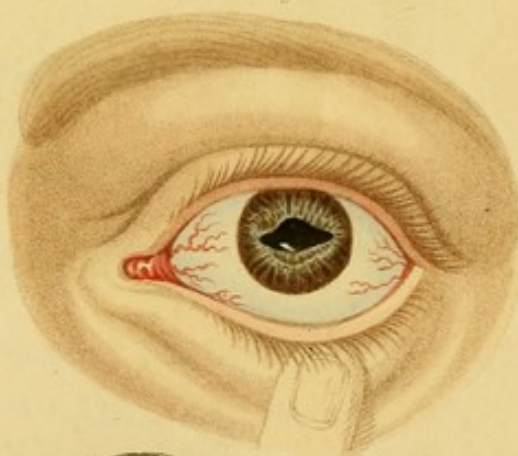
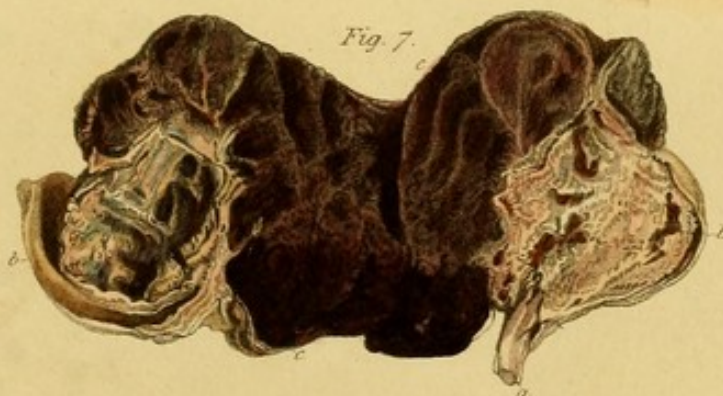



Fig. 7.









WORKS BY MR. GUTHRIE.

---

OBSERVATIONS

ON

GUN-SHOT WOUNDS,

ON

INFLAMMATION, ERYSIPELAS, MORTIFICATION, INJURIES of NERVES and of the EXTREMITIES, requiring the greater Operations of Amputation at the Hip Joint, Shoulder Joint, &c. : with the History of the Author's successful Case of Amputation at the Hip Joint. Third Edition, 8vo. plates, boards, 18s.

---

OBSERVATIONS ON HÆMORRHAGE,

WOUNDS OF ARTERIES,

AND ON THE THEORY OF ANEURISM;

with a Description of the proper Methods of performing the different Operations on the great Arteries. 8vo. boards.



*Valuable Works just published by Burgess and Hill.*

A SERIES of ENGRAVINGS, intended to illustrate the Structure of the BRAIN and SPINAL CHORD in MAN. By HERBERT MAYO, Surgeon and Lecturer on Anatomy. Folio, price 2*l.* 2*s.*

*Also, by the same Author,*

OUTLINES of HUMAN PHYSIOLOGY. 8vo. boards, 14*s.*

"Under this title Mr. Mayo has published a system of physiology, distinguished no less by the clearness and perspicuity of its style, than by the sound and judicious views of the human economy which it presents. Accustomed to deliver lectures on anatomy and physiology, Mr. Mayo has learnt to state, at once lucidly and concisely, the body of knowledge which has been long accumulated; and the advantage which he possesses as a practical physiologist, enables him to digest no less ably the facts included in more recent discoveries, to which he has himself contributed. We recommend those who are interested in medical science to peruse for themselves the volume to which we have thus called their attention."—*Journal of Science, &c.*

A COURSE of DISSECTIONS, for the use of Students. 12mo. plates, 7*s.* 6*d.*

"We have looked over this Course of Dissections, and we venture to predict, that it will be found more completely adapted to the practice of the dissecting-room than any Manual hitherto published in this country."—*Med.-Chirurg. Review.*

A LARGE ENGRAVING of the ANATOMY of the EYE, with a concise Description. Coloured, 9*s.*

This beautiful and accurate engraving, exhibiting a section and two dissections of the eye, is particularly recommended to the notice of the profession. It is the largest and most superb plate of the eye ever published.

A MAP of the INTERNAL EAR, copied from the Drawing used by Mr. CHARLES BELL, in his Lecture Room, Great Windmill Street. Coloured, 7*s.* 6*d.*

This useful and beautiful plate represents the intricate anatomy of the Ear, and the course of vibrations through the several cavities.

DERMOTT'S ANATOMICAL PLATES, Nos. 1, 2, and 3; containing the Anatomy of the Face, Neck, Axilla, Superior Extremity, Bend of the Fore Arm, and Hand; with outlined Drawings and copious Descriptive References. By G. D. DERMOTT, Surgeon and Lecturer on Anatomy, Little Windmill Street. Price 1*l.* 19*s.*

"Whoever takes the trouble to examine these plates attentively, will agree with us, that they are among the most correct illustrations of the subjects embraced which have ever been published. They do Mr. Dermott infinite credit."—*Medico-Chirurgical Review.*

*Also, by the same Author,*

REFLECTIONS of the PERITONEUM, Nos. 1 and 2. Price 4*s.*

A TREATISE on the different Methods of investigating the DISEASES of the CHEST, particularly Percussion and the use of the Stethoscope. Translated from the French of M. COLLIN, with an additional Preface, by W. N. Ryland, M.D. Second Edition, with a Plate. Price 2*s.* 6*d.*

"It is a very useful pocket companion while studying the use of the Stethoscope, and the general means of ascertaining the nature of thoracic diseases."—*Medico-Chirurgical Review.*

ELEMENTS of the THEORY and PRACTICE of PHYSIC, designed for the use of Students. By GEORGE GREGORY, M.D. Lecturer on the Theory and Practice of Physic in London, Senior Physician to the St. George's and St. James's Dispensary, &c. &c. &c. Second Edition, boards, 16*s.*

Every part of this work has been carefully revised, and many additions to it have been made, suggested partly by the recent observations of contemporary writers, and partly by the author's more extended experience, and the author hopes considerably improved.

LONDON:

PRINTED BY CHARLES WOOD,

Poppin's Court, Fleet Street.



