

Surgery illustrated : compiled from the works of Cutler, Hind, Velpeau, and Blasius : with fifty-two plates / by A. Sidney Doane.

Contributors

Doane, A. Sidney 1808-1852.
Cutler, Thomas.
Hind, George W., 1802-1885.
Velpeau, A. 1795-1867.
Blasius, Ernst, 1802-1875.
Francis A. Countway Library of Medicine

Publication/Creation

New York : Published by Harper & Brothers, 1836.

Persistent URL

<https://wellcomecollection.org/works/xbmmrfnk>


License and attribution

This material has been provided by This material has been provided by the Francis A. Countway Library of Medicine, through the Medical Heritage Library. The original may be consulted at the Francis A. Countway Library of Medicine, Harvard Medical School. where the originals may be consulted. This work has been identified as being free of known restrictions under copyright law, including all related and neighbouring rights and is being made available under the Creative Commons, Public Domain Mark.

You can copy, modify, distribute and perform the work, even for commercial purposes, without asking permission.




Wellcome Collection
183 Euston Road
London NW1 2BE UK
T +44 (0)20 7611 8722
E library@wellcomecollection.org
<https://wellcomecollection.org>

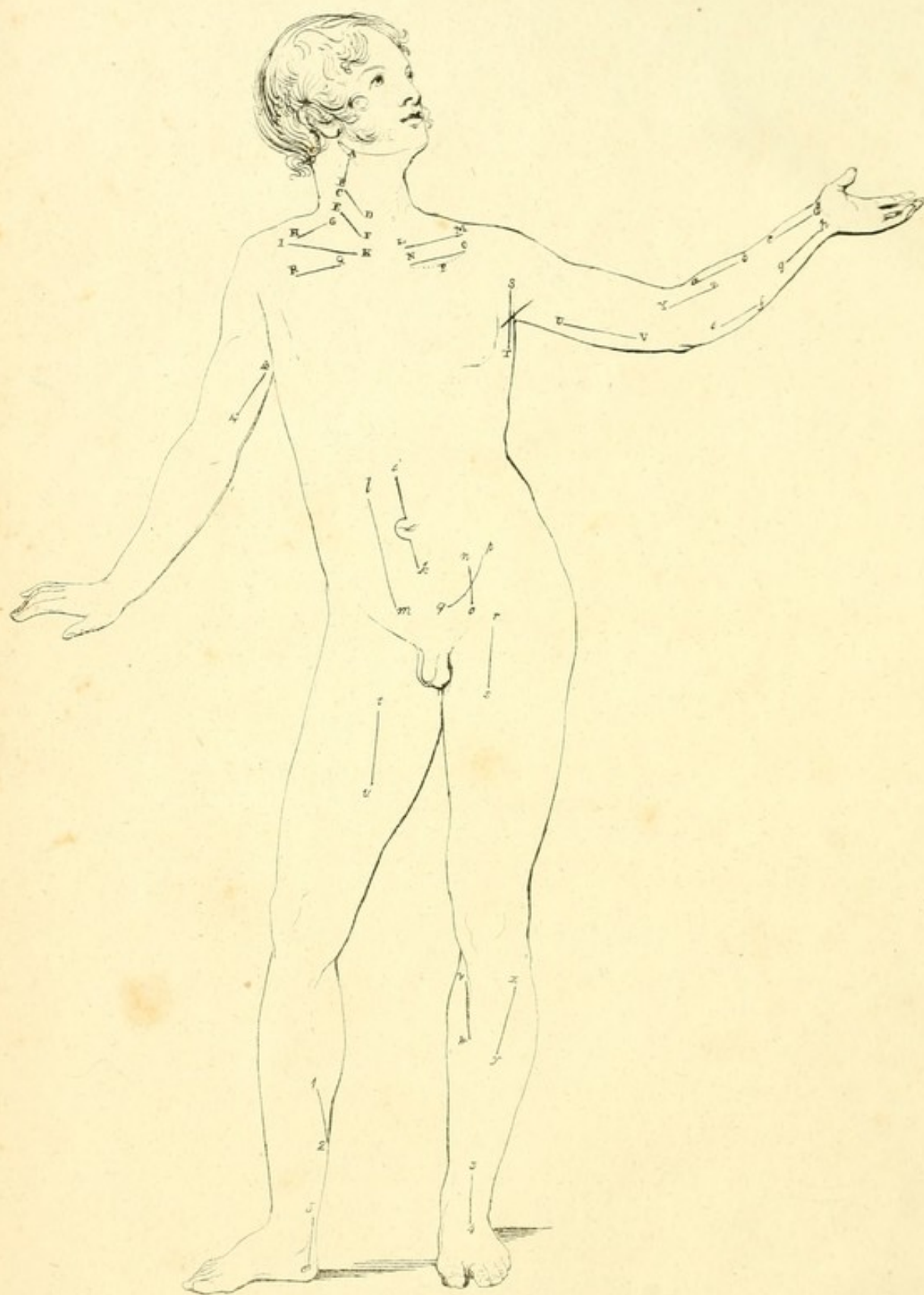

BOSTON MEDICAL LIBRARY
in the Francis A. Countway
Library of Medicine ~ *Boston*





Digitized by the Internet Archive
in 2011 with funding from
Open Knowledge Commons and Harvard Medical School



SURGERY ILLUSTRATED.

COMPILED

FROM THE WORKS

OF

CUTLER, HIND, VELPEAU, AND BLASIUS.

WITH FIFTY-TWO PLATES.

BY A. SIDNEY DOANE, A.M., M.D.

NEW-YORK:

PUBLISHED BY HARPER & BROTHERS,

NO. 82 CLIFF-STREET.

1836.

SURGERY ILLUSTRATED.

CHURCH

FROM THE WORKS

CUTLER, HIND, VEEBEAN, AND BISHOP.

Entered, according to act of Congress, in the year 1836, by
HARPER & BROTHERS,
In the Clerk's office of the Southern District of New York.

BY A. SIDNEY DOANE, M.D.

NEW YORK:

PUBLISHED BY HARPER & BROTHERS,

NO. 22 NASSAU STREET.

1836.

P R E F A C E .

THE kindness with which the translation of *Midwifery Illustrated* has been received by the profession, and the great demand for works of a similar character in the other branches of medicine, have induced the compiler to bring together, in a single volume, materials drawn from sources of high authority, and not within the reach of every one.

On the subject of *bandages*, he has used freely Cutler's *Surgeon's Practical Guide*,* &c., a book of acknowledged utility, containing the results of practice, of personal observation in the British and continental hospitals, and also facts drawn from the best writers on surgery generally, or in this department of the science in particular. Mr. Cutler remarks, that "he has introduced nothing but what has appeared to him decidedly useful;" and that "he has still allowed for cases of great consequence an ample choice of means." In this section, the compiler has also referred frequently to Gerdy's *Traité sur Bandages*; and while it is freely admitted that only the most important bandages are described, yet he would claim for this section of the book the special notice of the profession, as the subject of dressings and bandages is generally too much neglected.

In the section on *fractures of the extremities*, it will be seen that the illustrations here presented differ from those generally found in surgical works. "The object of our plates," as Mr. Hind remarks, (from whose *Series*,† &c., this part of the book is compiled,) "is solely to introduce to the view of the student such plans of the different fractures of the bones of the extremities as may enable him at once to effect the reductions

* The *Surgeon's Practical Guide in Dressing and in the Methodic Application of Bandages*. Illustrated by numerous Engravings. By Thomas Cutler, M. D. late Staff Surgeon in the Belgian Army. London, 1834.

† A *Series of Twenty Plates, illustrating the Causes of Displacement in the Various Fractures of the Bones of the Extremities*. By G. W. Hind, M. R. C. S. of London, &c. London, 1835, in folio.

necessary, and suggest to him the principle on which they should be treated. In order to render the description of each plate as concise as possible, the appearances, the displacement, and the treatment of the fractures, have alone been stated."

We come now to the section on *surgical operations*. We do not pretend to have done all on this topic that might have been accomplished: the best illustrations of the most common operations have been selected from the extensive works of Velpeau* and Blasius,† and brief descriptions of the same have been borrowed from the most popular writers, with a view to give the student and practitioner a better idea of these operations than can be gained merely by reading.

Here we will close. In this work we make no pretensions to originality, thinking that the profession will be benefited more by a compilation of facts than by an original book of theory. Our aim has been to be useful. It is for medical men to determine whether we are, or are not, successful.

232 Grand Street,

New York, 7th April, '36.

* Nouveaux Elements de Medicine Operatoire, accompagnés d'un Atlas de 20 planches, 4to. par Alf. A. L. M. Velpeau. Paris, 1832.

† Erklärung der Akiurgischen Abbildungen, &c. vom Dr. Ernst Blasius, Professor an der Universität zu Halle. Berlin 1833.



SURGERY ILLUSTRATED.

SECTION FIRST.

BEFORE proceeding to describe the principal operations in surgery, we shall devote a few pages to the subject of dressings, bandages, &c., with which it is highly necessary for the student to be acquainted.

Lint is a tissue so well known that a description of it is unnecessary.

Charpie is a name given by the French to a collection of filaments, separated from morsels of old linen rag of loose texture, which they prefer in lieu of lint; it may be used in all cases where the employment of lint is indicated, and will be found to absorb much better. It is divided into two kinds, the *charpie brute* and the *charpie râpée*. The *brute* is either fine or coarse according to the linen employed in its fabrication; the fine sort is placed in immediate contact with the surfaces of wounds, on account of its softness and absorbing qualities; the coarse is employed as an upper stratum for reasons of economy. The *râpée* is a kind of down, made by scraping fine linen rag or long charpie with the back of a knife: it appears to be more irritating than the first kind, and absorbs the pus with greater promptitude.

In France, the first kind of charpie takes the name of *plumasseau*, *bourdonnet*, *tente*, *tampon*, *meche*, or *pelote*, according to the manner in which its fibres are arranged.

The *Plumasseau* [Pl. I. fig. 1.] is a mass of charpie, the filaments of which are laid parallel to each other, the ends being folded under and flattened between the palms of the hands. *Plumasseaux* are made of different sizes and forms, to adapt themselves to the parts upon which they are to be applied. They are useful for covering wounds or ulcers, preserving them from the contact of foreign bodies and from cold, for cleansing wounds, for applying to them some topical medicament, as a thin ointment, &c. They should neither be so thick as to surcharge the part, nor so thin as to become too quickly penetrated by the pus.

The *Bourdonnet* [I. 2.] is a little mass of charpie rolled into an oblong form. It is usually tied in the middle: it serves to absorb the pus in a deep wound, and to prevent a premature union of its edges.

The *Tente* differs from the *bourdonnet* only in size; it is, however, usually rolled tighter. It is employed in diseases of the anus, and in those cases generally in which it is required to dilate an opening or canal. The *bourdonnet* is sometimes made of prepared sponge, or of gentian root.

The *Tampon* [I. 3.] is a mass of charpie varying in size, rolled between the hands into the shape of a ball: it serves for cleansing ulcerated surfaces and for stopping hemorrhage. For the latter indication the tampon is frequently made of the *boletus igniarius*, or puff ball.

The *Meche* [I. 4.] is an assemblage of filaments of charpie ranged parallel to each other, and doubled at the centre: it is introduced into fistulous openings, &c., upon the point of the probe, and effects their obliteration gradually from below upward.

The *Pelote* is a large tampon surrounded by a morsel of soft rag, the edges of the latter being brought together and firmly tied: it is occasionally used in the treatment of hernia, and in the compression of large vessels, in operations, accidents, &c.

Compresses are pieces of linen used for confining dressings of charpie or lint in their proper situation, preserving wounds from the action of the air, equalizing the surface of members, compressing the soft parts, &c. The linen made use of should be moderately fine, and free from darns or hems. Compresses are folded or otherwise arranged, in various manners, to fulfil these several indications. They are either square or oblong: of the first variety are,

The *Common Square Compress*, cut or rent sometimes of an oblong form, and then doubled so as to form a perfect square.

The *Perforated Compress*, [I. 5.] a square piece of fine linen rag, pierced with a considerable number of small holes; when applied, its under surface is smeared with a little of any simple ointment. It is employed to cover a large suppurating surface, as it allows the dressings to be easily removed, which would otherwise adhere. The perforated compress is used also in wounds which penetrate into a cavity, an opening of the cranium, thorax, abdomen, or to a wound of a large joint, as the knee. In cases of this character, the lint should always be applied over a cribriform compress: without this precaution, the fibres of it may enter the wound, and cause a tedious suppuration and even more serious symptoms.

The *Maltese Cross*, [I. 6.] formed by doubling a square compress twice, and then cutting it diagonally with scissors a certain distance towards its centre: it is applied over the stump of a member after amputation, in order to confine the dressings. Of the second variety are,

The *Common Oblong Compress*, [I. 7.] which is usually four times as long as it is wide; it serves to surround the trunk, or a member, for a variety of purposes.

The *Single Split Compress*—an oblong piece of linen split in the manner represented in the plate; [I. 8.] it is applied over the stump of the limb in amputations of the arm or thigh, to protect the soft parts from the teeth of the saw; the tails passing one on each side of the bone.

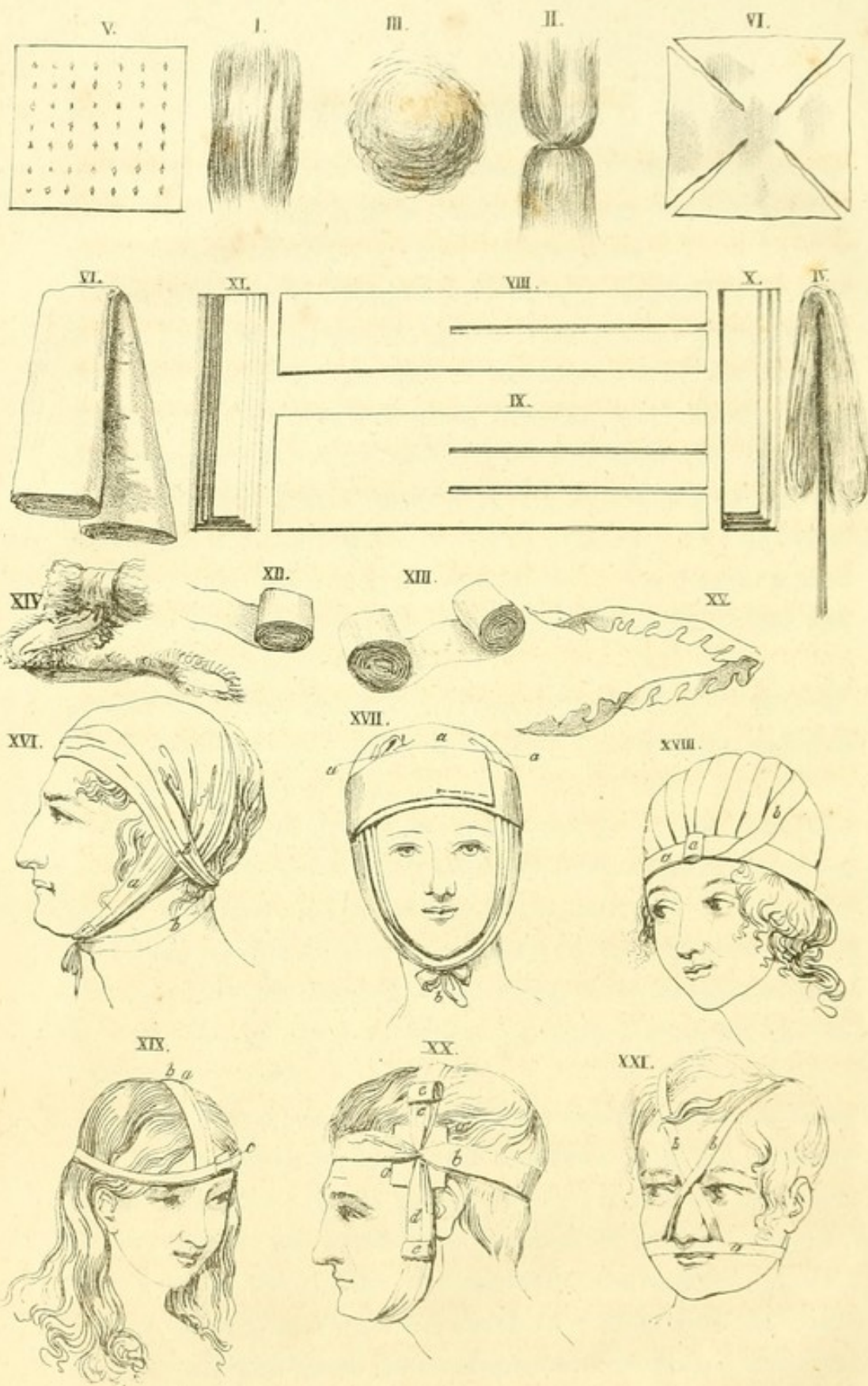
The *Double Split Compress* [I. 9.] differs only from the preceding in being split into three heads; it is employed with the same intention in amputations of the fore-arm and leg; the central head being passed between the radius and ulna, or the tibia and fibula.

The *Common Graduated Compress*; [I. 10.] a piece of linen folded several times upon itself; these folds ought to cover each other entirely.

The *Graduated Pyramidal Compress*; [I. 11.] to form this compress the surgeon takes a strip of linen about a foot long, and of a breadth proportionate to the extent of the parts to be submitted to its action; he begins by folding it backward and forward from one end to the other, each fold diminishing in breadth: the whole resembles in form, to a certain extent, a triangular prism.

Rollers are of linen, cotton cloth, or flannel; those of linen and cotton cloth are employed indifferently in all ordinary cases in which a roller is indicated; sometimes, however, flannel rollers are preferable: they afford greater warmth; they possess the quality of absorbing moisture freely; and their elasticity renders them peculiarly adapted to the treatment of rheumatismal and cedematous swellings, and even of fractures and dislocations, when they are followed by much tumefaction. Rollers are long bands rolled up into one or two heads; hence the terms, single and double-headed

PL. I.



roller. The parts of a single-headed roller [I. 12.] are, the *head*, of *cylindrical* form, the *initial* end, or free extremity, and the *end*, properly so called, which remains concealed in the cylinder, and eventually terminates the bandage: the parts of a double-headed roller [I. 13.] are, the heads (containing the ends), and the centre, called by the French the *plein*. No particular directions need be given for the rolling of a band, although it is of great importance that it should be done with care; when it is not sufficiently tight, it is unsteady in the surgeon's hands, often slips through the fingers, and is difficult to apply; on the contrary, when it is rolled firmly, it can be applied with the utmost promptitude and precision.

For a *Seton* [I. 14.] we use a narrow strip of soft linen rag, a few of the longitudinal fibres of which are drawn out from each side, leaving a jagged border, or a skein of silk or thread, or better still, as it is much more cleanly, a slip of India rubber, or gum elastic, about four inches long; it is used for exciting inflammation and suppuration, by being pushed through a fold of the skin, in a needle made for the purpose.

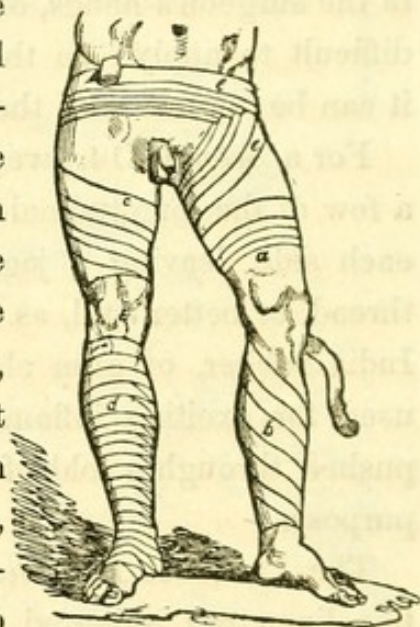The *Protective Bandelette* [I. 15.] is a very narrow strip of fine linen rag, smeared with simple ointment, and snipped along one border with scissors, as represented in the plate. It is used to surround a wound or ulcer, in order to protect its edges from the dressings which cover it, and which by their adherence would frequently disturb the process of cicatrization.

Bandages are used to confine in their proper places the dressings and other surgical remedies, and also those parts of the body which have been displaced, but which the surgeon has restored to their proper position.

Simple bandages are those which are formed by the application of the roller only, as the compressive bandage for

ulcers on the leg, that for the suppression of hemorrhage from the temporal artery, the capeline, &c.; and *compound* those which have a complex form of preparation, such as the T, the split-cloth, the eighteen-tailed bandage, &c. They have received particular appellations from their direction or form, and uses: hence they assume from the first the names of circular, spiral, reversed, and spica; and from the second, those of uniting, dividing, compressing, expelling, and retaining.

Of the first kind, that called the *circular* (*a*), is formed of horizontal circumvolutions, which almost entirely overlap each other. The *Spiral Bandage* bears its definition in the name; it is called by the French *rampant* (*b*), where the borders of the roller barely touch, and the circumvolutions are not very numerous: it is said by them to be in *doloires* (*c*), where the turns, somewhat less elevated, and consequently more numerous, overlap each other by about two thirds of the entire width of the band. In some cases, as for instance, in applying a roller to the leg, the turns cannot be laid down flatly, as the upper border will compress the salient part of the limb, while the lower one hangs loose. This inconvenience is obviated by reversing it at every turn, so that the superior border becomes the inferior, and the external face the internal: the hand should press lightly over each reverse to flatten and equalize it. This is the *Reversed Bandage* (*d*).



Two things are to be observed in applying the reversed

bandage ; one is not to unrol, in making the angle, more of the band than is absolutely necessary ; the other, to carry the angles upward in a perpendicular line, and always far from the part affected.

When the turns of the roller cross each other in the form of the Greek *lambda*, and leave the band one third discovered, the Λ 's being applied upon each other, the bandage is called *Spica (e)* : it is said to be ascendent or descendent, according as the doloires are directed toward the superior or inferior part of the limb.

Of the second kind, the *Uniting Bandage* is that which is used in incised wounds ; it should be adapted to their direction, according as they have a longitudinal or transverse course more or less complete : for longitudinal wounds it is constructed with a double-headed roller, the breadth of which ought to correspond to the length of the wound : a longitudinal slit is to be made in the middle, in order to allow the surgeon, when applying the bandage, to pass through it the head of the roller, and bring together the edges of the wound ; this bandage takes the form of the *spica descendens*. Or it may be made for such wounds with a single-headed roller, by dividing it at one end to a convenient distance into three tails, and making a little way beyond the termination of these, three longitudinal openings to receive them. The uniting bandage for transverse wounds consists of two strong linen bands of the width of the wound, and as long as the member ; one of these is to be split to about half its length into two or three tails or *bandelettes*, and the other perforated in the middle with three corresponding longitudinal openings.

The *Dividing Bandage* is used in the treatment of burns, and of wounds attended with great loss of substance, for preventing the formation of seams or unsightly cicatrices.

The *Compressing Bandage* is that employed for making compression in sprains, cedematous swellings, callous ulcers, varices, aneurisms, erectile tumours, &c.

The *Expelling Bandage* is employed in the treatment of ulcers, deep-seated abscesses, contused wounds, &c. It is composed of a roller applied over graduated compresses, upon the region wherein the pus or blood is lodged, to which it is desired to give issue: it prevents these fluids from insinuating themselves along the interstices of the muscles, detaching the skin from its adhesion to the subjacent parts, and forming sinuses.

Retaining Bandages are those which serve to confine dressings and displaced parts in their proper situation. This class includes bandages for hernia, and those for fractures and dislocations.

In applying a common roller for the construction of these bandages, we take the cylindrical part of it in the right hand, and hold the initial end between the thumb and finger of the left; then applying the external face of the latter upon some point of the circumference of the part, and retaining it there for an instant under pressure of the fingers of the same hand, we unrol the head and pass a few circulars about it, of moderate tightness, in order to fix it. The head in being unrolled should be held between the thumb and first two fingers, or between the thumb and index finger alone, so that it may turn upon its axis, and in this way it is much less liable to escape than when held in the palm: each time it changes hands, the one that receives it should unrol so much only as will allow of its arriving at the point at which it should pass into the other. A bandage is useless which does not give the most perfect support to the parts, maintain them in the position necessary to insure the fulfilment of the indication proposed, and exert on the member an equable compression:

for this, it sometimes requires to be moistened, which will cause it to fit more firmly and evenly; when applied too tight, or when the compression is not uniform, very serious consequences arise, such as œdematous swellings, and even mortification. Bandages should always be terminated opposite to the affected part.

In the department of surgery, which constitutes the subject of the present section, more perhaps than in any other, is the practitioner's reputation exposed to the severity of criticism; and on the degree of knowledge and dexterity which he evinces in this, to be attested by the greater or less acuteness of the patient's sufferings, the duration of the treatment, and the issue of the case, will be found to depend the favourable or unfavourable general opinion of his talents: the majority of people can only appreciate what is palpable to the senses in the practice of the healing art, and therefore it is not surprising that they exercise their privilege of criticism to its utmost limits here.

In commencing a dressing, the first care of the surgeon, when it *can* be done, should be to place himself on that side of the patient upon which he is to act. His movements ought to be entirely unrestrained: he begins by cleansing the parts with a sponge or dossil of lint, employing, when necessary, warm water or some appropriate lotion; if there be any hairs near the edges of the affected part they are to be carefully shaved off: the dressings should be laid on very lightly in all cases where compression is not indicated. That done, he places the patient in the position the least likely to fatigue him; and in certain cases, such as fractures, protects the limb from the pressure of the bed-clothes by some mechanical contrivance, as the fracture box. In the next dressing, his own position and that of the patient being attended to as above, he proceeds to uncover the parts,

moistening first of all the applications where they adhere to them, in consequence of the pus or blood becoming dried; when the same roller is to serve for the second or a subsequent dressing, he should unwind it from the part and rewind it at the same time. Should he have employed charpie, he is to take off the non-adherent layer of it with a pair of dressing forceps, and separate the rest in the process of cleansing the wound: this and the neighbouring parts being at length in a fit state to receive the dressings, he proceeds to their application in attending to the rule just laid down. As it is important not to expose a wound longer than is absolutely necessary to the action of the air, which may be considered in most instances injurious, it is always better for the surgeon to prepare beforehand the objects of which the dressing is to be composed, in order that he may be able to apply them in quick and regular succession.

No means ought to be neglected for protecting the nascent cicatrices; the albuminous couch which covers the granulations, and the pellicle which extends from the edges of the solution of continuity to the centre, should be always left undisturbed, as they are the first products of the process of cicatrization.

The necessary interval of time that should elapse between each dressing is wholly dependant upon circumstances, such for instance as an abundant purulent discharge, the nature of the applications, and in some cases, even the state of the atmosphere; some time is necessary after certain operations, as amputation, extirpation of tumours, &c., for the local inflammation to subside, which generally happens about the second day, when the dressings may be changed; but whenever pain, inflammation, mortification, or other serious accidents supervene, the dressings must be attended to immediately. Bandages upon fractures, luxations, and herniæ,

usually remain for a considerable time without derangement. The circumstances which demand the more frequent application of dressings, are putrid exhalations from suppurating surfaces during warm weather, the employment of medicated liquids containing aromatics, alcohol, &c.; of remedies which become rancid, as oils, ointments, &c., and those whose degree of action is relative to the duration of their contact, such as caustics.

When a wound or ulcer is in full progress of cicatrization it should not be disturbed oftener than is absolutely necessary. The surgeon, to use the words of La Faye, being only the minister of nature, ought ever to lend his aid at her demand, but be extremely cautious of disturbing her in her operations, by rashness, or an inconsiderate zeal.

SECTION SECOND.

WE proceed to describe particularly a few of the most important bandages.

BANDAGES OF THE HEAD AND NECK.

The *Four-tailed Bandage of the Head* [I. 16.] is formed of a strip of cloth, a yard long and six inches broad, split at each end to within three fingers' breadth of the centre. It is applied as follows: when the wound is on the forehead, the unsplit portion is adapted to it, and the two upper tails, carried posteriorly, are fixed at the back of the head; the lower tails are then fastened either upon the vertex or beneath the chin, as the surgeon may consider it more convenient. To confine a dressing upon the summit of the head, the posterior tails, *a*, are brought down and secured beneath the chin; the anterior tails, *b b*, after being carried to the nape of the neck and crossed, are fixed before the throat. In applying it to the nape of the neck, the upper tails are conducted over the forehead, from whence, after being made to cross each other, they are returned, and fastened at the occiput; the lower tails pass round the neck. This bandage, a very simple and convenient one, is of great utility in wounds of the head, as it can be applied over every point of this part, by merely changing its direction.

The *Six-tailed Bandage* [I. 17.] is formed of a piece of linen, a yard long and a quarter of a yard wide, split at each

end, to within three fingers' breadth of the centre, into three portions, the central being somewhat broader than the others. In applying it the surgeon first reverses the posterior tails upon the central, and the anterior upon the posterior; placing the bandage upon the summit of the head, he takes the central tails, *a a a*, between the thumb and fingers of each hand, and passing them along the ears, secures them underneath the chin, *b*, observing, however, to fold the edges of each tail inward so as to give it a triangular form, the base corresponding to the unsplit portion; the frontal tails are to be directed from the anterior to the posterior part of the head, where they should overlap each other; and the occipital tails at length brought forward and secured upon the brow. Its use is the same as the preceding, but it has the double advantage of not being liable to displacement, and of confining a larger dressing.

The *Capelina*, [I. 18.] *the bandage of Hippocrates*, is formed by a double-headed roller. The centre of the roller is placed upon the occiput. After two or three circles the rollers intersect each other upon the forehead and occiput; one of these being then reflected over the vertex to the forehead, the other is continued in a circular course. They next cross each other upon the forehead, when the first head is carried obliquely backward to the occiput, and reflected by the side of the other. The last, *a a*, is continued in a circular direction, but the first, *b*, is again brought over the head, and carried in this way backward and forward in *doloires* till the head is entirely covered. This elegant bandage serves to confine dressings upon the head, but is rarely now employed; the ancients used it to compress the heads of hydrocephalic patients.

The *T Bandage of the Head* [I. 19.] is formed by a band two yards long and two inches wide, upon which, at about

one third of the entire length, a bandelette, half a yard long and of the same width, is stitched at right angles. The band is rolled up into two heads of different sizes. Placing himself before the patient, the surgeon applies it to the middle of the forehead, the uppermost edge being that which corresponds to the vertical portion, *a*, of the bandage, in order that the latter, after traversing the vertex, may hang loosely upon the nape of the neck; he now unfolds the heads in passing them along the temples to the occipital region, where they cross the bandelette, which should be immediately reflected upward, *b*, and secured upon the brow by a few turns of the larger head, *c*. A double T may be formed by simply stitching a second bandelette upon the transverse portion, at a convenient distance from the first. Like all the foregoing, it is a retaining bandage; in the choice of these, the surgeon must of necessity be guided by circumstances.

The *Nodose Bandage*. [I. 20.] For this is used a simple band four yards long and two fingers' breadth wide, rolled up into two heads of unequal size. The unrolled portion being applied over the graduated compresses, *a*, that cover the wounded artery, the surgeon conducts the two heads before and behind, to the opposite temple, where he crosses them in order to return to the point of departure; he now gives them a turn or twist, *b*, which enables him to carry one over the summit of the head, and the other underneath the chin, *c d*, to the sound side, where they meet and cross as in the first instance; from thence they are conducted in the same course, *e e*, to the point of departure, and a second twist being effected, they are carried, for the third time, to the opposite temple, and for the third time also returned horizontally and knotted: being conducted finally, the one head over the vertex, and the other underneath the chin, the bandage is terminated by a few circulars of the long head.

It is used for stopping hemorrhage of the temporal artery, or of any of its branches; it may be conveniently replaced by a graduated compress and a single-headed roller, a few circulars of moderate tightness being all that is in general required to arrest the flow of blood.

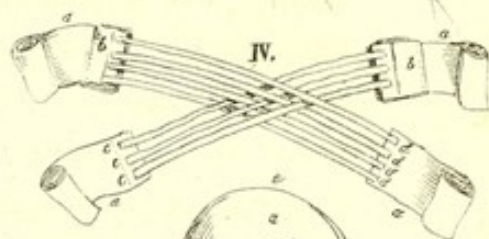
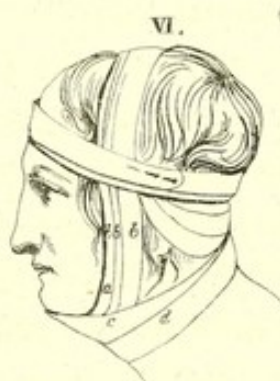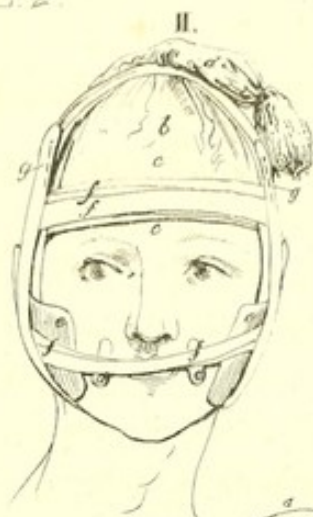The *Double T Bandage of the Nose* [I. 21.] is composed of a narrow band about a yard long and half an inch broad, upon the middle of which are stitched at right angles, and about three fourths of an inch apart, two others of the same breadth, and of about one half the length of the first. The middle of the transverse band, *a*, is placed upon the upper lip, the two others being directed upward; the extremities of the first are then conducted below the ears as far as the nape of the neck, where they are fastened by a bow; the vertical bands, *b b*, crossed at the root of the nose, are diverged upon the brow, and carried along the parietal bones to the transverse portion of the bandage, under which they are made to pass, and are reflected upward and secured. It is used simply to confine a dressing upon the nose.

The *Monocle* [II. 1.] is composed of a single-headed roller four or five yards long and two fingers' breadth wide. In applying it, two horizontal turns are first made round the forehead; the head of the roller upon reaching, for the second time, the nape of the neck, is carried under the ear of the affected side and obliquely upward to the eye, inclined towards its internal angle; pursuing the same direction, it crosses the forehead over the sound eye near the temple of the same side, to arrive again at the nape. Two or three more oblique turns being made in a similar manner, in the form of *dolaires*, open inferiorly, *a a a*, the bandage is terminated by a few horizontal circulars about the brow, *b b*. It is used to confine a dressing upon the eye; but, being liable to displacement, the head should be covered with a nightcap.

The *Bandage for the Hare-lip Operation*, which is figured in Pl. II. fig. 2, is composed as follows: two small pledgets to be placed under the extremities of the needles, *a a*;—a moderate sized roller;—a double-headed roller, three yards long and a finger's breadth wide;—a bandelette four feet long;—two graduated compresses of sufficient thickness to prevent the uniting bandage when applied upon the cheeks from touching the needles;—lastly, a four-tailed bandage. [I. 16.]

It is applied in the following manner: the patient's head being covered with a nightcap, *b*, which is fixed by a few circulars of the single-headed roller, *c c*, the centre, *d*, of the bandelette is applied upon the vertex, and the extremities allowed to hang down on each side of the face; an assistant covers these with the graduated compresses, *e e*, which he places opposite to the commissures of the lips, at the same time that he pushes the cheeks forward. That done, the centre of the double-headed roller is applied upon the forehead; its heads are directed toward the nape of the neck, crossed, brought forward horizontally, first over the compresses, then the lips, where they are crossed anew, and returned successively to the occiput and forehead, *f f f*. This is to be continued until the roller is entirely used, and its ends are fastened to the cap with pins: the extremities of the bandelettes are now reflected upward and pinned upon the top of the head, *g g*, and the whole apparatus is secured with the four-tailed bandage of the chin. [II. 5.]

M. Thillaye's Bandage for Hare-lip [II. 4.] is composed of four pieces of tape, each about two feet in length, and broad in proportion to the depth of the lip, *a a a a*; to the extremities of two of these bands, which may be denominated posterior, are stitched two small linen pledgets or cushions, *b b*, about three quarters of an inch square; while the two extremities of the others, or anterior tapes, are folded under



to have more solidity. Upon the extremity of one of these, are stitched three strips of extremely narrow riband, *c c c*, three inches and a half long, to connect it with one of the pledgets, to which also they are to be in like manner fastened, with a small space left on the free edges: four strips of riband, *d d d d*, similar to the first, are stitched to the extremity of the anterior tape of the opposite side, which, after being passed through the intervals of the first set, are fixed to the other pledget. By this disposition the bandelettes attached to either of the anterior tapes will be found attached to the pledget of the opposite side; the free extremities of the tapes are then rolled up and pinned. Two small graduated compresses, eight lines long by six wide;—two cushions, large enough to occupy the space comprehended between the zygomatic arch on each side, and the inferior maxillary bone;—a single-headed roller of moderate size;—and two bandelettes, one a foot, and the other a foot and a half long. The mode of its application is this: the single-headed roller is first of all passed horizontally round the patient's head, to afford points for the fixing of certain parts of the apparatus; after which, an assistant applies, at the distance of half an inch from the incised part, the graduated compresses, *e e*, which he retains in place, while the surgeon applies the central portion of the quadruple-headed roller upon the lip; the latter then carries the heads of the posterior bands, to which the pledgets are attached, in a horizontal direction over the cushions, *f f*, placed between the zygomatic arch and the lower edge of the inferior maxillary bone, as far as the nape of the neck; from hence, after crossing each other in changing hands, they are made to ascend obliquely to the forehead, where the ends, *g g*, are pinned to the circles of the roller. Taking now the anterior bands, he pulls them in opposite directions, and, by the aid of the

pledgets, brings the edges of the wound into contact; the heads of these two bands pursue the same course as those of the preceding, and the ends are fixed in like manner to the circles of the roller.

The bandettes serve to render the apparatus more secure; the first, *h*, passes along the sagittal suture, being attached before and behind to the circumvolutions of the roller; and the second being applied by its middle, *i*, to the chin, passes upward to the temples, where it is fixed to the same circumvolutions; a few stitches, *k k*, are inserted to connect it with the cushions, and the whole is retained by the four-tailed bandage of the chin.

The *Four-tailed Bandage of the Chin*. [II. 5.] For this bandage is required a strip of cloth, a yard long and six inches broad, split at each end to within three fingers' breadth of the centre. In applying it, the central part is placed upon the chin; the two upper tails, *a a*, are carried simultaneously toward the nape of the neck, whence, after changing hands, they are conducted obliquely upward and forward to the forehead and pinned; the lower tails, *b b*, are then directed upward, passing before the ears, and are crossed at the summit of the head, from whence they are returned and fixed beneath the chin.

This bandage is employed, not only for operations for hare-lip, but it forms part also of the apparatus for fracture of the lower jaw, and is used to retain a reduced luxation of the condyles of that bone.

The *Chevaster Bandage* [II. 6.] requires a single-headed roller five yards long and three fingers' breadth wide. We apply it by placing the initial end of the roller on the nape of the neck, and fixing it by a few horizontal turns about the head; the head of the roller is next carried beneath the ear opposed to the affected side, then beneath the chin, and

finally upon the fractured side of the maxillary bone; thence it is made to ascend, *a*, along the face and pass obliquely over the vertex to arrive behind the ear of the sound side; it pursues twice or thrice the same circular course in forming *doloires*, *b b b*, open toward the median line of the face; it is then conducted round the neck in order to embrace the anterior part of the chin, *c*; still conducted onward, but more obliquely in order to surround the neck, *d*, it gathers up the plaits of the first turn, and after being made once more to describe a vertical circular, it exhausts itself in horizontal turns about the head.

It is used in fractures of the neck of the inferior maxillary bone.

Observation.—Some graduated compresses are previously placed behind the angle of the jaw, in order that the turns of the bandage may exert a greater pressure, and consequently push the lower fragment forward.

Bandage for Transverse Wounds of the Neck. [II. 7.] This bandage requires a single-headed roller four yards long;—a band a foot long and three fingers' breadth wide;—a body bandage with thigh-straps;—and a compress a yard and a half long by eight inches wide, folded lengthwise in four. In applying it, a nightcap, *a*, is fixed upon the patient's head by a few horizontal turns, *b b*, of the roller, which are made to fix at the same time the extremities of the band, *c*, placed by its centre upon the inferior part of the chin. The body bandage, *d*, is applied round the chest and pinned. The centre, *e*, of the compress being lastly applied upon the upper and back part of the head, and secured by a few more horizontal turns of the roller, its pendent extremities are firmly fastened to the forepart of the body bandage, *f f*.

Bandage for Bleeding at the Jugular Vein. [II. 8.] This is composed of a ligature a yard and a half long;—a graduated

compress ;—a single-headed roller five or six yards in length and three fingers' breadth wide.

Application.—The patient's head being inclined to the side opposite to that on which the operation is to be performed, the graduated compress is laid upon the jugular vein at the lower part of the neck ; the surgeon then applies the centre of the ligature upon the compress, and carries the extremities one before and the other behind the chest, to the opposite axilla, where he ties them in a bow-knot.

The operation ended, he passes lightly round the patient's neck a few horizontal turns, *a a*, of the roller, to confine the dressing ; or a few such turns and three oblique circulars, *b b b*, carried underneath the opposite axilla, terminating always by one or two circulars about the neck. To avoid the ill consequences that might by possibility arise from the passage of air into the jugular vein, Baron Larrey recommends compression to be kept up until the wound is healed.

Bandage for Wry-Neck. [II. 9.] In this bandage we use a single-headed roller three yards long and an inch and a half wide ;—some soft compresses or a cushion to protect the axilla against the pressure of the roller ;—a napkin to surround the trunk. In applying it, the initial extremity, *a*, of the roller being directed toward the affected side, is placed upon the middle of the forehead and fixed by a few horizontal circulars ; these should be secured with pins. The remainder, *b*, of the roller is then carried behind the shoulder opposite to the side affected, and under the axilla, where the cushion ought to be previously placed, after being stitched firmly to the forepart of the napkin ; care being taken, however, to pull it with sufficient force to restore the head to its natural position. This bandage is used in cases of spasm or paralysis of the sterno-cleido-mastoidean and platysma-myoides muscles. It raises the head, brings round the face

forward, and when the affected parts have been operated on, opposes itself to the contractile efforts of the antagonist muscles.

Plate second, figure tenth, represents Professor Jörg's apparatus for the same purpose. This apparatus consists of a pair of leather stays and of a band or fillet for the head; on the centre of the forepart of the stays is a sort of pulley or groove, which can be turned round with a key, in one direction, but becomes fixed in the other, through the means of a spring; a band passes obliquely upward from the pulley to the fillet, to which it is attached behind the ear; when the band is drawn downward by the pulley, it lowers the mastoid process and approximates it to the sternum; it counteracts in this way the antagonist muscles, and restores the head to its natural position.

The *Body-Bandage of the Thorax with Scapulary* [III. 1.] is composed of a napkin, or large compress of the same form, folded lengthwise in three;—a band two feet long, split nearly to the end. In applying it, the napkin, *a*, is passed under the body, and the two extremities brought upward to the chest, upon which they are made to overlap each other; they are then pinned *b*; the unsplit extremity of the band being next fastened to the posterior part of the body-bandage, the tails are brought forward one over each shoulder, and secured in front, *c c*, to form the scapulary.

Use.—To confine dressings upon the chest; to furnish points for the attachment of parts of several other bandages: in dislocations of the head of the humerus it is made to embrace the limb and fix it against the thorax; the forearm in such cases should be suspended in a sling.

For the *Quadriga; or Crossed Bandage of the Thorax*, [III. 2.] we use a double-headed roller ten yards long and three fingers' breadth wide. The centre of the roller is

applied to the sternum; the two heads are carried, one under each axilla, to the back, where they are made to cross; returned from thence to the forepart of the chest, they change hands and are carried obliquely to the shoulders, intersecting each other in the form of an X: from the shoulders they are made to descend obliquely behind the back, each to the opposite axilla, and thus form a second X; they are now brought forward horizontally, and crossed upon the sternum, the upper one being reversed upon the lower, to avoid wrinkles; that done, they are conducted horizontally to the spine, crossed, and returned again to the sternum, where a second reverse is made in a similar way. These turns and reverses are repeated till the chest is covered, and the whole is terminated by one or two plain circles, *a a*, carried about the chest upon the last reverse. This bandage is used for the same purposes as the preceding, but as it is liable to get loose, many surgeons employ a body lacing instead of it.

The Inguinal Bandage. [III. 3.] One edge of a triangular piece of linen of convenient dimensions is rounded off to correspond to the upper and internal part of the thigh, *a*; to the base of this is sewed a band, *b*, of about a yard and a half in length, and to its summit a bandelette, *c*, two feet long. In applying it, the extremities of the band are carried round the pelvis on either side as far as the sacrum, whence they are returned and tied in a bow, *d*, above the pubes, while the bandelette, passing downward between the thigh and scrotum, is attached behind to the transverse portion of the bandage. It is used to retain dressings upon the groin of a patient confined in bed.

The Double T Bandage of the Pelvis [III 15.] is composed of a roller, *a*, of sufficient length to pass twice or three times round the pelvis, and three fingers' breadth wide;—two bandelettes, *b b*, each half a yard in length, and an inch in

breadth: the bandelettes are stitched to the roller at right angles, at about one fourth of its entire length. The mode of applying it is as follows: the transverse portion of the bandage is glided under the loins, that the vertical bandelettes may correspond to the median line of the posterior face of the pelvis; its extremities being passed round the body, are fixed with pins; the bandelettes are then brought under the perineum, crossed, and directed upward and outward to be fastened to the anterior part of the roller. Its use is to maintain a dressing or surgical apparatus applied to the perineum, anus, or vagina. It is sometimes necessary to fix a scapulary to this bandage, to prevent it from becoming displaced.

Suspensory, or Bag-Truss of the Scrotum. [III. 9.] The size of the bag can only be determined by the volume of the scrotum, to which it should be proportioned. It is ordinarily made from two pieces of linen or soft drilled duck, six fingers' breadth long and four wide: the pieces being laid together with exactness, two portions are cut out curvilinearly, as shown in Plate III. fig. 5, by the dotted lines: the divided edges from *a* to *b* being sewed together, a sort of bag is formed, which presents at the middle of its upper part an opening, *f*, through which the penis passes. A belt, *c*, two fingers' breadth wide, and rather longer than is necessary to describe the circle of the body twice, is then sewed along the upper edges of the bag: to the superior border of this belt, at about two fingers' breadth each way from the centre, are attached two small loops of tape or riband, *d d*, and about as far again from the centre two mould-buttons, *e e*.

Two bandelettes are, in the next place, fastened to the lower angle of the bag, each of about half a yard in length, with two button-holes near their free extremities.

The penis being engaged in the triangular opening, *f*, of the bag, and the scrotum perfectly enveloped, the belt is

carried round the pelvis, and being returned through the loops, *d d*, tied above the pubes, *g*; the two bandelettes are then made to ascend from the perineum along the inferior borders of the glutei muscles, to be buttoned to the belt in front, *e e*. The use of this bandage is to support and confine dressings upon the scrotum; to serve also for points of attachment to other apparatus. It is chiefly employed in swelled testicle, hydrocele, and irreducible scrotal hernia.

Hunter's Apparatus for retaining a Catheter in the Urethra [III. 6.] requires a bag-truss, with two small rings, *a a*, attached to the forepart, immediately above the ears of the bag; and two small tapes. From this apparatus the tapes are fixed by their centre, one to each ring of the catheter; the latter is then introduced into the bladder; after which one of the loose extremities of each tape is passed through the corresponding ring of the belt, and tied to its fellow in a bow, *b b*.

Mr. Hunter sometimes modified the apparatus in the following manner. When the catheter was introduced, he inclined the outer end downward so as to be nearly in a line with the body; he kept it in this position by means of the belt of a common bag-truss, to which were fastened two thigh-straps: bringing the latter forward round the thighs and alongside of the scrotum, he fastened their extremities to the belt at the part where the ears of the bag are generally fixed. The straps were each furnished with a small ring, just where they passed the root of the penis, and to these he connected the end of the catheter by a small piece of tape.

India-Rubber Apparatus of the French Surgeons. [III. 7.] In forming this, two small strips of India-rubber are first cut of different lengths, and formed into rings, by means of a few fine silk stitches; one of these should be of sufficient size to adapt itself to the circumference of the penis, and the other to that of the catheter. Four more strips are then cut of the

same material, of sufficient length to extend from the middle of the penis to about half an inch beyond the orifice of the urethra, and are attached by their extremities to the two rings. In applying the apparatus, the outer end of the catheter, *a*, is engaged in the smallest of the two rings, *b*; the catheter is then introduced into the bladder, while the large ring, *c*, is made to embrace the body of the penis. In order to prevent the catheter from slipping outward through the ring, the four longitudinal strips are bound to it firmly near the latter, with a bit of waxed thread or silk.

This apparatus may be conveniently modified, by employing only one ring and a small piece of narrow riband, thus: the surgeon ties the centre of the riband to the outer end of the bougie or catheter, and introduces the instrument into the urethra; he applies the two bandelettes thus formed along the sides of the penis, and passes over these the gum-elastic ring; the bandelettes are now reflected forward, and fixed to the extremity of the instrument by a bit of waxed thread. The India-rubber apparatus is preferable to all others, on account of its simplicity, and for the perfect manner with which it retains the instrument in the urethra.

Hull's Abdominal Supporter [III. 8.] consists of a pad, *a a*, of the form represented in the plate, attached by a metallic spring, *b*, to a cushion, *d*. When applied to the body, in the mode seen in fig. 9, it is fastened by attaching the straps, *g*, to the buttons, *e*. When necessary, a pessary can be connected with the instrument, and worn with it. The Abdominal Supporter has been found by many physicians to be extremely useful in many affections of the uterus.

Pessaries are instruments made of ivory, box-wood, or elastic-gum, which are introduced into the vagina, to sustain the parts in cases of prolapsus uteri, prolapsus vaginæ, &c. They vary in form; they are either annular; [III. 10, 11.]

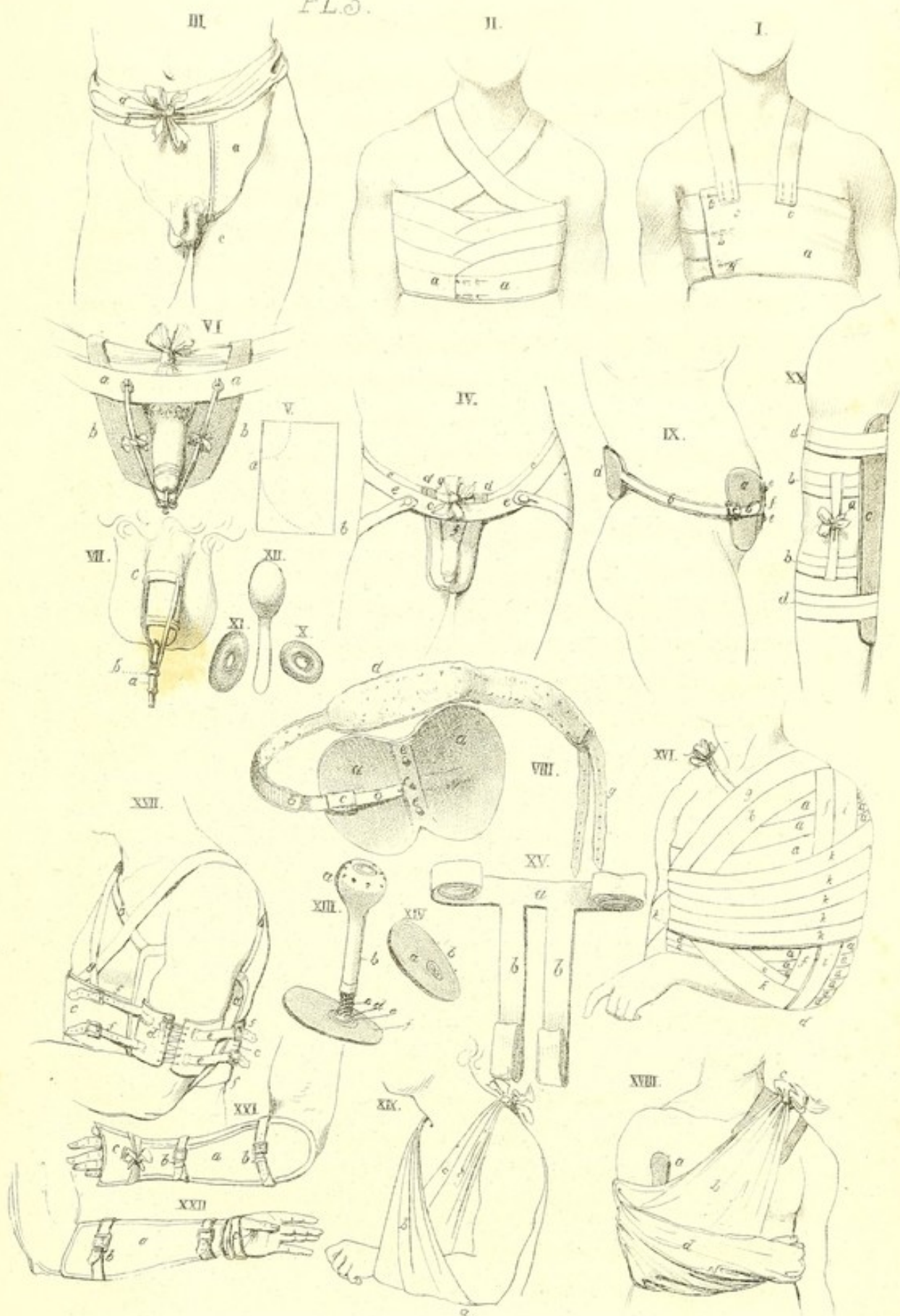
oval; [III. 12.] in the form of a figure of 8; or on a stem. [III. 13.] The last kind, Mr. Duffin's modification of the *Pessaire à Bilboquet* of the French, is usually made of box-wood and ivory; the head and upper portion of the stem, *a b*, are of box-wood hollowed, the former being slightly concave upon the summit, where it is perforated with small holes. The lower portion of the stem is of ivory, also hollowed; the upper end, *c*, of this last portion is turned spirally, in order to screw into the first; while the lower end, *d*, is in the form of a ball, which rests loosely in an ivory cup, let into a box-wood shield, *e f*. The ball-and-socket joint allows the instrument to conform itself to the movements of the body, while the whole receives a steady support, from the shield being confined to the perineum by a T bandage. The screw in the stem of the pessary, allows of the length of the instrument being adapted to that of the vagina.

Fig. 14, represents the under surface of the shield, *a*, with the opening of the canal of the pessary externally, *b*.

Application of Pessaries.—The bladder and rectum are, first of all, to be evacuated; the woman should then be placed near the edge of the bed, with the pelvis elevated by a pillow, and the thighs put sufficiently apart. The surgeon, having smeared over the pessary with a little pomatum or sweet oil, separates the labiæ externæ with the index and middle finger of the left hand, while with the right he gently introduces it into the vagina. In introducing an annular pessary, he directs it edgewise, and having fairly engaged it within the vagina, he introduces the index finger into its opening, to bring it to a horizontal position.

BANDAGES OF THE UPPER EXTREMITIES.

Figure of 8 of the Shoulder and Axilla. It is composed of a single-headed roller, seven or eight yards long and three



fingers' breadth wide. The mode in which it is applied is as follows: two circulars are first made round the arm of the affected side, passing from without to within, and from before backward. The head of the roller is then carried behind and above the shoulder, and conducted obliquely downward before the chest to the axilla of the opposite side, from whence it passes first behind the back, then over the shoulder, to cross the above descending turn and regain the point of departure; several turns of the roller are made in this way, to form a sort of figure of 8, and the whole bandage is terminated by a few circulars round the upper part of the arm.—It is used to confine dressings applied to the shoulder, or to the axilla: it is made to exert compression in the axillary space, by means of graduated compresses.

Figure of 8 for Fracture of the Clavicle. For this we require a single-headed roller, eight yards long and four fingers' breadth wide. The shoulders being held back by an assistant, in order to allow of the fragments of the bone being placed and maintained in contact, the surgeon fixes the initial extremity of the roller, by making a couple of circulars round the upper part of the arm of the affected side; he then carries the head backward to the opposite shoulder, round which he passes it, to return to the first, which he surrounds in a similar manner; these turns of the roller are applied alternately about each shoulder, and the end pinned, or secured by a few stitches.

Dessault's Bandage for Fracture of the Clavicle. [III. 16.] It is composed of two single-headed rollers, each from seven to eight yards long and three fingers' breadth wide;—a wedge-shaped cushion, formed of a piece of soft linen rag, filled with tow or oat-chaff; the cushion should be nearly as long as the humerus, and four or five inches wide at the

base; its thickness is usually about two inches and a half;—lastly, a few compresses.

The fracture being reduced, the cushion is placed, with its base uppermost, under the axilla, and the forearm flexed. The surgeon lays hold of the elbow, and carries it forward, upward, and inward, pressing it forcibly against the breast; the arm is now confided to an assistant, who holds it firmly fixed in this position with one hand, while with the other he supports the forearm; the ribands fixed to the base of the cushion, are carried one before, and the other behind the chest, obliquely upward, and tied upon the opposite shoulder, *c*.

The surgeon, in the next place, taking one of the rollers, applies its initial extremity under the axilla of the sound side, and fixes it by two horizontal turns about the body, which pass over the upper part of the arm; he then descends with it, in forming doloires, *a*, which should be drawn tighter as they approach the elbow; this is to be entirely surrounded, and the end of the roller pinned.

The compresses are now placed upon the fractured bone, and the surgeon applying the initial end of the second roller, also, under the opposite axilla, attaches it to the doloires of the first by a few stitches or a pin; the head of the roller is carried upward, and across the breast, *b*, to the compresses upon the fractured bone; from hence it is brought down behind the shoulder and arm, and being passed under the elbow, *d*, is conducted obliquely upward, *e*, to the point of departure: it is then carried obliquely upward over the posterior part of the chest to the compresses, and descends along and in front of the arm, *f*, to the elbow, which it embraces; from the elbow it ascends obliquely upward behind the chest to the axilla, and sets out again, as in the first instance, before the chest, *g*, to traverse the fractured part, the shoulder, the posterior face of the arm, to embrace

a third time the elbow, and be returned again before the chest, *h*, to the axilla; lastly, it passes obliquely upward behind the chest to the shoulder of the fractured side, in front of the arm, *i*, under the elbow, behind the chest to the axilla, and is exhausted in horizontal doloires, *k*. A few stitches should be inserted in various parts of the bandage, to prevent the doloires from becoming displaced, and the forearm should be suspended by a sling.

Baron Boyer's Bandage for the same. [III. 17.] *Composition.*—A wedged-shaped cushion for the axilla; a belt of webbing, or of linen quilted, about five inches wide, to surround the trunk, closing at the ends by means of straps and buckles; and a circlet for the arm, constructed of the same materials as the belt, which laces in front. Four straps are attached to the circlet, two on each side, near the uniting edges, while, to correspond with these, four buckles are fastened upon the belt, two before and two behind the arm.

Application.—The cushion, *a*, is placed in the axilla, and the ribands, *b b*, carried one before and the other behind the chest to the opposite shoulder, and tied; the belt, *c*, is then passed round the body, beneath the cushion, and a little above the bend of the elbow, and buckled posteriorly. Next, the circlet, *d*, is laced upon the arm, which is confined to the trunk by means of the straps and buckles, *eeee*, *ffff*, of the same; a scapulary, *g*, is sometimes added. While the elbow is thus firmly fixed to the side, the cushion tends by its resistance to push the superior part of the arm upward and outward. The elbow may be moved either forward or backward by merely tightening the anterior or posterior straps. This bandage acts on the same principles as that of Dessault, but is preferable to the latter, as well from the circumstance of its not being liable to become displaced, as from causing a more limited compression upon the chest;

the compression is capable of being regulated by means of the straps and buckles which unite the ends of the belt.

Handkerchief Bandage for Fractures of the Clavicle, &c. [III. 18.] *Composition.*—Two large handkerchiefs or pieces of strong linen of the same form ;—a cushion for the axilla ;—a soft pad for the opposite shoulder. In applying it, first, the cushion, *a*, is to be placed in the axilla, and the arm put into the proper position, with the forearm bent ; the doubled edge of one of the handkerchiefs, *b*, folded cornerwise, is then made to envelop the elbow, while the corners support the hand ; the posterior long extremity is carried up behind the back to the opposite shoulder, upon which the pad, *c*, is to be previously placed, and the anterior one brought up in front to meet it and be tied.

The second handkerchief serves to confine the elbow and forearm more securely by being carried round the waist, and fastened upon the opposite side of the trunk.

Sling for the Forearm. [III. 19.] In forming this we use a napkin or square handkerchief folded triangularly. The handkerchief thus folded is passed between the patient's arm and chest, the doubled edge corresponding to the wrist, and the corners to the elbow, *a* : the ends are then carried upward, the anterior one, *b*, on the side opposite to the affected limb, and the posterior one, *c*, on that corresponding to the injury, to be tied in a knot or bow, *d*, behind the neck. This bandage, used in fractures, &c. of the upper extremities to support the forearm, is preferable to the handkerchief bandage in all cases where it is not deemed necessary to keep the arm fixed in a state of immobility against the chest.

Sir Astley Cooper's Bandage for Fracture of the Olecranon Process [III. 20.] requires two strips of linen, each about half a yard long ;—two small rollers ;—a roller of a larger size ;—and a split deal splint, of a sufficient length to extend from the

margin of the axilla to about half way down the forearm. In applying it, the patient's arm is to be put into extension, and the fragment pressed down until it touches the ulna; a strip of linen is next to be applied upon each side of the joint, and one of the small rollers passed round the limb above, and the other below the olecranon, to secure them, *b b*. The extremities of each slip being reflected and tied together, *a*, the rollers are drawn nearer to each other, and the fragment of the olecranon kept in the closest apposition possible with the ulna. Lastly, the split deal splint, *c*, well padded, is applied along the front of the arm, and secured with a bandage, *d d*, which is to be frequently wetted with an evaporating lotion.

Amesbury's Splints and Bandage for Fractures of the Fore-arm below the Olecranon. These are composed of a narrow split deal splint of sufficient length to reach from the elbow to the tips of the fingers;—Mr. Amesbury's two convex splints;—cushions for the three;—lastly, a small band. In applying these, the arm is to be raised by an assistant, and turned so as to bring the bones in a proper line, and the hand in a position nearly supine. The surgeon then adapts the long convex splint, *a*, [III. 21.] to the back of the forearm, with its most convex part opposite the space between the ulna and radius. The short convex splint, *a*, [III. 22.] should be also placed in such a manner that the middle of its convexity is opposite the middle of the forearm. The assistant then holding these splints firmly upon the arm, the surgeon proceeds to place the deal splint along the line of the ulna. The straps, *b b*, *b b*, figs. 21 and 22, fixed upon the convex splints, are then to be buckled round the limb, in order to secure the splints and produce a moderate degree of pressure. The hand is to be secured to the back splint by the band, *c c*, figs. 21 and 22, and the arm placed in a sling.

BANDAGES OF THE LOWER EXTREMITIES.

Baron Boyer's Apparatus for Fracture of the Neck of the Femur [IV. 1.] is composed of a splint of particular construction for extending the limb;—a foot-support;—a kind of padded belt, which is buckled round the upper part of the thigh;—two common flat splints of the length of the limb, one for the anterior and the other for the internal part of the thigh;—and some cushions, tapes, and wadding.

The splint is about four feet long and three fingers' breadth wide. Along half the length of this splint runs a groove, about half an inch broad, the extremity of which is covered with iron; to this groove a screw is adapted, which occupies its whole length, one end of it being supported against the plate of iron covering the extremity of the groove, and the other made to fit a key by means of which it is to be turned. On the inside of this splint a contrivance for holding up the foot-support is fastened to the screw. The upper part of the splint is received in a sort of pouch or bag adapted to the external side of the thigh-belt. The sole or foot-support, which has two branches at its inferior part, is made of iron, and covered with soft leather. It is connected by means of a mechanical contrivance, as just mentioned, with the screw. To that part of the sole which is near the heel, is attached a broad piece of soft leather, which being split on each side into two straps serves for fixing the sole to the foot.

The thigh-belt is of strong leather, covered with the same material of a softer quality, and well stuffed with wool: near the place where its two ends are buckled together on the limb, a little leather pocket is sewed for receiving the upper end of the external splint.

Application.—The patient being properly disposed upon the bed, a piece of linen of the length of the limb and about three quarters of a yard broad, called a *porte-attelle*, or splint-

wrapper, is passed under the limb, lying upon the five ordinary tapes, *m m m m m*. In the next place, the thigh-belt is applied, the surgeon having previously surrounded the upper part of the limb obliquely with a cushion of wadding, four fingers' breadth wide, and the length of the thigh-belt, in order to moderate the pressure of the latter, and render it more supportable, *a a, b, c, d*. The hollows of the sole of the foot and the lower part of the leg are filled up with wadding or tow, and the foot-support, *e*, is fastened to the former by means of the soft leather straps attached to its under surface, which pass round the lower part of the leg; should, however, these straps appear insufficient to fix the iron sole to the foot firmly, an extra band, *f*, may be applied in the same manner.

That done, the surgeon proceeds to reduce the fracture, and afterwards adapts the upper extremity of the splint to the pouch of the thigh-belt, *g, h, i*; the foot-support being connected with the splint, the cushions, and the anterior, *k*, and internal splints are to be applied, and the whole fixed by means of the tapes, as in the ordinary bandages for fractures of the thigh. Lastly, by turning the winch, *n*, the iron sole is lowered, drawing the foot, to which it is attached, along with it; the superior extremity of the splint is thus pushed upward, and the member elongated to the necessary extent.

Amesbury's Apparatus for Fractures of the Upper Part of the Femur. [IV. 2.] This is composed of three pieces of board, of sufficient length to rest upon the sides of the bedstead, *b*, by which the apparatus itself is to be raised from the floor. One of these, *c c*, should be placed near the lower end of the frame, *a a*; the second near the lower end of the upper plane, *e*; and the third near the upper end of the frame. The middle and lower planes, *d d*, being raised to the proper

degree of elevation, rest upon the rack, *i*, of the frame, and are covered by a hair mattress, which should extend the whole length also of the plane, *e*, as they lie connected together. The mattress should be provided with a hole at the part which corresponds to the middle plane of the apparatus. A blanket and sheet, with a hole in each, to correspond to the hole in the mattress, are to be applied over this, and stitched round the edge, *l l l*, and round the hole in the centre, placed opposite the trap-door, *f*, in order to prevent them from getting into folds and incommoding the patient.

Application.—The patient is to be placed upon the mattress with the perineum opposite the hole in the middle plane of the apparatus; and the lower limb, *m m*, over the double inclined plane. The foot of the injured limb should then be fixed by means of a band, *n*, and a pad placed just below the external malleolus, to the foot-board, *k*, which will keep it upright, with the heel close down against the mattress. After which the middle plane, *d*, should be adapted to the length of the sound thigh, by the two portions of board of which it is composed being moved upon each other so as to elongate or shorten it as it may be found necessary; it is fixed by the screw *g*. The pelvis and limb may be thus kept perfectly quiet, and motion of the fragments totally prevented; continued extension may be made in the line of the thigh-bone, and retraction of the limb prevented, while neither inversion nor eversion of the foot can possibly take place. When the *neck* of the thigh-bone is fractured, there are two indications to be fulfilled, namely, to prevent the upper end of the femur from dropping from its natural line, and keep the fractured surfaces in perfect contact. The first is done by properly placing a small pad under the trochanter major, between it and the mattress; and the second by a padded splint, *q, r*, placed along the outer side of the thigh, and secured to the

pelvis and lower part of the thigh by two simple bands, *t*, *s*, which should be tied round the pelvis, so as to exert a sufficient degree of pressure to keep the fractured surfaces in contact. In fractures of the *trochanter major above the neck*, the limb should be kept in a position to allow of the great toe being in a line with the anterior superior spinous process of the ilium. Unless, in these cases, there is fracture also of the neck of the bone, it is unnecessary to keep up extension ; it suffices to apply the middle of a four-tailed bandage over a pad of lint just above the trochanter, two of the tails of which should be carried round the pelvis and drawn rather tightly, to prevent the bandage from slipping off, and the remaining two, also upon a pad, round the upper part of the thigh, and fastened as close as the case may require. The object of this bandage is to counteract the contraction of those muscles which have a tendency to separate the fractured surfaces. A splint should also be applied along the outer side of the thigh as in fracture of the neck ; its object is to keep the trochanter in a proper line with the shaft of the bone. In fractures *between the trochanters just below the neck*, the same position is necessary as in fractures of the neck of the bone ; the trochanter prevented from dropping by a hard pillow being placed beneath it, and the upper and lower fragments kept in a proper line by means of the side splint lightly applied. In fractures *below the trochanter minor*, the limbs ought to be placed over the double inclined plane, fixed at a right angle, and the injured limb extended to its natural length by the elongation of the middle plane. A common splint, well padded, and long enough to reach from the tuberosity of the ischium to the ham, should be placed under the thigh upon some straps, another upon the outer side, another upon the inner, and a fourth upon the front of the thigh. They should keep up a pressure, judiciously regulated,

upon the limb, by means of straps and buckles ; *u u*, represent the bedclothes thrown back.

Bandage of Scultetus for Fractures of the Body of the Femur. [IV. 3.] It is composed of five bands or tapes a yard long and two fingers' breadth wide, to be placed, three under the thigh, and the remaining two under the leg, (3.)—they should be lined along their middle third, to prevent them when tied from becoming twisted ;—a large piece of linen, to serve for a splint-wrapper, a yard wide, and a little longer than the limb ; —a quantity of bandelettes, three fingers' breadth wide, each long enough to make a circular and a half about the limb, and sufficiently numerous to cover it in its entire length in overlapping each other by about half or two thirds of their width, fig. 1, 2, 1, 3, 5, &c.;—two or three longitudinal compresses, several times folded, to surround lengthwise the injured limb : they should be saturated upon their application with an appropriate lotion ; they serve also for preserving the bandelettes from the contact of pus or blood ;—three splints : the external one should extend along the outside of the limb from the crest of the ilium to a little beyond the foot ; the internal one, along the side of the same, from a little below the pubes to the same distance ; and the anterior one from the upper part of the groin nearly to the bend of the instep ;—three cushions of oat-chaff, of the same length as the limb, to be interposed between the splints and bandelettes ;—lastly, a roller a yard and a half long to cover the foot, and a band to support the same.

Application.—The several objects of which the apparatus is composed being placed over the pillow upon which the limb ought to rest, the patient should be carried to the bed, the fractured limb extended along the middle of the apparatus, and the reduction proceeded with forthwith. The limb having resumed its natural length, the assistants are still to continue

the reductive efforts, while the roller is applied upon the foot, and the wetted compresses placed along the thigh. That done, the bandelettes are applied, in succession, from the lower part of the leg to the upper part of the thigh; for which purpose the surgeon takes hold of the extremity nearest himself of the last bandelette, an assistant, opposite, fixes the other extremity, and extends it completely across the limb in the form of an oblique circular; taking next the extremity held by the assistant with one hand, while with the other he maintains the first firmly in position, he applies it in like manner obliquely round the limb, to intersect the first upon its forepart: the extremities should always be carried underneath the limb, and if too long, a portion should be cut off or carefully folded under.

When the bandelettes are all applied, the splints, fig. 4, *a*, are rolled up in the longitudinal borders of the wrapper to about two fingers' breadth from the limb, and then, being a little elevated, the two cushions, fig. 4, *b*, are carefully introduced. The third cushion is then applied along the forepart of the member, and above that the third splint, fig. 4, *c c, d d*. The assistant now embraces with both hands the entire apparatus, while the surgeon fastens the tapes, commencing by the one that corresponds to the middle of the thigh, knotting them on the outer side of the limb, *e e e e e*. Lastly, the middle of the band is applied upon the sole of the foot, and the extremities, after being crossed upon its forepart, are pinned to the lower part of the apparatus, *f*.

Mr. Amesbury's Apparatus for Fracture of the Middle and Lower Thirds of the Femur.—Composition.—The apparatus is divided into three portions, independent of splints and straps, one of which is for the thigh, fig. 5, *a*, another for the leg, *b*, and the third for the foot, *c*. There are two thigh-pieces made to each apparatus, one of which is bevelled off

at the lower end to the right and the other to the left, so that when one of them is fixed to the leg-piece, which is hollowed out to receive the back of the leg, the leg and thigh-piece together are adapted to the natural line of the right limb; and when the other thigh-piece is joined to the leg-piece, they are adapted to the natural line of the left limb; this arrangement Mr. Amesbury considers necessary, in order to preserve the figure of a perfectly-formed limb, which is not straight, but turns inward a little at the knee. The leg and thigh portions are connected by means of a little steel or brass pin, *d*. Behind the apparatus is a steel bar, *e*, coated with brass, and fixed to the back of the leg-piece. To the upper end of this bar is fixed what Mr. Amesbury calls a brass foot, fig. 6, *f*, to which is attached a bolt, acted upon by a spring. There is a hole in the centre of this brass foot, which is traversed by the bolt in the transverse direction. At the back of each thigh-piece is a rack, *g*, with several projections, each having a hole bored through the middle, for the purpose of receiving the bolt attached to the brass foot-piece. The foot-piece is connected with the steel bar in such a manner as to be easily fixed upon either of these projections. By being fixed upon either of these, except that nearest the leg-piece, the leg and thigh-pieces become fixed together so as to form a double inclined plane; see fig. 5; the angle of this may be varied at pleasure, by altering the position of the brass foot-piece from one of the teeth or projections of the rack to another. At the upper end of the thigh-piece is a sliding brass plate, *h*, fig. 2, so adapted that it may be applied to either of the thigh-pieces at pleasure. This contrivance allows of the thigh part of the apparatus being adapted to thighs of various lengths. The upper end of this plate is turned off, so that, when it is properly padded, it may bear against the tuberosity of the

ischium without injuring the integuments. At the back of the sliding plate are placed a couple of brass bars, *ii*, which answer the double purpose of rendering the sliding plate more secure when it is fixed upon the thigh-piece, and of preventing the pelvis-strap, to be noticed presently, from slipping from the apparatus. There are little studs, *l*, placed at the back of the apparatus, for the purpose of receiving the straps by which the apparatus is confined to the limb.

The pelvis-strap is of leather, furnished with a sliding pad, and is long enough to reach round the thigh and round the pelvis. Three short splints are also required, to be placed upon the thigh.

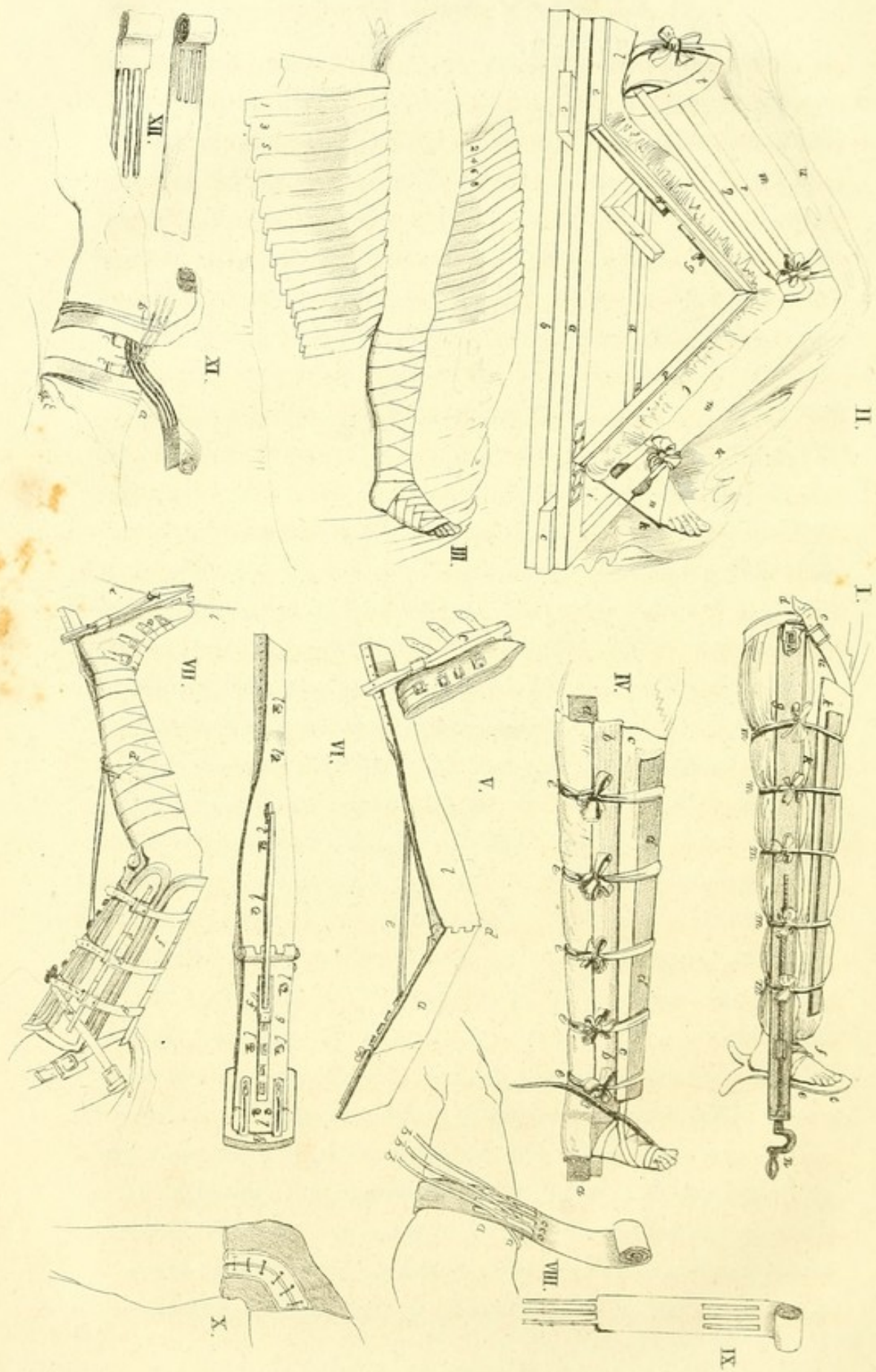
Application.—The apparatus and splints being properly padded, the surgeon commences by placing the pelvis-strap between the bars and the plate or sliding portion; he then applies a single-headed roller, *d*, fig. 7, spirally about the leg, from the toes to the bend of the knee. In the next place, an assistant takes the small of the leg in one hand, and places the other under the knee to raise the limb, and at the same time to keep the knee bent while the surgeon places the apparatus under it. When the limb is properly placed, the shoe, *a*, previously padded in the inside, is buckled to the foot, while the foot-board, *b*, and leg-piece are placed at nearly right angles; this gives the foot support and steadies it. The leg is to be supported along the whole of its under surface, in order to give it an equal bearing upon every point of the apparatus, and this is done by means of tow or wadding, *c*, placed under the small of the leg, between the long pad and the leg-piece. The leg is fixed upon the apparatus by a roller carried spirally round both, from the ankle to the bend of the knee.

To confine the fractured parts in their natural position, the assistant takes the apparatus and the knee between his

hands, and extends the thigh gradually in a line with the thigh-part of the apparatus, which the surgeon supports against the back of the thigh. When the surgeon has fitted together the fragments of the bone, he applies the splints; the first, *e*, on the outer side of the thigh, from the great trochanter to the lower part of the outer condyle; the second on its inner side, reaching from the pubes to the lower part of the inner condyle; and the third, *f*, upon the forepart of the thigh, from a little below the superior anterior spinous process of the ilium, to the base of the patella. The splints are kept in place by the straps, *g g g*, fixed to the studs on the back part of the apparatus. Lastly, the pelvis-strap, *h*, is to be carried round the limb, under the strips of leather of the splints, and made to cross on the outer side, while the *buckle-end*, with the sliding pad, is carried round the pelvis and made to meet the other end in front, where it should be buckled. The tapes, *i i*, serve for fixing the lower part of the apparatus to the foot of the bed.

The *Uniting Bandage for Longitudinal Wounds of the Thigh* [IV. 9.] is formed as follows: one end of a piece of linen, of sufficient length to make three or four circumvolutions round the member, and of a breadth correspondent to the length of the wound, is divided so as to form three bandelettes about an inch broad, and long enough to embrace three fourths of the circumference of the limb; at a convenient distance further on, are made three longitudinal perforations, opposite to, and of the same breadth as the bandelettes. The remainder of the band is then rolled up;—two common graduated compresses also are required.

In applying this bandage [IV. 8.] the undivided portion, situated between the bandelettes and the perforations, being adapted to that part of the limb which is exactly opposite the wound, the graduated compresses, *a a*, are placed one



on each side of the latter, at the distance of about three fingers' breadth from its edges; the bandelettes, *b b b*, are next passed through the corresponding perforations, *c c c*, and the surgeon brings the edges of the wound in contact, by drawing the extremities of the band in contrary directions; the rest of the application consists in firmly securing the bandelettes by some circulars, made with the remainder of the strip of linen.

This bandage may be used in longitudinal wounds of the upper as well as the lower extremities. It may generally be replaced, however, with advantage, by strips of adhesive plaster, over which a common dressing should be applied, and confined by a single-headed roller; the strips should be applied about a quarter of an inch apart, where great closeness is required, or otherwise they may be more distant; this is an extremely necessary precaution, as the confinement of blood, and still more of any extraneous body, would be liable to occasion the formation of an abscess, that would disunite the parts.

The *Uniting Bandage for Transverse Wounds of the Thigh*. [IV. 12.] For this bandage we require a piece of stout cloth of the same width as the wound, and as long as the member, which is to be divided to nearly half its length into three tails or bandelettes; another and similar piece of cloth should be perforated in the middle, with three corresponding longitudinal openings. The remainder of the objects consists of two common graduated compresses, and two single-headed rollers, one six and the other nine yards long, both three fingers' breadth wide.

In applying it, [IV. 11.] the limb is put into complete extension; the surgeon applies the initial extremity of the longest roller upon the side of the pelvis corresponding to the wound, fixes it by two or three horizontal circulars, and

conducts the head of the roller along the thigh in *dolaires*, *a*; that done, he extends the perforated band along the limb, observing to allow the upper extremity to pass a few inches beyond the last turn of the roller, and the openings to lie upon the wound; he fixes a portion of the upper extremity, by means of two or three circulars carried round the limb, at some distance above the solution of continuity, and reflecting what remains of it downward, secures it by a few more turns. Confiding now the head of the roller to an assistant, the surgeon takes the remaining roller, fixes its extremity below the knee by a few circulars, and carries the head spirally to the lower part of the thigh, *b*; next, placing the split band along the limb, the tails directed toward the wound, beyond which they should extend by about three fourths of their entire length, he fixes its lower, or undivided portion, in the same manner as he had done the upper portion of the first band, and resigns the head to an assistant. Lastly, having applied the compresses, *c c*, one above, and the other below the wound, he passes the bandelettes through the corresponding perforations, and draws these free extremities of the bands in contrary directions, in order to approximate its edges; when he considers the edges of the wound to be sufficiently in contact, he extends the bands along the limb, and while the assistants maintain them firmly fixed, confines them with what remains of the two rollers. In cases where this bandage is insufficient to maintain the contact of the edges of the wound, in consequence of the movements of the patient, a splint ought to be placed along the limb, on the side opposed to the injury. It may be employed in all similar wounds of the upper and lower extremities, in cases of fracture of the patella and os calcis, and of rupture of the tendo Achillis.

Weiss's Elastic Knee-Cap [IV. 10.] is made of an elastic tissue lined with India-rubber; lacing at the side, as seen in

the drawing. It is much preferable to the common figure of 8 bandage, where compression is required.

Amesbury's Apparatus for Fractures of the Patella [V. 1.] is composed as follows: two pads to be placed, one above and the other below the knee, each about six fingers' breadth wide, and long enough to pass halfway round the limb; the pads are connected by two short straps and buckles;—five straps, with buckles, to pass round the limb, three above and two below the knee, in order to fix them;—a long strap, to pass from the upper pad, to which it should be fastened, along one side of the leg and under the foot to meet a buckle attached to the same pad on the other side;—a properly-padded straight splint to extend along the thigh and leg:—and lastly, a handkerchief, or a band about three quarters of a yard long.

Application.—A shoe is first to be applied upon the patient's foot, furnished at the sides with two small loops, *ff*, and the leg extended upon the padded splint, *e*, after which the pads, *a*, *b*, are placed above and below the knee, and secured, together with the splint, by means of the five straps mentioned above; the fragments are then to be brought into close contact by means of the short strap, *c*, and the long strap, *d*, which should pass through the loops of the shoe. The lower part of the splint is maintained against the leg by means of the handkerchief or band.

Amesbury's Apparatus for Fractures of the Leg. [V. 2.] This apparatus is composed of a thigh-piece, properly shaped to receive the back of the thigh, having a pair of lateral splints connected with it, and some studs for the retention of straps;—a leg-piece, immoveably connected to the thigh-piece at an angle, and hollowed out for the reception of the back of the leg;—a foot-piece, which may be so shifted as to adapt the leg-piece to the length of the leg. The

foot-piece should not rise higher than is necessary to form a right angle with the leg-piece when connected with it. There are some holes in each side of this, and a strap is attached to it, bearing upon one end a buckle;—a shoe, with a wooden sole, for the reception and retention of the foot, to which are attached two straps for connecting it with the foot-board; the shoe is supported by a foot-strap, which, when in use, extends from one side of the thigh-piece round the lower part of the foot-board, where it is passed under a strip of leather placed there to keep it in its place, and then carried up to the opposite side of the thigh-piece, where it is buckled.

The apparatus ought to be adapted to the sound limb in cases of simple fractures of the leg, and well padded; a small concave pad too should be placed on the inside of the heel of the shoe, and another pad upon the sole. Two side splints are required, the outer one extending from the foot-board to the upper part of the outer condyle of the femur, and the inner one from the foot-board to the inner condyle;—also a split deal shin-splint; and in cases of oblique fracture a thin pad to be applied upon the instep, covered with a piece of pasteboard, a little wetted, which, when dry, serves to equalize the pressure and keep the instep easy.

Application—in the first or inflammatory stage.—The shoe, *a*, containing the heel and sole-pads, should be carefully placed upon the foot; the instep-pad should then be placed upon the instep, and the shoe closed over it, and closely confined to the foot by means of the buckles and straps attached to it for that purpose. An assistant should then place one hand under the knee, and, taking the foot in the other, raise the fractured limb, bringing it round so that it may rest on the heel. When the limb is raised, the surgeon places the

apparatus under it, and brings the angle of the same opposite the bend of the knee, directing the assistant to lower the limb upon it.

The surgeon now fixes the shoe, *a*, to the foot-board, *b*, by means of the straps attached to the sole. By the aid of this shoe he is enabled to raise or lower the foot according to the length of the heel or thickness of the calf, so as to bring the lower portion of the fractured bones into a proper line with the upper, as far as respects any angular projection backward or forward. A padded splint should be placed upon the front of the thigh, and the whole of the thigh-part of the apparatus fixed to the thigh by means of the straps, *c*. That done, the foot-board should be raised nearly to a right angle with the leg-piece, and fixed in this position by the foot-strap, *d*, care being taken that the heel does not bear against the sole of the shoe. The fractured ends should next be noticed; and if the foot requires to be raised or lowered, it may be done by means of the strap which confines the shoe to the foot-board.

The part of the pad, *e*, which lies under the small of the leg, should be raised and supported in close contact with it by means of tow placed between the pad and this part of the apparatus, so that the whole length of the back of the leg may have an equal bearing upon the apparatus.

The lateral splints are next to be applied, the longest upon the outer side of the leg, and the shortest upon its inner side. The lower ends of these splints should be fastened to the foot-board by means of narrow tapes passed through the holes at the sides, and the upper end kept close to the leg by the circular strap, *g*, passed round the limb over the splints and the apparatus.

With respect to the position, the limb thus fixed should be placed with the apparatus resting upon the heel; the two

planes should be connected, as seen in the plate, by means of the steel bar, which forms part of the apparatus for fractures of the thigh, described page 42, and the whole steadied by tapes attached to the foot-board, and passing off from thence to the sides of the foot of the bed. Surgical applications may be made by unbuckling the circular leg-strap, and throwing back the side splints.

When the inflammation is subdued.—Some strips of soap-plaster, each about an inch and a half wide, should be applied with very moderate tightness round the limb, and sufficiently close; they should pass from the ankle to a considerable distance above the fracture. The ends should be crossed on the sides or front of the leg, and cut off, so as to be easily turned back, when it is necessary to observe the state of the skin. Some strips also, or a short roller, should be passed round the foot to prevent œdematous swelling in that part. When this is done, and the side-splints reapplied, the shin-splint should be properly adjusted, and the whole leg-part of the apparatus supported by three circular straps and buckles.

The cross bar may be now removed, and the apparatus furnished with a sling or thong of leather fixed to the lower end of the leg-part of the apparatus; by means of this, the limb may be moved passively at pleasure; the patient may recline upon a sofa, or rest his leg upon the seat of a chair. He may walk, too, with the assistance of crutches, passing in this case the sling over the neck, as in the ordinary way; the movements of the limb, however, should be always passive, and never by the action of its own muscles. In a fortnight or three weeks' time, according to circumstances, the foot-board should be shifted a little higher up the leg-piece, to press the fractured ends together, and hasten their consolidation.

Oblique Fractures.—In these cases, extension must be made in the following manner:—the thigh-piece of the apparatus must first of all be pressed up closely against the back of the thigh, and the foot-board shifted down, so as to make the space between the foot-board and the thigh-piece longer than the leg; an assistant then grasps the foot and ankle in his hands, and makes gentle extension in the natural line of the bone, so as to bring the fractured parts into proper adaptation; when this is done, the surgeon keeps up the extension by buckling the strap, which is fixed transversely to the shoe, round the foot-board. Great care must be taken that the broken extremities unite in the relative position which they naturally occupy; for this purpose auxiliary pads and rollers must be judiciously applied, according to the bone affected and the nature of the obliquity. The fullest particulars relating to this part of the treatment will be found in Mr. Amesbury's "Practical Remarks on the Nature and Treatment of Fractures of the Trunk and Extremities," published in 1831.

Dupuytren's Bandage for Fractures of the Lower Extremity of the Fibula [V. 3.] is formed with a cushion, about two thirds filled with oatchaff, and of sufficient length when doubled to extend from the malleolus internus to the knee;—a strong splint two feet long and three fingers' breadth wide;—and two single-headed rollers, from four to five yards long.

Application.—As soon as the fracture is reduced, the wedge-shaped cushion, *e*, with the base directed downward, is to be applied along the inner side of the leg; the splint, *b*, is next to be applied on this, and made to extend about four inches beyond the sole of the foot; these two portions of the apparatus should be confined to the limb, *a*, above, by one of the rollers passed in circulars round it, *c*, from just

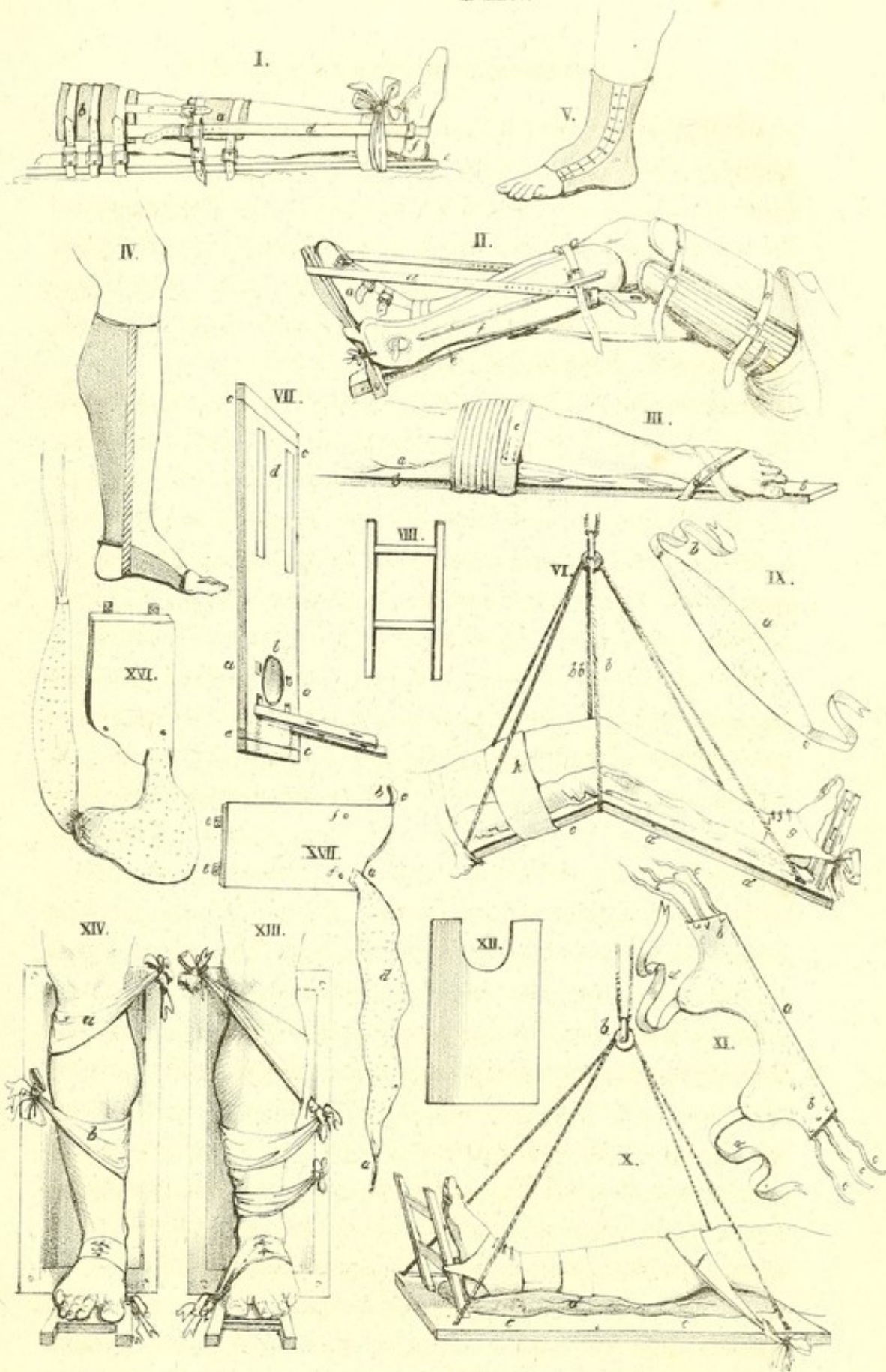
below the knee to about halfway down the leg, and below, by the second roller, carried round the foot and instep in the form of a figure of 8, *d*. Care should be taken in applying the second roller to draw the foot inward, toward the splint, and maintain it firmly in the state of adduction. The posterior part of the limb should repose, in a state of demi-flexion, upon pillows made to form an inclined plane.

Schoolbred and Renwick's Metallic Elastic Laced Stocking [V. 4.] is employed for the compression of varicose veins, and also for the support of tender and extensive cicatrices of these parts, being much preferable to the ordinary rolled-bandage; it accommodates itself perfectly to the form of the leg, exerts an equal compression throughout its whole extent, and is not liable to become deranged.

Weiss's Elastic or India-rubber Gaiter [V. 5.] is used for sprained ankle, or weakness of the ligaments of the lower part of the leg and foot.

The Suspension Apparatus of M. Sauter, for the Treatment of Fractures of the Lower Extremities, consists of a straight board, furnished with a cushion, and suspended, something in the manner of a scalebeam, from the ceiling or top of the patient's bed, by means of cords; its object is to give support to a fractured limb, and allow of lateral movement.

For constructing it, we require a thin board, proportioned in length and breadth to the size of the limb; [V. 7.] it should be a little broader, and a few inches longer than the latter. Thus, for fractures of the leg, it should extend from the bend of the knee to three or four inches beyond the heel. This board should be covered by a cushion, fig. 10, *d*, of its own magnitude, made of oatchaff, bran, cotton, hair, tow, or in short of anything that could answer the same purpose, and be readily procured; the cushion should have sufficient firmness to afford a plane of some resistance to the



limb, and yet be capable of moulding itself exactly to its form. A hole, fig. 7, *c*, should be pierced near each of the angles of this board, for the passage of the suspension cord. Each end of the cord should be introduced through the corresponding holes at one extremity of the board from below upward, and, after being drawn to the same length, passed from above downward through the holes of the other extremity, and firmly knotted. The cord will thus form two parallel bows of equal length, which, by being held at the middle, will suspend the board as a perfect plane, or allow of its receiving more or less inclination either way, according to the distance, on one side or other of the centre, upon which the point of support is made to act. The support here spoken of consists of another cord, one end of which should be carried through a staple driven into the ceiling, above the injured limb, and the other made to pass under the collected bows. By pulling, therefore, in contrary directions the extremities of this second cord, the board may be elevated to the necessary degree; and by knotting them, the elevation thus obtained steadily preserved.

Instead of the staple, it would be better to employ a pulley. A pulley would likewise be found more convenient for the connexion of the perpendicular and transverse cords, as seen in fig. 10, *b*. The first of these pulleys would afford greater facility in the elevation of the board, while the second would serve to give it the due degree of inclination, with but little effort, and without occasioning the slightest shock.

As the free sliding of the cords would be detrimental to the treatment of the case, from the circumstance of the board being liable to alter its position by the least movement of the patient, it is advisable to tie the two bows together near the pulley, and introduce between the latter and the ligature a small splinter of wood, which will naturally prevent the bows from retrograding.

These preliminary arrangements, with the exception of the introduction of the splinter, should be made before the limb is placed upon the board, in order that it may be immediately elevated when the former is applied upon the cushions. Care also should be taken to arrange beforehand the patient's bed, by pressing it down at the part corresponding to the apparatus, in order that his horizontal movements may not be interrupted. As soon as the limb has been elevated to a certain height, it is advisable to place a pillow underneath the board, which should remain there till the fracture is reduced, and the position, &c., of the limb conveniently arranged. The suspension apparatus, when isolated, yields to the slightest impulse imparted by the patient in his movements, occasioning neither shock nor pain.

The facility which patients have of moving themselves in this way is so great, that, as M. Mayor has remarked, they may be seen changing their position with the utmost facility, obeying, through means of the common utensils, the calls of nature, and even gliding upon another bed of equal height.

Nevertheless, as may be readily conceived, it would be imprudent to permit them to indulge in any inconsiderate movements, as this would occasion and keep up in the osseous fragments a mobility that would impede their consolidation. When it is found impossible to suppress the indulgence of such imprudent movements, the surgeon must have recourse to the bandage of Scultetus, with the aid of splints, or else the pasteboard, to be spoken of farther on.

It has been already said, that in fractures of the leg, in which the suspension apparatus presents the most advantages, a simple board, extending from the bend of the knee beyond the heel, is sufficient. A simple board, arranged in the same manner, and which, departing from the tuberosity of the ischium, would pass also beyond the heel by a few inches,

would be equally sufficient for a *fracture of the shaft of the femur*, if it was considered proper to place the limb extended upon its posterior face; but for those surgeons who prefer the demiflexion of the leg upon the thigh, and the latter upon the pelvis, the following apparatus becomes indispensably necessary. Two boards must be procured, the one precisely similar to that called *tibial*, of which mention has been already made, represented fig. 7; the other *femoral*, *c*, fig. 6, extending from the ham to the ischiatic tuberosity, and articulating with the preceding, either by means of hinges, *e e*, fig. 17, or simple ribands, which should pass through the corresponding holes, with which the extremities of these boards are pierced, and be knotted underneath. The suspension of this double inclined plane is effected in the same manner as the simple tibial board, with this difference only, that the two bows are extended from the superior extremity, fig. 17, *ff*, of one of these boards, to the inferior extremity of the other. But in order to form the two inclined planes, which are to support the limb in demiflexion, a small cord, *b b*, should be passed from below upward, through one of the holes of the upper extremity of the tibial board, fig. 6, across the point of support, and thence, from above downward through the other hole of the same extremity, under which the two ends should be knotted together. In this way, the extremities of the two boards, which correspond to the bend of the knee, may be made to describe an angle, more or less acute, according as the limb is required to be placed in a greater or less degree of flexion.

When position alone is insufficient to maintain the fractured extremities of the bone in apposition, and it is indispensably requisite to exert continued extension, or, in short, when more solidity is required to be given to the apparatus, the femoral board should be shaped out at its internal and

superior angle, in the manner represented in fig. 17, and furnished with a belt, which will be spoken of farther on.

The boards, thus arranged, are not only useful in fractures of the shaft of the femur, but also in the treatment of fractures of the neck of that bone; they fulfil perfectly, in presenting two inclined planes for the flexion of the thigh and leg, the indication of the pillows of Sir Astley Cooper, which are often inefficient, and the machines of Sir Charles Bell, Earle, and Delpech, which are much more complicated, and consequently of less easy and general application. In short, one of the advantages for which the suspension apparatus deserves to be made known, is its simplicity, and its possibility of being constructed at all times, and in all places. "In country practice," says M. Mayor, "in isolated districts, every portion of this apparatus may be readily procured without occasioning the least embarrassment to the surgeon."

"For myself, I may say," continues this gentleman, "I have never experienced the slightest difficulty. I have sometimes substituted any common bands, when the proper cords failed me; I have nailed these to the board when I have had no instrument to bore the ordinary holes; I have employed nails for screws, and tow, wool, or rags, to form the directing bands (*bandes de direction*); these last materials, as also bran, sawdust, moss, and even soft hay, have served me in constructing my cushions for the boards; the bark of a tree, moistened leather, the binding of an old book, have supplied the place of pasteboard; rope-ends, skin, or strong cloth, have not unfrequently replaced the metallic hinges."

The double-boarded apparatus, it may be observed, will be found extremely useful in the case of fracture of the leg, with tendency to displacement, more especially when this occurs near the knee-joint, from the impossibility of applying

the garter, (*jarretiere*,) one of the directing bands of which mention will be made farther on.

A simple tibial board, shaped out at the superior and internal angle, would suffice for cases of fracture of the arm and forearm, when the injury is of so grave a nature as to require the patient to keep his bed; for in ordinary cases, the common sling alone, or supporting a convenient board, would answer better, inasmuch as the patient would be at liberty to walk about.

Although particularly applicable to fractures of the limbs, the suspension apparatus of M. Mayor may, under other circumstances, be of important use. It will readily be conceived how great might be its utility in any painful diseases seated upon one or other of the limbs, as well as in certain white-swellings, in arthritic and rheumatic tumefactions of the foot, or in any other serious affections of the knee, or of the articulation of the foot and leg. Its use might be extended to the treatment of transverse wounds of the thigh, or of the tendo-Achillis, for which the most perfect immobility is indispensable. There cannot be a better means, so long as the immobility of the fractured part is ensured, of allowing the patient to vary his position in bed.

Adaptation.—It is not sufficient to place a fractured limb, after its reduction, upon an immoveable plane, in order to effect the cure. If this were true, for very simple cases, which would be but exceptions; if, for instance, in the majority of cases of simple fracture of the femur, a convenient position and a retentive bandage might be made to replace all those complicated machines, which do more honour to the mechanical knowledge of their inventors than to their knowledge of physiology; it is not the less certain, that other means are required also, to maintain the fractured extremities of a bone in perfect contact, to overcome the

involuntary as well as the spasmodic contractile efforts of the muscles and the indocility of the patient.

In most cases of fractured limbs, the fragments face each other; whence the necessity of exerting pressure in the direction of their diameter, if the displacement exist in relation only to the axis of the body of the bone, or of pulling at the same time at the lower fragment, if the displacement is longitudinal, or, in other words, if the broken ends overlap, in order to effect their coaptation. The hands alone of the surgeon and assistant are sufficient to fulfil effectually these indications; but as they are only temporary means, recourse must be had, in order to render the effects permanent during the whole time necessary to the consolidation, to the aid of a machine, which, in accomplishing this end, will in no respect inconvenience the patient.

Let the fracture of a leg be taken as an instance; if it be of such a nature as not to require the continued extension of the limb, and position alone suffices to maintain the broken ends in apposition, the surgeon has only to confine himself to the application, below the knee, of a tie or *garter*, the central portion of which has merely to be applied upon the anterior, or one of the lateral faces of the limb, and its ends attached either separately on each side, or together, on the outside or inside of the board. [Fig. 10, *f*, and fig. 14, *a*.] The object here in view, as will be easily perceived, is to fix the limb upon the board and give a due direction to the superior osseous fragment. The garter, like all the other directing bands, may be made of a bit of common roller, or a longitudinal compress; but M. Mayor prefers those he ordinarily employs. These directing-bands, the form of which may be seen, fig. 9, should be thick and quilted, in order to preserve their shape, and prevent them from exercising a painful pressure. They should be constructed of two pieces of

linen cloth, from three to five fingers' breadth wide at the middle, with a layer of wadding, charpie, tow, or wool, interposed between them, *a*; to the two extremities of these bands should be sewed tapes of convenient dimensions, *b*, *c*. Figs. 13 and 14, indicate so clearly the manner of arranging them, that it is unnecessary to dwell upon them longer here; the place, however, they are to occupy upon the limb, will be spoken of hereafter.

When the simple bands are found insufficient to fix the limb solidly upon the board, or when it is necessary, in order to keep the fracture reduced, to exert continued traction on the limb, the following pieces must be added. To the inferior extremity of the board, fig. 7, a foot-support is to be adapted, of the shape of a ladder, fig. 8, by means of mortises, *a a*, pierced in the former to receive it; it should be from eight to ten inches high, and form with the board an angle of about eighty degrees.

The object of this foot-board is to fix the heel-strap, (*la talonnière*,) fig. 11, *a b c d*, which, on one hand, embraces accurately the instep, heel, and malleoli, fig. 6, *g*, and, on the other is attached, by means of two tapes, fig. 11, *d d*, which terminate it, to one of the sides of the ladder, according to the direction desired to be given to the limb.

Thus, by means of the garter on one hand, and the foot-frame and heel-strap on the other, the elongation of the limb may be effected, and the overlapping of the fractured ends prevented. The extension is produced and maintained by the heel-strap, and the counter-extension by the garter, without taking into account the weight of the body and the fixture of the limb upon the apparatus; while the heel-strap itself prevents rotation, inward or outward, of the lower fragment.

But that alone is not sufficient to restore the limb to its

natural form when the fragments are displaced in respect to the diameter of the bone ; and if the shortening of the bone has been provided against, nothing has yet been done to maintain the fractured ends in apposition. The following is the manner in which this indication is fulfilled : instead of using, as is generally the case, the uniform pressure exerted by the eighteen-tailed bandage or that of Scultetus, with splints applied upon the soft parts that surround the ends of the bone, M. Mayor has recommended a mode more simple and more efficacious, and one which has the advantages of not covering with any portion of apparatus the part of the limb at which the fracture is seated ; of permitting the surgeon to visit it as often as he pleases, without the help of an assistant ; and of remedying the displacement, if any such should have occurred, as well as dressing the wound, should one exist, without meddling with the apparatus. The means in question consist in placing upon the part of the limb toward which the end of the bone is directed, and where it projects, the centre of a directing-band, fig. 14, *b*, and fastening the extremities to the opposite side of the board ; care being taken, however, to see that the fracture is properly reduced. Two bands, which act in opposite directions, are occasionally necessary, but more frequently the desired effect is obtained by one alone. The middle of the band should be applied upon the most convex part of the deformed limb ; one of its extremities is to be passed immediately under it, the other over, and both drawn with sufficient force, and fastened to a peg, inserted at the side of the board, which corresponds to the concavity of the limb, or, in default of this, to a mortise pierced about this spot ; they may be even nailed at once to the board.

The directing-bands should not be placed until the heel-strap and garter are adapted ; the latter being fixed to the

board upon the opposite side to that toward which the neighbouring band is to be directed ; without attending to this, the two extremities of the limb would be found to yield to the inverse tractions of the bands. The disposition of these several pieces will be seen in figs. 13 and 14. In comminuted fractures, with extreme tendency to displacement, a piece of pasteboard, fig. 12, should be applied upon the anterior part of the limb, with the notch corresponding to the instep.

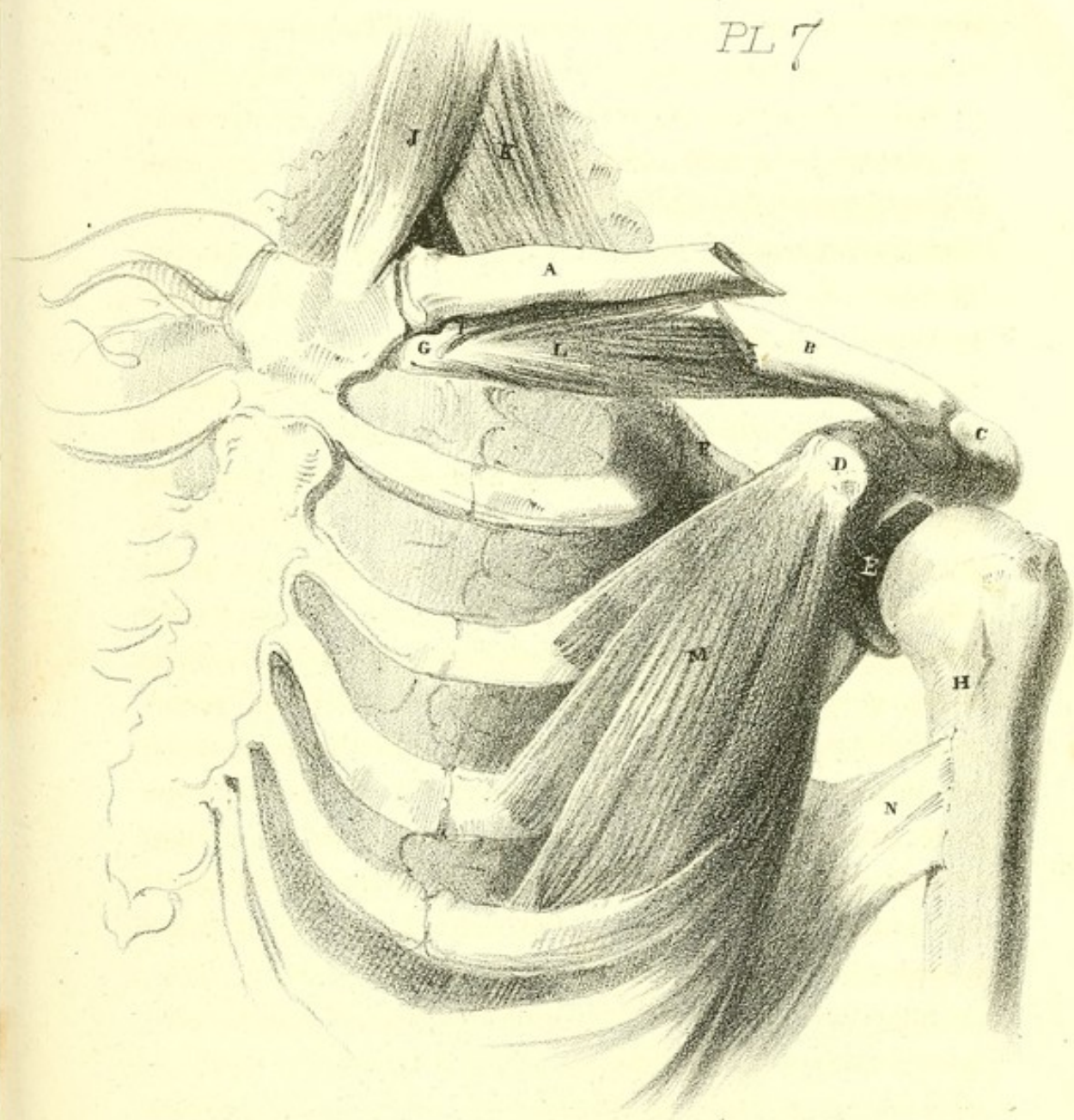
To fix the femoral board more firmly, the surgeon should apply the large quilted band, *d*, in fig. 17. This band should be long enough to pass as a belt round the body, and terminate by a strap, *a*, to be attached to a strap and buckle, *b c*, fixed to the external and superior part of the board. This band serves at once as a body-bandage and thigh-strap ; it passes first of all upon the groin of the injured side, then round the corresponding ilium and along the back, and is returned over the pubes to the upper part of the fractured thigh, where the buckle, fixed to the outer side of the board, receives it, or where, when this is wanting, it may be fastened to some other convenient point of attachment. This belt, which, as may be perceived, tends to fix securely the femoral board upon the pelvis, is employed with the notched portion of the board, against which the tuberosity of the ischium rests, to make the counter-extension, or, in other words, the resistance necessary to meet the tractions of the heel-strap ; while the latter acts at the same time upon the limb which it elongates, and upon the board which it pushes upward ; first beneath the ham, and then upon the ischiatic tuberosity. Lastly, it is this portion of the apparatus which performs the greatest part in the effort ; but as it is aided, firstly, by the weight of the limb, which, placed upon an inclined plane, tends to descend, and, secondly, by the effort itself, which


tends to elevate the bend of the knee, there can be no reasonable apprehension of the formation of sloughs or excoriations; such as the ordinary machines for continued extension too frequently produce.

This apparatus appears to unite all the qualities necessary for the reduction and consolidation of fractures of the neck of the femur, but MM. Mayor and Sauter have thought it sometimes necessary to add to the apparatus just described, the piece represented by fig. 16, which may on most occasions be entirely dispensed with.

To resume; when it is required to maintain a reduced fracture of the femur, of whatever nature it may be, whether situated near the knee, or in the shaft or neck of the bone, whether simple or complicated, with or without obliquity of the fragments, the thigh and leg are to be extended over the inclined plane, well cushioned, the belt applied round the thigh and pelvis, and the foot attached to the ladder inserted in the lower end of the tibial board. The large quilted band, represented figs. 16 and 17, is made to embrace the whole apparatus to confine the limb upon the board, when there is no deformity; or the bands of direction, already described, made use of, when the limb is curved, or there is any tendency to curvature, in the manner shown by figures 14 and 15.

PL 7





SECTION THIRD.

OF FRACTURES OF THE EXTREMITIES.

FRACTURE OF THE CLAVICLE. [VII.]

- | | |
|--------------------------------------|--|
| A. Sternal portion of the Clavicle. | I. Rhomboid, or Costo-clavicular ligament. |
| B. Acromial portion of the Clavicle. | J. Sternal portion of the Sterno-cleido-mas- |
| C. Acromion process of the Scapula. | toideus muscle. |
| D. Coracoid process of the Scapula. | K. Clavicular portion of the Sterno-cleido- |
| E. Glenoid cavity of the Scapula. | mastoideus muscle. |
| F. Superior angle of the Scapula. | L. Subclavius muscle. |
| G. Cartilage of the First Rib. | M. Pectoralis minor muscle. |
| H. Os humeri. | N. Latissimus dorsi muscle. |

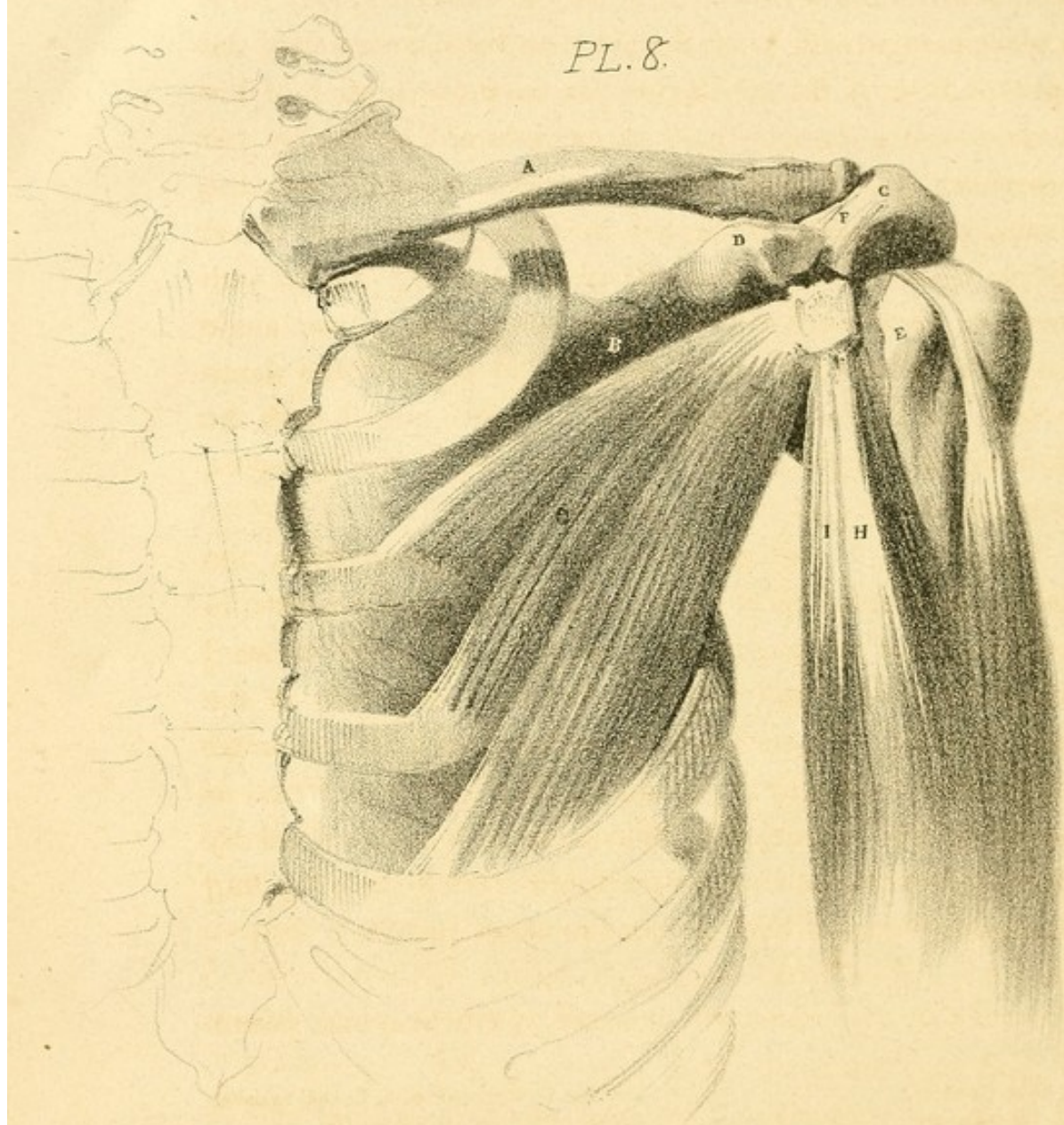
Appearances.—When the clavicle is fractured, as seen in the plate, between the insertion of the coraco-clavicular ligaments and its sternal articulation, the broken ends project, the sternal portion being the more prominent, and the integument drawn tightly over it; while the extremity of the acromial portion projects, but only in a very slight degree, and on a lower level; the inner portion of the bone rides over the outer; the length of the clavicle is diminished, and consequently the shoulder is brought nearer to the chest; the arm hangs useless by the side, and is in close relation with it. The general squareness of the shoulder is no longer observable, and the patient cannot raise his hand to his head; the fulcrum, by the attachment of which the scapula is held up in its natural situation, and upon which it moves, being lost. Such, then, are the characters. Little manual examination is here necessary: by passing the fingers along the upper edge of the clavicle, the exact situation of the fracture is immedi-

ately discovered; at the same time, by grasping, with the other hand, the shoulder, and drawing it outward, as well as raising the scapula, the two ends of the fractured portions are brought into contact, and the crepitus can be distinctly perceived.

Causes of displacement.—The muscles, which are attached to the two portions of the bone, act on it each in a different manner, and thus cause the displacement. The inner portion, or sternal extremity, will retain nearly its natural position; but it will incline slightly forward. It may be said, why does not the sterno-cleido-mastoideus draw it upward?—so it does; but only to the extent of supporting it in its natural situation; not beyond this. A strong ligament, (the costo-clavicular,) which runs from the cartilage of the first rib to the lower surface of the neck of the clavicle, controls the elevation of the fractured inner portion. Independently of this, the attachment of the clavicular portion of the pectoralis major counteracts the muscle attached above, (the sterno-cleido-mastoideus,) and gives the broken end an oblique direction forward.

The outer or acromial portion is displaced as in the plate. This portion of the bone falls from its natural level, and is drawn at the same time inward towards the sternum, passing to a certain degree below the broken extremity of the sternal portion of the clavicle. The causes of the displacement will be found to depend principally on the weight of the arm drawing down the scapula; and with it, necessarily, the outer portion of the clavicle to which it is attached, where it is held by the pectoralis minor and latissimus dorsi muscles. Besides the depression of this portion of the bone, it is drawn forward and inward from the action of the subclavius muscle, whose attachment to the cartilage of the first rib, as its fixed point, gives the broken bone that direction; it is held firmly

PL. 8.



in this situation by the muscle, and on this circumstance depends the chief difficulty in treating a fracture of the clavicle. Were it not for the weight of the extremity, very little displacement would occur, farther than the drawing in of the outer portion by the subclavius, for the outer portion of the clavicle would then be held in its natural position by the trapezius. The scapula itself is turned upon its axis, the glenoid cavity being depressed from the causes enumerated above; so that the base, instead of being nearly parallel with the spine, now takes a new direction, viz. the inferior angle is approximated to the spine, and is held there by the rhomboideus major, while the superior angle is pulled from the spine by the weight of the arm, and raised by the trapezius, levator scapulæ, and rhomboidei muscles.

Treatment.—Upon the basis of the foregoing facts, the plan of treatment becomes at once evident. It consists, in the first place, in bringing the acromial extremity outward and on the same line with the fractured extremity of the inner portion; and, secondly, in raising the scapula and outer portion of the clavicle to its original level with the sternal or fixed portion. These two indications may be obtained by applying Boyer's bandage for fractured clavicle [iii. 17. p. 33.] or the handkerchief bandage for the same, [iii. 18, p. 39.]

FRACTURE OF THE CORACOID PROCESS OF THE SCAPULA. [VIII.]

- | | |
|---|---|
| A. The Clavicle. | F. The Coraco-acromial or Deltoid ligament. |
| B. The Scapula. | G. The Pectoralis minor muscle. |
| C. The Acromion process of the Scapula. | H. The short head of the Biceps Flexor Cubiti muscle. |
| D. The Coracoid process of the Scapula fractured. | I. The Coraco-brachialis muscle. |
| E. The Humerus. | |

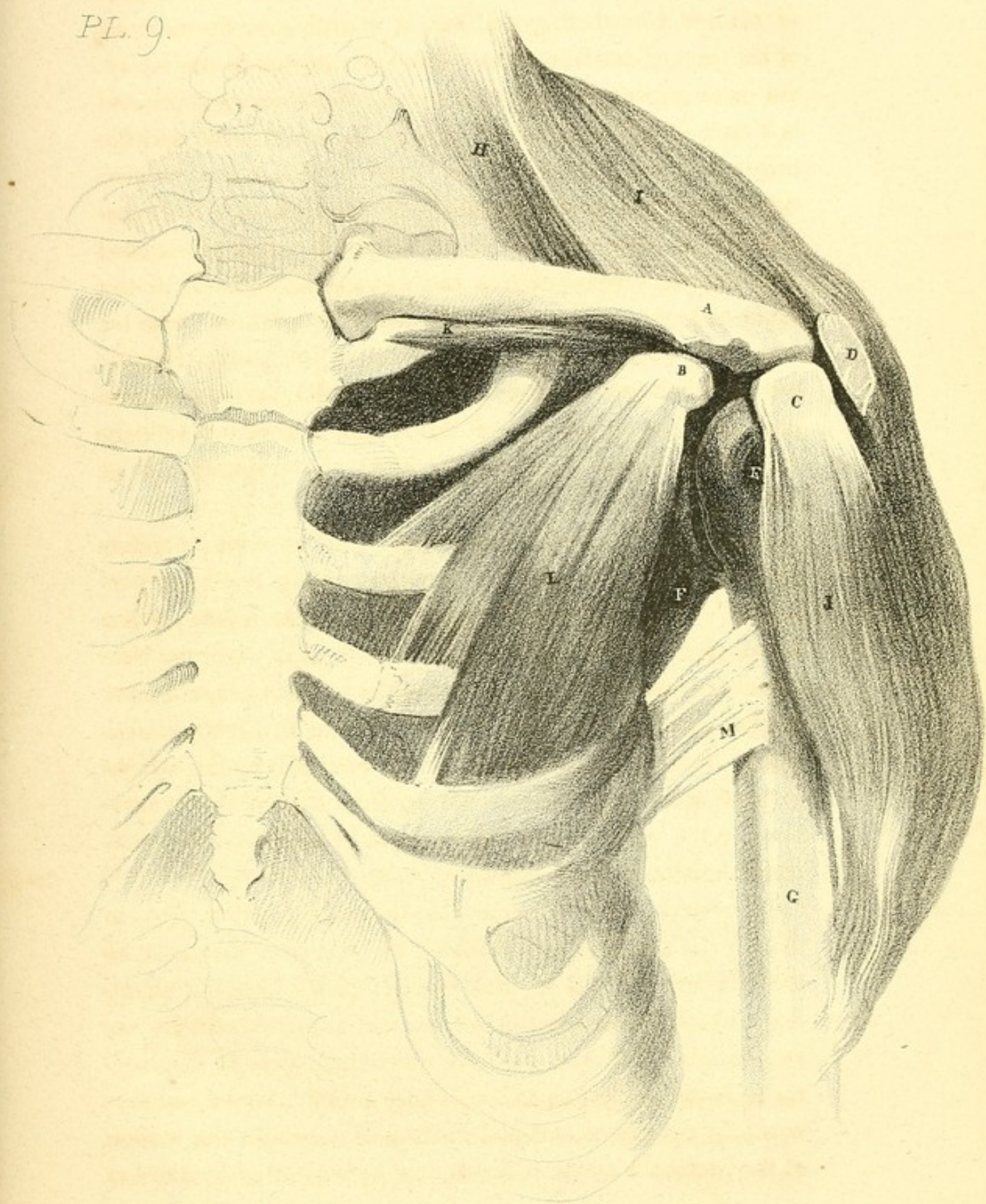
Appearances.—The appearances, when this accident has occurred, are the same as in the natural condition of the parts; and excepting the consequent tumefaction, there is no external

deformity ; it is only by the patients referring you to the seat of pain, and by their partial loss of control over the motions of the upper extremity, that you are directed to the injury. On examination, the detached portion of the coracoid process is found drawn downward beyond its usual level, and the finger may be inserted in the space between the two portions, when the broken surfaces of both can be readily distinguished. No crepitus is felt until the humerus is raised and thrown forward across the thorax, the forearm at the same time being flexed, in which position those muscles which have displaced the loose portion are partly relaxed : the thumb being now placed in the axilla, and the fingers grasping the anterior part of the broken portion, it is brought upward to its natural situation, when the crepitation is at once distinguished.

Causes of Displacement.—These will be seen by reference to the plate. The muscles displacing the loose portion of the bone, are the pectoralis minor, whose action draws it slightly inward toward the thorax, while the conjoined tendons of the coraco-brachialis and short head of the biceps, which are attached to the tip, draw it directly downward ; but the limit of its descent is controlled by the attachment of a strong ligament running from the tip of the acromion to the whole extent of the coracoid process,—the coraco-acromial or deltoid ligament.

Treatment.—The treatment in this case consists, first, in flexing the fore-arm and bringing the arm over the chest, so that the hand of the injured side grasps the opposite shoulder ; by these means the biceps and coraco-brachialis are considerably relaxed : the only remaining cause of displacement is the pectoralis minor, whose action may be counteracted by placing a soft pad in the axilla behind the tendon of the pectoralis major, which should be supported by another

PL. 9.



bandage firmly applied over the shoulder. The humerus should then be pushed upward, so that the head of the bone pressing up the coraco-acromial ligament raises with it the displaced portion of the scapula. In this situation the arm should be firmly fixed by a broad roller.

FRACTURE OF THE ACROMION PROCESS OF THE SCAPULA. [IX.]

- | | |
|---|---|
| A. The Clavicle. | G. The shaft of the Humerus. |
| B. The Coracoid process of the Scapula. | H. The Levator Scapulæ muscle. |
| C. The detached portion of the Acromion process of the Scapula. | I. The Trapezius muscle ; the Clavicular portion of which is removed. |
| D. The broken surface of the spine of the Scapula. | J. The Deltoid muscle. |
| E. The head of the Humerus. | K. The Subclavius muscle. |
| F. The inferior costa of the Scapula. | L. The Pectoralis minor muscle. |
| | M. The tendon of the Latissimus dorsi muscle. |


Appearances.—The shoulder loses its rotundity ; a slight prominence is seen on the anterior part, while the posterior and upper part presents an irregularity, because the fixed surface of the broken spine of the scapula is slightly elevated. The scapula is drawn upward and backward, and the shoulder is brought nearer the thorax. The position of the clavicle, likewise, will be found to be changed, the acromial extremity being somewhat depressed, while the sternal extremity, at the upper part, becomes more prominent than on the opposite side. The displaced portion of the acromion is readily discovered by following the upper edge of the clavicle outward, where it will be found situated on the fore and upper part of the head of the humerus. The arm hangs in close relation with the side, and the patient is unable to raise it : thus the appearances in some degree resemble those seen in fracture of the clavicle.

Causes of Displacement.—When this fracture takes place, the loose portion of the bone is drawn slightly forward and downward by the deltoid muscle, and is thus brought close to

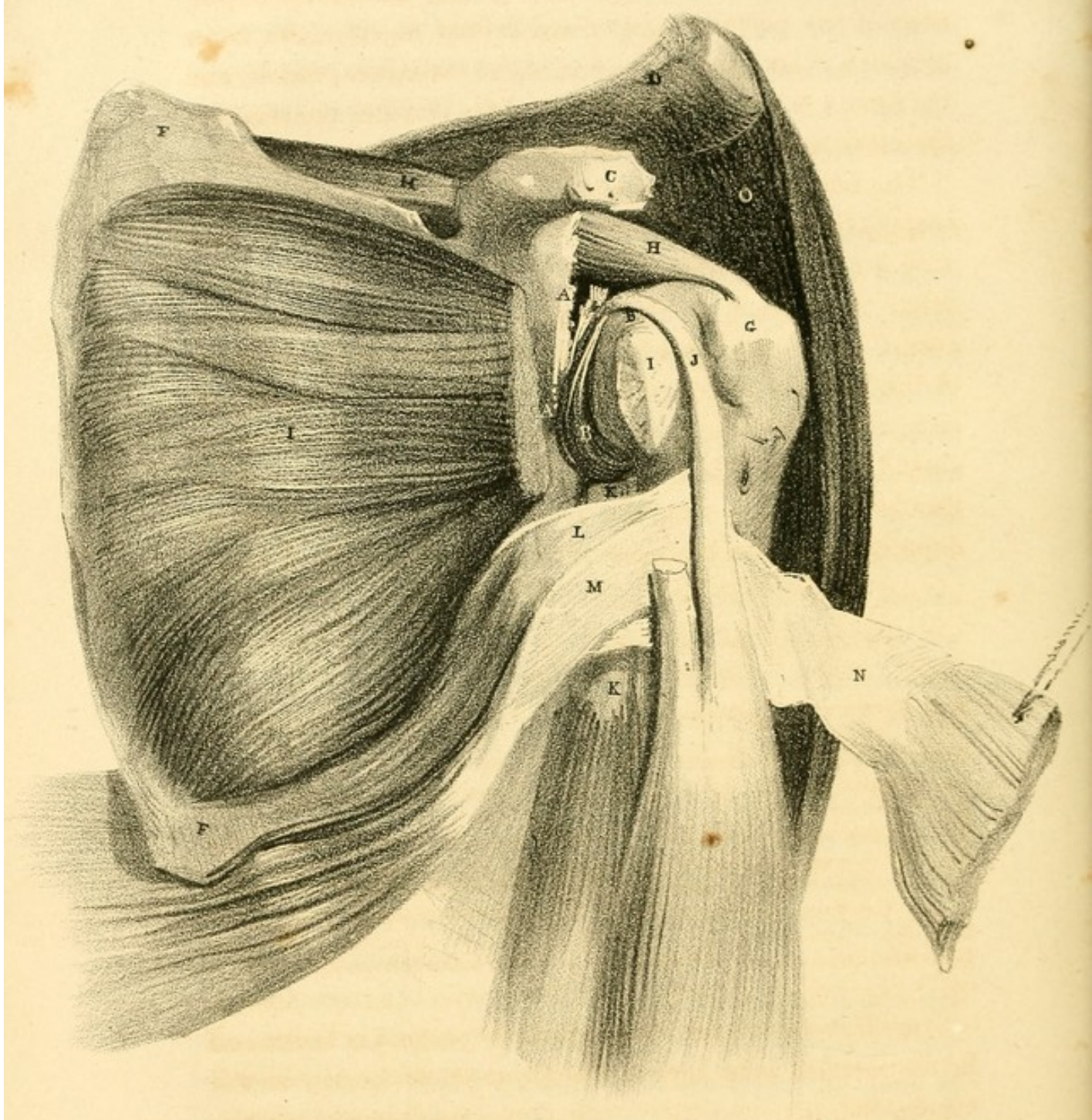
the head of the humerus ; its attachments to the clavicle, and likewise to the coraco-acromial ligament, limit the action of the external fibres of the deltoid muscle. This displacement does not depend altogether upon the action of the deltoid, but likewise upon the muscles which are attached to the clavicle.

The clavicle is no longer fixed, but is set at liberty ; that portion of the scapula to which it is attached being broken off ; so that it will now become the bone which is acted upon, rather than a fixed point for the attachment of those muscles which act upon the extremity or thorax. In its natural situation, the clavicle is in part supported by the acromial process of the scapula, but this connexion no longer exists. By what then is it displaced ? It is drawn downward, by the subclavius muscle, in the direction of the first rib ; forward, and again downward, being rolled upon itself by the clavicular portions of the pectoralis major and deltoid, which muscles overcome the action of the clavicular portions of the sternocleido-mastoideus and trapezius ; so that the acromial extremity of the clavicle will be found resting upon the coracoid process. The scapula takes nearly the same situation as that described in fracture of the clavicle, the superior angle being raised by the levator scapulæ, while the glenoid cavity is depressed by the weight of the extremity, the pectoralis minor, and latissimus dorsi muscles.

Treatment.—The treatment of this fracture is nearly the same as of that of the coracoid process. The fracture may be readily discovered by tracing with the finger the spine of the scapula towards the clavicle, when the loose portion is detected. One hand being placed firmly on the shoulder, and the arm at the same time raised and rotated by the other hand, the crepitus is distinctly felt. The principal object in the treatment is, to bring the arm forward over the chest,



PL. 10.



where it should be firmly fixed; by which means the portions of the pectoralis major and deltoid muscles, the latter of which is attached to the end of the acromion process, and the former to the anterior surface of the clavicle, are relaxed; the clavicle then resumes its natural situation.

The humerus should now be pushed up firmly against the scapula, in order to raise the coraco-acromial ligament, and with it necessarily the detached portion of the acromion process. A bandage should be passed over the shoulder, and carried down under the forearm; by which means the head of the humerus will be firmly fixed under the acromion process, and will lift it to its natural level. A spica bandage should now be applied, the folds being turned over the injured shoulder; in this way the spine of the scapula will be depressed, and the broken surfaces held in contact.

FRACTURE OF THE NECK OF THE SCAPULA. [X.]

- | | |
|---|--|
| A. A. The fractured surfaces of the neck of the Scapula. | isting between the two cut surfaces is caused by the removal of a portion of the muscle. |
| B. B. The detached Glenoid cavity. | |
| C. Coracoid process. | J. Tendon of the long head of the Biceps muscle. |
| D. Acromion process. | |
| E. Superior angle of the Scapula. | K. K. Long head of the Triceps muscle. |
| F. Inferior angle of the Scapula. | L. Teres major muscle. |
| G. Great tuberosity on the head of the Humerus. | M. Latissimus dorsi muscle. |
| H. H. Supra-spinatus muscle. | N. Pectoralis major muscle reflected. |
| I. I. Subscapularis muscle: the interval existing between the two cut surfaces is caused by the removal of a portion of the muscle. | O. Part of the Deltoid muscle, the Clavicular portion having been removed. |

Appearances.—When the neck of the scapula is broken off in the manner here shown, the appearances presented will correspond in some degree with those which occur in dislocation of the head of the humerus into the axilla. The acromion process becomes distinct, the point projecting as in dislocation; below this, a flatness may be observed, in consequence of the head of the bone having fallen below its

proper level; the head of the bone may even be felt in the axilla, though not fully occupying it, and it can be easily raised and placed in its natural position; the crepitus can be distinctly perceived, only when the shoulder is thus raised.

Causes of Displacement.—The causes of displacement depend principally on the weight of the extremity drawing down the loose portion of the scapula; for, this portion being detached, the humerus loses its means of support. It will be remembered, that to the upper edge of the glenoid cavity there is attached the long head of the biceps muscle, and to the lower surface we have attached the long head of the triceps muscle, so that the loose portion of the bone is held in close relation with the head of the humerus; consequently, whatever direction the humerus takes, the glenoid cavity will follow it. Independently of the depression of the head of the bone, it will be found to have changed its position, having turned upon its axis. A line drawn perpendicularly to the centre of the articulating surface of the humerus, in the natural situation, would look obliquely inward and upward; but now, in its altered position, it would look obliquely backward and upward. The great tuberosity is necessarily directed forward: this arises from the actions of the subscapularis and pectoralis major muscles. The head of the bone is drawn into the axilla against the upper part of the inferior costa of the scapula, by the combined actions of the last two muscles, together with the latissimus dorsi, teres major and minor, and supra and infra spinatus.

The nature of the accident will be at once evident, by placing the hand over the acromion process, the fingers grasping the shoulders firmly: by now raising the arm, at the same time that it is drawn outward, the rotundity of the shoulder is immediately restored; and by rotating it while in the raised position, the crepitus will be distinctly felt. The

support being removed, the arm falls, and the shoulder again presents the appearance already described. In the dislocation, the head of the bone is fixed, and the same force which raises the head in fracture, must be greatly increased, and differently applied, in dislocation. Should the fracture have taken place on a line with the coracoid notch, the appearances would be the same as in the situation here shown; for, independently of the attachments of the coraco-brachialis, pectoralis minor, and short head of the biceps, the bone would be supported by the coraco-acromial ligament. The fracture above described is also limited in its displacement by the coraco-humeral ligament.

Treatment.—The treatment in this case consists in placing a soft pad in the axilla, by which means the head of the bone and glenoid cavity are forced outward, so that the actions of the subscapularis, pectoralis major, latissimus dorsi, supra and infra spinatus, teres major and minor, muscles, are counteracted: the humerus should now be pushed upward, the pad in the axilla being fixed either by the figure of ∞ bandage, or the clavicle bandage of Sir A. Cooper. In raising the head of the humerus, the glenoid cavity necessarily moves with and retains its natural relation to it; for the tendon of the long head of the biceps passing directly over the head of the bone acts as a splint, by which means its relation is preserved; otherwise, the irregularities of the broken surfaces might cause permanent displacement. The arm should now be bound from the elbow to the shoulder, by passing a double-headed roller from the forearm near the elbow, bringing either end over the spine of the scapula, where they should cross, and again carrying them down to the chest on the opposite side; by these means the head of the bone is retained in its natural position: the two ends now being brought round to the injured side, and the arm fixed, (the forearm being

flexed at a right angle with the arm, and supported with a short sling,) the biceps muscle is relaxed, and the loose portion of bone remains in its natural position.

FRACTURE OF THE NECK OF THE HUMERUS ;

i. e. IMMEDIATELY BELOW THE TUBERCLES AND ABOVE THE INSERTIONS OF THE PECTORALIS MAJOR, LATISSIMUS DORSI, AND TERES MAJOR, MUSCLES. [XI.]

Fig. I.

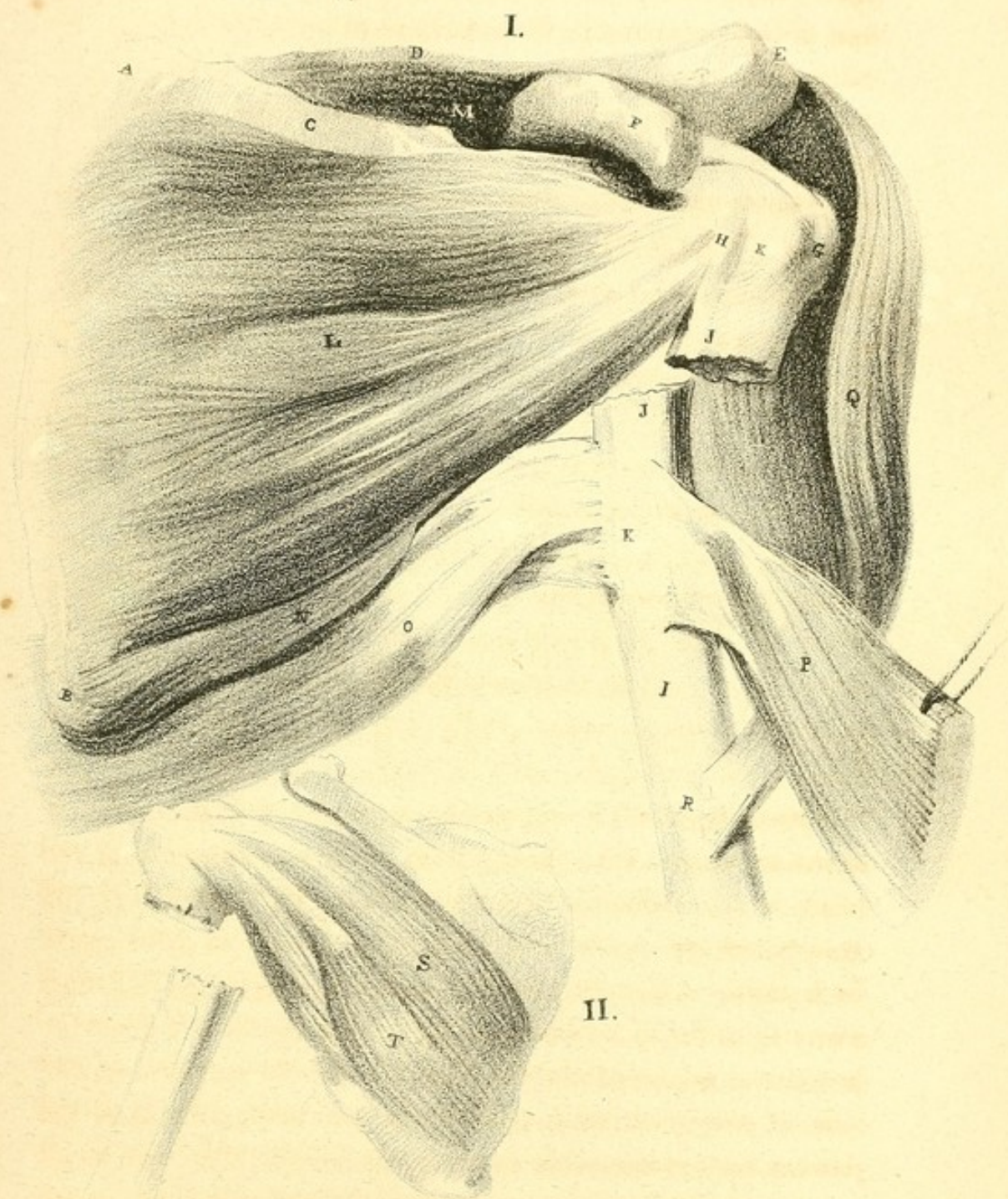
- | | |
|---|-------------------------------------|
| A. Superior angle of the Scapula. | K. K. Bicipital groove. |
| B. Inferior angle of the Scapula. | L. Subscapularis muscle. |
| C. Superior costa of the Scapula. | M. Supra-spinatus muscle. |
| D. Spine of the Scapula. | N. Teres major muscle. |
| E. Acromion process. | O. Latissimus dorsi muscle. |
| F. Coracoid process. | P. Pectoralis major reflected. |
| G. Great tuberosity of the Humerus. | Q. Part of the Deltoid muscle. |
| H. Lesser tuberosity of the Humerus. | R. Insertion of the Deltoid muscle. |
| I. Shaft of Humerus displaced. | |
| J. J. The broken surfaces of the two portions of the Humerus. | |

Fig. II.—Posterior View of the Scapula.

- | | |
|--------------------------|------------------------|
| S. Infra-Spinatus muscle | T. Teres minor muscle. |
|--------------------------|------------------------|

Appearances.—The appearances presented in this fracture agree somewhat with those which occur in dislocation of the head of the humerus into the axilla. The position of the arm, taken generally, may be said to accord in both cases. In fracture of the neck of the humerus, the elbow is drawn away from the side, while the upper portion of the shaft below the situation of the fracture appears to rest against the side of the chest, as in dislocation into the axilla; and the patient cannot raise his hand to his head. The two cases however, differ as follows: when dislocation of the shoulder has taken place, the acromion process becomes prominent, and even distinct to the eye, and there is a general flatness of the surface from the removal of the head of the bone,

PL. 11.



which ought to occupy the space ; the deltoid muscle then falling across the glenoid cavity and occupying it. In fracture we find the reverse : the shoulder presents an increased rotundity, but in a trifling degree ; the acromion process becomes more concealed than in the natural situation of the parts, in consequence of the head of the bone being drawn upward against the ligament above it, by which means a slight elevation takes place on the superior part, thus producing the rotundity ; and this rotundity is rendered more conspicuous by a depression immediately below the level of the glenoid cavity of the scapula, from the lower portion of the humerus being drawn inward, while the upper remains nearly in its usual position, as before stated, viz. slightly raised.

Causes of Displacement.—By reference to the plate, the fracture will be observed as described above ; the portion above the fracture (to which we have attached, on the anterior part at the lesser tubercle, the subscapularis muscle, while, on the outer part of the greater tubercle, is attached the supra-spinatus, and to the posterior part of the same tubercle the infra-spinatus and teres minor) will be drawn outward and slightly upward, immediately under the coraco-acromial ligament.

The upper extremity, viz., the broken end of the lower portion of the bone, will be found drawn inward, producing an evident concavity at this point. The elbow is at the same time separated from the side. By reference to the plate, we find inserted in the upper extremity of the lower portion of the bone, the pectoralis major, latissimus dorsi, and teres major, muscles ; the former into the outer edge of the bicipital groove, the two latter into the inner edge of the same groove ; the combined action of these three muscles is to draw the upper extremity of the lower fractured portion towards the side of

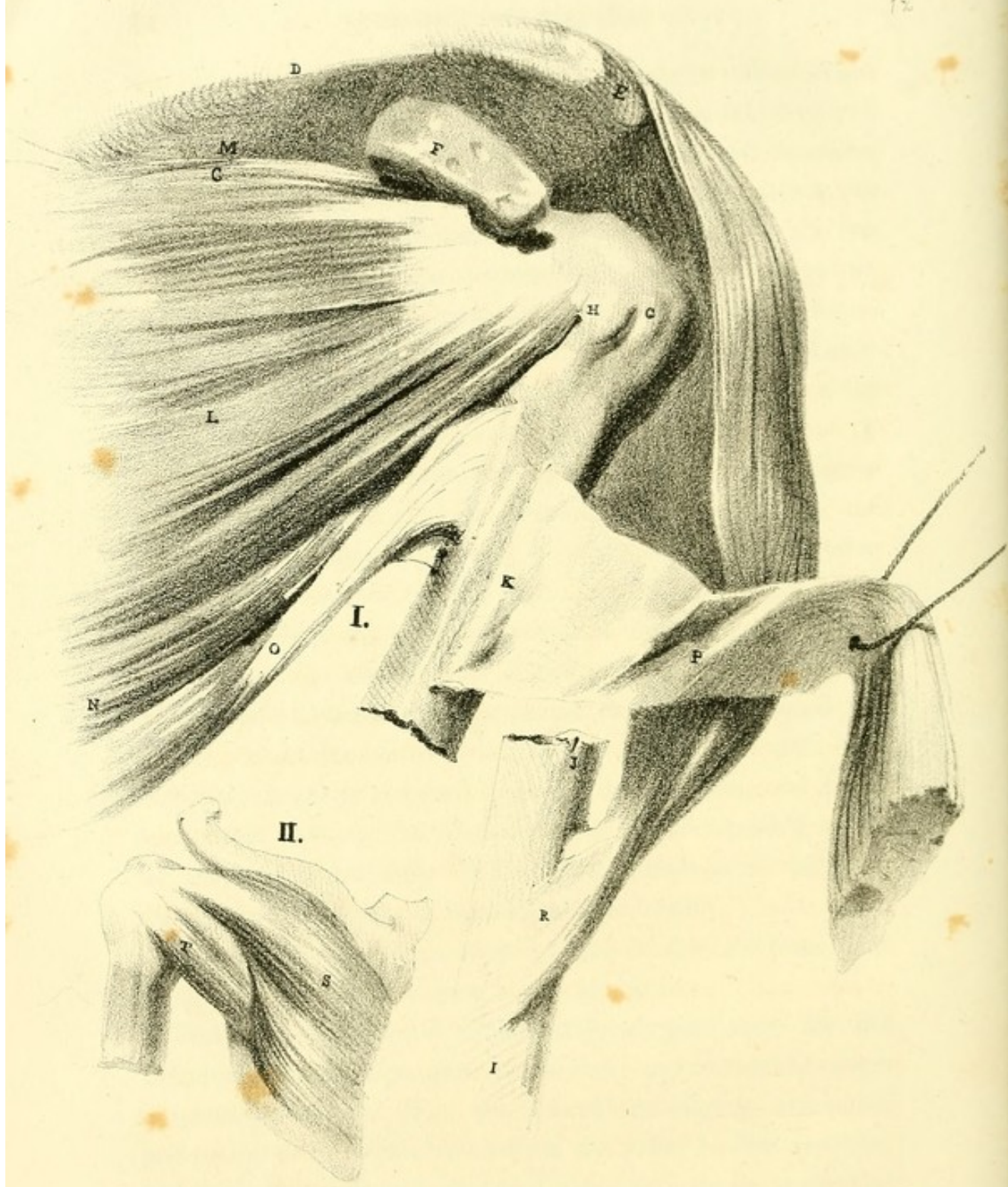the thorax, where it is held, so that, whatever action takes place, the bone now moves on this point as the fulcrum.

Below the insertion of the three last-mentioned muscles, and at about the middle of the outer part of the humerus, we find inserted the deltoid muscle, whose action draws the humerus from the side ; but the bone being fixed by the pectoralis major, latissimus dorsi, and teres major, at its upper extremity, and moving on this point as its centre, the insertion of these muscles being the fulcrum, the lower end of the humerus consequently moves obliquely outward.

Treatment.—The accompanying plate will perhaps suggest what should be the plan of treatment in this fracture : the displacement altogether arising from the actions of the powerful muscles inserted into the humerus. The lower portion of the bone suffers the greatest degree of displacement, in consequence of the attachments of the pectoralis major, latissimus dorsi, and teres major, muscles, drawing it toward the thorax, while the deltoid directs the elbow outward : this deformity is easily reduced by fixing the shoulder, and at the same time drawing the arm outward and downward, when the crepitus is distinctly felt ; upon the removal of the force the original deformity is immediately resumed.

So trifling is the displacement of the head of the bone, that little or no deformity occurs at the shoulder.

The plan that would immediately suggest itself for the reduction and final position of the limb, would be that which is usually adopted. The arm should be slightly extended, and at the same time drawn from the side : in this position, the common wood or pasteboard splints are to be applied at four sides of the arm, and there held firmly by a cotton roller ; between the upper part of the bone and the thorax, a firm conical pad is placed, with its base in the axilla, the apex pointing downward, and slightly hollowed out for the recep-



tion of the arm; they are to be closely bound together, taking care that the conical compress is firmly fixed to the side of the chest: in this way the elbow is approximated to the side, and adapted to the oblique surface of the compress. By this means the action of the deltoid muscle is counteracted; while the base of the pad or compress, which is above, counteracts the actions of the pectoralis major, latissimus dorsi, and teres major, muscles: by thus forcing the humerus from the side, the lower fractured portion is firmly fixed with its broken surface looking directly upward.

The superior portion of the bone is now depressed, and its fractured surfaces are brought in contact: this is accomplished by means of a cotton roller passed over the shoulder and carried under the apex of the conical pad; thus the whole extremity is supported, and the weight of the arm is prevented from separating the fractured surfaces. In this manner the whole of the muscles producing the various displacements of the bone are counteracted. The forearm should now be bent at a right angle, and be kept in a sling.

FRACTURE OF THE SHAFT OF THE HUMERUS,

BETWEEN THE INSERTIONS OF THE PECTORALIS MAJOR, LATISSIMUS DORSI, AND TERES MAJOR, AND ABOVE THE INSERTION OF THE DELTOID. [XII.]

Fig. I.

- | | |
|-------------------------------------|---|
| A. Superior angle of the Scapula. | J. J. The fractured surfaces of the bone. |
| B. Inferior angle. | K. Bicipital groove. |
| C. Superior costa. | L. Subscapularis muscle. |
| D. Spine of the Scapula. | M. Supra-spinatus fossa. |
| E. Acromion process. | N. Teres major. |
| F. Coracoid process. | O. Latissimus dorsi. |
| G. Great tuberosity of the Humerus. | P. Pectoralis major reflected. |
| H. Lesser tuberosity. | Q. Deltoid muscle. |
| I. Shaft of the Humerus. | R. Insertion of the Deltoid. |

Fig. II.—Posterior View of the Scapula.

- | | |
|--------------------|-----------------|
| S. Infra-spinatus. | T. Teres minor. |
|--------------------|-----------------|

Appearances.—In this fracture, the position of the two portions of the bone is precisely the reverse of that described as

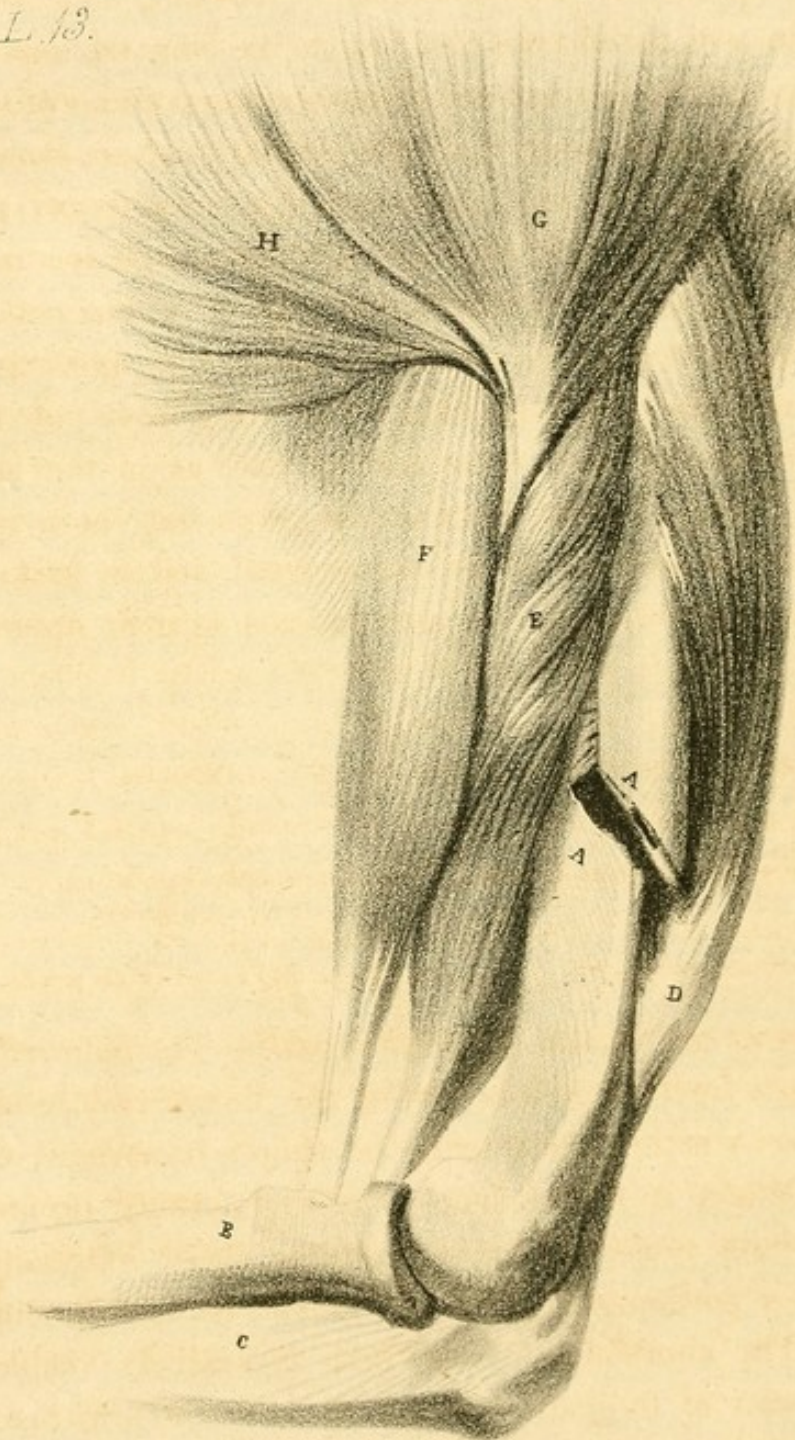found in the foregoing. The fracture occurs directly below the insertion of the teres major, latissimus dorsi, and pectoralis major, muscles, and above the insertion of the deltoid. The deformity consequent upon this fracture consists in a slight shortening of the limb, in consequence of the lower portion being drawn upward; while at the same time a prominence is observed about the middle of the outer part of the arm, immediately above the insertion of the deltoid muscle: from the projection of the broken end of the lower portion riding over the upper, the width of the arm is considerably increased, and the elbow is directed, but in a very slight degree, towards the chest: these circumstances at once indicate the nature of the accident.

Causes of Displacement.—The upper portion of the bone is here found drawn down to the side of the thorax by the united actions of the pectoralis major, latissimus dorsi, and teres major, muscles, and is held in this position; while the lower portion is pulled outward, and slightly upward, by the action of the deltoid muscle, which is inserted into the upper extremity of the lower portion of the fractured bone, so that it takes rather an oblique direction, the elbow inclining to the side; the obliquity is trifling, but may be readily observed.

Treatment.—The treatment in this fracture is rendered simple in consequence of the comparatively few muscles producing the deformity.

It will be observed, by referring to the plate, that the upper portion of the bone is drawn inward by the pectoralis major, latissimus dorsi, and teres major, while the lower portion is drawn outward and upward by the deltoid alone; to this portion our attention should be first directed. The two portions of the bone should in the first place be brought into apposition in the following manner: extension should be made at the elbow, giving to it at the same time a direction

PL. 13.



correspondent with the upper portion; a roller should then be applied, as usual, from the bend of the elbow, commencing at the upper part of the forearm. This being done, four lath splints, well lined with tow, should be adapted, one to either surface of the arm; thus holding the two portions of the bone in contact. A conical pad, as in the last fracture, should now be placed between the upper portion and the thorax, for the purpose of directing it outward: this being well secured, the splints may now be bound to the arm by a firm cotton roller, taking care that the forearm is bent at a right angle with the arm, and thus supported: the whole may now be firmly fixed to the side of the conical pad, as in the last described fracture: thus the muscles displacing both the upper and lower portions will be counteracted, and the broken surfaces brought in apposition and secured in their natural situations.

FRACTURE OF THE SHAFT OF THE HUMERUS.

IMMEDIATELY BELOW THE INSERTION OF THE DELTOID MUSCLE. [XIII.]

- | | |
|--|---|
| A. A. Two surfaces of the Os humeri fractured. | E. Brachialis anticus muscle. |
| B. Radius. | F. Biceps flexor cubiti muscle. |
| C. Ulna. | G. Deltoid muscle. |
| D. Triceps extensor cubiti muscle. | H. Part of the Pectoralis major muscle. |

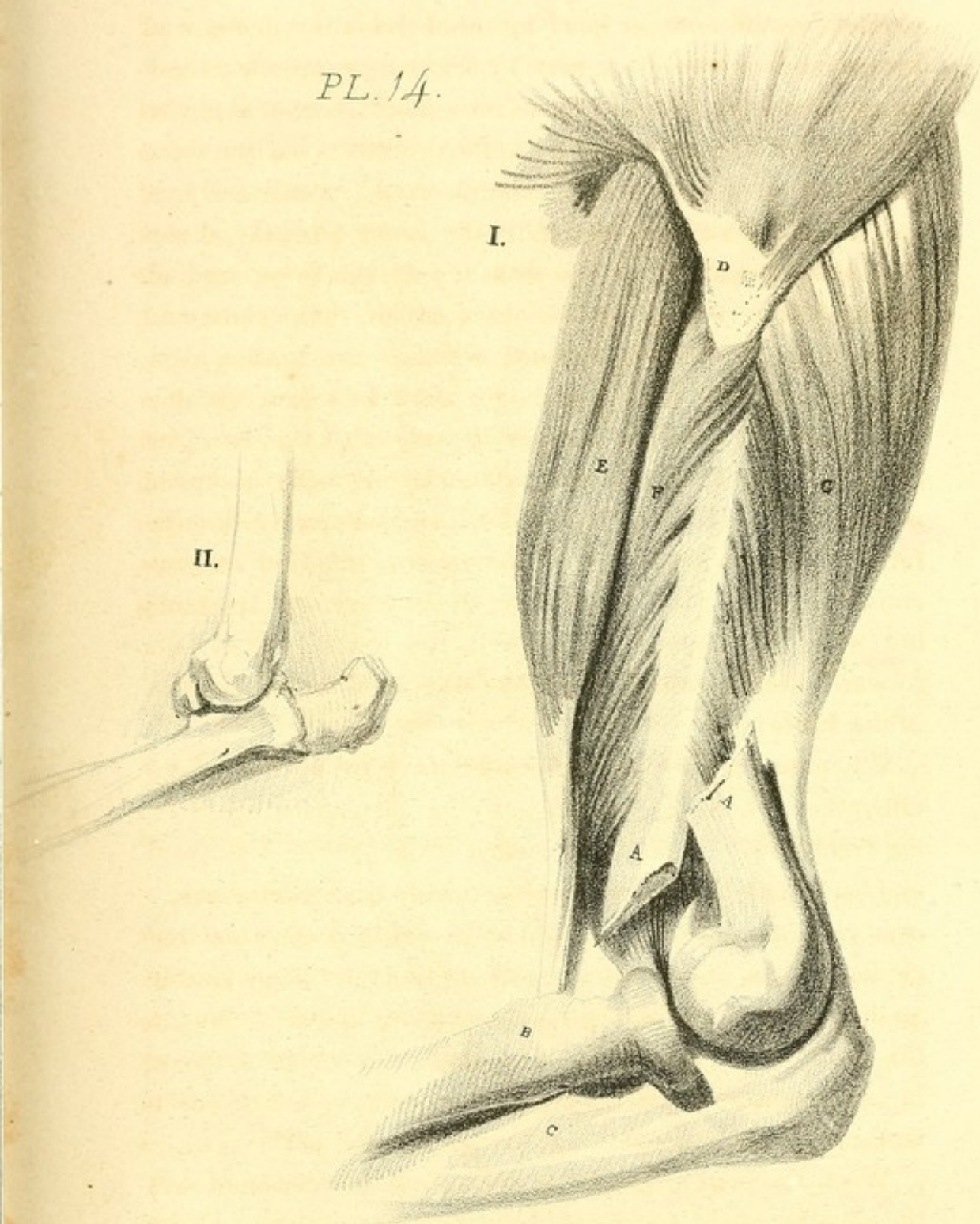
Appearances and Causes of Displacement.—The deformity that succeeds fracture in this part of the humerus depends entirely upon whether the fracture be simply transverse, or oblique. When it is transverse, little deformity occurs, except a slight projection forward of the upper extremity of the lower portion, and then only under certain circumstances. The shortening of the limb is scarcely visible. The incapacity of the patient to use or raise the arm need hardly be enumerated as a symptom; and even the projection forward of this portion does not depend upon muscular action, but takes place from the mechanical force that has


been applied. The humerus, at this situation, is firmly clothed on the anterior part by the brachialis anticus and biceps, and on the back part by the triceps muscle: these antagonize each other, so that their natural action would be to draw the broken surfaces in close contact; but the force necessary to produce the fracture would occasionally, if applied with great violence, give the lower portion a direction corresponding with the direction of the force applied. Independently of this, we should consider the weight and long-lever power of the forearm, which, when unsupported, would descend by its own gravity; and the forearm descending would draw with it the lower portion of the bone, by means of the muscular connexion existing between them, moving on the elbow as the centre. In fracture, we find the forearm always supported by the patient, and from this circumstance no displacement occurs in the transverse fracture; but when this support is removed, the lower portion falls forward slightly, simply from the alteration in the position of the forearm.

When the fracture takes place obliquely, the circumstances altogether differ. On referring to the accompanying plate, the fracture is observed to incline from above downward and backward, the two surfaces in this instance gliding easily over each other by the combined actions of the biceps and brachialis anticus on the anterior part, and by the triceps muscle on the posterior; so that the appearances in oblique fracture, in this situation, are shortening of the limb, with evident increase in its circumference at the point of fracture, with the broken surfaces of the bone pushing through the soft parts.

When the bone is broken in a direction the reverse of this, the situation of the parts would likewise be reversed. In the plate, the lower portion is the most anterior, from the causes already pointed out; but should the fracture occur in the

PL. 14.





opposite direction, then it is clear, upon this principle, that the same portion (the inferior) would glide backward, and the superior portion would be anterior to the lower portion,—the reverse of what is seen in the plate.

Treatment.—In this case the treatment consists simply in placing splints on either side of the arm, having first produced extension sufficient to reduce the deformity, which is easily done by pulling the arm at the elbow; care, however, is required in handling the extremity, particularly when the points of the broken ends of the bone are near the surface, as is not unusually the case. This extension should be continued for some time, so that the muscles, being kept constantly on the stretch, may lose their power: a roller should then be applied carefully round the arm, from the elbow; four firm splints, lined with tow or lint, are now to be placed one on either side of the arm, and those well and firmly adjusted by means of a cotton roller; the forearm is then to be supported by means of a handkerchief round the neck; thus the broken surfaces are brought into immediate contact. If the bandage becomes at all loose, the disposition of the surfaces to ride over each other should be immediately prevented by a readjustment of the splints and bandages.

FRACTURE OF THE HUMERUS IMMEDIATELY ABOVE THE CON- DYLES. [XIV.]

Fig. I.

- | | |
|--|------------------------------------|
| A. A. Broken surface of the Os humeri. | E. Biceps muscle. |
| B. Radius. | F. Brachialis anticus muscle. |
| C. Ulna. | G. Triceps extensor cubiti muscle. |
| D. Deltoid muscle. | |

Fig. II.

Shows the situation of the bones in the dislocation of the Radius and the Ulna backward.

Appearances and Causes of Displacement.—The appearances in this fracture, where the obliquity corresponds with

that represented in the drawing, (obliquity forward and downward,) are as follow: the limb is considerably shortened, and incapable of motion; the forearm, unless supported, hangs useless by the side, while there is an increase in the circumference of the limb at the point fractured; in fact, the same circumstances take place as in fracture at the situation last described, and they depend on exactly the same cause: but from the situation of the fracture in this instance, which is immediately above the condyles of the humerus, the appearances vary; indeed, we have precisely the characters of dislocation of the ulna and radius: a reference to the accompanying plate will at once explain how this arises. The lower portion of the bone will be drawn, or will rather glide, backward, about an inch, over the broken surface of the upper portion, by the combined actions of the brachialis anticus and biceps muscles, which are situated on the anterior part, and by that of the triceps, which is on the posterior part.

When the forearm is supported, this deformity does not take place to its fullest extent: but should the arm be allowed to fall loose, or should it be depressed, the deformity is fully developed; for the forearm carries with it the lower portion of the humerus, which then projects, backward; and then a dislocation is suspected. The increase of the deformity, however, under these circumstances, should at once satisfy the surgeon of the non-existence of dislocation; for when the dislocation referred to has taken place, the act of extending the forearm would in some degree diminish the deformity.

Should the fracture have taken place in the opposite direction, but in the same situation, this deformity does not occur: the appearances then would be as follow; the point of the broken surface of the upper portion would project through the integument, were it not that the strong tendon of the triceps muscle protected it. The prominence will now take

place on the anterior part; but the displacement is readily distinguished as arising from fracture, the broken surface posteriorly being distinct both to the eye and touch.

The reduction of the bones requires considerable force, and cannot be perfectly effected till all tumefaction is subdued. The hand being placed near the elbow on the forearm at the same time that the shoulder is supported; extension is then produced, and the deformity disappears; but as soon as this force is removed, the displacement instantly returns.

Treatment.—The treatment in this case requires considerable care, in consequence of the difficulty experienced in applying splints so as to keep up the extension, and from the disposition of the surfaces to ride over each other. The plan usually adopted is, to apply a roller from the hand to the elbow: an assistant now makes extension, the bones being held in apposition and the forearm fixed with the thumb upward, so that it is in the state between pronation and supination; by this means the muscles of the forearm attached to the humerus are relaxed, and the bone is freed from their action: the roller is carried round the arm to the shoulder. An angular splint should at this stage be applied to the inner side of the arm, having been previously well padded with tow, and fixed firmly to the forearm only by means of a cotton bandage; so that the perpendicular portion of the splint is adapted to the inner side of the arm, while the horizontal portion is applied to the palmar surface of the forearm. Extension is again produced, until the broken surfaces are brought into immediate relation, where they are held: the bandage is now to be firmly applied around the splint and carried up to the shoulder.

FRACTURE OF THE CORONOID PROCESS OF THE ULNA. [XV. 1.]

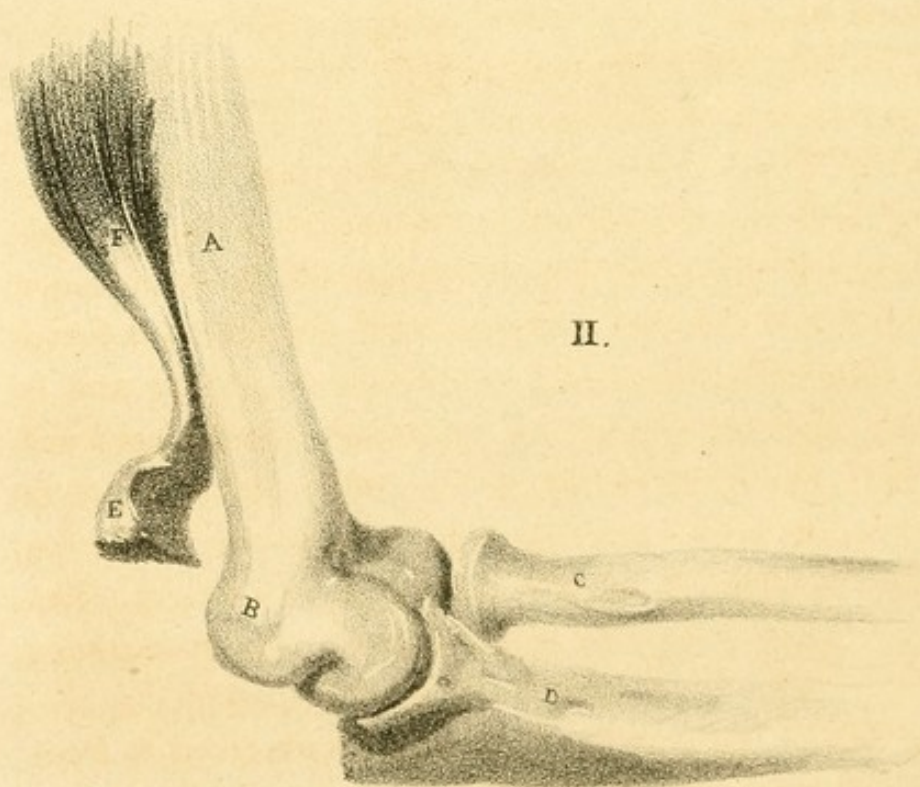
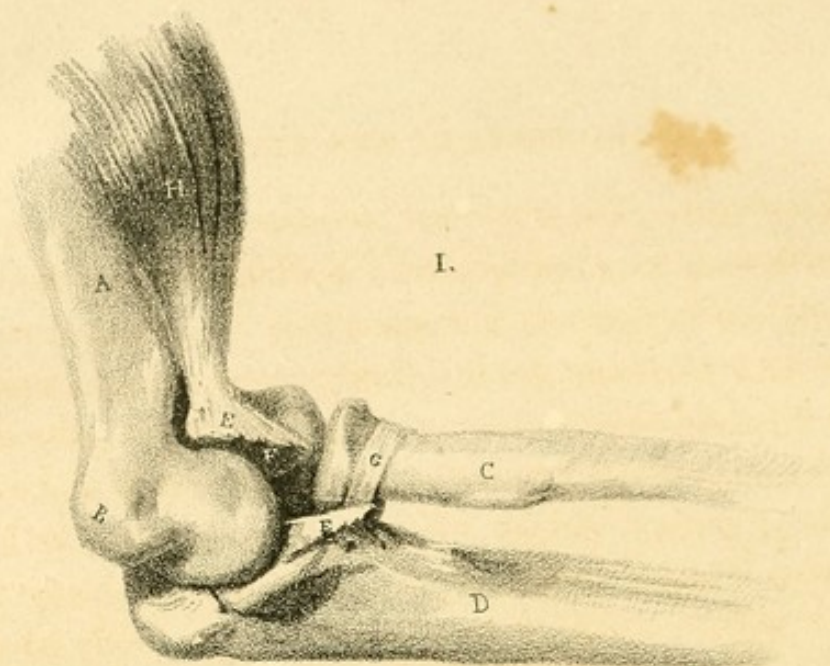
- | | |
|-------------------------------------|---|
| A. Shaft of the Humerus. | E. Detached Coronoid process of the Ulna. |
| B. Internal Condyle of the Humerus. | F. F. Broken surfaces. |
| C. Radius. | G. Annular ligament of the Radius. |
| D. Ulna. | H. Brachialis anticus muscle. |

Appearances and Causes of Displacement.—The appearances which characterize this accident vary considerably. Should the tip merely be broken off, the loose portion will be drawn upward, either on a level with, or above, the coronoid fossa of the humerus. The tendon of the biceps muscle becomes prominent, forming an elevated ridge in the centre of the bend of the arm, in consequence of the falling in of the integument on either side, by the removal of the brachialis anticus and coronoid process from below it. The loose portion of the bone, when the arm is flexed, may be readily felt below the upper part of the tendon of the biceps muscle.

The sole displacing muscle in this fracture is the brachialis anticus, which is attached directly to the upper part of the process.

Should the fracture take place near or at the root of the process, the case becomes more complicated, for then the ulna in the extended position of the forearm is drawn backward and subluxated by the action of the triceps muscle, but this displacement is immediately reduced by flexing the forearm: neither is the dislocation complete, for it is held nearly in its natural situation by the ligamentous connexion with the radius.

The fracture may likewise take place so low down that the attachment of the anterior extremity of the annular ligament of the radius becomes either lacerated or pulled upward: in which case the radius is displaced, the action of the biceps muscle drawing it upward: these cases, however, come more immediately under the head of dislocation.



Treatment.—The treatment recommended in this fracture consists in flexing the forearm; in which position the ulna is brought upward, nearly in contact with the detached portion: a bandage should be applied firmly round the arm, commencing at the shoulder and being carried downward to the elbow; by this means the brachialis anticus muscle is relaxed, the displaced portion of bone brought downward, and its broken surfaces retained in apposition. The forearm, being flexed to the utmost, should now with the arm be firmly bound to the side of the chest. The union of this fracture, in the few cases related, has been generally ligamentous.

FRACTURE OF THE OLECRANON PROCESS OF THE ULNA. [XV. 2.]

A. Shaft of the Humerus.
B. Internal Condyle of the Humerus.
C. Radius.

D. Ulna.
E. Detached Olecranon process.
F. Triceps extensor cubiti muscle.

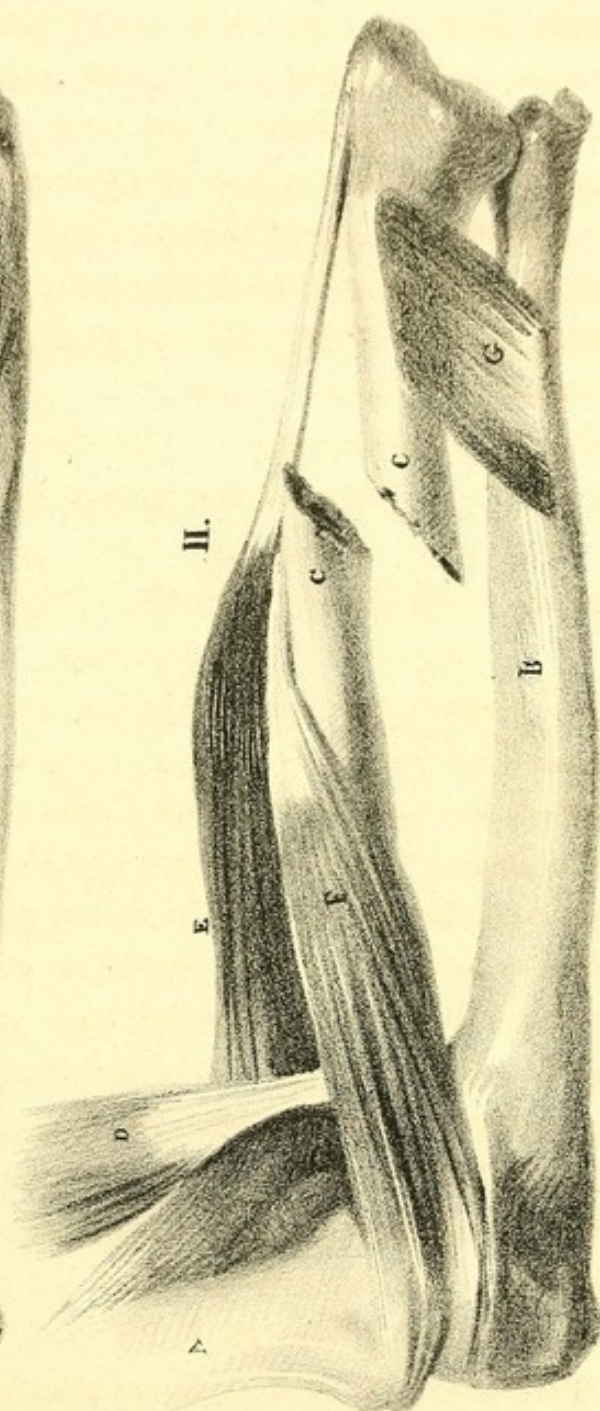
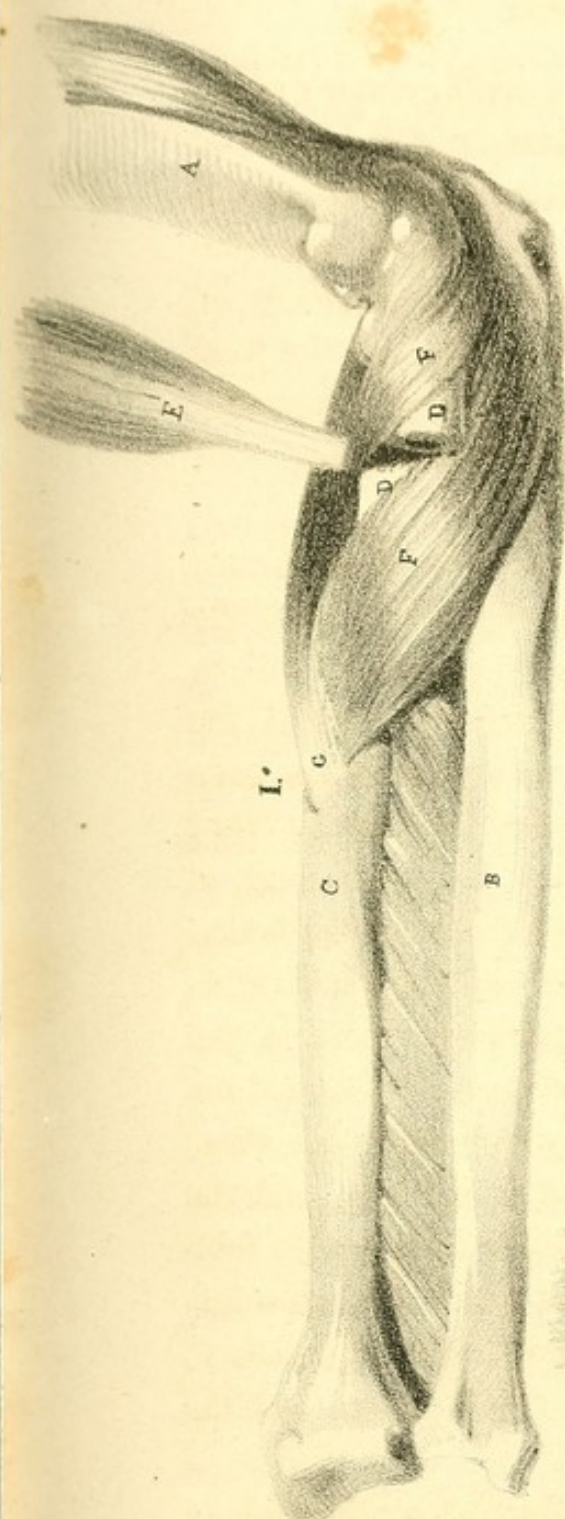Appearances.—This accident is characterized by the following appearances:—In addition to the ordinary pain and swelling, the olecranon process is drawn upward, the prominence of the elbow is lost, and a considerable depression is found at the posterior part. The circumference of the arm is increased by the contraction of the triceps: the patient loses the power of extending the arm at will; and when it is extended, which takes place from the relaxation of the biceps and brachialis anticus, the arm falls by its own weight. The hollow at the posterior part is then considerably diminished; but, when flexed, the depression is much increased.

On referring to the plate, the fracture is observed to have taken place about the centre of the concave articulating surface, (the sigmoid cavity) which is the weakest part of the process. Should the arm be flexed during the fall or blow, the displacement and injury done would be greater than if it had been extended; for in this case the triceps would con-

tract with much more violence, and to a much greater extent : the accident occurring then in this position of the forearm, the surrounding parts suffer much more injury ; the strong ligamentous connexions of the joint are lacerated and contused by the violent action of the muscle, independently of the contusion arising immediately from the force applied from without : and the broken portion is drawn upwards to a greater extent than when the fracture is caused by a less degree of violence.

Causes of Displacement.—The displacement is occasioned solely by the action of the triceps drawing up with it the detached portion ; but even here the displacement will be limited according to the situation of the fracture. Should the tip of the process merely be broken, the portion of the bone will be drawn up much higher than when the fracture takes place at the root ; for when the bone is broken through at the root, the firm ligamentous fibres, viz., those of the lateral and posterior ligaments commonly prevent any considerable degree of displacement ; by simply extending the arm, the surfaces are brought into immediate contact : but should the force under these circumstances have been considerable, these firm ligamentous connexions are broken through, and the displacement then becomes as distinct as in the other fracture. Where the fracture has occurred nearer the extremity, extension of the forearm will not bring the surfaces together ; the loose portion of bone must be drawn down, and the crepitus will then be felt.

Treatment.—The treatment in this fracture consists simply in extending the arm, by which means the broken surface of the shaft of the ulna is brought nearer to the displaced portion. By now placing the hand above the olecranon, it may be brought down, thus approximating the two surfaces : then by moving the loose portion laterally, the crepitus is distinctly felt. Sir



Astley Cooper's bandage [III. 2.] which is fully described on page 34, should now be applied.

FRACTURE OF THE NECK OF THE RADIUS. * [XVI. 1.]

- | | |
|--|---|
| A. Humerus. | E. Biceps muscle. |
| B. Ulna. | F. F. Supinator brevis, cut through to expose |
| C. Radius. | the broken surface of the upper por- |
| D. D. Broken surfaces of the neck of the | tion of the Radius. |
| Radius. | G. Pronator teres muscle. |

Appearances.—It is difficult to detect the exact seat of a fracture of the neck of this bone. The position of the arm at once indicates a fracture of the radius; for in fracture of this bone, the forearm is always in a state of pronation and retains this position; the motions of the forearm are entirely lost, but the extent of pronation is not more than what is natural; (as is the case in all fractures of the radius, this only excepted). Little deformity takes place in fracture at this situation, as the parts are so thickly clothed and surrounded with muscles; the only deviation that is observed is a slight fulness on the anterior and upper part of the forearm, attended with inability to rotate it.

Causes of Displacement.—The upper portion of the bone will be found drawn slightly outward and downward, but not to any considerable extent. It will be remembered that the radius above the fracture, or even perhaps at the fractured part, is surrounded by the annular ligament, which prevents its displacement beyond a certain limit, unless this ligament is lacerated. The action of the supinator radii brevis muscle is the sole cause of the displacement of this portion of the bone: this muscle arises from the outer condyle of the humerus, and is inserted into the anterior part of the head and upper extremity of the radius; its action is to rotate the radius outward: the few fibres attached above the fracture roll the head of the bone outward, and likewise give the broken

surface the same direction. The lower portion of the bone is drawn forward, upward, and inward. The biceps muscle, which is inserted into the tubercle of the radius, and consequently into the upper extremity of the lower portion, is, in the natural state of the parts, a flexor of the forearm through the medium of the radius: independently of this action, it likewise, under certain circumstances, becomes a supinator: the latter of these actions, when fracture has taken place at this point, is entirely lost, in consequence of the separation of the shaft from the upper fixed point upon which it moves; the lower portion of the bone is then drawn forward and slightly upward by the action of the biceps, producing fulness on the anterior part of the arm. But it must be remembered, that the oblique ligament of the radius is now on the stretch, as well as the fibres of the supinator radii brevis, which are in action: these counteract in some degree the effect of the biceps muscle. The lower portion of the bone is drawn inward: this displacement depends upon the action of the pronator teres muscle, which arises from the inner condyle of the humerus, and is inserted into the middle and outer part of the radius: its action is to draw the radius over the ulna, (to pronate the arm,) and it is consequently the cause of the displacement; for the bone, having now no fixed point above on which it can move, by the contraction of this muscle, takes the direction inward. These facts account at once for the difficulty which exists in distinguishing the crepitus, for the broken surfaces look in opposite directions; the upper being directed downward and outward, while the lower is directed inward and upward.

Treatment.—The treatment in this fracture consists in flexing the forearm, and placing it in a state between pronation and supination, in which position the lower portion of the bone is held in a state of perfect rest; for then the biceps,

supinator brevis, and pronator teres, together with the mass of flexor and extensor muscles, are thrown into a state of relaxation. A roller should be applied from the hand to the elbow; previously to which a soft compress should be placed external to the head of the radius, and the bandage passed firmly around, securing it in its situation; by means of which the head of the bone is forced inward and retained in its natural situation. A broad splint applied both to the palmar and dorsal surfaces of the forearm, retains the bones in their natural situations.

FRACTURE OF THE RADIUS NEAR THE CENTRE. [XVI. 2.]

- | | |
|--------------------------------------|-------------------------------|
| A. Humerus. | E. Supinator longus muscle. |
| B. Ulna. | F. Pronator teres muscle. |
| C. C. Broken surfaces of the Radius. | G. Pronator quadratus muscle. |
| D. Biceps muscle. | |

Appearances.—The appearances in this fracture are, a fullness of the upper half of the forearm, with evident diminution of the lower half; the motions of the arm are entirely lost; the lower half is in a state of pronation beyond what is natural; the hand hangs awkwardly with the thumb downward.

Causes of Displacement.—The upper portion of the bone will be found drawn upward and inward, producing the fullness described at the upper part of the forearm: this arises from the actions of the biceps and pronator teres muscles. The biceps, which is inserted into the tubercle of the radius, draws the superior portion of the bone upward, and at the same time rolls it outward, giving it the position of supination; while the pronator teres, which is inserted into the lower end of the upper portion, draws it inward, and partly counteracts the actions of the biceps and supinator brevis (the situation of which muscle is shown in the last plate); so that this portion of the bone is held between pronation and supination,

inclining to the latter position. The lower portion will be found drawn downward and inward to a state of complete pronation, the broken surface inclining towards the ulna, and nearly in contact with it, moving on a fixed point,—its attachment to the lower extremity of the ulna. This displacement is caused by the action of the pronator quadratus muscle, which arises from the anterior surface of the ulna, and is inserted into the radius, as seen in the plate. This portion of the bone is likewise drawn into a state of pronation by the same muscle. The supinator radii longus muscle, instead of performing its natural action, in consequence of the lower extremity of the bone having now lost its centre of motion above, assists in depressing the broken surface; for by the action of this muscle, the styloid process is elevated, being the lever in which the muscle is inserted: the ulna then becomes the fulcrum upon which the radius moves, so that the upper extremity of the lower portion of the radius is held in contact with the ulna, by means of the supinator radii longus and pronator quadratus muscles.

Treatment.—The elbow is to be bent, the hand to be placed in a position between pronation and supination, that is, the palm of the hand should look to the breast of the patient. After reducing the ends of the fracture when they appear to be displaced, the common splints are to be applied. Only two splints are necessary, one to be placed along the inside, the other on the outside of the forearm.

FRACTURE OF THE SHAFT OF THE ULNA. [XVII. 1.]

A. Humerus.

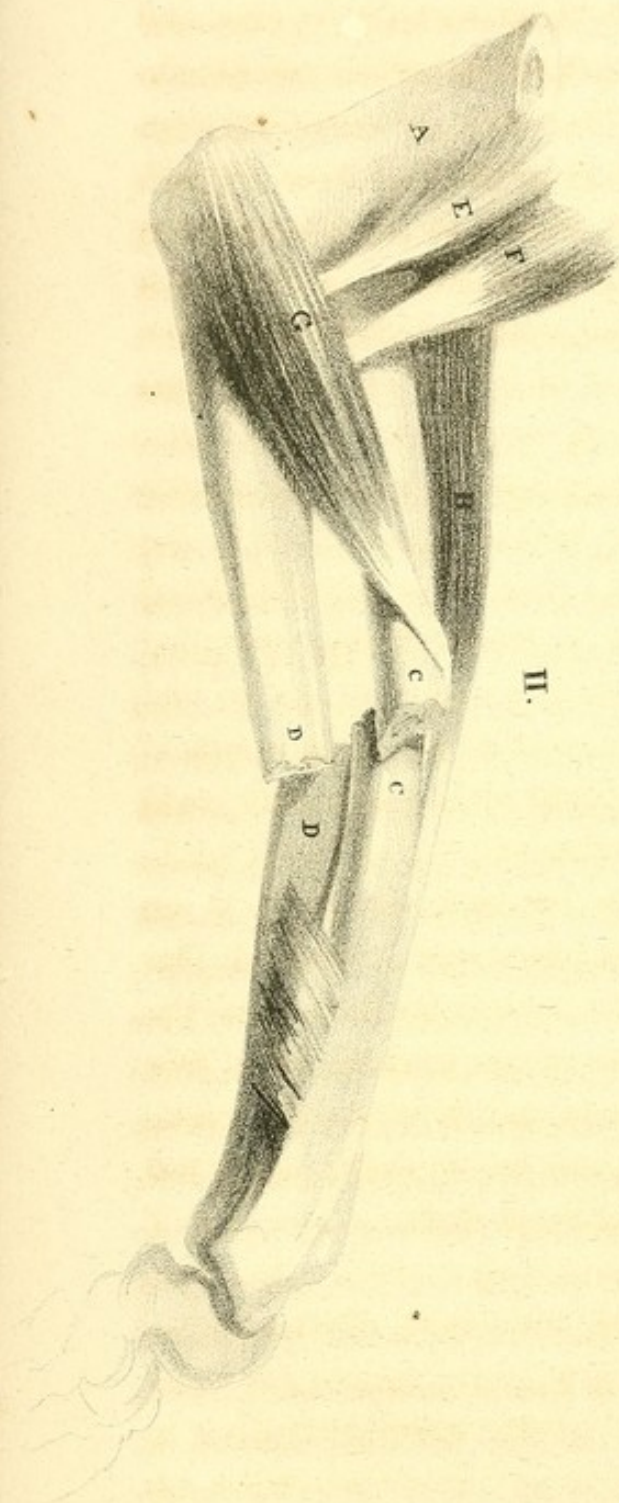
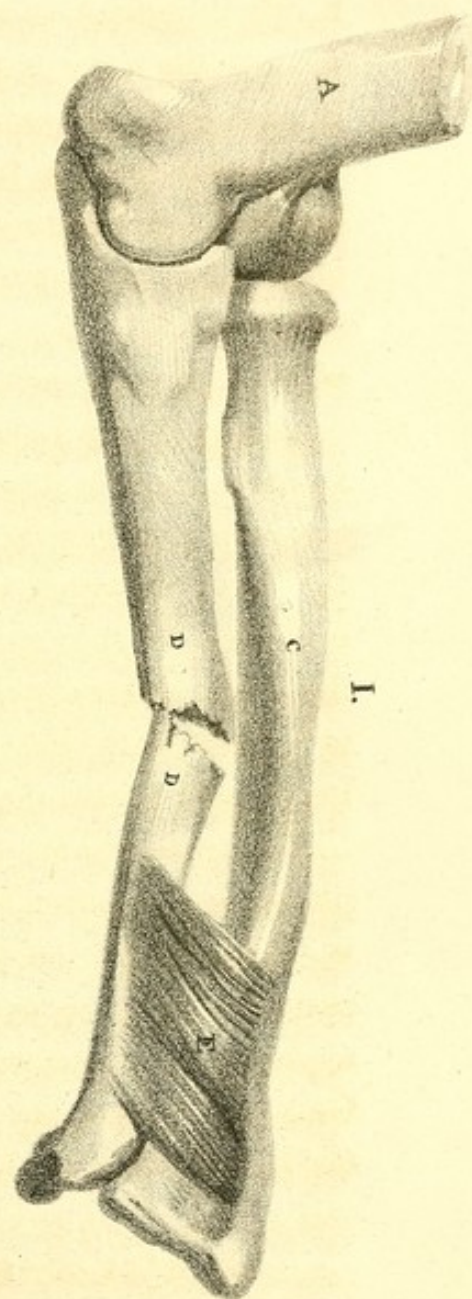
B. Inner Condyle of the Humerus.

C. Radius.

D. D. Broken surface of the Ulna.

E. Pronator quadratus muscle.

Appearances.—In fractures of this character, when the ulna is traced with the fingers, an evident depression can be



felt at the inner and inferior part, in consequence of the lower portion of the ulna being directed outward against the radius. The arm will likewise present an appearance of tumefaction, not only at the immediate situation of the fracture, but also upon the dorsal and palmar surfaces, by the partial protrusion of the muscles lying upon the interosseous ligament. The position of the limb will not be considerably changed; the motions are performed imperfectly, but still some degree of lateral movement may be accomplished by the patient without assistance, although it is attended with much pain.

Causes of Displacement.—The positions of the two portions of the bone are accurately represented in the accompanying plan. The upper portion of the bone is retained in its natural situation by the brachialis anticus muscle. The carpal or lower extremity will be displaced by the action of the pronator quadratus, which draws the broken surface outward in contact with the radius.

The radius has, in consequence of the fracture of the ulna, lost its principal means of support, which is the ulna; so that the weight of the hand depresses the radius, bringing it in contact with the broken surface of the upper portion of the ulna, which retains its natural situation. The radius is not thrown into a state of pronation; for the muscles performing the actions of pronation and supination are on the stretch when the arm is depressed, and by their combined actions retain the bone nearly in its natural situation. The supinators overcome the action of the pronators, and the radius is not acted on by the pronator quadratus, as its fixed point of origin, which is the ulna, is set at liberty: the action of the supinators, however, is still retained, so that, were it not for the weight of the hand, the forearm would be thrown into the utmost state of supination.

Treatment.—Extension having been made, the muscles

replaced, and the fractured surfaces brought into apposition, the forearm should be flexed, and held in a position between pronation and supination. In the fracture of the bones of the forearm, considerable care is requisite to keep the bones separated, as they tend to fall to the interosseous space, where the radius sometimes becomes united with the ulna, (anchylosed,) by which the rotatory motions of the forearm are entirely lost. The essential point in the treatment of this fracture consists in preserving this interosseous space undiminished: this is accomplished by placing two pads of soft material, one on the palmar and another on the dorsal surface of the forearm: firm splints should now be applied over these compresses, by which means they force the muscles which have been displaced into their natural situation between the bones, and prevent their approximation. Bandages are not usually recommended in these fractures; but simply an occasional strip, one at the elbow, another at the wrist, and a third in the centre of the forearm, which are amply sufficient to hold the splints in their places. The whole should now be supported in a sling, and the hand should be kept in a line with the forearm, the thumb upwards.

FRACTURE OF THE RADIUS AND ULNA NEAR THE
CENTRE. [XVII. 2.]

- | | |
|-------------------------------------|------------------------|
| A. Os humeri. | F. Biceps muscle. |
| B. Inner Condyle of the Humerus. | G. Pronator teres. |
| C. C. Broken surface of the Radius. | H. Supinator longus. |
| D. D. Broken surface of the Ulna. | I. Pronator quadratus. |
| E. Brachialis internus. | |

Appearances.—When both bones of the forearm are broken, there is little shortening of the limb, but an angular bend may be readily seen, by the bones projecting and pushing out the soft parts on the dorsum; the wrist is drawn forward; a degree of swelling is seen, not only on the dorsum, but

also on the palmar surface of the forearm, in consequence of the displacement of the muscles lying upon the interosseous ligament; the power of pronation and supination is entirely lost, and the slightest motion of the hand is extremely painful. The crepitus is perceived upon making extension and at the same time rotating the arm at the wrist.

Causes of Displacement.—The displacement of the bones depends upon the following causes:—

Most generally, although not always, the lower portions of the bones of the forearm are drawn backward, as seen in the plate; they are occasionally drawn forward; this, however, depends altogether upon the nature and manner of the force or weight applied. The portion of the radius above the fracture will be found inclining upward and inward, and lying above the level of the ulna: this position depends upon the action of the biceps and pronator teres muscles; the former of which raises the broken surface, while the latter inclines it inward. This portion of the radius will likewise be rolled upon itself by the biceps acting as a supinator together with the supinator brevis. The upper portion of the ulna retains nearly its natural situation, but is a little elevated by the brachialis anticus muscle: the normal space between the bones is always maintained above the fracture. The principal displacement occurs below the fracture: the radius rolls to the inner side of the ulna in a state of pronation, by the action of the pronator quadratus muscle added to the weight of the hand; the broken surfaces are then in contact, and are drawn upward by the combined actions of the flexor and extensor muscles.

Treatment.—The treatment adopted in this case is the same as in fracture of the ulna. [See description of fig. 1, plate xvii.]

FRACTURE OF THE LOWER ENDS OF THE RADIUS AND ULNA. [XVII. 1.]

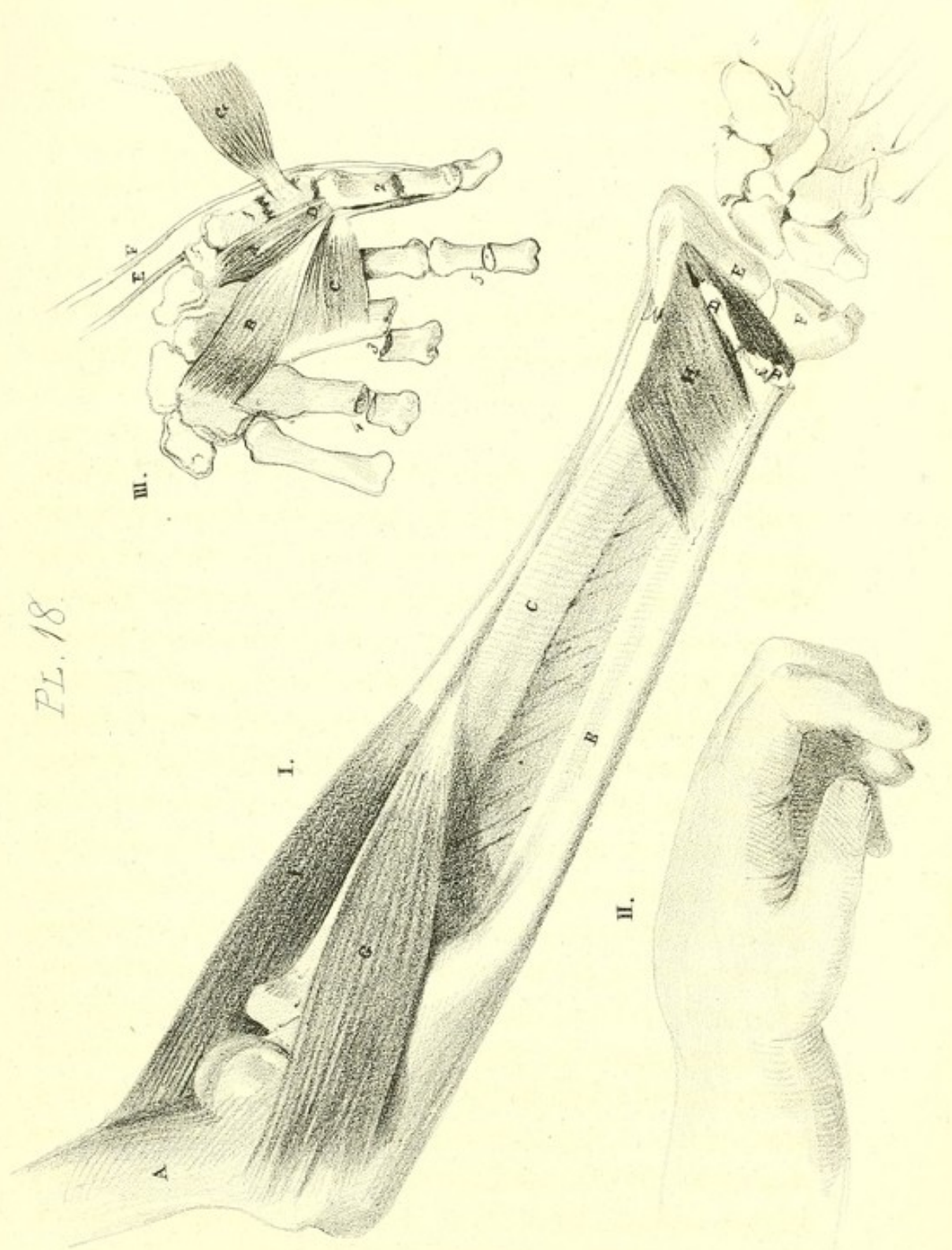
- | | | | |
|-------|--|-------|------------------------------------|
| A. | Humerus. | E. | Lower end of the Radius displaced. |
| B. | Ulna. | F. | Lower end of the Ulna displaced. |
| C. | Radius. | G. | Pronator teres. |
| D. D. | Broken surfaces of the upper portions
of the Radius and Ulna. | H. H. | Pronator quadratus. |
| | | I. | Supinator longus. |

THE APPEARANCE OF THE WRIST

AFTER FRACTURE HAS TAKEN PLACE, AND ITS RESEMBLANCE TO DISLOCATION. [XVII. 2.]

- | | | | |
|----|-----------------|----|-----------------|
| A. | Dorsal surface. | B. | Palmar surface. |
|----|-----------------|----|-----------------|

Appearances.—This injury usually arises by a fall from a height. In two cases of late occurrence, from which the accompanying drawings were made, the fracture was occasioned by the patient falling from the window-sill, while in the act of cleaning the window. The appearances in this fracture very much resemble those presented in dislocation of the carpus backward: great pain is felt at the seat of injury, and considerable bruising, and ecchymosis is the consequence, accompanied always with projection as well as tumefaction on the anterior part just above the carpus; for it generally happens that this point comes in contact with the ground, by which means the detached lower ends of the bones are driven backward, while the broken surfaces of the upper portions of the bones are forced forward, producing the prominence on the anterior part, in consequence of the integument being drawn tightly round them, thus rendering the displacement more evident. Fig. 2, of the accompanying plate will explain this; for the detached portions will be seen drawn upward behind the ends of the upper portion, by which means a prominence takes place on the back part below the level of that which exists on the anterior part; so that when the swelling exists on the one side, a corresponding depression necessarily takes place at the point immediately opposite.



Another great peculiarity in this accident is the position of the hand compared with that of the forearm: the hand will be found in the position between pronation and supination, at the same time that the forearm is in a state approaching to a more complete pronation, though not to the full extent. The parts being thus displaced, considerable force will be required in order to produce sufficient extension to render the crepitus distinct; and when the extension is accomplished, and the force again withdrawn, the parts immediately resume the same situation: the control of the rotatory motions of the arm is completely lost.

Causes of Displacement.—The lower extremities of the bones of the forearm are instantly drawn up by the combined actions of the flexors and extensors, and held behind the lower ends of the upper portions. (In a dissection made by Mr. Arnott, in a girl who died with peritonitis, consequent upon the injuries received during a fall which produced this accident, the situation of the parts was precisely that which is represented in fig. 1.) Independently of the drawing backward of these portions, their broken surfaces are held together by a few remaining fibres of the pronator quadratus; and in the case just alluded to, the broken surface of the upper portion of the radius projected through the fibres of that muscle. The situation of these portions, likewise, will at once explain why the hand takes a direction different from that of the forearm. The broken surfaces of the shafts of the two bones will be found drawn almost in close relation by the action of the pronator quadratus, and thrown into a state of pronation by the pronator teres, the broken surfaces projecting forward; so that the detached portions are held in close relation behind the upper portions; the styloid process of the radius being elevated by the supinator longus, and the wrist supported by the extensor carpi radialis longior and brevior, and by the extensors of the thumb.

Treatment.—The treatment recommended in this case is the same as described in the fracture of these bones higher up. (See description of plate xvi. fig. 2.)

FRACTURES OF THE FINGERS. [XVII. 3.]

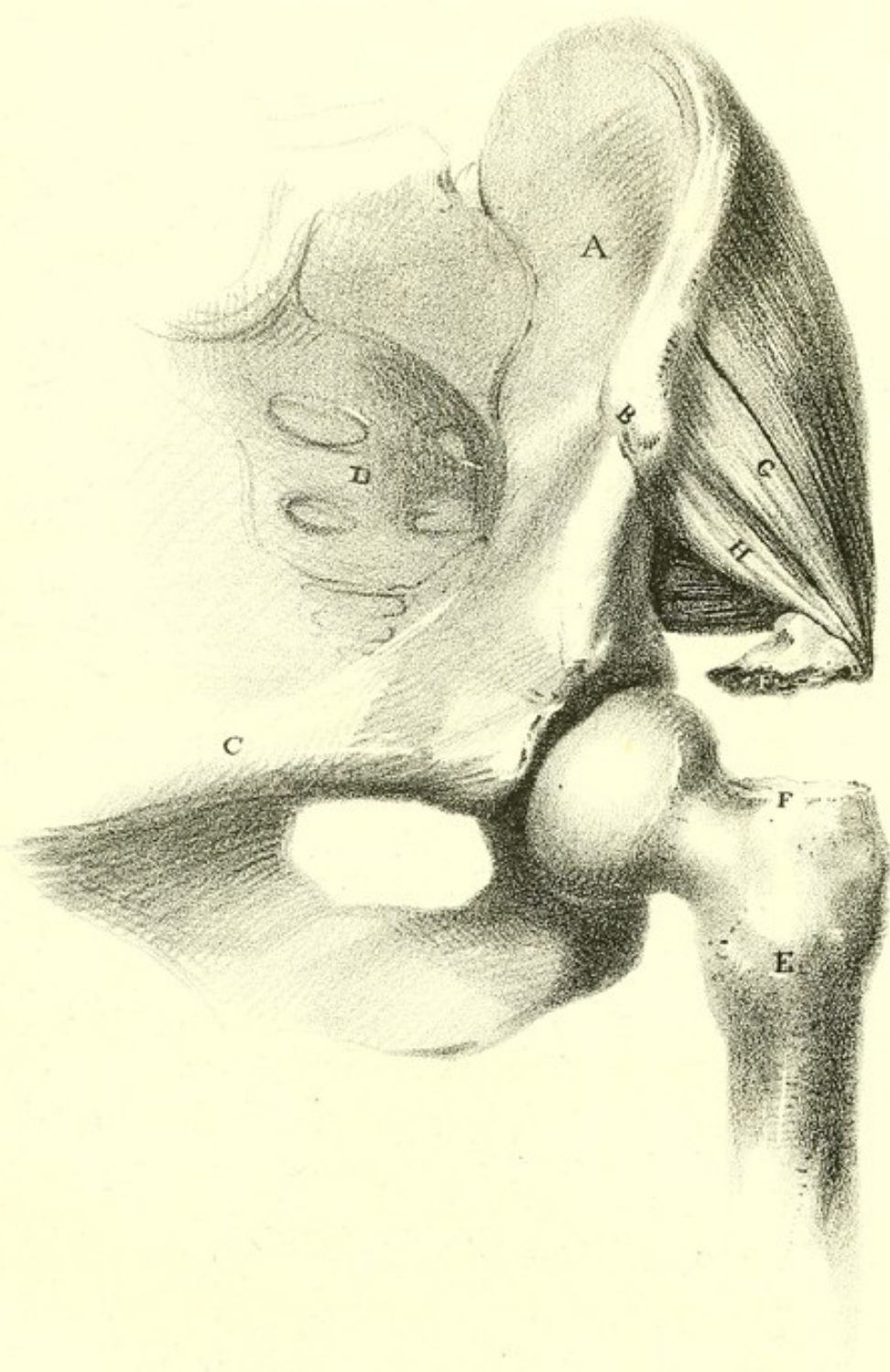
- | | |
|--|--|
| 1. Fracture of the metacarpal bone of the thumb. | 4. Fracture of the metacarpal bone of the ring finger. |
| 2. Fracture of the first phalanx of the thumb. | 3. Fracture of the first phalanx. |
| 3. Fracture of the metacarpal bone of the middle finger. | |


- | | |
|--|--|
| A. Opponens pollicis. | E. Abductor longus pollicis. |
| B. Part of the Flexor brevis pollicis. | F. Extensor secundi internodii pollicis. |
| C. Adductor brevis pollicis. | G. Abductor brevis pollicis. |
| D. Tendon of Flexor longus pollicis. | |

Causes of Fracture.—Fractures of the bones of the metacarpus are always caused by the direct application of force. If the hand be pressed forcibly between two bodies, or if a heavy body fall on it, comminuted fracture will be the result, and most generally several of the metacarpal bones are fractured at once.

Treatment.—The same kind of treatment is requisite as in the preceding cases. To preserve the bones in their natural situation, the palm of the hand is laid over a cushion or pad adapted to the hollow of the palm and fingers, and then a roller is to be brought down over the forearm, over the hand and wrist, including the pad.

When the bones of the fingers are broken, they are to be set with pieces of pasteboard, moistened, over which a small roller of tape is to be applied. The hand is to be placed on a flat splint or finger-board, always keeping the hand, forearm, and elbow, well supported in a sling.





FRACTURE OF THE GREAT TROCHANTER OF THE FEMUR. [XIX.]

A. Ilium.	E. Femur.
B. Anterior superior spinous process of the Ilium.	F. F. Broken surfaces of the Trochanter major.
C. Pecten of the Pubes.	G. Glutæus medius muscle.
D. Sacrum.	H. Glutæus minimus muscle.

Appearances.—The appearances, when this accident has taken place, will scarcely lead to the suspicion of fracture: the patient refers you to the seat of pain; but, from the indistinctness of these parts even in the natural condition, little can be gained by examination. The position of the limb remains unaltered; there is neither eversion nor shortening, but the foot is generally benumbed. In a case related by Sir A. Cooper, the patient, who was a girl aged sixteen, walked to her home, and did not apply for advice till six days after the accident. The best mode of distinguishing the nature of the injury, is to place the patient in the erect position, and to bring the knees together; for in that position the trochanters are rendered most prominent: and upon comparing the two sides, and examining with the fingers applied to either, a depression may be detected between the loose and fixed portions; but the force requisite in producing this fracture creates occasionally so much tumefaction, that we may be deprived even of this assistance. The portion of bone which is displaced is likewise so small that it is with difficulty distinguished. A slight prominence and increased rigidity may be observed above the trochanter, and by abducting the thigh, at the same time that the glutæi muscles are pressed downward, an indistinct crepitus may be felt.

Where the fracture has occurred from excessive violence, the displacement will take place to a much greater extent than when a less degree of force is applied; for in the former case the strong prolongation of the tendons will be lacerated.

Causes of Displacement.—The displacement is caused by

the action of the glutæus medius and minimus muscles, by which the loose portion of bone is drawn upward and inclined forward; but should the fracture have taken place at the root, then the displacement of the detached portion will be greater; for by the attachments of the external rotators, viz., the pyriformis, gemellus superior, obturator internus, gemellus inferior, and obturator externus, all of which are inserted into the pit of the trochanter, it would be drawn not only upward, as shown in the plate, but inward toward the dorsum of the ilium, thus facilitating considerably the diagnosis of the injury.

For the treatment of this fracture we refer our readers to page 39.

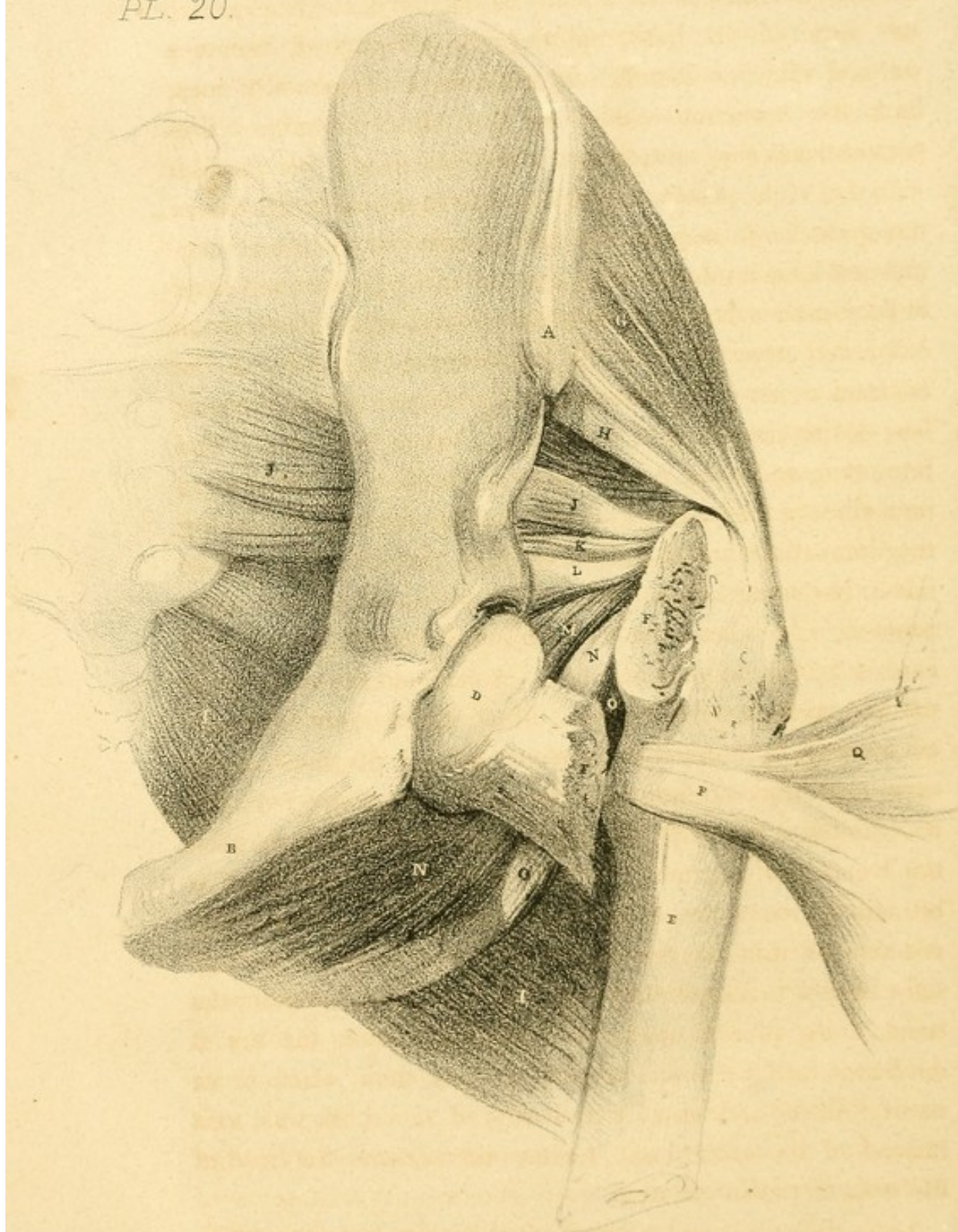
FRACTURE OF THE NECK OF THE THIGH-BONE.* [XX.]

A.	Anterior superior spinous process of the Ilium.	I. I.	Glutæus maximus muscle.
B.	Pubes.	J. J.	Pyriformis muscle.
C.	Sacrum.	K.	Gemellus superior muscle.
D.	Head of the Femur.	L.	Obturator internus muscle.
E.	Shaft of the Femur.	M.	Gemellus inferior muscle.
F. F.	Fractured surfaces of the Femur.	N. N.	Obturator externus muscle.
G.	Glutæus medius muscle.	O. O.	Quadratus femoris muscle.
H.	Glutæus minimus muscle.	P.	Iliacus internus reflected.
		Q.	Psoas magnus reflected.

Appearances.—This injury is characterized by shortening of the limb and eversion of the foot, which form the principal diagnostic marks of the accident: it is distinguished from dislocation either upon the pubes or into the thyroid foramen; as in neither of these cases is there any degree of shortening, although the foot takes the same direction, outward. In dislocations upward, the leg becomes shorter, but the toes are invariably directed inward. The shortening of the limb may take place to the extent of two inches, or even more; but in

* The upper part of the shaft of the femur is here necessarily drawn outwards somewhat beyond the situation it would naturally occupy, for the purpose of showing more fully the muscles at the posterior part, which would be otherwise entirely concealed.

PL. 20.



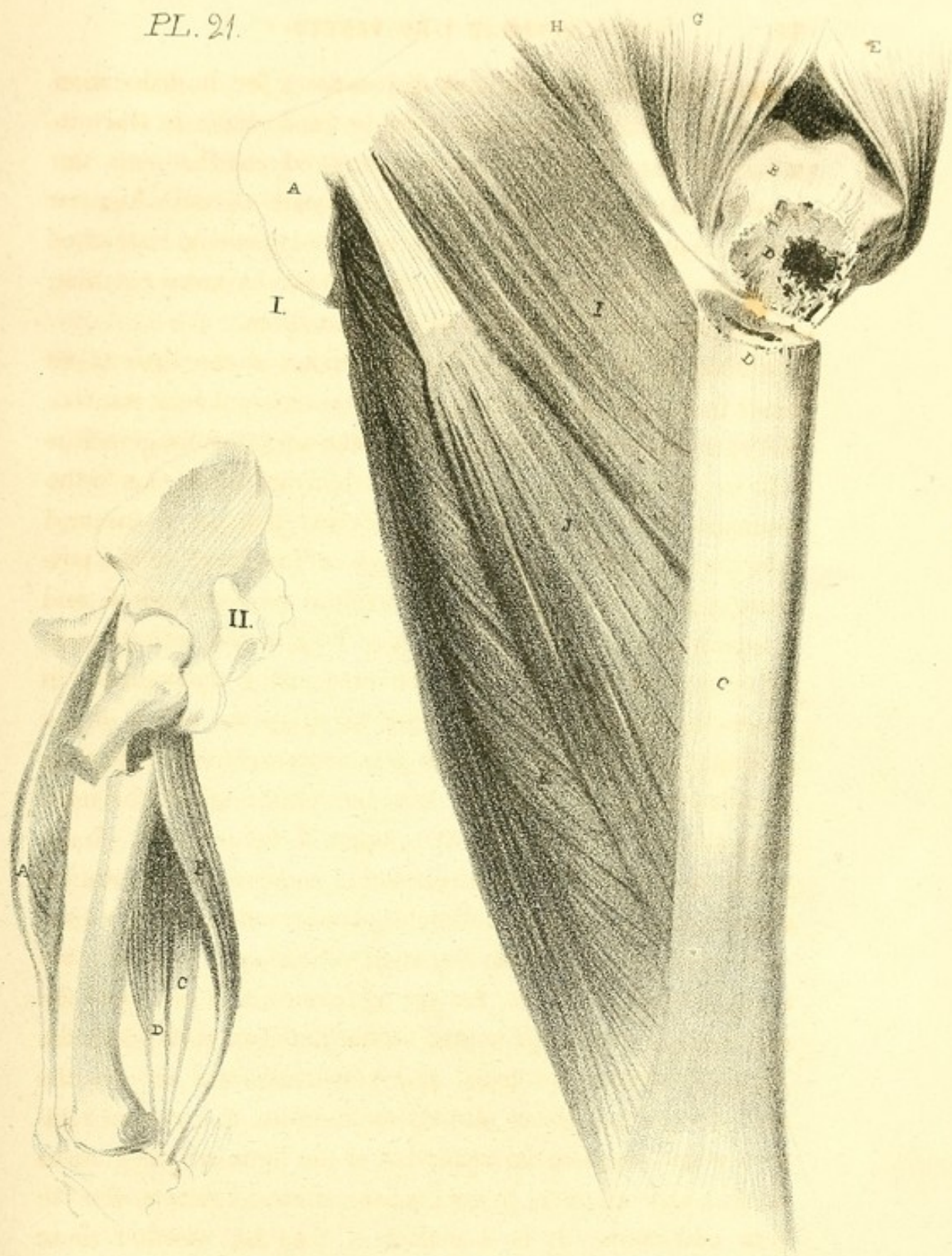
some cases, though these are rare, little deformity occurs, as when the fracture takes place at the root of the trochanter; the neck of the bone, splitting the trochanters, becomes wedged into the fissure, and may, as it occasionally does, limit the retraction and eversion of the extremity. The patient loses the control over the limb, which lies parallel with that of the uninjured side: deep-seated pain is also felt in the groin, in consequence of the pressure of the *psoas magnus* and *iliacus internus* over the capsular ligament and head of the bone: a degree of unnatural fulness takes place at the outer and upper part of the hip, from the swelling of the contracted muscles; although the trochanter major becomes less distinct, not only in appearance, but to the touch. The retraction, and even the eversion of the limb, do not always immediately follow the injury. In such cases, however, by the immediate rotation of the limb, the crepitus can be instantly distinguished. Where the limb assumes the usual position, i. e. shortened and turned outward, the crepitus cannot be felt, unless extension is made so far as to bring the limb to its original length. Much unnecessary pain may be avoided by abducting the upper part of the bone, at the same time that the limb is rotated and fully extended: this accomplished, the hand should be made to press firmly upon the trochanter, for now the broken surface of the shaft is brought down to the broken surface of that portion which remains fixed in the acetabulum; and by rotating the limb, the crepitus is immediately felt. In producing rotation, the hand being placed upon the trochanter major, the arc it describes will be found somewhat less than when in its natural state, and as though it moved round its own axis instead of the natural and more remote centre. the head of the bone in the acetabulum.

• Little difficulty can be experienced in this case as to deter-

mining between fracture and dislocation ; for in dislocation the head of the bone remains firmly fixed, while in fracture a certain degree of motion is permitted : neither can the bone be extended as readily as in dislocation ; and when the dislodgement of the head of the bone commences, instead of gliding smoothly as in fracture, it descends by jerks, catching on the irregularities of the opposing surfaces.

Causes of Displacement.—The eversion of the limb takes place from the combined actions of the external rotators, viz., the pyriformis, gemellus superior, obturator internus, gemellus inferior, obturator externus, all of which are inserted into the trochanteric fossa, while the quadratus femoris is inserted into the intertrochanteric line ; these are situated on the posterior part : on the anterior part, the psoas magnus and iliacus internus, which run down to be inserted into the posterior surface of the lesser trochanter, also act powerfully in producing the eversion. These, aided by the action of the glutæi, together with that of the pectinæus and triceps adductor muscles, which are inserted into the inner edge of the linea aspera, assist in producing this change in the position. Independently of the actions attributed to some of those muscles already enumerated as rolling the bone outward, they likewise combine in drawing the shaft of the bone upward ; but independently of these, the rectus femoris will be found the principal agent in this action on the anterior part, while the biceps, semimembranosus, and semitendinosus act on the posterior part. Those already enumerated as external rotators, which assist in the retraction of the limb, are the glutæus medius and minimus, psoas magnus, iliacus internus, and the four adductors. It is a matter of dispute, whether these muscles are actually the cause of the eversion : it is thought by some, that the eversion arises from the natural inclination of the limb and weight of the foot.

PL. 21.



The first of these was the establishment of the first public school in the city, in 1630. This was the first of a long series of schools which have since been founded in the city, and which have played a great part in the education of the people of Boston. The second was the establishment of the first public library in the city, in 1630. This was the first of a long series of libraries which have since been founded in the city, and which have played a great part in the education of the people of Boston. The third was the establishment of the first public hospital in the city, in 1630. This was the first of a long series of hospitals which have since been founded in the city, and which have played a great part in the education of the people of Boston. The fourth was the establishment of the first public workhouse in the city, in 1630. This was the first of a long series of workhouses which have since been founded in the city, and which have played a great part in the education of the people of Boston. The fifth was the establishment of the first public almshouse in the city, in 1630. This was the first of a long series of almshouses which have since been founded in the city, and which have played a great part in the education of the people of Boston. The sixth was the establishment of the first public prison in the city, in 1630. This was the first of a long series of prisons which have since been founded in the city, and which have played a great part in the education of the people of Boston. The seventh was the establishment of the first public court in the city, in 1630. This was the first of a long series of courts which have since been founded in the city, and which have played a great part in the education of the people of Boston. The eighth was the establishment of the first public office in the city, in 1630. This was the first of a long series of offices which have since been founded in the city, and which have played a great part in the education of the people of Boston. The ninth was the establishment of the first public church in the city, in 1630. This was the first of a long series of churches which have since been founded in the city, and which have played a great part in the education of the people of Boston. The tenth was the establishment of the first public school in the city, in 1630. This was the first of a long series of schools which have since been founded in the city, and which have played a great part in the education of the people of Boston.

Treatment.—For the treatment of this fracture many plans have been suggested; some surgeons preferring the straight position of the limb, and extension produced by the application of Dessault's splint: by others, Boyer's apparatus for fractures of the neck of the femur, [IV. 1.] described on page 36, is used; but the mode now most usually adopted, as combining simplicity of application and comfort to the patient, is that recommended by Amesbury, and described on p. 38.

FRACTURE OF THE FEMUR BELOW THE TROCHANTER MINOR.

[XXI. 1.]

- | | | | |
|-------|-------------------------------|----|--------------------------|
| A. | Pubes. | G. | Iliacus internus muscle. |
| B. | Upper portion of the Femur. | H. | Psoas magnus muscle. |
| C. | Shaft of the Femur. | I. | Pectinæus muscle. |
| D. D. | Broken surfaces of the Femur. | J. | Adductor longus muscle. |
| E. | Glutæus medius muscle. | K. | Adductor magnus muscle. |
| F. | Glutæus minimus muscle. | | |

Fig. II. Exhibits the muscles retracting the lower portion of the Femur.

- | | |
|--------------------|---|
| A. Rectus femoris. | C. D. Semimembranosus and semitendinosus. |
| B. Biceps. | |

Appearances.—The most prominent feature in the character of the limb subsequent to this accident, is an unnatural protrusion at the upper part of the thigh, in consequence of the drawing forward of the upper portion: an unusual degree of pain takes place, when the fracture occurs in this situation, from the greater degree of displacement that exists; the broken and ragged surface being drawn directly forward, more or less of the soft parts suffer injury and laceration. The limb will become slightly everted, and at the same time shortened.

The displacement will be found to exist principally in the upper portion of the bone, the lower having suffered slight eversion, and being somewhat retracted: the crepitus cannot be perceived, as is usual, by extending and rotating the limb,

for the two surfaces look in nearly opposite directions ; that of the superior portion will be directed upward and forward, while the lower will look backward and incline downward. Should the attempt to reduce the fracture be made by depressing the upper portion, and extending the lower till the surfaces meet, much unnecessary pain will be the consequence ; for on removing the pressure, the bone would be again immediately drawn upward, to the same situation it before occupied, when fresh laceration of the soft parts would be the result ; hence, the fracture should be reduced by raising the thigh until the lower portion is brought upon the same line with the upper, when the deformity will disappear.

Causes of Displacement.—The upper portion of bone will be found projecting almost at a right angle with the pelvis, producing the elevation already described, in consequence of the actions of the *psoas magnus* and *iliacus internus*, both of which are inserted by means of a combined tendon in the posterior surface of the lesser trochanter ; it will also be rolled outward upon its own axis, by the actions of the two last-named muscles, together with that of the external rotators, viz., the *pyriformis*, *gemellus superior*, *obturator internus*, *gemellus inferior*, *obturator externus*, and *quadratus femoris*, as seen inserted into the pit of the trochanter, in the foregoing plate, at the same time that its natural obliquity will be somewhat destroyed by the actions of the *glutæi* muscles. The displacement of this portion is considerably greater than when the fracture occurs at the middle of the shaft, for in the latter case a greater surface of resistance is offered by the opposing soft parts above it, independently of the longer lever power of the bone, which would in some degree oppose the action of the displacing muscles.

The lower portion is displaced principally by the actions of the *pectinæus* and the three adductor muscles ; all of

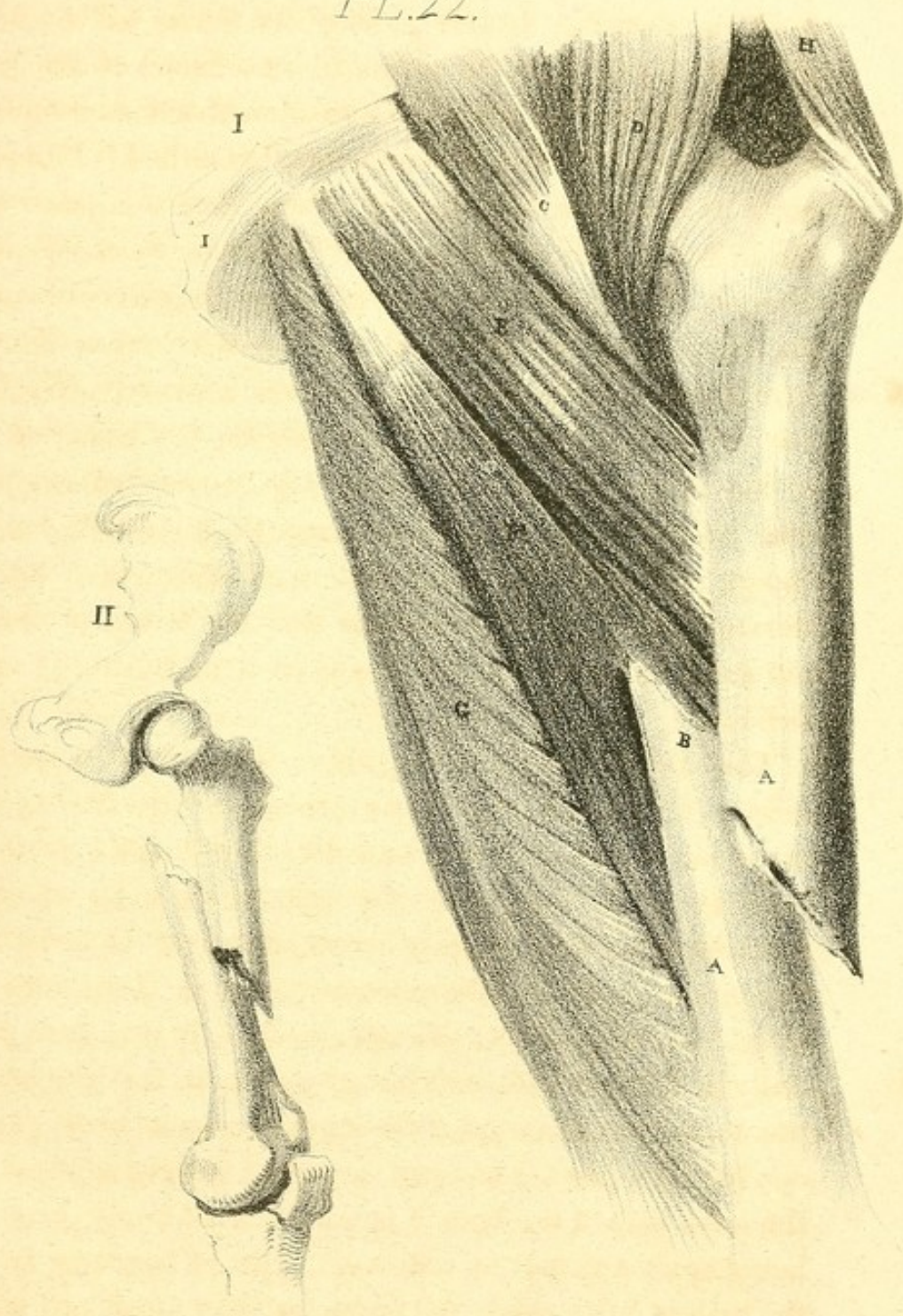
which being inserted into the inner edge of the linea aspera, draw this portion upward and inward, at the same time that it is slightly everted by the same muscles, directing the toe outward. The retraction of the limb is produced by the actions of the rectus on the fore part, and by the biceps, semimembranosus, and semitendinosus on the posterior part; so that the broken surface of this extremity of the bone is pulled upward, behind and to the inner side of the upper portion.

Treatment.—The plan of treatment in all fractures of the thigh, whether occurring high up, as in the accompanying plan, or in the situation of the two succeeding ones, is generally the same. The means adopted, however, are of two kinds; each having strenuous supporters, and each pretending to possess a decided superiority over the other. The one consists in placing the limb upon the double inclined plane, by which the displacing muscles are all brought more or less into a state of repose; the other, in extending the limb by means of the long splint, without any attention to the great principle in the treatment of fracture,—the relaxation of the displacing muscles. In the former, the plan of proceeding, as soon as circumstances will admit, is to produce extension at the knee, at the same time that the lower portion is raised on a line with the upper, when the broken surfaces are brought in contact; for the upper portion is drawn up, and there held so firmly, that some little difficulty will be experienced in depressing it, and when brought down to its proper level, its tendency to the original displacement will be a means of great annoyance and difficulty during the after treatment; so that by raising the lower portion, and bringing it to the same level with the upper, the difficulties are in a great measure obviated. In this position the thigh should be surrounded with a cotton roller neatly applied from the knee to the hip; and a broad splint, lined with lint or tow, should

be placed along the outer part of the limb, while another also should be applied to the inner side : both being secured firmly by means of a broad cotton roller ; the limb being now laid upon the inclined plane, and the patient placed nearly in a sitting posture. In this position the femur will be flexed upon the pelvis, and the points of attachment of the *psoas magnus* and *iliacus internus* approximated, and consequently their power and extent of contraction diminished. Independently of the advantage already arising from this position of the limb, the retracting muscles will likewise be considerably relaxed ; for the knee being elevated and the pelvis advanced, the attachments of the *rectus* are brought nearer each other, so that its action is in a great measure lessened. We have yet remaining the retractor muscles on the posterior part of the thigh : the position of the leg on the inclined plane also answers the end of relaxing these, which are the *biceps*, *semimembranosus*, and *semitendinosus* ; for, by flexing the leg, their insertions into the bones of the leg are made to approach their origins from the tuberosity of the ischium.

The application of the long splint is as simple as the foregoing. The limb having been extended, and the bones placed in apposition, the surgeon commences by rolling the extremity from the foot to the hip, enveloping it thickly in its whole extent with successive layers of cotton bandages : the limb during this process is kept in the extended position. Dessault's long splint is now applied to the outer surface, having been previously well lined with soft tow or cotton, so that the adaptation to the irregularities of the surface may be more perfect, and likewise prevent unequal pressure : having adjusted it to the outer side of the limb, it is now secured firmly (extension being again applied) by repeated layers of bandage, so that the limb is fairly cased and immoveable. A soft pad is now

PL.22.



THE HISTORY OF THE
CITY OF BOSTON
FROM THE FIRST SETTLEMENT
TO THE PRESENT TIME
IN TWO VOLUMES
BY NATHANIEL BENTLEY
OF THE BARR

THE FIRST VOLUME
CONTAINING THE HISTORY
FROM THE FIRST SETTLEMENT
TO THE YEAR 1780
LONDON: PRINTED BY J. JOHNSON, ST. PAULS CHURCH-YARD, 1787

THE SECOND VOLUME
CONTAINING THE HISTORY
FROM THE YEAR 1780
TO THE PRESENT TIME
LONDON: PRINTED BY J. JOHNSON, ST. PAULS CHURCH-YARD, 1787

to be placed between the scrotum and upper part of the thigh of the injured side ; a broad strong tape is placed below the pad, the ends of which are brought outward, one anterior to the thigh, the other behind it : the two ends of the tape are now carried through separate divisions in the upper part of the splint, and, when pulled upon in a direction downward, act as a lever, forcing the splint downward, and with it the limb to which it is attached : in this way extension is made until the limbs are of equal length, when they are secured by a knot, so that the extension may be either diminished or increased at will.

FRACTURE OF THE SHAFT OF THE FEMUR NEAR THE CENTRE.

[XXII. 1.]

- | | |
|-------------------------------------|----------------------------|
| A. A. Femur. | F. Adductor longus muscle. |
| B. B. Broken surfaces of the Femur. | G. Adductor magnus muscle. |
| C. Psoas magnus muscle. | H. Glutæus medius muscle. |
| D. Iliacus internus muscle. | I. Symphysis of the Pubis. |
| E. Pectinæus muscle. | |

The circumstances connected with the causes of displacement, and treatment of this fracture, are fully detailed in the description of the preceding plate. The appearance of the limb differs so far from the foregoing, that the prominence produced by the elevation of the broken surface of the upper portion, is much less distinct than in the fracture higher up. The eversion is likewise more complete ; for in this situation the glutæus maximus has no control over the lower portion ; so that it is not only everted to a greater extent, but the broken surface takes a more oblique direction inward. Fig. 2, of the succeeding plate will likewise show why the broken surface of this portion is also inclined backward, which takes place from the gastrocnemius, popliteus, and plantaris muscles.

FRACTURE OF THE FEMUR IMMEDIATELY ABOVE THE CON-
DYLES. [XXIII. 1.]

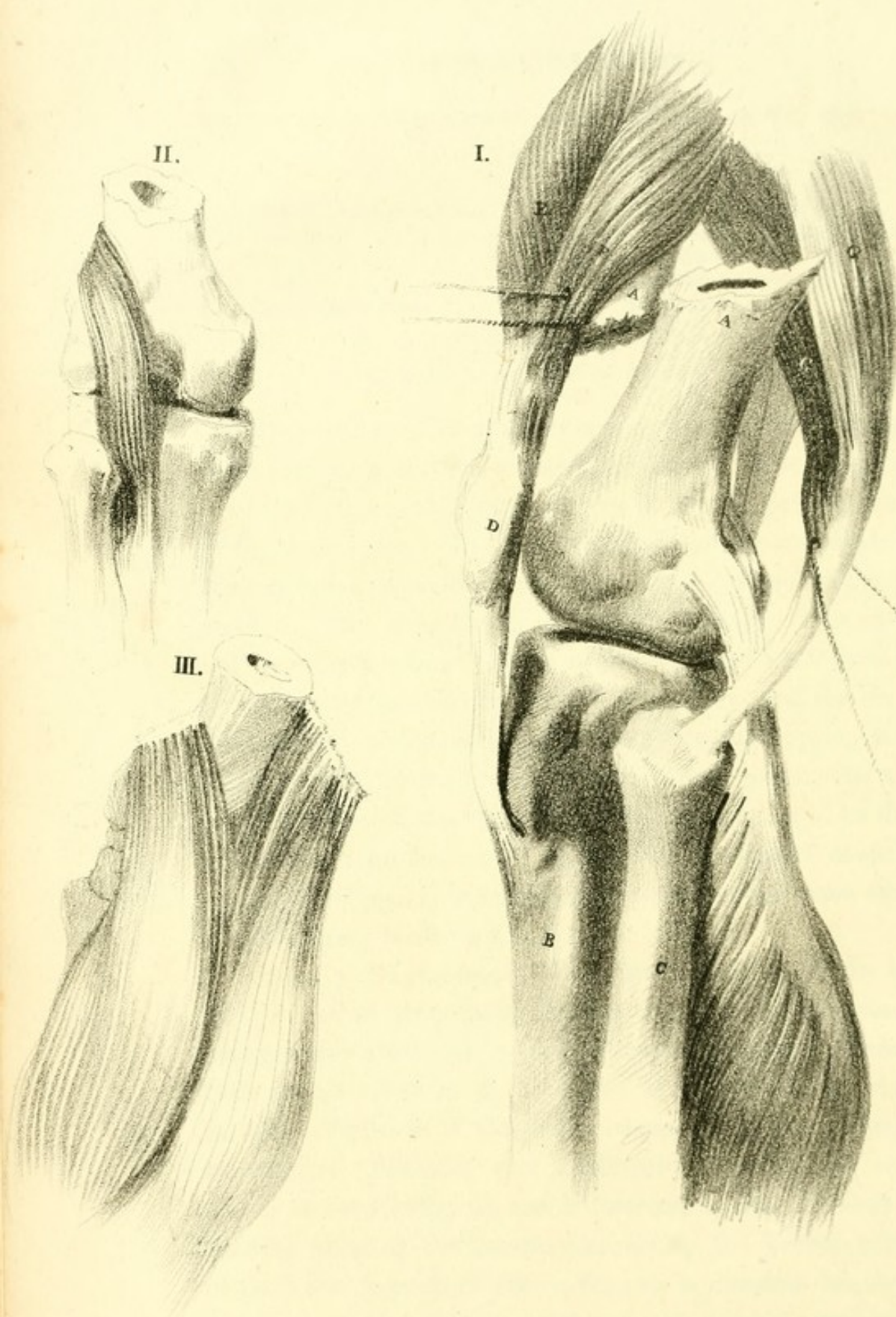
- | | |
|-------------------------------------|---|
| A. A. Broken surfaces of the Femur. | F. Part of the vastus externus. |
| B. The Tibia. | G. G. The two heads of the Biceps muscle. |
| C. Fibula. | H. Semitendinosus muscle. |
| D. Patella. | I. Semimembranosus muscle. |
| E. Rectus femoris muscle. | J. Gastrocnemius muscle. |

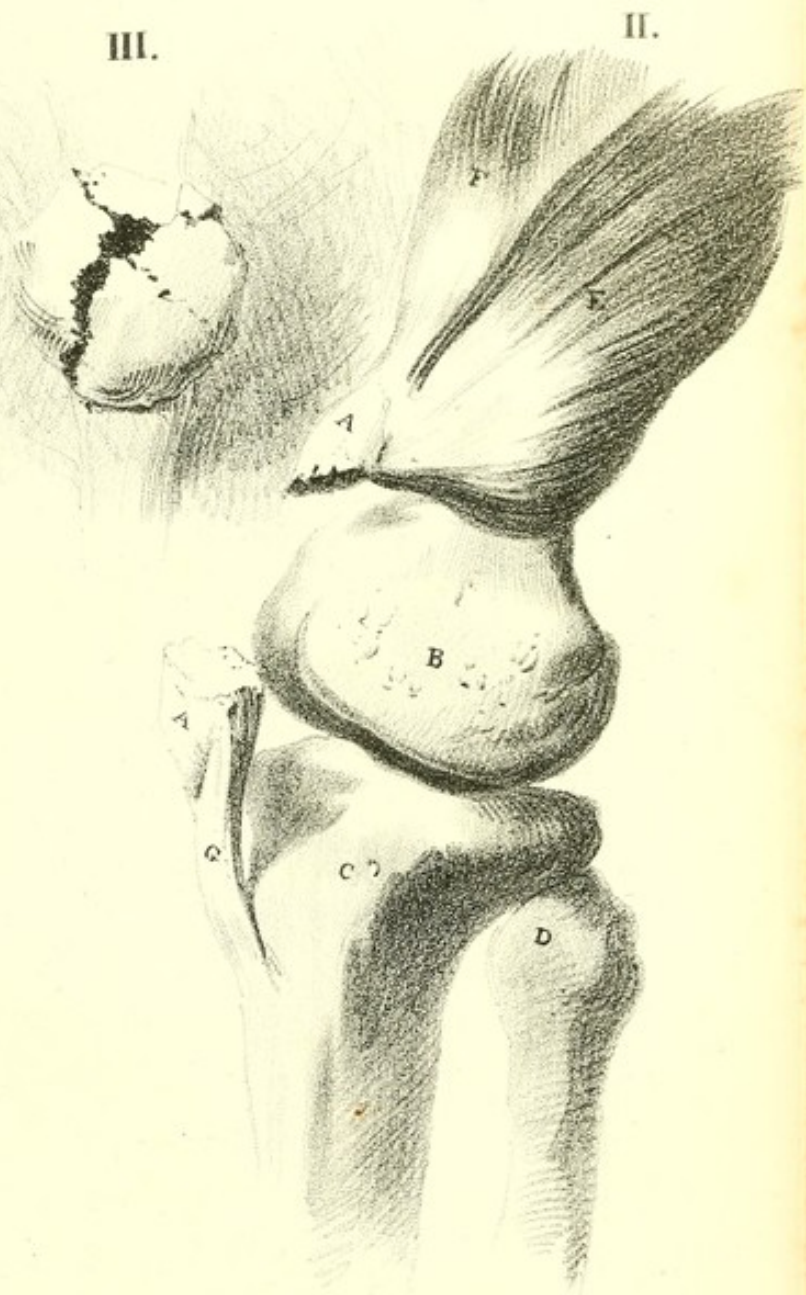
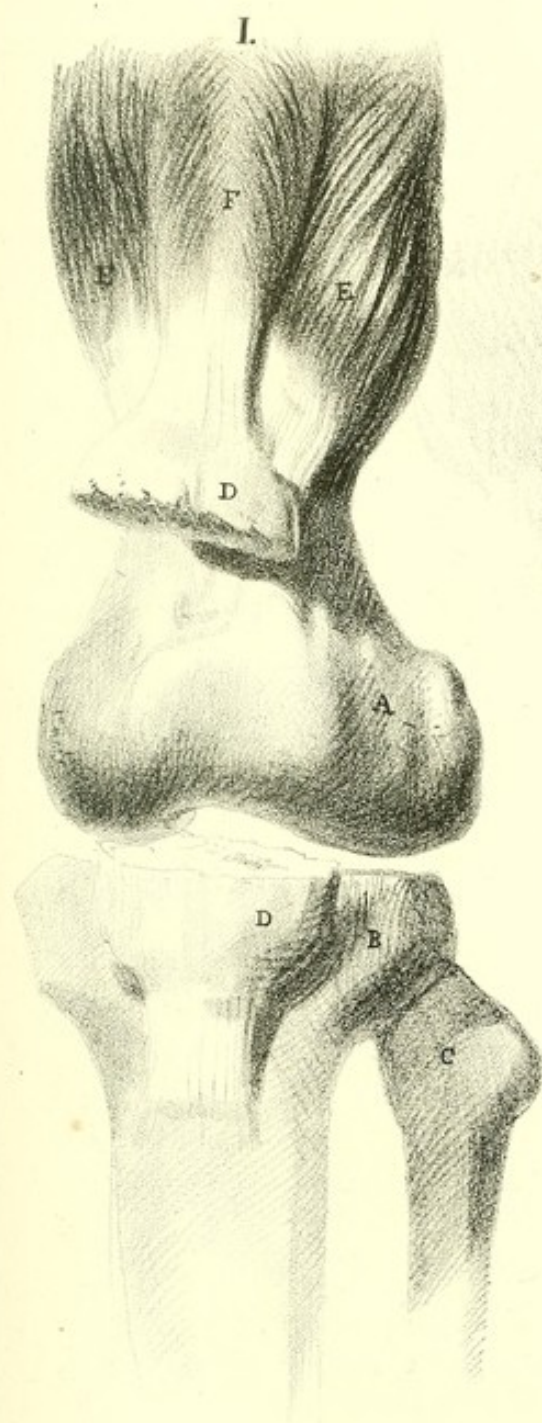
Fig. II. Shows the upper attachment of the Plantaris.

Fig. III. Shows the upper attachments of the Gastrocnemius.

Appearances.—The appearances consequent upon this accident vary to a certain extent from those which have been described as presenting themselves in the foregoing fractures of the same bone. The limb will be found somewhat shorter than natural, dependent upon the same causes as the preceding. The foot, likewise, will be everted. The patient will lose the power of motion in the leg; and great pain will be felt at the immediate seat of the injury, and this is not unfrequently accompanied with numbness and cramp of the under surface of the foot and toes. Upon examination, the circumference of the thigh just above the knee will be found somewhat increased; and by pressing the finger deep into the popliteal space, the displaced portion of the bone can be felt projecting backward.

Causes of Displacement.—The lower portion of the bone will be found principally displaced, and will be observed drawn backward, by a set of muscles which produced little or no effect in the fractures which have been shown in other situations of this bone; these muscles are the gastrocnemius, plantaris, and popliteus: the first of which arises as seen in fig. iii, and is attached to the os calcis: so that the fibres of the muscle contracting, the broken surface of the lower portion of the os femoris is directed backward, the upper heads or origins of this muscle having now become the moveable attachments: the remaining two muscles like-





wise assist in the same action, and with the same effect. The upper portion of the bone will be found little changed in its direction; with this exception, that it inclines to a state of adduction and partial elevation, being raised by the *psoas magnus* and *iliacus internus*, and drawn inward by the *pectinæus*, *adductor brevis*, *longus*, and *magnus*. The remaining circumstances connected with the displacement, viz., the eversion and retraction of the parts inferior to the fracture, are produced by the same muscles that have been already described, in the explanation of plate xxi., as producing the same effect.

Treatment.—The plan for the adjustment of the broken surfaces in this fracture may be conducted upon the same principle as in the two preceding cases, the details of which will be found in the description of plate xxi. Should the double inclined plane be preferred, the flexed position of the leg will at once relax the *gastrocnemius*, *plantaris*, and *popliteus* muscles; for, when flexed, their points of attachment are brought near to each other, and the parts left in repose.

FRACTURE OF THE PATELLA. [XXIV.]

Fig. I.—FRONT VIEW.

- | | | | |
|-------|----------------------------------|-------|--------------------------|
| A. | Femur. | E. E. | Vasti muscles. |
| B. | Tibia. | F. | Rectus femoris. |
| C. | Fibula. | G. | Ligament of the Patella. |
| D. D. | The two portions of the Patella. | | |

Fig. II.—LATERAL VIEW.

- | | | | |
|-------|--------------------------------|----|--------------------------|
| A. A. | Broken Patella. | E. | Vastus externus. |
| B. | External condyle of the Femur. | F. | Rectus femoris. |
| C. | Tibia. | G. | Ligament of the Patella. |
| D. | Fibula. | | |

Fig. III.—The Patella fractured by violence directly applied.

Appearances and Causes of Displacement.—When transverse fracture of the patella has taken place, which is consequent upon the inordinate action of the muscles, the appearance of the knee at once attracts attention from its peculiar flatness,

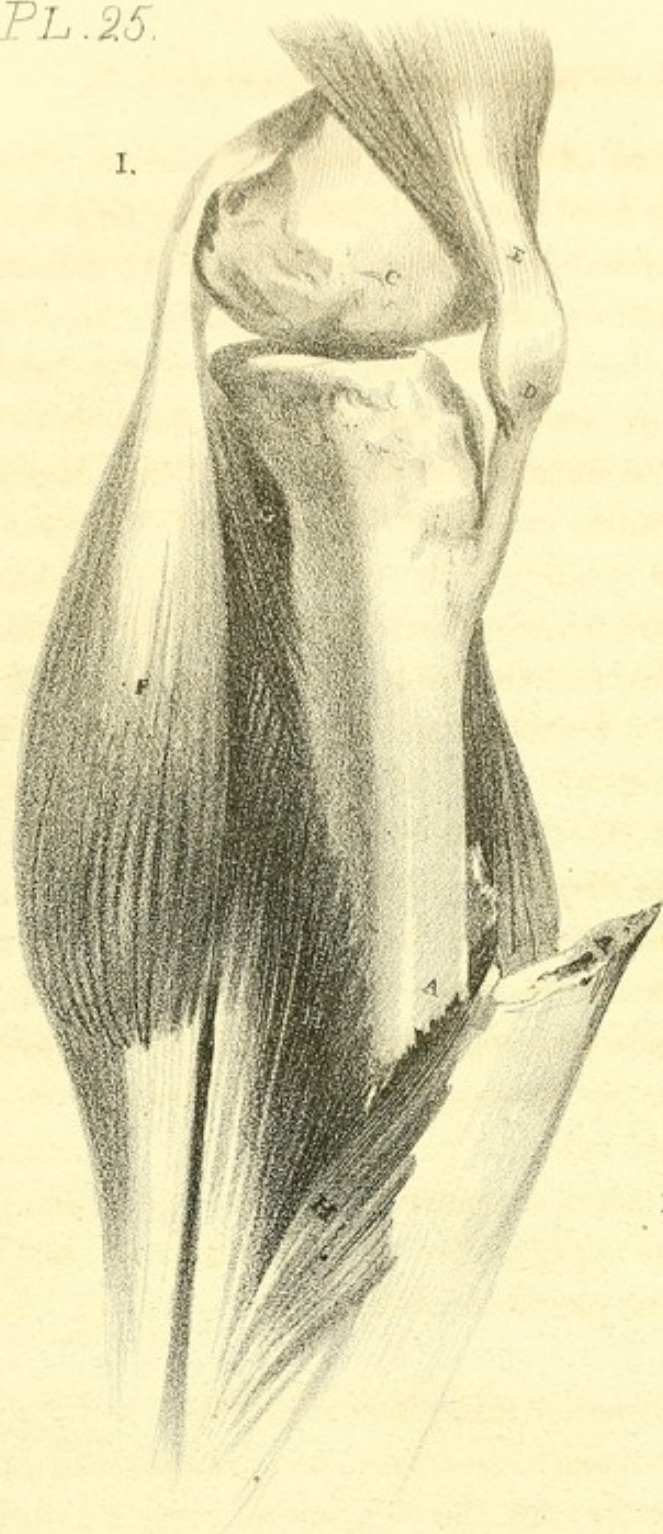
the prominence of the patella being no longer observable; and when the hand is applied to the part, the fingers sink into a hollow bounded by the two portions of the patella above and below, and on either side by the projections of the condyles of the femur: the upper portion of the patella will occasionally be drawn up into the thigh, even to the extent of four or five inches; but the limit of this displacement depends upon the extent of laceration of the fibres of the tendon of the quadriceps extensor or cruris: the lower portion retains nearly its natural situation, being supported by the surrounding fibrous tissue. The patient loses the control over the leg; it is useless, and has only the power of flexion; when he attempts to walk, it bends under him, having, by the separation of the patella, lost the power of the extensor muscles. The displaced portion may be felt above the knee, and, by extending the leg, may now be brought down with the assistance of the hand to its original situation; when lateral motion is produced, the crepitus is at once evident.

The displacing muscles in this fracture are the rectus femoris, vastus externus and internus, with the cruræus, all of which are inserted around the upper edge of the patella; these raise the upper portion by their combined actions. The ligament of the patella holds the lower portion in its natural situation.

Should the fracture take place in a perpendicular direction, (which is comparatively a very rare occurrence,) little displacement occurs; for the two lateral portions, during the actions of the muscles, are by means of the articulating surfaces of the femur, which incline backwards, meeting in the centre, forced against each other, and held in apposition.

Treatment.—The plan of treatment, upon the subsidence of inflammation, should be in the first place to flex the thigh upon the body, and to extend the leg fully, at the same time

I.



II.



III.



that the foot is raised above the level of the patient: the object will be at once evident upon considering the attachments of the displacing muscles. The muscles displacing the upper portion, which have been already enumerated, are the rectus femoris, vastus externus, vastus internus, and cruræus. The attachments of the rectus femoris above to the ilium, and at its inferior part to the patella, would necessarily be relaxed by raising the knee towards the pelvis, but not yet to the full extent: the patient should now be placed in a sitting posture, by which the attachments of the muscle are still more approximated and fully relaxed. In extending the leg, the lower portion of the patella is brought up toward that which is displaced; for should the limb be allowed to hang, the adaptation of the two surfaces would never be accomplished. Having secured the patient in this position, the upper portion of the bone should now be gradually brought down, until the broken surfaces are in immediate contact, and then Amesbury's apparatus for fractures of the patella, [V. 1.] described on page 47, should be applied.

FRACTURES OF THE TIBIA AND FIBULA. [XXV.]

Fig. I.

- | | | | |
|-------|---|-------|--------------------------|
| A. A. | Broken surfaces of the Tibia. | F. | Gastrocnemius muscle. |
| B. | Fibula fractured. | G. | Popliteus muscle. |
| C. | Internal condyle of the Femur. | H. H. | Fibres of the Soleus. |
| D. | Patella. | I | Tendon of the Plantaris. |
| E. | Tendon of the Quadriceps extensor cruris. | | |

Fig. II. Oblique fracture of Tibia and Fibula.

Fig. III. Transverse fracture of the Tibia only.

Appearances and Causes of Displacement.—When both bones are broken, the appearance of the limb depends on the nature of the fracture; for when it takes place simply in a transverse direction, little displacement occurs beyond a

depression of the lower portions, which not only fall by the weight of the foot, but are assisted to that position by the mass of muscle on the posterior part of the leg: the surfaces do not remain wholly in contact, but rest against each other at their posterior edges, so that the broken surfaces project forward, and are evident below the integuments. But should the fracture have taken place obliquely, the displacement, and consequent injury, would be greater, and the case rendered naturally more complex.

The fracture as seen in fig. 1, is of this kind, and has taken a direction obliquely from before; downward and backward the obliquity is considerable, and by the power of the whole of the muscles the two surfaces slide easily the one over the other; but in consequence of the muscles on the posterior part being stronger and more numerous, the heel is drawn backward independently of the shortening, so that the displacing causes in this case are precisely the same as in transverse fracture, but producing a greater displacement, altogether dependent upon the circumstances of the fracture.

Where the fracture is the inverse of that shown in the plate, the upper portion would project, and the lower would be drawn backward and upward.

In either of these cases, the diagnosis is at once formed; for, by tracing with the finger along the anterior spine of the tibia, the irregular edges of the broken surfaces are felt prominent under the skin, or seen even projecting through it, thus rendering it compound. When the obliquity of the fracture is in a lateral direction, (as in fig. 2,) the displacement would differ from either of those already described: the lower portions of the tibia and fibula in that case would be drawn backward and upward, from the causes already described as acting upon those fractures before enumerated, and

would incline outward, not altogether from the obliquity of the surfaces, but likewise from the action of the muscles giving them that direction.

Compound fracture of the tibia is of frequent occurrence, in consequence of this bone being situated so immediately below the integument, and covered solely by it: the lower extremity being drawn backward, the end of the bone is protruded through the integument, the weight still continuing to act; the lower portion is thus driven over the superior, and there held firmly by the whole of the muscles of the leg acting simultaneously; but in consequence of those on the posterior part being more numerous, and possessing superior power, even to the raising the whole weight of the body, the heel is drawn by them backward and slightly upward.

When the tibia is fractured, and the fibula remains uninjured, (as in fig. 3,) the accident is not so easily detected, for then the fibula prevents the displacement of the fractured surfaces: however, by passing the finger along the anterior spine, the irregularity can be at once felt; and by rotating the foot, the knee being at the same time fixed, the crepitus is distinguished.

Should the fibula alone suffer fracture, some difficulty may also be experienced in detecting it; but by pressing the thumb firmly against the bone at any situation in the direction towards the tibia, the crepitus can generally be felt. Much tumefaction accompanies this fracture, as it usually follows immediate injury of the part, and as the patient not unfrequently walks after the accident.

Treatment.—The adaptation of the broken surfaces offers very little difficulty, unless the tibia projects through the integument; in which case, should the bone project to any extent, the reduction is difficult, and cannot be effected unless

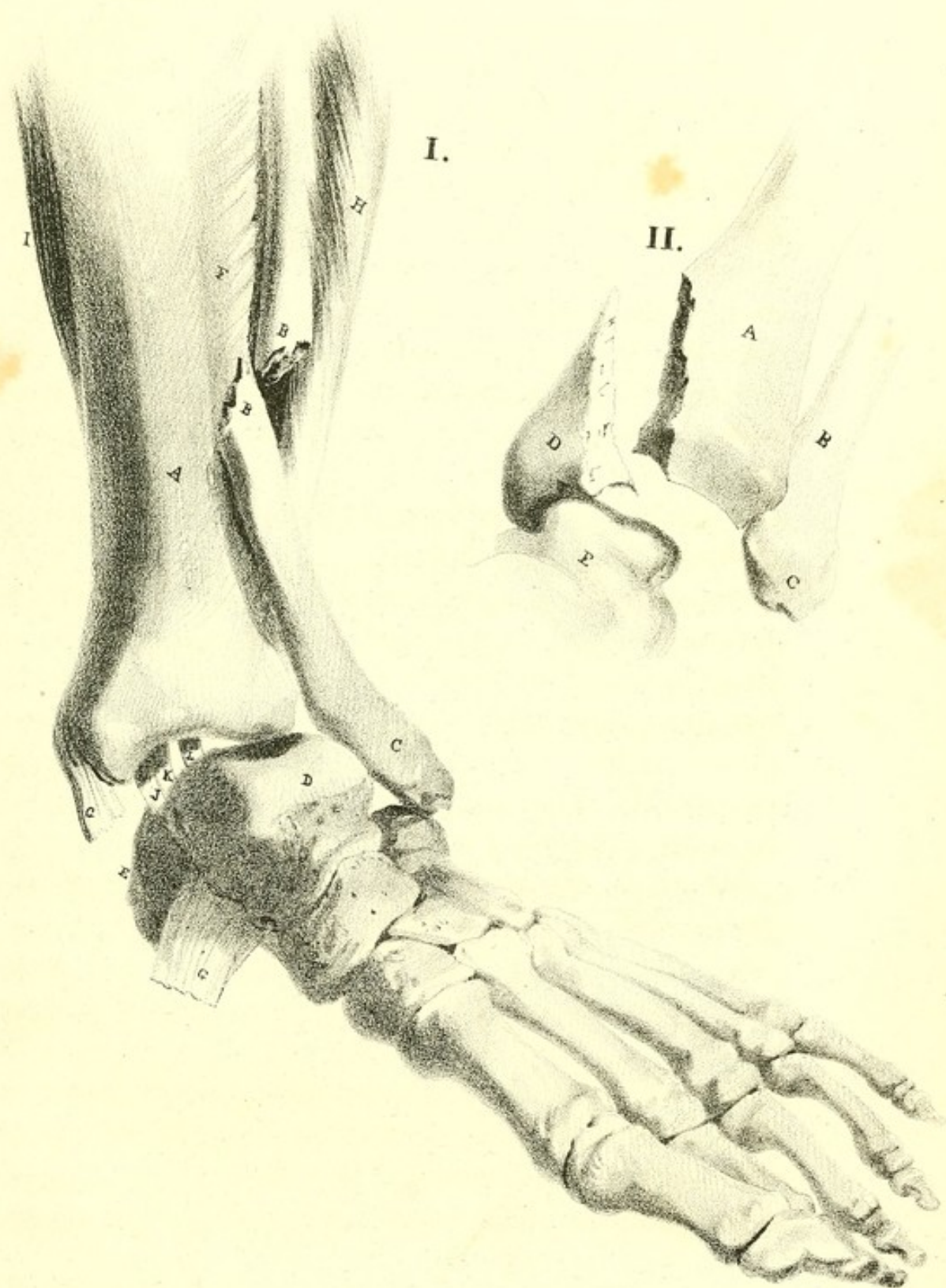
the leg be flexed, and the lower portions of the bones directed backward; and this attempt proving unsuccessful, it may be necessary to remove a portion of the projecting bone with the saw.

The difficulty which exists in this case, (see fig. 1,) depends not only on the strong muscles already described as drawing the lower portions of the tibia and fibula upward, and directing the heel backward, but also upon the muscles situated between these bones on the anterior part of the leg (which are, the tibialis anticus, extensor digitorum communis, and extensor longus pollicis): these, in consequence of the thrusting forward of the lower portion, are put upon the stretch, and are the means of holding the two portions more closely and firmly together; those fibres also of the solæus muscle which are situated below the point of fracture, have likewise the effect of holding the lower portion of the tibia in firm relation with the upper portion.

The principle upon which fracture of both bones of the leg should be treated, is to place the limb in that position in which the whole of the muscles would become at once relaxed; for this purpose the double inclined plane is occasionally adopted, particularly in cases of compound fracture, for by its use the parts are more readily examined and dressed, without the necessity of disturbing the limb.

But where the fracture has not become compound, the usual mode of dressing is to apply Amesbury's apparatus for fractured leg, [V. 2.] described on page 47. Maunoir's apparatus, [V. 6.] has also been found extremely useful.

In fractures of the fibula, the splint which is applied to the outer part of the leg should project beyond the foot, in order to prevent it from turning outward.



FRACTURE OF THE FIBULA, WITH PARTIAL DISLOCATION OF THE
TIBIA FROM THE ASTRAGALUS. [XXVI. 1.]

- | | | | |
|-------|--------------------------------|-------|--|
| A. | Lower end of the Tibia. | G. G. | Ruptured Deltoid ligament. |
| B. B. | Broken surfaces of the Fibula. | H. | Part of the Peroneus longus muscle. |
| C. | Malleolus externus. | I. | Part of the Soleus muscle. |
| D. | Astragalus. | J. | Tendon of the Tibialis posticus. |
| E. | Os calcis. | K. | Tendon of the Flexor longus digitorum. |
| F. | Interosseous ligament. | L. | Tendon of the Flexor longus pollicis. |

Causes of Fracture.—This accident takes place when a person is in the act of jumping, and when the foot alights upon an uneven part of the ground, so as to be twisted outwardly ; or it takes place when a heavy man stepping from the carriageway to the footpath, places the outside of the foot only on the kerbstone, and it slips into the gutter everted. In either of these cases, the tibia does not rest perpendicularly upon the astragalus ; for in consequence of the turning outward of the foot, the weight of the body forces the tibia from off the astragalus, separating its attachments to this bone, and also the ligamentous connexions with the fibula, so that it glides easily over the inclined surface of the astragalus ; the malleolus internus protrudes inward, and, in consequence of the eversion of the foot, the attachments of the triangular or deltoid ligament are drawn apart, and rupture of the ligament necessarily follows. The weight of the body is no longer supported by the tibia, for it is already partly dislocated from off the astragalus, so that the weight is now transferred to the fibula, and, by means of the eversion of the foot, the lower end of the fibula rests upon the os calcis ; but being unable to sustain the weight, it gives way about a hand's breath above the malleolus externus, (the two broken surfaces resting against the tibia,) which will be found the weakest point in the bone, for here the spines which strengthen its whole extent become nearly deficient, and the bone is consequently thin and weak. Sometimes the tibia is com-

pletely driven from off the astragalus; in which case the integument would suffer laceration, and the accident become compound.

Appearances.—When this fracture has taken place, the foot will be found twisted outward, the inner edge directed downward, while the outer side will be turned upward; so that instead of the sole of the foot resting on the ground, the inner part of the ball of the great toe and heel will occupy its situation: the motions of the foot will be altogether lost, and any attempt to bear upon or move it produces excruciating pain: a prominence will be seen at the inner side of the ankle, from the projecting end of the tibia; while on the outer side, just above the external malleolus, a depression exists, in consequence of the lower portion of the fibula being driven and held against the tibia, and the integument necessarily following it. The toes will be directed downward (pointing), and the heel will be at the same time elevated.

Causes of Displacement.—The force having been applied, and the fracture produced, as already explained, the whole of the muscles on the posterior part of the leg are at once brought into action, and in consequence of their displacement, the direction of their natural action is altered; so that, instead of controlling the motions of the foot and direction of the toes, they now, from their combined effort and altered situation, hold the foot in the position shown in the last paragraph, viz., turned outward. The muscles producing this deformity on the outside, are the peroneus longus and brevis; while those passing behind the malleolus internus are, the tibialis posticus, flexor digitorum communis, and flexor longus pollicis. The heel is drawn up, and the toe pointed, by the action of the gastrocnemius, soleus, and plantaris muscles.

Treatment.—The nature of the fracture will be at once evident upon examination; the end of the tibia will be readily

felt, over which the integument is stretched; the accident is accompanied by considerable tumefaction and ecchymosis; and upon moving the lower end of the fibula with the fingers, the crepitus is generally distinguished. In order to reduce the parts to their natural situation, it will be necessary in the first place, to relax those muscles retaining the bones in their displaced positions; for, should the attempt be made without attention to this circumstance, much pain will be the consequence, and in all probability the attempt will prove unsuccessful. For this purpose the leg should be flexed upon the thigh, by which means the muscles situated on the posterior part (which have already been enumerated) would be relaxed and the parts set at liberty: by now producing extension, at the same time giving the foot the natural direction, the bones are reduced and the deformity disappears.

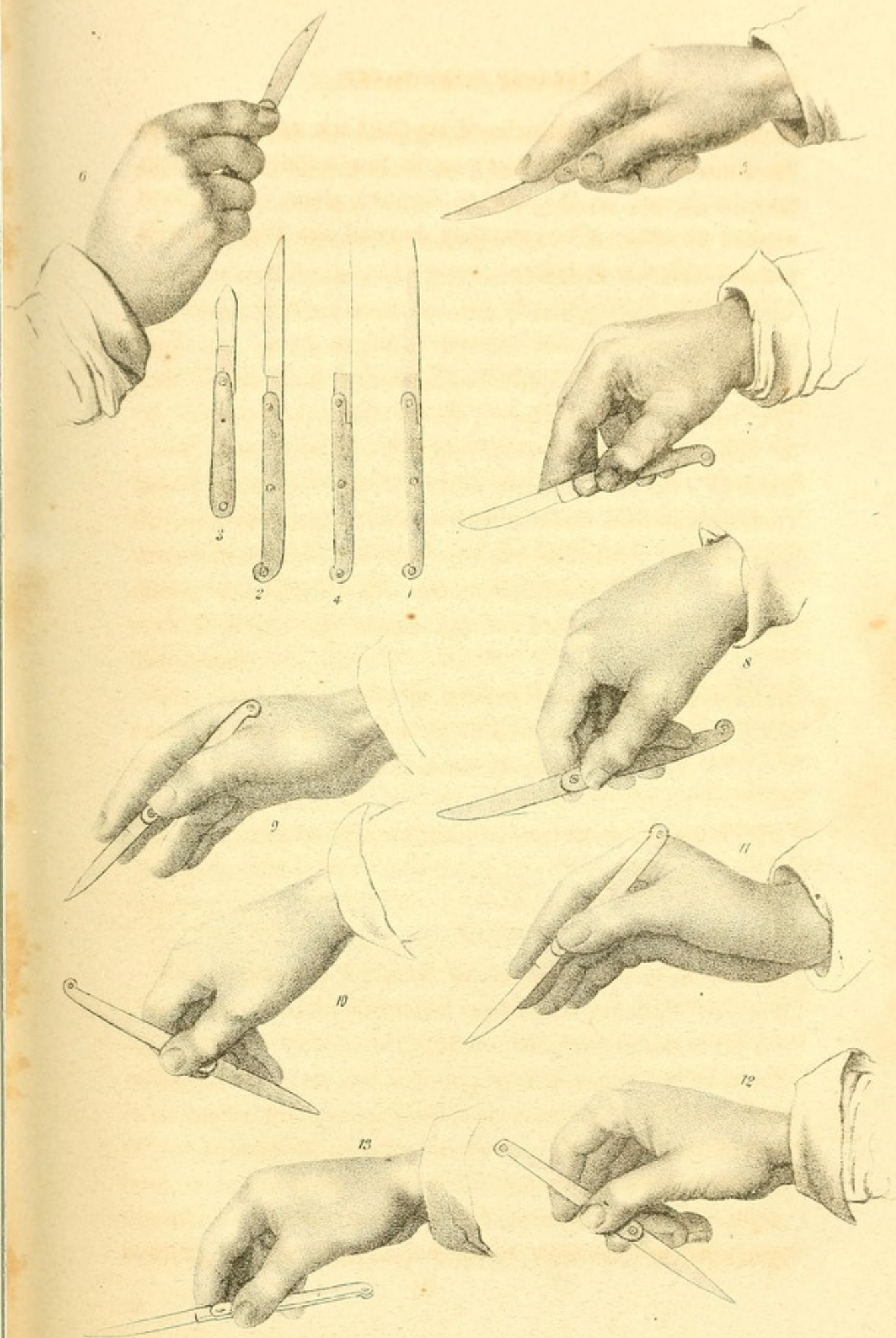
The fracture may now be treated by applying Dupuytren's bandage, (seen in plate v. fig. 3,) which has been used by that eminent surgeon with great success.

FRACTURE OF THE MALLEOLUS INTERNUS. [XXVI. 2.]

- | | |
|------------------------|---|
| A. Tibia. | D. Malleolus internus separated from the shaft of the bone. |
| B. Fibula. | |
| C. Malleolus externus. | E. Astragalus. |

This accident is produced by the same means as the last, (fig. 1,) only that the foot when meeting the ground is inverted, by which the whole weight of the body is sustained by the malleolus internus, and it gives way at the moment the shock is received: the tibia and fibula are then driven forcibly from off the astragalus, passing outward. The deformity in this case is precisely the reverse of that which takes place as described in the last accident, and consequent upon the same causes; the treatment may therefore be conducted by laying

the limb on a splint extending from the knee, and adapted to the form of the leg and foot; or, in this accident, the limb may be placed on the double inclined plane, with splints applied on either side, extending beyond the foot, and well padded with tow or cotton.



the first of these is the fact that the
the second is the fact that the
the third is the fact that the
the fourth is the fact that the
the fifth is the fact that the
the sixth is the fact that the
the seventh is the fact that the
the eighth is the fact that the
the ninth is the fact that the
the tenth is the fact that the
the eleventh is the fact that the
the twelfth is the fact that the
the thirteenth is the fact that the
the fourteenth is the fact that the
the fifteenth is the fact that the
the sixteenth is the fact that the
the seventeenth is the fact that the
the eighteenth is the fact that the
the nineteenth is the fact that the
the twentieth is the fact that the
the twenty-first is the fact that the
the twenty-second is the fact that the
the twenty-third is the fact that the
the twenty-fourth is the fact that the
the twenty-fifth is the fact that the
the twenty-sixth is the fact that the
the twenty-seventh is the fact that the
the twenty-eighth is the fact that the
the twenty-ninth is the fact that the
the thirtieth is the fact that the
the thirty-first is the fact that the
the thirty-second is the fact that the
the thirty-third is the fact that the
the thirty-fourth is the fact that the
the thirty-fifth is the fact that the
the thirty-sixth is the fact that the
the thirty-seventh is the fact that the
the thirty-eighth is the fact that the
the thirty-ninth is the fact that the
the fortieth is the fact that the
the forty-first is the fact that the
the forty-second is the fact that the
the forty-third is the fact that the
the forty-fourth is the fact that the
the forty-fifth is the fact that the
the forty-sixth is the fact that the
the forty-seventh is the fact that the
the forty-eighth is the fact that the
the forty-ninth is the fact that the
the fiftieth is the fact that the
the fifty-first is the fact that the
the fifty-second is the fact that the
the fifty-third is the fact that the
the fifty-fourth is the fact that the
the fifty-fifth is the fact that the
the fifty-sixth is the fact that the
the fifty-seventh is the fact that the
the fifty-eighth is the fact that the
the fifty-ninth is the fact that the
the sixtieth is the fact that the
the sixty-first is the fact that the
the sixty-second is the fact that the
the sixty-third is the fact that the
the sixty-fourth is the fact that the
the sixty-fifth is the fact that the
the sixty-sixth is the fact that the
the sixty-seventh is the fact that the
the sixty-eighth is the fact that the
the sixty-ninth is the fact that the
the seventieth is the fact that the
the seventy-first is the fact that the
the seventy-second is the fact that the
the seventy-third is the fact that the
the seventy-fourth is the fact that the
the seventy-fifth is the fact that the
the seventy-sixth is the fact that the
the seventy-seventh is the fact that the
the seventy-eighth is the fact that the
the seventy-ninth is the fact that the
the eightieth is the fact that the
the eighty-first is the fact that the
the eighty-second is the fact that the
the eighty-third is the fact that the
the eighty-fourth is the fact that the
the eighty-fifth is the fact that the
the eighty-sixth is the fact that the
the eighty-seventh is the fact that the
the eighty-eighth is the fact that the
the eighty-ninth is the fact that the
the ninetieth is the fact that the
the ninety-first is the fact that the
the ninety-second is the fact that the
the ninety-third is the fact that the
the ninety-fourth is the fact that the
the ninety-fifth is the fact that the
the ninety-sixth is the fact that the
the ninety-seventh is the fact that the
the ninety-eighth is the fact that the
the ninety-ninth is the fact that the
the hundredth is the fact that the

SECTION FOURTH.

SURGICAL OPERATIONS.

THE different varieties of the bistoury, the *straight*, the *probe-pointed*, the *convex*, and the *English*, are seen in plate xxvii. figs. 1, 2, 3, and 4 ; the different modes of holding the bistoury or scalpel, as recommended by the best French writers, are shown in the same plate.

In the *first* position, [XXVII. 5.] the bistoury is held like a table-knife, and the edge of the blade looks downward. The handle of the instrument is grasped firmly in the palm of the hand, by the ring and little finger ; the thumb and middle finger seize the instrument at the union of the blade and handle, and the index finger is placed on the back of the blade. This is the most common way of holding the knife, which is kept in place very firmly, and may be guided in any direction.

In the *second* position, [XXVII. 6.] the bistoury is held like a table-knife, but the edge of the blade is turned upward. Here the front of the handle rests against the palm of the hand, and the thumb and index finger grasp its sides, while the other three fingers are under it. This position of the knife is preferred for making incisions from within outward.

In the *third* position, [XXVII. 9.] the bistoury is held like a writing-pen, the edge of the blade looks downward, and the point forward. The bistoury is grasped as in the first position, with the thumb and first two fingers ; the ring and the little

finger are at liberty, and find a point of support near the parts operated on. This position is used in delicate incisions and dissections.

In the *fourth* position, [XXVII. 10.] the bistoury is held like a writing-pen, but the point looks backward; the middle finger projects more or less on one side of the blade, and then being flexed, turns the point of it towards the wrist of the operator, so that the edge of the bistoury looks towards the palmar face of his hand.

In the *fifth* position, [XXVII. 11.] the bistoury is held like a writing pen, the edge of the blade looking upward. In dissecting or making an incision in front of the operator, or in enlarging certain deep-seated openings, the relations of the edge of the bistoury are often changed, and its point is turned to the wrist of the surgeon, [XXVII. 12.]

The *sixth* position, in which the bistoury is held like the bow of a violin, occupies, as it were, the place between the first and second positions; the handle of the instrument rests within the hand, as in the former; while it is kept in place by the ends of the fingers, as in the second. It differs from both, however, as the bistoury is horizontal to the axis of the limb, and supported on one side by the pulp of the extended fingers, while the thumb is applied to the other. The three varieties of this position are easily characterized: in the first, the edge of the bistoury looks downward, [XXVII. 7.] in the second, it is turned upward, [XXVII. 8.] and in the third, [XXVII. 13.] it is directed to the right or left. The first variety is particularly indicated in cases of scarifications, for making incisions in phlegmonous erysipelas, and also for opening large subcutaneous abscesses. The second variety is rarely used, except in cutting on a grooved director; the third is adopted in but a few cases, where there is danger of wounding a subjacent organ, and we are obliged to cut hori-

zontally and gradually, the layers which present themselves, as is the case in tying certain arteries, and in operating for strangulated hernia.

Sutures.—The principal sutures used in surgery, are represented on plate XXVIII. They are the following:—

The *interrupted* suture: [XXVIII. 1.] *a, a, a*, represent the points of the suture, and *b, b, b*, the knots. The best needles for making this suture, are those which correspond in shape to the segment of a circle, and which have the same breadth and thickness in every part except near the point; the ligatures used should be flat, and formed of waxed silk or thread. In common cases, it is better to commence the suture at the upper or right lip of the wound, to pass through one edge of it from without inward, and the opposite edge from within outward. The operation is thus performed more promptly and with less pain. The number of stitches in the suture, will depend in a great measure on the size of the wound; the common rule, however, is one stitch to every inch of wound. In ordinary cases, the ligatures may be withdrawn in from three to five days after they are introduced. The interrupted suture is that which is generally employed when a suture is required.

The *looped* suture: [XXVIII. 2.] *a, a*, represent the extremities of the ligature, and *b, b, b*, the stitches. In this suture, the needle passes first through the tissues on the right side, and is then carried through those on the left side: it is now passed again through those on the left side, but a little higher up than before, and is carried to the right side, and so on. The advantages claimed for this suture are, that the tissues are not easily cut or torn out, on account of the loops on each side: but although it was improved by Beclard, it is now little used.

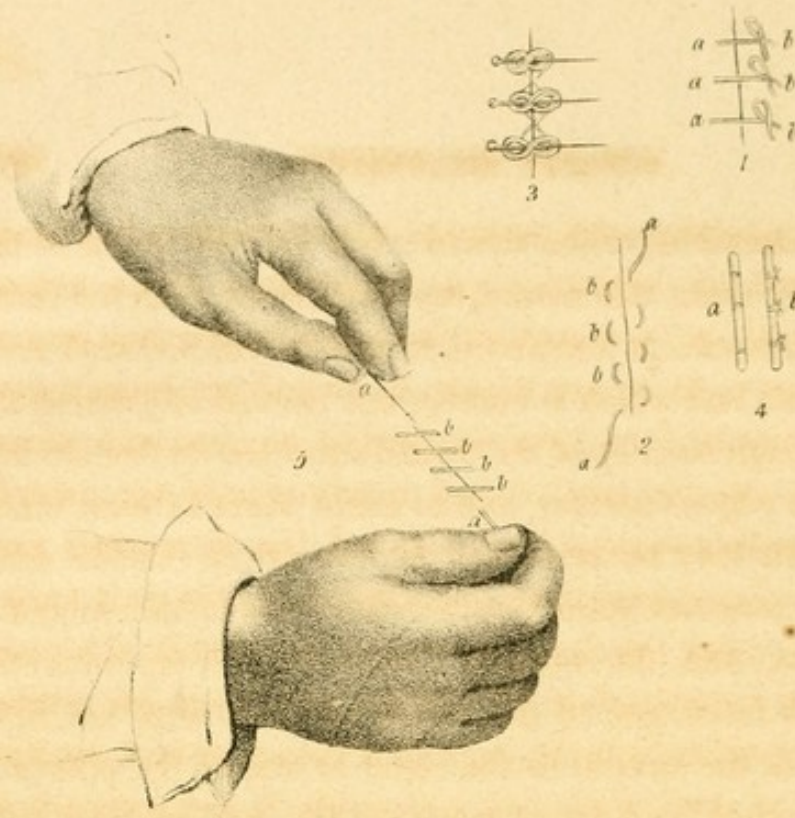

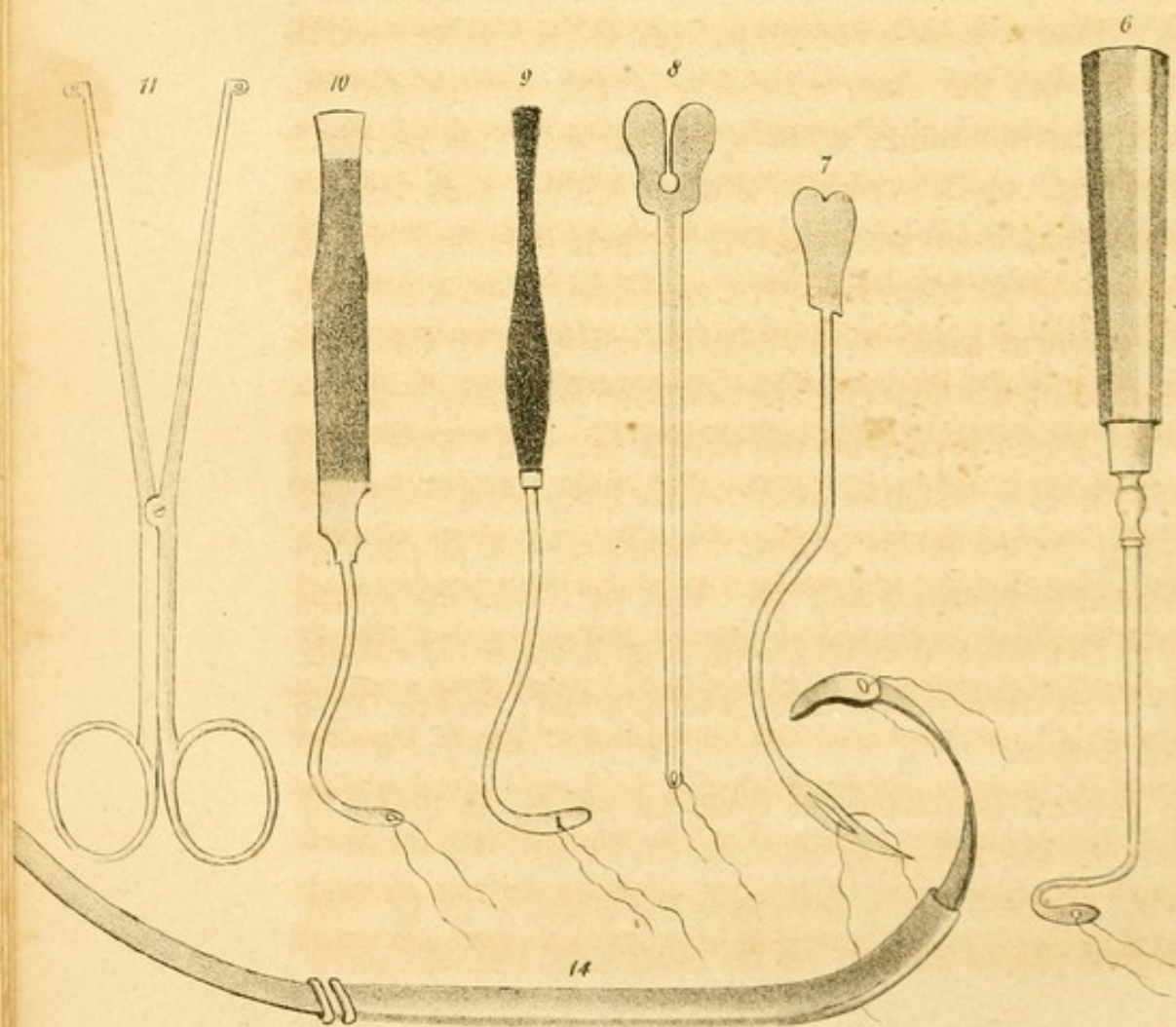
The *twisted* suture. [XXVIII. 3.] This is formed by

introducing metallic pins through the sides of the wound, over which the thread is passed in the following manner: on the upper pin is placed the centre of a long ligature; it is then passed crossed several times around the extremities of the pin, in the form of a figure of ∞ and is carried in the form of an X to the next pin, and is crossed over its head and point, as over those of the first; it is now passed to the third pin, from whence it is returned in X form to the second pin, and thence to the first. The ends of the ligature are now either knotted, or they are twisted and placed under the metallic pins. This suture is much used in operations for harelip, and sometimes in wounds of the eyelids and other moveable parts.

The *quilled* suture, [XXVIII. 4.] which Velpeau considers too much neglected: *a* and *b*, represent cylinders of bougie, wood, whalebone, or metal, in which the loose extremities of each thread are knotted. Cooper has given the following brief directions for making this suture: He says, "Take as many needles as stitches intended to be made, arm them with a double ligature, or one capable of being readily split into two; introduce the ligatures through the wound, cut off the needles, lay a piece of bougie along one side of the wound, and tie the ends of the ligatures over it; next draw the other extremities of the ligatures so as to bring the first piece of bougie into close contact with the flesh; lay the second piece of bougie along the opposite side of the wound, and tie the other end of the ligatures over it with sufficient tightness. The advantages of this suture are, that it exercises a perfectly equal pressure on all the parts brought together by the ligature, it is firmer than any other, and it is less liable to tear the soft parts; it is particularly suited for straight, long, and deep wounds of the abdomen and limbs. It however requires more time and care than the continued suture.

The *continued* or *glover's* suture: [XXVIII. 5.] *a, a*, repre-

the first of these is the fact that the
 the second is the fact that the
 the third is the fact that the
 the fourth is the fact that the
 the fifth is the fact that the
 the sixth is the fact that the
 the seventh is the fact that the
 the eighth is the fact that the
 the ninth is the fact that the
 the tenth is the fact that the
 the eleventh is the fact that the
 the twelfth is the fact that the
 the thirteenth is the fact that the
 the fourteenth is the fact that the
 the fifteenth is the fact that the
 the sixteenth is the fact that the
 the seventeenth is the fact that the
 the eighteenth is the fact that the
 the nineteenth is the fact that the
 the twentieth is the fact that the
 the twenty-first is the fact that the
 the twenty-second is the fact that the
 the twenty-third is the fact that the
 the twenty-fourth is the fact that the
 the twenty-fifth is the fact that the
 the twenty-sixth is the fact that the
 the twenty-seventh is the fact that the
 the twenty-eighth is the fact that the
 the twenty-ninth is the fact that the
 the thirtieth is the fact that the
 the thirty-first is the fact that the
 the thirty-second is the fact that the
 the thirty-third is the fact that the
 the thirty-fourth is the fact that the
 the thirty-fifth is the fact that the
 the thirty-sixth is the fact that the
 the thirty-seventh is the fact that the
 the thirty-eighth is the fact that the
 the thirty-ninth is the fact that the
 the fortieth is the fact that the
 the forty-first is the fact that the
 the forty-second is the fact that the
 the forty-third is the fact that the
 the forty-fourth is the fact that the
 the forty-fifth is the fact that the
 the forty-sixth is the fact that the
 the forty-seventh is the fact that the
 the forty-eighth is the fact that the
 the forty-ninth is the fact that the
 the fiftieth is the fact that the
 the fifty-first is the fact that the
 the fifty-second is the fact that the
 the fifty-third is the fact that the
 the fifty-fourth is the fact that the
 the fifty-fifth is the fact that the
 the fifty-sixth is the fact that the
 the fifty-seventh is the fact that the
 the fifty-eighth is the fact that the
 the fifty-ninth is the fact that the
 the sixtieth is the fact that the
 the sixty-first is the fact that the
 the sixty-second is the fact that the
 the sixty-third is the fact that the
 the sixty-fourth is the fact that the
 the sixty-fifth is the fact that the
 the sixty-sixth is the fact that the
 the sixty-seventh is the fact that the
 the sixty-eighth is the fact that the
 the sixty-ninth is the fact that the
 the seventieth is the fact that the
 the seventy-first is the fact that the
 the seventy-second is the fact that the
 the seventy-third is the fact that the
 the seventy-fourth is the fact that the
 the seventy-fifth is the fact that the
 the seventy-sixth is the fact that the
 the seventy-seventh is the fact that the
 the seventy-eighth is the fact that the
 the seventy-ninth is the fact that the
 the eightieth is the fact that the
 the eighty-first is the fact that the
 the eighty-second is the fact that the
 the eighty-third is the fact that the
 the eighty-fourth is the fact that the
 the eighty-fifth is the fact that the
 the eighty-sixth is the fact that the
 the eighty-seventh is the fact that the
 the eighty-eighth is the fact that the
 the eighty-ninth is the fact that the
 the ninetieth is the fact that the
 the ninety-first is the fact that the
 the ninety-second is the fact that the
 the ninety-third is the fact that the
 the ninety-fourth is the fact that the
 the ninety-fifth is the fact that the
 the ninety-sixth is the fact that the
 the ninety-seventh is the fact that the
 the ninety-eighth is the fact that the
 the ninety-ninth is the fact that the
 the hundredth is the fact that the



sent the extremities of the thread ; *b, b, b, b*, the points of the suture. To make this suture, we commence as in the interrupted suture, except that a straight needle will be found more suitable than one which is curved, and instead of passing the needle through each lip of the wound successively, we attempt to bring its edges together, and to adapt them to each other, so that both may be transfixed by the needle at the same time. An assistant holds together the sides of the wounded integuments, and the surgeon pinches them up with the thumb and forefinger of the left hand, and with his right hand carries the needle to the right or upper lip, passes it through the fold, and draws it out on the left side : he then carries it obliquely over the wound to the right side, three or four lines from the first puncture, where it is again introduced. This process is continued until the last point extends a little beyond the other extremity of the wound, and the whole suture resembles a few spiral turns. This suture is now but little used, except in sewing up the cadaver ; but Velpeau thinks it advantageous for wounds of hollow organs.

Ligatures of the Arteries.—The remaining figures on plate xxviii. represent some of the instruments used in tying the different arteries. The crooked needle of Deschamps is seen in fig. 6. Fig. 7 represents the needle of Petit. Fig. 8, the grooved director, which is used to pass ligatures around vessels. Fig. 12, the stylet needle. Other curved needles are represented in figures 9 and 10. Fig. 14 shows the curved needle of Desault, employed for securing deep-seated vessels. Fig. 11 is an instrument termed a *serre nœud* ; and fig. 13, a grooved forceps.

The general directions for tying an artery, as given by Velpeau, are the following :—

Having selected the point where the artery is to be tied, the surgeon places himself on the same side with the aneu-

rism, and commences the operation, by stretching the integuments, either transversely, by means of the thumb, index finger, and cubital edge of the hand, or by placing the extremities of the fingers on the course of the vessel, parallel to its direction, as is recommended by Lisfranc. He then divides the skin to the extent of from two to four inches: this incision should be made with a convex-edged bistoury, rather than with a straight bistoury; and it is better that it should be a little too long than too short; but in most cases, where the vessel does not lie very deeply, an incision two or three inches long is sufficient. It is most frequently made in the direction of the artery, but sometimes in that of the fleshy fibres, in which case it crosses the vessels more or less obliquely. We should be careful not to make the first incision too deep, as it is better to repeat the first incision, than to come directly on the artery. The integuments being incised, we see the aponeurosis, which is divided in the same manner, if the artery is still at some depth. If this be not the case, or if the operator is not very sure of his hand, he passes a grooved director under the vessel, and this serves as a conductor and a guide to the bistoury. The other layers should be cut successively with the same precautions, and to the same extent. Having arrived at the fasciculus of vessels and nerves, we must first open the common sheath. The director is here highly important. It should be introduced from below, upward, or in the contrary direction, within this sheath, being careful to raise it alone, and not to permit any of those parts which it might be dangerous to wound, to slip between it and the instrument. To separate the artery, we still use the grooved director, which should be made of steel, (rather than of silver or gold,) and should be slightly flexible, a little conical, without a cul-de-sac, and less blunt than the common grooved director. It is held in the man-

ner of a pen, and the end of it is introduced between the vein and the artery; then, by gentle motions to and fro, sustained by a moderate though permanent pressure, the two vessels are separated for the extent of several lines. In proportion as the separation takes place, we reverse the position of the director, in order that its beak may incline by degrees, under the posterior face of the vessel, and may be seen on the opposite side; there, the index and middle finger of the other hand, separate the nervous trunks, or push backward and outward all the parts which are to be divided. The same director, before being withdrawn, must still perform another duty; that of serving as a guide to the passage of the ligature: whether we employ for this purpose a simple probe, with an eye in one extremity, as is recommended by Dupuytren, Richerand, and most French surgeons, or if we prefer for deep ligatures the curved needle, held with forceps, (as is figured in Dorsey's work,) the needle of Petit, Deschamps, &c. Desault proposed, in cases where we were obliged to operate at the bottom of a deep narrow cavity, to use a spring needle, very similar to the sound of Bellocque, which needle has been modified in England by Ramsden, Earle, and Brenner. In these difficult cases, Sir Astley Cooper uses a steel wire, supported by a handle, strongly curved at its free extremity, and terminated by a knob, in which is an opening for the thread. Scarpa speaks highly of a small thin spatula of pure silver, which is flexible enough to adapt itself to the form of all the parts to be embraced. But the grooved director, as we have already mentioned, ought rarely to be found insufficient in the hands of a skilful surgeon: it separates the artery very neatly, and almost without rupture of the surrounding tissues. When it is once on the other side of the vessel, we do not see why it would not be possible to glide the head of a flexible probe along its

groove, and thus pass the ligature, and more particularly as an eye may be made near the point of the probe, to pass the thread at the same time that it separates the circumference of the artery. Every practitioner, however, understands the mechanism of these different instruments, and can easily see if one be preferable to the others. It is not only useless, but even dangerous, to raise the vessel and separate it from the adjacent parts with the fingers, as Scarpa advises. If this be done, the tissues are lacerated, and we have a contused wound, which must necessarily suppurate, while it is important for it to be as clean and regular as possible. This is best accomplished by the director, which allows the operator to act more safely and promptly, and to pass the thread around the vessel, without displacing or deranging its natural relations, at the same time exposing it as little as possible.

The ligature should be tight enough to close the vessel hermetically, not only at the time of the operation, but afterwards. This cannot be accomplished when any muscular tendinous, or aponeurotic fibres, or even any cellular tissue is included with the artery, because these parts shrink and thus the ligature is loosened, and rendered almost useless; and we must also avoid passing the extremities of the thread, twice, one within the other, to form what is called the *surgeon's knot*; for let this knot be drawn as tightly as possible, the vessel often remains open. We should then use two simple knots. If the ligature is of an animal material, the two ends are cut off, and the rest is left in the wound; if otherwise, one extremity of the ligature hangs out of the wound. If in laying the artery bare, the surgeon perceives that it is diseased, that its parietes are yellow, fragile, or encircled with calcareous plates, it might, perhaps, be prudent to flatten it as Scarpa advises, instead of tying it. Nevertheless, Lawrence, Sir Astley Cooper, and Briot, have placed a simple ligature about

arteries obliterated, fragile, and entirely changed, and have had no cause to repent of it. In such cases, the strips of skin used by Dr. Jamieson may be very useful, when we cannot do better by making a new incision, and performing the operation higher up.

Dressing.—The wound, after being cleansed and freed from all foreign bodies, should be immediately closed. The worst thing which can happen is suppuration from the arteries. Immediate reunion, on the contrary, most generally ensures success; but it should be promoted from the bottom of the wound towards its edges, and not from the skin towards the deep parts, which is liable to be produced by the points of suture used by some surgeons; hence we must endeavour to keep the edges of the wound in exact contact, by means of graduated compresses, strips of adhesive plaster, and by position. Then, after wrapping a small piece of fine linen round the exterior portion of ligature, it is turned towards the lowest angle of the incision. A perforated compress, [I. 5.] spread with cerate, is then applied; and this being covered by a pledget of lint, or one or two oblong or square compresses, a few turns of the bandage secures the whole.

The different incisions required for securing the different arteries, are seen very clearly in the frontispiece [VI.] :—

The line A B shows the incision for the superior thyroid artery, as recommended by Bujalsky. C D, that for the carotid artery. E F, Zang's incision for tying the carotid artery. G H, Zang's incision for tying the subclavian artery above the clavicle. I K, Hodgson's incision for the same operation. L M, the incision for tying the subclavian artery on the trachial edge of the scalenus anticus muscle. N O, the incision for tying the subclavian artery below the clavicle. Q R, Rust's and Zang's incision for the same. S T, Lisfranc's incision for tying the axillary artery in the axilla.

W X, incision for tying the brachial artery. Y Z, incision for the same on the elbow. *a b*, incision for the ligature of the radial artery in the upper part of the forearm. *c d*, incision for the ligature of the radial artery at the radio carpal articulation. *e f*, incision for tying the ulnar artery in the upper part of the forearm. *g h*, incision for the same at the carpal articulation. *i k*, Cooper's incision for tying the descending aorta. *l m*, Stevens's incision for tying the internal iliac. *n o*, incision for the ligature of the external iliac, according to Abernethy and Scarpa. *p q*, Cooper's incision for the same. *r s*, incision for tying the crural artery below the crural arch. *t u*, incision for the crural artery in the middle of the thigh. *v w*, Marjolin's incision for tying the posterior tibial artery in the upper third of the leg. 12, Lisfranc's incision for the same vessel in the middle of the leg. 56, incision for the same vessel behind the inner malleolus.

We now proceed to state the mode, as given by Velpeau, for tying the principal arteries.

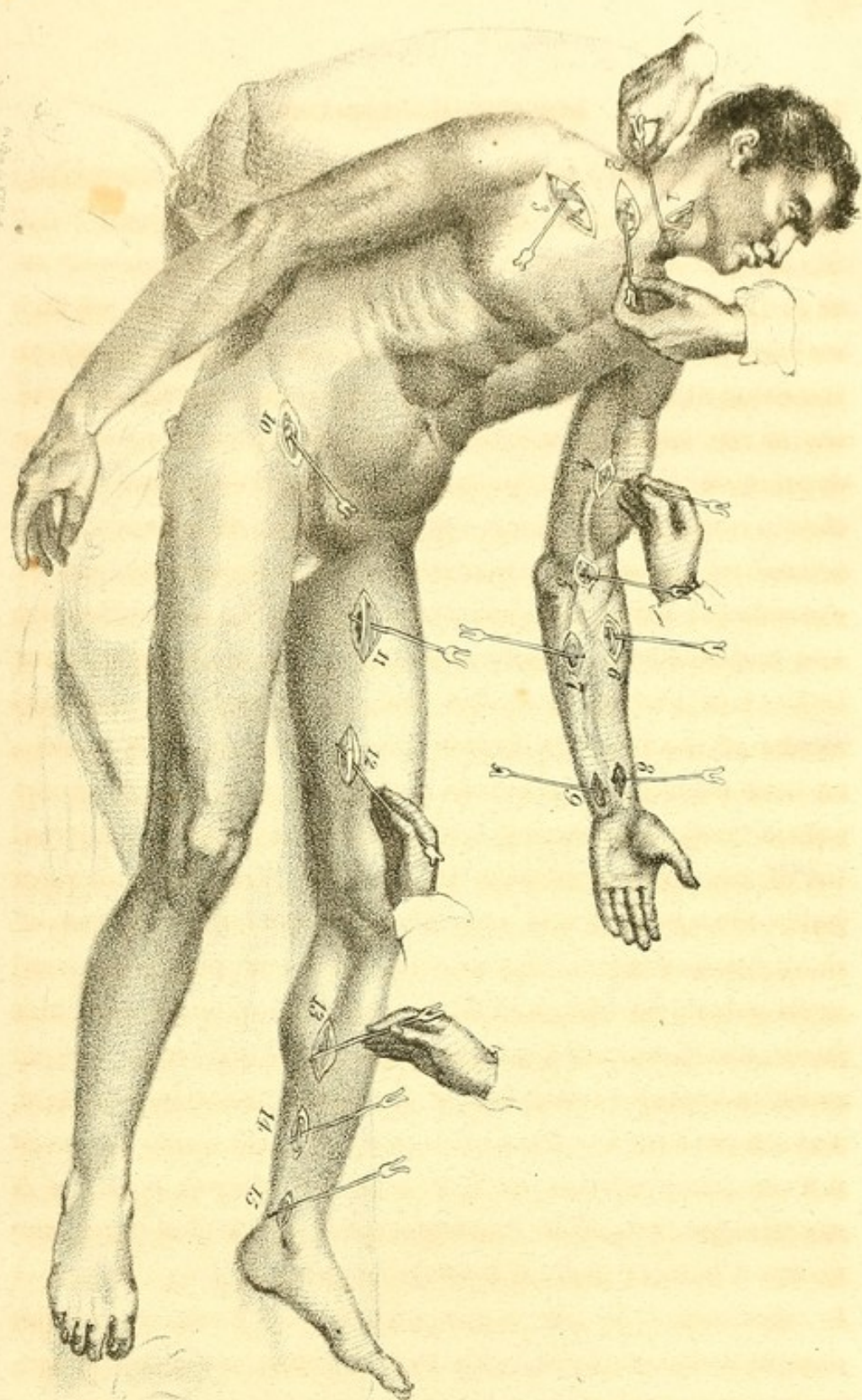
Innominata.—For tying the innominate, Dr. Mott made an incision about three inches long above the clavicle, extending from the outer part of the sterno mastoideus muscle to the front of the trachea; he then made another incision of the same length along the internal edge of the sterno mastoideus muscle, and brought it to the internal extremity of the first; he then divided the whole sternal portion and a great part of the clavicular origin of this muscle, so as to turn it outward and upward. On pushing aside the jugular vein, the subclavian, and some little veins and the surrounding nerves with the handle of the scalpel, he discovered the carotid. Seeing that it appeared diseased, he proceeded to the innominate, which he tied with a simple ligature of silk.

Velpeau, however, recommends the following process as preferable:—

The operator stands on the left side, and makes an incision in the suprasternal hollow of the neck, about two inches long, on the internal edge of the left sterno mastoideus muscle, obliquely, from without inward, or from left to right ; he thus divides successively the skin and the subcutaneous layer, the superficial lamina of the *fascia cervicalis*, the fatty cellular tissue, and a second fibrous lamina ; he then meets, behind the sterno thyroideus muscle, the thyroid plexus, and the thyroid artery of Neubauer, when it exists ; he pushes aside or ties the last-mentioned vessels, and then arrives at the trachea. Here the left subclavian vein and the internal jugular of the opposite side present themselves, which must be detached, and pushed with caution to the right and upward, by means of the sound. The surgeon then flexes the head of the patient a little, and attempts to feel the artery with his forefinger, between the trachea and the right sterno hyoid muscle ; having discovered it, he first isolates its concavity, by passing from before backward, between it and the superior *vena cava*, with all possible care, the extremity of a slightly-curved sound. He then passes this instrument in the same manner on the side toward the trachea, in order to denude its posterior surface, and to raise it ; he now curves the sound a little more, which serves to direct the eyed stylet, whether it is passed from before backward, and from right to left, or from behind forward, and from left to right, taking care also during the whole of the manual not to tear the pleura, not to touch the parvagus, which is left on the right, and not to draw too much on the subclavian vein : it would perhaps be better, in fact, upon a living subject, to raise or depress this vein, so as to pass the sound between it and the trachea, than to withdraw it as I have above directed. This process, which is certainly more simple, more rational, and less dangerous than any other, has also this advantage, that the same incision would serve equally well for the ligature

of either of the subclavian arteries on the inside of the scaleni muscles, and of either of the carotids at their origin.

Carotid.—The patient should lie on his back, his breast slightly elevated, the neck moderately extended, and the face inclined toward the unaffected side; the surgeon stands on the same side with the aneurism, seeks the anterior edge of the sterno mastoideus muscle, which is indicated by a slight depression; he makes an incision about three inches long in the direction of this edge, commencing at the level of the cricoid cartilage, and terminating near the sternum; but he extends the incision higher up, though in the same direction and with the same guide, whenever the malady permits the ligature of the artery in the *omo hyoid* triangle. A second stroke of the bistoury divides the platysma myoides muscle, and the cervical aponeurosis, and exposes the fibres of the sterno mastoideus muscle. The assistant draws the internal lip of the wound towards the median line. The operator holds the external and muscular lip outward, by means of the index and middle finger of the left hand, places the head in its natural position, and afterwards divides the fibro cellular layer, which extends from the sterno hyoid and sterno thyroid muscles to the posterior face of the sterno mastoideus muscle, and passes over the front of the vessels. The *omo hyoideus* muscle then presents itself as a narrow reddish band; if it impedes the use of the instruments, it is divided upon the director, but generally it is easy to preserve it by drawing it to either side with the finger, with a blunt hook, or with the extremity of the probe. Above and below are seen the vein and artery enveloped in their common sheath, the anterior wall of which incloses the descending branch of the ninth pair of nerves. This sheath should be at first perforated opposite to the artery, and not to the vein, with the beak of the director; it should then be divided upon the same instrument



with the bistoury, to the extent of one or two inches. When the jugular vein becomes so much distended, during inspiration, as to conceal a part of the carotid and embarrass the surgeon, it should be compressed at the superior angle of the wound, and it will collapse immediately. The sound, held like a pen, is then directed between the two vessels, [XXIX. 1.] one or two fingers of the opposite hand fix the artery and prevent it from slipping towards the trachea, whilst by gentle movements to and fro, and pressure upon the point of the instrument, the operator passes it along the posterior surface so as to raise the artery without violence, and without touching the pneumo gastric or the great sympathetic nerve, or any of their branches.

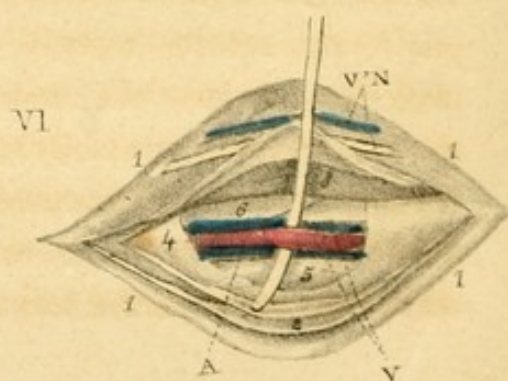
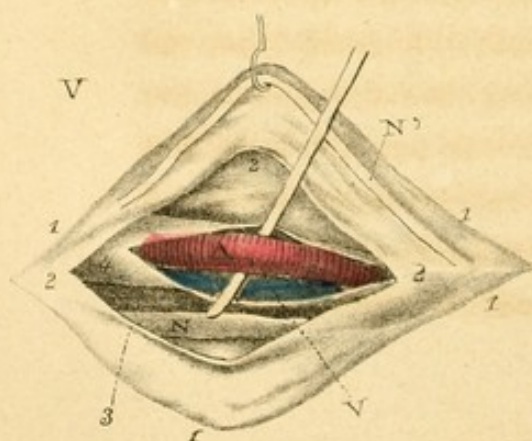
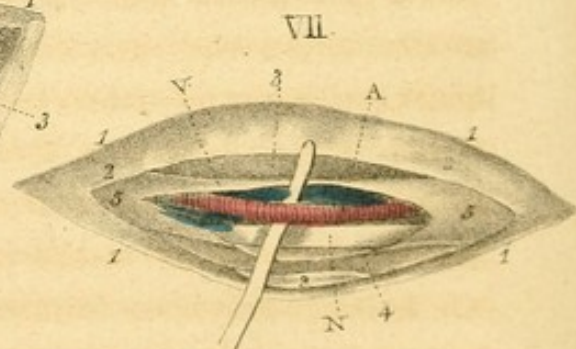
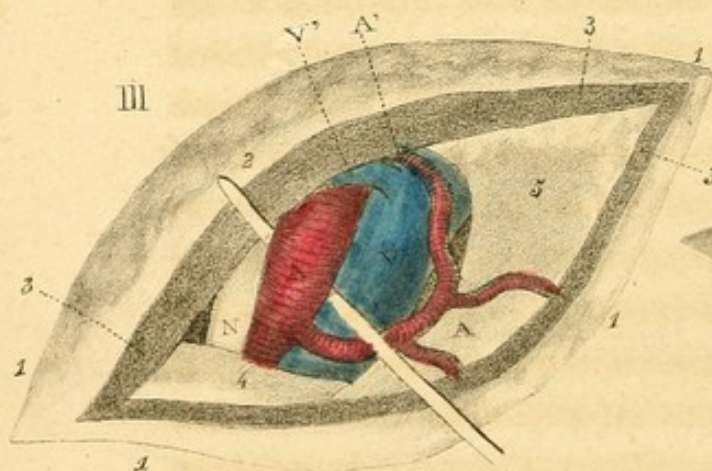
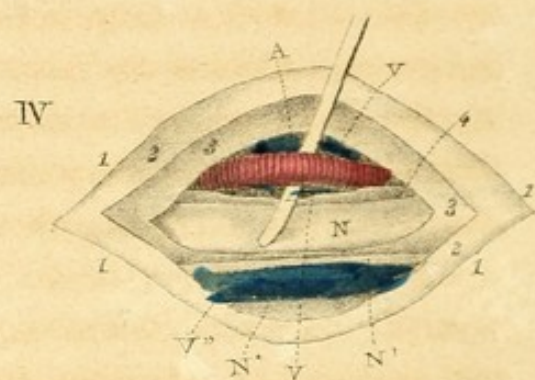
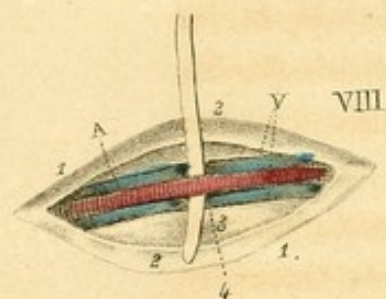
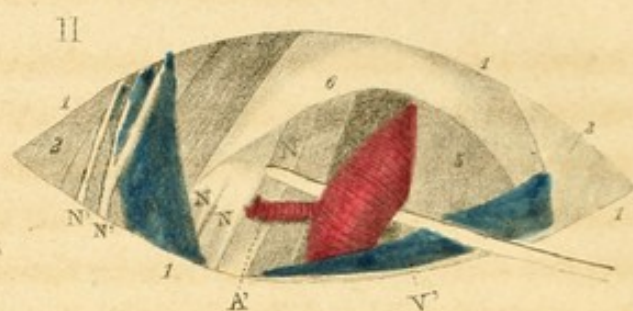
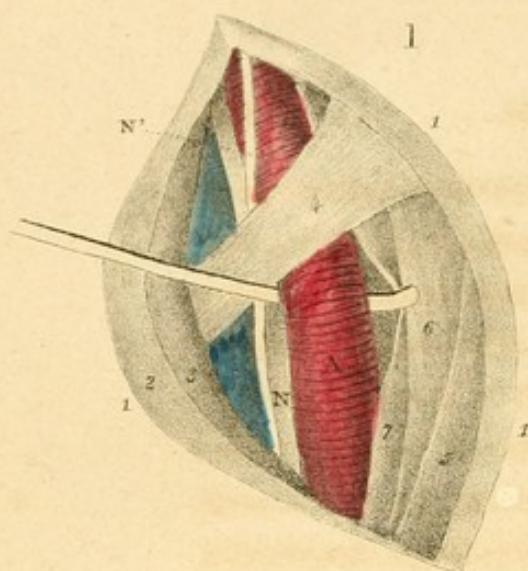
The relations of the carotid artery with the adjacent parts are seen in plate xxxi. fig. 1. Here 1, 1, 1, represent the lips of the wound of the integuments properly separated—2, 2, platysma myoides muscle, divided and drawn back with the skin—3, sterno mastoideus drawn outward—4, omo hyoideus crossing the artery, and dividing the infra hyoid region into two triangles—5, sterno hyoideus muscle—6, the sterno thyroideus muscle—7, fibrous sheath which separates the muscles from the vessels—A, common carotid artery disengaged from its sheath in the omo tracheal triangle, and raised by the beak of a sound—V, jugular vein pushed outward—N, pneumo gastric nerve situated between the vein and the artery—N', descending branch of the ninth pair of nerves.

Subclavian.—The patient should be placed on his back, his chest being slightly elevated: the head and the neck should be turned to the healthy side, while an assistant depresses the shoulder as much as the aneurism will admit, separating the arm from the trunk. The integuments are then divided transversely, at an inch above the clavicle, from

the external edge of the sterno mastoid muscle to the trapezius: we cut in the same directions, the cellular tissue, the fibres of the platysma myoides, and the external jugular vein, between two ligatures, if it cannot be held aside with a blunt hook; we soon come to the aponeurosis, which is divided: the edge of the scalenus muscle can then be felt by the index finger directly below, and on the inside of the sterno mastoideus muscle.

After tearing or separating from the bottom of the wound the cellular tissue, the lamellæ, the filaments, the ganglions, with the end of the sound, or with a good pair of dissecting forceps, the finger is again carried to the root of the scalenus muscle, to feel the tubercle of the first rib. This tubercle is a sure guide in these cases, so that, if the pulp of the index finger be turned a little outward and backward, without leaving the tubercle, it falls almost constantly on the vessel. When the vessel is once found, the eye is no longer necessary. The nail being applied against its posterior and outer face, serves as a conductor for a curved sound or for the needle used. If we pass the end of this instrument from before backward, and a little from without inward, it soon becomes engaged under the artery, which is elevated. [XXIX. 2.] The surgeon then holds the artery in its place, and prevents it from changing its position by passing his finger between it and the first fasciculus of the brachial plexus of nerves.

The relations of the subclavian artery and the parts adjacent, are seen in plate xxx. fig. 2.—1, 1, 1, represent the contour and lips of the wound—2, cervical edge of the trapezius muscle—3, clavicular attachment of the sterno mastoid muscle—4, omo hyoid muscle—5, scalenus anticus muscle—6, aponeurosis freed from the cellular tissue and from the lymphatic ganglions, and then divided and raised—A, sub-



clavian artery emerging from the thorax, raised from before backward, and from within outward by a sound, between the tubercle of the first rib, or the scalenus muscle, and the inferior cervical branch of the brachial plexus—A', posterior cervical artery, which passes between the nervous cords of the plexus and goes backward—V, external jugular vein, which is very large in this subject, and is situated far posteriorly—V', subclavian vein partly concealed by the clavicle, and crossing the anterior face of the scalenus muscle to enter into the chest, behind the sterno mastoid muscle—N, N, N, fasciculi, which form the axillary plexus of nerves—N', N', superficial descending branches of the cervical plexus, or the supra acromial nerves.

Axillary artery.—By the term axillary artery is understood that portion of the brachial trunk which extends from the clavicle to the origin of the humeral artery. In tying it, the limb is first carried from the trunk, and the shoulder is thrown a little backward. The surgeon then stands between the breast and the arm, and commences his incision two fingers' breadth to the outside of the sterno clavicular articulation, and extends it to a point beneath the coracoid process, in the direction of the fibres of the pectoralis major muscle, taking care to stop some lines from the interstice between the pectoral and the deltoid muscle. If any little artery present itself under the skin, it is immediately tied; the fleshy fibres are gradually separated rather than divided with the bistoury; a very distinct yellow stratum indicates that the operator has passed through the muscle, the fibres of which are then relaxed by lowering the limb a little, so that the lips of the wound may be more easily separated. To avoid the slightest danger of wounding the vessels, the director or probe should here be substituted for the cutting instrument; the operator tears with its beak the adipose and cellular stratum and the

coraco clavicular aponeurosis, whilst the left index finger, bent into a hook, depresses with considerable force the upper edge of the pectoralis minor. The surgeon will soon distinguish the vein, which may be known by its size and bluish colour, or the first branch of the brachial plexus of nerves. In seeking for the artery between and behind these two cords, the director is guided on the external side of the vein, which it is necessary to push a little towards the thorax. The instrument is then made to penetrate by a to and fro movement to a depth of from four to six lines, in such a way, that in raising it again from behind forward and from within outward, it may not fail to bring up the arterial trunk, [XXIX. 3.] from which the operator removes the nerve either with the finger nail or with the beak of another director.

With these precautions, the secondary vessels and the nervous cords, at least on the dead subject, are easily avoided, and the artery is exposed. By placing the ligature immediately under the cephalic vein, the operator is almost sure to embrace the axillary artery between the acromials, which are left above, and the external thoracics which pass below. The supplementary branches which maintain the circulation in the member after this operation, are the acromial, the subscapular, the transverse cervical, the internal mammary, and some others of minor importance, all of which anastomose with the circumflex, the common scapular, and the external mammary artery.

The relations of this artery with the contiguous parts are shown in plate xxx. fig. 3—1, 1, represent the lips of the wound—2, 2, layer of fat and that of the aponeurosis—3, 3, section of the pectoralis major divided in the direction of its fibres—4, superior edge of the pectoralis minor—5, 5, adipose substance and deep aponeurosis torn—A, axillary artery brought forward by the sound, after being disengaged from

the vein, which is on the inside, and the nerve nearest to the chest, which is on the outside—A', A', acromial and anterior thoracic branches, which arise from the principal artery by a common trunk—V, axillary vein—V', cephalic vein, proceeding from the arm to the axillary vein—N, first branch of the brachial plexus.

Brachial artery.—The forearm being extended on the arm, the surgeon looks for the groove at the edge of the biceps, carries the bistoury in the line of the artery from above downward in the right arm, and from below upward in the left, and divides the integuments for a space of from two to three inches. He then glides the left index finger into the wound, and feels for the median nerve, which appears as a cord of considerable firmness, and may be distinguished from the artery, as the latter pulsates: he then divides successively, upon a director, the aponeurosis and the sheath which it gives to the medio digital nerve; he tears the cellulo fibrous sheath of the vessel, and always with the beak of the sound: separates the artery from the surrounding veins, [XXIX. 4.] and ties it. Its relations with the surrounding parts are figured in plate xxx. fig. 4.—1, 1, 1, 1, represent the circumference of the wound—2, 2, the enveloping aponeurosis—3, 3, another aponeurotic fold, which serves as a common sheath for the bundle of vessels and nerves—4, fibrous septum, which separates the artery from the median nerve—A, brachial artery—V, V, collateral veins—V", basilar vein—N, median nerve—N', cutaneous nerve—N*, ulnar nerve.

Brachial artery at the elbow.—In tying the artery in this situation, the following rules are to be observed:—

The forearm being extended on the arm, an incision is made three inches long, parallel to the radial or superior edge of the pronator teres muscle, commencing nearly an inch above the epitrochlea, and terminating in the middle of the

bend of the arm. Beneath the skin we find the superficial veins, the median basilic vein, and the branches of the cutaneous nerve which accompany it. These are held out of the way by an assistant with a blunt hook, or the beak of a probe bent for the purpose. Whenever any of their branches impede the operation, or cannot be displaced conveniently, they should be tied and divided. The aponeurosis is next seen, and must be divided upon the director; even when the superficial tendon of the biceps can be preserved, it is better to sacrifice it: the remainder of the operation will thus become much more easy, and a powerful cause of inflammatory strangulation will be destroyed. After removing the surrounding lamellar and adipose cellular tissue from the artery, and having separated it from the deep vein or veins, and from the median nerve, the operator passes between it and this latter cord the extremity of a probe, with which he raises the artery, [XXIX. 5.] whilst with a nail of the other hand he hinders the veins from following it, or from lying under the point of the instrument. The ligature is then applied.

The relations of the artery with the adjacent parts are seen in plate xxix. fig. 5.—1, 1, 1, circumference of the wound—2, 2, 2, aponeurosis divided and turned over—3, 3, part of the brachialis anterior muscle—4, sheath of the artery—A, artery raised above the aponeurotic expansion of the biceps—V, collateral vein—N, median nerve—N', branch of the musculo cutaneous nerve, separated at the same time as the corresponding lip of the wound with a hook.

Radial artery.—In tying the radial artery in the upper part of the arm, the incision must be at least two inches long, and be a little oblique from within outward, so that it may not fail to pass over the line of direction of the artery. If the superficial radial vein, or the common median vein presents itself

under the skin, it must be pushed aside with the director. It is better to fall some lines on the outside than on the inside of the edge of the supinator longus muscle. In the former direction, the aponeurosis presents only a single layer, while in the other, that is, over the edge of the muscle, a primary lamina must first be divided, and the fleshy fasciculus drawn somewhat outward; a second layer appears beneath, which is cut upon the director, and the artery may then be easily taken up. [XXIX. 6.]

The relative situation of this artery is seen in plate xxx. fig. 6.—1, 1, 1, 1, circumference of the wound—2, 2, first layer of the aponeurosis divided and turned over—3, inner edge of the supinator longus muscle—4, second layer of the aponeurosis—5, flexor sublimis muscle—6, tendon of the pronator teres—A, artery raised between the veins—V, collateral veins—V', N, superficial vein and nerve.

Ulnar artery.—If the ulnar artery is to be tied at the upper part of the arm, an incision is made three or four inches long, beginning at three fingers' breadth from the trochlea of the humerus, and descending to the middle of the forearm, on the inner side of the tendon of the flexor carpi ulnaris muscle. The aponeurosis being laid bare, we look for the interstice between the flexor ulnaris and the flexor minimi digiti muscle; to find this we have only to draw the internal edge of the wound towards the cubital side of the member; and in returning afterward toward the median line, the first yellow or grayish trace indicates the interstice required. An incision is then made in the aponeurosis upon the external edge of this line, of the same extent with that in the skin; this done, the flexor ulnaris and the flexor minimi digiti are separated from each other by means of the index finger, the handle of a scalpel, or a director; the surgeon will then see at the bottom of the wound a large yellow or whitish cord, which

is the cubital nerve, having the artery on its radial side. [XXIX. 7.] In taking up the latter it is not even necessary to see it. It may be safely raised by passing the beak of the sound between it and the nerve.

The relations of the artery and parts adjacent are seen in plate xxx. fig. 7.—1, 1, 1, the contour of the wound—2, 2, 2, the first aponeurotic layer—3, flexor sublimis muscle—4, ulnaris internus muscle—5, 5, second aponeurotic layer—A, ulnar artery—V, collateral vein—N, ulnar nerve.

Radial artery above the wrist.—In performing this operation the hand should be held supine; the surgeon then, standing on the cubital side, divides the integuments to the extent of from one to two inches over the course of the artery, taking care not to proceed too deeply at first. He then cuts the aponeurosis upon a grooved director, so as to avoid touching the vessels. [XXIX. 8.]

In plate xxx, fig. 8, 1, 1, represent the contour of the wound—2, 2, the aponeurosis—3, 3, tendon of the radialis anterior muscle—4, pronator quadratus muscle behind the vessels—A, radial artery separated from its veins, V.

Ulnar artery above the wrist.—The hand being placed as in the preceding operation, the surgeon makes an incision of the same extent and in the same direction, cutting on the radial edge of the flexor carpi ulnaris muscle, or in the inner groove of the forearm. After dividing the skin, the fatty layer, the thin fibrous lamina which covers the tendon of the flexor carpi ulnaris, and pushing this tendon to the inside, the artery can be seen through a second layer on the radial side of, and a little anterior to, the ulnar nerve. [XXIX. 9.]

The relations of the artery are seen in plate xxxi. fig. 1.—1, 1, represent the contour of the wound—2, 2, aponeurosis, 3, tendon of the flexor carpi ulnaris pushed inward—4, 4, 4,

deep layer of the aponeurosis—A, artery attended by the veins, V—N, anterior branch of the ulnar nerve.

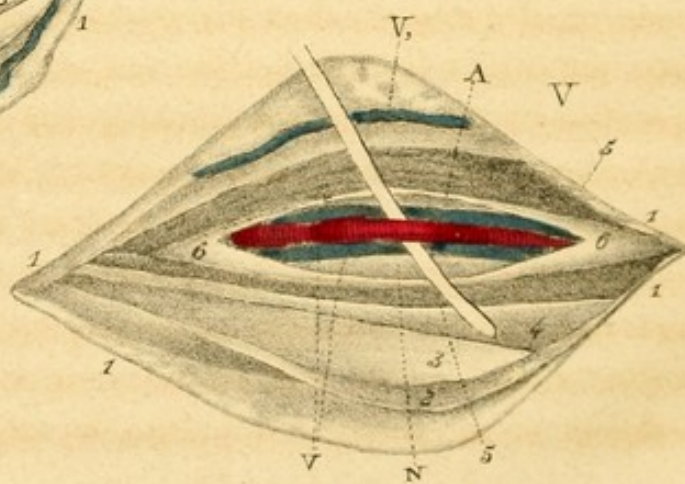
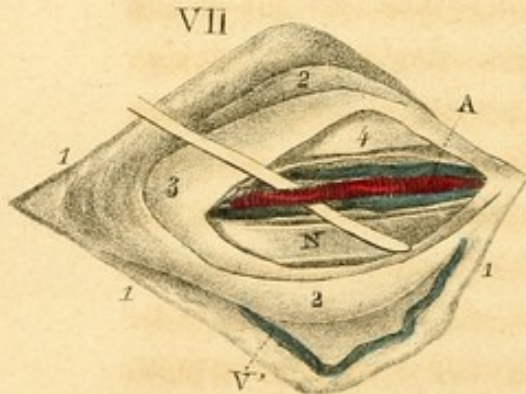
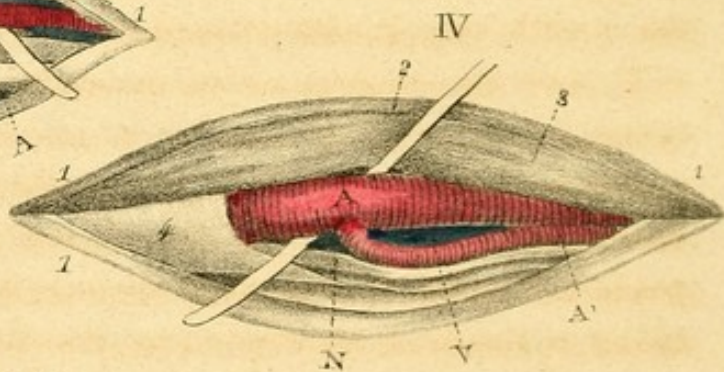
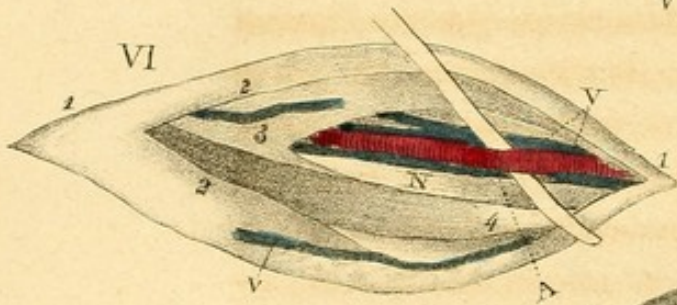
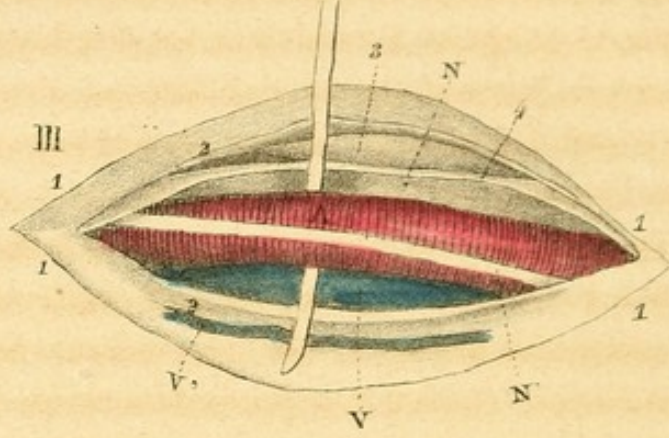
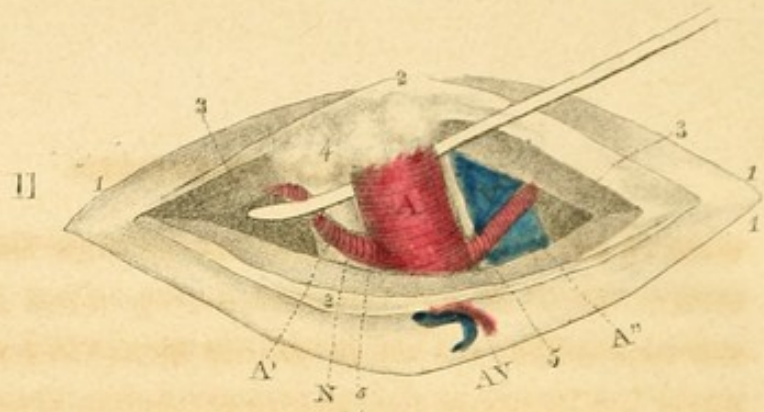
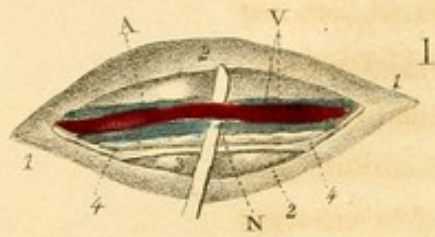
External iliac artery.—The following operation is recommended by Velpeau, as the simplest and easiest.

The patient lies on his back, the limb being moderately extended and kept in its position by assistants. The operator then places himself on the side of the aneurism, and makes a slightly-curved incision, three inches long, parallel with and a little above the fallopian ligament; the middle of the incision is on a level with the artery. The first stroke of the bistoury divides the skin and the *fascia superficialis*; if the flow of the blood from the branches of the external epigastric artery impedes the operation, this artery should be tied. The aponeurosis of the external oblique muscle then appears. For greater security, it is well, though not indispensable, before making the incision, to pass under this tissue a grooved director. The fibres of the internal oblique muscle are next seen, which may be divided by an experienced surgeon with the cutting instrument; otherwise their inferior extremity is to be detached with the point of a director, pushing them backward and upward, while the left index finger fixes and retains the inferior edge of the wound; the *fascia transversalis* is then torn in the same manner as far as the spermatic cord, which is pushed aside in the same direction as the fleshy fibres. From this point, in order to avoid the peritoneum, particularly when the ligature is to be carried upon a very elevated point of the iliac fossa, the finger should be used instead of the sound; in other cases the latter is preferable. Now, if the eye of the operator cannot distinguish the objects, the forefinger thrust into the wound, the lips of which should be kept separate, will easily feel the artery upon the internal edge of the psoas, and the side of the superior strait. We now penetrate with the director the sheath

which it receives from the fascia iliaca, directing the beak of the instrument upon its internal side, and detaching it from the vein by careful movements to and fro. After this separation, which should be as small as possible, but yet should comprise the whole circumference of the artery so as to detach it completely from the iliac vein and from the nervous branch which crosses their surface, the operator, in order to pass the ligature, may use an eye-probe conducted along a director, or the needle of Deschamps, or any other convenient instrument. [XXIX. 10.] During the operation, but particularly at its termination, it is highly important that the abdominal muscles be kept relaxed, and that the patient should refrain from any effort, from making the slightest movement, otherwise the intestines will certainly present themselves at the incision, and a wound of the peritoneum will be almost inevitable.

The relations of the external iliac artery are seen in plate xxxi. fig. 2.—1, 1, 1, represent the edges of the wound—2, 2, aponeurosis of the obliquus externus muscle—3, 3, obliquus internus muscle—4, ganglion sometimes found before the artery—5, 5, edges of the fibrous sheath, which separates the artery A from the nerve N, and from the vein V—A', circumflex artery of the ilium—A'', epigastric artery—A''' V', artery and vein of the integuments.

Femoral artery in the upper part of the thigh.—In this part, an incision of from two to three inches is generally sufficient to expose the artery. The centre of this incision should be four fingers' breadth from the fallopian ligament; the knife should be carried in the direction of the line represented by the course of the vessel, a little outward rather than too much inward, on account of the saphena vein. After dividing the skin and the fatty layer, the aponeurosis presents itself; before dividing it, we should remember that below, the inner



edge of the sartorius muscle usually separates it from this artery, which is not the case in the upper part of the inguinal triangle. This lamina being opened and the muscle pushed outward as far as necessary, we pass a grooved director, to serve as a conductor for the bistoury, under the superficial layer of the arterial sheath. Finally, we insulate the vessel, [XXIX. 11.] being careful to wound neither the crural vein nor the adjacent nerves.

The relations of the femoral artery with the contiguous parts are seen distinctly in plate xxxi. fig. 3—1, 1, 1, represent the circumference of the wound—2, 2, the first lamina of the aponeurosis—3, edge of the sartorius muscle—4, second lamina of the aponeurosis, or the arterial sheath—A, femoral artery having on the outside the crural nerve N, on the inside the crural vein V, and crossed by the saphena nerve N'—V', internal saphena vein, imbedded in the cellular tissue.

Femoral artery at the lower part of the leg.—Put the sartorius muscle in action by placing the leg in the tailor's position, then make an incision three inches long about the centre of the thigh, in the oblique direction of this muscle, and on its inner edge: continue it through the integuments and fat till the border of the muscle is exposed. Observe the direction of the fibres, to ascertain that you have not come on the vastus; then elevate the sartorius; draw it a little outward, which brings the femoral sheath into view; open this by a small incision, and then dilate it, cutting from within outward: this exposes the artery, [XXIX. 12.] which has the vein rather behind and to its outer side.

The relation is seen distinctly in plate xxxi. fig. 4—1, 1, 1, represent the contour of the wound—2, the aponeurosis—3, the sartorius drawn outward—4, deep aponeurosis, giving a sheath to the artery A—V, the femoral vein, and N the

crural nerve, situated on the inside of it—A', a large anastomotic branch.

Posterior tibial artery in the calf of the leg.—The operator stands on the outside of the limb, and makes an incision about four inches long in the direction of the inner edge of the tibia, and about a finger's breadth from it, separates the saphena vein, divides the aponeurosis, comes perpendicularly on the fibres of the soleus, which he cuts, layer by layer, as if to arrive at the posterior face of the tibia, very near its outer edge: he soon perceives a fibrous, thick and shining layer, in which fleshy fibres are inserted: this is the deep aponeurosis, through which pass several branches of vessels. The artery is directly under, [XXIX. 13.] surrounded by its attendant veins, and accompanied by the nerve which is distinguished from it by its roundness, size, and yellow colour.

The connexions of this artery are seen in plate xxxi. fig. 5—1, 1, 1, circumference of the wound—2, first aponeurotic lamina—3, gastrocnemius—4, cellular layer, which separates the gastrocnemius from the soleus—5, section of the soleus muscle—6, 6, deep aponeurosis—A, tibial artery, having a vein, V, on each side—N, posterior tibial nerve—N', internal saphena vein pushed forward.

Posterior tibial artery below the calf.—When we wish to tie this artery between the malleolus and the calf of the leg, we make a straight incision from two to three inches long, at an equal distance from the inner edge of the tibia and from the achilles tendon. When the skin, the fatty layer and the superficial layer of the aponeurosis are divided, we attempt, with the sound, to lay bare the deep aponeurosis. We then divide this layer to the same extent as the skin, being careful to use the bistoury only on the groove of a director. We then fall directly on the artery, [XXIX. 14.] especially when we have taken the precaution to cut the tissues perpen-

dicularly ; that is, by carrying the bistoury from behind forward, from the inner towards the outer side of the leg, as if seeking for the fibular edge of the tibia. We would remark, that if the integuments are incised nearer the bone than we have stated, there is but one aponeurotic layer to be divided ; but in coming on the muscles at a much greater distance from the vessel, we run more risk of being confused than if we pursue the course pointed out.

The relations of the artery with the parts adjacent are seen in plate xxxi. fig. 6.—1, 1, 1, represent the circumference of the wound—2, first aponeurotic layer—3, second aponeurotic layer—4, achilles tendon, situated between the two layers of the aponeurosis—A, tibial artery, situated a little more deeply—V, collateral veins—N, posterior tibial nerve—V', branch of the saphena vein.

Posterior tibial artery behind the malleolus.—We make a slightly curved incision concave anteriorly, commencing an inch above and terminating an inch below, and passing three lines at least from the posterior edge of this prominence. When we operate at the commencement of the calcaneal groove, we must proceed with care, divide the tissues layer by layer, and pass the grooved sound under the aponeurosis before cutting it with the bistoury, in order to avoid wounding the artery, which is sometimes situated very superficially : if we make the incision nearer to the malleolus, we might easily come upon one of the fibro synovial sheaths, which it contributes to form, the inflammation resulting from which might be dangerous. If the incision be made farther back, it would be difficult to find the artery, and the operation would be much more laborious. The artery being separated from the adjacent parts, it may be raised with a sound. [XXIX. 15.]

The relations of the artery are seen in plate xxxiv. fig. 7—

1, 1, 1, represent the contour of the wound—2, 2, first aponeurotic layer—3, deep aponeurosis—4, tendon of the tibialis posticus muscle—A, artery—V, veins—N, tibial nerves—V', subcutaneous veins.

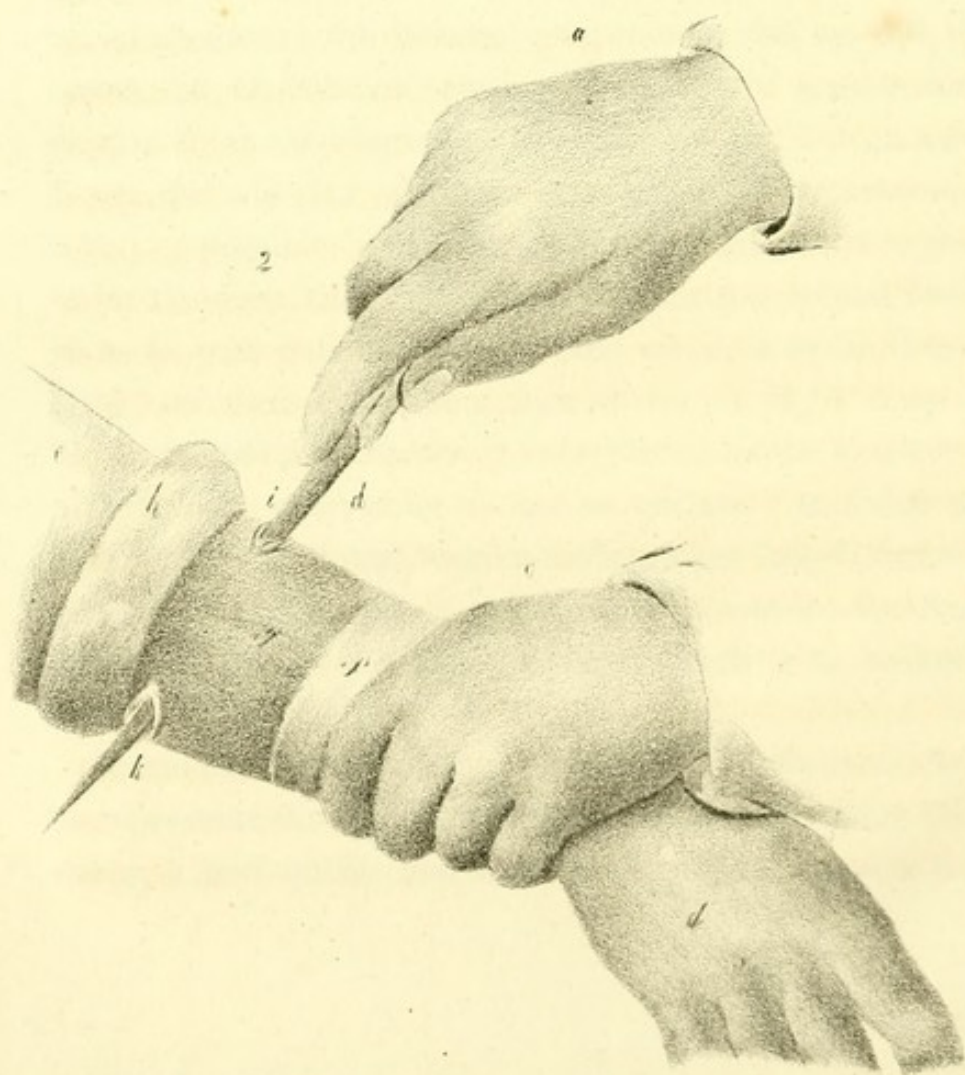
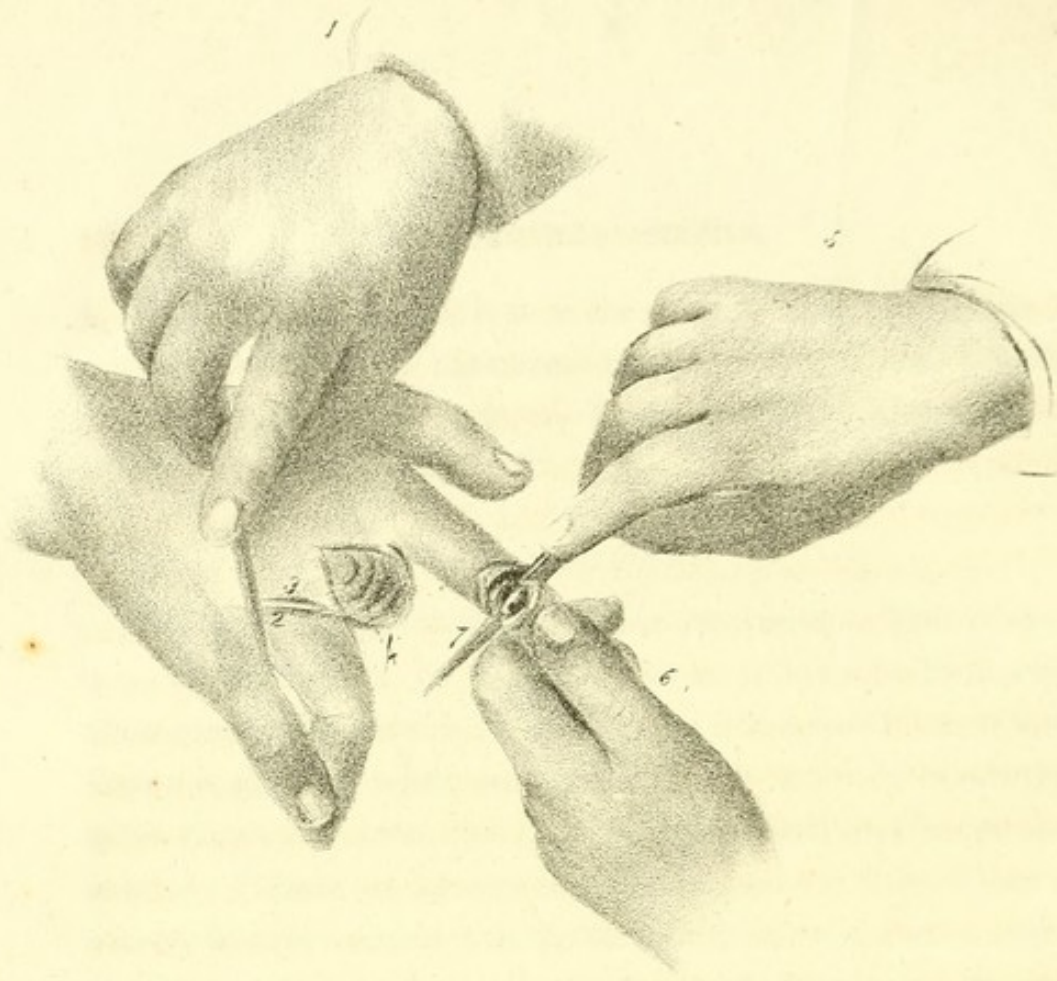
AMPUTATIONS.

Flap operation for removal of the phalanges.—This operation, as performed by Velpeau, is as follows:—The surgeon grasps the diseased finger, draws it towards himself and flexes it slightly, while an assistant holds the root, bends the other fingers, or separates them from the first, and keeps the hand in a state of pronation. The operator then takes a narrow bistoury, holds it in the first position, and cuts a small semilunar flap convex toward the nail, passing from one side to the other, through the whole course of the anterior fold of the skin. The divided integuments are drawn back by an assistant: the bistoury, which is carried up with them, opens the articulation, cutting the extensor tendon across, divides the lateral ligaments on the right and left, passes between the articular processes, avoiding their prominences as much as possible. As soon as the surgeon comes to the anterior ligament, the edge of the instrument is turned forward, so as to pass over the palmar face which is to be disarticulated, and form a flap from four to six or eight lines long. The principal dependance is to be placed on the anterior flap, although the other is by no means useless. In order not to make it too short, and to give it the proper length, before the incision is terminated, it is prudent to measure the flap by raising it against the articular face, which is to be covered by it.

Amputation of the phalanges is seen in plate xxxii. fig. 1—5, represents the right hand of the operator holding the bistoury, 7, and cutting the anterior flap, *a*, to separate from it

32

34



the second phalanx, which the left hand, 6, moves and attempts to separate from the first. An aid should hold with his left hand the root of this finger and the thumb; while with his right hand he keeps the other three fingers flexed.

Amputation of the fingers.—The surgeon, the assistants, and the hand of the patient, being situated as in the preceding case, the operation is commenced in the same manner. The surgeon seizes the diseased finger with the left hand, flexes it very slightly, separating it a little from the others, then begins the incision on the dorsal face, and behind the articulation with the heel of the bistoury, which he brings gently forward to the edge of the commissure, and with which he turns the palmar face of this finger, cutting exactly on the semicircular line which separates it from the hand. Having arrived at the opposite edge, he brings the bistoury again to the anterior or phalangeal extremity of the wound, and carries it obliquely to the metacarpus, to unite the two extremities of the incision. Without leaving the part which he wishes to remove, he separates the lips of the incision as much as possible, divides the extensor tendons, then the lateral ligaments and the posterior half of the articular capsule, flexes the finger still more, drawing it as if to dislocate it, passes the bistoury on its palmar face, proceeding through the articulation, and terminates by dividing the flexor tendons and the soft parts which unite the phalanx to the cellular cushion of the hand.

Instead of turning the palmar side of the finger, after reaching the commissure, it is more convenient to make the second incision like the first. The finger is then disarticulated, and we proceed as has been described. A V shaped incision is thus made, and the wound does not present an oval form till after the operation.

In plate xxxii. fig. 1—1, represents the right hand of the

surgeon, terminating the incision 2 of the integuments, an incision commenced on the back of the carpus, 3, so as to turn around the whole root of the finger—4, shows the appearance of the wound directly after the amputation: we see there, proceeding from behind forward, the extensor tendon, the head of the bone, the section of the ligaments, the flexor tendon and its sheath. We must suppose here that an aid separates the other fingers.

Amputation of the wrist.—Circular method: the assistant who holds the forearm, draws the integuments backward. The surgeon seizes the hand of the patient, and flexes it while he cuts on the dorsal face; inclines it toward the radius while he cuts on the inside to the ulna, when he comes to the outside, and extends it when the instrument is passed below. In this manner he makes a regularly circular incision, a finger's breadth in front of the processes of the forearm, and confines himself first to the division of the skin, which is easily pulled back to near the articulation. A second cut divides all the tendons at the edge of the retracted integuments. Finally, the articulation is opened on one side or the other, taking the corresponding styloid process as a guide, and passing the bistoury in a line convex posteriorly.

Flap operation.—Lisfranc's method. The hand and forearm being placed in supination, are fixed by the assistant, who compresses at the same time the radial and ulnar arteries. The operator takes a narrow knife, perforates the tissues of the radius towards the ulna, or from the ulna towards the radius, according as he operates on the right or left limb, at the styloid processes, thus passes between the soft parts and the anterior face of the carpus, then draws the knife forward, and cuts as before a semielliptical flap, about two inches long. This flap being raised or turned backward, the

surgeon makes immediately a semicircular incision on the back of the wrist, somewhat similar to that just described; divides at the same time the extensor tendons almost on a level with the joint: then disarticulates, by passing under the point of one of the styloid processes, and finishes as in the circular method.

The flap operation is shown in plate xxxiii. fig. 1—*a*, the right hand of the operator holding the knife, *b*, almost horizontally, to cut the palmar flap and remove the hand, *d*, which he sustains and depresses with the left hand, *c*—*e*, dorsal flap raised on the forearm—*f*, fatty layer and anterior edge of the wound—*g*, dorsal aponeurosis of the metacarpus—*h, h, h, h*, divided tendons of the extensor muscles—*l*, radial and ulnar arteries—*k*, head of the ulna. The articulation being traversed, we see anteriorly, *m*, the head formed by the union of the scaphoid, the semilunar bone, and the pyramidal bone posteriorly—*i, i*, the corresponding cavities presented by the radius and the ulna; then, a little further, three fibrous sheaths, a radial, an ulnar, and a central one, for the tendons of the three principal packs of muscles which extend the hand or the fingers.

Amputation of the forearm.—The circular operation, as practised by Velpeau, is as follows: the patient sits on the edge of his bed, or on a chair if the tourniquet is not used; an assistant standing behind him, presses the brachial artery against the humerus, below the axilla, resting on it the four fingers of his hand alone, or making compression by a pledget, a rolled bandage, &c.; another assistant holds the forearm in pronation, and is ready to draw the skin towards the elbow. The limb which is to be removed is wrapped in a cloth, and in turn should be supported by a third assistant. The operator stands on the inside, and unless he is ambidexter, seizes the forearm above the point where the skin is to be incised, if it be on the left

side, and below, if on the right. He then divides the external envelope circularly as far as the aponeurosis, two or three fingers' breadth below the place where the bones are to be sawed. If any cellulo fibrous bands prevent the retraction of the integuments, the surgeon immediately divides them, bringing back the knife in a circle, as in the first instance, to the external and posterior face of the radius: he then cuts the muscles as nearly with the skin as possible, dividing first those of the dorsal region, next those of the palmar region, and lastly those of the radial region. The divided muscles retract more or less; the knife is brought backward on the dorsal face of the ulna; it is now drawn toward the operator. Its point glides on the posterior interosseous fossa, which it traverses deeply and returns, dividing all it meets, to the posterior face of the radius, around which it turns. It is then carried beneath to do anteriorly what has just been done posteriorly, and nothing now remains around the bones. The middle head of the double split compress, [I. 9.] is immediately introduced with the forceps through the interosseous space, proceeding from the palmar to the dorsal face. The flesh being thus protected and drawn back, the surgeon proceeds to saw the bones, beginning with the radius, continues operating both on the radius and ulna, but terminates by the latter. After amputating the limb, the split compress is removed, the parts are loosened, and the arteries are then sought for. The anterior interosseous artery, attended by a nervous filament, which must be left untouched, is found at about the centre of the palmar face of the ligament of the same name. The radial, which is situated farther outward, and more superficially, is seen between the supinator longus, the flexor carpi radialis, and the flexor pollicis longus: it is so far from the nerve, that no particular care is required in tying it. On the inside, between the flexor carpi radialis, the flexor sublimis,

and profundus, we find the ulnar artery, having its nerve on the inside. The posterior interosseous artery, which ramifies in the extensor muscle, demands no attention, unless the forearm is amputated near its upper part. The wound should be united from behind and before, and the adhesive straps should be applied in this direction. In this manner, we obtain a transverse linear wound, the angles of which embrace the bones, and allow the remains of the corresponding ligature to hang out, while the centre should be brought out at the middle of the wound.

The circular operation for removing the forearm is shown in plate xxxii. fig. 2—*a*, the right hand of the surgeon grasping his knife, *b—c*, the left hand supporting the wrist of the patient, *d—e*, part of the forearm, to be held by an assistant—*f*, incision of the skin about two inches below the point where the bones are to be divided—*g*, the flesh and aponeurosis denuded of their integuments—*h*, flap of skin and fatty tissue dissected and raised—*i*, point where the knife entered—*k*, point where the knife came out.

Flap operation.—The limb being in a state of pronation, the surgeon cuts the palmar flap, gliding his knife from one side of the forearm to the other, between the bones and the soft parts, which he cuts obliquely from above downward. To form the dorsal flap, he draws the lips of the wound backward, returns the point of the knife to the superior part of the first incision, passes it behind, and terminates with the same precautions as before: the assistant then holding back all the flesh, the surgeon cuts around the radius and ulna, the split compress is passed between the bones, and they are divided as before.

Arm.—Circular operation.—The patient being placed, and the artery compressed, as in operating on the forearm, an assistant holds the limb from the trunk at nearly a right an-

gle. The rule is for the surgeon to stand on the outside, but when the left arm is operated on, there is some advantage in standing on the inside. The left hand of the surgeon is thus still enabled to draw the skin as the knife divides it. The integuments are incised as near the elbow as possible. In cutting the muscles circularly, on a level with the retracted skin, it is important to divide the whole of the biceps. We might even first cut this muscle alone, as is advised by Cooper, so as not to touch the muscles of the deep layer, except at a few lines from the point where the bone is to be sawed. When the humerus is exposed, the separation of the fleshy fibres from it for the space of an inch or two, and parallel to its length, as advised by Bell and Graefe, cannot be injurious. Hello asserts that the deep fibres thus preserved, are the only ones which can cover the stump. It is necessary also to dissect the skin, as Alanson remarks, if the other tissues are to be divided perpendicularly by one incision. In all events, we must be careful that the radial nerve does not escape the knife. The last fleshy layer should be cut about three inches above the division of the integuments. The application of the single split compress, [I. 8.] and the sawing of the bone, present nothing peculiar. The humeral artery is found between the biceps and the inner portion of the triceps, attended by the median nerve, and between its two concomitant veins. The two or three other arterial branches which require attention, will be indicated by their jets of blood.

Klein's flap operation for removing the arm.—A narrow knife is passed entirely through the arm from the radial to the ulnar side, grazing the bone, and thus forms the first semilunar flap, about three inches long: after forming a second in the same manner, from the opposite side, the two are raised. We then divide the few muscular fibres remaining adherent to the bone, and saw the bone in the usual manner.

the first of these was the discovery of the
 gold mine at Potosi in 1545. This discovery
 led to the rapid growth of the city of Potosi
 and the mining industry in general. The
 second was the discovery of the silver mine
 at Zacatecas in 1563. This discovery led
 to the rapid growth of the city of Zacatecas
 and the mining industry in general. The
 third was the discovery of the silver mine
 at Guanajuato in 1563. This discovery led
 to the rapid growth of the city of Guanajuato
 and the mining industry in general. The
 fourth was the discovery of the silver mine
 at Mexico City in 1563. This discovery led
 to the rapid growth of the city of Mexico City
 and the mining industry in general. The
 fifth was the discovery of the silver mine
 at San Juan de los Rios in 1563. This
 discovery led to the rapid growth of the city
 of San Juan de los Rios and the mining
 industry in general. The sixth was the
 discovery of the silver mine at Santa Fe
 de Bogota in 1563. This discovery led to
 the rapid growth of the city of Santa Fe
 de Bogota and the mining industry in
 general. The seventh was the discovery
 of the silver mine at Lima in 1563. This
 discovery led to the rapid growth of the
 city of Lima and the mining industry in
 general. The eighth was the discovery
 of the silver mine at Cuzco in 1563. This
 discovery led to the rapid growth of the
 city of Cuzco and the mining industry in
 general. The ninth was the discovery
 of the silver mine at Arequipa in 1563.
 This discovery led to the rapid growth of
 the city of Arequipa and the mining
 industry in general. The tenth was the
 discovery of the silver mine at Trujillo in
 1563. This discovery led to the rapid
 growth of the city of Trujillo and the
 mining industry in general. The eleventh
 was the discovery of the silver mine at
 Huancayo in 1563. This discovery led to
 the rapid growth of the city of Huancayo
 and the mining industry in general. The
 twelfth was the discovery of the silver
 mine at Tarma in 1563. This discovery
 led to the rapid growth of the city of
 Tarma and the mining industry in general.
 The thirteenth was the discovery of the
 silver mine at Ayacucho in 1563. This
 discovery led to the rapid growth of the
 city of Ayacucho and the mining industry
 in general. The fourteenth was the
 discovery of the silver mine at Ica in 1563.
 This discovery led to the rapid growth of
 the city of Ica and the mining industry in
 general. The fifteenth was the discovery
 of the silver mine at Arequipa in 1563.
 This discovery led to the rapid growth of
 the city of Arequipa and the mining
 industry in general. The sixteenth was
 the discovery of the silver mine at
 Trujillo in 1563. This discovery led to
 the rapid growth of the city of Trujillo
 and the mining industry in general. The
 seventeenth was the discovery of the
 silver mine at Huancayo in 1563. This
 discovery led to the rapid growth of the
 city of Huancayo and the mining industry
 in general. The eighteenth was the
 discovery of the silver mine at Tarma in
 1563. This discovery led to the rapid
 growth of the city of Tarma and the
 mining industry in general. The nineteenth
 was the discovery of the silver mine at
 Ayacucho in 1563. This discovery led to
 the rapid growth of the city of Ayacucho
 and the mining industry in general. The
 twentieth was the discovery of the silver
 mine at Ica in 1563. This discovery led
 to the rapid growth of the city of Ica
 and the mining industry in general.

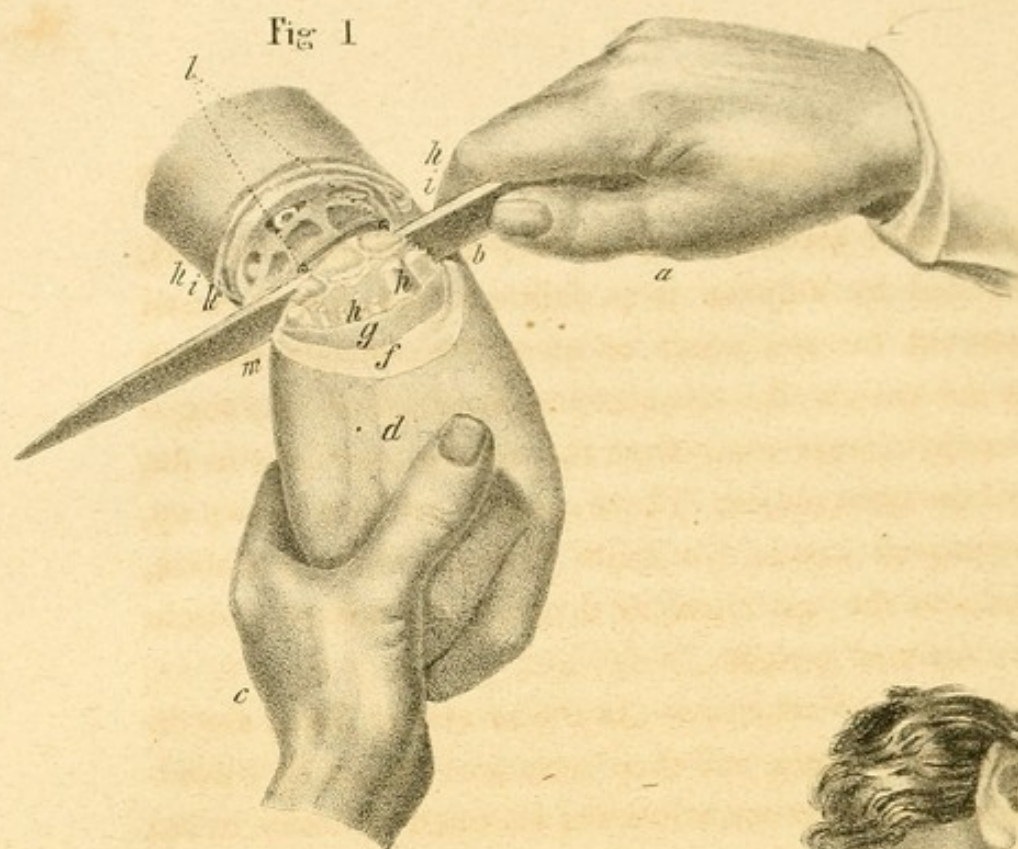
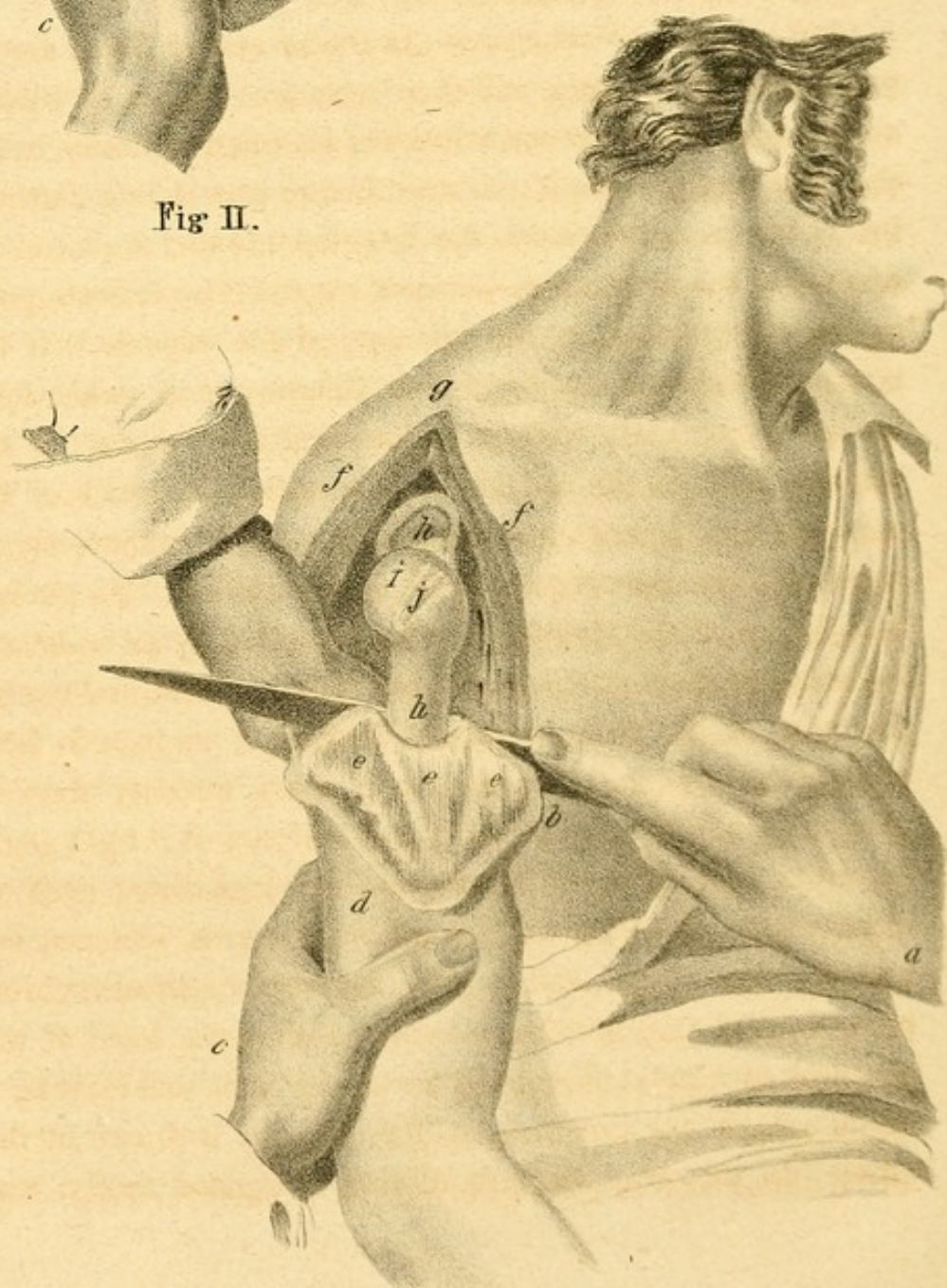


Fig II.



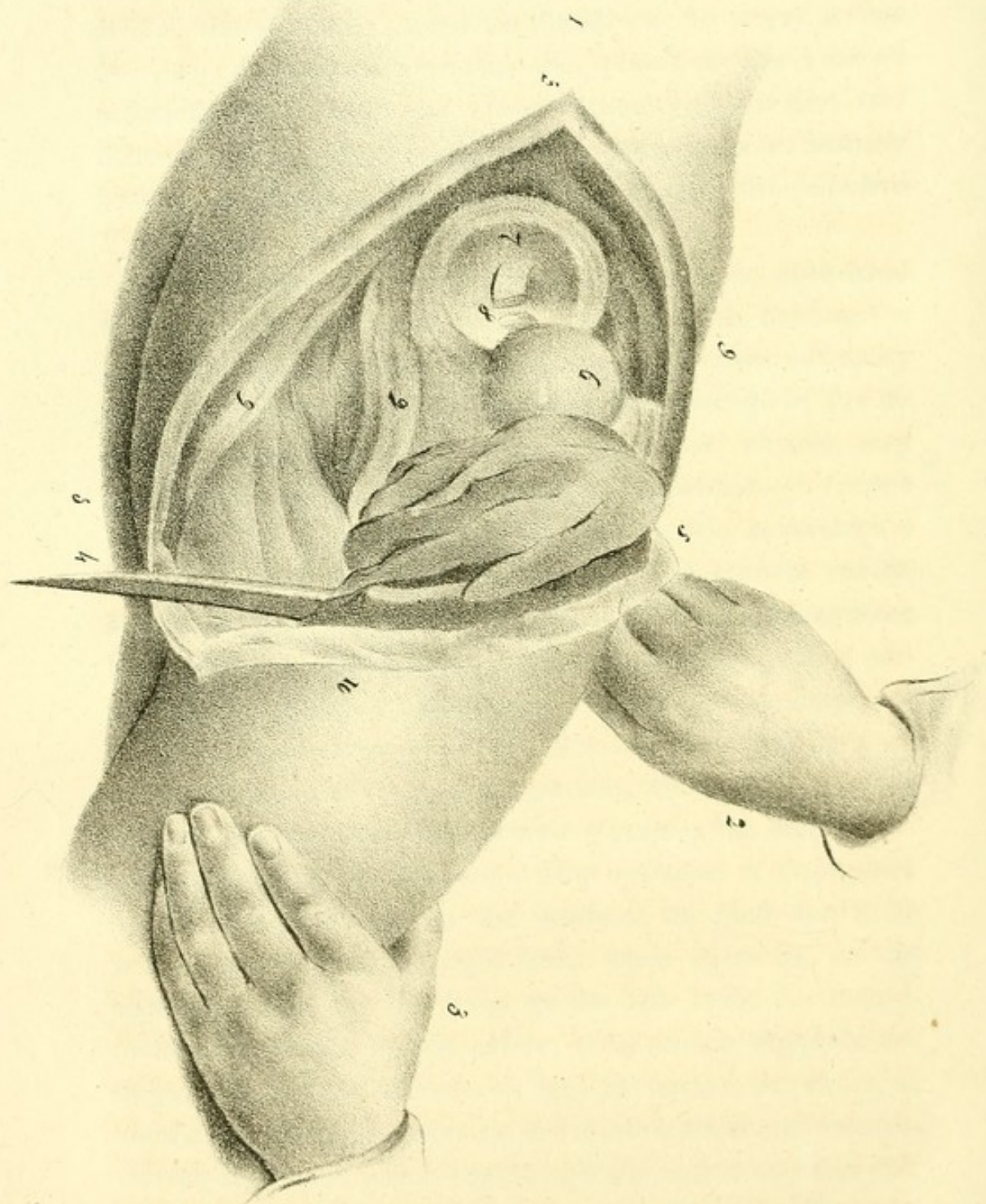
Amputation of the arm at the joint.—The *circular* method, recommended by Velpeau, is as follows: the skin is raised and dissected for the space of about two inches, without touching the vessels: the muscles are then divided by a single stroke, carried transversely from the coraco brachialis to the tendon of the teres major. These muscles are then drawn up, and the surgeon passes his knife through the articulation, and concludes the operation by dividing the triceps muscle and the cluster of vessels.

Oval method.—*First stage.*—As the muscular fibres are divided near their origin, and their retraction cannot be considerable, it is advantageous, when the shoulder is fleshy, to cut the skin, and to have it retracted before proceeding farther; but if this is not the case, the integuments and flesh can be divided at the same time.—*Second stage.*—The delicate point in the oval method, is the opening of the capsule. If the bistoury penetrates too deeply, the fibrous pouch yields, folds up like a wet cloth, and is rather bruised than cut: if the bistoury falls on the outside of the anatomical neck of the humerus, the ligamentous adhesions will be imperfectly divided, and the operation will be more difficult. To obviate this, the lips of the wound must be separated by an assistant; the surgeon then grasps the arm with one hand and causes the head of the bone to project, turning it on its axis from without inward: he then carries a sharp bistoury flatwise between it and the flesh, places this bistoury at a right angle on the capsule, at or a little beyond the anatomical neck of the humerus: he then divides all the tendons, commencing with the teres minor, and terminating with the subscapularis, being careful that nothing escapes: taking the head of the humerus as a point of support for the incision, and rotating it on its axis in one direction, as the bistoury is drawn in the other. In this way, the articulation is opened freely, and

the arm is easily luxated: the remnant of the capsule is now rendered tense, and is separated, the bistoury being carried forward, backward, and then inward, as if to shave the bone. In the *third* stage, the assistant, standing on the outside of the shoulder, places his thumb on the artery before the glenoid cavity, compresses this vessel on the kind of peduncle which unites the lower extremity of the first two incisions, while, with a small knife, or with the same bistoury hitherto used, the surgeon divides the base of the primitive V, and separates the limb from the trunk.

This operation is seen in plate xxxiii. fig. 2—*a*, right hand of the surgeon holding the knife, *b—c*, left hand, holding the arm, *d*, in such a manner as to separate the upper extremity as much as possible, so as to favour the passage of the instrument—*e, e, e*, triangular flap of the deltoid muscle, very much depressed, to show the base of the wound—*f, f*, edge of the division, which forms an acute angle superiorly, a little in front of the acromion process, *g—h*, glenoid cavity, fringed by the remains of a fibrous capsule—*i*, cartilaginous head of the humerus, surrounded near its neck, *j*, by a portion of the articular capsule—*k*, body of the humerus, exposed by the depression of the deltoid flap—*l*, right hand of an assistant placed behind the patient, who compresses the axillary vessels, while the operator separates the limb.

Amputation of the hip joint.—Flap operation of Dupuytren.—The surgeon stands on the inside of the limb, and if he is ambidexter, uses the right hand when operating on the right limb, and the left hand for the left limb: the integuments are drawn to the pelvis; the surgeon supports the thigh, and inclines it more or less in flexion, extension, or abduction: he then makes on the inside a semilunar incision, convex inferiorly, which begins near the antero superior iliac spine, and terminates at the tuberosity of the ischium: he



first divides the skin which is immediately drawn back ; he then cuts the muscles in the same direction, and thus has an inner flap four or five inches long ; this is raised ; the half of the capsule is now divided, at least very near the cotyloid cavity, as if it were intended to cut the head of the femur crosswise, without attempting to enter into the articulation : the limb is abducted and luxated ; the internal ligament is made tense and divided, and the knife is then passed on the outside of the head of the bone : the section of the articulation being thus finished, the external flap is made, and the operation is terminated.

Oval method.—The patient lies on the healthy side ; the surgeon, situated behind the haunch, makes first an oblique incision, which commences above the great trochanter, and should be carried backward, outward, and downward, below the ischium ; a similar one is made forward and inward : then with a second cut in each incision, the muscles are divided as deeply as possible : he cuts the articulation at its outer face, at the same time that the limb is abducted by an assistant, and passes through the articulation from without inward, as soon as the head of the femur is luxated. Finally, while a second assistant raises the two lips of the wound, the interosseous ligament is divided, as also the inner part of the capsule, and all the soft parts, which are separated on the inside by the first two incisions, or form the base of the V, of the triangle first circumscribed.

This operation is seen in plate xxxiv.—1, represents the haunch of the patient, who lies on the opposite side—2, the hand of the surgeon, holding the knife, 4, while the left hand, 3, supports the thigh, 10, which is to be separated from the trunk—5, 5, the superior angle and lips of the wound—6, the head of the femur, dislocated and detached from the cotyloid cavity, 7—8, the interarticular ligament divided—9, 9, 9, 9,

sections of the different muscles. An assistant holds the diseased haunch, and another takes charge of the leg.

Amputation of the thigh.—Having made the incision through the integuments, and dissected them back as far as may be thought necessary to cover the stump, you are to cut through the superficial set of muscles, and divide the deeper set of muscles, situated immediately round the bone, at least two inches higher than the spot where the incision was made: this will prevent the formation of a conical stump. The arteries which require to be tied are, the femoral, the profunda, the great anastomotic, and some articular twigs; and if the operation is performed high up, the profunda, the superficial muscular, some branches of the circumflex, of the obturator, and of the ischiatic arteries.

Amputation of the leg.—First divide the integuments which have two places of adhesion, viz., over the tibia and over the fibula: having separated these, and likewise the connecting cellular membrane, the skin is loosened to the extent of two inches, and this quantity will be sufficient to cover the stump. As soon as the skin has been separated in front and on the outside of the leg, the surgeon is to detach the skin from the calf for about an inch, and having reflected or drawn this portion out of the way, he places the edge of the knife close to the edge of the retracted or reflected skin, at the back of the limb, and cuts obliquely upward through the muscles of the calf, from the inner edge of the tibia quite across the fibula, supposing the operator to be on the outside of the right leg, and that this is the limb to be amputated. In making this last incision, it is essential to incline the edge of the knife obliquely upward; in this manner, the skin will be longer than the muscles, and the cure accelerated.

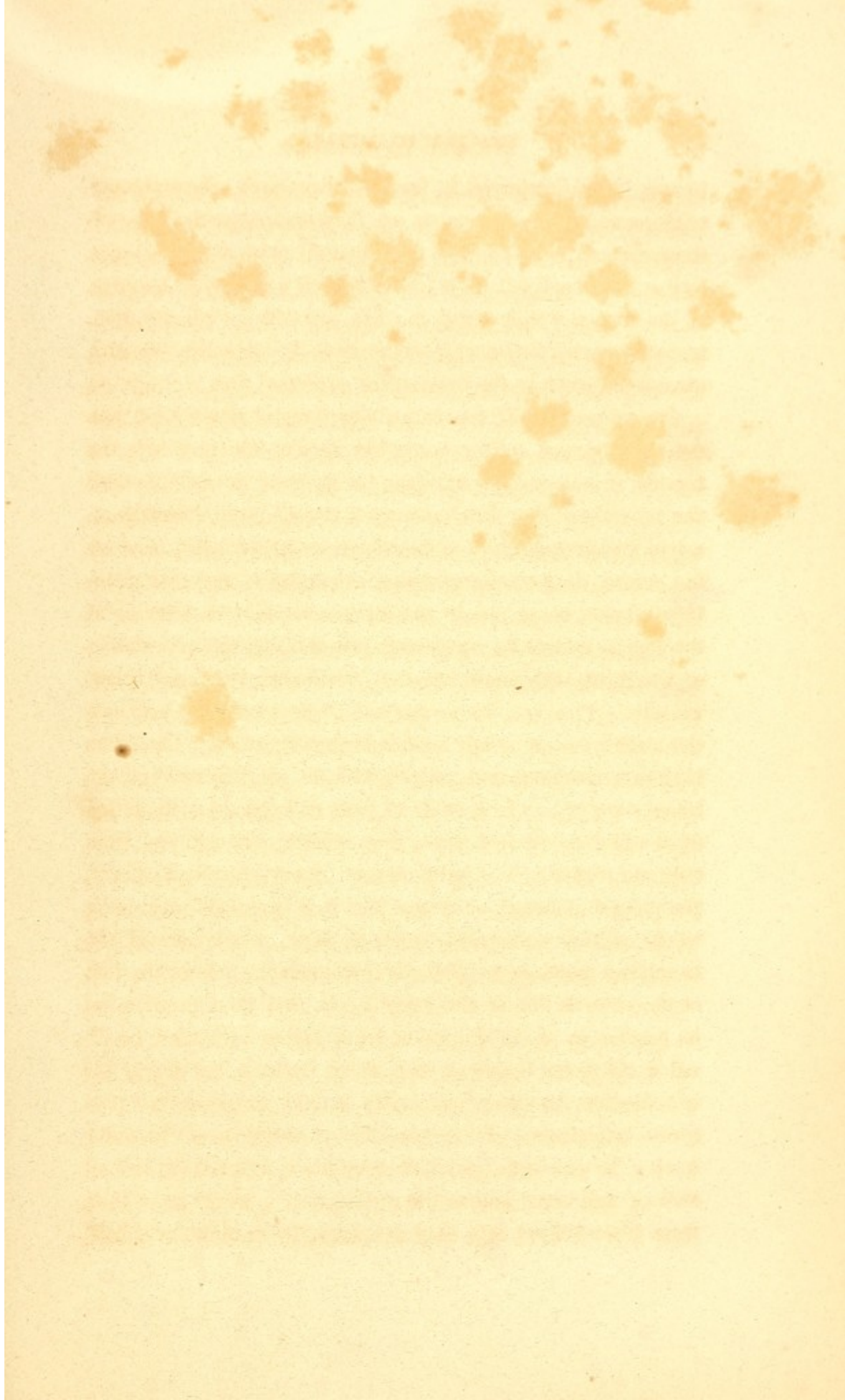
The flap formed of the integuments and muscles of the calf is then held back by an assistant, while the surgeon

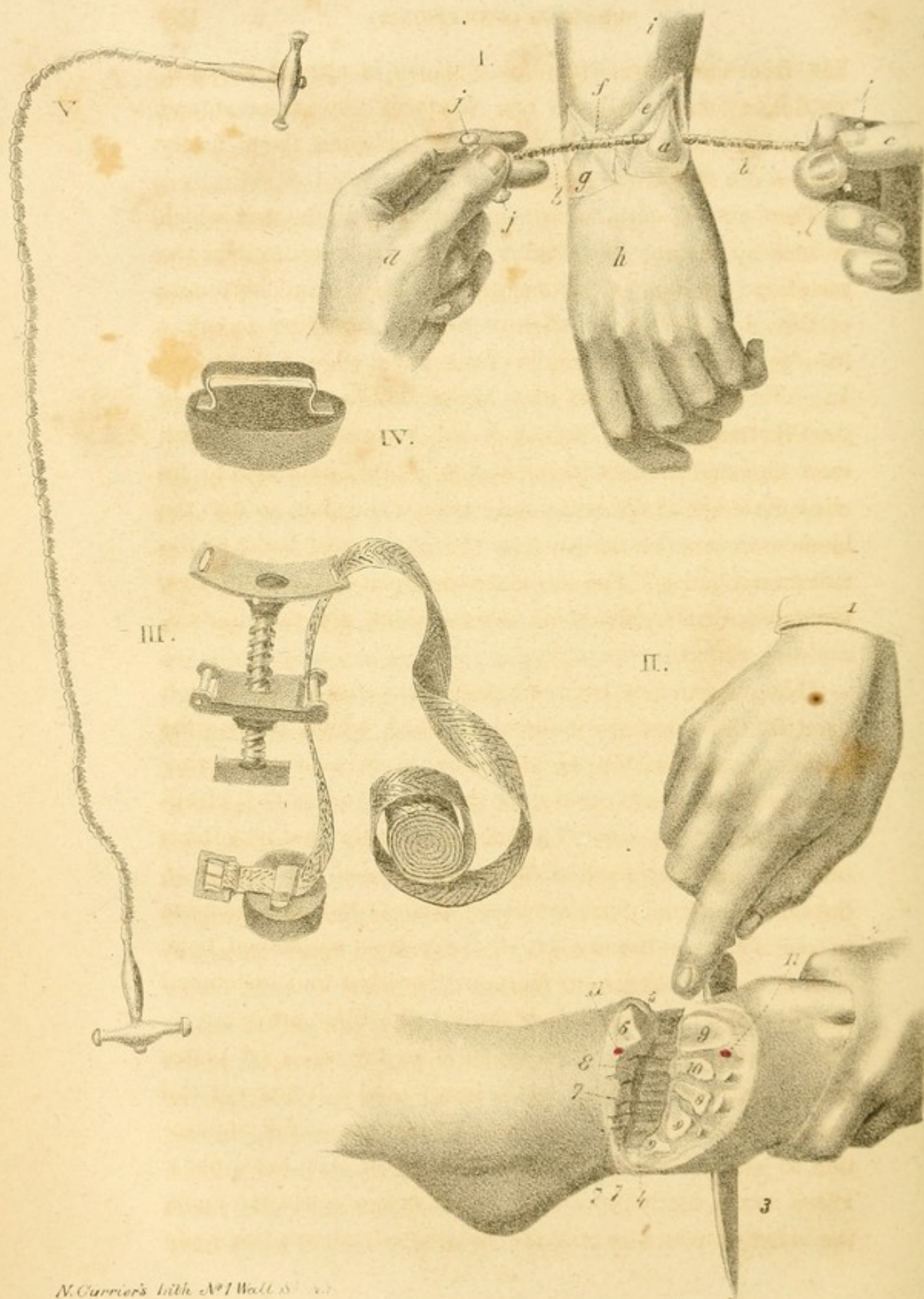
completes the division of the rest of the muscles, and that of the interosseous ligament, by means of the catling. The soft parts are now protected by the double split compress, introduced between the tibia and fibula, the bones are sawed, and the limb removed. The arteries which require to be tied, are the anterior tibial, found in front of the interosseous membrane, and between the extremities of the bones: the posterior tibial, situated more inwardly than the last among the fibres of the soleus muscle, and the peroneal artery: sometimes also the large muscular arteries require to be tied.

Amputation of the metatarsus.—Lisfranc's mode of performing this operation is as follows:—*First period.*—The patient sits on the table or bed; the operator uses a narrow and firm knife during the operation: if he be ambidexter, the rule is to commence at the outer edge of the foot; he consequently holds the knife with the right hand in operating on the right limb, and with the left hand in removing the left limb: if he is not ambidexter, he begins in this latter case at the inner side of the metatarsus. An assistant holds the lower part of the leg, and compresses the posterior tibial artery behind the internal malleolus, and the anterior tibial artery on the ankle, and at the same time retracts the skin from this latter. The surgeon glides his index finger from before backward, along the dorsal and external edge of the fifth metatarsal bone, and the inner and plantar face of the first, and finds the two extremities of the articular line; he then places the thumb and index finger of one hand on the tubercle of each of these bones; and takes hold of the dorsal face of the foot, in order to act more easily on the metatarsus. Holding a knife in his other hand, he makes a semilunar incision convex anteriorly, the extremities of which fall on the two tubercles indicated by the fingers: this incision should divide only the skin and subjacent cellular

tissue. The integuments being drawn back, the extensor tendons and other soft parts are then divided at the edge of the retracted skin, so that this second incision corresponds to the articular line. It is important, on arriving at the edge of the foot, not to descend too low towards its plantar face, lest at the termination of the operation, the necessary breadth cannot be given to the base of the principal flap.

Second period.—If the cuboido metatarsal articulation has not been opened by the same cut as that which divides the tendon, it is opened by carrying the point of the knife behind the tubercle of the fifth metatarsal bone, in the direction of a line which would fall obliquely, first on the head, then on the centre, then on the posterior extremity of the first metatarsal bone, being placed almost transversely on arriving at the fourth, inclined again forward on entering the articulation of the third, which is separated by carrying the knife transversely. The second metatarsal bone generally prevents the knife from going any farther in that direction. The knife is then withdrawn, and carried with its point upward on the inner edge of the foot, so as to pass through the articulation of the first metatarsal bone, from within outward, and from behind forward. The surgeon soon places it perpendicularly, the point downward, and turns the blade backward on coming to the second metatarsal bone, or to the inner side of the cuneiform mortise : he plunges it towards the sole of the foot at the summit line of the bony facets, and then pressing on its handle, so as to vibrate it from before backward, he divides the great ligament, termed by Lisfranc, the *key of the articulation* : he again withdraws it, and seeks for the posterior articulation of the second metatarsal bone : in order to this, he places the point horizontally across the superficial face of this bone, and as the articulation is never more than three lines behind, it is easy to open it, by cutting every half





line, from the central articulation, which is already exposed, until it is found. All the bony surfaces now separate, and the point of the knife being passed between them, easily divides the rest of the ligaments.

Third period.—It now remains only to form the flap, which is done by shaving the plantar face of the bones to near the metatarso phalangeal articulations. The digital extremity of this flap should be slightly rounded, in order to adapt itself to the curved semicircle of the dorsal edge of the stump. In order that the internal edge of the flap may not be thinner than the external, the handle of the knife should be much more elevated than its point, and it is important also to incline the edge of the knife early toward the skin, so that the blade may not be arrested by the phalangeal head of the metatarsal bones. The internal and external plantar arteries, the anterior tibial, and some others, which are unimportant, are divided in this operation.

This operation is seen in plate xxxv. fig. 2—1, the left hand of the surgeon—2, his right hand, which, holding the knife, grasps the top of the foot, 3, is about to terminate the flap which covers the articular surface—4, bleeding surface of the flap—5, prominence of the first cuneiform bone—6, articular facet of the same bone—7, 7, 7, facet of the last three cuneiform bones—8, base of the tarsal mortise to receive the extremity, 10, of the second metatarsal bone—9, 9, 9, 9, cartilaginous facets of the other four metatarsal bones—11, 11, extremities of the anterior tibial artery.

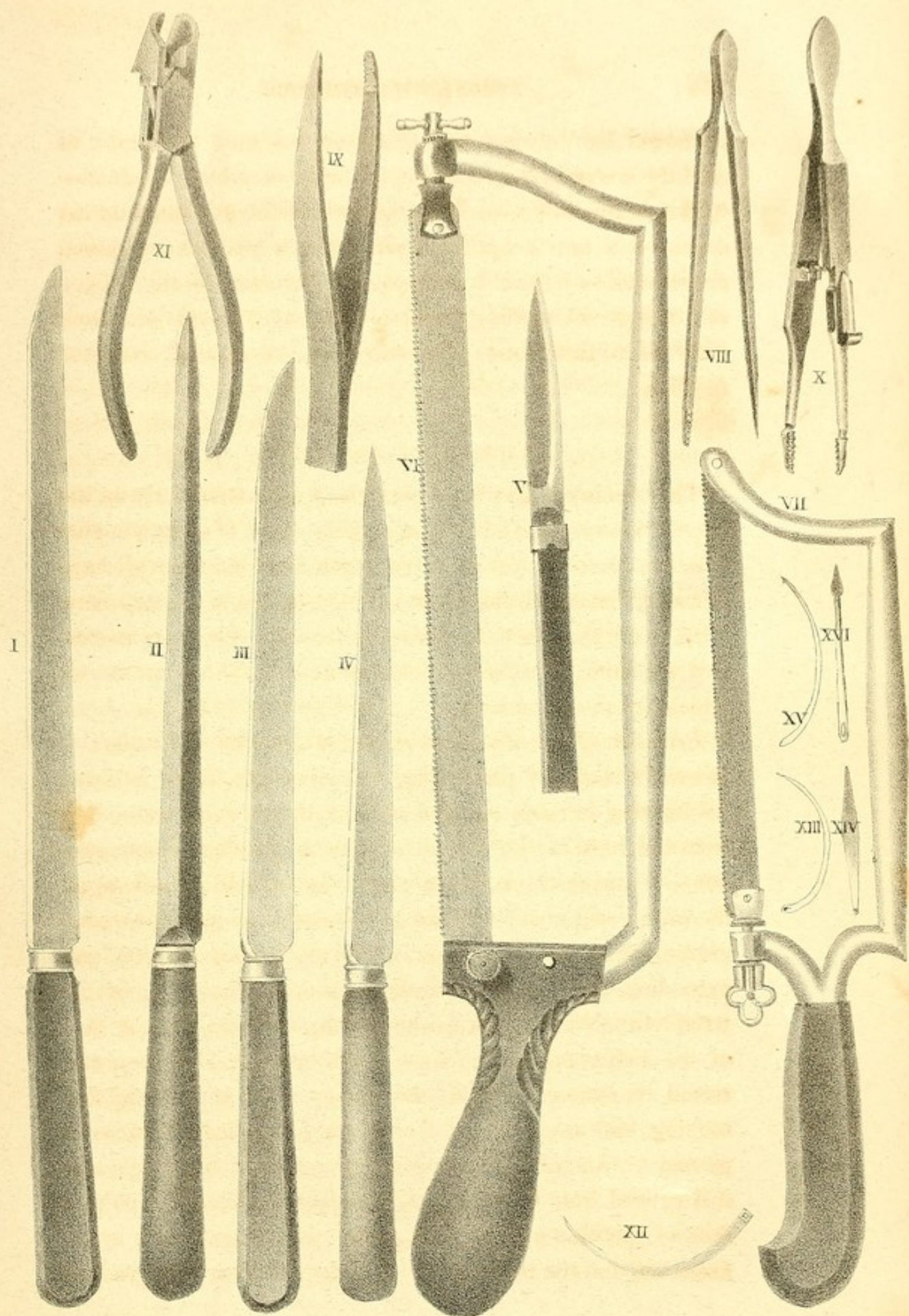
The instruments used in amputation are seen on plates xxxv. and xxxvi.—Plate xxxv. figs. 3 and 4, represent the parts of a tourniquet—fig. 5, is a chain-saw, the application of which is seen distinctly in fig. 1 of this same plate. Plate xxxvi. fig. 1, represents a common amputating knife, the edge of which is exactly straight—4, shows the knife

preferred by Velpeau, which, on approaching the point, is slightly convex—3, is a knife, the edge of which is blunt—2, is a catling—5, a bistoury, sometimes found in amputating cases—6, a newly-modified saw—7, a saw of the common construction—8 and 9, forceps—10, forceps for the torsion of arteries—11, cutting forceps—13 and 14, a side and front view of a new form of needle—15, 16 and 17, common needles.

EXCISION OF THE JOINTS.

This operation has been performed most frequently on the upper extremities, and although many cases of complete success are recorded, yet its advantages and disadvantages are so nicely balanced, that it is rejected by many practitioners. This is not the place, however, to discuss its relative merits, and we shall, therefore, proceed to describe those operations which are most common.

Resection of the carpal extremities of the ulna and radius.—Moreau's mode of performing this operation is as follows: An incision is made on each edge of the forearm, extending from the root of the thumb and from the last metacarpal bone, to two or three inches above the styloid processes of the radius and ulna: a transverse incision is now made, beginning at the carpal extremity of each lateral incision, and extending from eight to twelve lines on the back of the wrist: thus we have an L shaped flap on the posterior face of the radius and ulna: these flaps are now dissected and raised, commencing with the ulna; after separating, detaching, and isolating the tendons, a protecting compress is passed between the two bones, by means of a spatula, and it is carried from the interosseous space between the palmar face of the ulna and the soft parts. It is then taken by an assistant, and the two ends of it are drawn towards the radius,




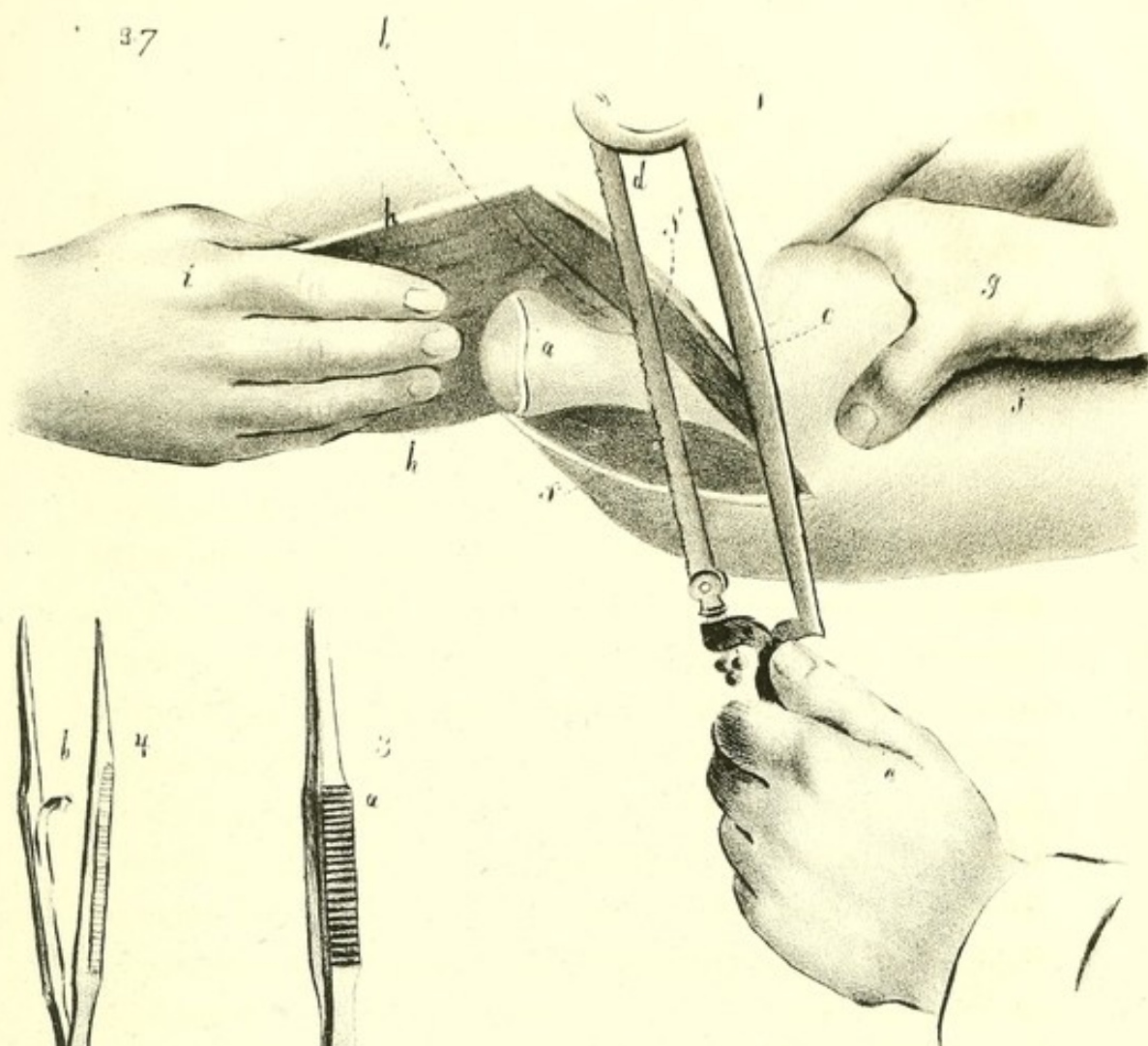
in order to protect the flesh in that direction. The surgeon now divides the bone with a saw, and detaches it from the carpus and radius with a bistoury. He then proceeds to dissect the second flap and the numerous tendons and the artery, and repeats on the radius what has been done on the ulna.

This operation is seen on plate xxxv. fig. 1. By means of the L shaped incision, the triangular flap, *e*, or *f*, is cut on the back of the limb, *i*. The contour of the ulna, *a*, being disengaged from the soft parts, we pass under it by means of a spatula, a curved probe, or a grooved director, the extremity of the saw, *b*, *b*. This saw is then moved by the hand of the surgeon, *c*, and that of the assistant, *d*, who hold its handles, *j*, *j*, while the hand of the patient, *h*, is carried outward and forward by another aid who supports it. By proceeding in the same manner, the head of the radius, *h*, is extirpated.

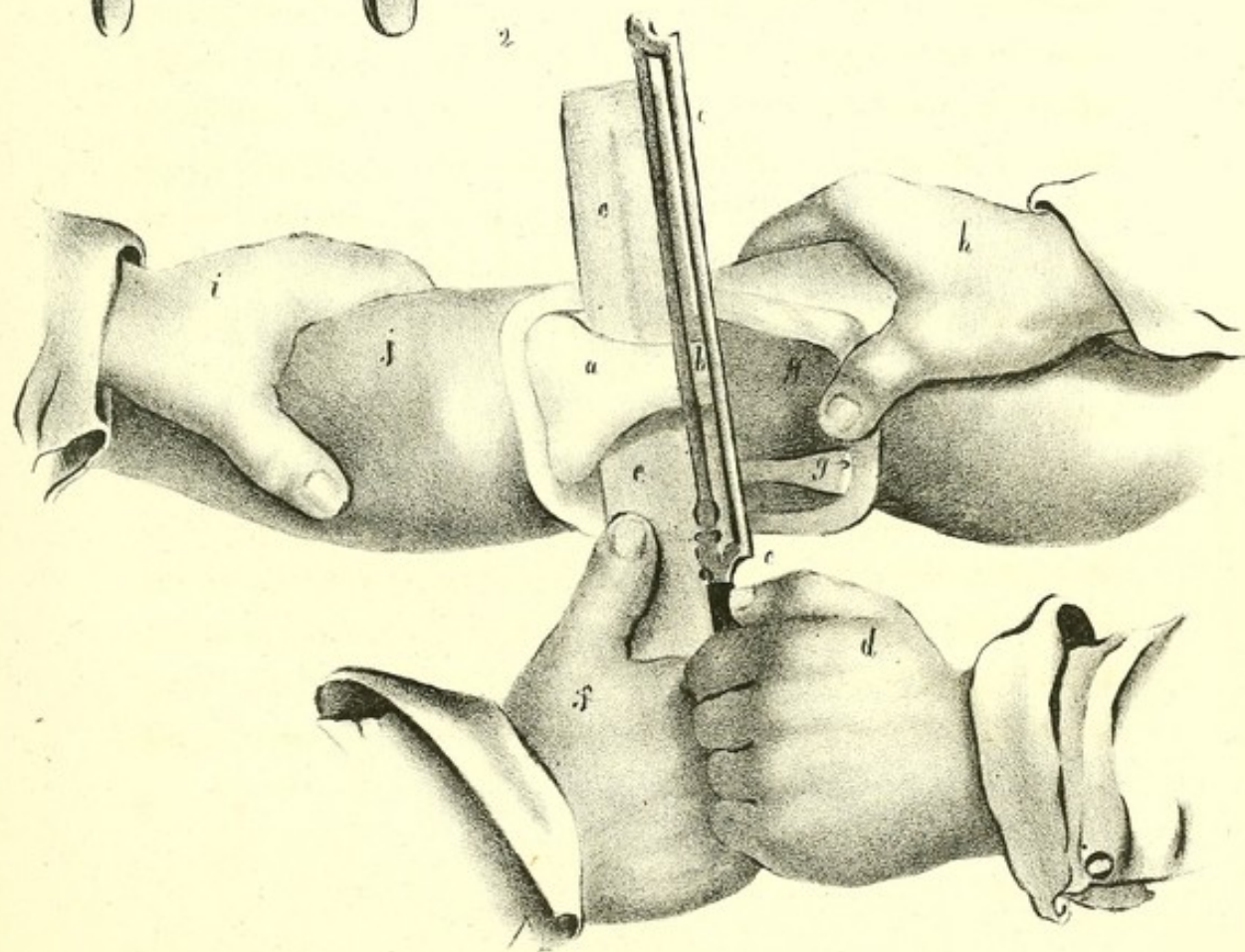
Resection of the elbow.—The patient lies on his belly, or at least on the healthy side. The humeral artery is compressed by an assistant, who also supports the soft parts of the arm, while the forearm is extended by another person. The surgeon, standing on the outside of the arm, makes an incision about two inches long on the outer edge of the humerus, commencing or terminating on the epicondyle, and extending upward, so as to separate the brachialis internus muscle from the outer part of the triceps. Another incision is then made on the inner edge of the arm, the lower extremity of which falls on the olecranon process, rather than on the epitrochlea, to avoid the ulnar nerve. These incisions are united by a third, which is transverse, and which divides the tendon of the triceps: the flap is dissected and raised: it is held by an assistant, and if the extremity of the bones of the forearm appears sound, the operation on the humerus is continued;

but if not, the lateral incisions are extended downward, and an inferior flap is formed, which resembles the first; as soon as the ulnar nerve is exposed, the bands which fix it between the epitrochlea and the olecranon process are separated, and then, while the forearm is extended, it is carried before the inner tuberosity of the humerus, as has been stated. After this, the operator draws forward the flesh which is undivided, and slightly flexes the limb; separates the fleshy fibres from the anterior face of the bone with the point of the bistoury; passes a thin piece of wood before the humerus, and saws the bone; takes hold of the upper extremity of the bony fragment which he wishes to remove, separates all the tissues from it, and divides the anterior, the lateral, and the posterior ligaments. If the ulna and radius are to be divided, he detaches, below the disease, the end of the brachialis internus muscle, and also that of the biceps, and terminates by dividing the bones as may be most convenient. In this case, it is better not to disarticulate the humerus, but to divide the radius and ulna. It is always easy to avoid the brachial artery, which is separated from the humerus by a thick muscle. After removing the bones, tying the vessels, if any require it, and cleaning and regulating the wound, the elbow is extended, the two flaps are brought together, and united by two or three stitches, and attached in the same manner by their edges to the anterior soft parts. Two pledgets of lint, some graduated compresses, a scultetus bandage, cushions, and two thin splints, keep the surfaces in contact, and the limb perfectly motionless.

This operation is displayed in plate xxxvii. fig. 2. The limb operated on is the left; the patient is placed on his belly. After making a quadrilateral flap, *g, g*, at the expense of the triceps muscle, a flap which is raised by the left hand, *h*, which at the same time supports the arm, the flesh is de-



2



tached anteriorly, so that a thin layer of pasteboard, or of wood, *e, e*, or even a compress, folded several double, may be passed between it and the bone: this is guided by the hand, *f*. The saw, *c*, is carried in such a manner by the hand, *d*, that its blade, *b*, falls almost perpendicularly on the body of the humerus, while the hand, *i*, acting on the forearm, *j*, favours its motions. In case it was necessary to remove the extremity of the radius and ulna, the lateral incisions must be extended downward, and a third made from *a* to *j*, to have two lower flaps instead of one; the bones of the forearm being exposed, they are sawed in the same manner as was the humerus.

Resection of the head of the humerus.—The diseases which require the performance of this operation, are the same as those for which the arm was formerly amputated at the joint. Velpeau's mode of performing it is seen in plate xxxvii. fig. 1. The surgeon forms a broad triangular flap, by making two incisions, four inches long, parallel to the fibres of the deltoid muscle, one on the anterior, the other on the posterior edge, which are then joined below the summit of the acromial process, by a transverse incision. This flap is raised by the hand of an aid, *i*, who stands behind. The surgeon takes hold of the diseased arm, *j*, with his left hand, *g*, divides the capsule and the tendons which strengthen it on the head of the bone, *a*, in the same manner as if the limb were to be amputated; the humerus is then dislocated, and the glenoid cavity, *b*, is exposed; the edges of the wound, *f, f*, are separated, or depressed: the surgeon now takes the saw, *c*, with his right hand, *e*, and the blade, *d*, is applied on the body of the bone, as low as the disease requires: it is then carried obliquely from below upward.

Resection of the knee joint.—As this joint resembles that of the elbow, Moreau thinks that the resection of one must be

made in the same manner as the other. He therefore begins by two lateral incisions, near the edges of the calf, the lower extremities of which incisions are united by dividing transversely the skin and the end of the triceps cruris below the patella, so as to penetrate to the articulation: he then separates the posterior face of the bone from the surrounding flesh: the quadrilateral flap, circumscribed by the first three incisions, is dissected and raised: the lateral ligaments are divided; a large knife is then carried on the posterior face of the femur, to separate the soft parts from it, taking care to avoid the popliteal vessels, and the bone is then sawed. If the bones of the leg are affected, the external incision may be carried to the head of the fibula; another is made on the crest of the tibia: thus two lower flaps are formed, an internal and an external, which are dissected and depressed. The posterior face of the tibia is separated from the vessels and nerves, and also from the head of the gastrocnemii muscles: and, finally, all the diseased parts are removed with a saw.

Resection of the tibio-tarsal articulation.—For this operation, Moreau recommends two incisions on each side of the leg, one extending up three or four inches from the summit of the malleolus; the other commencing at the same point, and directed transversely forward to the insertion of the peroneus brevis on the outside, or of the tibialis anticus on the inside: the longitudinal incisions should be made to the bone, and the others should penetrate only through the skin. The external flap is dissected, to disengage the fibula from its surrounding tendons, and this bone is then divided by means of a chisel, or chain-saw, and it is disarticulated from above downward, by dividing the fibrous fasciculi, which unite it to the tibia, astragalus, and os calcis. The tibia is separated from the soft parts in the same manner, and divided and disarticulated: if the astragalus is diseased, it must be partially

or entirely removed. After the operation, the foot should be brought near the lower extremity of the leg, and be kept in this position by adhesive straps and proper bandages.

TREPHINING.

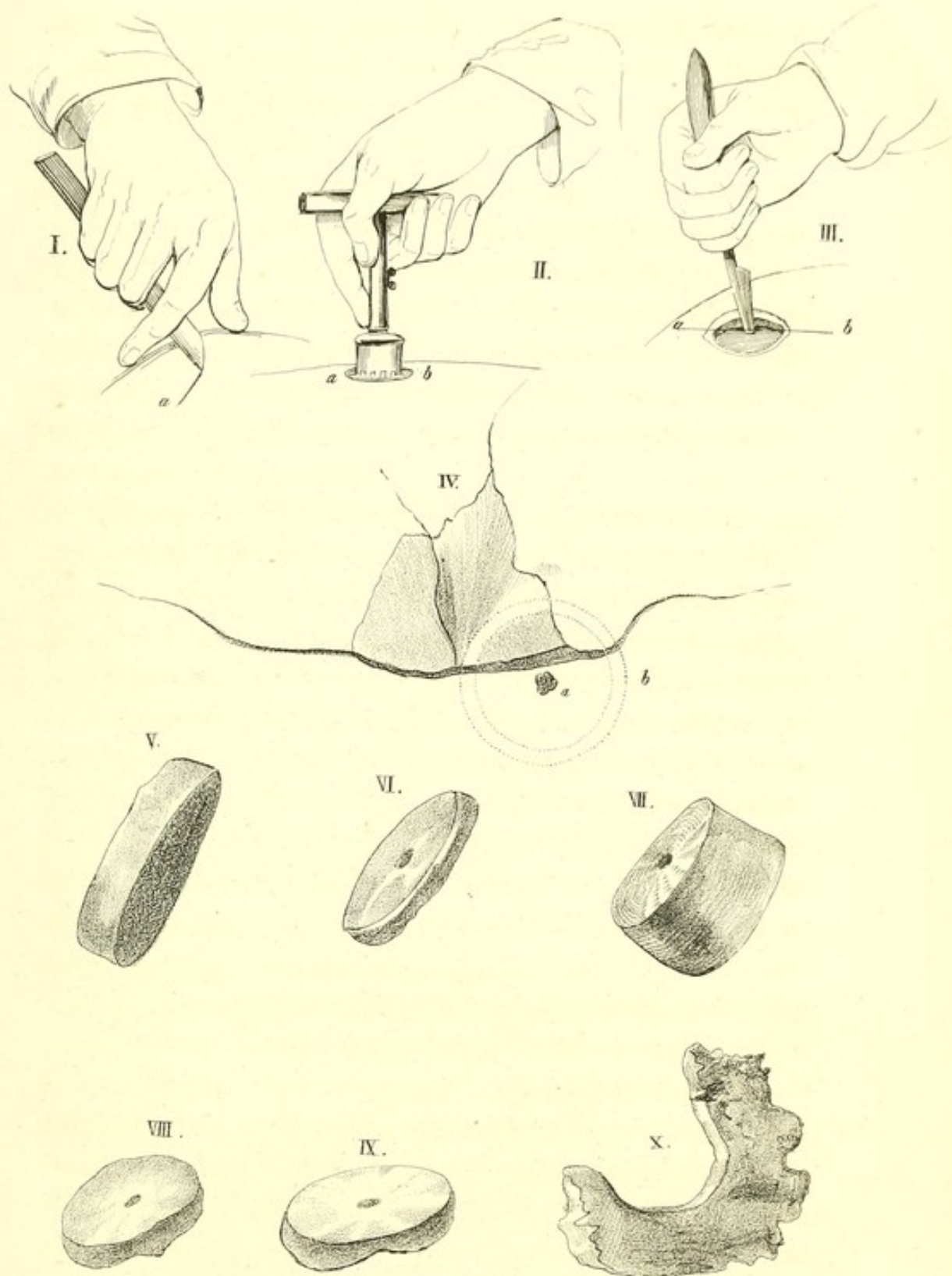
The operation of trephining is required in simple fractures, with depression, on symptoms of compression continuing after depletion; in compound fractures, with depression, unattended with symptoms of compression; when extravasations of blood exist between the skull and dura mater, and sometimes when it is probable that matter exists between the dura mater and cranium.

The instruments required for trephining, are, 1st, a scalpel, for dividing the integuments: 2d, an instrument termed a trephine, consisting of a simple cylindrical saw, with a handle placed transversely, as in a gimlet; from the centre of the circle which the teeth of the saw describe, projects a sharp little perforator, termed a centre-pin; the upper part of the centre-pin is made to screw in a corresponding hole at the inside of the top of the saw, and may be removed at pleasure: its use is to fix the trephine when it is first applied; that is, before the teeth of the instrument have made a sufficient circular groove, in which they can work steadily: 3d, an elevator.

In performing this operation, a crucial incision is to be made, and the integuments turned aside; next, we cut through the pericranium, and scrape it off: the trephine is then applied, taking care that the centre-pin is moved as soon as a circle is made, which in young persons, where the bone is sawed through easily, will be requisite very early, and being careful also that the dura mater is not injured. At first, the surgeon may saw boldly and quickly, occasionally withdrawing the trephine, and wiping the bony matter from its teeth:

on coming to the diploe, blood issues from the wound: after this, it is necessary to proceed with the utmost caution: it must be remembered, however, that in many parts of the skull, which are liable to be trephined, no diploe exists. After the skull is perforated, the elevator should be introduced, and the depressed bone can thus be raised to its natural situation. The operation should never be performed in the course of the longitudinal sinus, or on the line that extends from just above the nose, along the top of the head, to the tuberosity of the occiput; nor over the frontal sinuses; nor over the anterior inferior angle of the parietal bone, just above the zygoma, on account of the great artery of the dura mater; nor behind the ears, in the posterior inferior angle of the same bone, lest the great lateral sinus be laid open. Fractured portions of these bones may be raised by the elevator.

The operation of trephining is seen in plate xxxviii. Fig. 1 shows the incision for the division of the integuments—*a*, the first incision. Fig. 2 shows the mode of holding the trephine, the thumb supporting it on one side, the last three fingers on the other, while the index finger is extended along the shaft of the instrument to the top of the crown; by moving the hand alternately in pronation and supination, the instrument describes a semicircle. Fig. 3 shows the application of the elevator. Fig. 4 shows the spot where the trephine is applied, in a case of complex fracture: the pyramid of the crown is placed on the highest part of the fracture, *a*. Fig. 5, shows a portion of bone removed by the trephine, in which the outer and inner table is seen, and also the diploe. Figs. 6 and 7 are two trephined portions of bone, which vary much in thickness. Figs. 8 and 9 are two, in which the inner face is uneven. Fig. 10 represents a piece of bone which has exfoliated after the operation of trephining.



TRACHEOTOMY.

For this operation, as performed by Velpeau, the following instruments are necessary : a straight or convex bistoury, a probe-pointed bistoury, one or more canulas, arranged with ribands and ready for use, delicate forceps, several ligatures and hooks, or sounds curved in a hook-form, and the different articles of dressing. The patient lies on his back, his head thrown back, but only to a moderate degree : if carried backward too far, the respiration is more difficult. The surgeon stands on the right side, so as to cut from above downward ; he grasps the larynx with the left hand, while he divides the tissues, holding the bistoury in his right hand.

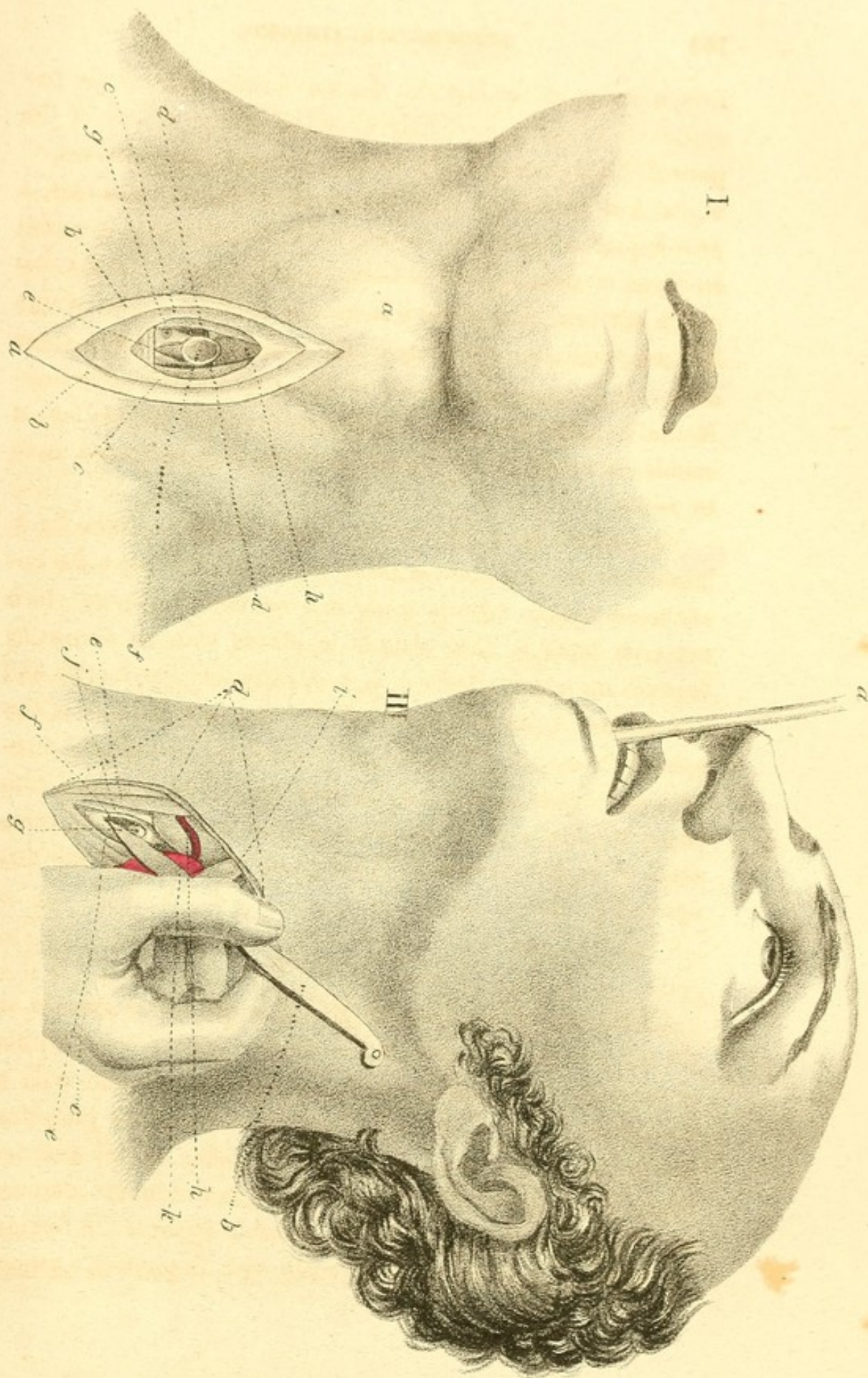
Operation.—In order that the operation may be performed well, the incision of the soft parts should extend from the transverse fold of the thyroid body, that is, from near the cricoid cartilage, to the sternum. After cutting the integuments and the aponeurosis, the vessels present themselves, and these are tied as they are opened ; the veins of the thyroid plexus, which must also be tied, when they cannot be avoided, and the middle inferior thyroid artery when it exists, and which would be dangerous to wound. Having come to the trachea, if the venous blood runs freely, and if the case is not urgent, the operation may be suspended until the hemorrhage ceases ; but if the operation admits of no delay, these vessels must be tied, and the trachea opened. Although the straight bistoury, held like a writing pen, is sufficient for this opening, which should include, at least, the fourth, fifth, and sixth, if not the third, or the seventh ring, yet some practitioners prefer the probe-pointed bistoury. This part of the operation being finished, the course now to be pursued, depends upon whether a foreign body is to be extracted from the trachea, or whether it is intended to relieve suffocation arising

from a lesion of the larynx. In the former case, if the foreign body is not immediately expelled by the efforts of the patient, but is seen at the wound, the operator removes it: when, however, it remains immoveably near the bronchia, a proper pair of forceps is carefully introduced, and it is seized by them if possible: it is best, however, not to make too much exertion, as numerous cases are recorded where foreign bodies, which the surgeon could not discover, have come away of themselves, and been found among the dressings. If the surgeon intends to establish artificial respiration, a canula is immediately placed in the wound, and fixed there by ribands.

The operation of tracheotomy is seen in plate xxxix. fig. 1. The head of the patient is thrown back moderately: the lips of the wound are separated to show the different layers which must be divided. The canula is placed with its concavity forward and downward—*a, a, a, a*, represent the angles and lips of the divided integuments—*b, b*, superficial layer of the aponeurosis—*c, c*, its deep layer—*d, d*, sterno hyoidei muscles—*e*, inferior rings of the trachea—*f*, canula, provided with two small rings—*g*, one of the largest of the infra hyoid veins divided—*h*, portion of the thyroid gland exposed, and crowded upward by the canula.

ŒSOPHAGOTOMY.

Operation.—The patient is placed in the same manner as for tracheotomy, except that the face must be inclined a little to the right. The surgeon stands on the left, and with a straight bistoury divides the integuments and the platysma muscle for an extent of two or three inches on the anterior edge of the sterno mastoideus muscle, between the sternum and the larynx, and as nearly as possible opposite the foreign body, which must be felt previously with Dupuytren's probe-



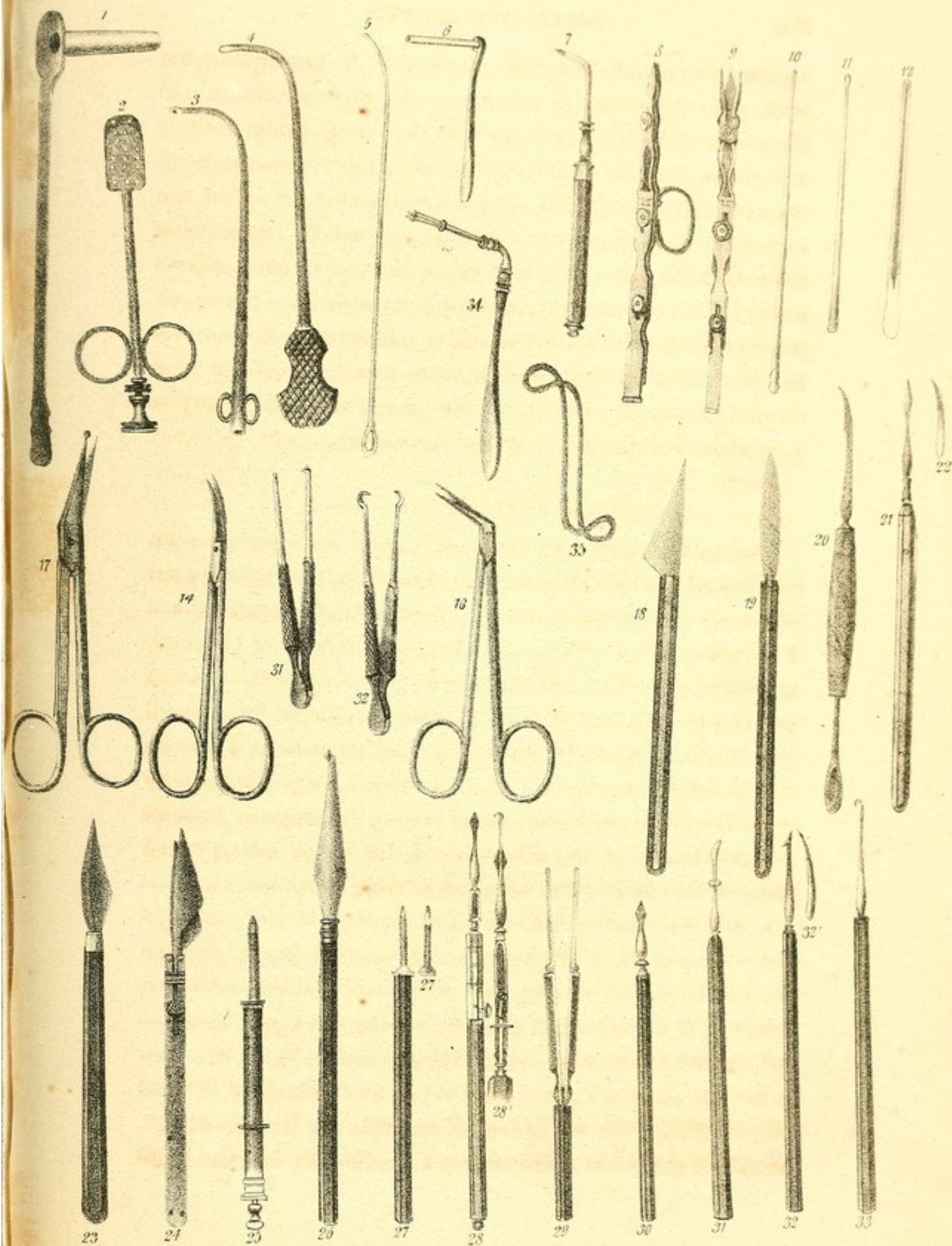pointed sound, or with some other instrument: the sterno mastoid muscle is then pushed outward, and the omo hyoideus and sterno hyoideus are exposed: these also are separated: the surgeon now tears with the beak of a director, or divides carefully with a bistoury, the fibro cellular layers which are more deeply situated, in the same manner as if he wished to tie the primitive carotid artery: he raises the thyroid body, and pushes it inward and forward, continues with the same precautions till he comes to the groove, which exists laterally between the œsophagus and trachea; finds there the inferior laryngeal nerve, and introduces into the mouth an arrow-headed sound, if he intends to use it; causes its beak to project through the œsophageal tube at the base of the wound; seizes it and fixes it with the thumb and left index finger: an aid pushes its stylet, and the surgeon carries the point of his bistoury on the grooved concavity of this blade, and immediately makes in the œsophagus an incision proportional to the size of the body to be extracted. When no conductor is employed, the canal must first be opened by a small puncture, through which a grooved director is passed into it, and the wound is then enlarged with a bistoury, or with blunt scissors. If the foreign substance does not present itself at the opening, forceps, or some appropriate instrument is introduced to find it. The wound may be united by the first intention. If any large branch of an artery be opened, it must be tied. A gum-elastic œsophageal tube should now be introduced through the nostrils or mouth into the stomach, and kept there till the third or fourth day, so that the food and drinks given to the patient during this time, may not hinder the union of the wound in the œsophagus, and may not be diffused in the infra hyoid region.

The operation of œsophagotomy is shown in plate xxxix. fig. 2. The first incision has been made, and the bistoury, *b*,

begins to penetrate into the esophagus, *f*, favoured by the beak, *g*, of the sound, *a*, which is previously introduced into the mouth and the pharynx, to near the foreign body, in order to push out the œsophagus, and to disengage it from the large vessels which surround it—*a*, angles and anterior lip of the wound of the integuments—*e*, *e*, sterno mastoid muscle on the outside, sterno hyoid and sterno thyroid on the inside—*h*, the left lobe of the thyroid gland, crossed by a branch of the superior thyroid artery—*i*, omo hyoideus muscle, discovering, in front of the thumb of the right hand, *c*, or of the back of the bistoury, a portion, *k*, of the primitive carotid artery—*j*, trachea, situated on the left of the œsophagus.

OPERATIONS ON THE EYE.

The instruments used for operating on the eye are seen on plate xl. Fig. 1 shows a canula used for the cauterization of the unguiform bone, in operating for fistula lachrymalis—2, a variety of the palette of Cabanis—3, canula of Gensoul, for cauterizing the nasal canal from below upward—4, a full catheter of the same author—5, another catheter, less curved and less convenient—6, a protective canula, used in cauterizing the unguiform bone—7, Pellier's punch for perforating the unguiform bone, or the lacrymal sac—8, cystitome of Desault—9, cystitome of Bataille—10, 11, 12, stylet and grooved director for clearing the nasal canal from above downward—13, mandrin, the head of which is elastic and cleft, to withdraw the canula of Dupuytren—14, small scissors, concave on the edges, for cutting the pupil—15, Pellier's elevator, made of silver wire, and used for raising the upper eyelid—16, curved scissors for cutting the pupil—17, Maunoir's scissors—18, cataract knife of Beer—19, cataract knife of Wenzel—20, crooked knife of Tenon, as modified by Boyer—21, 22, front and side view of Dupuytren's needle—23, cataract knife



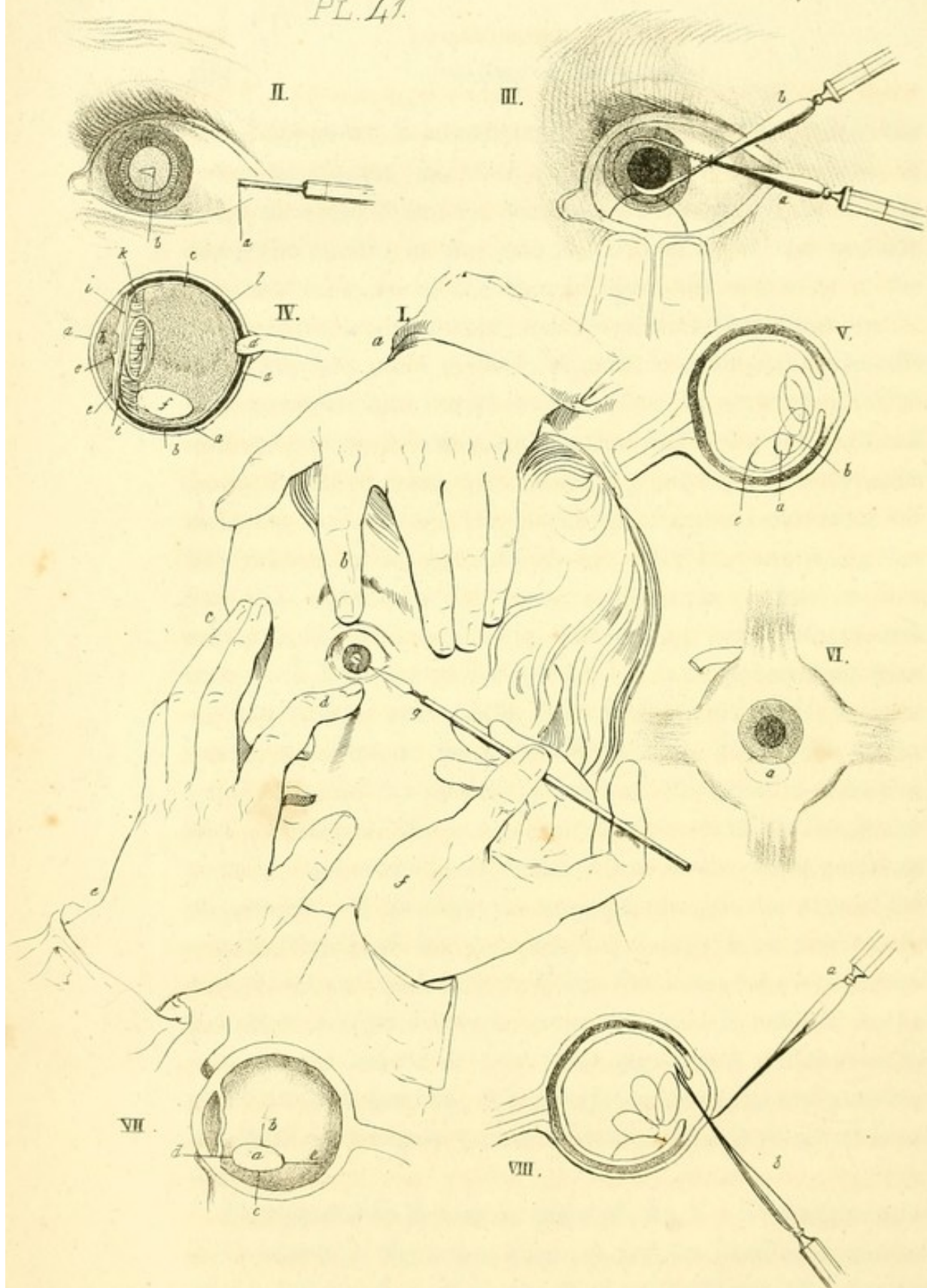
of Richter—24, double knife of Jœger—25, cataract knife of La Faye—26, knife of Siegerist—27, 27', side and front view of Hey's needle—28, raphi ankistron of Emden, open—28', the same, closed—29, hooked forceps of Reisenger, a side view, and consequently the points are not seen—30, Beer's straight needle, or blade to cut the posterior capsule, after the lens has been removed—31, an instrument for cutting up the crystalline lens by the operation of keratonyxis; the prominence on the staff prevents the instrument from penetrating into the eye too deeply—32, 32', front and side view of the hooked needle of Beer—33, Walther's hook—34, wolf's-tooth forceps for the cornea—35, triple-hooked forceps.

CATARACT.

Operation by depression.—The patient either lies in bed, as is recommended by Dupuytren, (in which position the depressed lens is less likely to resume its natural place,) or he sits in a high chair; the surgeon sits or stands as is most convenient for him; in the former case his motions are more steady, his elbow being supported; in the latter, he is more at ease. An assistant passes his hand round the patient's head, and raises the upper eyelid. If any instrument be required to raise the eye, the elevator of Pellier should be used; but this is generally unnecessary. If the patient be in bed, the surgeon stands on the right in operating on the left eye, and on the left for the right eye; the sound eye being covered with some lint, the surgeon depresses the lower lid with the index finger corresponding to the diseased side, and with the other hand grasps the cataract needle like a writing pen, and carries its point perpendicularly on the sclerotica, a line and a half or two lines from the transparent cornea, and a little below its trans-

verse diameter ; it is introduced in this part just where the retina terminates, and the ciliary ligament commences, in order to avoid them, as also the ciliary artery, as it goes along the middle of the external convexity of the eyeball, between the sclerotic and choroid coat : the concavity of the needle is turned downward, and one of its cutting edges toward the cornea, the other toward the orbit, in order that the needle may penetrate into the globe of the eye, by separating rather than by cutting it : the handle is first inclined downward and forward ; the surgeon then raises it gradually in the opposite direction, as it enters the posterior chamber, and rests his two fingers on the patient's cheek. Before penetrating farther, the instrument is turned on its axis, so that its concavity looks backward, and that it may pass without risk under and then before the crystalline lens, penetrating from without inward, and a little from before backward, without touching the iris or the lenticular capsule, if possible, to the pupil, and into the anterior chamber : the point is then carried circularly on the anterior circumference of the lenticular capsule ; the envelope of which is thus destroyed as perfectly as possible. This done, the surgeon plunges the axis of the needle directly in the cataract, and brings it by a vibratory motion outward and backward into the base of the eye, below the pupil and the vitreous humor, where it is held for half a minute : the needle is now disengaged, and withdrawn by slight rotatory motions : it is brought to the horizontal position, its convexity is again turned upward, and it is removed from the eye.

This operation is seen in plate xli. fig. 1. The upper eyelid is raised by the index finger, *b*, and the head is supported by the left hand, *a*, of an assistant. The lower eyelid is depressed by the index finger, *d*, of the left hand, *c*, of the surgeon, who rests the other fingers, *e*, on the root of the nose,



while with his right hand, *f*, he holds the needle, *g*. The latter is just at the position, when, having come to the pupil, and having torn its anterior capsule circularly, its concavity is placed on the crystalline lens, to bring it by a vibratory motion, downward, backward, and outward. [XLI. 3.]

Fig. 5 on this plate (a perpendicular section of the eye) shows the place of the depressed lens in the vitreous body. The lens has moved from its normal place, which is the upper oval, through the next two ovals; its anterior face, *a*, looks downward and forward; its upper end, *b*, looks upward and forward, and its lower extremity, *c*, looks downward and backward. Fig. 6 gives a front view of the place of the depressed lens in the eye; the lens is marked by the dotted line, *a*, and appears oval from its oblique direction downward. Fig. 7 shows the reclination of the lens in the vitreous body, seen by a perpendicular section of the eye. The lens *a*, has its anterior face, *b*, turned upward; the posterior, *c*, downward, its lower edge, *d*, forward, and its upper, *e*, backward.

Hyalonyxis.—The object of this operation, proposed by Bowen, is to penetrate into the vitreous body from behind forward, and from without inward, then to open the posterior sheath of the capsule, and to bring down the crystalline lens without touching its anterior envelop. This operation is seen in figs. 2 and 4. Fig. 4 shows the position of the cataract in the eye—*a, a, a*, the sclerotica and cornea—*b*, choroid coat—*c*, retina—*d*, optic nerve, as it enters the eye—*e*, iris and lower edge of the pupil—*f*, place occupied by the lens after the operation—*g*, space for the normal position of the lens—*h*, anterior chamber of the eye—*i*, posterior chamber, which is so narrow that no instrument can be passed between the lens and the iris without wounding the latter or the ciliary processes—*k*, ciliary processes—*l*, vitreous body.—

Fig. 2. In this figure, Bowen's needle is introduced three lines behind the cornea, and one line below its transverse diameter. Being passed at *a*, through the sclerotica, and between the ciliary processes and the lens, it is carried at *b*, through the anterior wall of the capsule, and through the pupil (dilated previously by applying Belladonna) into the anterior chamber of the eye. The convex face of the needle looks forward, and the eye is turned toward the nose.

Keratonyxis with reclination of the lens.—[XLI. 8.] The needle, *a*, is passed into the anterior chamber of the eye, through the lower or external part of the cornea, and comes to the pupil: the concavity of the instrument is now turned downward; the capsule is opened; the crystalline lens is detached; its upper edge is hooked, depressed, and turned over, and at the same time pushed below the pupil into the vitreous body; the course of the lens and its reclination is shown in the figure by the dotted ovals. If possible, however, it is better to break the lens into small pieces.

By Extraction.—The patient and assistants being placed as for depressing the lens, the surgeon presses down the lower lid with the index finger, which rests at the same time on the caruncula lacrymalis: in order to keep the globe of the eye firmly to the inside, the cataract knife is taken with his other hand, and its point is carried half a line or a line before the sclerotica, his little finger resting on the temple: he passes it into the anterior chamber perpendicularly to the axis of the cornea, a little above its transverse diameter: he now inclines the handle of the knife backward, the point of which, without this precaution, would wound the iris; he then carries it horizontally, but firmly, to the opposite point of the cornea, which is again pierced, but from within outward: he now advances it in this line, but without pressing on its blade: the knife should be carried directly forward,

until the lower semicircle of the cornea is divided, as near as possible to the sclerotic coat; that is, at a line or a line and a half from the great circumference of the iris. As the least pressure on the ball of the eye would be dangerous, when this section is completed, the assistant drops the eyelid, and the patient closes the eye for a moment. The operator now introduces the curved needle with its convexity under the flap of the cornea, and turning the point toward the forepart of the capsule, moves it upward and downward, and laterally from side to side, making a sort of crucial incision, and dividing the crystalline capsule freely. Now, if the cataract has not come of itself into the anterior chamber, it is brought outward by gentle pressure. The operator places the left index finger against the lower part of the eye: he then with his right hand, places the handle of the cataract knife, or the back of the curette of David, on the upper lid, in order to press the globe slightly to and fro. The lens soon passes through the pupil, and its edge appears at the wound of the cornea. It is removed with the curette, the needle, or the point of the knife, and the operation is terminated. If the opaque flaps of the capsule are large enough to endanger the success of the operation, they should be extracted with forceps. All other fragments should be removed in the same manner, if the spatula or curette are insufficient. Those, however, which remain in the anterior chamber should be left to themselves, unless they are very large.

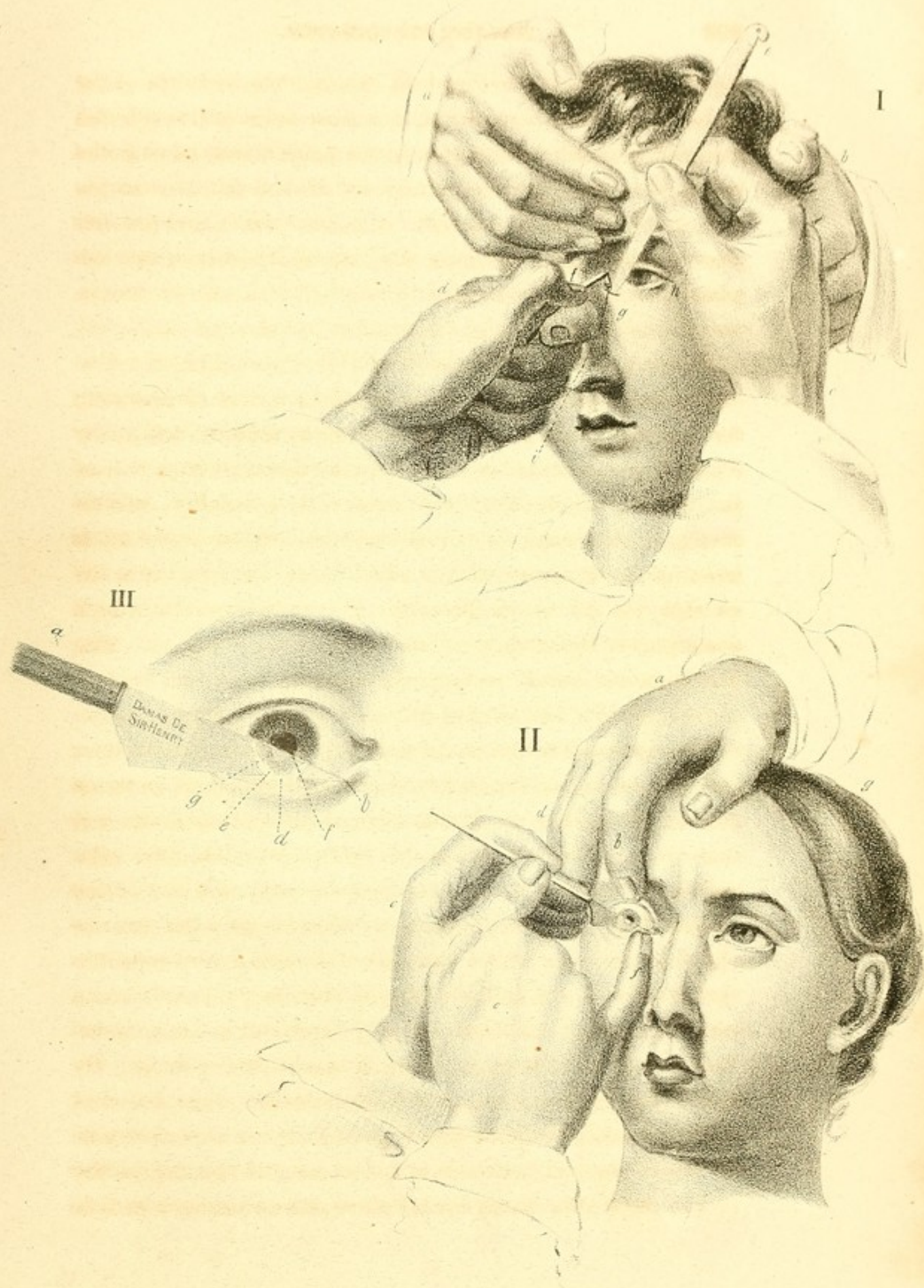
This operation is seen in plate xlii. fig. 2. The plate represents the operation just as the section of the cornea is terminated.—*a*, the right hand of an assistant, who raises with his index finger, *b*, the upper eyelid, while the other fingers rest on the temple—*c*, the left hand of the surgeon, holding the cataract knife, like a pen, and directing it a little from above downward, while the little finger of the right

hand, *e*, depresses the lower eyelid, and supports the globe of the eye. The instrument, *d*, passes entirely through the anterior chamber. The edge of its point, *g*, on leaving the eye and coming to its great angle, glides on the edge of the nail, *f*, which serves as a point of support for it, and protects the surrounding tissues until the flap of the cornea is completed.

ARTIFICIAL PUPIL.

Velpeau remarks, that there are three modes of operating for artificial pupil, an operation which is required either by opacity in the cornea, or by the contraction or obliteration of the natural pupil. Of these three modes, the first is *corectomia*, or *iridiotomy*, in which the iris is incised: the 2d is *iridectomy*, or *corectomia*, in which a piece of the iris is excised: the 3d is *iriodialysis*, or *coredialysis*, in which some part of the circumference of the iris is detached. The operation preferred by Velpeau, however, is a combination of the first two, and is as follows:—

Operation.—The knife used, [XLII. 3.] is a little longer and narrower than Wenzel's; it cuts on both edges as far as four lines from the point, and from thence to the handle it is dull: it is held like a pen, and is pushed, like any other cataract knife, through the cornea, from the temporal side of the orbit a little obliquely backward. On reaching the anterior chamber, the point of the knife is to be carried very carefully through the iris into the posterior chamber, returned again into the anterior chamber, passing through the same membrane, three or four lines distant from the first incision. By continuing to push it on, until it pierces the cornea a second time, it is easy to divide that kind of bridge which covers its anterior face, and to detach one extremity of this flap of the iris entirely, after changing the other into as narrow a pedicle



as is desirable. We thus have a division equivalent to a loss of substance. The morsel of membrane which is divided, soon contracts, and is finally lost in the aqueous humour. When the above operation is performed skilfully, the piece can be excised entirely. In fact, if the instrument acts equally upon the two attached points of the band which is to be divided, until the section of one is completed, the other may be detached merely by pushing forward the ceratome a little, and inclining its edge toward the cornea.

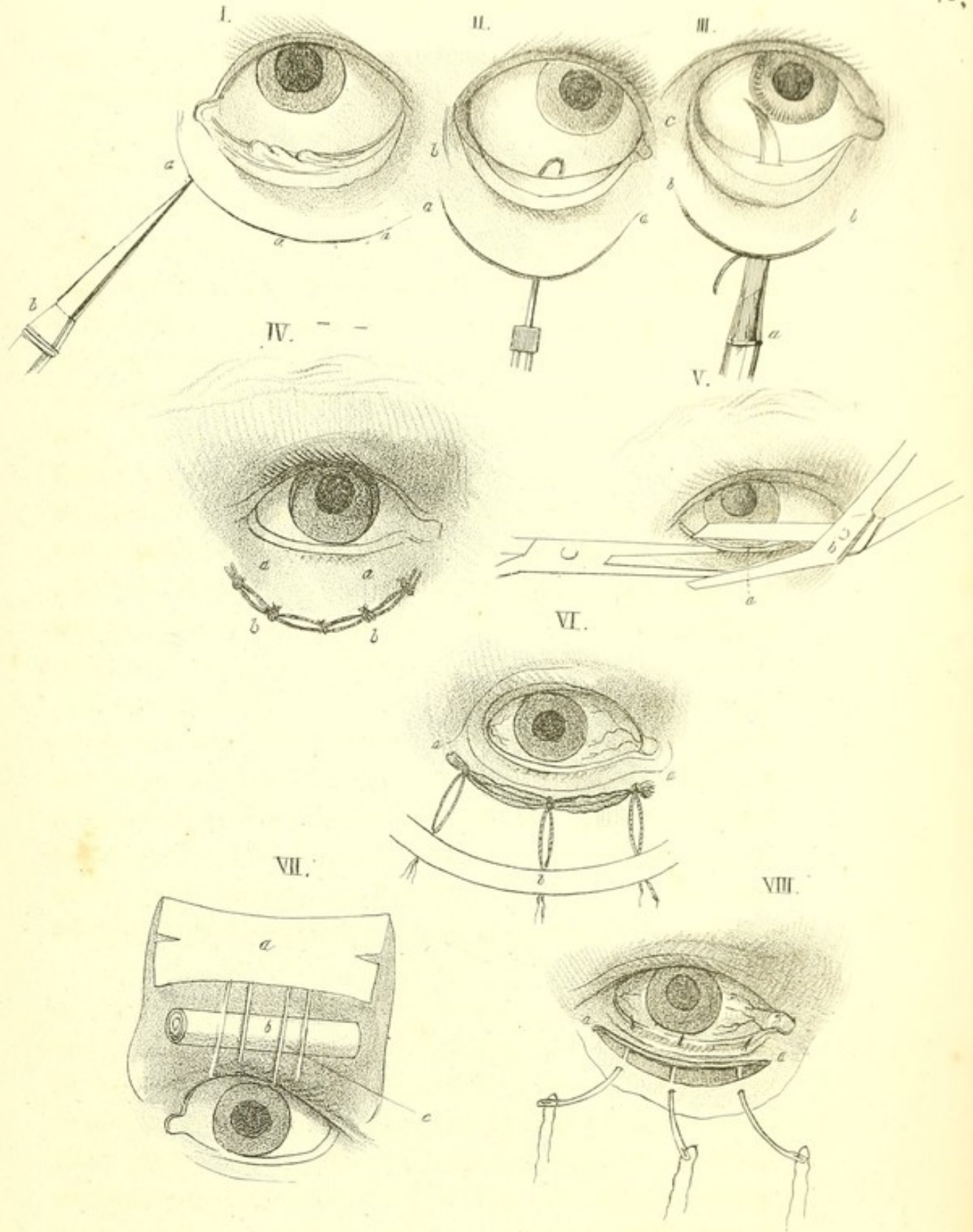
In plate xlii. fig. 3, we see the knife, *a*, carried as for cataract, through the cornea twice : when its point arrives at *b*, the flap, *e*, of the iris is completely detached. The back of the knife, *g*, is seen only because the natural pupil, *f*, of the eye is preserved. In withdrawing the knife from *c* to *a*, we avoid cutting the point, *d*, of the flap of the cornea, which is still attached to the sclerotica.


FISTULA LACHRYMALIS.

By this term we understand all obstructions of the lachrymal passage, preventing the natural flow of the tears and mucus from the eyes to the nose. Numerous methods have been proposed for removing this complaint : these are classed by Velpeau under five different varieties. In the first, threads, tents, or some foreign body is passed through the natural opening : in the second, the lesion is removed by mechanical dilators, introduced through the accidental opening : in the third, a metallic canula is left in the nasal canal : in the fourth, the disease is treated by means of the cautery : and in the fifth, an artificial passage is formed for the tears. After stating these different operations, Velpeau remarks, that whatever method may be preferred, the opening of the sac and the exploration of the canal, is nearly the same in all. In order to reach the canal, an assistant draws the eye-

lids toward the temple; and the surgeon then feels for the anterior lip of the lachrymal groove, with the index finger corresponding to the diseased side, and presses out gently any gluy matter that may be in it. He then takes a straight, firm and narrow bistoury with the other hand, and passes the point of it behind the nail of the directing finger, and pushes it obliquely inward, backward, and downward into the sac: the handle of the instrument is then raised toward the eyebrow, in order that it may descend perpendicularly into the nasal canal: the surgeon then takes a drill with its canula, or a grooved sound or stylet, and carries its extremity on the back or anterior face of the bistoury, which thus serves as a director for the former. When the canal is not cauterized, the operator holds the catheter or sound like a writing pen, and introduces it to the distance of one inch, its concavity being turned downward and outward: the end is then raised a little, in order that the lip of the instrument may be engaged under the inferior spongy bone, and glide on the wall of the nose: it is then withdrawn gently forward, to within six or eight lines of the nasal opening: its concavity is gradually turned upward and outward: the surgeon now, by a vibratory motion, attempts to introduce the beak of the instrument into the orifice of the nasal canal, and then passes it without difficulty to the angle of the eye, or even into the lacrymal sac.

In plate xlii. fig. 1, the second period of the operation is seen. The surgeon with his right hand, *a*, withdraws the bistoury, *e*, from the wound, *g*, while with the left hand, *d*, he presses down the canula, *i*, with the aid of the mandrin, *f*. An assistant, standing behind, holds the external angle of the eyelids, *h*, with the left hand *b*, and supports the patient's forehead with the right, *a*. The canula ought to penetrate as the bistoury is withdrawn, and it should glide on the back





or the posterior face, rather than on the anterior face of the cutting instrument.

ECTROPIUM.

Ectropium, or eversion of the lids, is caused by ulceration of their edges, and by cicatrices and contractions of the skin of the lids, which tend to evert them. It may be removed by cutting from the affected eyelid a triangular V shaped flap, the base of which corresponds to the eyelids. The two sides of the wound are then united by suture.

Dieffenbach's operation for the relief of this disease is seen in plate xliii. fig. 1.—*a, a, a*, show the place of a semilunar incision in the skin of the eyelid, which is made with the straight knife, *b*. In figure 3, the double-edged knife, *a*, is carried from the wound, *b, b*, through the conjunctiva, and the latter is divided in the direction of the external wound. In figure 2, a hook is carried through the wound, *a, a*, to the inner face of the conjunctiva, and this divided portion is drawn through the external wound and removed. In figure 4, the two edges of the external wound and of the conjunctiva are united by five stitches, and the eyelid, *a, a*, appears again in its natural place.

ENTROPIUM.

Entropium, or inversion of the eyelids, is produced by ulceration of the tarsi, the cicatrices formed by the healing of lippitudinous ulcers, which change the shape of the lids, so that the eyelashes are turned inward, and irritate the conjunctiva and the whole organs.

The operativa for the relief of this complaint is seen in plate xliii. In fig. 5, the inverted eyelid is taken up in a fold, *a*, with forceps, and divided with the scissors of Richter, *b*. Fig. 8, shows the elliptical wound, *a, a*, formed by this di-

vision, in which three needles are inserted. In fig. 6, we see the wound, *a, a*, united by three stitches, and the ends of the stitches are attached on the cheek by a strip of adhesive plaster, *b*.

TRICHIASIS.

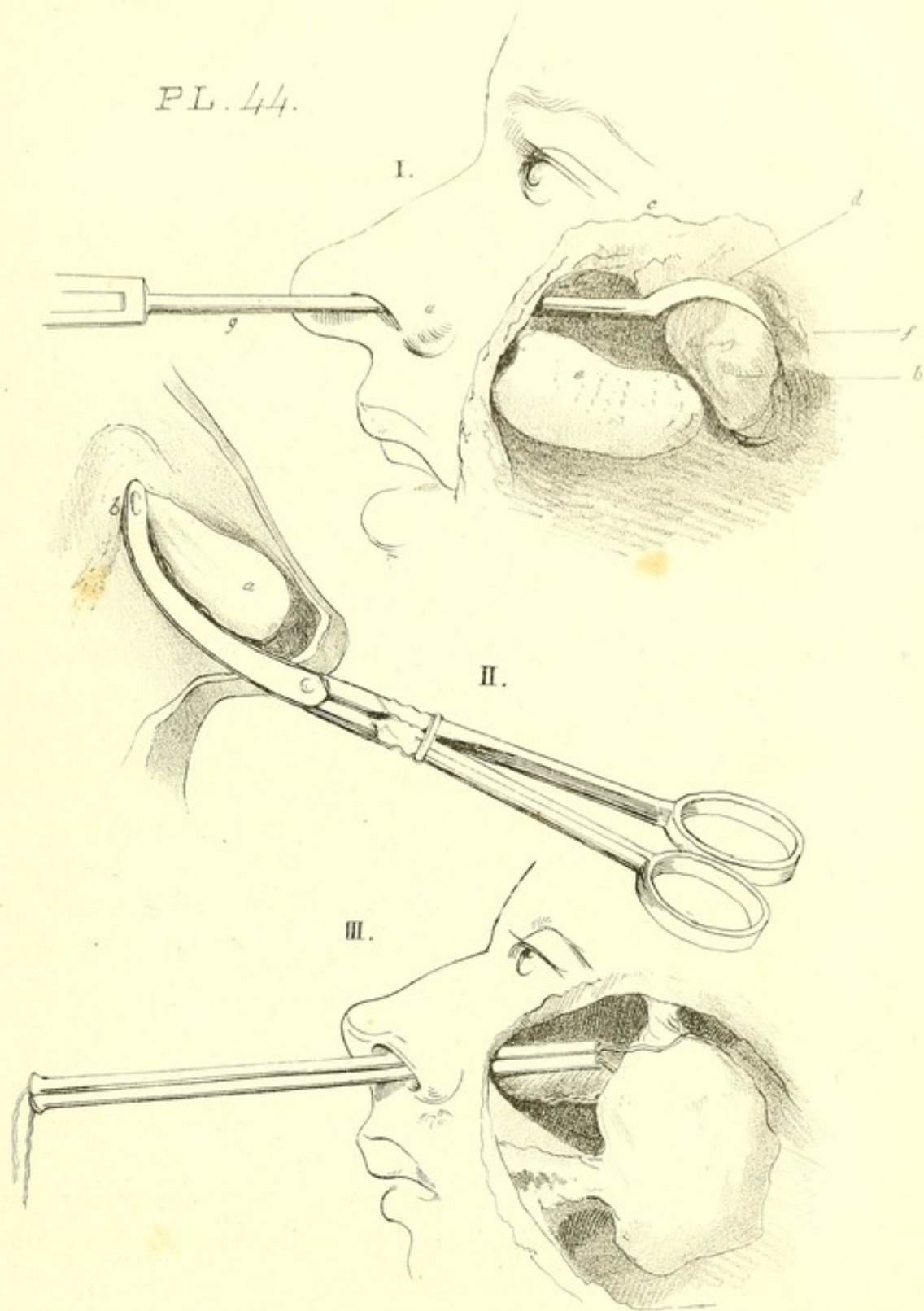
Trichiasis is that state of the eyelashes in which they become altered in growth, and turned inward on the globe of the eye, irritating the conjunctiva at every motion.

Different modes of treatment have been pursued for this complaint. Sometimes the eyelashes are plucked out; sometimes the edge of the eyelid is cut off. Plate xliii., fig. 7, shows Köhler's operation for this complaint. Two threads, *c*, are introduced by means of a needle through the eyelid, one quarter of a line from the inner and outer angle of the eye, and two lines behind the tarsus. These threads are passed over a cylinder, *b*, situated in the depression, below the supraorbital ridge, and are attached by means of adhesive plaster to the forehead.

NASAL POLYPI.

Nasal polypi may be removed by various modes; by cauterization with a hot iron; or with styptics, and among the latter, the sulphate of zinc has been used with great success—by extraction with polypus forceps, by excision, and by the ligature.

A polypus is extracted in the following manner:—Introduce into the nostril a probe in a direction between the superior and inferior turbinated bones, to ascertain the exact situation of the peduncle. The polypus forceps (which have the inside of their points roughened, to prevent them from slipping) are then passed into the nose, the probe serving as a guide: the forceps grasps the peduncle, and with a twisting



motion, the polypus is torn from its attachments and removed. This operation is seen in plate xliv. fig. 2, in which *a* represents a polypus, the anterior extremity of which is attached by its base, *b*, to the inferior turbinated bone, and to which the forceps are seen applied.

The excision of a polypus with a crooked knife, (after J. Bell's method,) is seen in the same plate, fig. 1.—*a*, marks the limit between the cartilage of the nose and the bony opening of the nose—*b*, a depression existing on the prominence of the vomer, when it is not pressed out by a polypus—*c*, the superior turbinated bone, to which the polypus was attached—*d*, the remains of a polypus, which filled the whole cavity of the nose, the rest of which has been removed by the knife—*e*, the direction of the inferior turbinated bone—*f*, a larger and entire polypus, which fills the posterior cavity of the nares—*g*, the direction of the knife.

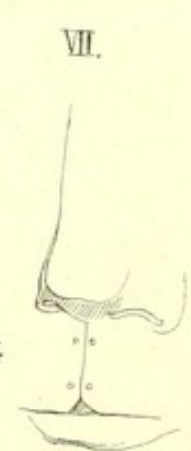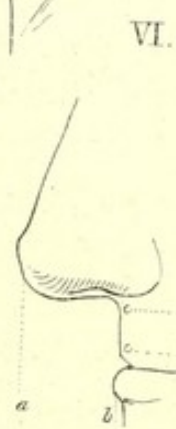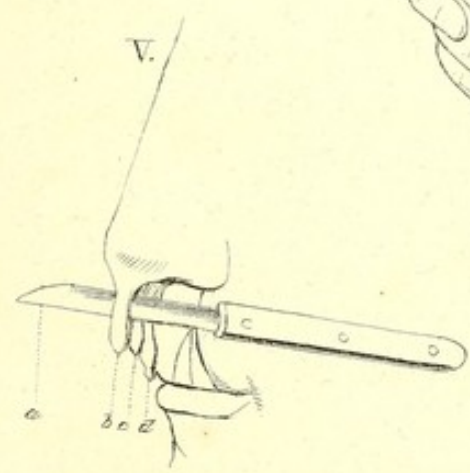
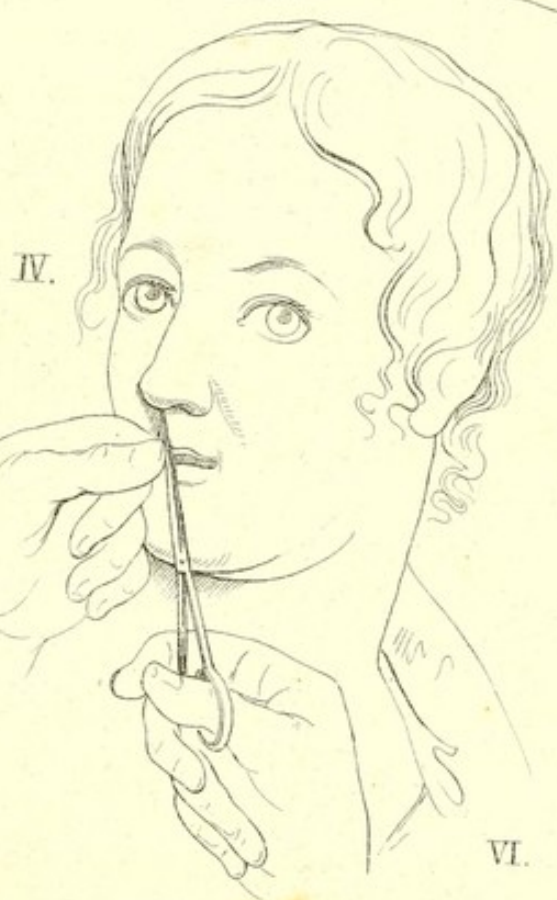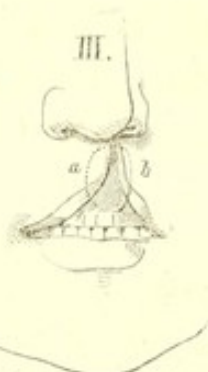
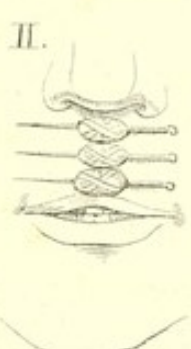
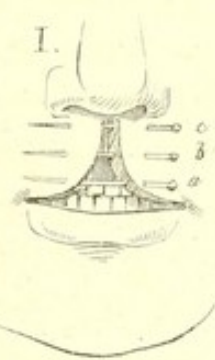The removal of a polypus by ligature is shown in fig. 3 of this plate. A ligature, inserted in a double canula, is first passed into the cavity of the nostrils, and to the posterior nares, where it is seized with a hook and brought into the mouth: when there, the ring and middle fingers are introduced into the mouth; the ligature is seized and passed over the body of the polypus, as is seen in fig. 3. It is then drawn tightly around the roots of the diseased portion, which is thus strangulated and sloughs off.

HARELIP.

In operating for the removal of harelip, the simple principle is to make raw the two edges of the fissured part, bring the two sides evenly together, and keep the two lips of the division in perfect contact, until they have become united. The mode of performing this operation is as follows:—

Single Harelip.—The patient is placed on a chair, in a

good light, and his head is held firmly by an assistant, in such a manner as to enable him to compress the external maxillary arteries, beneath and in front of the masseters, and to push forward the cheeks toward the median line, and hold the lip, if necessary, while the surgeon makes his incision. The surgeon sits or stands before the patient, and seizing the left inferior angle of the division with a hook, as is done by Roux, or with forceps, or simply with the forefinger and thumb of the left hand, he cuts off the rounded portion of the fissure, and even a little of the sound parts, making a fresh, straight, and regular wound; for this incision, either scissors or a scalpel may be used. The lip itself is now stretched by the thumb and forefinger, and a portion of it which corresponds to the edge just incised, should be removed. In order to make the suture, the operator again seizes the right angle of the fissure with his left index finger and thumb: with his right hand, he carries the point of the first needle on the skin, half a line above, and three lines on the outside of, the rosy edge of the lip: he introduces the needle a little obliquely from below upward, from before backward, and from the skin toward the mouth, so that it may pass through the tissues, and emerge at the union of the two anterior thirds with the posterior third of the bleeding part; the direction of the needle is then changed: it is pushed through the other lip from behind forward, from above downward, and from within outward, so that it may enter and leave the part as nearly on a level as possible, describing in its course a slight curve, the convexity of which looks a little backward and upward. Its two extremities are then included in a noose of thread prepared for this purpose, which allows the assistant to stretch properly the whole extent of the lip, while the surgeon fixes the second needle, and even the third, if three needles are thought necessary. The twisted suture,



[XXVIII. 3.] is now applied in the mode stated on page 118, after which, the harelip bandage, [II. 2.] described on page 20, may be applied.

The operation for single harelip is seen in plate xlv. Fig. 4 shows the removal of a portion of the fissure with scissors, the surgeon holding it with the thumb and forefinger—in fig. 1, we see three harelip pins introduced through the two sides of the wound—in fig. 2, the edges of the wound are brought together, and the twisted suture is applied—in fig. 3, *a*, *b*, show the arched-formed wound, which is made in lieu of a straight wound, when the lip at the fissured part is very short.

Double harelip.—In the double harelip, if the palatine arch be not defective, two different states may occur. Sometimes the two fissures are separated only by a narrow and slightly prominent tubercle, which must be removed by the incisions; sometimes, on the contrary, this tubercle is too large to be destroyed without inconvenience: in this case, whether it descends or not to the edge of the lips, it is better to pare off its two sides, at the same time with the external edges of the double division, which it separates. In the first case, all the needles are passed through it: in the second, the highest, or the two highest only, are introduced, in order to fix it in the middle of the suture. This method of performing the operation, which is the oldest, is also the most prompt and certain. If, however, the middle flap be very broad at its base, a needle may be passed through its summit, and one or two others may be introduced from each side. After the cure, the cicatrix resembles a capital Y, and represents also the course of the naso labial columns. The patient is cured as readily as if affected with simple harelip, and the consecutive inflammation is no greater than in that case.

In plate xlv., fig. 5, we see the operation for double hare-

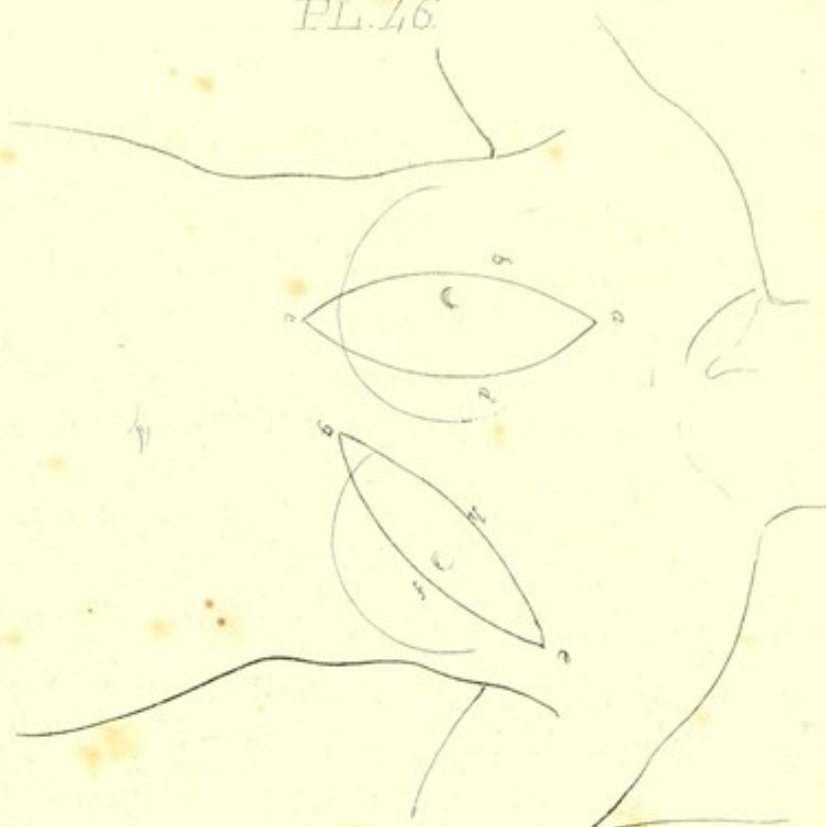lip; the central cuticular appendage is divided to the cartilage of the nose into two halves, *b, c*, by the convex knife, *a*. These are united sometimes by two and sometimes by three needles. Fig. 6 shows the parts after they are joined—*a, b*, is the outer cuticular appendage, which unites with the cartilage of the nose, and forms a nasal septum. Fig. 7 is a front view of the nose and lip when the cure is completed.

EXTIRPATION OF THE BREAST.

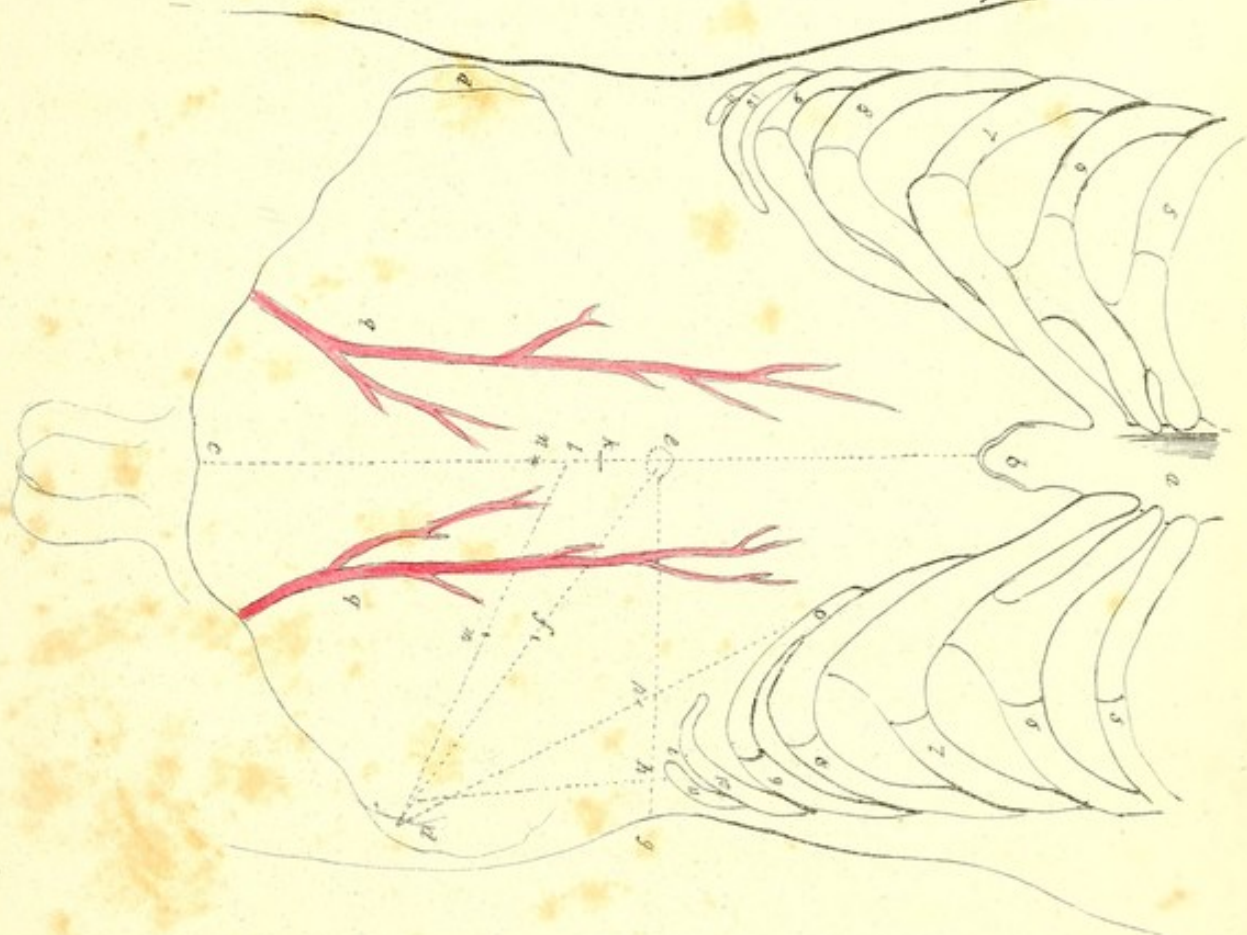
When the mammary gland requires to be removed, the patient sits in a chair, or lies on the operating table, the latter position being preferable. The head and chest are raised by an assistant, so that the breast may project as much as possible, and the arm corresponding to the diseased side is extended, so as to raise the pectoral muscle. Another assistant supports the tumor with one hand, and with the other holds a sponge, to wipe away the blood during the operation. The surgeon draws the skin in the opposite direction, and makes first the inferior incision in the semilunar form, which form is preferred by most operators; he then depresses the diseased mass, and makes his superior excision, beginning at the superior extremity of the first wound, and terminating at its lower angle; the ellipse is thus completed: the diseased mass is then dissected from below upward, commencing at the outer side of the incision: the hemorrhage is arrested by the assistants, who place their fingers on the bleeding orifices. The breast being removed, the vessels are tied; the edges of the wound are brought together, and kept in place by adhesive plaster; after which, lint, compresses, and bandages are applied.

On plate xlv., fig. 1, on the left side, the elliptical incision, *f, g*, is made, which terminates a line or two above the gland, unless the axillary glands require to be removed, in which

I.



II.



case it is extended into the axilla to the point, *e* ; the ellipse is then finished by making the incision, *e, h, g*. On the right side is seen an incision in a different direction, extending, *a, b, c*, over the outer, and, *a, d, c*, over the inner half of the breast, which unite one line above and one line below the gland.

PARACENTESIS ABDOMINIS.

The usual mode of performing this operation is to place the patient in a high chair, with a pail between his knees. A sheet is crossed round the abdomen, and pressed tightly by an assistant, who holds the ends of it. The spot which is to be perforated having been settled, the surgeon makes an incision with his lancet, and introduces the trocar: the point generally selected for puncture is in the linea alba, about an inch below the umbilicus.

In plate xlv., fig. 2, is seen the place for the operation—figs. 5 to 11, on both sides, show the three inferior true ribs, and the four superior false ones—*a*, sternum—*b*, xyphoid cartilage—*c*, symphysis pubis—*d, d*, crest of the ilium—*e*, umbilicus—*f*, the centre of a line drawn from the umbilicus to the crest of the ilium ; this spot is sometimes selected for the operation—*e, g*, a line drawn from the umbilicus outward, and *i, d*, a line drawn from the last rib to the crest of the ilium—*h*, point where these lines cross, and where the abdomen is sometimes punctured—*k*, centre between the xyphoid cartilage and the symphysis pubis—*l, d*, a line commencing two thirds of a line below, *k*, and running to the crest of the ilium, in the centre of which, *m*, Lisfranc introduces the trocar—*n*, point for puncture in the linea alba—*o, d*, a line drawn from the anterior end of the second false rib to the crest of the ilium, on the left side, in the centre of which, *p*, Zang makes his perforation for tympanitis

abdominis—*q, q*, show the course of the epigastric artery on both sides.

STRANGULATED HERNIA.

A hernia is said to be strangulated, when it is not only confined within the parts into which it has descended, but when it is so much compressed by the narrow part through which it has passed, that the circulation (in the intestine and omentum which has descended) is in a great degree stopped.

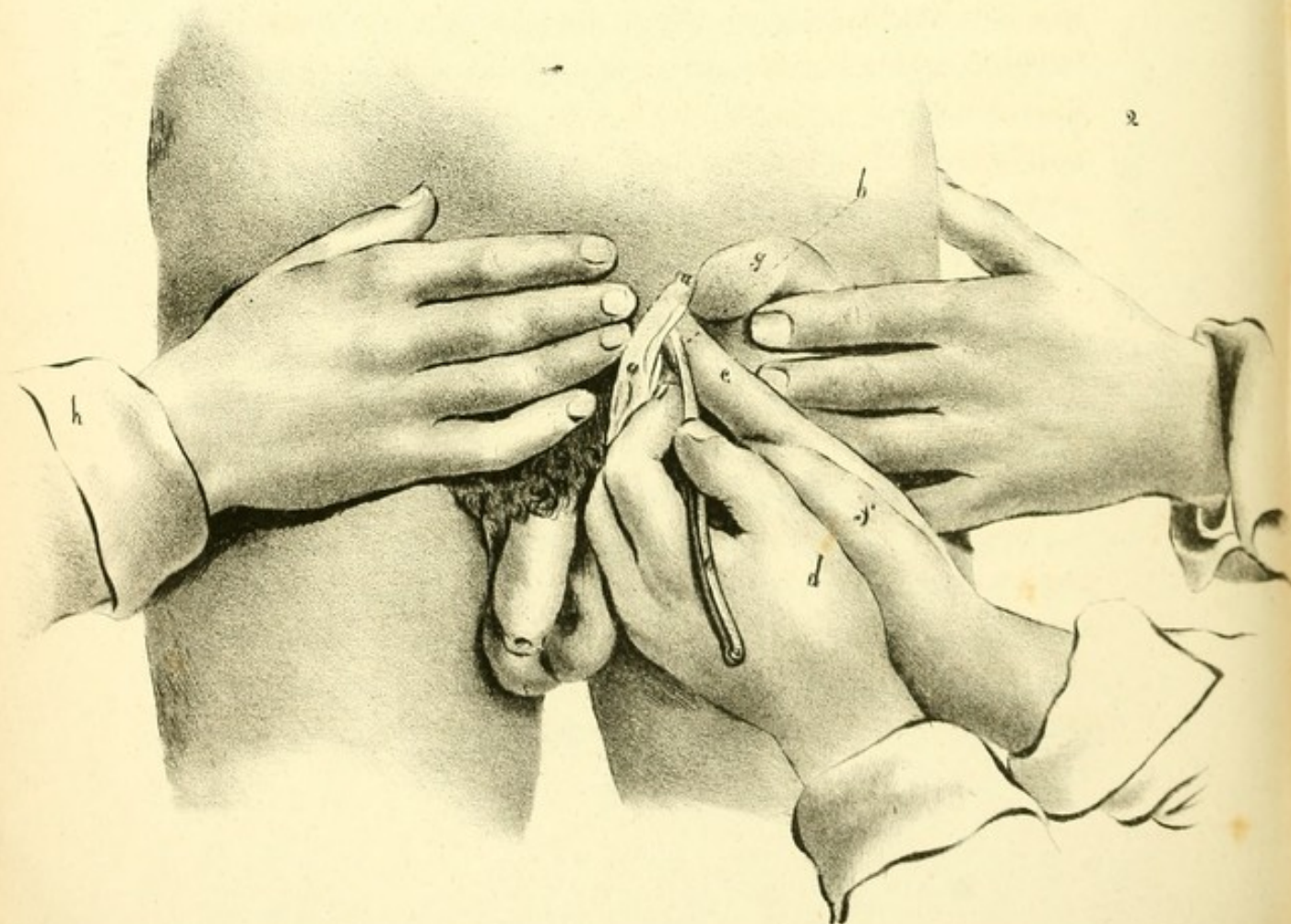
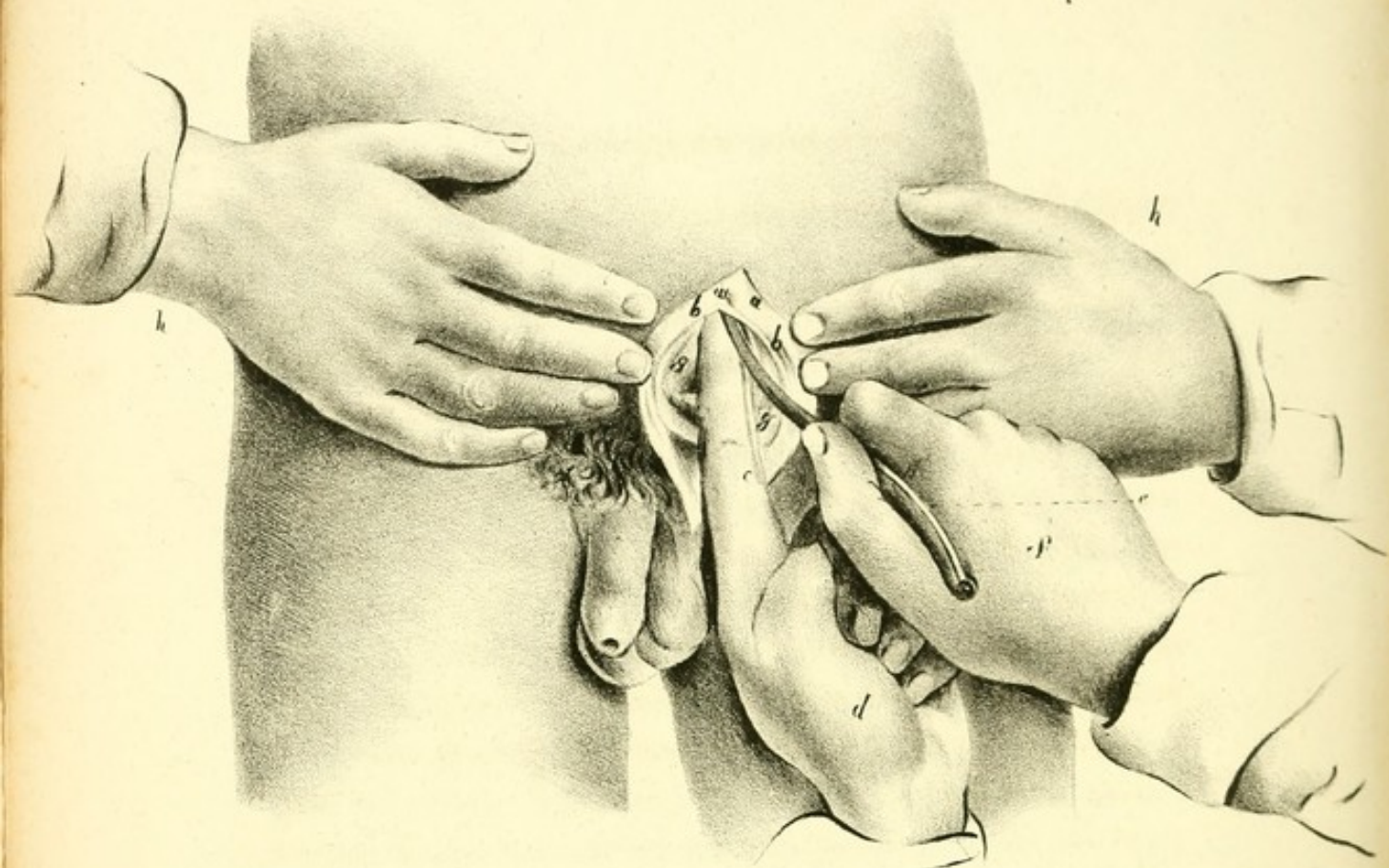
If the different remedies employed for the reduction of hernia as the taxis with the warm bath, bleedings, &c., are not attended with success, the patient must submit to an operation which is performed as follows:—

The patient should be placed on a table from two to three feet high, with the legs hanging over the end; the hair having been removed from the pubes, you should commence the incision from the upper part of the tumor, in whatever situation it may be, and carry it along its middle to the lower part. There will be no necessity to continue the incision quite to the lower part, if the hernia is large, as then it often happens that there are vessels crossing in that part. By the first incision, you lay bare the fascia of the cord, and in doing this you will divide a small artery, the external pudendal, which crosses directly opposite to the abdominal ring; take your tenaculum, and secure the two ends of the bleeding vessel, and then scratch through the fascia of the cord, just below the ring, with considerable care, separating it from the cremaster muscle; a small opening being made, you introduce a director upward to the abdominal ring, and inferiorly to the lower part of the swelling, and divide the fascia more or less, as may be required. The next parts that will be brought into view, are the fibres of the cremaster muscle, passing obliquely from above downward; this covering is

of considerable density, and must be opened with care ; a director is to be introduced under it, in the same manner as the fascia of the cord, and then it is to be divided ; as soon as this is done, the hernial sac becomes exposed ; it is of a blue appearance, and semi-transparent from the fluid it contains. Having laid bare the sac, you pinch it between your fingers, and feel distinctly the intestine and omentum within it ; in rubbing the sac between the fingers, do not use any force, as this is exceedingly dangerous. When you have raised the sac so as to separate it from its contents, take the knife and make a small cut into it, not downward, but in a lateral direction ; place the instrument horizontally, so as to avoid the danger of wounding the intestine, a danger to which you would be exposed if you cut downward. As soon as an opening is made, water generally escapes, if intestine be included in the sac, and there are no adhesions. Having opened the hernial sac, a director is to be introduced as far as the abdominal ring, and then it is to be divided up to that extent ; the director is then to be carried to the lower part of the sac in the same manner. When both omentum and intestine are in the sac, the omentum will be found before, and the intestine behind ; there will also be a small portion of omentum at the upper part. After having opened the hernial sac, the great difficulty commences : you are next to feel for the stricture ; put your little finger into the hernial sac, and ascertain if the stricture is situated at the abdominal ring ; and if so, spread the omentum on the forepart of the intestine, like an apron, so as to cover it entirely ; by this plan, the intestine is less liable to be wounded, and it adds exceedingly to the security of the patient ; and then you pass a probe-pointed bistoury, guided on the finger, and divide the stricture, not very freely, but to a small extent ; a slight motion of the knife will do.

The stricture, however, does not generally exist at the external ring, for it is usually situated at the upper part of the hernia, just opposite to the tendon of the transversalis muscle, or else in the hernial sac itself; and what you have to do is to slit up the abdominal ring, to hook up the abdominal muscles, and draw them upward toward the abdomen; then to pull down the hernial sac; by this means you expose the stricture, and render the operation more safe to the patient. The probe-pointed bistoury is blunt to the extent of a quarter of an inch, sharp for half an inch, and then blunt again, so that you may introduce it on the director and finger, and divide the stricture without fear of cutting too much. You must divide the stricture in the centre, and cut *directly upward*, let the hernia be where it may, and you will be in no danger of wounding the epigastric artery. The stricture being divided, you next return the intestine before the omentum. You should always, at this stage, introduce a finger, to see whether the parts are freely returned or not, and are not compressed at the place where the stricture was situated. If there is any air in the intestines projecting above the stricture, bring it down into the lower part, and by this means they will be more easily returned. The intestines should be returned piecemeal to the cavity of the abdomen, and then the omentum should succeed it.

Plate xlvii., fig. 1, represents an inguinal hernia on the right side. The skin and subjacent layers, *a, a*, are freely divided, and are separated by the hands, *h, h*, of an assistant, who draws the sac in the same manner. With his left hand, the surgeon glides the bistoury, *e*, under the extreme and upper angle of the ring, and cuts it upward and outward. The index finger, *c*, of the right hand, *d*, which supports the back of the instrument, depresses the intestines, *g, g*, at the same time. In operating on the left side, the right hand



would conduct the bistoury and the left would crowd back the intestines.

Fig. 2 in this plate represents a crural hernia of the right side. The herniary envelopes, *a, a*, are divided in the direction of the groin, and are drawn inward by the hand, *h*, of an assistant, who pushes the intestines, *g*, with his other hand, *i*, in a contrary direction. The edge, *b*, of the bistoury, *c*, held with the right hand, *e*, in an almost horizontal direction, is situated there in the concave edge of Gimbernat's ligament, which it cuts, from without inward, and a little from above downward. The index finger, *e*, of the hand, *f*, pushes aside the viscera and assists the instrument.

Strangulated Umbilical Hernia.—This operation, which is the simplest and easiest operation for hernia, is by no means the most successful, as it is very difficult to obtain a flap of skin to close the opening made during the operation. The mode of performing it is, first, to make an incision across the tumor, and then another at right angles, so that the whole resembles the letter **J** inverted. The integuments being divided, the corners of the incision are to be turned aside, by which the hernial sac is seen. This being carefully opened, the finger is to be passed to the orifice of the sac, at the umbilicus, and a blunt pointed bistoury introduced on it. The stricture is to be divided upward in the direction of the linea alba. Having returned the intestines, the parts are to be brought together and a flap formed from above to cover the opening.

The envelopes of an umbilical hernia, are shown by a perpendicular division of it in the centre, in plate *xlvi*., fig. 1: *a, a, a*, represent the general integuments; *b, b*, the abdominal muscles; *c*, the peritoneum; *d*, mouth of the herniary sac; *e, e*, herniary sac; *f, f*, end of the linea alba at the ori-

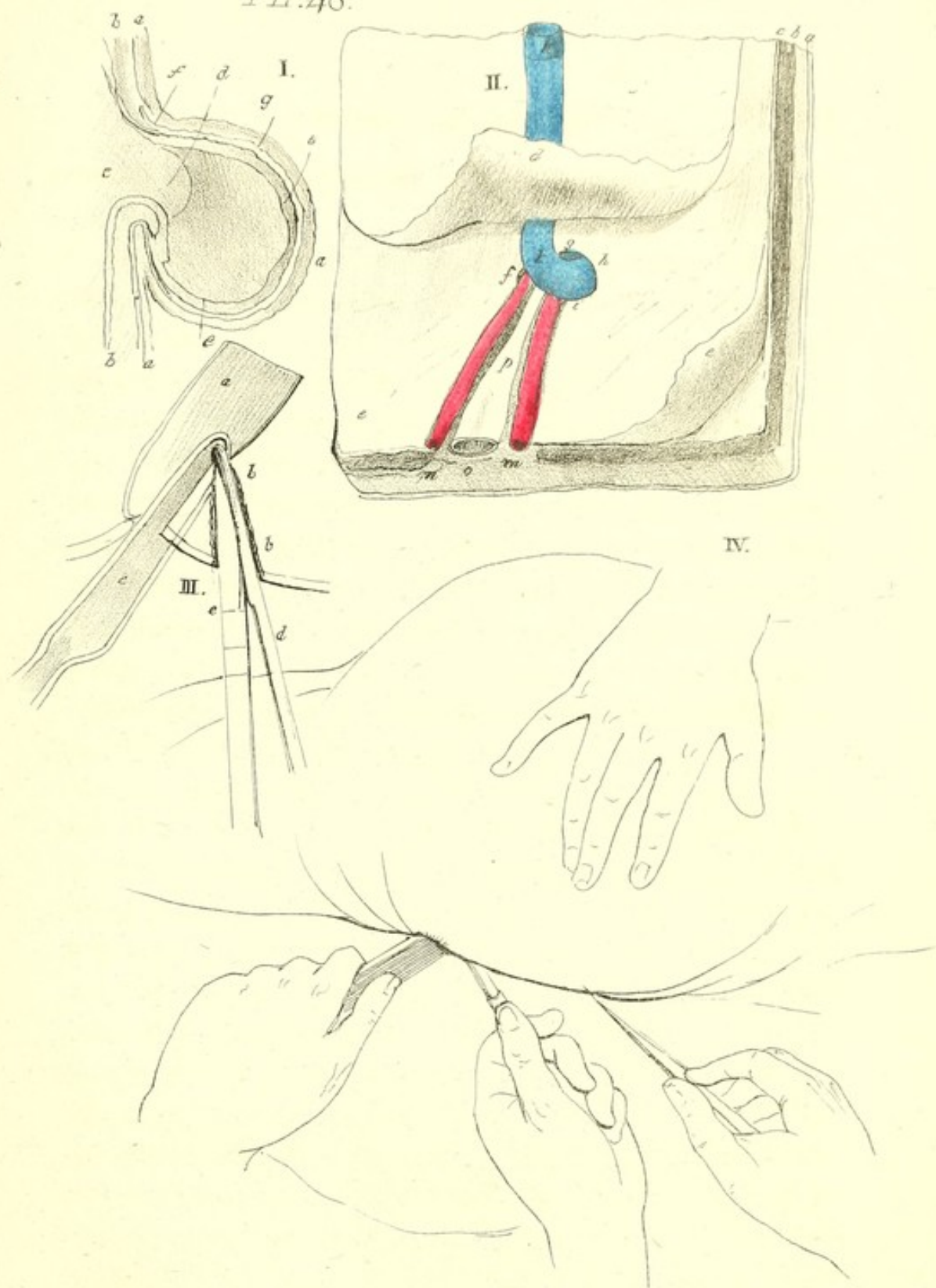
fice of the sac; *g*, fascia which extends below the integuments and covers the sac.

Figure second on this plate, is a view from the inside of the umbilicus and the umbilical vessels, as seen in a healthy and new-born child: *a*, represents the skin; *b*, the fat between the skin and the abdominal muscles; *c*, the rectus abdominis muscle; *d*, part of the peritoneum turned upward; *e, e, f, g, h, i*, tendinous expansion which extends from the oblique and transversalis muscles and forms the umbilical ring; *f, g, h, i*, the fibres of the upper segment, of which, *g*, are more arched than in the lower *i*; *f, g, h*, a depression or groove between the upper arch and the umbilical vein; *k, k*, umbilical vein; *m, n*, right and left umbilical artery; *o, p*, a portion of the bladder and urachus.

FISTULA IN ANO.

By fistula in ano we understand a sinuous ulcer in the neighbourhood of the anus and rectum. When the disease requires an operation, it is performed as follows:—a small probe-pointed bistoury is introduced into the fistula; the finger is passed up the rectum to meet the instrument; the point of the instrument is carried downward and the intervening parts are divided. If the fistula be very extensive, it will be necessary to put the finger on the extremity of the instrument, and to draw it downward. If the fistula does not open into the rectum, the instrument must be passed up the sinus until it reaches the extremity: the finger is then introduced into the rectum to meet the knife; the cellular tissue is now cut, and the instrument is brought into the rectum.

The French mode of operating, however, differs a little from this, and is as follows:—a gorget made of ebony is introduced into the rectum, with its concavity turned toward the fistula. A steel director, slightly pointed, and without



a cul-de-sac, is then passed through the fistula, till the point comes in contact with the gorget; by cutting on this gorget, all the parts between the internal opening of the fistula and the anus are divided. The latter operation is seen in plate *xlvi*., fig. 3, in which the gorget is introduced into the rectum, held by an assistant; the director is placed in the fistula, and the surgeon, holding the bistoury in his right hand, is ready to continue the operation.

In fig. 4, the next step in the operation is seen: *a*, represents the rectum; *b, b*, the fistula; *c*, the gorget introduced into the rectum; *d*, the director passed through the fistula and towards the gorget; *e*, the knife introduced in the director, with its edge toward the gorget.

LITHOTOMY.

The instruments employed in the operation of lithotomy, are bandages, a sound, a staff, a gorget, forceps, knife, and the lithotome cachée; all these, however, are not necessary for every operation. The sound should be fitted to the size of the urethra, for, if a small sound be used in a large urethra, or vice versa, the stone will very often escape the touch. The staff should be as large as the urethra will admit, and a little more curved than the sound; its groove should be large and deep, which will render the knife or gorget less liable to slip in its passage to the bladder. The lithotome cachée consists of a knife enclosed in a sheath, which, after being introduced into the bladder and turned with its edge downward and outward, cuts its way out when withdrawn. Other instruments than these are sometimes used, some of which are figured on plate *xlix*., and will be described in treating of that plate.

There are different modes of cutting for stone; that most commonly practised is the lateral operation; and when the

knife is used, is performed as follows :—the patient being placed in a favourable position on the operating table, and properly secured, either by bandages or by the aid of assistants, is sounded : the staff is then introduced, and rested on the stone : the surgeon makes an incision on the left side of the perineum which commences at the symphysis pubis, and is carried downward and outward to midway between the anus and the tuberosity of the ischium, and terminates opposite to the centre of the anus : this cut will pass through the skin and fat and expose the accelerator urinæ muscle. The operator now divides this muscle between the bulb of the penis and left crus ; and then with his fingers presses the bulb under the right ramus of the ischium to prevent it from being wounded : this being done, he divides the transversus perinei, and feels with his left finger for the groove of the staff, cuts into the groove at the membranous part of the urethra, and bringing down the handle of the staff, pushes the knife forward into the bladder, and then cuts through the prostate gland and the neck of the bladder downward and outward, corresponding to the external wound. He now introduces his finger again into the wound, feels for the groove of the staff, and then withdraws that instrument. He keeps his finger in the bladder, and introduces the forceps with their flat side next to it : having with the forceps carefully felt for the calculus, it is grasped and withdrawn.

When the gorget is used, the first part of the operation is the same as with the knife : the staff being introduced, and the opening into the groove through the membranous part of the urethra having been completed, the surgeon fixes the beak of the gorget in the groove, and brings the handle of it towards himself, at the same time pushing the gorget into the bladder, its point being inclined upward : the staff must now be withdrawn and the forceps passed into the bladder,

along the hollow of the gorget ; the latter instrument is then removed, and the stone is extracted.

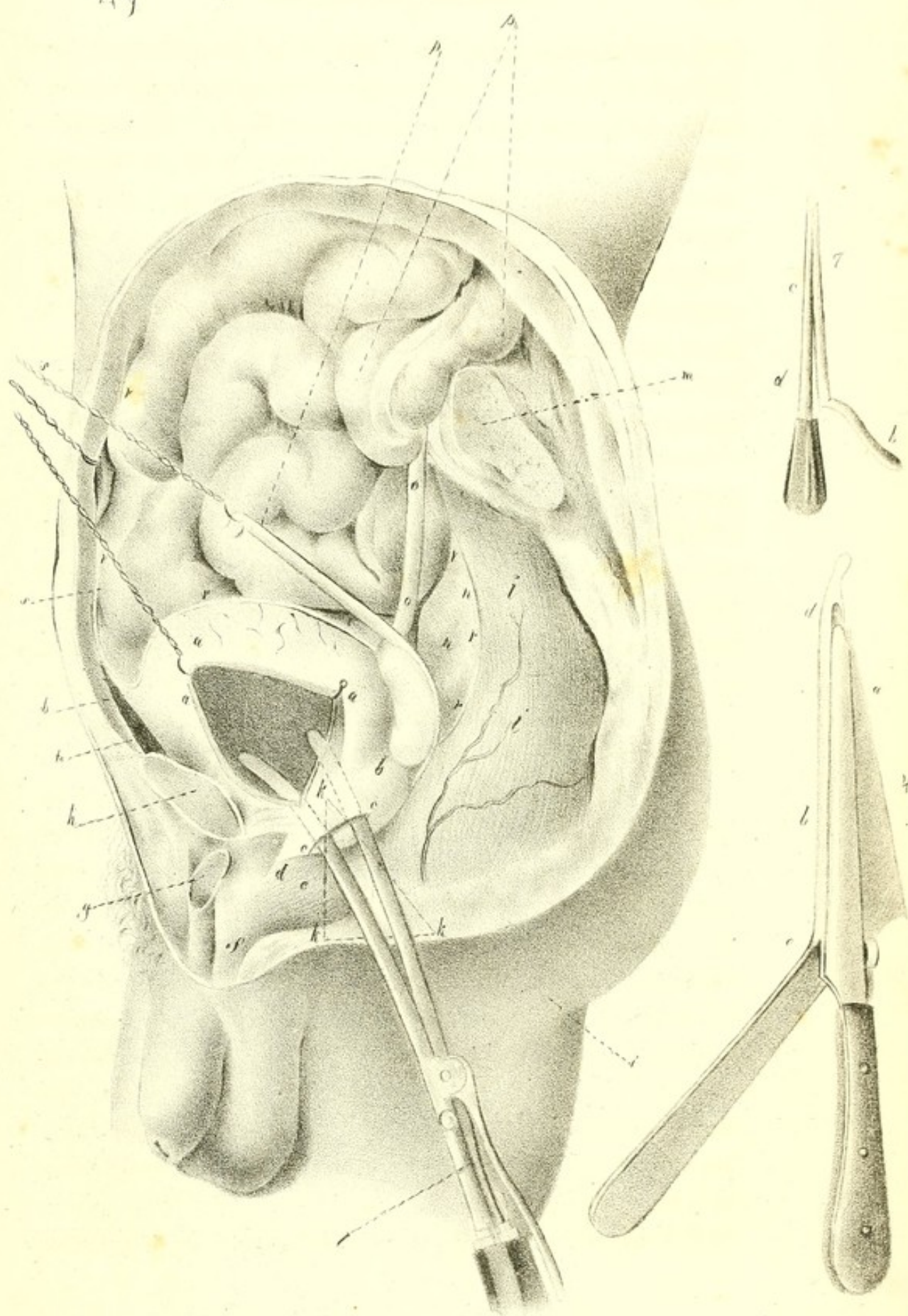
When the lithotome cachée is used, the skin, the fat, and the transverse muscles, being divided as in the common operation, and the urethra opened, the scalpel is laid aside, and the beak of the lithotome is introduced into the groove of the staff. Of course, the surgeon, previous to the operation, will have settled the distance to which the blade of the instrument is to pass out of the sheath, and which must necessarily depend on the age of the subject and the presumed size of the calculus. When the beak of the lithotome has been inserted in the groove of the staff, the surgeon takes hold of the handle of the latter instrument with his left hand, and brings it a little towards himself, and at the same time pushes the lithotome into the bladder, with the handle depressed as much as possible. The staff is now withdrawn, and the surgeon feels for the stone with the sheath of the other instrument, in order to judge of the size of the calculus, and whether the distance to which the blade of the knife is intended to move out of the sheath is such as to make an opening of the requisite size. Things being properly determined, the lithotome is to be held in a position calculated to make a division of the parts which is parallel to the cut in the integuments, and by means of the lever the cutting blade of the instrument is then to be disengaged from its sheath. The surgeon now draws the opened lithotome toward himself, in a perfectly horizontal manner, so as to make the necessary division of the prostate gland and orifice of the bladder.

High Operation.—In this operation, the instruments used are, a probe-pointed bistoury, a sonde-a-dard, (a sound containing within it a dart or stylet,) and a pair of forceps, similar to those used in the lateral operation. The following

is a brief description of the mode of operating:—pass the sonde-a-dard into the bladder, and, by depressing the handle, endeavour to make its point project just above the symphysis pubis in a line with it and the linea alba: push forward the stylet, and it will appear in this situation. An incision two inches long must then be made in the direction of the linea alba, through the integuments down to the bladder, which is supported against the part by the point of the sound; and then, with a probe-pointed bistoury, make an opening into the bladder, against the edge of the wound; withdraw the sonde-a-dard; pass down the forceps, and remove the stone.

The surgical anatomy of the parts interested in lithotomy is seen in plate xlix. The patient lies on his left side; the left part of the abdomen, including the haunch and thigh, is removed, the section being on the outside of the median line. As it is situated, the lithotome cachée of F. Come, *l*, would almost inevitably wound the end of the rectum, *l, l, l*, unless we were careful to raise the handle on withdrawing it. The urethro-anal triangle, *k, k', k''*, represents, by its superior edge, *k, k'*, the line of entrance, and by its inferior, *k, k''*, the line of departure for the knife, which divides the passages previous to the introduction of the lithotome cachée. Its lower angle, *k''*, falls on the anus, *i*; its deep angle, *k*, on the neck of the bladder; and its anterior angle, *k'*, on the anterior part of the perineum. The instrument raised to *k', c, k*, cuts without danger the prostate gland to *b*: while in the position in which it is seen, it would almost inevitably wound the intestine, if the wound *c, c'*, should be extended beyond *e*. The incision, if commenced in the membranous part of the urethra, *d*, would present some advantages for the extraction of the calculus; but it would be difficult to avoid the bulb, *e*.

The seminal vesicle, *a*, is not endangered except in the



rectovesical operation, in which the calculus is extracted through the rectum. In fact, as the incision is then limited between the cavity of the peritoneum, *n, n*, and the prostate gland, *b*, the vas deferens, *p*, or the pouch which extends along its outer side, is liable to be wounded, if Sanson's process be followed. The peritoneum, *r, r, r, r, r, r, r, r*, which extends from the front of the rectum, *l, l*, ascends behind the bladder, *a, a*, to line the posterior face of the abdominal muscles, *s, s*, leaves the urethra, *o, o*, and the seminal duct on its outer face in the subjacent cellular tissue. They have been raised here to show the other parts better.

In the high operation, we penetrate first into the cellular space *t*, and the bladder may be then opened from the root of the urachus, *v*, to the sheath of the lithotome, opposite the section of the pubis, *h*.

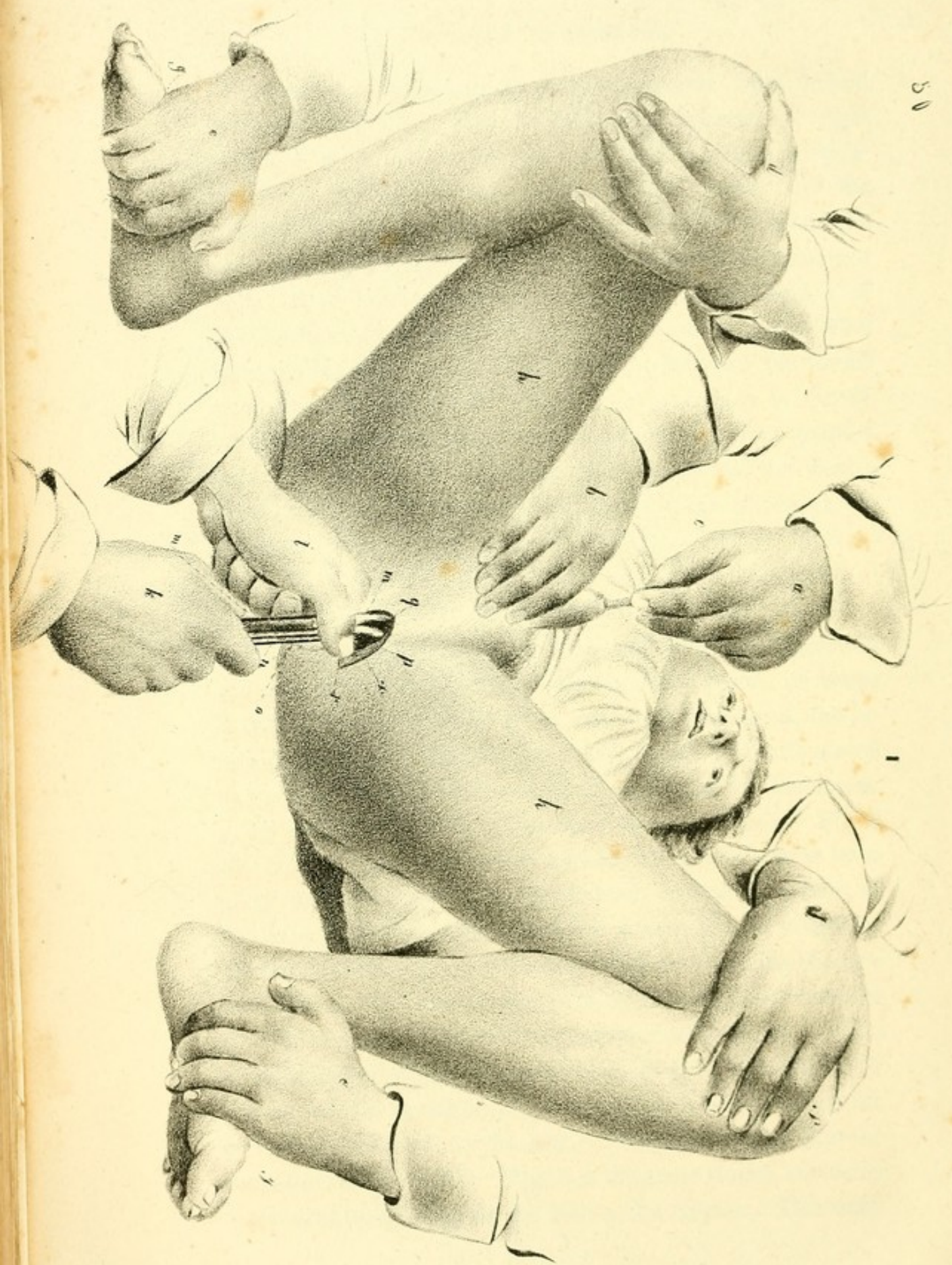
Fig. 4 in this plate, shows the lithotome gorget of Blounfield. The crest of the blade, *a*, allows it to glide in the groove of the conductor, *b*, from *c* to *d*, with the greatest ease. Fig. 7 shows the lithotome trocar of F. Côme. When the point, *a*, has come into contact with the space marked *t*, on fig. 1, the surgeon holds the body of the instrument, *d*, firmly against the pubis, *h*, while with the other hand he carries the handle of it, *b*, and the edge, *e*, from the side of the umbilicus to *s*.

Plate 1. shows the operation. An aid standing on the right, holds with his left hand, *a*, the catheter, *c*, while with his right hand, *b*, he slightly raises the scrotum. The legs, *i, i*, and the thighs, *h, h*, are flexed, separated, and raised, and are kept thus by two assistants. With the hands, *d, d*, they press the knees, *f, f*, against their chests, while with the other hands, *e, e*, they hold the inner edge and plantar face of the feet, *g, g*. The integuments and all the soft parts are divided to the bladder. The lithotome of Côme is introdu-

ced closed, and is opened to cut the prostate from behind forward. The back of its sheath rests against the right ramus of the pubis, rather than directly against its symphysis or the upper angle of the wound, *q*, and thus the blade, *p*, is directed almost crosswise on the edge, *s*, and not more toward the angle, *r*, of the incision of the integuments—its rod, *n*, is held against the handle, *m*, by the hand, *k*, of the operator, who opens it in this manner, while in the other hand he takes the sides of the joint, *o*, between the thumb and the radial edge of the index finger, which is flexed. The whole is a little more depressed here and more inclined than is necessary, as otherwise the wound and the instrument would be hidden in great part by the hands of the surgeon.

LITHOTRITY.


The instruments required for performing this operation are seen on plate li. Fig. 1 is the brise pierre, or stone breaker, of Jacobson: *f*, is the protecting canula; *d*, the inferior or moveable branch, jointed at *b*, *b*, *b*, and articulated at *e*, with the fixed or dorsal blade, *c*, moved by the screw, *g*, by the aid of a vice. The stone is grasped at *a*. Fig. 2 shows the same instrument closed. Fig. 3 is a new brise pierre of Herteloup: *a*, the fixed blade of the apparatus; *b*, the moveable blade, the extremity of which, *e*, is struck by the hammer during the operation; *d*, a vice to bring the two branches against one another; the instrument is separated at *e*. Fig. 4 shows the same apparatus closed. Fig. 5 is the straight sound of Gruithausen: *a*, *a*, body of the algali; *b*, summit of the mandrin, *g*, *g*, uniting at *e*, with the sound, and which is moved by the ring *c*; *f*, space showing that the instrument is shortened. Fig. 5 is the same sound, enclosing a mandrin terminating in the crown of a trepan. This man-

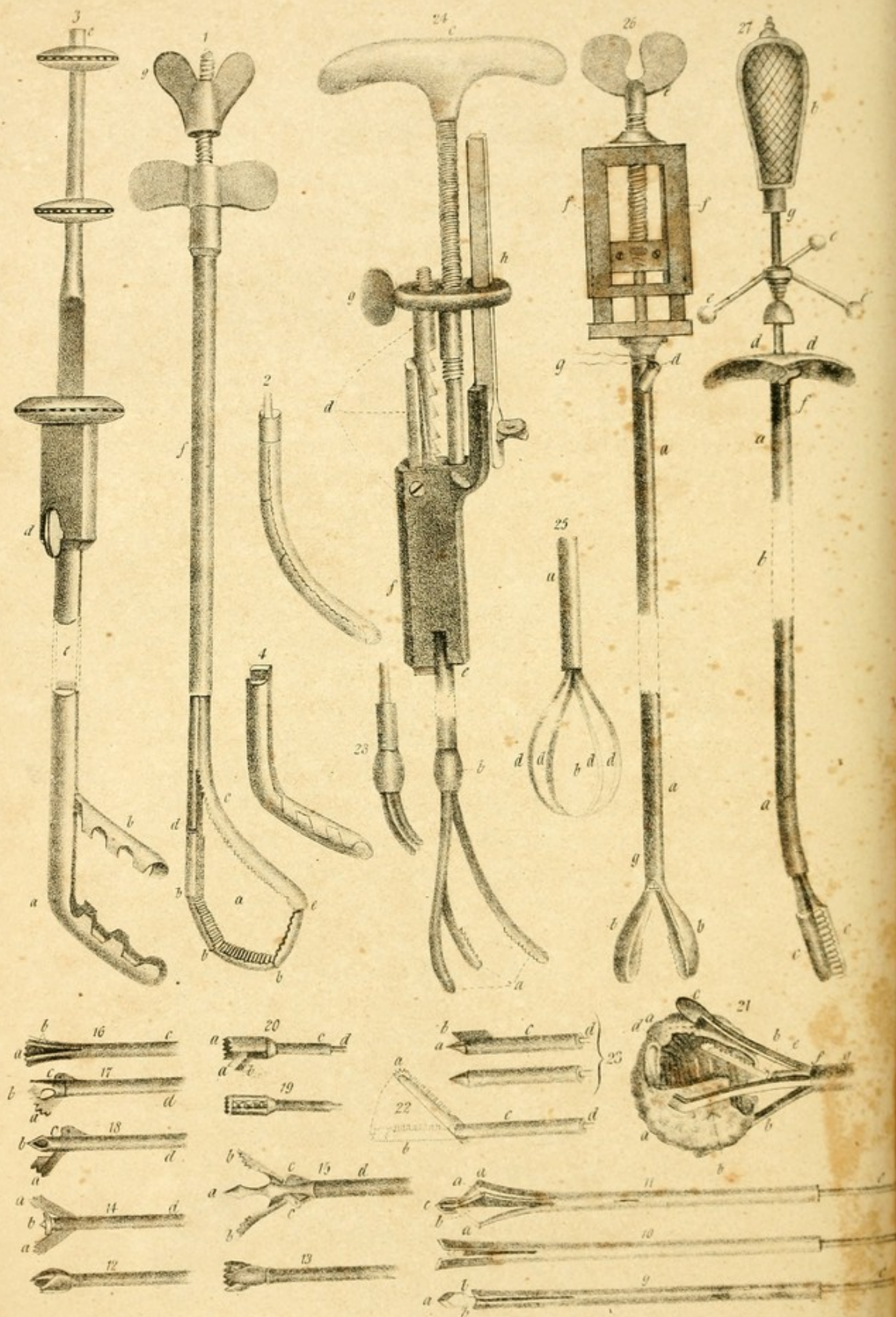


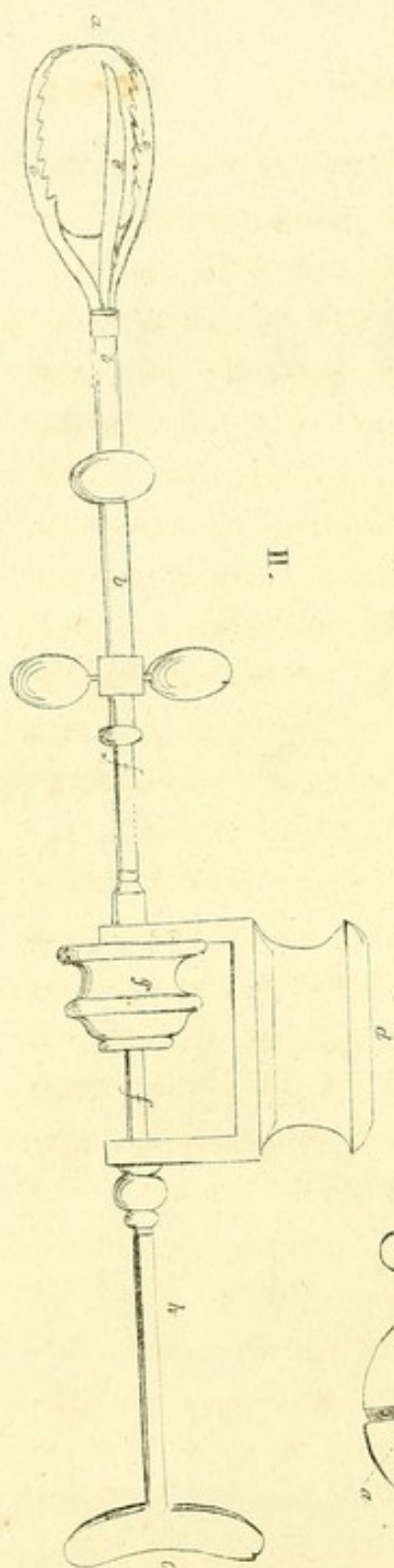
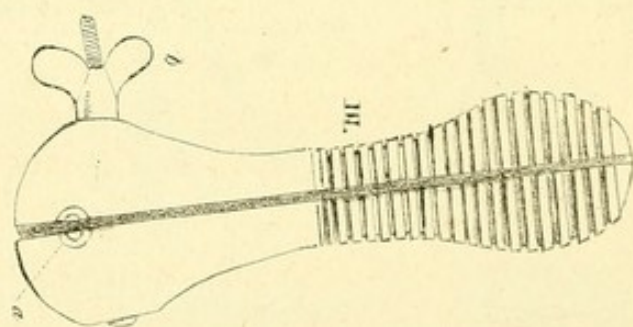
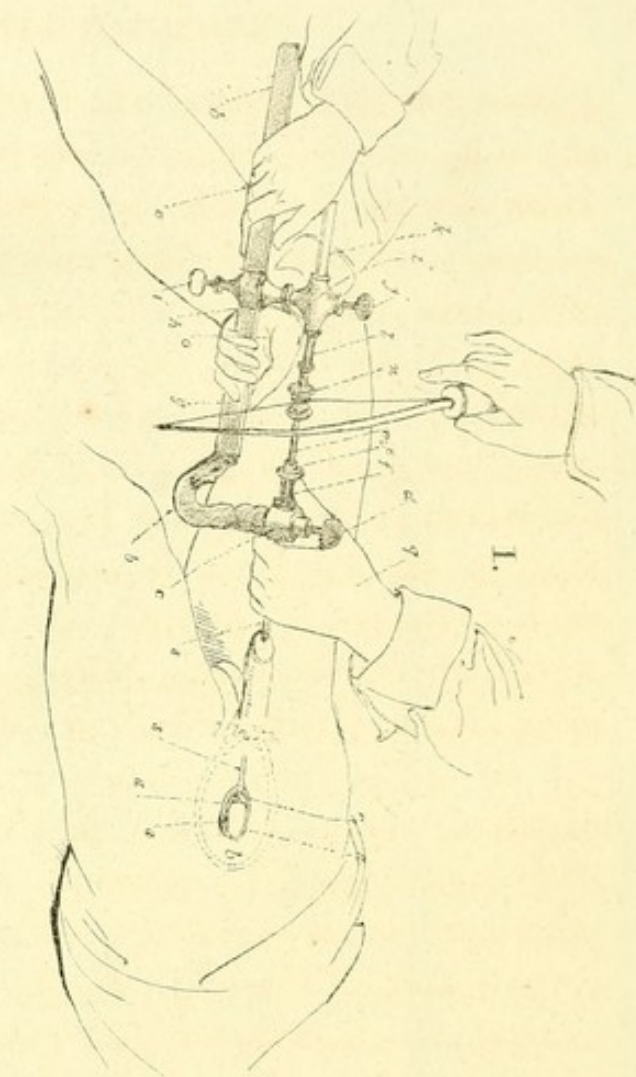
drin is kept steady in the tube by three circles of leather, and has at its extremity, *e*, a pully which receives a bow-string. The opening, *b*, gives issue to the pieces of the calculus as they are broken off from the principal stone. In fig. 6, this mandrin terminates in an iron lance, *b*; it also has at its extremity a pulley, and within it is a loop, *a*, of brass wire, the two ends of which, *d, d*, are seen at the extremity of the instrument. Fig. 7 is a bent saw, or drill, proposed at first by Leroy: *a* is the sheath; *b*, the acting part of the instrument; *c, d*, the mandrin, of which it is the continuation. Fig. 8 is the double drill of the same writer: *a*, the sheath; *b, b*, the separated blades of the drill; *c*, a centre piece, which opens or closes the drill according as the former is pushed from or drawn into the sound. Fig. 9 is the foret-a-chemise, or borer of Rigal, closed, and ready for the operation: *a*, the projecting head, which being drawn back between the two blades, *b, b*, by the handle, *c*, produces the separation seen in fig. 10. Fig. 11 is the cutting borer: *a, a, a*, cutting blades articulated with the head, *c*, of the first borer, *b, c*, and with the branches of the canula, *d*. Figs. 12 and 13, borers used by Civiale. Fig. 14, a new borer of Leroy. Fig. 15, borer of Tanchon: *a*, point of the borer, *d*; *b, b*, toothed wings of the borer, articulated at *c, c*, with the central portion, by which they are moved. Fig. 16, the fraise a tete et a chemise of Rigal: *a*, central head, which on being withdrawn, separates the blades, *b*, from their protector, *c*. Fig. 17, the simple borer of Pecchioli, or Tanchon, modified by Charrière: *a*, the wing, pushing back its heel, *c*, as it separates from the drill, *d*, the point of which is seen at *b*. Fig. 18, the same instrument in its primitive state. Fig. 19, the lithotriteur of Heurteloup, closed. Fig. 20, the same open: *a, a*, head and point of the drill, *c*; *b*, the wing of the borer, which is moved by the rod *d*. Fig. 21, the pince a forceps of Heur-

teloup, a litholabe, one of whose branches, *b, b, b, b*, is longer than the others, and is called a capuchin, *c*,; the calculus, *a*, *a*, is held by it, and reduced to a shell, *d*, by the action of the evideur, *e*, which is moved by the rod, *f*, which glides with the litholabe in the conducting canula, *g*. Fig. 22, represents the evideur of Heurteloup, articulated with the tube, *c*; its dentated portion is pushed forward by the blade *d*, and is here inclined from its natural direction, *b*, to its extreme point of departure, *a*. Fig. 23, perforators of the same practitioner, one of which is closed, the other open: *a*, triangular point of the borer, *c*,; *b*, extreme blade, separated by the action of the mandrin, *d*.

M. Civiale's method of performing this operation is seen on plate lii. fig. 1. The patient lies on his back, his breech is raised by a cushion, and his legs are semiflexed, and project from the foot of the bed. A common sound is introduced into the bladder, and then some warm water, or some emollient or mucilaginous fluid, is injected into it, the quantity of which is proportional to the size of that viscus. The sound being then withdrawn, the instrument is introduced immediately after, like a common straight sound, in the following manner:—the surgeon stands on the right side of the patient, or between his legs; he depresses the penis, so as to make it parallel with the thighs, which should be slightly flexed: the instrument is held with the right hand, and introduced, the urethra having been previously dilated and rendered less sensible by the repeated introduction of flexible sounds, beginning with those of two lines diameter, and terminating with those of three and a half or four lines diameter. The instrument penetrates easily to the symphysis pubis. We then feel by the contact of the sound with this solid part, that it has come to the bulb: the penis is depressed, and the beak of the instrument







is directed a little higher, which thus passes through the membranous portion, and comes to the prostate gland. The utmost care must be taken to give the sound the direction mentioned, and which is indispensable for its introduction, for there is danger of making a false passage: its point might penetrate into the depression near the bulb, might pass through the inferior wall of the urethra, and might come to the anus. If the prostate is healthy, it is generally sufficient to depress the hand, and raise the point of the instrument: the sound then penetrates into the bladder. The blades of the forceps are then expanded, and the calculus is seized and fixed; the instrument is held firmly by a vice, and the surgeon applies the bow. On commencing the perforation, the operation must be slow: if the stone be friable, the lithotriteur penetrates easily, and its action is attended with a dull sound; but when the stone is hard, the sound is more acute, and the lithotriteur makes but little progress. The boring may be continued for about ten minutes, but then it is necessary to stop, in order not to fatigue the patient; but the operation may be performed again in from three to five days.

In order to withdraw the instrument, the vice is unscrewed, the forceps are opened, and the stone is pushed back by the lithotriteur, and the forceps is drawn into its sheath; the blades also should be closed. Some fragments of the calculus are frequently brought away with the forceps: if they are so large as to render the removal of the instrument painful, they might be crushed by pushing the head of the lithotriteur against the teeth of the forceps.

In plate lii. fig. 1, the calculus, *b*, embraced by the three-bladed forceps, *a, a, a*, is seen through the bladder at the moment when the borer, *r*, begins to perforate it. The left hand, *q*, of the surgeon keeps it firm; resting partly on the

external canula, *s*, which is also supported by the head, *c*, of the mandril lathe, and also on the loose portion, *f*, of the litholabe, while the left hand moves the bow—*m*, portion of the staff of the drill, which gradually penetrates into the protecting canula, *e*, in proportion as the spiral spring concealed in the upper branch *k, l*, of the lathe, pushes its loose portion, and the bow moves its pulley, *n—b, b*, lower part of the mandril which an aid holds firmly with his two hands, *o, o*, placed below. The use of the vice, *j*, is to arrest, when it is necessary, the expansion of the spiral spring which presses against the drill, and that which is seen at *i*, is designed to fix properly the two portions of the instrument, one against the other; and that which is marked *d*, fixes the litholabe within the external canula.

Fig. 2, is the apparatus of Amussat. It is more simple than the preceding but is less useful. The calculus, *a*, reacts with too much advantage on the branches, *e, e, e*. Its canula, *b, b*, is badly arranged. Fig. 3 represents the vice which is opened or closed by unscrewing the screw, *v*. In its opening, *a*, is placed the portion of the apparatus, seized by the head, *c*, of the mandril lathe on fig. 1.

CONTENTS.

	Page
BANDAGES and Dressings, - - - - -	5
Plumasseau, - - - - -	6
Bourdonnet, - - - - -	6
Tampon, - - - - -	6
Meche, - - - - -	6
Compresses, - - - - -	7
Rollers, - - - - -	8
Bandages, - - - - -	10
Dressing Wounds, - - - - -	13
Bandages of the Head and Neck, - - - - -	16
Four-tailed Bandage, - - - - -	16
Six-tailed Bandage, - - - - -	16
Capelina, - - - - -	17
T Bandage, - - - - -	17
Nodose Bandage, - - - - -	18
Double T Bandage, - - - - -	19
Monocle, - - - - -	19
Hare-lip Bandage, - - - - -	20
Four-tailed Chin Bandage, - - - - -	22
Chevaster Bandage, - - - - -	22
Bandage for Transverse Wounds of the Neck, - - - - -	23
Bleeding at Jugular Vein, - - - - -	23
Wry-Neck, - - - - -	24
of Thorax with Scapulary, - - - - -	25
Quadriga, - - - - -	25
Pelvis, - - - - -	26
Bandages of the Upper Extremities, - - - - -	30
Lower Extremities, - - - - -	36
Sauter's Suspension Apparatus, - - - - -	52
Fracture of Clavicle, - - - - -	63
Scapula, - - - - -	65
Acromion Process, - - - - -	67
Neck of Scapula, - - - - -	69
Neck of Humerus, above the insertion of Deltoid, - - - - -	72
Shaft of Humerus, - - - - -	75
Shaft of Humerus, below the insertion of Deltoid, - - - - -	77
Humerus above Condyles, - - - - -	79
Coronoid Process of Ulna, - - - - -	82
Olecranon of the Ulna, - - - - -	83
Neck of Radius, - - - - -	85

	Page
Fracture of Radius near centre, - - - - -	87
Shaft of Ulna, - - - - -	88
Radius and Ulna near centre, - - - - -	90
Lower ends of Radius and Ulna, - - - - -	92
Fingers, - - - - -	94
Great Trochanter of Femur, - - - - -	95
Neck of Femur, - - - - -	96
Femur below the Trochanter Minor, - - - - -	99
Shaft of the Femur, - - - - -	103
Femur above the Condyles, - - - - -	104
Patella, - - - - -	105
Tibia and Fibula, - - - - -	107
Fibula, with Dislocation of Tibia, - - - - -	111
Malleolus Internus, - - - - -	113
Positions of the Bistoury, - - - - -	115
Sutures, - - - - -	117
Ligatures of the Arteries, - - - - -	119
Amputations, - - - - -	140
Excision of the Joints, - - - - -	154
Trephining, - - - - -	159
Tracheotomy, - - - - -	161
Œsophagotomy, - - - - -	162
Operations on the Eye, - - - - -	164
Cataract, - - - - -	165
Artificial Pupil, - - - - -	170
Fistula Lachrymalis, - - - - -	171
Ectropium, - - - - -	173
Entropium, - - - - -	173
Trichiasis, - - - - -	174
Nasal Polypi, - - - - -	174
Harelip, - - - - -	175
Extirpation of the Breast, - - - - -	178
Paracentesis Abdominis, - - - - -	179
Hernia, - - - - -	180
Fistula in Ano, - - - - -	184
Lithotomy, - - - - -	185
Lithotriety, - - - - -	190

INDEX

TO

ILLUSTRATIONS.

Nos.		Plate. Fig.
1 to 11.	Dressings and rollers, - - - - -	I.
12	22. Rollers and bandages, - - - - -	I.
23	32. Bandages, - - - - -	II.
33	47. Bandages and splints, - - - - -	III.
48	54. Dressings for fractures, - - - - -	IV.
55	71. do. do. - - - - -	V.
72	Fracture of clavicle, - - - - -	VII.
73	Fracture of scapula, - - - - -	VIII.
74	Fracture of the acromion process of the scapula, -	IX.
75	of the neck of scapula, - - - - -	X.
76	Fracture of neck of humerus, - - - - -	XI. 1.
77	Posterior view of scapula, - - - - -	XI. 2.
78	Fracture of shaft of humerus above the insertion of the deltoid muscle, - - - - -	XII. 1.
79	Posterior view of scapula, - - - - -	XII. 2.
79	Fracture of shaft of humerus below the insertion of deltoid, - - - - -	XIII.
80	Fracture of humerus above condyles, - - - - -	XIV. 1.
81	Dislocation backward of radius and ulna, - - -	XIV. 2.
82	Fracture of coronoid process of ulna, - - - - -	XV. 1.
83	olecranon, - - - - -	XV. 2.
84	neck of radius, - - - - -	XVI. 1.
85	radius near centre, - - - - -	XVI. 2.
86	shaft of ulna, - - - - -	XVII. 1.
87	radius and ulna, - - - - -	XVII. 2.
88	lower ends of radius and ulna, - - - - -	XVIII. 1.
89	Appearance of wrist after fracture, - - - - -	XVIII. 2.
90	Fractures of the fingers, - - - - -	XVIII. 3.
91	Fracture of the great trochanter, and of femur, -	XIX.
92	neck of femur, - - - - -	XX.
93	94. femur below the trochanter minor, - - - - -	XXI.
95	shaft of femur, - - - - -	XXII.
96	98. femur above the condyles, - - - - -	XXIII.
99	101. patella, - - - - -	XXIV.

Nos.		Plate. Fig.
102 to 104.	Fractures of the tibia and fibula, - - -	XXV.
105	of fibula, - - -	XXVI. 1.
106	malleolus internus, - - -	XXVI. 2.
107	119. Positions of bistoury, - - -	XXVII.
120	124. Sutures, - - -	XXVIII.
125	132. Instruments for aneurism, - - -	XXVIII.
133	Incisions for aneurism, - - -	VI.
134	Arteries shown in the figure, - - -	XXIX.
135	142. Anatomical relations of arteries, - - -	XXX.
143	149. " " " - - -	XXXI.
150	Amputation of phalanges, - - -	XXXII. 1.
151	forearm, - - -	XXXII. 2.
152	wrist, - - -	XXXIII. 1.
154	arm at joint, - - -	XXXIII. 2.
155	hip joint, - - -	XXXIV.
156	tarsus, - - -	XXXV. 2.
157	Excision of radius, - - -	XXXV. 1.
158	humerus at neck, - - -	XXXVII. 1.
159	condyles of humerus, - - -	XXXVII. 2.
160	176. Instruments for amputation, - - -	XXXVI.
177	187. Trephining, - - -	XXXVIII.
188	Tracheotomy, - - -	XXXIX. 1.
189	Œsophagotomy, - - -	XXXIX. 2.
190	224. Instruments for cataract, - - -	XL.
225	233. Cataract, - - -	XLI.
234	Extraction of the lens, - - -	XLII. 2.
235	Artificial pupil, - - -	XLII. 3.
236	Fistula lachrymalis, - - -	XLII. 1.
237	245. Operations on the eye, - - -	XLIII.
246	249. Extraction of nasal polypi, - - -	XLIV.
250	256. Harelip, - - -	XLV.
257	Extirpation of breast, - - -	XLVI. 1.
258	Paracentesis abdominis, - - -	XLVI. 2.
259	260. Strangulated hernia, - - -	XLVII.
261	262. Umbilical hernia, - - -	XLVIII.
262	263. Fistula in ano, - - -	XLVIII.
264	Lithotomy, - - -	XLIX.
265	Operation, - - -	L.
266	290. Lithotrixy instruments, - - -	LI.
291	295. Operation of Lithotrixy, - - -	LII.

HARPER & BROTHERS

HAVE RECENTLY PUBLISHED,

SURGERY ILLUSTRATED. Compiled from the works of CUTLER, HIND, VELPEAU, and BLASIUS. By A. SIDNEY DOANE, A. M., M. D., with two hundred and eighty Illustrations, contained in fifty-two plates. pp. 200.

MIDWIFERY ILLUSTRATED. Translated from the French of J. P. MAYGRIER, by A. SIDNEY DOANE, A. M., M. D., with eighty-two plates. New edition. pp. 168.

THE STUDY OF MEDICINE. BY JOHN MASON GOOD, M. D., F. R. S. Improved from the Author's Manuscripts, and by Reference to the latest Advances in Physiology, Pathology, and Practice. BY SAMUEL COOPER, Prof. Surg. in Univ. London. Sixth American, from the last English Edition. With Notes, by A. SIDNEY DOANE, A. M., M. D. To which is prefixed, a Sketch of the History of Medicine, from its Origin to the Commencement of the Nineteenth Century. By J. BOSTOCK, M. D., F. R. S. 2 vols. 8vo. pp. 1400.

THE PHILOSOPHY OF LIVING ; or The Way to Enjoy Life and its Comforts. By CALEB TICKNOR, A. M., M. D. 18mo.

HOOPER'S MEDICAL DICTIONARY. From the last London Edition. With Additions, by S. AKERLY, M. D. 8vo.

COOPER'S SURGICAL DICTIONARY. In 2 vols. 8vo. Greatly enlarged.

THEY HAVE FOR SALE,

A MANUAL OF GENERAL, DESCRIPTIVE, AND PATHOLOGICAL ANATOMY. By J. F. MECKEL. Translated from the French of JOURDAN & BRESCHET, by A. SIDNEY DOANE, A. M., M. D. 3 vols. 8vo. pp. 1600.

A TREATISE ON TOPOGRAPHICAL ANATOMY ; or The Anatomy of the Regions of the Human Body. By PH. FRED. BLANDIN. Translated from the French by A. SIDNEY DOANE, A. M., M. D. 1 vol. 8vo. With a 4to. vol. of Plates. pp. 400.

CLINICAL LECTURES ON SURGERY. Delivered at Hotel Dieu, in 1832, by BARON DUPUYTREN. Translated from the French by A. SIDNEY DOANE, A. M., M. D., 1 vol. 8vo. pp. 312.

A MEDICAL AND TOPOGRAPHICAL HISTORY OF THE CHOLERA. By SCOUTETTEN. With a Report read at the Royal Academy of Medicine, at Paris, in 1831. Translated from the French by A. SIDNEY DOANE, A. M., M. D. With a Map. 1 vol. 8vo. pp. 100.

A TABLE OF THE ARTERIES OF THE HUMAN BODY. Translated from the French of CHAUSSIER. by A. SIDNEY DOANE, A. M., M. D. With the French and German Synonymes.

IN PRESS,

ANATOMY ILLUSTRATED. Compiled from the Works of CHALDINI, CLOQUET, TIEDEMANN, and others. By A. SIDNEY DOANE, A. M., M. D.

A TREATISE ON THE THEORY AND PRACTICE OF MEDICINE AND SURGERY. By L. C. ROCHE, and J. L. SANSON. Translated from the French, with Notes, by A. SIDNEY DOANE, A. M., M. D.



23. X. 116

COUNTWAY LIBRARY OF MEDICINE

RD
32
D65

RARE BOOKS DEPARTMENT

