

**Mastoid abscesses and their treatment / by A. Broca and F. Lubet-Barbon ;  
tr. and ed. from the French by Henry J. Curtis.**

**Contributors**

Broca, Auguste, 1859-1924.  
Lubet-Barbon, Fernand, 1857-  
Francis A. Countway Library of Medicine

**Publication/Creation**

London : Lewis, 1897.

**Persistent URL**

<https://wellcomecollection.org/works/jf2q7vjr>

**License and attribution**

This material has been provided by This material has been provided by the Francis A. Countway Library of Medicine, through the Medical Heritage Library. The original may be consulted at the Francis A. Countway Library of Medicine, Harvard Medical School. where the originals may be consulted. This work has been identified as being free of known restrictions under copyright law, including all related and neighbouring rights and is being made available under the Creative Commons, Public Domain Mark.


You can copy, modify, distribute and perform the work, even for commercial purposes, without asking permission.

**wellcome  
collection**

Wellcome Collection  
183 Euston Road  
London NW1 2BE UK  
T +44 (0)20 7611 8722  
E [library@wellcomecollection.org](mailto:library@wellcomecollection.org)  
<https://wellcomecollection.org>



BOSTON  
MEDICAL LIBRARY  
8 THE FENWAY




29 10 10

MASTOID ABSCESSSES

AND

THEIR TREATMENT.



# MASTOID ABSCESSSES

AND

## THEIR TREATMENT

BY

A. BROCA, M.D.

CHIRURGEON DES HÔPITAUX DE PARIS, PROFESSEUR AGRÉGÉ À LA FACULTÉ  
DE MÉDECINE, MEMBRE DE LA SOCIÉTÉ DE CHIRURGIE

AND

F. LUBET-BARBON, M.D.

ANCIEN INTERNE DES HÔPITAUX DE PARIS

TRANSLATED AND EDITED FROM THE FRENCH

BY

HENRY J. CURTIS

B.S. & M.D., LOND.; F.R.C.S., ENG.

ASSISTANT TO THE PROFESSOR OF PATHOLOGY, UNIVERSITY COLLEGE,  
ASSISTANT IN THE EAR AND THROAT DEPARTMENT, UNIVERSITY  
COLLEGE HOSPITAL, LONDON

WITH ELEVEN COLOURED ILLUSTRATIONS.

LONDON

H. K. LEWIS, 136 GOWER STREET W.C.

1897




MASTOID ABSCESSES

29 8 26

8075

LONDON:

H. K. LEWIS, 136 GOWER STREET, W.C.



TO

DR. GRAHAM LITTLE,

ASSISTANT PHYSICIAN TO THE EAST LONDON HOSPITAL  
FOR CHILDREN, SHADWELL,

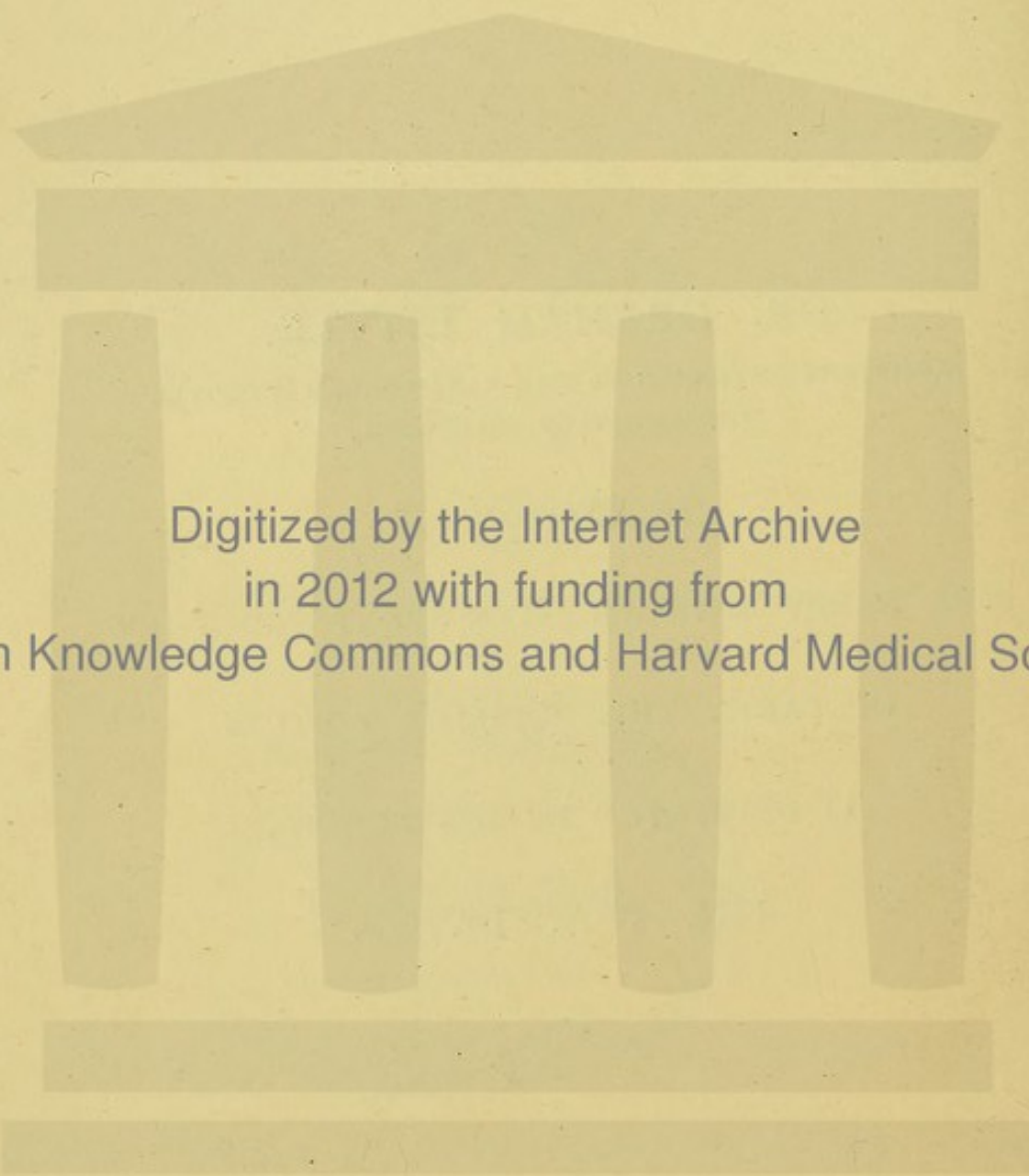
*In Memory of*

THE HAPPY DAYS WE HAVE SPENT TOGETHER

IN PARIS, THIS ENGLISH EDITION

IS DEDICATED BY HIS FRIEND,

THE TRANSLATOR.



Digitized by the Internet Archive  
in 2012 with funding from  
Open Knowledge Commons and Harvard Medical School

## TRANSLATOR'S PREFACE.

---

THE present volume is a translation of a memoir entitled "Les Suppurations de l'Apophyse Mastoïde et leur traitement," which was published in 1895, after having been awarded the Prix Meynot by the French Academy of Medicine in 1894.

The authors, Professor A. Broca—the distinguished son of a most distinguished sire—and Dr. F. Lubet-Barbon, having written such an admirably clear account of the subjects included under the above title, from clinical, pathological, and therapeutical standpoints, with careful descriptions in detail of the more modern operations, such as those of Schwartz and Staëke, it appeared to me well worthy of translation into English. I have to express my best thanks for the authors' very courteous permission to do so. At the same time, I beg to thank the French publisher, M. Steinheil, for so kindly allowing the use of five blocks illustrating the instruments used, and referred to, by the authors.

The eleven coloured illustrations are from an ex-

tremely valuable paper entitled "Two Cases of Disease of the Middle Ear, with Remarks on the Anatomy of the Mastoid Antrum," published in the "International Clinics," Vol. II., Sixth Series. This contains the substance of a Clinical Lecture delivered at the University College Hospital, London, by Mr. Rickman J. Godlee, Surgeon to Her Majesty's Household, Surgeon to University College Hospital, etc., to whom I must again express my sincere obligation for permission to utilise his most beautiful drawings, from preparations which were made originally by Professor G. D. Thane, President of the Anatomical Society of Great Britain and Ireland, for the section on "Superficial and Topographical Anatomy," in the last edition of "Quain's Anatomy." Their clearness and accuracy, from an anatomical point of view, will, I trust, materially assist the reader in following the authors' descriptions of this most important region.

For the convenience of English readers unaccustomed to French measures, fresh blocks for the temperature charts have been made, and an additional one engraved to indicate the correspondence between French centimetres and English inches, so that the one may be converted into the other at a glance. An Index has also been prepared for the English Edition.

# CONTENTS.

---

	PAGE
INTRODUCTION . . . . .	I

## CHAPTER I.

MASTOID ABSCESSSES . . . . .	6
------------------------------	---

### SECTION

1. SKETCH OF THE PATHOLOGICAL ANATOMY AND PHYSIOLOGY	6
2. SYMPTOMS . . . . .	25
3. DIAGNOSIS . . . . .	50
4. INDICATIONS FOR TREATMENT . . . . .	80
5. TREATMENT OF THE ACUTE FORMS OF MASTOIDITIS . . . . .	III

## CHAPTER II.

MASTOID FISTULÆ . . . . .	145
---------------------------	-----

### SECTION

1. PHYSICAL SIGNS AND BONY LESIONS . . . . .	147
2. INDICATIONS FOR TREATMENT AND OPERATIVE TECHNIQUE	165
3. INTRACRANIAL COMPLICATIONS . . . . .	209

## CHAPTER III.

	PAGE
CHRONIC SUPPURATIVE INFLAMMATIONS OF THE MIDDLE EAR, WITH LATENT MASTOIDITIS . . . . .	217

## CHAPTER IV.

RESULTS . . . . .	229
-------------------	-----

*Cases—*


(A) ACUTE MASTOIDITIS, WITH ACUTE OTITIS MEDIA . . . . .	229
(B) ACUTE DIFFUSE OSTEITIS OF THE TEMPORAL BONE . . . . .	237
(C) MASTOIDITIS, WITH CHRONIC OTITIS MEDIA—COMPLETED . . . . .	239
(D) MASTOIDITIS, WITH CHRONIC OTITIS MEDIA—STILL UNDER TREATMENT . . . . .	247

A. <i>General Statistics</i> . . . . .	252
--	-----

B. <i>Results According to the Nature of the Lesion</i> . . . . .	253
---	-----

1. MASTOID COMPLICATIONS OF ACUTE OTITIS MEDIA . . . . .	254
2. MASTOID COMPLICATIONS OF CHRONIC OTITIS MEDIA . . . . .	255
3. DIFFUSE OSTEITIS OF THE TEMPORAL BONE . . . . .	258
4. EBURNATION (SCLEROSIS) OF THE MASTOID PROCESS . . . . .	258

INDEX . . . . .	259
-----------------	-----






## NOTE.

---

PLATES I. to IV. are from drawings kindly lent by R. J. Godlee, Esq., M.S. (Lond.), F.R.C.S. (Eng.).

The Canal of the Antrum, or "Aditus ad Antrum," as it is termed in the text, is the passage between the Antrum and the Attic, the apex of the latter being indicated in Plates I. and II. by the name "Epitympanic Recess."






PLATE I.

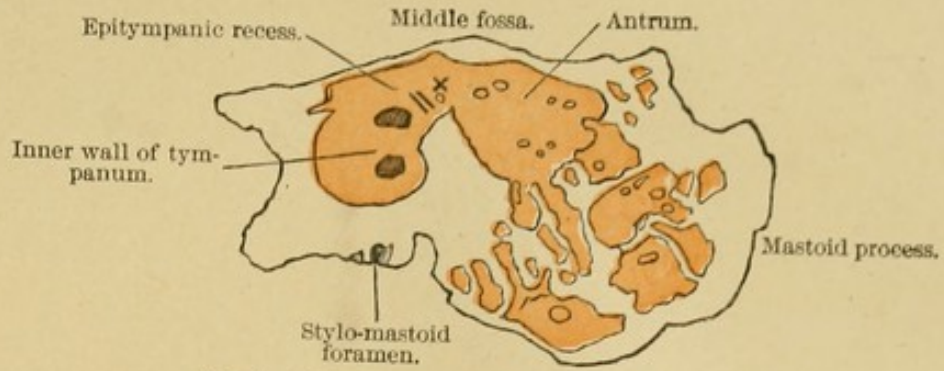


FIG. 1.—Sagittal section of left temporal bone.

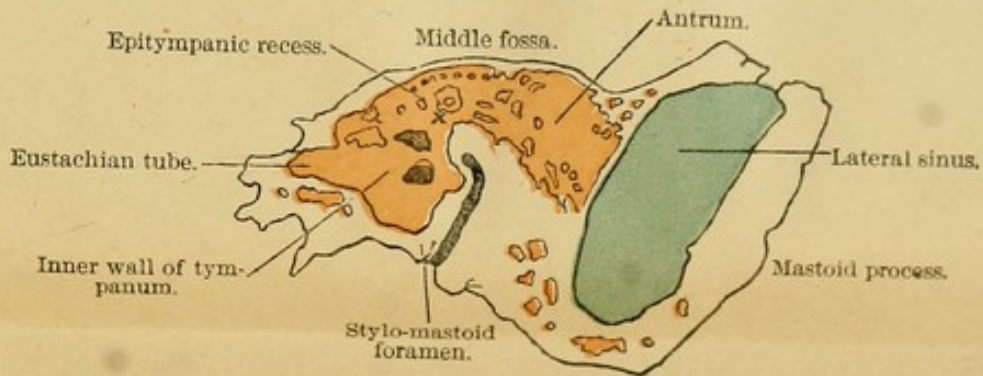


FIG. 2.—Sagittal section of left temporal bone made internally to that shown in Fig. 1.

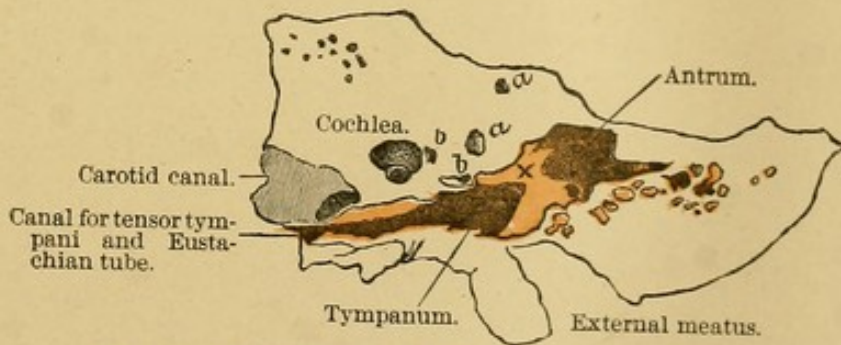




FIG. 3.—Oblique section of left temporal bone in direction of Eustachian tube. *aa*, superior semicircular canal; *bb*, aqueduct of Fallopius.

In each drawing X is placed over the prominence formed by the external semicircular canal and just above the elevation caused by the aqueductus Fallopii.








PLATE II.

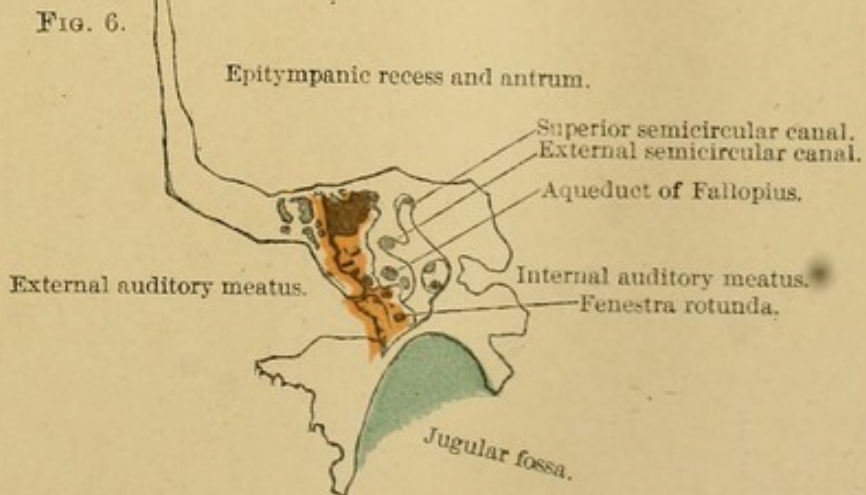
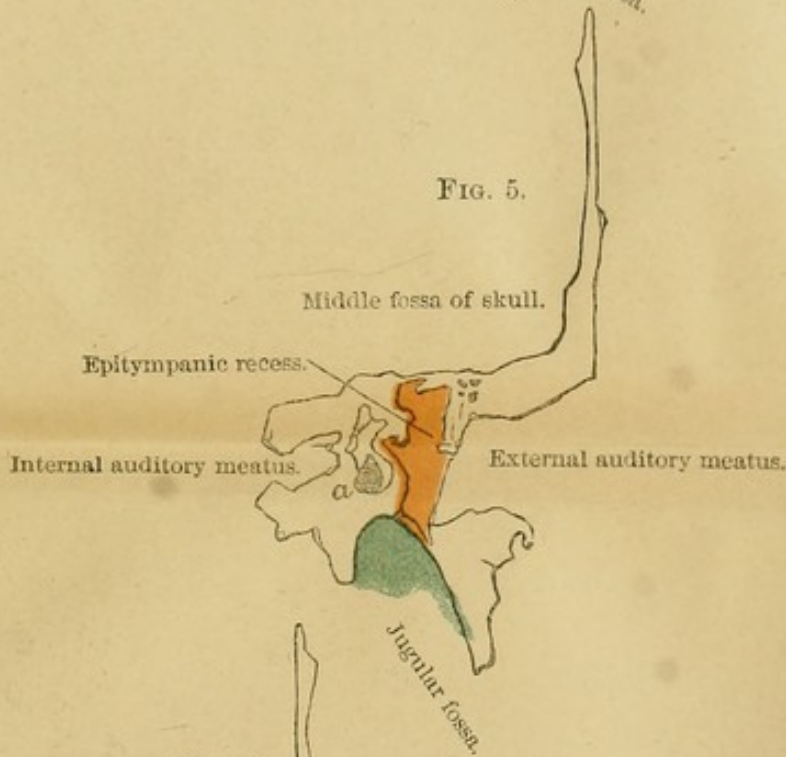
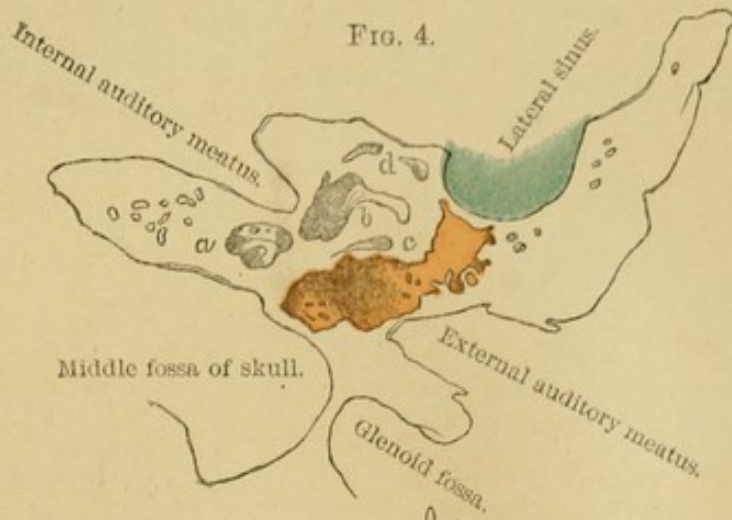




FIG. 4.—Horizontal section of left temporal bone. *a*, cochlea; *b*, vestibule; *c*, aqueduct of Fallopius.

FIG. 5.—Frontal section of right temporal bone looking forward. *a*, vestibule.

FIG. 6.—Frontal section of right temporal bone looking backward.









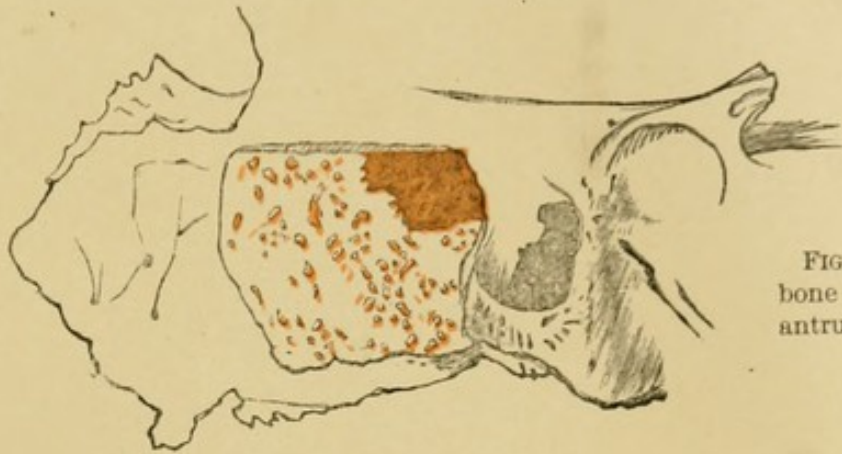


FIG. 7.—Part of the right temporal bone of a child, showing mastoid, antrum, and small mastoid cells.

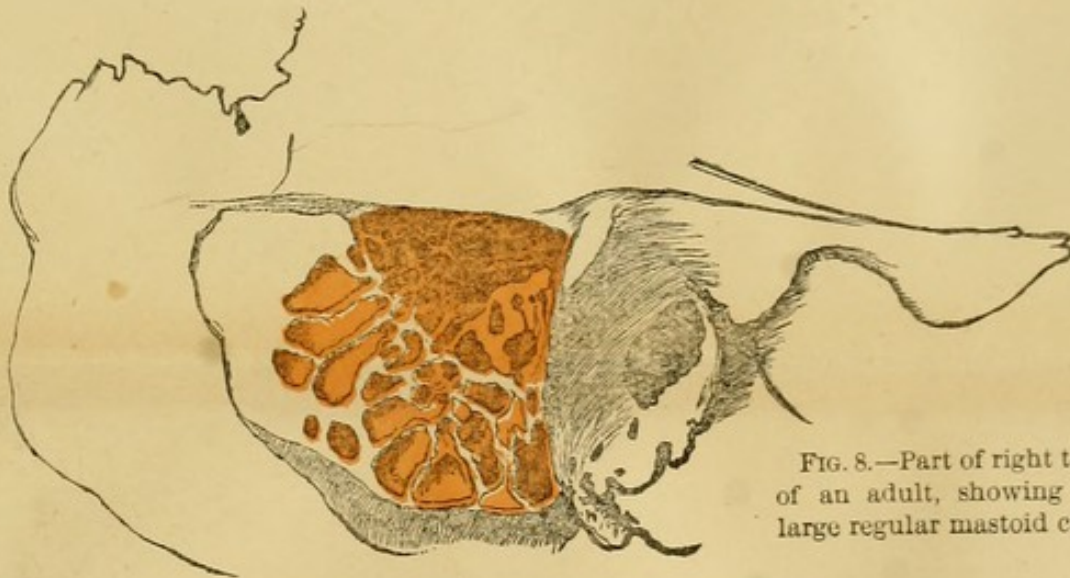


FIG. 8.—Part of right temporal bone of an adult, showing antrum and large regular mastoid cells.

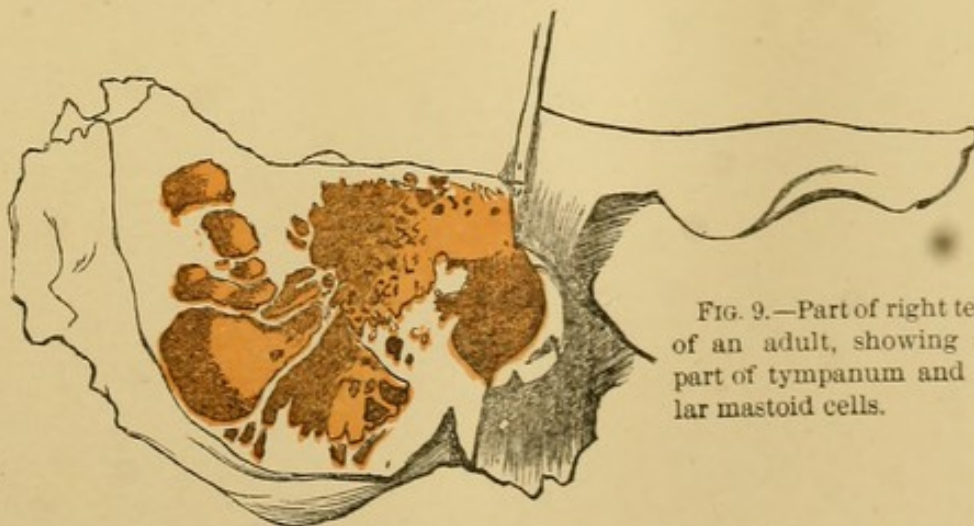




FIG. 9.—Part of right temporal bone of an adult, showing antrum and part of tympanum and large irregular mastoid cells.







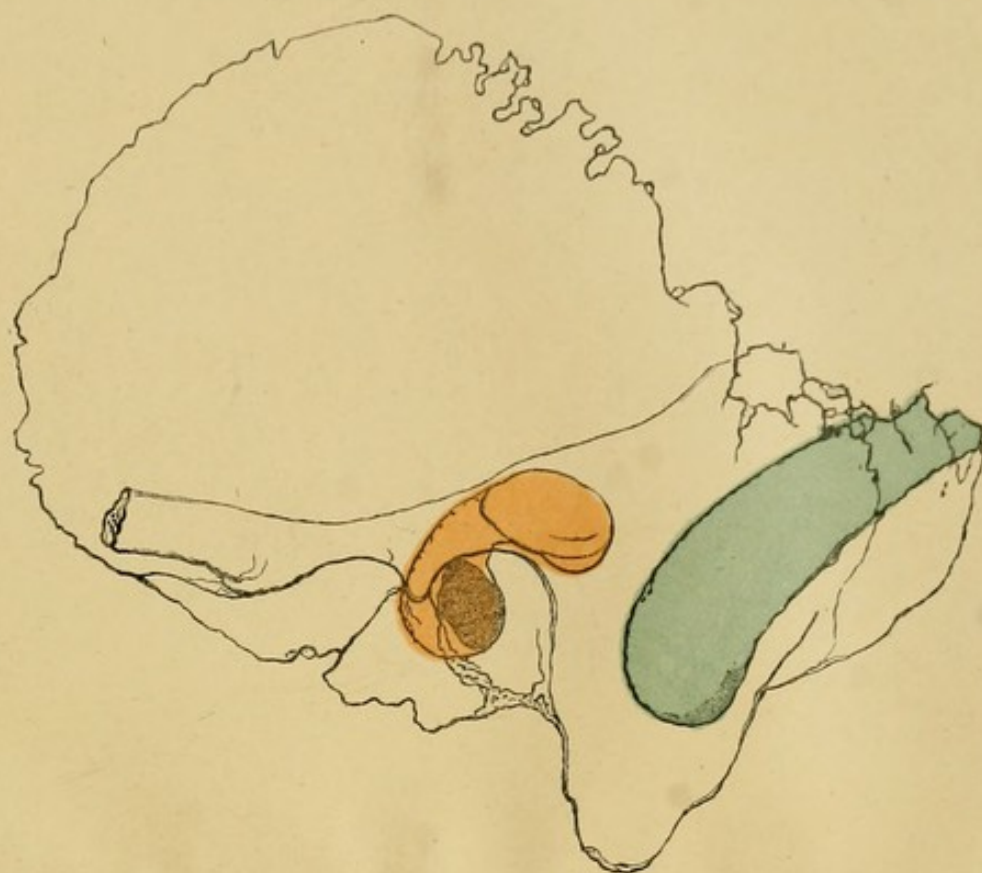


FIG. 10.—Left temporal bone, outer aspect, showing relations of tympanum, antrum, and lateral sinus to the surface.

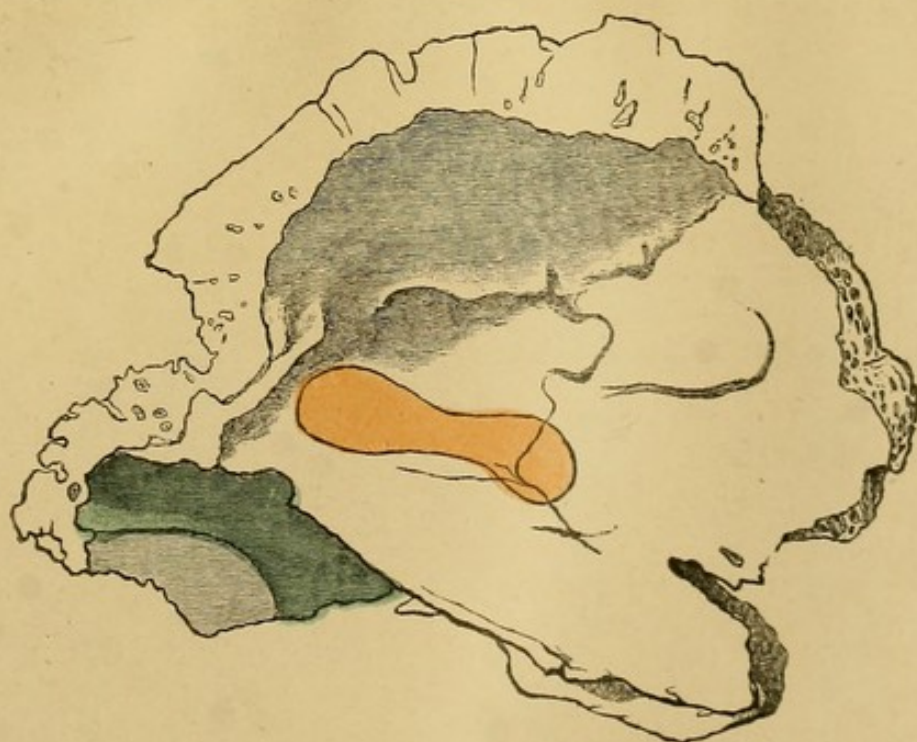

FIG. 11.—Inner and upper aspect of left temporal, showing relations of tympanum and antrum to middle fossa and of lateral sinus to posterior fossa.






PLATE V.

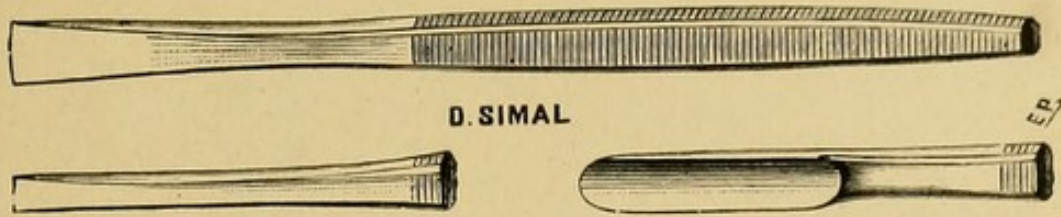


Fig. 1.—Chisels and Gouge.

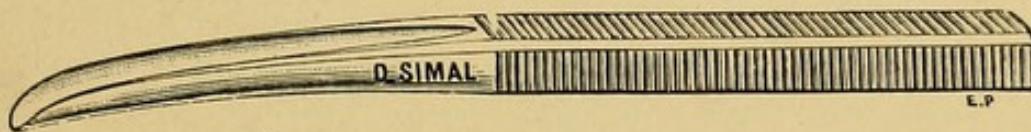

Fig. 2.—Stacke's Gouge.

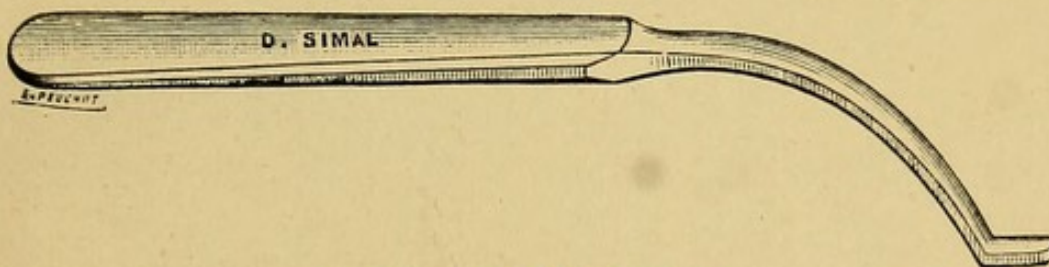


Fig. 3.—Stacke's Protector.

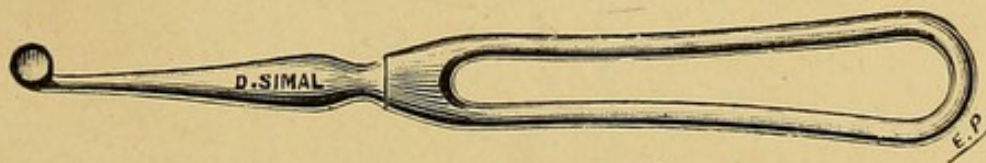


Fig. 4.—Sharp Spoon, or Curette, for the Mastoid.



Fig. 5.—Small Sharp Spoon, or Curette, for the Tympanic Cavity.




PLATE VI.

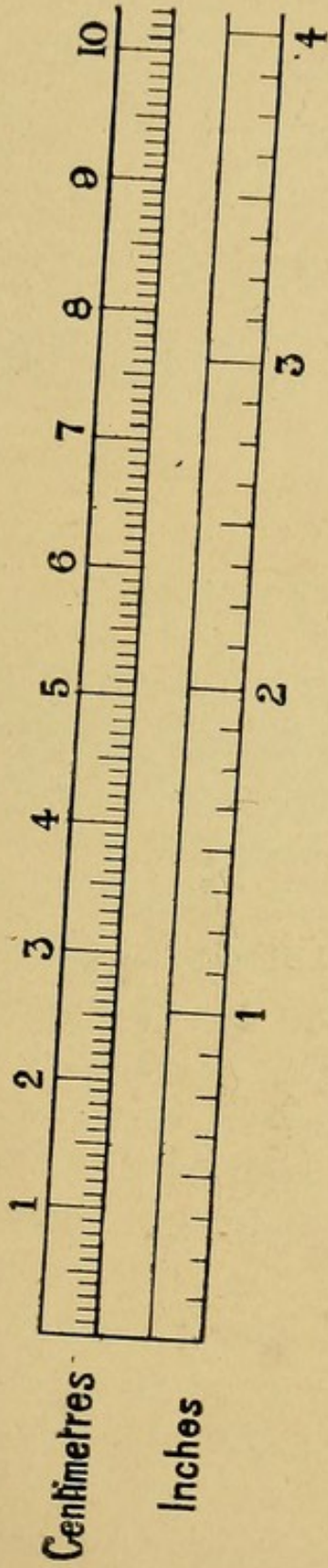



Plate VI. has been inserted so that the French measurements of length mentioned in the text can be converted at a glance into the corresponding fractions of inches.

1 Centimetre (1 cm.) = 10 Millimetres (10 mm.), and is equivalent to a little more than  $\frac{3}{8}$  inch.

$\frac{2}{3}$  Centimetres = 1 inch (approximately).





# MASTOID ABSCESSSES.

---

## INTRODUCTION.

THE surgical treatment of the mastoid is at the present moment engaging the attention of both general and aural surgeons. From year to year operations multiply, methods are perfected, the indications for them become more precisely defined, and there are better results. Several important discussions on this subject have taken place at Congresses and Otological Societies in France, America, and Belgium. So we think it may be useful if we, in turn, state the practical conclusions to which our own operations—amounting at the present time to 146, performed upon 129 patients—have led us.

In the account of our investigations it would doubtless have been very interesting to have contrasted the differences which may exist between the various forms of mastoiditis, according to their cause and the organism which gave origin to them.

One knows, indeed, that various micro-organisms infect the middle ear, and set up there—either in a

state of purity or in association with others—lesions, the course of which is probably not always the same.

But if the bacteriology of the middle ear, especially in the hands of Netter, Zaufal, and Moos, has given most important results theoretically, in practice the question cannot yet be considered from this point of view.<sup>1</sup>

Indeed, we are ourselves not uninterested in the bacteriological data; and in a good number of the abscesses which were operated on before the fistula stage, we cultivated the pus.

We have thus made some interesting observations, and we shall mention, for instance, a mastoid abscess where we found a pure culture of the coli bacillus.

But the facts are not yet sufficiently numerous—ours, as in the case of those of other writers—to allow us to sketch out even a classification founded upon such data; and, remembering the normal communication of the tympanum with the exterior, by means of the Eustachian tube, this is the more so, as infection is sometimes mixed, even when the membrana tympani is not perforated, and as this occurs most often when perforation has been effected.

In the same way, we do not believe that we can make an etiological classification, according to the general infectious disease in the course of which the ear complication has arisen—one knows with what frequency arise secondary inflammations of the middle ear and mastoid process.

<sup>1</sup> The literature on this point has been collected, in a quite recent memoir, by M. Lermoyez and F. Helme, entitled "Les Staphylocoques et l'Otorrhée," *Ann. des mal. de l'or. et du lar.*, January 1895, p. 35.

True, it has been observed that there are some slight peculiarities in the course followed by the inflammations of the middle ear and mastoid which follow measles, scarlet fever, and influenza ; but at the present time these are not sufficient to enable us to give separate descriptions of them. We will even add that, in our opinion, it would be astonishing if in the future these distinctions can be shown to have a practical value.

Middle ear affections, in fact, are not specific complications of the diseases we have just enumerated, but rather secondary infections by pyogenic organisms, which inhabit the pharynx, where they grow readily, owing to the presence of lymphoid tissue, which shelters them : spreading from this, they often infect the middle ear, favoured by the morbid conditions previously mentioned.

We are compelled, therefore, to retain the old classification, based upon the external condition of the lesions, upon the more or less acute evolution, clinically, and associated with more or less important and more or less old otitis media.

We only consider, in this work, the inflammations of the mastoid following suppurations of the middle ear, and we leave untouched those lesions which do not originate in the ear itself, only dwelling upon them in passing, for the purpose of differential diagnosis.

As the result of this limitation to our subject, we shall perhaps be blamed in that we have not expatiated upon cholesteatoma : to this we reply in advance, that, however classical it may have become, we do not



know if the theory of Bezold, that this disease originates in the ear, is correct.

We shall confine ourselves, then, to inflammations properly so called. In order to study the inflammations of the mastoid following middle ear disease, some subdivisions arise, in which it is necessary to take into account the nature and the degree of the disease in the ear quite as much as that in the mastoid. If one examines first of all the mastoid region, the first thing to strike the eye is as follows: the skin covering the process is intact, or fistulous. When no fistula exists, two conditions have to be distinguished—according as the otitis in point is acute, or it is a question of a downright chronic otorrhœa; and from this point of view the mastoid complications will be sometimes acute, with or without abscess, sometimes subacute, sometimes chronic or even latent.

The fistula, which is the almost constant termination of mastoid abscesses left to themselves, or treated by simple incision, does not possess here the importance which it acquires in other suppurations occurring in a completely closed cavity: then the surgeon acts with more security and a better result, if he finds himself in the presence of a subcutaneous abscess, where he can avoid the mixed infections—infections realised when the patient comes for advice about an abscess already fistulous. Here, on the contrary, we repeat, that when the disease is subcutaneous it communicates, or at least it has communicated, with the exterior by means of the middle ear. A mastoid abscess is, so to say, a “blind internal fistula,” and its opening externally merely changes it into a complete fistula.

One will not be astonished, then, that the course to be pursued depends much less upon the presence or absence of a mastoid fistula than upon the duration and severity of the symptoms, and the anatomico-pathological observations upon the condition of the mastoid, the antrum, the middle ear and its ossicles—observations made either in advance, by clinical examination, or in course of the operation itself.

But, for purposes of description especially, we shall retain the division into mastoid abscesses and fistulæ, indicating when dealing with the former the treatment suited to acute cases, and in connection with the latter that for the relief of chronic cases.

Following this, a short chapter will be devoted to the latent mastoid affections which complicate the chronic inflammations of the middle ear.

After these entirely practical articles, we shall analyse our statistics and give an abstract of our cases. More than one hundred of the latter are derived from the Hospital Trousseau, where Professor Lannelongue has been good enough to entrust his Out-patient Department to one of us for more than two years. It is there that, operating often together, we have been able to collect our special observations.

Thanks to our master, we have been able to acquire a thorough clinical experience, and we are grateful to him for his liberality.

## CHAPTER I.

### *MASTOID ABSCESSSES.*

#### § I. SKETCH OF THE PATHOLOGICAL ANATOMY AND PHYSIOLOGY.

WE have no intention here to enter into a long account of the normal or pathological anatomy ; but we should not be able to come to any distinct and practical conclusions if we did not point out, by means of a brief *résumé*, what is the course of these affections.

The cavity of the tympanum and the mastoid cells, connected by the canal of the antrum, the petro-mastoid canal of Sappey, or "aditus ad antrum,"<sup>1</sup> form really a single cavity, like a wallet,<sup>2</sup> the three segments of which have a very variable importance, according as one regards them from the physiological or the pathological point of view.

Physiologically, indeed, the tympanum is, in this system of cavities, a particularly important cell, for, being provided with the ossicles, this is in the path of the sound-waves ; it is of service, therefore, for audition. Pathologically, its importance is equally great : patho-

<sup>1</sup> See Plate I. Figures 1 and 2.

<sup>2</sup> This continuity has been well demonstrated by Tillaux, *Traité d'anat. topogr.*, 6<sup>e</sup> éd., p. 123 : Paris, 1890.

genically—first, for infections, whether they have proceeded from the Eustachian tube or from a ruptured tympanic membrane, commence in it; practically, because disease of the ossicles may necessitate special and more or less complex remedial measures.

But in many respects the tympanum is, from the point of view of inflammations of the system of cells of the middle ear, far less important than the collection of the other petro-mastoid cells; and this because of the much smaller size of the former compared with the latter. Let us see then, in general, how the cavities into which the mastoid process is hollowed out are constituted. One finds, first of all, behind the tympanum, in the upper part of the mastoid process, an air-cell called the mastoid antrum. It is placed behind and a little above the orifice of the external auditory meatus, at the level of the articulation of the incus with the head of the malleus (Schwartz). Its floor is situated a little below a process, which bounds the external auditory meatus at one spot, and is formed by the junction of the squamous and petrous portions of the temporal bone (supra-meatal spine). It is the only air-cell which exists at birth and during the first months; and when we come to study the question of operation, we shall see what consequences result from this.

But, little by little,—and this development must be compared up to a certain point with that of the sinuses of the face,<sup>1</sup>—cells become hollowed out around the antrum, their number being very variable, it is true; so that Zuckerkandl, whose researches have been made

<sup>1</sup> Upon this question see Tillaux, *Traite d'anat. topogr.*, 6<sup>e</sup> éd., p. 134: Paris, 1890.

known by Professor Duplay, has established the following types :—

1. In thirty to forty per cent. of the cases, the mastoid shows numerous cavities (*processus mastoïdeus pneumaticus*).

2. In twenty per cent. of the cases, one does not find air-cells below the antrum, but only a spongy substance, analogous to the diploë, containing vessels and fatty tissue; sometimes, even, the mastoid is eburnated (*processus diploëticus*).

3. In forty to fifty per cent. of the cases, these two structures are associated; and, besides the air-cavities, there exists diploëic substance, especially in the antero-superior segment of the mastoid.

The diploëic type, where the mastoid cells are practically reduced to the antrum, or nearly so, is therefore rare; and if we except young children, among whom it is the rule, it is, according to our observations, even more rare than Zuckerkandl and Politzer consider.

Almost always; then, in the adult, the mastoid is hollowed out into numerous cavities, which communicate with one another, and with the antrum, by passages, which are sometimes, it is true, very fine, exactly like needle-punctures bored through thin partitions. The mastoid is, then, in short, a sort of sponge,<sup>1</sup> all the cells of which finally open into the antrum, and the axis of all these cells is directed towards the antrum, like radii towards the centre of a sphere. From this centre some are directed in front, towards the external auditory meatus, which they close and limit in its postero-superior portion (border-cells); others,

<sup>1</sup> Cp. Plate III.

which are very variable in size, are directed straight downwards (large air-cells); others, altogether behind and below, are directed towards the occiput; and, finally, there are others, behind and above, passing to unite with those of the squamous portion. Does not this arrangement resemble the spokes of a wheel about a hub?

But all these air-cells and all these partitions are lined by a mucous membrane identical with that of the tympanum—*i.e.*, rich in glands, and secreting abundantly. One can understand, then, that, relatively to that of the tympanic cavity, the superficial area of the mastoid cells is immense. In fact, except for some small folds which occur about the ossicles, the mucous membrane of the middle ear simply lines the six walls. In the air-cells, on the contrary, it is multiplied to a considerable extent by the incomplete partitions, exactly as the leaves of copper turnings which fill up the Leyden-jar offer an extraordinarily multiplied surface for accumulation.

With these preliminary statements, let us now see how the infections of the middle ear behave. These infections arrive via the Eustachian tube, and naturally they first reach the cavity of the tympanum—*i.e.*, the first cavity, or *air-cell*, which they meet with in their course. But, according to Professor Tillaux,<sup>1</sup> in nearly all the cases of acute inflammations of the ear the canal of the antrum, the antrum, and the mastoid cells are successively attacked. Previously, the proof of this was afforded us clinically by its being shown that almost always there was from the outset of these

<sup>1</sup> *Loc. cit.*, p. 132.

cases of otitis a certain amount of tension, discomfort, and pain—spontaneous, or on pressure—all over the mastoid.

With these observations we may compare those of Politzer,<sup>1</sup> which he has made upon the cadaver. This author writes, in fact: "In all the cases of suppurative otitis media in which there did not exist during life any trace of inflammation of the mastoid process, neither spontaneous pains, nor tenderness on pressure, and where the autopsy was made, we constantly found pus in the mastoid cells."

In explanation of the pathology, Politzer adds: "This is readily understood, if we remember that each time a suppuration occurs in the cavity of the tympanum, gravity causes the pus to penetrate into the mastoid during the position of repose of the patient." He moreover admits the propagation of the inflammation by continuity of the mucous membranes; in our opinion this second factor is much the more important.

So long as the canal of the antrum remains quite permeable, the pus contained in the mastoid air-cells flows away into the tympanum when too full, and thence to the exterior through the perforation of the membrana tympani; and it is even probable that in the otorrhœa of acute otitis media the discharge is in greater part from the air-cells and not from the tympanum.<sup>2</sup> Does not this result from what we have said

<sup>1</sup> Politzer, *Ann. des mal. de l'or. et du lar.*, 1892, No. 5, p. 317. *Disc.*, p. 382.

<sup>2</sup> This opinion, which, in our experience, is absolutely in accordance with the facts of the case, has already been maintained by Professor Duplay.

upon the areas of surface of the mucous membrane of air-cells compared with that of the tympanum? And there are still other important arguments.

If, for instance, a paracentesis of the membrana tympani is done to let out a purulent effusion of the middle ear, at the time only a little pus escapes; but during the following hours an abundant discharge of fluid is observed, which is from the mastoid air-cells without doubt; and if air-douches are given and repeated from time to time, one sees the pus escaping in gushes each time. Moreover, very frequently at the very time when a mastoiditis with the usual symptoms declares itself, the discharge from the external auditory meatus ceases abruptly, especially if, as sometimes but rarely happens, the perforation of the membrane cicatrises up during the onset of the mastoid abscess; this has produced an occlusion of the canal of the antrum, to the importance of which occlusion we shall return. Lastly, when there exists an acute mastoiditis accompanied by an acute otitis media with purulent discharge, it is usual after opening up the mastoid for the otorrhœa to cease; and the membrane repairs itself, without treatment of the tympanum.

We have just spoken of the occlusion of the canal of the antrum; it has, in fact, an important pathological rôle. If this canal and the perforation of the tympanic membrane are large and gaping—for, although such has been stated, the pus *never* escapes by the Eustachian tube—the mastoid cells become thoroughly emptied; their involvement is only indicated externally by slight symptoms, or not at all, and the disease can be cured without operation. But if the free discharge



of pus is interfered with, and the perforation of the tympanic membrane is too narrow, and especially if the swollen mucous membrane narrows or obliterates the *aditus*, the conditions will be found to have changed. This occlusion of the *aditus* is still more facilitated by the position of the short process of the incus in front of it. Then the products of inflammation can no longer be expelled, "the wolf will be locked up in the fold," and the characteristic symptoms of mastoiditis will be seen to start up: the infective agent, shut up in a closed cavity in the bone, will incite those conditions we are accustomed to observe— inflammatory swelling and pain—and it will tend to open externally by the passages we are about to examine.

We see, then, that sometimes—during the onset of the mastoid complication—the middle ear, left to itself, is cured, or almost so, and the perforation of the membrane closes in part, sometimes even completely. We may refer, upon this question, to our Case LIV. (p. 205). It is that of a boy, aged seven years, who was admitted into the hospital in October 1893, and who had had, at the age of fifteen months, an otorrhœa, the cause being unknown, with swelling behind the ear, which was treated by simple incision; in fifteen days the incision had cicatrised. The child, who had ever since had otorrhœa for some days every year, was brought to us at the hospital, because he had a mastoid abscess, whilst the *membrana tympani* and the hearing were perfectly sound.

What will become of pus once thus shut up in a closed space? That depends to a certain extent

upon the often varying anatomical construction of the mastoid process. Now the position of the collection of pus in the mastoid process will be in accordance with the mode of distribution of the air-cells: at the base of the process, when the antrum alone will be developed, or almost so, as is the case in young children; or in the body of the process itself, when we have the "pneumatic" type of Zuckerkandl (p. 8). But the most important thing is the direction in which the pus tends to spread, and the process by virtue of which it is propagated to a greater or less distance. The pus tries to get to the surface, almost always towards the external aspect of the mastoid, giving rise thus to the classical mastoid abscess behind the ear. Sometimes, but much more rarely, it is directed towards the internal aspect, to spread thence into the neck, along the insertions of the digastric or sterno-mastoid muscles: in our clinical study we shall have to lay stress upon this special form of mastoiditis.

But if migration in these directions is prevented, for one reason or the other, we have to face two equally dangerous alternatives. Without doubt the air-cells adjacent to the meatus afford yet another safety-valve. After having produced by their swelling what has been called the "dip" (*chute*) of the postero-superior boundary of the canal, they may become fistulous externally, and in that way the pus escapes. This is what occurred in three of our patients (Cases X., XXII., CXIX.). This route will rarely be chosen by the pus, and the infection will tend—with, unfortunately, only too great a frequency—to reach, superiorly, the level of the roof of the aditus and the middle

cerebral fossa ; and, posteriorly, to the groove of the lateral sinus.

Thence follow the gravest complications : subdural collections of pus, meningitis, cerebral abscesses, thrombosis of the lateral sinus. Often enough the bone is inflamed, rarefied, and softened in one or several of these directions. It is not uncommon to find at the bottom of a mastoid abscess, behind the ear, a spontaneous perforation, or at least a red, depressible area, into which the curette readily sinks. There is, in fact, an abscess no larger than a shirt-button. So for certain subdural collections. So, where there was no such subdural collection, in one of the cases one of us operated on with a view of arresting a meningitis already quite marked, the roof of the aditus was found rarefied, breaking away under the curette to such an extent that, after scraping the diseased bone, the dura mater was found bare to a considerable extent. In this child (Case XLVI.), the wall of the lateral sulcus was in the same condition, and the sinus likewise was also exposed.

This caries of the lateral sulcus is not very rare, since we have observed it well marked on five other occasions—once in an acute case, four times in chronic cases.

When the relations of the middle ear and its accessory parts have been examined upon the cadaver, and the thinness of the roof of the aditus and of the lateral sulcus has been noticed, and when, in operating upon the living, the lesions—often advanced—presented by the bone have been taken into account in these very dangerous regions, one is rather astonished that grave complications are not more frequent.

We have just indicated the cases in which, after having destroyed the mucous membrane, the pus perforates the bone in order to collect under the skin, or more rarely under the dura mater. In the formation of these "shirt-button" abscesses, the thickness and hardness of the cortical layer of bone which surrounds the air-cells doubtless plays a part. But in reality, this actual perforation only occurs in a minority of cases. Most frequently, when a mastoid abscess is opened, one does not find the bone actually perforated, but simply laid bare, affected by a more or less evident osteitis; and the latter attacks, in different cases, the external, internal, posterior or superior wall, being greatly influenced by the thickness of these walls. Moreover, the bands of connective tissue, the blood and lymphatic vessels, and the nerve branches can act as a guide or as passages for the migration of infectious agents. Thus, M. de Rossi<sup>1</sup> tells us that across the petro-squamous suture stretches a broad and thick layer of connective tissue, which serves to explain in part the frequency of abscesses upon the external wall of the mastoid process, sometimes with destruction of the bony tissue of this region. About the lymphatic vessels we can scarcely speak at present: we will only say that in several of our patients operated on, glandular masses, more or less extensive, occupied the upper portion of the sterno-mastoid region, below the affected mastoid process (Case XXXIII., for instance). The blood-vessels, on the contrary,

<sup>1</sup> Emilio de Rossi, "Pénétration du pus dans le crâne dans la carie du temporal, avec abcès par congestion du cou," *Ann. des mal. de l'or. et du lar.*, 1889, t. xv., p. 100.

have an undoubted importance: the arteries and veins, because around them there are sheaths of connective tissue, in which micro-organisms can wander; the veins, because, affected with phlebitis and a septic thrombosis, they are in themselves a channel for the propagation of infection. Now of the numerous vessels, the veins, especially, pass from the mucous membrane of the air-cells to the external surface of the mastoid process, passing across the superficial bony ("cortex") layer. The veins on the other side pass, in part, directly into the lateral sinus. Around these veins, and into their interior, septic mischief can spread, and hence, by means of a peri-phlebitis, superficial subperiosteal abscesses, and abscesses surrounding the lateral sinus in its groove may occur without the bone at this level being necessarily perforated.

We do not wish to discuss fully the *rôle* of these processes in the origin of intracranial complications, which we are content to enumerate. Our aim is simply to show how it is that in most cases it is insufficient merely to incise mastoid abscesses: the deeply situated intra-mastoid collection of pus will only be evacuated if the bone has been opened up, upon which one ought not to count. If this is not so, the pus will remain in the air-cells, and, after the incision of the subperiosteal abscess, will give rise to a fistula, the dangerous consequences of which we shall study further on.

In the preceding pages we have only spoken of the suppurations affecting the natural cavities of the middle ear, and it is only as a result of the spread of the pus contained in the mastoid cells that we have considered

the sub-periosteal abscesses of the mastoid process. In addition to these abscesses, others have been described which have resulted from a periostitis of the mastoid process, without infection of the air-cells being a necessary intermediary between the suppuration in the tympanic cavity and the abscess externally. The question is worth careful consideration, for one sees at once that upon its solution will depend the indication to open up or leave intact the mastoid.

In 1875 Professor Duplay devoted a remarkable research to periostitis of the temporal bone. Since then he has returned to the study of these cases of periostitic otitis, in a lecture published in the *Bulletin médical*, and in an article in the *Traité de chirurgie*.<sup>1</sup> This research is important both from the point of view of pathological anatomy, and clinically. It is solely upon these anatomical data that we shall insist here.

One knows (and we have already mentioned it) that often, under the infected and destroyed mucous membrane, the bone is more or less inflamed. Now S. Duplay informs us that "there exists a form of sub-acute otitis media which may be called a 'periostitic otitis,' for it affects both the tympanum and the bony external auditory meatus. In this form the inflammation first starts in the middle ear, and extends rapidly to the auditory meatus after complete destruction of the membrana tympani. It is also common to see the inflammation of the periosteum extend to the bony

<sup>1</sup> S. Duplay, "De la périostite du temporal, etc.," *Arch. gén. de méd.*, 1875, t. i., p. 513. "Otite ostéo-périostique," *Bulletin médical*, August 27th, 1890, p. 797. "Otite moyenne; ostéo-périostite de l'apophyse mastoïde," *Traité de chirurgie*, t. iv., p. 661 et 723: Paris, 1891.

parts which are in direct continuity with the bony auditory meatus—that is to say, the surface of the mastoid process and the squamous portion of the temporal bone. In a case of this kind, where I was able to make a post-mortem examination of the ear, I found the periosteum of the tympanum, of the auditory meatus, of the mastoid process, and of the temporal fossa detached from the subjacent bone, which presented marked vascularisation.” As regards the periostitis of the mastoid process more especially, M. Duplay adds: “The inflammation spreads from the periosteum of the middle ear and auditory meatus to that of the neighbouring regions, and principally to that of the mastoid process and temporal fossa, which is easy to understand when one considers that the bony auditory meatus is directly continuous, by its postero-superior portion, with the external surface of the mastoid process and of the temporal fossa. We cannot find an obstacle to this propagation in the insertion of the cartilaginous portion of the auditory meatus, for it is made by means of bundles of fibres more or less separated from one another, but always leaving considerable cellular spaces between them. This periostitis of the mastoid process, from the spread of a periostitis of the middle ear, is common enough in young children in whom the bony auditory meatus is hardly developed, and in whom the cavity of the tympanum is seen to be nearly on a level with the temporal bone.”

It is undeniable that there do exist cases of “periostitic otitis” which correspond exactly with the precise description we have just reproduced. We will even add that such separation of the periosteum

of septic origin may complicate a chronic otitis media of the ordinary type. For instance, one of us operated, at the Hospital Trousseau, upon a child in whom the foetid and intermittent discharge from the ear had existed for two or three years. Five weeks before admission to the hospital, the mastoid region had commenced to swell, and the child was brought to us with a fistula following upon a recent incision. The probe introduced through the meatus struck the bared posterior wall; introduced through the fistula, it touched bare bone in front; but the incision which was free and typical proved that the mastoid process retiring upon the squamous portion of the temporal bone was hard, eburnated, and not laid bare; that the abscess beneath the periosteum extended both towards the temporal fossa and the meatus. By following the probe, one was led directly into the middle ear, which was opened by Stacke's method, and in less than six weeks the child was completely cured.

CASE I.—*Chronic Otitis Media. Abscess behind the ear, without Mastoiditis. Stacke's Operation. Cure.*

Charles G.; aged  $7\frac{1}{2}$  years; admitted to the hospital September 23rd, 1893.

*History.*—This child, whose father died of an acute disease, and whose mother is quite healthy, had measles eighteen months ago; but for two or three years previously his ear had been discharging freely, though intermittently. The pus was foetid. Five weeks ago the mastoid region began to swell; the child lost his appetite; had fever, but was not delirious; and on September 16th he was taken to the St. Louis Hospital,



where the abscess was opened. The incision remaining fistulous, the child was brought to the Trousseau hospital.

*At the present time* there is an abundant and foetid discharge from the ear; the induration and pain behind the ear have disappeared. A finger's breadth behind the upper half of the retro-auricular furrow, there is an incision  $1\frac{1}{2}$  cm. long ( $\frac{3}{5}$  in.),<sup>1</sup> from which almost nothing escapes. The probe, introduced through the external auditory meatus, came upon the bared posterior wall; passed through the fistula, it also met with bare bone, anteriorly.

*September 24th. Operation.*—An incision the whole length of the retro-auricular furrow, and a transverse cut to the middle of the posterior lip. A pocket of an abscess was thus opened up, extending especially upwards and above the ear, towards the temporal fossa; the bone did not appear at first sight at the bottom of the wound. After incising the periosteum, and completely stripping it up, the mastoid process was seen, white, everywhere hard, without channels, lined with granulations, and eburnated in appearance. Above the base of the mastoid the temporal bone made a projection, whence extended a kind of ridge, in the middle of which was a depression, where a fibrous band was firmly adherent. This tissue once stripped up, there was evident the superficial layer of bone, everywhere hard, and in which the probe did not discover any narrow channels. On the contrary, scraping the granulations brought me between the bony meatus and

<sup>1</sup> For the correspondence between French with English measurements of length throughout this book, see Plate VI.

the separated cartilaginous meatus; there remained no trace of the membrana tympani. The bony canal had at its superior aspect a triangular form, the postero-superior wall making a convexity there. The protector (Pl. V. Fig. 3) was then introduced into the attic, the wall of which was removed by a narrow gouge and mallet. This wall was remarkably hard and thick. By curetting the cavity of the tympanum, I brought away the numerous granulations, especially marked near the orifice of the Eustachian tube, and the remainder of the incus. This done, I searched for the canal of the antrum, and was unable to find it with the point of the probe. The meatus was split open, then plugged to the bottom with tampons, and closed; the incision was sutured, except the lower angle, through which a drainage-tube was passed. The usual dressings.

The stitches and the drain were removed on the eighth day. There has never been any suppuration; and the child went to Laroche to convalesce, on November 13th, quite cured.

The rectal temperature never rose beyond 99·8° Fahr.

In this case, which is unique among all those we ourselves have been able to collect, one fact appears to us to stand out prominently—the atrophy and eburnation of the mastoid process. Will not this occur especially when the pus does not find mastoid air-cells, or spreads as it goes, as in the preceding case, towards the temporo-mastoid region, separating up the periosteum of the meatus? And supposing that when the mastoid air-cells do exist and this separation occurs, yet would it not be prudent to open these

air-cells, the constant infection of which the autopsies of Politzer, already mentioned, prove? This view seems to us to be the correct one, and on that account we attribute great importance, both theoretically and practically, to the eburnation of the mastoid process. But when the mastoid has not been hollowed out into air-cells, as a rule the antrum exists, and near it the so-called "border cells" which are in contact with the external auditory meatus. Also, before concluding absolutely that the mastoid is not involved, it is necessary to examine very carefully this region. Thus we shall relate, further on, a case in which one of us operated upon a mastoiditis limited to the border cells, and in which the apex of the mastoid process was eburnated, the lesion having at first been mistaken for a boil of the external meatus.

Before concluding this chapter, we ought to give a brief *résumé* of a work that M. Pauzat has quite recently brought out, upon osteomyelitis of the temporal,<sup>1</sup> and in which, coming to almost the same practical conclusions as ourselves, he attempts to show that we must compare the osteomyelitis of the temporal with that of the long bones; that, after even a slight lesion of the lining membrane of the tympanum, infection of the subjacent bone may arise, and extend sometimes with a remarkable rapidity; that an abscess within the mastoid is not the necessary intermediary for an otitis terminating in a phlebitis of the lateral sinus and

<sup>1</sup> J. E. Pauzat, "De l'ostéomyélite du temporal comme complication de l'otite moyenne suppurée," *Ann. des mal. de l'or, et du lar.* September 1893, No. 9, p. 754.

purulent infection, but that in this case there is an osteomyelitis.

It is certain that we may have a suppurative osteitis, both very severe and very extensive, by infection of the petrous and the mastoid portion, at a point bared after destruction of the lining mucous membrane. But is it the same thing to say that we must distinguish, as a sort of morbid entity, osteomyelitis of the temporal, partial or total, acute or subacute? We do not think so. A single difference, which is of the highest interest, separates this osteomyelitis from that of the long bones with which M. Puzat tries to compare it: we only allude, as likewise does M. Puzat, to the spontaneous osteomyelitis of these long bones. It is that these long bones are infected after an inoculation at a distance, whilst here (*i.e.*, in the temporal) it is a case of direct inoculation. In the osteomyelitis of adolescence, one sees the femur attacked, for instance, in succession to a boil on the face, which has served as a door of entry for the staphylococcus pyogenes aureus; here, on the contrary (*i.e.*, in the temporal), the pus proceeds from the mucous membrane which lines the cavities of the temporal bone itself. If one wishes to make a comparison, one can think of the forms of osteitis of the maxillæ following penetrating dental caries.

In the anatomical sense of the word, there is osteomyelitis with every possible degree of acuteness and with every possible consequence, from the simple gingival abscess to acute and total necrosis. But, for the practitioner, what is the important point? The idea of the door of entrance. If this is dealt with, if this is closed, if the carious teeth are removed in

good time, prophylaxis is all-powerful. The same for the temporal bone, if the cavities of the middle ear, and especially the mastoid cells, are disinfected in good time, which M. Pauzat also was the first to recommend.

But we do not believe, in spite of M. Pauzat, that one ought to compare this opening up of the bone, designed to asepticise the point of departure of the infection, with that which, in spontaneous osteomyelitis of the long bones, opens the medullary canal, the point of arrival of the infection. The practitioner ought to remember just this, that the opening up of the mastoid is, before everything, a preventive measure against the grave complications in which partial or total osteomyelitis of the temporal ends; whence this idea that one ought to intervene early, without waiting long enough for the complications to declare themselves. Osteomyelitis of the temporal bone is a consequence of inflammations of the middle ear, badly attended to, with or without mastoiditis (most often with mastoiditis); and the principal interest in the thirty cases collected by M. Pauzat, in Gaujot's Clinique, is to demonstrate to us with perfect clearness to what dangers patients are exposed when the opening up of the mastoid is not undertaken in good time, indicated, nevertheless, by local and general phenomena. This is in nowise a reproach; for in 1878, when these cases were collected, opening up the mastoid process was far from being so frequently practised, and, above all, of being so well-regulated a proceeding as nowadays. Even now, however, intervention is sometimes too long deferred, and one of us has noted five patients who

succumbed because they were operated upon too late. At the end of this volume (Cases. XCV. to XCIX.) will be found a summary of their history, which will be published *in extenso* elsewhere.<sup>1</sup>

## § 2. SYMPTOMS.

Inflammation of the mastoid cells may be a complication of every suppurative middle ear inflammation, acute or chronic. On the other hand, it itself can be of variable severity, and it may even sometimes be latent. But as we are now considering it from the point of view especially of therapeutic and operative indications, we shall pass by for the moment, in our clinical picture, the chronic and latent mastoid inflammations, and we shall only occupy ourselves for the present with the acute inflammations of the mastoid and mastoid abscesses. These form, in fact, an important clinical group deserving some consideration. Let us say again that we do not see in our description the signs by which we can demonstrate that the air-cells are attacked in nearly all cases of suppurative otitis media. We are only concerned with the cases where, in consequence of the anatomical modifications which we have dealt with at the beginning of the preceding paragraph, a mastoiditis begins to arise, so to speak, on its own account, and in which, from that time, the complication surpasses the original disease.

When, in the course of a suppurative otitis media, inflammatory phenomena spread to the mastoid process,

<sup>1</sup> A. Broca, "Osteites diffuses du temporal," *Bull. de la Soc. anat.* : Paris, 1895.

the symptoms of this complication become immediately marked enough to relegate to a lower plane the signs accompanying the simple otitis media. The general condition, which was good enough whilst the tympanum alone was affected, becomes suddenly worse; fever and rigors—varying, moreover, as to their intensity—are observed. It is rare for the temperature to rise above  $104^{\circ}$  Fahr.; and sometimes during the whole onset of the disease it remains normal, or almost so,—about  $98.7^{\circ}$  Fahr. is exactly what one sometimes sees in patients with a huge mastoid abscess, and in them the febrile condition appears remarkably slight. But perhaps if one were more often consulted quite at the onset, then, if there were not up to that time an abscess behind the ear, one might oftener observe a more marked rise of temperature. Sometimes under these circumstances the general condition becomes rapidly very serious; and we call attention, *apropos* of this, to our Case II., in which we have the history of a child who, on the fifth day of a suppurative otitis, was seized with mastoiditis, and on the sixth was brought to the hospital, almost comatose, with temperature  $104^{\circ}$  Fahr. Opening up of the mastoid, done at once, gave exit to a little pus surrounding the lateral sinus; and on the morning of the next day the temperature fell to  $98.6^{\circ}$  Fahr., and did not alter from this.

CASE II.—*Mastoiditis with symptoms of Meningitis. Mastoid Process and Tympanum opened up. Cure.*

Emile F.; aged 7 years; admitted to the hospital June 10th, 1893.

*History.*—At five years of age he had a bad fever;

at six years, measles. Five or six months ago he had a fall on his head; up to this time he had not had any otorrhœa. Fifteen days after, without having any discharge, he complained of the right ear; but these pains soon disappeared, and the child was quite well up to June 3rd. Yet it was noticed that for some time he had suffered from an obstinate coryza, with nasal voice and snoring at night.

*June 3rd.*—After having walked about all day, he complained of suffering much pain in his right ear; at the same time he was very feverish.

*June 5th.*—After a slight interval, the pains returned, and were still more severe; and during the day there was a discharge of yellow pus from the ear.

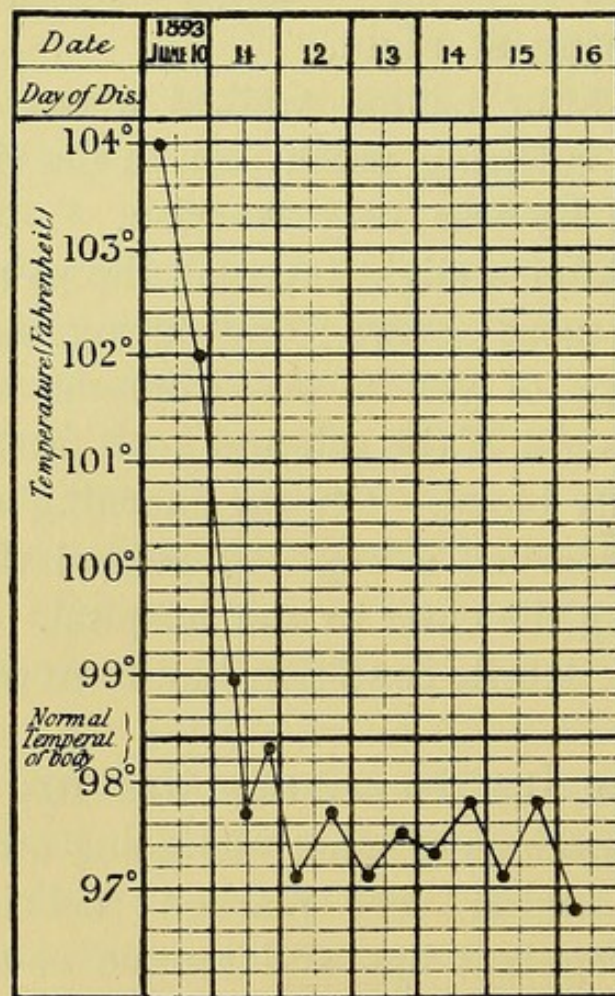
During the night of the 9th and 10th fresh discharge, this time chiefly blood. On the morning of the 10th the mother remarked a swelling behind the ear, and decided to bring the child to the hospital. During the whole week the febrile condition had been progressively getting worse.

*On admission,* the temperature was 104° Fahr.; the child was unconscious of what was going on about him; "typhoid" condition very marked; delirious; pupils equal; pulse regular; lips and tongue covered with a dark fur. In the external meatus were seen clots of blood. Behind the ear there was slightly marked œdema; but the mastoid process was tender on pressure, as indicated by the child's gesture.

*Operation.*—The mastoid was opened up the same day at 4 p.m. There was no pus beneath the periosteum. The air-cells, opened at the seat of election, only contained some granulations; but in curetting them away,



I found that the bone was friable behind; and in hollowing it out, I laid bare the lateral sinus, around about which was a small quantity of liquid and blood-stained pus. This done, in order to make sure of avoiding any retention of pus, I opened up and curetted the canal of the antrum and the tympanum.



CASE II.

There were some granulations, but the ossicles were healthy. Plugging with iodoform gauze, as usual. In the evening the temperature fell to 102° Fahr., and next morning it was 98.7° Fahr., and from this time it never went beyond from 98.6° to 99.4° Fahr.

The first dressing was made on June 15th. There

was no pus. The child went out, and returned twice a week for dressing.

On June 18th the cavity began to suppurate.

*June 19th.*—The bottom of the cavity is granulating well and is filling up. Below is seen the mastoid process, white and necrosed.

*September 16th.*—The sequestrum, being movable, was taken away.

From the month of October the child was brought for dressing with much less regularity.

*October 20th.*—He returned with a narrow cicatrised track behind the ear. There is a slight discharge from the ear—carbolic glycerine applied.

*April 13th, 1894.*—No discharge from ear. Cavity, covered with epidermis as far as the tympanum, opens behind the ear.

The bacteriological examination of pus, made by M. Péron, revealed the presence of streptococcus.

At the same time that fever, of greater or less intensity, appears, or even without the appearance of fever, the pains which had supervened at the onset of the acute otitis, and which had ceased after the perforation of the membrana tympani, reappear—sometimes dull and constant, sometimes with exacerbations, especially at night. Arising spontaneously, these pains are commonly seated behind the external auditory meatus, and thence radiate, in different directions, towards the occiput, the neck, the nape, towards the face, sometimes—Poltzer says—towards the teeth and towards the shoulder. Mastication may be painful, which is associated with a certain degree of inflamma-

tion of the bony canal (external auditory), and so of the glenoid cavity of the temporo-maxillary articulation.

In the memoir already mentioned, M. Pauzat insists upon the value of this symptom in the diagnosis, at its onset, of that which he calls "acute and total osteomyelitis of the temporal bone." It is evident that it was particularly marked in the three of his own cases in which the author directed our attention to this osteomyelitis, with its gravest sequences. But since we became acquainted with M. Pauzat's memoir, we have looked for this symptom, and have found it quite marked in a woman suffering from a simple mastoid abscess (Case XXIX.).

Movements of the head exaggerate the pains, and this will not be wondered at when we consider that several muscles of the neck—the sterno-cleido-mastoid, the splenius, the trachelo-mastoid, and the digastric—are inserted into the inflamed mastoid. From this may result a sort of torticollis, owing to an instinctive contraction for the purpose of fixing this region, in which the chief part is due to the sterno-mastoid generally, but in which the attitude, however, has not always been clearly made out, considering the antagonism which exists in certain respects between the splenius and the sterno-mastoid; also we understand that, as a general rule, there is chiefly an inclination of the head from the affected side, rotation being often nil, or almost so. Radzich<sup>1</sup> has devoted a special paper to the study—diagnosis and prognosis—of the torticollis arising in the course of cases of otitis

<sup>1</sup> Radzich, quoted by Grandhomme, *Thesis for Doctorate*, p. 25: Paris, 1890.

media. According to him, it indicates almost always a mastoid complication, with myositis of the sternomastoid. But one cannot be absolutely certain, for he recognises that there may be another cause, especially an inflammation of the cervical glands; and Radzich mentions a case developed in the course of measles, when there was no trace of periostitis of the mastoid. This torticollis was very marked in our Cases V. and XXII.

Besides movements, localised pressure exaggerates the pains. Everywhere over the surface of the mastoid pressure is badly borne, but—and Schwartz rightfully insists upon this—it is particularly so below the temporal ridge; and this is so even when there is no change produced either in the colour or consistence of the superficial soft parts. Sometimes, according to Politzer, who, it is true, does not attach too much importance to this observation, the pain on pressure is specially localised at the spot which indicates the position of the abscess. In our opinion this last point is not important, for we believe that the typical opening up of the mastoid, at the seat of election, should always be done.

At the end of a variable period of time the integuments of the mastoid area undergo modifications, the initial phases of which are readily appreciated on comparing the sound with the diseased region. Normally, the skin here is white, delicate, and easily raised into folds between the fingers. In the case under consideration it becomes hot, thick, and little movable. Then follows an œdematous swelling, soon becoming red, in which the finger produces pitting on pressure.

This œdema may extend a considerable distance, encroaching upon the fold behind the ear, and carrying forward the auricle, the direction of which becomes almost at right angles to the skull. Nevertheless, this extreme deviation rarely ever exists, unless a retro-auricular abscess has formed.

But, before considering the different ways in which pus attempts to gain the exterior, we must indicate certain phenomena which occur in connection with the meatus and the tympanic cavity.

First of all, the purulent discharge from the meatus by the external auditory canal. In a large number of cases—the greater number, perhaps—it diminishes, it may even cease altogether. We have already indicated, in the preceding paragraph, the conclusion that we draw from this fact. Here, then, we are in disagreement with Politzer,<sup>1</sup> according to whom the suppuration of the ear is very abundant: “It is but rarely that I have seen this discharge from the ear dry up, although the inflammatory symptoms, as regards the mastoid, may persist with the same intensity.” And, further on,<sup>2</sup> he adds: “Most often a profuse suppuration indicates persistence and extension of the abscess; conversely, one may think of the abatement of the disease when the pus becomes less abundant. I have, however, seen cases where the cessation of the otitis media occurred at the same time the perforation cicatrised, whilst, on the contrary, these morbid symptoms persisted still for a great while as regards the mastoid process.” Far from being the exception, these last conditions are the rule; and we do not think that the opinion of Politzer

<sup>1</sup> *Loc. cit.*, p. 320.

<sup>2</sup> *Loc. cit.*, p. 321.

is correct even for the mastoiditis of influenza, discussed specially in the memoir which we quote.

As for mastoid abscesses in general, one has only to peruse our cases to prove how frequently occurs diminution and even cessation of the discharge. We will add that it is not uncommon to find children in whom the otorrhœa has always been little or nothing.

If we examine the meatus and tympanic cavity with a speculum, we are first of all struck by a very important modification, which we are accustomed to call the "dip" (*chûte*) of the postero-superior wall of the meatus. It is, in fact, analogous to the œdematous swelling, which we have just described, on the external surface of the mastoid; but it will be useful to enter into some details concerning this symptom, the diagnostic value of which is considerable (Schwartz, S. Duplay).

We know that the external auditory meatus is formed by three bones: in front, below, and behind, by the tympanic; above, by the squamous portion of the temporal. But whilst above and in front the tympanic portion passes to join the squamous, above and behind there remains between these two bones a space which is completed by the mastoid portion of the temporal—the third bone entering into the composition of the canal. This mastoid portion of the temporal is hollowed out into air-cells,—the border-cells of the meatus, very superficial air-cells, covered in by a very thin wall,—so, when they are inflamed, a swelling of the postero-superior wall of the canal results.

This so-called "dip" of the postero-superior wall is very easily made out by the speculum. Sometimes it is so marked as to transform the lumen of the canal

into the form of a crescent, with the concavity backward—in which condition we shall only be able to see the membrana tympani with the utmost difficulty; such examination may even become quite impossible. According to Politzer,<sup>1</sup> this symptom has but little value as an indication for operative measures on the mastoid process: this is not our opinion, nor that of Schwartz.

When the “dip” of the postero-superior wall of the canal permits examination of the membrana tympani, it may be found either intact or perforated. If intact, it may be in one of two conditions—either there has never been any perforation and otorrhœa, or the perforation has become closed; and we have already mentioned our Case LIV. as an instance of this kind of condition.

But as a rule one ascertains clearly a perforation. The perforation is often small, and blocked by a thick fluid, which pulsates, sometimes closed by a polypoid growth which protrudes through it. This last point, upon which Schwartz insists, appears to us also of vital importance. In these cases the enlargement of the perforation and the removal of the polypus permit the pus to obtain free exit by the canal, and we shall see, in discussing the treatment, that this measure, when done early, may produce cessation of the symptoms of mastoiditis. At other times the perforation has continued wide open, is in a good position, but little or no pus escapes: then it is in such cases that the retention (of pus) in the mastoid is caused chiefly by the obstruction of the canal of the antrum.

<sup>1</sup> *Loc. cit.*, p. 320.

## SPONTANEOUS EVOLUTION. MIGRATION OF PUS.

If the mastoiditis, more or less acute, such as we have just described, at the period when the pus is still retained in the interior of the natural cavities of the middle ear, is left to itself, spontaneous resolution is possible. Little by little the pain and œdema diminish, and finally the patient gets well. Often, it is true, this should be considered rather as a remission than a cure; and Politzer<sup>1</sup> lays stress on those cases in which "every symptom had disappeared for some time, and where the indications of the formation of an abscess reappeared suddenly and with such violence that immediate operation was necessary." We must, therefore, beware of telling the patient that he is safe from further troubles too prematurely. In every case, moreover, such resolution, whether spontaneous or as the result of treatment, is the exception; and if the disease is left to itself, the pus tends to escape externally, by moving towards the surfaces—external, internal, or postero-superior—of the mastoid cells—*i.e.*, towards the skin, deep parts of the neck, or the lateral sinus and the brain.

We reserve to a later chapter the consideration of those points in the diagnosis to which abscess of the border cells of the meatus give rise. As, on the other hand, the discussion of the symptoms, diagnosis, and treatment of the intracranial complications of suppurative inflammations of the middle ear,<sup>2</sup>

<sup>1</sup> *Loc. cit.*, p. 321.

<sup>2</sup> See A. Broca and O. Maubrac, "Des complications intracrâniennes des otites moyennes suppurées, envisagées spécialement au



would lead us too far from our subject, and would, in fact, require a special treatise, we must now discuss the migrations which may be spoken of as external: the one common, with the classical abscess behind the ear; the other rarer, but very interesting, form, with a deep-seated cervical abscess.

I. *Retro-auricular Mastoid Abscess*.—When a retro-auricular abscess has formed, the œdematous swelling increases, the skin is brawny and becomes of a reddish-violet colour, and soon in this swelling a prominence is localised, so to speak, capable of enlarging to the size of an apple or an egg. In palpating this tumour, which generally is a little less tender to pressure than was the mastoid at the beginning, one notices softness, and fluctuation little by little becomes more distinct and more superficial.

In his memoir,<sup>2</sup> M. Puzat says, in speaking of mastoid abscesses, that before the formation of the collection of pus externally, the bony shell being distended, "one may feel the elevation and depression, under pressure, of the external table of the mastoid process." This is a symptom that we have never

point de vue de leur traitement," *Memoire couronné par la société de chirurgie, Prix Laborie, 1893*. This memoir forms part of a treatise on "Cerebral Surgery" now in the Press.

A. Broca, "Les abcès encéphaliques consécutifs aux suppurations de l'oreille," *Gaz. hebd. de méd. et chirurg.*, 1893, No. 38, p. 445.

A. Broca, "Abcès du cerveau et méningites consécutifs à des suppurations de l'oreille moyenne," *Bull. de la Soc. anat.*, 1894, p. 561.

A. Broca, "Les complications intra-crâniennes des otites moyennes suppurées," *Rev. prat. d'obst. et de pædiatrie*, pp. 206, 225, and 289: Paris, 1894.

<sup>2</sup> *Loc. cit.*, p. 783.

confirmed in the numerous patients, at all stages, which we have examined.

The ear is pushed away from the head, being carried forward, when the pus has collected.

J. L. Petit has stated that, by methodical pressure, one may empty mastoid abscesses into the tympanic cavity. The fluctuation behind the ear then ceases, and at the same time there is noticed an abundant discharge from the meatus; and that, on the other hand, on telling the patient to make an effort, the collection behind the ear will then be seen to re-form. This symptom may be present, but it requires the mastoid to be spontaneously opened up, and, further, that the canal of the antrum be patent and of large diameter. But these conditions are rare. On the other hand, such an investigation is to be avoided when there is tenderness on pressure; for, whatever may be said to the contrary, it does not lead to any practical conclusion.

In one of our patients we made this observation, which was only too evident directly the finger was placed upon the region behind the ear; but it was quite a special case, in a child in whom one of us had opened up the mastoid several months previously, and in which the chronic otitis, insufficiently attended to afterwards, had caused a return of the abscess behind the ear, and the cicatrix was raised into a little white knob as large as a hazel-nut, which was indolent, and emptied itself into the meatus on the gentlest pressure. But we must not forget that this mastoid had been freely opened up, which is not to be compared with spontaneous perforations. It is a rare symptom in

the acute attacks of mastoiditis associated with acute middle ear disease; it is much less so in the mastoid abscesses of chronic middle ear disease. This is easy to understand; for in the acute cases it is exceptional to find a perforation of any size in the external wall of the mastoid, whilst it is frequent enough in old fistulæ.

CASE III.—*Mastoid Abscess. Mastoid opened up. Wound dressed irregularly. Relapse. Abscess emptying itself through the Meatus. The Mastoid Process and Middle Ear opened up. Cure.*

G.; admitted to the hospital January 13th, 1893.

*History.*—Father, deaf-mute, healthy; mother healthy, as also a brother aged fourteen years. Born at term. Patient was in good health up to the last few weeks, when he had scarlet fever. At the desquamative stage he had a discharge from the ear; seven or eight days later there appeared, without fever, an abscess behind the ear, on account of which the child was brought to the hospital.

*January 14th, 1893. Operation.*—Mastoid process opened up.

*February 1st.*—The child, when progressing well, was taken away by the mother, contrary to advice, on account of the presence of whooping-cough in the ward; and it was not brought back to be dressed.

Only in the month of August, it appeared, did the wound cicatrise, but the discharge from the ear persisted. Towards the end of October the child suffered from pains; and on December 16th, 1893, it was brought back to the hospital with an abscess

behind the ear as large as a hazel-nut, bulging out the thinned cicatrix. Light pressure emptied this collection, and then pus was seen to escape in abundance through the meatus.

The abscess having been incised, the mastoid was found perforated. After scraping this cavity, I opened into the tympanic cavity in the usual way. Extraction of the incus, both branches of which were carious. The malleus was not seen. Wide cleft in the meatus, the two angles of which were sutured to the posterior incision. Plugged with gauze, as usual.

The child—who was not admitted to the ward this time—returned regularly for dressing twice a week. During the first few days suppuration was considerable, but it soon diminished. The plugging with gauze was always done principally through the external meatus.

*February 25th.*—The meatus, which is well dilated, does not suppurate any longer. The posterior cavity has been reduced to a granulating surface as large as a lentil. From this time the local condition was uniformly good, but an intractable fistula persisted towards the apex of the mastoid process, without any discharge from the meatus.

*October 28th, 1894.*—Whilst dressing the wound, a horse-hair stitch was found at the bottom of the little fistula, and was cut out.

By October 29th the fistula was closed.

*February 1895.*—Cure remained permanent.

The situation of these abscesses is very variable. In the majority of cases they occupy the upper part

of the mastoid process, behind the meatus, sometimes even above it, spreading towards the temporal fossa, raising and effacing the furrow behind the auricle. Sometimes the swelling appears on the external aspect of the auricle, raising the cartilages and obliterating the folds in the upper region of the meatus; and from this part, to the abscess behind the ear, fluctuation is observed. In other cases the abscess forms at the apex of the mastoid process, when it is generally smaller, separated from the auricle by the furrow behind the ear which is still present. We shall mention, in illustration of this form, our Cases IV. and LIV. Sometimes even the apex appears free, the pus having sunk into the upper part of the sheath of the sterno-mastoid muscle (Case V.).

*CASE IV.—Mastoid Abscess at the Apex of the Mastoid Process. Opened up. Cure.*

*History.*—A. R.; aged 7 years; admitted to the hospital April 22nd, 1893, on account of a white swelling of the knee, of four years' duration, and at the present time fistulous and in a bad state. Father and brother died of tuberculosis.

*June 5th.*—Without there being any previous discharge from the ear, a swelling was observed at the apex of the mastoid process. The skin was red and puffy; the furrow behind the ear was not obliterated; and as there was no otorrhœa, it was thought to be probably a suppurative inflammation of the mastoid lymphatic gland, keeping in mind, however, the possibility of its being the alternative—a mastoid abscess.

*June 7th. Operation.*—Fluctuation being evident, the

abscess was opened, and the mastoid process explored and found to be laid bare to the apex. It was opened up at the seat of election, the air-cells being filled with pus. The canal of the antrum appearing healthy, the tympanum was not opened. Plugged with gauze, no sutures being employed.

The dressings were made, as usual, every four or five days, and the cure was complete by July 31st.

*December 31st, 1893.*—The child is still attending the hospital for the white swelling of the knee. The mastoid is in excellent condition. The scar is white, linear, absolutely concealed by the auricle.

*September 30th, 1894.*—*In statu quô.*

*CASE V.*—*Mastoid Abscess in the sheath of the Sternocleido-mastoid Muscle. Operation. Cure.*

*History.*—M., 16 years of age, had an attack of influenza in April 1893, and, following upon this, a discharge from the right ear, which appeared after intense pain, and was treated in the country by syringing. At the end of a month the amount of discharge was unaltered, but the patient complained of severe pains all over the right side of the head. At the same time there appeared a swelling behind the ear. She was brought to us after ten days. The auricle was noticed to be pushed forward; and behind it there was a swelling, not very large, but which, we were informed, had diminished in size during the two or three days preceding, and at the same time the pains had also decreased.

*Present State.*—To-day, the tumour itself is situated below the apex of the mastoid, forming a mass extending

along the length of the sterno-mastoid muscle. No fluctuation can be obtained, but there is some resistance all over this region. The skin retains its normal tint. The head is kept fixed by a sort of torticollis. There is a perforation of considerable size in the membrana tympani, but no discharge escapes therefrom. The air-douche produces the characteristic sound of a perforation, but does not expel any fluid. The diagnosis made was a mastoid, perforated spontaneously, the pus from which had spread into the sheath of the sterno-mastoid muscle.

*June 14th, 1893. Operation.*—A large incision descending below the apex of the mastoid process, and passing to unite again with the furrow behind the ear; tissues thick and slightly infiltrated. In the sheath of the muscle, quite in the upper part, was a little collection of pus, smaller in amount than one would have suspected from the size of the tumour; and a perforation of the bone itself, of at least half a centimetre ( $\frac{3}{16}$ " square, was met with above, which led into the air-cells, full of pus, granulations, and some bony *débris*. Scraped, and the cavity plugged with gauze, the extremities of the incision being sutured.

Dressed after eight days, with no rise of temperature. Wound in good condition. Dressed every four days; and at the end of a month the patient departed, cured, with the perforation in the membrana tympani closed, and hearing normal.

The first form, we say, is the most frequent. We have only noticed it specially in young children, which is natural, since our anatomical knowledge teaches us

that the antrum is the only mastoid cell at this time of life.

Generally, at the time when the external abscess starts, there appears to be an arrest of the local and general symptoms. The fever is moderated; the temperature scarcely rises above  $100\cdot4^{\circ}$  to  $101\cdot3^{\circ}$  Fahr., and often even remains about  $98\cdot6^{\circ}$  Fahr., only exceeding the normal by some tenths of a degree; the pains abate, being quite sharp enough, however.

If the abscess is left to itself, it makes its way out after a certain time, with perforation of the skin; and often the patient experiences a considerable degree of relief. But we hasten to add that this spontaneous evolution almost always merely results in relief, and not in cure, and that, after it, there persist simultaneously a chronic otorrhœa and a mastoid fistula, the inconveniences and dangers of which we shall try to make clear in the next chapter; and when we consider the treatment, we shall attempt to prove that the simple, so-called Wilde's, incision is scarcely better than the spontaneous opening. Here is an instance showing, amongst many other things, how a spontaneous opening leads to a fistula.

CASE VI.—*Mastoid Fistula, following an Abscess which opened spontaneously. Mastoid Process and Tympanic Cavity opened up. Cure.*

M. L., 6 years of age, was admitted to the hospital on May 5th, 1893.

*History.*—This child, who was operated on, at the age of four years, for a tumour of the forehead (the scar of which is still visible), had measles when two years



old. About one year afterwards there commenced an otorrhœa, soon followed by a swelling behind the ear, which rapidly proceeded to open spontaneously. It was intended to treat the child for this, but it had an attack of typhoid fever, and the child remained at the Hospital Trousseau from July 26th to August 22nd, 1892. When admitted to the surgical side, there was abundant otorrhœa and a mastoid fistula behind the ear.

*Operation.*—On May 21st, 1893, an incision was made behind the ear. The mastoid was found to be spontaneously perforated. Granulations scraped, the aperture enlarged, and the tympanic cavity scraped. The ossicles were not seen.

The child left the hospital June 7th, and came then to be dressed at the consultation. Cure by the end of November 1893.

*January 28th, 1894.*—The scar over the mastoid is sound, slightly depressed. There remains a slight otorrhœa.

II. *Cervical Mastoid Abscess.*—When the pus passes towards the internal surface—perforated, or simply bared—of the projecting part of the mastoid, there arises a painful brawny swelling, then a fluctuating abscess in the upper part of the neck—an abscess which spreads along the insertions of the digastric, the deep surface of the sterno-mastoid, and which especially occupies the retro-maxillary region, resembling a true latero-pharyngeal abscess, being able to extend even as far as the nape of the neck. Thence it can spread throughout the side of the neck, and has been seen

(Zaufal and Jacobi)<sup>1</sup> even in the mediastinum. During this time the external surface of the mastoid looks normal, but is tender on pressure.

This abscess, by its size, depth, and vasculo-nervous connections, is incomparably more grave than the ordinary form behind the ear; and if the published cases are examined, it will be seen that there is a considerable mortality.

Bezold,<sup>2</sup> it appears, was the first to insist upon this form of mastoiditis, with the abscess in the neck high up and deeply situated. Subsequently, several works were published. Moos,<sup>3</sup> for instance, has seen four cases of this variety, in men from twenty-four to fifty-three years, three of which followed recent middle ear disease; there were two deaths and two recoveries. The death supervened in one with manifestations of cerebellar abscess; in the other, with symptoms of septicæmia; and one of the patients cured presented extremely grave symptoms, with rigors and oscillations of temperature amounting to about  $10\frac{1}{2}^{\circ}$  Fahr.

Guye, who reported two similar cases to the second Congress of Belgian Otologists, in 1891, informs us that, in a patient of Kisselbach, the pus spread towards the pharynx, giving rise to a retro-pharyngeal abscess. In the two cases under his own care he obtained a cure. In the first an interesting symptom was noticed: the pains were excruciating, the meatus was blocked

<sup>1</sup> See a recent case of Dr. Wilson (Bridgeport), *Amer. otol. soc.*, May 1894; and *Annals of diseases ear and larynx*, 1894, vol. xx., p. 915.

<sup>2</sup> Bezold, *Deut. med. Woch.*, 1881, No. 28, p. 381.

<sup>3</sup> S. Moos, "Sur la forme de mastoïdite décrite par Bezold, et la thrombose du sinus-latéral," *Arch. of otology*, 1890, vol. xix., p. 161.

by polypoid masses, and, after destroying one of these polypi, Guye saw that pressure upon an abscess in the neck caused a discharge of pus from the meatus. The history of the second case of Guye is as follows :—  
“ It occurred in a man of sixty-five years, who suffered from a suppurative otitis media in the left ear, with mastoiditis, following an attack of pharyngitis. Four months later, the tympanic membrane having cicatrised up, there was some hyperostosis of the posterior wall of the meatus, and the patient complained of sharp pains along the neck, whilst the mastoid process was hardly at all tender. There was some thickening in the neck. The mastoid was opened up. But, fifteen days later, the temperature rose ; the purulent discharge became abundant, then it stopped suddenly ; whilst deglutition became difficult, and a retro-pharyngeal abscess formed and had to be opened ; then two other abscesses, which collected lower down, were opened.”

In this case also, pressure upon the neck increased the discharge from the ear. This extension towards the neck is possible even in the acute attacks of mastoiditis accompanying attacks of acute otitis media ; and it was so in a case reported by Moll, in 1892, at the third Belgian Congress of Otologists. A man, aged fifty years, had influenza in December 1891 ; ten days later, an attack of otitis media on both sides ; fifteen days later, a painful swelling of the right mastoid region, which soon spread to the retro-maxillary region ; and on February 20th it became necessary to open up the mastoid and incise the deep abscess, after resection of the apex of the process.

We shall mention yet another case, followed by

death from meningitis and thrombosis of the sinus, published in 1894 by H. Knapp,<sup>1</sup> and where the autopsy showed clearly a perforation of the internal surface of the mastoid.

Another variety of mastoiditis with cervical abscess is represented by the case of E. de Rossi, to which we have already alluded in our study of the anatomy and pathology. In this case, reported by the author to the Academy of Medicine at Rome, when the cervical abscess was opened into, the pus, collected at the lower part of the neck, flowed away through the external auditory meatus, ascending along the vasculo-nervous tracts, crossing the posterior perforated space, penetrating thus into a subdural abscess, then passing through a perforation in the wall of the lateral sinus, so as to escape into the mastoid antrum, and finally into the tympanic cavity. If it is preferred to trace the course of the pus in the direction of its invasion, the following evolution is observed<sup>2</sup> :—

Otitis media, mastoiditis, perforation of the bony wall of the lateral sinus (sigmoid fossa), subdural abscess having spread to the neck along the vasculo-nervous channels, after having passed through the posterior perforated space.

It should be noted that in this case the membrana tympani had remained intact. A cure was obtained by opening up the mastoid, evacuation of the subdural abscess, and by large and deep incisions in the neck.

<sup>1</sup> H. Knapp, "Un cas de mastoïdite dite de Bezold," *Zeitschr. für Ohrenheilk.*, t. xxiv., p. 161. See also Pomeroy, *Ann. des mal. de l'or. et du lar.* 1888, t. xiv., p. 580.

<sup>2</sup> Cp. Plate IV.

In our own cases we have one which corresponds perhaps to a latero-pharyngeal mastoid abscess (Case VII.). It is that of a little girl, who was brought to the hospital with a mastoid fistula. A few days later she had attacks of dyspnœa, and a latero-pharyngeal abscess was opened through the pharynx—so as to avert the most urgent symptoms. Then, the pus having again collected, the symptoms reappeared, and the mastoid was opened up, and at the same time the abscess in the neck was freely incised in a direction parallel with the posterior border of the sterno-mastoid muscle. The finger, introduced into the cavity, reached as far as the pharynx, but, directing it towards the internal surface of the mastoid, no bare bone could be felt; so that we do not hesitate to say that it was not a question of an associated suppurative inflammation of the gland.

CASE VII.—*Mastoid Fistula. Latero-pharyngeal Abscess. Mastoid and Tympanic Cavity opened up. Abscess incised. Cure.*

E. C., 3½ years of age, was brought, on April 24th, 1893, to the consultation at the hospital.

*History.*—This child had whooping-cough in March 1892; then, in April, a “reappearance of measles,” followed almost immediately by typhoid (?) fever. Since then she has never been strong; has had prurigo infantilis, bad eyes, crusts in the nose. About six months later, from no known cause, she suffered from otorrhœa, and soon afterwards from a swelling behind the ear, which was twice incised by a doctor; and for the last two months there has been a fistula.

*Present State.*—The child, whose antecedents have been good (the parents and one brother being healthy), is marasmic, unhealthy, and has had fever from time to time. There is a fistula behind the right ear. We sent it to Dr. Lubet-Barbon for an examination of its ear. She attended the clinique on April 25th, breathing badly, and having tonsillitis. M. Lubet-Barbon found behind the right tonsil a resistant swelling, incision of which was followed by the escape of a large quantity of pus. Examination with the speculum showed the membrana tympani to be destroyed and the tympanic cavity full of granulations.

Relieved by the incision in the pharynx, the child was brought, on May 1st, to the hospital, where she was admitted for operation on the fistula. The abscess had returned.

*May 2nd. Operation.*—Mastoid and tympanic cavity opened up. Removal of diseased ossicles; then, at the same sitting, an incision along the posterior border of the sterno-mastoid muscle, and free drainage of the abscess in the wall of the pharynx. After this, the usual dressing was applied.

The child left the hospital on June 4th, almost completely cured, complete cure resulting after some dressings. She returned towards the middle of December, for an abscess in the left submaxillary lymphatic gland (caries of a lower molar), which was opened. Cured by January 15th, 1894. At this time, the child, always having been subject to sore throats and coryza, was very well—better than she had been at any period previous to the operation. When seen again, in September 1894, she was in excellent condition, locally and generally.

## § 3. DIAGNOSIS.

The diagnosis, to be complete, should include the solution to the following two problems:—

1. Is there disease of the mastoid?
2. Did this disease start in the middle ear?

As for the diagnosis of the state of the tympanic cavity, it is directly connected with the consideration of the indications for treatment.

## I. IS THERE DISEASE OF THE MASTOID?

The diagnosis must be considered in three different cases:—

- a. Where there is apparently no alteration in the tissues covering the mastoid.
- b. Where there is an abscess or œdematous swelling in the mastoid region.
- c. Where there is an abscess of the maxillo-pharyngeal triangle.

*a. Where there is no alteration apparent in the tissues which cover the mastoid process.*

The symptoms which we have just been considering are present almost, but not quite, always; and it must be clearly understood that pus can exist in the mastoid cells without any swelling or redness of the skin in the region behind the ear. These cases are, moreover, the most dangerous, for it is in them that, the pus not passing externally through the too thick bony outer wall, one is suddenly astonished, sometimes, by the onset of the most grave intracranial complications.

It is in circumstances of this kind that it would

be valuable to have the information afforded by the illumination of the mastoid cells and by the functional examination of the hearing.<sup>1</sup>

Without doubt some researches have been made in this direction. Caldwell,<sup>2</sup> for instance, introduced into the meatus a little electric lamp, provided with a window which is turned against the posterior wall. As soon as the lamp is lighted, the mastoid cells become translucent from the base to the apex of the mastoid; if pus is present, the area remains opaque, on the contrary. When the auditory canal is too narrow or too painful, the lamp is placed behind the mastoid, and one decides according to the presence or absence of a rosy hue in the middle ear and the meatus. This special method of examination has not entered into general practice, and the rarity of its employment does not permit one to decide its exact value. But we ought not to reject it merely on *à priori* grounds, for we all know what progress a similar method has made in the diagnosis of abscesses in the antrum of Highmore.

<sup>1</sup> Ferreri (*Lo sperimentale*, November 1883) recommended exploratory puncture. This is a blind method of procedure, to which we are opposed—although, according to a case published recently by Chincini, its author does not seem to have given it up. Eulenstein (*Mon. f. Ohrenh.*, 1894, t. xxviii., p. 73), according to Kœrner and Moos, had obtained considerable information by percussion of the mastoid, which revealed the density. We are sceptical in regard to this sign, upon which the author no longer lays so much stress.

<sup>2</sup> C. W. Caldwell, "Transillumination of the mastoid cells as a means of diagnosis of mastoiditis interna suppurativa," *New York Medical Journal*, July 15th, 1893, vol. ii., p. 66.

<sup>3</sup> See also Urbantschitsch, "Soc. imp. roy. de méd de Vienne," May 20th, 1892, reported in the *Wien. klin. Woch.*, May 26th, 1892, p. 315.



We will not say as much for the researches which depend on the examination of the hearing; the integrity of this function is, in fact, variable, and depends on variable conditions, in turn dependent on those which the transmission of the sound-waves produces.

In one case the hearing is abolished, in another it is preserved, according as the manifestations on the part of the middle ear remain at the acute stage, or diminish, during the onset of the mastoid complication. We will add, whilst fully acknowledging that we have not yet put this method to the proof, that we have but little confidence in the future which awaits the sign upon which V. N. Okouneff of St. Petersburg has recently laid stress.<sup>1</sup>

In case of a mastoid abscess there would be a manifest diminution of the bony conduction of sound in the region occupied by the abscess. This phenomenon can readily be proved by means of a tuning-fork, made to vibrate upon the patient's vertex, whilst the skull is auscultated by means of an otoscopic tube, provided with a caoutchouc funnel of very small size, placed upon different points of the mastoid process. If no abscess exists, the sound of the tuning-fork is perceived distinctly everywhere. When, on the contrary, there is a focus of pus in the mastoid process, the sound is considerably weakened as soon as the otoscope tube reaches the region of the abscess. Thanks to this method, M. Okouneff was able to diagnose mastoid abscess in two patients who only presented doubtful symptoms of this lesion, and also

<sup>1</sup> V. N. Okouneff, *Vratch*, 1893, pp. 1325, 1353.

to determine the exact situation and extent, which was confirmed on opening up.

For the present we conclude that the diagnosis of these cases of mastoiditis, without any apparent alteration externally, must continue to be undertaken by the ordinary means of investigation ; and all the more so as often enough it will be a question of an operation of emergency, for which the practitioner at a distance from a large town will not have the time—if he wishes to save the life of his patient—to call to his aid a specialist, who alone possesses the special instruments required for the examinations just indicated. Under these circumstances, then, the spontaneous pain becoming more violent, the fever more intense, the rigors more frequent, the delirium repeated, vomiting supervening in the course of an acute otitis media, and accompanying a diminution of discharge from the ear, ought to make one suspect the complication, and hasten operative interference. And then, is there really *no* local indication ? There is no redness and swelling of the integuments behind the ear, it is true ; but the mastoid process will always be tender to pressure, sometimes, even, this sensitiveness will be exquisite. Associated with a notable rise of temperature and headache, this pain behind the ear, on pressure, acquires a considerable diagnostic value ; and we shall see, in considering the treatment, that if it does not yield readily to ordinary medical treatment, it constitutes an important indication for operation. We refer, on this point, to our Case II. and to the temperature chart. Moreover, the cells of the body of the mastoid, which are relatively deeply placed, do not show at all

externally, or hardly at all; but the air-cells bordering upon the meatus are much more superficial, and in the doubtful cases, the redness, œdema, and the "dip" of the posterior wall of the meatus, become of the greatest use in diagnosis.

We do not further insist upon these almost identical conditions, which we shall have to discuss so as to state forthwith the indications for treatment, and we shall content ourselves here with relating some cases.

CASE VIII.—*Mastoid Abscess. Mastoid opened up.*

*History.*—Mrs. H., housewife, 54 years of age, came to the hospital on January 18th, 1894, complaining of intolerable pains in the head, in the right half of the skull, and pains localised behind and below the right ear.

*Present State.*—The mastoid region does not present to the eye anything abnormal, but is very tender to pressure, especially towards the apex; the region below the ear is still more painful, and a small gland is found there. The meatus is normal; the membrana tympani is normal everywhere but for a slight thickening. Complete deafness in the right ear; hearing in the left, normal. Catheterism produces a loud click, normal, without any relief to the troubles in the head, nor of the pains.

*Treatment.*—Ice-bags over the mastoid region, warm carbolic glycerine (1 in 15) instillations into the meatus.

*January 20th.*—Pains a little less, but still always severe.

*January 23rd.*—The ear has discharged freely, but the mastoid pains persist; perforation of the membrana

tympani in the antero-inferior region ; catheterism ; irrigation through the Eustachian tube.

*January 25th.*—The discharge has diminished ; the pus is thicker, almost solid ; catheterism ; irrigation through the Eustachian tube.

*January 29th.*—The mastoid pains continue to be as severe, the pains in the head intolerable. The patient has not slept for fifteen days. The parts behind the ears are somewhat brawny. The pulse is 110. Owing to the pains, sleeplessness, brawny induration, and fever, operation has been decided upon.

*February 3rd. Operation.*—The mastoid was opened up. Superficial parts healthy. In the usual position was found eburnated bone, and no cellular cavity. The antrum was found to be slightly higher than normal. The size of this cavity appeared greatly reduced, and scarcely any pus was met with there, but much granulation-tissue, which extended up towards the aditus. Cured, and plugged with iodoform gauze.

The same evening the pulse was no more than 80 ; temperature, 99.5° Fahr.

*February 4th.*—Temperature—morning, 98.6° Fahr. ; evening, 98.9° Fahr. ; more pains in the head.

*February 10th.*—The patient is in very good condition. The dressing being removed, the wound looks quite healthy.

Complete cure by the end of February.

CASE IX.—*Acute Mastoiditis. Mastoid opened up. Cure.*

B. S. ; 15 years of age.

*History.*—Acute otitis media, following influenza,

fifteen days ago. For four days, pains very severe in the region of the mastoid; œdematous swelling; "dip" of the postero-superior wall of the meatus; rather large perforation of the membrana tympani.

*April 21st. Operation.*—No pus beneath the skin or periosteum. Opening up at the seat of election led into a cavity full of pus and granulations; cavity curetted, enlarged and drained. Cessation of the pains. Temperature about 98·6° Fahr.

*April 27th.*—First dressing; drainage-tube replaced. Dressed subsequently three times, at intervals of five days.

*July 12th.*—The patient is cured; the hearing is normal; the perforation cicatrised.

*b. There are signs of inflammation behind the ear.*

In these cases, which constitute the great majority, certain affections can present some one of the characters of acute mastoiditis, when this is not the trouble. We have to consider, from this point of view, the inflammation of the mastoid lymphatic gland and boils in the meatus. Moreover, with each of these lesions the opposite error may be made—that is to say, one may fail to recognise a mastoiditis which does exist. To conclude, we shall consider what importance is to be attached to the attempts at the differential diagnosis between the periostitis of the mastoid process and inflammation of the mastoid cells.

(a) *Inflammation of the Retro-auricular Lymphatic Gland.*—Following impetiginous ulcerations of the hairy scalp, various excoriations of the skin over the mastoid region or of the pinna, various lesions of the meatus,

such as eczema or boils, the gland behind the ear can become the seat of an adeno-phlegmon, resulting in fever, slight rigors, shooting pains, heat, redness, and cellulitic swelling of the mastoid region. Then the gland suppurates, and fluctuation reveals the existence of an abscess.

The diagnosis is not to distinguish between this adeno-phlegmon and abscesses of the mastoid process, which occur towards the base of the latter—that is to say, on a level with the antrum, and which raises, detaches, and pushes forward the auricle in effacing the fold behind the ear.

An adeno-phlegmon never acts in this way, and does not encroach upon the auricle. But regarding the mastoid abscesses which occupy the middle part and apex of the mastoid process, the question is sometimes more delicate, and especially so when there exists at the same time a discharge from the ear, and when infection of the skin is produced by the treatment directed against this discharge: local irritants in the meatus, accidental blisters behind the auricle.

In adeno-phlegmon of the gland the pains will be less radiating; pressure upon the bone itself above the tumour will make no impression; the redness of the skin will be sharply marked and earlier; the brawny induration of the soft tissues will appear sooner and will be more marked, more phlegmonous; the retro-auricular furrow will not be obliterated.

If we have exact information upon the mode of onset, a great step towards the solution of the problem will be made; for in suppurative inflammation of the lymphatic gland the lesion will commence by the

engorgement of the gland, which will be painful, hard, and rolling under the finger; whilst in mastoiditis the swelling will, from the commencement, involve the bone. Before deciding, we should examine with great care if there does not exist a possible way of entrance for the infectious germs into the tributary regions of the mastoid gland. In all cases, finally, the careful examination of the meatus is imperative; for, it goes without saying, that the "dip" of the postero-superior wall will decide the question, in doubtful cases, in favour of mastoiditis.

Sometimes, in spite of every investigation, the diagnosis will still remain somewhat obscure; and we may refer, on this point, to our Cases IV. and LIV.

The conclusion to be drawn is, that on every occasion in which we open a superficial abscess in the mastoid region, we should explore most carefully, with the finger and probe, the subjacent bone, in such a way as to make quite sure whether or not there exists a bare spot; and if one is found, we should there and then commence the operative treatment of the mastoiditis.

(b) *Furunculosis of the External Meatus.*—A boil in the meatus is very often a source of error, and that in several clinical varieties which it is of importance to distinguish.

The reasons why, in a general way, confusion is possible are as follows:—Furunculosis of the meatus is accompanied by violent pains, due to the boil not being able to develop readily in a narrow tube, to the skin being rather thin, and resting almost directly upon an unyielding bony surface. If with these pains

there are, in addition, fever, and even rigors, a purulent discharge, only slight in amount, from the meatus, an œdematous swelling behind the ear, which may be of considerable size,—we can well imagine how much hesitation may arise at first sight. It will be still more justifiable if in this swelling the gland behind the ear is congested and even suppurates; if around the concha of the ear—most often below, however,—an abscess connected with the lymphatic gland occurs; above all, finally, if the boil is situated superiorly and posteriorly, producing a swelling which simulates the “dip” of the postero-superior wall of the meatus.

In the preceding case we have shown how a boil may simulate mastoiditis. But, conversely, mastoiditis may be mistaken for a boil—in certain very special conditions, it is true—of which our Case X. is the type. Suppose it to be a sclerosed mastoid process, of which the cavities are reduced to the antrum and to the cells bordering on the external meatus, the region behind the ear remaining normal, or almost so, the only physical sign will be the “dip” of the superior wall of the meatus—and we might readily attribute it to a boil causing this limited swelling. This is what happened in our own case. But the error was quickly rectified; for, after incising it, the probe came in contact with the bone.

CASE X.—*Mastoiditis limited to the Cells bordering on the Meatus. Operation. Fistula.*

*History.*—L., 46 years of age, postman, came to the clinic, complaining of pains in the left ear. For some days insomnia; several rigors; tongue white; scanty



discharge from the ear. A small vesicle was found on the postero-superior portion of the membrane, and at this spot a paracentesis was done, which relieved the patient for some days.

*May 5th, 1893.*—The patient has suffered much. Scanty discharge; small perforation; paracentesis repeated.

*May 13th.*—Discharge scanty, but little pain.

*May 25th.*—The air-douche produces a discharge of a small quantity of pus through the perforation.

*May 27th.*—Air-douche.

*May 30th.*—The patient is in great pain. Upon the posterior-superior wall of the meatus is a swelling, painful to the touch, which is considered to be a boil of the meatus. No mastoid symptoms.

*June 1st.*—Œdematous swelling of the whole of the auricle, which is carried forward; but no brawny induration over the mastoid, which is not painful to pressure. What was thought to be a boil was opened; and a probe, introduced through the narrow channel, revealed a small bit of bare bone, which made us doubtful of its being a boil. A free incision was made, through which escaped several grammes (about a drachm) of pus.

*June 3rd.*—Since yesterday there has been great relief; the patient has slept. Pus still escapes through the incision, and very little through the perforation.

*June 13th.*—Abscess closed, and the pains returned. A fresh opening was made into the meatus. Improvement.

*July 1st.*—A little discharge, and some pain, but slight brawny induration of the mastoid region. It

appears that our patient has had from the commencement a mastoiditis which has opened into the meatus through the anterior cells of the mastoid. We mistook for the moment the swelling of the meatus for a boil, in the absence of mastoid symptoms. To-day, there being no longer any doubt, it was decided to operate.

*July 18th. Operation.*—A free incision was made across the thickened and indurated tissues, which led down to the bone laid bare to a considerable extent. Scraping, hollowing out the mastoid, and separation of the periosteum. The large air-cells of the apex of the mastoid were not found, and at this spot the bone was eburnated. This is probably the explanation of the few really mastoid symptoms observed during the course of the disease; the inflammation, spreading from the tympanic cavity through the aditus, had remained confined to the upper and anterior cells of the mastoid, and then came to the surface *viâ* the meatus in this way. Dressed with iodoform gauze.

During the week which followed the operation the pains disappeared completely, the appetite returned, the patient felt better. At the end of two months he was able to start again his duties as postman, although the wound was not closed. It remained fistulous; and still, to-day (at the end of December 1893), the probe reveals a bare bony spot, which will compel us a little later on to operate again. The passage remaining fistulous, we decided to operate.

*June 26th, 1894. Operation.*—Incision of skin, passing through the fistulous opening. The cavity in the bone, where many fleshy granulations were found, was scraped. At the bottom of it, were fine canals in the bone,

directed upwards and forwards. The crater-like cavity was enlarged posteriorly as far as the sinus, and above to the temporal line. The posterior wall of the meatus was exposed, the meatus detached above and behind, and in the attempt to follow one of the channels as far as the tympanic cavity, the posterior-superior wall of the meatus was removed. The bone was soft and friable, bleeding profusely. The protector (Pl. V., Fig. 3) led into another cavity, directed, not above and in front, but below and behind, and containing bony spicules—at the level of the semicircular and facial nerve canals. The position of the latter (facial nerve) was noticed too late to avoid wounding it. Thorough scraping, with plugging through the posterior wound and the meatus. The patient woke up with facial paralysis.

The sequel to the operation was simple—there was no fever, and the dressing was applied through the posterior wound and the meatus. To-day, the cavity appears completely covered in by skin, except at one spot above and behind, a few millimetres in size, where the bone is still bare.

Whatever the direction in which the error may present itself, the general principles of diagnosis are the same. First of all, by careful examination, even before the probe has touched the bare bone, the swelling of the boil has not altogether the same appearance as the “dip” of the posterior-superior wall of the meatus: it is, in fact, pointed at the apex, and not rounded. The slightest touch with the point of the probe causes the patient to cry out, if it is a boil; whilst the swelling of the air-

cells bordering on the meatus forms a tumour almost painless on pressure. The pain of the boil is even so severe that one should proceed very cautiously in introducing the speculum. Secondly, it is rare for a boil to be single; and, either at the same time or in succession, there exists almost always one or two others, which speedily makes the diagnosis evident. Finally, we should not forget that if there is at the same time the remains of an eczema of the meatus, a boil is probable.

Moreover, the careful analysis of the pain elicited furnishes information of the utmost importance. If we remember that a boil, accompanied by more or less lymphangitis and adenitis, is a lesion of the soft parts exclusively, and that mastoiditis, on the contrary, attacks first of all the skeletal structures, these differences will be explained.

In the case of a boil, if one alters the position or moves about the pinna of the ear, severe pain will be caused. On pressure around the ear (and especially behind the ear, in case of a boil on the posterior wall), opposite the swelling of the meatus, directing the pressure towards the latter, will cause the patient severe pain; on the other hand, pressing upon the mastoid process a little behind the retro-auricular furrow, and exactly perpendicular to the bone, we shall find this region quite insensitive to pain. If a suppurative inflammation of the mastoid lymphatic gland complicates the question, the differential signs which we have previously stated should be remembered; and in this particular case the inflamed gland is situated usually in the hollow in front of the apex of the

mastoid. This gland, moreover, is neither the only one nor the first attacked: *there is an inflammation of the gland, with tenderness on pressure, in front of the tragus.*

Finally, in doubtful cases catheterism should be practised; and we shall hear neither the noise of a perforation nor a rumbling, unless the boil has developed in a meatus, already unhealthy, infected by the secretions proceeding from the tympanic cavity.

(c) *Retro-auricular Lymphangitis.*—What we have just said as to the boil is applicable to the various forms of lymphangitis which originate as the result of the excoriations of the meatus and auricle. These forms of lymphangitis are seen accompanying acute eczema of the meatus, and even a simple chronic otorrhœa. The pain in front of the ear, the congestion of a gland in the hollow behind the jaw, and the relative insensitiveness of the bony skeleton to pressure enable us to establish the diagnosis; and several times we have cured, by wet dressings, patients to whom it had been proposed doing Wilde's incision or even opening up the mastoid process.

(a) *Periostitis of the Mastoid Process.*—We come now to the diagnosis of what is most insisted on in the classical works of surgery—viz., that by which we can differentiate between periostitis of the mastoid and inflammation of its air-cells. To make clear the data upon which such a diagnosis is made, we can hardly do better than quote the passage which has been devoted to it in the recent *Traité de chirurgie*,<sup>1</sup>

<sup>1</sup> T. iv., p. 725: Paris, 1891.

by Professor S. Duplay—one of the writers who has most and best studied the question.

“ In the beginning it is easy to distinguish the swelling which belongs to the one and to the other of these affections. In simple periostitis the swelling is diffuse—the furrow which exists between the concha and the mastoid process has disappeared ; in inflammation of the mastoid cells the swelling is more exactly circumscribed—the furrow which exists between the concha and mastoid process persists. The pain, on pressure, is much more marked and more superficial in simple periostitis than in inflammation of the mastoid cells.

“ The examination of the auditory meatus may also afford valuable information. Periostitis of the mastoid process is associated with osteo-periostitis of the tympanic cavity, which is constantly accompanied by a periostitis of the meatus ; the signs of this affection will therefore be observed. Suppuration of the mastoid cells, on the contrary, is not necessarily associated with a periostitis arising in connection with otitis media ; it is always accompanied by a purulent catarrh of the tympanic cavity, the signs of which—perforation of the membrana tympani, the existence of an otitis with granulations, small and large, and polypi—will be made out. In other, more rare, cases, whilst all the signs of an otitis media are observed, with pain and swelling of the mastoid region, the examination of the ear shows the membrana tympani injected, lustreless, thickened, sometimes bulged towards the exterior.

“ Finally, whether the membrane be intact or perforated, there is still one sign which indicates almost certainly suppuration of the mastoid cells—viz., the

existence of redness of the skin, with œdematous swelling, limited to the posterior wall of the bony auditory meatus. In fact, we know that at this level the meatus corresponds with the mastoid cells."

In considering the anatomy and pathology, we mentioned one of our cases, which clearly indicated that we may have an abscess behind the ear without mastoid suppuration, the probe entering directly from the purulent collection into the tympanic cavity, passing between the meatus where covered with skin, and the bony meatus where laid bare. In this patient—which we only saw, it is true, some days after an incision made by another doctor—the swelling corresponded well, by its position and shape, to the description just quoted. But we ought to add that in a number of cases, and particularly in young children,<sup>1</sup> the mastoid abscess, corresponding absolutely to the preceding account, has as its origin a suppuration of the antrum, the mastoid being laid bare at a spot limited to its level.

Periostitis of the mastoid is said to be observed most often in young children; but we have observed a considerable number of cases under one year old which were brought to us before the abscess was opened. In

<sup>1</sup> Mastoid abscess is very frequent in children, as will be seen on perusing our cases. We lay stress on this point, because, in a recent thesis (Paris, 1890), Dr. Grandhomme says (p. 32): "Compared with suppurations of the ear, which are frequent, mastoid abscesses are rare in children." Then he gives a special clinical description of caries and necrosis of the mastoid in children, which does not correspond with what we have seen. On this point see also Cheate, "The mastoid antrum in children," *Lancet*, December 3rd, 1892, vol. ii., p. 1264.

all, the abscess occupied the base of the mastoid process, obliterated the auricular furrow, tending to spread towards the temporal fossa; and in *all* of them we found at the bottom of the abscess a bare bony spot, of variable size, which, on being cut open by means of a gouge or curette, led us into the antrum full of pus.

That an unusually able clinician, then, can diagnose almost certainly periostitis from inflammation of the air-cells, we are the first to admit; but, personally, the diagnosis is as a rule obscure. On the other hand, we think that periostitis of the mastoid is very rare, since we have only met with one case out of 133 (in 128 patients).

We think that in practice the proper rule should be as follows:—The abscess behind the ear having been opened as if it were a case of mastoiditis, the bottom of the abscess cavity should be explored with the finger, to make sure that the nail does not grate against rough bone. That done, we should see whether from this spot the probe is directed towards the meatus and enters as far as the tympanum; but this would be exceptional. And, further, we must examine with care if it is not one of those rare cases of sclerosis with suppuration limited to the border air-cells—of which we have three instances (Cases X., XXXII., CXIX.). If in this way we do not find the meatus separated up by the pus, in practice we conclude it to be a case of mastoiditis; for we repeat—and, moreover, we are supported by the authority of Politzer, who makes the same statement—we have always found pus in the air-cells when the mastoid process is cellular.



*c. There is an abscess in the maxillo-pharyngeal triangle.*

In these cases, which are rare, we should hesitate, on account of their very rarity, to consider the mastoid at fault. In fact, almost all the abscesses in this region are cases of suppurative inflammation of the lymphatic glands (adeno-phlegmon), the mouth or pharynx being the seat of invasion. Clearly enough, if there is well-marked tonsillitis, or acute dental caries, we must not think of the mastoid. On the contrary, mastoiditis would be diagnosed without fear of a mistake if there were, at the same time, otitis media with swelling and pains in the region behind the ear. But if a patient suffers from otitis media, with mastoiditis, either latent or accompanied by fistulæ—*i.e.*, without reaction, or swelling, or redness, or pain in the region behind the ear—and suffers at the same time from adenoid growths, with nasal catarrh (and we know that such a combination is frequent), can he not have a suppurative inflammation of the glands by infection through the naso-pharynx just as much as a mastoid abscess behind the jaw? And relative frequency speaks in favour of the former hypothesis.

The diagnosis, therefore, will remain often enough in doubt. Happily, in practice, the rule of procedure appears fairly definite: we must open the abscess by an incision parallel with the sterno-mastoid, and explore with finger and probe, as we have just said, the internal aspect of the mastoid; and, afterwards, we should examine the external surface, according to circumstances, in accordance with the principles to be stated shortly.

These same considerations are applicable to the altogether exceptional cases, such as that of E. de Rossi.<sup>1</sup>

Another variety which may lead to error, when the progress is insidious, is abscess following inflammation of the cervical vertebræ. Schwartze relates that a case was sent to his clinic, with the diagnosis of mastoid abscess, suffering from Pott's disease in the cervical region; and, according to him, the opposite mistake is also possible.

## 2. DOES THE MASTOID DISEASE ORIGINATE IN THE MIDDLE EAR.

Suppose then, we have established, in a general way the diagnosis of a lesion of the mastoid process—does this lesion originate in the middle ear?

On this point, examination of the hearing tells us something, but it is indisputable that the chief fact which strikes the eye first of all is the existence of a discharge from the ear.

<sup>1</sup> Apropos of this last case (see p. 15), and also those of Guye, where pressure upon an abscess in the neck caused the discharge of pus from the meatus (see p. 46), we shall make some reservations. There exist, in fact, suppurative inflammations of the latero-pharyngeal region which, in children, open into the external auditory meatus, owing to a special small orifice in the bone: at first sight, we might consider it a form of the mastoiditis of Bezold (see A. Broca, Meslay, and Mayet, *Bull. de la soc. anat.*, p. 948 *et seq.*: Paris, 1894). This aperture in the antero-inferior wall of the meatus is situated naturally in front of the membrana tympani; but it is to be noted that de Rossi and Guye have observed the tympanic membrane to be intact. In the absence of an autopsy it is difficult to make any statement, but we desire to call attention to these particular points, which one of us shortly intends studying in detail.

It is true that, in our first section, we attempted to explain how, in our opinion, the pus, where there is a copious discharge from the ear, is derived from the air-cells much more than from the tympanum. But the origin of the infection is in the pharynx; the track taken is the Eustachian tube, the tympanum, and lastly the mastoid. Also, we do not agree with the view of Küster, developed by Körner,<sup>1</sup> that osteitis of the mastoid process is the primary affection; and, judging by one case of his own, Körner thinks that, especially in diabetics, the suppurations of the ear will be the sequel, not the cause, of the mastoid affection.<sup>2</sup>

We might be more positive, and adopt the views of Küster for the cases *where the mastoid disease arises without having been preceded by a discharge from the ear*; and for those where it is noticed during the operation, there is no communication with the tympanum. But still, we must make some reservations in such a statement. A great number of children on whom we have operated have never had discharge from the ear; and yet we think that infection, in almost all these cases, has come through the pharynx, but that the membrana tympani has not been perforated.<sup>3</sup> On

<sup>1</sup> O. Körner, "A case of primary diabetic osteitis of the mastoid process," *Archiv. f. Ohrenh.*, 1889—90, vol. xxix., p. 61.

<sup>2</sup> Apropos of glycosuria, we think it interesting to note a fact where, on the contrary, Truckenbrodt has seen this symptom marking the onset of meningitis, to which the patient succumbed in the course of an acute otitis media associated with influenza. (Second Congress of North German Otologists, held at Berlin, April 7th, 1890. Reported in *Zeitschr. f. Ohrenh.*, 1890, vol. xxi).

<sup>3</sup> Compare D. Previtt, *St. Louis Courier of Medicine*, June 1887; Derouet, *Arch. de méd. et pharm. milit.*, October 1889, t. xiv., p. 330; Giles, *Glasgow Medical Journal*, May 1889.

the other hand, after what we shall say upon the eburnations of the mastoid in the course of old-standing otorrhœas, and upon the possible isolation of certain air-cells, who would venture to state that a chronic lesion not actually communicating with the tympanic cavity has not communicated with it at some time?

It is, then, with extreme reserve that, exception being made of cholesteatoma—of which we do not wish to speak in this treatise—we accept the so-called *idiopathic suppurations of the mastoid cells*, independent of an initial middle ear inflammation. And we are also sceptical—but for other reasons—in regard to *primary or idiopathic forms of external periostitis*. These attacks of periostitis, to which Wilde's incision owes its success, have been described especially by Voltolini and by Knapp, and recently Dr. Lévi<sup>1</sup> thinks that cases he has described are instances. Following colds often, they readily become bilateral; there will be no alteration as regards hearing.

Although the writers engaged in this question try to lay down the differential diagnosis between this affection, a boil, and suppurative inflammation of the lymphatic glands, we believe, with Professor Terrier,<sup>2</sup> that they must have, often enough, made such an error in diagnosis; and, on the other hand, it is to be noted that in certain cases, classed as forms of primary periostitis of the mastoid process, the fact of their having originated in the middle ear is evident,

<sup>1</sup> Lévi, "Primary external osteo-periostitis of the mastoid process, and primary suppurative inflammation of the mastoid cells," *Gaz. hebdomadaire de médecine et de chirurgie*, p. 660: Paris, 1889.

<sup>2</sup> Jamain et Terrier, *Man. de pathol. et clin. chirurg.*, t. ii., p. 578.

even when the mastoid cells are diseased. We will mention, in reference to this point, the cases of Ayres<sup>1</sup> (of Cincinnati).

Whilst making these reservations, we would not absolutely deny the existence of a primary osteitis of the temporal bone generally, and of the mastoid portion in particular.

It would not be reasonable to say that, because the temporal is exposed to direct infection arising from the tympanic cavity, it escaped from osteomyelitis due to general infection, similar to that which attacks other bones; and we ask ourselves, for instance, whether it was not a question of true osteomyelitis of the temporal (we employ this word, as will be seen, in a different sense to that attributed to it by M. Pauzat) in two quite young children, upon whom we operated for an abscess behind the ear, where no otorrhœa preceded, and in which our curette passed between the two ununited portions of the bone. We can really only make hypotheses, more or less plausible, upon this subject, which deserves more serious investigation.

CASE XI.—*Osteomyelitis of the Mastoid portion of the Temporal. Operation. Cure.*

M. S., aged 4 months, was brought on April 24th, 1893, to the hospital.

*History.*—It is the only child of its parents, both quite

<sup>1</sup> Ayres, *Arch. of Otolology*, 1890, vol. xix., p. 95. In the first case the patient never had had anything the matter with the ears; but after making an incision, the sound penetrated into the air-cells. In the second case, it is to be noticed, the patient had had a suppuration some time before in the ear.

healthy. No previous illness. Fifteen days ago the ear discharged for four or five days, but already, before this, there had been swelling behind the ear. For eight days this swelling has been stationary. At present there is a typical mastoid abscess of large size.

*April 25th. Operation.*—Abscess incised. Mastoid opened by the curette, which passed between the two ununited portions. In the depths was seen the outline of the tympanum. Drained and sutured.

*May 19th.*—Child is quite well, the stitches and drain having been removed on May 2nd.

*December 27th.*—The child was, at our request, brought for inspection. The cicatrix was perfect, the ear had never discharged since the operation, and the general condition was excellent.

CASE XII.—*Mastoid Fistula, arising from Osteomyelitis (?) Mastoid and Tympanum opened up. Cure.*

F. R. ; 3 years old ; admitted to the hospital January 12th, 1893.

*History.*—Mother died of tuberculosis, father healthy. One child died at the age of one month. Following a severe and prolonged attack of bronchitis, the child—till then quite healthy—had a mastoid abscess, which a doctor treated by simple incision. As the fistula persisted, the child was brought to the hospital.

*January 28th. Operation.*—Removal of a sequestrum between the squamous and mastoid portions ; excision of the postero-superior portion of the outline of the tympanum ; tympanum curetted, and ossicles removed. The three portions of the temporal are ununited.

The mastoid retreats remarkably upon the squamous portion.

The child left the hospital before it was cured, and then it was lost sight of. It was seen again February 27th, 1894, quite cured, and without discharge from the ear. The hearing is good.

All that we can say is, that we have found in these two patients lesions different from those which we have seen in numbers of other young children, in whom the operation consisted simply of opening up the antrum. Another variety is the sclerosing osteitis, upon which M. Duplay has, with reason, laid stress in his remarkable memoir upon opening up the mastoid,<sup>1</sup> most often from no known cause, sometimes after shock. The mastoid becomes painful, and if opened up, it is observed to be eburnated. During recent years this affection, the origin of which is still obscure in many cases, has been very thoroughly studied by G. Nuvoli.<sup>2</sup>

In these patients, as a rule, a complete cure is obtained by hollowing out the mastoid; and, as has been very justly stated by M. Duplay, there is in this a very clear indication for opening it up. In our own cases there were two of this kind; and where an operation was done, an excellent result followed. In

<sup>1</sup> S. Duplay, *Arch. gén. de méd.*, May and June 1888, pp. 586, 719.

<sup>2</sup> G. Nuvoli, "Ostéite condensante douloureuse de l'apophyse mastoïde," *Boll. delle malatt. dell' orecchio*, May 1891, vol. ix., No. 5, p. 27. See also Owen and Pye, *Brit. Med. Journal*, 1885, vol. ii., p. 64; Lippincott, *Journal of the Am. Med. Assoc.*, vol. xiv., p. 50, Chicago, 1890; Florency, *Paris méd.*, 1886, p. 157; Knapp, *Trans. of the Amer. otol. soc.*, vol. iii., p. 676, New Bedford, July 20th, 1886.

one of our patients the causation remained unknown (Case XIII.). The inference to be drawn from these facts is, that we shall not regret having opened the mastoid in these cases where mastoiditis is diagnosed and where no affection of the air-cells or even a single cell is found; and when an operation of this kind has been undertaken, one should not excavate further into the mastoid under the pretext of searching for an imaginary mastoid abscess.

CASE XIII.—*Painful Sclerosing Osteitis of the Mastoid.*  
*Operation. Cure.*

C. complains of very severe pains in the side of the left mastoid process.

*History.*—No swelling, no tenderness on pressure, no discharge from the ear. The patient does not know what originates his pains; they are lancinating, almost constant, with exacerbations at night. He has facial paresis of the same side. The application of leeches, powdering with chloride of methyl, the air-douche, the applications of ice, fails to relieve the pain. The mastoid process is therefore to be opened up.

*February 5th, 1892. Operation.*—We found a mastoid eburnated, in which there was much difficulty in making an aperture. The opening up of the bone carried very deeply—to a depth of 2 cm.; did not encounter any air-cells. Suture; union by first intention.

Since this period the pains have not reappeared, and the facial paresis has disappeared. The patient has been seen several times since, and appeared quite well (February 1895).



CASE XIV.—*Painful Sclerosing Osteitis of the Mastoid.*  
*Operation. Cure.*

J. L.; 9 years of age; admitted to the hospital December 11th, 1892.

*History.*—This child is the only daughter of parents who are quite healthy; it enjoys good general health, in spite of whooping-cough at four years and scarlet fever at six years. For the last three years, following on a blow which she received from a gas-burner, she has suffered pain, distinctly localised to the tip of the right mastoid process; this tenderness, which is greatly increased by pressure, sometimes manifests itself spontaneously, occurring as shooting pains. Besides the tenderness on pressure, local examination shows that on the right side the mastoid projection is a little more prominent than on the left. No redness or other alteration of the skin and subcutaneous tissues.

*December 11th, 1892. Operation.*—Opening up at the seat of election. The mastoid is hard, eburnated; no air-cells present. Union without drainage; aseptic dressing.

*December 18th.*—Stitches removed; union perfect. The child left the hospital.

Since then she has been seen on several occasions, and, at our special request, she was brought back to us on December 30th, 1893. The scar is almost invisible; the mastoid is absolutely quiet, both spontaneously and on pressure; the hearing is excellent, the general condition perfect.

When, as in Case XIV., a definite external cause

(trauma) intervenes, and when, on the contrary, there is neither otorrhœa nor trouble with the hearing, primary sclerosing osteitis may be said to exist. But the clearness of diagnosis may be less marked; so much so, that after certain forms of chronic otitis media, the mastoid has been seen eburnated, and to become the origin of radiating pains (Case XV.).

In the two cases, moreover, operation is indicated, and should be done according to the rules laid down (p. 165), with reference to mastoid fistulæ. In two instances of this kind which we report, we obtained one successful and one negative result, in spite of several operations.

CASE XV.—*Eburnation of the Mastoid Process following Otitis Media. Operation. Cure.*

The patient, named Gil, 30 years of age, was admitted to the hospital, under the care of Dr. Monod, January 10th, 1894, for pains situated at the level of the right mastoid process.

*History.*—Was healthy up to September 1873. At this time she had *la grippe*, with quinsy, and suppurative otitis media; very severe pains in the ear, which only disappeared when the membrana tympani ruptured spontaneously, with discharge of pus from the meatus. The discharge continued from this time up to a month ago. Since its disappearance there have been pains in the head and at the level of the mastoid. Subnormal temperature. At the end of a month, not finding any improvement in her condition, the patient decided to come to the hospital.

*Present State.*—On examination, there is no rise of

temperature. A little redness, heat, and œdema at the level of the mastoid ; and pressure with the finger gives rise to pain. No discharge from the external auditory meatus.

Dr. Monod asked Dr. Broca to examine the case, and the latter decided, after examination, that opening up the mastoid was indicated.

*The operation* was done on January 15th, 1894. The mastoid was opened, by means of a chisel, at the level of the antrum, but no pus was found. The mastoid distinctly eburnated. At the bottom of the cavity the aditus was visible, and the probe passed into it.

This operation resulted in disappearance of the pains in the head, and from the first evening the patient was able to sleep.

The patient left the hospital eight days later, and returned for dressing every four days.

Seen again at the end of February. Cicatrisation complete. No pains and no headache.

CASE XVI.—*Painful Eburnation of the Mastoid Process (old Otorrhœa). The Mastoid hollowed out. Unsuccessful.*

N., 18 years old, came to the hospital April 21st, 1892.

*History.*—Complained of hearing buzzing noises in the left ear, and of having very severe and spontaneous pains in the whole of the left mastoid region. The pains are increased by pressure at the level of the mastoid insertion of the sterno-mastoid muscle ; they radiate especially behind and below. Also, there

exists a purulent discharge of old standing from the ear, and a perforation of the membrana tympani is seen.

The treatment of the otorrhœa, continued for several months, led to the disappearance of the discharge, but not cicatrisation of the membrana; and the pains persisted, with alternate accentuation and diminution, in spite of every method of treatment adopted. (Horteloup's leech, choride of methyl.) They became so unbearable as to prevent sleep. The patient lost appetite and was wasting, so we decided to operate December 2nd, 1892.

*Operation.*—Incision; periosteum stripped up easily; but when the mastoid process was attacked with a chisel, very hard bone was met with, in which one could hardly make an opening. The air-cells were not seen in the position where they are usually met with. The opening appearing large enough, the wound was closed, sutured with care, and dressed.

The dressing was removed on the seventh day, and the wound united by first intention.

During the days following the operation the patient appeared to improve; she slept and ate, but did not find the pains disappear. She ceased attending the hospital after some days, but without much improvement,—she complained always of pains; and these pains became so unbearable that we attempted a second operation on June 7th, 1893. This time we opened up still more thoroughly the mastoid region, up to the canal of the antrum. Union by first intention. We ought to say that this second operation was not accompanied by success from the functional point of view.

In order to give a complete sketch of the diseases of the mastoid region, it remains for us to mention syphilis, tuberculosis, tumours, innocent and malignant, (sarcomata, carcinomata), sebaceous and dermoid cysts. But we do not wish to weary ourselves with these rarities, for these affections are either very rare in themselves or very rarely so disposed as to give rise to error.

When a mistake is possible, is it always avoidable? Schwartze, whose skill is so great, once plunged a bistoury into a mastoid sarcoma, which he mistook for an abscess. Let his example be a warning in diagnosis to the presumptuous.

As for cholesteatoma, we shall say simply this: in many of the cases we believe we have to do with a chronic suppuration of the middle ear; and in operating, we came across a cholesteatoma of the mastoid which gave no indication previously of its presence.

#### § 4. INDICATIONS FOR TREATMENT.

For the successful study of the treatment of acute mastoiditis it is of importance to distinguish two classes, according as the mastoid complication supervenes in the course of an acute or of a chronic otitis. It is especially upon the former that we lay stress for the moment.<sup>1</sup>

I. *Mastoiditis resulting from an Acute Otitis Media.*—There have been many discussions and dissertations

<sup>1</sup> Lubet-Barbon and Alfred Martin, "Traitement des suppurations mastoïdiennes," *Bull. et mém. de la soc. franç. d'otol., de laryng., et de rhinol.*, t. x., p. 53: Paris, 1894.

upon the therapeutic indications in mastoiditis which complicate attacks of acute otitis ; and this especially so, as we shall see in the course of this treatise, in order to try and limit the indications for operative measures. The justification of timidity seems to have been the principle aim of the majority of aurists ; but we must, however, recognise that some of us have contended for early and radical operations.

To make our point of view understood at once, we will say that the latter appear to us to be, in principle, in the right. Nevertheless, we are far from pretending that it is always necessary to open an inflamed mastoid ; and we think that, in order to state the indications precisely, the facts should be divided into two main categories—viz., with, or without, an abscess appreciable externally.

(a) *There is no external abscess.*—We have tried to make it clear, in the preceding pages, that every acute otitis media is accompanied by a similar inflammation of the mastoid cells. But in the majority of these cases, the canal of the antrum remaining patent, the pus easily evacuates itself without it being necessary to operate on the mastoid process : the mastoid affection requires no special treatment. It has, doubtless, been proposed to open the air-cells in almost all cases of acute otitis. This is not, from certain points of view, unreasonable—and perhaps the treatment of the acute suppuration of the ear would thus be conducted with more safety and rapidity ; but admitting the good results obtained by simple and classical methods, we do not believe it right to commend opening up the mastoid for the acute forms of otitis accompanied by

a little tension and pains about the mastoid—that is to say, for the majority of cases.

But when, in consequence of the obstruction of the perforation in the membrana tympani or of the aditus, the pus is pent up in the air-cells, when does the mastoid complication resulting surpass the initial disease? In these very conditions we do not believe it necessary to have recourse to the knife at once. Sometimes, as a matter of fact, even at this point the mastoiditis cures itself quite spontaneously; and this recovery becomes frequent if the non-operative procedures are well attended to.

As to the local and mastoid treatment, the only clear indication in our opinion consists in relieving the pain; and we cannot lay claim to having caused, by manœuvres at a distance, the resolution of the inflammation in the air-cells, which may occur naturally.

By attentive and regular treatment cure is obtained, most often in these slight cases, and even sometimes when the mastoiditis is already very pronounced, with severe pain, fever, œdema, and redness behind the ear. But if, in spite of the care we indicate, rapid cessation of the symptoms is not observed, then we recommend operation, without waiting for serious complications.

In our opinion, the principal indications are the persistence and severity of the pain behind the ear, the intensity of the fever, the gravity of the general symptoms, and the suggestion of meningeal symptoms. Obviously, even when the symptoms are serious, we do not advise opening up the mastoid if the tympanic cavity is intact or insufficiently opened. So we begin,

then, by clearing out the middle ear well, and often the result will be surprising. But if, although these symptoms are present, we are sure there is nothing retained in the tympanic cavity, there need be no further hesitation, even if the mastoid region appears normal or almost so. Several times we have operated in these conditions, and we have only had to congratulate ourselves thereon. We will mention, for example, our Case XXVIII., where, after the mastoid was opened, we saw the headache disappear and the temperature fall from  $104^{\circ}$  to  $98.6^{\circ}$  Fahr. In this child's case we only acted in this way after making quite certain that treatment by the natural passages was impossible. But sometimes we advise not even attempting this treatment; and it was thus in our Case II., where the opening up of the mastoid was performed as an urgency operation, without time being taken to ascertain exactly the condition of the tympanum and its contents, in a child brought to the hospital comatose, with high fever, where, from the very next day, recovery was remarkable.<sup>1</sup>

In cases of this kind, then, we must be guided by the general symptoms, without allowing ourselves to be hindered by the apparent soundness of the mastoid region, especially by the absence of an abscess; and so it is, being even more radical than Politzer, we understand early operation.

When Politzer read, before the Society of Otology,

<sup>1</sup> Pomeroy, *Amer. soc. of otology*, 1886, vol. iii., p. 680. Th. Heimann, *Ann. des mal. de l'or. et du lar.*, 1891, t. xvii., p. 328. Dalby (and discussion), *Med. chir. trans.*, vol. lxxviii., p. 115: London, 1885. Suné Y. Molist, *Cong. intern. d'otol. et lar.*, p. 14: Paris, 1889.



Laryngology, and Rhinology of Paris, the memoir we have already quoted on several occasions, several of his colleagues, especially Gellé<sup>1</sup> and Lœwenberg,<sup>2</sup> did not agree with his conclusions—almost, in fact, charged him with rashness, and declared that without operation they cured almost all their patients. But we do not think that Politzer's operations were so dangerously early. In proof of this, we only require the observations he produced. The author undertakes to prove that the specially serious mastoiditis due to influenza ought to be opened at a very early date ; and to support his opinion he relates the history of a woman, thirty-five years of age, who, being attacked by influenza in December 1891, was treated from January 3rd (by another doctor) for acute otitis ; was seized with undoubted mastoiditis in the first days of February ; was admitted to the hospital on March 1st, and was then only operated on on March 12th because of grave cerebral complications (coma ; temperature 103.1° Fahr.), though since her admission she had an abscess behind the ear and a considerable "dip" of the postero-superior wall of the meatus. Altogether, six weeks were lost ; and death from cerebral abscess did not surprise us. If we had had to criticise Politzer upon his communication, then, we should certainly not quarrel with him as to his "rashness," since, in our

<sup>1</sup> The views of Gellé will be found defended, moreover, by his pupil Orgogozzo in his thesis and in a memoir which the latter has inserted in the *Annales des maladies de l'oreille et du larynx*, 1892, p. 821.

<sup>2</sup> Lœwenberg had already energetically maintained these conservative opinions before the *Congrès de chirurgie*, in 1885, First Session, p. 642.

own practice, we have never allowed a mastoiditis *with abscess* to develop continuously for twelve days. For if the operation appears to us to be urgent, as we have just said, in certain cases where the mastoid region is not even œdematous, after there is an abscess, the urgency can no longer be questioned.

CASE XVII.—*Acute Mastoiditis without Abscess. Cured by Operation.*

F. C. ; 30 years of age.

*History and Present State.*—Acute otitis media, with rigors ; very severe pains since the commencement, preventing sleep, and associated with excessive tension in the whole of the head. Seen on the third or fourth day of his otitis, in April 1892 : small perforation ; membrana tympani bulging ; tenderness on pressing upon the mastoid, with no alteration of the integuments. Paracentesis ; air-douche. Amelioration for the first day, but, two days after, the orifice of the perforation was closed by a small bead of granulation tissue. Perforation enlarged ; removal of granulation tissue by curette. Two days later, similar obstruction and similar treatment, which led to a slight cessation of the symptoms. But the mastoid became more painful and a little swollen, and the general condition became worse, with rigors and fever.

*Operation.*—Superficial structures healthy. After carefully stripping up the periosteum, the cortical part of the bone appeared healthy, but of a slightly bluish colour. Opening up at the seat of election, which led rapidly into a suppurating cavity. Sutures ; drainage.

Cure at the end of a month, without incident. Hearing normal.

CASE. XVIII.—*Acute Mastoiditis without Abscess. Operation. Cure.*

C. ; 3 years old ; admitted June 1893.

*History and Present State.*—Suppurative otitis media, secondary to *la grippe*, dating about three weeks, in a pale, weakly child. When it was brought to us there was a very abundant discharge, containing flakes and mucus, escaping externally by a small perforation, which is still diminished by the presence of red granulations in the tympanic cavity. Tenderness on pressing upon the mastoid. Paracentesis ; air-douche ; evacuation of an enormous quantity of muco-purulent liquid during the night following. Improvement. At the end of five days the perforation was again pin-point, and there was swelling and redness behind the auricle. We indicated to the parents the probability of an operation. Paracentesis again ; ice-bags maintained continually on the mastoid. Diminution of the redness. For fifteen days the discharge went on freely, and we thought we had avoided operation ; when once more, after a sleepless night, the child was brought back to us, and we observed the mastoid to be swollen and red. The same methods which had succeeded in our hands on one occasion were employed again, but unsuccessfully, and we operated.

*Operation.*—Incision through the soft parts and periosteum ; no pus visible. The superficial bone appeared healthy, but opening up at the seat of election showed us that it was very thin, and the first blow of the chisel

caused the pus to gush out. Opening of the antrum—full of granulations. Cured; plugged; dressed as usual.

Cure at the end of two months, without incident.

Seen again in perfect condition December 1894.

(b) *There is an external abscess.*—We have, in our clinical description, indicated the two kinds of abscess—retro-auricular and retro-maxillary, this latter being altogether exceptional. As a matter of fact, we have only seen the retro-auricular abscess.

When an abscess has formed behind the ear, the practice, which is “as old as the hills,” consists in opening it. But it seems to us that this practice, glorified in our time by the name of “Wilde’s incision,” ought to be definitely given up.

Wilde, we are aware, never proposed to treat, by the simple incision, inflammation of the mastoid cells. He recommended, given a mastoid abscess, to make a *tentative incision*, which will definitely cure, if it is only a periostitis, but which is to be followed by opening up of the mastoid if the symptoms do not diminish at the end of twenty-four to forty-eight hours. We hold the same view as to this tentative incision as Professor Duplay: “This practice, adopted by the majority of aurists, appears to me to be without any advantage, and causes the loss of valuable time. If there really is pus in the mastoid cells, the external incision is of no avail, and it is certain, in my experience, that it has only succeeded in diminishing the symptoms in the cases where it was not a question of inflammation of the mastoid, but of a simple periostitis.”

Unfortunately all surgeons are not of the opinion of this great master; and some of us, dreading the results of the opening up, and imbued, moreover, with the false idea that in the majority of cases the swelling behind the ear is due simply to the periostitis, have deemed it sufficient to open the retro-auricular abscess, by making in this region a deep incision, including soft parts and periosteum. This incision certainly has the advantage of subduing the pains caused by the retention of pus under the periosteum by releasing it; but, except in the cases described by Professor Duplay, the periostitis is not the whole trouble—it is only the symptom, and the expression of the deep suppuration of the mastoid cells. In reality, in the cases which we are dealing with, Wilde's incision will only have as a result the opening of one of two purulent collections—the most external and least dangerous; whilst the other, the deeper, will continue in its progress.

Wilde's incision is nothing else than the artificial opening of an abscess which would have opened spontaneously some days later, occasioning as the result a fistula.

Without doubt, after this operation the pains cease and the general condition is improved. The discharge diminishes as after the spontaneous opening, but most often this improvement only lasts a few days. Two things may happen: either the symptoms of suppuration within the mastoid reappear in all their severity; or, in spite of Wilde's incision having been made, one is compelled to open up the bone; or, secondly, the superficial wall of the mastoid is perforated unnoticed, from within out, by caries of the bone, and a fistula is established between the system of air-cells and the exterior.

Also, we ask ourselves how Drs. Gellé and Lœwenberg, for instance, could for several years have cured all their cases of mastoiditis which were treated without opening up a single mastoid, as they consider Wilde's incision the severest of useful operative measures? We do not dispute the possibility of success with the simple incision into the collection behind the ear: from time to time frequently one sees cure after the spontaneous opening of the abscess. When the mastoid is spontaneously and widely opened up, the pus from the air-cells discharges externally; the sequestra, if there are any, are got rid of, and cicatrisation takes place as after a surgical operation. But this spontaneous perforation is not the rule. In general, the bone is simply laid bare, without being perforated. And we cannot say that these fistulæ and recurring abscesses are rare: we have operated on more than fifty, and almost all the patients had been submitted to Wilde's incision.

We believe, then, that the successful results of this treatment would be wholly exceptional if they were not supported by frequent errors in the differentiation from the various forms of peri-auricular lymphangitis; and this is why we have insisted upon this affection at such length.

The diagnosis, as we have said, will sometimes remain obscure; and it is for this reason that we recommend, after every incision into an abscess behind the ear, the tentative exploration of the subjacent bone, to make sure whether the mastoiditis has not laid bare some spot. Let them show us, then, patients, with the mastoid bared (and not spontaneously opened up), cured

by simple incision,—and we require, moreover, that these patients should be followed up for a long while ; for our Cases XIX. and XX. compel us to take into consideration the recurrences, more or less distant, after an apparent success of the simple incision. We will here mention two, among other instances.

CASE XIX.—*Mastoid Abscess. Simple incision. Cicatrisation. Persistence of the pains. Mastoid opened up. Cure.*

*History.*—M. X., 46 years of age, whilst living in Spain, had, at the commencement of 1890, influenza, and at the same time suppurative otitis media on the right side. After a very short time very severe pains in the mastoid region set in, with the formation of an abscess behind the ear. Wilde's incision was made. A considerable quantity of pus escaped, but the pains did not cease ; they became so violent that the patient could no longer attend to his work, and was obliged to keep to his bed. The same condition continued, with rigors and the onset of fever, until towards the month of May, when the patient came to France. The discharge from the meatus was not considerable. There was a perforation of the membrana tympani at its antero-inferior portion, but the mastoid was always extremely tender. Complete deafness on the right side.

*September 12th, 1890. Operation.*—Mastoid opened up ; very little pus in the superficial cells.

Dressed eight days after the operation. Rapid cure.

On November 15th the patient left Paris, free from pain, with the perforation of the membrana tympani closed and the hearing as it was before the discharge.

CASE XX.—*Mastoid Abscess. Simple incision. Recurrence two years later. Mastoid Fistula. Operation. Cure.*

P. B.; aged 9 years; admitted to the hospital June 7th, 1893.

*History.*—The parents, who are quite healthy, have lost one child from measles. The mother says that the child's left ear has discharged since quite an early age, disappearing for some days and then reappearing. The right ear has never discharged. Two years ago an abscess behind the ear occurred, which was opened up, and then closed after fifteen days. But a month ago another formed, as large as an egg, which opened spontaneously.

*At present* there remain two fistulæ behind the ear, each as large as a penny piece, with granulations. The mastoid everywhere is tender to pressure. The meatus is completely blocked by a polypus.

*June 15th.*—Mastoid opened up at the seat of election, where it presented an orifice, only admitting the probe, and surrounded by hard and dense bone. After curetting the air-cells, which contained a few masses, of caseous appearance, the protector (see Fig. 3) was introduced into the canal of the antrum, which was very large and full of granulations; the meatus was separated up, and then the tympanum opened. The malleus was found in the middle of the granulations; the incus was not seen. There were no sequestra and no caries. Plugging with iodoform gauze through the wound and the meatus. The dressings were applied as usual.



The child was taken away by its parents on August 10th, having still a cavity packed with granulations everywhere. Highest temperature (rectal), 100° Fahr. Since this it has returned, but irregularly, to be dressed.

At our request it was brought back for our inspection on December 26th, 1893. The cicatrisation is perfect; but there remains a slight otorrhœa, which is being attended to very irregularly. The mastoid is not tender.

So that we come to the conclusion that when the bone is found bared at the bottom of an abscess behind the ear (and we shall say the same for peri-pharyngeal abscesses of mastoid origin), immediate opening of the air-cells is indicated. The tentative incision is only justifiable if in case of urgency the necessary instruments are not at hand for readily carrying out radical treatment, and if it is believed to be more prudent in the meantime not to abandon the abscess to itself for a still longer period. The following two cases are examples of this:—

CASE XXI.—*Mastoid Abscess. Tentative incision. Opening up. Cure.*

C. D.; aged 1 year.

*History.*—I was called to this little girl July 29th, 1893, by my friend Dr. Schrœder. It was a sturdy child, brought up in the country, on the bottle; its personal and hereditary antecedents were excellent. She has never had any of the acute diseases of infancy; but eight days ago, without previous otorrhœa, she was seized with fever, soon followed by swelling behind

the ear. On July 28th the child was brought to Paris. The same evening Dr. Schröder let out pus by a puncture made at the spot where the abscess pointed, and he begged me to come and examine the child the following day. I found a swelling still considerable in size. Lemon-coloured fluid escaped from the incision. No otorrhœa.

*Operation.*—Immediately, I opened the mastoid, which the incision had enabled me to see bared over a surface about the size of a shilling; and there I found a surface as large as a lentil where the bone was depressible. After removal of this lamella, by a curette, I found pus in a mastoid cell, which was scraped. There was nothing appreciable in the canal of the antrum. Drainage-tube in the wound, which was sutured, and another in the meatus.

*August 3rd.*—The child is very well. The dressing has been changed. There is no suppuration in the meatus. Some drops of pus upon the deep end of the posterior drainage-tube. I replaced one drainage-tube, slightly flattened, and removed it on August 8th.

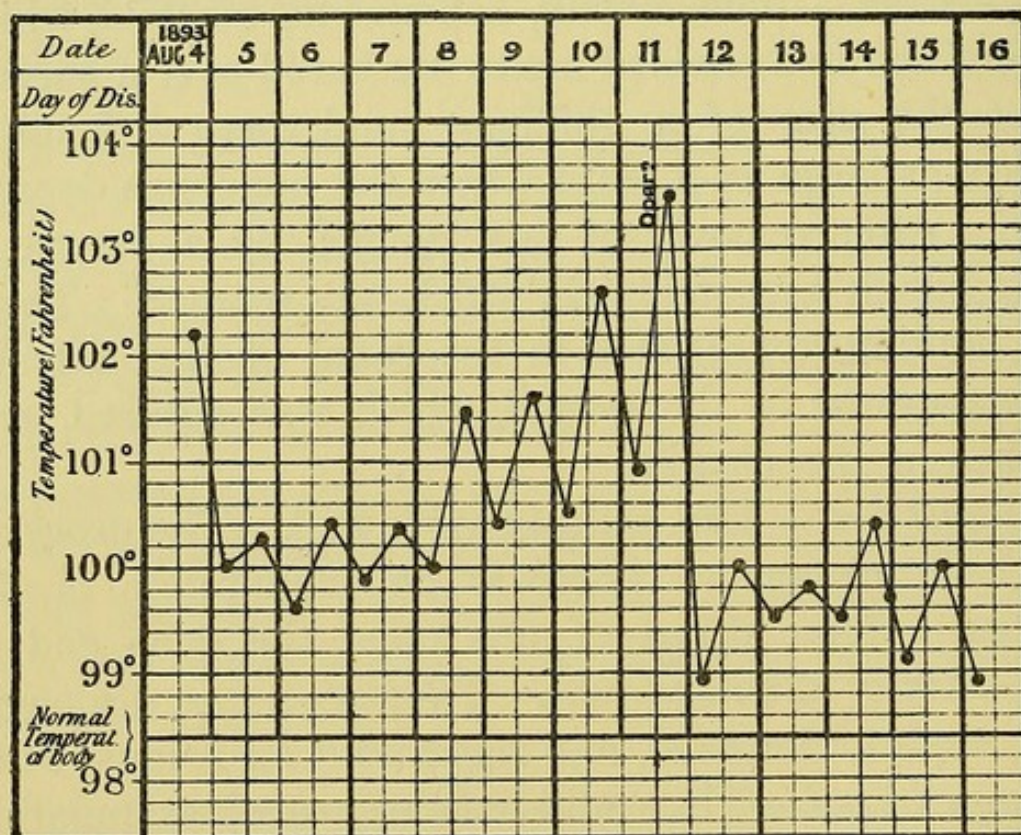
*August 23rd.*—There still remains a small granulating spot at the angle where the drainage-tube had exit. The child went to the country, where it was completely cured in a few days.

Since then it has been in very good health, as Dr. Schröder writes me on December 15th, 1893.

CASE XXII.—*Mastoid Abscess. Tentative incision. Subsequent opening of the Mastoid. Cure.*

E. K.; 9½ years old; admitted to the hospital August 4th, 1893.

*History.*—Out of sixteen children, eight are dead. The father suffers from chronic bronchitis. The child's usual health is good. Eight days ago it was seized with very severe pains in the right ear, with mastoid swelling, fever, and repeated attacks of epistaxis. Quinine sulphate was given without success, and at the end of two or three days the ear began to discharge.



CASE XXII.

*At present* there is, on the right side, a tense swelling behind the ear, with redness and tenderness on pressure. The sterno-mastoid muscle is contracted; the movements of the neck are painful.

*August 5th.*—In my absence, Mr. Manson, the house-surgeon, simply opened the abscess, and for three days the fever fell from  $102.2^{\circ}$  to  $100.4^{\circ}$  Fahr.; but it was not long before it rose again, and the pains persisted.

*August 11th.*—Temperature rose above  $102.2^{\circ}$ ; and on the morning of the 12th the mastoid was opened up at the seat of election.

The next day the fever ceased, to reappear no more; the same for the pains.

*August 17th.*—The child was taken away by its parents, who promised to bring it back to be dressed. They did not keep their word, but had it dressed at a dispensary.

Cicatrization was obtained in about a month. At our request the child was brought up on December 25th, 1893. Cicatrization was perfect, the mastoid quiet, and the otorrhœa dried up. Hears voice whispered at  $6\frac{1}{2}$  feet; watch at  $\frac{1}{50}$  in.

One further question deserves to be raised: the subjects attacked by mastoid abscess are recovering from an acute disease, especially scarlet fever; sometimes, also, they have retained after this scarlet fever an albuminuria more or less marked,—would it not be proper, then, in order to allow more time to convalesce, to let them at first submit to the simple incision, so that the opening up may be undertaken later on, when they will be in a better condition to undergo a more serious operation?

We do not think so; and, except in certain cases of grave cachexia, which we have never yet met with, we recommend operating even in the presence of albuminuria, fully believing that the suppression of all the infectious foci known, as rapidly and radically as possible, is, in spite of what has been maintained, the best method of treating secondary infections of

the viscera. On this point we refer to our Case XLVIII. (of which the subject was, moreover, tuberculous), and we shall relate here an analogous instance. In these two patients we not only opened up the antrum, but did the very much more laborious and complex operation which consists in opening, at one time, the mastoid and the tympanic cavity. We acknowledge, moreover, without hesitation, that, in the patient of Case XXIII., we should today confine ourselves to opening the mastoid and to curretting the aditus, as we shall say in a moment.

CASE XXIII.—*Mastoid Abscess. Mastoid and Tympanic Cavity opened up. Cure.*

M. H. ; admitted to the hospital July 20th, 1893.

*History.*—Nothing of importance in the family history. At two years of age the child had whooping-cough ; at three years of age, diphtheria. Also, when two years of age, he had two abscesses in the chest wall, the scars of which are visible. In the month of May last he had scarlatina, and ever since he has had albuminuria. A little time after (two months ago), he had a copious discharge of pus from the right ear ; and fifteen days ago the mastoid abscess appeared, preceded by marked fever, with pains in the right ear, restlessness, and some delirium.

*Present State.*—Behind the right ear is a large abscess. The meatus is full of foetid pus. The mastoid region is tender on pressure. The child is pale, with somewhat œdematous lids, and is emaciated. Examination of the urine shows a large quantity of albumen. The

child coughs a little, but presents nothing definite on percussion and auscultation.

*July 20th. Operation.*—The abscess was incised, and the mastoid laid open around a spontaneous perforation situated  $1\frac{1}{2}$  cm. behind the meatus, and through which granulations projected. The canal of the antrum, very large and full of granulations, was opened upon the protector. I did not remove the ossicles in the midst of the granulations of the tympanum.

The child left the hospital in November, still suffering from a mastoid fistula, for which he came to be dressed regularly twice a week.

The plugging was at one time made too much through the wound behind the ear, and not enough through the meatus, which closed up, and thus delayed the recovery. The meatus was then, from the end of December, methodically plugged. Soon suppuration ceased, and on January 30th the fistula behind the ear closed.

*February 24th, 1894.*—The cicatrisation has remained perfect. The ear does not discharge. The posterior wall of the meatus, however, in its deepest portion, presents a granulating non-cicatrised surface.

Since this time the child has been brought back from time to time for an intermittent and slight otorrhœa, which ceases every time after instillations of carbolic glycerine have been made regularly for several days. The cicatrisation behind the ear remains sound.

To conclude, we will consider an exceptional case, since we have only a single one, although of importance in practice—that of bilateral attacks of acute

mastoiditis. In this case we believe that the best plan is to operate on the two sides at one sitting. Simple opening up of the mastoid is a very harmless operation, which an experienced surgeon can perform in less than a quarter of an hour; and there is no inconvenience in doing this twice, one after the other, upon a patient. This procedure, differing from that which we recommend for the bilateral attacks of chronic mastoiditis, which are much more frequent, has given us rapid and complete success.

CASE XXIV.—*Acute Mastoid Abscesses. Both Mastoids opened up. Cure.*

I. D., 6½ years of age, was brought to the hospital on January 3rd, 1894.

*Family History.*—Good. The father, however, suffers from Addison's disease. The child had measles July 1893, and since has for a long time had enlarged glands in the neck. In October 1893 the right ear began to discharge; some days later the left ear was attacked. The pus which escaped sometimes had a very foetid odour. The discharge ceased towards December 15th, but at the same time there appeared a swelling behind the right ear. Soon there appeared a similar one behind the left ear.

On January 3rd, 1894, the child came to the hospital. It presented, on the right side, an abscess as large as a walnut, situated behind the superior extremity of the pinna of the ear; on the left side, the abscess—as large as a hazel-nut—was placed behind the upper third of the auricle.

*January 3rd, 1894. Operation.*—On the *right* side,

abscess opened. At the bottom, the bone presented a small perforation as large as a lentil. The curette entered a cavity as large as a small pea. The probe did not penetrate anywhere. Mastoid opened up at the seat of election. Pus found in the mastoid cells, which remained separated from the preceding cavity by a wall, which was destroyed with a fine gouge. The air-cells were curetted; then, the canal of the antrum appearing in good condition, a drainage-tube was inserted, and sutures applied. On the *left* side, the abscess was similarly opened, and a bare spot, symmetrical with that on the opposite side, was found. In scraping it out with a curette, the dura mater was reached superiorly. Mastoid laid open at the seat of election, and the cells were found full of pus; they were larger than those of the opposite side. Drainage; suture.

*Bacteriological Examination of the Pus by Dr. Péron.*  
—Streptococcus (in the abscesses of) both sides.

*January 10th.*—First dressing. The suturing has not succeeded. Stitches and drains removed. Plugging with iodoform gauze.

The child left the hospital on January 10th, and since has come to be dressed twice a week.

Cure by March 24th, 1894. No further trace of discharge from the ear. No pain. Hearing good. General condition excellent.

It remains for us to ask what ought the operation to be in its main principles, and if we ought to confine ourselves to the opening of the air-cells, or, on the contrary, go further and penetrate to the tympanic



cavity? In other words, we must not forget the mastoid complications of acute attacks of otitis media.

The reply to this question is fully stated in the paragraph dealing with the pathological anatomy and physiology. There we have said that, in our opinion, from a pathological point of view, the affection of the mastoid is of much greater importance than that of the tympanum; we have shown how, sometimes, the middle ear tends to recover, and to recover even when, with the aditus blocked up, the mastoid abscess declares itself and progresses.

From this it follows that the principle is to open the air-cells, but respect the tympanum, free drainage of which is useless. It is the rule, after this opening, for the discharge from the tympanic cavity to dry up of itself; and the latter cicatrises up, without it being necessary to act directly upon it. Yet in some subjects, after having thoroughly curetted the air-cells, we find the canal of the antrum to be wide, full of granulations and pus, surrounded by bone, which is red, rarefied, and friable under the curette.

As for mastoid abscesses, with recent otitis media, these cases, we admit, are rare; but, briefly, they do exist, and we believe it good surgery to let oneself be guided step by step according to the lesions observed. Simple opening up is what we must aim at; but we must not convert this precept into an absolute law, in spite of local manifestations occurring by the way. In the case of several children, both of us, operating together or separately, have thus been led into the tympanic cavity. Some of these patients have no doubt had for several months a

suppurating cavity, but the majority have been quickly and thoroughly cured, and all have finally been cured. Whilst laying stress on this, we allow that it is an exceptional method; but it is only necessary to read the following two cases to be convinced that it is sometimes justifiable. On the other hand, we do not hesitate to admit that, in the patients in Cases XXIII. and XXVII., we probably set to work too quickly, and doubtless simply laying the mastoid open would have sufficed.

CASE XXV.—*Mastoid Abscess. Mastoid and Tympanum opened up. Cure.*

Y. D., 14 months old, was brought to the hospital on June 29th, 1893.

*History.*—This child, whose family history is good, was suckled by the mother till five months old; since then it has been bottle-fed. In the month of December it had bronchitis; in February, measles; in April, an abscess about the anus, on which I operated on the 14th, and which is to-day completely healed. It has impetigo of the hairy scalp, coryza, and scabs about the nostrils. Six weeks ago it began to have a discharge from the left ear; then, eight days ago, the mother noticed a swelling behind the ear. This swelling has steadily increased in size. For the last three days it has been stationary. The child has been feverish ever since.

*Present State.*—In the middle of the mastoid there is an abscess, red and fluctuating, as large as a walnut, tender on pressure.

*June 30th. Operation.*—After opening the abscess, the mastoid, which was bared, was found friable enough to break down under the curette; the air-cells, and particularly the antrum, were full of pus and granulations. In scooping out the friable bone, and without using the fine gouge, I got right in to the tympanic cavity, after destroying the posterior-superior wall of the meatus, and in the middle of the granulations in the tympanum I brought away the ossicles.

The pus, examined by Dr. Péron bacteriologically, was sterile.

The temperature reached 100° Fahr. on the second day.

The first dressing was on the eighth day.

From this time the child was dressed regularly every four or five days.

*December 30th, 1893.*—Behind the ear a narrow fistulous track persists.

At the end of February 1894 a cure was obtained, and there was neither a fistula behind the ear nor otorrhœa.

CASE XXVI.—*Mastoid Abscess. Mastoid and Tympanum laid open. Cure.*

*History.*—E. D., aged 4½ years, was admitted to the hospital on April 25th, 1893 (special department for measles), and went home on May 25th, with the left ear suppurating and painful. This discharge, which had commenced towards the eighth day of the disease, ceased spontaneously. About a week ago the swelling behind the ear commenced, and at present there is a

typical mastoid abscess, the skin over which is red and thinned. As to the family history, it is to be noted that the parents have lost one child of meningitis and another of bronchitis.

*Operation.*—On June 2nd the child was admitted into the hospital and the operation done immediately. Beneath the opened-up abscess the mastoid presented a small spontaneous perforation, which was enlarged by a sharp spoon. The granulations had separated and split up the external auditory meatus; and I scraped the mastoid cells, the canal of the antrum, and the tympanic cavity. Plugging with iodoform gauze through the wound and the meatus.

The further dressings were made as usual, without anything specially noteworthy, and the child left the hospital on August 7th completely cured.

*October 17th.*—It was brought back to me because, since last evening, there has been a slight discharge from the meatus. The mastoid cicatrix is in perfect condition. On examination with the speculum no trace of the membrana tympani is evident; one sees the promontory, from which there is a slight leaking.

The child has, since that time, been treated by instillations of carbolic glycerine.

*November 15th.*—The discharge from the ear having dried up, the child was brought back, because it suffered from bronchitis, for which it was readmitted to the hospital, which it left on December 4th.

At the present time (January 1894) it is convalescing at Laroche.

CASE XXVII.—*Mastoid Abscess, with Facial Paralysis. Mastoid and Tympanum laid open. Cure.*

F. V., 2½ years old, was brought to the hospital on September 26th, 1893.

*History.*—Father unknown, mother healthy. The child has not had any of the eruptive fevers. Three weeks ago he had the thrush, with quinsy and fever. For a long time he had suffered from impetigo of the scalp. Twelve days ago the ear began to discharge, and eight days ago the mastoid region began to swell. The facial paralysis which the child shows has existed for three weeks, and followed convulsions which lasted three days.

*September 27th, 1893. Operation.*—Abscess opened; the bone above the mastoid was bare to the extent of a two-shilling piece. There is a simple channel into the bone, from which escapes a small drop of pus, behind and above the meatus. The very capacious cavity of the antrum and the tympanum laid open and curetted. After curetting the tympanum, removal of the ossicles, which appeared healthy. Many granulations in the tympanic cavity. Suture of the superior half of the wound and of the meatus. Plugging with iodoform gauze.

*Bacteriological Examination by Dr. Halipré.*—Pure streptococcus.

Rapid cure, with the usual dressings.

The child has not returned to the hospital since the end of November.

On February 6th, 1894, it was examined. There is a considerable amount of discharge from the ear which is not being attended to. Behind the ear,

cicatrisation complete. The hearing appears somewhat lessened; yet the mother had not noticed having had to speak more loudly to the child.

What has just been said indicates that, contrary to Politzer, we advise always opening the antrum and exploring the aditus. Politzer<sup>1</sup> thinks that the suppurating cavities in mastoiditis hardly ever communicate with the antrum, and that there is never any need to try and establish such communication, whereby the disinfected cavity would be again infected by the pus which has come from the tympanum. The doctrine we are trying to establish is altogether opposed to the latter view. That sometimes we do not find the antrum narrowed and obliterated we admit; but it is necessary to search, so as to verify its condition.

II. *Acute Mastoiditis complicating a Chronic Otitis Media.*—When in the course of a chronic suppuration of the tympanic cavity there supervenes an acute mastoiditis, with or without abscess round about the mastoid, the indications for treatment do not depend solely upon the condition of the mastoid lesions, but also upon those of the tympanum.

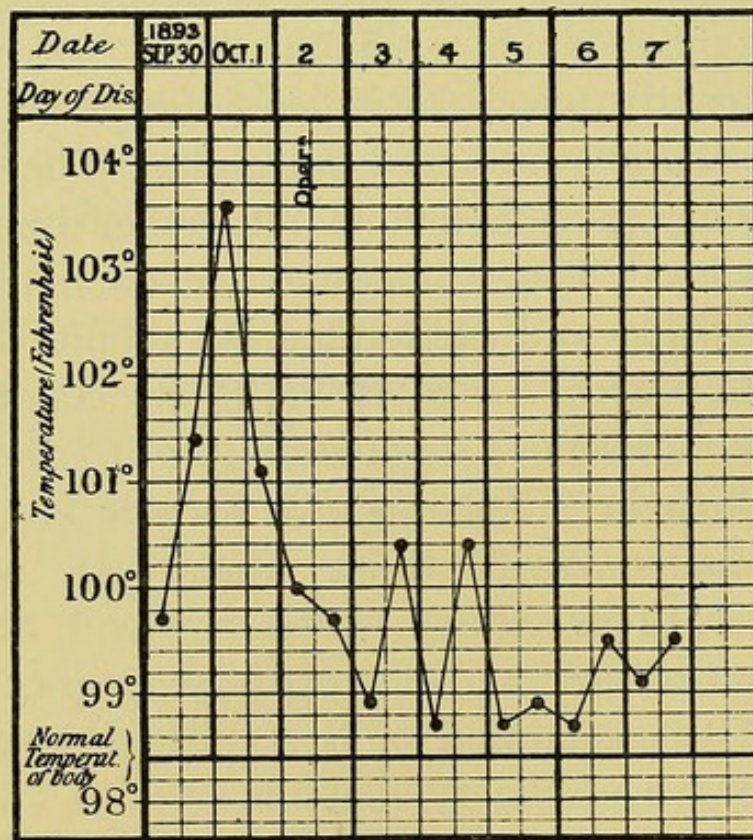
As regards the mastoid abscess, considered by itself the rule to be observed is very simple; it is identical with that we have just indicated for attacks of acute mastoiditis, and it consists in the free opening and drainage of the external abscess and of the mastoid cells. This operation may be as urgent as in a case of acute otitis, even when there is no external abscess; and thus it was that we operated in the following case:—

<sup>1</sup> *Loc. cit.*, p. 330.

CASE XXVIII.—*Old Otorrhœa, with Acute Mastoiditis, without external abscess. The Mastoid and Tympanum laid open. Cure.*

M. G. ; aged 14½ years ; admitted to the hospital on September 17th, 1893.

The *family history* of this child was fairly good. Father and mother healthy ; one brother, fourteen years



CASE XXVIII.

of age, had an affection of the chest ; one brother, four years of age, had, at the same time as his sister, a discharge from the ear, which was quite cured by treatment with iodoform powder. She herself had scarlet fever in June 1893, but her ear discharged before, as the result of a fall on the head (?). At any rate the right ear had discharged for three and

a half months, and the left for one and a half months, when scarlet fever ensued, after which the otorrhœa became more abundant at the same time that the pains increased. This exacerbation of the symptoms continuing, the child was admitted to the hospital.

*On admission*, suppuration of the attic of both sides, with polypi on the left.

In spite of the removal of a polypus of the left, and curetting the tympanic cavity, the mastoid became acutely inflamed, the fever rising, on October 1st, to  $103.6^{\circ}$  Fahr. At the same time, the tenderness on pressure upon the mastoid became intense, without œdema or redness. Headache, general condition serious; and on October 2nd, owing to the urgency of the case, an operation of emergency was done, the mastoid and tympanum being laid open. Caries of the ossicles.

This treatment resulted in an immediate lowering of the fever, and caused the pains to cease.

The dressings were made as usual.

The wound behind the ear had cicatrised up by the end of December, and the discharge from the left ear ceased under the influence of dressings with carbolic glycerine at the end of January; but there persisted some otorrhœa from the right. On the right side Dr. Boulay noticed that there was a polypus and a narrowing of the meatus, due, perhaps, to an exostosis of the inferior wall.

*February 10th*, 1894.—Removal of the polypus.

*February 17th*.—Cauterisation of the granulations with nitrate of silver.

*February 28th*.—On the left side the cure has



remained perfect for a month, without fistula or otorrhœa, the child not having any dressing. Hearing very deficient on both sides, as before the operation.

In February 1895 the result still remained good. The child has been operated on for the right side (see Case LXI.).

After having opened the mastoid, we should act in the depths of the wound according to the conditions observed *en route*, removing, by the curette, all friable and carious portions of the mastoid; and thus one will sometimes be led to lay bare, to a variable extent, either the sinus, or the dura mater, or the two. More often, also, one may observe, in following up more and more closely the granulations and the pus, that it is necessary to destroy the canal of the antrum and enter the tympanic cavity. But if in many of these cases we cannot decide accurately, before resorting to the knife, how far it would be necessary to push the operation, it would not be good surgery to say that this is the ideal way of procedure. Our ideal is to establish, after a complete diagnosis, a well-defined plan of operation; and it is for this reason that it is indispensable to have made, in advance, a methodical examination of the tympanum.

In the preceding pages, when speaking of the acute suppurations, we have, to put it briefly, considered the tympanum as almost negligible. As regards the chronic otorrhœas, it is not always so.

Doubtless our way of looking at these things will not change when it is a question of a chronic inflammation limited to the mucous lining; but it ought to

be modified altogether when, beneath the mucous membrane, the ossicles or the walls of the tympanum are inflamed, affected with osteitis and caries. The diagnosis, it is true, is not always easy to establish between these varieties of chronic and suppurative otitis media—*i.e.*, according as they arise in the mucous lining or in the bony wall. We possess, however, some data which it is important to notice.

When there exist these bony affections—of the walls of the tympanum, as well as of the ossicles—they are often situated above; and these latter alone interest us, caries of the handle of the malleus, and of the long process of the incus, not giving rise to attacks of mastoiditis: (1) affections of the ossicles, at the level of the handle of the malleus, and especially at that of the body of the incus, as if there were a kind of suppurative arthritis of the articulation situated between these two bones; (2) affections of the tympanum, at the level of the walls of the cupola, called “the lodgment” of the ossicles, or attic, and principally upon the external wall of this cupola, or attic (*pars ossea* of the external surface of Walb, “wall of the lodgment” of Gellé).

By what, then, can we recognise a suppuration coming from the attic or crossing it? There is a point in diagnosis that we shall merely touch upon, in such a way as to indicate only what is necessary for making our subject<sup>1</sup> clear.

A first variety is that where the perforation by which

<sup>1</sup> For further details as to suppurations of the attic see E. Weismann, “Traitement des suppurations de l’attique,” *These de Paris*, 1892-1893, No. 204.

the pus escapes from the tympanic cavity into the meatus is situated in the membrane of Shrapnell,<sup>1</sup> sometimes even above, in the wall of the attic, as has been very well demonstrated by S. Duplay. One can, then, be certain that the suppuration comes from the attic. But it is not always so, and many suppurations of the attic discharge by a common perforation of the tympanic cavity. To establish the diagnosis, it is necessary, after having freed the meatus, the membrane, and the tympanum from the products (thick pus, polypi) which may obstruct them, completely to stop the flow of pus with very dry mops of cotton-wool, and observe whether the pus, which soon appears again, whilst still looking at it through the speculum, comes from above, descending, drop by drop, over the internal wall of the tympanic cavity.

If the pus undoubtedly comes from the attic, and if at the same time there is mastoiditis, we can be almost certain that we shall have to follow up the perforation in the bone as far as the tympanum without there being any need to commit oneself in advance to the more complicated explorations. However, it will always be good to find out, by examining with a bent probe, if a bare bony spot is not to be met with in the attic—a manœuvre which, it is true, often requires much delicacy, and, on the other hand, is often unsuccessful, even when the bone itself is diseased: if positive information is proof indisputable, a negative fact goes for nothing.

We confine ourselves, for the present, to this brief

<sup>1</sup> See R. Raoult, "Des perforations de la membrane de Shrapnell," *Th. de doct.*, No. 166: Paris, 1892-1893.

summary of the indications for operation: in fact, whilst considering mastoid fistulæ, we shall have an opportunity of entering into the developments which to a great extent are applicable to the mastoid abscesses of chronic inflammations of the middle ear. These views will be found completed in the chapter which we shall devote to the latent mastoid lesions, which often complicate chronic attacks of otorrhœa, especially by affections of the attic.

#### § 5. TREATMENT OF THE ACUTE FORMS OF MASTOIDITIS.

I. *Non-Operative Treatment.*—We have said that it may be considered that the propagation to the air-cells of the mastoid process, of inflammation primarily seated in the middle ear was almost the rule in acute otitis media. Mastoiditis is, then, somehow, the constant companion of otitis media. There may come a moment when this companion gains upon the otitis, develops on its own account, presents a special train of symptoms, and occasions the complications which are peculiar to it.

This consideration compels us, in every case of acute otitis, to watch with care the spread of the inflammation: we shall, so to speak, have to be lying in wait for the mastoiditis; we shall have, as a constant source of occupation, to prevent it; and when it has been produced to a slight extent, we shall endeavour to have at hand simple means for the purpose of checking it. With a view to this, we shall take care that the pus escapes easily through the meatus to the exterior. If the perforation of the membrane is too small or badly

placed, it must be enlarged: if need be, a large one must be made in an inclined part of the membrane.

The air-douche, frequently repeated, several times in the day—catheterism, if the air-douche is insufficient—will aid the evacuation of the pus. We must insist upon the air-douche administered in accordance with the rules—with the bag, according to Politzer's method. Its efficacy is superior to that of irrigating the tympanum through the Eustachian tube: air, in fact, enters much more readily than water into all the interstices of the tympanic cavity, and through the *aditus ad antrum*, which we know is situated on the posterior wall of the tympanum, exactly in a line with the orifice of the Eustachian tube (anterior surface); it penetrates as far as the antrum and the neighbouring cells, from which it expels the fluid (pus). The water will penetrate less easily, not into the tympanum, but into the antrum; will swell up the mucous membrane, and this swelling will still more block the narrow channel of the aditus. Therefore, the liquid will scarcely pass the canal of the antrum, although Politzer attributes to the irrigation good results, "though in the majority of the cases there does not exist any communication between the abscess of the mastoid and the antrum." We think that even if the passage were passed, the liquid would not have sufficient force to thoroughly irrigate the air-cells; whilst it is undeniable that, after the air-douche, the cells empty themselves by the temporarily dilated canal.

When already the phenomena are more marked on the part of the mastoid,—spontaneous pains and tenderness on pressure, redness and swelling of

the skin, and a slight degree of periostitis,—we may, by the air-douche, arrest the progress of the complication. To this we may add with success the application of ice-bags to the mastoid region, or refrigeration by Leiter's tube. The pain may be relieved by the application of leeches to the tip of the mastoid. Horteloup's leech has given good results. We must beware of vesicatories, the therapeutic value of which is doubtful, and which have the serious inconvenience of infecting the field of operation, should further measures be judged necessary. The same may be said of the actual cautery.<sup>1</sup>

Be it well understood that we are not to lose sight, all this time, of the condition of the membrana tympani, that the perforation is to be maintained gaping, and that if some granulation bulges through the orifice, it is to be removed by *serre-nœud* or *curette*.

In spite of everything, mastoiditis may develop, and an abscess beneath the periosteum form, which is indicated externally by a more circumscribed swelling, and œdema, and, in the interior of the meatus, by the same phenomenon which is expressed by the "dip" of the postero-superior wall of the meatus.

When things have gone so far, we rarely see an improvement in the symptoms by the simple methods of treatment we have mentioned; we must then be prepared to open up the mastoid.

II. *Laying open the Mastoid*.—We have already expressed our opinion of Wilde's incision: it will be almost always useless, and very often dangerous,

<sup>1</sup> Advised by Lacoarret, *Ann. de la policl. de Bordeaux*, 1889, p. 6; also by Ménière, *Gas. des hôp.*, February 28th, 1889, p. 228.

since it gives a false security to the patient and the doctor. Those who admit, as we do, that cases of phlegmonous periostitis are rare which are not the expression of a bony inflammation, will do wisely,—the soft parts having been cut through, and also the periosteum,—to search the external surface of the mastoid for a diseased spot; and, if it is not found, to perforate according to the rules, being certain, then, that in the air-cells will be found the cause of the symptoms. The progress of surgery, moreover, enables us to do this operation without the patient running any risks, and to-day it has become a regular practice in otology. But it has not always been so; and it may be stated that few operations have been, on the one hand, more enthusiastically lauded, and, on the other, more vehemently denounced.

The first idea of opening the mastoid by means of an operation is due to the anatomist Jean Riolan (1649), who proposed it with the view of improving the hearing in a case of obstruction of the Eustachian tube. The first to practise it for mastoiditis was Jean Louis Petit.

At the same time as Petit, Morand trephined successfully in a case of caries of the mastoid. He also opened a subdural abscess. Jasser, a Prussian military surgeon, successfully practised it several times at this same period, not only to drain cases of suppuration, but also to improve the hearing. The communications of Jasser gave rise, from this point of view, to the most fallacious hopes. The operation was considered as the radical cure for deafness, and it was done almost everywhere. But several cases of death

were published, and the otologists (Itaro, Bonnafond, Wilde) participating in an unfortunate reaction, condemned it in every case. However, Toynbee, who otherwise never practised it, maintained that it was indicated in cases of retention of pus.

At the end of 1860, Forget (of Strasbourg) and von Trœltzsch again drew attention to it; and, with some hesitation, several scattered cases were reported. But it is, above all, to Schwartz (of Halle) that the laying open of the mastoid process owes the place it occupies in otology; and it is to be remarked that all the modified operations, and the majority of those tentative measures which have resulted in making us better acquainted with and more adept in the practice of this operation, are due to the pupils of this great master (Eyssel, Kisselbach, Kretschmann, Stacke).

In France, until the last few years, this question was hardly studied. Scarcely any advantage had been taken of the work done in Germany by Schwartz and his pupils, by Hartmann (Berlin), by Zuckerkandl, Bezold, and Politzer, when, in 1888, this subject was again taken in hand by S. Duplay,<sup>1</sup> who, in a remarkable critical review, made known to us the anatomical and surgical data upon which we ought henceforth to base our operations. More recently, we must specially refer to an interesting article in which Dr. Ricard<sup>2</sup> has insisted upon the anatomy of the region, and is in favour, from the point of view of operative measures, of the methods of Hartmann and Politzer, which, it

<sup>1</sup> S. Duplay, *Arch. gén. de méd.*, May and June 1888, pp. 586, 719.

<sup>2</sup> A. Ricard, "De l'apophyse mastoïde et de sa trepanation," *Gaz. des hôp.*, 1889, No. 25, p. 205.



is true, are not the best in our opinion, as we are about to say.

Schwartz has published, on several occasions, the results of his statistics; and in his "Treatise on the Diseases of the Ear" we find a remarkable study of the question now before us. His method, except for some modifications in detail, is that which we employ. It is, therefore, with his account that we shall conclude this review of operative measures—though it should be first, in order of time—after having criticised the other proposed procedures.

We see from the anatomy of the mastoid that three organs are readily wounded if we do not operate with care and dexterity: the lateral sinus, situated behind; the dura mater and the brain, situated above the roof of the antrum; the facial nerve, situated below and in front.

We mention here these organs, whose precise situation it will be more useful to specify when we indicate our method of procedure, because the fear of wounding the sinus has already, for a long time, induced von Trœltzsch to propose opening the antrum through the meatus. With this idea we may compare that of Karl Wolff, who recommended removing, with a chisel, layer by layer, the posterior wall of the meatus, after having cut through the concha and the cutaneous meatus,<sup>1</sup> as if we wished to enlarge it behind the bony meatus. It does not seem to us that this method is

<sup>1</sup> For the special discussion of this point see Hessler, "Can opening the mastoid process through the meatus be regarded as having the same value as the other methods?"—*Cong. Intern. de Berlin* 1890, vol. iv., 11th section, p. 35: Berlin, 1891.

to be recommended; and we quite understand that Kisselbach, after having had bad results from it, thenceforth favoured the method of Schwartze.<sup>1</sup>

First of all, opening the antrum through the meatus alone is not always free from risks. Allowing that it is at some distance from the lateral sinus and the middle cerebral fossa, yet it comes near the facial and the external semicircular canal, which may easily be injured. But now, comparing injury of the facial nerve with that of the sinus, we may almost say that the first is, if not the gravest, at least the most annoying. In fact, when an antiseptic surgeon, possessed of a cool head, opens the sinus, the operation is rarely rendered more serious; the patient practically never succumbs if the wound is well plugged, and the real inconvenience of this surgical complication is that one is compelled to interrupt the operation and postpone completing it for some days or weeks later. On the other hand, when once the facial nerve has been cut, the subject is deformed to the end of his days. We do not wish to push this conclusion to a paradox, but we do think that it is not wise to expose the facial nerve to the risk of its being cut, in order the more surely to avoid perforating the sinus.

This is not all: the opening through the meatus is

<sup>1</sup> Upon the relative harmlessness of opening the lateral sinus, cf. von Baracz, *Wien. med. Woch.*, 1887, p. 1260. Seven cases followed by recovery, although in that of Guye the air had entered. There were, however, some cases of death; for example, one mentioned by Ricard in his article. Quite recently G. Chincini (*Arch. ital. d'otol.*, 1895, t. iii., p. 55) has published four cases followed by recovery (three operated on by E. de Rossi, one by Ferreri). But the frequency of this complication astonishes us.

not made at the most dependent part; it approaches the antrum at its middle, since we know that this cavity commences superiorly at 2 or 3 mm. above the superior wall of the meatus, at the level of the articulation of the incus and head of the malleus, and ends in the large air-cells at the tip of the mastoid. But now the opening cannot be prolonged downwards, because of the facial nerve, which is lodged in the same wall of the meatus, at the inferior portion of the posterior surface of the latter. Also, the evacuation of the pus from the cell at the tip of the mastoid will be made with difficulty, and, on the other hand, to apply the dressings will not be easy as they have to penetrate into the suppurating cavity through a narrow orifice, deeply situated, where the eye and the probe have access with such difficulty.

What we have said as to opening through the meatus we repeat, or almost so, in the case of the method of Küster.<sup>1</sup> After having laid open the antrum, this surgeon removed the posterior wall of the meatus. We do not think that this ought to be generalised for cases of acute otitis, but the operation of Küster is the complement of opening up the mastoid in chronic cases, with or without fistula, where affections of the tympanum require, as we have said when considering the indications for treatment, a direct and special procedure.

Therefore we are in favour of opening through a spot behind the ear, which alone enables us to operate with precisely marked points, and ensures free drainage.

<sup>1</sup> Küster, *Deut. med. Woch.*, 1889, p. 254. Discussion at the *Soc. de méd. int. de Berlin*; completely reviewed by Jacobson, *Arch. f. Ohr.*, 1889, vol. xxviii., p. 288.

But it still remains for us to choose between several methods. Before deciding this choice, we must recapitulate the anatomy of the region, for it is upon this that it depends.

The three rocks we have to avoid are, we have already said, the lateral sinus, the dura mater, and the facial nerve; and we might add to them a fourth, the external semicircular canal,<sup>1</sup> which otherwise only becomes of interest when the operation is prolonged into the tympanum. Let us state these relations precisely.

The works of anatomists, whose names we have already several times mentioned, have shown that—to recapitulate briefly the general topography—the groove of the lateral sinus<sup>2</sup> is hollowed out of the internal surface of the posterior half of the mastoid. To be more precise, we will say that as a general rule there is no danger in opening the sinus if we keep from 15 to 18 mm. behind the meatus. But this relationship is not absolutely fixed. In two per cent., according to Hartmann, the sinus is much further forward; so much so, says Ricard, “that laying open the mastoid will almost certainly reach it.” In a single specimen where the mastoid was thin and sclerosed, as Hartmann says, Ricard observed this arrangement, but there were still 12 mm. between the posterior wall of the meatus and the groove of the sinus. According to Hessler, this dangerous proximity of the meatus and sinus is at the same time both greater and more frequent, since in his own practice

<sup>1</sup> See Plate I.

<sup>2</sup> See Plate I. Fig 2, and Plate IV.

he had seen four cases where the sinus was situated in front of the mastoid antrum.<sup>1</sup>

Nevertheless, we must reply to this objection that, if it is freely opened, with the use of accurate landmarks, the cavity of the antrum will always be separated from the sinus by this interval. The danger becomes real when the mastoid air-cells are not found, especially when we are led into the depths.

The thickness existing between the external surface of the mastoid and the sinus is, in fact, very variable. Superiorly, especially, it is thin, not exceeding 3 or 4 mm. (Ricard); whilst below, bearing in mind the considerable obliquity of the sinus, it possesses a thickness of 2 or 3 cm. Whence the formula, correctly expressed by Ricard—"The posterior half of the mastoid process is dangerous on account of its proximity to the lateral sinus, but the danger diminishes proportionally as one keeps clear of the base, so as to get nearer the apex of the mastoid."

This relationship is not the only one of interest to us: we have further to consider the brain, the facial nerve, and the transverse semicircular canal.

There is no risk of opening the cranial cavity if we remain below the horizontal line which passes through the supra-meatal spine. This line, in fact, which marks the junction between the squamous and mastoid portions of the temporal, is almost always below, rarely at the level of, and almost never above, the floor of the cranial cavity.

<sup>1</sup> Hessler, Four cases of caries of the middle ear, with the sinus placed in front of the mastoid antrum, *Arch f. Ohr.*, 1887-8, t. xxvi., fasc. 3 and 4, p. 169.

As for the facial nerve and the semicircular canal, they have been the object of a special work by Noltenius,<sup>1</sup> who has examined, from this point of view, twenty-two normal petrous bones, from Hartmann's collection—prepared by horizontal sections. The average distances are :

(1) Between the supra-meatal spine and the facial nerve canal 15½ mm. (minimum 11).

(2) Between the spine and the semicircular canal, 16½ mm. (minimum 13).

(3) Between the starting-point for opening the mastoid and the facial nerve canal, 22 mm. (minimum 18).

(4) Between the starting-point for opening the mastoid and the semicircular canal, 22 mm. (minimum 17).

Finally, we should remember that the facial nerve canal is included in the inferior half of the posterior wall of the meatus, which region must be taken care of. Hence it follows, summing up all these facts, that there is, at 4 or 5 mm. behind the superior half of the posterior border of the external auditory orifice, an area of about 1 cm. square in the adult, through which we may penetrate with practically no danger. Moreover (and here we are at variance with the ideas of Politzer), we consider that we must always proceed directly to the antrum, which is the only constant air-cell; the others are often wanting in children and in sclerosed mastoids. This being so, we can choose between the different procedures which have been proposed.

In France, until the last few years, the classical operations were those of Délaissement and Poincot.

<sup>1</sup> Noltenius, *Cong. d'otologie de Berlin*, April 22nd, 1889.

Poinsot<sup>1</sup> recommends opening up at the base and laying bare the mastoid by an incision parallel to the concha of the ear, and at a distance from the latter of 10 to 15 mm. That is to say, that he works exactly at the level of the region, which is dangerous, owing to the sinus.

On the contrary, Délaissement,<sup>2</sup> haunted by the fear of the sinus, and desirous, moreover, to drain at the lower level, recommends opening up at the apex of the mastoid. This loses sight of the fact that the air-cells of the apex do not always exist, especially as in young children (in whom mastoid abscess is frequent) they never exist.<sup>3</sup>

So that we unhesitatingly conclude, in agreement with Schwartz and Hartmann, in Germany, and Professor Duplay and Ricard, in France, that the region for surgical interference in the mastoid is the anterior half of the base of the mastoid, and, we add, at 4 to 5 mm. behind the meatus, in order to certainly avoid entering at a deep level into the meatus, which we know is oblique above and behind. But how is the bone to be attacked? Three instruments have been proposed: the gimlet, the trephine, and the chisel. As to the trephine, it need be no further discussed, because it is a blind instrument; and we would willingly

<sup>1</sup> Poinsot, Art. "*Mastoïde*" in the *Nouv. dict. de méd. chir. prat.*, 1875, t. xxi.

<sup>2</sup> Délaissement, "De la trépanation de l'apophyse mastoïde," *Th. de Paris*, 1868, No. 141.

<sup>3</sup> Cavaroz, *Thèse de doct.*, Lyon, 1893, sér. 1, No. 791, maintained, by means of Polisson's observations, that in certain conditions one must avoid scraping out the apex. We do not believe such practice will be beneficial.

say as little about the gimlet, if some modern writers had not considered it necessary to invent some new models.

We only mention the discussion which took place between Schwartze and A. H. Buck, to prove that the gimlet according to one, and the chisel according to the other, predisposes to erysipelas<sup>1</sup>: with what we know to-day (and even when Buck wrote) upon the etiology of erysipelas, discussion is idle. But what is certain is, that the gimlet is an instrument altogether too narrow and blind: it makes an insufficient perforation, and readily pierces the sinus; if the deep layers are found to be softer than one expected them to be, it slips through into the deeper structures. Too extensive loss of substance of the superficial layers of bone, and hence delayed healing, a more depressed cicatrix, a larger incision of the soft parts, are the many and unjustifiable reproaches Buck makes against the gouge. Let us pass by gimlets and the drills recently proposed,<sup>2</sup> and say that almost all surgeons—following Schwartze in this—have given in their adhesion to the use of the chisel and the gouge worked by the small leaden mallet.

The chisel and gouge may be the ordinary ones, about a centimetre wide (about  $\frac{2}{5}$  in.). But in order to dig into a bone, in which an error of 1 or 2 mm. may be followed by grave operative complications,

<sup>1</sup> A. H. Buck, "On some points in the operative technique in perforating the mastoid process," American Society of Otology, July 20th, 1886: *Transactions*, etc., New Bedford, t. iii., p. 623.

<sup>2</sup> Laurent, Third Congress of Belgian Otologists, 1892: *La Clinique*, Brussels, t. vi., p. 391.

<sup>3</sup> See Plate V.



we recommend rather the use of instruments with narrow blades, 4 to 5 mm. wide, if one is operating on a child, and well sharpened—for a clean cut is the best; and, further, one is better able to control the slipping of the instrument.

But would not an unwary blow of the mallet quickly send the chisel into the sinus? In dread of this, certain writers recommend shaving, so to speak, the mastoid, chip by chip, with the chisel held parallel to the bony surface. Hartmann recommends this, Ricard agrees with him, and Politzer<sup>1</sup> insists upon it. But in the case of an operator who knows the anatomy of this region, who knows how to be guided by the bony landmarks, this fear appears to us to be chimerical. All that we can say is, that out of a hundred and forty-three operations we have never opened the sinus. We therefore entirely agree with the advice of Professor S. Duplay, who recommends that the instrument should be directed “parallel with the posterior wall of the meatus.”

The *description of the method of operating*, derived directly from that of Schwartze, by which, in our own practice, we open the mastoid antrum, allows us once more to pass in review the principal facts which we have just considered so fully.

First, we shall give the typical method suited to the case where there is *no abscess behind the ear*, where, from the operative point of view, the superficial layer of bone met with ought to be everywhere healthy.

1. *Incision of the soft parts.*—The area of operation being shaved to a sufficient extent, and disinfected in

<sup>1</sup> *Loc. cit.*, p. 329.

the usual way, an incision is made in the furrow behind the ear, at 1 or 2 mm. behind the latter. This starts from the apex of the mastoid, and is directed from below upwards to the level of the temporal line—a bony crest, situated a little above the superior border of the external orifice of the meatus, in a line continuous with the posterior root of the zygoma. This line is always easily felt in man ; it corresponds to the junction of the mastoid and squamous portions of the temporal bone. Deeply, in the thickness of the bone, it is generally placed below the middle cerebral fossa, sometimes actually at the level of this middle cerebral fossa, and very rarely above it. It will serve, therefore, to limit, superiorly, the field of operation.

The incision should include the soft parts and the periosteum. From its upper end proceeds another incision directed behind, perpendicularly to the first, and about 2 cm. (about  $\frac{3}{4}$  in.) long. These two incisions between them map out an angular flap, which is raised by the periosteal elevator and stripped from the bone, from above downwards, and from before backwards, so as to lay bare the whole surface of the mastoid process and the posterior border of the bony meatus. The bleeding is, as a rule, inconsiderable, because in this procedure no important vessels are cut. The flow of blood proceeding from the small veins or arteries will stop spontaneously, since the periosteum has been very carefully detached from the subjacent bone ; forci-pressure forceps are now applied, which, kept on under aseptic compresses, will help, moreover, to hold down automatically the pinna and the flap.

In Schwartz's operation there is only one incision, which is made *entirely over the mastoid*, 1 cm. (about  $\frac{2}{5}$  in.) posterior to the furrow behind the ear and parallel with this furrow. In this case the periosteum is separated up about the two lips of the wound. We think that the scar is less concealed by the auricle, ultimately, and, above all, that one cannot, by a single incision, lay bare the important part of the mastoid to a sufficiently great extent. In fact, hæmorrhage being checked and the triangular flap raised, the mastoid is uncovered in its entire extent—above, as far as the temporal line; below, as far as the apex; in front, to the posterior border of the external auditory orifice; behind, to the very commencement of the mastoid process.<sup>1</sup>

2. *Bony Landmarks*.—We make for the landmarks so as to open up the mastoid, unless well-marked disease of the bone invites, so to speak, perforation at that spot.

<sup>1</sup> Since these pages were written (February 1894), we have somewhat modified our views on this subject. Certainly to enable one to get a clear view, the angular flap we described is particularly favourable, and beginners will find it useful to employ it; but having acquired much experience in mastoid operations, there is enough light with a single longitudinal incision which goes the whole length of the furrow behind the ear. In this way the scar of the transverse branch of the angular incision—always somewhat visible—is avoided. We prefer this incision to that of Schwartz, because it leads directly to the meatus, which it is imperative to see, so that it may serve as a landmark, because, after separating up the upper lip with an elevator, it allows one to reach the whole of the antrum with equal facility, and because, finally, the scar concealed in the furrow behind the ear is quite invisible—unless searched for by drawing forward the auricle. We lay stress on this last point, for now and then the operation of laying open the mastoid has been discredited, as leaving an unsightly scar. Such criticism is devoid of all foundation.

We remember that the antrum is situated towards the postero-superior angle of the meatus, a little behind a slight bony eminence situated upon the same border of the meatus, which is called the supra-meatal spine. Hence we ought to open behind the meatus and at the level of the spine. These two landmarks are admirably well seen if the mastoid has been carefully laid bare by the periosteal elevator. Now is the time for the operation. After this stripping up of the periosteum, a hollow probe is inserted into the membranous meatus; then, on the border of the bony meatus, one seeks for the spine with the finger nail.

*The superior limit of action* is marked by the temporal line; *the anterior limit* by the border of the meatus, from which one must keep at least half a centimetre distant on the surface, because the meatus is directed posteriorly, and one does not fail to get into the deeper structures if this distance is not preserved.

*The inferior limit of action* is not of great importance, since we know that in many cases the air-cells extend almost to the apex of the mastoid; and in the cases where the mastoid is eburnated, where the system of air-cells is reduced to the antrum, it would be mere labour lost to go too low.

*The posterior limit* it is very important to know precisely, because in the deeper regions, at the postero-superior portion of the mastoid process, is found an important structure, limiting the antrum above and behind, wound of which must be avoided—namely, the lateral sinus. Opening this large vessel, if it is not followed by grave symptoms, has always the

disadvantage of being a troublesome complication of the operation, and gives rise to a hæmorrhage which often is sufficient to prevent completion of the operation.

Unfortunately, the situation of the sinus is eminently variable: sometimes it is situated upon the superior confines of the antrum, and is separated from it by the thick, compact substance; sometimes it is very near this air-cell, and descends very low towards the apex of the mastoid.<sup>1</sup>

The anatomists (Schwartz, Zuckerkandl, Ricard) have shown that one runs the least danger by limiting posteriorly the field of operation to a little less than  $1\frac{1}{2}$  cm. (about  $\frac{1}{2}$  in.) behind the meatus.

3. *Opening the Antrum.*—The opening should be made within the limits of this quadrilateral space, which gives the greatest chance of finding the mastoid antrum. First, the 5-millimetre chisel is applied behind the superior half of the posterior border of the meatus, exactly parallel with the meatus, and it is driven in, by some short, sharp blows of the mallet, 2 or 3 mm., keeping it firmly in the left hand, so as to accurately limit its penetration. We continue through the upper cut, quite horizontally, to the level of the supra-meatal spine. The third cut will be inferior, situated 1 cm. below the preceding in the adult, 5 mm. in the child, and also exactly parallel with it (the second), and perpendicular to the first. After which we have to

<sup>1</sup> In a series of memoirs, Kœrner has studied the variations of these relations according to whether the skull is dolicho- or brachycephalic. There are no data of practical importance at present. Cf. Schuelzke, *Arch. f. Ohr.*, 1889-90, t. xxix., p. 201 and 1890, t. xxx., p. 137 also A. Randall, "Preliminary notes on craniometric studies in relation to aural anatomy," *Trans. of the American Otol. Soc.*, 1892.

remove the little square of superficial bone by dividing the posterior border, which is the dangerous one. To reach it, one slightly inclines the blade towards the meatus, so as to cut a slight bevel, but without realising that parallelism to the surface of the mastoid which Hartmann, Politzer, and Ricard desire.

When the small square which we have marked out has been removed, at what depth shall we find the mastoid antrum, and, if it is not found, to what depth can we penetrate without danger? Sometimes the superficial bony layer is so thin that, at the first blow of the chisel, one breaks it as if it were an eggshell; sometimes, on the contrary, it is a centimetre or even more in thickness.

In sclerosis of the mastoid, where the bone is almost entirely eburnated, the antrum is reduced to its minimum, and is not found in the zone which we have indicated, but a little higher up. In the adult, one may, according to Schwartze, extend these explorations in the depths to  $2\frac{1}{2}$  cm. In the child, one imagines it would not be the same; also, in it, when the system of air-cells of the apex is poorly developed, the mastoid antrum, properly so called, is easy to find.

In the case of sclerosis we may go above the superior limit, and look for the "aditus ad antrum," which will be found, in default of the antrum, very little below the linea temporalis. When, beneath the superficial layer of bone, we do not immediately meet with the antrum or the air-cells, but rather friable red tissue, the best thing to do, we think, is to scrape it out, bit by bit, with a special sharp spoon, narrow and solidly-made, deep and very sharp. Thus there is no delay

in entering into the cavity sought ; and if one works chiefly above and in front, inclining towards the postero-superior wall of the meatus and the assumed position of the aditus, the sinus will not be opened into. Otherwise, if one proceeds slowly and with care, all that one risks is laying bare to a variable extent the external surface of the sinus or of the dura mater, which we have done several times, without inconvenience of any kind, in the acute or chronic case where the corresponding bony wall was softened by osteitis.

Such is the typical method of operating, which is suitable when there is no abscess behind the ear and no bare bony point.

*When there is an abscess* it must first be opened by the typical incision behind the ear ; then, with the finger nail and probe, the bare bone must be sought for ; and this done, after having carefully taken the landmarks for this point in its relation to the meatus (this is important, for often after scraping the bone one can scarcely see any difference), the periosteum is stripped off with the elevator exactly as in the preceding case ; and, *whatever the diseased condition directly noticed on the external surface of the mastoid, we should always aim at doing the typical operation.*

The affected bony point is often recognisable by its blackish colour, depressibility, friability, and the drop of pus which is seen to escape ; it is then of prime importance to determine exactly, by its relations with the supra-meatal spine and the posterior border of the meatus, if it is placed at the seat of election for opening the mastoid. This is the rule, for instance, in a young child, where, situated behind and *above* the

meatus, it corresponds almost directly with the antrum. Then we may enter the mastoid with the sharp spoon, cautiously, and scrape out the bone, always keeping the edge directed in front and above. But if the bare spot, or even the spontaneous perforation, is situated in a doubtful place, especially if very much posterior, we must open up at the seat of election, without taking it into account, and inclining from the antrum towards it, once the antrum is opened.

The mastoid cavity being opened, pus, fleshy granulations, and sequestra are found. These sequestra, sometimes lamelliform, sometimes cubical and of large size, are more frequent in the <sup>young</sup> child than in the adult. Their separation is favoured in children by the squamo-mastoid suture. They are most often formed by sloughy walls of the air-cells.

The pus, granulations, and sequestra are removed by the sharp spoon, used very carefully, since one knows it is directed towards the sinus, the brain, and the facial nerve, the position of which one ought constantly to bear in mind. Often in front of the cavity there will remain some lamellæ of the superficial bony wall, which must be removed by the gouge,<sup>1</sup> after having introduced beneath them a bent protector to avoid any slips.

It is very important to thoroughly open up all the air-cells of this diseased mastoid, not to leave any infected bony cavity over which the skin could cicatrise up, when the symptoms would continue as if nothing had been done. This complete scraping out of the air-cells at the tip of the mastoid, after opening the antrum, is as a rule very easy to do in the acute

<sup>1</sup> See Plate V. Fig 3.



cases, where the mastoid is rarely ever sclerosed. It is so sometimes, however; and one of us found himself confronted with this difficulty. In a woman suffering from mastoiditis after *la grippe*, with an abscess behind the ear, he opened the antrum, and after scraping it, found himself confronted with a cavity having tough resisting walls everywhere; the aditus, when explored, appeared healthy; and towards the tip, the probe did not discover any narrow channels in which it was entangled. Contrary to our custom, he contented himself, therefore, with laying open the antrum; and, three months later, he had to open the air-cells at the tip, which he found full of pus, without abscess of the soft parts superficial to the bone.

CASE XXIX.—*Acute Mastoid abscess, with painful mastication. Spontaneous opening up of the Antrum. Secondary abscess of the air-cells at the tip of the Mastoid.*

*History.*—R. R., 47 years of age, was in England during November 1893. It was a stormy day when she embarked at Calais, and she caught cold. She was confined to her bed for twelve days with influenza. About the fourth day (November 26th), coryza, with headache; next day the coryza disappeared, but the patient suffered from pain in the ear. Since then the pains in the ear have not ceased, but there has never been otorrhœa.

From December 7th patient treated by catheterism and inflation with Politzer's bag, at the same time that carbolic glycerine was dropped into the ear.

*December 27th.*—The patient complains of more

severe pains, which have rapidly become intense ; she did not sleep in the night, and this morning there is a swelling behind the ear. Mastication is difficult, and the patient has pain in opening the mouth. There is no torticollis. The sterno-mastoid muscle is free. Slight fever ( $100\cdot4^{\circ}$  to  $101\cdot3^{\circ}$  Fahr.).

*January 6th.*—Application of “morphine stupes” behind the ear.

*January 8th.*—The patient brought to Dr. Broca by Dr. Lereboullet. There is a fluctuating abscess behind the upper half of the pinna of the ear. The furrow is obliterated ; there is redness and great tenderness on pressure.

*January 9th.*—Fluctuation in a semicircular area above and behind the meatus. Incision. Spontaneous perforation just behind the meatus, encroaching upon the wall of the meatus, but not entering into the tympanum ; cavity, size of haricot bean. Around about, the bone is eburnated, and the probe does not discover any narrow track leading to the tip of the mastoid. Drain ; suture ; iodoform gauze dressing.

*January 16th.*—Not a drop of pus—only some “plastic lymph.” Removal of stitches and drain.

*January 23rd.*—Doing well ; pain constant, but slight.

*January 30th.*—A small fistula remains, and there is fluctuation at the site of the old abscess ; at the same time, there is a painful œdema of the posterior parts. All the sutures are untied by means of a probe, and a large quantity of pus escapes. Plugging of the meatus and the abscess cavity.

*February 3rd.*—The abscess cavity is everywhere lined with granulations.

*February 6th.*—The patient complains of pains in the inferior parieto-occipital region, where there is some œdema. These pains radiate as far as the frontal region. Mastication is still painful.

*February 25th.*—Superficial cavity, everywhere vascularised, in very good condition ; no purulent discharge from the meatus.

*March 3rd.*—The wound is cicatrised, but the region is œdematous and painful—so that on March 11th the tip of the mastoid was laid open. Escape of a considerable quantity of pus, contained in a huge cavity with friable walls.

The cure, by plugging with iodoform gauze, was only obtained by July 31st. This good result was maintained when seen in September.

*Bacteriological Examination.*—Streptococcus.

The cavity having been thus thoroughly disinfected, if the condition of the aditus were ascertained, it would almost always be found intact in cases of acute otitis. The operation once finished, the incision can be sutured and drained ; but although when the suture succeeds several days are thus gained, it is more prudent, we consider, to plug the cavity with iodoform or salicylic gauze.<sup>1</sup> A fold of this is then introduced into the meatus. Wool and bandage as usual. We are not accustomed to irrigate the wound after the operation, nor at the subsequent dressings.

The first dressing remains *in situ* for eight days—if there is neither fever nor soaking through of discharge,

<sup>1</sup> Secondary suturing might be attempted, perhaps, as Gruber recommends, *Int. klin. Rundschau*, 1891, pp. 1217, 1261.

which is the rule. At the end of this time it is changed, and the stitches and drain are removed. If it has been plugged, this is repeated every three or four days. This dressing ought to be done with the greatest care, in such a way that the wound is filled up regularly from the depths to the surface: if the superficial structures are allowed to unite too soon, there persists beneath them a suppurating cavity in the bone, and it will speedily give rise to a fistula. At the end of four to six weeks, as a rule, the wound is filled up.

3. *Laying open the Tympanic Cavity.*—When it is desired to open at the same time both mastoid and tympanum, the operative procedure is as follows<sup>1</sup>:—

The cutaneous incision includes the whole length of the furrow behind the ear, from the tip of the mastoid to the superior insertion of the auricle, inclining itself, consequently, in front to its upper extremity, towards the temporal fossa.

The periosteum being thoroughly divided, it is stripped up with the periosteal elevator all along the posterior lip, over the whole extent of the mastoid; then, with a thin and narrow elevator, the meatus is separated from its bony attachments, over the whole extent of the posterior and superior walls, and in the posterior portion of the inferior wall. The meatus thus stripped off is cut transversely, and as deeply as possible. Through this cleft, the skin of the anterior and inferior portion of the meatus is seen; this area of skin is cut to the bone, and, with the elevator, all this antero-

<sup>1</sup> Cf. Zaufal, "Zur Geschichte und Technik der operativen Freilegung der Mittelohrräume," *Arch. f. Ohrenh.*, 1894, t., xxxvii., fasc. 1 and 2, p. 33.

inferior portion is detached from the bony meatus, proceeding from the deeper structures to the surface. The cutaneous meatus is in this way completely detached. Auricle and meatus are then carried completely forward and kept there by a blunt hook, and there, beneath our eyes, is the external orifice of the meatus, stripped of its soft parts, as in the skeleton. At this stage, having the parts fully exposed to the light, we can operate with assurance. At the bottom of the bony meatus is seen the tympanic membrane, or cavity of the tympanum, if the former has disappeared.

At this period of the operation the blood flowing towards the sloping portion fills the meatus. It is checked by stuffing into this cavity strips of gauze, dry and aseptic, so that it is tightly plugged for some minutes, after which, the soft parts being turned back, one operates almost bloodlessly.

When we have thus the bone quite bare, the antrum is opened at the seat of election, as has been said in the preceding paragraph.

The antrum being opened, we look in its anterior and superior angle for the orifice of the aditus; and the probe, or rather the Stacke's protector (see Plate V., Fig. 3), introduced through this orifice, enters the tympanic cavity. This probe is then separated from the exterior by a variable thickness of bony substance, which constitutes the external wall of the canal of the antrum: it is this external part which one must remove in order to make a free communication between the cavity, which has just been scraped out, with the tympanic cavity, and so transform the tunnel of the aditus into a trench.

For this purpose, taking as one's guide the direction of the probe or protector, which remains in place in the aditus during the whole of this time of the operation, one hollows out, from without in, a trench, which, so to speak, goes and meets that of the probe. The superior limit ought scarcely to cross the temporal line. The inferior limit should not go lower than the point of junction between the lower and upper halves of the external auditory meatus, this last limit being necessary for the protection of the facial nerve, which, curving for the last time between the fenestra ovalis and the external semicircular canal, descends in the inferior half of the wall of the auditory meatus so as to reach the stylomastoid foramen.

The trench being extended towards the protector until this is freed, it is made to issue between the superior and inferior flaps; and in the depths, at the place it occupies, an eminence is seen—the external semicircular canal, which the probe protected during the opening up of the trench. The tympanum and antrum form from this time two cavities united by the aditus, like the two spheres of a dumbbell joined by the transverse branch.

The tympanic cavity is cleaned out with the special long curette, the remains of the ossicles are removed, every corner of this irregular surface is curetted, the angles of the trench are smoothed away, the cavities of the mastoid air-cells are made to communicate one with another, and the operation on the bone is complete.

Throughout the whole of the operation arrest of hæmorrhage is secured—so that one can always see

clearly when working—by mopping up the blood continually with sponges of dry and aseptic gauze, with which pressure is applied for some moments. Then turning back the soft parts, the cutaneous meatus is split in its entire length, as far as the membranous meatus, following its superior line, and we make use of it to cover in and skin over the largest portion possible of the bony cavity which has just been opened. For that purpose it is spread out, and each of its angles fixed by a point of suture to the corresponding portion of the posterior wound.<sup>1</sup> Plugging will ensure the exact apposition of the flaps.

This plugging is done with a strip of iodoform or salicylic gauze, which is introduced through the meatus by Lister's forceps, and which is brought back through the posterior wound so as to lead it as far as the tympanum. This strip is pushed in fairly tightly; then a second is introduced, less tightly, through the wound behind the ear, the two extremities of which have been sutured. The other portions of the dressing are as usual.

The dressing is renewed, unless otherwise indicated earlier, on the eighth day; then it is done every two or three days, always taking care to plug the tympanum through the meatus, so as to prevent the latter from shrinking up. Also, the fleshy granulations, often exuberant, are curetted or cauterised.

It must be understood that for the cure several

<sup>1</sup> A. af. Forselles (*Arch. f. Ohrenh.*, 1894, t. xxxvi., fasc. 3, p. 145) recommends introducing a flap cut at the expense of the external lip of the incision behind the ear. Kretschmann (*ibid.*, t. xxxvii., fasc. 1 and 2, p. 25) mentions another autoplasmic procedure, in which two flaps are taken from the skin behind the ear.

months will be required, during which repeated dressings will be necessary.

If the covering in with epidermis is of slow occurrence, it can be stimulated to activity by moist dressings, made by introducing a strip of cotton-wool soaked in 1 in 2000 sublimate solution.

When the suppuration has become almost nil, instillations of boric acid alcohol<sup>1</sup>\* are used.

Cure occurs either by skinning over of the tympanum and cicatrisation behind the ear, or by skinning over of the tympanum, aditus, and antrum, from which results a huge non-suppurating cavity which opens behind the ear (Cases VII., XXX., XXXI., L., LXII.).

We considered, at first, that the former method of cure was the more favourable: it is, in fact, the one which best respects external appearances. After the cure, the cicatrix is as little apparent as that of a simple opening of the mastoid; and in the case of some patients it is at most a slight depression that testifies to the depth to which the bone has been excavated. On the other hand, it is certain that one obtains thus complete successes, sometimes even with remarkable rapidity. But atresia of the meatus, in spite of every care with which the pluggings are done, is not always easy to avoid. Several times we thought patients were cured; but at the end of a variable time pains have recurred, and after having dilated up the meatus we

<sup>1</sup> E. Weismann. *Bull. et mem. de la soc. franc. d'otol.*, etc., p. 259 : Paris, 1894

\* [Boracic acid powder gr. xxx, sp. vin rect. ℥i, to be diluted with two or three times its volume of water when used, and, as soon as the patient can tolerate it, using it undiluted.—ED.]



have liberated some drops of pus. If the meatus is not plugged to the bottom, reaching into the tympanum, for months and months the cure will be hindered by the cicatricial contraction of the meatus.

So we have gradually determined to keep the orifice behind the ear more and more dilated by stretching the meatus divided posteriorly. We have, in fact, noticed in several of our old operation cases that this method of cicatrisation with a huge cavity behind the ear was never any inconvenience, as we shall mention in the following case, relating to a boy operated on more than two years ago. The hearing is abolished on the side operated upon; but this is not constant, and, moreover, we have not observed that it was, on the average, less altered in the cases where the wound behind the ear had levelled up.

*CASE XXX.—Mastoid Fistula. Mastoid and Tympanum, spontaneously perforated, laid open. Cure, with huge cavity left behind the ear.*

J. B.; 15 years old; admitted to the hospital on November 17th, 1892.

*History.*—The mother, whose general health was good, died in child-birth. The father, two brothers, and one sister, are quite healthy. Born at term. At the age of eighteen months, prolonged eye-troubles, during the continuance of which appeared a discharge from the ear, slight in quantity, but continuous: treated by internal tonics. At the age of twelve years the boy had scarlet fever: treated at another hospital. At fourteen years, typhoid fever, during convalescence from which, following a blow behind

the ear, a retro-auricular abscess appeared : treated by simple incision. Cure, with a slightly leaking fistula, and formation of successive small abscesses. Persistent otorrhœa.

*November 26th, 1892. Operation.*—After the incision behind the ear a large spontaneous perforation was reached, full of caseous pus, and leading into the tympanum; afterwards, careful curetting, during which no trace of ossicles was observed. Plugging with iodoform gauze.

The operation took an exceedingly simple course.

The boy was sent away, on February 9th, 1893, for breach of discipline, the local condition being very good. Since, he has been dressed regularly at the clinic of Dr. Lubet-Barbon.

The cavity has gradually, but steadily, skinned over; and in October I again saw the boy (cured, however, for a long time), having a cavity opening behind the ear by a large aperture, and showing, though skinned over and dry, a complete and typical perforation. I put in a plug of iodoform gauze, solely with the idea of closing this hole.

Seen again December 31st, 1893. The patient has in his cavity, which is still gaping and skinned over, a strip of iodoform gauze, which I put there three months ago, imbedded in a soft mass of cerumen. No traces of pus. Gauze dry and odourless. No hearing on this side.

The only objection is that this huge, gaping cavity behind the ear is almost always visible and very disfiguring. But this objection is not of importance, for

nothing is simpler than to freshen the edges of the orifice, free them with the periosteal elevator, and suture. This little operation, which can easily be done in a few minutes, with one or two centigrammes of hydrochlorate of cocaine, was undertaken most successfully by one of us in the following case:—

CASE XXXI.—*Mastoid Fistula. Mastoid and Tympanum laid open. Cure, with a huge cavity behind the ear, closed subsequently by a plastic operation.*

L. S., 18 years of age, was sent to the hospital by my colleague, Dr. Le Gendre.

*Family history* presents nothing of importance.

*History.*—At four years of age there was a fluctuating tumour posterior to the furrow behind the left auricle, which was incised, and a counter opening made; a drainage-tube was used. One of these openings closed, whilst the other persisted, giving rise to a discharge, slight in amount, but with no tendency to dry up. Otherwise there was no pain or any general symptoms. Ever since, there has been discharge, more or less continuous, both through the external auditory meatus and the fistula. Three years ago the deafness, which increased progressively, became absolute. As regards treatment, injections with infusion of walnut leaves have been used. No improvement appearing, in spite of treatments ordered successively by various specialists, the patient came for advice to the hospital.

*Present State.*—There is: (1) a fistula in the region altogether above the furrow behind the ear—the fistula just admitting the probe, which is pushed into the deep structures, and meets a rough and bare

piece of bone; (2) a cicatrix 2 cm. (about  $\frac{4}{5}$  in.) posterior to the furrow behind the ear; (3) abundant discharge from the ear; (4) polypi in the tympanic cavity.

*November 18th, 1893. Operation.*—Incision into the fold behind the ear. Above the mastoid was a cavity full of granulations, about a centimetre in diameter. After curetting this, the cutaneous meatus was detached; a thin bony lamella still separated it from this cavity. This wall was removed by a chisel and hammer, after first introducing the protector into the tympanum. Tympanic cavity scraped. It contained abundant granulations, in the midst of which were found the remains of the incus and the handle of the malleus, adherent to the remaining portion of membrana tympani. Beneath the cavity in the mastoid the mastoid cells containing granulations were reached; with the gouge the bony parts which covered them in were removed, and the cutaneous portion of the meatus split as far as the concha. Plugging with iodoform gauze, especially through the meatus.

*November 20th.*—Dressed. Left facial paralysis noticed. From this date the patient has been dressed very regularly twice a week. The meatus, split as far as the concha, has remained gaping widely, and the orifice behind the ear equally so. It has also been very easy to plug right down to the bottom, and suppuration has always been very slight.

Towards the end of January the covering in with skin commenced to spread remarkably over the fleshy granulations which lined the cavity in the bone. By this time the facial paralysis was improved, the cheek

was less flaccid, and the left half of the lip was more movable; the left eyelids did not close.

*February 6th, 1894.*—The skinning over of the cavity has made great progress; the suppuration is almost nil. The dressing will only be done every eight days.

*March 6th.*—The skinning over is completed, and the cavity is only treated with daily instillations of boracic alcohol.

After having watched the patient, and noticed for several weeks that the cicatrization remained sound, on May 19th, 1894, after subcutaneous injection of a centigramme of hydrochlorate of cocaine, I freshened, in circular fashion, the lips of the orifice behind the ear, and freed the posterior half of the circumference, stripping it off by a periosteal elevator from the bone to which it adhered; that being done, I sutured the two lips of the wound behind the auricle in a vertical line. On the eighth day the stitches were removed: primary union. Since this time the patient has often been seen, and the result remains good. The only apparent trace of the operation is a linear cicatrix, white, movable, and completely concealed in the furrow behind the ear. The facial paralysis persists, but is much diminished. The lids close well, and the deviation of the mouth is no longer appreciable when the patient speaks (January 1895).

## CHAPTER II.

### *MASTOID FISTULÆ.*

WHEN a mastoid abscess has been left to itself, or, what is almost the same thing, when it has been treated by the simple incision—the so-called Wilde's incision—as a rule a fistula remains. This rule is not without its exceptions, it is true; and, when the subjacent bone has undergone a sufficiently large spontaneous perforation, cure may occur at the end of a variable period by the unaided efforts of nature.

But the writers who extol Wilde's incision are absolutely wrong when they declare—if they have not opened forms of suppurative inflammations (adenophlegmons) or abscesses of the lymphatic glands arising from furunculosis—that most often it leads to rapid cure. Whatever they say, fistula is frequent; and in proof of this, we only need mention our forty cases, amongst which there are several where the fistula was of long duration (see Case XXXI., above).

Without doubt some aurists, dreading operation, affirm that after the formation of fistulæ the danger is averted; and they repeatedly state to the parents that “this will disappear at its formation, or at puberty.”

It is certainly true, on the one hand, that mastoid abscesses are relatively of great frequency in early childhood; on the other hand, that persistent mastoid

fistulæ are rare in adults. But the real reason of this is, in our opinion, that the patients die before reaching puberty: that is, chronic suppuration of the ear, with bony disease of the tympanum and mastoid, with or without fistula, is a serious affection which directly endangers life through infection of the lateral sinus, meninges, or brain. It has been maintained that around the old focus of suppuration in the petrous there arises a hyperostosis (bony hypertrophy) protecting the intracranial structures. This is an absolute error. There certainly is a hyperostosis, but it leads to eburnation of the mastoid and thickening and narrowing of the meatus. In this way arises an obstruction to the flow of pus towards the exterior. But the spread towards the interior is only the more to be feared; and in a recent memoir, Lemcke,<sup>1</sup> of Rostock, has well demonstrated, in eight cases of his own, the dangers of these hyperostoses, and the tendency of the affections in like circumstances to spread towards the cranium, and this even without any manifestation on the part of the mastoid.

We shall confirm this view by saying that in cases where chronic mastoiditis was accompanied by vertigo, headache, nausea, and vomiting, there was, in our patients, an evident eburnation of the mastoid (Cases XXXV., XLIII., XLIV.).

So that, in our opinion, a mastoid fistula is a serious affection, which deserves to be studied with care and treated energetically.

<sup>1</sup> Lemcke, "Ueber Hyperostose des Felsenbeins bei chronischer Ohrenerkrankung und ihre Beziehung zur intracraniellen Erkrankungen otitischen Ursprungs," *Berl. klin. Woch.*, 1893, pp. 888, 925.

## § I. PHYSICAL SIGNS AND BONY LESIONS.

The almost constant situation of mastoid fistulæ is the region behind the ear—yet this is not absolutely constant; and fistulisation of the border air-cells into the meatus may be observed. We have already mentioned, in this connection, our Case X.; here is an instance which requires no further explanation from us (see also Case CXIX.).

CASE XXXII.—*Fistula of the border air-cells. Mastoid and Tympanum laid open. Cure.*

*History.*—T., a woman aged 26, complains of a discharge from the right ear, occurring repeatedly since twelve years of age. The present discharge reappeared in greater abundance about a month ago. The patient complains, moreover, of very severe pains in the ear, which prevent sleep. The discharge is fœtid.

*Present State.*—On inspection, a cicatrix is seen in the mastoid region, but the patient does not remember the time when this scar was formed. At the orifice of the meatus there is found a polypus of considerable size, which is bathed in pus. The polypus is removed by the serre-nœud. It does not appear to proceed from the tympanum, but from the wall of the meatus itself; in fact, the ear being cleansed, there is found, on the posterior wall of the meatus, granulations which appear to line an orifice. A probe introduced amidst these granulations results in the discovery of a rather deep track, directed almost perpendicularly to the direction of the meatus, from before back and from below up, and in such a way that a bent probe introduced so as



to follow this direction penetrates to a depth of 2 cm. At the bottom of this fistulous passage the bone is felt, and appears to be bare.

Behind the point where the granulations are situated the meatus is contracted: one cannot see whether or no the membrane exists, but by the air-douche one notices a whistling noise. The watch is heard at 5 cm. (about 2 in.).

*July 18th.*—Granulations of the posterior wall curetted.

*July 26th.*—The patient is very little relieved. She had pain all last night, and has a sensation of tension in the ear; she is pale, anæmic, and has lost her appetite. By means of a bent cannula introduced into the fistulous track the cavity to which this track led has been irrigated. This washing out brought back very foetid caseous pus. It was followed by an increase in the pain, and it was decided then to lay open the mastoid process.

*The operation* was done on August 1st. Incision behind the ear, which led down to the bone. It was hardly necessary to break up with the chisel a thin superficial layer which formed the shell of a huge cavity full of caseous pus, with large clots of blood, and lined with granulations. This cavity communicated, by the fistulous track already seen, with the lumen of the meatus, and was only separated from it by the soft parts. The posterior wall of the bony meatus having disappeared as far as the tympanum, this was made to communicate freely with the cavity by removing the internal wall of the aditus and the external wall of the attic. By a longitudinal incision of

the meatus we cut, at the expense of the latter, a strip which was sutured to the posterior lip of the incision behind the wound; and the meatus, the tympanum, and the cavity, hollowed out spontaneously in the mastoid, were plugged with iodoform gauze.

The dressing was renewed five days later. The sutures were removed. Through the orifice of the meatus there is easy access into a large cavity, which soon became filled up with fleshy granulations.

*September 15th.*—The fleshy granulations are proliferating, and skinning over is not occurring. To hasten this we applied two skin grafts, one of which took, and the other served as a point of departure for a central cicatrisation.

*October 15th.*—Skinning over is almost complete, except in one part of the *cul de sac* which corresponds to the tympanum, and in another corresponding to the tip of the mastoid.

The dressing with iodoform gauze renewed every eight days.

*December 1st.*—All the surface of the cavity is cicatrised, the skin appearing as an invagination at the level of the orifice of the meatus.

*October 1894.*—The result remains good.

*The fistula behind the ear*, which occupies a spot situated at a variable height above the mastoid, and at a variable distance from the meatus,<sup>1</sup> is generally an

<sup>1</sup> In Huntington Richards's case, remarkable, moreover, for the excessive temporising of the surgeon, the fistula was placed at 6 cm. (about  $2\frac{1}{2}$  in.) behind the meatus, in the occipital bone, *Med. Rec.*, N.Y., December 11th, 1886, vol. xxx., p. 654.

aperture of small dimensions. Generally, the situation is fairly high up, at the level of the antrum rather than of the air-cells, so that often the probe is directed downwards.

Exceptionally one sees a large ulceration, at the bottom of which appears, pale and necrosed, the entire mastoid, with the part of the squamous portion adjacent to its base (Case XLIX.). Almost always it is a narrow channel, often filled up with exuberant fleshy granulations, which bleed when examined with the probe; and the latter sometimes reaches simply bare bone, sometimes penetrates into a cavity, where it meets with one or several movable sequestra. The probe introduced through the meatus also strikes the bared bone posteriorly.

Through this fistula, as well as through the meatus, so often obstructed by fleshy granulations in the form of polypi, pus, more or less abundant and more or less foetid, escapes. The communication between the fistulous orifice and the tympanum is, in many of these cases, easy to demonstrate by means of an injection which is made to pass from the fistula into the meatus, or *vice versa*. Needless to say, this does not occur if at the bottom of the fistula the mastoid has spontaneously perforated, or if, as in our Case I., the track passes directly between the bony and the cartilaginous meatus, so as to reach the tympanum, where the ossicles are carious.

Another variety—very rare, since in our forty cases we have never met with it—is that in which a fistula situated at the base of the mastoid traverses the bone and passes directly beneath the dura mater. We shall

mention, as an example, a case of this kind published by Picqué.<sup>1</sup>

The bony lesions which we have mentioned up to now are eburnation of the mastoid and meatus, spontaneous perforations, and sequestra. We must pass these in review, and we shall commence with the spontaneous perforation.

*Spontaneous perforation* is not rare, since we have come across it in a score of cases. But usually the perforation is insufficient. Its seat of election is at that for the opening up of the mastoid; but often enough it is at a distance from this, and in particular frequently occurs more posteriorly, in the neighbourhood of the sinus. Its size is very variable; so for its depth. Sometimes the bone is destroyed—except for some carious and softened *débris*—as far as the tympanum, so that spontaneously the track extends to the tympanum; and in spite of this large deficiency in the bone, the cavity does not empty itself, nor get filled up, and the fistula persists (Cases XXX., XXXIII., for instance). On the other hand, frequently the fistula ends in the bone simply laid bare, or perforated by a hole which admits scarcely the extremity of the probe. Around this bared or perforated spot the bone shows a very varying consistence, according to the case. Sometimes, in fact, there is actual caries, more or less extensive, of the mastoid and postero-superior wall of the meatus, so that one has to scoop out the diseased bone with the curette in order to penetrate freely into

<sup>1</sup> Picqué, "Abscess sous dure-mérien, consécutif à une otite moyenne, trépanation, guérison," *Ann. des mal. de l'or. et du lar.*, 1890, t. xvi., p. 439.

the tympanum, and scrape it in turn. Of this variety we shall give as examples the following cases :—

CASE XXXIII.—*Mastoid Fistula. Spontaneous perforation of the Mastoid and of the Tympanum. Hollowing out. Cure.*

A. G., 25 months old, was brought to the hospital on July 25th, 1893.

*History.*—Her parents are healthy. She has a brother, ten months old, also healthy. No history of previous acute illness. She was operated on at the age of six weeks for a swelling behind the left ear, followed by otorrhœa six weeks later. Then she spent one year in the country, in fairly good health, except for the otorrhœa. But six months ago the swelling behind the ear reappeared, and this time burst ; since, it has remained fistulous.

*At present* the left ear is obstructed by a large polypus, and gives exit to an abundant and very fœtid purulent discharge. There is also a fistula behind the ear at the base of the mastoid. No facial paralysis.

*July 29th. Operation.*—After an incision behind the ear, and laying bare the bone, I found in the mastoid a cavity full of granulations, in the midst of which there were several sequestra, one of which was very large. The posterior wall of the bony meatus had disappeared, and there was a cavity formed spontaneously, which led to the tympanum. The tympanum was curetted. I did not find any traces of the ossicles there. Around this cavity the bone was hard ; no caries. Without suturing the incision, the wound and the meatus were plugged with strips of iodoform gauze.

There was nothing special in the treatment after the operation.

*October 14th.*—Cicatrization complete. Behind the ear exists a depressed scar, adherent to the bone. The otorrhœa is absolutely checked.

*December 27th.*—I operated on this child for a subacute suppurative adenitis occupying the left upper sterno-mastoid region. The inflamed gland was present at the time of my first operation, but it has only gone on to suppuration a few days ago. The condition of the ear continues to be perfectly satisfactory.

CASE XXXIV.—*Mastoid Fistula. Spontaneous perforation. Opening of the Tympanum. Cure.*

L. H. ; 8 years old.

*History.*—Discharge from the right ear for five or six years, and from the left ear for a little time. Two years ago, mastoid abscess of the right side, which burst spontaneously and terminated in a fistula.

*To-day* (March 29th, 1893) the ear discharges through the fistulous track and the meatus. The orifice of the fistulous channel is placed at the apex of the mastoid, and a probe can be pushed in there from below upward to a depth of nearly 3 cm. The edges of the fistula are granulating, and bleed readily. The pus which escapes therefrom is fœtid. As regards the meatus, a tumour is observed situated at the posterior part, and which appears to communicate with the mastoid abscess, for pressure upon the tumour increases the discharge. Posterior to the tumour inspissated and fœtid pus is found.

*The operation* was done at the clinic on May 4th,

1893. After removing the thin cortical layer remaining, a cavity the size of a walnut was reached, filled with soft caseous material, which it sufficed to evacuate with the curette. The posterior wall of the bony meatus has completely disappeared, and the tumour perceived in the meatus is due to the abscess cavity excavated at the expense of the mastoid. A free communication was made between the tympanum and the mastoid cavity by destroying the external wall of the attic and of the aditus. There was nothing special in the rest of the operation.

The temperature for the first seven days oscillated about  $98.6^{\circ}$  Fahr. On the seventh day the dressing, which had a slightly fœtid odour, was removed.

The dressings were removed every four or five days, the plugging being done especially through the meatus. The skinning over of this large cavity proceeded slowly; fleshy granulations started, and were cauterised or removed by curette. But at the end of four months the posterior wound was closed; the ear no longer discharged; the external orifice of the meatus afforded access to a huge skinned-over cavity.

*August 1894.*—The result is maintained.

Sometimes, on the contrary, this sclerosing, eburnating osteitis, to which we have already alluded, exists. It is in such cases that the mastoid presents a thick and hard superficial bony layer, which encloses rudimentary air-cells—sometimes even none, and the antrum only remaining. In such cases, if the affection appears at an early age, the mastoid undergoes an arrest of development, so that it appears small, atrophied, receding upon the squamous and upon the

meatus (Case I.). Finally, it is in such cases that between the different air-cells the partitions may become completed, thus isolating a cavity which no longer communicates with the antrum; and in a case of this kind one of us had to do, as two separate operations upon the same patient, Stacke's operation and opening up of the mastoid (Case XXXV.).

CASE XXXV.—*Chronic Middle Ear Disease, with eburnation of the Mastoid. Mastoid Abscess independent of the Aditus. Stacke's Operation. Mastoid laid open.*

*History.*—N., 16 years old, was sent to us on November 30th, 1893, for a discharge from the left ear since four years of age. This discharge has never ceased. At different times, after violent pains, there have occurred attacks of inflammation ending in supuration of the mastoid, bursting externally and healing spontaneously at the end of some weeks. In fact, one sees over the left mastoid a cicatrix which is the result of these complications.

The patient came to-day because these pains had returned, accompanied by attacks of giddiness and vomiting. She had neither fever nor rigor. In the meatus was noticed foetid pus; and a special feature was the characteristic narrowing of the meatus, situated almost at the junction of the internal with the two external thirds. The central orifice scarcely permitted the introduction of the probe. Examination showed that we had to do with a membranous diaphragm produced at the expense of the soft parts, and not to a periostitis of the meatus.

We decided to do Stacke's operation, and observed



that the aditus ad antrum conducted to a rather deep *cul de sac* with eburnated walls. We returned to the part of the mastoid where the cicatrix had been found, and removed the superficial layer of bone to within half a centimetre of the tip of the mastoid, at the point where, ordinarily, the large cells are found. This opening up led us into a bony cavity with eburnated walls, not communicating either with the antrum or any other cell, and full of caseous *débris*. It appeared as if this cavity had been separated from the system of mastoid cells, had inflamed, burst, and recovered spontaneously. We curetted it, removing the eburnated wall which separated it from the meatus, from the aditus ad antrum, and from the tympanum, above and below. There was nothing special as regards the rest of the operation. The pains and vertigo ceased.

*February* 1895.—The patient has still a slightly suppurating cavity opening behind the auricle.

Finally, *sequestra* are frequent. They are met with either in the form of a sort of bony dust, mixed with granulations which fill the air-cells, the aditus, and the tympanum, or in the form of one or several irregularly cubical masses. They are situated in a cavity more or less huge, which occupies the whole of the mastoid, the canal of the antrum, and the tympanum; and this cavity, after their removal, presents walls either soft or hard, according to the case. Sometimes the lateral sinus and the dura mater are found laid bare over an area more or less extensive.

In the case of a child on whom we operated twice, and who finally died of meningitis, there were, each

time, very large sequestra; and finally, the petrous being almost entirely destroyed, there remained an enormous cavity, reaching as far as the wall of the pharynx (Case XXXVI.).

CASE XXXVI.—*Mastoid Fistula, with sequestra. Two successive operations. Death from Meningitis.*

A. N., 3 years old, was admitted to the hospital on October 30th, 1892.

*Present State.*—There is an extremely abundant and fœtid discharge from the right ear, a fistula behind the ear which discharged pus, and complete facial paralysis.

*November 5th. Operation.*—Incision behind the ear. A huge cavity was reached which contained a large sequestrum.

After this operation the local condition improved at first, then the suppuration returned as fœtid and abundant as in the past. Apyrexia.

*March 10th, 1893.—Further operation.* An enormous cavity reached containing numerous sequestra, the bony walls of which were everywhere friable; so that after curetting, the whole of the petrous disappeared, and the cavity was limited above by the dura mater, internally by the pharynx.

Following upon this operation, the child had slight fever, yet not rising above 100° Fahr., and it succumbed on March 28th, 1893.

*At the autopsy,* suppurative basal meningitis. Some tubercles in the meninges. No visceral or glandular tuberculosis.

Such are the bony affections against which we have

to contend. These briefly stated anatomico-pathological facts were indispensable, to enable us to discuss the indications for treatment. In this short review we have outlined the signs which result altogether from the observations by the eye and exploring the bone with the probe.

Among the functional symptoms we shall point out the relative frequency of facial paralysis. This symptom is associated frequently (Cases XXXVIII., XXXIX.), but not always (Case XXXVII.), with the existence of sequestra. It is produced either because necrosis attacks the part of the bone which contains the canal of the facial or because the nerve is simply compressed by the granulations and inflammatory products. In the first case the paralysis is incurable (Case XXXIX.), in the second it is curable (Cases XXXVII., XXXVIII.).

CASE XXXVII.—*Chronic Otitis Media, with Mastoid Abscess and Facial Paralysis. Mastoid and Tympanum laid open. Cure.*

E. le C. ; 9 years of age ; admitted to the hospital January 20th, 1893.

*History.*—Her father, after typhoid fever, became deaf in the left ear. Four brothers and sisters died of diphtheria. Had diphtheria when aged three and a half years. Since two years of age the left ear has become the seat of a slight discharge, which has persisted without any cessation or augmentation. The child has never had any other complaint. On January 3rd, 1893, on waking, the mother noticed the whole of the left half of her face swollen, and at the same time an enlargement

behind the left ear, the size of a small walnut. For fifteen days, in accordance with the doctor's advice, the mother treated it with poultices and injections into the ear, which led to an abundant discharge, without the swelling becoming smaller; otherwise, the child slept and ate well.

*January 20th, 1893.*—The child was brought to the hospital, and was immediately admitted. Abscess behind the left ear; polypus of the tympanum; facial paralysis.

*January 21st. Operation.*—Abscess behind the ear incised, and under it was found a spontaneous perforation of the mastoid. Antrum and tympanum curetted.

The child left the hospital January 29th; then returned for dressing twice a week. Cure was obtained by June 6th.

The child was seen again January 23rd, 1894. Since the month of June it has been well, but a slight amount of discharge from the ear persists. Instillations of carbolic glycerine.

The hearing is very imperfect on the left side, without being quite completely abolished; the facial paralysis has gone.

CASE XXXVIII.—*Chronic Mastoiditis, with Facial Paralysis. Mastoid and Tympanum laid open. Cure.*

*History.*—M. M., 15½ years old, came to the clinique April 22nd, 1893, for a very long standing and intermittent discharge from the right ear. The latter has discharged since she was eighteen months old. At this period, in the course of an acute otitis, an abscess was

formed behind the ear, which opened spontaneously, and was followed by a fistula. This finally dried up, and at its site a depressed cicatrix is seen. Since then the ear has not ceased to discharge intermittently; the pus which escapes is more or less abundant, but always foetid. Fifteen days ago the patient experienced violent pains in the same ear, and five days afterwards facial paralysis of this side supervened.

*At present* there are no longer spontaneous pains and no swelling; the ear suppurates, and the facial paralysis, although very marked, is still beginning to diminish. After irrigation, a polypus was seen filling the whole of the meatus; this was removed with a serre-nœud. This removal permitted washing out of the tympanum, whence issued a large quantity of caseous and foetid pus. Other polypi, smaller, and appearing to come from the upper part of the tympanum, were seen. This facial paralysis supervened suddenly, in the course of an old otitis media, in an ear filled with fleshy granulations, having presented formerly mastoid complications, and, going on improving, although very slightly, from the day of its production, made one think of compression of the facial nerve, either by a sequestrum or by some other cause. We decided to open up the mastoid process, and this was done on April 29th.

*Operation.*—The stripping up of the periosteum was accomplished with difficulty, especially at the level of a bony depression situated just below the linea temporalis. At the bottom of this depression, by means of a probe, was found a narrow channel through the bone, leading into the antrum. Antrum opened at this level, and

a spacious cavity was reached, full of caseous pus and granulations, containing a small sequestrum in the upper part. This having been scraped, the tympanum was opened into in the ordinary way. Remainder of operation as usual.

During the days following the operation the patient did not complain of any pain. The temperature oscillated about  $98.6^{\circ}$  Fahr.

*May 4th.*—First dressing. No pus in the dressing. The latter is done only through the meatus. Facial paralysis notably diminished.

*May 8th.*—The wound is in good condition ; slightly fœtid discharge upon the dressing. The patient left the hospital, and is to come for dressing regularly twice a week.

The very spacious cavity, every part of which can be inspected through the meatus, is frequently covered up by fleshy granulations, which are cauterised with silver nitrate. Little by little, however, it gradually cicatrised, and by December 1893 the patient had recovered completely from the facial paralysis. There is no fistula behind the ear, and the latter does not discharge. The meatus, cavity of the antrum, and the tympanum, form one cicatrised diverticulum.

*February 1895.*—The patient is very well.

CASE XXXIX.—*Mastoid Fistula, with sequestrum and Facial Paralysis. Mastoid and Tympanum laid open. Cure.*

E. R., 8 years of age, was admitted to the hospital March 17th, 1893.

*History.*—The mother died from small-pox eight days

after a confinement ; her general health was good. The father is very healthy, as also two sisters. There are two half-brothers of the father, one aged three years, the other aged eight months ; both healthy. Born at term. No diseases. At about the age of five years, without apparent cause, there commenced a fairly abundant discharge from the ear. Treatment, by injections of carbolic acid water, with no result. Towards the month of December 1892 there formed behind the ear a small, red, painful tumour the size of a hazel-nut. This abscess speedily burst, and remained fistulous. Since, as facial paralysis appeared, the child was brought to the medical consultation, where she was admitted. The following day Dr. Sevestre, discovering that the child had a fistula behind the ear, sent her on to the surgical department.

*March 25th, 1893. Operation.*—Extraction of a sequestrum from the petrous. Tympanum opened up. Plugged with iodoform gauze.

Further dressings as usual.

The cavity slowly filled up, and the child was sent away cured to Berck-sur-Mer, September 15th, 1893.

*February 1st, 1894.*—The child is at present at Berck-sur-Mer. According to information from the father, who has been to see her there, a month ago she no longer had any otorrhœa, and the mastoid cicatrix remained firm. General condition excellent. The facial paralysis persists.

*CASE XL.—Mastoid Fistula, with Facial Paralysis. Mastoid and Tympanum laid open Result doubtful.*

A. A., aged  $3\frac{1}{2}$  years, was admitted to the hospital July 28th, 1893.

*History.*—This child, whose family history is good, has always been well till recently. Four months ago he had at the same time measles and scarlet fever, with a relapse at the end of a month. Two months ago he began to complain of pains in the head and in the ears. There was no discharge. Soon afterwards arose on the two sides, but especially on the right, a swelling behind the ear; that on the left quickly disappeared, but on the right it formed an abscess, which was twice opened. This incision seemed to be in good condition, when, three days ago, the parents noticed that the child's face was drawn to the right, and that the general condition became rather poor.

*On admission* there was found, besides a right facial paralysis, a fistula behind the ear of the same side. The meatus was obstructed at the bottom by fleshy granulations.

During the three days which preceded the operation the temperature oscillated between  $98.6^{\circ}$  and  $100.4^{\circ}$  Fahr.

*August 3rd. Operation.*—The usual incision. The mastoid presented above the meatus a track lined with granulations, into which the curette was introduced. Below this passage all the air-cells contained granulations. The shell of bone which surrounded them was removed upon the protector (Plate V., Fig. 3) by means of a gouge and mallet. After curetting the air-cells, the canal of the antrum appeared very large and full of granulations. This being so, the tympanum was opened by the usual method. In the middle of the granulations which the curette removed from the tympanic cavity the carious incus was found. The malleus was not seen.



After the operation there was no reaction. The dressings were made as usual every three or four days.

*August 17th.*—The child left the clinique to go to Nièvre. There was a granulating cavity, which looked healthy.

We shall further mention the attacks of vertigo already noticed in our Case XXXV. With these we shall compare the following, which enters into series with certain cases of "meningitis," of which we shall speak in a moment.

CASE XLI.—*Attacks of Vertigo caused by an abscess of the Antrum. Opened up. Cure.*

*History.*—C., aged 34 years, male, on May 2nd, 1894, after a warm bath, experienced a sensation of fulness in the right ear, as if some water remained there, and slight pains, which increased during the following days. On May 6th the membrana tympani ruptured, the ear discharged abundantly, and there was great relief. The discharge continued to be free, without giving rise to any inconvenience; but at the commencement of June he had slight attacks of giddiness, and came to see us. He informed us that, having formerly been extremely healthy, in 1888 he had a bad attack of bronchitis, since which he has never ceased to have a cough, and has it very severely every winter. Auscultation negative. The family history presents nothing special. The discharge is very abundant, and comes through a large perforation in the antero-inferior

segment of the membrane. No fever; no pain in the mastoid.

The attacks of vertigo increasing, in spite of the usual treatment, and the patient not being able any longer to stand upright, we decided to operate on July 21st, 1894.

*Operation.*—Incision. Antrum laid open. Mastoid eburnated. The antrum, very deeply placed, was found full of pus. The cavity was curetted and made to extend to the tip of the mastoid, but none of the other air-cells were found. Plugged with iodoform gauze.

Cure resulted in three weeks, without elevation of temperature.

*December 1894.*—This result is maintained.

## § 2. INDICATIONS FOR TREATMENT AND OPERATIVE TECHNIQUE.

The two questions which present themselves are the following :—

1. When should one do anything? and when is operation contra-indicated?—that is to say, what are the clinical indications?

2. How should one operate?—that is to say, what are the anatomical indications which it is convenient to include under operative technique—for in most cases we must modify, in accordance with the actual conditions found, the typical plan of operation proposed beforehand?

1. *Clinical Indications.*—From what we have said at the commencement of this chapter, our opinion clearly follows without there being any need to insist upon it further. We recommend operation as soon as possible,

without trusting to nature, whose weak-willed trustees are too often insufficient to prevent fatal complications. Moreover, we are even accustomed to complete the operation, since we were consulted by a patient who recently had been treated by Wilde's incision.

When there is a fistula, we have no longer to do, as in cases of acute mastoiditis, with an operation of emergency or almost so. Except, however, when there exist intracranial complications more or less clearly diagnosed, the operation ought then to be done without any delay, if it is a question of a cerebral abscess or a phlebitis of the sinus. We believe, also, that one ought to treat the fistula when meningitis is suspected. Without doubt, for acute suppurative meningitis, we can do nothing; and if we wish to operate merely so as to preserve the statistics as free as possible from fatal results, we should avoid touching these patients.

But such ought not to be our aim; and as the operation is, at most, ineffectual, and is limited to preventing the patient succumbing to an otherwise fatal meningitis, we think that it ought to be attempted: in the first place because, as regards confirmed meningitis, there exist, with or without mastoid fistula, instances analogous to our Cases II. and XLII., where the symptoms—where indications of meningitis (to be unbiassed as to their exact nature)—have yielded with a marvellous rapidity, or at the end of some days, to disinfection of the middle ear and its annexes; in the second place because our diagnosis is not always quite certain between meningitis, thrombosis of the sinus, and cerebral abscess.

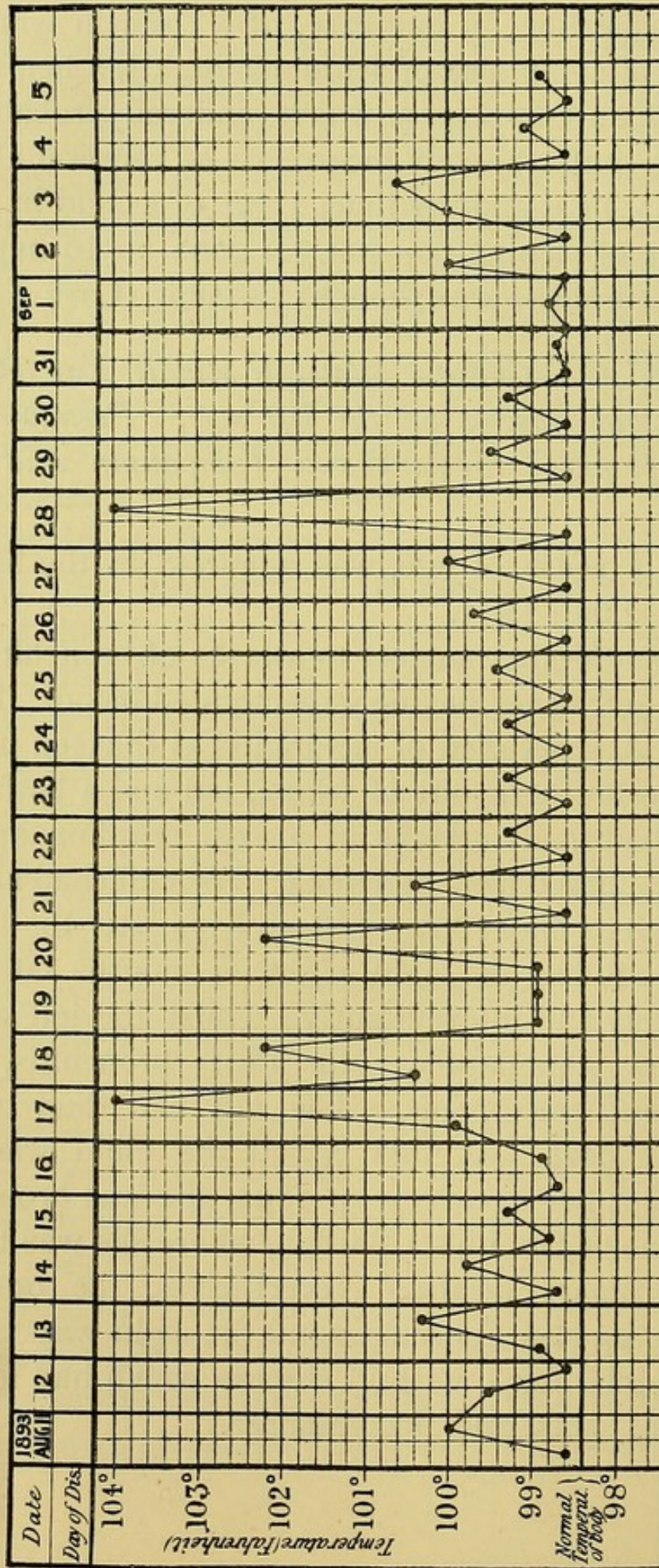
This was why one of us operated twice in some cases of this kind, with no illusive hopes as to the probable result.

It was a question, in one case, of a child in whom, in the midst of symptoms of acute meningitis, a hemiplegic attack suddenly appeared, which rendered probable the diagnosis—unfortunately incorrect—of cerebral abscess (Case XLV.); at another time, a case of a child in whom the chance of meningitis—not yet gone on to suppuration, and curable—was thought possible (Case XLVI.).

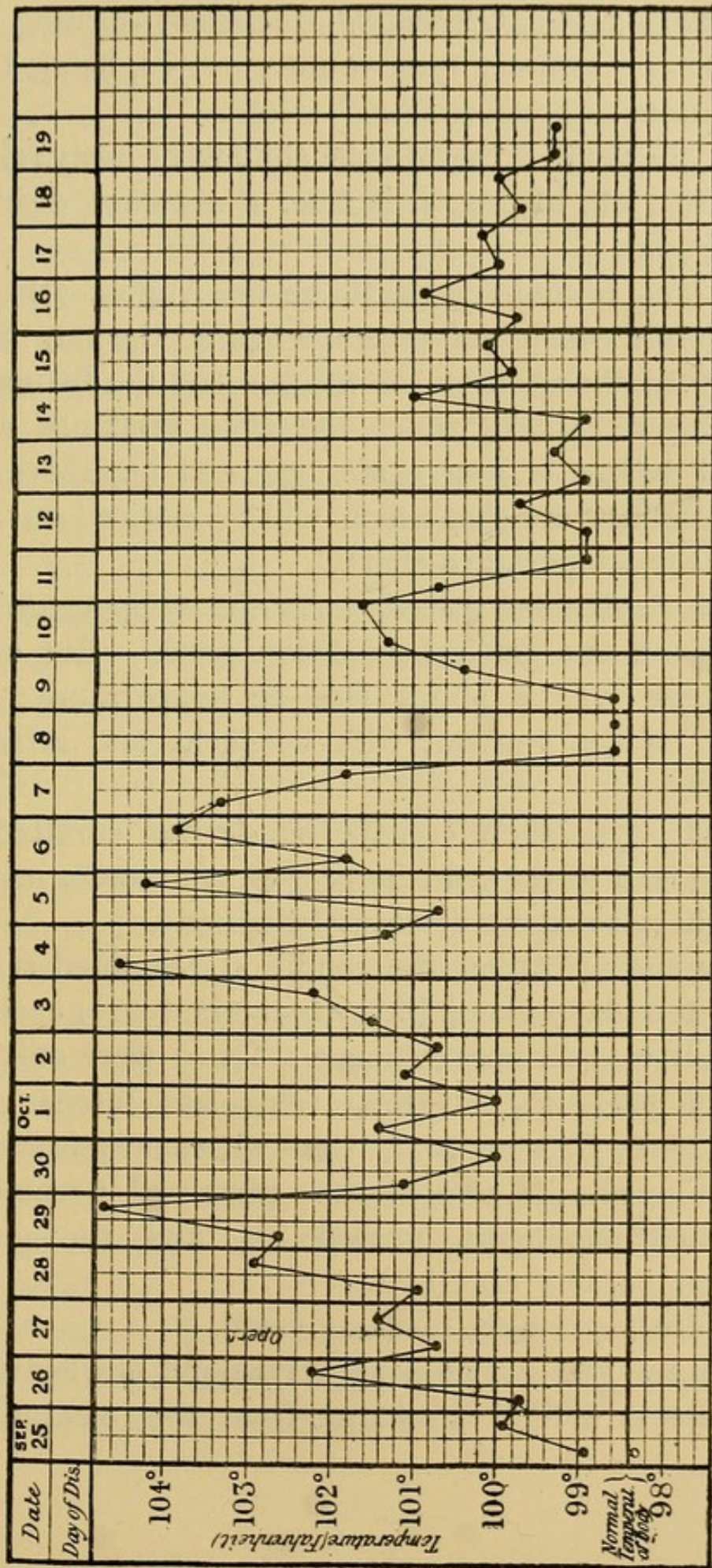
CASE XLII.—*Chronic bilateral Middle Ear Disease, with Mastoid Abscess on the left side. Pseudo-meningitic symptoms. Mastoid and Tympanum laid open. Recovery.*

B. R., 5 years of age, was admitted to the hospital February 22nd, 1893.

*History.*—Mother subject to attacks of bronchitis, but vigorous, and never having expectorated blood. Father healthy. A sister died of meningitis at thirteen months old. Two brothers, one of whom, ten and a half years old, has had many attacks of a skin eruption and the other has suffered from otorrhœa. The child had measles about April or May 1890. Fifteen days later the left ear discharged; then the right, eighteen months later, but not so freely and intermittently; whilst the left always suppurated abundantly. In 1891 bronchitis, with pleurisy and pneumonia. The left ear then became completely deaf. At this period the child was very ill, and after her recovery, in 1892, she was brought to the clinique of Dr. Lubet Barbon, where she was treated by the ordinary means. Nevertheless, the otorrhœa continued, and on February 22nd the child was brought to the hospital for a mastoid abscess which had formed, with fever, pains, and sleeplessness.



CASE XLII.



CASE XLII. (concluded.)

*February 24th. Operation.*—Incision ; opening up at the seat of election ; tympanum curetted, being full of granulations.

After the usual dressings the child went away relieved on April 13th, having, it is true, a constant discharge from the ear.

She was brought back to us on August 7th for a small fistula which had reopened behind the ear. Slight purulent discharge from the meatus and the fistula.

During the weeks which the child remained at the hospital before it was again operated on, there were several febrile attacks, which will be noticed on referring to the temperature chart.

From September 4th to 25th the temperature was normal and the general condition good. But on the 25th there was a slight rise of temperature ; more marked on the morrow, with headache and attacks of drowsiness.

On the 27th, therefore, the fistula was curetted, and found to lead to the tympanum by a granulation-covered track, there being no disease of the bone.

After the operation the condition remained serious, as for ten days meningitis threatened to supervene. Then followed an improvement. There were still some signs of pressure, but they were less intense ; and, finally, since October 21st, when thermometric tracings were stopped, the temperature remained normal, the threatened meningitis passed off, and the general condition became excellent.

The dressings were made as usual.

*December 15th.*—The posterior wound has healed up, but there is a fetid discharge from the meatus ; the

tympanum is covered with granulations, and there is free drainage.

*February 3rd, 1894.*—Examination by Dr. Boulay. The right ear presents a very large perforation. With the probe the attic is explored, but no bare bone felt. On the left side the membrana tympani has disappeared. The probe brings away caseous masses.

In February a small fistula reopened behind the ear, which discharged but slightly, and rapidly cicatrised up.

*July 7th, 1894.*—The child was brought back to the hospital because, for the last fifteen days, the ear has been suppurating a little at intervals. Instillations of boracic acid alcohol.

Since this time the cicatrisation has remained firm, but from the two ears there is a little discharge from time to time.

CASE XLIII.—*Chronic Mastoiditis, with attacks of vertigo and vomiting. Mastoid laid open. Recovery.*

*History.*—G., 39 years of age, male, came to the hospital on June 26th, 1894, for pains in the ear, which started ten days ago, with discharge and deafness. Up to this date he had never had any ear symptom, and appears to have enjoyed good health. The discharge is serous, and not large in amount. After cleaning up, a punctiform perforation was found situated in the upper part of the membrane. The perforation was enlarged by a paracentesis, and this operation was followed by great relief.

*June 30th.*—Discharge very abundant: catheterisation caused a large quantity of pus to escape through the orifice made by paracentesis.



*July 16th.*—The discharge has diminished. A granulating spot is seen upon the inner wall of the tympanum. Boric acid dressing. The ear still suppurating very abundantly.

This discharge continued through the months of August and September, without modification of the general condition, except when the granulations blocked the orifice in the membrane.

In the early part of October the patient began to complain of attacks of vertigo. On October 8th he had a rigor, with fever and attacks of vomiting. The discharge was always very abundant. The perforation persisted, and there was no alteration of the tissues covering the mastoid, and no tenderness on pressing this bone.

*October 10th.*—The patient is unable to stand upright or walk; he constantly vomits, but there have been no fresh rigors. It is decided to lay open the mastoid.

*October 13th. Operation.*—Mastoid air-cells laid open; no pus found. Antrum deeply placed; opened, and found full of fleshy granulations, but no collection of pus. The antrum and aditus were curetted from behind forward. The communication between the antrum and tympanum being considered sufficient through the aditus, this last cavity was not opened; the opening in the bone was plugged with iodoform gauze, as also the meatus.

*October 20th.*—First dressing; no trace of pus, either in the wound or the meatus. Since the operation the patient has had no fever, no vertigo, and no vomiting.

*February 15th, 1895.*—The patient is still under treatment; his general condition leaves nothing to desire,

but there remains a suppurating cavity, at the bottom of which is felt with the probe a bare bony point.

CASE XLIV.—*Chronic Mastoiditis, with attacks of vertigo and vomiting and Facial Paralysis. Mastoid and Tympanum laid open.*

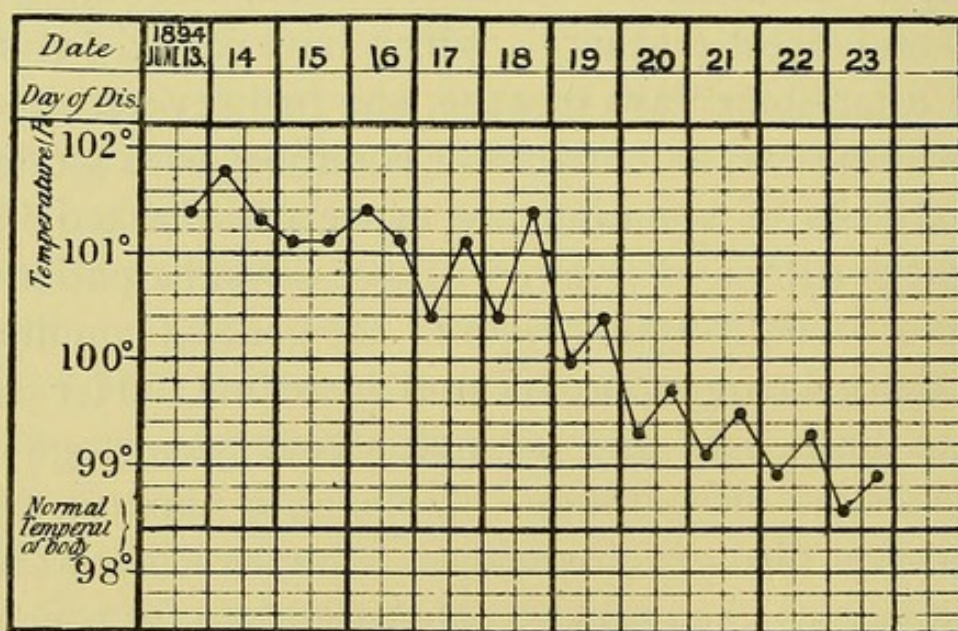
*History.*—B., a woman 24 years of age, came to the hospital on June 2nd, 1894, for a right suppurative otitis media, of about three weeks' duration, beginning with pains and slight discharge, which have lasted ten days; then, after some days of ease, she had severe shooting pains in the ear, and attacks of vomiting, with giddiness. The attacks of vomiting are especially marked in the upright position. For two or three days the patient has had, moreover, irregular rigors; the general condition is bad, there being anorexia and insomnia. Her father died of bronchitis and laryngitis four years ago; one of her sisters died of lung trouble, aged nineteen years; one brother died of convulsions. She herself has always been anæmic; menstruation appeared late (at seventeen years of age); she has had a left suppurative otitis media, which was cured, the traces of which can still be seen.

The right ear presents a large perforation behind the handle of the malleus, with some foetid purulent discharge. A bent probe introduced through this perforation is able to penetrate very high up into the attic. Catheterisation does not expel the pus nor improve the giddiness. The mastoid appears healthy; there is no tenderness on pressure. Irrigation of the tympanum is done by means of a Hartmann's cannula.

After a second visit to the hospital the patient became

so ill that it was necessary to visit her at home. The pains of the head, especially of the right side, are unbearable; they radiate as far as the neck. The attacks of vomiting are almost constant, and the vertigo is such that she cannot lie in her bed.

On June 13th facial paralysis supervened, with slight discharge of fœtid pus from the ear. In the presence of this fresh localising symptom, operation was decided



CASE XLIV.

on, it being determined to keep as far as possible from laying bare anatomically the facial nerve.

*Operation.*—Opening up the mastoid at the supposed level of the antrum was laborious, the bone presenting the hardness of ivory. After penetrating for 2 cm., neither air-cells nor antrum were met with; searching lower down (about  $\frac{3}{4}$  in.) towards the apex of the mastoid, this was found compact, with no cellular cavity. The postero-superior wall of the meatus, which separated the hole thus

made from the meatus and the tympanum, was removed; and the external wall of the tympanum was also removed as far as the superior limits of the latter. The superior wall was also taken away, so that the dura mater was laid bare; this membrane appeared healthy, and did not bulge through the perforation. The opening up was continued deeply as far as the promontory and the bend in the facial nerve canal, and there was found there a carious spot; and some very thin bony lamellæ, which appeared to belong to the internal ear, were removed. In fact, there was visible a rounded canal, which seemed to be the transverse semicircular canal opened. Below was found another bent canal, which appeared to be the aqueduct of Fallopius, the facial nerve being wanting; the whole of this cavity was carefully curetted, until no more diseased part was seen.

The rest of the operation presented nothing special.

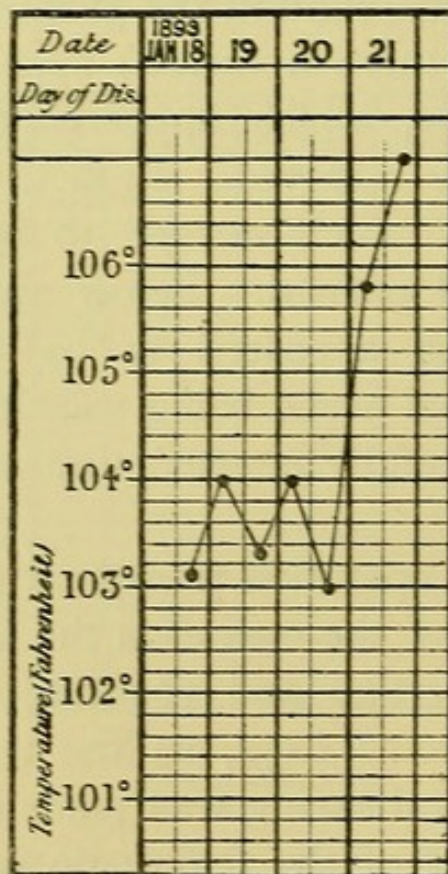
From the date of the operation the pains diminished, the attacks of vertigo and vomiting ceased, but the fever continued some days, as the temperature chart shows. The first dressing was made three days afterwards, on account of the fever; no pus was found in the cavity. Shortly after the fever ceased, the pains and vertigo disappeared and the general condition became, once more, good.

*To-day* (February 1st, 1895) the posterior wound has closed. The meatus leads into a huge cavity almost entirely skinned over, except quite at the bottom, where some fleshy granulations, which reappear time after time, make us fear a small bony lesion.

CASE XLV.—*Suppurative Otitis Media, with Suppurative Meningitis. Mastoid, Tympanum, and Cranium laid open. Death.*

L. L., 11½ years old, was admitted to the hospital January 19th, 1893, under the care of Dr. Le Gendre.

*History.*—Father tuberculous; mother healthy; one



CASE XLV.

brother tuberculous. Two years ago the child had pleurisy; two months ago, otitis media on the right side, followed by persistent otorrhœa. When the child was brought to the hospital it had suffered for six days from headache, constipation, and vomiting. On admission, besides these symptoms, the temperature was 104° Fahr.; pulse 80, irregular; nape of neck rigid and painful;

slight internal strabismus of the left eye. Abundant and fœtid discharge from the right ear. Treated by irrigations.

*January 20th.*—Left hemiplegia occurred suddenly during the night; left facial paralysis; pulse 180; coma; mydriasis on the right side. My friend and colleague Le Gendre having asked me to examine the child, we concluded, considering the sudden hemiplegia, there was possibly a cerebral abscess. Before we parted, therefore, I laid open the mastoid, the aditus, and the tympanum; it was only in the last place that we found pus, granulations, and the carious ossicles. This done, I opened with the chisel the roof of the aditus, enlarging the breach towards the temporal fossa. I laid bare the dura mater, which bulged slightly, over an extent equal to a two-shilling piece. Although it pulsated, I made an incision, and saw the brain, and punctured it with the trocar in three directions; the punctures remained clean. Plugging with iodoform gauze, as usual.

Next morning, comatose condition. Death in the evening.

*At the autopsy* suppurative meningitis at the base, extending to the right Rolandic area, with softening in the deeper parts. No cerebral abscess. The part of the brain punctured was not at all inflamed. The other viscera were healthy.

CASE XLVI.—*Mastoid Fistula. Acute Meningitis. Mastoid and Tympanum laid open. Death.*

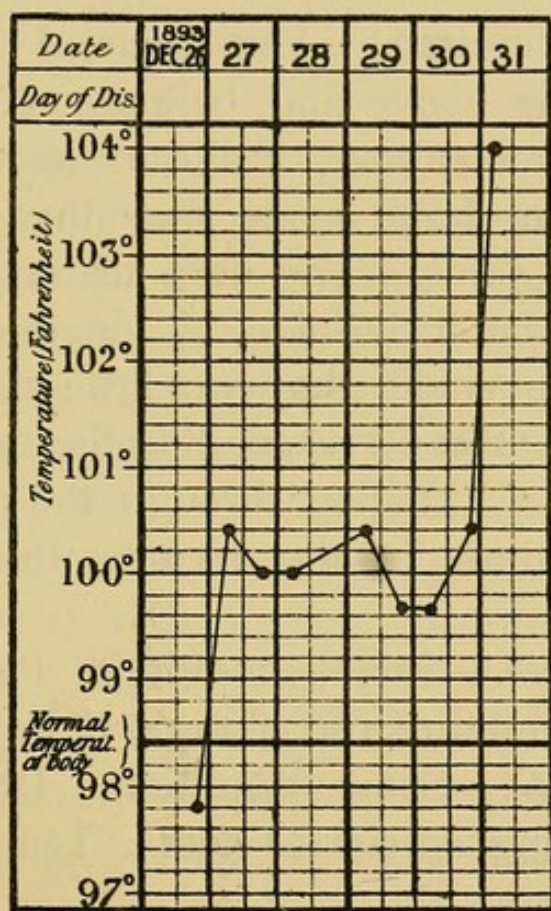
L. V., aged 5 years, was admitted to the hospital December 26th, 1893, under the care of Dr. Sevestre.

*History.*—Both parents healthy ; one sister healthy, and one died fifteen days old. A year ago the child had measles, followed by otitis ; and since this period the ear has discharged. But the clinical clerk who took the notes of the early history did not see the mastoid fistula, and it is not known how long it has existed. Since the measles the child has never completely recovered ; he has always a cough, is wasting, and eats badly. From time to time he has vomited, and there is constipation. Eight days ago he vomited on several occasions, complaining of his head ; was very pulled down ; the constipation increased ; and, finally, he was brought to the hospital on December 26th, 1893, and was admitted. That evening the temperature was  $97.7^{\circ}$  Fahr.

*December 27th.*—Temperature in the morning  $100.4^{\circ}$  Fahr. ; evening,  $98.6^{\circ}$  Fahr.

*December 28th.*—The child is much wasted and poorly developed. He grumbles very much ; lies on his back, when he is not examined, with the eyes closed and the belly retracted. It has the *tache cérébrale*. When aroused he is sulky ; cries ; allows examination with difficulty. Since his admission he has not vomited. The bowels acted spontaneously in the daytime of the 26th and in the night of the 27th and the 28th. Tongue whitish, a little spread out ; nothing in the throat ; abdomen flat and resistant. The liver and spleen cannot be felt. In the chest one finds at the left apex, behind, a little dulness. The child breathes very badly, and auscultation is negative, except for some subcrepitant râles on the left side, not numerous, and scattered. Auscultation of the heart negative. The pulse is almost

regular. Every twenty or twenty-five beats, however, a slight period of arrest is observed between two pulsations; these arrests repeat themselves in the force of the pulsations with a certain regularity. No paralytic phenomenon on the side of the bulbar nerves. Finding these meningitic signs a little disagreeing from those



CASE XLVI.

of ordinary tubercular meningitis, and observing an abundant discharge from the left ear, Dr. Péron, in charge of the ward, examined the mastoid region, and found there a fistula, and caused the child to be at once brought down to me. Temperature 100° Fahr. The fistula is situated behind the meatus, in the furrow behind the ear. The probe comes upon sequestra both



through the fistula and through the meatus. Suppuration profuse. Immediately, I made a T-shaped incision. The mastoid has been opened up spontaneously, to form a vast cavity, which contains, besides a pulp of sequestra, a huge sequestrum of about 1 cm. cube. After curetting this cavity, I observed that the spontaneous perforation extended into the tympanum, which was similarly curetted. This done, I saw that the bone was friable above and behind. After curetting this point, I saw, above, the dura mater laid bare over an area as large as a sixpenny piece; below and behind, the sinus. The dura mater pulsated well, and did not form a hernia. A longitudinal cleft of the meatus was made, the two little flaps of which were sutured to the corresponding lips of the incision behind the ear. Plugging through the meatus as far as the tympanum. In the evening the temperature was  $99.3^{\circ}$  Fahr.

*December 29th.*—Same condition. Pulse 128, but regular. Temperature  $100.4^{\circ}$  to  $99.7^{\circ}$  Fahr.

*December 30th.*—Same condition. Dressed in the evening. Nothing special to note. Temperature  $99.7^{\circ}$  to  $100.4^{\circ}$  Fahr.

*December 31st.*—Sudden elevation of temperature ( $104^{\circ}$  Fahr.); coma; pulse frequent and irregular. In the presence of these symptoms I incised the dura mater in the area laid bare, and although it pulsated I made into the brain two punctures, which remained white. Death at two o'clock in the afternoon.

*At the autopsy* suppurative meningitis along the course of the vessels, exactly limited to the left temporal region and to the fissure of Sylvius of this side

Nothing at the base ; no effusion into the ventricles ; no tubercles visible to the naked eye. Old bilateral pulmonary tuberculosis, especially marked on the left side, where a small cavity is met with near the hilum, probably developed at the expense of an intrapulmonary gland. The glands of the hilum are caseous on both sides. Nothing in the kidney, spleen, liver, and heart.

It appears to us useful to dwell upon these complications ; for if one is well warned of their possibility, one should be able to cure patients who would be left to die, if one believed, without fuller information, that the meningitis had really spread to an incurable extent. Must one explain these symptoms of "meningismus" (the meningitic state) by a simple reflex irritation, or by an actual commencement of meningitis, from a congestion and an œdema of the meninges around a focus of infection ? This second hypothesis seems to us most to approach the truth, in the present state of our knowledge ; but, whatever the interpretation, the important thing is to thoroughly recognise these cases in which we have seen attacks of giddiness, vomiting, or of coma itself, yield to opening up the mastoid and the tympanum.<sup>1</sup>

These are not the only complications, and we must also take into consideration the grave septic phenomena, without apparent thrombosis of the lateral sinus. Even in the gravest cases we should not despair of the final result ; and the following instance offers great encouragement to tentative operations.

<sup>1</sup> A. Broca, *Bull de la soc. anat.*, p. 581, 1894.

CASE XLVII.—*Middle Ear Disease. Mastoid Abscess. Stacke's operation, and opening up of the Mastoid. Cure.*

Charles M. ; 11 years of age.

*History.*—The left ear has discharged since infancy, but intermittently. Every time the patient has an attack of coryza or a sore throat, there is a reappearance of symptoms as regards the ear.

*May 29th, 1893.*—Severe pains in connection with the ear, with bad general condition, fever, and rigor.

*June 6th, 1893.*—Measles, with coryza well-marked. He appears to have had at the same time polypi in the meatus, which were touched by a doctor with a galvano-cautery. However, this may be, after the disappearance of the measles, the fever persisted irregularly, with rigors ; and the chart, placed at our disposition, showed evening exacerbations reaching as high as 105.8° Fahr., followed by morning remissions, with complete apyrexia.

*June 24th.*—The patient was brought to us for the first time. Emaciated, complexion leaden, skin always damp and clammy. He presents the aspect of a patient absorbing pus. He has frequent rigors ; he eats little, and appears to suffer in the head, but at the present moment to a very moderate degree. As regards the ear, the soft parts present but little alteration. The skin at the level of the mastoid process presents the normal colour and thickness. The mastoid region is not swollen ; it is painful to the touch, especially at the apex. Through the meatus escapes a small quantity of pus, and, when irrigated, one notices, with some difficulty, on account of the swelling in the lumen of

the canal, that there is no more membrane, and that the pus appears to come from the posterior-superior angle of the tympanum. This irrigation and cleaning up appear to improve the symptoms of fever and rigors.

*Operation.*—Owing to the bad general condition, and notwithstanding that the result might be most uncertain, the mastoid was laid open on June 27th. The tympanum being opened by Stacke's method, the attic was found full of granulations, and among them the remains of the incus. The aditus was opened into, and its external wall removed, and a small cavity in the bone found, full of caseous pus. This was hollowed out at the expense of the roof of the aditus ad antrum, which adjoined a *cul-de-sac* below and behind, but ascended superiorly above the roof of the antrum. At this spot the dura mater was seen. Below, the antrum was reduced to the minimum; and there were no other air-cells in the mastoid—reduced to an eburnated mass, upon which the chisel broke. In the evening, temperature  $104.7^{\circ}$  Fahr.

During the following days the digressions between the morning and evening temperatures were less marked, and there appeared to be no longer the large oscillations of septicæmia; but there were, during the day or night, febrile rises reaching  $104.6^{\circ}$  and  $105.1^{\circ}$  Fahr., with no well-marked rigor preceding these elevations of temperature.

On account of the fever the dressing was removed on the third day, and a pallid wound was found, without pus or inflammatory reaction, such as one is accustomed to see in grave general conditions. Fresh dressing (iodoform gauze).

From July 1st to July 4th the same condition was maintained, without great improvement; but on the 4th the patient made a fresh start. The dressing was renewed on July 3rd. Same condition of the wound. From this day the temperature fell to between  $98.6^{\circ}$  and  $100.4^{\circ}$ , to rise no more; the general state improved, the appetite returned, and our patient was restored to health. It looks as if, in spite of the operation, the symptoms of meningitis which complicated the sub-dural abscess continued, and were only arrested when, at the end of several days, the primary source of infection had been removed.

Since this period the patient has continued to improve; the posterior wound and bony cavity have filled up, and he would be altogether independent of our care had there not been the difficulty which we have experienced in trying to prevent the contracted meatus from becoming obstructed.

To-day there remain hardly any granulations in the tympanum, and all the discharge disappeared in April 1894. Seen again, cured, in August 1894.

One other fact deserves to be taken into consideration. It is not uncommon for the subjects of mastoid fistula to be the seats of diverse tubercular lesions, extinct or active. Is it indicated in these patients to treat the mastoid lesion surgically, without disturbing the tubercular infection? We think so; for, according to our fairly numerous observations, we believe we can state (1) that one can quite well cure the diseased ear; (2) that those operated on are not exposed to the complications of generalised tuberculosis

which certain writers dread. We only quote here a single instance, which is interesting because the patient was not only tuberculous, but also suffered from post-scarlatinal albuminuria.

CASE XLVIII.—*Mastoid Fistula on the right side. Mastoid laid open. Subsequently Pott's Disease. Cold Abscess of the frontal bone.*

F. L., aged 11 years, was admitted to the hospital on October 17th, 1893.

*History.*—Has had three brothers and one sister, who all had scarlatina; two brothers died of it, the sister recovered from it, as also the other brother, but the latter had a discharge from the ear for a month. Our patient also had scarlatina in July 1892. The right ear commenced to discharge in August, and has always discharged since this time, with variations more or less in the amount. Two months ago an abscess appeared behind the ear, which opened spontaneously. Many cervical glands supplicated formerly, the scars of which remain.

*Present State.*—There is a fistula posterior to the furrow behind the ear, altogether above it, surrounded by flabby granulations, having an area of about a six-penny piece. Some otorrhœa, but not very considerable in amount. The probe enters into the fistula almost directly forwards, and meets bare bone.

*October 24th.*—Œdema of the lids and face.

*October 26th.*—An examination of the urine reveals two grammes of albumen. Milk diet and naphthol. The quantitative analysis of the albumen has been made daily; and a table will be seen at the end of the case.

*October 27th. Operation.*—Incision in the fold behind the ear, passing above through the fistula. The pocket did not extend either towards the mastoid or towards the meatus, but above the meatus, beneath the temporal muscle, over an extent of 3 to 4 cm. Temporal carious, friable under the curette; granulations, in which was a sequestrum as large as a hazel-nut. At the base of the mastoid was a small vascular orifice, larger than the others, with no trace of osteitis around. Nothing towards the meatus. Mastoid laid open at the seat of election. The air-cells, which contained some granulations, curetted. Fistula excised. Suture, with a drain-tube passing through the lower angle.

The patient departed in good condition on November 13th, and returned to be dressed.

*November 19th.*—The wound is going on well; the drain tube has been removed; all the rest of the incision is entirely healed. Early Pott's disease is observed in the mid-dorsal region, which the child's aunt has perceived a short time.

*November 25th.*—Seen again, with a cold abscess on the right lateral portion of the frontal bone, which was opened on the 26th, and the child again admitted to the hospital.

*December 15th.*—The ear still discharges a little. The posterior wound shows many buds of granulation tissue, but appears to be doing well.

*January 6th, 1894.*—Track behind the ear very short; no pus.

*January 20th.*—Stripping up of a centimetre of skin behind the ear. Meatus easily plugged; no pus.

*January 23rd.*—The small stripped-up portion of

skin, posteriorly, was incised with a snip of the scissors.

*January 30th.*—The cold abscess in the frontal region has been cured; the same condition in the mastoid; no pus in the meatus.

*February 24th.*—There persists a fistula at the superior angle of the fold behind the ear. The meatus no longer suppurates.

The frontal abscess is cured. The Pott's disease is stationary.

*April 1st.*—Small fistula behind the ear; no discharge from the ear.

AMOUNT OF ALBUMIN.

				grammes.
<i>October 27th</i>	...	..	... Albumin	0'00
„ 30th	...	...	„	1'00
<i>November 1st</i>	...	...	„	0'50
„ 2nd	...	...	„	'20
„ 3rd	...	...	„	'20
„ 4th	...	...	„	'20
„ 5th	...	...	„	'20
„ 6th	...	...	„	'20
„ 7th	...	...	„	'20
„ 8th	...	...	„	'20
„ 9th	...	...	„	'20
„ 10th	...	...	„	'10
„ 11th	..	...	„	'10
„ 12th	...	...	„	'10
„ 21st	no more traces of albumin.			

Our conclusion therefore is, that in case of mastoid fistula there is no contra-indication to operation.

In some subjects the chronic mastoid affections are



bilateral. We recommend then to operate in two stages ; for the complete opening up of the mastoid and tympanum is always a sufficiently laborious and long operation, which often lasts half an hour or more. One would therefore only operate on the two sides the same day if urgent symptoms are observed, such as those to which we have made allusion above. We made an exception to this rule in a little girl of twenty-two months, in whom, after operating on one side, we noticed that there was over the other mastoid a large fistula, at the bottom of which was seen a huge sequestrum, moving when probed. With a stroke of the curette the sequestrum was brought away, and the child was cured without another operation (Case LI.).

If on one side an abscess exists, on the other a fistula, where the ear trouble has quieted down, one would commence with the abscess.

*CASE XLIX.—Bilateral Mastoid Fistulæ, with complete necrosis of the two Mastoids. Mastoid and Tympanum laid open. Cure.*

O. L. ; aged  $4\frac{1}{2}$  years ; admitted to the hospital on September 4th, 1893.

*History.*—Mother paralysed when forty years of age ; died suddenly at the age of forty-two years. Father and two brothers healthy. Had scarlatina a year ago, following which there was a swelling of the cervical glands ; shortly afterwards, purulent discharge from the ears. Returning to Paris, on July 18th, a doctor was consulted, and he removed a sequestrum from the mastoid process (piece brought by patient). The ear

of the same side had never discharged: at all events, at present it discharges but little.

*At present* slight otorrhœa both sides. On the right side a fistula, at the bottom of which bone is not seen; on the left side a large fistula, at the bottom of which the mastoid, white and laid bare, is seen.

*September 8th.* Operation on the left ear.—Removal of a sequestrum comprising the mastoid. The canal of the antrum was full of granulations. By the usual means the tympanum was reached; and thence the malleus was extracted, the incus not having been seen.

After the first dressing the child left on September 14th. When it had quite recovered, it was brought back so as to be operated upon on the right side, where the fistula has persisted all along.

*October 7th.*—The left ear is doing well; the cavity is granulating up everywhere. On the right there is a depression, in the centre of which is a fistula which suppurates very slightly, but through which bare bone is reached; likewise through the meatus, the probe comes upon bone.

The right side was operated on.

The mastoid receded upon the temporal bone. Behind the meatus was a cavity full of granulations. The wall of the meatus was removed with the gouge upon the protector. The canal of the antrum was very large. Extraction of the malleus, which was healthy, and of the incus—the two extremities of which were carious. It was enveloped in granulations.

*December 1893.*—The child is in very good condition.

*January 6th, 1894.* Left ear.—A little pus from the

wound, which has slightly opened, and is occupied by a bud of granulation. Nothing noteworthy as regards the meatus, which is readily plugged.

*Right ear.*—No pus. Slight fistula behind the ear. Meatus well plugged.

*By February 1894* the child was cured. On the two sides cicatrisation of the wound was obtained. There remained slight intermittent otorrhœa. The narrowing of the meatus was considerable.

CASE L.—*Chronic bilateral Suppurative Otitis Media, with Abscess on the right, and Fistula on the left side. Mastoid and Tympanum laid open on both sides. Cure. (Cold Abscess of Rib.)*

F. E. M. ;  $4\frac{1}{2}$  years old ; admitted to the hospital on April 14th, 1893.

*Family History.*—The father and mother have had seven children, four of whom are dead : one from the sequelæ of measles, in December 1892 ; one born dead ; one of meningitis, and one of diarrhœa. The last children are being nursed. The present child had had measles and whooping cough at the same time, in December 1892. The mother did not know at all whether at this time the ears discharged ; but shortly after, there appeared some swellings behind the ear, which a doctor diagnosed to be mumps. The child had much fever, and delirium continually ; for three months has been up every night. In the course of February or March the abscesses were opened ; a renewal of symptoms soon after, for which a fresh incision was made at St. Louis. Then, the advice

that no attempt to cure these abscesses having been given, no further attention was paid to them, and the child became more and more deaf. Then it was brought to the Hospital Trousseau.

*Present State.*—On the right, two abscesses—one below the antrum, violet-red and painful; slight discharge through the meatus. On the left side, a fistula just admitting the probe, which leads down to rough, bare bone; no discharge through the meatus.

*Right side* operated on April 15th. Incision. Tympanum laid freely open and curetted. Plugged with iodoform gauze; then dressed as usual.

*Bacteriological examination* by M. Halipré, house-surgeon, gave the following results:—Cover-slip preparations negative. Bouillon remained clear, but examination of it showed streptococci.

*Left side.*—Operation on the fistula June 24th. Large sequestrum from the mastoid and squamous portion of the temporal. Tympanum curetted. Dura mater laid bare superiorly.

During the treatment of the mastoids operated on, the nurse one day noticed by chance a small tumour in the back, on the right side.

*July 25th.*—I observed, internal to the vertebral border of the right scapula, at the level of its lower half, a tumour slightly larger than a five-shilling piece, circular, flattened, with convex and regular surface, uniform in consistence, soft, unilobulated, fluctuating, the skin being supple and movable.

*Diagnosis.*—Cold abscess.

*August 4th.*—Incision parallel with the vertebral border of the scapula upon the tumour, which I

completely dissected out. It was beneath the muscle, extending down to the ribs in loose connective tissue easy to dissect, with a prolongation ascending beneath the scapula. Superiorly, by dissecting, I reached the pedicle. Cauterisation by means of a tampon soaked in chloride of zinc (1 in 10). No suspicious spot on the bone. Drainage ; suture ; pressure, with iodoform gauze dressing.

The child recovered very rapidly, with no fistula, and healing by primary union.

The dressing of the ears, done regularly, presented nothing special, the wound healing well.

*December 15th.*—I examined the little patient again to-day, and found the suppuration on the right completely stopped. The posterior orifice has not filled up, so that a hole remains, which makes the cavities of the tympanum and conduit, which are skinned over, communicate with the exterior. On the left, contraction of the meatus. The posterior wound appears doing well.

*January 16th.*—No pus. The small posterior fistula about 2 cm. long ; meatus a little narrowed. Posterior fistula touched with tincture of iodine. The cure of the right ear is maintained. General condition excellent. The costal abscess has remained cured.

*May 12th.*—From the left ear came a small sequestrum, after which rapid cure followed.

*July 3rd.*—The child left the hospital, completely cured. On the two sides the cicatrised cavity opens freely behind the ear.

*September 3rd.*—Local and general condition excellent.

CASE LI.—*Bilateral Mastoid Fistulæ.*

M. D. ; 22 months old.

*History.*—Disease commenced at the age of eight months, on the right first, then on the left. About two months afterwards, bilateral abscess behind the ears.

In March 1893, simple incision.

*March 12th, 1894.*—On each side a large fistula, at the bottom of which was seen black necrosed bone.

*March 15th.*—On the left side, extraction of a huge simple sequestrum ; tympanum laid open. On the right, extraction of a sequestrum, and the cavity curetted.

Cure complete on September 18th.

2. *Anatomical Indications.*—We shall commence by showing how the operation should be conducted in the simple fistulæ ; and we shall ask, in conclusion, what modifications the operation should undergo if there exist intracranial complications.

In the presence of a simple mastoid fistula the surgeon should, clearly, act as if it were an ordinary bony fistula ; that is to say, extirpate all the diseased bone, and drain freely, plugging the cavity which results from this operation.

What now complicates the question is, that we do not attack a blind external fistula, like all the other bony fistulæ, but a complete fistula, extending from the pharynx to the skin, passing through complex cavities, tympanum, and mastoid cells, with walls, more or less carious, and necrosed.

Exceptionally, nevertheless, an actual blind fistula can form as a consequence of those eburnations of the mastoid, of which we have previously spoken ; and

already we have mentioned, in this relation, that one of us has found an abscess confined to one mastoid air-cell, perfectly shut in, in a subject in whom it had previously been necessary to open the antrum and attic by Stacke's method.

The latter is a rarity, since, in the numerous patients that we have seen and operated on, once only an arrangement of this kind has been met with (Case XXXV.). But this is a proof that in these old mastoids, with old otorrhœas, it is not always possible to determine precisely in advance what will be done, how one will operate, and, above all, where one will go. Some rules, however, ought to be known, by means of which the surgeon who is already well acquainted with the typical operations (the description of which we have given in the preceding chapter) will be able to discharge the duty which devolves upon him. What is this duty? To follow to their farthest limits the infected tissues,—granulations, and bone—which keep up the suppuration.

The question reduces itself, then, to this, in the majority of cases: which is the surest way to penetrate into the tympanum through the mastoid process? The goal of the operation should be, we repeat, the tympanum: this is why a fistula of the mastoid process is not, generally, a simple blind external fistula, and why it communicates on the deep aspect with the tympanum.

In its origin the tympanum was the starting-point of the bony suppuration; it is through it that the infective agents have entered into the mastoid, and, with some exceptions, the communication between

the tympanum and the mastoid exists, or has existed, sometimes narrow, as the fine track, and sometimes irregular, as the fistula. To be sure of checking the discharge one must go to its sources, travelling in the reverse direction, the road taken by the pus, air-cells, antrum, aditus ad antrum, tympanum.

At the commencement of our practice we were not so radical, and so it is that we were obliged, in the following case, to undertake several evacuations successively, because of not having acted thoroughly the first time.

CASE LII.—*Mastoid Fistula. Incomplete laying open of the Mastoid. Successive operations. Very slow cure.*

*History.*—C., 16 years old, was operated on eight years ago, by Wilde's incision, for a mastoid abscess secondary to a suppurative otitis media. Since this period a discharge from a fistula, which gushes forth from very high up, at the level of the upper border of the meatus. The fistula is directed below and in front.

*Operation.*—Mastoid eburnated below the fistula; fistulous cavity curetted. But we were wrong not to go into the tympanum through the orifice of the aditus, and remove the posterior wall of the meatus, as we did to-day.

At the end of a month and a half the wound closed, but shortly after reopened, through a fresh fistula. Curetted again. Cauterised with chloride of zinc, followed by treatment and prolonged dressings for more than six months, without any improvement resulting.



*Third operation.*—The cavity was enlarged, and it was thoroughly laid open within the possible limits; and the sinus was exposed. But we did not do enough as regards the tympanum.

Scraping, cauterisations, and simple dressings continued for four or five months. Cicatrisation occurred slowly, and the fistula finally closed.

*February 1895.*—The cure has remained good for two and a half years; but there remains a discharge through the tympanum, coming from the attic and probably from the aditus ad antrum.

First of all, as regards the cutaneous incision. The formal rule is to plan it typically, at the seat of election, 2 mm. posterior to the furrow behind the ear, without paying too much attention to the position of the fistula. To this incision, which will pass from the tip of the mastoid to the temporal region, curving over the auricle, is joined another incision, extending horizontally from before back, so as to facilitate the exposure of the bone; and in doing this, we should pass, by preference, through the fistula. It is therefore useful to slit up this pathological opening, as curetting the granulations and excising the sclerosed tissues which surround it are indicated.

After the skin incision, the subjacent bone, which will have been previously thoroughly explored with finger and probe, is laid bare very carefully with the rugine. This done, several conditions may be met with which demand different methods of treatment, more or less complex, according as the mastoid is merely laid bare or perforated, according as it is

eburnated or carious, or as the perforation is narrow or wide, or as there are or are not sequestra.

In the midst of these varying conditions one broad rule may nevertheless be formulated: the mastoid must be cleared out, always bearing in mind the landmarks which indicate the organs to be taken care of, and directing oneself always towards the antrum.

Finally, one other question presents itself: how to act as regards the tympanum.

In order to make it clear what course should be adopted, we shall commence by taking two extreme cases and comparing the one with the other: firstly, where the work of the surgeon has been almost entirely done by nature; secondly, where, on the contrary, the mastoid presents merely a limited bare area. Between these two is the condition of bony fistula more or less wide.

Taking the simpler case, where the petrous bone is in great part destroyed by osteitis. Beneath the skin, we open then into a large perforation, which is made larger in a few moments by removing the friable border surrounding it with the curette; we thus enter into a huge cavity, which contains sequestra, granulations, and caseous pus. With a few strokes of the curette the contents are evacuated, the granulations are removed step by step, and we arrive at length, without having resorted to the fine gouge, at the tympanum, the postero-superior wall of the meatus being found spontaneously destroyed by caries or by formation of a sequestrum. This done, in the cavity which now presents itself, and which is plugged for some minutes so as to arrest the hæmorrhage, the consistence of the

bony walls is ascertained with the probe, the red and friable spots are scraped until everywhere the tissue is hard, but doing this slowly, gently, and carefully, millimetre by millimetre, when approaching the roof of the aditus,<sup>1</sup> that is to say, the dura mater, the facial nerve, and, above all, the sinus. Often enough sinus and dura mater will be found bared, but they will not have been perforated. We conclude by slitting up the meatus and plugging the cavity, as has already been mentioned (p. 138).

What is the nature of such a case as we have just depicted? The tympanum, aditus, and mastoid process have been converted into a single cavity. This is precisely what we ought to do artificially in the case which we are going to consider now; and where the mastoid is hard and merely bared, there exists at the same time lesions of the bony wall of the tympanum or of its ossicles. In this case the typical operation is indicated, which consists in proceeding from the mastoid, thus entering the tympanum, which is then curetted.

The typical procedure being that described on pages 124 and 135, it remains for us to point out how it should be modified in the various special cases. In order to do this operation nicely, the first rule is not to lay too much stress upon the position of the mastoid laid bare or of the small perforation which is found. Clearly, if after stripping up the periosteum from the

<sup>1</sup> In one of Martin's cases (*Soc. médico-prat. de Paris*, April 27th, 1885), when the curette, in scooping out a carious mastoid, reached the superior wall of the excavation, the extensors of the fingers of the opposite side contracted.

bone one encounters a spot with little or no perforation, but carious and friable, it will be right to attack it with the curette, provided we are suspicious of the sinus behind. But for the majority of cases this would not be good treatment. We should open the mastoid at the seat of election with the fine gouge and mallet, find and curette the air-cells, and thence seek the canal of the antrum, so as to open it out into a trench and reach the tympanum. The same holds good in certain cases of fistula, but not in all.

The superficial bone can, in fact, be opened from within out at any part of the mastoid, sometimes at the seat of election, sometimes at the level of the air-cells, sometimes at a spot removed from the origin of the suppuration and in relation with it by an intra-osseous track of varying diameter. The position of the orifice and of the direction of the track will be of some assistance in relation with these facts, but we cannot take too much care in sounding with the probe the track of a fistula. We do not know, in fact, where it will end; we do not know what thickness of bone separates the cavity from those important structures which border upon it (lateral sinus, brain, facial nerve, internal ear). Sounding too precipitately or too roughly may lead to the breaking open of the protecting bony layer, and all the more so as this carious and soft bone is unable to resist the least pressure. Hæmorrhage, perforation of the skull, and facial paralysis are sometimes the result of this.

This being said, two cases may present themselves: first, where the surgeon can make use of the fistula to enable him to reach the antrum; or secondly, where

he considers he ought not to use it, and prefers to penetrate into the antrum and tympanum by opening up at the seat of election.

For the first case it is not possible to give one general method of operating: in fact, if the surgeon enters the mastoid along the fistulous track, the course of the operation could and should be modified during the operation itself, according to the length and direction of the track, as well as the form and dimensions of the cavity in which this track terminates. Be this as it may, all these explorations should be made carefully and cautiously; they ought to be directed so as to make the fistula communicate with the antrum. We must take care not to remove any bony wall without having previously made sure, by passing beneath it a protector of some kind (bent probe, hollow probe, Stacke's protector), that no important organ is contained in its thickness. But if the track of the fistula is difficult to define, it will always be prudent to lay open the antrum at the seat of election, being able to join up the fistulous track, by means of the chisel, to the newly excavated cavity.

The examination of the mastoid cells is usually easy, and particularly so when the mastoid has been hollowed out into a cavity containing little sequestra—Case XXXIII., for instance. But here fresh difficulties occur, in the shape of sclerosis of the mastoid. We have already alluded to a patient in whom one of us was obliged, in two distinct stages, to open a mastoid cell, closed in all directions, then the tympanum, with the antrum; and often, in these eburnated mastoids, with thick cortex, we can only find by means of

the chisel the remaining mastoid cells. Sometimes, even, we shall be compelled to give it up, no cavity or depressible point existing in the mastoid; and we refer to the patient in whom one of us, intending to lay open the mastoid for a fistula behind the ear, was obliged to modify his proposed operation, and confine himself to Stacke's operation, leaving untouched the eburnated and atrophied mastoid (Case I.). But these cases are rare, and almost always we shall find a cavity persisting, if certain rules of conduct are followed.<sup>1</sup> The chief aim ought always to be the investigation of the antrum.

We mentioned in the preceding chapter, when describing the operative technique in the treatment of acute mastoiditis (see p. 128), at which place we ought to search for the antrum: it is in a quadrilateral space, limited superiorly by the supra-meatal spine and the temporal line, anteriorly by the wall of the meatus, the inferior limit being variable and otherwise of little importance, the posterior being also variable, but, contrary to the preceding, being of great importance, since crossing this boundary exposes the sinus to injury. We have said that one is liable to this accident in going further than  $1\frac{1}{2}$  cm. from the posterior wall of the meatus. In this area, the superficial layer of bone being removed, the antrum is laid bare.

But in the special cases with which we are concerned a cavity is not always so easily encountered.

<sup>1</sup> Huntingdon Richard emphasises the gravity of these cases; but in his own case he operated blindly, using a gimlet. But we can only bring these operations to a successful termination by means of the gouge and mallet. *Trans. Amer. Otol. Soc.*, New Bedford, 1890, vol. iv., p. 527.

In fact, the bone that has been laid open is a bone diseased for a long time, having undergone strains from repeated inflammations, which have altered its texture, have eburnated its substance, and caused its cavities to disappear, or have greatly diminished them. There are no longer large air-cells; the cavity of the antrum is pushed very high up, shortened, sometimes reduced to a *cul de sac* of the aditus; and in place of these there is an eburnated mastoid, in which the chisel has as much difficulty in opening a passage as in case of a billiard ball. It is to be remarked that in these cases the mastoid, being retracted, is of less dimensions than that of the healthy side, and it is seen to recede beneath the projecting squamous.

If, in these conditions, we desire to find the antrum, it is necessary to go higher, above the supra-meatal spine, which ordinarily is found situated at the level of the roof of the antrum, and open through the temporal line carefully. Throughout the operation a bent probe must be introduced into the depths and in the supposed direction of the aditus ad antrum, in front and above, so as to penetrate into this aditus and indicate the path to be followed. The operation will be long and laborious, and ought to be conducted with a great regard to the anatomical relations of the region, if one wishes finally to penetrate into the aditus. Another variety is that in which the mastoid has neither opened spontaneously nor become eburnated, but is softened by caries: in these cases, intermediate between the two preceding, it is not attacked with a fine gouge, but it is scraped out with the curette, then, with the mallet, the postero-superior wall of the meatus is

removed, if the clinical examination, or observations made during the operation, demonstrate that it is desirable to go on and clean out the tympanum.

The opening up and curetting the tympanum are not always indispensable: for instance, in our Case LIII., a mastoid, with caries and a fistula of long standing, was scooped out without touching the tympanum, and cure, obtained in less than three months, has been maintained now for a year.

CASE LIII.—*Mastoid Fistula. Carious Mastoid scraped out. Cure.*

A. D.,  $7\frac{1}{2}$  years, was admitted to the hospital December 8th, 1892.

*History.*—The father and mother are healthy. Five children, one of whom died, aged thirteen months, of broncho-pneumonia; the other children are healthy. Born at term. The child had measles at five years of age, and whooping cough at six years. At the age of five and a half years, following exposure to a bad draught (?), she had intense pains in the ear. Almost at the same time there appeared behind the ear a small, red, and painful swelling. No discharge from the ear. Simple incision over the mastoid. Poultice. The abscess healed, leaving behind a fistula.

On December 8th the child was admitted to the hospital; on December 10th she was operated on.

*Operation.*—After an incision behind the ear, the mastoid was reached, and found to be friable in its whole extent, and scraped out with the curette. This done, there remained a large wound, at the bottom of which,



posteriorly, the lateral sinus was laid bare. The tympanum was not opened, the canal of the antrum appearing healthy. The wound was touched with chloride of zinc and plugged with iodoform gauze.

The child left the hospital on December 18th, the day after the first dressing. General reaction nil; local condition excellent. She returned here for the dressing every four or five days, and was completely cured by the end of February 1893.

I saw the mother again on January 15th, 1894. The child was in the country, and since then she could not be examined. Her general condition was excellent, and the mastoid cicatrix remained perfect.

In order to determine what one ought to do as regards the tympanum, important information is furnished in advance by careful examination with the otoscope and by investigation of the hearing. It will be noticed if the hearing is or is not preserved, and to what degree it is so; it will also be very carefully noticed whether the membrane has been perforated—the signs which lead us to recognise suppuration of the attic. Sometimes, even, the membrane will be found cicatrised, or nearly so.

Thus, as regards the patient, Case LIV., although there had been a chronic mastoiditis, with subacute abscess, the otorrhœa had ceased for a long time, the membrane was intact, the hearing was normal. Also, in operating, we only scraped out the mastoid and the canal of the antrum, without penetrating into the tympanum. The result, however, quickly proved us wrong, for soon a relapse supervened, for which we

had to do the complete operation. Observation of the anatomy, it is true, would have made us push this to the end the first occasion if the clinical examination had not led us to believe, with an almost certainty, in the integrity of the tympanum. The canal of the antrum, in fact, was very large, full of granulations, surrounded by friable bone (like the whole of the remainder of the mastoid), into which the curette entered as if going into butter. But the rule, in similar circumstances, is to freely open the canal of the antrum.

CASE LIV.—*Mastoid Abscess, with Chronic Otitis Media. Cure. Relapse. Mastoid and Tympanum laid open.*

A. D., 7 years old, was admitted to the hospital October 25th, 1893.

*History.*—He had never had either measles or scarlatina; but at the age of fifteen months his left ear discharged, and there followed a swelling behind the ear, which was incised: this incision, the scar of which is visible, was closed by the end of fifteen days. The mother says only blood came from it, but that the discharge from the ear was abundant. Since this period, every year during September the ear discharged for two or three days. For two months very severe pains in the ears have arisen, which last the whole day, with some short remissions; they cause the patient to cry out.

*Present condition.*—At a good finger's breadth from the fold behind the ear, at the level of the lower and

posterior part of the left mastoid, there exists a white and supple cicatrix, beneath which is a swelling as large as half a walnut. At this point there is such exquisite tenderness on pressure that I have been unable to examine for fluctuation. The child presents the attitude of slight torticollis of the left sterno-mastoid. There is neither redness, nor œdema, nor brawniness of the superficial planes. The auricle is not pushed forward; the fold behind the ear is not effaced. No actual otorrhœa. In spite of the position of the abscess—very low and far back—I did not diagnose an adeno-cellulitis, because the local sensitiveness was too severe for an adenitis of moderately acute degree, taking into consideration the absence of all modifications of the skin and of the subcutaneous plane. Membrana tympani normal. Hearing perfect.

*October 27th.*—The child being asleep, I noticed that the swelling fluctuated. I made a vertical incision, 4 cm. long. Over its highest point, and beneath the superior insertions of the sterno-mastoid, which I was obliged to cross, I found an abscess full of thick pus. In the anterior extremity of this pocket the finger nail felt a small bared surface, and there the probe engaged itself, further in front, in a small stripping up of the periosteum of about half a centimetre, where it rubbed upon the bone. I removed it by a crucial incision, and scraped the mastoid with the rugine, and the bared spot then appeared as large as a lentil, slightly depressed, blackish, depressible by the probe. This spot, situated at  $1\frac{1}{2}$  cm. behind the lower half of the meatus, was hollowed out by the curette, and below it I entered into the mastoid air-cells, full of pus and granulations; above it, in the

squamous portion, a track leading to a cavity in inflamed bone, as large as a pea, and containing granulations, situated above the meatus. After scraping out this cavity, the entrance of the aditus was enlarged by a fine gouge, and curetted; but the posterior wall of the meatus was preserved, and the tympanum, which appeared healthy, was not curetted. After plugging with iodoform gauze, going to the bottom of the antrum, the wound edges were brought together by two points of suture at each angle.

The temperature reached  $99.8^{\circ}$  Fahr. in the evening; all the rest of the time it never went above  $99.4^{\circ}$  Fahr.

The first dressing was made on the fourth day, and renewed every four days.

*December 10th.*—The child left the hospital completely cured.

*January 8th, 1894.*—The child was again admitted to the hospital, after spontaneous opening two days previously of a mastoid abscess the size of a hen's egg, through which much pus escaped. This abscess had commenced about fifteen days previously. Wet dressing. The next day the pus had entirely disappeared. At the lower part (about the lower third) of the fold behind the ear there existed a fistula with a large orifice, skin-covered and oval, 1 cm. in the long diameter; the fistula, about 2 cm. deep, led to the bone, which appeared healthy.

*January 19th. Operation.*—Incision over the mastoid, encircling the margin of the fistula a little behind the meatus. A cavity was reached full of grumous and fungating tissue. Cavity in the bone, the wall of which was everywhere resistant. The lateral sinus was not

found exposed. The canal of the antrum was very large, and contained granulations; around it the bone was solid. On stripping off the cartilaginous meatus there escaped pus from between it and the bony meatus. The tympanum was entered by means of the protector; it was curetted, and the incus, which appeared healthy, removed. The malleus was not seen. Cicatrisation was very slow.

On September 4th, 1894, the child left the hospital apparently cured; but on October 29th it was brought back because it had had pains for some days. At the bottom of the narrowed meatus there were some drops of pus. It is only right to add that the child was in an unusually filthy condition.

In January 1895 there still persisted a little otorrhœa; treated by plugging the meatus and instillations of carbolic glycerine.

We may conclude that in mastoid fistulæ, or, more generally, in chronic suppurative mastoiditis, we ought, in the great majority of cases, to penetrate into and freely open the tympanum, and we should not deviate from this rule if in the course of the operation it is distinctly made out that the aditus is healthy.<sup>1</sup>

<sup>1</sup> This method, in which one proceeds step by step in a direction the reverse of that taken by the pus, seems to us much better than that suggested by Chaput (*Revue intern. de rhinol.*, 1893, p. 49), in which a big, rectangular resection of the whole of the petrous is made. Out of three cases, Chaput produced facial paralysis thrice; but in sixty-eight chronic cases of our own, we only produced this paralysis five times, and in two of these, even, it was temporary (Cases LXII., CXII.). It is to be noted in two of these instances (Cases XXXI., CXXI.) the disease was very advanced, with carious bone, which was almost exclusively dealt with by means of the curette.

To conclude this chapter it remains for us to indicate the very special and exceptional case where the fistula, extending to the border air-cells, opens into the meatus. One should then, exactly as in the preceding case, do the typical and complete operation, through the track behind the ear (Cases XXXII., CXIX.).

### § 3. INTRACRANIAL COMPLICATIONS.

In the preceding pages we have intentionally kept to simply mentioning all that is related to the intracranial complications of attacks of otitis media. Already, however, in studying the indications for treatment in case of fistula, we have been obliged to be a little tedious in the matter, for in these conditions they are sufficiently frequent for the clinician to take them into consideration. But we came to the conclusion that they were not a contra-indication to operation ; rather, on the contrary, that they were an indication for immediate operation : that is to say, the surgeon ought to know how to act in like circumstance. We shall therefore briefly summarise the course we recommend ; the development of the subject would require a special memoir.<sup>1</sup>

*Suppurative meningitis*, when pronounced, being under the new order of things beyond the resources of art, there could be no question of modifying the operative procedures for it.

*Thrombosis of the lateral sinuses*,<sup>2</sup> for a long time

<sup>1</sup> A. Broca, *Bull. de la soc. anat.*, 1894, p. 561.

<sup>2</sup> The surgeons who have most studied this question are A. Lane, Ballance and Shattock, Salzer. For details see A. Broca and O. Maubrac, *loc. cit.*

considered to be inevitably fatal, has been for some years treated surgically with success. The operative procedure consists in ligaturing the internal jugular in the neck, below the clot, opening it over the clot, then laying open the mastoid, laying bare and opening the sinus, clearing out the infectious clot, and disinfecting the portion of vein intermediate between the two wounds. It is unnecessary to add, on the other hand, that the mastoid and tympanum are cleansed in the completest manner; therefore the operative technique is identical with that which we have mentioned for non-complicated fistulæ—the operation is only pushed further by deliberately going down upon the sinus. As for the ligature of the jugular vein in the neck, the method of operating does not concern us here.

There only remains the question of *cerebral abscesses*. These abscesses, the diagnosis of which is often obscure, so that one easily lets the indication for operation slip by,—and we acknowledge being undoubtedly guilty of this error in Case LVI., and probably also, in spite of the absence of an autopsy, in Cases LV. and LXVI.,—occupy almost always the temporal lobe in children; in adults it is the same in the majority of cases, but often enough the cerebellum is affected. The majority of surgeons advise opening them by trephining the skull above, and more or less in front of, the mastoid, if they are cerebral; below and behind, if they are cerebellar.

With Wheeler, Picqué, and Février, A. Broca and O. Maubrac, we affirm that, except for special indication afforded by unusual signs of localisation, the mastoid and tympanum ought to be opened, the roof of

the aditus removed, and through it, after having created a sufficiently wide breach, the inferior surface of the sphenoidal lobe should be explored. The most weighty arguments are as follows :—

1. The diagnosis between the three classes of cerebral complications is often doubtful: as in Case XLV., where meningitis, with no trace of abscess, produced a sudden hemiplegia. The operation, then, ought to be exploratory; and passage through the mastoid will only serve to verify the state of the sinus.

2. Although it has been said that cerebral abscesses only rarely start "at a distance," almost always they are in direct contact, sometimes in fistulous communication, with an inflamed and bared spot in the roof of the tympanum or aditus. This is the shortest way to find them; and, besides, it is the most favourable place for drainage.

3. Often intermediary between osteitis and cerebral or cerebellar abscess is a collection of pus, which strips up the dura mater (subdural abscess), and which can only be opened through the passage in the mastoid.

4. This subdural abscess can by itself cause symptoms identical with those of cerebral abscess, the diagnosis of which from cerebellar abscess, on the other hand, is usually well-nigh impossible. But the passage through the mastoid alone permits the necessary explorations, which will enable us, without danger, and by a single operation, to investigate possible diseased foci, leading us step by step through the bony affections as they are met with.

5. Supposing, finally, that simply trephining the temporal bone is as good—which we do not believe—



as draining the mastoid for cerebral abscess, regarded by itself, it ought not any the less to be rejected, since the formal rule ought to be always to commence by insuring perfect disinfection of the mastoid and tympanum. We have said, in fact, that this often suffices to check the brain symptoms, even when grave.

It must therefore be laid down in principle that the passage through the mastoid is always to be opened when one proceeds, immediately or secondarily, to explore the cerebrum : as the other measures proposed have been for the *better* drainage, it is bad not to make it (the mastoid passage) serve the two purposes.

Summarising these propositions, the following conclusions may be drawn :—

1. The mastoid operation is the same whether there are, or are not, cerebral complications.

2. Except for special symptoms, having agreed to the clinical diagnosis of a cerebral abscess or of thrombosis, or excepting local conditions noted in the bone at the time of operation, the rule ought to be to confine oneself at first to operating thoroughly on the fistula. If at the end of twenty-four to forty-eight hours the symptoms have not yielded, the roof of the aditus should be removed, and the dura mater and brain explored (examination of pulsations and exploratory puncture).

Our last conclusion is contrary to the course which has recently been extolled by Picqué and Février.<sup>1</sup> Haunted by the fear of not recognising a subdural or intra-cerebral abscess, these writers recommend

<sup>1</sup> Picqué et Février, *Ann. des mal. de l'or. et du lar.*, 1892, p. 883.

opening the mastoid, and "combining this opening with that of the cranium by Wheeler's method in the frequent cases where a suppurative otitis media is accompanied by painful and febrile phenomena, with or without mastoiditis." But all attacks of acute mastoiditis are like this, and a good number of chronic ones also. As for the acute attacks, our experience enables us to state that it is not necessary thus to explore the brain on the affected side. All our cases of operations on simple mastoiditis recovered, and we have seen only four patients succumb, affected with diffuse osteitis of the petrous bone, without our discovering at the autopsy a lesion of the nervous centres. As for the cases of chronic mastoiditis, three times only out of sixty-eight cases did we fail to recognise at first a cerebral abscess; not being incised then, which was a mistake, death followed. One of these cases will be summarised further on (Case LVI.). We give *in extenso* the other two: we shall see there that the blame is attributable to each of us once, but that in the third patient this unfortunate temporising was not our fault.

We ought to add that, in a quite recent communication to the *Société de chirurgie*, Picqué has rather wished to make one of us<sup>1</sup> "a slight concession," and adopt the conclusion that we have just defended; and we are glad to state that Drs. P. Berger, G. Marchant, and Lucas-Champonnière hastened to congratulate him on it.

<sup>1</sup> A Broca, *Bull. de la soc. anat.*, 1894, p. 571; and *Congr. franç. de chir.*, 1894. (See *Ann. des mal. de l'or. et du lar.*, 1895, vol. xxi., pp. 11, 14.)

CASE LV.—*Chronic Otitis Media, with Mastoiditis. Mastoid laid open. Death from Cerebral Abscess.*

*History.*—M. F., 48 years old, had, in the month of August 1894, an abundant purulent discharge from the right ear, arrested almost instantaneously by an insufflation of boracic acid powder. Since this time hearing has become bad. F. has buzzing sensations and severe pains at the junction of the right frontal and parietal bones, the pains being exacerbated at night, preventing him from sleeping.

About November 20th he came to see me. No fever. The right membrana tympani was reddish, appeared thickened and as if infiltrated. Upon Shrapnell's membrane was seen a small cup-shaped eminence, the size of a millet seed, with a little hole in the middle. The air-douche slightly improved the hearing, but did not give the signs of an effusion in the tympanum. There was, moreover, no pus in the meatus. Shrapnell's membrane incised. The subsequent air-douche did not produce the characteristic bruit of perforation; nothing escaped from the orifice.

About December 2nd the pains persisted, perhaps a little less strongly; but after a carriage-drive, during which F. perceived quite distinctly a sensation of cold in the right ear, the pains started again, the insomnia returned. He came to see me two days after, with a painful swelling at the apex of the mastoid, the base not being painful. The membrane was redder. Paracentesis, air-douche: no pus; but next day there was upon the perforation a little whitish mass, which appeared to be dried pus. The symptoms increased;

the swelling extended along the sterno-mastoid sheath, with slight œdema. Examination with the otoscope revealed the "dip" of the postero-superior wall of the meatus.

*December 11th. Operation.*—Incision. No abscess. Cortical layer of bone removed. At the tip, and a little in front, of the mastoid a bare spot was found leading to the air-cells: opened up at the level of the air-cells, descending towards the tip of the mastoid, which was removed. We proceeded from below up as far as the antrum, which was freely opened, and found full of fleshy granulations. Cured and firmly plugged.

Dressed six days later. No fever. Wound aseptic.

During the following eight days no fever; the pain diminished a little, but never completely ceased. The patient did not recover his strength; did not rally as one is accustomed to observe after a successful operation. The wound, otherwise, was in very good condition: communicated freely with the tympanum through the antrum. We considered the question of a deep-seated complication, but there was no definite sign to give sufficient indication for operation.

*December 30th.*—The patient had a slight attack of vertigo during the dressing. The temperature rose to 100.4° Fahr. Slight exacerbation of the pains. Pulse normal. No tender spot on percussing the surface of the skull. Wound in very good condition.

Four days later, attacks of vomiting; severe attacks of vertigo. The temperature rose to 104° Fahr., but the pulse remained slow (80). We concluded from this time that there was a cerebral abscess, and we took the opinion of two of our colleagues: these confirmed

our own view. We were inclined to trephine there and then, but the case did not appear to be so alarming but that the operation could be postponed till two days after. The patient the same night became comatose, and died next day.

CASE LVI.—*Chronic Mastoiditis, with old Cerebral Abscess. Mastoid and Tympanum laid open. Death.*<sup>1</sup>

R. C. ; 13½ years old.

Three years ago, otorrhœa ; mastoid abscess, which spontaneously opened, then again formed after some days, two and a half years ago ; then, two years ago, similar conditions ; then two years' quiescence, but persistent otorrhœa.

Fifteen days ago, a fresh mastoid abscess.

*January 14th, 1894.*—Mastoid and tympanum opened up.

*January 31st.*—Death.

*At the Autopsy.*—Old abscess in the temporal lobe.

<sup>1</sup> A Broca, *Bull. de la soc. anat.*, p. 561.

## CHAPTER III.

### *CHRONIC SUPPURATIVE INFLAMMATIONS OF THE MIDDLE EAR, WITH LATENT MASTOIDITIS.*

THIS chapter will be very short, because, to make it complete, a profound study of suppurations of the attic and their treatment, of Stacke's operation in particular,<sup>1</sup> would be necessary, which would lead us far from our subject; but, confining ourselves entirely to the exposition of the surgery of the mastoid, it is impossible for us not to sketch, in its main points, a picture of these chronic discharges from the ear, which are complicated by latent mastoid affections, so that the surgeon starts intending to enter directly into the tympanum, and ends by freely opening up the mastoid. Is this not the necessary counterpart of the preceding chapter, where we have seen the surgeon lay open the mastoid and be led step by step into the tympanum?

The attacks of chronic otorrhœa which we have in view at the present moment are those suppurations of the attic concerning which we have already said a few words in connection with acute mastoid abscesses

<sup>1</sup> E. Weismann, "Traitement des suppurations de l'attique," *Th. de doct.* : Paris, 1892-93, No. 204. See also six cases of Luc, *Bull. et mem. de la soc. franç. d'otol., de lar., et de rhinol.*, p. 186 : Paris, 1894.

complicating chronic inflammation of the middle ear, and again in connection with mastoid fistulæ. As we have just said, they are sometimes kept up by inflammation of the mucous membrane alone, but usually they are symptomatic of carious bones, leading down either to the ossicles or to the walls of the tympanum, and, most often of all, the lesions are complex, affecting several bones at once.

Finally, we have already tried to make it clear that the exact diagnosis of the lesions is often most obscure; that if, when the probe gives positive information, it can be affirmed that there is one or several bones diseased, when it gives negative results we can by no means infer that the mucous membrane is alone inflamed.

In practice, when the probe does not meet with bare bone, we begin by the non-operative treatment of the suppurations of the attic, by irrigations and antiseptic instillations; and we only treat the mastoid if a clinically evident complication occurs. But when the bony lesions of the attic are certain, or when—these lesions being impossible to make out clinically—the suppuration is decidedly resistant to the ordinary methods of treatment, the aspect of the question is changed: surgical interference is imperative.

From the first, removal of the malleus has been proposed and practised, with or without taking the incus, through the natural passages. Subsequently many procedures were suggested, all of them very unreliable; and great progress was attained the day Stacke made known his method.

In its chief features, Stacke's operation, the details

of which we have not indicated, consists in making an incision behind the ear, separating the auricle, then the meatus as far as the tympanum, and introducing into the attic, through the tympanic orifice, a curved "protector," upon which the postero-superior boundary of the meatus (the wall of the attic) is removed with gouge and mallet. The attic is then wide open, and nothing is easier than, by manipulating with forceps and curette, to remove the incus and malleus, to take out the granulations, and scrape the carious walls.<sup>1</sup>

And notice how we are brought back to the surgery of the mastoid. Out of thirty-three cases, twice only, after investigating, *de visu*, the condition of the antrum, did Stacke consider himself able to rely on simply opening the attic without opening the antrum! The principal result of this surgical method will therefore be to demonstrate peremptorily that the mastoid almost always, even when examined clinically it appears perfectly healthy, participates in disease of the attic. One

<sup>1</sup> In connection with Stacke's operation we shall mention a confusion made by Dr. Moure in a recent communication (November 21st, 1893) at the *Soc. d'ophth., lar., et otol. de Bordeaux et du S. O.* (Compte rendu officiel, *Gaz. hebd. des sc. med. de Bordeaux*, February 11th, 1894, p. 68). Dr. Moure presented a patient who had undergone "Stacke's, or Küster's, operation," which "consists in opening the tympanum through the mastoid process." After what we have said, it is clear that this is neither Stacke's nor Küster's operation, but the complete laying open, of which we have spoken in studying the treatment of fistulæ. We insist on this because recently C. R. Holmes (*Zeitschr. f. Ohrenheilk., t. xxv., fasc. 3 and 4, p. 269*) has described "Stacke's operation, modified by Schwartze." This modification consists, to begin with, in opening the antrum, and passing thence into the tympanum. To speak the truth, this is the suppression, pure and simple, of Stacke's operation—an operation the indications for which we consider to be rare, but real.



will not be astonished at this on remembering that the aditus opens exactly into the attic; and this, no doubt, is one of the principal reasons why suppurations of the attic are particularly abundant and obstinate.

So that only twice has Stacke not opened the antrum at the same time as the attic; and once he regretted acting thus, for secondary infection of the mastoid necessitated a special operation. This being so, one objection immediately occurs to one's mind: why not always open first the mastoid, particularly the antrum, and go thence into the attic?—why trouble to render an operation more difficult by doing it the wrong way, since it will almost invariably end by being completed? This objection would be valuable if the complete operation were necessary *constantly*, but it is only *almost constantly*; and so, in cases of this kind where no symptom enables us to assert the participation of the mastoid, we ought to try and cure our patients in two or three weeks, instead of assuredly imposing, without fail, long months of treatment, which recovery from a complete laying open of the mastoid and tympanum generally requires. These cases are rare, but they do exist, and we shall mention in support the rapid successes of Cases I., LVII., LVIII., LIX.<sup>1</sup>

In principle, moreover, a surgical operation is good when it starts from the known, so as to confine it to

<sup>1</sup> C. Gruenert (*Arch. f. Ohrenh.*, 1893, vol. xxxv., pp. 198, 231) publishes forty-three cases operated on by Stacke's method in the hospital at Halle. With the first series, already published, he reaches a total of a hundred cases, with fifty-eight cures. Contrary to our opinion, he advocates resting content with laying bare the attic. His view is also shared by Panse (*Arch. f. Ohrenh.*, 1892-93, vol. xxxiv., p. 248).

the possible. It is unsound, on the contrary, to take as the starting-point a possible, or even probable, consequence of a known lesion, which thus becomes the finishing-point. This second method is only to be recommended if the first is impracticable.

But, considered as an exploratory measure, Stacke's operation is of great value ; and as—if one has any experience of the surgery of the ear—it leads to good results readily and without trouble, it ought to be preserved. It would be obviously unfair to use the results of his first trials to demonstrate the uselessness of his invention.

Our practical conclusion is, that suppuration of the attic resisting non-operative treatment ought to be dealt with by Stacke's operation, by which one can always advantageously verify the state of the aditus ; and in many of the cases—in the majority even, but here we do not go as far as Stacke himself, according to whom it is almost the total number—one will open, upon the protector, the aditus, then the antrum, then the air-cells. This is what we did in our Cases LXI. to LXVII. ; and, finally, the anatomical result is identically that which we have made known in the case of mastoid fistulæ.

We connect, then, in the following chapter the study of the results of opening up the tympanum, completed by that of the mastoid, with the study of the results of the inverse operation. So that we may not have to return to this again, we shall say that the *true Stacke's operation* (laying open the tympanum alone) has provided us, out of six cases (Case I. and LVII. to LXI.), four recoveries : one secondary opening up of the mastoid

(Case LXI.); one death from meningitis—following operation (Case LX.); one death from cerebral abscess—previous to the operation (Case LXIII.). It would, however, be unjust to attribute a mortality of one in six to this method. Stacke's operation cannot be more severe than the complete operation, the harmlessness of which we shall see directly.

CASE LVII. (abstract).—*Suppuration of the Attic. Stacke's Operation. Recovery.*<sup>1</sup>

Girl; 18½ years old.

*History.*—Old otorrhœa on right side. Treated at the clinique from September 8th, 1891. Attacks of vertigo; whistling noises. Repeated and unsuccessful removal of polypi, malleus, and incus. Stacke's operation December 13th, 1892. The improvement (in the otorrhœa and functional troubles) was immediate; but the complete recovery, delayed by cicatricial contraction of the meatus, was only obtained in November 1893. The cure was maintained in February 1894.

CASE LVIII. (abstract).—*Suppuration of the Attic. Stacke's Operation. Recovery.*<sup>2</sup>

Girl; 18 years old.

*History.*—Otorrhœa right side since six years old. Attacks of earache, headache, vertigo, buzzing noises. Failure of ordinary method of treatment, and removal of the malleus (from April 1890 to November 1892).

<sup>1</sup> Case VII. of Weismann's Thesis.

<sup>2</sup> Case VIII. of Weismann's Thesis.

*November 22nd, 1892.*—Stacke's operation. Immediate cessation of the functional troubles.

Cure by April 1st, 1893.

CASE LIX.—*Suppuration of the Attic. Stacke's Operation. Recovery.*

L. T. ; 7 years old.

*History.*—Admitted to the hospital September 16th, 1893. Abundant and fœtid otorrhœa, dating back ten months, coming from attic.

*September 20th.*—Stacke's operation (carious incus, healthy malleus). Aditus normal. Complete suture of the incision behind the ear. Plugging through the meatus.

*September 27th.*—Removal of stitches. Primary union. No pus in the meatus.

*October 12th.*—No further dressing.

*October 17th.*—Patient discharged, cured.

CASE LX.—*Suppurative Otitis Media. Caries of the inner wall of the Tympanum. Facial Paralysis. Stacke's Operation. Death from Meningitis.*<sup>1</sup>

Man ; 40 years old.

*History.*—Treated at the clinique from June 3rd, 1893, for pain in the ear, accompanied by otorrhœa. Repeated and unsuccessful removal of polypi springing from the upper part of the tympanum. Enlargement of the perforation. Extraction of the malleus.

*July 18th.*—Facial paralysis.

*July 21st.*—Stacke's operation, following which the

<sup>1</sup> Case published *in extenso* by Dr. Lubet-Barbon, *Arch. intern. de lar.*, vol. ii., No. 5, p. 257 : Paris, 1893.

temperature rose (from  $102.2^{\circ}$  to  $104^{\circ}$  Fahr.). Symptoms of meningitis.

Death on July 26th.

*At the Autopsy.*—Suppurative meningitis.

CASE LXI.—*Suppuration of the Attic. Latent Mastoiditis.*

M. G. ; 15 years old. (For the left ear, see Case LXII.)

*History.*—On April 21st, 1894, Stacke's operation, in the course of which the aditus appeared healthy. Following on this, pains in the mastoid, which was laid open July 1st, 1894.

*February 1st, 1895.*—Cavity suppurating but very little, and only now and then: opens behind the ear through a cicatrised orifice above the incision.

CASE LXII.—*Suppuration of the Attic. Stacke's Operation, followed by opening up the Mastoid. Recovery.*

*History.*—Q., 7 years old, came to the clinique on March 14th, 1893, for a discharge from the left ear which had lasted nearly five years. The discharge was very abundant; the meatus full of whitish, badly smelling pus. After irrigating it, it was noticed that the membrane had totally disappeared. The lower part of the tympanum was covered by granulation tissue. The right ear was healthy. There was nasal catarrh. The granulations were cauterised with silver nitrate (1 in 30) and dressed with carbolic glycerine. After some weeks of this dressing, the discharge had not diminished.

*April 13th.*—Removal of the polypus, situated on the inner wall of the tympanum ; its base was cauterised with silver nitrate.

*May 4th.*—The ear discharged less. A boracic acid dressing was tried.

*May 26th.*—Fleshy granulations were still found ; and the alternate increase and decrease of the discharge, and the constant production of fleshy granulations decided us to do Stacke's operation, and open up the mastoid.

*July 27th, 1893.*—The child was admitted to the hospital, and was operated on the same day. After opening and curetting the tympanic cavity by Stacke's method, the canal of the antrum was found full of granulations, and step by step the mastoid was completely opened up.

The day after the operation incomplete facial paralysis was noticed. This paralysis did not cease after the packing with gauze had been renewed and made less tight ; but it gradually improved. Dressings as usual.

*February 17th, 1894.*—Behind the ear, at the level of the skin incision, is an aperture as large as a shilling, giving access to a huge cavity, the outer two-thirds of which are skinned over. At the bottom is a red surface, bleeding readily, with granulations at the lower part. In front and in the depths, at the level of the tubular orifice, is a small drop of clear and transparent fluid, which reappears when mopped dry.

Complete cure was obtained by July 1894, and the patient left the hospital, August 26th, 1894, with a huge cavity skinned over and freely open behind the ear, which had not supplicated for more than a month.

CASE LXIII.—*Suppuration of the Attic. Latent Mastoiditis.*

R. P. ; 28 months old.

*History.*—Measles three months ago, followed by bronchitis ; and otitis media, with a persistent discharge.

Pus coming from the attic, on July 1st, 1893, Stacke's operation done. The granulations were followed step by step into the aditus, then into the tympanum.

*At the present time* (the end of September 1894) there is a cavity, suppurating but very little : opens behind the ear, but it has not entirely skinned over in the deepest part. Child puny : cured of a cold abscess of the left radius, operated on February 15th, 1893 ; still under treatment for a cold abscess of the right olecranon, operated on August 21st, 1893.

CASE LXIV.—*Suppuration of the Attic. Latent Mastoiditis.*<sup>1</sup>

Boy ; 3 years old.

*History.*—Otorrhœa for eighteen months. Suppuration of the attic, which has resisted the classical methods of treatment from April 2nd, 1892, to January 6th, 1893. Fever ; rigors.

*January 6th, 1893.*—Stacke's operation, completed by opening up the mastoid—the aditus and the antrum being found full of granulations. Facial paralysis, due to packing (gauze), for it ceased the day after the first dressing—made on the eighth day.

Recovery, with cavity skinned over, and opening behind the ear.

<sup>1</sup> Case IX. of Weismann's Thesis.

CASE LXV.—*Latent Cholesteatoma of the Mastoid, with suppuration of the Attic. Persistent Fistula.*<sup>1</sup>

Girl ; 15 years old.

*History.*—Otorrhœa at five years of age, which appeared to have been cured, and reappeared three or four months ago. Classical treatment at the clinique from August 30th to the month of November, 1892, failed.

*November 12th.*—Stacke's operation, completed by opening up the mastoid.

Since this time, in spite of variety of treatments, cauterisations, and scrapings, it has not yet been possible to attain definite cicatrisation of the cavity ; but to-day the suppuration is slight and limited, and cholesteatomatous masses are no longer found (February 1895).

CASE LXVI.—*Suppuration of the Attic. Stacke's Operation, completed by opening up the Mastoid. Death from a Cerebral Abscess antecedent to the operation.*<sup>2</sup>

*History.*—A woman, aged 50 years, was seized with pains and otorrhœa in December 1892, after twenty years of apparent cure. Pains in the head ; insomnia ; attacks of vomiting. Stacke's operation at first declined by the patient, was accepted four days afterwards, the symptoms (drowsiness, vomiting) being aggravated.

*January 4th, 1893.*—Stacke's operation, completed by opening up the antrum : filled partly with granulations, partly thick pus.

For eight days marked improvement ; then return of cerebral symptoms.

<sup>1</sup> Case XII. of Weismann's Thesis.

<sup>2</sup> Case XI. of Weismann's Thesis.



*January 13th.*—Death.

No autopsy, but the diagnosis of abscess is almost certain.

CASE LXVII.—*Suppuration of the Attic. Stacke's Operation, completed by opening up the diseased Mastoid. Under treatment.*

C. C. ; 4 years old.

*History.*—At one year old, mastoid abscess on the right side, operated on February 1892; then on the left side, March 1892. Persistent otorrhœa. On the right, purulent discharge from the attic. The probe meets with a bare spot.

*October 24th, 1894.*—Stacke's operation (incus carious), completed by opening up the mastoid and following up the granulations.

*February 1st, 1895.*—No longer any suppuration. Some scales in a cavity almost entirely skinned over. Opening behind the ear.

## CHAPTER IV.

### RESULTS.

IN this chapter, which will be statistical, we propose to analyse the results of the different operations which we have just studied. We shall commence by publishing a summary of the cases which we considered useless to report *in extenso* in the course of this memoir.

#### (A) ACUTE INFLAMMATIONS OF THE MASTOID, WITH ACUTE OTITIS MEDIA.

##### CASE LXVIII.—*Mastoid Abscess.*

E. L. ; 2½ months old.

Onset, from no known cause, one month ago. No otorrhœa.

*March 27th*, 1894.—Abscess incised (pneumococcus) and mastoid opened.

*May 1st.*—Cured.

*August 25th.*—Small fistula opened.

Closed by September 1st.

##### CASE. LXIX.—*Mastoid Abscess.*

H. D. ; 5 months old.

At three months old, diarrhœa, green stools, vomiting ;

checked only a few days ago. Six days ago, an abscess behind the ear.

*February 21st, 1894.*—Mastoid opened.

Cured at the end of March. General condition excellent.

CASE LXX.—*Mastoid Abscess.*

E. R. ; 7 months old.

Twenty-five days ago had influenza ; eight days ago, swelling behind the ear, without otorrhœa.

*May 19th, 1893.*—Mastoid opened up (pneumococci and streptococci associated).

*July 15th.*—Cured.

CASE LXXI.—*Mastoid Abscess.*

J. D. ; 7 months old.

Otorrhœa from no known cause for six weeks ; ceased three weeks ago, and onset of swelling behind the ear.

*May 4th, 1894.*—Abscess incised and antrum opened.

*June 15th.*—Cured.

CASE LXXII.—*Mastoid Abscess.*

L. G. ; 8 months old.

Ten days ago, as the result of a blow (?), swelling in the mastoid region, without otorrhœa.

*May 8th, 1894.*—Mastoid opened.

*July 28th.*—Cured.

CASE LXXIII.—*Mastoid Abscess.*

D. D. ; 9 months old.

Coryza for two months ; swelling behind the ear, without otorrhœa, for three months.

*January 24th.*—Abscess cut into (pneumococcus) and antrum opened up.

*April 17th.*—Cured.

CASE LXXIV.—*Mastoid Abscess.*

L. R. ; 11 months old.

Operated on May 15th, 1893, for an abscess behind the ear. Mastoid opened up.

Rapid recovery, which had remained good on October 2nd, and also on January 10th, 1894. (Mother suffers from lupus of the face.)

CASE LXXV.—*Mastoid Abscess.*

E. F. ; 11 months old.

Otorrhœa for several days, then mastoid abscess.

On the tenth day (May 2nd, 1893), abscess incised (pneumococcus) and mastoid opened up.

*July 1st.*—Cured.

CASE LXXVI.—*Mastoid Abscess.*

R. P. ; one year old.

Onset on January 8th, 1894 ; three days later, abscess behind the ear, with no otorrhœa. Cause unknown.

*January 16th.*—Abscess incised (staphylococcus) and antrum opened up.

*March 6th.*—Cured.

*May 7th.*—Seen again, cured.

CASE LXXVII.—*Mastoid Abscess.*

J.-B. C. ; 16 months old.

Onset three weeks ago, without otorrhœa.

*July 1st, 1893.*—Abscess incised (pneumococcus) and mastoid opened up.

*August 29th.*—Cured.

*November 18th.*—Seen again, in perfect health.

CASE LXXVIII.—*Mastoid Abscess.*

F. V. ; 2 years old.

One month ago had a sore throat, probably diphtheria ; for fifteen days, a swelling behind the ear.

*April 12th, 1893.*—Abscess incised (strepto- and pneumococci) and mastoid laid open.

*May 25th.*—Cured.

CASE LXXIX.—*Mastoid Abscess.*

G. K. ; 2½ years old.

Three weeks ago had measles, with rather severe sore throat ; ten days ago, slight otorrhœa ; eight days ago, mastoid abscess.

*July 8th, 1894.*—Abscess incised (staphylococcus albus) and mastoid opened up—one stroke of the gouge entering the brain.

*August 23rd.*—Cured.

CASE LXXX.—*Mastoid Abscess.*

A. B. ; 2½ years old.

A huge acute abscess behind the ear, without otorrhœa.

*November 15th, 1894.*—The mastoid laid bare ; scraped out with curette.

*January 6th, 1895.*—Cured.

CASE LXXXI.—*Mastoid Abscess.*

G. H. ; 2½ years old.

Came to the hospital for a mastoid abscess, which commenced fifteen days ago, following six weeks after an otitis media, due to influenza.

Antrum opened up.

Recovery, with membrana tympani and hearing normal.

CASE LXXXII.—*Mastoiditis, without Abscess.*

G. R. ; 4 years old.

Had had measles when two years old, whooping cough when three and a half years. Bronchitis slight for a month. The last five or six days without otorrhœa. Slight œdema. Fever. Pain and redness over the mastoid region.

*March 24th*, 1894.—Mastoid opened up ; contained pus.

*May 16th*.—Cured.

In October patient was very well.

CASE LXXXIII.—*Mastoiditis, without Abscess.*

A. M. ; 4½ years old.

Two years ago, measles ; six weeks ago, bronchitis, then scarlatina ; fifteen days ago, adenitis, albuminuria ; ten days ago, swelling behind the ear, no otorrhœa.

*July 31st*.—Mastoid opened up. Granulations in the antrum.

*October 2nd*.—Cured. Membrana tympani sound.

CASE LXXXIV.—*Mastoid Abscess.*

E. R. ; 5 years old.

Came to the hospital on the twenty-eighth day of an attack of otitis media following scarlatina. For last two days the otorrhœa has ceased. Abscess behind the ear.

Antrum opened up.

Cure in six weeks.

CASE LXXXV.—*Mastoid Abscess.*

L. B. ; 5½ years old.

Mastoid abscess from no known cause, and with no otorrhœa, at the end of February 1893.

*March 4th.*—Abscess incised (pus sterile) and mastoid opened up.

About May 15th, cured.

*December 27th, 1894.*—Local and general condition excellent.

CASE LXXXVI.—*Mastoid Abscess.*

J. R. ; 7 years old.

Measles a year ago. Eight days ago, swelling behind the ear, but no otorrhœa.

*March 28th, 1894.*—Abscess incised (pneumococcus) and mastoid opened. A little pus from the meatus during the operation.

*August 4th.*—Cured.

CASE LXXXVII.—*Mastoid Abscess.*

B. V. ; 7½ years old.

In April 1894, scarlatina. Otorrhœa, both sides, from

this time ; eight days ago it stopped, and a mastoid abscess appeared on the right side.

*June 20th.*—Abscess incised (no organisms found) and mastoid opened.

*August 28th.*—Cured.

CASE LXXXVIII.—*Mastoid Abscess of right side.*

C. M. ; 7 years old.

For the last eight days, mastoid abscess, with no otorrhœa and from no known cause.

*July 21st, 1893.*—Mastoid opened up.

*September 15th.*—Cured.

*January 5th, 1894.*—Seen again, in good health.

CASE LXXXIX.—*Mastoid Abscess of left side.*

E. H. ; 10 years old,

Measles three years ago ; modified small-pox two years ago.

*August 18th, 1893.*—Scarlatina. On the fifteenth day otitis media ; then otorrhœa, which ceased at the time a mastoid abscess formed.

*October 17th.*—Admitted to the hospital.

*October 18th.*—Mastoid opened up.

*November 26th.*—Cure, with membrana tympani reformed, and good hearing.

CASE XC.—*Mastoiditis, without Abscess.*

J. P. ; 10 years old.

*May 13th, 1894.*—Acute tonsillitis both sides, which lasted eight days. Tardy convalescence.

*June 7th.*—Pains in the right ear.



*June 10th.*—Fever. Puffiness of the region behind the ear. Deafness.

*June 12th.*—Œdema over the mastoid, tenderness on pressure, no otorrhœa. Mastoid opened up, found to contain pus.

*July 28th.*—Cured. Hearing normal.

In October, quite well.

CASE XCI.—*Mastoid Abscess.*

A. C. ; 15 months old.

Mother tuberculous. Mastoid abscess for fifteen days. Otorrhœa fifteen days.

*January 17th, 1895.*—Mastoid opened up.

*February 1st.*—Cavity everywhere granulating healthily.

CASE XCII.—*Mastoid Abscess.*

G. L. ; 7 years old.

*November 27th, 1894.*—Scarlatina. Pains in the ears since the onset. Otorrhœa since the commencement of convalescence.

*January 10th, 1895.*—Discharge ceased ; pains ; swelling in mastoid area ; general condition bad ; then return of the otorrhœa.

*January 15th.*—Incision ; huge perforation at the tip of the mastoid. Lateral sinus bare in the abscess. The friable bone scraped out.

CASE XCIII.—*Mastoid Abscess of left side.*

L. L. ; 8 months old.

Fifteen days ago, bronchitis and swelling behind the ear, without otorrhœa.

*June 3rd, 1893.*—Abscess incised and mastoid opened up.

*July 10th.*—The mastoid being almost cured, during the excessively hot weather infantile diarrhoea set in; child bottle-fed.

*July 18th.*—Death.

CASE XCIV.—*Mastoid Abscess.*

M. D. ; 17 months old.

*March 17th, 1893.*—Measles.

At the commencement of April, whooping-cough.

*April 15th.*—Abscess behind the ear.

*April 21st.*—Abscess incised (streptococcus, staphylococcus, and pneumococcus) and mastoid opened up. Whooping-cough very severe; paroxysms of violent coughing very frequent.

*April 28th.*—Broncho-pneumonia.

*April 29th.*—Death.

(B) CASES OF ACUTE DIFFUSE OSTEITIS OF THE  
TEMPORAL BONE.<sup>1</sup>

CASE XCV.—*Diffuse Osteitis of the Temporal Bone.*

R. P. ; 7 months old.

Father and mother tuberculous. Otorrhœa since two months old.

*November 23rd, 1894.*—Admitted to the hospital. Abscess behind the ear. The carious bone scraped

<sup>1</sup> These cases, which we summarise here to complete our statistics, will be published later on by one of us. See A. Broca, "Ostéite diffuse du temporal," *Bull de la soc. anat.*: Paris, 1895.

out as far as the tympanum. The general condition, deplorable before the operation, remains the same.

*November 29th.*—Death.

*At the Autopsy.*—Diffuse osteitis. No meningitis.

CASE XCVI.—*Gangrenous Mastoid Abscess.*

E. D. ; 9 months old.

Measles and bronchitis at the age of five and a half months. Since this time, painful symptoms as regards the ear ; then swelling behind the latter. Some days ago a medical man incised the abscess. Black, friable, necrosed bone, with foul smell ; scraped out with the curette. Dura mater and lateral sinus exposed.

Death on the third day.

No autopsy.

CASE XCVII.—*Diffuse Osteitis.*

E. S. ; 21 months old.

Ten months ago, severe diarrhœa, lasting three weeks ; two and a half months ago, measles ; ten days ago, with no otorrhœa, a mastoid abscess.

*September 3rd, 1894.*—Abscess incised (pneumococcus) and mastoid opened up. Discharge of pus through the meatus during the irrigation of the wound behind the ear. Subsequently, the general condition was bad, wound flabby, bone necrosed.

*October 20th.*—A fresh operation: destruction of the cavity ; exploration of the meninges, but no abscess discovered. Tympanum carious for some distance.

*October 24th.*—Death.

CASE XCVIII.—*Acute Osteitis.*

E. G. ; 6 years old.

Measles and whooping-cough at three years of age ; then white swellings of the right knee and arch of the left foot : at the present time these are fistulous.

*July 17th.*—Admitted to the hospital with symptoms of acute mastoiditis, dating from eight days ago.

*July 18th.*—Mastoid opened up (streptococci, various micrococci, bacilli of putrefaction) ; persistence of infective symptoms.

*July 29th.*—Removal of all dead bone.

*August 1st.*—Death.

*At the Autopsy.*—No intracranial lesions.

CASE XCIX.—*Acute Osteitis.*

Woman ; 44 years of age.

Old otorrhœa. For four days, diffuse swelling in the temporo-mastoid region.

*August 31st, 1894.*—This area completely opened up. Persistence of symptoms of infection and meningitis.

## (C) CASES OF MASTOIDITIS, WITH CHRONIC OTITIS MEDIA (CASES COMPLETED).

CASE C.—*Mastoid Fistula.*

A. J. ; 21 months old.

Commenced four months ago. Simple incision, which remained fistulous. No otorrhœa.

*July 15th, 1893.*—Mastoid and tympanum opened up.

Cure relatively rapid, and was maintained in January 1894.

CASE CI.—*Mastoid Fistula.*

C. G. ; 2 years old.

When three months old, bronchitis ; when eight months, measles ; when fifteen months, whooping-cough. Six weeks ago, without any otorrhœa, a mastoid abscess, which was incised one month ago.

*April 12th.*—Mastoid opened up (pneumococcus).

*August 14th.*—Cured.

*September 4th.*—Membrana tympani and external auditory meatus normal.

CASE CII.—*Mastoid Fistula.*

G. A. ; 2 years old.

Eleven months ago, measles ; eight days afterwards, an abscess behind the ear became, spontaneously, a fistula.

*January 16th, 1894.*—Mastoid opened up (sequestrum) and also the tympanum (incus carious, malleus healthy.)

*July 1st.*—Cured, and cavity filled up.

CASE CIII.—*Mastoid Fistula.*

H. C. ; 2½ years old.

Ten months ago, mastoid abscess ; then transient otorrhœa. Simple incision of the abscess ; fistula.

*May 28th, 1893.*—Mastoid and tympanum opened up.

*November 26th, 1893.*—Extraction of a sequestrum in the lower part of the squamous.

*November 1894.*—Cured.

CASE CIV.—*Mastoid Fistula.*

L. M. ; 4 years old.

Measles five to six months ago, following which, mastoid abscess, without otorrhœa. Simple incision.

*June 26th, 1893.*—Admitted to the hospital with a fistula behind the ear.

*July 13th.*—Mastoid and tympanum opened up.

*August 20th, 1893.*—Left the hospital.

*January 1894.*—Returned, entirely cured. Hearing good.

CASE CV.—*Mastoid Fistula.*

H. R. ; 3 years old.

*January 3rd, 1893.*—From no known cause, mastoid abscess ; treated by simple incision ; persistent fistula.

*October 18th.*—Mastoid and tympanum opened up.

*March 6th, 1894.*—Entirely cured.

*December 1894.*—Seen again, in excellent condition.

CASE CVI.—*Mastoid Fistula.*

A. V. ; 4½ years old.

Slight whooping-cough at the end of 1891 ; in January 1892, otorrhœa for some days ; in June 1892, mastoid abscess, treated by simple incision, persistent fistula.

*December 10th, 1892.*—Mastoid and tympanum opened up.

*February 25th.*—Cicatrization.

In June 1893 a small fistula reopened : some granulations scraped ; rapid cicatrization. Six months later, another little fistula, not communicating with the tympanum, which did not suppurate, but led down to a spot of bone laid bare. The mother refused a further operation.

CASE CVII.—*Mastoid Abscess, with Chronic Otitis Media.*<sup>1</sup>

E. P. ; 12 years old.

Admitted, on December 10th, 1892, to the hospital. Old otitis media, following measles ; swelling behind the ear for one month. Polypi of the tympanum. The bent probe met with bare places in the attic.

*December 11th.*—Mastoid and tympanum laid open.

*April 6th.*—Cured. The pus of the abscess contained the bacterium coli in a state of purity.

CASE CVIII.—*Mastoid Fistula.*

J. D. ; 23 years old.

Otorrhœa, from no known cause, since the age of twelve years ; mastoid abscess, following the treatment of a polypus with the galvano-cautery, operated on in August 1892, and remaining fistulous.

*April 20th, 1890.*—Mastoid and tympanum laid open.

*October.*—Cured, with persistence of a little otorrhœa.

CASE CIX.—*Mastoid Fistula.*

L. P. ; 7 years old.

Measles and whooping-cough two years ago. Otorrhœa for five months ; mastoid abscess for one month, incised fifteen days ago.

*June 3rd, 1893.*—Mastoid and tympanum laid open.

*September 21st.*—Cicatrisation complete ; persistent slight otorrhœa, which still continued in January 1894, and was not attended to.

<sup>1</sup> Case X. of Weismann's Thesis.

CASE CX.—*Mastoid Abscess.*

E. S. ; 7 years old.

Old otorrhœa (two years), following on measles. Abscess behind the ear (September 2nd, 1892), treated by simple incision.

*September 21st.*—Mastoid laid open.

*November 20th.*—Left the hospital.

*January 1894.*—Seen again : otorrhœa always profuse ; cicatrised behind the ear.

*July 1894.*—Still a little otorrhœa (attended to very irregularly).

CASE CXI.—*Mastoid Fistula.*

A. M. ; 8 years old.

Measles since scarlatina in May 1892 ; mastoid abscess then, treated by simple incision.

*December 10th, 1892.*—Mastoid and tympanum laid open.

*January 15th.*—Left the hospital incompletely cured, then irregularly dressed. Cicatrised behind the ear in about two months. The cicatrisation maintained in January 1894 ; but there remained a very slight otorrhœa, which was not attended to.

CASE CXII.—*Left Mastoid Fistula.*

A. P. ; 19 months old.

*June 1893.*—Onset of otorrhœa, following on infantile cholera.

*July.*—Simple incision of a mastoid abscess.

*December 2nd.*—Extraction of a sequestrum from the mastoid ; removal of carious incus and sound malleus.



In March 1894, cavity behind the ear cicatrised, but there remained a little otorrhœa.

*May 23rd.*—Onset of cerebral symptoms.

The child was brought back on May 30th to the hospital.

*June 2nd.*—Death.

No autopsy.

CASE CXIII.—*Right Mastoid Abscess.*

E. B. ; 8 months old.

Father and mother phthisical. Old otorrhœa. One month ago, commencement of a swelling behind the ear.

*May 31st, 1893.*—Mastoid and tympanum laid open. Gradual cachexia.

*June 26th.*—Death.

*At the Autopsy.*—Generalised tuberculosis.

CASE CXIV.—*Mastoid Abscess.*

L. ; 9 months old.

*History.*—Father tuberculous. Three months ago, suppurative otitis media. Discharge fœtid for one month. For the last ten days a fluctuating tumour, without redness or œdema behind the auricle, towards the tip of the mastoid. General condition, cachectic.

*December 8th. Operation.*—The incision gave exit to rather a large quantity of pus. The finger, introduced into the bottom of the wound, enabled one to feel on the bone a rough surface, but a probe passed to this place was unable to penetrate into any cavity in the bone. Over the bared spot the cortical layer of bone was removed with the chisel: through the opening

caseous pus escaped. The cavity was enlarged below and in front with the curette, and a fairly large quantity of the same pus, with fleshy granulations and bony *débris*, withdrawn. A cavity was thus cleaned out, apparently formed at the expense of the mastoid and squamous portions of the temporal. This, as it were, preformed cavity was the size of a large hazel-nut, was full of caseous pus, and its smooth walls were of whitish aspect. Chloride of zinc rubbed in till whitened. Dressed with sterilised gauze.

Three days later the child had not had fever. It was suckled, and took its nourishment as before the operation.

Death from cachexia on the tenth day.

CASE CXV.—*Right Mastoid Fistula.*

L. V. ; 11 months old.

Old otorrhœa. Fistula.

*March 4th*, 1893.—Mastoid and tympanum laid open ; bone friable and granulating.

*March 19th*.—Death.

*At the Autopsy*.—Tuberculosis of the meninges, lung, and tracheo-bronchial and mesenteric glands.

CASE CXVI.—*Mastoid Abscess.*

A. L. ; 14 months old.

Sickly and feeble from the age of eight months, when it had an attack of gastro-enteritis ; relapses in December and January. Diarrhœa since February 27th. Aphthous ulcers in the mouth. Three weeks ago, onset of swelling behind the ear.

*March 10th.*—Mastoid laid open (multiple small sequestra), and the tympanum was reached.

From April 3rd the child has been in good condition, and its ulcers have disappeared.

*June 18th.*—Locally, after going on very well, it had an attack of measles (at home); and died of broncho-pneumonia on June 22nd.

CASE CXVII.—*Mastoid Fistula.*

E. G.; 2 years old.

A month ago, otorrhœa; eight days after it ceased, a mastoid abscess appeared. Simple incision.

*April 1st, 1893.*—Mastoid laid open.

The child, being in a fair way of recovery, had an attack of measles on June 28th, and died of broncho-pneumonia on July 6th.

CASE CXVIII.—*Mastoid Fistula.*

P. B.; 3½ years old.

Whooping-cough when eighteen months of age; measles at twenty-seven months, and, since then, multiple cold abscesses. Otorrhœa on the right side for the last four months; for eight days, pains on this side.

*February 10th.*—Removal of a polypus from the tympanum.

*February 15th.*—An abscess behind the ear incised, and the mastoid laid open. A huge cavity, containing a large sequestrum and extending spontaneously into the tympanum, was scraped. The following day there was a slight facial paralysis, which rapidly disappeared.

*September 8th, 1894.*—Cavity behind the ear, which suppurates very little and is in great part skinned over. The child has multiple semi-fluctuating cold abscesses, several of which are still under treatment. Little by little, tuberculous cachexia.

*January 1895.*—Death, the ear wound being in good condition.

(D) INFLAMMATIONS OF THE MASTOID, WITH CHRONIC OTITIS MEDIA. PATIENTS STILL UNDER TREATMENT.

We shall first give *in extenso* a third case of the mastoid becoming fistulous in the meatus through the frontier cells (see Cases X., XXXII.).

CASE CXIX.—*Mastoid Fistula opening into the Meatus.*

*History.*—P., 13 years old, had already come to the clinique in April 1892 for discharge from the right ear, and presented at this time a polypus situated at the postero-superior portion of the tympanic outline. The ear was cured by removal of the polypus and scraping the point of implantation (*i.e.*, pedicle). The cure was maintained until September 1894, when the right ear began to discharge afresh.

P. came to the clinique on September 29th, 1894, with a large polypus, which was removed. The base appeared to be attached outside the membrana tympani, upon the posterior wall of the meatus; the bone was bared over a small area, and within this space fleshy granulations were observed and cauterised with chromic acid. The membrana tympani was

perforated in the postero-inferior segment; no pus appeared to escape from the tympanum. On introducing a bent probe into the spot where bare bone was felt, a fistula was found, directed from below up, and from before back, which led into the mastoid. We considered that there had formerly been mastoiditis in an eburnated mastoid; the pus not having been able to open a passage to the exterior through the outer surface of the mastoid, had escaped externally through the meatus by perforating the air-cell, which we have designated "border cells."

(The indication for operation is very clear; and we have here a case, not so old, but similar to that of our Case XXXII.)

*January 5th, 1895. Operation.*—Incision—auricle detached—meatus cut through in front and behind. Mastoid laid open at the seat of election below the temporal line, which did not prevent the dura mater being found. We returned then from the side of the fistula in the meatus, into which the protector was introduced, the external wall of this, hard and sclerosed, being removed. A cavity in the form of a corridor was thus laid bare, which was directed from before back, and then above in the direction of the antrum, and which contained thick pus and granulations. Below and behind, the mastoid is, naturally, eburnated; the external wall of the aditus was destroyed, with the external wall of the tympanum; the healthy ossicles were removed; the meatus was incised longitudinally; the posterior incision was stitched from above down, and the dressing made through the meatus.

Five days later, union was almost complete posteriorly. No pus. Dressed through the meatus.

CASE CXX.—*Mastoid Abscess.*

G. L. ; 5 years old.

Between the ages of fourteen months and three years has had successively measles, scarlatina, and varicella. Otorrhœa, starting when two years old, followed these eruptive fevers. Four months ago, mastoid abscess ; incised ; rapid cicatrisation.

*November 18th, 1893.*—Fresh abscess.

*November 23rd.*—Mastoid and tympanum laid open (incus carious, malleus healthy).

At the present moment there is a cavity, hardly suppurating at all.

CASE CXXI.—*Mastoid Abscess.*

M. D. ; 4 years old.

A year ago, measles, followed by otorrhœa two and a half months ago ; swelling behind the ear. One and a half months ago, abscess opened up ; cicatrised in eight days. Eight days ago, a fresh abscess.

*April 25th, 1894.*—Mastoid and tympanum laid open ; lateral sinus laid bare.

Next day, facial paralysis.

*February 1st, 1895.*—Continuous suppuration, though very slight. The facial paralysis has almost disappeared.

CASE CXXII.—*Mastoid Abscess.*

C. B. ; 5½ years.

Suppurative otitis media, of three years' duration, apparently cured. Ten days ago, acute attack—abscess behind the ear.

*April 3rd, 1894.*—Abscess opened (streptococcus). Mastoid and tympanum laid open. Followed by facial paralysis.

*Feb. 1st, 1895.*—Facial paralysis has almost disappeared.

CASE CXXIII.—*Mastoid Abscess.*

A. S. ; 17 months old.

Otorrhœa for five months ; swelling behind the ear for one month.

*Sept. 13th, 1894.*—Mastoid and tympanum laid open.

*February 1st, 1895.*—Practically no pus.

CASE CXXIV.—*Mastoid Fistula.*

G. A. ; 6½ years old.

For six months, otitis media and abscess, which remained fistulous after incision.

*Nov. 11th, 1894.*—Mastoid and tympanum laid open.

*February 15th, 1895.*—No longer suppurates. Cavity, opens behind the ear by an orifice lined with skin.

CASE CXXV.—*Mastoid Fistula.*

G. S. ; 5 years old.

Left otorrhœa, almost since birth. Mastoid abscess operated on two years ago, cured in two months, relapse four months later.

*Nov. 11th, 1894.*—Mastoid and tympanum laid open.

*February 1st.*—Hardly any suppuration.

CASE CXXVI.—*Mastoid Abscess.*

M. W. ; 4 years old.

Otorrhœa for two years ; mastoid abscess for ten days.

*Nov. 22nd, 1894.*—Mastoid and tympanum laid open.

*February 1st.*—Doing very well.

CASE CXXVII.—*Mastoid Abscess.*

M. B. ; 5 years old.

Otorrhœa for two and a half years ; abscess for four days.

*Nov. 30th, 1894.*—Mastoid and tympanum opened up.

*February 1st.*—Doing very well.

CASE CXXVIII.—*Mastoid Fistula.*

*History.*—A girl, aged  $2\frac{1}{2}$  years, had already been brought to the hospital for an imperforate meatus.

In July 1894, after sore-throat, the child had, without any discharge from the meatus, an abscess behind the ear, with fever and delirium.

*August 3rd.*—The abscess was opened, and led down to the mastoid, bare and spontaneously laid open below and in front. The perforation led into a cavity full of pus and fleshy granulations. There followed a narrow, but deep, fistula, which we decided to operate on, on October 23rd.

*Operation.*—The cavity already existing was enlarged in all directions, especially above and in front. The tympanic portion of the meatus was removed, with the incus and malleus, surrounded by granulations and thick pus. The whole cavity, antrum and tympanum, was scraped. Flaps were not made at the expense of the meatus, because the meatus, naturally obliterated, did not exist. Plugged with iodoform gauze, after cauterising with chloride of zinc.

*February 1st.*—The wound is in good condition, but the cavity is not allowed to close up because of a small point of bared bone which is in the depths.



CASE. CXXIX.—*Mastoid Abscess.*

J. D. ; 6 months old.

Otorrhœa, on both sides, for three months; foetid subacute mastoid abscess since January 1st. Slight facial paralysis.

*January 13th, 1895.*—Mastoid and tympanum laid open (sequestrum).

In conclusion, we shall make a general statement with regard, successively, to

(A) The general conclusions from our statistics,

(B) The results following the disease treated.

A. GENERAL STATISTICS.

If we consider our statistics as a whole, we obtain the following figures: 143 operations on 128 patients, for 133 mastoids.<sup>1</sup>

Twenty-one patients died; but almost every one of these fatalities were altogether independent of the operation. They divide themselves, in fact, into the following categories:—

1. Four patients died from intercurrent maladies: infantile cholera, 1; the broncho-pneumonia of measles, 2; or from whooping-cough, 1.

2. Four died from a chronic tuberculosis, which preceded the operation (Cases CXIII., CXIV., CV.,

<sup>1</sup> Cases XXVIII. and LXI. refer to the two mastoids of the same patient. All the other cases where affection was bilateral (Cases XXIV., XLIX., L., LI.) are counted as single ones. Nine patients were operated on twice on the same side; two in acute cases (Cases X., XXIX.); eight in chronic cases (Cases II., XVI., XXXVI., XLII., LIV., XCVII., XCVIII., LXI.); one was operated on three times (Case LII.).

CXVIII.). In none of these patients did the operation appear to us to have aggravated the tuberculosis.

(It is to be remarked that six others of our cases operated on were said to be tuberculous.)

3. Five have succumbed to meningo-encephalic complications preceding the operation.

4. Five have succumbed to the diffuse inflammations of the temporal bone, with septic symptoms which the operation could not check.

5. One succumbed to the late cerebral complications.

6. Two were finally carried off by a septic meningitis following the operation (extraction of a huge sequestrum ; Stacke's operation).

To appreciate in its entirety the gravity of the operations we have just described, it is undoubtedly necessary to deduct patients from the first five categories. We have then, as the total, two post-operative deaths out of 143 operations ; both were due to meningitis, which is not surprising, since we operated on a spot already septic and very near the meninges.

#### B. RESULTS ACCORDING TO THE NATURE OF THE LESION.

We shall divide this subject into four paragraphs :

1. Mastoid complications of acute inflammation of the middle ear, with or without abscess externally.

2. Mastoid complications of chronic inflammations of the middle ear (acute or chronic abscess, fistulæ forms of latent mastoiditis).

3. Forms of diffuse osteitis of the temporal.

4. Eburnation of the mastoid.

### 1. *Mastoid Complication of Acute Otitis Media.*

We have operated in forty-nine cases of this kind upon forty-eight patients, one of them having an abscess in each mastoid (Case XXIV.). We include in this category the patient in Case CI., with quite recent fistula and acute otitis, so that laying open the mastoid alone sufficed.

Our results are :

<i>Laying open the mastoid alone</i>	. 44 cases.
Recoveries . . . . .	38 „
Relapses . . . . .	2 „
Under treatment . . . . .	2 „
Deaths unconnected with the operation . . . . .	2 „
Deaths from the operation . . . . .	0 „

The two patients under treatment were operated on only six weeks ago, and have almost recovered.

The two fatal cases succumbed to an intercurrent malady (infantile cholera, and whooping-cough, with broncho-pneumonia).

One of the patients cured was obliged to be operated on twice (Case XXXIX.).

The relapses occurred :

(1) In a patient on whom we insufficiently operated (Case X. ; mastoiditis of the frontier air-cells).

(2) In a patient not attended to regularly (Case III.).

The patients cured have no otorrhœa, and their hearing is perfect.

<i>Mastoid and tympanum laid open</i>	. 5 cases.
Recoveries . . . . .	5 „

Two of the patients cured, it is true, still have a little otorrhœa.

In two of these cases we believe that to-day we should confine ourselves to simply laying them open; in three others, the complete laying open was indicated from the intensity of the general symptoms or the local disorders (Cases XXV., XXVI.).

## 2. *Mastoid Complications of Chronic Otitis Media.*

We operated on sixty-seven patients for these conditions, four having bilateral affections—or seventy-one mastoids.

One of the patients was obliged to undergo simple laying open of the mastoid, then the tympanum was also opened up (seventy-two operations). In two, we were obliged to do a secondary scraping out.

<i>Simple laying open of the mastoid</i>	. 5 cases.
Perfect recovery . . . . .	I case.
Cicatrization, with persistent otorrhœa	I „
Relapse . . . . .	I „
Fistula lasting six months . . . . .	I „
Death from an intercurrent malady . . . . .	I „

The death occurred in the third month from broncho-pneumonia following measles. The results of this operation, as one sees, are only moderately good, since there is only a single perfect recovery. The patient who recovered, with otorrhœa, was operated on three times.

We think that for cases of this kind the laying open of mastoid and tympanum should always be done.

<i>Mastoid and tympanum laid open</i>	. 67 cases.
Perfect recovery . . . . .	. 26 „
Recovery, with slight otorrhœa . . . . .	. 9 „
Result unknown, but certainly recovered from the operation . . . . .	. 1 case.
A small fistula no longer communicating with the tympanum . . . . .	. 2 cases.
Death, with cerebral symptoms previous to the operation . . . . .	. 5 „
Death, with cerebral symptoms consecutive to the operation . . . . .	. 1 case.
Death, with late cerebral symptoms . . . . .	. 1 „
„ from tuberculosis . . . . .	. 4 cases.
„ „ intercurrent measles . . . . .	. 1 case.
Patients under treatment . . . . .	. 17 cases.

Amongst the patients cured, seven have a huge cavity skinned over, opening behind the ear.

If we wish to appreciate exactly the curative value of the operation, we must exclude, firstly, the death from the operation; secondly, the deaths from pre-existing meningitis; thirdly, the deaths from chronic tuberculosis or from intercurrent maladies; fourthly, the unknown cases.

In this way, there remain fifty-five cases, which give us:

Recovery perfect . . . . .	. 26 cases.
„ with slight otorrhœa . . . . .	. 9 „
Death, with late cerebral symptoms . . . . .	. 1 case.
Small fistula not communicating with the tympanum . . . . .	. 2 cases.
Under treatment . . . . .	. 17 „

So long as slight otorrhœa persists, we cannot be absolutely satisfied with the result ; for it proves that there probably exists in the bone a point of infection, very limited, without doubt, but always a dangerous thing : and in this way one of our cases operated on (Case CXII.) was carried off at the end of more than four months through cerebral complications.

We will add that, in the majority of patients with persistent otorrhœa, a regular treatment after the operation is not enforced. Their condition is, moreover, considerably improved upon that which existed before the operation.

Among the two patients with small fistula behind the ear, not communicating with the tympanum, but leading down to a bare point of bone, quite limited in extent, there was one on whom, on account of various associated tuberculous manifestations—Pott's disease especially—we did not feel it wise to operate again. In the other, we are convinced that the little girl would have been cured after scraping the diseased bone, but the mother refused to let us do so (Cases XLVIII., CVI.).

The patients under treatment are seventeen in number, eight of whom were operated on less than three months ago. The nine others were operated on more than six months ago ; and for these we might begin to despair, had we not seen absolute cures, after we had almost considered the cases hopeless. In all the improvement is slow, but evident ; and, moreover, there are five in whom the cavity scarcely suppurates at all ; there is another who suffers from cholesteatoma.

We consider we may conclude that (1) the opera-



# I N D E X .

---

*f.n.* = footnote.

- |  |  |
|--|--|
| <p>ABSCCESS of the antrum of Highmore, 57.</p> <p>— of the cerebellum, 45, 210, 211.</p> <p>— cerebral, 14, 166, 167, 210 <i>et seq.</i>, 213 <i>et seq.</i>, 222, 227.</p> <p>— cervical mastoid, 44-47.</p> <p>— cold, of frontal bone, 185.</p> <p>— — of rib, 190.</p> <p>— around lateral sinus, 16.</p> <p>— latero-pharyngeal, 44, 48, 57, 69 <i>f.n.</i></p> <p>— of the mastoid—"a blind internal fistula," 4.</p> <p>— — at the apex of, 40.</p> <p>— — diminished bony conduction in, 52.</p> <p>— — emptying through the meatus, 37, 38.</p> <p>— — frequency in children, 66 and <i>f.n.</i></p> <p>— — gangrenous, 238.</p> <p>— — localised (independent of aditus), 155.</p> <p>— — pathological anatomy and physiology of, 6-25.</p> <p>— — from periostitis, 17.</p> <p>— — "shirt button," 14, 15.</p> <p>— — subcutaneous, 4, 5, 58.</p> | <p>Abscess of the mastoid, subperiosteal, 16, 17.</p> <p>— in maxillo-pharyngeal triangle, 44, 46, 50, 68, 87.</p> <p>— peri-pharyngeal, 92.</p> <p>— retro-auricular, 32, 36, 56-58, 87, 141.</p> <p>— retro-maxillary; <i>see</i> Maxillo-pharyngeal, <i>supra</i>.</p> <p>— retro-pharyngeal, 45, 46.</p> <p>— subdural, 14, 15, 47, 211.</p> <p>Adenitis and lymphangitis, 63, 153.</p> <p>Adeno-phlegmon, 57, 68, 145.</p> <p>Aditus ad antrum, 6, 9, 10, 37, 112, 129, 134, 205.</p> <p>Air-cells of the mastoid, 7, 8, 9, 127.</p> <p>— — at the apex of, 131, 132.</p> <p>— — at birth, 7.</p> <p>— — of the body of, 53, 54.</p> <p>— — "border," 8, 22, 33, 67, 147.</p> <p>— — — abscess of, 35.</p> <p>— — — fistula of, opening through meatus, 147, 209, 247, 248.</p> <p>— — illumination of, 51.</p> <p>— — large, 9.</p> <p>— — in young children, 122.</p> |
|--|--|



- Air-douche, Politzer's method, 112, 113.
- Albuminuria, post-scarlatinal, 185 *et seq.*
- Anatomical indications, mastoid fistulæ, 193.
- Antrum of Highmore, abscess of, 57.
- Antrum, mastoid, 7, 67, 202.
- — — depth of, 129.
- — — opening of, 128.
- — — opening of, through meatus, 115-118.
- — — position of, 7, 119 *et seq.*, 129, 201.
- — — aditus ad, or canal of the, 6, 9, 10, 37, 112, 129, 134, 205.
- — — occlusion of, 11, 12, 34, etc.
- Atresia of the meatus, 139, 140.
- Atrophy of the mastoid, 201.
- Attic, suppuration of, 109 *et seq.*, 204, 217 *et seq.*, 222 *et seq.*
- Auricle, carried forward in mastoiditis, 32, 37, etc.
- Ayres on osteitis of the temporal bone, 72 *f.n.*
- BACILLUS coli communis in mastoid abscess, 2, 242.
- Bacteriology of the middle ear, 2 and *f.n.*, 3; see "Pneumo-," "Strepto-," "Staphylo-coccus," and "Bacillus coli communis."
- Ballance and Shattock on thrombosis of the lateral sinus, 209.
- Baracz, von, on wound of lateral sinus, 117 *f.n.*
- Berger, 213.
- Bezold on cervical mastoid abscess, 45, 69.
- Bezold on opening the mastoid, 115.
- — — on the origin of cholesteatoma, 4.
- Bezold's mastoiditis, so-called, 47 *f.n.*, 69 *f.n.*
- Bilateral attacks of acute mastoiditis, 98.
- — — mastoid fistulæ, 188, 193.
- — — suppurative otitis media, 190.
- Boil of external auditory meatus, 22, 56-59, 62, 63, 71, 145.
- Bony hypertrophy, 146.
- — — landmarks, 126-128.
- — — lesions in mastoid fistulæ, 147.
- Border-cells; see Air-cells.
- Boric acid alcohol, 139.
- Brain, 116, 120, 146, 199.
- Broca, A., on "Cerebral abscess and mastoiditis," 216 *f.n.*
- — — on "Cerebral abscess and meningitis, following middle ear disease," *ibid.*
- — — on "Cerebral abscesses following middle ear disease," 36 *f.n.*, 210.
- — — on "Diffuse osteitis of the temporal," 25 *f.n.*, 237 *f.n.*
- — — on "Intracranial complications of suppurative otitis media," *ibid.*
- — — (with O. Maubrac) on "The treatment of intracranial complications of suppurative otitis media," 35 *f.n.*
- — — on "Thrombosis of the lateral sinus," 209 *f.n.*
- Broca's, A., treatise of "Cerebral Surgery," 36 *f.n.*
- Buck, A. H., on perforating the mastoid, 123.

- CALDWELL on transillumination of the mastoid cells, 51.
- Caries of the mastoid, 197, 198, 202, 203.
- — and meatus, 151.
- of the tympanum, 218.
- Cases—
- I. Mastoid abscesses (chap. i.).
  - II. Mastoid fistulæ (chap. ii.).
  - III. Chronic suppurative inflammations of the middle ear (chap. iii.).
  - IV. Summary—
    - (A) Acute inflammations of the mastoid, with acute otitis media, 229-237.
    - (B) Acute diffuse osteitis of the temporal bone, 237-239.
    - (C) Mastoiditis, with chronic otitis media—cases completed, 239-247.
    - (D) Inflammation of the mastoid, with chronic otitis media—patients still under treatment, 247.
- Cautery, the actual, to be avoided, 113.
- Cavaroz, 122 *f.n.*
- Cells of the mastoid; *see* Air-cells.
- Cerebral abscess; *see* Abscess, cerebral.
- fossa, middle, 14, 117, 125.
- Cervical mastoid abscess, 44-47.
- Cervical vertebræ, Pott's disease of, 69.
- Chaput on resection of the petrous, 208 *f.n.*
- Chinchini on wound of the lateral sinus, 117 *f.n.*
- Chisels, 123, 124.
- Chloride of methyl, 79.
- Cholesteatoma, 3, 71, 227, 257.
- Chronic otitis media complicated by acute mastoiditis, 105.
- Chronic suppurative inflammations of the middle ear, with latent mastoiditis, 217 *et seq.*
- "Chute" or "Dip," 13; *see* "Dip."
- Cold abscess of frontal bone, 185.
- — of rib, 190.
- Coli communis bacillus in mastoid abscess, 2, 242.
- Coma, 181.
- Complications, intracranial, of suppurative otitis media, 35.
- mastoid, of acute inflammation of the middle ear, 253-255.
- — of chronic inflammation of the middle ear, including latent mastoiditis, 255.
- of mastoid fistulæ, 166, 209 *et seq.*, 257.
- Cysts dermoid, 80.
- sebaceous, 80.
- DALBY, 83 *f.n.*
- Deglutition, difficult, 46.
- Délaissement's operation, 121, 122.
- Dental caries and maxillary osteitis, 23.
- Dermoid cysts, 80.
- Derouet, 70 *f.n.*
- Diagnosis, 50 *et seq.*
- Diffuse osteitis, acute, 237, 238, 253, 257.
- Digastric muscles, spread of pus along, 13, 44.
- "Dip" ("chute"), 13, 33, 34, 54, 56, 58, 59, 62, 113, 215.
- Diploëtic or Diploïc type of mastoid, 8.
- Discharge from ear sometimes

- diminished in mastoid abscess, 32, 33.
- Dressing after opening the mastoid, 134, 135.
- Duplay, S., 8, 10 *f.n.*, 17, 18, 33, 115, 122.
- on attic suppuration, 110.
- on diagnosis between simple periostitis and mastoiditis, 65.
- on sclerosing osteitis, 74 and *f.n.*
- on the use of the chisel, 124.
- on Wilde's incision, 87.
- Dura mater, 46, 119, 150, 156, 198.
- EBURNATION of the mastoid, 21, 22, 71, 72, 127, 129, 132, 146, 151, 154, 193, 197, 200-202, 253, 257.
- Eczema of the meatus, 63.
- of the scalp, and inflamed retro-auricular glands, 57.
- Erysipelas, 123.
- Eulenstein on percussion of the mastoid, 51 *f.n.*
- Evolution, spontaneous, 35.
- Extensors of opposite fingers contracting whilst curretting mastoid, 198 *f.n.*
- External auditory meatus, anatomy of, 33.
- — atresia of, 139, 140.
- — periostitis of, 65.
- semicircular canal, 117, 119 *et seq.*, 137.
- FACIAL nerve and its canal, 62, 116, 118 *et seq.*, 137, 198, 199.
- — injury of, 117.
- paralysis, 62, 143, 158 *et seq.*, 173, 199, 208 *f.n.*, 223.
- Ferreri, wound of lateral sinus, 117 *f.n.*
- Ferreri on cerebral abscess, 210, 212, 213.
- Fistula, blind internal, 4.
- blind external, 193, 194.
- complete, 4.
- of border cells opening into meatus, 147, 209, 247, 248.
- of mastoid, 5, 145 *et seq.*
- — bilateral, 188.
- — position of, 149 *f.n.*, 150.
- Floreny, 74 *f.n.*
- Forget (of Strasbourg) on opening the mastoid, 115.
- Forselles, A. af., 138.
- Frontal bone, cold abscess of, 185.
- Furunculosis of the external meatus, 22, 56-59, 62, 63, 71, 145.
- GANGRENOUS mastoid abscess, 238.
- Gellé, 84 and *f.n.*
- and Læwenberg, 89.
- General statistics, 252.
- Giles, 70 *f.n.*
- Gimlet, use of, condemned, 123.
- Glands, mastoid lymphatic, 56.
- — position of, 63.
- retro-auricular lymphatic, 56-59.
- suppurative inflammation of, 63.
- affected in the sterno-mastoid region, 15.
- in front of the tragus, inflammation of, 64.
- Gouge, 123, 124.
- Grandhomme, mastoid abscess in children, 66 *f.n.*
- Gruber, 134 *f.n.*
- Gruenert on Stacke's operation, 220 *f.n.*
- Guye, on retro-pharyngeal abscess

- following cervical mastoid abscess, 45, 46, 69 *f.n.*
- Guye, wound of the lateral sinus, 117 *f.n.*
- HALIPRÉ, 104, 191.
- Hartmann on opening the mastoid, 115, 122, 124, 129.  
— on the lateral sinus, 119.
- Hartmann's cannula, 173.
- Heimann, 83 *f.n.*
- Hemiplegia, secondary to meningitis, 211.
- Hessler on opening the mastoid through the meatus, 116 *f.n.*  
— on the relation of the antrum to the sinus, 119, 120.
- Holmes, C. R., on "Stacke's operation modified by Schwartze," 219 *f.n.*
- Horteloup's leech, 79, 113.
- Hyperostosis, 146.
- "IDIOPATHIC" forms of periostitis, 71.  
— suppurations of the mastoid, 71.
- Illumination of the mastoid cells, 51.
- Impetigo and inflammation of mastoid lymphatic glands, 57.
- Incision, simple or Wilde's, 43, 64, 71, 87 *et seq.*, 113, 145, 166.
- Incision of soft parts in opening mastoid antrum, 124, 125.  
— — mastoid fistulæ, 165.
- Incus and malleus removed for attic suppuration, 218, 219.
- Indications for treatment of mastoid abscess, 80 *et seq.*  
— — of mastoid fistulæ, 165.
- Internal jugular vein, ligature of, 210.
- Intracranial complications of mastoid fistulæ, 166, 209 *et seq.*, 257.  
— — of suppurative otitis media, 35.
- Irrigation of the tympanum, 55, 112, 173.
- JACOBI on cervical mastoid abscess, 45.
- Jacobson, 118 *f.n.*
- Jamain and Terrier, 71 *f.n.*
- Jasser, 114.
- Jugular, internal, ligature of, 210.
- KISSELBACH on opening the mastoid, 117.
- Knapp on fatal meningitis and thrombosis of lateral sinus, 47.  
— on primary, or "idiopathic," external periostitis, 71.
- Kærner on dolicho- and brachycephalic skulls, 128 *f.n.*  
— and Küster on primary diabetic osteitis of mastoid, 70.  
— and Moos on percussion of the mastoid, 51 *f.n.*
- Kretschmann's autoplasmic procedure, 138.
- Küster, 70, 118.
- LACÔARRET, 113 *f.n.*
- Landmarks, bony, 126-128.
- Lane, Arbuthnot, on lateral sinus thrombosis, 209 *f.n.*
- Lannelongue, 5.
- Latent cholesteatoma, 227.  
— mastoid affections, 5.  
— — with chronic suppurative otitis media, 217 *et seq.*  
— — and suppuration of the attic, 224, 226 *et seq.*

- Lateral sinus, explored through the mastoid, 211.  
 ——— injury of, 116, 117, 172, 199.  
 ——— laid bare, found surrounded by pus, 28, 130, 156.  
 ——— phlebitis of, 22, 166.  
 ——— relations of, 116, 119, 128.  
 ——— spread of pus to, 14, 146.  
 ——— thrombosis of, 14, 47, 166, 209.  
 ——— sulcus, caries of, 14.  
 ——— perforated, 47.  
 Laurent on gimlets and drills, 123.  
 Laying open the mastoid, 113, 128, etc.; *see* Operation.  
 ——— the tympanum, 135, 136.  
 Leech, Horteloup's, 79, 113.  
 Leeches, 113.  
 Leiter's tube, 113.  
 Lemcke on hyperostoses, 146.  
 Lesions, bony, in mastoid fistulæ, 147.  
 Lévi on primary idiopathic periotitis, 71 and *f.n.*  
 Ligature of internal jugular vein for thrombosis of lateral sinus, 210.  
 Lippincott, 74 *f.n.*  
 Lœwenberg, 84 and *f.n.*  
 Lubet-Barbon, case of lateral-pharyngeal abscess, 49.  
 ——— (with Alfred Martin) on "Treatment of mastoid abscesses," 80 *f.n.*  
 ——— on "Suppurative otitis media, death from meningitis," 223 *f.n.*  
 Luc, 217 *f.n.*  
 Lucas-Champonnière, 213.  
 Lymphangitis and adenitis, 63.  
 ——— retro-auricular, 64.  
 Lymphatic glands, suppurative inflammation of (adeno-phlegmon), 57, 68.  
 MALLEUS, removal of, for attic supuration, 218, 219.  
 Marchant, 213.  
 Martin, contraction of extensors of opposite side on curetting the mastoid, 198 *f.n.*  
 Mastication, painful, 29, 30.  
 Mastoid, abscess of; *see* Abscess of the mastoid, *supra.*  
 ——— atrophy of, 21.  
 ——— complications of acute and chronic otitis; *see* "Complications," *supra.*  
 ——— disease of, where it originates, 69.  
 ——— without previous otorrhœa, 70.  
 ——— eburnation of; *see* Eburnation of the mastoid.  
 ——— fistula of; *see* Fistula.  
 ——— illumination of the cells of, 51.  
 ——— inflammation of, with no external abscess, 82.  
 ——— with external abscess, 87.  
 ——— acute, complicating chronic otitis media, 105.  
 ——— "Bezold's mastoiditis," so-called, 47 *f.n.*, 69 *f.n.*  
 ——— bilateral and acute, 98.  
 ——— following acute otitis media, 80.  
 ——— following influenza, 33, 84, 132.  
 ——— chronic, 146.  
 ——— latent, 5, 217, 224, 226.  
 ——— spontaneous cure of, 82.

- Mastoid, inflammation of, treatment  
of acute forms of, 111 *et seq.*  
— lymphatic glands, 56.  
— complete necrosis of, both  
sides, 188.  
— opened through the meatus,  
116-118.  
— opened to reach cerebral  
abscess, 210 *et seq.*  
— osteitis of, sclerosing, 68, 72,  
74, 76.  
— perforating spontaneously, 37.  
— periostitis of, 64, 71.  
— retracted, 202.  
— sclerosis of, 68, 72, 74, 76, 121.  
Maubrac on cerebral abscess, 210.  
Meatus, external, anatomy of, 33.  
— atresia of, 139, 140.  
— periostitis of, 65.  
Membrane, tympanic, intact in  
mastoiditis sometimes, 69, 70.  
— — repair of, after opening  
up the mastoid, 11.  
— — ruptured, a source of in-  
fection, 7.  
— Shrapnell's, 110.  
Menière, 113 *f.n.*  
Meninges, œdema of, 181.  
" Meningismus," 181.  
Meningitis, 14, 146, 157, 164, 166,  
167, 176, 177, 222, 223.  
— symptoms of, in a case of  
mastoiditis, 26.  
— and thrombosis of lateral  
sinus, 47.  
— suppurative, treatment of, 209.  
Meslay and Mayet on the mastoid-  
itis of Bezold, 69 *f.n.*  
Methyl chloride, 79.  
Migration of pus, 13, 35, 36.  
Molist, Suné Y., 83 *f.n.*  
Moll, 46.  
Moos, 2, 45.  
Morand, 114.  
Moure on Stacke's operation, 219  
*f.n.*  
Mucous membrane of mastoid cells,  
9.  
— — of tympanum, 9, 22.  
NECROSIS, complete, of both mas-  
toids, 188.  
Nerve, facial; *see* Facial nerve.  
Netter, 2.  
Noltenius on the facial nerve and  
semicircular canal, 12.  
Nuvoli on sclerosis of the mastoid,  
74.  
ŒDEMA of skin over mastoid, 32,  
33, 59.  
Okouneff on the examination of  
hearing in mastoiditis, 52.  
Opening the antrum, 128.  
— the tympanum, 135, 136.  
Operation, main principles of, 99,  
100.  
— ideal procedure, 108.  
— technique for mastoid fistulæ,  
165.  
— the authors', 124, 126 *f.n.*  
— Schwartze's, 126.  
— Stacke's, 219.  
Orgozzo, 84 *f.n.*  
Ossicles, affection of, 109.  
Osteitis, 15, 22, 23, 130, 211.  
— sclerosing, 74, 76 *et seq.*  
— of petrous bone, 197.  
Osteomyelitis of the temporal bone,  
22, 24, 72.  
— "acute and total," of temporal  
bone, 30, 72.

- Otitis media, "subacute or periostitic," 17, 18.
- Otorrhœa of acute otitis chiefly from the mastoid 10, 11.
- may be diminished in commencing mastoiditis, 32, 33.
- Otosopic examination, 204.
- Owen and Pye, 74 *f.n.*
- PAINFUL mastication, 30.
- Pains in mastoid disease, where situated, 29.
- Pathology of mastoid abscess, 6-25.
- Pauzat on osteomyelitis of the temporal, 22-24, 30, 36, 72.
- Percussion of the mastoid, 51 *f.n.*
- Perforation; *see* Spontaneous perforation.
- of the middle ear, 18.
- "Periostitic otitis," 17, 18.
- Periostitis of the mastoid, 18, 56, 64, 66, 67, 113.
- with osteo-periostitis of the tympanum, 65.
- of meatus, 65.
- phlegmonous, 114.
- Peri-phlebitis, 16.
- Péron, "Streptococcus in mastoid abscess," 29, 99, 102.
- Petit, J. L., 37, 114.
- Petro-mastoid canal, 6.
- Petrous bone, diffuse osteitis of, 213.
- Phlebitis of the lateral sinus, 22.
- Physical signs of mastoid fistulæ, 147.
- Piqué on cerebral abscess, 210, 212, 213.
- on subdural abscess, 151.
- Plastic operations, 138, 142.
- Pneumatic type of mastoid, 8, 13.
- Pneumococcus, 229, 231, 234, 240; (with streptococci), 230, 232, 237.
- Poinsot's operation, 122.
- Politzer, 8, 10, 31, 32, 35, 67, 83, 84, 105, 112, 115, 128.
- on irrigating mastoid, 34.
- on otorrhœa in mastoiditis, 72.
- on the "dip," 34.
- Pomeroy, 83 *f.n.*
- Pott's disease, 69, 185-187.
- Pressure over mastoid region producing discharge from meatus, 46, 47, 69.
- Previtt, D., 70 *f.n.*
- Primary osteitis of the temporal bone, 72.
- or idiopathic external periostitis, 71.
- Processus diploëticus, 8.
- mastoïdeus pneumaticus, 8, 13.
- Protector of Stacke, 131, 136, 137, 200, 219.
- Pus, its direction of spread, 13.
- never escapes by the Eustachian tube, 12.
- position according to the type of mastoid, 13, 39, 40.
- shut up, is "a wolf in the fold," 12.
- RADZICH on the torticollis occurring during otitis media, 30 *f.n.*, 31.
- Randall, "Cranimetric Studies," 128 *f.n.*
- Resolution, spontaneous, 35, 82.
- Results, 229 *et seq.*
- A. General statistics, 252.
- B. According to the nature of lesion, 253.

- Retro-auricular lymphatic gland inflamed, 56-58.  
 — lymphangitis, 64.  
 Retro-maxillary cervical abscess, 44.  
 Ricard on the anatomy of the mastoid, 115, 119 *et seq.*  
 — on opening the mastoid, 124, 128, 129.  
 — on wound of lateral sinus, 117 *f.n.*  
 Richards, Huntingdon, on mastoid fistulæ, 149, 201.  
 Riolan, Jean (1649), 114.  
 Rossi, E. de., on mastoiditis with cervical abscess, 15, 47, 69.  
 — on wound of the lateral sinus, 117 *f.n.*
- SALZER on thrombosis of lateral sinus, 209.  
 Sarcoma, 80.  
 Schuelzke, 128 *f.n.*  
 Schwartze on the use of the chisel, 123.  
 — on the "dip" of the meatus, 34.  
 — on laying open the mastoid, 33.  
 — on œdema of skin over mastoid, 33.  
 — on position of mastoid antrum, 7.  
 — on Pott's disease of cervical vertebræ, 69.  
 — on pressure below temporal ridge, 31.  
 Schwartze's operation, 116, 117, 122, 124, 128.  
 — treatise on "Diseases of the Ear," 116.
- Sclerosis of the mastoid, 21, 22, 59, 67, 71, 72, 121, 127, 129, 132.  
 Sebaceous cysts, 80.  
 Semicircular canal, external (or transverse), 117, 119 *et seq.*, 137.  
 Septicæmia in cervical mastoid abscess, 45.  
 Sequestra in mastoid antrum, etc., 131, 151, 156, 157, 197, 200.  
 Shattock on thrombosis of the lateral sinus, 209 *f.n.*  
 "Shirt-button" abscess, 14, 15.  
 Shrapnell's membrane, 110.  
 Skin over mastoid, œdema of, 31, 32.  
 Sphenoidal lobe, 211.  
 Spontaneous evolution, 35, 43.  
 — perforation of mastoid, 37, 42, 43, 47, 145, 150, 151.  
 — resolution, 35.  
 Stacke's operation, 19, 115, 155, 182, 194, 201, 217, 218 *et seq.*  
 Staphylococci and otorrhœa, 2 *f.n.*, 231, 232.  
 Statistics, 5.  
 — A. General, 252.  
 — B. According to the lesion, 253.  
 Sterno-mastoid muscle, spread of pus along, 13.  
 — — abscess in sheath of, 40, 41, 44.  
 — — contraction of, producing torticollis, 30, 31.  
 Streptococci found, 29, 99, 104, 134, 191, 249.  
 — with pneumococci, 230, 232.  
 — — and staphylococci, 237.  
 — with putrefactive organisms, 239.  
 Subdural abscess, 14, 15, 47, 211.



- Sub-periosteal abscess of mastoid, 16, 17.  
 Suppuration of the attic, 204.  
 Suppurative otitis media, 10.  
 — — pathology of associated mastoiditis, 10.  
 Supra-meatal spine, 7, 120, 127, 130, 201, 202.  
 Symptoms of mastoid abscess, 25 *et seq.*  
 Syphilis, 80.
- TACHE cérébrale.  
 Temperature in mastoid abscess, 26, 53.  
 Temporal line, 125, 201, 202.  
 — lobe, 210.  
 Tenderness on pressure behind ear, importance of, 53.  
 Terrier, 71.  
 Tillaux, 6 *f.n.*, 7 *f.n.*, 9.  
 Torticollis, 30, 31, 206.  
 Toynbee on opening the mastoid, 115.  
 Transillumination of the mastoid cells, 51.  
 Treatment, indications for, 80 *et seq.*  
 — of acute mastoiditis, 111.  
 Trœltch, von, on opening the mastoid, 115, 116.  
 Truckenbrodt on glycosuria preceding meningitis, 70 *f.n.*  
 Tube, Eustachian, a source of infection, 7, 9.  
 Tubercular lesions associated with mastoid fistula, 184.  
 Tuberculosis, 80.
- Tumours, 80.  
 Tympanic membrane, ruptured, a source of infection, 7.  
 — — perforation of, 65.  
 — — repair of, after opening mastoid, 11.  
 Tympanum, 6, 7.  
 — irrigation of, 112.  
 — osteo-periostitis of, 65.  
 — purulent catarrh of, 65.  
 "Typhoid state" in mastoiditis, 27.
- URBANTSCHITSCH, 51 *f.n.*
- VERTIGO, 146, 155, 164, 171-173.  
 Vesicatories, to be avoided, 113.  
 Voltolini on idiopathic periostitis, 71.
- WALBE, on the attic, 109.  
 Weismann, 109 *f.n.*, 217 *f.n.*, 139 *f.n.*  
 Wheeler on cerebral abscess, 210-213.  
 Wilde's incision, 43, 64, 71, 113, 145, 166.  
 — — tentative only, 87 *et seq.*  
 Wolff on opening the mastoid through meatus, 116.
- ZAUFAL, 2.  
 — on cervical mastoid abscess, 45.  
 — on opening the tympanic cavity, 135 *f.n.*  
 Zuckerkandl's researches, 7, 8, 13, 115, 128.

SELECTED LIST  
OF  
NEW AND RECENT WORKS

PUBLISHED BY

H. K. LEWIS,  
136 GOWER STREET, LONDON, W.C.

(ESTABLISHED 1844).

---

*\*\* For full list of works in Medicine and Surgery published by H. K. Lewis see complete Catalogue sent post free on application.*

---

SYDNEY RINGER, M.D., F.R.S.

Holme Professor of Clinical Medicine in University College; Physician to University College Hospital,

AND

HARRINGTON SAINSBURY, M.D., F.R.C.P.

Physician to the Royal Free Hospital and the City of London Hospital for Diseases of the Chest, Victoria Park.

**A HANDBOOK OF THERAPEUTICS.** Thirteenth Edition, 8vo, 16s. [Now ready.]

H. ALDERSMITH, M.B. LOND., F.R.C.S.

Medical Officer, Christ's Hospital, London.

**RINGWORM AND ALOPECIA AREATA:** Their Pathology, Diagnosis, and Treatment. Fourth Edition, enlarged, with new Illustrations, demy 8vo, 10s. 6d. [Now ready.]

A. BROCA, M.D.

Chirurgien des Hôpitaux des Paris, &c.

AND

F. LUBET-BARBON, M.D.

Ancien Interne des Hôpitaux de Paris.

**MASTOID ABSCESSSES AND THEIR TREATMENT.** Translated and edited by HENRY J. CURTIS, B.S. and M.D. (Lond.), F.R.C.S. (Eng.), Assistant to the Professor of Pathology, University College, London, &c. With coloured Illustrations, cr. 8vo, 6s. [Now ready.]

E. W. GOODALL, M.D. LOND.

Medical Superintendent of the Eastern Hospital of the Metropolitan Asylums Board; Formerly Medical Registrar to Guy's Hospital;

AND

J. W. WASHBOURN, M.D. LOND., F.R.C.P.

Physician to the London Fever Hospital; Assistant Physician to Guy's Hospital, and Lecturer in the Medical School.

**A MANUAL OF INFECTIOUS DISEASES.** Illustrated with Plates, Diagrams, and Charts, 8vo, 15s. [Now ready.]

A. C. ABBOTT, M.D.

Professor of Hygiene, and Director of the Laboratory of Hygiene, University of Pennsylvania.

**THE PRINCIPLES OF BACTERIOLOGY:** A Practical Manual for Students and Physicians. Fourth Edition, with 106 Illustrations, 19 being coloured, post 8vo, 12s. 6d. *nett.*  
[Just ready.]

---

JAMES ANDERSON, M.D., F.R.C.P.

Late Assistant Physician to the London Hospital, &c.

**NOTES ON MEDICAL NURSING;** from the Lectures given to the Probationers at the London Hospital. Edited by E. F. LAMPORT, Associate of the Sanitary Institute. Third Edition, crown 8vo, 2s. 6d.  
[Now ready.]

---

E. CRESSWELL BABER, M.B. LOND.

Surgeon to the Brighton and Sussex Throat and Ear Hospital.

**A GUIDE TO THE EXAMINATION OF THE NOSE WITH REMARKS ON THE DIAGNOSIS OF DISEASES OF THE NASAL CAVITIES.** With Illustrations, small 8vo, 5s. 6d.

---

FANCOURT BARNES, M.D., M.R.C.P.

Physician to the Chelsea Hospital; Obstetric Physician to the Great Northern Hospital, &c.

**A GERMAN-ENGLISH DICTIONARY OF WORDS AND TERMS USED IN MEDICINE AND ITS COGNATE SCIENCES.** Square 12mo, Roxburgh binding, 9s.

---

H. CHARLTON BASTIAN, M.A., M.D., F.R.S.

Examiner in Medicine at the Royal College of Physicians; Physician to University College Hospital, etc.

I.

**PARALYSES: CEREBRAL, BULBAR, AND SPINAL.** A Manual of Diagnosis for Students and Practitioners. With numerous Illustrations, 8vo, 12s. 6d.

II.

**VARIOUS FORMS OF HYSTERICAL OR FUNCTIONAL PARALYSIS.** Demy 8vo, 7s. 6d.

---

RUBERT BOYCE, M.B., M.R.C.S.

Professor of Pathology in University College, Liverpool.

**A TEXTBOOK OF MORBID HISTOLOGY FOR STUDENTS AND PRACTITIONERS.** With 130 coloured figures, royal 8vo, 31s. 6d.

CHARLES H. BURNETT, A.M., M.D.

Clinical Professor of Otology in the Woman's Medical College of Pennsylvania; Aural Surgeon to the Presbyterian Hospital, Philadelphia.

**S**YSTEM OF DISEASES OF THE EAR, NOSE AND THROAT. By 45 Eminent American, British, Canadian and Spanish Authors. Edited by CHARLES H. BURNETT. With Illustrations, in two imperial 8vo vols., 48s. *nett.*

---

HARRY CAMPBELL, M.D., B.S. LOND., M.R.C.P.

Physician to the North-West London Hospital.

I.

**T**HE CAUSATION OF DISEASE. An exposition of the ultimate factors which induce it. Demy 8vo, 12s. 6d.

II.

**F**LUSHING AND MORBID BLUSHING, THEIR PATHOLOGY AND TREATMENT. With plates and wood engravings, royal 8vo, 10s. 6d.

III.

**D**IFFERENCES IN THE NERVOUS ORGANISATION OF MAN AND WOMAN, PHYSIOLOGICAL AND PATHOLOGICAL. Royal 8vo, 15s.

IV.

**H**EADACHE AND OTHER MORBID CEPHALIC SENSATIONS. Royal 8vo, 12s. 6d.

---

R. E. CARRINGTON, M.D., F.R.C.P.

**N**OTES ON PATHOLOGY. With an Introductory Chapter by J. F. GOODHART, M.D., F.R.C.P., Physician to Guy's Hospital. Edited by H. E. CROOK, M.D. Lond., F.R.C.S. Eng., and G. MACKESON, L.R.C.P., M.R.C.S. Cr. 8vo, 3s.

---

ALFRED H. CARTER, M.D. LOND., F.R.C.P.

Senior Physician to the Queen's Hospital; Professor of Therapeutics, Mason College, Birmingham, &c.

**E**LEMENTS OF PRACTICAL MEDICINE. Seventh Edition, crown 8vo, 10s.

---

FRANCIS HENRY CHAMPNEYS, M.A., M.B. OXON., F.R.C.P.

Physician-Accoucheur and Lecturer on Obstetric Medicine at St. Bartholomew's Hospital, &c.

**L**ECTURES ON PAINFUL MENSTRUATION. Royal 8vo, 7s. 6d.

**WALTER S. COLMAN, M.D., F.R.C.P.**

Assistant Physician to the National Hospital for the Paralysed and Epileptic,  
&c.

**SECTION CUTTING AND STAINING: A Practical**  
Introduction to Histological Methods for Students and  
Practitioners. Second Edition, with Illustrations, crown 8vo,  
3s. 6d.

---

**E. TREACHER COLLINS, F.R.C.S.**

Assistant Surgeon to the Royal London Ophthalmic Hospital, Moorfields;  
Hunterian Professor, Royal College of Surgeons, England, 1893-94

**RESEARCHES INTO THE ANATOMY AND PA-**  
**THOLOGY OF THE EYE.** With 10 Plates and 28  
Figures in the text, demy 8vo, 6s.

---

**W. H. CORFIELD, M.A., M.D. OXON., F.R.C.P. LOND.**

Professor of Hygiene and Public Health in University College, London.

I.

**DWELLING HOUSES: their Sanitary Construction and**  
Arrangements. Fourth Edition, with Illustrations, crown  
8vo. [*In preparation.*]

II.

**DISEASE AND DEFECTIVE HOUSE SANITATION.**  
With Illustrations, crown 8vo, 2s.

---

**SIDNEY COUPLAND, M.D., F.R.C.P.**

Physician to the Middlesex Hospital, and Lecturer on Practical Medicine in the  
Medical School, etc.

**NOTES ON THE CLINICAL EXAMINATION OF**  
**THE BLOOD AND EXCRETA.** Third Edition, 12mo,  
1s. 6d.

---

**H. RADCLIFFE CROCKER, M.D. LOND., B.S., F.R.C.P.**

Physician for Diseases of the Skin in University College Hospital.

**DISEASES OF THE SKIN: THEIR DESCRIPTION,**  
**PATHOLOGY, DIAGNOSIS, AND TREATMENT.**  
Second Edition, with Illustrations, 8vo, 24s.

---

**EDGAR M. CROOKSHANK, M.B.**

Professor of Comparative Pathology and Bacteriology, King's College,  
London.

I.

**A TEXT-BOOK OF BACTERIOLOGY: Including the**  
Etiology and Prevention of Infective Diseases, and a  
short account of Yeasts and Moulds, Hæmatozoa, and Psoro-  
sperms. Fourth Edition, illustrated with 22 coloured plates and  
273 illustrations in the text, med. 8vo, 21s. *nett.* [*Now ready.*]

II.

**HISTORY AND PATHOLOGY OF VACCINATION.**  
2 vols., royal 8vo, coloured plates, 20s. *nett.*

HERBERT DAVIES, M.D., F.R.C.P.

Late Consulting Physician to the London Hospital, etc.

**T**HE MECHANISM OF THE CIRCULATION OF  
THE BLOOD THROUGH ORGANICALLY DIS-  
EASED HEARTS. Edited by ARTHUR TEMPLER DAVIES, B.A.,  
M.D. Cantab., M.R.C.P. Crown 8vo, 3s. 6d.

---

HENRY DAVIS, M.R.C.S. ENG.

Teacher and Administrator of Anæsthetics at St. Mary's Hospital, and Anæ-  
sthetist at the Dental Hospital of London.

**G**UIDE TO THE ADMINISTRATION OF ANÆS-  
THETICS. Second Edition, fcap. 8vo, 2s. 6d.

---

ROBERT W. DOYNE, F.R.C.S.

Surgeon to the Oxford Eye Hospital; Ophthalmic Surgeon to St. John's  
Hospital, Cowley, etc.

**N**OTES ON THE MORE COMMON DISEASES OF  
THE EYE. With test types, crown 8vo, 2s.

[*Now ready.*]

---

DR. A. DÜHRSEN.

Late first Assistant in the Obstetric Clinic of the Charité Hospital in Berlin.

I.

**A** MANUAL OF GYNÆCOLOGICAL PRACTICE FOR  
STUDENTS AND PRACTITIONERS. Translated and  
Edited from the fourth German edition, by JOHN W. TAYLOR,  
F.R.C.S., Surgeon to the Women's Hospital, Birmingham, &c.;  
and FREDERICK EDGE, M.D. LOND., F.R.C.S., Surgeon to the  
Women's Hospital, Wolverhampton. With 120 Illustrations,  
cr. 8vo, 6s.

II.

**A** MANUAL OF OBSTETRIC PRACTICE FOR  
STUDENTS AND PRACTITIONERS. Translated  
and edited from the sixth German edition by JOHN W. TAYLOR  
and FREDERICK EDGE. With Illustrations, cr. 8vo, 6s.

[*Just published.*]

---

W. ELDER, M.D., F.R.C.P. EDIN.

Physician to Leith Hospital.

**A**PHASIA AND THE CEREBRAL SPEECH ME-  
CHANISM. With Illustrations, demy 8vo, 10s. 6d.

[*Now ready.*]

6    **New and Recent Works published by**

---

**W. SOLTAU FENWICK, M.D., B.S. LOND., M.R.C.P.**

Physician to Out-patients at the Evelina Hospital for Sick Children, &c.

I.

**THE DYSPEPSIA OF PHTHISIS:** Its Varieties and Treatment, including a Description of Certain Forms of Dyspepsia associated with the Tubercular Diathesis. Demy 8vo, 6s.

II.

**DISORDERS OF DIGESTION IN INFANCY AND CHILDHOOD.** With illustrations, demy 8vo, 10s. 6d.  
[Now ready.]

---

**J. MILNER FOTHERGILL, M.D.**

I.

**INDIGESTION AND BILIOUSNESS.** Second Edition, post 8vo, 7s. 6d.

II.

**GOUT IN ITS PROTEAN ASPECTS.** Post 8vo, 7s. 6d.

III.

**THE TOWN DWELLER: HIS NEEDS AND HIS WANTS.** Post 8vo, 3s. 6d.

---

**ERNEST FUCHS.**

Professor of Ophthalmology in the University of Vienna.

**TEXTBOOK OF OPHTHALMOLOGY.** Translated from the Second German Edition by A. DUANE, M.D., Assistant Surgeon, Ophthalmic and Aural Institute, New York. With 190 Illustrations, large 8vo, 21s.

---

**PROFESSOR DR. PAUL FÜRBRINGER.**

Director of the Friedrichshain Hospital, Berlin, &c.

**TEXTBOOK OF DISEASES OF THE KIDNEYS AND GENITO-URINARY ORGANS.** Translated by W. H. GILBERT, M.D., Physician in Baden-Baden, &c. Vol. I., demy 8vo, 7s. 6d.

---

**SIR DOUGLAS GALTON, K.C.B., HON. D.C.L., LL.D., F.R.S.,**  
formerly Secretary Railway Department Board of Trade; Assistant Inspector-General of Fortifications, &c.

**HEALTHY HOSPITALS. OBSERVATIONS ON SOME POINTS CONNECTED WITH HOSPITAL CONSTRUCTION.** With Illustrations, 8vo, 10s. 6d.

JOHN HENRY GARRETT, M.D.

Licentiate in Sanitary Science and Diplomate in Public Health, Universities of Durham and Cambridge, &c.

**T**HE ACTION OF WATER ON LEAD: being an inquiry into the cause and mode of the action and its prevention. Crown 8vo, 4s. 6d.

---

ALFRED W. GERRARD, F.C.S.

Examiner to the Pharmaceutical Society.

**E**LEMENTS OF MATERIA MEDICA AND PHARMACY. With the New Official Remedies, 1890. Crown 8vo, 8s. 6d.

---

JAMES F. GOODHART, M.D. ABERD., F.R.C.P.

Physician to Guy's Hospital, and Consulting Physician to the Evelina Hospital for Sick Children.

**O**N COMMON NEUROSES; OR THE NEUROTIC ELEMENT IN DISEASE AND ITS RATIONAL TREATMENT. Second Edition, crown 8vo, 3s. 6d.

---

JOHN GORHAM, M.R.C.S.

**T**OOTH EXTRACTION: A manual on the proper mode of extracting teeth. Fourth edition, fcap. 8vo, 1s. 6d.

---

GEORGE M. GOULD, A.M., M.D.

I.

**T**HE STUDENT'S MEDICAL DICTIONARY: Including all the words and phrases generally used in Medicine, with their proper pronunciation and definitions. Tenth Edition, 8vo, 14s. *nett.* [Now ready.]

II.

**A** POCKET MEDICAL DICTIONARY, giving the Pronunciation and Definition of about 12,000 of the Principal Words used in Medicine and the Collateral Sciences. 32mo, 4s. *nett.*

---

LANDON C. GRAY, M.D.

Professor of Nervous and Mental Diseases in the New York Polyclinic, &c.

**A** TREATISE ON NERVOUS AND MENTAL DISEASES FOR STUDENTS AND PRACTITIONERS OF MEDICINE. With 168 Illustrations, 8vo, 21s.



DR. JOSEF GRUBER.

Professor of Otology in the University of Vienna, &c.

**A TEXT-BOOK OF THE DISEASES OF THE EAR.**

Translated from the German, and Edited by EDWARD LAW, M.D., C.M. EDIN., M.R.C.S. ENG., Surgeon to the London Throat Hospital for Diseases of the Throat, Nose and Ear; and COLEMAN JEWELL, M.B. LOND., M.R.C.S. ENG. Second edition, with 165 Illustrations, and 70 coloured figures, royal 8vo, 28s.

W. S. HEDLEY, M.D.

Medical Officer in charge of the Electro-Therapeutic Department of the London Hospital.

I.

**THE HYDRO-ELECTRIC METHODS IN MEDICINE.** Second Edition, with Illustrations, demy 8vo, 4s. 6d.

II.

**CURRENT FROM THE MAIN:** The Medical Employment of Electric Lighting Currents. With Illustrations, demy 8vo, 2s. 6d.

III.

**PRACTICAL MUSCLE-TESTING; AND THE TREATMENT OF MUSCULAR ATROPHIES.** With Illustrations, demy 8vo, 3s. 6d. [*Now ready.*]

BERKELEY HILL, M.B. LOND., F.R.C.S.

Professor of Clinical Surgery in University College,

AND

ARTHUR COOPER, L.R.C.P., M.R.C.S.

Surgeon to the Westminster General Dispensary, &c.

**SYPHILIS AND LOCAL CONTAGIOUS DISORDERS.** Second Edition, entirely re-written, royal 8vo, 18s.

NORMAN KERR, M.D., F.L.S.

President of the Society for the Study of Inebriety; Consulting Physician, Dalrymple Home for Inebriates, etc.

**INEBRIETY: ITS ETIOLOGY, PATHOLOGY, TREATMENT, AND JURISPRUDENCE.** Third Edition, 8vo, 21s.

F. CHARLES LARKIN, F.R.C.S. ENG.

Surgeon to the Stanley Hospital,

AND

RANDLE LEIGH, M.B., B.SC. LOND.

Senior Demonstrator of Physiology in University College, Liverpool.

**OUTLINES OF PRACTICAL PHYSIOLOGICAL CHEMISTRY.** Second Edition, with Illustrations, crown 8vo, 2s. 6d. *nett.*

**LEWIS'S PRACTICAL SERIES.**

*In Crown 8vo Volumes, with Illustrations.*

- THE TREATMENT OF PULMONARY CONSUMPTION.**  
By VINCENT D. HARRIS, M.D. Lond., F.R.C.P., Physician to the City of London Hospital for Diseases of the Chest, etc., and E. CLIFFORD BEALE, M.A., M.B., Cantab., F.R.C.P., Physician to the City of London Hospital for Diseases of the Chest, etc. 10s. 6d. [Now ready.]
- THE SURGICAL DISEASES OF CHILDREN AND THEIR TREATMENT BY MODERN METHODS.** By D'ARCY POWER, M.A., M.B. Oxon., F.R.C.S. Eng., Demonstrator of Operative Surgery at St. Bartholomew's Hospital, &c. 10s. 6d.
- DISEASES OF THE NOSE AND THROAT.**  
By F. de HAVILLAND HALL, M.D., F.R.C.P. Lond., Physician in Charge of the Throat Department at the Westminster Hospital, &c. 10s. 6d.
- PUBLIC HEALTH LABORATORY WORK.**  
By H. R. KENWOOD, M.B., D.P.H., F.C.S., Assistant Professor of Public Health, University College, &c. Second Edition, 10s. 6d.
- MEDICAL MICROSCOPY.**  
By FRANK J. WETHERED, M.D., M.R.C.P., Medical Registrar to the Middlesex Hospital. 9s.
- MEDICAL ELECTRICITY.**  
By H. LEWIS JONES, M.A., M.D., F.R.C.P., Medical Officer, Electrical Department, St. Bartholomew's Hospital. Second Edition, 10s. 6d.
- HYGIENE AND PUBLIC HEALTH.**  
By LOUIS C. PARKES, M.D., D.P.H. Lond. Univ., Lecturer on Public Health at St. George's Hospital, etc. Fifth Edition, 10s. 6d.
- MANUAL OF OPHTHALMIC PRACTICE.**  
By C. HIGGENS, F.R.C.S., Lecturer on Ophthalmology at Guy's Hospital Medical School, &c. 6s.
- A PRACTICAL TEXTBOOK OF THE DISEASES OF WOMEN.** By ARTHUR H. N. LEWERS, M.D. Lond., M.R.C.P., Obstetric Physician to the London Hospital. Fifth Edition, 10s. 6d.
- ANÆSTHETICS, THEIR USES AND ADMINISTRATION.**  
By DUDLEY W. BUXTON, M.D., B.S., M.R.C.P., Administrator of Anæsthetics at University College Hospital, etc. Second Edition, 5s.
- ON FEVERS: THEIR HISTORY, ETIOLOGY, DIAGNOSIS, PROGNOSIS, AND TREATMENT.** By A. COLLIE, M.D. 8s. 6d.
- HANDBOOK OF DISEASES OF THE EAR.**  
By URBAN PRITCHARD, M.D. (Edin.), F.R.C.S., Professor of Aural Surgery at King's College, London, etc. Third Edition, 6s.
- A PRACTICAL TREATISE ON DISEASES OF THE KIDNEYS AND URINARY DERANGEMENTS.** By C. H. RALFE, M.A., M.D. Cantab., F.R.C.P., Physician to the London Hospital. 10s. 6d.
- DENTAL SURGERY FOR GENERAL PRACTITIONERS AND STUDENTS OF MEDICINE.** By ASHLEY W. BARRETT, M.B. Lond., M.R.C.S., L.D.S., Consulting Dental Surgeon to the London Hospital. Third Edition, 3s. 6d. [Now ready.]
- BODILY DEFORMITIES AND THEIR TREATMENT.**  
By H. A. REEVES, F.R.C.S. Ed., Senior Assistant Surgeon and Teacher of Practical Surgery at the London Hospital. 8s. 6d.

J. WICKHAM LEGG, F.R.C.P.

Formerly Assistant Physician to Saint Bartholomew's Hospital.

**A GUIDE TO THE EXAMINATION OF THE URINE.** Seventh Edition, edited and revised by H. LEWIS JONES, M.D., Medical Officer in charge of the Electrical Department in St. Bartholomew's Hospital. With Illustrations, fcap. 8vo, 3s. 6d.

---

**LEWIS'S POCKET MEDICAL VOCABULARY.**  
Second Edition, 32mo, limp roan, 3s. 6d.

---

WILLIAM THOMPSON LUSK, A.M., M.D.

Professor of Obstetrics in the Bellevue Hospital Medical College, &c.

**THE SCIENCE AND ART OF MIDWIFERY.** Fourth Edition, rewritten, with numerous Illustrations, 8vo, 18s.

---

JEFFERY A. MARSTON, M.D., C.B., F.R.C.S., M.R.C.P. LOND.

Surgeon General Medical Staff (Retired).

**NOTES ON TYPHOID FEVER:** Tropical Life and its Sequelæ. Crown 8vo, 3s. 6d.

---

WILLIAM MARTINDALE, F.C.S.

AND

W. WYNN WESTCOTT, M.B. LOND.

**THE EXTRA PHARMACOPŒIA,** with Medical References, and a Therapeutic Index of Diseases and Symptoms. Eighth Edition, limp roan, med. 24mo, 9s.

---

A. STANFORD MORTON, M.B., F.R.C.S. ENG.

Surgeon to the Moorfields Ophthalmic Hospital, &c.

**REFRACTION OF THE EYE:** Its Diagnosis, and the Correction of its Errors. Sixth Edition, small 8vo, 3s. 6d.

---

C. W. MANSELL MOULLIN, M.A., M.D. OXON., F.R.C.S. ENG.

Surgeon and Lecturer on Physiology at the London Hospital, &c.

I.  
**SPRAINS; THEIR CONSEQUENCES AND TREATMENT.** Second Edition, crown 8vo, 4s. 6d.

II.  
**ENLARGEMENT OF THE PROSTATE:** its Treatment and Radical Cure. With plates, 8vo, 6s.

WILLIAM MURRAY, M.D., F.R.C.P. LOND.

I.  
**R**OUGH NOTES ON REMEDIES. Second Edition,  
crown 8vo, 3s. 6d.

II.  
**I**LLUSTRATIONS OF THE INDUCTIVE METHOD  
IN MEDICINE. Crown 8vo, 3s. 6d.

---

WILLIAM MURRELL, M.D., F.R.C.P.

Lecturer on Materia Medica and Therapeutics at Westminster Hospital.

I.  
**M**ASSOTHERAPEUTICS; OR MASSAGE AS A  
MODE OF TREATMENT. Fifth Edition, crown 8vo,  
4s. 6d.

II.  
**W**HAT TO DO IN CASES OF POISONING. Eighth  
Edition, royal 32mo, 3s. 6d. [Now ready.]

---

G. OLIVER, M.D., F.R.C.P.

I.  
**P**ULSE-GAUGING: A Clinical Study of Radial Measure-  
ment and Pulse Pressure. Illustrations, fcap. 8vo, 3s. 6d.

II.  
**O**N BEDSIDE URINE TESTING: a Clinical Guide to  
the Observation of Urine in the course of Work. Fourth  
Edition, fcap. 8vo, 3s. 6d.

III.  
**T**HE HARROGATE WATERS: Data Chemical and  
Therapeutical, with notes on the Climate of Harrogate.  
Crown 8vo, with Map of the Wells, 3s. 6d.

---

DR. A. ONODI.

Lecturer on Rhino-Laryngology in the University of Budapest.

**T**HE ANATOMY OF THE NASAL CAVITY, AND  
ITS ACCESSORY SINUSES. An Atlas for Practitioners  
and Students, translated by ST CLAIR THOMSON, M.D. LOND.,  
F.R.C.S. ENG., M.R.C.P. LOND. Plates, small 4to, 6s. *nett*.

---

WILLIAM OSLER, M.D., F.R.C.P. LOND.

Professor of Medicine, Johns Hopkins University, &c.

**O**N CHOREA AND CHOREIFORM AFFECTIONS.  
Large 8vo, 5s.

---

LOUIS C. PARKES, M.D. LOND., D.P.H.

Lecturer on Public Health at St. George's Hospital, &c.

**I**NFECTIONOUS DISEASES, NOTIFICATION AND  
PREVENTION. Fcap. 8vo, cloth, 2s. 6d., roan, 4s. 6d.

R. DOUGLAS POWELL, M.D., F.R.C.P.,

Physician Extra-ordinary to H.M. the Queen; Physician to the Middlesex Hospital; Consulting Physician to the Hospital for Consumption and Diseases of the Chest at Brompton.

**DISEASES OF THE LUNGS AND PLEURÆ INCLUDING CONSUMPTION.** Fourth Edition, with coloured plates and wood-engravings, 8vo, 18s.

---

DR. THEODOR PUSCHMANN.

Public Professor in Ordinary at the University of Vienna.

**HISTORY OF MEDICAL EDUCATION FROM THE MOST REMOTE TO THE MOST RECENT TIMES.** Translated by EVAN H. HARE, M.A. (OXON.), F.R.C.S. (ENG.), F.S.A. Demy 8vo, 21s.

---

SAMUEL RIDEAL, D.SC. (LOND.), F.I.C., F.C.S., F.G.S.

Fellow of University College, London.

I.

**PRACTICAL ORGANIC CHEMISTRY.** The detection and properties of some of the more important organic compounds. 12mo, 2s. 6d.

II.

**PRACTICAL CHEMISTRY FOR MEDICAL STUDENTS,** Required at the First Examination of the Conjoint Examining Board in England. Fcap. 8vo, 2s.

---

J. JAMES RIDGE, M.D., B.S., B.A., B.SC. LOND.

Medical Officer of Health, Enfield.

**ALCOHOL AND PUBLIC HEALTH.** Second Edition, Crown 8vo, 2s.

---

FREDERICK T. ROBERTS, M.D., B.SC., F.R.C.P.

Professor of the Principles and Practice of Medicine in University College; Physician to University College Hospital, &c.

I.

**THE THEORY AND PRACTICE OF MEDICINE.** Ninth Edition, with Illustrations, large 8vo, 21s.

II.

**THE OFFICINAL MATERIA MEDICA.** Second Edit., entirely rewritten in accordance with the latest British Pharmacopœia, with the Additions made in 1890, fcap. 8vo, 7s. 6d.

---

H. D. ROLLESTON, M.D., F.R.C.P.

Fellow of St. John's College, Cambridge; Assistant Physician and Lecturer on Pathology, St. George's Hospital, London;

AND

A. A. KANTHACK, M.D., M.R.C.P.

Lecturer on Pathology, St. Bartholomew's Hospital, London.

**PRACTICAL MORBID ANATOMY.** Crown 8vo, 6s.

[CAMBRIDGE NATURAL SCIENCE MANUALS.]

ROBSON ROOSE, M.D., F.R.C.P. EDIN.

I.  
**G**OUT, AND ITS RELATIONS TO DISEASES OF  
THE LIVER AND KIDNEYS. Seventh Edition, crown  
8vo, 4s. 6d.

II.  
**N**ERVE PROSTRATION AND OTHER FUNC-  
TIONAL DISORDERS OF DAILY LIFE. Second  
Edition, demy 8vo, 18s.

WILLIAM ROSE, B.S., M.B. LOND., F.R.C.S.

Professor of Surgery in King's College, London, and Surgeon to King's  
College Hospital, &c.

**O**N HARELIP AND CLEFT PALATE. Demy 8vo,  
with Illustrations, 6s.

BERNARD ROTH, F.R.C.S.

Fellow of the Medical Society of London.

**T**HE TREATMENT OF LATERAL CURVATURE  
OF THE SPINE. With Photographic and other Illus-  
trations, demy 8vo, 5s.

DR. C. SCHIMMELBUSCH.

Privat-docent and Assistant Surgeon in Prof. v. Bergmann's University Clinic  
at Berlin.

**T**HE ASEPTIC TREATMENT OF WOUNDS.  
Translated from the Second German Edition by A. T. RAKE,  
M.B., B.S. LOND., F.R.C.S. ENG., Registrar and Pathologist to  
the East London Hospital for Children. With Illustrations,  
crown 8vo, 5s.

G. E. SHUTTLEWORTH, B.A., M.D.

Late Medical Superintendent, Royal Albert Asylum for Idiots and Imbeciles  
of the Northern Counties, Lancaster, &c.

**M**ENTALLY - DEFICIENT CHILDREN: THEIR  
TREATMENT AND TRAINING. With Illustrations,  
crown 8vo, 4s.

ALEXANDER J. C. SKENE, M.D.

Professor of Gynæcology in the Long Island College Hospital, Brooklyn.

**T**REATISE ON THE DISEASES OF WOMEN.  
Second Edition, with 251 engravings and 9 chromo-litho-  
graphs, medium 8vo, 28s.

J. LEWIS SMITH, M.D.

Physician to the New York Foundling Asylum; Clinical Professor of Diseases  
of Children in Bellevue Hospital Medical College.

**A** TREATISE ON THE MEDICAL AND SURGICAL  
DISEASES OF INFANCY AND CHILDHOOD.  
Eighth Edition, with Illustrations, large 8vo, 21s. [*Now ready.*]

E. HUGH SNELL, M.D., B.SC., LOND.

Diplomate in Public Health of the University of Cambridge; London County Council Medical Officer to the Blackwall Tunnel.

**C**OMPRESSED AIR ILLNESS, OR SO-CALLED  
CAISSON DISEASE. Demy 8vo, 10s. 6d. [*Now ready.*]

---

JOHN KENT SPENDER, M.D. LOND.

Physician to the Royal Mineral Water Hospital, Bath.

**T**HE EARLY SYMPTOMS AND THE EARLY  
TREATMENT OF OSTEO-ARTHRITIS, commonly  
called Rheumatoid Arthritis. With special reference to the Bath  
Thermal Waters. Small 8vo, 2s. 6d.

---

JAMES STOCKEN, L.D.S. ENG.

Pereira Prizeman for Materia Medica; Late Dental Surgeon to the National  
Dental Hospital.

**D**ENTAL MATERIA MEDICA AND THERAPEU-  
TICS. Fourth edition, revised by LESLIE M. STOCKEN,  
L.R.C.P., M.R.C.S., L.D.S.; and J. O. BUTCHER, L.D.S. ENG.,  
Assistant Dental Surgeon to Guy's Hospital. Fcap. 8vo, 4s.

---

ADOLF STRÜMPELL.

Professor and Director of the Medical Clinique at Erlangen.

**A** TEXT-BOOK OF MEDICINE FOR STUDENTS  
AND PRACTITIONERS. Second edition translated  
by Dr. H. F. VICKERY and Dr. P. C. KNAPP, with Editorial Notes  
by Dr. F. C. SHATTUCK, Visiting Physician to the Massachusetts  
General Hospital, &c. With 119 Illustrations, imp. 8vo, 28s.

---

C. W. SUCKLING, M.D. LOND., M.R.C.P.

Professor of Materia Medica and Therapeutics at the Queen's College,  
Physician to the Queen's Hospital, Birmingham, etc.

I.  
**O**N THE DIAGNOSIS OF DISEASES OF THE  
BRAIN, SPINAL CORD, AND NERVES. With Illus-  
trations, crown 8vo, 8s. 6d.

II.  
**O**N THE TREATMENT OF DISEASES OF THE  
NERVOUS SYSTEM. Crown 8vo, 7s. 6d.

---

J. BLAND SUTTON, F.R.C.S.

Assistant Surgeon to the Middlesex Hospital.

**L**IGAMENTS: THEIR NATURE AND MORPHO-  
LOGY. Second Edition, wood engravings, post 8vo, 4s. 6d.  
[*Now ready.*]

HENRY R. SWANZY, A.M., M.B., F.R.C.S.I.

Examiner in Ophthalmology to the University of Dublin; Surgeon to the National Eye and Ear Infirmary, Dublin, etc.

**A HANDBOOK OF DISEASES OF THE EYE AND THEIR TREATMENT.** Sixth Edition, Illustrated with Wood Engravings, Colour Tests, etc., large post 8vo, 12s. 6d. [Now ready.]

ALBERT TAYLOR.

Associate Sanitary Institute; Chief Sanitary Inspector to the Vestry of St. George, Hanover Square, etc.

**THE SANITARY INSPECTOR'S HANDBOOK.** Second Edition, with Illustrations, cr. 8vo, 5s. [Now ready.]

E. G. WHITTLE, M.D. LOND., F.R.C.S. ENG.

Senior Surgeon to the Royal Alexandra Hospital for Sick Children, Brighton.

**CONGESTIVE NEURASTHENIA, OR INSOMNIA AND NERVE DEPRESSION.** Crown 8vo, 3s. 6d.

SIR JOHN WILLIAMS, M.D., F.R.C.P.

Professor of Midwifery in University College, London, &c.

**CANCER OF THE UTERUS: BEING THE HARVEIAN LECTURES FOR 1886.** Illustrated with Lithographic Plates, royal 8vo, 10s. 6d.

E. T. WILSON, M.B. OXON., F.R.C.P. LOND.

Physician to the Cheltenham General Hospital, &c.

**DISINFECTANTS AND ANTISEPTICS: HOW TO USE THEM.** In Packets of one doz. price 1s., by post 1s. 1d. [Just thoroughly revised.]

BERTRAM C. A. WINDLE, D.SC., M.D., M.A. DUBL.

Professor of Anatomy in Mason College, Birmingham, &c.

**A HANDBOOK OF SURFACE ANATOMY AND LANDMARKS.** Second Edition, revised with the collaboration of T. MANNERS-SMITH, M.A., M.R.C.S., Lecturer on Osteology, Mason College, Birmingham. With illustrations, post 8vo, 3s. 6d. [Now ready.]

EDWARD WOAKES, M.D. LOND.

Senior Aural Surgeon, London Hospital; Lecturer on Diseases of the Ear, London Hospital Medical College.

**ON DEAFNESS, GIDDINESS, AND NOISES IN THE HEAD.** Fourth Edition, Part I., with Illustrations, 8vo, 10s. 6d. [Now ready.]

OSWALD ZIEMSEN, M.D.

Knight of the Iron Cross, and of the Prussian Order of the Crown.

**THE TREATMENT OF CONSTITUTIONAL SYPHILIS.** Post 8vo, 3s. 6d.



**LEWIS'S DIET CHARTS.** A Suggestive set of Diet Tables for the use of Physicians, for handing to Patients after Consultation, modified to suit Individual Requirements; for Albuminuria, Anæmia and Debility, Constipation, Diabetes, Diarrhœa, Dyspepsia, Eczema, Fevers, Gall Stones, Gout and Gravel, Heart Disease (chronic), Nervous Diseases, Obesity, Phthisis, Rheumatism (chronic); and Blank Chart for other diseases. 5s. per packet of 100 charts, post free.

A special leaflet on the Diet and Treatment of Infants is sold separately. 12, 1s.; 100, 7s. 6d., post free.

**LEWIS'S FOUR-HOUR TEMPERATURE CHART.**

Meets the requirements of a chart on which the temperature and other observations can be recorded at intervals of of four hours. Each chart will last a week. 20, 1s.; 50, 2s.; 100, 3s. 6d.; 500, 14s.; 1000, 25s.

**CHART FOR RECORDING THE EXAMINATION OF URINE.**

Designed for the use of medical men, analysts and others making examinations of the urine of patients, affording a convenient method of recording the results of the examination. 10, 1s.; 100, 7s. 6d.; 250, 15s.; 500, 25s.; 1000, 40s.

**CLINICAL CHARTS FOR TEMPERATURE OBSERVATIONS, ETC.**

Arranged by W. RIGDEN, M.R.C.S. 12, 1s.; 100, 7s.; 250, 15s.; 500, 28s.; 1000, 50s.

Each Chart is arranged for four weeks, and is ruled at the back for making notes of cases; they are convenient in size, and are suitable both for hospital and private cases.

**LEWIS'S CLINICAL CHART, SPECIALLY DESIGNED FOR USE WITH THE VISITING LIST.** This Temperature Chart is arranged for four weeks, and measures 6 X 3 inches. 12, 6d.; 25, 1s.; 100, 3s. 6d.; 500, 16s. 6d.; 1000, 30s.

**LEWIS'S NURSING CHART.** Printed on both sides. 20, 1s.; 50, 2s.; 100, 3s. 6d.; 500, 14s.; 1000, 25s.

\* \* MR. LEWIS is in constant communication with the leading publishing firms in America and has transactions with them for the sale of his publications in that country. Advantageous arrangements are made in the interests of Authors for the publishing of their works in the United States.

MR. LEWIS'S publications can be procured of any Bookseller in any part of the world.

*Complete Catalogue of Publications post free on application.*

*Printed by H. K. Lewis, Gower Street, London, W.C.*

