A treatise on diseases of the eye : for the use of students and general practitioners : to which is added a series of test types for determining the exact state of vision / by Henry C. Angell.

Contributors

Angell, Henry C. 1829-1911.
Francis A. Countway Library of Medicine

Publication/Creation

Boston : Otis Clapp, 1891.

Persistent URL

https://wellcomecollection.org/works/qfk4km88

License and attribution

This material has been provided by This material has been provided by the Francis A. Countway Library of Medicine, through the Medical Heritage Library. The original may be consulted at the Francis A. Countway Library of Medicine, Harvard Medical School. where the originals may be consulted. This work has been identified as being free of known restrictions under copyright law, including all related and neighbouring rights and is being made available under the Creative Commons, Public Domain Mark.

You can copy, modify, distribute and perform the work, even for commercial purposes, without asking permission.

Wellcome Collection
183 Euston Road
London NW1 2BE UK
T +44 (0)20 7611 8722
E library@wellcomecollection.org
https://wellcomecollection.org

No. 28. D. 138.

BOSTON
MEDICAL LIBRARY
ASSOCIATION,
19 BOYLSTON PLACE.

Received Sept. 16. 1899.
From
~~Loaned by~~ J. J. Minot. M. D.

28. B. 138

Dr F. Minot

Compliments of

H. C. Angell

April 20 '91

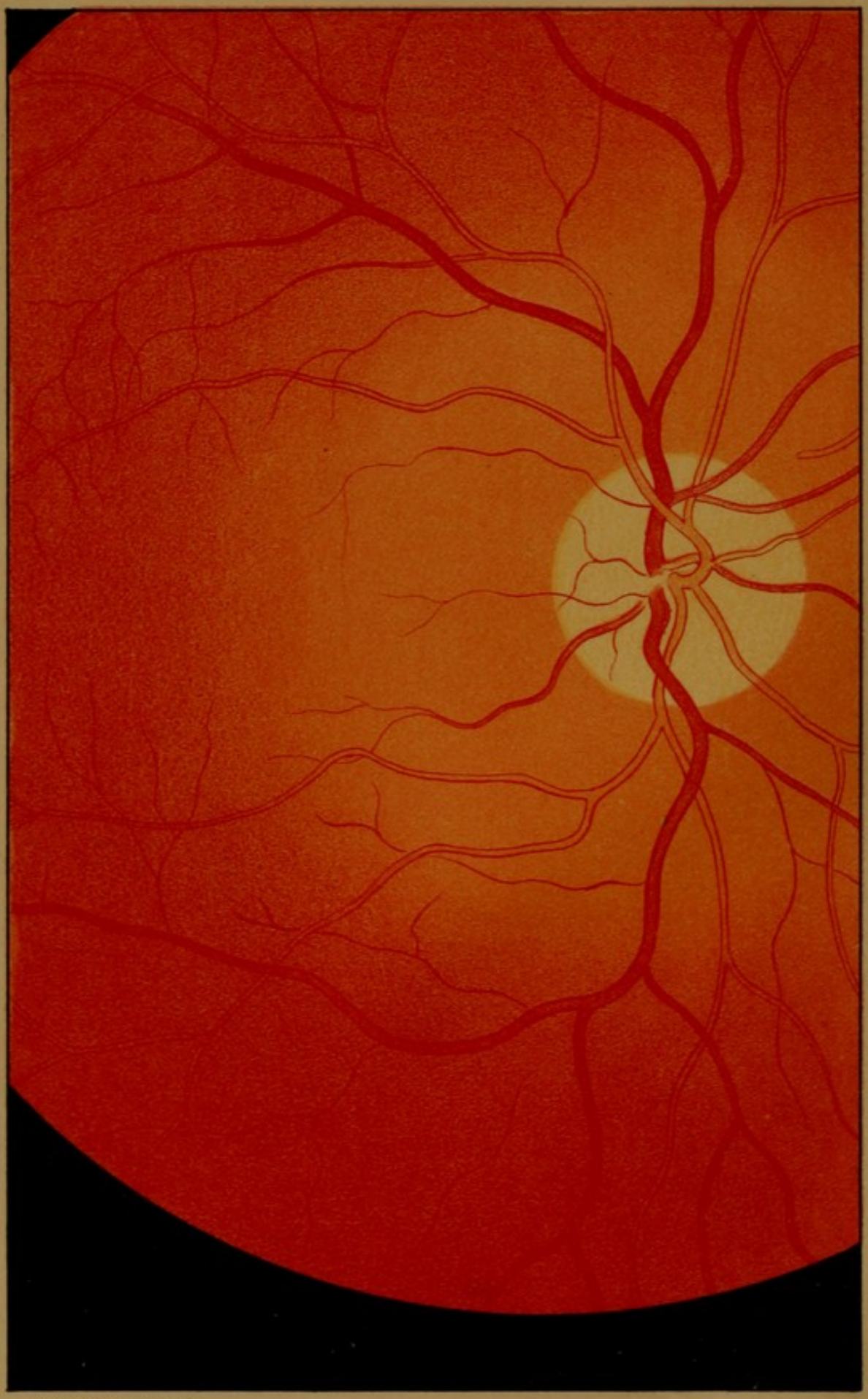

FORBES LITH. CO. BOSTON

The fundus of the eye as seen with the ophthalmoscope. After Von Jaeger, first published in 1856. The face of the optic disc should be more pinkish in color. The arteries of the retina are the lighter, the veins the darker vessels.

A TREATISE

ON

DISEASES OF THE EYE;

FOR THE USE OF

Students and General Practitioners.

TO WHICH IS ADDED

A SERIES OF TEST TYPES FOR DETERMINING THE EXACT STATE OF VISION.

BY

HENRY C. ANGELL, M.D.,

PROFESSOR OF OPHTHALMOLOGY IN THE BOSTON UNIVERSITY SCHOOL OF MEDICINE.

SEVENTH EDITION,

REWRITTEN AND ILLUSTRATED.

BOSTON:

OTIS CLAPP AND SON.

1891.

2019

Copyright, 1891,
By Henry C. Angell.



University Press:
John Wilson and Son, Cambridge.

PREFACE TO THE SEVENTH EDITION.

THE present edition is mostly re-written, and is more fully illustrated than its predecessors. It is also favored with contributions from my friend Dr. F. Park Lewis, of Buffalo. His articles are placed in brackets and marked by his initials.

As in former issues, the aim has been to make the book suitable for the use of physicians in general practice.

BOSTON, April, 1891.

PREFACE TO THE SIXTH EDITION.

THE sixth edition is remodelled and to a certain extent rewritten. As heretofore it has not been thought advisable to devote great space to the indication for the use of *internal* remedies. Such indications can be found elsewhere, and their consideration might easily be made to double or treble the size of the book. The main purpose of the work is to make the nature and diagnosis of ophthalmic affections comprehensible to the non-specialist, and after this, to teach how to avoid the bad, and how to avail of the good, in the topical, mechanical, and surgical treatment of the various defects and diseases of the eye.

BOSTON, January, 1882.

PREFACE TO THE THIRD EDITION.

An attempt has been made in this edition to bring the work up to date in ophthalmologic science, without materially increasing its size. Alterations or additions have been made in nearly every chapter, and a Glossary of scientific terms has been placed before the Table of Contents, which may be of convenience to students and others.

Boston, August, 1873.

PREFACE TO THE FIRST EDITION.

My readers are requested to bear in mind that this work is written, not for specialists, but for homœopathic physicians in general practice, — for those too busied with the whole to devote a great amount of time to any one part of medicine and surgery. The endeavor has been to treat the subjects embraced clearly and concisely, in the hope of presenting a volume attractive enough, and small enough, to induce the busiest to give it some attention.

. . . . . .

In the preparation of this work, I have had the advantage of copious notes taken during a somewhat prolonged attendance at the European clinics; and I have availed myself without hesitation, also, of the privilege of taking and appropriating whatever I have found desirable in the standard or periodical works devoted to ophthalmology.

Boston, March, 1870.

CONTENTS.

CHAPTER I.

PAGE

BRIEF SKETCH OF THE RISE AND PROGRESS OF OPHTHALMIC SURGERY 1

CHAPTER II.

ANATOMY AND PHYSIOLOGY.

The Eye, as a whole, best described by the use of Geographical Terms. — The different Tissues of the Globe. — Ciliary Muscle. — Optic Nerve. — Tenonian Capsule and Lymph Spaces. — Tears and Secretion of Conjunctiva. — Physiology of Vision. — Excitation of Nerves. — Act of Seeing. — Eye as an Optical Instrument. — Irremediable Optical Defects 5

CHAPTER III.

EXAMINATION OF THE EYES.

Objective and Subjective Examination. — Implements and Instruments. — Bandaging the Eye 26

CHAPTER IV.

THE OPHTHALMOSCOPE.

The Principle of. — How to use it. — What to observe. — Lateral Illumination. — Difficulties of Diagnosis formerly. — Importance of the Ophthalmoscope to the General Practitioner . . . 37

CHAPTER V.

REFRACTION, ACCOMMODATION, AND THEIR ANOMALIES.

PAGE

Myopia. — Hypermetropia. — Accommodative Asthenopia. — Astigmatism. — Cylindrical Glasses. — Muscular Asthenopia. — Presbyopia. — Prisms for testing the Equilibrium of the External Muscles 49

CHAPTER VI.

THE CONJUNCTIVA.

Passive Hyperæmia of the Conjunctiva. — Simple, Catarrhal, Purulent, Egyptian, Congenital or Infantile, Prophylaxis in Infantile, Gonorrhœal, Diphtheritic, Follicular, and Granular Conjunctivitis. — Pannus. — Scrofulous Ophthalmia. — Phlyctenular and Exanthematous Conjunctivitis. — Pterygium. — Pinguecula. — Warts, Cysts, and Dermoid Tumors and Hemorrhage of the Conjunctiva 94

CHAPTER VII.

THE CORNEA AND SCLERA.

Phlyctenular and other Forms of Keratitis: Ulcerations of the Cornea. — Staphyloma Anterior. — Conical Cornea. — Arcus Senilis. — Opacities of the Cornea. — Episcleritis. — Staphyloma of the Sclerotic 134

CHAPTER VIII.

THE IRIS.

Hyperæmia of the Iris. — Simple, Rheumatic, Suppurative, and Serous Iritis. — Prolapse of the Iris. — Cyclitis. — Artificial Pupil. — Mydriasis. — Myosis. — Action of Atropine. — Action of Eserine, Pilocarpine, Duboisine, Gelsemine, Homatropine, and Cocaine. — Iridodonesis. — Cysts of the Iris . . . 155

CHAPTER IX.

THE CHOROID AND VITREOUS.

PAGE

Hyperæmia of Choroid. — Simple, Disseminated, Syphilitic, and Suppurative Choroiditis. — Hyalitis, Simple and Suppurative. — Opacities of the Vitreous. — Muscæ Volitantes. — Hemorrhage into the Vitreous. — Synchysis. — Sparkling Synchysis. — Cysticerci of the Eye 172

CHAPTER X.

GLAUCOMA.

Acute, Subacute, Chronic Inflammatory, Chronic Non-inflammatory, and Absolute Glaucoma. — Glaucoma Fulminans. — Iridectomy. — Sclerotomy. — Other Operations for Glaucoma . 181

CHAPTER XI.

THE RETINA AND OPTIC NERVE.

Retinal Hyperæmia. — Retinitis Serosa, Exudativa, Albuminurica Syphilitica, Apoplectica, and Pigmentosa. — Detachment of Retina. — Glioma Retinæ. — Ischæmia Retinæ. — Paralysis of Retina. — Embolism of the Central Artery of the Retina. — Neuro-Retinitis. — Atrophy of Nerve 199

CHAPTER XII.

AMBLYOPIC AND OTHER AFFECTIONS.

Diagnosis of and Various Causes of Amblyopia. — Simulation of Blindness. — Hemeralopia. — Color Blindness. — Retinal Asthenopia. — Anæsthesia Retinæ — Neuralgia Oculi. — Effects of Electric Light 222

CHAPTER XIII.

THE CRYSTALLINE LENS.

PAGE

Cataract. — Complications with other Affections. — The Cause of Cataract. — Hard and Soft Cataracts. — Nuclear, Striated, Black, and Siliquose Cataract. — The Infantile, Lamellar, and Cortical Varieties. — The Various Operations by Extraction, Absorption, and Depression. — Secondary Cataract. — Capsular Cataract. — Dislocation of the Lens. — Traumatic Cataract. — Aphakia 235

CHAPTER XIV.

SPECTACLES — ARTIFICIAL EYES.

Cataract Glasses. — Pantoscopic, Prismatic, and Stenopaic Spectacles. — Eye Protectors. — Artificial Eyes. — The Dioptric System of Enumeration of Lenses 257

CHAPTER XV.

THE MUSCLES OF THE EYE.

Paralysis of all the different Muscles of the Eyeball, and of the Ciliary Muscle. — Spasm of Ciliary Muscle. — Strabismus, Convergent and Divergent. — Operations for the Division of the Muscles 263

CHAPTER XVI.

THE EYELIDS.

Blepharitis. — Acne Ciliaris. — Herpes Zoster Frontalis. — Ectropium. — Entropium. — Meibomian Cyst. — Other Tumors — Hordeolum. — Epicanthus. — Lagophthalmos. — Blepharospasm. — Ptosis 280

CHAPTER XVII.

THE LACHRYMAL APPARATUS.

PAGE

Epiphora and Stillicidium Lachrymarum. — Inflammation of Sac. — Blenorrhœa of Passage. — Stricture. — Dilatation of Sac. — Fistula. — The Probe, the Style. — Stilling's Operation. — The Lachrymal Gland 289

CHAPTER XVIII.

AFFECTIONS OF THE WHOLE EYE AND OF THE ORBIT.

Hydrophthalmia. — Medullary Cancer. — Grave's Disease. — Affections of the Orbit 302

CHAPTER XIX.

INJURIES OF THE EYE.

The Lids. — The Conjunctiva. — Anchyloblepharon. — Symblepharon. — Foreign Bodies within the Globe. — Use of the Magnet. — Injuries of the Cornea, the Iris, the Lens, the Sclerotic. — Hemorrhage into the Anterior Chamber. — Sympathetic Ophthalmia. — Sympathetic Irritation. — Removal of the Eye. — Division of the Optic and Ciliary Nerves. — Exenteration 305

CHAPTER XX.

THE EYE IN RELATION TO THE GENERAL SYSTEM.

In Diagnosis. — In regard to its own Integrity. — As a Possible Cause of Functional Nervous Disease 322

CHAPTER XXI.

PAGE

LIST OF A FEW INTERNAL REMEDIES, WITH THE OPHTHALMIC AFFECTIONS, OR THE SUBJECTIVE AND OBJECTIVE SYMPTOMS OF THE EYES, FOR WHICH THEY HAVE BEEN FOUND USEFUL IN THE PRACTICE OF THE WRITER.

External Remedies 330

CHAPTER XXII.

TEST TYPES.

First Series. — Second Series. — Tests for Astigmatism . . . 338

INDEX 349

GLOSSARY.

Refraction	The power of the eye to focus rays of light.
Accommodation	Power of the eye to adjust the vision for different distances.
Astigmatism	Irregular refraction, an optical defect.
Hypermetropia	Over-sight. Deficient refraction.
Myopia	Near-sight. Excessive refraction.
Presbyopia	Old-sight. Deficient accommodation.
Optical Defect . . .	Defective power of accommodation or refraction.[1] Error of refraction.
Ametropia	The general term for an optical defect of any kind, impairing vision.
Anisometropia	Unequal refractive power of the two eyes in a person.
Emmetropia	Without error of refraction. An emmetropic eye is supposed to be optically perfect.
Amblyopia	Impaired sight, not due to refractive errors alone. Obscure diseases of the fundus.
Optic Disc	Optic nerve at its entrance of the eye as seen with the ophthalmoscope.
Staphlyoma Posticum .	Bulging of the coats of the eye posteriorly around the optic disc.
Fundus	Back part of the interior of the eye.
Tension	Hardness or softness of the eyeball.
Diplopia	Double vision.
Photophobia	Intolerance of light.
Asthenopia	Weakness of sight.
The Media	The transparent cornea, lens, aqueous and vitreous humors.

[1] Exceptionally, "optical defect" may mean defective sight from disease of the transparent media, namely, corneal opacity, etc.

BOSTON MEDICAL
DEC 1 1899
LIBRARY.

DISEASES OF THE EYE.

CHAPTER I.

BRIEF SKETCH OF THE RISE AND PROGRESS OF OPHTHALMIC SURGERY.

It appears that the ancient Egyptians were the first to divide the practice of medicine and surgery into distinct departments, and that in those days there were practitioners who devoted themselves especially to the study and treatment of diseases of the eye and ear. Recently published translations from a work written a thousand years before the time of Hippocrates show that eye diseases were better known at that time than had been supposed. That greater progress was not made in medicine at that epoch is to be attributed to the primitive condition of anatomy and pathology, and to the fact that whatever knowledge of this kind existed was regarded as the exclusive property of its possessor, to be left like an heirloom to his family or his successor.

The Arabians, Greeks, and Romans possessed considerable information in regard to diseases of the eye; and Celsus, in the first century, wrote accurately on diseases of the eyelids, described pterygium, and an operation for its removal not unlike that practised at the present day.

After this we hear little of affections of the eye, until the beginning of the eighteenth century; and even as late as this, oculists were but itinerant quacks and lecturers who trumpeted their fame at fairs, in front of the booths in which they practised. There were female oculists also in those days. An author of that time says, "About five years since, I saw a woman in Holborn, by King's Gate, that had a dissolution of vitreous humor in the right eye, a narrowness of the inward chamber and immobility of the pupil, and half was dilated. The crystalline was opaque and shrunk in its bigness, pressed against the pupil and was of whitish-gray, by reason of the fibrous parts of its crooked and contracted segments, so that she could not perceive any light with that eye. She asked me if I could do her any good; I told her there was no hope, for she could not see the least glimmering because her cataract was accompanied with a gutta serena which was perfect. She told me that Mrs. Jones, a famous woman for couching of cataracts, would have couched her some years before." The same author writes of the "Cataplexia of the eye which Hippocrates speaks of," and goes on in this remarkable way: "Some call this the conick movement which is the parrexis or helcosis and abruption precision, or ulceration and solution of the continuity of the optic nerve, caused from a stroke, wound, or fall of humors or apostimation." He says further that the "Syntosis of Galen or the syntomosis is a collaption, compression, flabbiness of said nerve, which is affected by dryness," and so on. Some of the remedies in use only one hundred and fifty years ago

are equally remarkable. A scarificator was made of beards of barley tied into a little brush. Applications in common use were vipers' fat, gall of the eel and pike, a mixture of ants and honey, and applications of a less delicate nature. As original and curious as any, was the insertion in the eye of a living louse, of which it was remarked, that "it tickleth and pricketh and rendereth the eye moist and rheumatic."

Towards the middle of the last century the attention of the profession, especially in Germany, began to be directed towards the study of ophthalmology, and this awakened interest finally led, in 1773, to the foundation at Vienna, in connection with the University, of a department of ophthalmology. This school became famous for its successful and distinguished teachers, and in this respect flourished without a rival for many years.

About the year 1840, Dieffenbach, of Berlin, first practised his operation for strabismus, the success of which gave an impulse to the study of the physiology and pathology of the muscles of the eyeball.

We come now to the year 1851, the date of the discovery of the ophthalmoscope. From the very earliest times the luminosity of the eye, especially in the cat and the dog, had been observed, and had been regarded by the people with superstitious awe. In the year 1704, Méry saw the retinal vessels in the eye of a cat under water, but not until some years later was the cause of this luminosity properly referred to light received into the eye from without. Cumming, in 1846, came very near depriving Helmholtz of the honor of his great discovery ; and Reute, who improved the ophthalmoscope

in 1852 and rendered it practical, may be fairly said to divide the honor of its invention with Helmholtz.

Since the discovery of this instrument the progress of ophthalmology in all its branches has been not only rapid beyond precedent, but more rapid than the most sanguine could have hoped for. It is impossible here to more than allude to some of these great advances and their results. Recognition and accurate description of the different diseases of the optic nerve and retina, and their frequent connection with affection of the brain, heart, and kidney; diagnosis of diseases of the choroid and vitreous; classification of opacities of the lens giving rise to variety and improvement in operations for cataract; the operation of iridectomy, rendering glaucoma a curable disease; improved methods of making artificial pupil; rational surgical treatment of disorders of the lachrymal apparatus; demonstration of the laws of refraction and accommodation of the eye, which has been of incalculable value in the diagnosis and treatment of a large class of cases due to imperfect vision; the diagnosis and relief of astigmatism; the treatment of asthenopia and insufficiency of the ocular muscles; the progress in entoptics; the detection of cysticerci in the eye; the introduction of the use of atropine, eserine, and especially cocaine; the less indiscriminate use of caustics, — these and many other improvements in diagnosis and treatment, which I do not mention even by name, were and are the results of the marvellous impulse given to the study of disease of the eye by the discovery of the ophthalmoscope.

CHAPTER II.

ANATOMY AND PHYSIOLOGY.

ANATOMY.

It is proposed in this chapter to give simply the essential points in the anatomy and physiology of the eye, such as it would seem almost imperative that every student and practitioner should be familiar with.

GENERAL DESCRIPTION OF THE EYEBALL.

The spherical organ of vision, or globe of the eye, resting upon a cushion of fat within the orbital cavity, movable in all directions, directly communicating with the brain through the optic nerve, is best described, as a whole, by the use of geographical terms. The eyeball is the globe; the anterior pole, the centre of the cornea; the posterior pole, the centre of the fundus; and an imaginary line, passing through the centre of the globe, connecting the poles, is the axis. An imaginary plane, perpendicular to the axis dividing the globe into a posterior and anterior hemisphere, is the equator. The vertical meridian divides the globe into a nasal and temporal hemisphere, and the horizontal meridian divides it into a superior and inferior hemisphere.

The main envelopes or coats of the globe are three: the sclerotic and cornea, the choroid, and the retina.

THE SCLEROTIC, OR SCLERA,

is the outer and protective coat, and, if we include the cornea, may be said to completely cover the eyeball. It is fibrous in structure, a firm, dense membrane, provided with lymph channels, bluish-white in youth, as seen through the conjunctiva, and yellowish-white in adult or old age.

Posteriorly, the sclerotic is partly merged in the sheath of the optic nerve at its entrance into the eye, but a fine tissue from it and the choroid, interwoven with the neurilemma of the optic nerve, passes across the nerve entrance, being perforated like a sieve for the passage of the optic nerve fibres. This opening in the sclera is two millimetres (a millimetre being one twenty-fifth of an inch, or about half a line) in diameter, and the sieve-like membrane covering it is known as the lamina cribrosa. The sclera is rather more than a millimetre in thickness posteriorly, but becomes gradually thinner as it approaches the front of the eye, until it receives the tendons of the four straight muscles near the edge of the cornea. Anteriorly, the fibres of the sclera are merged in the cornea; and, near the periphery of the latter, it encloses a circular canal called the canal of Schlemm, which gives passage to a plexus of veins. Posterior to this canal, in the trabecular tissue near the junction of the iris and the membrane of Descemet are the lymph spaces of Fontana. The sclera is not rich in blood-vessels, and probably has no supply of nerves at all; but, near the optic nerve entrance, and anteriorly, near the cornea, it is pierced by so

many nerves and vessels for the supply of other parts of the eye, that its firmness in these places is considerably lessened.

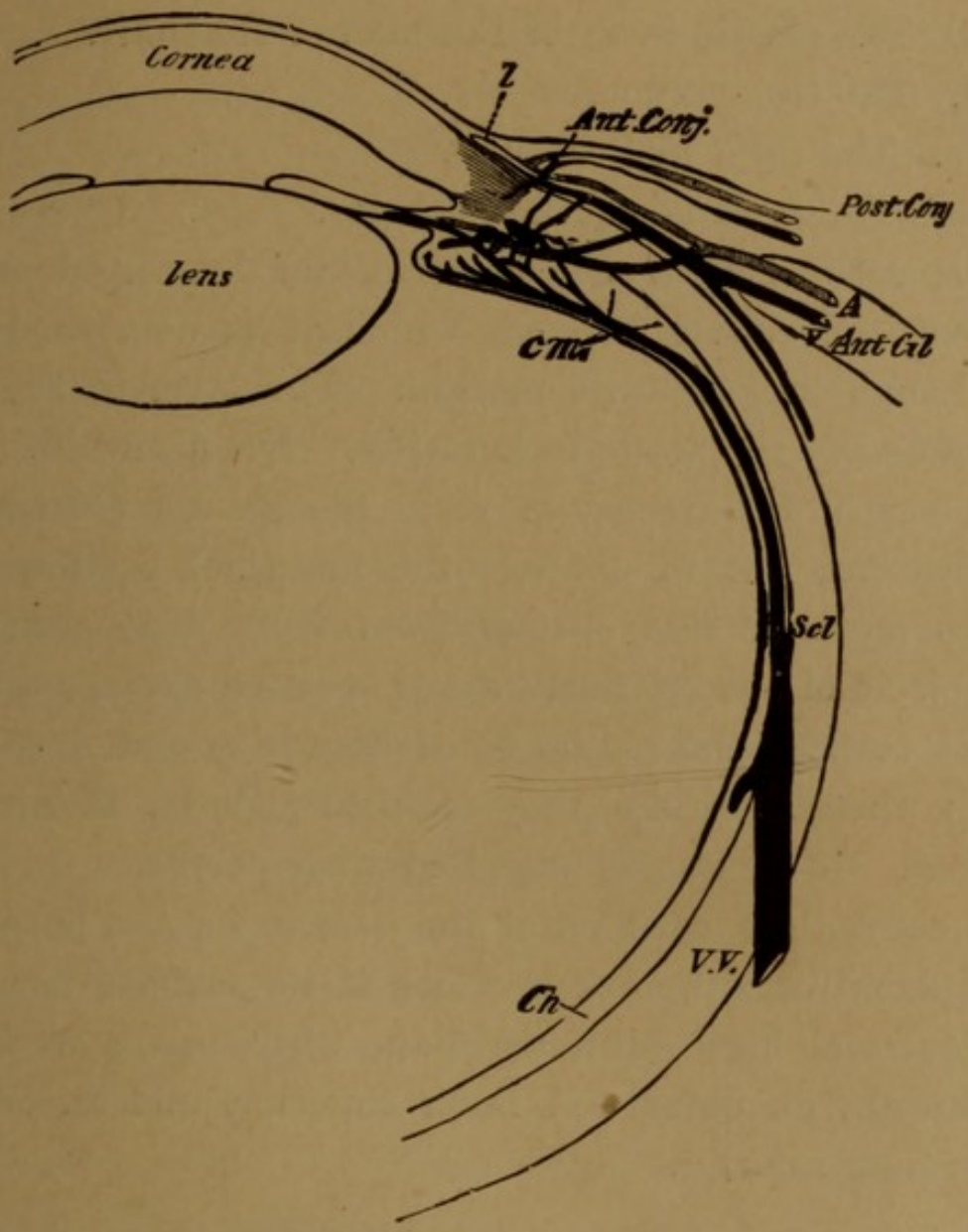

FIG. 3.

THE CORNEA,

which forms the transparent front of the globe, is curved so as to form a segment of a smaller sphere than the sclerotic. It is also a firm, dense membrane, and of about the same thickness as the sclera, but thinner

at the centre than at the periphery. It is divided into five distinct layers. From the outside we have: —

1st. The epithelial layer.

2d. The elastic layer of Bowman or Reichart.

3d. The true cornea.

4th. The layer of Descemet.

5th. The internal epithelial layer.

The corneal substance is permeated by a system of intersecting canals, through which it is nourished by the lymph vessels at its margin. The layer of Descemet does not suppurate in keratitis. See page 140.

In youth, the cornea is very, though not perfectly, transparent, but in old age the marginal portion becomes more or less opaque from fatty degeneration. The circle of opacity thus formed is called arcus senilis.

The cornea contains no blood-vessels except near its edge; when, therefore, they are seen upon it, disease is present. It is largely supplied with nerves.

A convenient division of the cornea, for the purpose of designating different portions of its surface, is by a vertical and horizontal meridian, which gives us four quadrants: an outer and inner superior, and an outer and inner inferior.

THE CHOROID, OR UVEAL TRACT.

The second coat of the globe is a vascular and pigment tunic, covering the eye posteriorly, and extending forward and forming a part of the ciliary body and the iris. These tissues together form what is termed the uveal tract. Like the sclera, it is pierced posteriorly to admit the optic nerve and the retinal vessels.

Anteriorly, a short distance in front of the equator, it is merged in a circle of plaits or folds, which, taken together, form the ciliary body. The choroid is divisible into four layers: beginning at the pigment layer of the retina, they are the vitreous, the capillary, the vascular, and the suprachoroidal layers. These layers are connected by cellular tissue more or less pigmented. The pigment layer, formerly described as being the inner choroidal layer, belongs to the retina. The chief vessels of the choroid are the venæ vorticosæ, the trunks of which pass out through the sclera in a very oblique direction, posterior to the equator. See Fig. 3. The choroid and inner surface of the sclera are connected loosely by a delicate elastic web; and the space within the meshes of this tissue, between the two coats, is called the perichoroidal space. The nerves of the choroid are parts of the third, fifth, and sympathetic. They are the long and short ciliary nerves, and both pierce the sclera near the optic nerve entrance, passing forward over the external surface of the choroid, forming at the ciliary region the ciliary plexus, which supplies the iris, ciliary muscle, cornea, and the ciliary blood-vessels. The blood supply is from the long and short ciliary arteries.

THE RETINA,

forming the third tissue of the globe, may be regarded as an organized expansion of the optic nerve. It is divided by recent authorities into ten layers; namely, the internal limiting layer, *the layer of nerve fibres*, the ganglionic, molecular, granular, inter-granular, exter-

nal granular, external limiting, *layer of rods and cones*, and *the pigment layer*. The three layers which I have italicized — the second, ninth, and tenth — are the layers of practical importance. The layer of nerve fibres is an expansion of the fibres of the optic nerve over the retinal surface. The radiation of fibres from the optic disk is not symmetrical, but, like the vessels,

FIG. 4.

chiefly upward and downward in direction and tending mostly towards the temporal portion, as shown in Fig. 4, after De Wecker and Von Jaeger. This layer is thicker around the nerve entrance, and gradually thins out as we approach the ora serrata. It is the conducting layer, and the ninth — the layer of rods and cones — is the percipient layer. The cones are directed towards the centre of the eye, the apex of each pointing backward, and resting on the tenth, or pigment, layer. This pigment layer — regarded formerly as a part of the

choroid — does not, like the nervous structure of the retina, stop in front, at the ora serrata, but passes forward, covering the ciliary body and the posterior surface of the iris. The macula lutea, situated at the posterior pole of the globe, corresponding in size to the optic disk, has in its centre a depression called the fovea centralis. The second, seventh, and ninth layers are found well represented at this spot, but the other layers are, to a great extent, wanting. The vessels of the retina, emerging from the optic disk, like the nerve fibres, pass chiefly upward and downward, curving towards the temporal side of the retina, dividing in an arborescent manner, avoiding always the macula lutea.

THE CILIARY MUSCLE.

A short distance in front of the equator, the choroid is arranged in small plaits or folds around the lens; and these ciliary processes, some seventy or eighty in number, form part of the ciliary body. The latter is made up chiefly of the ciliary muscle, covered by the choroid and the pigment layer of the retina. The ciliary muscle, or muscle of accommodation, has two sets of fibres: the anterior, which are circular; and the posterior, which are meridional.

The radiating, or meridional, fibres have their origin near the canal of Schlemm, and are lost in the choroid and ciliary processes. The development of this muscle differs greatly in different individuals, the myope having usually more meridional, and the hypermetrope more circular, fibres. The ciliary body is one of the chief secreting tissues of the eye.

THE IRIS

may be considered as a continuation of the choroid. It is the iridescent, exquisitely colored membrane, the opening in which is called the pupil, that hangs as a vertical screen in front of the lens. It is attached at its margin to the internal epithelial layer of the cornea at its junction with the sclera by the ligamentum pectinatum. The pupil is not exactly in the centre of the iris, but slightly below, and towards the nasal side. The iris is more muscular than the choroid. It has a sphincter muscle for diminishing, and probably a dilator muscle for enlarging, the size of the pupil. Posteriorly, the surface of the iris is covered by the pigment layer of the retina. Anteriorly, it receives an epithelial covering from the inner layer of the cornea. The iris is one of the extremely sensitive parts of the eye, being richly supplied with nerves as well as with blood-vessels.

THE CRYSTALLINE LENS

is suspended from the ciliary processes, directly behind the iris, and in contact with the pupillary margin. Posteriorly, it rests against the vitreous body which is hollowed out to receive it. It is a transparent, bi-convex body, enclosed in a transparent capsule, about nine millimetres in diameter, and three or four in thickness. It is laminated in structure, and more convex posteriorly. The centre, or nucleus, is harder than the marginal or cortical portion. The lens becomes harder and less elastic as life advances; and, by the same stages,

changes from a colorless substance in youth to a straw-color, and finally, in old age, to a brownish-amber tint. It also enlarges in size with advancing age, but if cataractous, becomes less in size and weight. For purposes of description, it may have, like the globe, a posterior and anterior pole, an equator, and, like the cornea, quadrants. The capsule is spoken of as the posterior and anterior capsule. The lens has neither vessels nor nerves.

THE ZONULE OF ZINN,

or suspensory ligament of the lens, is the medium by which the ciliary muscle acts upon the lens or its capsule in accommodation. It is a delicate, transparent tissue from the hyaloid, or investing membrane of the vitreous, which, in front, passes between the margin of the lens and the ciliary body, and is inserted into the anterior and posterior capsule, near the equator. The existence of circular fibres has recently been discovered in this tissue.

THE VITREOUS HUMOR (VITREOUS BODY)

occupies the entire posterior part of the globe between the lens and the fundus enclosed in the delicate hyaloid membrane. It is a jelly-like body, nearly colorless, and consists of about ninety-eight parts water. It has cells but neither vessels nor nerves. The hyaloid canal, containing a watery fluid, passes from the posterior capsule of the lens to the optic disk, directly through the vitreous.

THE AQUEOUS HUMOR

occupies the portion of the eye in front of the lens and posterior to the cornea called the anterior chamber. It also fills the small space between the posterior surface of the iris towards its periphery and the lens called the posterior aqueous chamber. It is nearly pure water, and, when evacuated, rapidly re-secretes.

SECRETION OF THE INTRA-OCULAR FLUIDS.

The capillary layer of the uveal tract is supposed to be the active agent in the secretion of these fluids which pass outward to the suprachoroidal space and also inward through the retina into the vitreous, thence through the lens to the Zonule of Zinn into the anterior chamber, mixing with the fluid secreted by the ciliary body and iris, and forming the aqueous humor. The exit is supposed to be chiefly through Fontana's spaces and the canal of Schlemm. From these openings it gradually passes through interfascicular lymph spaces in the sclera to the space of Tenon and thence to the vaginal spaces of the optic nerve.

THE OPTIC NERVE

has its origin in two roots, chiefly from the corpora geniculata, but also from the thalmus opticus and the corpora quadrigemina. At the optic commissure, or chiasma, there is a complicated intercrossing of the nerve fibres, as explained on page 220. The nerve brings with it from the brain an inner sheath, or neurilemma, the delicate fibres of which enclose a capillary

network of blood-vessels from the pia mater. A second sheath, received after the nerve enters the orbit from the dura mater, divides into two layers; one lining the orbit, the other forming the external sheath of the nerve. The intervaginal space is found between the two layers of the sheaths of the optic nerve, and is continuous with the arachnoid cavity. There is also a supravaginal space between the sheath of the nerve and the neurilemma, and a perineural space between the neurilemma and the nerve itself. These spaces connect with the lymph spaces of the eye. The entrance of the nerve into the eye is about four millimetres distant from the posterior pole of the globe, towards the nasal side, and just below the horizontal meridian. The orbital portion of the nerve is rather more than one inch in length.

THE CONJUNCTIVA,

covering the front of the eyeball, called the ocular conjunctiva, extends back nearly to the equator, and is there reflected on to the inner surface of the eyelids. It is loosely attached to the sclera, except at the corneal margin, and is throughout very vascular. Towards the inner canthus is a fold called the plica semilunaris, a rudiment of a third eyelid; and still nearer the inner angle is the caruncle.

The conjunctiva of the lids is called the palpebral, and that of the edge of the lids, the tarsal conjunctiva. The posterior portion of the conjunctival sac, where it passes from the globe to the lids, is known as the retrotarsal fold, or cul de sac, or fornix. The conjunctiva

is a mucous membrane, vascular, transparent, and, with the exception of the ocular portion, thickly studded with papillæ, which increase in size as we approach the retro-tarsal fold. Here are also the glands of Krause. It is also richly furnished with blood-vessels and nerves, the latter chiefly from the tri-facial, or fifth.

THE EYELIDS

have for their base a thin plate of cartilage (so-called, although it is not cartilage proper, but rather a dense connective tissue), convex anteriorly, so as to fit the globe. Externally they are covered by the orbicularis muscle and integument, and internally by the conjunctiva. Beneath the external muscular covering is a connective adipose tissue, in which, near the margin of the lid, are the follicles of the cilia, or eyelashes, the sebaceous glands, and the glands of Henle. Within the cilia are also the orifices of the Meibomian glands, from which an oily matter exudes to present a barrier against the overflow of tears. The Meibomian glands are plainly visible beneath the conjunctiva; and this circumstance is often serviceable in diagnosis and treatment of disease of the conjunctiva. (See page 101.) The levator palpebræ superioris springing from the apex of the orbit is attached to the upper edge of the tarsus, and is supplied by a branch of the third nerve.

THE LACHRYMAL PASSAGE.

On the margin of each lid, near its inner angle, is situated the punctum lachrymalis, the delicate opening into the canaliculus leading in a horizontal direction to

the lachrymal sac. The canaliculi, which usually meet before reaching the lachrymal sac, are about six millimetres long, and the sac which lies in the lachrymal groove, or canal, is about ten millimetres, and its continuation, the nasal duct, is of the same length. The size of these passages is further spoken of in Chapter XVII. Horners' muscle lies behind the lachrymal sac.

THE LACHRYMAL GLAND

is placed in the lachrymal fossa, near the outer angle of the roof of the orbit. It secretes the tears, which reach the eyeball through six to twelve minute ducts opening into the conjunctiva at its reflected portion lying underneath the gland.

The tears, however, as we find them in the conjunctival sac, are made up of the secretion of the lachrymal gland plus the secretion of the conjunctiva. The latter secretes a lachrymal fluid, or tears, as well as mucus, so that the eye is still moistened, and the transparency of the cornea preserved, even if the lachrymal gland be extirpated.

THE TENONIAN CAPSULE AND MUSCLES OF THE GLOBE.

The Tenonian capsule is a smooth, fibrous membrane or texture, loosely embracing the globe, enveloping or ensheathing the muscles, vessels, and nerves that pass through it, having its origin in the sclera, in a circle posterior to the equator, near the entrance of the ciliary nerves, so that, posterior to this, is a free space on the sclerotica, in the centre of which is the entrance of the optic nerve. Anteriorly, this capsule loses itself

in the conjunctiva near the cornea. The four recti muscles of the globe — the externus, internus, superior, and inferior — have their origin at the apex of the orbit, pass forward, and are inserted by tendons about eight or nine millimetres in width into the sclera near the cornea. The line of insertion of the internal rectus is about five millimetres from the corneal margin, but the insertion of the other straight muscles is slightly further back. Where these muscles pierce the Tenonian capsule near their insertion, they receive a sheath from it which is carried forward, and inserted with the tendon into the sclerotic. Between the layers of the Tenonian capsule is a lymph space in connection, as proved by injections, with the perichoroidal lymph space, and, as I have stated, with the intervaginal spaces around the inner sheath of the optic nerve, and thence with the arachnoid cavity of the brain. The superior oblique has its origin with the recti muscles, runs forward through its pulley at the inner and superior angle of the orbit, and then passes under the superior rectus to its insertion in the posterior hemisphere, near the upper edge of the external rectus. The inferior oblique has its origin at the inner angle of the orbit, near the opening for the nasal duct, and, passing beneath the inferior rectus, is inserted into the posterior hemisphere, between this muscle and the rectus externus. The action of these muscles on the globe, and the nerves with which they are connected, are spoken of in Chapter XV.

PHYSIOLOGY OF VISION.

It has been already remarked that the retina is the perceptive, or, more properly speaking, the receptive, part of the visual organ, while the optic nerve completes the act of vision by carrying the retinal impression to the brain. The cornea, lens, and humors, called as a whole the refracting media, being transparent, permit the passage of the rays of light, and, having convex surfaces, bring them to a focus upon the retina. It is obvious, therefore, that either a failure of the optic nerve to convey impressions, or any disease of the retina destroying its receptive function, must occasion blindness. A loss of transparency in the refracting media, by preventing the rays of light from reaching the retina, is also fatal to vision.

THE EXCITATION OF NERVES

is produced through mechanical, chemical, electric, or thermometric changes. The retinal nerves are excited by rays of light, as the auditory nerves by waves of sound, the nerves of the sense of touch by contact; and, the result of this excitation being conveyed to the brain, we have the perception of sight, hearing, or touch. All nerves are apparently similar in structure; all convey impressions, when excited, at the rate of about one hundred feet per second towards either end of their fibres, the nature of the sensations conveyed depending not upon the nature of the agent employed, but entirely upon the organ with which they are connected. Motor nerves, when irritated, produce move-

ment, because connected with muscles; glandular nerves, secretion, because connected with a gland; sensitive nerves, sensation, because belonging to organs of sensation. It follows, therefore, that any of the agents of excitation mentioned, if they could be brought to bear upon the nervous portion of the retina, might produce the subjective sensation of sight. Thus, pressure of the side of the eyeball with the finger, or a weak electric current through the eye, gives an impression of light to the eye, although no light is present. So disease of the eye or brain, or narcotic drugs, produce similar phenomena. The retina and optic nerve being infinitely more sensitive to rays of light than any other nerve-structure of the body, and being in constant functional activity from this excitation, we naturally connect the *sensation* of light with the *presence* of light, even if no light be present.

THE VISUAL PURPLE

is due to a red-purple color in the outer part of the retina. It cannot be seen with the ophthalmoscope. On exposure of the eye to light, this color pales; but darkness reproduces it. It is produced by a secretion of the epithelial pigment cells of the retina; but as its increase or decrease does not correspond to the retinal current of liquid from the suprachoroid, it is not supposed to be of direct importance to vision.

THE ACT OF SEEING,

when we take into account its complicated nature, is accomplished in an extraordinarily short space of time.

The luminous waves of light, moving with a velocity of 200,000 miles per second, strike the retina, are translated into molecular vibrations of nervous matter, which in turn are converted by the brain into a sensation of vision. It has been estimated that the above changes, constituting the act of seeing, require no more than the four billionth part of a second for their performance. Letters upon a printed page lighted by an electric spark have been seen in forty-eight billionths of a second.

It is supposed that each rod and cone conveys its own portion of the retinal picture to the brain, so that the well-known fact that the picture as a whole, upon the retina, is reversed or inverted, offers no bar to our comprehending the fact that the brain perceives the object in its true position. This phenomenon would be inexplicable, if the retina as a whole were supposed to convey the picture.

BINOCULAR VISION.

It is also necessary in binocular vision that the image of the object should be caught by nearly corresponding points of the two retinæ.

When the two eyes are directed towards a distant object, their visual axes are practically parallel; but, if we regard an object at a distance of eighteen inches, the two axes converge at an angle of about eight degrees. With each eye separately, therefore, we see near objects from slightly different points of view. If we regard the frustum of a solid cone, we see more of the right side of it with the right eye and more of the left side with the left eye. The mental combination of the two differ-

ent perspective views gives us the idea of solidity, or a third dimension, thickness. Distance, which is the equivalent of this third dimension, is also determined by vision with both eyes. The difficulty of snuffing a candle with one eye closed is well known. We judge of distance by the muscular sense of the effort that converges the optic axes, somewhat as we judge of the weight of an object by the muscular effort required to raise it.

THE EYE AS AN OPTICAL INSTRUMENT

is by no means so perfect as generally supposed. Myopia, hypermetropia, and astigmatism are optical defects of a large minority of mankind, and are more or less remediable by proper treatment. These are considered elsewhere; but there are certain defects common to all eyes which may be styled

IRREMEDIABLE OPTICAL DEFECTS.

These are given by Helmholtz, and are chiefly as follows: —

a. Lack of perfect transparency in the cornea and lens, and fluorescence of both. A strong light concentrated on the cornea and lens will show each to be less clear than the aqueous between them. Fluorescence is the property that some substances have of becoming faintly luminous from blue or violet light. The bluish tint of a solution of quinine in water is an example of fluorescence. A blue light thrown into the eye shows the same haziness in the cornea and lens, and the phenomenon is supposed to be due to the presence of

quinine or some similar substance in these structures. These parts of the eye are therefore inferior to the clear and perfectly transparent lenses used by the optician in the manufacture of optical instruments.

b. Spherical aberration, due to lack of correspondence of the axes of the cornea and lens, to the lack of symmetry in the former and the peculiar structure of the latter. This constitutes a slight astigmatism, the nature of which is noticed elsewhere.

c. Achromatism or chromatic dispersion of rays. The solar rays being made up of the different colors of the spectrum and each color being refracted in a different degree by the same medium, they are not united by it in a single focus. Look at a street lamp at a distance through a violet-colored glass. This stops the intermediate green and yellow rays, and allows the first and last rays, the violet or blue and the red, to pass into the eye. The result is that the red is focussed, but the violet and the blue are seen in a broad halo around the red gas-light. The reason this defect is not oftener remarked is that the intermediate rays of the spectrum being brighter, the less luminous red and blue are scarcely noticed beside the intense images of the others. Optical instruments are free from this defect.

d. Slight color-blindness is common to all eyes. The eccentric portion of the retina does not perceive green and red as soon as other colors. If we test the field of vision as described on page 37, we shall find that the *color* of a red object is not recognizable as far away as the outline of it. The eye also fails to distinguish a difference between a white produced by the union of

scarlet and bluish-green light, and a white produced by a yellowish-green and violet; yet the first comes out black in a photograph, the latter very bright.

e. The *distinct* part of the field of vision is very small; the entire field of vision of an optical instrument is very limited in extent, but distinct in every part.

f. Muscæ volitantes. These are noticed elsewhere.

g. The blind spot in the retina, due to the space occupied by the entrance of the optic nerve. Make a small cross on a sheet of white paper, and three inches at the right make a black dot. Shut the left eye, and, holding the paper at arm's length, fix the right eye on the cross; on bringing the paper gradually nearer, it will be found that at about eleven inches from the eye the dot will not be seen. The blind spot is sufficiently large to hide the face of a man at six or seven feet.

h. There are also gaps in the field of vision caused by the blood-vessels of the retina. These vessels running in front cast a shadow on the layer of rods and cones which lies farther back. The splits in the visual field may be recognized by looking at the sky through a delicate pin-hole in a card, moving the latter from side to side at the time.

i. The yellow spot, the most sensitive point of the retina, is by virtue of its yellow tint unable to recognize weak blue light. The smaller stars are seen better by astronomers if they look slightly at one side rather than directly towards them.

This formidable array of common optical defects is unnoticed by us, chiefly because, having two eyes, one makes up for the temporary visual disturbance in the

other; even with one eye, these defects are rarely noticed, owing to the great mobility of the eye and its continuous change in direction, and to the fact that the imperfections are mostly away from the centre of the field of vision. Habit, inattention, experience, the power of accommodation, may also be given as reasons why our natural visual defects are unobserved. Nevertheless, these optical defects do exist in all eyes; and, as Professor Helmholtz observes, if an optician offered for sale an instrument with these defects, one would be justified in refusing to buy it.

CHAPTER III.

EXAMINATION OF THE EYES.

OBJECTIVE EXAMINATION.

AFTER a glance at the exterior aspect of the lids, their margin, the cilia, the general appearance of the eyeball as to position or prominence, we may turn our attention to the different tunics of the globe which permit of examination from without. For this purpose a good light is necessary, and the best, generally speaking, is that which falls obliquely on the eye of the patient from a very near window. A still stronger light may be had, when necessary, by *lateral illumination*, as explained in the chapter on the Ophthalmoscope. If we suspect a foreign body, if conjunctivitis with discharge be present, if the lids seem thickened, if any sensation is complained of beneath the upper lid, if there is enlargement of the mucous papillæ of the lower lid, the upper lid should be reversed. This proceeding requires but a moment, can never do harm, and may often give us at once the key to the difficulty.

To reverse the upper lid it is merely necessary to raise it slightly with the thumb of the left hand, then seizing firmly the central cilia and edge of the tarsus between the forefinger and thumb of the right hand, the lid is pulled slightly downward and away from the

eyeball, and while the patient is requested to look downward, at this instant the lid is tilted over the point of the left thumb, which is used as a fulcrum. If necessary, a probe may be used as a fulcrum, placing it half an inch above the margin of the lid and parallel with it. The signification of the various kinds of redness of the eye is noticed under simple conjunctivitis. The surface of the cornea should be carefully scrutinized for delicate opacity, ulceration, abrasion, or unevenness.

A few weeks since a young lady called for me to aid her in the selection of suitable glasses. She did not see well at a distance. There was no refractive error; nor could I find any abnormal condition of the eye whatever. I thought of old opacity of the cornea, but did not find it. After learning, however, that in childhood she had suffered from an affection which was undoubtedly a purulent ophthalmia, I felt positive that the cornea must be at fault. On taking her again into a darkened room, and re-examining the surface of the cornea by oblique illumination, *and comparing her eyes* under the strong light with those of her companion, I discovered a delicate cloudiness in both corneæ. Without the aid of lateral illumination and the comparison with the perfect cornea of a normal eye, the haziness might have escaped detection.

The size of the pupil, its form, its mobility, and the color of the iris should be noticed. The mobility may be tested by closing the eye and then raising the upper lid gently with the thumb, observing the reduction in the size of the pupil as the light strikes the eye, or by

shading the open eye with the hand, then removing the hand quickly. In either of these experiments the eye not under examination must be closed, to avoid sympathetic influence between the two. If the pupil is sluggish in movement, or does not appear exactly circular, if the iris is at all discolored, we should drop into the eye a solution of atropine (one or two grains to the ounce of water), in order to determine whether there is adhesion between the posterior surface of the iris and the anterior surface of the capsule of the lens. If adhesions exist, the enlarged pupil will be irregular in form. It is sometimes necessary to use a solution of atropine stronger than this, of four or six grains to the ounce, when the iris is diseased, in order to affect the size of the pupil sufficiently. See article on Mydriasis. The appearance of the surface of the iris may be abnormal as to color, texture, plastic deposits, and condylomata. The significance of these objective examinations and their details will be found when we come to speak of the diseases of the various structures of the eye.

Tension or *hardness* of the eyeball is to be noted in order to determine the degree of intra-ocular pressure. It is determined by gentle pressure through the closed lids upon the eyeball with the tip of the forefinger. The two eyes may be compared, or a sound eye with the diseased one, in order to fix the degree of hardness or softness with more accuracy. Signs to denote the amount of intra-ocular pressure are sometimes used. Thus: T. 1, T. 2, T. 3, indicate first degree or slight, second degree or considerable, third degree or extreme tension (hardness) of the ball; while Tn., T? indicate tension

normal, tension doubtful. The same letter and figures preceded by the sign minus mean reduced tension or softness of the globe. Thus: T — 1, first degree of reduced tension.

The mobility of the eye is to be tested by requesting the patient to follow the finger, which is moved in various directions, in order to detect paralysis of any muscle. And the strength of the external muscles may be further tested, if desired, by prisms. See pages 85, 88.

SUBJECTIVE EXAMINATION.

The Pain.

The nature, seat, and severity of the pain complained of by the patient are of importance as an aid to diagnosis and *a fortiori* to the selection of appropriate remedies. A dull pain in and around the eyeball, with a sensation of heat, the pain very much increased by using the eye, points to asthenopia. Smarting and burning, or a sensation as if sand were in the eye, indicate a conjunctivitis. Severe pain with photophobia and lachrymation denotes sensitiveness of the ciliary nerves, as in deep-seated conjunctivitis, corneitis, iritis, or any inflammation affecting the ciliary region, at the junction of the cornea and sclerotica. Deep-seated pain in the eye, or just above it, recurring periodically, accompanied by dimness of vision, is to be seriously regarded, and is characteristic of beginning glaucoma.

The severity of the pain, however, is not alone a safe criterion by which to judge the gravity or slightness of an affection of the eye. When present, it helps us to

determine the nature of the disease, but it may be absent sometimes in the most serious cases, such for instance as glaucoma, amaurosis, or choroiditis.

Photophobia, with no pain, or appearances of inflammation externally, indicates hyperæsthesia retinæ — too great a sensibility of the retina. Retinitis, by itself, is a rather rare disease, and would be characterized by a want of sensibility and the necessity of a strong light to see distinctly.

The State of the Vision.

The visual power of a diseased eye is an important diagnostic point in the examination. This may be determined by the use of the test types annexed to this volume. If the patient reads No. 1 or 2 readily, and also the letters of No. 12, 15, or 20, at twelve, fifteen, or twenty feet respectively, with the naked eye or by the help of suitable spectacles, his sight is perfect. His visual power = 1. Good sight for a few moments followed by confusion of vision, suggests asthenopia. Rapid diminution of vision as objects recede from the eye, points to myopia. Lack of clearness in regarding objects near and distant, indicates hypermetropia or astigmatism. Defective sight for near objects and normal vision for distance, is characteristic of presbyopia. Cloudiness of sight, improved towards night and in dull weather, suggests cataract. If "spectacles never did any good" we think of astigmatism; then amblyopia, and serious internal disease of the eye will be thought of if glasses have recently needed frequent changing, or become unserviceable. If the patient cannot see the

largest sized letters, he may be able to count fingers held quite near the eye. Failing in this he may distinguish between light and darkness. Seat him before a window, and then interpose between his eyes and the light some dark object of sufficient size; or a still better test, because it admits of measurement, is to take the patient into a room from which daylight is wholly excluded. He may be able to point in the direction of the lamplight, even if it is quite dim; or he may be able to discern it only when it is very brilliant, or he may not be able to see it at all. If he cannot tell with certainty, whether we shade it from him or whether it shines full in his face, there is no vision to be improved. In these experiments, if one eye alone is being tested, the other should be covered with a folded handkerchief so as to exclude the light from it. A healthy eye will distinguish light from darkness with the lids firmly closed.

The Field of Vision.

The extent of the field of vision, about 90° outward, 55° inward and downward, and 45° upward, may be determined by directing the patient to look steadily at one finger held before his eye at a distance of eighteen or twenty inches. We then move our other hand about at a distance of two feet below, above, and on each side, from the finger towards which the patient is steadily to look, noting whether he sees the hand or can count the fingers. The finger which we hold up is at the centre of the visual field and it may be necessary to bring the other hand very near to this before it can be

seen. A few weeks since, I found the field of vision so much narrowed in a case of *retinitis pigmentosa* that the patient could not distinguish an object moving until it came within an inch or an inch and a half of the centre of the field, showing that only a part even of the yellow spot itself retained its normal function. A normal eye will distinguish an object moving at a distance of from two to three feet from the central point of vision. The field of vision may be mapped out when great accuracy is desirable. Put the patient before a blackboard, at the distance of fifteen inches; make a dot for him to fix the eye on; then approach a piece of chalk in a long black handle from different directions, recording always the point where the chalk is first perceived by a dot; afterwards unite these dots by a continuous line, and the boundaries of the field of vision are sketched. There is also an instrument for accurately measuring the field of vision, called a Perimeter.

Diplopia.

Double images occur in paralytic strabismus, and frequently after an operation for the cure of concomitant strabismus; it also occurs sometimes in heterophoria. See page 89. Monocular diplopia is a result of irregular refraction from abnormal curvature of the cornea or lens, of mal-position or dislocation of the lens, of inequalities of the corneal surface from old cicatrices, or of bands of membrane stretched across the area of the pupil. We may readily produce double images by holding a convex lens of medium strength partly before one eye so that we may look through it and not through it at the same time, at objects across the room.

IMPLEMENTS AND INSTRUMENTS.

Trial Glasses.

Complete sets of trial glasses, or spectacles, are necessary for those who propose to prescribe suitable glasses for the various optical defects. The selection of proper glasses for patients is a very important and responsible duty, and should not be undertaken unless the practitioner is disposed to give sufficient attention to it to do it in a scientific manner. Let the haphazard selection of glasses be left to the itinerant vender and optician. The proper glass having been determined, its number and kind are to be written out and presented by the patient to a respectable optician. A complete outfit of trial glasses comprising the convex and concave, spherical and cylindrical, the prismatic and the colored, will amount to some two hundred, or the equivalent of a hundred pairs of spectacles. See Fig. 5. To such as do not propose a more or less complete equipment for the above purpose, I would suggest a few glasses merely as an aid in diagnosis.

Weak convex lenses, of thirty, forty, and fifty inches focus, will help to determine a hypermetropia, or a beginning presbyopia. If the patient sees No. 20 at twenty feet as well with as without, or better with than without either of the glasses, he is hypermetropic. In beginning presbyopia the same glasses should aid in reading the No. 1 print. Ordinary concave glasses will aid in the differential diagnosis of a slight myopia and hypermetropia. Through concaves of thirty or forty inches focus, a myope should see distant objects more

clearly, and a hypermetrope less clearly. The same spherical convex or concave glasses will aid in determining an astigmatism, in connection with the metallic plate and slit. A slip of colored glass will be useful in

FIG. 5.

testing double images, and a few prisms are necessary to measure the strength of the ocular muscles when this is desired.

The ophthalmoscope perhaps ought now to be consid-

ered indispensable to the general practitioner. Very necessary also are a pair of silver lid-elevators (Fig. 6),

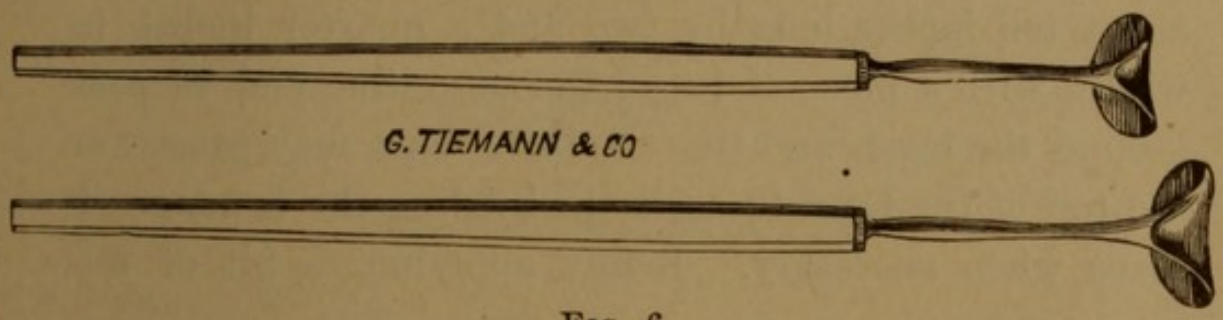

FIG. 6.

and for the extraction of foreign bodies embedded in the cornea, a wire speculum, self-adjusting (Fig. 7), a

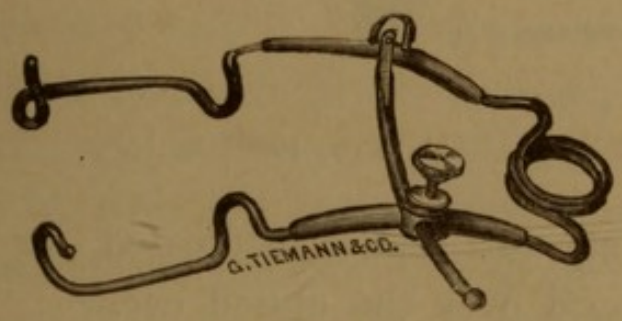

FIG. 7.

fine needle and a delicate spatula, spud or grooved needle (Figs. 8, 9), and a pair of delicate forceps for



FIG. 8.



FIG. 9.

steadying the eyeball are useful. The Snellen eyelid tourniquet is an almost indispensable aid in removing cysts of the lids. Fig. 10, on the next page.

Bandaging the Eye.

The ordinary bandage may consist of a piece of linen about ten inches long by two and a quarter inches in width, with a piece of broad tape at either end to pass around the head, and tie. A third tape may pass over the top of the head to assist in holding the bandage in place when necessary. Before applying, a bit of ab-

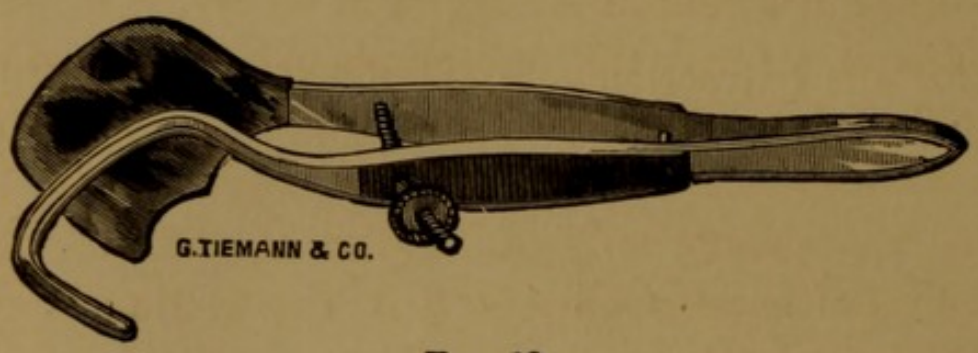

FIG. 10.

sorbent cotton, anti-septic, medicated, or otherwise, should be placed over the closed eye.

The compress bandage should be one and three-quarters yards in length and about one and a half inches in width, and made of linen, or, still better, fine elastic flannel. To apply it, commence above the affected eye, pass it across the forehead to the opposite side, above the ear, to the back of the head, below the ear, then up across the affected eye, and pin it securely to the first portion upon the forehead.

CHAPTER IV.

THE OPHTHALMOSCOPE.

In order to see into the interior of an eye, it is necessary first of all that the interior should be lighted up. The old notion that an eye under certain nervous conditions becomes luminous from within is not correct. It can be illuminated only by light from without. The second condition necessary is, that, having thrown rays of light into the eye under examination, we should place our own eye in such a position relative to the one illuminated, as to catch the reflection of the rays of light which we have thrown in. These two conditions are absolutely necessary, and any further ones merely add to the convenience of examination or render our examination more accurate. With a bit of common window-glass we can fulfil these two conditions. Seat the patient in a darkened room with a lighted lamp by his side, the flame about on a level with the eye to be examined. This fragment of glass held in front of the pupil, and quite near the eye under examination, throws a sufficient light from the lamp directly into his eye. This fulfils the first condition. The eye is illuminated. Now put your own eye behind the glass directly opposite that of the patient, and it will catch the return rays passing from his eye through the glass into yours, and

you will see the entrance of the optic nerve, or optic disc as it is termed, and the vessels of the retina passing over and away from it. (See plate opposite titlepage.) The fragment of glass is in reality an ophthalmoscope, all ophthlamoscopes are merely modifications of this, and and do not differ from it in principle. It has been found more convenient, however, to substitute a mirror for the plane glass, with a small hole at its centre for the eye of the observer. The mirror may be plane, convex, or concave. A concave mirror reflects more light into the eye, and hence renders the details of the fundus more

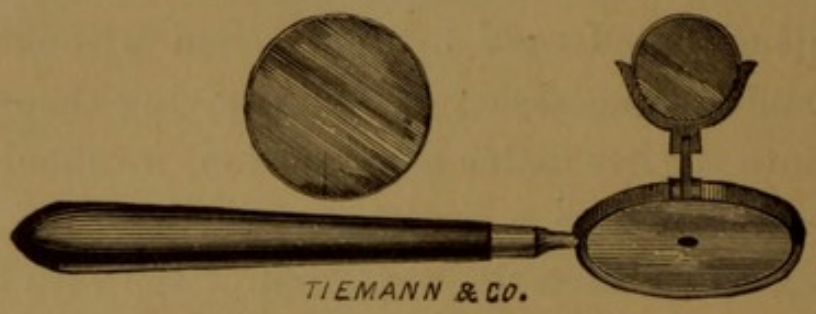

Fig. 11.

distinct. To the same end also it has been found serviceable in practice to hold immediately before the observed eye, with the left hand, a convex glass of about two inches focus. This convex lens enlarges the field of vision; and, although we get an inverted image, on the whole it facilitates an examination so much as to render its use almost indispensable in the examination of the deeper structures of the eye. There are some forty or fifty different kinds of ophthalmoscopes in use. The one most common, and to be commended, is that of Liebreich (Fig. 11), though oculists use the more costly and complicated ones of Loring or Knapp. It con-

sists of a metallic mirror slightly concave, about an inch and an eighth in diameter, set in a metallic frame, with a handle which pushes into itself so as to be no more than two inches in length when not in use, and convenient for the pocket. In the centre of the mirror

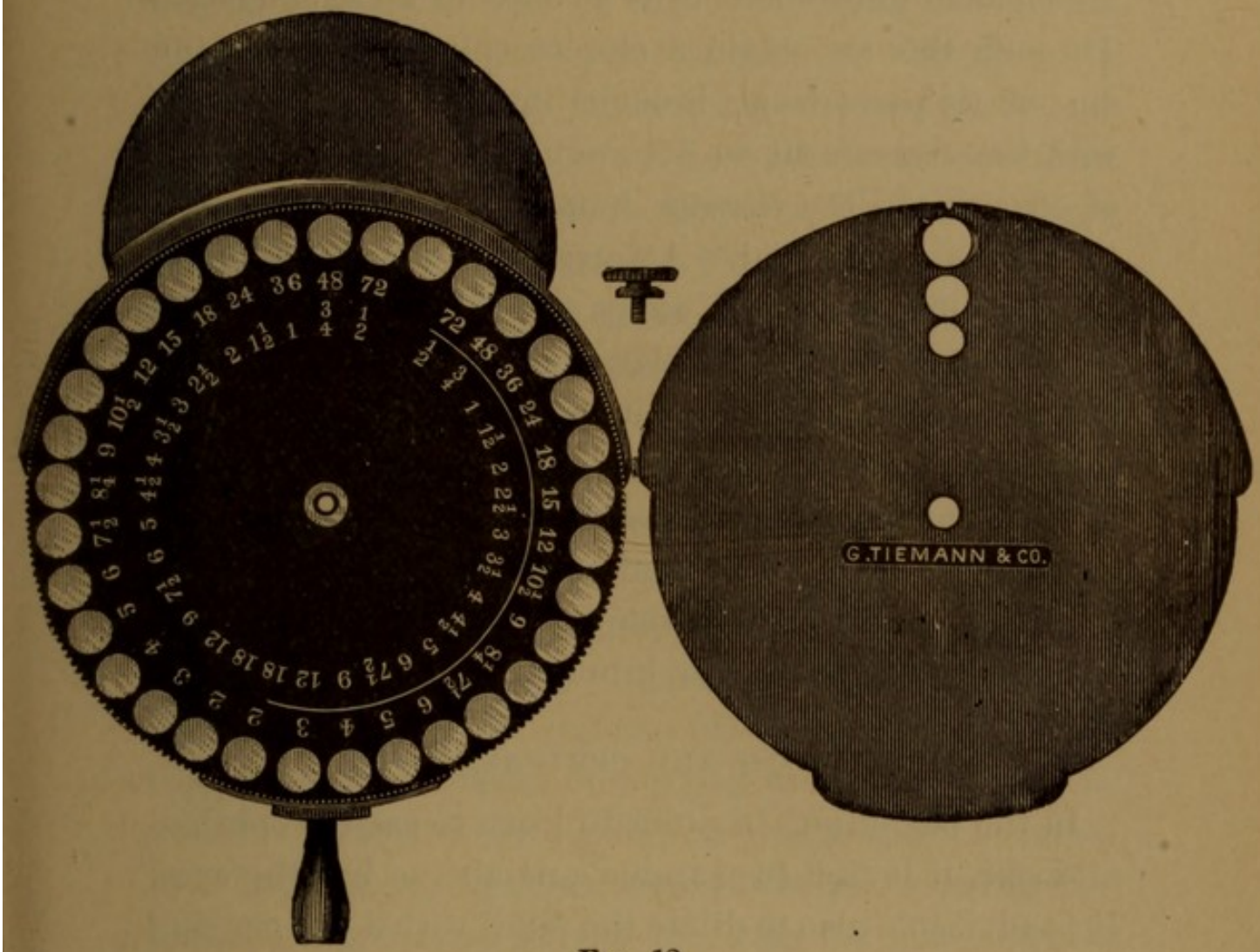

Fig. 12.

is an aperture one-eighth of an inch in diameter, and attached to the frame of the mirror is a hinged bracket to hold a small convex or concave lens, to assist the eye of the observer if necessary. The object glass or convex lens is rather larger than the mirror, of about two inches focus, and may be set also in a metallic frame with a

short handle. The more elaborate "refraction ophthalmoscope" is used by oculists generally, and is represented by Fig. 12 on the preceding page. A very interesting form of instrument is the binocular ophthalmoscope, so constructed that by means of prisms we are enabled to use both eyes at once in an examination. Through this we obtain a stereoscopic view of the fundus, all its parts being brought into relief. It is easier with this instrument to determine the relative positions of opacities in the vitreous humor, or extravasations in the retina or choroid. Attractive, however, as the binocular ophthalmoscope seems to be, I find that in practice I seldom use it. It is large, cumbersome, and heavy, and requires more time for its proper use, and ordinarily, therefore, its advantages do not in practice appear to be of sufficient importance to compel its employment.

Another, the aut-ophthalmoscope, is so arranged that, by an ingenious combination of mirrors, one may look with his right eye directly into his left, or *vice versa*.

HOW TO USE THE OPHTHALMOSCOPE.

In the beginning, in order to learn to use the ophthalmoscope, it is best to examine a number of healthy eyes. It is advisable also to dilate the pupil with a two per cent solution of cocaine — which will so enlarge the field of vision in a few moments as to make the examination more interesting and instructive. Cocaine is preferable to atropine for this purpose as its effect on the pupil passes away in a few hours. It must be remembered that if we use the convex object glass we get an *indirect* or *inverted* picture of the fundus, and without the interposi-

tion of the object glass we get a *direct* or *upright image.* Having seated our patient in a room from which daylight is completely excluded, with a good steady light at his left side, we take up the mirror in the right hand, put it close to our own eye and our eye to the aperture, and on a line with the eye to be examined, and distant from it perhaps eight to twelve inches. Turning the mirror slightly towards the lamp, we illuminate the eye of the patient. Already we have learned something, because all eyes cannot be illuminated, — an opaque lens, for instance, prevents it. Now, hold with the left hand the convex object glass before the illuminated eye, at the distance of an inch and a half or two inches, directing the patient to look in the direction of our left ear when we are to examine his left eye, and our right ear when we direct our attention to his right eye, — in other words, directing that the eye under examination shall be turned slightly inward so as to bring the optic nerve directly opposite or behind the pupil. To examine the region of the macula lutea the patient should look straight forward, directly at the eyes of the observer. It will be recognized as a spot slightly darker in color, with no vessels running over it. Having illuminated the fundus of the eye with the mirror in the right hand, we must be careful not to change its position while we are adjusting the convex glass held in the left hand, otherwise we shall fail to see the interior of the eye from lack of light.

If the patient is myopic we gain a more distinct view by approaching our own eye a little, and if he is hypermetropic we see better by increasing, slightly, the

distance between our eye and his. If our own eye is presbyopic or hypermetropic we may also find it advantageous to use in the hinged bracket behind the mirror one of the little convex glasses of eight or ten inches focus which belongs to the ophthalmoscope. The convex glasses will also be found serviceable if the eye of the patient is hypermetropic.

In the *direct examination* without the object glass in the left hand, if we desire to examine the disc or fundus, we must approach our eye very near to that of the patient; but to simply test the transparency of the media, — the lens or humors, — we place our own eye at a distance of fifteen or eighteen inches from the eye under observation.

The appearance of the fundus of the normal eye differs considerably in different individuals. The fundus of the eye of a light-complexioned person is light-red, while that of a dark-complexioned one is dark-red, owing to an abundance of pigment in the choroid, and in the pigment layer of the retina. In the former, we may see many of the vessels of the choroid which give the fundus a striated appearance. In very dark eyes the choroidal vessels are invisible. See Frontispiece.

The disc or optic nerve entrance appears generally, to me, of a slightly yellowish-grayish pink. In dark eyes more white and glistening, in light eyes more rosy in color. It is usually circular in form, but in astigmatism often has the appearance of being oval when it really is circular.[1] Its edge is sharply defined, and

[1] Suppose, for instance, a case of astigmatism where the cornea is too convex in the vertical meridian. The optic disc appears oval

near it may be seen occasionally a slight crescentic line of pigment. The face of the disc is more pinkish at its inner half, and where the retinal vessels emerge from it.

The *retinal vessels* run principally upward and downward, an artery, known by its light color, and two veins running in each direction. The retina itself, in a healthy state, is transparent, and cannot be seen. Exceptionally in very dark eyes, it may be detected as a gray film, in the immediate vicinity of the disc. The *physiological excavation*, not unfrequently noticed in the healthy nerve disc, is spoken of in connection with pathological excavations in the remarks on atrophy of the optic nerve. *Venous pulsation* may sometimes be observed in the healthy eye. It is to be looked for in that part of the retinal vein between the centre of the nerve disc and its edges. It may be produced by gentle pressure on the ball of the eye with the finger. Similar arterial pulsation indicates intra-ocular pressure, and is not found in the healthy eye. The ophthalmoscopic appearance of *the diseased eye* is spoken

in a vertical direction if we make a direct examination. In *indirect examination* it will appear *oval in a horizontal direction.* The reason of this is plain. Our convex glass makes objects appear larger if held near them, but if removed from the object beyond its focus (about two inches) we have an image inverted and reduced in size. Now, in a case like the above, the eye lends the greater refracting power to the glass in a vertical direction, and the inverted and reduced image will, of course, be reduced most in the direction of the greatest refractive power. The convexity of the glass and the cornea combined being greater in the vertical line, the inverted image of the disc is reduced most in this direction. Hence it appears oval horizontally.

of in connection with the various affections which demand its aid for their diagnosis and intelligent treatment. I may remark here, however, on the great importance of what is termed lateral or oblique illumination in detecting diseases of the anterior part of the eye. A good rule to follow in ophthalmoscopic examinations, — one that will save time, facilitate diagnosis, and prevent error, — is to always commence the examination by

LATERAL ILLUMINATION.

Lateral Illumination of the eye is best conducted in a darkened room, also. The patient sits relatively to the light, as in the ophthalmoscopic examination. The convex object glass is to be held between his eye and the light, the patient facing the observer, so that a strong light is thrown obliquely on to the front of the eye illuminating the cornea and anterior chamber. We may in this way detect opacities of the lens, examine with the greatest nicety the surface of the cornea and the texture of the iris. A second convex glass may also be used at the same time to look through as a magnifying power, if desirable.

DIFFICULTIES OF DIAGNOSIS IN DISEASES OF THE EYE, FORMERLY.

Before the discovery of the ophthalmoscope, by Helmholtz, in 1851, very little, comparatively speaking, was known concerning the internal diseases of the eye, and the little knowledge which we possessed was very inexact. The history and progress of this kind of disease

it was of course impossible to determine with any certainty. Diseased eyeballs were rarely dissected after death; and when this was done, it yielded but scanty return for the labor. A comparison of the pathological anatomy in such an instance, with the symptoms observed during life, in an organ of which nothing objective in regard to its deeper structures could be previously determined, afforded little satisfaction, and still less serviceable information. We may say, therefore, that previous to the introduction of the ophthalmoscope, our entire knowledge, almost, of the diseases of those parts of the eye posterior to the crystalline lens was conjectural. When the cornea and the iris and the lens presented no appearances of lesion, and yet the patient's visual power was impaired, we were disposed, and it might be said perhaps that we were compelled, *nolens volens*, to attribute the visual disturbance to some affection of the optic nerve. In the words of another, when neither the patient nor the doctor could see anything, it was amaurosis![1]

IMPORTANCE OF THE OPHTHALMOSCOPE TO THE GENERAL PRACTITIONER.

It is within a short time only that, in the treatment of general nervous disorders, the attention of the profession has been called to the importance of knowing the exact condition of what has been fitly termed the outpost of the central nervous system, — the nervous structure of the posterior portion of the eye, the condition of

[1] Amaurosis sei jener Zustand wo der Kranke nichts sieht und auch der Arzt nichts. — *Walther.*

which gives, in many cases, a picture of the condition of the brain itself. The ophthalmoscope is, therefore, destined in the future to be of great service to physicians in the treatment of a large class of diseases of the brain and nervous system. Among disorders of this kind which the general practitioner is called upon to treat, and in which the ophthalmoscope has already proved serviceable are the following: meningitis, encephalitis, hydrocephalus, cerebral hemorrhage, tumors, epilepsy, insanity, locomotor ataxy, nervous fevers, and myelitis.

In the optic nerve disc, for instance, we may see congestion and effusion, inflammation of substance and sheath, anæmia, and atrophy. An optic neuritis is connected with meningitis of the base of the brain, with a tumor, with large hemorrhage. An atrophy of the nerve, which may be recognized as either progressive or stationary, is accompanied by disease of the brain, cerebellum, or spinal cord. In lead poisoning there has been noticed a change of color and transparency in the optic nerve disc. In the retina, we detect inflammations, fatty or fibrous exudations, and hemorrhages; in the choroid, loss or disturbance of pigment, hemorrhages, and effusions; and in the blood-vessels of the fundus generally are observed diminution in size, dilation, obliteration, tortuosities, pulsations, varicosities, blood stases, displacement, effusion, and rupture. In albuminuria or Bright's disease, one may watch the changes that finally result in degeneration of the substance of the retina, and defective nutrition of the optic nerve.

Chronic headache, especially when the location of the pain is unusual or seems permanently fixed, and when accompanied by vomiting, should be regarded with suspicion, and every means taken to determine the state of the brain. Severe headaches and bilious vomiting have been known to herald final disease of the brain, and amaurosis. The ophthalmoscope will sometimes be of value in enabling the practitioner to determine the significance of these symptoms, whether they are to be regarded as of cerebral or of gastric origin, or are due merely to errors of refraction or muscular insufficiency.

In insanity, the ophthalmoscope has become an important agent in determining its course. Of a large number of patients submitted to examination, many have been found to present affections of the optic nerve. Dr. Allbutt, of the Leeds Infirmary, found that in fifty-three cases of that kind of insanity known as general paralysis, forty-one had disease of the optic nerve. The affection begins as a pink suffusion of the disc, and ends in white atrophy. It resembles in appearance the "red and white" softening of the brain. Of fifty-one cases of mania, more than half showed symptoms of disease of the optic nerve, — a stasis followed by consecutive atrophy, or white or mixed atrophy. After a paroxysm, there is a paralysis of the blood-vessels and about the disc, causing hyperæmia. In dementia and in idiocy, and in insanity, from epilepsy, a large number of cases show disease of the optic nerve or retina.

Thus investigations in regard to the diseases involving the brain and nervous system are greatly aided by ocular examination of the nervous and vascular tissues

of the eye with the ophthalmoscope. Here we *see* a diseased nerve, and measure with our eye the progress of the affection. It has been remarked with truth that hereafter no record of a nervous affection can be considered complete unless it gives a faithful account of the ophthalmoscopic appearance of the retina and optic nerve.

CHAPTER V.

REFRACTION, ACCOMMODATION, AND THEIR ANOMALIES.

REFRACTION of the eye, or the refractive power of the eye, is the phrase used to express its power of bringing rays of light entering the pupil to a focus in the vicinity of the retina.

Accommodation expresses the ability of the eye to increase or lessen its refractive power by means of the ciliary muscle and iris. Thus, in a state of rest, regarding a distant object, the emmetropic (normally refractive) eye needs no exercise of its power of accommodation, because the cornea and lens are precisely convex enough to bring parallel or distant rays of light to a focus on the retina. The latter is situated at a distance of about one inch behind the cornea, and the refractive power of the eye at rest is about equivalent to a convex glass of one-inch focus. But if we regard an object near the eye, the rays fall no longer parallel upon the cornea, but divergently, and of course a greater focussing power is needed to bring them to a point at the proper distance behind the lens. A refractive power, the equivalent of a one-inch convex glass, is insufficient, and the exercise of the power of accommodation becomes necessary.

Accommodation of the Eye

is brought about by the contraction of the ciliary muscle, which causes, through the medium of the Zonule of Zinn, an increased convexity of the crystalline lens, mostly at its anterior surface, giving it a higher refractive power. This action relaxing the tension of the Zonule of Zinn, permits the lens through its own elasticity to assume a more convex form. There are also the associated movements; namely, the periphery of the iris is drawn slightly backward, the pupil becomes smaller and is moved forward, the anterior choroid is moved forward, and there is a perceptible forward movement of the whole eyeball.

BOSTON MEDICAL LIBRARY. DEC 1 1896

CONVERGENCE,

so that the two eyes may be directed to the same point, is also, in binocular vision, more or less inseparable from accommodation.

DISTINCTION BETWEEN REFRACTION AND ACCOMMODATION.

It is to be remarked that the power of accommodation in the eye may be entirely suspended (for instance by the instillation of atropine), and still the refraction remain sufficient for distant vision. In presbyopia, the accommodation is much lessened in power, so that the near point for fine print may be as far as fifteen inches or farther from the eye, while the emmetropic eye is able to see the same print distinctly at three inches. The former, like the latter, has perfect refractive power for distance. In myopia, the antero-posterior diameter

of the eyeball being lengthened, the refractive power is too great for distant objects, — the power of accommodation may be unimpaired. In the hypermetropic eye the same diameter is too short; there is a lack of refractive power, — the rays of light reaching the retina before being focussed, — while the accommodative power may be good.

REFRACTION AND ITS ERRORS.

Considering rays of light from distant objects, or from objects distant more than six metres or eighteen feet, as parallel rays, we may say, in general terms, that in the —

Emmetropic eye,	parallel	rays	are	brought	to	a	focus	*upon*	the retina.
Myopic eye,	"	"	"	"	"	"	"	*before* "	"
Hypermetropic eye,	"	"	"	"	"	"	"	*behind* "	"
Astigmatic eye,	"	"	"	irregularly	focussed.				

MYOPIA (NEAR-SIGHT).

The optical defect of the myopic eye is exactly the reverse of that of the hypermetropic, — that is, its refractive power being in excess, parallel rays of light are brought to a focus before reaching the retina. This is due to the increased antero-posterior diameter of the eye, the bulging of the globe being posterior, at the entrance of the optic nerve. The retina is thus pushed too far back from the cornea and lens. This elongation of the posterior pole of the eyeball can be seen by requesting the patient to look as far inward as possible; we then notice also that the space in the orbit between the outer canthus and the globe, observable in the em-

metropic (normally refractive), and especially in the hypermetropic eye, is completely filled by the distended

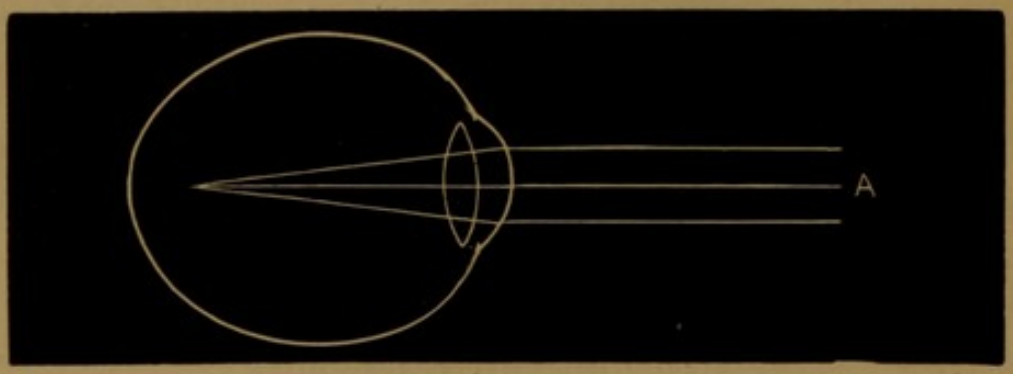

FIG. 13.

globe. Exceptionally, myopia may be the result of too great refraction, the axis of the eye not being increased.

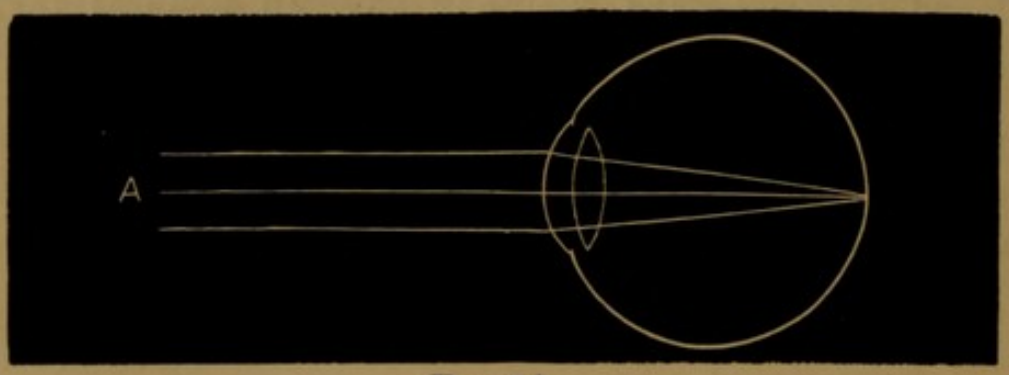

FIG. 14.

Figure 13 above represents a myopic eye, the axis of which is so long that the rays of light from A are focussed before reaching the retina.

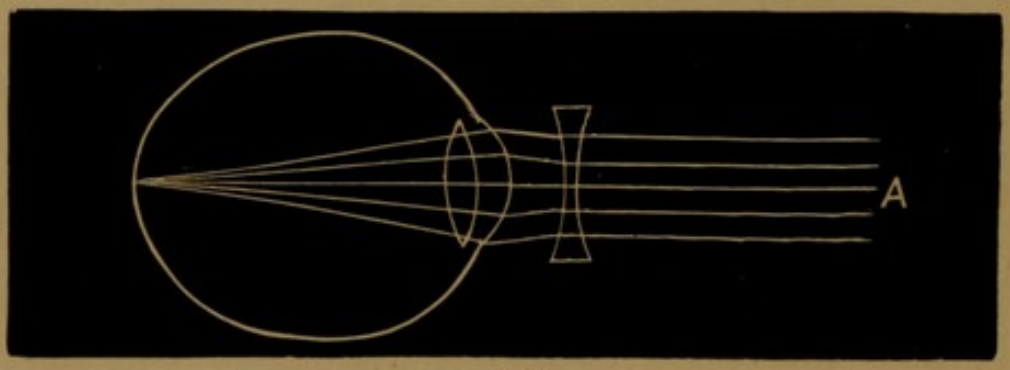

FIG. 15.

Fig. 14 shows the form of the emmetropic eye, which corresponds so perfectly with its refraction that parallel

rays of light from A are brought to a focus exactly upon the surface of the retina.

In Fig. 15 we have the myopic eye again, but being provided with a suitable concave glass, its refraction is thereby so far diminished that the parallel rays of light are properly focussed.

THE CAUSE OF MYOPIA.

Myopia is rarely congenital, often hereditary, and perhaps often acquired. It is possible that an hereditary predisposition to the affection may exist in those cases where it is acquired, and in which no myopic parentage can be traced.

Late researches tend to show that, among school children, the myopic eyes are recruited, as the process of education goes on, mostly from those of hypermetropic refraction; that, in young children, this form of optical defect is very common, but as time goes on and the eye is used for near objects in study, and especially if the child is not robust, the hypermetropic refraction is lost and the eye becomes myopic. This change to myopia is all the more likely to occur if there is an astigmatism also. The astigmatic eye is usually weak and irritable, especially if the astigmatism is myopic. Such eyes pass directly over from hypermetropia to myopia. It is affirmed that an emmetropic eye will, in all probability, escape injury during the educational period; but comparatively few eyes can be strictly classed as such. Progressive, or acquired myopia in young people may not be directly attributable, therefore, to the process of education, although education undoubtedly encourages

and hastens its development in all those children whose eyes deviate from the emmetropic standard. Unfortunately, the greater number of eyes are found to be hypermetropic, and these pass easily over into the myopic; it is nevertheless a fact that certain conditions tend strongly to the production of myopia. I have known several students at different times in Vienna, who informed me that when quite young they saw as far as their fellows, but that after commencing their studies, and pursuing them late at night in their homes among the mountains, with no light but that of a miserable tallow candle, and sometimes even less than that, — a shred of cotton in a cup of oil, a light so dim and flickering that the book must be held within a few inches of the eye, or the head be bent over so as nearly to touch the paper when writing, — after studying in this way for a few years they became myopic. We know that myopia is more common among the educated than the illiterate, and that it is usually progressive in schools from the elementary grade upward. Probably this progress is somewhat in proportion to the general health of the pupil. But it must be said also that the worst and most dangerous form of progressive myopia is oftenest met with among the illiterate. The severest case I have ever seen was in a young uneducated Italian here in Boston. Such cases are inherited, and are so progressive and destructive as to be called by some writers "malignant myopia."

Diagnosis. — The diagnosis of myopia is not difficult. It must not be taken for granted, however, that because a patient holds his book too near, or because he does

not see well at a distance, he is therefore near-sighted. Astigmatism, and especially hypermetropia, may equally produce defective vision, characterized by such symptoms. Still, no opacities of the cornea or lens being present, if the indistinctness of vision increases very rapidly as large letters are removed from the eye, we may be tolerably certain of myopia. A better test is to hold before the eyes weak concave glasses, say of thirty or forty inches focus. If the patient sees better, he is in a great majority of instances near-sighted. Occasionally, however, persons of good accommodative power see more distinctly, for the moment, through weak concave glasses, though not myopic, and sometimes when a very high degree of myopia is present, weak concaves are of almost imperceptible benefit; therefore, to make our diagnosis certain, it is better to ascertain beforehand about the number of the glass required to correct the myopia. This may be done by finding the farthest point at which the patient can read the finest type, such as Brilliant and if this be at a distance of six, eight, or ten inches from the eye, we may place before his eyes concave glasses of a corresponding number; if his far point is eight inches, a concave glass of eight inches focus will enable him to see well at a distance, and the existence of myopia is demonstrated beyond a doubt. Another ready and convenient proceeding for the diagnosis of either near-sight or over-sight is mentioned under the head of Hypermetropia at page 68.

Myopia is also diagnosed with the ophthalmoscope. For this purpose we use the erect image (simply the

mirror, without the convex object glass), and find that we can see the optic nerve disc and retinal vessels, when the pupil is large, distinctly at a short distance from the eye. On moving our head to either side, we find the image moves in the opposite direction; we obtain an inverted image of the fundus of the globe exactly the reverse of that obtained in the hypermetropic eye under a similar examination. We may also detect a myopia or hypermetropia by the use of the ophthalmoscope with the object glass. In myopia, if we increase the distance between the observed eye and the glass, the optic disc appears larger; in hypermetropia it appears smaller; in emmetropia its size remains unaffected by the movement. A two per cent solution of cocaine will enlarge the pupil somewhat and make these examinations easier for the physician. See page 334.

Pathology. — The pathological changes in severe cases of myopia and staphyloma posticum, and an accompanying choroiditis, consist chiefly in an atrophy of the choroid resulting from the inflammation. This occurring principally around the nerve entrance, permitting the white sclerotic to shine through, we have, as a result, a characteristic, large, irregularly outlined crescent. The irregular deposit of pigment is owing to the same cause as are also the exudations into the vitreous, and the possible final separation of the retina to a greater or less extent from the choroid. With the choroid the retina suffers also, and finally becomes atrophied in the region of the optic nerve and macula lutea.

In such cases there may be phosphenes, flashes of

colored light, spectra, metamorphopsia, as well as amblyopia.

But the above diseased conditions are found only in a high grade of myopia in adults. Most cases of slight and medium grades of myopia are free of serious pathological changes. The ordinary small whitish crescent so often seen at the outer margin of the optic disc, due to the retraction or thinning of some, or all, of the choroidal layers is not of pathological importance. This variety of myopia does not lead to blindness. It may progress, but unless the progress continues beyond adult

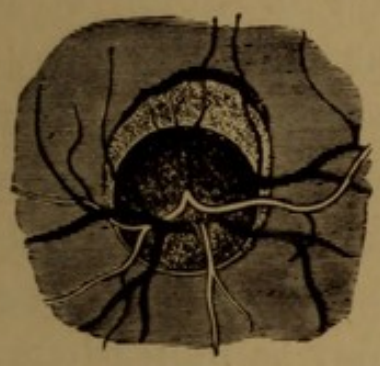

Fig. 16.

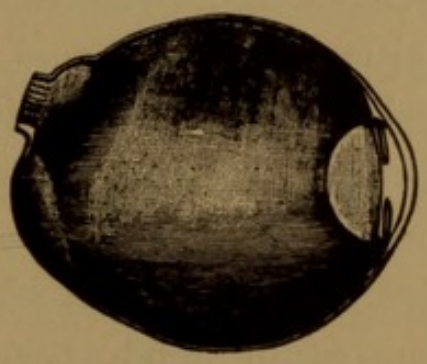

Fig. 17.

age, it need not occasion alarm. A crescent as large as that of Fig. 16, after Von Jaeger, might be considered rather serious. The eyeball as represented in Fig. 17, from Nettleship, shows great elongation and a necessarily high grade of myopia.

The treatment of myopia must sometimes be medical, especially in the case of weakly children, but more usually optical and hygienic. When there is considerable muscular asthenopia, if the eye is irritable, the conjunctiva injected, the ophthalmoscope showing a hyperæmic condition of the nerve disc with or without staphyloma posticum, and the patient complains of pain

around and sometimes in the eye, with feeling of tension and heaviness in the eyeball, the prescription of glasses should be temporarily delayed until, by complete rest of the eyes and proper remedial measures, the irritable state of the eye is removed. Gentle use of the eye douche will be found grateful, also a lotion composed of a drachm of spirits of ether nitrate to six or eight ounces of pure water, to which may be added a few drops of aromatic vinegar, the wash to be sponged over the closed lids and about the eye several times a day and allowed to evaporate. For hyperæmia of the conjunctiva a collyrium of ten grains of borax, or four grains of boracic acid, to the ounce of water may be used. Often the application of very hot water for five minutes over the closed lids, several times a day, will prove grateful. In some cases it may be wise to paralyze accommodation with atropine and allow complete rest to the eyes for some weeks. There may be indications for general medical treatment, the general health of the patient being of very great importance in nearly all cases of disease of the eye. Children with progressive myopia are rarely healthy. Rapid growth, muscular and nervous debility, frontal headache, coated tongue, capricious appetite, are often present.

Spectacles. — Generally speaking, no preliminary treatment is called for, and our first step is to select the appropriate glasses. They are to be selected with the greatest care. If too weak, they are comparatively useless; if too strong, a positive injury. The degree of myopia is determined by the negative focus of the glass which neutralizes it. If a patient reads No. 1 of the

test type at six or eight inches, his myopia is one sixth or one eighth. A concave glass of six or eight inches focus should, theoretically speaking, enable him to read No. 20 at twenty feet, and to see well at a distance. Practically, however, we find it necessary to prescribe concave spectacles rather weaker than this. If the myopia is one eighth, vision will be most perfect through glasses of one ninth or one tenth; which of the two numbers will prove best is to be determined by trial. The reason of this non-correspondence of the number of glass to the degree of myopia is this: the patient's far point being eight inches, the visual axes were converged for this distance, and with convergence of the eyes is associated accommodation (an increased convexity of the crystalline lens); in looking at a distance through the prescribed glasses, the visual axes are of course parallel, and there being no accommodative power (increased convexity of the crystalline lens) to overcome, the glasses should be proportionally weaker. The proper glass to enable him to read music or small print at twenty-four inches would be of about twelve inches focus. The formula would be: $-\frac{1}{8}+\frac{1}{24}=-\frac{1}{12}$. The patient's power of accommodation will influence greatly the choice of spectacles. When little or no accommodative power exists, as is often the case in a high grade of myopia, spectacles may be given which completely neutralize the myopia and entirely supplant any little accommodative power present. When only a tolerable power of accommodation is found, it is advisable to prescribe glasses which partially supplant it. Thus if our patient has a myopia of one eighth, and finds glasses of one ninth best,

if his power of accommodation be one twelfth, he will, through these glasses, be obliged to use his whole power of accommodation for reading at a distance of twelve inches. This is not safe, lest symptoms of fatigue supervene, his eye become irritable, and his myopia be increased. He should, therefore, be provided with weaker spectacles for reading; concave glasses, for instance, of sixteen or eighteen inches focus, by diminishing but little the convexity of his crystalline lens, enable him to see easily at ten or twelve inches, and tolerably at a short distance beyond. He should therefore, like the myope without accommodation, provide himself with two pairs of glasses, one for reading and one for distance. If perfect or normal accommodation is present, as is sometimes the case in the slighter forms of myopia in young persons, a single pair of glasses which neutralize the near-sight may be worn for both far and near vision. As a rule, however, it is prudent to prescribe for near objects concave spectacles which only *partially* neutralize the myopia, and enable him to read comfortably at fourteen or sixteen inches. Rules are often, however, of little practical service. The myopia must be corrected by suitable glasses whether their strength correspond or not to the apparent degree of near-sight. Frequently very strong glasses will be necessary for distant vision, and the patient will find it convenient to carry eye-glasses to use temporarily before his spectacles. These eye-glasses must, of course, be concave and of just the power to supplement the spectacles sufficiently to neutralize the myopia for distant vision. When the myopia is slighter than one fourteenth or one thirteenth,

fine print being read easily at fourteen inches, spectacles need not be prescribed, but simply the proper eye-glasses for distant vision.

The chief danger in the selection of spectacles is that of getting them too strong,[1] and so overtaxing the eyes for near objects. De Wecker believes the great prevalence of myopia in Germany to be due partly to wearing too strong glasses. I believe it may be due principally to the peculiar text in which their books are mostly printed. The sharp and accurate vision necessary to distinguish the letters requires the text to be brought too near the eye, thus favoring the habit of short-sight.

Spectacles, therefore, should not be bought at random of opticians or itinerant venders, but should be prescribed by a competent physician or oculist. When one eye is myopic and the other hypermetropic, the more serviceable eye should alone be provided for. If we prescribe a concave for one and a convex glass for the other, the former diminishing and the latter magnifying objects, it will be difficult to fuse the different sized images on the retina. Actual trial, however, is the best method of determining these matters. The best rules have their exceptions. I have a patient whose right eye is myopic and astigmatic, and whose left eye is hypermetropic. For the first he wears an eighteen-inch concave cylindrical, and for the second a sixteen-inch convex spherical glass, and with these reads more comfortably with both eyes than with either eye

[1] De Wecker's rule is very good in doubtful cases: "Éviter de donner dans l'hypermétropie des verres trop faibles, et d'en prescrire de trop forts dans la myopie."

alone. In non-diseased eyes the phosphenes, spectra, flashes of colored light, and like phenomena arise from over-sensibility of the retina, and generally disappear under treatment of the irritable condition of the eye. If they do not, like muscæ volitantes and scotoma, they will be rendered less apparent and troublesome by the use of colored glasses.

After prescribing with the greatest care the proper glasses, it is necessary in the progressive myopia of young people to enforce strict hygienic measures. Our patient should not work continuously at near objects, but should rest a short time at intervals of a quarter or half hour, and always whenever the eyes feel in the least fatigued. He should never work or read with the head bent forward, as this promotes intra-ocular congestion. The light should fall upon his work from behind, so that the eye may be protected from glare. Children's school desks should, therefore, be made sufficiently high and sufficiently sloping, and be placed, as regards light, to fulfil these conditions.

In the myopia of children, enforced rest of the eyes will often produce very great improvement in vision; that is, the grade of the myopia is improved. The improved sight is apparently not wholly due to the removal of the slight tension of the ciliary muscle common in these cases, as the paralyzation of the muscle by atropine produces an effect considerably less than the final effect of complete rest. Nor is it due to the curative effect of rest on the amblyopia. Often no amblyopia is present. I attribute the improvement to a change in the shape of the globe due to an exclusive

use of the eye for distance. See page 49, Accommodation of Eye. We should prescribe, in these cases, daily use of the eyes for *distant* objects in the open air.

In very high degrees of myopia, such as one fourth, one third, or one half, even if no amblyopia be present, we cannot expect the patient to read large print through his glasses at a point as distant as a normal eye would do it. The powerful concave glasses diminish the size of the image too much. Very strong concaves are also inconvenient to the wearer, by compelling him to move his head always in looking to the right or left. His glasses are so deeply hollowed that he must always look through their centre, or they produce the effect of prisms or decentred glasses.

Finally, it should be remarked, that in a certain number of cases of accommodative asthenopia in slightly myopic young people, it may be advantageous to prescribe convex glasses for near work. Even in cases where concave glasses are worn for distant vision, I have found weak convex glasses necessary for the eyes in reading. Such cases are exceptional, but they occur. The same is true also in myopic astigmatism of a low grade. We find that for reading, a weak convex cylindrical lens is best; while for distance, a concave cylindrical is required. I may add here, that in high grades of myopia there is frequently an astigmatism also, and that what we at first take for an amblyopia may be remedied, to a certain extent, by proper cylindrical glasses. Many myopes, therefore, when the myopia is considerable, require a combination of cylindrical and spherical concave glasses. And not unfrequently there

is insufficiency of the internal recti requiring the combination of prisms, base in, also.

The power of convergence is not infrequently impaired in myopia. This need not necessarily be due to weakness of the internal recti muscles but rather to a lack of ability in the muscles to work together so as to converge the eyes for the proper distance to give easy and distinct vision. The recti interni may also be weak. See Muscular Asthenopia, page 84 *et seq.*

Finally it may be stated that recently, Fukala reports operations for discission of the lens in twenty-three cases of very high grade of myopia with excellent results. Absorption of the lens made the refraction emmetropic, hypermetropic, or less myopic, and greatly lessened the amblyopia. In one case vision was raised from one tenth to one half, in another from one twenty-fifth to one half.[1]

HYPERMETROPIA AND ASTHENOPIA (ACCOMMODATIVE).

Hypermetropia,

as we have already seen, is that condition of the eye in which its antero-posterior diameter is too short in comparison with the refractive power (convexity) of the crystalline lens and cornea. The rays of light consequently reach the retina before they are brought to a focus, forming circles of diffusion, and vision is indistinct. A convex glass, or spectacles, by supplementing the refractive power of the natural lens, enables the patient to focus the rays of light upon the retina, precisely

[1] Ophthal. Review, vol. ix. p. 304.

as in presbyopia. In presbyopia, however, rays of light from a distance — that is, what are termed parallel rays — are brought to a focus on the retina without the use of accommodating power; while, in hypermetropia, the exercise of this power is always necessary, even for distant vision, and, in the higher grades of the affection, convex glasses are also necessary for all distances. A hypermetropic eye is generally smaller in all its dimensions than the emmetropic or normally refractive, and is usually congenital and hereditary. This form of hypermetropia is sometimes called *axial* in distinction

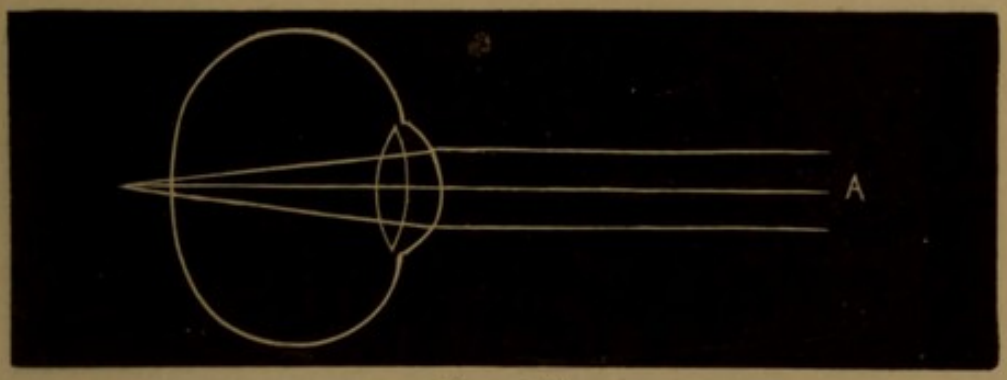

Fig. 18.

to a form which is occasionally met with, due to an insufficient curvature of the refractive media, and called *curvature* hypermetropia. The same is true of myopia which, usually axial, may exceptionally be curvature myopia caused by excessive curvature of the refractive media.

Fig. 18, above, is intended to represent an eyeball of the hypermetropic form; the parallel rays of light from A are seen to reach the retina before being brought to a focus. Such an eye might perhaps focus parallel rays by the exercise of its power of accommodation; but if the range of accommodation were limited, or the grade

of the hypermetropia too high, it could only see at a distance by the aid of a convex glass.

In Fig. 14, we have the emmetropic eye, and the difference in the length of the axes of the two eyes is clearly observable. The first eye is so flattened that its axis is too short for its refractive power; while in the second the shape of the eye is precisely adapted for its power of refraction.

In Fig. 19, we see the hypermetropic eye with a suitable convex lens before it. The glass so supplements its refraction that parallel rays of light are focussed just

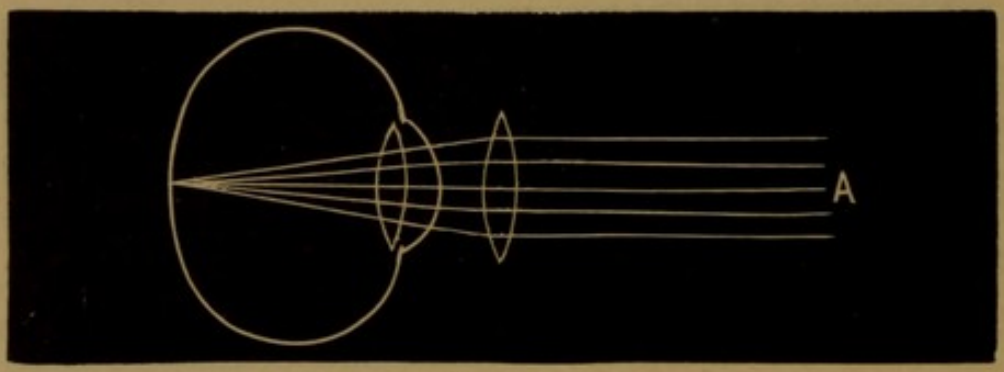

Fig. 19.

as they reach the retina, and without the exercise of accommodation.

It has been stated already that the hypermetropic form of the eyeball is more common in early life than any other, and that it furnishes the greater number of recruits for acquired myopia. I have occasionally found it quite puzzling in young subjects to decide at once whether they were over-sighted or near-sighted. They appeared by turns to be both, and were undoubtedly just at the turning point into confirmed myopia. It should be borne in mind as of practical value in treatment, that a hypermetropia may decrease with age, and

that a change to weaker glasses may after a time become expedient.

Hypermetropia is divided by Donders into *facultative*, *relative*, and *absolute*.

Facultative is the slightest form, where the patient accommodates readily for all distances; presbyopia occurs rather early, and then asthenopic symptoms are apt to occur; while, in

Relative hypermetropia, although the patient can accommodate so as to see well at all distances, yet this is only accomplished through great efforts of accommodation, and by converging the optic axes strongly at the same time. Such persons are almost certain to become asthenopic.

Absolute hypermetropia is a condition of the eye in which the patient sees distinctly only by the aid of convex glasses. Without spectacles no effort of accommodation, however great, will suffice to focus rays of light upon the retina. A hypermetropic refraction is caused in the emmetropic eye after the loss of the lens in extraction, and also in aged people from a high grade of presbyopia.

DIAGNOSIS OF HYPERMETROPIA.

Let the patient look at No. 20 of the test type at twenty feet, and if his vision is improved or not lessened by looking through convex glasses of thirty or forty inches focus he is hypermetropic. These glasses would not render the vision of an emmetropic eye more acute. But it may happen that, although slightly hypermetropic, he does not see as well through the convex

glasses, or he may even see as well, through concave glasses of thirty or forty inches negative focus, as in myopia. He is not myopic, however; but in looking through the concave glasses he involuntarily exerts all his power of accommodation; and when this power is considerable, he overcomes, for the time being, his own as well as the additional hypermetropia caused by the concave glasses. Slight tension of the ciliary muscle might also cause an apparent myopia. Ordinarily, however, we find that a weak convex glass improves vision; if it does not, we may try the effect of paralyzing the accommodation by the instillation of atropine. We can then determine the whole extent of the hypermetropia, both latent and manifest. If after an hour or two we try our convex glasses again, we may find that whereas, previously, he could only see well through convex thirty, he now sees best through convex twelve or fifteen. His manifest hypermetropia was only one thirtieth; but his latent, being added, gives him really a hypermetropia of one twelfth or one fifteenth. The hydrobromate of homatropine in one per cent solution may be used in these cases generally, as its unpleasant effects on accommodation pass off in a day or two.

Another, and very simple test, for anomalous refraction, without the aid of glasses, is mentioned under Amblyopia.

We may diagnose the affection also by means of the ophthalmoscope, using the direct image. With this we see the details of the fundus at a little distance, as in myopia, only in this instance we get our image uninverted. A movement of the observer to the right or left

will produce a similar movement in the image, and not the reverse as in myopia. Approaching nearer, we find the field of vision unusually large, and the optic disc apparently small, but distinct, just the reverse of what we notice in myopia. In myopia, however, we may render the fundus of the eye distinct by using a concave lens in the hinged bracket behind the mirror, and in hypermetropia we may make the fundus more distinct by the same use of a convex lens. In this way, by the direct or upright image, we may not only detect the existence of an optical defect, but determine its nature; and the number of the lens plus or minus, our own eye being emmetropic or made so by a proper glass, will give us the measure of the manifest and sometimes the total hypermetropia, or myopia. The newest forms of the ophthalmoscope have a large number of lenses so arranged as to be quickly available in diagnosing and measuring ametropia. But the accurate use of

THE OPHTHALMOSCOPE IN MEASURING AN AMETROPIA

requires practice. The accommodation of the patient must be relaxed, and if the dark room in which the examination is made be sufficiently spacious, or if, as in my ophthalmoscopic room, a dark curtain be arranged on the wall opposite the patient, this may be accomplished; otherwise atropine is necessary. The observer must also relax his accommodation. Then, the convex lens, beginning with the weakest that enables the observer to see the region of the *macula lutea* or some of the retinal vessels running from the edge of the optic

disc most distinctly, is supposed, if the defect is a hypermetropia, to give its measure. In the same way, using concave lenses, the degree of a myopia is determined. The optic disc is not available when strict accuracy is desired, as, not being at the *fovea centralis*, it cannot be at the same distance from the centre of the cornea. In myopia it is sometimes anterior to the *macula*. As an aid in determining and confirming, in connection with other tests, the existence of optical objects, the ophthalmoscope used in this way is convenient. This method of measuring optical defects is good practice for oculists, if for no other reason than that it breaks into their routine habits of diagnosis.

The shadow test will also aid in determining an error of refraction. The light is thrown into the eye by the usual concave ophthalmoscopic mirror from a distance of about four feet. It should be shaded from the patient, and may be at the side or just over his head. The room must be darkened so that no object in front of the patient shall hinder the more or less complete relaxation of accommodation. We now notice, in moving or rotating the mirror slowly on its horizontal axis, whether the red reflex in the pupil moves with the mirror in the same direction, if so we have a myopia. If it moves in the opposite direction or against the mirror we have a hypermetropia, a slight myopia, or emmetropia. By putting trial spectacles on the patient we may determine approximately the degree of myopia or hypermetropia. If myopia, the weakest concave lens before the eye that reverses the movement of the reflex gives us the meas-

ure of the error of refraction and indicates the proper glass for its correction. Similarly, the weakest convex lens which reverses the movement of the reflex gives us nearly the amount of hypermetropia. In the latter test the convex glass indicated will be somewhat too strong, and in all cases, nearly, a more correct estimate of the degree of refractive error will be obtained by the use of a mydriatic. The direct method with the ophthalmoscope as given at page 69 is, I think, more certain and more practical. I have assumed in the above, that the observer uses the ordinary Liebreich concave mirror. If a *plane* mirror is used, the movements observed will be exactly the reverse; that is, in myopia against the mirror, in hypermetropia and emmetropia with the mirror. In slight myopia, — that is, of one dioptric, or less, — the movement with either mirror is as in emmetropia.

Spectacles *for distance* should not be prescribed for hypermetropia, if the patient can see well and without fatigue, as after being used for distant vision they become indispensable for all time; but for near vision, they should be ordered the moment asthenopic symptoms appear. In higher grades of the affection, where vision for all distances is imperfect, glasses which correct the *manifest* hypermetropia may first be worn; and later, when the eyes become accustomed to these, stronger ones may be prescribed, if necessary, so as to correct more or less of the *latent* defect also. Exceptionally, such patients require the stronger glasses from the first and reject the weaker ones.

ACCOMMODATIVE ASTHENOPIA

may be defined as a condition of the eye in which it cannot be used continuously for near vision, even in the best light, without pain and confusion of sight, although for the first moment the patient sees with ease and distinctness. The eyes are sound in appearance, in movement, in visual form, in convergence of visual axes, but they rebel against all use, however moderate. After the least service upon near objects, they feel fatigued, full, hot, and sometimes become quite painful, the pain extending to the head, or following the branches of the fifth nerve.

It is not unusual for asthenopic eyes to show a slight hyperæmia of the conjunctiva, and in the neurotic we often notice an enlarged and rather sluggish pupil. The dilated pupil is not due to local disease, but to reflex disturbance of the ciliary nerves from irritation of the sympathetic. In these cases we find spinal irritation or disturbance of the uterine or digestive functions. The dilatation of the pupil is, when it exists, an additional hindrance to distinct vision for near objects, by admitting too much light and too many lateral rays, and by increasing the circles of diffusion. As the rays reach the retina before being focussed, the object is not pictured upon the retina at a single point, but by a number of conical pencils of rays in the form of circles which, overlapping each other, render the image blurred. Sometimes there is to be observed a hyperæmic condition of the optic nerve disc and retina similar to the hyperæmic state of the conjunctiva. In rare instances,

the optic nerve itself appears to be the principal seat of the pain. I can recall instances where the least exercise of the eye produced deep-seated pain of the globe.

Formerly, asthenopia was looked upon as a grave affection, and as a probable precursor of amaurosis, or some other disease fatal to sight. It is sometimes a symptom of general debility, arising from exanthematous or febrile affections, from overwork, mental troubles, dissipations, abuse of the eyes, and like causes. All these, however, only express the occasional, or exciting cause. The primary cause is usually to be sought in a more or less faulty state of the refraction, the consequent fatigue of the ciliary muscle, and the resulting irritable condition of the eye. Some hypermetropic eyes escape asthenopia for a time from having been originally endowed with a wide power of accommodation. A youthful normal eye is sometimes able to read the finest type, No. 1, from three up to eighteen inches; while another may be able to read it only from four up to twelve inches, — the first showing an accommodative power of considerably greater range than the second. Moreover, according to Von Graefe, there is considerable difference exhibited by different individuals in the impunity with which they may exert a great part of the accommodative power at their disposal. Some persons, for instance, are unable to use one half of this power for any length of time without injury, while others use more than three quarters without fatigue. In the first, there appears to be a lack of energy in the ciliary muscle; while, in the second, it is unusually vigorous. Hence it may follow that the more or less perfect opti-

cal construction shall in some instances give but an imperfect indication of the serviceableness of an eye for fine work. The working power of the eyes may also depend, to a certain extent, upon the equilibrium of the external ocular muscles. See page 84 *et seq.*

TREATMENT OF ACCOMMODATIVE ASTHENOPIA.

The first and most important indication in the treatment of accommodative asthenopia is to relieve the painful and overworked ciliary muscle by supplementing the refractive power of the crystalline lens with suitable convex glasses.

Sometimes, when the affection is of long standing, and the whole eye seems to have been reduced to an extremely irritable and sensitive condition, we may have considerable trouble in finding glasses that can be worn with comfort; and yet, if the eyes are to be used at all, the help of glasses is absolutely required. It may be necessary in those cases to completely paralyze the accommodation for some weeks by the instillation of atropine, simply for the purpose of resting the eye.

For the selection of glasses, I generally determine the amount of manifest hypermetropia, by permitting the patient to look at No. 20 print at a distance of twenty feet, or where an emmetropic eye would see it with distinctness. Then I find the lowest convex glass through which he can read the print, and this determines the degree of manifest hypermetropia. Having determined this point, I prescribe, if the hypermetropia is thirty-six, a convex glass of thirty inches focus; if it is fifty, glasses of about forty inches focus, and so on.

De Wecker advises that the manifest and about one fourth of the latent hypermetropia should be corrected by the first glasses presented. In practice, however, it is often necessary to begin with a weaker glass (D + 0.75 or + 48), and then change, after a few weeks, to those of a greater refractive power, in order to complete the cure. But the strength of the convex glasses will depend greatly on the amount of latent hypermetropia, and this is to be determined with the ophthalmoscope, or by atropine and the test types.

We must remember that in myopia the convergence is always in excess of accommodation, while in hypermetropia the accommodation is in excess of the convergence. In neither optical defect do the ciliary and the internal recti work together harmoniously; hence, probably, a great part of the discomfort.

Sometimes, in asthenopia due to facultative hypermetropia, the glasses, after having served to cure the asthenopic symptoms, may be discarded.

The systematic use of the glasses after the Dyer method is usually advisable. Thus, we take as a starting point for the exercise of the eyes in reading, that period of time asserted by the patient to be the longest that he can use his eyes without fatigue. It may be one minute or less, or it may be five or ten minutes. He is then instructed to put on his glasses and read the given time through them three times a day, adding one minute to this time each day, until perhaps a half-hour is reached. Then two minutes a day may be added; and when the patient can read from one to two hours at a sitting, without fatigue, the cure is complete. Reading by artificial light may finally be practised in the

same way. The reading matter should not be of too absorbing a nature, and the patient should be made to understand that the sole purpose of the reading is for the hygienic exercise of the eyes.

If the asthenopia is clearly the result of general debility, due to diminished energy of the muscular system generally, and the hypermetropia is slight, or wholly wanting, it is possible that the restoration of vigorous health through internal medication, generous as well as prudent dietetic regulations, or change of air, with systematic exercise of the eyes in reading as just described, may cure the asthenopia without the necessity of a resort to spectacles at all. I have found the Dyer method alone — that is, without glasses — sufficient in a certain number of cases.

ASTIGMATISM.

This is an anomaly of refraction dependent generally on a lack of symmetry in the different meridians of the cornea. It was noticed by Young, in 1793, but first correctly explained by Donders, who published a work on the subject in 1862. Previous to the researches of Donders, there had been recorded less than a dozen cases for seventy years; since his investigations, cases are recorded daily. Astigmatism is congenital, or may be acquired from wounds or ulceration of the cornea. It is divided into the *regular* and the *irregular*.

Regular Astigmatism

is called *simple* when one meridian of the cornea is emmetropic and the opposite myopic or hypermetropic. It is *compound* when both meridians are myopic or hy-

permetropic, but in different degrees, as if, for instance, in the vertical meridian the cornea were sufficiently convex to make a myopia of one eighth, while in the horizontal line it might be only convex enough for a myopia of one sixteenth. In rare instances there is *mixed astigmatism*, one meridian being myopic, the other hypermetropic.

Irregular Astigmatism

is due to imperfections in the structure of, or to partial dislocation of, the lens, or to its partial opacity. It is found also in conical cornea, and results from ulcerations of the cornea, and occasionally from irregularity of its surface after cataract operations. In these cases the meridians of greatest and least refraction are not at right angles to each other, and this form of astigmatism is rarely benefited by glasses. Lately, however, conical or cylindroconic glasses are said to have proved quite useful.

DIAGNOSIS AND TREATMENT.

To determine whether a patient is astigmatic, we have only to place some well defined lines running in vertical, oblique, and horizontal directions before him at considerable distance, — perhaps thirty feet, — and then gradually approach them so as to find if, at any distance, one set of lines appear clear and the other indistinct. If such a point *can be found* he is astigmatic; if not, we are obliged to refer his defective vision to some other cause. See test type, page 348.

We must bear in mind that no eye is perfectly symmetrical in form, and so we may expect to find that vertical and horizontal lines will not be seen always with

equal distinctness; but usually this asymmetry is so slight that no annoyance in vision is occasioned. It is well to begin the test of imperfect vision through spherical glasses, and finding that these do not render vision sufficiently acute, we may be quite sure that we have a case of astigmatic refraction.

Having determined the existence of astigmatism, if we permit the patient to hold a metallic disc before the eye, in which there is a slit of about a line or rather less in width, and rotate it until it comes opposite the emmetropic meridian of the cornea, so that rays of light are received by the eye through this meridian alone, he will see distinctly, reading No. 20 at twenty feet. This supposes a case of *simple astigmatism*, one meridian of the cornea being normally refractive or emmetropic. To neutralize this astigmatism and render vision acute, we have only to prescribe weak concave or convex cylindrical glasses.

CYLINDRICAL GLASSES

are segments of a cylinder; whereas ordinary glasses are segments of a sphere. A concave spherical glass, for instance, increases in thickness from the centre in all directions. A concave cylindrical glass, held with its axis in a horizontal direction, is equally thin throughout in its horizontal plane, but in its vertical plane increases in thickness from the centre like a spherical concave. Those rays of light which strike a cylindrical lens at right angles with the plane of its axis are refracted, and those which strike *in the plane of its axis* are not refracted at all. Cylindrical glasses are, there-

fore, unlike spherical, to be rotated before the eye until the plane of their refraction comes opposite that plane of the cornea which requires it.

In *compound astigmatism* we proceed to determine first, how much we can improve vision by the ordinary glasses, convex or concave. Suppose it a case of myopic astigmatism, and we find sight best through a spherical concave glass of one twentieth. We then select a weak concave cylindrical glass, and placing it before the other, allow the patient to look through both, rotating the last until its axis is in the right direction. If it proves too weak we try others. We may determine also, in advance, the number of the cylindrical glass required, with tolerable exactness by noting the different strength of two glasses, through one of which horizontal lines are best seen, and through the other of which vertical ones are plainest. Take the two letters on the next page made up of horizontal and vertical lines. A. sees N blackest, but with convex No. 15 sees Z blackest. With cylindrical convex No. 15 axis vertical, his astigmatism will be corrected. B. sees Z blackest through No. 60 concave, and N blackest through No. 20 concave. Then[1] $-\frac{1}{20} - \frac{1}{60} = -\frac{1}{30}$. A cylindrical -30 glass with the axis horizontal would neutralize his astigmatism.

[1] A concave glass is designated by the sign $-$, and a convex by the sign $+$; *s.* spherical; *c.* cylindrical; $\bigcirc$ combined with. Hence, $+1.5$ *s.* $\bigcirc$ $+.75$ *c.* axis vertical Left, means the prescription for the left eye of a spherical convex lens of one dioptric and a half, in combination with a convex cylindrical one of three quarters of a dioptric. Or, under the old enumeration, a spherical No. 24 with a cylindrical No. 48, the axis of the latter vertical.



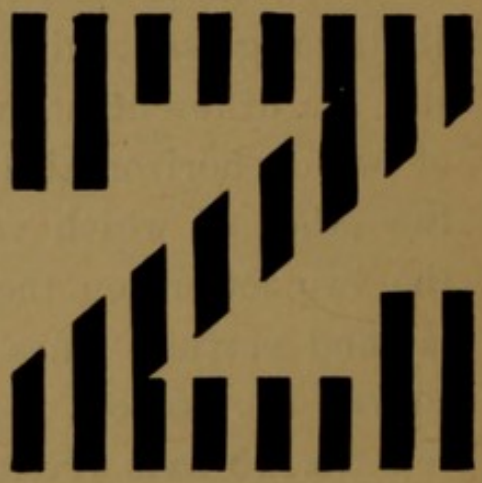





A color test is recommended by Green, of St. Louis. Bright red and blue, or other shades of these colors, rendered brilliant by transmitted light, as when hung at a window, are most practical. The colors are arranged in radiating lines. I have mentioned also a simple test for astigmatism under Amblyopia.

MIXED ASTIGMATISM.

This form may require by-cylindrical glasses for its correction. A plano-cylindrical convex glass for the hypermetropic meridian, and a plano-cylindrical concave glass for the myopic meridian of the cornea are to be selected and put together, their axes at right angles, then rotated before the eye until their best position is found. Or the defect may be remedied by a combined spherical and cylindrical lens, as shown below.

A mixed astigmatism may be quickly diagnosed by the use of the stenopaic slit. Placing the slit before the eye vertically, or in that direction in which by the aid of spherical glasses the lines appear blackest, we determine the nature and extent of the optical defect in this meridian of the cornea. Let us suppose, for instance, that we find a spherical convex glass of two dioptrics (eighteen inches focus) gives the best vision in the vertical meridian, and that a spherical concave of one dioptric (thirty-six inches focus) is best for the horizontal meridian. We may correct this defect in two ways. First, we select a *cylindrical* lens + 3 D, and place it before the eye, its axis horizontal; this overcorrects the hypermetropic astigmatism by one dioptric. We then put with this lens a concave *spherical*

of one dioptric. This corrects the myopic astigmatism, and also reduces the convex cylindrical of three dioptrics to a lens of two dioptrics, just what the optical defect demands. Or, we may make use of a convex cylindrical lens of two dioptrics, its axis horizontal, combined with a concave cylindrical lens, its axis vertical. The latter course is the one that I generally adopt.

Astigmatism may also be diagnosed with the ophthalmoscope, as mentioned in the chapter preceding,

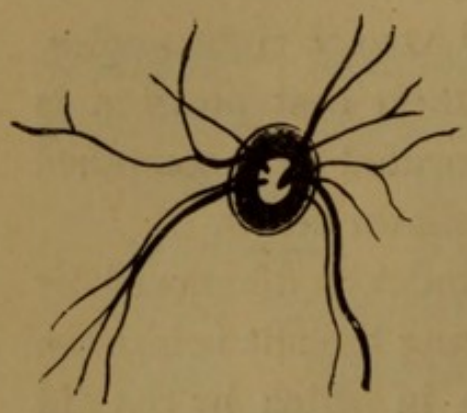

FIG. 20.

The optic disc in astigmatism, seen by the indirect method (reversed image).

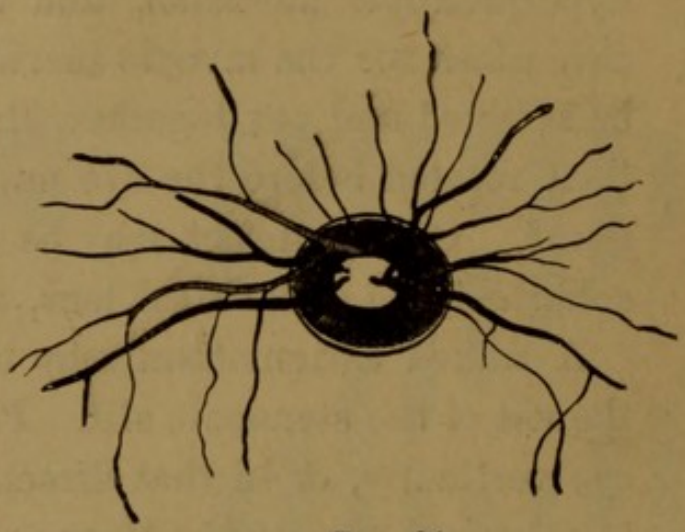

FIG. 21.

The same disc seen by the direct method (upright image). After Nettleship.

the disc appearing oval instead of circular. With the upright image it may be approximately measured. We find the lens which, placed behind the hole in the mirror, gives us most distinctly a vessel running in one direction, then replace this lens by one which gives us the most distinct view of another vessel running in an opposite direction. The difference in the power of these two lenses is the measure of the astig-

matism. Similarly by the shadow test (see page 70), if we note the strength of the lens before the eye of the patient that reverses the direction of the reflex or shadow in one meridian, and then the lens required to reverse the shadow in the meridian at right angles to the first, the difference in strength of the two lenses will give an approximate measurement of the degree of astigmatism. The curve of the cornea sometimes changes perceptibly from pressure of the lids and external muscles of the eye. The degree of astigmatism is also varied more or less at different times by the exercise of the power of accommodation.

Astigmatism uncorrected by glasses may, of course, give rise to accommodative or a mixed form of asthenopia.

It is indeed a very frequent cause of painful asthenopic symptoms, and in such instances requires the corrective glasses to be selected with great care and accuracy. Hypermetropia with astigmatism, in young persons, is supposed to pass over frequently into myopia.

In view of this it may be said that astigmatism is, in early life, a most serious optical defect, and that its subjects, like those that are myopic, should be carefully guarded during the educational period. The later the earnest study from books begins, in the life of children with these errors of refraction, the less probability of harm to the eyes. If school life, or protracted reading, writing, and drawing, were never begun before the age of eight or ten, weakness of vision would notably decrease. In the case of school-children, therefore, whenever there is a doubt in regard to the optical condition of the eyes, it is the duty of the family physi-

cian to advise that they should be examined by a competent ophthalmic surgeon.

MUSCULAR INSUFFICIENCY. LACK OF MUSCULAR EQUILIBRIUM. MUSCULAR ASTHENOPIA. DYNAMIC SQUINT.

This condition is due to weakness of an external ocular muscle, or to an increase of tension in the opposing muscle; the result is a lack of muscular equilibrium which sometimes gives rise to asthenopic symptoms and especially to headaches. Exceptionally, a number or all the ocular muscles appear to be weak. Errors of refraction, a neurotic temperament, or an exhausting occupation or illness are apparently the cause of this condition.

[When all refractive errors have been corrected, and even in cases in which the refraction has always been normal, we occasionally meet with patients who still find difficulty in using the eyes, and who complain of soreness of the eyeballs, headache, and a strained, tired feeling when the eyes are used for any length of time at close work. Frequently more pronounced nervous symptoms are present, nausea, dizziness, insomnia, pain in the spine, or general nervous exhaustion.

The tenotomy, especially of the upper or lower muscles, should never be attempted by one not skilled in ophthalmic surgery, because of the danger, in such nice re-adjustments, of over-correction. Injudicious tenotomy in chorea and epilepsy has given warrant to the severest criticism of conservative surgeons; but while it is too early to determine the full value of this opera-

tion, it is beyond question that in certain nervous diseases, even chorea and epilepsy may be influenced by imperfect co-ordination of the eye-muscles; and while it has long been recognized that nervous diseases not infrequently affect the eyes, it is a fact, becoming daily more emphasized, that we may trace the origin of many baffling nervous derangements directly to eye-strain. The nicest discrimination is necessary, therefore, in these cases, in locating the exact relation of cause and effect.

There can be no absolute standard of the strength of the muscles of the eyes, as variations will depend upon the age and general physical condition of the patient; but it has been found that, as compared to its antagonist, each muscle must have a relative strength that can vary only within narrow limits. If, for example, the internal rectus is able to overcome a prism of 40°, the external rectus should overcome a prism of not less than 6°. The ratio is about 6 or 7 to 1. If any one of the external ocular muscles is disproportionately weak, it may be impossible to use the eyes without either local or general discomfort.

The method of testing the eyes in these conditions, while simple, requires patience and care. A candle flame at a distance of twenty feet is the object usually chosen. Now if a prism of sufficient strength were placed before the eye, double vision would be produced. In testing the strength of any of the straight muscles of the eye, prisms of increasing strength are placed before the eye, the edge towards the muscle whose strength is to be determined, and the strongest

with which single vision can be retained will measure the strength of the muscle.

In manifest weakness of one or more of the muscles, the cause, if possible, must be found. It may be dependent upon general constitutional weakness, or may follow any exhausting illness, but more commonly it is the result of protracted eye-strain.

Treatment.

If muscular weakness is simply a reflex symptom from ovarian, rectal, gastric, or spinal irritation, the original disturbance must, of course, first be determined and corrected. If, however, nothing points to any such possible cause, or if, as sometimes happens, the asthenopia persists after the possible cause has been removed, the attention must then be directed to the eyes.

It will frequently be found that the refraction is imperfect, and the adjustment of suitable glasses will often strengthen the atonic muscle by removing the strain upon which the weakness was dependent.

But in a certain proportion of cases, the insufficiency of the muscle will be the only defect apparent, and our efforts must then be directed towards a restoration of the normal balance. This may sometimes be done by a system of ocular gymnastics.

Prisms which require some effort to overcome are employed for a certain length of time daily, until the weakened muscle gradually regains its strength.

A more satisfactory method will be found, however, in the use of weak prisms placed to relieve the strained

muscle and which may be worn continuously. Noyes has found in a large experience that many permanent cures may be made in this way.

Having exhausted other methods of treatment, operative interference may be considered, and the tendon of the muscle which is disproportionately strong may be partially or entirely divided.

Before determining upon this method of procedure, the diagnosis must be verified by most careful tests. Ordinarily, tests may be made as already described; but before venturing upon a tenotomy the relative strength of the muscles should be ascertained beyond question, and an instrument of precision is valuable. Stevens has devised such an instrument, which he calls a phorometer. It consists of an upright supporting a cross-bar; upon the latter is a spirit-level, which makes it possible to obtain a perfect horizontal. In a sliding groove on the cross-bar are placed prisms with the bases out, and of such strength that double images are obtained. If the head of the observer is held erect, and the eyes are properly placed, these double images should appear on the same plane.

If there is a difference in the height of the images, it will indicate a difference in strength or position of the corresponding vertical muscles, and the difference may be measured by another prism held with the base up or down until parallelism is restored.

In a like manner a lateral divergence is shown. A prism is placed with the base up or down upon the phorometer, and when the muscles co-ordinate, the double images will lie in the same vertical meridian.

If one should deviate to one side or the other, the degree of prism which will again bring it in line, will indicate the proportion of cases of severe functional nervous disease. A surgical restoration of correct muscular balance is followed by brilliant results. — F. P. L.]

For testing the equilibrium of the external ocular muscles I find the simple glass rod of Maddox useful and sufficient in ordinary cases. The rod is to be one fourth of an inch in diameter, and may be three or four inches in length for convenience in handling. Held vertically before the pupil of the right eye, let us say, it changes the form of the gas or candle flame, which is twenty feet or more distant, into a fine horizontal line. This line should pass directly through the flame as seen with the other eye at the same time. If the line passes over or below the flame, then the line of vision with the right eye is below or above that of the left. When the rod is held horizontally before the eye, it changes the form of the flame to a *vertical* line. If this line is seen *with the right eye* at the *right* of the flame, the line of vision tends outward, there is weakness of the external rectus, or what practically produces the same effect, too great tension of the rectus internus. If the fine line seen with the *right* eye appears to the *left*, there is weakness of the internus. That is, if the line is seen at the right with the right eye and at the left with the left eye, there is weakness of the externus and too great convergence. The degree of a prism put before the naked eye, base out, that just brings the line into the flame gives the amount of the over-convergence, — that

is, the measure of the weakness of the recti externi. In case of too great divergence the lines being seen at the *left* with the right eye, and at the *right* with the left eye, the measure is made with a prism, base in, similarly.

Adduction of the eye is found by placing prisms of increasing strength, base out, before the naked eye; the strongest through which the eyes fuse the two images of a candle-flame at twenty feet, gives its measure. *Abduction* is found by prisms, base in, similarly.

The Stevens nomenclature for these muscular deviations is convenient, and is as follows:—

Orthophoria, the visual lines tend to parallelism.

Heterophoria, the visual lines do *not* tend to parallelism.

HETEROPHORIA
- *Esophoria*, visual lines tend inward.
- *Exophoria*, visual lines tend outward.
- *Hyperphoria*, tending of the visual line of either eye above its fellow.

Hence *exophoria* signifies insufficiency of the internal recti, and *esophoria* of the external recti. *Hyperexophoria* would signify a tending of the visual lines upward and outward, and *hyperesophoria*, a tending of the lines upward and inward.

To restore parallelism of the visual lines in esophoria, a prism with the base out is required; in exophoria, a prism with the base in. Very often there is an error of refraction to be corrected also, so that a convex lens in esophoria is combined with the prism, and in exophoria, a concave lens with the prism may also be necessary; and in either case there may be astigmatism, so that

sometimes one spectacle lens may be ground as a prism, a cylinder, and a spherical lens, to meet the required conditions.

I do not find the daily gymnastic exercise of the external ocular muscles with prisms, as recommended by Stevens and others, to be of great benefit. Some patients say that these exercises make the eyes feel better; but I do not find that the weaker muscles are strengthened thereby. The apparent increase of strength in the internal recti is undoubtedly due to the knack that the patient gets of using his accommodation. Thus a patient of mine in a short time could overcome prisms of 80°, base out; but his exophoria of 1° remained the same as in the beginning when his adduction was only 24°. Some patients do not acquire this knack readily, and then there is no apparent increase of strength in the internus.

Prisms to assist the weaker muscles may often bridge over the unpleasant effects of muscular disarrangement until improvement takes place and the eyes work well without their aid. The asthenopia of a muscular insufficiency is often due to merely temporary lack of innervation in feeble or neurotic subjects. The apparent relative strength of the external ocular muscles in such persons, as measured by prisms, is extremely variable. Such a patient showed an exophoria of 16°, but after four days only 10°. After wearing prisms of 3°, base in, for two weeks the exophoria measured 16°, then a week later 8°; a week later it became an esophoria, and later a slight exophoria. The prisms were discarded, a correction of a slight myopic astigmatism was made, the

Dyer method of exercise of the eyes practised, and the asthenopia and headaches steadily improved.

In most people, an apparent want of muscular equilibrium is without significance; and the same is true of those showing a weak adduction or weak abduction. A medical friend shows an adduction of 10°, an abduction of 7°; but he has never had an asthenopic symptom. Another shows an esophoria of 1°, his adduction 7°, his abduction is 9°; and these measurements were carefully made and repeated. He should suffer from exophoria and suffer badly; he has never had anything more than a slight accommodative asthenopia from over-sight of one dioptric. A lawyer with adduction of 9° and abduction of 8° never had a symptom of eye ache, and rarely a headache in his life.

Instances like these are not rare. The conditions as stated above, and the varying and unstable tension or weakness of these muscles are recognized by surgeons generally; but the situation calls for great conservatism in respect of operative interference. Tenotomy, or "button-holing," should be held in reserve for rare and exceptional cases. Some of the more distinguished ophthalmic surgeons, indeed, strongly oppose these operations. Thus Roosa says,[1] in speaking of the prevailing treatment of muscular insufficiencies by many surgeons, "As to tenotomies nowhere in surgery has a more desolate field been left by operative procedure, than that made by oculists and neuralogists with mistaken zeal in the cutting of muscles of the eye." He says further, "I believe that none of these insufficiencies

[1] Ophthalmic Review, vol. ix. p. 286.

lead of themselves to asthenopia," of which he believes refractive errors to be the cause, and that to the error of refraction is due the insufficient muscular action. "Those who have been examining the muscles so carefully have been considering effects, not causes."

PRESBYOPIA.

Far or old sight is a symptom of advancing years, and is due to senile loss of elasticity in the lens. Distant vision remains good, but no effort of the ciliary muscle is sufficient to render the lens convex enough to bring rays of light from near objects to a focus on the retina. Hence the necessity for convex glasses. It is *not* advisable to postpone the use of glasses as long as possible at the expense of discomfort and fatigue of the eye. The proper glasses for a presbyope are such as will enable him to read No. 1 at ten or twelve inches. It is convenient to have two pairs of spectacles, the stronger one for evening use. *Rapidly increasing presbyopia* is to be viewed with suspicion, as it is often a precursor of glaucoma.

SECOND-SIGHT,

popularly so called, occasionally comes to elderly people who, after using glasses for years, find themselves able to dispense with their aid, and yet read with tolerable comfort. Such persons have unusually small pupils, so that, practically speaking, only the central rays of light are admitted to the eye, and no focussing power is called for.

may also occur, so that not only is the absence of convex, but the substitution of concave, glasses an improvement to the vision. Such instances are due to commencing cataract, when, as sometimes happens, the lens has become more convex from swelling, but still retains its central transparency. This condition is often the explanation, also, of the "second-sight,"—ordinary print, in such cases, being read more easily without the usual convex glasses.

CHAPTER VI.

THE CONJUNCTIVA.

PASSIVE HYPERÆMIA OF THE CONJUNCTIVA.

HYPERÆMIA of the conjunctiva is of very common occurrence, and is due to over-use or abuse of the eyes, or to optical defects, as in asthenopia. The appearance of the eye is very similar to that observed in mild conjunctivitis, but there is no discharge from the conjunctiva, and usually very little or no lachrymation, and the smarting, itching, and heaviness of the lids is markedly increased in the evening. Reading manuscript by strong artificial light, or by a too weak light, and the hazardous practice of reading habitually in the horse and steam cars, and that worst and most dangerous of habits for the eyes, that of reading in bed by artificial light, — often excite this congestion. This state of the conjunctiva may be a reflex symptom of a similar condition, or more serious disease, of the internal structures of the eyes. The use of the eyes for reading increases the hyperæmia and asthenopic symptoms, if such are present.

Treatment.

To cure this affection, it is of course necessary to remove its cause. Optical defects must be remedied by appropriate glasses. Injurious use of the eyes must be

given up and overwork proscribed. As palliatives, the use of the eye douche, always with closed lids, is excellent, or bathing in tepid water, or vinegar and water, a few drops of tincture of hamamelis or tincture of opium or of hydrastis in a cup of water, or a grain or two of sulphate of zinc, or of acetate of lead, — any of these, adhering of course to the one which seems most grateful to the eye, may be used as a fomentation, either warm or cold, to the lids several times a day. If preferred by the patient, these lotions may be used to saturate a bit of lint or linen which may be laid over the lids for a quarter of an hour, three or four times a day. The solution need not enter the eye, but will, of course, occasion no pain of consequence in case this should happen. Sometimes fomentations of very hot water for five minutes, three or four times a day, suffice.

CONJUNCTIVITIS.

An inflammation of the conjunctiva is easy to diagnosticate, and yet a mistake is possible if one is not in the habit of observing accurately the difference in the appearance of a reddened eye in different kinds of inflammation. For instance, in the simplest conjunctivitis, in place of the usually invisible vessels of the conjunctiva, we have a network of bright red vessels plainly seen to be superficial and movable by the touch of the finger over the smooth surface of the sclerotica. On the other hand, in a severer, deeper-seated conjunctivitis, like the scrofulous, or lymphatic, and the granular, we have, in addition to this vascular network, the close parallel lines of immovable sub-conjunctival ves-

sels running towards the edge of the cornea, in a state of congestion. This condition gives a pinkish-red zone around the cornea, often more clearly defined in iritis and keratitis. In scleritis, or episcleritis, there is presented still another redness of a violet or purple tinge. It appears nearly always in rather large and tolerably well-circumscribed patches, and is sometimes mistaken by the general practitioner for phlyctenular conjunctivitis, although the bright red color and papular appearance of the latter, and the peculiar color of the deep-seated spots of the former, render the differential diagnosis easy in ordinary cases.

Simple Conjunctivitis.

Simple conjunctivitis differs in degree, rather than in form, from the acute catarrhal. It is generally the result of slight injury to the eye, contact of a foreign body, exposure of the eyes to dust, smoke, cold winds, or dampness, glare of light, impure air, or from some other local cause. The subjective symptoms are very trivial usually. There may be some itching and sensation of heat in the lids, or a feeling as if there were sand in the eye. We ought to determine by ocular inspection, whenever our patient complains of a sensation as if a foreign body were in the eye, or when a simple conjunctivitis does not yield readily to treatment, whether there may not be some foreign substance lodged beneath the upper lid. The immediate cure of a conjunctivitis after three weeks of ineffectual treatment, by the simple eversion of the upper lid and the removal of a bit of quartz, is mentioned in the chapter on Injuries of the Eye.

Catarrhal Conjunctivitis.

The objective symptoms in *catarrhal conjunctivitis* are more marked than in the simple form of the affection. The congestion of the superficial vessels of the conjunctiva is greater, and in elderly people chemosis may be present. The edges of the lids appear swollen, the palpebral conjunctiva is distended from serous infiltration, particularly at its reflected portion, its papillæ are enlarged, and its surface presents a velvety appearance. There is a secretion of clouded mucus, alternating sometimes with a secretion muco-purulent in character. This discharge is often abundant, but rarely as profuse as in purulent conjunctivitis, and is more or less contagious. Probably the contagiousness is in direct ratio to the increased admixture of pus globules in the discharge. A healthy conjunctiva may be successfully inoculated with the secretion of an acute catarrh.

The subjective symptoms are not very characteristic. There is the complaint of not seeing well at a distance, and the common symptom of a feeling at first of dryness, and as if sand or some foreign body were in the eye, and there is a heavy uncomfortable feeling about the lids which leads to a desire to rub them, and frequently a slight burning and smarting sensation. There is rarely severe pain, nor is the photophobia marked. The above subjective symptoms vanish, to a great extent, as a case becomes chronic. As to the treatment, it should be simple in acute cases. No doubt acute catarrh of the conjunctiva, under proper hygienic conditions, and under circumstances controlling the causes

which have produced it, frequently disappears in the course of a week or two without any treatment whatever. In other cases, however, it may be sufficiently severe from the commencement to require treatment.

Treatment.

In the first or inflammatory stage the cold douche, or cold compresses, will afford great relief. No irritating collyria are permissible at this stage. Later, simple collyria, such as a solution of five to ten grains of borax, four grains of boracic acid, two grains of alum, or one grain of sulphate of zinc, one grain of nitrate of silver, each to the ounce of water, will often be found serviceable. A solution of bi-chloride of mercury 1 : 10000 may sometimes be useful also. If the affection prove very obstinate, and the discharge assume a puriform character, the case should be treated as a purulent conjunctivitis. A solution of nitrate of silver, of five grains to the ounce of water, may be used, but not as a collyrium. The lids, upper and lower, should be everted, and held in this position with the left hand; the patient should close the eye gently, this will bring the everted lids together and prevent contact with the cornea. The conjunctiva thus exposed is painted by means of a camel's hair pencil with this solution, which after a second or two is washed off with tepid water from another pencil. If the pain is afterwards severe, it will be relieved by bathing the eyes in cold water, by cold compresses, and frequently through simple contact of the eyes with the cool out-door air.

The applications may be made daily or on every second

day. The good results that often follow this use of the nitrate of silver are doubtless due to its germicidal properties. If active inflammatory symptoms are present, — that is, a very bright red, congested, and swollen conjunctiva when the sub-conjunctival vessels are visibly involved, and when the ciliary nervous system is sensitive, as shown by pain and photophobia, — irritating applications should not be made. In all cases where irritating collyria are used, it is advisable not to push their employment too continuously, but rather alternate them from time to time with the use of the cold compress. In chronic cases it is advisable to see that a collyrium which the patient takes home be not too strong. It is necessary, also, to remember that in a conjunctivitis occurring in two individuals of different nervous organization, where in each case it seems to be of the same nature and to require the same remedy, one may use a wash with great benefit which the other may be quite unable to bear. Whenever, therefore, there is doubt about the strength of the solution it is advisable to instruct the patient that if the pain after its use continues beyond a minute or two, it is too strong, and should be diluted with an equal quantity of water. It is safer, also, to direct that the collyrium be used not oftener than twice a day. It has often been my experience, when called in consultation with physicians, to find that in conjunctivitis, complicated and uncomplicated, collyria when used at all have been frequently too strong, applied too often, and to eyes already too sensitive and irritable.

We should bear in mind the contagiousness of some

catarrhs of the conjunctiva. The patient should be warned of this danger, so that he may not propagate the disease. Frequently the affection assumes an epidemic character, attacking whole families and neighborhoods. In the chronic form of this affection the results of topical application to the lids will not prove as satisfactory as in the acute. Improvements will be followed by relapses, and many cases will prove extremely tedious in treatment. If, however, the affection seems to be purely local and confined to the eyes, our prognosis will be more favorable than when it is merely a part of a catarrhal affection of the air passages generally or of the lachrymal duct.

"*Pink eye*" is a form of epidemic catarrh seen mostly in young people, which is quite contagious and is usually most prevalent in the spring months. It derives its popular name from the fact that the ocular conjunctiva is usually deeply congested, giving the eyeball a noticeably pinkish-red hue. It is best treated by cold at the beginning and later by mild astringent washes. Owing to the ciliary irritation, pain, and photophobia irritating collyria are not well borne. A 1% solution of boracic acid I have found useful, also nitrate of silver 1:500 and bi-chloride of mercury 1:25000. The disease, supposed to be caused by a small bacillus constantly found in the discharge, does not invade the cornea and the prognosis is favorable.

HYGIENIC MEASURES.

In conjunctivitis of all kinds, attention should be given to hygienic regulations. Very sensitive eyes should be protected against bright light during the day or

night by plain blue or smoke-colored glasses, which will afford also a measurable protection against wind and dust. Grayish-yellow glasses are lately recommended as grateful to the eyes if photophobia be present. The patient should use the eyes with moderation, especially by artificial light, and should carefully avoid all places where the air is necessarily impure, — such as crowded rooms, like the theatre, lecture-room, ball-room, or rooms where tobacco-smoke prevails. He should be counselled also to avail himself, as much as possible, of the beneficial influence of a pure out-door air, and should be advised that when necessary to use the eyes in reading, writing, or fine work, preference should be given to the morning hours when the light is constantly growing better.

PURULENT CONJUNCTIVITIS.

Purulent conjunctivitis, which is to be regarded only as a severer and more dangerous form of the catarrhal, is distinguished from the latter by the character and greater abundance of the secretion, the greater swelling of the lids in consequence of the serous infiltration being also sub-conjunctival, the great injection of the sub-conjunctival vessels as well as the increased vascularity of the conjunctiva proper, the chemosis so frequently present, and by the increased size of the mucous papillæ, often termed granulations. One of the most practical methods of determining at once whether you have a blenorrhœa or a simple catarrh to deal with, is, by the easy proceeding so long taught in the clinics of Arlt, of Vienna. The upper lid is to be everted, and if the

conjunctiva is sufficiently transparent for us to see the lines of the meibomian glands running towards the edge of the tarsus, we have a catarrh; if the infiltration is so great as to hide these glands, we have no longer a catarrh but either a purulent, a granulated, a diphtheritic, or some graver form of ophthalmia. In purulent conjunctivitis the cornea is apt to become involved, and this form is generally more contagious.

The Treatment,

during the inflammatory stage in which there is often considerable fever, must be purely antiphlogistic. Ice-water compresses should be perseveringly used, and these with the perfect quiet of the patient, and the administration of aconite, suffice to control measurably the acute symptoms. I have never resorted to the use of leeches, and I have often seen them used in these cases when I thought them unnecessary. If but one eye is attacked, the other should be bandaged as a precautionary measure, and in all cases of purulent ophthalmia the attendants should be warned that the greatest cleanliness and attention to the contagious character of the secretion is necessary for their own safety. After the inflammatory symptoms are subdued, as shown by the diminished swelling of the lids and the pale-red and relaxed condition of the conjunctiva, and the watery discharge become thicker and purulent, anti-septic applications are indicated. If the cornea is involved, care must be taken that a caustic application does not come in contact with it, by painting it on the everted lids and immediately washing it off as pre-

viously directed. See Treatment of Gonorrhœal and Infantile Ophthalmia.

Egyptian, or military, ophthalmia is a variety of purulent conjunctivitis often complicated by a follicular granulation. It was first recognized and named after an unprecedentedly severe epidemic originating in the troops of the English and French armies stationed in Egypt. It spread so fearfully that after the Napoleonic wars, England alone had upward of five thousand blind invalided soldiers to care for. It is doubtful whether this form of the disease is more contagious than any other. Very likely any form of the affection getting a foothold among masses of people crowded together — as in armies, almshouses, and charitable institutions — would spread rapidly. Uncleanliness and bad ventilation are attractive conditions for this disease. The contagion of a purulent ophthalmia, as is well known, may engender a very light or a very severe form of the affection, — a mere catarrh or a diphtheritis. In the beginning the disease is hardly contagious, but becomes so as it progresses, and the discharge increases in quantity and consistency. The form of the disease produced by contagion seems to depend on local or atmospheric conditions as well as upon the constitution or age of the person infected. See Treatment of Follicular and Granular Ophthalmia.

INFANTILE OPHTHALMIA.

Conjunctivitis in the New-born.

Ophthalmia neonatorum is a purulent conjunctivitis which comes on a day or two after birth. Excep-

tionally it may make its appearance not until the sixth or seventh day after birth. It begins by a redness and swelling of the lids and a slight watery discharge which sometimes increases with great rapidity a few hours later. Its cause is generally to be sought in a gonorrhœal or leucorrhœal discharge of the mother. In mild cases where the discharge is whitish, not very abundant, and chiefly mucous in character, the free use of cold compresses, a careful and frequent removal of the secretion with a bit of absorbent cotton may suffice to carry the case through to a speedy and successful termination. Such are mild cases. In other instances the affection is severe, and requires prompt and energetic local treatment in order to insure favorable results. The responsibility of the physician in a severe case of ophthalmia neonatorum is very great. Intelligent treatment is surprisingly effective, but negligent or unskilful treatment is often deplorable. Our asylums for the blind afford many mournful examples of the results of neglect or bad treatment in this affection.

TREATMENT OF SEVERE CASES.

If the disease increases in severity in spite of our treatment, we ought never to neglect to determine by careful inspection whether the cornea be intact or not, because upon this condition depends the treatment and the nature of our prognosis. It is not a very difficult matter to obtain a view of the cornea even when the lids are much swollen. The child is to be held by the nurse, its head resting between the knees of the surgeon, and in this position there is generally little difficulty in

forcing the lids apart. If the fingers alone are insufficient in consequence of the swollen condition of the conjunctiva, an elevator may be used. It is remarkable how neglectful many physicians are of this simple procedure, but in no other way can a case be treated intelligently. After the inflammatory symptoms have been reduced by the use of cold compresses, and the discharge has become purulent, I use a collyrium of nitrate of silver, one grain to the ounce of water. It is quite mild, and I believe generally very effective. It is particularly indicated when the discharge is copious and wholly purulent. This should be dropped into the eye, after it has been carefully cleansed from the discharge, twice a day. A change of collyria often hastens the cure; and one of the best substitutes for the above is boracic acid, ten grains to the ounce of water. It may be used five or six times a day, or one may use a mild wash of bi-chloride of mercury 1:20000. In a few days, if the profuse discharge still continues, and especially if the increased haze upon the surface of the cornea indicates a complication in this direction, a solution of five grains of the nitrate of silver to the ounce should be painted with a brush upon the everted lids and immediately washed off with tepid water or neutralized by the application of a solution of common salt and water. No evil consequences whatever can result from this proceeding, and not unfrequently the beneficial results of it are seen after a single application. It need not be often repeated. Cold compresses may be employed to lessen the irritation immediately afterwards, and I prefer as internal remedies after aco-

nite in the commencement, mercury when the discharge is profuse, and the alternation of arsenicum with this remedy if the cornea is ulcerated. It is advisable in these cases, so long as the discharge is profuse, to direct that the discharge be carefully removed from the eye every half hour with absorbent cotton, by day, and every hour by night. I will give the outlines of a case which occurred twenty years ago in illustration of this treatment.

Mrs. G., of Boston, brought to me her babe, three weeks old. It had been suffering from purulent conjunctivitis since two or three days from its birth, and, up to the date of her visit, had been steadily growing worse. The physician in attendance had not attempted an examination of the cornea, but had advised her to keep the eyes as free from the discharge as possible, to apply cloths wet in cold water, and had administered small powders internally. The lids were somewhat reddened and swollen in appearance, and considerably puffed up, from the quantity of pus beneath them. After the removal of the accumulated pus, which was accomplished by repeatedly separating the edges of the lids, giving it exit, and wiping it gently away with a soft sponge wet in tepid water, I was able, by means of an elevator, to open the lids sufficiently to determine the condition of the cornea, and make a prognosis as well as diagnosis. The cornea of the right eye was found hazy, and slightly opaque at its upper and inner edge. In the left eye, the corneal opacity was greater; and directly over the pupil was an ulcer which had already broken through, and occasioned, as I afterwards found, a deposit of matter upon the anterior surface of the capsule of the lens, and a slight adhesion of the free edge of the iris. The mother was informed that the mischief done to the left eye was irreparable; that perfect restoration of sight was impossible; that the disease would probably progress no further, and that vision, to a limited extent, would be preserved to this

eye. As to the right eye, there was no question as to its perfect restoration. The lids were reversed and painted with a solution of nitrate of silver, ten grains to the ounce of water, which was allowed to remain only a second or two, and immediately washed away with tepid water. The nitrate of silver was used in an unusually strong solution, because it seemed necessary to check at once, if possible, further progress of the disease. I have noticed that when a case is severe, the lids considerably thickened, and the mucous papillæ very much swollen and prominent, it will bear, with good results and without marked reaction, a much stronger solution of nitrate of silver than it would be prudent to apply in a milder case. In this instance, the mother informed me, on her second visit, that the night after the application of the caustic was the best which the child had passed since its birth. There had been no reaction, and consequently no application of cold to the lids had been necessary. Under the circumstances, I concluded to touch the lids a second time with the same solution. This was done on the second day; and again the child had a remarkably comfortable night. On the fifth day, the discharge, which had been very profuse, was considerably lessened in quantity. The mother herself could see a decided improvement, and began to have great confidence in the treatment. I now diluted the solution with an equal part of water, making it five grains to the ounce; and after a week, it was reduced still more, making it about two grains to the ounce. I had taken the precaution, also, of dropping into the left eye a solution of atropine, two grains to the ounce, in order to draw away the edge of the iris as much as possible from the corneal opening. The application of the solution above described was made but six times, at intervals of forty-eight hours, when, the discharge having almost entirely ceased, I gave the mother simply a solution of sulphate of zinc, one grain to the ounce of water, to be dropped daily into each eye; and in two weeks from this time the child was well enough to require no further treatment.

THE PREVENTION OF INFANTILE OPHTHALMIA.

At the Lying-in Hospital at Leipsic the following prophylactic treatment is adopted. The eyes of the infant are immediately washed out with water, a drop of a two per cent solution of nitrate of silver is instilled, and the eyes are covered for twenty-four hours with cool compresses moistened in a two per cent solution of salicylic acid. These measures were first adopted for the infants of diseased mothers only, but subsequently extended to all others. The result was, that for six months, in two hundred infants so treated, not one case of ophthalmia occurred. In one case where the application of the nitrate of silver had been accidentally neglected, a slight case of conjunctivitis appeared.

A simpler treatment is employed at Halle; namely, for nine months the eyes of the infants were washed out, as soon as the head was born, with a one per cent solution of carbolic acid. This treatment reduced the percentage of ophthalmia from 12.5 per cent to 3.6 per cent, and the disease when it did appear assumed a milder form.

It would seem, in view of the above facts, that a grave responsibility for the condition of the eyes of the new-born rests upon the obstetrician. I recall last year an otherwise perfectly healthy infant, sent to me by the family physician for treatment; the child was four weeks old, and both corneæ wholly destroyed from purulent inflammation. Of course the child was totally blind, and was to go through life totally blind. Such cases would be almost impossible if a careful prophylactic treatment were generally observed. It is entirely feasible for a physician to carry out the treatment.

Undoubtedly nitrate of silver is the most available germicide we have for the eye. A solution in water of 1 : 100 — that is, four to five grains to the ounce — destroys vitality in about twelve seconds. Carbolic acid is too irritating for the eye, in any solution strong enough to be effectual, and the same may be said of bi-chloride of mercury, 1 : 1000 being required to destroy vi-

tality in forty-five seconds. To be effective the fluid should act quickly because it becomes diluted almost at once by the secretions of the conjunctiva. A 1 % solution of nitrate of silver is therefore the preferable germicide to be used as a prophylaxis; and the next best, but far less certain, and more irritating, are carbolic acid 1 : 100 and bi-chloride of mercury 1 : 5000. Boracic acid prevents the development of germs but does not destroy them. A ¼% nitrate of silver solution will produce a similar effect.

GONORRHŒAL CONJUNCTIVITIS.

Gonorrhœal conjunctivitis, so called, is a variety of this affection associated with a similar discharge from the urethra, due to sympathy or extension of the virus over the system, or, as more frequently happens, to direct contact of a urethral discharge with the eye. In the former case, the attack occurs simultaneously in both eyes; in the latter, it commences in one eye first, generally the right, and in its severe form is one of the most rapid and destructive diseases to which the eye is subject. In its mild form the disease resembles a light purulent ophthalmia, and requires similar treatment. In the contagious form, the inflammation is sometimes exceedingly violent. I cannot describe the nature and treatment of this disease better than by giving the main details of a case of a severe type under my care many years ago.

CASE OF GONORRHŒAL OPHTHALMIA.

G. L., a young man of seventeen, was brought me by his father, Oct. 10, 1868, to be treated for an inflammation of the eyes. The right eye was closed, the upper lid so largely swollen that, at first glance, I thought of abscess. On turning my atten-

tion for a moment to the other eye, the lids of which were but little affected externally, I noticed considerable injection of the vessels of the conjunctiva on either side of the cornea. The affection of the right eye had been noticed first two days previously; but the great swelling had not come on until this morning. The pain was not very severe; the patient, pale and anxious-looking. The lower lid was but slightly distended, and by drawing it downward and away from the upper one which overlapped it, I could see a marked chemosis of the conjunctiva of the globe. There was no doubt about the diagnosis of the case. As the father seemed nervous and apprehensive, however, I concluded to say nothing about its peculiar nature for the moment, telling him simply that the affection was severe, that the left eyelids, on the next day, would probably be very much in the condition presented by those of the right eye to-day; that the boy was not well enough to be out, and that he must be treated in bed. Ice-water compresses to be applied to right eye constantly, and to the left whenever the cold could be borne or felt grateful. Aconite to be taken every hour.

The next morning the external appearance of both eyes was about the same, the upper lids of both being enormously distended. The right was less sore to the touch, and I was enabled to determine the state of the globe more definitely. The cornea was still intact, but considerably lessened in circumference through the overlapping of the conjunctiva, the chemosis being very great. The conjunctiva bulbi was red and puffed, looking "like a piece of raw meat." Pulse, one hundred and twenty. Ice-water compresses to be continued night and day. Aconite internally. I now ascertained that the patient had contracted a gonorrhœa three weeks previously. The discharge from the urethra is still rather profuse.

Oct. 12. Externally the swelling of the lids is somewhat lessened, the appearance of the eyes the same. The discharge is rather thin and flocculent, not such as could be desired. The pain is not severe; pulse about the same; prognosis doubtful. The same treatment to be continued. The sanious discharge

to be wiped out from beneath the upper lid with a camel's-hair pencil moistened in warm water, and the edges of the lids to be tenderly cleansed with a soft sponge and tepid water,

Oct. 13. Swelling of the lids much lessened externally. Inflammation is still too acute to admit of caustic application. Appearance of the globe the same, the chemosis being considerable. Discharge still watery and slight. Used twice a day a weak solution of carbolic acid in cleansing the inner surface of upper lid. Attendants getting weary and worn in changing the ice-water compresses night and day, I had two little ice-bags constructed and connected by a bridge, like diminutive saddle-bags, to be saddled across the nose, the little bags filled with small bits of ice to rest one over each eye. The upper lid was found still too tender to bear their weight, but a day later they could be borne, and were afterwards used constantly, thereby saving the nurses much labor. Aconite and mercury internally. The discharge during the next few days became more copious and pus-like, and the external lids became gradually less swollen and red.

Oct. 15. Appearance of conjunctiva nearly the same; cornea not fully transparent, that of the right eye quite hazy at its upper third. Raised the upper lids and painted them with nitrate of silver, five grains to the ounce, immediately washing it off with tepid water.

Oct. 16. Treatment continued.

Oct. 17. Considerable pain in the left knee, which I found slightly swollen, and very sensitive to touch. A water compress was applied; pulse, which had fallen to one hundred, now rose again to one hundred and twelve. Aconite and macrotin internally.

Oct. 18. Left knee-joint largely swollen, measuring, with the leg extended, fourteen inches at its largest circumference; sensitive to pressure, and immovable; but less painful than yesterday. Right knee painful, and beginning to swell. Discharge from urethra continues. Eyes much the same in appearance. Cornea of right eye the worse of the two. Prognosis, which

had seemed for a few days more favorable, now again doubtful, in consequence of this new inflammation of the knee-joints, which bids fair to reduce the vitality of the patient as it has already his courage, and renders the question as to the power of the cornea to maintain the integrity of its tissues a doubtful one. Treatment continued.

Oct. 22. Fever lessened, more appetite, knees less painful, but largely swollen, and the right one immovable. Eyes no better; discharge quite copious. Treatment the same.

Oct. 23. Discovered, this morning, what I had been fearing from the first, — namely, ulceration of the cornea. The chemosis having in a measure subsided, the conjunctiva bulbi had receded from the edge of the cornea, which it had previously overlapped, and so uncovered in the right eye a crescent formed ulcer extending nearly around the upper half of its circumference. It was deep, its edges sharp and clean, so that it was necessary to look closely in a favorable light to see its whole extent. An ulcer on the left cornea in nearly the same relative position, not so great in extent, but still ugly and dangerous looking, was discovered also. Both ulcers looked, I thought, as though they were growing larger, therefore without some change of treatment the right eye would certainly be lost, and perhaps the left one too. I therefore made an immediate change in treatment. His pulse was one hundred, the tongue was nearly clean, and he had expressed a strong desire for solid food. I determined, if possible in the present state of his digestive organs, to gratify his wish to the fullest extent. A rare beefsteak was prepared for him at once, and he was to be fed similarly three times a day. Beef-tea was also to be in readiness, so that if he tired of steak it could be substituted for it. He was to have at each meal all the rare beef he desired. I further substituted for the solution of nitrate of silver, which I had been using, one of fifteen grains to the ounce, applying it thoroughly to the reflected portion of the upper and lower lids, and immediately washing it away with tepid water. It caused no pain whatever. Mercury and macrotin were given internally.

Oct. 24. Ulcers look no better; knees improving slowly, and can be drawn up or moved slightly without great pain, but are still largely swollen. Patient eats freely of the steak and digests it without trouble; slept better than usual through the night. The discharge from the eyes is rather less; continued treatment; but before the cauterization I dropped a solution of atropine into each eye to keep the iris rigid, and as much as possible away from danger in case of rupture of the cornea from the ulceration. After the cauterization the eyes are bandaged sufficiently tightly to prevent movement of the lids. I find the eyes bear this cauterization, repeated every twenty-four hours, well, and it has already lessened the discharge.

Oct. 26. Ulceration appears slightly improved, especially in the left eye, where the edges of the ulcer are slightly tinged with yellow, and at the bottom a gelatinous look, as though the reparative process were commencing. Similar indications, but less marked, are also to be seen in the more important ulcer of the right cornea. Patient complains of shortness of breath, which I find is probably occasioned by overtaxing the digestive organs, so I restrict the diet somewhat in quantity, and give nux vomica and bryonia for twenty-four hours. Other treatment continued.

Oct. 28. Shortness of breath gone. The eyes are decidedly better. The ulcers are slowly filling up. Discharge from the eyes less. The cauterization now causes quite severe pain, so that ice compresses have to be resorted to afterwards, for a half hour before bandaging. Internally mercury and macrotin.

Oct. 30. Eyes improving; knees improving also, but slowly. The present solution of nitrate of silver being now too strong, I reduce it one half, making about seven and a half grains to the ounce, which is borne well. Discharge from the eyes much less; from the urethra, also, somewhat less. Patient's appetite good, and he is allowed to indulge it in nourishing food to the fullest extent.

Nov. 6. Improvement in all respects; he manages to walk about the room moderately. Ulcer in the left cornea reduced

to a mere trace, that of the right surely but slowly filling up. He can read coarse print.

Nov. 12. Acuteness of vision is nearly perfect, as the opacity, left on the cornea from the ulceration and the reparative process, does not encroach at all on the pupil.

I may mention here that, some three months afterwards, this patient came again under treatment for rheumatic iritis, — a disease of the eye, which often follows gonorrhœal rheumatism. The affection of iris in this instance was only of three weeks' duration.

Conjunctivitis diphtheritica is very rarely seen in this country or in England. It is occasionally epidemic in Berlin. It resembles the preceding in many respects, but is usually more severe and dangerous. The discharge is at first, yellow, thin, and flocculent, the swollen lids rigid from deep-seated fibrinous effusion, the pain and heat very great. In a few days the discharge assumes a purulent character, the lids become less rigid, there may be fibrinous exudation from the conjunctiva, the cornea is very apt to grow hazy and ulceration or sloughing ensues.

The treatment indicated is that for purulent ophthalmia, except that much greater caution is necessary in the use of caustic or irritating applications.

Membranous or *croupous* ophthalmia resembles the diphtheritic, but is less severe, and there is less rigidity of the lids. It is not often met with here. I have had only two cases in twenty years. The treatment is similar to that for purulent ophthalmia.

CONJUNCTIVITIS FOLLICULOSA

is seen first in the temporal portion of the conjunctiva of the lower lid in a number of slight, semi-transparent vesicles. These are swollen lymph follicles, and when numerous may extend to the upper lid, and cover the entire palpebral conjunctiva, but more thickly the reflected portions. It is often found in connection with granular or trachomatous affections, of which it is a variety, or a milder phase, and like those is due often to unfavorable hygienic surroundings. By itself, unmixed with trachoma, follicular conjunctivitis does not result in cicatricial or other structural change in the conjunctiva or pannus. Uncomplicated cases are nearly always mild, and sometimes so mild as to occasion no inconvenience even when the swollen follicles are quite numerous. But this condition renders the mucous membrane of the lids more susceptible to inflammations of all kinds. Usually the subjective symptoms are those of a hyperæmia; after use of the eyes there is burning, congestion, a feeling as of sand between the lids, and there may be a slight discharge which is contagious.

Treatment.

The simple astringents mentioned for acute catarrhal conjunctivitis will often prove efficacious; but, on the whole, I have found a collyrium of boracic acid, of from six to eight grains to the ounce of water, more generally useful than any other. Strong astringents or caustics should never be used. The affection is often obstinate, recurring again and again; and when this occurs there

will generally be found some constitutional dyscrasia. See Treatment of Scrofulous Ophthalmia. In a case of an adult that I have recently been treating, irritation, lachrymation, and photophobia were the troublesome symptoms. Perfect rest in a dimly lighted room, and the free use of a six grain solution of boracic acid, were the measures that proved most grateful and beneficial. The attack lasted four weeks. He informed me that he was always apprehensive of a recurrence of the disease, as he had suffered from similar attacks, at intervals, for a dozen years. Sometimes they had been slighter, and sometimes more severe than this.

ACUTE CONJUNCTIVITIS GRANULOSA (TRACHOMATOSA)

is characterized by pain in the eye, photophobia from ciliary irritation, and particularly by the sensation as of a foreign body beneath the lids. If the latter be everted there will be noticed in addition to the swollen papillæ, and intermingled with them, little gray points which are true or follicular granulations. After a week or more, the conjunctiva becomes more swollen, the discharge abundant and purulent, and at this stage of the disease it is difficult to distinguish the affection from a conjunctivitis purulentia. This purulent stage continues for some weeks, and may be treated as a conjunctivitis purulentia, exercising great care in regard to the use of irritants. So long as photophobia and lachrymation are marked, no irritating collyria can be used safely. Later, with the exercise of this caution, the affection may be treated like the chronic form mentioned on the next page. *The cause of this affection* is,

generally, defective hygienic conditions and contagion. It spreads rapidly, like the military ophthalmia, among masses of people. Either from neglect of all treatment, or from improper or imperfect treatment, or want of persistence on the part of the patient, the disease is very apt to become chronic. The secretion diminishes little by little, the general inflammatory state of the conjunctiva disappears, and the disease concentrates itself beneath the upper lid, and we have a

CHRONIC CONJUNCTIVITIS GRANULOSA,

and generally this is soon supplemented by an affection of the cornea, called pannus.

Trachomatous pannus is a vascular development within the epithelial layer of the cornea. There is sometimes an extension of the granulations from the upper lid to the ocular conjunctiva, and thence to the cornea, but a pannus may be caused by friction and pressure upon the cornea of the roughened surface of the palpebral conjunctiva, and usually therefore, when we see it, we know without further examination that we have a granulation of the lid. The granulations, which are often of a mixed form, papillary and follicular, are on the inner surface of the upper lid, mostly upon the reflected portion, and the pannus, of course, is generally found upon the corresponding upper half of the cornea. When later, it has extended downward and encroached somewhat upon the pupil, so that vision is impaired, the patient becomes alarmed, and seeks the advice of the physician. The indication in a case of this kind is invariably to cure the granulated

lid. This being accomplished, the pannus disappears of itself.

A further unfortunate condition, whether pannus be present or not, is found in the structural changes in the lids due to old granular affection. These are dryness, shrivelling, and cicatricial contractions of the conjunctiva. This in turn may lead to displacement of the cilia, trichiasis, districhiasis, entropion, or xerosis. Fig. 22, from Nettleship, shows a granular lid and the beginning of structural change.

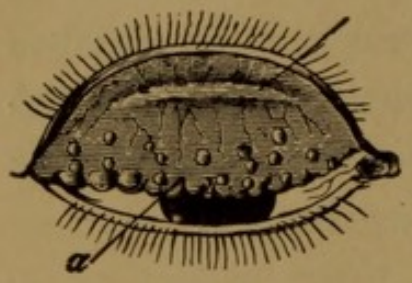

Fig. 22.

TREATMENT OF GRANULAR OPHTHALMIA.

The treatment of this class of cases is sometimes difficult and discouraging, owing to frequent relapses. If, as is frequently the case, the patient has suffered for many months or years, has been previously treated unsuccessfully, is gloomy and despondent in anticipation of coming blindness, he should be assured that his case is not hopeless; and that, with the proper amount of perseverance on his part, a permanent relief, with a more or less complete restoration of vision, is almost certain. A pannus — something growing gradually over the sight of the eye, and threatening eventually to shut out all vision — is usually a disease of fearful omen to the patient. He comes to the surgeon, also, with fear and trembling, from the idea that the growth upon the cornea must be cut off. No doubt this view is sometimes imparted by the physician who confounds the

growth with that of pterygium. The patient then, in the first place, should be rendered as cheerful and hopeful as possible. Hygienic regulations, such as previously mentioned, should be strictly enforced, and the general health, which in these cases is apt to be deficient, must be restored.

As a local means of curing the granulated lid, I employ a smooth crystal of alum, a crystal of sulphate of copper, and occasionally a crayon composed of one part nitrate of silver to two parts nitrate of potash. Pure nitrate of silver in substance I never use. A smooth crystal of sulphate of copper is, perhaps, most serviceable when the eye is in condition to be benefited by irritating applications. The upper lid being reversed, it is drawn lightly and quickly across that portion of the lid seen to be thickened and granulated, and those portions of the conjunctiva not involved are carefully avoided. Considerable pain will ensue; and if the patient is very sensitive, it is advisable to apply tepid water or weak salt and water to the conjunctiva the instant after the touch with the caustic. Otherwise, the patient may, after the lapse of a few minutes, if the pain does not cease of itself, bathe the eyes in cold water. Immediately after this application the eye will present a reddened and injected appearance, and should on no account be used until this injection disappears, which will be perhaps in an hour or more. There will also be a feeling of irritation in and about the eye, and until this artificial irritation has fully disappeared, no second application of the crayon should be made. Whether, therefore, the process is to be repeated once in forty-

eight, or seventy-two, hours, or not oftener than once a week, must depend entirely upon the reaction caused by it. Meantime cold or hot water may be used freely; vaseline, if the lids adhere together in the morning, and the administration of constitutional remedies, when necessary, continued. In sub-acute cases, where there is considerable secretion, the application of a solution of nitrate of silver in water, of the strength of five or ten grains to the ounce, will be useful. It should be painted upon the reversed upper lid, and after fifteen or twenty seconds, neutralized by weak salt and water, from a second brush. In many cases, and especially in such as have been treated injudiciously or too heroically, mild applications will prove more beneficial. Such, for instance, are the aqua chlori, diluted with water one-half or more, a solution of one to three grains of either nitrate of silver, sulphate of copper, aluminate of copper, alum, sulphate of zinc, to an ounce of water. In some cases I have used an unguent of one grain of sulphate of copper, or aluminate of copper, to the drachm of vaseline or lanoline. A mild unguent of the same may be made by adding three grains of tannin to the drachm. It is prudent to begin with mild applications if there is much ciliary irritation, and in many cases it will be necessary to feel our way along by frequent change of remedy. Sometimes the eye will bear no irritant whatever.

Pressure is frequently a potent auxiliary in these cases. It can be accomplished by placing a dry compress of absorbent cotton over the gently closed lids, so arranged that it shall be thickest at the angles

and diminished gradually towards the meridian, in order that the pressure exerted may be as uniform as possible over the granulated surface. An elastic band — flannel makes a good one — is then passed around the head, to hold the compress firmly in its place, and may be drawn as tightly over the eye as can be conveniently borne. This bandage is to be worn night and day, and the compress is to be readjusted upon the eye as often as it becomes displaced. I will relate a case or two in illustration of this mode of treatment.

Miss B., aged twenty-four, visited me first in April, 1865. She complained of irritation and weakness in the left eye, and had recently become much alarmed at the discovery that she could scarcely see to read with it. I found a fully developed pannus extending nearly to the centre of the pupil, well supplied with vessels extending downward across the limbus cornea on to its substance. The prognosis, as far as improvement of vision in this eye was concerned, was favorable; *complete* restoration, a sharp, distinct vision like that of the normal eye is very often impossible. The faintest remnant of haziness of the cornea will occasion indistinctness sufficient to annoy the patient. When no cloudiness remains, and the cornea regains its transparency, if there is the least irregularity of surface, minute depressions or flattened facets, the rays of light will be abnormally bent in passing through the cornea, and the image upon the retina will be deformed and more or less indistinct. If, therefore, a doubt exists as to a complete restoration of the cornea it is unwise to promise a perfect recovery of vision. The case of this patient was a very old one. In her early youth she remembered an affection of her right eye, and the sight had never been as clear as that of the left up to the present attack. On examining the cornea of the right eye by lateral illumination, little irregular

flattened facets were distinctly seen, which accounted for the lack of sharpness of vision. The lid of the left eye was reversed, and the cause of the growth upon the cornea was found in the granulated state of the conjunctiva. The diseased surface was lightly touched with a crystal of sulphate of copper, very cautiously at first, until the eye became somewhat accustomed to the process. Severe pain followed the operation for the first two or three times, but this was effectually controlled by bathing the eye in cold water and exposure to the open air. This eye had suffered from an acute attack of inflammation, as she informed me, more than a year before, but had apparently fully recovered after a few weeks. For a while it continued strong, but gradually grew more and more irritable, until within a few months she had scarcely been able to use it at all. She was under my care nearly five months, and completely recovered. This process of cauterization was repeated on an average about once in three or four days. Mercury was the remedy principally administered, although she had other remedies for disturbances in her general health during this period. Towards the end of the treatment my attention was called to the benefit of bandaging the eye in similar cases, and she employed this means also with the effect, I think, of hastening the cure. On visiting me nearly two years later, while with the right eye she was unable to read No. 1 type, with the left eye, the one which had been under treatment so long for the pannus, she could read it with ease.

Miss W. came to me first in May, 1867. She also, like the other, was suffering from pannus upon the left eye, and from the same cause. Like the other, also, she had suffered years previously from a probably similar affection in the other eye, The right eye she affirmed had been cured by a doctor in Boston, who had cut the cornea across its upper portion superficially, and had also made longitudinal incisions upon the inner surface of the upper lid. These incisions, she said, were painful, but always afforded her relief, and eventually cured her eye. She wished me to treat her left eye now in a similar manner. I

declined her method, and touched the granulated lid lightly with a bit of sulphate of copper, but it would not do. After a week I gave up the attempt to touch the granulations at all. The eye was rather the worse for the treatment. The ciliary system of nerves was involved to such a degree that the irritation caused profuse lachrymation and severe pain and photophobia. I therefore gave up temporarily the use of irritants of all kinds. Water was used several times a day, and a compress and bandage, as previously described, was applied, to be worn always at night, and, when convenient, during the day. After two or three weeks there was much less congestion, and the pannus had so far disappeared that the patient could read large print with tolerable fluency. I now began brushing the granulations beneath the lid with a weak solution of sulphate of zinc, which I found could be borne every two or three days. The bandage was continued with great benefit, and during the first part of the treatment, while the eye was irritable, spigelia, and later, mercury were administered internally. After two months' treatment no trace of the pannus was left, and vision was the same in either eye.

Aqua chlori is recommended for obstinate pannus from granulated lids, and two to four parts of olive oil to one of oil of turpentine also. Inoculation of the eye with pus to create an acute purulent inflammation has been more or less successful in desperate cases in clearing up the cornea and restoring vision, and the same may be said of jequirity, but both these measures are heroic and not without danger. *Peritomy*, an operation in which the conjunctiva with its sub-tissues is excised with forceps and scissors, around the edge of the cornea, I have seen Mr. Bowman, of London, perform with good results. Favorable results, it is said, have also followed the operations of lengthening the palpebral fis-

sure, so as to remove the pressure of the upper lid upon the cornea.

The more experience one has in granular or trachomatous conditions of the conjunctiva, the more one is inclined to prefer the milder to the so-called heroic treatment. Caustics and strong astringents are sometimes necessary, but their use should not be prolonged, and they may often be dispensed with to the advantage even of eyes that appear to tolerate them fairly. Thus, I find myself of late years substituting a crayon of alum in cases where formerly I should have used a crayon of sulphate of copper, and I often use a three grain solution of nitrate of silver.

Naturally, much depends upon the fact as to whether ciliary irritation exists to any great extent. If it does, caustic or astringent applications are not borne well, and may do harm rather than good. Pain, photophobia, and lachrymation indicate ciliary irritation, and when considerable, contra-indicate astringents, apart from other considerations. In some of these cases one should carefully regard the condition of the iris. Atropine will sometimes be useful.

Recently, as an intercurrent application, I have found boracic acid, four to six grains to the ounce of water, serviceable. In acute or sub-acute cases the boracic acid, being a disinfectant as well as a very mild astringent, may be used freely several times a day. When used in a four grain solution in cases of even marked ciliary irritation, it is usually borne well and is often decidedly beneficial.

SCROFULOUS CONJUNCTIVITIS OR SCROFULOUS OPHTHALMIA

I place in this chapter, inasmuch as its primary seat is usually the conjunctiva; the cornea, iris, and sclerotica becoming later involved.

DIAGNOSIS.

It is hardly necessary to dwell on the diagnosis. The mere circumstance that ciliary irritation and photophobia so affect the orbicularis that its spasmodic closure nearly renders it impossible to see the eye at all, is of itself an almost unerring indication of the nature of the disease. It is necessary, however, to see the eyeball, in order to determine its precise condition, and form a correct prognosis. A few whiffs of chloroform or ether will sometimes quickly relax the orbicularis; but I prefer a resort to the lid-elevators, to be used as mentioned in ophthalmia neonatorum. Separating the lids we shall find the palpebral conjunctiva red, swollen, and velvety looking, the ocular conjunctiva injected, the pinkish zone around the periphery of the cornea well marked, the cornea probably dull, opaque, or ulcerated, and the iris perhaps contracted. There is sometimes a good deal of ciliary neuralgia present, and the dread of light may be so intense that the child cannot be induced to turn its face towards the most moderate light, even with its eyes tightly closed.

Fortunately the disease is not always so severe as this, and the photophobia much less intense. In these cases, by means of coaxing, and some little artifice to excite their curiosity, we may, through the exercise of

considerable patience, arrive, with most children, at a hasty view of the cornea sufficient for our purpose. Cocaine, if the case is docile enough to permit its use, will make the examination easier. Often the cornea will be found nearly transparent, and the disease confined to the conjunctiva and edges of the lids. Generally, however, even if the cornea appears unaffected, the ocular as well as palpebral conjunctiva is involved, and the inflammation is so deep seated as to reach the vessels beneath the conjunctiva, as shown by the pinkish zone around the edge of the cornea. The irritation of the ciliary plexus of nerves is marked, the eye is exceedingly sensitive to all external influences, there is copious lachrymation, and any irritation is followed by violent reaction. In some chronic cases these symptoms are measurably lessened in severity, but after all a leading characteristic of these cases is the ciliary irritation, and the consequent extreme sensitiveness of the eye. I dwell on this point because of its importance in the treatment.

TREATMENT OF SCROFULOUS OPHTHALMIA.

The treatment of these cases must be largely constitutional. The disease of the eye is but one of the manifestations of a disorder that pervades the entire system, and topical means can at best be only palliative. Soothing applications, however, like tepid water, milk and water, quite warm or hot fomentations of water, or warm water medicated with belladonna or chamomile or poppy leaves, atropine, or cocaine will frequently quiet a ciliary neuralgia or great restlessness, when

simple internal remedies alone do not suffice. There are, moreover, some phases of this disease, such for instance as when its chief seat appears to be the edges of the lids, where a mild mercurial ointment, rubbed gently between the cilia, — if necessary while the child is asleep, — will produce sometimes marvellously favorable results. It should be continued a long time nevertheless, if we hope for permanent benefit, and mercury may be given internally at the same time.

This is not the place, nor is it necessary, for me to remark at length on the nature or pathology of what is called scrofula and its appropriate treatment in general. In the management of these diseases of the eye, hygienic and dietetic regulations are of the first importance. Fresh air, light, warm clothing, and good diet are indispensable always. In regard to light, I do not believe in keeping the patient in a dark room. If there is no ulceration of the cornea, no special attention in a hygienic way need be given in this affection to the patient's dread of light. The celebrated Professor Beer, who formerly had charge of the department of the general hospital for diseases of the eye during many years, in Vienna, used to take children affected with severe photophobia and place them in a position so that the sunlight might fall directly into the eye, and then force the lids apart. This appears like a very dangerous proceeding, but I have the authority of the grandson of the operator, the late Prof. Ed. von Jaeger, to the effect that no unpleasant effects followed the treatment. A rather heroic method, or one which mothers at least would consider so, was practised by Professor Graefe,

in Berlin. When the eyes were better and yet the photophobia did not yield, he dipped the child's head under water, perhaps several times, thoroughly frightening it, and usually with the result of overcoming the spasm of the orbicularis. I have seen tartar emetic given to children, in London, for the purpose of making them sick and relaxing the orbicularis. A 2% solution of cocaine will often prove useful in such cases.

When there is an ulcer on the cornea or a vesicle near its edge in the stage of excoriation, the photophobia may arise from the exposure of denuded nerve fibres; and then the progress in reproducing an epithelial covering for the exposed nerves will be very much hastened by bandaging the eye. The bandage will also serve the purpose of preventing friction of the lids in winking, lessen irritation and pain, and tend to prevent rupture of the cornea if it happen to be the seat of a deep ulcer. Children also have a disposition to constantly rub their eyes, — a trifling circumstance enough, but one which frequently has seemed to me a chief cause of the continuance of the inflammatory state, — and this the bandage of course completely remedies. This bandage should be changed several times a day, and the discharge washed from the eye, if discharge be present. Sometimes great pain and restlessness will be promptly relieved by dropping a 2% solution of cocaine into the eye; and its quieting influence seems to expedite the cure. A weak solution of atropine will often prove useful also, when the cornea or iris is involved. The atropine should never be dissolved in alcohol or alcohol and water, because alcohol applied to the eye is an irritant,

and usually contra-indicated in cases where atropine is likely to prove useful as a sedative.

It is almost, or quite, impossible to give even an outline of the treatment that may be required in scrofulous ophthalmia, because, aside from the different tissues of the eye which may be affected, the patient, so far as my experience goes, almost invariably suffers from general disturbance of the health.

PHLYCTENULAR CONJUNCTIVITIS,

or *herpetic or pustular* conjunctivitis, as it is frequently termed, may be considered as a phase of scrofulous ophthalmia. It occurs usually in children, and mostly in those of a so-called scrofulous diathesis, and very rarely in children otherwise in good health. It is characterized in its simple form by the appearance of a reddened point upon an inflamed base of the conjunctiva, slightly raised, and situated usually either at the limbus of the cornea, or upon the sclerotica near its junction with the cornea. This red point usually terminates in a vesicle, which, changing into a slight excoriation or ulcer, gradually disappears, and leaves no trace behind. There is generally some irritation of the ciliary nerves, and, as a consequence of this, some photophobia and lachrymation. These symptoms being greatly increased when the vesicle or vesicles happen to come on the cornea or at its limbus. If the vesicles are not developed in too great numbers, and are not too near the cornea, the disease is very slight, and requires very little treatment. I was once consulted by an adult, in a case of herpetic conjunctiva, whose physician had in-

formed him that he had probably a pterygium growing over the sight of the eye, and it would have to be removed by an operation. He was a sculptor, and I advised him to remain at home for a few days, so as to avoid the dust of his studio, and he was soon cured without further treatment. Many cases, however, are much severer than this and not as easily disposed of; and in all, the tendency to recur again and again is strongly marked.

Treatment.

The best remedy for this disease is the external application of powdered calomel. The inspissations of the powder should be made by taking up a minute quantity of the fine powder on a camel's-hair pencil, then holding the pencil vertically before the affected eye, between the forefinger and thumb of the right hand, having exposed the surface of the under lid with the left hand, tap the handle of the brush rather smartly with the ring finger of the right hand, at the same instant tossing the brush slightly towards the lids, and some of the fine dust will be projected directly into the eye. This manœuvre is simple, but it requires a little practice to do it neatly. The calomel should be very fine, but little should be taken up on the brush, and no lumps of it thrown into the eye. Neither should it be blown into the eye through a tube; it is too coarse treatment for a delicate eye, though convenient for the nose or ears. The calomel seems to exercise a specific influence in these cases, due to its germicidal properties. I formerly thought the calomel simply an irritant used in this way,

but am now convinced to the contrary. It *does* irritate, and should therefore be used cautiously if the eye is very sensitive and dreads the light. For the photophobia, tartar emetic will often be serviceable. Ciliary neuralgia may often be quieted by chamomilla, using at the same time warm fomentations of chamomile water over the closed lids. Very severe pain may be quickly relieved by the instillation of a two per cent solution of cocaine. The general treatment will be that indicated for scrofulous ophthalmia. Norton advises sulphur internally as specially serviceable, and directed to the constitutional symptoms so often manifested by an eruption similar to that of the conjunctiva, at the alæ of the nose, angles of the mouth, behind or in the ears, and about other parts of the body.

Sometimes a herpetic point appears in the subconjunctival tissue, just at the edge of the cornea. When this is the case, and the sclera or the episcleral tissue is involved, the progress of the disease is tedious in the extreme. I have had an example of this variety where one vesicle remained imbedded beneath the conjunctiva for more than three months. It is difficult sometimes in such instances to determine whether such a case should be regarded as a conjunctivitis or an episcleritis. See Phlyctenular Keratitis.

Exanthematous conjunctivitis, occurring during eruptive fevers, does not usually demand special treatment. It is always present to a certain extent in measles, scarlatina, and variola. Any discharge should be removed, and the eyes should be protected against bright light. Bathing in tepid water, or milk and water, is

often grateful, and if the edges of the lids adhere, or are tender or excoriated, the application of vaseline, olive oil, or glycerine will be useful. If the discharge continues, a collyrium of one or two grains of nitrate of silver to the ounce of water may be used twice a day.

Pterygium is a hypertrophied condition of the conjunctiva, usually of a triangular form, the apex towards the cornea, the base at the semilunar fold. The growth is tendinous, and supplied with vessels. When red and irritable, rest of the eye, soothing applications like warm water, and bandaging for a few days will greatly relieve the condition. If it is not particularly annoying, and does not increase rapidly so as to threaten impairment of vision, by encroaching on the pupillary area, it is better not to disturb it, unless for cosmetic reasons the patient desires its removal. The operation is done by seizing the growth with delicate forceps and dissecting it from the cornea with a knife; then incise with scissors the conjunctiva from the upper corneal margin of the growth back to the centre of the base of the pterygium, and make a similar incision from the lower corneal margin of the growth and remove the lozenge-shaped portion of conjunctiva between the incisions. The conjunctiva above and below is then to be loosened from the sclera and drawn over the raw surface and stitched. A variation in the operation is to dissect up the growth, then double it inward upon itself and confine it by a deep suture. The operation for its removal is not always permanently successful. A less severe form of the disease consisting merely of a slight hyper-

trophy of the conjunctiva is readily and successfully removed with the forceps and scissors.

The cause of the disease is usually some injury of the eye or exposure which irritates the conjunctiva, and it sometimes results from a phlyctenular or other ophthalmia. A warm climate predisposes to the affection.

HEMORRHAGE BENEATH THE CONJUNCTIVA

may be known by its bright red color, by its occurring in circumscribed, well-defined spots, often extending up to the edge of the cornea. It may be due to a blow or fall, but often no assignable cause can be found. When it appears in feeble elderly subjects it may indicate a weakness of the blood-vessels generally, and an attack of apoplexy of the brain. Usually it is far more alarming to the patient than hurtful; but in severe cases with recurrence of the bleeding, rest and bandaging the eye may be advisable.

PINGUECULA.

The little elevation of a yellowish color observed in elderly people at the margin of the cornea, called pinguecula, is not annoying except from its conspicuousness. If desired it may be seized with delicate forceps, and snipped off with the scissors.

Warts of the conjunctiva may be treated in the same way.

Cysts of the conjunctiva are to be treated similarly.

Dermoid tumors, generally seated at the corneal margin, are best dissected out with the knife, care being taken not to go too deeply into the corneal and sclerotic tissues.

CHAPTER VII.

THE CORNEA AND SCLERA.

FROM a clinical point of view keratitis may be divided into two distinct forms, — namely, the suppurative and the non-suppurative. The first involves loss of true corneal substance and more or less impairment of sight. The second may result, and often does result in perfect restoration of the normal transparency of the cornea.

PHLYCTENULAR KERATITIS.

The cornea is frequently the seat of excoriation or ulceration in the vesicular or phlyctenular variety of scrofulous ophthalmia. The objective symptoms are those of phlyctenular conjunctivitis more strongly marked, with much greater ciliary irritation, congestion, and photophobia.

The vesicles, often situated at the corneal edge, are small grayish points which usually rupture and leave minute superficial ulcers. The affection belongs essentially to the period of childhood. A similar disease appears as a

Fascicular keratitis in which vessels run near each other in parallel lines over the corneal limbus on to the

cornea to supply material for the repair of the ravages of the small corneal ulcer. See Fig. 23, after Nettleship.

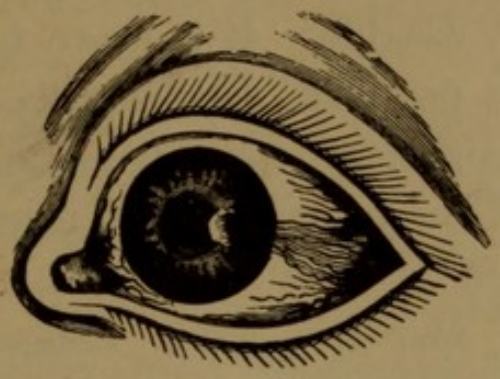

FIG. 23.

Superficial vascular keratitis is still another form of scrofulous affection of the cornea, characterized by the formation of a network of vessels over a circumscribed portion of the cornea which, in the affected region, is more or less infiltrated and roughened. This condition may be the result of repeated attacks of the phlyctenular variety of keratitis.

Treatment.

The treatment of phlyctenular keratitis should, in general, be that laid down for scrofulous ophthalmia on page 126. Arsenic and mercury as internal remedies are prescribed by me perhaps oftener than others; but iron and good feeding are often necessary, and the best possible hygienic conditions should be secured.

As for the external treatment, the ciliary irritation is so great that considerable caution is necessary. Powdered calomel is not well borne. A half or quarter per cent solution of atropine once a day is soothing, and a two per cent solution of cocaine for pain and photophobia

three or four times a day may be used. A solution of bi-chloride of mercury 1 : 10000 should be dropped in the eye as an anti-septic; if it irritates it may be used directly after the cocaine. If it prove too irritating boracic acid, one per cent, may be substituted. As the acute symptoms subside, one may use an unguent of four to six grains of the yellow oxide of mercury to an ounce of vaseline once or twice daily; but this often proves too irritating, and hot water fomentations may be equally serviceable. The water should be as hot as can be borne, and the small compresses which are to be placed over the closed lids should be changed every few seconds. These fomentations should be kept up for five to ten minutes three or four times a day, and as the acute symptoms subside, from ten to twenty minutes at one time.

In the beginning the eye should be bandaged for reasons given at page 128; but later, as the eye improves, the bandage may be discarded as tending to keep up the photophobia.

Vesicular, or herpetic, keratitis is rather rare. Sometimes a cluster of minute vesicles filled with transparent liquid are present on the cornea, and after catarrhal affections similar herpetic eruptions appear about the mouth and nose. The treatment is that for phlyctenular keratitis.

Bulbous keratitis is caused usually by injury of the cornea. The epithelium is raised and forms a rather large fluctuating vesicle filled with a transparent, and more rarely with a purulent, fluid. The detached epithelium should be removed under cocaine. The disease

is liable to recur. A somewhat similar condition is found after old affections involving tension of the eyeball, but the disease is then due to œdema of the cornea and is not amenable to treatment.

Dendriform keratitis is a very superficial ulceration of the cornea extending across it in the form of a branch or twig. It is best seen by lateral illumination. In a recent case, that of a young man of twenty-three, otherwise perfectly healthy, there was a good deal of photophobia but not much pain. Under cocaine I scraped the ulceration gently at first, then applied a solution of bi-chloride 1:5000 and bandaged the eye. The pupil was kept large by atropine, and he used a solution of bi-chloride 1:10000 three times a day. After three weeks the bandage was left off. He came to me on April 21, and was last seen on May 24, when there was no photophobia remaining, although traces of the ulceration were still faintly visible. Sight $\frac{20}{20}$.

Vascular interstitial keratitis may be considered as a severe, deeper-seated form of fascicular keratitis. The treatment should be similar, and in uncomplicated cases the prognosis is favorable.

Non-vascular interstitial keratitis in which one or more circumscribed infiltrations appear in the cornea gradually growing more opaque, may supervene from a vascular keratitis, or from some form of conjunctivitis, or may be due to some unknown cause. The prognosis is good; but the progress towards health may be very slow. Hot water compresses applied as directed at page 136, to be regulated as to frequency and time according to the reaction produced. It may be necessary to use the

hot water for a half hour three times a day. Atropine may be used to keep the pupil dilated and avoid iritic complication, and the general health should be guarded by proper hygienic and remedial measures.

Diffuse interstitial keratitis is of inherited syphilitic origin usually. It is sometimes possibly due to scrofulous diathesis, and a few observers believe that it may follow acquired syphilis as a secondary manifestation. It is often seen in children with the characteristic notched teeth of inherited syphilis. See Fig. 26, p. 157.

A slight grayish opacity of the cornea is first noticed, and this gradually increases in density until vision is reduced to mere counting of fingers near the eye. In uncomplicated cases the prognosis is favorable. The cornea usually becoming clear again after some time. I have always used atropine in these cases, and given mercury and iodide of potash internally, but have never been certain that the treatment influenced the course of the disease, which is invariably slow. The past year I used hot fomentations in the case of a boy of fourteen, and the result leads me to think it possible that the application of heat may hasten the absorption of the infiltration. L. R. came to me May 4. V. R. saw fingers near the eye. June 1. V. $= \frac{4}{200}$. July 5. $\frac{10}{20}$. Meantime the left eye became similarly affected in June, and grew gradually worse until July 5, when it began to improve. The boy was entirely recovered when I returned from my summer vacation in September. Here the disease was, in the right eye at least, of less than three months' duration.

Keratitis punctata superficialis, as described by Fuchs,

is a form of keratitis following an acute catarrhal conjunctivitis, and characterized by unusual ciliary irritation, pain, and photophobia. It is apt to recur, and then little dots are observed about the centre of the cornea, the marginal portion remaining clear. The dots are in the superficial layers of the true cornea beneath Bowman's membrane. The prognosis is good, but the course of the disease is very slow. It is most common to those between ten and twenty years of age. The treatment would be similar to that of a severe phlyctenular keratitis.

Deeper-seated affections of the cornea are *keratitis punctata*, secondary to disease of deep-seated affections of eye, see page 158.

Suppurative keratitis, which is sometimes met with as a result of severe purulent ophthalmia or from chemical or mechanical injury to the eye, or from surgical operations in the corneal tissue, is a grave form of the disease leading to ulceration. It is frequently accompanied by severe ciliary neuralgia. The rose-colored zone around the cornea, contraction of the pupil, and sometimes chemosis are present. We notice a gray opacity, which changes afterwards to yellow as the tissues become broken down, and the end may be a perforation of the anterior chamber. Or there may be extensive corneal abscess, perhaps interstitial infiltration forming onyx. Or a hypopion may result from precipitation of pus to the bottom of the anterior chamber (hypopium keratitis). See Fig. 24, from Nettleship, on the next page. The matter may reach the anterior chamber from extension of the suppurative inflammation to

the iris without perforation, or more usually from bursting of the posterior layer of the cornea. The elastic layer of Descemet is not subject to the suppurative process. Suppurative corneitis is very readily produced by injuries of the cornea in the aged or weak, and is not unfrequently met with as a sequence of typhus, typhoid, cholera, or diabetes.

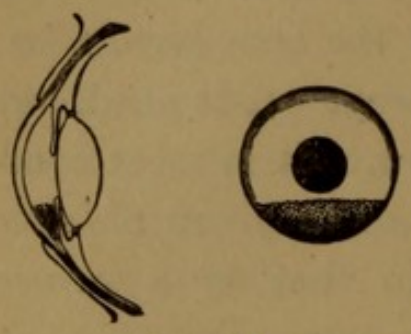

Fig. 24.

An indolent or non-inflammatory form of corneitis, where the absence of pain and irritation is a characteristic feature, is of still more dangerous nature. In neuro-paralytic corneitis the infiltration sometimes extends with great rapidity; and necrosis not only of the whole cornea ensues, but in rare instances the suppuration extends to the entire globe. All suppurative forms of keratitis, since the loss of corneal substance is involved, leave permanent opacities and more or less impairment of vision. All are probably due to infection; if not from without, then through the circulation from within, and this fact should of course influence our local treatment.

TREATMENT OF CORNEITIS GENERALLY.

The treatment of corneitis occurring during the course of the various ophthalmiæ has been sufficiently indicated. In the severe suppurative forms the eye should in the first place be bandaged, and the flannel band should be long enough to pass twice around the head, so that considerable pressure may be exerted on the ball of the eye. Pressure seems to have a controlling influ-

ence in limiting the extent of the suppuration, and every hair's-breadth of transparent cornea saved to the patient multiplies infinitely his visual power in the end. If the inflammatory symptoms are so marked as to indicate the cold compress, then the application of the compress bandage may be alternated with the use of cold water. It is hardly worth while to attempt to combine the cold and the compress at the same time. One or the other will be pretty sure to be inefficiently attended to. In the non-inflammatory form of keratitis, hot water fomentations of a temperature from ninety to one hundred Fahrenheit are indicated, the object being to create inflammatory reaction. The same treatment for the same object is serviceable in all forms of corneal affections if the inflammatory appearance is lost and resolution still doubtful. These fomentations are very potent agents for good, or, when indiscreetly used, for evil, and their application should not therefore be intrusted to other than trustworthy attendants. When a marked injection of the eye has been induced, they should be temporarily discontinued. Paracentesis is sometimes resorted to as a relief from intra-ocular pressure, to preserve the integrity of the cornea, and sometimes for the evacuation of hypopion or interstitial matter. Cocaine will often relieve pain.

Myotics must be used with caution as tending to ciliary irritation. Atropine is usually advisable.

SUPPURATING INTERSTITIAL KERATITIS.

This outline of a case of apparently total destruction of the cornea from suppuration, as I at first considered

it, may be instructive as showing the value of paracentesis combined with the application of heat in certain cases.

On June 7, 1879, Capt. B., aged sixty, master of a whaling vessel, was brought directly from his ship to my office. He had sailed some six weeks previously, with good sight, but off the coast of South Carolina had been attacked with inflammation of the eyes, had gradually become blind, and was obliged to bring his vessel back to port. He was led to my house as a blind man, but I found vision, left eye ten two-hundredths, right eye entirely blind; he thought he could distinguish the direction of a window in the sunlight, but failed to detect the presence of a sheet of white paper moving before the affected eye.

There was diffuse cloudiness of the whole cornea in the left eye, but it was not sufficiently dense to completely hide the iris and pupil. The conjunctiva was moderately injected around the corneal edge. The right eye presented a very different aspect. There was deep, dark injection of the entire ocular conjunctiva with chemosis; the cornea was yellow and opaque; the infiltration of pus between its layers was so marked a feature that I looked for its disintegration very shortly. The patient was assured that the left eye would probably be restored to fair sight, but was told that the right was inevitably lost. I instilled atropine into both, bandaged them, gave orders for a hot fomentation to each, of fifteen minutes three times a day. Gave him quinine, $\frac{1}{10}$ five grain doses, three times a day. The quinine was suggested by his general health, which, although not specially bad, was not up to his usual robust standard.

June 9. Left eye better, cornea clearing a little. The right eye is not changed in appearance. He cannot see a white paper moving before it. Made a small opening into the anterior chamber at the lower corneal margin with a Beer cataract-knife, which I consider the best instrument for this purpose if used cautiously. There was a discharge of aqueous followed by

aqueous turbid from pus, showing that hypopion probably existed also, but undetected owing to the complete corneal opacity. Treatment continued.

June 11. Left, better. Right can see a white paper before the eye owing to a little clearing up of the cornea at its inferior edge near the opening. Paracentesis again.

June 13. Left, improving. Right, about the same. Paracentesis.

June 16. Same. But the chemosis, which had been lessening, is now more marked above the cornea, and there appears to be a more dense infiltration of pus in that part of the cornea near it. Paracentesis. Use the hot fomentations for fifteen minutes only once a day.

June 18. Right eye less chemosis. Paracentesis.

June 20. Right, again clearing up a little. Paracentesis.

June 28. Right, better. Saw, near the eye, the large letter C number 200.

June 30. Right saw letters number 100 near the eye.

July 2. Improvement has ceased. Fomentations twice a day. Paracentesis.

July 5. Right eye better again. Sees letters number 70.

July 10. Right sees letters numbered 30 near the eye.

July 14, 16. Record is the same. The patient left Boston for his home a hundred miles away. His left eye had so far recovered that with D + 1.25 he could read print number 8 comfortably.

The distinction between a suppurative process in the cornea and some forms of ulceration is by no means clear, and the above case resembled somewhat the creeping ulceration of the cornea called the serpiginous ulcer. In a case of this kind now I should make free use of a wash of bi-chloride of mercury and probably use other anti-septic measures.

Aconite, internally, is the remedy to be employed

when the reaction is sufficient to warrant the application of cold to the eye, afterwards the remedies must be chosen with reference to general condition of the patient, never neglecting the digestive functions and a nutritious diet. Pain is best controlled by cocaine instillations and hot fomentations. In cases due to hereditary syphilis (diffuse corneitis) Norton advises aurum internally.

ULCERATION OF THE CORNEA.

Corneal ulceration is nearly always an indication of impaired health and weak vitality. There is always more or less congestion of the conjunctiva, and generally pain, lachrymation, and photophobia.

Strumous ulceration, not as the sequence of a vesicle, deeper, and nearer the centre of the cornea, occurs in scrofulous ophthalmia, beginning as an opaque speck. The

Ulceration in ophthalmia neonatorum is similar to this in appearance. A grayish opacity, its centre nearly transparent, the gray then giving place to a tinge of yellow, and this, as resolution sets in, changed again to gray. A blood-vessel, or leach of vessels, may often be seen to run from the sclerotic to the ulcer.

Transparent ulcer of the cornea is sometimes observed, in which the vision of the patient, instead of being clouded, suffers only from the irregular refraction of rays of light in passing through the uneven portion of the cornea. All objects appear distorted. The above are generally superficial ulcerations. Among the deep-seated ulcerations, the

Crescentic ulcer of the cornea, as described in the details of the case of gonorrhœal ophthalmia, is one of the more common, while the

Sloughing ulcer, from suppurative corneitis in the weak and ill-fed, and the analogous indolent ulcer seen in the aged, frequently complicated by hypopium and iritis, called the *creeping ulcer* (*ulcus cornea serpens*), probably of infectious origin, and sometimes due to injury of the cornea, are fortunately more rare in private practice. See Fig. 25, after Nettleship. Both these forms are very dangerous. The same may be said of a still more rare and fatal form, the *neuro-paralytic*, due to paralysis of the fifth nerve.

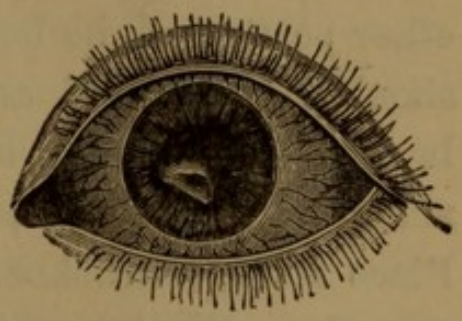

FIG. 25.

THE DANGER.

The chief danger of ulceration lies in the tendency to leave a more or less opaque scar or cicatrix in the corneal tissue, which, if it happen to be situated in or near the centre of the pupillary area, renders vision imperfect. Another danger lies in the direction of a perforation of the cornea, which may occasion a prolapse of the iris, resulting in adhesion between the iris and cornea, displacing the pupil, or distorting it, and perhaps engendering an iritis, or, if the perforation happen to be small and central, causing a deposition of matter on the surface of the lens capsule, or capsular cataract.

TREATMENT OF CORNEAL ULCERATION.

One of the most potent local measures for promoting a speedy healing of a corneal ulcer is a protective bandage. It is just as essential that the exposed surface of the cornea should be protected from the air, as that any other portion of the body, under similar circumstances, should be covered artificially. The quicker a fresh layer of epithelium is formed to cover the denuded nerve fibres, the sooner will the photophobia vanish. Place a single thickness of fine muslin over the closed eye, then fill the orbit, especially at the inner angle, with fine charpie, or absorbent cotton, so that the band of elastic flannel may press uniformly, but gently, upon the whole eyeball, just sufficiently to prevent winking.

It has been found serviceable sometimes when an ulcer threatens perforation to anticipate the rupture by puncturing it with a fine needle. The advantage of this is that the opening made is very small and regular, the aqueous humor flows off gently, and the iris, falling against the opening, adheres over a very minute surface, and when the aqueous humor once more accumulates, it will be quite likely to be torn away uninjured, and there will remain as a sequence of the disease but a small corneal opacity. Sometimes a perforation has been prevented by a paracentesis of the cornea at its edge, which relieves temporarily the intra-ocular pressure. In perforation it is of course advisable to prevent the iris being involved, if possible, and to this end the pupil should be kept widely dilated by atropine when the ulcer is situated centrally. If the ulcer is towards

the margin of the cornea, eserine or pilocarpine may be substituted, in order to contract the pupil as much as possible, and draw its edge away from the seat of the threatened breach; but eserine and pilocarpine are to be used tentatively as they are often ill borne.

Pain and photophobia are to be relieved by removing the bandage and using very hot water fomentations, or by the instillation of a two or four per cent solution of cocaine. The diet, in cases of this kind, ought to be as nutritious as the condition of the digestive organs will permit. Fresh meat should be prescribed, and the child should be kept in the open air as much as possible. No darkening of rooms should be permitted; on the contrary the sun should be allowed free access to the nursery, and welcomed as one of the best auxiliaries to the treatment. The dread of light is of course provided for by the bandage, which prevents access of all light, as well as air, wind, dust, smoke, and all deleterious external influences. In some instances of chronic, indolent ulcerations, heat, either dry or in the form of hot fomentations, is found to hasten a cure admirably. It is well to make the hot fomentations anti-septic by the addition of the bi-chloride of mercury. The examination of an ulcer on the cornea is much facilitated by *lateral illumination.* This gives us a correct idea of the depth, extent, and progress of the ulcer. When the ulceration occurs in the course of a granular or purulent ophthalmia, such applications as are necessary for the cure of the diseased conjunctiva are to be made as previously directed, care being taken that no irritating substance comes in contact with the cornea.

In certain indolent ulcerations a direct stimulating or anti-septic or germicidal treatment has been found useful in practical hands. The actual cautery or the galvano-cautery is applied to the ulcer. Or the ulcer is scraped and nitrate of silver applied. Or the ulcer is slit through its entire length with a Graefe cataract knife (Saemisch operation), or an iridectomy is done. But in spite of any and all treatment, deep-seated ulcerative processes in feeble constitutions often go on to fatal results so far as sight is concerned.

The internal or general treatment in ulcerations of the cornea must look to favorable hygienic conditions, good feeding, and the constitutional dyscrasia. Mercury and sulphide of calcium are accredited with a power of limiting suppuration, and arsenic is of acknowledged efficacy in debility and weakness. Whatever our internal remedies may be, the promotion of the appetite, digestion, and assimilation must not be lost sight of.

I have recently treated, in an adult, an ulcer of the cornea, following an acute syphilitic affection of the genitals. The cure was speedy and complete under biniodide of mercury internally, and the use of the bandage and the instillation of atropine, as auxiliaries.

STAPHYLOMA ANTERIOR.

Staphyloma of the cornea and iris sometimes occurs as a sequel of perforation or sloughing of the cornea. The iris falls against the opening, lymph is secreted and a cicatricial tissue, something of the nature of opaque cornea is formed. Being weak and inelastic under

intra-ocular pressure, it bulges forward, and forms a partial or total staphyloma of the cornea and iris. The disease is to be treated surgically. The intra-ocular pressure is most certainly relieved by iridectomy beneath that portion of the cornea which still retains transparency, so that the operation may serve at once the double purpose of improving sight and removing pain and disease. This presupposes the staphyloma to be only partial. When it is total, the bulging of the eye is so considerable as to present an unsightly appearance; it is irritable, painful, and all sight inevitably lost. In such cases the best thing to do, it has always seemed to me, is to remove the eye. Excision of the staphyloma involves too great risks; but lately De Wecker advises repeated punctures of the sclera in the vicinity of the equator.

Conical cornea, a transparent bulging at the centre, is most readily diagnosed by noting the difference in the size of the image of the window on the two corneæ, or by viewing the eyes in profile. It may also be recognized by the ophthalmoscope. By direct examination we see a central red illuminated space, around this a dark zone, and still outside of this a red ring of light. The dark zone is occasioned by the complete reflection and diffusion of the rays of light at the base of the central cone, where it joins the normal cornea through the periphery of which the outer red ring of light is reflected. One may also get an inverted image of the fundus of the eye, as in myopia, in consequence of the increased refractive power of the centre of the cornea. The bulging is not due to intra-ocular pressure, for the

eyeball is softer rather than harder than in the normal condition. It seems to be due rather to a thinning and weakening of the corneal tissue. The progress of the disease is generally slow. The increased curvature of the centre of the cornea renders the eye myopic, and there is irregular astigmatism. Concave, spherical, and cylindrical lenses may afford measurable optical correction, and sometimes hyperbolic lenses are useful. Surgical aid may be tried as a last resort and, when there is opacity at the apex of cornea, there is less to lose if an operation prove unsuccessful. Trephining, or removing a portion of the corneal apex, and an iridectomy may be of more or less benefit. Hirschberg perforates the apex with the actual cautery, following it later by an iridectomy.

Arcus senilis, a line of opacity extending partially or entirely around the periphery of the cornea, caused by fatty degeneration, requires no treatment, as it produces no visual disturbance.

Opacities of the cornea, resulting from previous disease of its tissue when slight and recent or when dense, the edges not sharply defined, and, in children, usually disappear in course of time without treatment. After all irritation of the eye has subsided it is possible that the use of stimulating collyria may hasten this result. A solution of two grains of sulphate of copper or zinc, or five grains of alum each to the ounce of water may be used once or twice daily. But I prefer usually the stimulating effect of hot fomentations of water, used for fifteen minutes or longer, night and morning. Whatever agent we may use to promote local reaction should

be changed from time to time as the eye becomes tolerant of it. Internal treatment should look to the improvement of the general health, I think. Calcaria, cannabis, sulphur, and a multitude of other internal remedies are accredited with having hastened the removal of these corncal opacities.

When an opacity is old, and has assumed a white, pearly, glistening appearance, its margin well-defined, and especially if in an adult, we shall fail in any attempt to remove it either by internal or external means. We have then the resource of an artificial pupil, to be made exactly behind such part of the cornea as retains most of its normal transparency.

We may also resort to the operation of tattooing the cornea. The coloring matter, usually India ink, is pricked into the cornea with a needle or delicate knife, and not only hides the unsightly opacity, but may improve vision in some cases by lessening the diffusion of light, just as the small aperture in stenopaic glasses, and the pin-hole in a card, render vision more acute.

Nussbaum, of Munich, some years since, tried the plan of removing the central portion of an opaque cornea, and inserting a circular window of glass. It was not successful; suppuration and expulsion of the glass followed. The operation of transplantation of cornea has also failed. It is always melancholy to be consulted by a patient, the interior of whose eyes is perfect, and who could see, if only the foggy cornea could be replaced by some transparent medium, and be obliged to tell him that there is no hope left for sight. It is not unreasonable to believe, I think, that the future of

surgery will provide some remedy, more or less complete, for these unfortunates.

EPISCLERITIS.

Episcleritis begins in the form of a dusky-red circumscribed spot, beneath the conjunctiva in the episcleral tissue or superficial tissue of the sclerotic, generally near the edge of the cornea. As it progresses, the color usually changes to a purplish hue, and there is more or less bulging. It causes a good deal of ciliary irritation and neuralgia, if it involves the edge of the cornea. Otherwise, there is slight or no pain and little injection of the conjunctiva. It is most common in adults, and is then no doubt a rheumatic or gouty affection. It is of not unfrequent occurrence in the course of a scrofulous ophthalmia, and accompanied by a conjunctivitis and some slight mucous discharge. It must not in these cases be confounded with a vesicular or phlyctenular ophthalmia. No ulceration or excoriation ensues, but the spot or nodule gradually pales away.

The immediate cause of the affection in adults is generally debility from overwork, or some depressing influence. It is not difficult to relieve or cure, when the patient can be thoroughly under control. Warm fomentations are always soothing, and atropine or cocaine, when necessary, will quiet the ciliary neuralgia which is apt to come on at night. All use of the eyes is to be prohibited, and a shade worn when in the open air. Constitutional disturbances will generally indicate the choice of internal remedies, otherwise I rely almost wholly upon the protiodide of mercury, which has

seemed to be very serviceable. An examination of the urine will often suggest the internal treatment. Gentle massage, for a minute or two, through the closed lids once or twice a day when the eye is not too sensitive is useful.

An unnatural bulging of the sclerotic often occurs as the result of old choroiditis or irido-choroiditis. It is not unusual in cases of glaucoma. It is situated commonly at the anterior part of the sclerotic behind the ciliary region, and is called frequently *anterior staphyloma* in distinction to a posterior staphyloma of the sclerotic seen in progressive myopia. The disease is not idiopathic, but supervenes upon inflammation of some portions of the uveal tract, and presents no characteristic features except in the bulged and bluish appearance of the thinned sclerotic. The treatment will be directed to the iris, choroid, or ciliary body. If there is increased tension of the eyeball, operative interference may be indicated. Sclerotico-choroiditis posterior is noticed under Myopia.

SCLEROTICO-KERATITIS AND IRITIS.

The bulging of the sclera anteriorly may also occur, exceptionally, as a result of an inflammation in the ciliary region which appears to include both cornea and iris, as well as the sclera. The dusky purplish color, already spoken of as characteristic of scleritis, may circumscribe the entire cornea, or not. There is generally considerable pain and photophobia, and the affection is persistent and often relapsing. The edge of the cornea near that part of the ciliary region most affected be-

comes cloudy or opaque. The treatment in these cases must be similar to that already given for ordinary episcleritis, except that the use of atropine in the affected eye is imperative on account of the iritis. The prognosis, on the whole, may be said to be favorable.

CHAPTER VIII.

THE IRIS.

HYPERÆMIA OF THE IRIS

PRESENTS symptoms similar to those of simple iritis, except that they are less marked, and the exudation is absent. It may be caused by over-exertion of the eyes for near objects, and often indicates a congestion of the deeper-seated structures of the eye. It is frequently noticed in scrofulous ophthalmia, and is not unfrequently one of the results of an injudicious use of caustics. The treatment will depend upon its course, and the nature of the associated affection. Generally it will require a treatment similar to that for iritis.

SIMPLE IRITIS, OR RHEUMATIC IRITIS.

The objective symptoms are injection of conjunctiva, also sub-conjunctival injection, the rose-colored zone around the cornea being well marked; generally there is contraction of the pupil, and always sluggishness in dilation and contraction, discoloration, — a blue iris becoming greenish, and a brown iris reddish-brown, — and there may be observed frequently a plastic exudation at the pupillary edge or on the surface of the iris. The pupil is usually irregular in form, its lower edges adhering to the lens capsule behind it. In severe cases

there is sometimes swelling of the lids, injection of the conjunctiva, chemosis, and the posterior surface of the cornea may be mottled by minute depositions of lymph. The subjective symptoms are sometimes merely dimness of vision and slight dread of light. At other times we find them very severe; there is great pain in the eyeball, around the orbit, and in the temple, generally worse at night, severe photophobia, and lachrymation. Acute iritis is frequently accompanied by a diffuse retinitis, and sometimes by hyalitis. It is advisable, therefore, when the aqueous is sufficiently clear, to use the ophthalmoscope to determine whether such complications exist. Gonorrhœal iritis, occurring during the course of a gonorrhœa, is similar to the rheumatic, but, unlike this variety, usually attacks both eyes at or nearly at the same time.

SYPHILITIC IRITIS,

the symptoms of which correspond generally to those above given, is a deep-seated form of inflammation, the tissues of the iris becoming swollen and thickened. In syphilitic iritis the exudation is usually copious, the swollen tissues of the iris impede circulation, the vessels become congested, and tortuous veins appear on the face of the iris. Observation by lateral illumination will be of help in noting the structural changes which occur. Little yellowish nodules may often be seen about the edge of the pupil, the mischievous purpose of which seems to be to stick the edge of the pupil firmly to the capsule of the lens. The aqueous humor becomes increased in bulk, and turbid from the admixture of pus

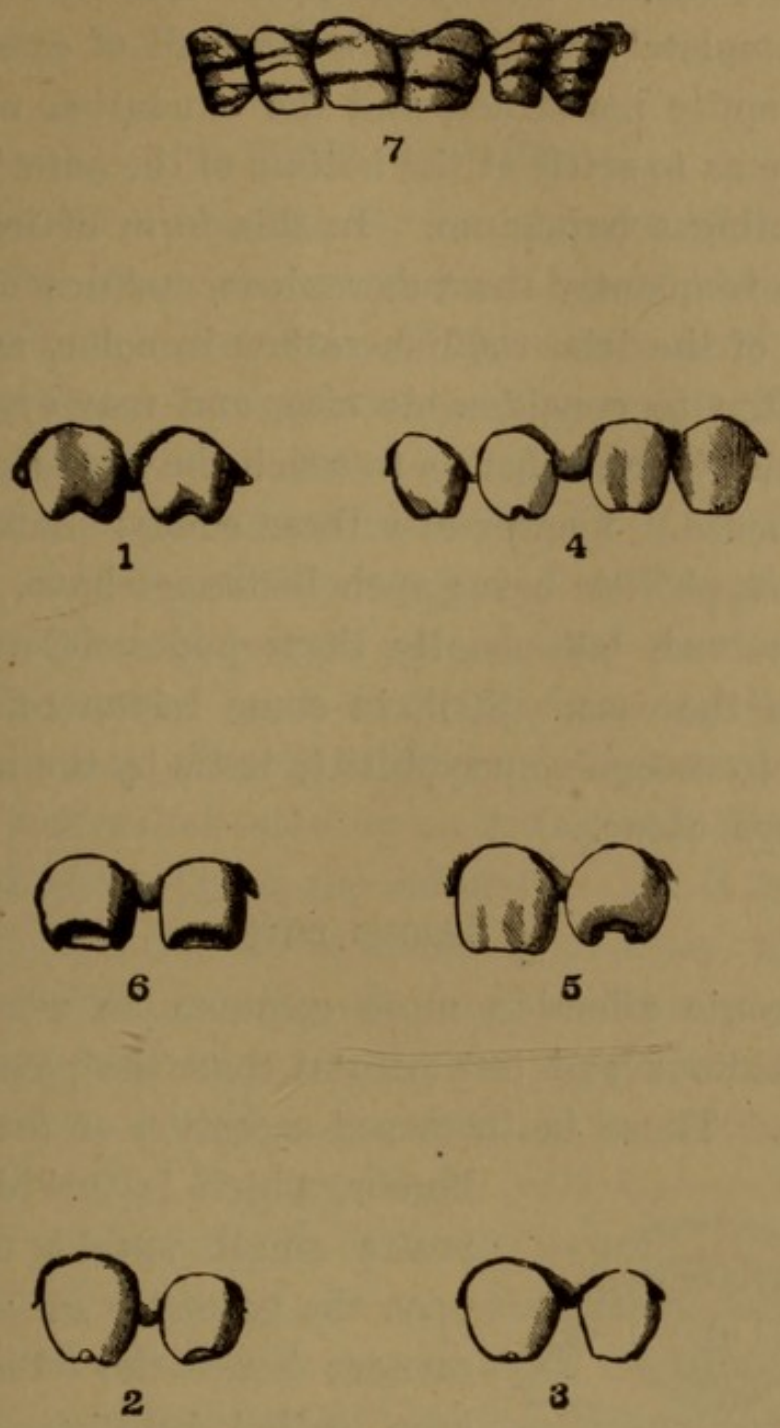

FIG. 26.

This illustration, from Nettleship, shows the appearance of the permanent teeth in instances where the enamel is wanting or is imperfect. The upper figure presents an unusually bad example. Generally the defective enamel is noticed only at the edge of the incisors, as in the remaining figures. Such teeth are often found in diffuse keratitis, serous iritis, etc.

and lymph thrown out by the iris. The latter is sometimes completely covered by a thin veil of exudation so as to be quite indistinct, and the exudation may be so extensive as to settle at the bottom of the anterior chamber, forming a hypopium. In this form of iritis there are also frequently the tuberculous nodules on certain portions of the iris, reddish-yellow in color, and which attain often to considerable size, and may even project so far into the chamber as to touch the posterior surface of the cornea. I never saw these condylomatous nodes in a non-syphilitic case; such instances have, however, been observed, but usually these nodes determine the nature of the case. Still, in some instances, it is impossible to recognize a syphilitic iritis by the inspection of the eye alone.

A SEROUS IRITIS

is a chronic affection more common in women than men, insidious and less painful than the plastic forms of iritis. There is increased secretion of the aqueous humor, which is turbid and deposits small specks of lymph upon the posterior surface of the cornea; hence the affection has been called *keratitis punctata.* It is frequently associated with choroiditis, and cyclitis, and the prognosis is not as favorable as in most other forms of iritis. There is apt to be an increase of tension, and therefore atropine may not always be used as freely as would be desirable. It is often, also, a cor-

Fig. 27.

neo-iritis, and then the prognosis is less unfavorable. See Fig. 27, from Nettleship.

DIAGNOSIS OF IRITIS.

This is made comparatively easy by a careful observance of the objective symptoms already mentioned; still, in certain cases, some of these are more or less masked by the great injection of the conjunctiva, and some may be absent. Thus, the pinkish zone around the edge of the cornea may be hidden from sight by the vermilion redness of the congested conjunctiva. In such cases a general practitioner, I have observed, may mistake the disease for a conjunctivitis, and this may lead to the prescription of an astringent eye-wash, which is always contra-indicated in an iritis, and always aggravates the severity of the affection. Or it may lead to the neglect of the use of atropine or some other mydriatic, a mistake too often deplored after an eye is lost. But in these doubtful cases, if the physician will take his patient near a window, and test the movement of the pupils as directed at page 28, he will find a sluggish movement of the iris, if iritis be present; but if the movements of the pupil in contraction and expansion are active and natural, he may be quite sure that he has not an iritis. If in doubt still, he may drop a four-grain solution of atropine into the eye and observe if the pupil dilate evenly or irregularly. If the pupil is irregular in form there are adhesions and iritis. When there are elements of uncertainty in the case, avoid all irritating applications, and then, at least, no harm will ensue. If it is an iritis, it will develop unmistakably in a short time.

THE CAUSE OF IRITIS

is frequently the exposure to changes of temperature, cold rain, wind, and like influences. The same causes which tend to develop a rheumatic attack, often occasion it. The pain often extends over the whole of one side of the head and face, and the patient is apt to suffer from relapses. It is frequently of traumatic origin (traumatic iritis), and frequently of syphilitic. Most cases of idiopathic iritis in children are probably of syphilitic origin. A chronic iritis, though not very often seen apart from a choroiditis, may supervene upon an acute attack. *The prognosis of the disease* when seen in the beginning, before extensive adhesions between the iris and capsule of the lens have formed, is very favorable. In unfavorable cases the result may be more or less extensive adhesion of iris to the anterior capsule of the lens. When the adhesion is complete around the edge of the pupil, the usual channel of communication between the posterior and anterior chamber of the aqueous is cut off and the iris bulges. See Fig. 28. The French call this condition "Iris bombé." Without surgical interference such condition might end in secondary glaucoma. Partial adhesions are of less import than was formerly supposed. I have under observation a patient that was unintelligently treated some twenty years ago; adhesions nearly complete; pupil occluded by a membrane; there is no sight in

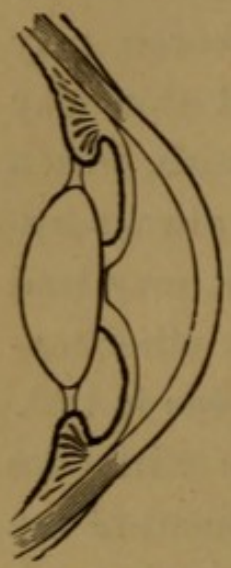

Fig. 28.

this eye, but it has never troubled her during all this time, and the sight of the other eye is perfect.

The Treatment.

The treatment should, in the first place, look to the prevention of these adhesions by the enlargement of the pupil to the full extent by atropine. This can never be safely neglected. For this purpose it should be used of the strength of four grains to the ounce, and be dropped into the eye at intervals of five minutes three or four times, morning, noon, and night. Less frequent use than this will sometimes keep the iris dilated to its maximum, but not always. In mild cases a drop or two once a day will often suffice. Another benefit of the use of atropine is that it gives the inflamed muscular tissue of the iris perfect rest through the complete paralyzation of the constrictor pupillæ. When, as may sometimes be the case, the eye does not bear the continued use of atropine well, an atropine conjunctivitis, so called, being set up, an efficient substitute may be found in Duboisine. Sometimes recent adhesions have been broken up quickly by the alternate use of a solution of atropine and calabar bean, thus producing extreme alternate dilation and contraction of the pupil; but this should not be attempted if acute symptoms are present, as the eserine would prove too irritating.

For internal medication I rely chiefly on aconite and belladonna in the beginning; later, the cause, and the condition of the patient must determine the treatment. Pain must be relieved, and hot water fomentations supplemented by cocaine instillations will usually do this.

Syphilitic cases will be benefited by mercury and such other remedies as may be approved by the attending physician. Gouty and rheumatic patients must have the constitutional remedies suited to such diatheses. I have often given salicylate of soda in these cases, and sometimes bryonia or colchicum; and I think the hot fomentations several times a day after all pain is gone are effectual in subduing the inflammation. The patient should be confined to the house and his room, even if the attack be not severe. The darkened room will not be so necessary if atropine be used, still in all cases it will be more agreeable to the patient to have the bright yellow light moderated to a certain extent. When necessary for the patient to go out, he should wear a shade. In chronic iritis, when adhesions are left and irritation of the iris is kept up by them, a strong mydriatic being of no avail in breaking them up, the operation of Corelysis may be indicated. After ascertaining the exact position of the posterior synechiæ by lateral illumination, a small incision is made through the cornea with a needle, and a blunt hook — called, from its form a spatula hook — is introduced, and the adherent iris separated from the lens. The great danger in this procedure, as indeed in all such operations on the iris, lies in the difficulty of avoiding the rupture or incision of the capsule of the lens.

The operation of Passavant, in which the iris is seized by delicate forceps, and gently broken from its attachments, is preferred by some. Often an iridectomy will prove more serviceable than either, especially if increased tension be present.

A chronic iritis, or irido-choroiditis, may sometimes be mistaken, at first, for a glaucoma; the diagnosis is corrected in such an event by testing the extent of the field of vision. If glaucoma is present we shall generally find it limited. *Choroido-iritis* is an affection primarily of the choroid, the iris being involved secondarily. The prognosis in the latter is more unfavorable; for while in the former an obscurity of vision may be due to a deposition of matter or pigment upon the capsule of the lens, in the latter it is due to changes in the deeper structures of the eye. The medical and hygienic treatment of these cases will be that of iritis and choroiditis.

PROLAPSUS OF THE IRIS

frequently occurs from perforation of the cornea from ulceration or otherwise. If slight, we may succeed in replacing it with a delicate probe, or, by enlarging the pupil with atropine, it may be pulled away from the gap. In any event the eye should be covered by a firm compress bandage, to prevent increase of the protrusion. If the prolapse is rather large and bulged outward from the aqueous humor, it should be pricked with a needle, causing it to shrink and dwindle away gradually. It may sometimes be necessary, after pricking it, to cut it off with scissors close to the cornea, to prevent its refilling. It should never be touched with caustic, according to the custom of some surgeons, as it causes great irritation, and may set up an iritis, and because under any circumstances it is quite an unnecessary risk to run.

CYCLITIS.

Cyclitis, or irido-cyclitis, may arise from a severe form of iritis in which there is an irrepressible tendency to cell proliferation, so that the disease soon reaches the ciliary bodies, or from injury of the eye. The inflammation in the ciliary body, when not idiopathic, corresponds in character to the nature of the iritis from which it originates. It is recognized by the tenderness of the eyeball to touch in the ciliary region, and it is generally the occasion of a good deal of ciliary neuralgia. Its treatment in the main is that given for iritis. It may arise also from the extension forward of a choroiditis, and would then require the treatment principally of a choroiditis. It is always a serious complication, and our prognosis should be guarded. It is noticed further under Sympathetic Ophthalmia.

ARTIFICIAL PUPIL.

The formation of an artificial pupil is indicated when the natural one has become closed by disease, and also, when, the pupil being normal or otherwise, the cornea has become opaque to a certain extent, but has still a transparent portion left. Behind this transparent bit of cornea exactly, the new pupil must be made. Or, if the cornea be transparent over considerable of its surface, we enlarge or extend the natural pupil in a direction which will render it most serviceable to the patient. Other things being equal, the extension of a

Fig. 29.

pupil downward and inward is best for vision, as seen in Fig. 29, from Nettleship.

The operation usually is that of iridectomy, the same, with an important exception, — that of the location of the incision, — as the iridectomy made for the relief of glaucoma, or intra-ocular pressure. A small incision is made into the cornea near the point beneath which we desire the new pupil. This incision is made generally with a keratome — a lance-shaped knife. Fig. 30. If a gush of aqueous humor has not already prolapsed the iris, we enter the anterior chamber with a pair of delicate forceps, and grasping a portion of the iris near the incision, draw it through the wound and snip it off with a pair of curved scissors. Fig. 31.



Fig. 30.

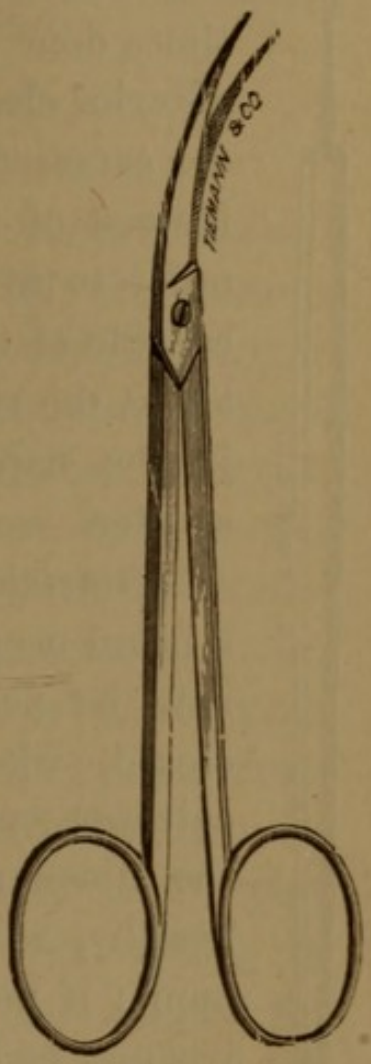

Fig. 31.

A narrower and sometimes better pupil, optically considered, is sometimes formed by the operation of iridodesis. The incision is made at the edge of the cornea with a broad needle. The chamber is entered with a blunt hook (Fig. 33), and the iris caught between its pupillary and ciliary edge, and

drawn through the wound, around which a loop of fine silk has previously been placed. The portion of iris drawn out is ligatured with the silk, and in the course of a few days sloughs off. A double iridodesis is frequently performed in opposite directions which gives a narrow slit for a pupil like that of a cat. This is the operation sometimes done for conical cornea. When the anterior chamber is very narrow, the slender cataract-knife of Graefe may be used instead of the lance-shaped keratome, in order to avoid the risk of wounding the capsule of the lens. The opening is made along the rim of the anterior chamber, as in the flap operation for cataract, only shorter.



Fig. 32.

Fig. 33.

Artificial pupil by incision simply, with a broad needle, such as Knapp's (Fig. 32), may be performed for a pupil entirely closed, when there is no lens, as after cataract operation. After the puncture, the fibres of the iris, if it is tolerably healthy, will retract sufficiently to form a pupil; if not, a bit of the cut edge of the iris may be drawn out at the small aperture in the cornea and excised with the scissors. A much more difficult operation, that of excising a triangular piece of iris with delicate scissors, is sometimes resorted to under similar circumstances.

AFTER-TREATMENT IN THESE OPERATIONS

may be very simple. A bit of linen is laid over the closed lids, the orbit filled out with a little charpie, or absorbent cotton, and a light bandage applied, and for forty-eight hours aconite may be administered hourly when the patient is awake. It is rarely necessary to resort to the cold compress.

MYDRIASIS

signifies the condition of the pupil when abnormal dilatation and more or less immobility are present. It is a well-known symptom, when binocular, of grave diseases of the brain. It is generally, however, of much less serious import, and may follow a rheumatic attack from exposure to cold or wet. It follows upon partial or complete paralysis of the third nerve, and is often of syphilitic origin. A very common extra-ocular cause, according to my experience, is irritation of the sympathetic, from disorder of the digestive organs, general neurasthenia, spinal irritation, or, in children, helminthiasis. Monocular, as well as binocular, it is often owing to deep-seated diseases of the eye, which, by diminishing the sensitiveness of the retina, impair the reflex action upon the ciliary nerves which control the pupil. It frequently follows injury of the eye.

Sometimes the cause cannot be discovered. I have seen a case of dilatation of one pupil of five years standing, in a woman of forty-five of apparently perfect health, the eyes otherwise normal in all respects. The affection occasionally follows injury of the sphinc-

ter of the pupil from pressure of the lens in extraction. A constant subjective symptom is the impairment of vision for near objects.

I cannot define any particular plan of treatment. It must vary constantly according to the nature of the exciting cause. The affection is often a concomitant of paralysis or disease of other parts of the eye, and the treatment is spoken of elsewhere. Eserine or pilocarpine applied to the eye is generally of temporary benefit in restoring the size of the pupil, and improving the vision for near objects; the same remedies are reported occasionally to have been of permanent benefit also.

ACTION OF ATROPINE AND DUBOISINE.

Atropine, to be used in the form of a solution of sulphate of atropine, which is exceedingly soluble in water, acts on the iris probably by paralyzing the circular fibres. The iris is extremely susceptible to its influence, a solution in water of $\frac{1}{10000}$ enlarging the pupil, which it reaches by absorption through the cornea, with great certainty in the course of an hour or two. The disadvantage of a weak solution lies in its feebleness in overcoming any adhesions between the iris and capsule of the lens, and also in its uncertainty of effect when the iris is diseased. For the enlargement of the pupil when the iris is healthy, a weak solution, such as a grain to ten or twelve ounces, is preferable, from the fact that its effect passes off in the course of a day or two. A solution of a grain or two to the ounce of water is often desirable on account

of the promptness of its action, a half hour only being required for its full effect. A solution of four grains to the ounce will act still more promptly, and will also paralyze the accommodation more or less completely; the effect of such a solution on the pupil will not pass wholly off for eight or ten days. A solution two or three times this strength may be used in attempting to break up old adhesions between the iris and lens capsule. Very strong solutions, thirty to fifty grains, are not to be commended, lest cerebral symptoms supervene. A long continued use of atropine renders the eye intolerant of it, and in very rare instances it proves too great an irritant to be used at all. Homatropine hydro-bromate acts similarly to atropine on the eye, but more feebly, and its effects pass away in a day or two. It cannot be relied on to perfectly paralyze the accommodation like atropine; still, used repeatedly, in some cases it acts sufficiently forcibly, and is then preferable to atropine as the eyes can be used so quickly afterwards.

Gelsemine in the form of a solution of the hydrochlorate in water is less useful in ophthalmic practice. Used in a solution of about four grains to the ounce of water, it causes a maximum dilatation of the pupil in about an hour, or a little later. For the purpose of ophthalmoscopic examination this alkaloid is, like homatropine, quite suitable, as its effects on the pupil pass off in a day or two, while a mydriasis from atropine may annoy a patient for a week or longer. Gelsemium, used locally, also affects the ocular muscles. Measured by prisms the internal rectus becomes

stronger, the external weaker; the internal gaining more than the external loses. Evidently the termination of the sixth nerve is specially affected. Given internally, it acts on this nerve, and in large doses also upon the third nerve. In poisonous doses externally or internally, it paralyzes the ocular muscles.

Duboisine is, owing to its rapid action in enlarging the pupil, often a convenient substitute for atropine. Four grains to the ounce of water in solution will enlarge the pupil *ad maximum*, in from six to ten minutes. When atropine causes irritation, it is also the best substitute, as its power over the pupil is more than equally great. It also paralyzes the accommodation, like atropine, and its effects pass off more quickly.

COCAINE

also causes a temporary enlargement of the pupil, and as it leaves the accommodation unaffected, acts quickly, and as its effects on the pupil pass away quickly, it is very suitable for dilating the pupil for ophthalmoscopic examinations. It contracts the superficial blood-vessels of the eye and causes a slight retraction of the eyelids.

MYOSIS,

signifying the abnormal contraction of the pupil, is sometimes seen in iritis, and frequently in disease or injury of the upper part of the spinal cord. It has also been observed in hyperæsthesia of the retina, and in persons who work at small objects, like watch-makers. Idiopathic myosis is extremely rare.

Eserine in the strength of one-eighth grain to one grain to the ounce of water contracts the pupil, the more quickly, the stronger the solution; but the strong solution is quite irritating to the eye. It will overcome the mydriasis of cocaine, but not of atropine. It causes spasm of accommodation and decreased tension of the globe.

Pilocarpine acts on the eye in a manner similar to that of eserine, and as it is less irritating, I use it frequently in preference to the former. It is inferior in myotic power.

Muscarine is reputed to cause an intense spasm of the ciliary muscle, and is also less irritating to the conjunctiva than eserine.

Iridodonesis, tremulousness of the iris, is a certain indication that the iris has lost the support of the lens, as after extraction, in dislocation of the lens, or as in hydrophthalmia, when the anterior chamber becomes enlarged.

Cysts of the iris may be excised together with that portion of the iris to which they are attached, by the operation of iridectomy.

Irideremia, absence of the iris; *coloboma*, cleft iris; *corectopia*, an eccentric position of the pupil; and *polycoria*, more than one pupil, — are congenital anomalies rarely observed.

CHAPTER IX.

THE CHOROID AND VITREOUS.

HYPERÆMIA OF THE CHOROID

is undoubtedly of frequent occurrence, but is very difficult to diagnose with the ophthalmoscope, as the vessels of the choroid are, except in very light-complexioned persons, almost completely hidden by the pigment layer of the retina. Nor unless the iris and ciliary bodies are also congested, does it seem possible to diagnose it without the ophthalmoscope.

CHOROIDITIS SIMPLEX, OR DISSEMINATED CHOROIDITIS,

can hardly be diagnosed with certainty without the aid of the ophthalmoscope, as the otherwise noticeable symptoms are common to other affections. There is usually some dilatation and sluggishness of the pupil, some failure of sight, irregular obscuration of the field of vision, so that perhaps but parts of objects are seen at once, and usually little or no pain. Sometimes the external appearance of the eye is quite normal. The *Ophthalmoscopic signs* are general cloudiness of the choroid or vitreous, but oftener we see small yellow-white patches of lymph, first at the periphery, afterwards about the macula lutea and optic disc, and later, if atrophy of the choroid occurs, the white sclerotic will

be seen shining through in spots. Still later, we may find consecutive atrophy of the retina and optic nerve.

FIG. 34.

Figs. 34, 35. We know that the exudation at first is in the choroid, from the observation that the retinal vessels are distinctly seen over these patches, and are not inter-

FIG. 35.

rupted in their course or obstructed, and from the fact that the retina retains its normal transparency.

The prognosis must of course be guarded, owing to the tendency to complication and atrophy of the retina and optic nerve. Sometimes, however, the exudations are absorbed, leaving but faint traces of their existence behind, and sight is quite restored.

Central choroiditis, a steadily decreasing visual power in elderly people with normal field of vision, points to a circumscribed patch of choroidal inflammation beneath the macula lutea. The ophthalmoscope shows a yellow-

FIG. 36.

ish, irregularly shaped spot with pigmented outlines, and there is no tendency towards spreading. There is no danger of total blindness. Figs. 36 and 37. *Metamorphopsia*, that is, distortion in the appearance of objects, is observed, and of course there is a central scotoma. See page 226.

Allied to this form of choroiditis is the *Ametropic retino-choroiditis* described by Gould.[1] It occurs in

[1] A. of Oph., vol. xix. No. 1.

young people, and is due to eye strain in ametropia, chiefly hypermetropic astigmatism. The macular region is slightly pigmented. The lesion is retinal. The treatment is to correct the ametropia by proper glasses.

The Treatment of Choroiditis Simplex

must be governed to a great extent by the state of our patient's health otherwise, and the cause of the disease.

FIG. 37.

This is frequently syphilis. Generally it will be found that the liver, digestive organs, or the uterus are disordered. All these circumstances will influence our treatment. At all events, the patient should abstain from the use of the eyes in reading or sewing, and guard them against bright light out of doors by wearing dark glasses.

In old cases of irido-choroiditis the operation of iri-

dectomy will frequently be indicated for the purpose of breaking the adhesions between the lens capsule and iris, as well as for the purpose perhaps of laying a pupil before a transparent portion of the capsule. The operation is, under these circumstances, beset with difficulties from the narrowness of the anterior chamber and the degenerated rotten condition of the iris. If the lens is wounded in the attempt, it must be extracted.

SUPPURATIVE CHOROIDITIS,

called also *panophthalmitis*, or *ophthalmitis*, is a very grave disease and its course often rapid. The eyelids are usually red, swollen, and œdematous, the chemosis very great, so that the eye appears swollen. The iris is bulged forward, and discolored; the eyeball sensitive to touch, the tension increased; and we notice, if the pupil is sufficiently clear, a yellow reflex from behind the lens, due to a purulent infiltration of the vitreous. Sometimes the pain in the eye and the region about it is of the most intense nature, at other times less severe. Sight is, of course, rapidly and greatly impaired, and frequently all sensation of light disappears.

The causes are suppurative inflammation of the iris and cornea in bad subjects, typhus, typhoid, pyæmia, injuries of eye, surgical operations, or sympathetic ophthalmia. Certain cases occurring with exhausting diseases have recently been proved to be due to the presence of streptococci in capillary vessels of the retina (*vide* Ophthal. Review, Vol. IX., April, 1890).

The Treatment of Ophthalmitis

in the commencement should consist of ice-water compresses and the internal use of aconite. It may be necessary afterwards, if hot fomentations and the administration of the indicated remedies do not relieve the severe pain, to resort to the subcutaneous injection of morphia in the temple, or the paracentesis of the cornea. If the febrile symptoms will permit, the patient should be allowed a most nourishing diet, and perhaps a tolerably free use of stimulants. It is, of course, often impossible to save the sight of the eye, and indeed frequently any part of the eyeball, in these cases, and sometimes life itself is endangered through the extension of the disease to the meninges of the brain. When the disease is foreseen, and before the suppuration has become general, enucleation of the ball is probably the best course to pursue. Recently the operation has been frequently performed, under strict anti-septic precautions during the suppurative stage, and no harm to the brain has ensued. Noyes relates a remarkable recovery under free incisions and antiseptic applications, after enucleation and threatening meningitis. Diseases of Eye, page 501.

Metastatic choroiditis sometimes follows a meningitis in young children, and leads to blindness and atrophy of the globe.

Serous choroiditis is usually associated with a serous iritis or irido-cyclitis, and would require similar treatment. See pages 158, 316.

Tubercular choroiditis, connected with a similar disease of the brain, is a very rare form of disease.

Miliary tuberculosis of the choroid associated with similar infiltrations in other organs, is more frequently seen. The vision is generally normal.

Tumors, ossifications, carcinoma, and sarcoma are met with in the choroid occasionally, but they are comparatively rare.

HYALITIS,

or inflammation of the vitreous humor, though usually an accompaniment of disease of other structures of the eyeball, may possibly occur idiopathically. In simple hyalitis we notice, with the ophthalmoscope, that the whole vitreous is clouded so that the details of the fundus are indistinct, while floating about in it are discovered delicate shreds of various sizes and shapes. Generally with this form of hyalitis there coexists a retinitis, choroiditis, or cyclitis.

A suppurative hyalitis supervenes upon suppurative iritis or irido-choroiditis, and occurs after cataract operations and injuries of the eye, and is sometimes the beginning of an ophthalmitis which destroys the entire globe. The treatment of hyalitis must have reference to the primary seat of the disease, which is in the choroid or retina. I have never met with it in its idiopathic form. The prognosis is not good.

Opacities of the vitreous are frequently due to remains of effusions of blood or lymph, degenerated, fatty, or pigmented cells, membranous débris of varied form and size. These opacities may be seen best with the oph-

thalmoscope in the upright image. Let the patient turn his eye in different directions in quick succession and the opacities will be noticed moving slowly about across the pupillary field. Such opacities must not be confounded with the condition called *muscæ volitantes*, usually a subjunctive symptom of less import.

Muscæ volitantes are either transparent or opaque, and are best seen by looking towards a white surface. They are probably caused in most cases by over-use of the eyes or by impaired general health, and consist of the débris of cells, shreds of tissue or fibre floating about in the vitreous, and slowly changing their position with every movement of the eye. They appear transparent and bead-like, or in other cases shred-like or as dark, queer-shaped bodies. Rest of the eyes should be enjoined, the general health attended to, and, if very troublesome, colored glasses may be worn which will render them less apparent. They are more common in myopic eyes.

The Treatment of Opacities of the Vitreous

must be directed to the removal of the cause, which will generally be found to be an irido-choroiditis, or choroido-iritis, or some affection of the deeper structures of the fundus. Occasionally fixed opacities of the vitreous have been torn through with a fine needle, and the visual powers of the patient improved by the operation.

Synchysis is the name for a fluid condition of the vitreous, in which its gelatinous consistency is lost. It is difficult to diagnose with certainty in all cases. The free movement of opacities presupposes it, and

when vitreous is lost from a wound or during an operation for cataract, we know that its loss is made good by a fluid or serous substance. *Sparkling synchysis* expresses a state of fluid vitreous holding crystals of cholesterine, which present a very striking and characteristic appearance under the ophthalmoscope. Their origin or mode of production is undetermined.

CYSTICERCI IN THE EYE.

Von Graefe had in eighty thousand patients eighty cases of cysticerci in the vitreous or retina: three cases in which it was in the anterior chamber; beneath the conjunctiva, five; and in the lens and orbit, one each. The result, when the cysticercus is deep seated, is the loss of the eye from inflammation, and degeneration of the choroid and vitreous. Von Graefe occasionally succeeded in saving the eye through the extraction of the parasite, but the operation is very difficult when the animal is seated behind the lens. Alfred Graefe has operated successfully in twenty cases out of forty-five. The original seat of the cysticercus is usually beneath the retina, where it may be seen with the ophthalmoscope as a grayish-blue vesicle, whence it emerges later into the vitreous. The affection is rare in this country; I have seen but one case in Boston.

CHAPTER X.

GLAUCOMA.

THIS is one of the most dangerous of all the diseases to which the eye is subject, and, without timely surgical interference, generally terminates in blindness, and, later, in complete degeneration of all the tissues of the eye. It is not a new disease, but up to the time of the invention of the ophthalmoscope it was not much understood. No remedies, surgical or other, having proved of much avail, it was quite natural that an almost uniformly fatal disease, of which very little in regard to its nature was known, should receive less attention than others better understood, and which permitted of satisfactory alleviation or cure. In 1854, Ed. von Jaeger, soon followed by Von Graefe, gave accurate descriptions of the morbid changes in the fundus occurring in the course of the affection which drew attention to the disease, the interest in which was widely and quickly spread over Europe when Von Graefe, in 1856, discovered a successful surgical remedy for it in the operation of iridectomy. Perhaps the most convenient and practical way in considering the disease is, to divide it into three forms, — the acute, subacute, and chronic.

THE PREMONITORY SYMPTOMS

of acute glaucoma are usually, first in order, an increased tension (hardness) of the eyeball. This is to be determined by touch, as previously described. The subjective symptom of fulness and swelling, so often felt in conjunctivitis, iritis, or scleritis, is not to be mistaken for increased tension of the ball which indicates the approach of an acute attack of glaucoma. With this tension come its first legitimate fruits, periodic dimness of vision such as one may produce by pressure of the finger upon the normal eye, lasting for a few moments or hours, and a rapid development of any previously existing presbyopia. The pupil is somewhat, but not greatly, dilated; and as a sequel of this, the patient notices a halo or rainbow around the flame of a candle. The ring around the light is at its outer side red; its inner, bluish-green. There may be more or less ciliary neuralgia over the eye, in the forehead, temple, and face; but in my experience, this symptom at this time is not common. The above premonitory symptoms are those observable without the use of the ophthalmoscope, and may occur merely at intervals of months; but gradually the intervals shorten, and only weeks or days intervene between the recurrence of the symptoms, and the next stage of the disease, *confirmed glaucoma*, may be looked for.

Hereafter, though there are to be perhaps periodic exacerbations, there may not be, as in the premonitory stage, any *perfect intermissions*. The patient may be suddenly seized with a terrible neuralgia over the

eye, in the forehead, temple, face, down the side of the nose, with severe constitutional symptoms, high fever, nausea, and even vomiting; so that the affection may be mistaken for severe bilious or typhoid fever. In one case, I found the disease had been diagnosed as an inflammatory affection of the brain. An examination of the eye, however, will correct the diagnosis. The lids will be found puffy and swollen, the conjunctiva injected, there is chemosis, more or less cloudiness of the aqueous humor, discoloration of the iris which appears bulged forward almost against the cornea, dilatation of the pupil, and decided tension of the eyeball. Vision is always greatly impaired. I have never known it wholly lost at this stage, although this has not unfrequently happened. Patients will generally see a hand held very near the eye, or be able to distinguish the large gilt letters on the back of a book. They are also disposed to speak of sudden flashes of light before the eyes, and perhaps other spectral phenomena. These, with some photophobia and lachrymation, and more or less anæsthesia of the cornea are the marked symptoms observed in the beginning of confirmed glaucoma.

As the acute attack passes away, the sight will grow better, and perhaps very much better, but the appearance of the eye with a modification of the severe inflammatory aspect remains. The attacks recur, the sight being left after each in a worse condition. The tension of the eye increases, the iris shrivels, the anterior chamber becomes still narrower, the sub-conjunctival veins appear turbid and tortuous, the field of vision

becomes greatly contracted, the sensibility of the cornea diminished, the so-called green reflex is marked. I say so-called green reflex, because the reflex, to my eye, is more slate-colored. No doubt it is sometimes *greenish*, but if one looks for a decided green reflex, such as is frequently noticed in the eye of a cat, he will be disappointed. The diminished sensibility of the cornea may be determined by touching it with a bit of paper twisted to a point.

THE OPHTHALMOSCOPIC SYMPTOMS

in the premonitory stage are wholly absent, or, at most, frequently of merely negative value, from cloudiness of the cornea. In the stage of confirmed glaucoma, there may be more or less excavation of the optic disc, dilation, and turgescence and tortuosity of the retinal veins, and venous pulsation. At a later stage of the disease we may find the arteries thin and pale, arterial pulsation, hemorrhage into and general cloudiness of the vitreous. The large excavation of the optic nerve differs from the physiological and amaurotic excavations, in size, depth, and in the abruptness of its edge, in consequence of which the retinal vessels, in curling over the margin at the border of the disc, are much displaced. Compare Figs. 38 and 39, on the next page, healthy optic discs, with those of Figs. 40 and 41. Frequently, however, the media in glaucoma are so turbid that nothing whatever can be seen with the ophthalmoscope. Fortunately, when this is the case, the other symptoms are so characteristic that no error in diagnosis need occur. The field of vision is usually contracted

at the nasal side. Fig. 42, after Von Jaeger, gives the ophthalmoscopic appearance of the fundus with slight cupping of the disc.

FIG. 38.

Sub-acute glaucoma does not differ in character from the acute. The symptoms are less severe, and its

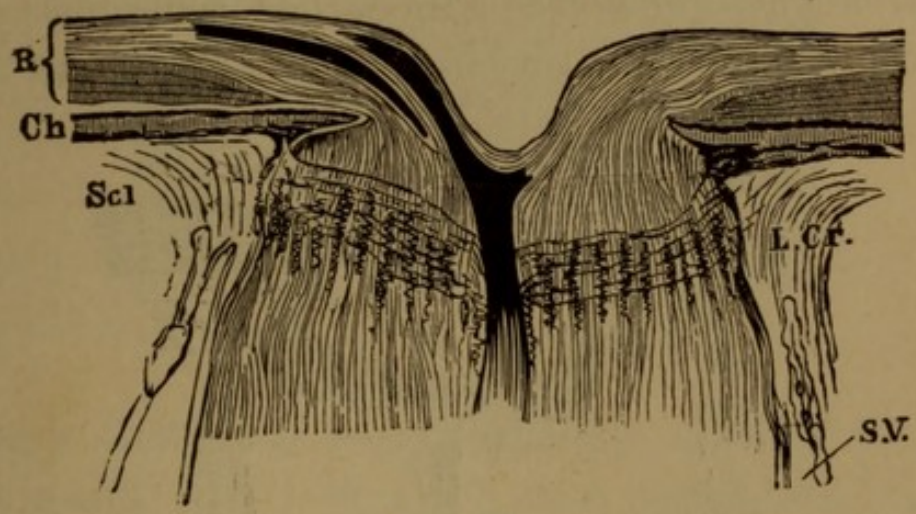

FIG. 39.

Vertical section of healthy optic disc, etc. × about 15. *R.* Retina, outer layers shaded vertically, nerve-fibre layer shaded longitudinally; *Ch.* Choroid; *Scl.* Sclerotic; *L. Cr.* Lamina cribrosa; *S. V.* Subvaginal space between outer and inner sheath of optic nerve. The central vein and one of the divisions of the central artery are seen in the nerve and disc. (After Nettleship.)

course less rapid, but the end is similar. It is not necessary to describe it.

Chronic inflammatory glaucoma is merely an advanced

stage of the acute form, when, the exacerbations having diminished somewhat in intensity, the inflammation is

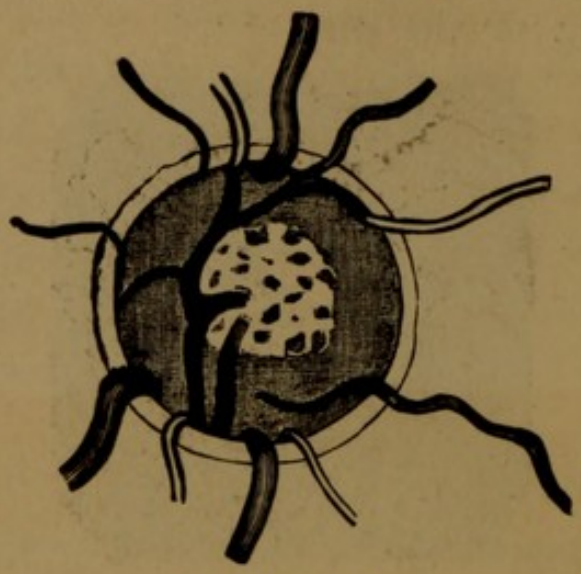

FIG. 40.

fixed and gradually progressive, and the sight gradually failing.

Chronic non-inflammatory glaucoma, sometimes called glaucoma simplex, is very insidious in its course, and of

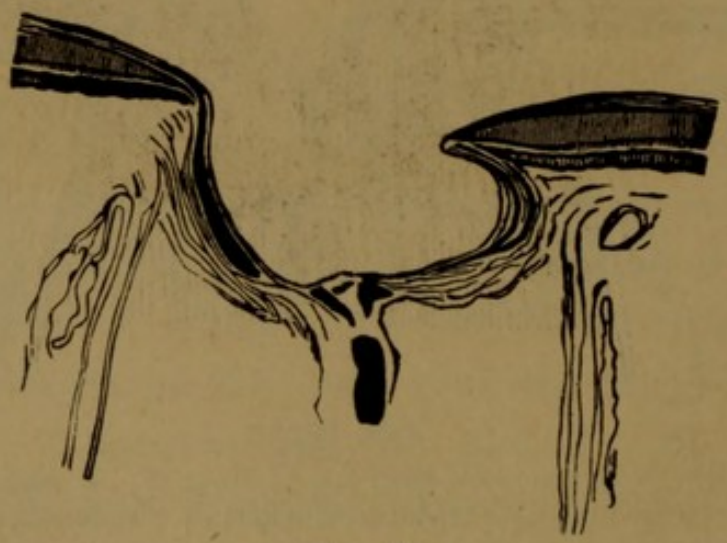

FIG. 41.

rare occurrence compared to other forms of the affection. It has not very unfrequently happened that patients have been unaware of the existence of this disease in one eye, the other being well, until it has completely

destroyed the sight. Generally the disease is far advanced before aid is sought. Vision fails, glasses are not of service, there may be a slight inflammatory attack, and they seek surgical advice. Frequently the eye appears normal, with perhaps the exception of a slightly dilated and sluggish pupil. That constant and characteristic symptom of glaucoma, increased tension of the globe, is usually present, and the ophthal-

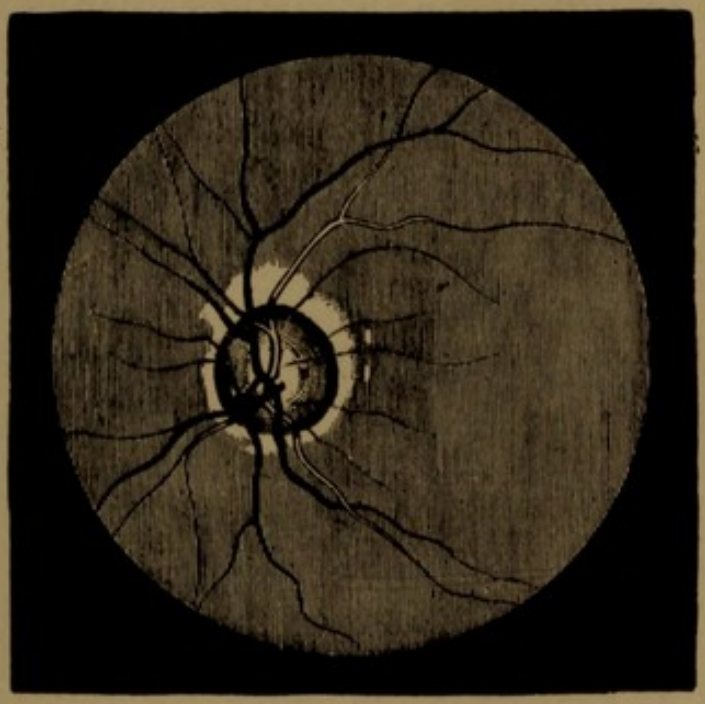

FIG. 42.

moscope will show a glaucomatous excavation of the optic nerve. Still in some cases these symptoms are not marked, and it will prove quite difficult to diagnose the case, but as the disease progresses, sooner or later inflammatory symptoms are apt to be manifested, as in the inflammatory forms previously spoken of. Whether this be the case or not, the eye gradually assumes the glaucomatous aspect as the globe grows harder.

Glaucoma fulminans is the name formerly given by Von Graefe to a very rare form of glaucoma, the most dangerous of all, in which the disease progresses with such fearful rapidity that the sight of a previously sound eye may be wholly destroyed in a few hours, or even, it is stated, in half an hour.

Absolute glaucoma, as the disease is termed when all perception of light has disappeared, is frequently distinguished at a glance by a pale-greenish opacity of the lens. At this stage of the affection the patient may suffer from severe attacks of ciliary neuralgia. Later, the iris becomes completely atrophied, the cornea opaque and softened, the choroid and retina degenerated, and hemorrhagic effusion takes place within the fundus, staphyloma of the sclerotic, and frequently inflammation and atrophy of the globe follow.

THE CAUSE OF GLAUCOMA

is not yet fully demonstrated. There is, first, an affection of the iris, ciliary body, and the choroid; then, an increase of the humors of the eye, and increased tension and excavation of the optic nerve; then, the cornea, sclerotic, and retina become involved. The space of Fontana is obliterated and there are adhesions between the periphery of the iris and the cornea. Compare Figs. 43, 44, after Nettleship. The fact that the sclerotic in this disease is found rigid and unyielding is supposed to be of importance; for the disease attacks generally only those of an age above thirty-five or forty, in whom the sclerotic coat has already attained a firmness and rigidity unknown in youth. An interesting

and perhaps rational theory is that which attributes the hyper-secretion of the fluids of the eye to some abnormal irritation of the nerves controlling these secre-

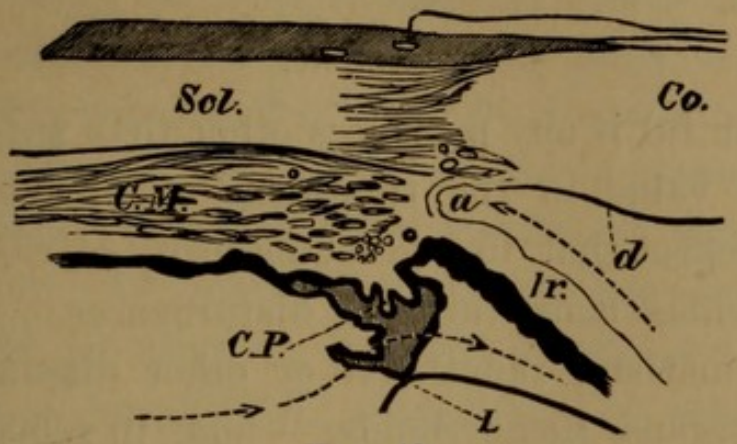

FIG. 43.

Section through the ciliary region in a healthy human eye. *Co.* Cornea; *Scl.* Sclerotic; *C. M.* Ciliary Muscle; *C. P.* two ciliary processes, one larger than the other; *Ir.* Iris; *L.* the marginal part of the crystalline lens; *a*, angle of anterior chamber; *d*, membrane of Descemet, which ceases (as such) before reaching the angle *a*. The dotted line shows the course probably taken by fluid from the anterior part of the vitreous into the posterior aqueous chamber, where it is augmented by aqueous humor secreted by the anterior part of the ciliary process, thence through the pupil (not shown) into the anterior aqueous chamber to the angle *a*. Suspensory ligament of lens not shown. × 10.

tions, this irritation being reflex from the sympathetic. This hypothesis makes the increase of fluids the essence of the disease, and the consequent tension of the globe

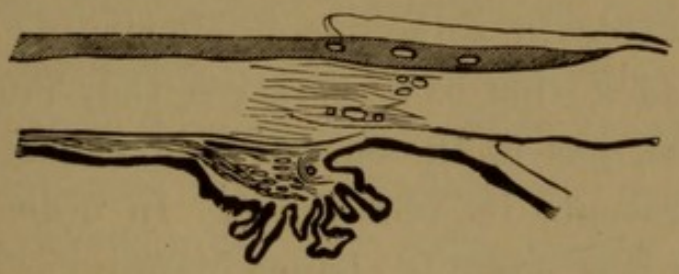

FIG. 44.

Ciliary region in a case of chronic glaucoma of three years' standing. Notice the adhesion of iris and cornea at the angle of the anterior chamber.

the cause of the inflammatory symptoms. The interior tissues of the eye become irritated and inflamed from this mechanical pressure, and finally degenerate

from disease and lack of nutrition. Natanson records twenty-eight cases of glaucoma following senile cataract extraction.

Treatment.

It is doubtful if any measures other than surgical are of positive value in the treatment of glaucoma; but when we reflect that in a great majority of cases there coexist serious constitutional disturbances, — such as gout, rheumatism, functional or other disease of the digestive organs, hemorrhoids, — and, in females, that the affection is apt to occur at the period of cessation of menstruation, it seems almost impossible to avoid the conclusion that the affection is often, primarily, extra-ocular; and that seen at the earliest stage, a careful, intelligent, medical treatment, combined with strict hygienic regulations, might prove curative in certain cases. In estimating the effect of medicines, however, we must not overlook the circumstance that an acute attack in the earliest stage may repeatedly pass off leaving the sight unimpaired. No doubt our remedies may prove serviceable in relieving or shortening the duration of an attack; but to be curative, they must prevent its recurrence, just as the operation of iridectomy when successful prevents its recurrence. In order to afford remedies the best possible chance of proving of permanent benefit, they should be administered also during the period of intermission. We can only be sure that the treatment is proving of real service when we find that *it reduces the hardness of the globe.* Whatever will reduce the tension of the eyeball in glaucoma will

cure or at least relieve it. It is said that a number of cases have been thus benefited, through relief of tension, by the use of eserine as a collyrium. Eserine should certainly be tried in the early stage of the disease, although I should myself never postpone an operation for this purpose, if it were clearly indicated. Some surgeons prefer pilocarpine to eserine, in glaucoma.

The habits of our patients should be scrupulously looked after. Of course a moderate use only of the eyes should be allowed, — bright lights and crowded places are to be avoided; sunlight to be modified and deprived of its piercing yellow rays by the use of colored glasses when in the open air, especially to be used to protect the eyes from the sunlight upon the snow, white sand, or water. In addition to this, all habits which affect the general health unfavorably, — such as the excessive use of tobacco, alcohol, or other stimulants, — all dissipations and exhaustive labor, mental or physical, should be strictly prohibited under penalty of loss of sight.

The diet should be attended to, any idiosyncrasies of the patient in this respect ferreted out, and indigestible articles forbidden. The diet, however, should be good and nutritious, and, particularly in elderly persons, the confirmed habit of indulgence in stimulants like tobacco, alcohol, tea, and coffee should not be interfered with, unless it be necessary to substitute moderation for excess.

Internal medical treatment cannot be relied on exclusively in the treatment of glaucoma. Doubtless it may be of more or less service in many rheumatic or

arthritic patients and in cases complicated by hepatic, hemorrhoidal, or uterine and other affections. Such complications will suggest the remedies better than they can be suggested here in a general way when indicated by symptoms apparently only remotely connected with the disease of the eye.

A serious obstacle to the success of any and all treatment lies in the fact that patients rarely consult a physician until the disease is confirmed, and too great tissue-changes have occurred. Many patients sent to me are such as have been completely blind for months, and sometimes years. In cases of complete blindness, an operation is indicated simply for the relief of a tormenting neuralgia over the eye. No restoration of sight is possible. Only now and then does a case present itself at the most favorable time for a successful operation. If we inquire into the cause of the delay, we find that no attention whatever was paid to the early symptoms; the attack was regarded as a headache, rheumatism from a cold, a neuralgia in the head, or some ailment not immediately connected with the eyes, and no advice was sought until after the advent of a terrible attack of acute inflammation, or until the sight was found permanently impaired, and spectacles of no service.

It is very difficult to relieve the severe ciliary neuralgia which occurs so often in acute attacks, except by surgical interference. An iridectomy, and frequently a simple paracentesis of the anterior chamber, will often relieve the pain as if by magic. Division of the ciliary muscle will also relieve the pain, and, like the others, accomplishes its result by removing the intra-

ocular pressure. Atropine can never be used with safety, and even cocaine has been known to induce a glaucomatous attack. Warm fomentations of simple water or warm water medicated with chamomilla, or opium, may be of some service.

Surgical Treatment.

Iridectomy in the early stages of acute glaucoma is frequently a cure for it. In the later stages, it is nearly always a palliative, and sometimes a cure. The operation is painful, and usually performed under the influence of a general anæsthetic; or possibly it may be done under cocaine, if the patient is not timid or restless. It is similar to the operation for artificial pupil already described at page 165, *except that we enter the eye from the sclerotic* near its junction with the cornea, and the opening is as large as the keratome or iridectomy lance will allow. The large opening, and the placing it in the sclera are for the purpose of excising a large segment of the iris, and insuring the section to reach quite back to the ciliary border. See Fig. 45, after De Wecker. This is supposed to insure a more certain and permanent relief of the intra-ocular pressure. The iridectomy should be made beneath the upper lid in order that the deformity in the

Fig. 45.



Fig. 46.

eye may be covered, and the bent keratome (Fig. 46) will be necessary for the incision. After the operation,

the eye is simply bandaged, and the patient kept quiet for a few days until the corneal wound heals and the artificially produced irritation is gone. Very rarely is the reaction sufficient to call for the application of cold compresses. The administration of aconite, for a day or two, may be advisable after the operation.

WHEN TO MAKE THE IRIDECTOMY.

An important point to be determined is the length of time we may wait, in case our remedies fail of the desired effect, before resorting to an operation. The ready answer, and the true answer, to a question of this kind is, *the sooner the operation is performed in a case of glaucoma* the better. Delays are exceedingly dangerous. But the patient is not often willing at the very commencement of the disease to submit to an iridectomy, even if we happen to be fortunate enough to be consulted thus early. As a rule, then, he may safely postpone the operation so long as the intermissions of congestion, pain, and blindness *are complete.* Meantime, the instillation of eserine may be kept up. When there is simply *re*-mission instead of *inter*mission the eye is in great danger; and if vision is continuously impaired, and especially if *the field of vision is contracted*, the operation should be postponed no longer than is absolutely necessary. We must, as before observed, always bear in mind that with or without medical treatment the subjective symptoms are constantly changing, and that while our measures may be palliative, they cannot be curative unless they reduce the abnormal tension (hardness) of the globe. In the

estimation of this tension we are to be guided by our sense of touch, rather than by any sensations of the patient. Both his eyes being closed, we press very gently with the tip of our fingers upon both eyeballs either separately or together, determining their comparative hardness, and comparing them in this respect, if necessary, with our own.

The prognosis, when iridectomy is performed in the premonitory or the very early stage of acute inflammatory glaucoma, is favorable. In order that this success should be nearly certain, the patient should, before operating, be still able to see large print, and the tissue of the iris be nearly in its normal condition. Still, success may crown an operation in acute glaucoma when vision is reduced to a mere perception of light.

In later stages of acute glaucoma, if vision be not too much impaired, and the field of vision not much contracted, permanent good results may be possible; but if the reverse of this obtains, the visual field is narrow, sight very much impaired, and the excavation of the optic nerve considerable, the result of the operation, though good, and offering a fair chance for the patient, may not be permanent.

In subacute and chronic glaucoma we may expect to prevent further loss of vision and preserve the eye from future inroads of the disease, provided sight is not wholly gone and the field of vision is not too much narrowed. In these cases, indeed, vision sometimes improves considerably; not rapidly always, as after an operation in acute glaucoma, but after the lapse of

some months. In non-inflammatory glaucoma the prognosis is not so favorable. In this form of the disease the more recently devised operation of sclerotomy, mentioned farther on, is preferred by some surgeons.

In absolute glaucoma, when all perception of light is gone, an operation is only indicated to cure pain, and prevent the recurrence of the inflammatory attacks.

It is not surprising when we consider that the operation of iridectomy offers a chance, however slight it may be, of restoring sight even in old and unfavorable cases, that it should often be performed against all indications, and even against all hope, and as a natural consequence that it should often fail. This occasions disappointment, and sometimes distrust of the value of the operation generally. It must not be forgotten, however, that there are pretty definite indications for surgical interference which cannot be ignored, if we expect our prognosis to prove correct, and that it is rather too much to expect of any operation that it shall prove successful when not indicated. It is not affirmed of the operation that it is a sure cure for glaucoma, but simply that *when indicated* it is the most reliable cure for glaucoma known at the present time, and that in a vast majority of instances it has proved successful.

The rationale of iridectomy in this disease is not demonstrated as yet. We know that iridectomy at its best permanently reduces tension, but *how* it does this is still a question. Exceptionally, there have been noticed cases of glaucoma without increased tension. In such instances iridectomy has proved serviceable also; it would, therefore, appear that the operation has some-

times a curative effect not due to the removal of intra-ocular pressure.

SCLEROTOMY.

The operation of sclerotomy is finding considerable favor with many ophthalmic surgeons as a substitute for iridectomy. It does not appear to reduce tension so effectually as iridectomy, nor is it so reliable for most forms of glaucoma. It is commended by some, however, for chronic glaucoma simplex, in which iridectomy is sometimes of little service, and may, perhaps, be advised in cases of hemorrhagic glaucoma, and in those of absolute glaucoma where, sight being gone, an operation for the relief of pain is indicated. The operation is usually done with the narrow cataract-knife, which is entered near the corneal margin of the sclera as if to make a small flap, some two or three millimetres in height. When the imaginary flap is about two-thirds finished, and the aqueous has escaped, the knife is slowly withdrawn. The operation is difficult, and there is not unlikely to be a prolapse of the iris, in which case the iris is cut off, and the operation results in an iridectomy. *Posterior sclerotomy* is done by making an oblique incision in the sclera from the equator of the eyeball extending backward from six to eight millimetres.

OTHER OPERATIONS FOR THE CURE OF GLAUCOMA

are those of division of the ciliary muscle and paracentesis corneæ. The first has not proved as permanent and certain in its results as would be desirable,

and the second requires a too frequent repetition to be generally feasible. Fig. 47 shows the form of needle

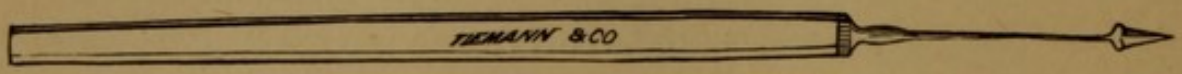

FIG. 47.

used for paracentesis. Both of these procedures are serviceable, as has been stated, in temporarily relieving ciliary neuralgia, and may sometimes answer the purpose of relieving pain in those old cases of glaucoma where the sight is irrevocably lost, and nothing more than relief from intolerable suffering is hoped for. The use of atropine in the ciliary neuralgia of glaucoma, or for enlarging the pupil, is not permissible, lest a fresh attack be induced. The operation for division of ciliary muscle is described at page 319.

SECONDARY GLAUCOMA.

Glaucoma sometimes supervenes upon injuries of the eye, and more rarely from deep-seated disease of the globe, such as choroiditis or irido-choroiditis, sympathetic ophthalmia, and other affections. It is to be treated surgically, but the chances of success are greatly lessened, except in young people and in cases where the exciting cause can be removed.

CHAPTER XI.

THE RETINA AND OPTIC NERVE.

RETINAL HYPERÆMIA.

A *hyperæmia of the retina* is more readily diagnosed than a similar condition of the choroid. In the active or arterial form there is some photophobia and lachrymation. In the passive or venous form these are absent. In the first, the ophthalmoscope shows a reddened disc from congestion of the capillary vessels upon its surface, and the larger retinal vessels may be somewhat increased in size. It is difficult to determine this, as in florid persons the vessels appear larger and more active than in pale or lymphatic individuals. If one eye only is affected, we can, by comparison, make our diagnosis quite certain. In the venous or passive form the retinal veins are dilated, dark, and perhaps tortuous. We notice venous pulsation, or it can readily be produced by pressure on the eyeball.

The Cause and Treatment.

Very often in these cases we find some abnormal state of the refraction or accommodation. I have treated scores of such cases, and the remedy is suitable glasses. It is caused also by exposure to bright light, or very

fine work by artificial light, and a radical change of occupation will do much to promote a cure. Very often there will be found disorder of some of the abdominal organs as a cause. The judicious treatment of any disorder of the general system may affect a cure of the eyes. Colored glasses are advisable for out-of-door use, if the photophobia is considerable. When the affection is severe, complete rest of the eyes should be enjoined.

RETINITIS.

In the serous form of retinitis we notice, with the ophthalmoscope, generally a veiled or hazy appearance of the retina, less marked at the macula lutea where the normal membrane is always of diminished thickness, and more decided about the optic disc, which is somewhat swollen from œdema, and its outline rather indistinct. The arteries are normal, but the veins appear dark and tortuous.

Externally, the eye looks well. Perhaps the pupil may be slightly dilated and sluggish; but, in my experience, this is not usually the case. Nor are there any of those symptoms of irritability of the eye which are so often and erroneously supposed to exist in retinitis,—such as photophobia, pain, lachrymation, and the phenomena which accompany retinal hyperæsthesia. The causes of this affection do not differ materially from those mentioned under Hyperæmia of the Retina, just described, and the treatment must be similar in character, but of course more prolonged, and cannot, in many cases, result as successfully. Our prognosis

should be more guarded; for, from the beginning, the sight is more impaired. The veil or cloud grows thicker until frequently the patient is almost totally blind. Frequently, if the disease continues many weeks, atrophy of the retina may ensue, and the sight be permanently destroyed. The eyes should always be protected by dark glasses, and no use of them whatever for near objects be permitted.

In retinitis exudativa, the deeper-seated or parenchymous form of retinitis, the ophthalmoscopic appearances of the eye are much more striking. The optic disc is reddish-gray, and its outline indistinct and irregular, so that it is almost impossible to find the line of demarcation between it and the retina. The arteries are more or less diminished in size, and the veins swollen and tortuous, and hidden here and there by extensive exudations of a whitish or grayish color, and blood extravasations are seen in various parts of the retina. The above is an ophthalmoscopic picture of a pathological condition in which the inflammatory condition of the retina has produced hypertrophy, stasis, proliferation of cells, colloid or fatty degeneration, and sclerosis; of course the ophthalmoscope will not afford so complete a picture as the above in all cases of the kind, but I have observed, on more than one occasion, appearances almost exactly corresponding to those described. Even in cases nearly like the above, the blood stasis is sometimes relieved, the exudations and extravasations absorbed, and the patient may regain considerable vision to remain permanently. This, however, is by no means the usual course. It more frequently ends in atrophy of the

retina and optic nerve. Vision during the progress of the affection is often tolerable until the region of the macula lutea is invaded. *Micropsia* is often noticed,—that is, all objects appear smaller than they really are. If you ask the patient to draw a given circle, he invariably draws it smaller than the reality. This is the result of a derangement in the position of the percipient elements of the retina. When an exudation separates these elements so that there are fewer of them in a given space, objects appear smaller; on the other hand when an atrophy leads to greater approximation of these elements so that there is an increased number within a given area, we have an enlarged image of objects or *macropsia.*

The Cause and Treatment.

The cause is frequently a neglected hyperæmic condition of the retina and optic nerve, disease of the heart, of the abdominal viscera, pregnancy, Bright's disease, diabetes, syphilis, or cerebral affections. The treatment should be directed to the removal of the cause, when this can be ascertained. When of syphilitic origin, the treatment will be more apt to result favorably than in cerebral or Bright's disease. Mercury should, I think, be relied upon to meet the retinal indications in this form of the affection, and arsenic and zinc for the nephritic variety, using such other remedies temporarily as the state of the patient's health or any special symptoms may require. See Chap. XXI. Hygienic rules should receive the greatest attention, and the eyes *must always be protected from bright light,*

by the use of colored spectacles. With the wisest treatment in every respect, the result will often prove unsatisfactory.

BRIGHT'S DISEASE, OR RETINITIS ALBUMINURICA.

The ophthalmoscopic appearance of the eyes in Bright's disease does not differ very much from that already described, except at a later stage of the affection, when we sometimes find around the optic disc a broad, white ring, and in the region of the macula lutea small stellated white spots, which are later

FIG. 48.

merged in the general exudation. Fig. 48, after Von Jaeger, represents nearly such a picture as seen with the ophthalmoscope.

The pathological changes are principally the serous infiltration of nerve and retina, — the fatty degeneration making the white patches, hypertrophied and sclerosed nerve fibres, giving rise to a striated appearance

of the fundus under the ophthalmoscope; capillary hemorrhages, due either to disorder of the circulation from hypertrophy and dilatation of the left ventricle, which is almost always present in Bright's disease, or to disease of the coats of the vessels.

Sight is very much impaired, although the extent of the field of vision is not limited greatly. Certain portions of the field are generally faulty, and of course vision is rarely very acute. Sudden amaurosis is liable to occur in this disease from uræmic poisoning. The patient becomes suddenly blind, and suffers from

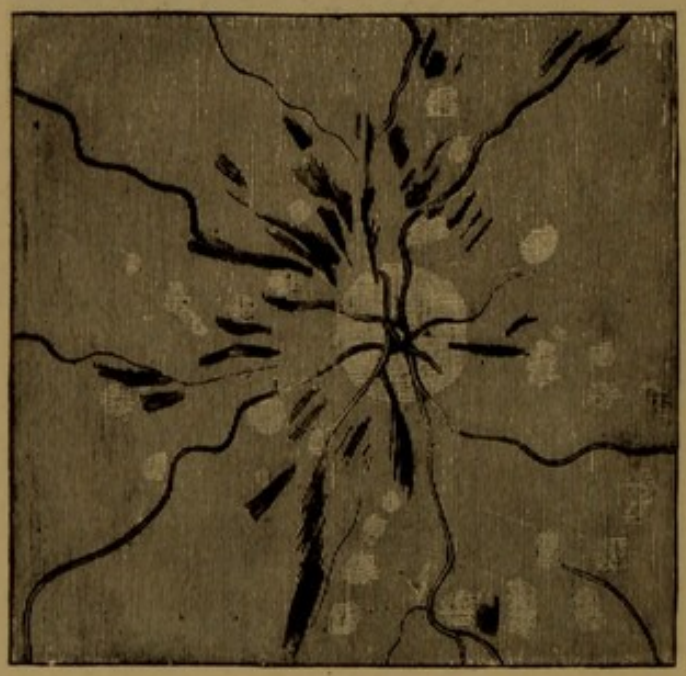

FIG. 49.

headache, vertigo, sickness, convulsions, and other general symptoms of uræmic poison.

Fig. 49, after Gowers, shows the results of very severe retinitis.

Why disease of the retina and kidney so uniformly coexist is not known. It has happened not unfre-

quently that failing sight, with the consequent ophthalmoscopic examination of the fundus of the eye, has led to the detection of disease of the kidney, confirmed by later microscopical examination of the urine. As a rule, nephritic retinitis does not lead to complete loss of sight; but normal vision, in cases of any severity, is not always regained. The amount of vision retained will finally be determined by the extent of disease of the nervous structure of the retina. If this has been great, it may lead to atrophy and blindness. The prognosis is, of course, most favorable in albuminuria after fevers or in pregnancy. The treatment, as far as the eye is concerned, will be merely hygienic, and medication must be directed to the cure of the primary seat of the disease, — the kidney.

SYPHILITIC RETINITIS, OR CHOROIDO-RETINITIS,

does not present so characteristic a picture for the ophthalmoscope, and the history of the case with the constitutional symptoms sometimes require to be consulted before the diagnosis is rendered certain. The appearance of the fundus is striated, and similar to that in retinitis albuminurica, but not so well marked. The stellated spots in the region of the macula lutea appear and disappear rapidly, and the vision improves and retrogrades correspondingly. Extravasations of blood are not usually noticed. *The pathological changes* are serous infiltration of the retina, inflammation and degeneration of the choroid, but fortunately the nervous structure of the retina is less apt to be impaired, and our prognosis is therefore favorable, and especially so

if the disease comes early under treatment. The disease is usually coincident with the constitutional symptoms of secondary syphilis, and the treatment must be directed to the removal of the constitutional affection. The retinitis progresses very slowly, and the patient is often troubled by relapses. Micropsia and marked night blindness are observed, and later a diminished field of vision. The choroid is usually involved, and the treatment recommended for choroiditis will generally be applicable in this form of retinitis.

IN RETINITIS APOPLECTICA OR HEMORRHAGICA

there is great tendency to extravasations of blood, which are sometimes so extensive as to hide partially the vessels of the retina, and the infiltrations are slighter, and serous in character. The sight is not so much impaired as the ophthalmoscopic appearance of the eye would indicate, unless the hemorrhage is situated about the yellow spot. The disease shows great tendency to relapses, and if hemorrhages recur often, and are at all extensive, our prognosis is not so favorable as otherwise. Apoplexy of the retina is caused by disturbances of the general circulation, frequently due to tumors within the orbit or cranium, or to thrombosis of the central artery of the retina. Hypertrophy of the left ventricle, or disease of the aortic valves, is not unusual in such lesions. It would be very difficult to state the precise treatment to be adopted in these cases. The general health should be made as perfect as possible, and the patient should, of course, be scrupulously correct and regular in his habits. Further

than this, the general aspect of each case must determine the course to be pursued in regard to medicine, diet, change of air, climate, and the like.

RETINITIS PIGMENTOSA, NIGHT BLINDNESS, TWILIGHT BLINDNESS, NYCTALOPIA,

as its names indicate, is an inflammation of the retina characterized chiefly by great pigmentation. The ophthalmoscope reveals the retina covered by large linear or reticulated irregular patches of pigment, more at the periphery of the fundus where the deposit commences first. Later, there is pallor of the optic disc, diminution of the retinal vessels, and frequently posterior polar cataract. It usually affects both eyes.

The striking subjective symptom in this affection is night blindness. This is the result of a torpid condition of the retina, produced by the insufficient supply of blood through the narrowed vessels, in consequence of which the retina requires a bright light to receive the impression of objects. This disease must not be confounded with a functional disorder of the retina called hemeralopia, or night blindness, mentioned under Amblyopia. The field of vision is often very much diminished in extent, so that while in a direct line one may



FIG. 50.

Extreme contraction of the visual field in a case of retinitis pigmentosa. The dark part represents that part of the field in the right eye which has been lost.

still read fine print, all around may be involved in darkness. In such event it may be difficult for a patient to find his way about. See Fig. 50. The disease is generally congenital, or hereditary, and sooner or later leads to blindness. Exceptionally, however, a certain part of the sight is retained. I have had a case of this disease under observation for twenty years. The man reads coarse type as readily as he did twelve years ago. Apparently the disease does not progress in this instance. It often occurs in marriages of consanguinity and with deaf-mutism. Treatment can only be palliative, but this may possibly postpone blindness for years. The patient's general health should be kept in good condition, and above all, the eyes should be spared fatiguing occupations, and guarded from bright light and heat. There is sometimes a physiological pigmentation of the retina making an ophthalmoscopic picture not unlike the disease in question.

DETACHMENT OF THE RETINA

is occasioned by serous effusion between it and the choroid. It most frequently occurs in the lower half of the fundus, and commences at the periphery. With the ophthalmoscope we must look for it first by *direct examination.* The light need not be very strong. Notice that the bright red of the fundus is only seen at the upper part of the pupil; all below is dark; or perhaps you catch the illuminated part of the pupil only after directing the patient to turn his eye in different directions. Do not approach the eye too nearly,

and you will see by carefully regarding the unilluminated part of the pupil, and apparently almost in contact with it, a grayish-blue cloud which undulates with every movement of the eye. Fig. 51, after Von Jaeger, represents this condition as seen with the oph-

FIG. 51.

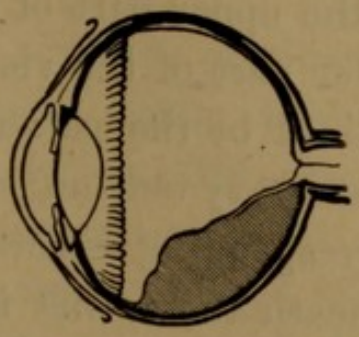

FIG. 52.

thalmoscope, and Fig. 52, from Nettleship, shows a sectional view of it. For lack of the simple precaution of using the *upright image*, and regarding the eye from the distance of twelve or fifteen inches at first, I have known an excellent ophthalmoscopist to overlook a large detachment of the retina. Once having made the diagnosis, we may examine the details with either the direct or reversed image. We find the floating opacity or retinal cloud crossed by dark, shrivelled, crooked vessels. Slight degrees of detachment of the retina are much more difficult to diagnose. This is sometimes best accomplished by beginning with a retinal vessel at the optic disc, and following it towards the periphery, where we may detect a change to a darker color, and a tortuousness in its course; and we make out at the same time a slight fold in the retina.

Vision is, as a matter of course, very much impaired.

That portion of the retina separated from the choroid by serous effusion no longer performs its function; but the part which maintains its connection with the choroid performs its function as usual. Hence it happens that the upper part of the field of vision is entirely obscured, or, if the detachment happen to have occurred in the upper part of the fundus, the obscurity is in the lower part of the visual field. Impaired vision is first noticed by the patient as a delicate cloud with indistinct wavy outline, at that point in the field of vision corresponding exactly to the situation of the effusion beneath the retina in the fundus. Linear objects appear wavy and broken, due, probably, to the disturbed connection of the retina at the edge of the detachment. There is often night blindness and sometimes a tendency to confuse the colors blue and green.

The cause of the disease is sometimes difficult to determine. It is frequently occasioned by a blow on the eye. In a patient of mine, during the past year, it could be traced directly to a fall a few months previous. It may be due to hemorrhage in disease of the choroid or retina. The commonest cause is, perhaps, a shrinking of the vitreous, which, dragging on the retina, causes a rupture, thus permitting the fluid of the vitreous to pass behind it.

The prognosis is unfavorable, as the separation generally goes on until the eye is rendered blind. Fortunately it is, in a vast majority of instances, confined to one eye. Sometimes, however, the disease ceases to progress after reaching a certain point, and the sight may improve; and if the detachment is not too exten-

sive, sight may be wholly restored through the absorption of the exudation, and reunion of the retina and choroid. The medical treatment is to be directed to the improvement of the general condition of the patient. Surgical treatment has as yet been of no avail.

GLIOMA RETINÆ

is the name given by Virchow to a tumor originating in the retina, and occurring mostly in young children, known generally by the name of encephaloid disease or fungus hæmatodes. In the commencement of the affection, the eye appears healthy externally, and there is no pain. The pupil is, however, more or less dilated, and the sight of the eye is gone. The disease is diagnosed with the ophthalmoscope at this stage; a circumscribed portion of the retina is mottled, opaque, and thickened in appearance. Soon the growth protrudes as a yellowish-white mass into the vitreous humor, and its vascular character in all its detail is observable. Rapidly now the growth increases, pushing before it the lens and iris, augmenting the intraocular pressure and pain, the cornea or anterior portion of the sclera bursts, and the tumor increases still more rapidly. It assumes later a dark hue from exposure to the atmosphere, exudes a sanious fluid which becomes incrusted on its surface, and bleeds easily.

The prognosis is always grave, and especially so if the disease is in an advanced stage. If the patient is seen early, the eye should be immediately enucleated; as cases are recorded where, after the lapse of several years, the disease has not returned. The optic nerve,

in performing the operation, should be excised far back near the optic foramen, so as to include the whole of the diseased portion, if possible. Even after the tumor has burst through the eye, an operation will give the only chance of prolonging life, and will certainly alleviate a great amount of suffering. The tumor breaks through, and appears externally in from one to three years from its commencement.

The cause of glioma is often very obscure. It occurs most frequently in children from two to ten years old. It is sometimes complicated with cerebral disease, as evidenced by headache, drows ness, stupor, or paralytic symptoms. It is often hereditary. I have seen two of four children of the same mother affected by it.

Ischæmia retinæ, so called, is an extremely anæmic condition of the retina, which is notably of rare occurrence, and has been cured by removing the intra-ocular pressure by paracentesis of the cornea or by an iridectomy.

Complete paralysis of the retina and total blindness have been observed after blows, and after a stroke of lightning. The ophthalmoscope does not always reveal the great change which one might expect to find under such circumstances.

Embolism of the central artery of the retina is a rare disease. I have had but three cases in my own practice. The loss of sight is sudden and almost total. The ophthalmoscope shows at first, a hazy fundus especially at the macula lutea; but just at the centre of this region a small red spot is frequently seen; later there is a pale optic disc, transparent however, and the

vessels running over it much attenuated. The arteries of the retina are very small, and partially bloodless, so that at certain points of their course they may appear like white threads. The veins of the retina present a somewhat like aspect, though less strongly marked. *Thrombosis of the artery* causes a similar appearance with greater tendency to hemorrhage. The disease is sometimes, but not uniformly, accompanied by valvular disease of the heart. Probably the class of remedies indicated in cardiac affections might frequently be of service in this disease. A few cases of cure by massage have been reported, but the prognosis is unfavorable.

OPTIC-NEURITIS (PAPILLO-RETINITIS).

Optic-neuritis, or *neuro-retinitis*, is a condition in which the optic nerve is the primary seat of the inflammation. This affection is often connected with disease of the brain. Not unfrequently the cause is cerebral tumor. Vision is generally greatly impaired, and, in a large number of instances, atrophy of the retina and optic nerve and blindness ensue. This sad termination, however, is not always certain. Even when the affection is cerebral in origin, the sight may remain unimpaired. A good prognostic symptom is afforded by testing the extent of the field of vision. If this is diminished in extent, we may expect more or less atrophy of the nerve. When the affection comes from the brain, there will usually be cerebral symptoms preceding, — such as headache, giddiness, vomiting, failure of memory, loss of taste, hearing, smell, convulsive or

paralytic attacks. In all cerebral fevers, optic-neuritis should be looked for with the ophthalmoscope, because it may exist for some time before vision is sufficiently impaired to direct our attention to the eye. In all suspected disease of the brain, of whatever nature, the ophthalmoscope should also be resorted to as an aid to diagnosis.

The ophthalmoscopic symptoms in the beginning are a hyperæmia and œdema of the disc, which is reddish,

Fig. 53.

its outline indistinct, and afterwards quite indefinable, loss of its transparency, while the effusion of lymph in the optic nerve gives it a striated and woolly aspect. The inflammation extends to the retina, rendering it hazy, its veins dark and tortuous, its arteries shrunken so as hardly to be visible, the vessels here and there hidden in their course beneath the infiltration. Around the disc are blood extravasations, and the exudations upon th disc itself are sometimes so considerable that

the vessels upon it are completely covered, and can only be traced to its margin, followed from the retina. Although both nerve and retina are usually involved, when the origin of the affection is cerebral, it is often more limited to the optic nerve, — a *papillitis* rather than a *neuro-retinitis*. Fig. 53, after Hughlings Jackson, shows a severe case of papillitis, and Fig. 54, from Nettleship, gives a nerve section of a similar condition.

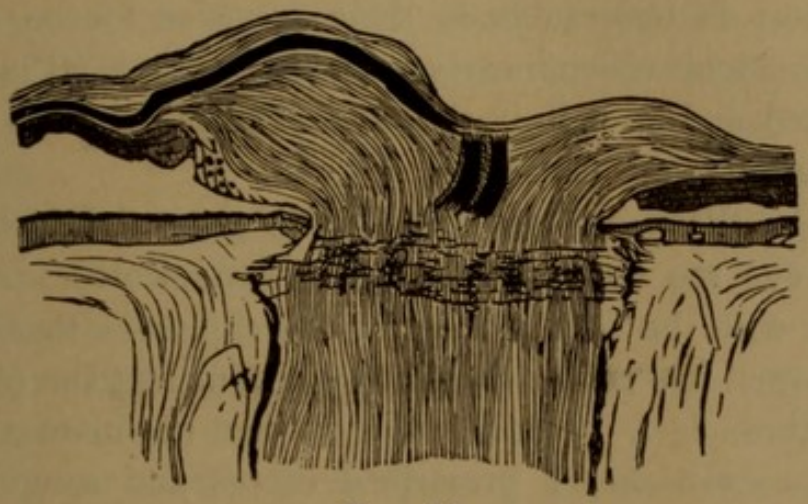

FIG. 54.

Section of swollen disc in papillitis, showing the swelling limited to the longitudinal nerve fibres, which are shaded. Compare Fig. 53, page 214.

The disease does not always, fortunately, present so unfavorable an aspect as this. In young and delicate females, for instance, it is much less grave usually; and the prognosis, when they come early under care, is more favorable. These cases are not cerebral, and indeed the patients are sometimes otherwise in good health. Often, however, there is general neurasthenia or menstrual disorders.

In a case of this kind under my care some years since, that of a young girl of seventeen, there were no catamenial troubles, but considerable spinal irritation in the region of the lower cervical vertebræ. She suffered also from congestive headaches in

the forehead and temporal region, general neurasthenia with perhaps slight attacks of hysteria. She was perfectly healthy looking, but not very robust. When she came to me, vision was very imperfect.

Jan. 5, 1867, she reads No. 8 print with the right eye, and only No. 13 with the left. There is hyperæmia of the optic disc in both eyes, and in the left fundus, the disc and its immediate vicinity are slightly obscured by a delicate reddish-gray haze. The pupils are abnormally dilated, but not much sluggishness is observable in their response to the action of light. Field of vision nearly normal in extent. Photophobia not marked, and no pain in the eyes. Belladonna and mercury, in alternation, were prescribed.

Jan. 24. Patient about the same in general health. Sight of right eye the same; of the left, a little worse. Acuteness of vision with the best eye about one eighth, — that is, print that a normal eye could read at twenty-four feet she could only read at three feet. Partly owing to her obstinate attacks of congestive headache, I prescribed cactus and sanguinaria in alternation night and morning.

March 6. Her headaches are less frequent and violent, and her sight in the right eye has improved. Acuteness of vision about one quarter. The left eye is no worse; continued medicine.

March 27. Better; acuteness of vision three quarters. Left eye better.

May 17. She can read No. 1 test type with either eye. General health very much improved.

The cause of the disease in this case was very obscure. Her eyesight now, after twenty-three years, remains good.

A somewhat similar instance is the following: —

Miss A. G. S., Milton, Oct. 20, V. R. $\frac{10}{10}$, L. $\frac{10}{128}$. Left fundus hazy. The blindness has been noticed for two weeks. She is otherwise healthy, but had been over-using her eyes. Has slight headache. No menstrual disturbance. Slight tenderness over

the lower cervical vertebræ. Gave her gelsemium tincture five drops night and morning.

Nov. 9, 1887. Patient's condition about the same.

Nov. 23. Better, V. $= \frac{9}{60}$.

Dec. 15. Better, V. $= \frac{10}{30}$. Optic disc faintly visible. Eye more sensitive to light.

Dec. 31. Better, V. $= \frac{10}{20}$.

Jan. 9. Better, V. $= \frac{10}{15}$, optic disc tolerably clear in outline but slightly pale. There is decidedly more retinitis than papillitis. A spot of fine pigmentation between the disc and macula. Micropsia. Objects at ten feet appear one half their real size.

Feb. 17. V. $= \frac{10}{12}$. Objects appear about two thirds their proper size.

Mar. 8. V. $= \frac{10}{10}$ nearly. Micropsia is passing away.

April 24. V. same, but eye can only be used for a short time. No micropsia.

June 15. Eye is getting stronger but the fine pigmentation of the retina remains.

I could form no idea of the cause of the disease in this case.

In most cases of neuro-retinitis, however, the prognosis should be very guarded. It will be most favorable, of course, when the affection can be traced to disorder of the uterine or some other important function that admits of a cure, and also in cases that supervene on convalescence from febrile disorders, especially if in these instances the ophthalmoscope does not show great or dangerous change of appearance in the optic nerve or retina. *Neuritis descendens*, as it is sometimes called, when it arises from intra-cranial causes, generally terminates sooner or later in total blindness. Generally speaking, it has been noticed that when the progress of the disease and loss of sight have been rapid, the prognosis is more favorable than when the

progress and loss of sight have been gradual. In relation to the medical treatment, it must of course vary according to the cause, the general health of the patient, and the exigencies of each individual case. Other things being equal, I should expect mercury, iodide of potash, and phosphorus to be oftener useful than belladonna, conium, nux vomica, and gelsemium.

Retro-bulbar neuritis is a milder disease in which slight or no change in the optic disc is observed; but there is a more or less distinct central scotoma, such as is observed in toxic amblyopia, to which the affection bears a strong resemblance. The prognosis is comparatively favorable. (See Knapp, Arch. Oph., Jan., 1891.)

ATROPHY OF THE OPTIC NERVE.

A marked symptom of this disease, noticeable at a glance, is the dilated and sluggish pupil, and generally, when the eye is quite blind, its almost complete immobility. Exceptionally, the pupil retains its activity, and, in spinal amaurosis, it may even be contracted and unequal in the two eyes.

The ophthalmoscopic appearances of the fundus are very characteristic. The nerve disc is pale, from the attenuation or disappearance of the small nutrient vessels on its face; there is bluish or bluish-green discoloration, especially seen in spinal atrophy; the transparency of the disc is lost, but though opaque, its outline is distinct (see Figs. 55, 56, after De Wecker); the retinal vessels are generally diminished in size, notably the arteries; and there is frequently an excavation of the optic disc. This excavation must be dis-

tinguished from a very slight physiological one which is congenital and often seen in the normal eye, situated at the centre, or a little towards the temporal side of the disc. In the physiological excavation, of course, none of the symptoms of atrophy above-mentioned obtain, the nerve being in its normal condition. In the atrophic excavation, which is shallow, its edges are gradually sloped, quite unlike the abrupt margin of the glaucomatous excavation. See Figs. 39 and 41. Hence the retinal vessels, in passing into the cavity from the

FIG. 55.

Atrophy of disc from spinal disease. The lamina cribrosa not visible.

FIG. 56.

Simple atrophy of disc. The stippling of the lamina cribrosa is exposed.

normal surface of the disc, do not appear under the ophthalmoscope as if displaced, as in glaucoma, but describe simply a curve. Sometimes in the physiological excavation this curve may also be abrupt enough to give a vessel the appearance of displacement.

The patient's sight is more or less impaired, the field of vision contracted, and the color sense is deficient. In secondary nerve atrophy, already spoken of as due to cerebral or spinal disease, retinitis, etc., we sometimes find the affection a sequel of *hemianopsia* that

is, a loss of half the visual field in each eye. The affection is sometimes associated with hemiplegia. Usually the loss is equilateral at the nasal half of one eye and at the temporal half of the other. See Fig.

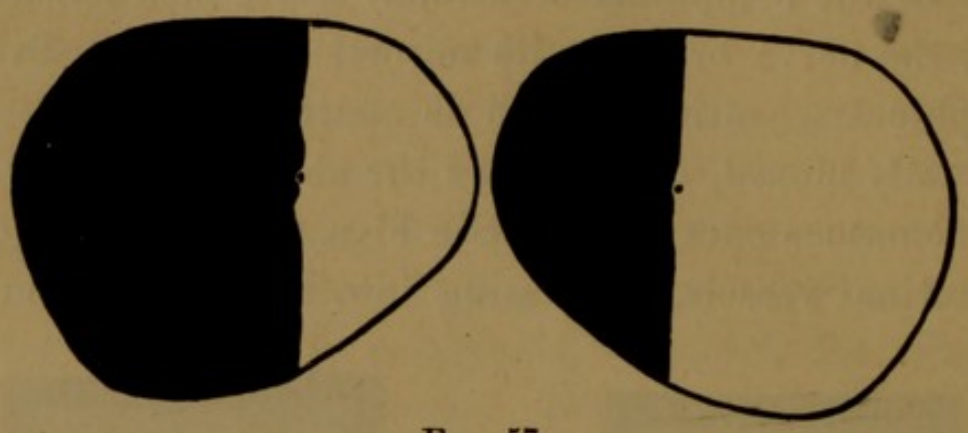

FIG. 57.

57. This condition is the more favorable for recovery. More rare is the loss of the two temporal halves of the retinæ; the loss of the two nasal halves is exceedingly rare, and leads to complete atrophy of the nerve. I once had a case when the field of vision was wanting in both upper halves. It must be remembered that the optic nerve fibres decussate at the optic commissure, so that the right nerve passes partly to the temporal or right side of the retina of the right eye, and to the nasal or right side of the retina of the left eye, while the left optic nerve supplies the left half of the two retinæ in a corresponding manner. Now, if the temporal side of each field of vision is limited, the disease must be seated at the commissure, and this augurs a bad termination. Blindness often comes on very rapidly. But if the field of vision is contracted equilaterally, total blindness is pretty certain not to ensue, indeed rarely or never occurs, unless the disease

extends afterwards to the commissure, or some new cerebral symptoms manifest themselves.

THE CAUSE OF PRIMARY ATROPHY

is sometimes obscure, but disease of the spine, notably locomotor ataxy, is not an uncommon cause. The prognosis is bad. In the secondary form the prognosis is, as we have seen, somewhat better. Sudden accession of blindness is not to be considered an unfavorable symptom, especially in children. It is favorable if the disease remain stationary for a considerable time, and bad if it manifest a slow, but certain progress. If the visual field is not contracted after the affection has continued for some time, it is a favorable sign, as is likewise the fact of the line of demarcation between the good and bad of the field being very distinct. Irregular contractions of the visual field occurring simultaneously, or in quick succession, in both eyes are unfavorable. Central scotoma are unfavorable if the visual field is much contracted, otherwise not. When the field of vision beyond the scotoma is impaired, it shows a lack of the power of transmission on the part of the retina, and progressive atrophy is to be feared. All auxiliary or accompanying symptoms are of great importance, because it is quite impossible to decide from the appearance of the optic nerve alone, if in many cases the atrophy be progressive or stationary. The medical treatment must differ so much in different cases that I do not know that I can do more than refer the reader to the indications and remarks in regard to treatment made under the head of Neuritis Optica.

CHAPTER XII.

AMBLYOPIC AND OTHER AFFECTIONS.

AMBLYOPIA.

THIS term, strictly speaking, is limited to those cases of imperfect vision in which the affected eye presents no recognizable objective symptoms, with or without the ophthalmoscope, and in which the impaired vision is not due to anomalous refraction, as in hypermetropia, myopia, and astigmatism.

In a general way, the term amblyopia is used to express impaired sight from any and every cause except that of optical defect. Thus we say, if we find that no glasses improve the acuteness of vision, that the patient is amblyopic, — meaning by the remark nothing more definite than that the blindness is not to be attributed wholly to abnormal refractive power, and that some disease of the fundus of the globe is present.

DIAGNOSIS OF AMBLYOPIA.

A simple, practical, and quite reliable method of diagnosing amblyopia, as well as impaired vision generally, is by the simple device of permitting the patient to look through a large pin-hole in a blackened card. *If this improves vision*, refraction is faulty, and will be corrected by suitable glasses. If vision *is not improved*,

the loss of visual power must be sought in some of the inner structures of the eye, and an ophthalmoscopic examination will be necessary. Of course nicer methods than this to determine faulty refraction, when the requisite concave and convex glasses are at hand, are those mentioned in the chapter on Anomalies of Refraction; but the requisite glasses are frequently not at hand in the office of the general practitioner, and the above test of Giraud Teulon will prove very convenient.

Thomson shows how this test may be made to indicate the exact nature of a case of anomalous refraction. In looking through the pin-hole at a gas-light at twenty feet distance, if the eye is ametropic (of defective refractive power), when the card is moved rapidly before the eye, the light will seem to dance. If the eye is emmetropic, the light will remain steady. In testing the eye of a patient in this way I found that the dancing of the light was removed by permitting him to look through No. 16 concave glasses, — those appeared to render his eye emmetropic. His eye was myopic $\frac{1}{16}$. In another instance the light danced when the card was moved up and down, but not when it was moved horizontally. This indicated ametropia in the vertical meridian, and it was found by trial that a concave cylindrical glass, No. 36, the axis horizontal, remedied the defect. The case was one of simple astigmatism. With two pin-holes, one eighth of an inch apart, in the card, an emmetropic eye will see one light, an ametropic eye, two. In myopia, the second image will be at the right, in hypermetropia, at the left. In the case of the myope just mentioned, by covering one of the

pin-holes with the red glass, he saw the red flame about eight inches at the right of the yellow, at a distance of forty feet. Through his No. 16 concave glass the red and yellow flames were one. In the case of astigmatism mentioned above, with the two holes held one above the other, at a distance of forty feet, he saw the red flame about four inches above the yellow. His cylindrical glass nearly fused the two images. In determining a hypermetropia by this method it will frequently be necessary to first paralyze the accommodation with a solution of atropine. An emmetropic eye may easily be made to test the correctness of these various methods by placing before it a convex glass which renders it myopic, or a concave glass when it becomes hypermetropic, or a cylindrical glass which renders it astigmatic.

CAUSE AND TREATMENT OF AMBLYOPIA.

Temporary congestion of the brain and nervous structure of the eye may be occasioned by suppression of exhalations from the skin through exposure to the cold or wet, by suspension of the catamenia, and by large doses of quinine or other drugs, the result of the congestion being dimness or entire suspension of vision. The reverse of this, a diminished supply of pure blood to the brain and retina, will also produce amblyopia. This enfeebled condition may be due to severe illness, excessive drain on the system through hemorrhage, uterine discharges, gestation, infant nursing, and like debilitating causes.

In such instances of impaired vision we should not

neglect an ophthalmoscopic examination. Our prognosis will be uncertain unless we can first establish a correct diagnosis. This cannot always be done, but it can often be done. The fact that the ophthalmoscopic examination frequently yields but negative results is of itself a favorable omen for the prognosis. Sometimes the examination of the interior of the eye reveals enough to make the future of the patient extremely doubtful. A few days since a case of amblyopia from pregnancy at the eighth month was sent to me, and on examination I found an optic neuritis with considerable effusion in the retina. The prognosis needs to be extremely guarded in such instances. Less perceptible changes than this in the fundus of the globe are followed by permanent impairment of vision. A number of cases have been published in which the blindness of pregnancy has terminated unfavorably.

We have many remedies suitable for congestion of the nervous tunic of the eye, — such as cactus, belladonna, sanguinaria, phosphorus, glonoine, and others. Hot pediluvia are sometimes serviceable, and the judicious use of the Turkish bath will benefit disordered functions of the skin. That the Turkish bath will also diminish the flow of blood to the brain has been proved by ophthalmoscopic examination made before and after the bath.

In those cases clearly due to an impoverished state of the blood, iron, arsenic, and other remedies will be indicated; but in addition to the appropiate medicines, a nutritious diet and sufficient rest and sleep should be prescribed. Hemorrhage and all unusual

drains on the vitality of the patient must be controlled before improvement can be looked for.

Blood poisoning, from drugs like lead, and narcotics like alcohol and tobacco, will produce amblyopia. Total abstinence from alcohol and tobacco would seem to be the only course for such as cannot draw the line between a stimulating and narcotizing use of these substances. Drug poisoning requires a specific line of treatment for each case; lead poisoning is said, recently, to be successfully treated by opium, through the hypodermic injection of morphia. Amblyopia may be the direct result of blood poisoning, but even in blanching and apparent atrophy of the optic nerve, a very grave symptom indeed, there are many cases recorded in which a more or less perfect recovery of vision is known to have taken place after the lapse of months or years of blindness. Quinine blindness, as well as deafness, is quite common. It often passes off rather slowly and exceptionally impairs the sight permanently. Salicylic acid has also caused amblyopia.

Dental neuralgia sometimes impairs vision, through reflex irritation from a branch of the fifth nerve. Removal of the offending tooth generally cures.

Tobacco amblyopia is a form of blindness now well recognized. There is a central scotoma, a blind or partially blind region in that part of the field, usually, which corresponds to the portion of the retina between the optic disc and the outer margin of the macula — the papillo macular bundle of nerve fibres. The scotoma is more defective as to color than form. The treatment in such cases is, of course, to enforce entire

abstinence from the use of tobacco, and then to look after the general health. Iodide of potash, as well as the hypodermic injections of strychnia are reported serviceable in nearly all forms of toxic amblyopia. My experience leads me to believe that *any* remedy, not of itself hurtful, will, at first, improve a nerve lesion, apparently; later the improvement ceases. I suppose such improvement is due to suggestion.

Temporary, and indeed persistent, amblyopia is sometimes due to disorders of digestion from impaired functional or other disease of the stomach or liver. These affections cause, through the medium of the sympathetic nerve, some disturbance in the nervous structure of the eye whereby vision is impaired. The same effect is produced on the sight, occasionally, from nervous or other apparently slight affections of the uterus. In fact, reflex disturbance of vision may in some instances be due to irritation of any part of the system, internal or external. In such event, especially if the ophthalmoscope shows no changes in the interior of the eye sufficiently marked to account for the visual disturbance, the treatment must be directed chiefly to the removal of the extra ocular lesion.

SIMULATION OF BLINDNESS

in one eye, by nervous or hysterical persons, by conscripts or prisoners, is readily detected by holding the finger or a ruler midway between the eyes and the print while the patient reads. If the patient sees with only one eye, vision will be interrupted, if with both, not. If this is not wholly satisfactory, by moving the ruler

slightly from side to side so as to cover each eye in alternation, any further simulation of blindness will generally be detected. The deception may also be shown by means of a prism, base inward or outward, before the normal eye. If there is a corrective squint or change in the direction of the eyes as the prism is removed, binocular vision is proved, or the base of the prism being upward or downward, if the patient sees double, binocular vision is certain. The stereoscope may also be used as a test, as binocular vision is requisite in order to appreciate its effects. Simulation of blindness *in both eyes* may sometimes be detected by observing the action of light on the size of the pupil. Mobility of the iris under the stimulus of light is a tolerably sure indication of sight in one or both eyes. Still, this test is not absolutely conclusive, and a bilateral simulation of blindness may prove difficult to detect.

HEMERALOPIA, OR IDIOPATHIC NIGHT BLINDNESS,

is generally considered a purely functional disease of the retina, in which no changes are observable with the ophthalmoscope. It is an affection confined in its origin almost wholly to warm climates, and will be remembered as one from which our soldiers on duty in the extreme South suffered considerably. Sailors in tropical regions are also frequent sufferers. The distinguishing characteristic of the disease is, a torpor of the retina, so that a bright light is required in order to stimulate it sufficiently to receive distinct impressions of objects; hence by night the patient's sight is unusually bad. The time of the day has no signifi-

cance, such as the name of the affection would indicate; for by a bright artificial light, he sees as well by night as if no affection of the eye were present.

The cause of the disease is exposure to glare of light, and impoverished condition of the blood. Both these conditions are present with our soldiers and sailors in warm latitudes. It is often met with in conjunction with malarial fevers, and the ill-fed and ill-housed peasants in the south of Europe and in Central America are subject to it. Sailors afflicted with scurvy are often subject to it.

The treatment is very simple and efficacious. Rest, protection of the eyes from bright light, such constitutional remedies as are necessary for the restoration of the general health, or change of climate, generally cure speedily. In Italy, where the affection is quite common, a popular remedy among the people is fumigation with the vapor from the liver of a sheep or other animal. Quaglino and some others have observed symptoms of retinitis in the ophthalmoscopic appearance of the fundus of the eye in this affection. Night blindness is a prominent symptom also of the disease called retinitis pigmentosa. In this affection the field of vision becomes limited, a subjective symptom which is not often observed in idiopathic night blindness.

COLOR BLINDNESS

is sometimes congenital. In these cases there is usually an inability to distinguish the shades of red, and red from its complementary color, green. Green-red blindness is also a symptom noticed in atrophy of the

optic nerve. *Achromatopsia*, inability to distinguish all colors, is usually due to disease of the optic nerve or optic nerve and retina. It has been noticed also as a symptom of myelitis.

The diagnosis by the Holmgren method is simple and can be carried out by any physician who will take the trouble to provide a plentiful collection of small skeins of worsteds, about one hundred in number, of the primary colors and their different shades. A skein of light green, for example, is selected from the mass of colors, and the patient is asked to select other shades that appear to him the most like it in color. If he hesitates and selects finally grays, neutral tints, light browns, etc., he is color blind for green. Given a light purple or rose-colored sample, if he matches it with light greens, grays, and light reds, he is red-blind. Blue-yellow blindness is very rare, and congenital total color blindness is also rare.

HYPERÆSTHESIA RETINÆ, OR RETINAL ASTHENOPIA

is characterized by severe photophobia, lachrymation, and all the symptoms of an irritation of the ciliary plexus of nerves. There are no ophthalmoscopic changes observable in the fundus of the globe. In cases which have come under my care there has been, uniformly, dilatation of the pupil. The sight is good in a diminished light, but the field of vision is usually somewhat contracted. It occurs mostly in young females in delicate health, of irritable nerves, hysterical, and suffering from catamenial disorder. The disease of the nervous structure of the eye is but an indication of the state of

the nervous system generally, and the treatment must be directed to the removal of the constitutional symptoms. I have found quite a variety of remedies necessary in different cases, and sometimes in the same case. Of course errors of refraction must be corrected by proper glasses, and then the indications are to restore the general health by such treatment as may be necessary. If *photophobia* be present, colored glasses should be worn in the open air, and it may be necessary to moderate the light to a certain extent in-doors. I have never yet found it necessary to confine persons for days in complete darkness, as has been practised and recommended. Indeed, it has seemed better to encourage the patient in attempting to accustom the eyes gradually to the daylight, as the general health is improved. The strong light is unpleasant rather than injurious. I never hesitate to use the ophthalmoscope freely in these cases, throwing a strong light directly into the eye. No sensitiveness whatever is noticed under the examination after the first few seconds, and I never heard of any after ill effects.

Anæsthesia retinæ is an affection produced by exposure of the eyes to extremely bright light for a long time. *Snow blindness* is a form of this disorder, and it is frequently brought on by continued application of the eyes under strong artificial light. The blindness takes the form of a cloud before the eyes, and may be of only short duration, or may continue for weeks. I was the subject of a similar affection myself during the past summer. After gazing out upon the ocean from a pleasant window for an hour, on going down on to the green

lawn I found that the grass appeared to be veiled by an exceedingly delicate blue haze. My friends declared that no such haze existed, and after a few minutes' rest, I saw no more of it. Many cases of this kind are more serious than this. The symptoms when severe are similar to those mentioned below under the effects of electric light, and may require for palliation a prolonged exclusion of the eyes from light, soothing application to the lids, and general constitutional treatment; but in the end there is complete recovery.

AFFECTIONS OF THE EYES FROM EXPOSURE TO THE ELECTRIC LIGHT.

Exposure to electric light may be productive of a severe affection, but is ordinarily not very serious in character, nor of long duration. There is lachrymation, ciliary irritation, slight swelling of the lids and of the ocular conjunctiva, and slight sensitiveness of the retina to light. These disturbances generally disappear in a few days. In severer cases the retina suffers more; there is a central scotoma and intense photophobia, together with the other symptoms common to the less severe form. Such attacks usually pass off in a few days, but occasionally a longer time is necessary for the restoration of the normal functions of the retina, as is shown by a case under my care last year. A woman of fifty, of neurotic tendency and impaired vitality, had exposed her eyes for several evenings to the glare of an arc light in the street opposite her window. I saw her three weeks after the exposure, on April 8th. There was severe photophobia, relative central scotoma, slight

chromatopsia, photopsia, accommodative asthenopia, and inability to distinguish fine print. The pupils were oval, vertically, and V. R. was $\frac{10}{15}+$; L. $\frac{10}{15}$. Field of vision not contracted. Ophthalmoscopic signs wanting. Rest of eyes, colored glasses, and care of general health by her physician, were prescribed.

May 3. Not much change.

June 3. Better; reads with + 2.50 D.

July 1. V. $\frac{10}{10}$ — O. U.

Nov. 13. General health good. Photophobia still, but it is now quite slight. V. = $\frac{10}{10}$, but she does not read No. 1 print quite as readily as formerly.

In this instance some seven months were required to restore the sight to its normal condition.

The irritation of the electric light on the eye is due to direct exposure, and is produced by the action of the chemical rays. (Widmark, Oph. Review, Vol. VIII. p. 172.)

HYSTERICAL AMBLYOPIA.

This disorder of sight, so far as symptoms are concerned, is nearly allied to anæsthesia and hyperæsthesia of the retina, and is seen in those suffering from functional or other nervous disease. There may, however, be a multitude of other symptoms than those mentioned under the above diseases. Sudden and complete blindness may occur, and as suddenly disappear. Or there may be central scotoma, or hemianopsia; and there is sometimes a strongly abnormal color sense.

The treatment of these cases is often tedious, partly from the fact that often no adequate cause can be dis-

covered to account for the condition, and partly from the fact that the nervous or mental state of the patient makes any treatment precarious and dependent. Every kind of treatment is accredited with having cured these cases: drugs by the score, hypnotism, faith cure, mind cure, metallotherapy, etc. My limited experience in the treatment of these cases is not clear enough to warrant special advice. The prognosis is good.

NEURALGIA OCULI

is usually associated with, or is merely a symptom of, a disease of the eye such as iritis, choroiditis, glaucoma, or some other affection, the treatment of which has been already indicated. In hysteria, it is but a phase of the neuralgias common in that disorder of the nervous system, and can only be cured by restoring the general health of the patient. It may be relieved by such measures as are recommended for ciliary neuralgia. I have on one occasion cured such a neuralgia in two or three minutes by the instillation of a drop of cocaine into the affected eye; and only one instillation was necessary.

CHAPTER XIII.

THE CRYSTALLINE LENS.

CATARACT.

CATARACT is an opacity of the lens, its capsule, or both lens and capsule, and may therefore be called *lenticular*, *capsular*, or *capsulo lenticular*.

DIAGNOSIS.

The subjective symptoms are dimness of vision, in proportion to the age or density of the opacity, which increases gradually, except in traumatic cataract when it may be sudden, and in congenital cataract. The patient sees better generally in a dim light; because, the pupil being larger, a portion of the lens from the centre towards the periphery is uncovered, and this part of the lens is usually clearer than the centre. For the same reason the instillation of atropine improves vision somewhat. The first symptom usually noticed by the patient with beginning cataract is, that distant objects appear slightly hazy, or as if surrounded by a halo; afterwards, as the cataract develops, vision for near objects is similarly impaired.

Objective symptoms. The pupil is generally normal in size and movement. The vacant look, rolling of the eyes, and tendency to look upward of amaurosis are

not present. The patient is inclined to look downward, and is able usually to fix the eyes on objects. If the affection has made considerable progress, a gray opacity is at once noticed *exactly* filling the area of the pupil,

FIG. 58.

Nuclear cataract. — 1. Section of lens. 2. Cataract as seen with ophthalmoscopic mirror. 3. Cataract as seen by lateral illumination.

the opacity being sharply limited by the pupillary margin. A corneal opacity may hide a portion of the iris, but a lenticular opacity can only obscure the pupil. The pupil should be enlarged with atropine, and the eye examined by oblique or lateral illumination.

Examination by lateral illumination enables us to determine the extent and nature of the opacity, whether complete or ripe, its color, its formation, whether nuclear or striated, and other details.

Direct examination with the ophthalmoscope is chiefly serviceable in detecting slight and beginning opacity of the lens, which would otherwise escape observation. The light should not be very strong, and the eye of the observer should be twelve or fifteen inches from that of the patient. There may be a general, but very slight, cloudiness of the whole lens, or the nucleus alone may be obscure (Fig. 58, after Nettleship), or delicate striæ may be seen running from the periphery towards the centre of the lens, as in Fig. 59 (Nettleship). These opacities will appear black instead of

grayish, as in the lateral examination. Beginning cataract may be confounded with separation of the retina, a fact which is noticed under Retinal Diseases. In cases where the cataract is dense or far advanced,

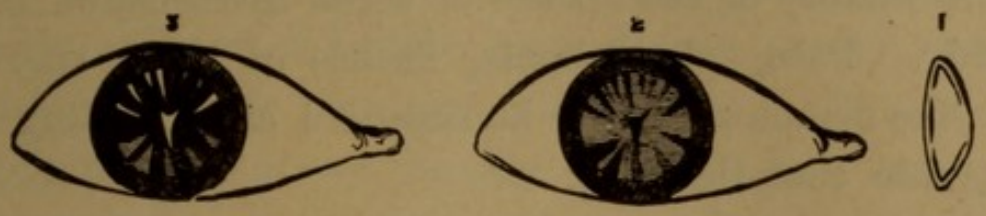

FIG. 59.

References as in Fig. 58.

the ophthalmoscopic signs are negative, as no light can be thrown into the eye.

COMPLICATION, WITH OTHER DISEASES OF THE EYE.

The most common complications are, —

The results of iritis,	Softening of the vitreous humor,
Choroiditis,	Sclerotico-choroiditis posterior,
Separation of the retina,	Amblyopia.

We may determine a complication or its absence, by testing the patient's visual power after the cataract is fully matured. He may be able to distinguish night from day, or the light from a window, and to note a hand before his eyes, even at a distance of three feet, and still we should not be justified in pronouncing the retina sound beyond a doubt. To render the absence of all complications sure, the patient should be able to discern a dim light in a darkened room at a distance of ten to fifteen feet. There should be no contraction of the field of vision, as tested by moving a lighted candle from one part of the visual field to the other. The patient's

eyes should be fixed on his finger at the distance of a foot during this test, and the candle should be shaded while its position is being changed; the tension of the eyeball should be noticed, and in cases of doubt, the whole history of the failure of sight investigated thoroughly. Pain, photophobia, flashes of light, spectra, and like symptoms are to be regarded as indicating unfavorable complications.

THE CAUSE OF CATARACT

is probably faulty nutrition of the lens. This may occur in old age, as in *senile cataract;* in disease of the kidney, as in *diabetic cataract;* or in abnormal change in the deep structure of the eye, as in *secondary cataract.* There is also a *congenital cataract*, dating from birth, and a *traumatic cataract* from injury.

Recently, investigations, by Schoen, in regard to the cause of senile cataract appear to show that the opacity begins frequently in those from twenty to thirty years of age, and notably in hypermetropic and astigmatic eyes, in the form of small white dots and streaks at the equator and in the horizontal meridian of the lens. Later, as age comes on, the opacities develop until the anterior cortical and nuclear portions of the lens become involved, and then the failure of sight is first noticed. Ametropia, deficient refractive power or errors of refraction, may then be considered one of the primary causes of senile cataract.[1] Opacities of the lens fall, practically, into two great divisions, the hard and soft.

[1] *Vide* A. of Oph., vol. xviii. No. 3.

HARD OR SENILE CATARACTS

are distinguished from soft cataracts by their color, which is gray, and, approaching the centre, yellowish-gray; they are of uniform appearance, or more frequently striated, the striæ presenting a pearly aspect. Senile cataract is also probable in all opacities of the lens in subjects above the age of fifty. Soft cataracts occur generally in younger persons, and are known by a lighter, more bluish tint, are less apt to be striated, or, if so, the striæ are less symmetrically arranged. Sometimes it is difficult to decide, when the age of the patient furnishes little help, whether a cataract be hard or soft. Less common forms of hard cataract than the *nuclear*, where the nucleus is opaque, the marginal portion remaining for a time transparent, and the more common *striated* form, presenting lines from the posterior or anterior cortical portion of the lens, or from both, and running towards the centre, are the so-called *black* cataracts, the centre or nucleus of the lens being dark-brown, the posterior polar cataract, as seen in Fig.

FIG. 60.

References as before.

60, and the *siliquose* where the lens is atrophied or overripe, and lies in its shrivelled capsule. (Morganian cataract.)

The progress of hard cataracts is very variable, sometimes slow for a time, and then rapid. They may, indeed, for a time not only cease to progress, but the patient may, temporarily, see better. It is wiser not to answer the invariable question of patients decidedly, as to the time when the cataract will be perfect. It is very certain that the ordinary senile cataract of one eye will, sooner or later, be followed by the same affection in the other.

THE OPERATION OF EXTRACTION

is indicated as soon as the cataract has ripened. We may judge of this by the appearance of the opacity, which is denser, deeper in color, and extends through the entire lens, so that the shadow of the iris at the circumference of the lens is scarcely visible. The vision is also reduced to the mere counting of fingers. Dilation of the pupil with atropine improves it less, as the periphery of the lens is involved in the opacity. When the cataract matures very slowly, it has been recommended by Förster to hasten its development by making a preliminary iridectomy and rubbing the cornea over the pupil and lens capsule. We may also operate before the cataract is fully ripe. The disadvantage of this is, that the transparent cortical portion of the lens, being softer than the opaque part, may separate from it, and be left to a great extent in the eye, and act afterwards as a foreign body, irritating the iris, and producing disturbance of vision. It is safer not to operate on both eyes at once.

THE PROGNOSIS.

The prognosis in extraction is very favorable. In uncomplicated cases there are probably not more than three or four per centum of entire failures.

The operations mostly practised for extraction are the *small flap*, and the *peripheric-linear*. The strict peripheric-linear operation of Graefe is losing ground with operators, from the danger of irido-cyclitis, which may follow immediately, or after the lapse of considerable time.

THE SMALL FLAP OPERATION.

The patient being in a recumbent position, an assistant separates the lids, or they are separated by a speculum, the operator fixes the eye by pinching up a fold of the conjunctiva with a pair of small forceps. He then enters the cornea, at its outer edge, either at its upper



FIG. 61.
Graefe cataract-knife.

or lower third, with a Graefe cataract-knife (Fig. 61), carries it steadily forward, cutting out either above or below, and making, according to his predetermined intention, either a superior or inferior flap.



FIG. 62.
Beer cataract-knife, formerly used for making the flap in extraction.

Allowing the patient now a moment's respite, the eye is again opened, the needle or cystotome introduced

(Fig. 63), and the capsule of the lens thoroughly lacerated. This being accomplished, the opaque lens, with or



FIG. 63.

without the aid of gentle pressure upon the eye, emerges slowly from between the lips of the wound. Any re-



FIG. 64.
Daviel Curette.

mains of the soft cortical substance of the lens are evacuated by gently pressing the cornea through the lid and by the aid of the curette or spatula. Fig. 64. Many operators make an iridectomy after completing the flap and before the evacuation of the lens; a few make a preliminary iridectomy about four weeks before operating for extraction.

Exigencies may arise during an operation like this to modify it somewhat. The corneal wound may have been made too small to admit of the passage of the lens. If so, it must be enlarged by cutting with curved scissors, — a proceeding sometimes difficult, the cornea lying directly upon the iris, there being no anterior chamber in consequence of the escape of the aqueous humor. The knife may have entered the cornea too far from its limbus, too near its centre. In this event, it is necessary to cut out in the sclerotica, and the wound will lie towards the inner canthus of the eye. This may render tedious manipulations necessary, after the open-

ing of the capsule, in order to force the lens inward to a point corresponding to the opening of the wound.

Sometimes, after rupturing the capsule, instead of the lens, we have a gush of vitreous humor from the mouth of the wound. In this case, it is necessary to remove the lens immediately from the eye, by means of a curette, or small spoon.

Deep-seated hemorrhage may occur, especially if the complication of glaucoma exist, and in such event the prognosis is bad. Owing to sudden escape of the aqueous humor, the iris may be forced against the knife, and wounded, in making the corneal flap. This may render an iridectomy necessary. The operation for extraction is done under cocaine. The instruments are disinfected, and the conjunctival sac thoroughly cleansed with a solution of bi-chloride of mercury 1 : 5000 before making the corneal incision.

PERIPHERIC-LINEAR EXTRACTION.

This operation, of Von Graefe, requires the recumbent position, and the lids to be separated by a stop-speculum. The eye, being held in position by delicate forceps in the left hand of the operator, is entered with the Graefe knife, the edge upward, in the sclerotic, about half a line from the corneal limbus and near its upper and outer portion, so that the anterior chamber will be opened across its extreme upper margin. Fig. 66, from Nettleship, shows the varied corneal sections in cataract operations. The knife, being entered at the temporal side, is pushed downward and inward until it

has entered the anterior chamber to the extent of two or three lines, when the handle is depressed and the point is carried horizontally forward towards the nasal margin of the cornea, so as to emerge in the sclerotic exactly opposite its place of entrance; the edge of the blade is then turned sharply forward, the knife pushed horizontally onward, and the section completed by drawing it backward from heel to point. The next step is to

FIG. 66.

Line of incisions in extraction of lens. — 1. Old flap. 2. Peripheral linear. 3. Upper and lower short flap. Dotted circle shows outline of lens.

make an iridectomy by seizing the iris which presents itself at the wound, and snipping it off. The capsule is then lacerated, and, by gentle pressure upon the eye, the cataract is forced through the opening. If, as sometimes happens, the lens is not readily evacuated, it should be drawn from the eye by a small spoon-like tractor or curette. The old process (1730) of syringing out the cortical remains is again revived; but it is one more manipulation of doubtful necessity, and one doubtful manipulation is undesirable. It may be said, further, that Nuel has found, by experiment, that pure water injected into the anterior chamber causes a detachment of the endothelium of Descemet's membrane, in a half minute or less. (Arch. Ophth., Vol. XIX. p. 306.)

EXTRACTION OF THE LENS WITH CAPSULE.

An opening is made in the sclerotic or at the corneo-scleral junction, followed by an iridectomy; a scoop is then introduced behind the lens and capsule, and both are extracted together. It is often done for hypermature cataracts.

RECLINATION OR DEPRESSION

for senile cataract has justly fallen into disrepute, and is seldom practised. The eye is entered through the sclerotica, about two lines from the cornea at the temporal side, just below the horizontal meridian. The needle employed is delicate, flattened, and spear-shaped



Fig. 67.

towards its point, and double-edged. See Fig. 67. It is carried forward until its flat surface is directly behind the pupil, and against the anterior capsule. The lens is then pressed gently backward and downward out of the field of vision. Its effects are brilliant at first, but not permanent. Now and then there is an exceptionally successful result. I saw, during the semester of 1863, in Vienna, a man who had reclination performed for cataract in the year 1839, and now, for the first time, was troubled by indistinct vision from a shred of opaque capsule.

All cataract operations are now done under cocaine. A 4 % solution is dropped into the eye twice or thrice

at five-minute intervals, and strict anti-sepsis is observed as in other surgical operations.

AFTER TREATMENT IN EXTRACTION.

After the operation, both eyes should be gently closed and a simple bandage applied, as described in chapter third under Bandaging. The bandage and charpie or anti-septic absorbent cotton may be renewed every day, the discharge gently washed away with tepid water. Attentions of this kind render the patient more comfortable, quiet, and less nervous, and so facilitate healing and a fortunate result. The patient should keep his bed about forty-eight hours, and then if all goes well he may exchange it for the sofa. The bandage may be continued for a week, and then be replaced by a broad shade, and the sooner after this the patient can get into the open air the better. The diet for the first day or day and a half may consist of farinaceous articles and beef-tea, but after this, should be generous, and nearly that to which he is accustomed. I generally administer aconite for thirty-six hours or more after the operation. If there is no pain or especial discomfort, it is best not to examine the eye by opening the lids during the first five or six days. If the eye is quite hot and painful during the first few hours after the extraction, cold compresses may be used. For the first forty-eight hours if the pain is severe, and the eyelids swollen with muco-purulent discharge, we have a dangerous complication, *suppuration of the cornea.* A compress bandage is to be applied, and the case treated as described under Suppurative Corneitis and Ophthal-

mitis. This complication avoided, we may have an *acute iritis.* Atropine should be instilled into the eye at once, of the strength of four grains or more to the ounce of water, not only for the purpose of securing immobility to the iris, but to prevent, if possible, closure of the pupil. The advent of acute iritis may be known by pain, photophobia, lachrymation, chemosis, discoloration of the iris, turbid aqueous humor, and contracted pupil. The treatment of iritis has been already given. Simple iritis, of a serous character, may come on later from irritation of the iris, and is less dangerous than the more rare *acute suppurative* or *traumatic* iritis above mentioned. *Prolapse of the iris* is liable to occur soon after extraction, in which case atropine and the bandage are to be immediately applied. In case of *corneal fistula* from imperfect union of the lips of the wound, the edges of the orifice may be touched cautiously with a solution of nitrate of silver which may effect the healing through the local inflammation set up by it. If this fail, an iridectomy to relieve intra-ocular pressure could be tried. *Cystoid cicatrix*, the name given by Von Graefe to a healing of the wound in the sclera or limbus corneæ through the intervention of cicatricial tissue which finally becomes thin and bulging, is noticed oftenest as a sequel of iridectomy for glaucoma. It may occur also in glaucomatous eyes after extraction. We cannot change the nature of the cicatrix, but we may perhaps prevent an increase of bulging, sometimes, by operating to remove intra-ocular pressure.

CAPSULAR OPACITIES AFTER EXTRACTION.

After fully dilating the pupil with atropine, the wrinkled, semi-opaque capsule which sometimes remains in the pupillary area is to be torn open under cocaine with a fine needle which is passed into the eye through the cornea. See page 250. It may be necessary to use two needles, one in each hand, entered at opposite sides of the cornea; their points meeting in the capsule can be moved in opposite directions, which renders the division of it easier and more certain. In some instances, if the membrane is dense, it may be divided by a very narrow knife which is made to enter the anterior chamber at the outer or inner edge of the cornea; sometimes it may be advisable to attempt the withdrawal of the tough capsule by means of the delicate canular forceps. It is a hazardous proceeding, and I have often known it to fail. None of these operations should be undertaken until all irritability of the iris has passed away, and after the operation, atropine should be instilled, and the patient kept for twenty-four hours in a subdued light. A concentrated artificial light is very serviceable in these delicate manœuvres.

SECONDARY CATARACT

is an opacity of the lens occurring in the course of glaucoma and other deep-seated diseases of the eye. As a rule, no operation for the removal of the cataract is indicated, as the risk is very great, without a prospect of corresponding benefit. The operation of mine, following an iridectomy for glaucoma, published in the

"New England Medical Gazette" for June, 1869, was unusually successful, more so perhaps than could have reasonably been hoped for. In that case, however, there were pretty certain indications that the fundus of the eye had been restored to a tolerably healthy condition. The patient could see a lighted candle in a darkened room at a distance of fifteen feet. There was evidence that the glaucoma had ceased to progress, and there was a chance that whatever improvement of sight might be gained by the removal of the opaque lens would be permanent.

SOFT CATARACT

occurs in children and in subjects under thirty-five or forty years of age. Its color and general appearance have already been noticed. One of the commonest forms of this lenticular opacity is the *infantile* or *congenital cataract.* It is either congenital, or develops during infancy. There are two varieties: the *lamellar*, called by German writers *schichtstaar*, is a central opacity surrounded by a more or less transparent zone of lens substance, so that when the pupil is fully dilated, the sight is usually improved to a remarkable degree. See Fig. 68, on the next page. It seems to be connected in some manner with infantile convulsions. The progress of the opacity is slow, sometimes almost imperceptibly so. Children with this form of cataract are often thought to be near-sighted. This idea may be corrected by the test mentioned under Amblyopia, and the cataract diagnosed by lateral illumination or the ophthalmoscope. The other variety of opacity, *the cortical cataract*, is much

more rapid in its course. This opacity is seen in the form of opaque striæ running from the circumference to the centre, the interstices at first showing transparent lens, which after a time becomes mottled, hazy, and opaque.

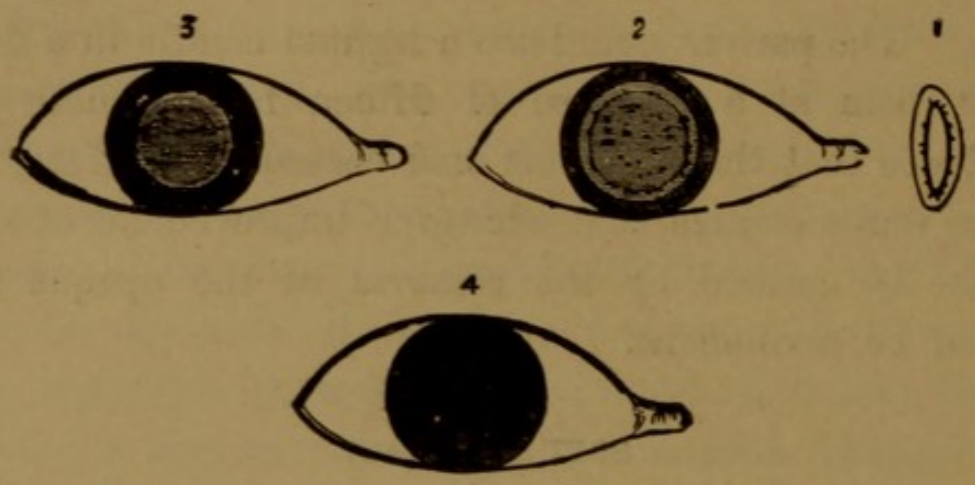

FIG. 68.

References as before (Fig. 58) for 1, 2, 3. In 4, the pupil is undilated. (After Nettleship.)

When mature, the cataract is bluish-white, more dense at the centre, the striæ often presenting a pearly aspect. In infantile cataract, an early operation is indicated in order to prevent, as far as possible, the amblyopia retinæ, which develops rapidly in young eyes, when the visual rays of light are excluded by opacities in the transparent media.

OPERATIONS FOR SOFT CATARACT.

The operations for soft cataract are those of *discission*, *linear extraction*, and *suction*. *Discission*, or *solution*, consists in entering the eye through the cornea with a fine needle, rupturing the capsule of the lens centrally, and lacerating more or less the lens substance, permitting its absorption by the aqueous humor,

which obtains access to it through the opened capsule. Before the operation, the pupil should be dilated with atropine, and, subsequent to it, should be kept as widely dilated as possible, to avoid contact with lens matter which might otherwise occasion irritation, possibly iritis. Several operations of puncturing or lacerating with the needle will be required before the whole of the substance of the opaque lens will be absorbed. The interval between each operation will probably be three months or more, according to the progress of absorption; whenever progress ceases, the operation is to be repeated. Too much lens matter should not be broken up at once, lest too much swelling of the lens substance ensue, causing great irritation. If this should happen, the lens may be immediately removed from the eye by linear extraction. After the operation, the patient should remain quiet for a day or two in a partially darkened room.

Iridectomy for an artificial pupil is sometimes done for lamellar cataract when it appears to be stationary or non-progressive. This affords very good vision if the circumference of the lens is clear and the opacity pretty sharply defined. It is perhaps the freest from danger of all operations, but if the cataract prove to be progressive and the opacity extends, the eccentric pupil is no longer serviceable, and the eye is perhaps not in quite so favorable condition for the most successful results from discission or linear extraction.

LINEAR EXTRACTION

should be performed a few days subsequent to a needle operation in which the laceration of the capsule and

division of the substance of the lens is more thorough and extended than in the one advised for discission and removal of the cataract by absorption. When the lens matter has become softened and swollen by admixture with the aqueous humor, the pupil being widely dilated by atropine, and the eye rendered anæsthetic by a 4% solution of cocaine, the cornea is opened at its temporal margin with a broad needle in an oblique direction. A curette is then introduced, the eye being fixed in the most convenient position with the forceps, and by gentle pressure upon the lips of the wound, the semi-fluid lens will flow gently down the groove of the curette, and be brought out at the small corneal aperture. Afterwards the simple bandage should be applied, and the patient kept in bed for twenty-four hours, the pupil being dilated by atropine, applied daily, until all signs of iritis have disappeared.

THE SUCTION OPERATION,

like the linear, is probably more easily accomplished a few days after breaking up the lens with the needle, although either operation may follow immediately, if necessary. The operation is like the last described, only in place of the ordinary curette, is substituted a tubular one, attached to a second tube, of glass, and this to a metal syringe, from which the suction power is obtained. The syringe is constructed so as to be worked by the right hand, which also guides the curette, while the left keeps the eye in position by the forceps.

Diabetic cataract, appearing in the course of a diabetes, is generally soft, but harder in elderly persons.

It is to be removed by extraction, if the health of the patient is not too much impaired. I have operated successfully in such cases, when the patient has had no prospect of living beyond a few months.

Fluid cataract is of rare occurrence. Generally there is a nucleus more or less firm. Suction, or linear extraction, is the suitable operation for it. In appearance, it is milky-white, homogeneous, and without opalescent stripes.

MEDICAL TREATMENT OF CATARACT.

Cataract is known to be a result of ergotism. It has also been produced in frogs by administering sugar in large quantities, or by injecting it under the skin. Chloride of sodium and alcohol have produced similar results. In our school, cures, or beneficial results, are reported to have followed the use of cannabis, conium, phosphorus, and many other remedies internally.

There are reports also of cures by galvanism, electricity, and massage of the eye. But senile cataract is curable in one way only; namely, by the removal of the opaque lens from the visual field through a surgical operation. (See cause of senile cataract, pages 238, 240).

CAPSULAR CATARACT.

Anterior capsular cataract, or anterior polar cataract, is usually situated centrally, and is caused originally by an inflammation of the iris or cornea. In young children the anterior chamber is very shallow, and in the new-born it scarcely exists at all, the cornea and lens being nearly in contact, so that an ophthalmia

would be likely to extend to the capsule, or, if purulent, leave some deposit upon its anterior surface. This condition sometimes gives rise to a form of cataract called *pyramidal:* it projects into the pupil, but is within the capsule of the lens. An artificial pupil is usually indicated in this form of opacity. In *capsulo-lenticular cataract*, both capsule and lens are extracted either separately or together.

DISLOCATION OF THE LENS

may be spontaneous, the result of a blow on the eye or head, or it may be congenital and hereditary. It is either *partial* or *complete.* The lens may be thrown backward into the vitreous humor, forward through the pupil into the anterior chamber, or by a rupture of the sclerotic it may be forced beneath the conjunctiva. In the latter case, and also when dislocated into the anterior chamber, it should be extracted. If lying in the vitreous, it may be permitted to remain, if its presence occasions no irritation, if otherwise, it should be extracted.

DIAGNOSIS.

There is generally pain, photophobia, lachrymation, tremulousness of the iris, and the signs of absence of the lens behind the pupil, mentioned under Aphakia. Lying in the anterior chamber, the lens may be plainly seen and recognized. Not long since, however, a case was sent me which had been called an opacity of the cornea. It was in an eye otherwise diseased, and the dislocation was occasioned by a blow on the head.

Under the conjunctiva, the displaced lens may be seen as a small semi-transparent swelling. In partial dislocations there will be monocular diplopia or polyopia. *Lateral illumination* will enable us to determine the amount of displacement. *Direct examination* with the ophthalmoscope is still better. We may then see the free edge of the lens as a dark crescentic line across the red pupil. Partial displacement often causes great irritation, and may lead to glaucomatous inflammation; in such cases the lens is to be extracted. Sometimes the great irritation experienced at first may be lessened by the instillation of cocaine, atropine, by warm soothing fomentations of belladonna, chamomilla, opium, and the internal administration of indicated remedies. In congenital or other cases, where the dislocation appears fixed, an operation for artificial pupil is indicated.

TRAUMATIC CATARACT.

The opacity in the lens generally commences within twenty-four hours after the injury to the capsule. It is at first confined to the locality of the wound, but soon involves the entire lens, spreading more rapidly, the younger the subject. There may be considerable pain and irritation resulting from the wound in the cornea, or laceration of the iris, or simply from the pressure of the swollen lens upon the iris. Traumatic cataract may occur from a blow, which, without the rupture of the external tunics of the eye, may nevertheless rend the capsule of the lens. The pupil should be kept dilated, and the treatment be similar to that mentioned in dislocation of the lens. After the irritation has sub-

sided, if the absorption of the lens is found to be going on, there should be no surgical interference; but if the pain continues, tension of the globe is increased, the pinkish zone around the border is marked, and traumatic glaucoma is feared, the lens should be extracted.

APHAKIA,

or absence of the crystalline lens, occurs after extraction, from complete dislocation, and after absorption of the lens. It may be recognized when the history of the case is not known, by the blackness of the pupil, diminished size of the anterior chamber, and tremulousness of the iris in case the latter has lost the support of the capsule also. The refraction of the eye is, of course, much changed. An emmetropic eye becomes hypermetropic, a hypermetropic eye more hypermetropic, a myopic eye less myopic, and the power of accommodation is gone. The spectacles suited to this condition of the eye are spoken of in the next chapter.

CHAPTER XIV.

SPECTACLES — ARTIFICIAL EYES.

SPECTACLES.

THE ordinary glasses for spectacles, in optical defects, are convex or concave *spherical*, except in astigmatism, when they are *cylindrical* or a combination of both spherical and cylindrical. In muscular insufficiencies they are prisms, either alone or in combination with the others. The nature and use of these glasses have already been sufficiently explained.

CATARACT GLASSES

are thick convex lenses of great refractive power. After extraction of the crystalline lens the accommodative power of the eye is lost, and therefore two pairs of spectacles will be necessary, one for reading, of about two and one-half inches focus, and the other four and one-half inches focus for distance. These numbers will vary somewhat according to the refractive state of the eye before operating, whether emmetropic, myopic, or hypermetropic. It is advised by some surgeons that the glasses should be small and encircled by a black ring of ebony or shell a quarter of an inch in width. Large glasses admit too much light into the eye, and cause a dazzling sensation. Sometimes a combination of cylindrical with

the spherical glasses is required in order to afford sufficient acuteness of vision for the patient to read with comfort.

Cataract glasses should not be worn for some weeks after the operation; while much irritation remains, it is better not to attempt the use of the eyes for near objects.

PANTOSCOPIC GLASSES,

verres à double foyer, are sometimes called Franklin glasses from the fact that he wore such. The upper and lower half of each glass have different foci. If a myope becomes presbyopic, the upper half of his glasses would be concave for distance, and the lower half convex, to neutralize his presbyopia in reading.

PRISMATIC AND DECENTRED GLASSES.

Prismatic glasses are useful in aiding or exercising certain muscles of the eye, as explained under Muscular Insufficiencies and the article on Strabismus. Decentred lenses are so constructed that the wearer looks through an eccentric part instead of the centre. A convex lens, for instance, may be so arranged that its centre lies a little to the inner side of the visual axis, in consequence of which a slight effect of a prism is produced.

EYE PROTECTORS.

Eye protectors made of curved glass are the best. Goggles with wire, silk, or glass sides keep the eye, as a general rule, too close and warm. For photophobia, simple colored spectacles of plain glass are sufficient, and may be darker or lighter in shade, according to the amount of protection required.

Strong plate-glass spectacles are worn by those finding it necessary to protect the eyes against chips and particles of stone or steel. It is proposed to make them of curved mica. Such spectacles would be cheap, durable, not likely to break, and very light.

STENOPAIC SPECTACLES,

composed of metallic plates with small central apertures, are useful in opacities or cloudiness of the cornea. They exclude the peripheral, and permit only the central rays of light to enter the eye; acuteness of vision for near objects is increased, but they are not serviceable for more distant views, as they limit the field of vision too much.

ARTIFICIAL EYES.

After enucleation or excision of the eyeball, or after excision of a staphyloma of the cornea, or in case of a shrunken globe from any operative interference or disease, the deformity may be almost completely removed by wearing a suitable artificial eye. It should not be worn steadily for a month or six weeks after the removal of the eyeball, lest irritation and inflammation of the conjunctiva ensue. To insert it, the upper lid is to be raised, the upper border of the artificial eye introduced beneath it, and the lid allowed to fall; then the lower lid is to be depressed and gently pulled forward, when the artificial eye will slip into place. To remove it, depress the lower lid, and with a hook or bodkin force its lower edge forward, and it will fall out. It should be caught on something soft or yielding so as not

to break or scratch it. It should be removed and cleansed every night, and, if worn every day, after six months should be exchanged for a new one, or repolished, as it becomes gradually roughened and may occasion irritation and inflammation.

THE DIOPTRIC SYSTEM IN THE ENUMERATION OF LENSES.

The unit in this system is the French metre, — that is, a lens of thirty-seven Paris inches focus, which for practical purposes we may consider the equivalent of our old No. 36. The new lenses are called dioptrics. The following table gives the new numbers, their focal distance, and their equivalents according to the old enumeration.

Numbers in dioptrics.	Focal distance. Paris inches.	Corresponding old numbers (nearly).
0.25	148	
0.50	74	72
0.75	49	48
1.	37	36
1.25	30	30
1.50	$24\frac{1}{2}$	24
1.75	21	20
2.	$18\frac{1}{2}$	18
2.25	17	16
2.50	15	15
2.75	$13\frac{1}{2}$	14
3.	$12\frac{1}{3}$	12
3.50	$10\frac{2}{5}$	10
4.	$9\frac{1}{4}$	9
4.50	$8\frac{10}{45}$	8
5.	$7\frac{2}{3}$	7
5.50	$6\frac{40}{55}$	$6\frac{1}{2}$
6.	$6\frac{1}{6}$	6
7.	$5\frac{2}{7}$	$5\frac{1}{2}$
8.	$4\frac{5}{9}$	5
9.	$4\frac{1}{9}$	$4\frac{1}{2}$

Numbers in dioptrics.	Focal distance. Paris inches.	Corresponding old numbers (nearly).
10.	$3\frac{7}{10}$	4
11.	$3\frac{4}{11}$	$3\frac{1}{2}$
12.	$3\frac{1}{12}$	3
13.	$2\frac{11}{13}$	$2\frac{3}{4}$
14.	$2\frac{9}{14}$	
15.	$2\frac{7}{15}$	$2\frac{1}{2}$
16.	$2\frac{5}{16}$	$2\frac{1}{4}$
18.	$2\frac{1}{18}$	
20.	$1\frac{17}{20}$	2

It will be noticed that the number of the lens in the new system does not correspond, as in the old system, to its focal length; but in order to find the focal length, we have only to divide the metre, about 36 inches, by the number of the dioptric. Thus D. 4 has a focal length of 9 inches; or, if we call the metre 40 inches (a metre is 39.337 English inches), a lens of 4 dioptrics is one of 10 English inches focal length.

To test the visual power, under this system, we place before the patient at a distance of six metres — about twenty feet — letters of the size of those numbered 20 in the second series of test type annexed to this volume. If he distinguishes these letters easily at six metres, his vision is $\frac{6}{6}$, or one. If he can only see larger letters, perhaps those numbered 70, at six metres distance, his V. $= \frac{6}{24}$ very nearly, the seventy feet being about twenty-four metres.

In a case of ametropia, take a convex lens of one dioptric (D + 1). If distant vision is improved or unimpaired by it, there is a manifest hypermetropia of one dioptric. If, in another case, vision is most improved by D — 4, there is a myopia of four dioptrics.

To test the range or power of accommodation. In the emmetropic eye, the nearest point at which vision is most distinct for small objects (the finest type) gives the measure of the accommodative power. For example, suppose this point to be one ninth of a metre from the eye, then four dioptrics would express the range of accommodation, the far point being infinite distance. The accommodative effort brought into service to see at this distance equals the effect of a convex lens of four dioptrics, if such a lens could be placed within the eye. The same method is available in a case of hypermetropia or presbyopia, the optical defect being first corrected by a proper lens. In a case of myopia, say of three dioptrics, — that is, the far point is twelve inches, and the near point at three inches, — the accommodative range is then from three to twelve dioptrics; that is, it equals nine dioptrics. Practically, however, in hypermetropia, I prefer to test the range of accommodation by fitting proper glasses for reading, and then noting the far and near points: thus yesterday, for a young man of eighteen years, with slight manifest hypermetropia, I presented D + 1 for reading. With these glasses he could read No. 1 type at thirteen centimetres and at forty-seven centimetres (from five and one-fourth inches up to eighteen and one-half inches), a very good power of accommodation. In the case of a woman of sixty, both hypermetropic and presbyopic, through glasses of three dioptrics she could read the finest type from twenty-three centimetres to forty-four centimetres; also a fair power of accommodation for her age.

CHAPTER XV.

THE MUSCLES OF THE EYE.

PARALYSIS.

THE nerves supplying the muscles of the eye are the third (oculo-motorius), fourth (trochlear), and sixth (abducens). The third supplies the internal, superior, and inferior recti, the inferior oblique, the levator palpebræ superioris, the constrictor pupillæ, and the ciliary muscle.

The fourth nerve supplies the superior oblique, and the sixth the external rectus.

The rectus externus moves the eye outward.
" " internus moves the eye inward.
" " superior moves the eye upward and inward, and rolls (inclines the vertical meridian) the eye inward.
" " inferior moves the eye downward and inward, and rolls it outward.
" superior oblique moves the eye downward and outward, and rolls it inward.
" inferior oblique moves the eye upward and outward, and rolls it outward.

The third and sixth nerves are more often affected, the fourth very rarely. For convenience in describing the diagnostic symptoms, we will consider the paralytic affection as occurring in the left eye.

PARALYSIS OF THE EXTERNAL RECTUS.

On moving an object before the eye from right to left (a lighted candle is convenient), a convergent squint is noticed. The movement of the eye to the left is sluggish. There is diplopia as the object is moved into the left half of the field of vision, the images being homonymous (not crossed, the right belonging to the right eye, the left to the left eye), parallel, of the same height, the distance between them increasing as the object is moved farther to the left. The position of the head is also characteristic, the patient carrying it turned somewhat to the left, in order to avoid the confusion of sight arising from the double images. A prismatic glass may be worn to correct the diplopia, as shown in Fig. 69.



FIG. 69.

This figure, from Nettleship, shows how a prism may correct diplopia. R (the right eye) is directed towards *x* instead of *ob* (the object), and two images of *ob* are seen. The prism *p*, before the right eye, deflects the rays to *y* (the yellow spot), and single vision is the result. In this case the right eye is supposed to be affected

A prism bends the rays of light towards its base. Applying it to the left eye, base towards the temple, rays of light are bent outward, and the image is projected inward towards that of the other eye. The prismatic glass should be just strong enough to fuse the two images. If we wish to exercise the paralyzed rectus so as gradually to strengthen it, we may prescribe

a weaker prismatic glass which does not quite fuse, but approximates very nearly the two images. The effort of the eye to fuse the images will call the rectus externus into action to a limited extent, and as it grows stronger we may weaken the prisms.

PARALYSIS OF THE INTERNAL RECTUS

is rarely met with as an isolated affection. The third nerve supplying also the superior and inferior recti, the inferior oblique and others, several muscles are simultaneously affected. The symptoms would, however, be the reverse of those just noticed, and prismatic glasses would be worn with the base inward. The patient would also incline his head slightly towards the right. In

PARALYSIS OF THE SUPERIOR RECTUS,

the eye will not turn upward readily. There is also a slight divergent squint. The inferior oblique drawing the eye outward, crossed double images will occur in the upper half of the visual field. The images are not parallel, diverge upward, and differ in height.

PARALYSIS OF THE INFERIOR RECTUS

would occasion symptoms just the reverse of the above. In

PARALYSIS OF THE SUPERIOR OBLIQUE

the deviation of the visual axis is very slight. There is a want of mobility noticed in the attempt to turn the eye downward and inward. Homonymous, or corresponding double images are seen in the lower half

of the field of vision. The left image (that of the affected eye) appears lower than the other. The images will be oblique, converging towards the top. The patient will be annoyed in descending stairs, which appear double, and irregular in outline. He will be apt to turn his head downward and to the right, so as to bring objects into the upper and left portion of the field of vision, avoiding the diplopia. Paralysis of the *inferior oblique alone* almost never occurs.

PARALYSIS OF THE THIRD NERVE

may be complete, affecting all the muscles supplied by it, or it may be partial, affecting only one or more of the muscles. In complete paralysis, say of the left eye, there is first ptosis. On raising the upper lid we find the eye restricted in its movements in the upward, downward, and inward directions. The rectus externus, being supplied by the sixth nerve, is unaffected, and the eye can consequently move outward. It can also move to a certain extent downward and outward, through the superior oblique, which is supplied by the fourth nerve.

Prognosis and Treatment.

Whether a cure of paralysis of the muscles of the eye can be prognosed, depends chiefly upon the cause of the affection; or whether the lesion be peripheral or central. If syphilitic, a not uncommon cause, the prognosis is generally favorable, the lesion being usually peripheral. If of rheumatic origin, the prognosis is highly favorable. When due to intracranial causes, or

severe injury, the prognosis is, of course, often unfavorable. The more acute the case, generally speaking, the better are the chances for a cure. In syphilitic cases, I believe iodide of potash, after mercury, to be the best remedy. In rheumatic cases, where the seat of the disease is probably the sheath of the nerve, my experience has been excellent with bryonia, gelsemium, mercury. Local treatment should not be neglected. Passive movements of the eye should be made by seizing the conjunctiva with the forceps and rotating it several times in succession towards the affected muscle. This can be done daily under cocaine. The patient should also exercise the eye by efforts to roll it towards the weakened muscle. The chances of cure are much increased if the paralysis is partial and only one nerve affected, the general nervous system being in good condition. In case of paralysis of the sixth nerve (external rectus), the condition of the abdominal viscera should receive more than ordinary attention, as this nerve seems to be particularly influenced by reflex action from the sympathetic. When other means fail, paralysis of the ocular muscles from peripheral or extracranial causes may sometimes be cured by electricity. Faradization does not appear to be as efficacious as the primary galvanic current.

Pain in the head, dizziness, loss of intellectual power, unsteady movements, and great difficulty in fusing the double images by prisms, all indicate a cerebral cause. Among the cerebral lesions may be mentioned tubercular deposits, hydrocephalus, effusions of blood, aneurisms, softening of the brain, and tumors. Ostitis,

periostitis, exostosis, and tumors situated at the base of the brain sometimes occasion the paralysis. Similar orbital affections may also cause it.

In children, oftener than in adults, a local paralysis may be the result of some nervous irritation in a distant part. Dentition is often the exciting cause, and in such instances the prognosis is nearly always favorable.

In adults the annoyance of the constant double vision is relieved by bandaging one eye, or by the use of spectacles, one glass of which may be dark or frosted.

Surgical Treatment.

Later when other remedial measures fail, or only partially complete the cure, the abnormal direction of the eye and the resulting diplopia may sometimes be remedied by an operation to restore the equilibrium of the muscles. This would consist probably of a tenotomy of the opposing, and an advancement of the weakened, muscle. The description of operations on the muscles of the eyeball is given under the article Strabismus.

PARALYSIS OF THE CILIARY MUSCLE

has been noticed chiefly during convalescence from severe fevers and debilitating diseases like diphtheria. It may be produced temporarily by dropping a mydryatic, like atropine, into the eye. The patient sees well at a distance, but is not able to read fine print. Near objects appear indistinct. Suitable convex glasses will restore near vision.

Perfect rest of the eyes and frequent bathing in cold

water should be enjoined. The diet in these cases ought to be generous and nutritious, and hygienic conditions should be made as favorable as possible. Remedies adapted to the impoverished condition of the patient's system may be used, but time alone will also cure the affection.

TENSION OF THE CILIARY MUSCLE

is met with in hypermetropia as well as in myopia. It occasions myopic refraction of the eye, so that the patient sees better in the distance through concave glasses. By paralyzing the ciliary muscle, however, we find that the eye is really hypermetropic; the tension appears to be the result of overworking the ciliary muscle in accommodating, or may be due to great exposure of the eyes to bright light. Rest alone or rest and atropine instillation are the remedies; later, the faulty refraction should be corrected by proper glasses.

Nystagmus, or involuntary oscillation of the eyeball, is owing to spasmodic twitching of the muscles which control the globe. It is most frequently seen in congenital cataract in children, but may be brought on by any affection of the eye which causes indistinctness of vision. Its cure can only be effected by restoring acuteness of vision to the diseased eye.

STRABISMUS (CONCOMITANT STRABISMUS).

By this term is meant a manifest deviation of the optic axes; latent or dynamic squint is noticed elsewhere.

When the eye is turned inward it is termed *convergent strabismus;* if outward, *divergent strabismus.* If confined to one eye, it is called *monocular;* if the squint alternates

between the two eyes, it is *binocular* or *alternating strabismus.* In the latter case, the acuteness of vision in the two eyes being about the same, the patient fixes sometimes one eye, sometimes the other, on the object, the squinting eye being the one not in use for the time being. In monocular strabismus the sight of the squinting eye is almost invariably impaired, and no attempt is made by the patient to use it.

In treatment it is practical to divide strabismus also into the *periodic* and the *confirmed*, although the pathology of the two is usually identical, and the first is but the precursor of the second. Occasionally, however, we meet with a periodic squint, especially in children, where the affection may be traced to some nervous irritation in a distant part, or to the cerebral irritation from dentition. No doubt that a squint of this kind arises often from partial paralysis of one or more of the ocular muscles, and is therefore not properly spoken of under the head of Concomitant Strabismus. In the latter there is a tension or an increased energy or shortening of a muscle, but the eyeball can be moved, although these motions may be somewhat restricted, outward or inward at will, and in this it differs from paralytic strabismus.

The causes of strabismus are errors of refraction, muscular insufficiencies, amblyopia, or any condition tending to inequalities of vision in the two eyes.

CONVERGENT STRABISMUS

is usually associated with hypermetropia. Donders believed this to be the case in seventy-seven per cent, and

De Wecker in eighty per cent. It will be remembered that in the hypermetropic eye the antero-posterior diameter is too short, and that parallel rays of light reach the retina before being focussed, and vision is therefore indistinct, that the refractive power of such eyes requires to be aided by convex glasses in order to prevent over-exertion in accommodating or *accommodative asthenopia.* In regarding near objects, still greater exertions to accommodate are necessary, and consentaneous with accommodation comes the convergence of the visual axes in order to fix both eyes on the same near point. Convergence, however, in such eyes is greater than under similar circumstances it would be, in normally refractive (emmetropic) eyes. A habit of turning the eyes inward is formed, which results first in a periodic, then in a permanent squint. The convergence being too great, the child finds it easier to see, if he turns one eye slightly outward or fixes with one eye; the fellow eye, following the movement, rolls still farther inward, and the habit of squinting begins. Such squint often makes its appearance in children at the age of four, five, or six years, when they are learning to read, and is often attributed to any cause but the right one. Sometimes its appearance is noticed a few years later, when the first earnest study is begun. If one eye happens to be more hypermetropic than the other, the tendency to squint is still stronger; for this eye may then turn inward without the annoyance which would otherwise be occasioned by the production of distinct double vision. The same would be true if in hypermetropia one eye should be amblyopic or defective in vision

from opacity of any kind, or if the rectus externus be unusually weak.

Ulrich, Segger, and others have shown that in non-squinting hypermetropic eyes, the abduction is stronger than in emmetropic eyes; hence the reasonable inference that in squinting eyes associated with hypermetropia the abduction is comparatively weak.[1]

DIVERGENT STRABISMUS

is very apt to be associated with myopia. Large staphyloma posticum, or posterior bulging of the globe, increases the tendency of the myopic eye to turn outward, as does also the frequent weakness in the internal recti met with in myopia. On account of the elongated shape of the eyeball it is difficult to converge to the near point for myopic vision. Therefore one eye is used and the other rolls outward. One eye being more myopic than the other increases the tendency to divergent strabismus. Great defects of sight in both eyes, vision being almost absent, are apt to produce slight divergent squint.

TO DETERMINE WHICH EYE IS AFFECTED.

Let the patient regard an object a few feet from him, then cover one eye with the hand, and note whether it is necessary for the uncovered eye to make a lateral movement in order to fix itself on the object. We try each eye in this way, and the deviating eye is the affected one. This determines the *primary deviation.* The *secondary deviation* is the associated movement which the

[1] Klin. Monatsblätter, quoted by Noyes, p. 176.

sound *covered* eye makes while the squinting eye is adjusting itself upon the object. The primary and secondary movements *are equal in extent.* This is an important fact in the differential diagnosis of ordinary or *concomitant* squint and *paralytic* squint. In the latter, the secondary deviation is the greater. Suppose the external rectus of the right eye paralyzed, and the eye turned inward. Hold an object before the eyes, and, covering the left, the right will move slowly outward, perhaps the distance of a line, in order to fix itself, while the

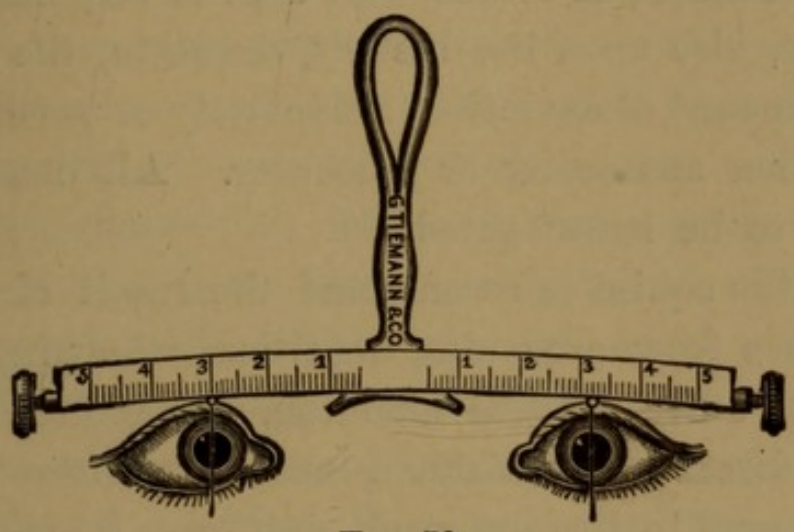

FIG. 70.

associated movement of the covered eye inward will probably equal two or three lines; the reason of this is plain: the right externus is very weak, the left internus healthy; the impulse necessary to turn the right eye outward is much greater than is necessary for the associated movement of the left eye inward, — hence the greater movement of the left eye.

The amount of the deviation of a squinting eye is found by marking with a pen the point on the lower lid directly beneath the centre of the pupil of the affected

eye, while it is turned inward or outward, and then covering the sound eye permit the former to fix itself on some convenient object, when a second mark beneath the centre of the pupil is again made. The distance between the two marks gives the extent of the strabismus. Several instruments are in vogue also for the measurement of squint, but the above method is simple and generally sufficiently exact. See Fig. 70.

Treatment.

The treatment, of course, will depend very much upon the cause, also upon the history, duration, the state of vision, amount of deviation, periodicity or permanency, and whether monocular or binocular. All these points are first to be investigated.

When the squint is recent, and the result of nervous disturbance from ascarides, dentition, whooping-cough, gastric or other visceral affection, the removal of the primary disease by suitable general treatment may restore the eyes to their normal position. I have known squint to disappear spontaneously.

I will not enumerate the many internal remedies accredited with the cure of this deformity, but I may say that I once heard a distinguished surgeon remark that forty per cent of the cases in young people get well by proper hygienic treatment and a correction of their optical defect by suitable glasses. Not long ago a lady, upon whose daughter I had operated for strabismus, informed me that the reason she had not insisted on an earlier operation in the case of her daughter was that she had herself been "cross-eyed" at the age of seventeen, but

that she had got better in course of time without treatment, and had believed no operation necessary. No doubt spontaneous cures of alternating squint are quite frequent.

Recent cases with hypermetropia may often be cured quickly by the use of convex glasses. The following is a case in point: Mr. B. called, on April 19, in consequence of a convergent strabismus of the right eye, since two weeks. He had also severe asthenopia for a number of weeks, brought on from over-use of his eyes in book-keeping. His general health was perfect. I found a hypermetropia of about one twenty-fourth, and prescribed convex glasses, at the same time cautioning him in regard to over-exertion of the eyes. At the end of a week the squint, which at first was more than a line in extent, had nearly vanished, and in two weeks it was gone. The asthenopia was cured also.

The periodic, divergent squint, seen often in myopes, may frequently be cured by prescribing the proper concave glasses, so that they may see distant objects without effort.

Orthopædic exercise of the internus or externus muscle, when the deviation is not of great extent, is sometimes curative. The exercise is best accomplished by means of prisms, and presupposes tolerable sight in the affected eye. If this does not exist, bandaging the sound eye systematically for a short time every day may, in a few weeks, restore sufficient vision for our purpose.

To correct a convergent squint the prism should be used with its base inward, thus inducing a corrective

squint outward. The eye is turned outward through the involuntary effort to fuse the double images, care being taken that the prism be of just sufficient strength to nearly, but not quite, accomplish the fusion. In order to exercise the internal rectus, the base of the prism should be directed outward. These orthopædic measures will generally be found more efficacious in slight paralytic than in concomitant squint. In the latter, however, they may be used to advantage, when necessary, with atropine, in perfecting the result of an operation, and especially in aiding to fuse the double images, which sometimes are very annoying after operations. See Fig. 69 on page 264. Another method of treatment favorably mentioned for convergent strabismus with hypermetropia, in children, is to paralyze the ciliary muscle with atropine, so as to prevent all attempts to accommodate, up to the time when suitable glasses can be worn. Commenced early, during periodic squint, this treatment has proved successful in some instances.

Surgical Treatment of Strabismus.

When the case is of long standing the operation of tenotomy is indicated, the object being to divide the shortened muscle at its insertion in the sclerotic, and permit it to reattach itself farther back.

The operation which I usually perform, and which I think most advisable, is that of Von Graefe. The eyelids having been separated by a speculum or an assistant, supposing it a case of convergent strabismus, the assistant turns the eye outward with a pair of for-

ceps. The operator then seizes with delicate forceps a fold of the conjunctiva near the cornea, just below the

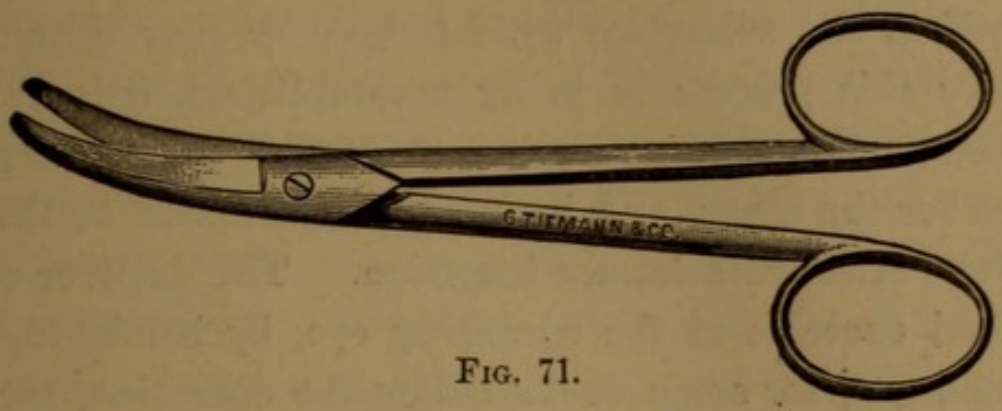

Fig. 71.

middle line of the insertion of the internal rectus. Snipping it through with the scissors (Fig. 71) he burrows underneath the conjunctiva somewhat, upward, downward, and inward, separating, to a limited extent, the subconjunctival tissue from the muscle. I prefer to adhere strictly to the Graefe method of opening the conjunctiva quite near the cornea, as less likely to cause retraction of the caruncle. The strabismus hook (see Figs. 72, 73) is now inserted beneath the tendon at its lower edge to raise it from the globe and hold it, and the muscle is divided by a succession of delicate snips with the scissors *as near as possible* to its insertion in the sclerotic.



Fig. 72. Fig. 73.

The operation is done under a four per cent solution of cocaine. Very little after-treatment is required. If the eye is hot and painful, a cold compress

may be applied over the closed lids, and a few doses of aconite administered. The divided muscle will reunite itself to the sclerotica within three or four days, and while this process is being accomplished, it is well to bandage *the sound eye*, so as to compel a central position for the other, and insure the attachment of the internus behind its former insertion. The daily or occasional exercise of the squinting eye, by bandaging the sound one, for some weeks before the operation, for the purpose of restoring acuteness of vision, when the eye is amblyopic, is commendable.

If the squint is of considerable extent it is better to operate on both eyes. For instance, if the strabismus is three lines in extent, by one operation on the affected eye we may reduce it to one line, then a slighter operation on the sound eye will bring the visual axes of both parallel. It is best to wait some weeks before operating on the second eye, in order that the full effect on the first may be determined. One operation will not usually remove more than from two to two and a half lines of deviation. The effect is increased by a free separation of subconjunctival tissue from the muscle when operating. The effect is decreased by avoiding this. The effect may be lessened when, after an operation, on testing the result we find that we have done too much, by inserting a deep conjunctival suture, bringing the edge of the wound, and with it the muscle, farther towards the cornea. A suture, carefully including the conjunctiva only, may be inserted diagonally, to hasten healing and prevent granulations from springing up in the wound, without lessening the effect.

Usually the sinking in of the caruncle, and the accompanying undue prominence in the globe, formerly noticed after operations for strabismus, are to be avoided by limiting the separation of the subconjunctival fascia with the scissors (avoiding, also, all unnecessarily large excursions with the hook), by conjunctival suture, and, above all, by being careful to divide the *tendon* of the muscle at its insertion. It is considered best by most operators not to attempt too great an effect upon one eye, but rather to divide the operation between both eyes; this avoids the disadvantage of setting back the internus of one eye so far as to prevent its turning inward freely, and thus disturbing the harmony of binocular convergence in accommodation, as well as the coordinate balance between the ocular muscles.

In rare instances, both in paralytic and concomitant squint, it becomes necessary to advance the insertion of a muscle so as to give it greater power. There are many methods of doing this, each differing more or less in detail from the other. For a description of these operations I am obliged to refer the reader to the larger works on Ophthalmology. They are quite difficult, and even in most experienced hands less effective, sometimes, than their promise. On the other hand, the result is often surprisingly satisfactory.

Finally, I would say that I do not, as formerly, advise an early operation in children. There may be exceptional cases when this might be desirable, but in general we should wait until the patient is eight or ten years old before operating.

CHAPTER XVI.

THE EYELIDS.

BLEPHARITIS, OR OPHTHALMIA TARSI,

is a follicular inflammation of the edges of the lids, which are red and swollen. Excessive secretion from the follicles of the cilia produces a morning agglutination of the lids in the beginning, and later, in severe cases, the secretion becoming purulent, there are pustules and superficial ulceration, the cilia fall out, the tarsal border becomes thickened and rounded, the lids are crusted, the puncta lachrymalia no longer catch the tears, and the excoriation and irritation of the edge of the lids are kept up by their constant overflow. The cause of the affection in mild cases may be over-use of the eyes, especially in an unwholesome atmosphere, and such causes, generally, as tend to produce a hyperæmia of the conjunctiva. Quite frequently an error of refraction is the primary cause of the trouble. Severe cases occur mostly in ill-fed and ill-housed scrofulous subjects, and often as a sequence of ophthalmia scrofulosa, or of exanthematous fever.

Treatment.

In mild cases, rest of the eyes, avoidance of impure atmosphere, the application to the edge of the tarsi at

night of vaseline or of an unguent of one grain of white precipitate to a drachm of vaseline, will suffice to cure. The correction of refraction by proper glasses is sometimes all that is necessary. In severe cases, in bad subjects, we must rely chiefly on the constitutional means mentioned under Conjunctivitis Scrofulosa. The name of the unguents recommended for these cases is legion, but I find one better and simpler than the others, and generally as effective as can be expected for an inflammation which may be regarded, often, as a local manifestation of a constitutional disease. It is made of two grains of the red oxide of mercury to a drachm of vaseline; a small portion is rubbed between the cilia or along the edge of the tarsi at night. Cleanliness must be rigidly insisted on; the crusts must be soaked off with tepid water, or milk and water, or warm water to which a little bicarbonate of soda has been added, every morning, or no treatment will avail much. For excoriated lids from overflow of the tears or eczema, a lotion of ten grains of borax to the ounce of water, to which a few drops of glycerine may be added, or a solution of one grain of the acetate of lead to an ounce of water, with the addition of a few drops of glycerine, will be grateful to the exposed surface, and prove useful at least as a palliative. Boracic acid can be used similarly, and an unguent, two grains of the acid to a drachm of vaseline, may be used on the edges of the lids. In such cases, slitting up the canaliculus, as directed in the next chapter, will often aid the tears in finding their proper channel.

HERPES ZOSTER FRONTALIS. (SEU OPHTHALMICUS.)

A number of affections of the eye have been observed associated with herpes zoster frontalis; among them are conjunctivitis, corneitis, ulceration of the cornea, iritis, paralysis of the third nerve, and the ophthalmic branch of the fifth. I once had a case of retinitis due to this affection. It has been noticed that unless the vesicles spread to the nose, the eye usually escapes all complication in the disease; and that the affection of the eye is generally most severe when the vesicles extend downward to the tip of the nose. The treatment of the eye will be mostly palliative, and such as has been given in this work in its proper place. The cure will depend upon the removal of the herpes zoster. The prognosis in such cases is good, except in old and feeble subjects.

MALPOSITION OF THE LIDS.

Ectropium, Eversion of the Eyelids,

may be caused by the various ophthalmiæ, and by cicatrices from injuries. Arlt, of Vienna, used to advise us in these cases to bandage the eye, the indication being to shorten the lids and to protect the exposed mucous surface from the air. The pressure is to be made by means of charpie and the bandage, not upon the eyeball, but at the angles of the lid, chiefly at the inner angle, so as to increase the tension of the orbicularis. After three or four days the improvement will be decided, provided the bandage has been readjusted whenever displaced.

Entropium, Inversion of the Lid,

is due generally to old purulent or granular ophthalmia, in which, both from the disease, and the prolonged use of caustics, structural changes of the conjunctiva have resulted. It is sometimes due, in the lower lid, to a spasmodic affection. *Trichiasis*, the turning inward of the eyelashes, and the consequent irritation of the surface of the cornea, is a usual feature of this affection. *Distichiasis*, a double row of cilia more or less regularly placed, results also from old ophthalmiæ. The cilia may be extracted in these cases with the cilia forceps. The simple excision of a fold of the skin beneath the lower lid will sometimes remove the entropium. In the treatment of ectropium and entropium, the palliative measures mentioned for ophthalmia tarsi and the medical and hygienic treatment recommended for scrofulous ophthalmia will always be indicated. In severe cases surgical means will be required also. For the multitude of operations suited to the various phases of these affections, I am reluctantly obliged to refer the reader to the more comprehensive surgical works. Syphilitic and cancerous ulcerations of the lid, the latter being usually of the rodent or epithelial variety, require the same medical treatment as if situated elsewhere. I have no new experiences to offer. A case of rodent cancer of the lid, now under my treatment for about six weeks, and of several years' standing, is improving under arsenic, internally, and Simpson's paste, externally.

TUMORS OF THE EYELIDS.

Chalazion, or Meibomian Cyst,

is a morbid enlargement of a meibomian gland, generally isolated and in the upper lid, but sometimes found in the lower lid, and sometimes a number are noticed in one lid at the same time. They are recognized at first as small hard prominences which, as they grow larger, gradually become softer. The contents are gelatinous, or semi-fluid, occasionally nearly fluid. Exceptionally they are hard or cartilaginous. Such tumors are usually an indication of impaired health. Mothers are frequently subject to them after confinement and nursing.

Treatment.

These cysts not unfrequently disappear without treatment. Sometimes the prescription of glasses to correct an optical error is all that is needed. Occasionally the application of an unguent of four grains of red oxide of mercury to an ounce of vaseline, applied to the tumor, night and morning, with attention to the general condition and the exercise of patience suffices to cure. Otherwise an incision is to be made in the tumor inside or outside the lid, and the contents removed by a small spoon or curette. A four per cent solution of cocaine is to be used, and may be injected into the tumor before incising, if desired. The Snellen forceps or tourniquet is useful to control the bleeding. See Fig. 10 on page 36.

OTHER TUMORS OF THE LIDS

are the *sebaceous*, or *dermoid*, which appear at the upper and outer margin of the orbit, but sometimes at the lower and inner, and when annoying are to be dissected out; probably no medical means will suffice for their removal. Milium or molluscum, small white tumors, are to be pricked or incised, and their contents squeezed out. *Nævi*, and *aneurisms by anastomosis*, are to be treated as in other parts of the body. *Warts* may be ligatured, or snipped off with the scissors.

HORDEOLUM, OR STYE,

is a small boil at or near the margin of the lid. It is rarely necessary to lance it. At the commencement, if the fever and pain are considerable, cold compresses and aconite are indicated. If dependent on general debility of the patient, the disease will be likely to recur unless the general health is restored, and often an error of refraction to which the recurrence of the affection may be due, should be corrected by glasses. *Abscess of the lid* is generally the result of injury. The treatment will be precisely the same as for abscess in other parts of the body. In case lancing is necessary, the incision should be made in a horizontal direction, so that the cicatrix remaining will be unnoticed.

EPICANTHUS

is a crescentic fold of skin overlapping the inner canthi of the eyes, giving the face in this region an Asiatic aspect. Operations are undertaken solely for

cosmetic considerations. I remember a case of epicanthus at Sichel's Clinic, in Paris, in a girl six or seven years of age. Sichel advised pinching up the skin at the bridge of the nose with the fingers, "ten or twenty times a day for five minutes." The deformity is congenital, and decreases as the child grows older. The operation for it consists in excising vertical folds of skin in the spaces between the eyes and uniting the edges of the wound with sutures.

PARALYSIS OF THE ORBICULARIS, LAGOPHTHALMOS,

prevents complete closure of the lids. After a time the eye becomes irritable from constant exposure; lachrymation, conjunctivitis, corneitis, and other evils follow. If the cause of the disease is peripheral, from exposure to cold or dampness. the remedies indicated for rheumatic affections generally will be indicated. The eye should always be shaded, or lightly covered. For the treatment when due to central or cerebral causes, see Treatment of Paralysis of Muscles of the Eye.

SPASM OF THE ORBICULARIS, OR BLEPHAROSPASM,

is met most frequently in scrofulous ophthalmia. It is a spasmodic closure of the lids, associated with affections of the eyes where considerable photophobia is present. It is met with in purulent and granular ophthalmias, keratitis, iritis, hyperæsthesia of the retina, in supraorbital neuralgias, and in cases of foreign body in the eye. With the removal of the above affections, the nature and treatment of which are spoken of elsewhere, the spasm of the orbicularis ceases.

Sometimes the disposition to spasmodic closure of the lids becomes chronic, and long and patient treatment is necessary to effect a cure. A case of mine of a year and a half standing, due apparently to hyperæsthesia of the retina, recovered under the administration of nux vomica and gelsemium and the use of colored glasses. The affection may be due to an accommodative or muscular asthenopia, and requires treatment as such. Occasionally, in severe neuralgia, when the spasm can be relieved by pressure over a branch of the fifth nerve, the branch has been divided by incision, and the disease cured. *Nictitation*, a slight convulsive twitching, or too frequent winking or blinking of the lids, is often noticed in very nervous or hysterical individuals. It often accompanies other nervous debility, is greatly increased by mental agitation, is sometimes under control through great effort, and at other times quite involuntary. It is often incurable, but may sometimes be removed by improving the condition of the nervous system of the patient. It is occasionally also an indication of eye strain from muscular or accommodative asthenopia.

PTOSIS,

or drooping of the upper lid, may be due to paralysis of the third nerve, or of the branch which supplies the levator muscle. In such instances the treatment should, in the main, be that laid down for paralysis of the ocular muscles. It is occasionally an objective symptom of eye strain.

The disease is sometimes congenital, and sometimes

the result of injury. An operation may be performed for its relief, but is not advisable unless the ptosis is nearly or quite complete, and occasions great inconvenience. The best operation is that for the subcutaneous contraction of the upper lid. A transverse incision is made along the margin of the lid, about two and a half lines from its edge. The lips of the wound being drawn apart, the integument is dissected from the orbicularis until the latter is sufficiently exposed. A horizontal strip of the muscle, three or four lines in width, is then excised, and the wound closed by sutures, which pass through the skin and the cut edges of the orbicularis.

Cases of partial ptosis in feeble persons from tumefaction of the lid due to effusion beneath the skin are not unfrequent, and are to be relieved only by such general measures as the impaired health demands.

CHAPTER XVII.

THE LACHRYMAL APPARATUS.

EPIPHORA,

OR the excessive secretion of tears, is due to some mechanical irritation of the eye like that of a foreign body, an inverted eyelash, to a conjunctivitis or ophthalmia, and to deep-seated inflammation of the eye. It is frequently a reflex nervous symptom in mental emotion and in various disorders of the general nervous system. The treatment must, of course, be directed to the removal of the irritation. It is perhaps doubtful whether hyper-secretion of tears, due to functional disorder of the lachrymal gland, and independent of affections of the eye, ever exists. Profuse lachrymation is not a symptom of any of the recognized diseases of this gland.

STILLICIDIUM LACHRYMARUM,

or the ordinary "watery eye," is an entirely different affection, and may always be suspected when one eye alone is affected, and no immediate cause of irritation is present. It arises from an obstruction to the flow of tears through the lachrymal passage. Finding no exit, the tears collect along the margin of the lower lid, and finally drop slowly over its edge upon the cheek. The lid, after some time, becomes red and swollen from this

constant moisture, and we have a monocular blepharitis or ophthalmia tarsi. When the lower puncta have become everted or obliterated so as no longer to catch the tears, the punctum and canaliculus are to be slit up, thus converting the outlet into an open channel.



Fig. 74.

Fig. 75.

SLITTING THE CANALICULUS

is a very simple operation, but by no means as easy as simple. I generally dilate the orifice somewhat with a delicate probe, and then putting the lid slightly upon the stretch, slit the canal with a pair of fine sharp-pointed scissors. I prefer to use the scissors because they are handy, and with the previous instillation of a four per cent solution of cocaine the operation becomes painless or comparatively so. Many operators insert a fine grooved director, and using it for a guide, slit the canal with a cataract knife. Others use a probe-pointed knife, like that of Weber (Fig. 74), or probe-pointed scissors, and still others, the instrument of Giraud Teulon, combining the grooved director and a spring knife. Fig. 75. Many surgeons prefer to open the upper canaliculus as affording a more direct way to the sac. When the upper lid is drawn well back, the direction of the canaliculus is almost in a line with the direction of the sac,

and the abrupt change of the probe from the horizontal to the vertical position, necessary when passing it from the lower canaliculus, is avoided. The upper canal is readily slit with a delicate probe-pointed knife like Weber's.

In rare instances the canaliculus may be obstructed by a foreign body, such as an eyelash, or a minute chalky concretion, the removal of which effects a cure of the case.

ACUTE INFLAMMATION OF THE LACHRYMAL SAC

comes on rapidly, and is often mistaken for erysipelas of the face. The region about the inner angle of the eye is exquisitely sensitive to touch, the lids are red and œdematous, and the inflammation and pain over the sac are intense until it bursts, when complete relief ensues. The cause of inflammation and suppuration of this kind is very likely to be a previous obstruction to the flow of tears due to a catarrh or blennorrhœa. Retention of the secretion in the sac gives rise to dilatation and hypertrophy, and favors the formation of abscess. Repeated suppuration leads to complete obstructions of the passage, to lachrymal fistula, and to disease of the lachrymal or superior maxillary bone. Nasal polypi sometimes obstruct the lachrymal passage. The treatment of these diseases of the lachrymal duct and sac will necessarily be mechanical as well as medical and topical.

Treatment of Acute Inflammation of the Sac.

Aconite and belladonna, in this affection, will be required internally, with cold, or perhaps ice-water com-

presses externally. By these means the formation of abscess and bursting of the sac, or the necessity of lancing the sac, are frequently averted. Another means of averting perforation is to slit the upper canaliculus, and passing down a narrow knife, incise the neck of the sac, which makes a free opening upward for the exit of pus. If the disease has progressed so far that suppuration is inevitable, it is better to change from cold to warm applications. If the sac is very much swollen, and the skin over it has become thin, so that bursting is imminent, it is advisable to lay it open in a downward and slightly outward direction. If left to find its own way out, the matter may escape at some ulcerated portion of the sac, which permits it to flow beneath the adjoining cellular tissue, and thus create additional swellings and finally find its way through the skin at considerable distance from its original seat. Our object should be to prevent complications of this kind, and to give the freest and speediest exit to the pus. After opening, the lips of the wound should be kept apart by a bit of lint to permit of free discharge, and the swelling poulticed if necessary. After a few days, when the inflammation has subsided, the canaliculus should be opened, and a probe passed into the sac to afford a free entrance and exit for the tears. The external opening of the sac may then be allowed to close.

If a considerable discharge of muco-purulent matter continues, the sac and duct may be syringed out with cold water daily, or with some anti-septic solution, — ten grains of boracic acid, or five grains of argentum nitricum, each to an ounce of water, I often use. The solu-

tions are to be employed daily, or every other day. To syringe the sac thoroughly, it is sometimes requisite to pass a cannula quite into it, attaching the syringe, like that of Fig. 76, to the mouth of the cannula afterwards. If necessary to the introduction of the cannula, which is perhaps as large as a number four to six of the Bowman probe, the neck of the sac and the internal palpebral ligament may be incised with a probe-pointed knife.

The selection of internal remedies is very much controlled by the general condition of the patient and by

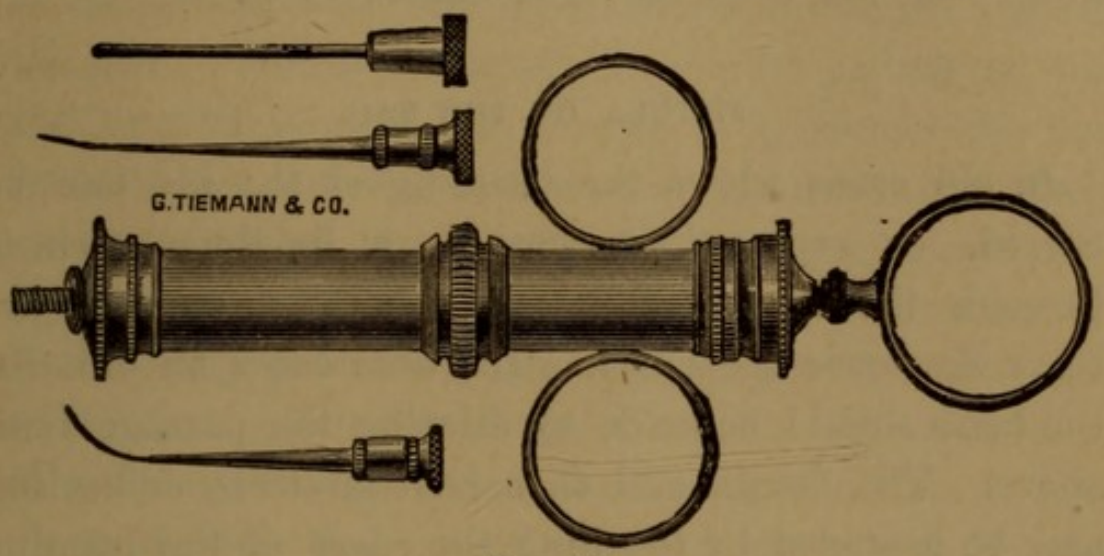

FIG. 76.

the diathesis. In scrofulous subjects, for instance, mercury, sulphide of calcium, or iodide of potash seem to be especially suitable, and will be indicated sometimes by the general symptoms. In other instances, remedies often selected for symptoms but remotely connected with the disease in question have been serviceable. In chronic cases, unless very mild, and of periodical recurrence, when internal remedies are curative through the restoration of the general health, mechanical means will be necessary as auxiliaries.

DILATATION OF THE SAC FROM DISEASE.

Firm pressure upon the sac will hasten its reduction to the normal size and condition. This can be made by a thick compress held in its place by a bandage. In chronic dilatation of the sac, where it is desired to apply the pressure for a considerable period, it has been found convenient to use a small spring truss, attached to a narrow band passing around the head horizontally just over the eyes, and kept in place by another band running over the head at right angles to it.

FISTULA OF THE SAC.

In old cases where the bursting of the sac has occurred, or repeatedly occurred, a fistulous opening through the skin remains; and by this channel the tears flow over the cheek. In these cases an exit for the tears should be made by dilating the passage from above. The fistula will then heal of itself, or healing may be hastened by touching the edges of the opening with a crayon of mild nitrate of silver, or sulphate of copper. In cases of this kind, disease of the bone is sometimes present, and treatment, if undertaken at all, is often unsatisfactory.

CHRONIC CATARRH OR BLENNORRHŒA OF THE LACHRYMAL PASSAGES,

may result from an acute inflammation of the sac; more frequently it is an extension of a nasal catarrh, and in my experience, it appears sometimes to be an idiopathic disease which comes on slowly and insidiously.

A patient presents himself to be cured of "watering" of an eye. He will hardly be able to inform us accurately of the date of the commencement of his trouble. It was first noticed in cold weather, and especially when out in cold winds. Afterwards, it was annoying in-doors, occasionally, and now the "watering" of the eye is continuous. We diagnose the case at once by putting a finger over the lachrymal sac and pressing gently upward, when a muco-serous discharge wells out through the punctum. It may be possible at this stage of the affection to press the contents downward through the nose. However this may be, if the patient is willing to give himself the trouble to press out the contents of the sac *several times a day*, avoid cold winds, over-exertion of the eyes, and pay proper attention to the condition of his general health, the chances are that he may go on for years, and perhaps for a lifetime, without any increase of the disorder. In addition to these hygienic regulations, mild collyria of zinc or alum dropped into the inner corner of the eye will often prove greatly beneficial. I have occasionally effected a cure by syringing the passage with mild astringents without resort to the probe. Furthermore, when the general health is at fault, one may sometimes remove the lachrymal disorder by restoring the system to a healthy state.

Treatment by Probing.

Patients are frequently impatient under the above treatment, and unwilling generally to follow such strict hygienic rules; they desire a treatment of some definite

duration, and which offers at the same time a tolerable chance of permanent cure. We then proceed to the removal of the stricture or strictures of the duct by probing. The probes used are usually of silver wire of uniform size throughout, like Bowman's. See Fig. 77. The Bowman probes are numbered from one to six or eight, No. 1 being quite fine, and No. 8 about one sixteenth of an inch in diameter. I generally commence with No. 2, and rarely go beyond No. 4 in size. The probes are flexible, and will remain bent in any direction we may desire. Generally, the probe finds its way into the duct more readily if bent slightly at the end before introducing. In probing the left duct, we stand before the patient, and keeping the concavity of the bent probe always towards us, enter the canaliculus, which has previously been slit up, or previously dilated for our purpose, pass-

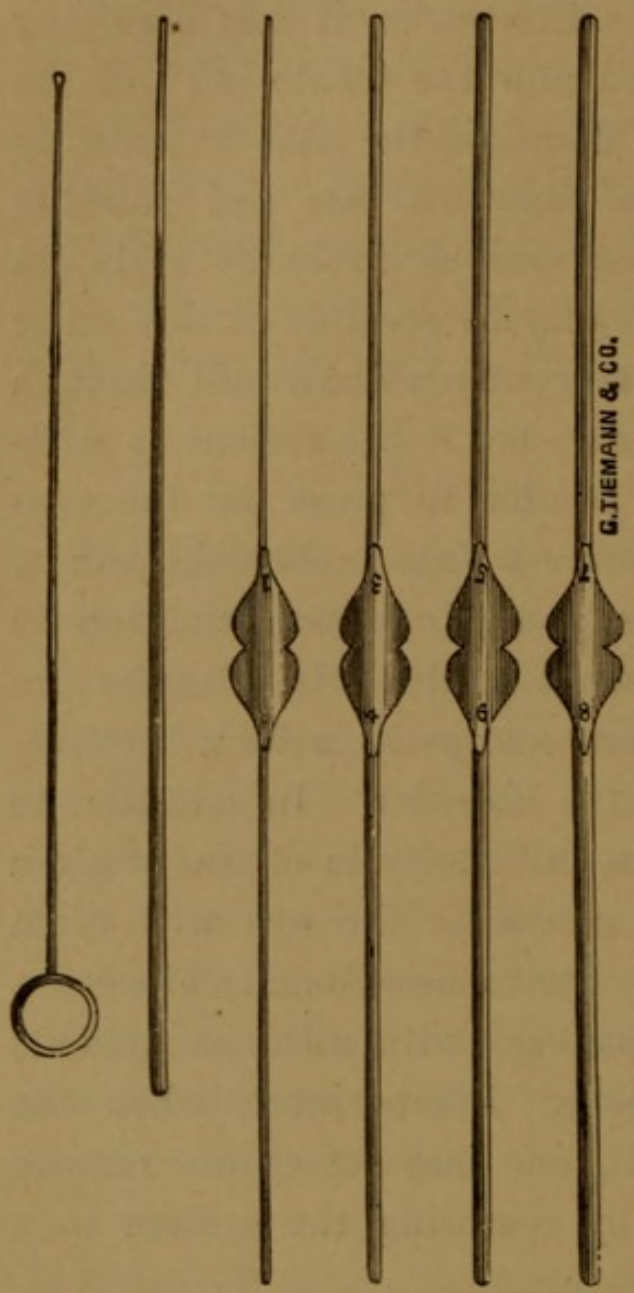

Fig. 77.

ing the probe in a horizontal direction, inclined slightly upward, at the same time stretching the integuments of the lower lid outward. Having reached the sac, as determined by the firm resistance of its inner wall to the end of the probe, and by the observation that the integuments at the inner angle of the eye do not appear to resist the probe or move forward with it, we turn the instrument in a vertical direction, and pass it down into the sac. To find and enter the nasal duct readily, the direction of the probe will now require to be slightly changed, so that its extremity shall point a little outward and forward, and, having entered the duct, it is to be pressed gently downward to the floor of the nose. If operating on the right lachrymal passage, we may hold the probe in the left hand, or stand behind the patient and use the right hand.

The probe may remain from ten to twenty minutes unless irritation or pain is felt, in which case it may be better to leave it only from one to five minutes.

A stricture may be situated at any point of the passage. Its most frequent seat is where the canaliculi join the sac, or below, where the latter is narrowed into the nasal duct. It is to be overcome by firm, but gradual and gentle pressure downward. Frequently a change from a larger to a smaller probe will be successful. Generally, however, the larger one is to be preferred if much pressure is necessary, as less likely to lacerate the lining membrane. Tact, gentleness, and sometimes a good deal of perseverance are requisite. One may sometimes try for two or three weeks, at intervals of two or three days, before overcoming a

stricture. When we find it impossible to enter the sac from the lower canaliculus, we may succeed, perhaps, from the upper, or it may be necessary to divide the stricture, before the probe can be introduced, with a narrow bistoury. Weber's delicate probe-pointed knife, or the narrow knife of Stilling, are suitable. The conical probe of Weber (Fig. 78), which increases rapidly

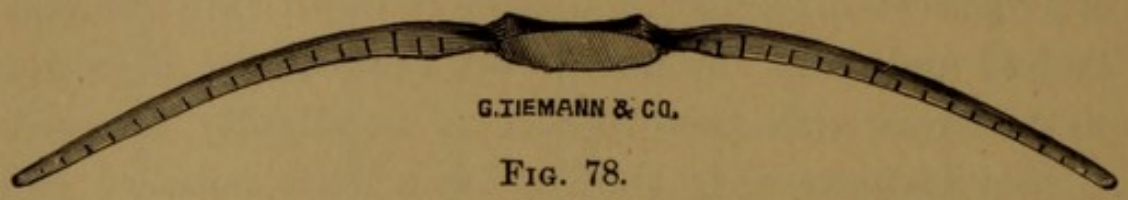

Fig. 78.

in size from the point, may sometimes be used as a dilator to advantage, and the use of the knife be dispensed with. Occasionally, the lining of the sac is so much thickened from inflammation and swelling, that it seems impossible to find the entrance of the nasal duct from the sac. In such instances, we may do better to relinquish all attempts at probing until time and the employment of local and constitutional remedies have reduced the inflammation somewhat, when the probing may be again attempted with better chances of success. Having once succeeded, the operation should be repeated on every second or third day, syringing also with mild anti-septic solutions, until the flow of tears through the passage is unimpeded, and the secretion becomes normal in quantity and appearance.

THE USE OF THE STYLE.

Attempts have been made to obviate the necessity for repeated probing, by the use of styles. Unlike the old-fashioned ones, these styles are introduced, like the

probes, from above, and are to be used for some months. When the discharge is not great they may be worn days or weeks without changing, and it is claimed that the irritation set up when the style is first attempted to be worn, soon passes off, and the patient finds it comfortable. They are made of silver or lead of different sizes, and may be flattened at the upper end so as to be bent over the lower lid like a hook. The styles are of wire, from one twenty-fourth to one twelfth of an inch or more in diameter, and one and three-quarters if for the lower, or two inches in length if intended for the upper canaliculus.

METHOD OF STILLING.

The method of Stilling proposes to cure the disease radically by a single operation. He first finds the seat of the stricture by probing, and then withdrawing the probe, introduces a small narrow knife in its place, and incises the stricture in three or four different directions. This method with probing or the wearing of a style afterwards is a usual one at the Moorfields Hospital, London. It may be a *dernier ressort* in obstinate cases, even if too severe a procedure for ordinary practice.

GENERAL REMARKS.

The most frequent obstacle to the permanent cure of catarrh or blennorrhœa is the tendency of the lachrymal passage to close again after it has been successfully dilated. I believe this tendency may be best overcome by a moderate and gentle dilation of the passages, and, when possible, avoiding all bruising, lacerating, and

even cutting of the lining membrane, and then by constitutional and local remedies endeavoring to restore the diseased mucous surface to as healthy a condition as possible. Professor Arlt, of Vienna, rarely went beyond the No. 4 Bowman probe, in size. He preferred not to risk a rupture of the epithelial lining of the passage, and remarks that at its nasal portion its normal capacity is not much greater than a No. 4 probe, and that where the canaliculi join the sac the diameter is less than that of No. 5. The following is his measurement on the cadavre of the sac and duct. A millimetre is equal to about one half of a line: —

THE SAC.	THE NASAL DUCT.
Length, ten. Width, four. Antero-posterior diameter, two millimetres.	Length, about ten. Width and antero-posterior diameter, each one and one-half to two and one-half millimetres.

In the zeal for dilating the duct as widely as possible, so as to prevent its reclosure, the catarrhal inflammation of the lining membrane and the dilatation of the sac are overlooked. I often succeed by using a No. 2 probe alone. Here is a case in point.

Mrs. H., Weymouth, had suffered from blennorrhœa of the right lachrymal passage for three years. May 22. I slit the lower canaliculus, under cocaine, with scissors, but did not succeed in passing probe No. 2. May 24. Passed probe No. 2 after injecting cocaine into the passage. May 28, 30. Passed probe No. 2 in the same way. June 2, 4, 8. Syringed with two per cent boracic acid. June 10. Passed probe No. 2 again. June 14, 18. Syringed with bi-chloride of mercury 1 : 20000. June 27, July 8. The eye is perfectly well.

The permeability of the tear passage, although a necessary stage in the progress of cure, does not always complete it. The abnormally dilated sac is to be reduced by pressure, and the catarrh treated by local and constitutional remedies, otherwise the germs of fresh inflammations are left behind, and the old obstruction reappears.

OTHER OPERATIVE MEASURES.

The operation for obliteration (so called) of the lachrymal sac by incision, and the application of caustics, or the actual cautery, has fallen nearly into disuse. The sac is rarely obliterated by the operation, and the result is generally unsatisfactory. It may be dissected out with the knife with better result it is said.

THE LACHRYMAL GLAND.

The lachrymal gland is subject, in rare instances, to acute and chronic inflammations, hypertrophy, fistula, and to cystic formations. The acute and chronic inflammatory affections of this gland are amenable to such treatment as would be suitable for similar affections in other parts of the body. The disease of the gland is so rare that details of symptoms and treatment may be left for larger treatises. In more than one hundred thousand cases of disease of the eye observed at the Ophthalmic Hospital in London, less than twenty cases of affections of this gland are recorded. It has been observed recently during an epidemic of mumps in three or four cases.

CHAPTER XVIII.

AFFECTIONS OF THE WHOLE EYE AND OF THE ORBIT.

HYDROPHTHALMIA, KERATO-GLOBUS,

DROPSY of the eye (so called), affects principally the anterior half of the eyeball. The peculiar stare which the prominence of the eyes gives the patient is very striking. The corneæ are increased in size, the anterior chambers in depth, and the irides are tremulous for lack of support. The pupils are dilated, and sometimes pear-shaped, and ultimately vision is more or less impaired. The sclerotica grows thin and bluish as the disease progresses, and all parts of the eye are finally involved. The progress of the affection is usually slow. It is probably incurable. Remedies like arsenic, mercury, and those suitable for affections of the cornea generally may be prescribed, in the hope, at least, of retarding the progress of the malady. Surgically, repeated paracentesis corneæ, and iridectomy have been productive of benefit.

EXOPHTHALMIC GOITRE, GRAVES' DISEASE,

as far as progressive bulging of the globe is concerned, resembles dropsy of the eye. It is associated

with hypertrophy of the thyroid gland, palpitation of the heart, and subsequent dilatation of its cavities, anæmia, visceral derangements, and, in females, with amenorrhœa. The disease is also accompanied by great nervous excitement and sometimes a capricious temper. Its progress is slow, and the prognosis is not as uniformly unfavorable as in dropsy of the eye. The treatment cannot be laid down, on account of the almost numberless complications which the disease may present. Hydropathic treatment is to be favorably mentioned as having been serviceable in this affection, and recently strophanthus is reported as useful.

MEDULLARY CANCER OF THE EYE

has been spoken of under the name of *glioma retinæ*. *Melanotic cancer* is probably the same disease, with the addition of more or less black pigment in its structure. *Sarcoma* is a recurrent growth, requiring similar treatment to cancer, but exhibits less tendency to secondary deposits. Before breaking through the anterior tunics of the eye, it has been mistaken for glaucoma. It can only be distinguished from cancer by microscopic examination. *Ophthalmitis*, or suppuration of the whole eye, is noticed in the chapter on the Choroid.

DISEASES OF THE ORBIT.

I have not the space to speak in detail of diseases of the orbit, and must refer the reader to works on general surgery. As regards diagnosis, tumors of the orbit are accompanied by more or less protrusion of the eye, and by diminished mobility of the globe, and sooner or later there is impaired vision. In inflammation and

abscess of the cellular tissue, there will be added to these symptoms pain in and around the ball, and tenderness on pressure of the globe backward. Tumors will generally require to be removed together with the eyeball; and inflammation and abscess will demand the same general treatment as if located elsewhere.

CHAPTER XIX.

INJURIES OF THE EYE.

THE EYELIDS.

For contusions and ecchymoses of the eyelids we have excellent remedies in arnica, hamamelis, and calendula. Lacerated or incised wounds are to be treated as usual in other parts of the body, except that especial care should be taken in accurately approximating the edges of such wounds in the lids, so as to guard against deformity. In burns and scalds, great care will be necessary during the cicatricial period to prevent plastic union of the two lids at the angles. This is to be prevented by inunction with simple cerate, and by directing that the lids be frequently opened. To prevent ectropium and a contraction which might prevent the eye from closing (lagophthalmos), the lids should be kept as much as possible on the stretch, and be bandaged with extreme care. For the same reasons it is always advisable, when possible, to bring the edges of wounds of the lids together by fine interrupted suture, rather than leave them to unite by granulation, and risk a loss of substance and contraction.

INJURIES OF THE CONJUNCTIVA,

of a chemical nature, are quite common. Those from quicklime are of the most serious to which the eye is

subject. Complete destruction of the tissues of the parts with which the lime comes in contact may result. Slaked lime, mortar, and plaster are not so rapidly destructive in their effect, but may in the end prove nearly as fatal. The chief danger, even in cases where the burn is not very extensive or very deep, is in loss of sight from opacity of the cornea. The whiteness of the corneal opacities in these cases is very marked, and it has been shown that the cicatricial tissue reproduced after these injuries contains lime.

The Treatment.

It is wiser not to attempt to neutralize the alkali by the use of weak acid. The eye is intolerant of acids in these cases, and they can hardly be of service unless applied *immediately* after the accident. It is better therefore to resort to olive oil or liquid vaseline at once, a small quantity of which is to be dropped into the eye. The lids are then to be everted, and the loose particles of lime removed with a delicate spatula. If the epithelial layer of the cornea is destroyed, it should be removed, and, if possible, the cauterized portions of the corneal substance should also be taken off, so that the reproduction of tissue may not only be speedy, but that the new tissue may be free from depositions of lime, and transparent. After the application of a few drops more of sweet oil or vaseline, the lids should be closed, cold-water dressings used for the first few days, and aconite administered.

In injuries from strong acids, a solution of carbonate of potash, or soda, five grains to an ounce of water, may

be used at first if the eye is seen soon after the injury; when this is not convenient, warm water may be substituted. Olive oil should then be used. In burns and scalds of the conjunctiva from hot fluids, olive oil should also be applied, the lids closed, and the eye lightly bandaged. Oil should be dropped into the eye two or three times a day, the lids cleansed from all discharge, and the bandage readjusted.

Injuries from gunpowder are sometimes serious, not only from the scorching and burning of the conjunctiva from the explosion, but from the circumstance, also, that unexploded grains of the powder are deposited in and upon the conjunctiva, and are sometimes forced through it into the tissue of the sclerotic, and often imbedded in the substance of the cornea. The lids are to be everted and syringed so as to remove all loose powder, then all superficially imbedded grains in the conjunctiva and cornea are to be removed with the spatula, broad needle, or curved scissors, and olive or castor oil dropped into the eye two or three times a day, and such general treatment resorted to as seems necessary.

Mechanical injuries of the conjunctiva, from foreign bodies such as cinders, dust, particles of iron, steel, glass, and the like, generally occasion a good deal of injection, and not unfrequently severe ciliary neuralgia, photophobia, and lachrymation. In the case of a single foreign body, like a cinder, it will generally be found beneath the upper lid near the edge, and rarely far back in the retrotarsal region. A small spatula may be used to remove it. It is not worth while however for a surgeon to attempt to do this without everting the upper

lid, nor by the introduction of other foreign bodies, like smooth pebbles called eye-stones, or smooth round seeds. Leave such proceedings as these to the foremen of establishments, and to domestic practitioners. The method of everting the upper lid is described elsewhere. A year or more ago a lady came to me for a conjunctivitis of one eye, accompanied by severe ciliary irritation, pain, and photophobia. She had been for three weeks under the treatment of a colleague, and during all this time she thought that she had not had one comfortable night's rest. Her symptoms all pointed to a foreign body, and on everting the upper lid there lay, partially imbedded in the substance of the conjunctiva, a minute bit of quartz with its sharp edges and angles. She had suffered for three weeks, when the exercise of a little circumspection would have relieved her at any time in three minutes. Splinters or other substances beneath the conjunctiva, if found impracticable to remove with delicate forceps, may be cut out with curved scissors. Impalpable particles of dust or sand may be washed out with the syringe and warm water. The use of cocaine will render these manipulations comparatively painless.

In the "American Journal of the Medical Sciences," Vol. L. p. 561, among other cases of neglected foreign bodies in the eye, is that of a German who was treated some time for granulated lids, until finally the cause of the affection was discovered in a neglected "eye-stone" which he had put into his eye six months previously, and which he thought had dropped out while he was asleep, as his wife said she had seen it in the bed. The removal of the "eye-stone" cured the eye. In the

"Ophthalmic Review," Vol. I. p. 337, is related in full the case of an old man who fell to the bottom of the stairs, and applied to a surgeon for a wound in the conjunctiva at the inner angle of the right eye. After a week's treatment the presence of a foreign body was suspected, and the next day a cast-iron hat-peg three and three-tenths inches in length was drawn from the wound. The patient recovered without unfavorable symptoms. Small particles, like gravel or dust, are to be removed by everting the lids and syringing them, and also by the use of the spatula or blunt probe, when necessary. See Fig. 8, p. 35.

ANCHYLOBLEPHARON

is the union of the margin of the lids with each other, either directly or by membranous bands. It is a result of injury, or ulceration from disease. The union is to be severed with the scissors or the scalpel, and reunion prevented by frequent separation, and by anointing the cut surfaces with olive oil.

SYMBLEPHARON

is the union of the inner surface of the lids with the eyeball, and may also be direct and close, or by membranous bands. In the latter case, the bands of union may be divided, and daily dressing with olive oil may possibly prevent a reunion. Generally, however, and especially when the adhesions are at all extensive, it will be necessary to resort to an operation, — namely, the separation of the lid from the ball, and the transplanting of conjunctiva from beneath the upper lid to

the new surface. The cause of the affection is an injury, usually a burn from hot fluid, metal, lime, or mortar.

DIAGNOSIS AND TREATMENT OF FOREIGN BODIES WITHIN THE GLOBE.

The diagnosis is sometimes quite difficult. When the foreign body cannot be seen, with or without the aid of lateral illumination and the ophthalmoscope, we may suspect its presence: —

If the pain does not yield to the usual palliative treatment, and is apparently disproportionate to the visible inflammation.

If the inflammation does not appear to be controlled by the treatment, to the usual extent.

If symptoms of inflammation of the deeper structures of the eye are present.

If there is a circumscribed iritis with exudation, limited to a given point, no foreign body being visible, the eye having been struck by a splinter of metal. I recall a case like this in the clinic of Von Graefe, a famous case where I happened to be present, and in which he made an iridectomy, and then removed the invisible bit of metal from behind the iris.

If there is non-union, or only partial union, of a wound through which a foreign body may have entered the eye.

In cases like the above, where the irritation or inflammation is continuous, an attempt should be made to find and remove the foreign body, and failing in this, the eye should be removed. Where the foreign body

can be seen, it should be removed in all cases when it can be done without serious risk of loss of the eye. It must be extracted at any hazard to the eye if irritation, pain, and inflammation are engendered by its presence, lest sympathetic inflammation destroy the other eye. Inflammation recurring in an eye which has lost all visual power from former injury, whether the presence of a foreign body be suspected or not, demands the removal of the eye. When a foreign body, like a bit of percussion cap for instance, remains in the eye, but causes no irritation, the sight of the eye being unimpaired by it, and its extraction would be hazardous to the eye, it may be left in its place; but the patient should be enlightened as to the nature of the risk he is taking, and instructed to return to the surgeon if symptoms of irritation come on in the injured eye.

THE USE OF THE MAGNET IN THE DIAGNOSIS AND REMOVAL OF FOREIGN BODIES FROM THE EYE.

The employment of the magnet in ophthalmic practice is not of recent origin. The "British Medical Journal" for July 17, 1880, gives the following quotation bearing date A. D. 1745: "There was one in Salisbury who had a piece of iron or steel stuck in the iris of his eye. The person was in very great pain, and came to me. I endeavored to push the iron out with a small spatula, but could not, and then applied a loadstone to it, and immediately it jumped out." There is lately a revival of interest in the use of the magnet, and a number of successful cases are reported. Either permanent or electro-magnets are used, and the foreign body to be

removed must, of course, be a fragment of either iron or steel. The presence of a bit of either of these metals hidden within the eye may sometimes be made known by the pain induced through the influence of a powerful magnet held near the affected eye. If, however, an eye in which there is known or suspected to be a foreign body *has become blind*, there should be no hesitation in advising its removal. Perhaps an exception might be made if the patient is intelligent and lives near the surgeon, and the eye is painless, and not tender to the touch in the ciliary region.

THE CORNEA.

Injuries of the cornea are more to be feared than those of the conjunctiva, from the fact that opacities upon its surface impair vision. Fragments of metals, or splinters, in its substance occasion great ciliary irritation, pain, injection, photophobia, and lachrymation. If the foreign body, owing to its small size or color, is difficult of detection, the pupil may be dilated with atropine so as to enlarge the dark background, and then oblique illumination and a magnifying glass employed. A delicate spatula or broad needle may be used for removing the foreign substance, and in all cases cocaine is to be used. Chemical injuries of the cornea may be treated as directed under Injuries of the Conjunctiva. Clear cuts or punctures of the cornea heal readily, and generally leave no scar behind. The danger in these cases lies in the possibility that the iris or the lens may have been wounded, and iritis or cataract supervene. The treatment of wounds or injuries of the cornea re-

quires entire rest of the eyes, if the ciliary neuralgia be considerable; warm fomentations and the instillation of atropine and cocaine as palliatives are required. Olive oil or castor oil is very grateful to the eye after the removal of a foreign body and in abrasions of the epithelial surface of the cornea, and a simple bandage should be applied over the closed lids.

THE IRIS AND LENS.

If a wound of the iris is clean, with no laceration, it may heal at once without iritis or suppuration. If a bit of iris protrude through an opening in the cornea, and cannot be readily replaced, either by careful manipulation, or the employment of atropine or eserine, it may be excised. Foreign bodies — such as bits of percussion cap, or steel — remaining in the substance of the iris will almost invariably set up an iritis, and should therefore be removed by an iridectomy, excising that portion of the iris in which the foreign body is situated. Injuries of the cornea and iris, like other injuries, sometimes result much less disastrously than we have reason to predict. I recall the case of a child two years old, that had run the blade of a pair of scissors into the right eye towards the inner angle, penetrating the cornea and iris. I expected, of course, traumatic cataract; but the direction of the instrument was such that the capsule of the lens was left intact. Iritis ensued; yet the eye finally recovered perfectly, leaving no corneal opacity behind, and no deformity, except a slight displacement of the pupil from a small synechia posterior, at the point of perforation of the iris. Now, after twenty

years, the deformity is hardly noticeable. In all wounds, when the anterior or posterior chamber has been entered, the eye should be bandaged immediately.

Hemorrhage into the anterior chamber may result from a wound of the iris, or from a detachment of its ciliary border. It may be so extensive as to completely hide the pupil and iris from view. I have known it to occur to this extent in the operation of iridectomy. It is the least dangerous form of intraocular hemorrhage, and the blood is usually soon absorbed.

When a wound of the anterior chamber is large, and the iris bulges, forming a sac distended with aqueous humor, it is not safe to excise it lest a farther prolapse occur. It should be pricked at intervals with a fine needle, so as to cause it to dwindle, and permit the edges of the wound to approximate. Later, it can be excised, if necessary. Traumatic cataract has been already spoken of.

Hemorrhage of blood into the vitreous is not very uncommon, either from disease of the coats of the vessels, or as a result of a traumatic injury to the choroid. It is sometimes distinguishable by a red reflex, with the ophthalmoscope; at other times the fundus is completely darkened, and cannot be lighted up.

I have recently seen a copious bleeding into the vitreous of one eye in a case of posterior polar cataract in an otherwise healthy man twenty-seven years old. It occurred at once, and during an interval in his visits to me. As this form of cataract is often connected with a diseased fundus, the hemorrhage is probably due to choroiditis; but in some instances the cause is more ob-

scure. I remember a girl of eighteen, in apparently good health, who had repeated bleeding in both eyes. The blood was partially absorbed, but the final outcome was a large scotoma in either eye. In a strong woman of forty-eight, after cessation of menstruation, bleeding took place into the vitreous of the right eye from the ciliary region, repeatedly during three years at intervals of some months, and was repeatedly absorbed, until finally a larger hemorrhage occurring, the eye became totally blind and remained so. The left eye is entirely free from disease since the other was lost, in 1887. The systematic use of hot water (from 105° to 110° Fahrenheit) for fomenting the eye daily, appeared to hasten the absorption of the blood in this case, before the hemorrhage became too copious.

THE SCLEROTIC.

Incised wounds in the sclera are not usually dangerous unless very extensive, but do not heal as readily as wounds in the substance of the cornea. Care must therefore be taken that the edges of the cut approximate exactly, and, if necessary to this end, a fine suture may be employed. *Rupture of the sclerotic* is a far more dangerous accident, frequently involving dislocation of the lens, prolapse of the iris, great loss of vitreous, and internal hemorrhage of the eye. Soothing applications should be made, and if after a few days no perception of light return, it is better and safer to enucleate the injured globe. *Injuries in the ciliary region* are especially dangerous as giving rise to sympathetic ophthalmia.

SYMPATHETIC OPHTHALMIA (CYCLITIS),

or *ophthalmia migratoria*, is an inflammation set up in a sound eye as the result of injury to the fellow eye in the ciliary region. As sympathetic ophthalmia does not uniformly follow such injury, it is probable that septic poisoning in the wound is usually a primary factor of causation. The micro-organisms reach the second eye through the medium of the optic and ciliary nerves. It is a matter of some doubt whether sympathetic inflammation ever occurs except after perforation of the eyeball of the first eye. This point, however, may still be disputed. The disease may follow an ulceration of the cornea or a cyclitis in the first eye, if a perforation occur, and it is often, or not very unfrequently, due to an operation on the first eye, for cataract, glaucoma, etc. Foreign bodies remaining within the eye are also a frequent cause; and although such bodies may not give rise to irritation in the wounded eye for many years, where once the irritation occurs, sympathetic ophthalmia in the other eye is often the result. Sympathetic disease is never to be considered impossible so long as there is tenderness of the injured eye to touch in the ciliary region.

The nature of sympathetic ophthalmia is that of serous or plastic and destructive cyclitis, which spreads rapidly to the iris and the choroid. In the beginning there is irritation, some injection of the conjunctiva, photophobia, lachrymation, increased tension, and severe asthenopic symptoms quickly supervening upon any attempt to use the eyes for reading, or for any sim-

ilar purpose. At this stage of the affection there is no pain when the eyes are at rest; later, there may be supraorbital neuralgia, great effusion of lymph, adhesion between the iris and anterior capsule, the choroid and vitreous become involved, and atrophy of the latter is followed by softening of the globe.

ENUCLEATION OF THE INJURED EYE.

The only justifiable course to pursue when sympathetic ophthalmia threatens in the uninjured eye is to remove the injured one at once. Enucleation of the ball, under complete etherization of the patient, is not a formidable procedure. The lids are to be well separated by a speculum; one or two assistants with sponges or absorbent cotton should be near to remove the blood during the operation, so that the view of the operator may be as little obstructed as possible. Suppose the left eye to be removed. The operator stands in front of the patient, who lies on a couch. Seizing the conjunctiva at the outer side of the globe near the insertion of the rectus externus, with the forceps, he makes an incision, and carries his blunt-pointed scissors quite around the circle of the cornea, dividing the conjunctiva as near the corneal limbus as possible. He then inserts a blade of the curved scissors beneath the external rectus, and divides it close to its sclerotic insertion. Relinquishing now his first hold with the forceps, he seizes the globe at the point of insertion of the rectus muscle, just divided, in order to obtain a firmer hold so as to move the eyeball at will. The superior and inferior recti and oblique muscles are successively

divided with the scissors close to the ball, and then with larger scissors, the globe being pulled as far forward and towards the nasal side as possible, the optic nerve is cut; a gush of blood follows from the ophthalmic artery, the forceps are relinquished, the ball is grasped with the fingers, the rectus internus divided, and the enucleation is completed. The hemorrhage is trivial, and readily controlled by cold water. In case of encephaloid of the globe, or tumors of the orbit, and like cases, the difficulties of the operation are much increased, and the various steps in it will be different, and other instruments may be necessary.

WHEN TO REMOVE THE INJURED EYE.

How soon, after the first symptoms of sympathetic irritation manifest themselves in the sound eye, shall the injured one be removed? Inasmuch as symptoms of irritation do not always give rise to the disease, and as the disease, if it occur, is not absolutely certain to be of that fatal type which ends in destruction of the eye and the total blindness of our patient, how long may we wait with safety? This question is sometimes difficult to answer; but in case the injured eye is already blind, or all hope of restoration of vision lost, we need not wait at all, for in such an event its removal is in no respect contra-indicated, and will in all probability guarantee the integrity of the remaining eye, *provided no symptoms of sympathetic ophthalmia have yet made their appearance.* After sympathetic disease has once commenced in the uninjured eye, the removal of the other is not a certain, although the best remedy known,

and succeeds in saving the remaining eye, especially if done at an early stage of the disease, in a majority of cases. The sympathetic inflammation usually appears in from three to six weeks after injury to the first eye. It may occur much later, but rarely earlier than this, so that an eye removed within three weeks after its injury is quite sure to prevent the migration of the affection to the sound one. Another means, that of division of the ciliary muscle, has recently been practised with some success. It might be worth while to try this, provided tolerable sight in the injured eye were still probable. An incision in the conjunctiva at that point in the ciliary region which is sensitive to the touch, is made with the forceps and scissors. The eye being steadied, a puncture is made in the sclerotica over the ciliary muscle, with a cataract knife, and the wound is closed with a suture.

The general treatment should enforce the strictest hygienic regulations, absolute rest of the eyes, a subdued light at home, and the protection of dark glasses out of doors. The diet should be nutritious and generous. The pupil should be kept dilated *ad maximum*, unless the mydriatic cause irritation by pulling on the adhesions between iris and lens, cocaine and hot fomentations are to be used to relieve pain, and internal and other remedies such as recommended for iritis are to be availed of.

SYMPATHETIC IRRITATION,

in the uninjured eye, may occur without giving rise to ophthalmia. It may be recurrent, coming on when-

ever there is an exacerbation of the inflammation in the injured eye, but it is to be distinguished from sympathetic ophthalmia by the important fact that no iritis with effusion of lymph is present. There is some injection, lachrymation, ciliary neuralgia, and severe asthenopic symptoms whenever use of the eye is attempted. It is probable that it never results in inflammation, although some writers maintain the reverse.

DIVISION OF THE OPTIC AND CILIARY NERVES

has been devised by Schoeler, of Berlin, as a substitute for enucleation in sympathetic ophthalmia. It is done under anæsthesia. An opening being made in the conjunctiva over the rectus internus or externus, the muscle is divided at its insertion in the sclerotic. The globe then being conveniently rotated, a pair of curved scissors is passed through the opening to the posterior part of the eyeball and the optic and ciliary nerves severed. The hemorrhage is of course considerable: the blood escapes into the cellular tissue of the orbit, the globe protrudes, and there is subsequently severe ecchymosis of the eyelids. Under the use of cold compresses for some days, the blood is, however, absorbed, and any ciliary irritation or tenderness in the other eye rapidly disappears, — the media through which the sympathetic irritation passes being no longer in connection with it. The advantages of this procedure over enucleation are chiefly these: —

The expense and annoyance of an artificial eye are avoided. If the eye, left in its place, is atrophied, it makes an excellent stump for the support of an artifi-

cial one. In children, the removal of an eye changes the development of its surroundings, and this operation offers a chance of escaping this disadvantage. The outdoor exposure of the empty orbit, in the poorer classes, may be avoided.

The disadvantages are chiefly these: —

There is sometimes considerable reaction and pain after the operation, and the effusion of blood disappears slowly.

It is sometimes necessary to remove the eye subsequently, in consequence of the inflammation set up.

The operation may fail, from a reunion of the severed nerves.

It is therefore too early to determine the value of this procedure as a substitute for enucleation. I think the tendency is to adhere to enucleation.

Evisceration or Exenteration,

a removal of the contents of the eyeball, is practised also to a considerable extent. The cornea is excised at its limbus, and the contents of the globe evacuated by the aid of a small spoon or spatula. The reaction is considerable. I have seen at Moorfields a small glass ball sewed up in the cavity of the sclera in place of the vitreous to improve the stump for an artificial eye. It is said to work well. (Mule's operation.)

CHAPTER XX.

THE EYE IN RELATION TO THE GENERAL SYSTEM.

[In considering the eye in connection with the general system, there are three relations in which its importance will be recognized: —

1. As an aid in the diagnosis of diseases otherwise obscure.
2. In regard to its own integrity.
3. As a possible cause of functional nervous disease.

IN DIAGNOSIS.

The conjunctiva may be a valuable index of the condition of other mucous structures. The constant hyperæmia of the *bon vivant* is no less characteristic than the blanching in the sclerotic. In the cornea too, the dulness or brilliancy of reflex will indicate the physical tone of the system in general. The annular zone or arcus senilis occasionally found may suggest a fatty heart or atheromatous degeneration of the arteries.

The pupil, through its intimate connection with the spine by way of the sympathetic, and with the brain by the motor oculi may indicate profound central lesions. In a case of spinal concussion that recently came under my observation, firm pressure over the seventh cervical vertebra caused instant dilatation of the pupil, and on

relaxation of the pressure, the pupil would immediately contract again.

The contracted pupils of cerebro spinal meningitis are familiar characteristics; while the Argyle Robertson symptom in which the pupils do not respond to light, but contract when the eyes are converged, is one of the early indications of locomotor ataxia.

With the ophthalmoscope the intra-cranial circulation is brought more or less into view, and the continuity of the optic nerve with the brain, and the retinal vessels with those more deeply situated, make it possible to demonstrate conditions which must otherwise be guessed.

Organic kidney lesions may find their first manifestation in an inflamed retina, while a retinal hemorrhage may anticipate by months the coming apoplexy. An optic neuritis is sometimes the only evidence of a chronic meningitis or pressure from a brain tumor, and a defective visual field may serve to localize a cerebral neoplasm. Protrusion of the eyeballs may be the first symptom of morbus Basedowii, and diplopia or ptosis the earliest indication of an approaching paralysis.

THE SECOND IMPORTANT RELATION

in which the eye must be considered in systemic diseases is that in which its own integrity may be threatened.

In the *eruptive fevers*, the eyes should always be watched. The catarrhal ophthalmia with which measles is ushered in is usually conjunctival. In those predisposed from malnutrition, bad hygiene, or scrofulosis, the cornea may be involved, and phlyctenulae form, although

destructive inflammation rarely ensues. The eyes are frequently left weak and sensitive, however, long after the eruption has disappeared.

In *scarlet fever*, there is often some hyperæmia of the conjunctiva coincident with the skin eruption, and exceptionally, keratitis. In a malignant case which came under my notice, a general tendency towards pus formation was present. Abscesses formed around the finger nails, in the palms of the hands, in the forearms, over the sternum, in both ears, and in the anterior chamber of both eyes.

In *meningeal inflammation*, whether uncomplicated or occurring as a feature of an eruptive fever, the nervous structures are more frequently attacked. In an examination of the inmates of the State Asylum for the Blind, at Batavia, New York, after corneal opacities and staphyloma from some form of purulent ophthalmia, the largest number of inmates were found to have optic nerve atrophy following meningitis.

If in *diphtheria* the exudation appears in the conjunctiva, danger to sight is imminent. The substance of the lids becomes densely infiltrated, the tissue swollen and hard, and the lids are raised only with difficulty. The pressure cuts off the nutrient supply, and unless the intumescence can be speedily reduced the cornea is destroyed. In convalescence, paresis of that branch of the third pair supplying the muscles of accommodation is not unusual. The pupils may be enlarged, though not necessarily, but in near vision sight is blurred. Use of the eyes should not be permitted until this condition has disappeared, or permanent weakness may result.

Before Jenner's time, to *small-pox* was attributed as large a proportion of the prevalent blindness "as to all other causes put together." Now, fortunately, such serious results are comparatively rare. There has been much question as to whether the pustules ever form in the corneal tissue. It seems far more probable, since the microbial origin of pus has been studied, that abscesses are the result of the introduction of bacilli from the suppurating pock into the eye. The epithelium being denuded, the cornea might be easily invaded by the pathogenetic bacteria, and too great care could not be exercised to prevent such infection. Ulcerations, probably from the pock, occur at times in the conjunctiva, and occasionally the canaliculus has been occluded by the resulting cicatrix.

While in *acute inflammatory rheumatism* serious ophthalmias are not common, in the *chronic* form and in *gout*, both the external and internal eye muscles may be affected. Rheumatic paralysis of extrinsic muscles, and iritis, which may take on a relapsing form, are not infrequent. The latter is always a dangerous complication.

Syphilis, the source of so many physical ills, may manifest itself during its course in any of the structures of the eye. The iris is most commonly affected, and the inflammation is usually of so passive a character that extensive adhesions may already have fastened the iris to the lens before the trouble is discovered. Gummy tumors, choroidal inflammations, and, less frequently, retinitis, may be phases of this dyscrasia. Hereditary syphilis may give rise to iritis with cataract, in infants,

and in children from ten to fourteen years of age to a parenchymatous keratitis of a most persistent character.

Scarcely less profound than syphilis in its effect upon the eye is *scrofula*. The lids and anterior portion of the ball are the parts chiefly affected, and the inflammation may be of any grade from the delicate red on the margin of the lids to deep corneal ulcers.

Phlyctenulae, either of the conjunctiva or cornea, are common, and after repeated attacks, if the scars are in the field of vision, the sight is likely to be obscured.

In tuberculosis, the eyes are rarely involved, although deposits are occasionally found in the choroid. In rare instances these deposits precede those in the lungs, and the ophthalmoscope may be of value in determining an early diagnosis. Vision is not usually impaired.

Attention has already been called to the eyes in various forms of *Bright's disease*. In the albuminuria of pregnancy, the retinitis is often rapid in its development. In such a case the eyes, almost as much as the kidneys, may influence the physician in inducing premature delivery. If organic changes have not taken place in the retina, an improvement in the renal condition is followed by better sight. If, however, hemorrhages have occurred and the finer nervous structures in the retina have been destroyed, vision must remain imperfect under the most favorable circumstances.

Valvular diseases of the heart and *atheroma* of the *arteries* occasionally give rise to emboli, which may be carried into the channels of the intra-ocular circulation, causing blindness.

In aörtic insufficiency, pulsation of the retinal vessels

can be discovered with the ophthalmoscope. The high arterial tension predisposes to hemorrhage from rupture of the smaller retinal vessels.

Diseases of the *sexual system* not unfrequently cause disturbance of sight. Irritation of the generative organs, dependent either upon masturbation or other cause, such as a contracted and adherent prepuce or hyper-sensitive and congested ovaries, may give rise to persistent and obstinate asthenopia. Conjunctival congestion or even more profound inflammations may result. The eyes are frequently influenced by *menstrual irregularities.* I have seen retinitis as a result of amenorrhœa, and vision was restored only when the menstrual function was regularly resumed. On the advent of puberty and at the climacteric the eyes are frequently affected, and slight refractive errors may cause serious disturbance.

In *diabetes*, if the sight becomes obscured, the lens should always be examined, as cataract occasionally occurs. The swelling of the lens may give rise to an apparent myopia, and in such a case lenticular opacity may always be looked for.

As might be expected the eyes are frequently involved in diseases of the *nervous system.* In locomotor ataxy, gray atrophy of the optic nerve may ultimately occur; while in cerebral tumors, swelling of the optic nerve — the so-called "choked disc" — is an important feature. The various cerebral nerves supplying the eye may be affected from either central or peripheral causes, and paresis of individual muscles, or of a group having the same nervous supply, is not uncommon.

In *herpes fascialis*, vesicles occasionally appear upon the

conjunctiva or cornea. In such case the resulting ulcers are always slow to heal. When the irruption follows the ophthalmic branch of the trigeminous, the ocular inflammation is much more severe, involving as it may, the iris and deeper structures.

THE THIRD RELATION

in which the eye must be considered in its connection with the general system is that in which it may be a *cause* of more or less severe nervous disturbances.

For a long time headaches have been definitely ascribed to refractive errors, or to imperfect balance of the ocular muscles. The pain is usually frontal or temporal, often in the eyes or back of them, rarely in the vertex, with frequently a drawing sensation extending to the back of the head. These headaches, from some unexplained reason, are often worse in the morning after sleeping. Sick headaches or headaches produced by travel or by watching moving objects can often be traced to some form of heterophoria, and will be relieved by its correction.

Comparatively recent investigation has shown that more remote nervous troubles may be dependent upon eye-strain. I have myself by the correction of astigmatism relieved persistent temporal neuralgia, and by tenotomy of the muscles in heterophorias overcome an insomnia of many years' standing, and great nervous irritation.

In those of neurotic tendency, the number of nervous symptoms which may arise as the result of eye-strain is legion.

Drowsiness is not uncommon, and disturbances of the appetite and digestion are frequent.

Among the symptoms traced directly to the eye, and said to be cured by the correction of muscular and refractive defects, are mental disturbances, aphonia, palpitation of the heart, pain in the ovaries, diarrhœa, rectal irritation, etc.

Reference has already been made to the effect obtained in chorea and epilepsy, by readjusting the muscles in heterophoria. But in these profounder lesions the subject is still *sub judice*, and it can be only by continued investigations, by careful and experienced observers, that the exact relations between cause and effect can be ascertained.

Among the symptoms that should direct attention to the eyes as a cause of nervous trouble, imperfect or painful vision is, of course, prominent. The symptoms of asthenopia, if persistent, should always suggest a possible refractive error, or muscular inco-ordination.

It rarely happens that nervous troubles distinctly dependent upon eye-strain obtain without definite eye symptoms; but it is not uncommon to find the nervous symptoms much the more prominent.

In any case where the symptoms of eye-strain or asthenopia occur, no examination can be considered complete until the eyes and eye-muscles have been subjected to a thorough and comprehensive examination.

F. P. L.]

CHAPTER XXI.

LIST OF A FEW INTERNAL REMEDIES WITH THE OPHTHALMIC AFFECTIONS, OR THE SUBJECTIVE AND OBJECTIVE SYMPTOMS OF THE EYES, FOR WHICH THEY HAVE BEEN FOUND USEFUL IN MY PRACTICE.

THE list which follows comprises merely the remedies which have been administered from indications furnished by the eye alone. Others have been found useful also, but they have been selected on account of symptoms apart from those of the eye, and for such as are familiar to all general practitioners. Many remedies having a strong affinity for the eye, judged by their pathogenesis, have not, in my experience, been found reliable. The diseases or symptoms given below have been repeatedly cured or relieved by a single remedy, the name of which is placed opposite each group. The dilutions or triturations used were the first, second, or third.

ACONITE. In the early stage of inflammations of the conjunctiva, cornea, and iris, and after surgical operations.

ALUMINA. In chronic blepharitis of adults, and in blennorrhœa of the lachrymal passage, with thin discharge.

ARSENICUM. In superficial and deep-seated ulceration of the cornea, especially in scrofulous subjects. Catarrhal ophthalmia, with thin secretion and irritation of the edges of the lids. Ulceration of the tarsal edges, with thin secretion, and in ophthalmia scrofulosa generally.

BELLADONNA. In photophobia; injection of the ocular conjunctiva; congestion of the retina and optic nerve; dilation of the pupil; ciliary neuralgia and pain in the optic nerve, with congestion. Neuritis optica (diagnosed with the ophthalmoscope). Scrofulous ophthalmia, with great congestion of the conjunctiva and photophobia.

BRYONIA. Scleritis or episcleritis. Rheumatic iritis. Conjunctivitis with soreness of the eyeballs to the touch and on moving them (cocaine).

CONIUM. Photophobia in scrofulous subjects or in scrofulous ophthalmia; keratitis.

CACTUS. Hyperæmia of retina and optic nerve; optic neuritis. Asthenopic symptoms in conjunction with a tendency to congestive headache or flushed face.

CHAMOMILLA. Ciliary neuralgia, especially in scrofulous or purulent ophthalmia of children.

GELSEMINUM. Accommodative asthenopia, with the usual subjective symptoms. Diplopia (from functional disturbance of accommodation in one eye). Ptosis from partial paralysis. Chronic spasms of the orbicularis. Muscular insufficiencies. Nictitation. Hyperæsthesia retinæ, with photophobia (nux vomica). Retinitis.

GLONOINE. Venous hyperæmia, or congestion of the retina and optic nerve.

HEPAR-SULPHUR or sulphide of calcium. Purulent ophthalmia Inveterate blepharitis with purulent secretion, in scrofulous subjects. Keratitis. Conjunctivitis herpetica.

HYDRASTIN. In acute catarrhal ophthalmiæ, with profuse discharge, especially in scrofulous or ill-nourished subjects.

IODIDE OF POTASH. Inflammation of lachrymal sac, with mucous discharge. Syphilitic iritis, choroiditis, and keratitis.

IRON, *ferrum metallicum* in different preparations, in various ophthalmic diseases if anæmic conditions are present.

MERCURY. Blepharitis, chronic or otherwise; purulent ophthalmia with copious discharge; keratitis diffusa, superficial and deep-seated ulceration of the cornea; phlyctenular

ophthalmia; syphilitic disease of any or all the different structures of the eye; episcleritis; scrofulous ophthalmia, with photophobia. In order to get a local effect of this drug in scrofulous ophthalmia I sometimes use an eye-wash, made of one eighth of one grain of perchloride of mercury to two ounces of water.

NUX VOMICA. Asthenopic symptoms. Photophobia from retinal hyperæsthesia. Dilatation of the pupil from spinal irritation. Diplopia from muscular asthenopia, from paralytic strabismus. Paralysis of sixth nerve (rectus externus). Homonymous diplopia. Weakened power of accommodation in one eye from over-exerting it. Severe pain in the eyes, and during the night, with conjunctival injection, brought on by over-use of the eyes, especially by artificial light (gelseminum, mercury). Spasmodic or involuntary closure of the eyes in adults (gelseminum).

OPIUM. Hyperæmia of the conjunctiva and borders of the tarsi, with injection of the ocular conjunctiva in connection with congestive headache.

PULSATILLA. Catarrhal ophthalmia with mucous secretion.

PHOSPHORUS. Retinal hyperæmia with congestion to the head. Flashes of light, dazzling points, or rings of various colors, before the eyes, indicating extreme sensitiveness of the retina.

QUININE, 1st trituration. Asthenopia, in debility; and in eye affections generally of malarial origin.

SANGUINARIA. Retinal congestions, with tendency to flushed face and congestive headaches. Superficial injection of the eyeball, with feeling of soreness.

SANTONINE. Asthenopia, especially in cases where there is evident loss of tone in the retina and accommodative apparatus. Such patients do not see quickly.

SCUTELLARIA. Spasmodic twitchings of the lids (gelseminum nux vomica).

SECALE. Asthenopia. Asthenopia with enlarged pupils, due to nervous debility. Diplopia from muscular asthenopia.

SPIGELIA. Conjunctivitis and iritis in children, particularly in those of scrofulous diathesis. Congestion of the ciliary vessels, as indicated by the pinkish zone around the cornea. Severe pain in and around the eyes, and on moving them. Severe photophobia from ciliary nervous irritation.

STILLINGIN. Asthenopia characterized by debility rather than inflammation, or marked irritation of the accommodative apparatus. Asthenopia from general debility.

SULPHUR. In chronic ophthalmia scrofulosa, with superficial corneitis, the pinkish zone well marked around the edge of the cornea, and photophobia.

TARTAR EMETIC. Photophobia in scrofulous ophthalmia of children. Pustular conjunctivitis.

ZINCUM. Retinal asthenopia. Anæsthesia retinæ. Neuritis optica. Acute retinitis albuminurica. Bright's disease (arsenic).

ZINCUM PHOSPHATE. Affections of the retina marked by great irritation. Hyperæsthesia retinæ, with photophobia, flashes of light and luminous spectra (zincum, nux vomica, gelseminum, phosphorus).

EXTERNAL REMEDIES.

The following are those that I have found most satisfactory in private practice: —

THE MYDRIATICS

are, of course, in almost constant use.

Atropine sulphate is always to be used in iritis. See pages 161, 168. Duboisine may be substituted if the atropine causes irritation, or after a time causes what is called an atropine conjunctivitis. It is used like atropine, of the strength of about one to four grains to the ounce. When used in stronger solutions it may affect the brain unpleasantly. In a solution of sixteen grains to the ounce I found it to produce a mild delirium or intoxication which lasted nearly twenty-four hours. There was an idiopathic

contraction of the pupils in an elderly lady, and as atropine produced no effect, I wished to try a more powerful mydriatic. It had no effect on the pupils.

Homatropine hydrobromate is convenient where a temporary effect only is desired. It paralyzes the accommodation, but not always so perfectly as may be desired. See page 169. If, therefore, we wish to produce a more positive effect on accommodation, we use atropine sulphate. Even this will sometimes fail to perfectly paralyze the ciliary muscle. The effect on accommodation with either of these substances is more certain if used at frequent intervals for a day or two before making an examination of the state of the vision. For rapid effect on accommodation, it has been proposed to use a solution containing two per cent homatropine and two per cent cocaine. The maximum effect is obtained in 30 to 60 minutes, but soon declines.

Cocaine muriate as a mydriatic is useful in ophthalmoscopic examinations. A two per cent solution enlarges the pupil in a few minutes, and the effect passes off in the course of the day. It increases the mydriatic effect of atropine when used with it, hence it is useful with the latter in iritis for this, as well as for its analgesic, property. It is used also as an aid to the action of eserine in glaucoma. As an anæsthetic it is available for nearly all operations on the eye. I have removed the eyeball under its anæsthetic effect without inconvenience to either patient or surgeon. However, in surgical operations of long duration, timid patients do better under ether. The prompt relief obtained by it in a case of neuralgia of the eye is given on page 234.

THE MYOTICS

in most frequent use are *eserine* and *pilocarpine.*

Eserine for glaucoma, see pages 171, 191. Its effects in reducing tension in glaucoma are supposed to be increased by using cocaine with it. In sluggish corneal ulceration it is used also in conjunction with cocaine. The solution for use in glaucoma should be weak, $\frac{1}{4}$ or $\frac{1}{2}$ grain to the ounce, or it may act too energetically.

Pilocarpine acts similarly to eserine on the eye but much more weakly, and is used in a solution of two to four grains to the ounce. It is less irritating than eserine, and I therefore use it more frequently in the mydriasis of asthenopia. It contracts the pupil less quickly and less forcibly than eserine, and is preferred for this reason, by some, in glaucoma. For subcutaneous injection, in old scleritis, keratitis in gouty or rheumatic subjects, and in choroiditis and retinal detachment, it is used in a solution of about four grains to a drachm of water, three drops of which are injected daily or less often. I have usually given it by the mouth, in doses of about one tenth of a grain.

ANTI-SEPTICS AND ASTRINGENTS.

Nitrate of silver for use in infectious diseases of the eye leads all other substances. It is spoken of at pages 98, 105, 112, etc., as a preventive of blindness, used as a disinfectant for mother and child in cases of confinement, it is noticed at page 108. In upward of 17,000 cases of this kind collated by Howe (Tr. N. Y. State Soc. '89), 8.66 % of disease occurred where these measures were not taken; but only 0.656% of disease was observed where a drop of a 2% solution of nitrate of silver for disinfection was made use of.

Bi-chloride of mercury may be used like the above, for the purpose of disinfection in a strength of 1 : 5000 to 1 : 25000. It may possibly be used somewhat stronger than this, but a healthy eye is intolerant of it at 1 : 15000. A solution of 1 : 5000 destroys germs in three minutes, and one of 1 : 10000 in about five minutes.

Chlorine water, when fresh, is the equal of the bi-chloride of mercury as a germicide. I formerly used it in purulent ophthalmia, but it is very unstable, and I rarely recur to it now.

Peroxide of hydrogen is an equally reliable anti-septic. I have had no experience with it.

Boracic acid, four to eight grains to the ounce, is useful in all forms of conjunctivitis, as a mild disinfectant.

Borax, biborate of soda, ten grains to the ounce, is chiefly serviceable in hyperæmic condition of the conjunctiva, or in mild conjunctivitis.

Sulphate of zinc and *sulphate of copper*, in solutions, I use very rarely at present. The latter in the form of crystal may be used cautiously in touching granulated lids with trachomatous pannus. See page 119.

Alum, in crystal form, may be freely used for granular conjunctivitis and is often preferable to the copper, as causing only slight reaction.

Cuprum aluminate may be useful also in granular lids, and in crystal form causes less reaction than the cuprum sulphate. Frequently a five to ten grain solution of nitrate of silver painted on the reversed lid is more effective than either of the above.

UNGUENTS.

The unguents that I have found most useful are the —

Red oxide of mercury, in blepharitis, see page 281, and the *citrine ointment* (nitrate of mercury) in the same affection, about one part of the citrine ointment to eight parts of vaseline. Other unguents are mentioned also at page 281.

Yellow oxide of mercury (Pagenstechers ointment), in the strength of two to four grains to the ounce of vaseline, I have used occasionally to advantage in sluggish ulcerations of the cornea, a small portion being inserted between the lids daily or less often. It is better borne within the eye than the other preparations of mercury. Berry advises its preparation with spermaceti ointment, with a few drops of olive oil, as less irritating to the eye. When indicated, an eighth of a grain of atropine can be added to either of these unguents.

KOCH'S REMEDY IN EYE AFFECTIONS.

Königshöfer (Stuttgart) reports[1] the result of treatment in ten cases, with Koch's remedy. In four cases of eczematous

[1] Opthal. Review, February, 1891.

ulcers of cornea in scrofulous children, and in two cases of tubercular disease of lids, one of interstitial keratitis, the effects were favorable, the corneal ulcers healing remarkably quickly. In three cases of iritis no results were reached.

I have remarked at page 169, in speaking of strong solutions of atropine, that caution should be observed in dropping them into the eye, lest cerebral disturbance should ensue. It must be remembered that liquids of all kinds, when dropped into the eye, reach the throat through the lachrymal duct almost as readily as when taken into the mouth. I think that this work was the first to call attention to this fact, and it would seem to be one of considerable importance. Any one who will take the trouble of testing in his own eye the effect of a few drops of a solution of two or three grains of iodide of potash to an ounce of water will, I think, be surprised to find how soon he will get the characteristic bitter of the alkali in the throat. They also enter the circulation by endosmosis through the cornea. I had long noticed the favorable effect of a collyrium of atropine (one grain to the ounce of water) in the photophobia of scrofulous ophthalmia, before it occurred to me that the internal effect of the belladonna might be, at least partially, the cause of the improvement. In prescribing collyria for the eye, we should therefore always take into account the possible, or perhaps we may say the unavoidable, internal effects.

CHAPTER XXII.

TEST TYPE.

THE first series of test type is presented merely as a convenience in noting the state of the vision, with or without glasses, for reading or near objects. The different sized print is numbered, so that a record can be made from time to time, and the progressive improvement or failure in visual power accurately determined. The second series, made up of different sized gothic letters, is intended for the more exact measurement of the patient's acuteness of vision. The numbers in this series indicate the distance at which an emmetropic eye should distinguish the letters. The letters of No. 6 should be named readily, in a good light, at six feet, 10 at ten feet, 20 at twenty feet, and so on. If No. 20 can be seen only as far as ten feet, then V. $= \frac{10}{20}$, or $\frac{1}{2}$; if it can be seen at twenty feet, then V. $= 1$, and the eye is emmetropic. Occasionally a person will be met with who can read the letters at a much greater distance than the average; and a very strong light is favorable for reading them at a greater distance also. The second series corresponds very nearly to the system of Von Jaeger and Snellen, — that is, the letters are of a height to be seen distinctly at an angle of 5° by an emmetropic eye.

FIRST SERIES.

No. 1.

I think it does not matter just when I first came to Venice. Yesterday and to-day are the same here. I arrived one winter morning about five o'clock, and was not so full of Soul as I might have been in warmer weather. Yet I was resolved not to go to my hotel in the omnibus (the large, many-seated boat so-called), but to have a gondola solely for myself and my luggage. The porter who seized my valise in the station, inferred from some very polyglottic Italian of mine the nature of my wish, and ran out and threw that slender piece of luggage into a gondola. I followed, lighted to my seat by a beggar in picturesque and desultory costume. He was one of a class of mendicants whom I came, for my sins, to know better in Venice, and whom I dare say every traveller

No. 2.

recollects— the merciless tribe who hold your gondola to shore, and affect to do you a service and not a displeasure, and pretend not to be abandoned swindlers. The Venetians call them *gransieri*, or crab-catchers; but as yet I did not know the name or the purpose of this *poverino*, at the station, but merely saw that he had the Venetian eye for color: in the distribution and arrangement of his fragments of dress he had produced some miraculous effects of red, and he was altogether as infamous a figure as any friend of brigands would like to meet in a lonely place. He did not offer to stab me and sink my body in the Grand Canal, as, in all Venetian

No. 3.

keeping, I felt that he ought to have done; but he implored an alms, and I hardly know now whether to exult or regret that I did not understand him, and left him empty-handed. I suppose that he withdrew again the blessings which he advanced me, as we pushed out into the canal: but I heard nothing, for the wonder of Venice was already upon me. All my nether-spirit, so to speak, was dulled and jaded with the long, cold, railway journey from Vienna, while every surface-sense was taken and tangled in the bewildering brilliancy and novelty of Venice. For I

No. 4.

think there can be nothing else in the world so full of glittering and exquisite surprise, as that first glimpse of Venice which the traveller catches as he issues from the railway station by night, and looks upon her peerless strangeness. There is something in the blessed breath of Italy (how quickly, coming south, you know it, and how bland it is, after the harsh, transalpine air!) which prepares you for your nocturnal advent into Venice; and O you! whoever you are, that journey toward this enchanted city for the first time, let me tell you how happy I count

No. 5.

you! There lies before you for your pleasure, the spectacle of such singular beauty as no picture can ever show you nor book tell you; beauty which you shall feel perfectly but once, and regret for ever.

For my own part, as the gondola slipped away from the blaze and bustle of the station down the gloom and silence of the broad canal, I forgot that I had been freezing two days and nights; that I was at that moment very cold and a little homesick. I could at first feel nothing

No. 6.

but that beautiful silence, broken only by the star-silvered dip of the oars. Then on either hand I saw stately palaces rise gray and lofty from the dark waters, holding here and there a lamp against their faces, which brought balconies, and columns, and carven arches into momentary relief, and threw long streams of crimson into the canal. I could see by that uncertain glimmer how fair

No. 7.

was all, but not how sad and old: and so unhaunted by any pang for the decay that afterwards saddened me amid the forlorn beauty of Venice, I glided on. I have no doubt it was a proper time to think all the fantastic things in the world, and I thought them; but they passed vaguely through my mind, without at all interrupting the sensations of sight and sound. Indeed, the past and present mixed there, and the moral and

No. 8.

material were blent in the sentiment of utter novelty and surprise. The quick boat slid through old troubles of mine, and unlooked-for events gave it the impulse that carried it beyond, and safely around sharp corners of life. And all the while I knew that this was a progress through narrow and crooked canals, and past marble angles of palaces. But I did not know then that this fine confusion

No. 9.

of sense and spirit was the first faint perception of the charm of life in Venice.

Dark, funereal barges like my own had flitted by, and the gondoliers had warned each other at every turning with hoarse, lugubrious cries; the lines of balconied palaces had never ended; — here and there at their doors larger craft were moored, with

No. 10.

dim figures of men moving uncertainly about on them. At last we had passed abruptly out of the Grand Canal into one of the smaller channels, and from comparative light into a darkness only remotely affected by some far-streaming corner lamp. But always the pallid, stately palaces; always the dark heaven with

No. 11.

its trembling stars above, and the dark water with its trembling stars below; but now innumerable bridges, and an utter lonesomeness, and ceaseless sudden turns and windings. One could not resist a vague feeling of anxiety, in these

No. 12.

strait and solitary passages, which was part of the strange enjoyment of the time, and which was referable to the novelty, the hush, the darkness, and the

No. 13.

piratical appearance and unaccountable pauses of the gondoliers. Was not this Venice, and is not Venice for ever associ-

No. 14.

ated with bra-
voes and unex-
pected dagger-
thrusts? That
valise of mine
might represent

No. 15.

unbounded
wealth to
the uncul
tivated eye.

No. 16.

Who, if I made an out cry, could understand the Facts of the Situa tion, as we say in the journals? To move on

[HOWELLS' VENETIAN LIFE.

SECOND SERIES.

No. 2.

LHDETFCIUO

No. 3.

EUCFOPGTHL

No. 5.

GTOHLEQFDI

No. 6.

HGFDPUOIE

No. 8.

IGOTCLEFU

No. 10.

UFTDHGPOE

No. 12.

QECPUFDIL

No. 14.

PDLFHOTGI

No. 20.

F P L O H

No. 32.

F H G T

No. 50.

U C P

No. 70.

L D

No. 100.

T H

No. 200.

INDEX.

ABBREVIATIONS and signs for lenses, 79.
Abscess, of cornea, 139.
    globe, 176.
    lachrymal sac, 291.
Accommodation, 49.
    anomalies of, 51.
    differs from refraction, 50.
    mechanism of, 50.
    paralysis of, 268.
    spasm of, 269.
Achromatism, 23.
Act of seeing, 20.
Amaurosis, 218, etc.
Amblyopia, 222.
    causes of, 224.
    diagnosis of, 222.
    treatment of, 224.
Anatomy, 5.
Anchyloblepharon, 309.
Anterior chamber, narrow in infants, 253.
Aphakia, 256.
Apoplexy of retina, 206.
Aqua chlori, the use of, 123.
Aqueous humor, 14.
Arcus senilis, 8.
Argen. nit., external use of, 98, 100, 105, 107, 111, 112, 120, 132, 148, 335.
    as a prophylactic, 108.
Arsenicum in corneal ulceration, 135.
    the use of, 330.
Artificial eyes, 259.
    pupil, 164.
Asthenopia, accommodative, 72.
    muscular, 84.
    retinal, 230.
    remedies in, 76.
Asthenopia, spectacles in, 74, 75, 76.
Astigmatism, 76.
    compound, 76, 79.
    diagnosis of, 77.
    irregular, 77.
    mixed, 77, 81.
    regular, simple, 76.
    spectacles for, 78.
    test type and lines for, 348.
Atrophy of optic nerve, 218.
    field of vision in, 219, 220.
    not uniformly fatal to sight, 220.
    ophthalmoscopic appearance of, 218, 219.
Atropine, action of, 168.
    an aid to diagnosis, 28.
    strength of solution, 159.
    use in eye affections, 161, 168, 169.
Aut-ophthalmoscope, 40.

BANDAGE, compress, 36.
    simple, 36.
Belladonna, its internal use, 331.
Binocular vision, 21.
Blepharitis, 280.
Blepharospasm, 286.
Blindness, simulation of 227.
Bright's disease, 203.
Bryonia, use of, 331.
Burns and scalds, 306, 307.

CANAL of Schlemm, 6.
    of Fontana. 6.
Canaliculus, obstructions of, 291.
    anatomy of, 17.
    to slit up, 290.

Cancer of the eye, medullary, 303.
Capsular cataract, 253.
opacities, 248.
Caruncle, 15.
Cataract, 235.
cause of, 238.
complications in, 237.
diagnosis of, 235.
by lateral illumination, 236.
by ophthalmoscope, 236.
objective symptoms of, 235.
prognosis in, 241.
subjective symptoms of, 235.
when ripe or complete, 240.
black, 239.
capsular, 253.
capsulo-lenticular, 254.
congenital, 249.
cortical, 249.
diabetic, 252.
fluid, 253.
hard, 239.
operations for, 240.
after treatment, 246.
lamellar, 249.
nuclear, 239.
pyramidal, 254.
secondary, 248.
senile, 239.
soft, 249.
operations for, 240.
striated, 239.
traumatic, 255.
treatment of cataract, medical, 253.
discission or absorption, 250.
extraction plus capsule, 245.
flap extraction, 241.
linear extraction, 251.
peripheric-linear extraction, 243.
reclination, 245.
suction, 252.
Cataract glasses, 257.
Catarrhal ophthalmia, 97.
treatment of, 98, 100.
Chalazion, 284.
Chamomilla, the use of, 331.
Choroid, anatomy of, 8.
hyperæmia of, 172.
sarcoma of, 211.
Choroid, tubercles of, 178.
Choroiditis, 172.
ametropic, 174.
central, 174.
disseminated, 172.
ophthalmoscopic appearance of, 172, 174.
simplex, 175.
suppurative, 176.
Chronic headache, need of ophthalmoscopic examination in, 47.
Ciliary body, 11.
muscle, 11.
nerves, 9.
processes, 11.
Ciliary muscle, action of, 49.
division of, 319.
paralysis of, 268.
spasm of, 269.
Closure of pupil in iritis, 164, etc.
after cataract operations, 247.
operations for, 164.
Cocaine, 170, 334.
Collyria in conjunctivitis, 335, 336.
internal effect of, 337.
Color blindness, 229.
Color of lens, 13.
Conical cornea, 146.
diagnosis of, 146.
artificial pupil in, 147.
Conjunctiva, affections of, 94.
anatomy of, 15.
cysts of, 133.
foreign bodies in, 307.
injuries of, 305.
warts of, 133.
Conjunctivitis, 95.
catarrhal, 97.
congenital, 103.
diphtheritic, 114.
eruptive, 129.
exanthematous, 131.
follicular, 115.
gonorrhœal, 109.
granular, 116, 117.
phlyctenular, 129.
purulent, 101.
pustular, 129.
scrofulous, 125.
simple, 97.
Contagiousness of ophthalmia, 100, 103, 108.

Convergent strabismus, 270.
Corelysis, 162.
Cornea, affections of, 134.
abscess of, 145, 148.
abrasions of, 313.
anatomy of, 8.
conical, 149.
haziness of, 125, 150, 312.
injuries of, 312.
lack of transparency of, 22.
opacities of, 150.
paracentesis of, 146.
perforation of, 149.
staphyloma of, 148.
ulcers of, 144.
crescentic, 112, 145.
deep, 145.
superficial, 134.
transparent, 144.
treatment of, 146.
Crossed diplopia, 264, 265.
Crossing of optic nerve fibres, 14, 220.
Crystalline lens, 12.
Cyclitis, 164, 316.
Cysticerci, 180.
Cysts of iris, 171.
of lids, 284.

Dacryo-cystitis, 291.
Detachment of retina, 208.
causes of, 210.
Diabetic cataract, 252.
Dilated pupil in disease of eye, 167, 182, 183, 218, 322, 324.
Dioptric system of lenses, 260.
Diphtheritic conjunctivitis, 114.
Diplopia, 32, 85, 87, etc.
homonymous, 264, 265.
Direct examination with ophthalmoscope, 42, 56, 68.
Diseases of the eye coexist with disease of the brain, 46, 323, 324.
coexist with insanity, 47.
impossible to diagnose formerly, 44.
made a specialty by the Egyptians, 1.
necessary implements in, for general practitioners, 33.
Dislocation of lens, 254.
Distance, how determined, 22.
Divergent strabismus, 272.
Division of ciliary muscle, 320.
Double vision, 32, 85, 87, 264, 265.
Dropsy of the eye, 302.
Duboisine, 168, 170, 333.

Ectropium, 282.
Electric light, effects of, 232.
Embolism of central artery of retina, 212.
Encephaloïd disease, 211.
Encysted tumors of lids, 284.
Entrance of optic nerve, 15.
Entropium, 283.
Enucleation of the eye, 317.
Epicanthus, 286.
Epiphora, 289.
Episcleritis, 152.
Epithelial, cancer of lid, 283.
Equilibrium of muscles, tests for, 85, 88.
Eserine, use of, 191, 334.
Esophoria, 89.
Evisceration, 321.
Examination of the eye, 26.
by lateral illumination, 44.
ophthalmoscopic, 37.
Excenteration, 321.
Excision of the eye, 317.
of staphyloma, 149.
Excitation of nerves of the eye, 19.
Excoriation of the lids, 281.
Exophoria, 89.
Exophthalmos, 302.
External remedies, 333.
Extraction. See *Cataract*.
of foreign bodies from the eye, 306, 307, 311.
Eye in relation to the general system, 322.
Eye protectors, 258.
Eyeball. See *Globe*.
Eyelashes, removal of, 283.
Eyelids, affections of, 280.
anatomy of, 16.
blepharospasm, 286.
distichiasis, 283.
ectropion of, 282.
entropion of, 283.

Eyelids, epicanthus, 285.
hordeolum, 285.
paralysis of, 286.
ptosis of, 287.
spasm of orbicularis, 286.
tinea tarsi, 280.
trichiasis, 283.
tumors of, 284.
wounds of, 305.
Eyes, artificial, 257.
to insert and remove, 259.

FAR-SIGHT. See *Presbyopia.*
Field of vision, 31.
to ascertain the extent, 31.
in amaurosis, 213, 220, 221.
in cataract, 237.
important to determine, 220, 221.
Fistula corneæ, 247.
lachrymalis, 294.
Flap extraction, 241.
accidents in, 241.
Fluid cataract, 253.
Fluorescence of lens and cornea, 22.
Fontana, spaces of, 6.
Foreign bodies in the conjunctiva, 307.
in the cornea, 312.
within the eyeball, 310.
Fourth nerve, paralysis of, 266.
Fovea centralis, 11.

GELSEMINUM, the use of, 331.
Glaucoma, acute inflammatory, 182, 183.
cause of, 188.
chronic, 185.
secondary, 198.
danger of delay in operating for, 194.
early symptoms of, 182.
excavation of nerve in, 187.
fulminans of Graefe, 188.
iridectomy in, 193.
medical treatment of, 190.
neuralgic pain in, 192.
non-inflammatory, 196.
ophthalmoscopic diagnosis of, 184.
operations for, 193, 197.
pathology of, 197.
Glaucoma, premonitory symptoms of, 182.
prognosis in, 195.
secondary, 198.
treatment, 190.
surgical, 193.
rationale of iridectomy, 196.
when to operate in, 194.
Glioma retinæ, 211.
treatment of, 211.
Globe, affections of the whole, 302.
description of, geographically, 5.
foreign bodies within, 310.
tension of, to determine, 28.
Goitre, exophthalmic, 302.
Gonorrhœal ophthalmia, 109.
Granular ophthalmia, 116, etc.
treatment of chronic, 118.
Grave's disease, 302.

HARDNESS of globe, to determine, 28.
in glaucoma, 182, 190.
Headache, need of ophthalmoscopic examination in, 47.
Hemeralopia, 228.
Hemorrhage in the ant. chamber, 314.
into the vitreous, 314.
under conjunctiva, 133.
Hepar. sulph., the use of, 331.
Herpes frontalis (seu ophthalmicus), 282.
Herpetic ophthalmia. See *Phlyctenular ophthalmia.*
Heterophoria, 89.
Homonymous diplopia, 264, 265.
Hordeolum, 285.
Hyalitis, 178.
Hyaloid membrane, 13.
Hydrastin, the use of, 332.
Hydrophthalmia, 302.
Hyperæmia of choroid, 172.
of conjunctiva, 94.
iris, 155.
optic nerve, 214.
retina, 199.
Hyperæsthesia retinæ, 230.
Hypermetropia, 64.
asthenopia in, 72.
diagnosis of, 67.

Hypermetropia, spectacles for distance in, not to be prescribed unless absolutely necessary, 71.
treatment of, 71, 74.
Hyperphoria, 89.
Hypopion, 139.

IMPLEMENTS and instruments, 33.
Inflammation of choroid, 172.
of conjunctiva, 95.
ciliary body, 316.
cornea, 134.
iris, 158.
lachrymal apparatus, 259.
lids, 280.
optic nerve, 213, etc.
retina, 200.
sclerotica, 152.
vitreous humor, 178.
whole eye, 302.
Injections of conjunctiva, 95.
significance of different redness of the eye, 95, 96, etc.
Injuries of conjunctiva, 305.
cornea, 312.
of the eyes, 305.
globe from gunpowder, 307.
from percussion caps, 311.
of iris and lens, 313.
lids, 305.
sclerotic, 315.
sympathetic ophthalmia, from, 316.
Internal remedies in eye affections, 330.
Intervaginal space, 15.
Involuntary oscillations of globe, 269.
Iridectomy, the operation, 164, 193.
in cataract, 251.
choroiditis, 164, etc.
conical cornea, 149.
glaucoma, 193.
Iridodesis, the operation, 165.
in cataract, 251.
conical cornea, 149.
Iridodonesis, or tremulous iris, 171.
Iris, adhesions of, 160, 161, 162.
anatomy of, 12.
bombé, 160.
cysts of, 171.
Iris, diseases of, 155.
epithelial covering of, 12.
hernia of, 163.
injuries of, 364.
prolapse of, 163.
tremulous, 171, 256.
Iritis, chronic, 163.
cause of, 160.
diagnosis of, 159.
serous, 158.
suppurative, 156.
syphilitic, 156.
traumatic, 313.
treatment of, 161.
Ischæmia retinæ, 212.

KERATITIS, 134.
bulbous, 136.
dendriform, 137.
diffuse, 138.
fascicular, 134.
interstitial vascular, 137.
non-vascular, 137.
punctata superficialis, 138.
suppurative, 139.
vascular superficial, 135.
vesicular, 136.
treatment, 140.
Kerato-globus, 302.
Koch's treatment in eye affections, 336.

LACHRYMAL apparatus, affections of, 289.
epiphora, 289.
gland, anatomy of, 17.
diseases of, 301.
passage, anatomy of, 16, 300.
obstruction of, 289, etc.
canaliculi, 291.
duct, 297.
sac, 291.
blennorrhœa of sac, 294.
fistula of sac, 294.
stricture of, 297, etc.
treatment of, 297, etc.
Stilling's operation, 299.
Lagophthalmos, 286.
Lamina cribrosa, 6.
Lateral illumination, 44.

Lateral illumination, in cataract, 236.
corneal opacities, 27, 150.
dislocation of the lens, 254.
Lens, affections of, 239.
anatomy of, 12.
dislocations of, 254.
geographical divisions of, 13.
wounds of, 215, 313.
Leucoma of cornea, 150, etc.
Levator palpebræ, paralysis of, 266.
Lime, injuries from, 306.
treatment for, 306.

MACROTIN, the use of, 332.
Macula lutea, 11, 24.
Mal-position of the lids, 282.
Meibomian cysts, 284.
glands, 16.
Mercury, in disease of eye, 331.
externally, 130, 331, 336.
Micropsia, 174, 202, 206.
Mortar, injuries from, 306.
treatment of, 306.
Mules' operation, 321.
Muscæ volitantes, 179.
Muscles of eyeball, description of, 17, 18.
equilibrium of, 84, etc.
testing condition of, 88.
by prisms, 85, etc.
phorometer, 87.
affections of, 84, 263.
paralysis of, 264.
Muscular asthenopia, 84.
treatment of, 86.
tenotomy in, 87, 91.
Mydriasis, 167.
Myopia, 51.
cause, 53, 54.
correction by glasses, 58.
senilis, 93.
diagnosis of, 54.
ophthalmoscopic appearance in, 56, 57.
progress of, 58, 62.
treatment of, 57.
hygienic, 62.
preventive, 62, etc.
surgical, 64.
Myosis, 170.

NASAL duct, 16, 300.
Neuralgia oculi, 234.
Neuritis descendens, 217.
Neuro-retinitis, 213.
case of, 215.
diagnosis of, 214, 215.
treatment of, 217, etc.
Nictitation, 286.
Night blindness, 228.
Nitrate of silver, use of, 120.
in granulations, 120.
purulent ophthalmia, 102, 105, 107, 112.
Nux vomica, internal use of, 331.
Nystagmus, 269.

OBJECTIVE examination of eye, 26.
Obliteration of lach. sac, 345.
Obstruction of lach. passages, 294, etc.
Opacities of cornea, 150.
lens and capsule, 235.
vitreous, 178.
Ophthalmia, catarrhal, 97.
diphtheritic, 114.
Egyptian, 103.
gonorrhœal, 109.
granular, 116.
herpetic, 129.
neonatorum, 103.
phlyctenular, 129.
purulent, 101.
pustular, 129.
scrofulous, 125.
sympathetic, 316.
tarsi, 280.
Ophthalmitis, treatment of, 177.
Ophthalmoscope, 37,
appearance of fundus with, 42.
retinal vessels with, 43.
binocular, 40.
direct examination with, 42.
how to use, 40.
importance to general practitioners, 45.
indirect exam. with, 41.
inverted image with, 41, 42.
Liebreich's, 38.
the "refraction," 40.
principles of, 37.

Ophthalmoscopic exam. necessary in chronic headaches, and in all suspected disease of the brain, 47, 213.
Optic axes, convergence of, in accommodation, 50.
disc, how to find it, 41.
nerve, anatomy of, 14.
atrophy of, 219.
diseases of, 213, etc.
oval appearance of, 42, 82.
neuritis, 213.
Optical defects, the irremediable, 22.
the remediable, 49.
Orbicularis, paralysis of, 286.
spasm of, 286.
Orbit, diseases of, 302.
diagnosis of, 302.
Oscillations of the eyeball, 269.

PAIN, diagnostic value of, 29.
remedies, external, 95, 147, 148, 161, 162, 192, 193, 234.
remedies, internal, 330, etc.
Pannus, 117.
Panophthalmitis, 177.
treatment of, 177.
Paracentesis of cornea, 142, 143, 146.
Paralysis of ciliary muscle, 268.
levator palpebræ, 266.
nerve, fourth, 266.
sixth, 264.
third, 266.
rectus externus, 264.
inferior, 265.
internus, 265.
superior, 265.
superior oblique, 265.
Paralytic affections, causes of, 264.
treatment of, 267.
surgical, of, 269.
by electricity, 267.
Passavant's operation, 162.
Perforation of cornea, 149.
lac. sac, 294.
Perichoroidal space, 9.
Photophobia in corneitis, 134, etc.
in iritis, 156.
retinal asthenopia, 230.
scrofulous ophthal., 131, etc.
not a symptom of retinitis, 30.
Photophobia, remedies for, 131, 330.
Physiological excavation of optic nerve, 185.
Physiology of vision, 19.
Pinguecula, 133.
Plaster, injuries from, 306.
treatment of, 306.
Posterior staphyloma, 56.
Powder, injuries from explosion of, 307.
Presbyopia, 92.
treatment of, 92.
Prisms, action of, 85, 88, 90, 264, etc.
for testing strength of muscles, 85, 88, 89.
Prolapse of iris, 163.
Pterygium, 132.
Ptosis, treatment of, 287.
Pupil, abnormal dilation of, 167.
description of, 14.
contraction of, 170.
artificial dilation of, 171.
contraction of, 173.
closure of, 164, 248.
Purulent ophthalmia, 101.
of infants, 103.
Pustular ophthalmia, 129.

QUADRANTS of cornea, 8.

RAPIDLY increasing presbyopia, 92.
Refraction, anomalies of, 51.
Refraction in amblyopia, 222.
astigmatism, 76, 77.
hypermetropia, 64, 65.
myopia, 51.
normally refractive eye, 52, etc.
differs from accommodation, 50.
Remedies, internal, 330–333.
Retina, apoplexy of, 206.
anæsthesia retinæ, 231.
anatomy of, 9.
hyperæmia of, 199.
nerves and vessels of, 10.
pigment, layer of, 10.
purple of, 20.
cancer of, 211.
detachment of, 208.
diagnosis, 209.

Retina, embolism, central artery of, 212.
glioma of, 211.
hyperæmia of, 199.
hyperæsthesia of, 230.
inflammation of, 200.
ophthalmoscopic appearance of, 201.
paralysis of, 212.
Retinitis, 200.
albuminurica, 203.
apoplectica, 206.
parenchymous, 201.
pigmentosa, 207.
syphilitica, 205.
diagnosis of, 200.
Retinoscopy, 70.
Rheumatic iritis, 155.

Sac, the lachrymal, 17.
Sæmisch operation, 148.
Schlemm, canal of, 6.
Scleritis or episcleritis, 152, 153.
Sclerotic, anatomy of, 6.
anterior staphylom. of, 148.
posterior staphylom. of, 56.
wounds of, 315,
Sclerotico-choroiditis posterior, 56.
diagnosis of, 56.
Sclerotomy, 197.
Scrofulous ophthalmia, 125.
treatment, 125, etc.
local, not serviceable, 125.
Second-sight, 92.
Senile cataract, 239.
Short sight, 51.
Simulation of blindness, 227.
Sixth nerve, paralysis of, 264.
Sketch of rise and progress of ophthalmic surgery, 1.
Snow blindness, 231.
Soft cataract, 249.
treatment of, 250.
Sparkling synchysis, 180.
Spasm of ciliary muscle, 268.
orbicularis muscle, 268.
Spectacles, 257.
cataract, 257.
cylindrical, 257.
decentred, 258.
kinds of, 257.
Spectacles, pantoscopic, 258.
prismatic, 258.
stenopaic, 259.
Spigelia, use of, 333.
Staphyloma anterior, 148.
Staphysagria, use of, 333.
Stillingin, use of, 333.
Strabismus, 269.
alternating or binocular, 270.
causes of, 270, 271.
concomitant, 269.
convergent, 270.
divergent, 272.
dynamic, 84.
measurement of, 273.
operations for, 276.
paralytic, 265, etc.
periodic or confirmed, 270, 275.
primary and secondary deviation in, 272.
remedies for, 274.
surgical treatment of, 276.
hygienic, 274.
Strictures of lach. passages, 289, etc.
treatment of, 291, etc.
by probing, 295.
styles, 298.
Stilling method, 299.
Strumous ophthalmia, 125.
corneitis, 134, etc.
Sulphur, internal use of, 332.
Suppurative corneitis, 139.
choroiditis, 176.
iritis, 156.
Suspensory ligament of lens, 13.
Symblepharon, 309.
Sympathetic irritation, 319.
ophthalmia, 316.
cause, 316.
treatment, general, 319.
by operation, 317.
when to operate, 318.
Syndectomy, or peritomy, 123.
Syphilitic disease of iris, 156.
cornea, 138.
retina, 205.

Tarsal tumors, 284.
Tartar emetic, use of, 333.
Tattooing the cornea, 151.

Tenonian capsule, 17.
lymph space, 18.
Tenotomy in squint, 276.
in dynamic squint, 87.
Tension of globe, to determine, 28.
in glaucoma, 207, 208.
operations for increased, 190, 193, 197.
Test type for astigmatism, 80.
for reading, 339.
to determine distant vision, 344.
Traumatic cataract, 255.
iritis, 313.
Tremulous iris, 171, 256.
Trichiasis, 283.
Tumors of choroid, 211.
conjunctiva, 133.
eyelids, 284.
iris, 171.
retina, 211.

Ulcers of cornea, 144.
eyelids, 283.
case of, 283.
Upper lid, how to reverse it, 26.

Venæ vorticosæ, 7-9.
Vision, acuteness of, 30.
double, 32-264.
field of, 31.
Vision, state of, its diagnostic value, 31, 220, 221.
weakness of. See *Asthenopia*.
Vitreous, affections of, 313.
anatomy of, 13.
cholesterine in, 180.
cysticerci in, 180.
fluidity of, 180.
foreign bodies in, 310.
hemorrhage into, 314.
inflammation of, 178.
opacities of, 178.

Warts of conjunctiva, 133.
eyelids, 285.
Weak sight. See *Asthenopia*.
Wounds of eyeball, 310.
eyelids, 305.
iris, 313.
sclerotic, 315.
sympathetic inflammation from, 316.

Yellow spot, appearance of, 42.
how to find it with the ophthalmoscope, 41.

Zinc, use of, 333.
Zinc, phosph., use of, 333.
Zonule of Zinn, 13.