

## **Studies in the facial region / by Harrison Allen.**

### **Contributors**

Allen, Harrison, 1841-1897.  
Francis A. Countway Library of Medicine

### **Publication/Creation**

[Place of publication not identified] : Lippincott, 1875.

### **Persistent URL**

<https://wellcomecollection.org/works/a8p2nt2b>

### **License and attribution**


This material has been provided by This material has been provided by the Francis A. Countway Library of Medicine, through the Medical Heritage Library. The original may be consulted at the Francis A. Countway Library of Medicine, Harvard Medical School. where the originals may be consulted. This work has been identified as being free of known restrictions under copyright law, including all related and neighbouring rights and is being made available under the Creative Commons, Public Domain Mark.

You can copy, modify, distribute and perform the work, even for commercial purposes, without asking permission.



Wellcome Collection  
183 Euston Road  
London NW1 2BE UK  
T +44 (0)20 7611 8722  
E [library@wellcomecollection.org](mailto:library@wellcomecollection.org)  
<https://wellcomecollection.org>







I.C. IV. 5


3. Moa 2

Prof. O. W. Holmes

with the respects  
of the Author







Digitized by the Internet Archive  
in 2011 with funding from  
Open Knowledge Commons and Harvard Medical School





STUDIES  
IN THE  
FACIAL REGION.

BY  
HARRISON ALLEN, M.D.,  
PROFESSOR OF ANATOMY AND SURGERY IN THE PHILADELPHIA DENTAL COLLEGE.

ILLUSTRATED WITH FIFTY-SIX WOOD CUTS.

---

(REPRINTED FROM "THE DENTAL COSMOS.")

---

PRESS OF  
J. B. LIPPINCOTT & CO.  
1875.





TO

C. NEWLIN PEIRCE, D.D.S.,

WHO HAS ALWAYS TAKEN AN ACTIVE INTEREST IN THE AUTHOR'S  
STUDIES,

THIS BOOK

IS AFFECTIONATELY DEDICATED.





## P R E F A C E.

---

THE Essays here collected are for the most part the jottings from lectures delivered to successive classes of dental students for the past seven years. They make no pretension to symmetry, but the author trusts that, whatever other defects he may be charged withal, errors of omission may not be among them. Any claim made for these Studies as original contributions can be defended only so far as the sections on Localization of Diseased Action and the Nomenclature of the Teeth may be so considered.

The majority of the Illustrations are to be accredited to the following sources: Sharpey and Quain, Wilson, Sappey, Leidy, Sylvestre, Walter, and the Dental Catalogue of Dr. S. S. White. Figures 10, 11, 12, 13, 18, 22, 24, and those from 36 to 56 inclusive, are original.

117 SOUTH 20TH STREET, PHILADELPHIA,  
January 1st, 1875.





# CONTENTS.

---

	PAGE
THE REGION OF EXPRESSION . . . . .	3
Muscles . . . . .	3
Surgical Anatomy . . . . .	11
The Porta . . . . .	19
THE REGION OF THE TEMPLE AND "THE ANGLE OF THE LOWER JAW." .	23
THE PAROTID REGION . . . . .	30
THE REGION OF THE EAR . . . . .	33
The Post-Auricular Space . . . . .	39
THE REGION OF THE LOWER JAW . . . . .	40
THE REGION OF THE UPPER JAW . . . . .	51
The Superior Maxilla . . . . .	54
The Malar Bone . . . . .	57
The Palatal Bone . . . . .	58
THE NOSE . . . . .	64
The Nasal Chambers . . . . .	65
The Ethmoid Bone . . . . .	66
The Turbinated Bone, and Vomer . . . . .	69
The External Nose . . . . .	74
THE MOUTH . . . . .	80
The Præ-Coronoid Space . . . . .	82
THE REGION OF THE TONGUE . . . . .	86
The Alveolo-Lingual Groove . . . . .	97
THE PHARYNX . . . . .	99
Post-Pharyngeal Abscess . . . . .	107
THE SPHENO-MAXILLARY REGION . . . . .	108
THE SUPRA-HYOID REGION . . . . .	110
THE NOMENCLATURE OF THE TEETH . . . . .	111





## THE FACIAL REGION.

---

THE face is among the most complex of the regions of the body: its functions are more varied; its connections are more embracing; its lesions are more deceptive,—the brain alone excepted.

The term “face” is employed in two ways. It is that portion of the head other than the cranium; it is the countenance. We speak of the face as lodged beneath the anterior third of the base of the brain, thus excluding the forehead. We say the “forehead is a portion of the countenance,” and thus again include it.

A gunshot wound of the face may imply a lesion extending from the skin to the posterior nares,—while a palsy of the face implies an involvement of the superficial parts alone.

Turning to the skeleton for our primary conceptions, we find the face to be that region which protects the visual, nasal, and dental organs.

Now structurally the face is an outgrowth from the cranium. It is seen to arise after three distinct methods,—first, a vertical prolongation from the frontal region forming the nasal bones, and the incisorial portion of the upper jaw. Second, a median prolongation from the base of the skull, creating the ethmoid bone and vomer. And third, lateral processes advancing toward the median line, which form the bulk of the upper jaw and the whole of the lower jaw. But these features, although of importance in the interpreting of malformations, have little practical value.

The face is dependent upon the cranium for attachment and support, but is independent of it in many particulars. It is best to consider it as having distinct mechanical features for its maintenance and peculiar functions. We must not, it is true, forget that it is a part of the skull; neither should we ignore its claims to being a very natural region.

Let us see for a moment how purely mechanical is its union with the brain case. While the face protects the cranial figure at its weakest point, which is the anterior cerebral fossa, it has no real significance as part of it. Every facial bone can be removed, provided we include the ethmoid bone among the cranial bones as is generally done, and the interior of the cranium will not be exposed. The points of union with the cranium are the zygoma, the pterygoid process, and the ethmo-



vomerine attachment, posteriorly; and the fronto-malar and the fronto-nasal sutures anteriorly. All these may be loosened or destroyed by violence, or the face be entirely removed, and the functions of the brain continue unimpaired.

Considering the face, therefore, as a region *sui generis*, we are first struck with its irregular figure. Externally, in examination of the face of the living subject, the hand passes down over three bony prominences, the supra-orbital ridges, the cheek-bones, and the inferior margin of the lower jaw. On the sides are encountered the zygomatic arch and the angle of the lower jaw. When the skull is examined the depressions between these lines are conspicuous, and the two great cavities, the orbits, are now exposed to view. Internally the face is still more varied. It is divided into two nasal chambers, and each chamber communicates with large spaces in the maxillary, frontal, and ethmoid bones.

But the most remarkable feature of the face is the lower jaw. This is a large, massive, movable lever, articulating with the skull, and operating upon the upper jaw (which is fixed) by powerful muscles. The cleft between the jaws is of no special value except in explanation of the architecture of the face; but when the soft parts are in position it forms the frame-work for the cavity of the mouth.

Every bone of the face, excepting the malar bone, is in contact with mucous membrane. This will prove to be a valuable point when we come to study diseased action.

We have not yet judged the face by the test which should be applied to every region,—namely, the limitation by relation of function. By this we mean marking out a region by lines which define the function of that region. For example, to call the ear a natural region is to imply that all its important parts are supplied with nerves, vessels, and muscles, having special reference to the acoustic sense. The face thus considered has boundaries very different from those suggested by the skeleton or living subject. Its chief muscle, the temporal, arises from the side of the cranium. The pterygoid arises from the under part of the sphenoid bone. The digastric arises from the occipital plane, and passes forward and downward as far as the hyoid bone. The internal maxillary artery, in addition to supplying parts we have denominated facial, supplies the tympanum and meninges of the brain. The relations of the nasal chambers to the upper part of the pharynx, and the oral cavity with the lower portion, make it impossible to draw any sharp line of limitation between these regions and that of the pharynx. In our lectures on this subject we will assume that a surgical region is, *per se*, a natural one, and to give proof of our convictions we propose in our remarks on the face to include the pharynx, and the neck down as far as the hyoid bone.



It is interesting to observe that the majority of the cranial nerves are distributed to this region. The auditory, pneumo-gastric, and spinal accessory nerves, are alone found within other portions of the body. And it is further not a little curious that the first and last of the cranial system of nerves, although arising from remote points, should be distributed within the same natural region.

The following is the division of our subject :

The Region of Expression.

- " " the Temple, and " Angle of Lower Jaw."
- " " " Ear.
- " " " Upper Jaw.
- " " " Nose.
- " " " Mouth.
- " " " Tongue.
- " " " Naso-pharynx and Palate.
- " Spheno-maxillary Space.
- " Supra-hyoid Space.

## I.

### THE REGION OF EXPRESSION.

#### *The Muscles.*

We will speak of expression from the point of view of the factors of expression,—the muscles. These produce either active or passive expression. The former is due to muscular action, the latter to general tonicity of the parts. There is an expression in the features in repose, which yields nice shades of distinction. The emotions have made their own record in the lines of the face (best seen in repose), which are only momentarily disturbed by any tricks the parts may have learned.

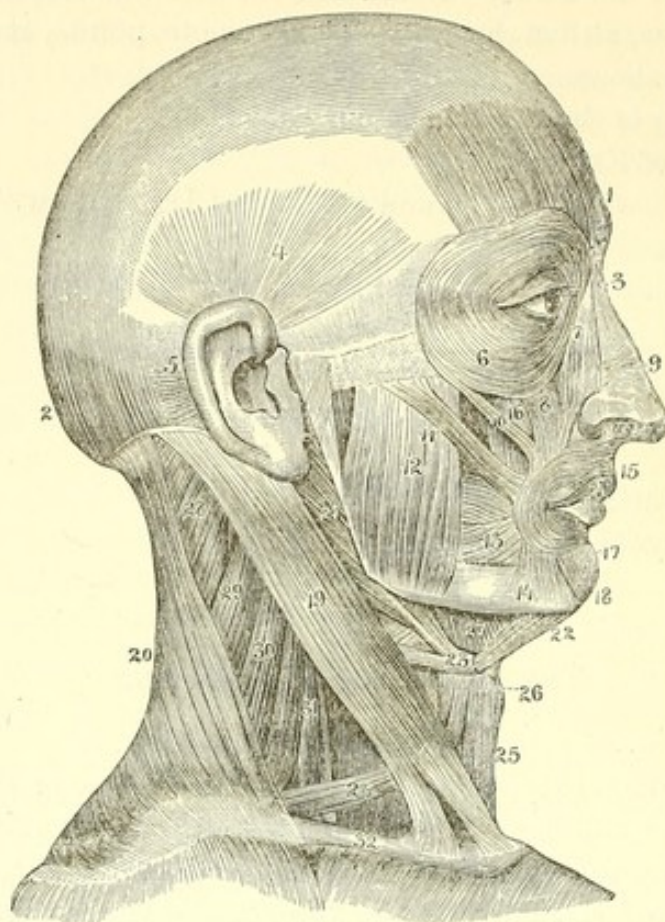
Wrinkles are caused by the superficial muscles being intimately united with the connective tissue and skin. A contracting muscle must perforce break up the skin over it into a number of transverse folds.

Healthy children with rotund cheeks have no wrinkles; but in the subjects of hospital marasmus (the scourge which annually sweeps away so many of our foundlings) the face becomes wrinkled like an old man's. We hold that, when the nutrition is fair, the study of the wrinkles gives us a guide to the position and meaning of the muscles, and we propose to invite attention to some of them. While we speak familiarly of faces "wrinkled with care," we shall see that the expression of the more pleasing emotions begets by far the greater number.

The region of expression is limited above by the frontal eminences, at the sides by the cheek-bones and by lines drawn thence to the lower jaw. The lower boundary of the region is defined by the chin. Within

this space are found all the facial muscles proper. They are easily associated in the mind, since they are supplied by the same nerve.

FIG. 1.



The muscles of the face are nineteen in number, and are divided into three groups, as follows :

(1) The fronto-palpebral group, including the frontal portion of the *occipito-frontalis* and *pyramidalis, nasi*, the *orbicularis palpebrarum*, and the *corrugator supercilii*.

(2) The nasal group. This comprises the several muscles about the nostrils. They serve to dilate or contract these openings. They are quite unimportant, and need not take our attention at this time.

(3) The oral group, including the *orbicularis oris* and the muscles inserted into it.

It is a noticeable fact that when muscles have delicacy of function, and denote peculiarities of the individual, they are subject to great variation. Such are those found in the face and the interior of the larynx. What muscles excel, in mobility, those of the countenance? or, in their combinations, those which control the voice? Their phases of form, while interesting to the physiologist, are confusing to the anatomist.

If it had been part of our plan, we could give many examples of



variation in the muscles of the face, but as they are of no practical importance we must pass them by. It is well to remember, in reviewing any arrangements of muscles by regions or layers, that the regions merge and the layers interlace. We must rest content with an arrangement which preserves harmony with familiar phenomena, while it is one easily remembered. We claim for our own a greater simplicity than Gray's, in which five distinct regions—viz.: the palpebral, nasal, superior maxillary, inferior maxillary, and inter-maxillary—are made; and greater consistency than Henle's, where the occipito-frontalis and orbicularis-palpebrarum are removed from the facial muscles.

**THE FRONTO-PALPEBRAL GROUP.**—The frontal portion only of the *occipito-frontalis muscle* (1) belongs to this group. The small posterior portion (2) is, physiologically, a distinct muscle operating upon the epicranial aponeurosis from behind. The frontal division is flat and thicker below than above. It consists of a median and two lateral portions in function, although the scalpel can demonstrate but one continuous layer. The median portion passes from the center of the forehead to the bridge of the nose, where it has been described as the *pyramidalis nasi*. It is, however, in no way a distinct muscle. The *origin* of the median portion in truth is from the nasal bones,—the *insertion* on the epicranial aponeurosis. The lateral portions may be said to arise from the last-named structure, and to be inserted into the brows beneath the orbicularis. The outer fibers are short, and are gradually lost upon the superficial temporal fascia.

The *orbicularis palpebrarum* (6) is comprised of two distinct portions,—the palpebral, covering the lids, and the orbital, surrounding the edges of the orbit. The palpebral layer arises from the palpebral ligament, and describes its ellipse entirely upon the lids. The orbital layer describes a larger curve. Its inner or nasal border is fixed to the bones about the corresponding orbital edge, where some of its fibers pass upward to the forehead, and a few less powerful fibers are lost in the elevators of the lip. Its outer and inferior edges are free. The fibers entering into the brow are short, curved, and compact; those overlying the cheek are more sweeping, and exhibit a looser structure. The intimate association of the upper and inner portion of the orbital division of the muscle with the frontal is at once seen when we come to study its functions.

The *corrugator supercilii* is generally described as a distinct muscle. It arises from the frontal bone, and is inserted a little above its points of origin into the orbicularis.

Now the two last-named muscles are strictly symmetrical, and can be separately contracted. We believe, to properly understand their actions, it becomes necessary to view the frontal muscle as we have proposed, reserving each lateral portion to the orbicularis and corru-



gator of its own side, and the median portion to a distinct group of fasciculi.

When both lateral portions contract, the brows ascend, and the space between them is slightly widened. The forehead is broken up into transverse wrinkles, which are more numerous at the sides than in the center, and are convex upward,—*i.e.*, concentrically with the curve of the brows. The wrinkles that form in the median space of the forehead do so perforce of the lateral contractions. The wrinkles here are generally but two in number, and are concave downward,—concentrically with the line of growth of the sparse hair of the inter-orbital space. In the forehead of the aged in repose, one sees three sets of wrinkles—a symmetrical set of the first division, small and numerous over the frontal eminences,—and a single median one composed of U-shaped lines.

When the brows are raised, and an effort is made to adduct them, they do not approach on the plane of their elevation, but at an angle downward and inward. This is caused by the corrugator supercilii muscles. The outer wrinkles now scarcely at all appear; the median ones persist, and a new set are seen at an angle to the last over the inner portion of the brow. These may unite with the transverse ones, and form what Mr. Darwin, in his "Expression in Man and Animals," has called the rectangular folds. But it has already been seen that the vertical member of the folds tends to be oblique by virtue of the corrugators, and the transverse ones are concave downward. Some individuals can attain in this act a higher degree of perfection than others; but with most the tendency to adduction overbalances the elevation of the inner extremity of the brow. In that event the internal orbital space is ridged by the approach of the brows into a single broad vertical fold, with two smaller ones at its sides. This is the frowning act, and is intensified by a transverse depression at the root of the nose.

At the stage when the brows are elevated, as above described, in order to demonstrate the rectangular folds, if a powerful effort be made to act upon the median fibers, the median wrinkles can be made to deepen, and the fibers, therefore, contract with depression of the brows, thus demonstrating their capacity to draw the scalp forward, while the outer fibers are already tense in keeping the brows elevated.

Mr. Darwin considers that "the central fasciæ of the frontal muscle are the antagonists of the pyramidal, and if the action of the latter is to be especially checked these central fasciæ must be contracted." (*Ibid.*, p. 190.) We cannot consider the pyramidalis as a distinct muscle from the frontal. The appearances already described can be explained without seeking for an antagonism between the median division and any muscles placed below it.



The action of the *orbicularis* is divided into the act of closure of the lids, and the adduction of the outer free edge. If in a dissection the skin about the eye is carefully removed by making an incision along the outer margin of the frontal muscle, and the orbicularis muscle with the former turned forward as one layer, we will observe as we approach the orbit a few fibers of attachment of the ciliary portion upon its outer margin. The contraction of the ciliary fibers between this attachment and the palpebral ligament must assist in depressing the upper lid. But with this exception the orbicularis has no connection with the outer orbital edge.

When the entire muscle is contracted to its utmost the brows descend, and are adducted as in frowning,—the motion ensuing from the outer toward the inner side. The changes in the skin caused by the act, in addition to those already seen in the brow, are first a depression below the inner canthus, extending to the fulness of the cheek,—a number of small vertical folds in the lower lid at the outer canthus,—a large number of wrinkles placed radiately to the outer malar portion of muscle from about the end of the brow around to the fulness of the cheek, making the old woman's "crow's-foot." The upper eyelid is depressed by the palpebral fibers; the lower eyelid is elevated by the general orbicular contraction.

If the skin over the face be watched during the orbicular contraction, the eminence of the cheek is seen to move slightly upward and inward. This is greater in some individuals than others. We have frequently seen a prominent vertical fold of skin lie between the side of the nose and the cheek fulness. If this fold is in a line with the elevators of the upper lip, and when the contraction is excessive, as in the attempt to separate the lids slightly while endeavoring to discern an object in the heavens at bright midday, the elevators themselves are induced to contract, and the upper teeth are disclosed.

From the extent of the outer fibers of the orbicular portions of the muscle we find that the points of origin of the zygomatic muscle and elevator of the upper lip are concealed. In certain diseases of the malar bone the orbicular fibers may become fixed, and imperfect contraction of the muscles surrounding the eye ensue. A case of a boy who had suffered from strumous caries of this bone recently came under our notice, which was remarkable for a depressed cicatrix over the malar prominence, and a retraction downward and outward of the lower eyelid. It was proposed to introduce a tenotome beneath the skin at the side of the depression, and by removing the point of tension to restore the parts to their normal position. To this, however, the parents of the boy would not consent. There was every prospect of this procedure relieving the lad of a deformity. In cicatrices the results of burns of the face, the eyelids are often distorted from a similar cause



to the above. In cases of gunshot wound of the face in which the ball has entered at the malar bone, the retraction of the skin and the orbicular fibers invariably produces the same malposition of the lid. The surgeon is often called upon to relieve the spasmodic contractions of the orbicularis, which come on as a result of prolonged conjunctivital irritation. A method often resorted to is to freely divide the malar fibers of the orbicularis, on a line with the external canthus.

The lower eyelid is free from fat. The connective tissue beneath the delicate skin is abundant. In many persons at middle age the lids sag, and become slightly œdematous. In the ecchymosis following a blow upon the eye, the blood collects in quantity in this loose baggy structure. In operations upon the lower eyelid the same tendency is seen. The "black eye" following the removal of a small tarsal tumor is often, for this reason, of unexpected annoyance to the patient.

THE ORAL GROUP.—The *orbicularis oris* is a true sphincter, and is by some called the sphincter oris. Occupying the entire thickness of the lip, it gives it the fleshy character so characteristic of this portion of the face. As a rule, the fibers of the upper lip are better developed than the lower, and their plane takes a more advanced position in the profile, while the demarkation line between the skin and mucous membrane is more sharply defined in the upper than in the lower lip. This is especially true of the lip in the young subject. We find that the human face as represented in Greek sculpture possesses a redundant upper lip with flexible angles. It gives a sensuous expression to the otherwise severe countenance. This is a mannerism due to the peculiarities of the Greek model, which, as is known, is based upon the proportions of the adolescent.

The upper lip is marked by a vertical median groove, the *philtrum*. It is believed by some authors to represent a weak point in the upper oral fibers. This opinion can receive no support from analogy. The depression below the lower lip is caused by the fixation common to all the proper chin tissue at the symphysis of the jaw, abruptly ceasing near the inferior margin of the mobile lower lip. The muscles of the oral group are arranged as radii to the ellipse of the orbicularis. The elevators and depressors of the lips are placed more or less vertically to the upper and lower fibers respectively; but the elevators, depressors, and adductors of the angles, are placed obliquely to the angles: the two first mentioned from the angle outward,—the last mentioned from the angle inward. For example, the elevators of the angles,—the *zygomaticus* and the *levator angulis oris*, find points of origin to the outer side of the angle above; the depressor—the *depressor anguli oris*—to the outer side below; but the adductors, the *M. incisivus labii inferioris*, and *M. incisivus labii superioris*, of Henle, which are the same as the "special fibers" mentioned by Gray, "by which the lips



are connected directly with the maxillary bones and septum of the nose," pass chiefly from the alveoli outward into the angles. Now the oblique are collectively more powerful than the vertical fibers. It is to this circumstance that expression is localized to so great a degree about the angles. Sir Charles Bell, in his classic essays on the *Anatomy of Expression*, has said that "the parts of the human face the most movable and the most expressive are the inner extremity of the eyebrows and the angle of the mouth." Of the two localities, the preference should be given to the latter. How few emotions are interpreted which do not call upon the muscles effecting changes at the angle of the mouth? And in the countenance which retains an expression in reserve,—where the tonicity of the parts are the only tell-tales,—how important a feature is the angle in study of physiognomy? Its position remains fixed in all conditions of nutrition. In the plump face of youth, before the rigid lines of maturer years are formed, or even at this time, when "sorrow hath struck so many blows and made no deeper wounds," the angle appears receding. The play of expression about it, as it lies shaded from the full outline of the cheek, adds to the beauty of the form as much as the tint of the skin gives warmth of color.

The only acts the orbicularis can perform unassisted are those pertaining to its proper use as a sphincter. Whistling and sucking are conspicuous among these. The vertical and oblique fibers perform more complex duties.

To speak first of the elevators of the upper lip. The thin sheet of muscular fibers extending from the side of the nasal process of the superior maxillæ to the lower edge of the orbit to above the opening of the infra-orbital canal, and divided into slips,—a nasal and a facial,—passes downward to be inserted into the alæ of the nose and the upper lip. Henle calls this muscle the *M. quadratus labii superioris*. We are in the habit in our schools of denominating each slip under a distinct name,—the nasal slip as the *levator labii superioris alæque nasi*, and the facial slip the *levator labii superioris*; while to the latter may be added the *zygomaticus minor*. Let us pray that the time may soon come when we can sweep away such pedantic rubbish from anatomy! No conscientious teacher can permit himself to employ two names where one does as good service. When the muscle contracts, it elevates the side of the lip and the wing of the nose. We have alluded to its harmonious action with the orbicularis in violent squinting. Owing to the slight convergence of the muscles of the opposite sides, when both contract the skin of the side of the nose is raised into oblique folds, the brow descends, and the lip and sides of the nose ascend, so that the root of the nose is wrinkled transversely as well, and the lower eyelid is pushed up and thrown into transverse wrinkles.



The elevation of the lower lip is, as a rule, associated with a little tension of the angles, and it is from the appearance of this shape in expressions of assumed dignity, that the muscle is often spoken of as the *superbus*. During its action the integument of the chin is corrugated. The depression of the lip is a simple act, to which the platysma myoid is in part accessory.

The tractors of the angle will now take our attention. The *zygomaticus major* and the *depressor anguli oris* are about on the same plane. The *levator anguli oris* is on a much deeper one, almost indeed, if not quite, on a plane with the buccinator. The fact that there are two oblique tractors above and only one below, shows with what greater ease we raise the oral angles than depress them.\* The "*mens sana in corpore sano*" lifts the emotions, as it were, and so adjusts the apparatus of expression that the face is ready to break into a smile at the faintest provocation. In so doing, the cheek tissues are shortened along the axis of the elevators, noticeably that of the *zygomaticus*. A deep groove is formed, extending from the upper margin of the nasal ala toward the angle. If the cheek is full, and the deposit of fat abundant, it is not wrinkled, but pushed up, raises the lower eyelid, and makes many "crow's-feet" about the outer angle of the orbit up to the line of the brow. If, in the child, the skin of the center of the cheek is united to the berry-like lobule of fat which lies alongside of the anterior border of the masseter, a dimple forms at that point.

Now the naso-labial groove is not a simple line, but is composed of two, one starting at the depression about the alæ, and is lost upon the margin of the orbicularis. This line is sometimes double in old men. The second lies about three or four lines beyond the oral angle.

The union of these lines into one is not apt to occur before middle age. The first lines we have often found associated with the points of insertion of the elevator of the lip, and the second invariably corresponds to the other edge of the orbicular fibers. The *depressor anguli oris* in contracting exaggerates the naso-labial groove, and when both operate the lips are curved downward and compressed. Forced contraction of the depressors, with depression of both lips, will of course destroy the naso-labial fold. In old age the angles droop, and a new groove, passing down directly from the ends of the oral fissure, leads to the jaw, while both lips are furrowed by numerous vertical wrinkles. What we have termed the angle, in introducing our remarks upon the subject of expression of the oral region, is to be used in a different sense from the same word when used to indicate the point where muscles are inserted. The latter are invariably received within the lateral fibers of the orbicularis at the angles. These form in a dissection of

---

\* Observe the placid expression of the face in the robust victims of sudden death.



the muscles of the face a firm muscular mass, continuous upward to the elevators of the angle, downward into the single depressor, and outward into the buccinator. It is held against the canine teeth, and gives a passive expression to the "set" mouth of the adult, and limits laterally the labial vestibule, as distinct from the buccal. If we take a mouthful of air and throw it across the mouth from side to side, as in gargling, the lower jaw being elevated, we are conscious of the exactness and firmness with which the oral angles reapply themselves to the canine teeth after removal of the tension of the cheeks.

Thus, we find facial expression limited to a few acts, which are grouped about two centers: the inner extremity of the brow and the angle of the mouth. The formulated descriptions of these acts are crude, compared to the subtle combinations employed in every-day intercourse of thought and feeling. We might compare the difference between the two to the analysis of the laryngeal muscles of a bird, and the attempt to explain thereby the exquisitely modulated song poured tumultuously from its throat. But we do not essay the æsthetic studies to which the contemplation of this subject would naturally lead us.

To the professional man the facial expressions are of great value: they inform him of the prevailing tendencies of the mind; prepare him for the difficulties he will encounter, besides guiding him in his selection of artificial dentures. No dentist neglecting the relations between facial and dental expressions can reasonably hope to achieve the highest success. He should, therefore, make a study of faces, searching for meanings among their folds and depressions, and, by studying the wrinkles of others, gain a useful "wrinkle" here and there for himself.

### *The Surgical Anatomy.*

We have found that the muscles of expression have two centers of motility,—the inner portion of the brow and the angle of the mouth. The main line of motion of the former is from the side of the region toward the median line, and of the latter from the median line to the side: for we frown, *i.e.* contract, the brows, with greater ease than elevate them; and smile oftener than "purse" the mouth. It is necessary, lest the pen run away with our judgment, to leave the inviting field of physiognomy and study the region of expression from a surgical point of view. But before doing so we beg the space of a paragraph to speak of two things.

The first of these is the curious expression often seen in cases of shock after injuries, and which appears as a prodrome to insidious symptoms. "The countenance," writes Dr. Geo. McClellan,\* who has well described this sign, "is unnatural. It presents an inquiring, anxious

---

\* Surgery, p. 18.



look about the forehead, eyes, and upper portions of the face, while all about the mouth and lips is smiling and composed." The second is the expression of the face due to loss of antagonism of the muscles, or to distortions consequent upon pressure of tumors. Facial palsy is a subject of such importance that we must reserve its consideration; the distortions from pressure will be alluded to incidentally as we point out the anatomical relations of morbid growths. Of what do we then speak? Of a very important feature; concerning which both palsy and mechanical distortion are interested, and to which the retracted and depressed oral angle are common,—namely, the effect of an active platysmus myoid muscle upon the inactive or weakened tissues of the face.

*Revenons à nos moutons!* The region of expression is remarkable in the arrangement of the *fascia*. In most regions of the body there is found after removal of the skin two delicate divisions of connective tissue, the superficial layer permitting free motion of the skin upon the muscles, and being a favorite site for deposition of fat, the deeper one affording vaginæ to the muscles, and fixing the direction of their lines of traction. In the region before us we find a different arrangement. The skin here is not separated from the fat which lies beneath it, nor are the muscles ensheathed, but instead, the fat and muscles are intricately associated. Indeed, the only muscle of the face having a fascial covering is the buccinator.

This absence of fascia is compensated for by cushiony masses of connective tissue, which are conspicuous in the following localities: the hollow of the cheek; beneath the zygomaticus, and over the buccinator muscle, especially near the root of the coronoid process; beneath the lower fibers of the orbicularis palpebrarum, particularly where it overlaps the elevators of the upper lip; between the latter muscle and the elevators of the oral angle; at the groove for the facial artery as it passes over the lower jaw; and at the symphysis beneath the depressor of the lower lip.

The skin of the face is everywhere thin, so that its scars are as a rule inconspicuous. A very different result follows extensive cicatrization of the deeper parts. Here, as seen after ulcerations from mercurial sore mouth, or destructive stomatitis from any cause, the connective (*i.e.* fibrous) tissue is abundantly present, and serves to contract the oral fissure, and for the most part converts the cheeks into intermaxillary ligaments binding the jaws. Hence we find in such cases ankylosis of the temporo-maxillary articulation.

In conditions more exactly approximating the normal one, as in ecchymosis following injuries, or in facial emphysema, we have proof that there is free communication through the region of expression by means of connective tissue. Ecchymosis is commonly limited to the injured spot. But sometimes, as in old persons, it may be extensive.



After fracture of the jaw, ecchymotic swelling may rapidly spread from the point of lesion under the skin of the neck and upon the chest upward to the cheek, to the lower eyelid of the opposite side, as well as inward to the mucous membrane of both hard and soft palate. Emphysema of the face is more rare. It follows fractures of the frontal bone over the frontal sinus, when it will be limited to parts about the forehead; or ensues upon an ulcer of the mucous membrane. T. P. Heslop\* narrates a case of emphysema in a little boy, aged four years, who, while recovering from measles, was attacked with ulcers at the angle of the mouth. Emphysema extended thence downward from the mouth along the entire length of the trunk. The disease terminated in death. It was found at the autopsy that the mucous membrane at the oral angle was separated from the integument, "so that the handle of a scalpel could be inserted nearly an inch into the cheek."

*The Fat.*—The fat of the face is abundant beneath the cheeks, but is sparsely distributed upon the lips, nose, eyelids, and forehead. The fibers of some of the muscles are interspersed with lobules of fat, as is notably seen in the depressor of the lower lip. As a rule, however, it lies either beneath the skin and around the more superficial muscles, or is less uniformly distributed among the deeper ones. A pad is quite constantly found beneath the quadrate elevator of the upper lip and the elevator of the oral angle, and a second between the latter muscle and the bone about the infra-orbital nerve at this point.

The fat everywhere presents a granulated appearance in the infant. The fullness of the cheek in the young is not due to the superficial layer alone, but to the deeper-seated mass lying partly upon the buccinator and partly upon the masseter muscle. This has received the name of the "button," from its figure, which is abruptly constricted at its base where it is continuous with the fat of the temporal fossa. The "button" resembles omental fat; it is surrounded by capsule-like connective tissue, and is crossed by branches of the transverse facial nerve. The prominence of the cheek is made yet more decided by the receding chin. As a natural result, should a child slip and fall upon the face, the cheeks suffer. If the laceration passes through the cutaneous layer of fat, and involves the "button," this structure may appear between the lips of the wound, as was seen in a case of Boyer's.†

*The Arteries.*—The arteries of the face are the facial, internal maxillary, and some of the terminal branches of the ophthalmic.

We will treat here only of the facial (Fig. 2, 6). This vessel is the third branch of the external carotid, and passes obliquely upward and inward toward the median line of the face. It is divided into cer-

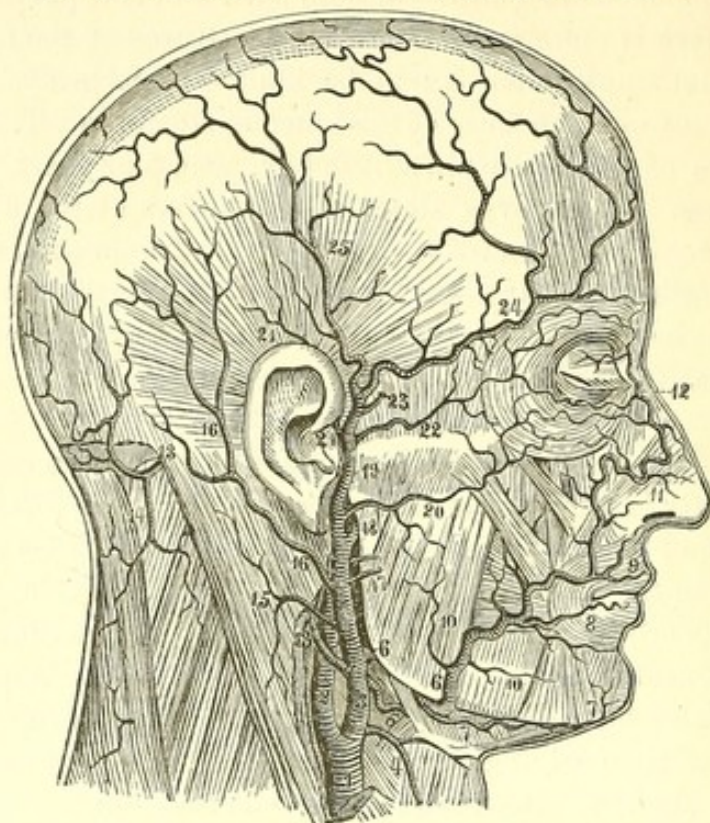
\* Med. Times and Gazette, 1868, 138.

† Recorded in Blandin's Surg. Anat., Am. ed., p. 85.



vical and facial portions; the latter again into the mandibular, oral, and angular or nasal.

FIG. 2.—SUPERFICIAL ARTERIES OF THE FACE.



6, facial artery; 7, submental; 8, inferior coronary; 9, superior coronary; 10, muscular branches; 11, small nasal branches; 12, angular artery.

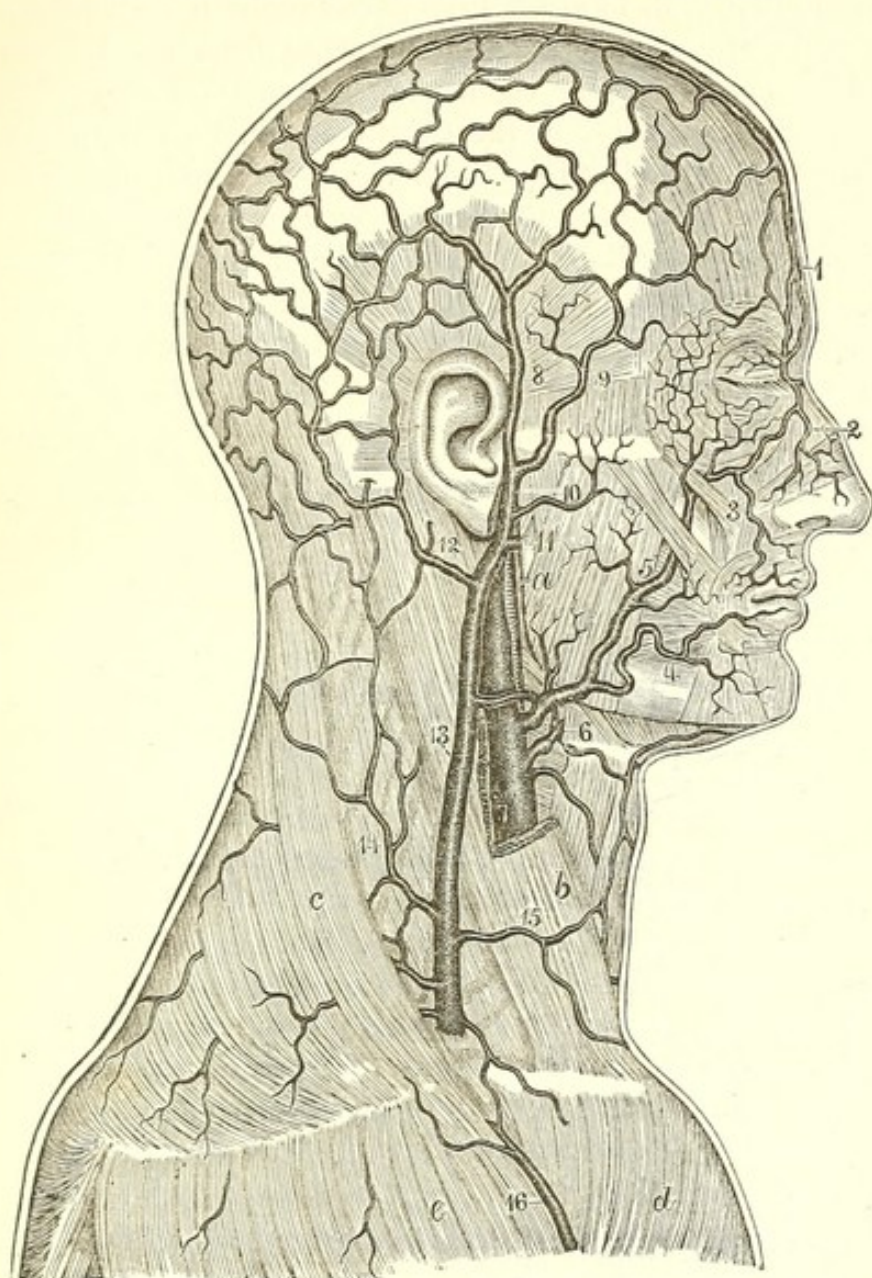
The *cervical portion* is short and tortuous. It lies in the loose connective tissue of the supra-hyoid space, and is remarkable for its intimate relation with the submaxillary salivary gland. It gives off a small branch, the submental (Fig. 2, 7).

The *mandibular portion* lies upon the lower jaw. It is covered by the *platysmus myoides*, and has the facial nerve lying to the outer side. At the oral region the artery passes directly to the outer side of the fleshy angle of the mouth. It is here covered by the *zygomaticus major* and the facial slip of the *quadrator labii superioris*. It again becomes superficial at the inner border of the latter muscle, when it is named the *angular artery*. No branches of note are given off from the outer side of the facial. The inferior labial branch (not shown in Fig. 2) goes to the muscular tissue and skin of the chin. The coronary branches (Fig. 2, 8, 9) go to both upper and lower lips, and present the following peculiarity,—they lie near the mucous membrane. This is particularly noticeable in the superior coronary branch. Its pulsation can be readily felt by the finger when placed within the mouth. Occasionally blows upon the lip will lacerate the walls of this vessel, when



hemorrhage of a confusing character may take place. Mr. Erichsen\* narrates an instance where bleeding from the above cause was allowed to take place unnoticed until, from the amount of blood which had been swallowed, the stomach rejected a large clot, to the great alarm of the patient and surprise of the physician.

FIG. 3 —THE SUPERFICIAL VEINS OF THE FACE.



1, frontal vein; 2, nasal vein; 3, 4, labial veins; 5, facial vein; 7, internal jugular vein; 11, internal maxillary vein.

The most important practical relation, however, of the facial artery, is at the point where it crosses the lower jaw. In consequence of the loose connective tissue at this point, when the vessel is divided the

\* System of Surgery, Am. ed., p. 378.



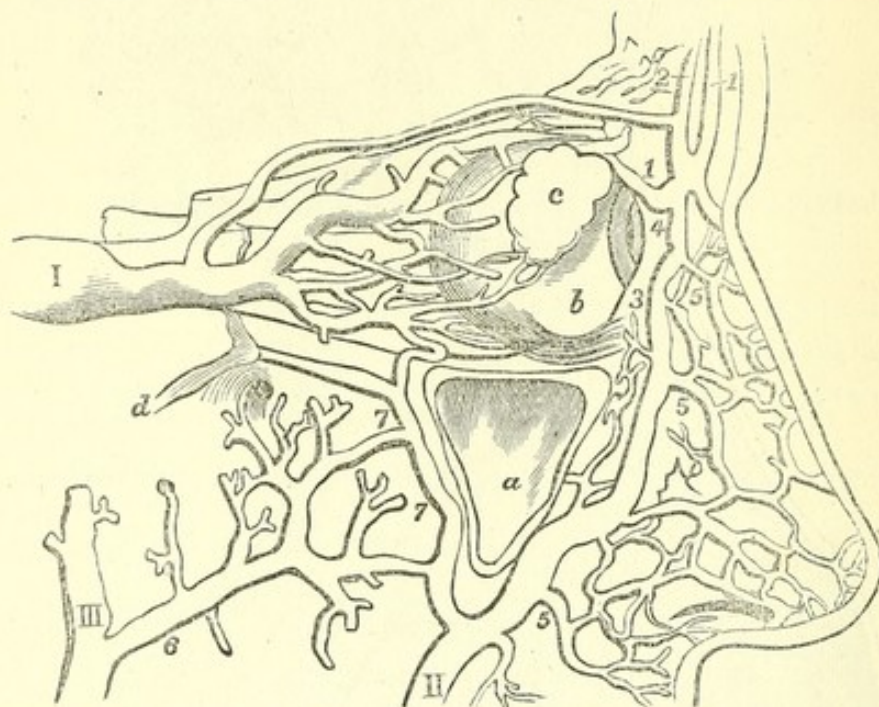
cardiac end will retract to a great distance, and much trouble is experienced in finding it.

*The Veins.*—The veins of the region of expression are of two kinds, the superficial and the deep. The superficial are the frontal, the supra-orbital, and the facial; the deep are the ophthalmic, the maxillary, and the infra-orbital.

The frontal (Fig. 3, 1) arises from the anterior portion of the scalp and the forehead, and receives some branches from the anterior temporal. It passes down near the median line of the forehead to terminate partly in the branches of the ophthalmic, and partly in the facial vein. In the living subject the frontal vein is well seen during the acts of frowning and laughing: the former in consequence of the frontal turgescence caused by the adduction of the brows on the vessel; the latter, by the contortion of the parts about the cheeks and mouth, preventing an easy descent of the frontal blood along the facial vein, and compelling it to take the narrower channel through the orbit.

The supra-orbital (Fig. 3, 2) is a smaller trunk than the frontal. It

FIG. 4.—DIAGRAM OF THE VEINS OF THE FACE AND ORBIT.



1, 1, frontal vein; 2, supra-orbital; 3, angular; 4, anastomotic branch between angular and frontal; 5, 5, 5, lateral nasal veins; 6, internal maxillary; 7, 7, anastomosing branches with ophthalmic and facial. I. ophthalmic; II. facial; III. temporo-maxillary; a, maxillary sinus; b, eyeball; c, lachrymal gland; d, superior maxilla.

carries blood from the brows and empties it chiefly into the orbit, though sending an anastomotic branch to the facial. The main portion is remarkable for running the entire length of the orbit before joining the ophthalmic.

The facial vein (Fig. 4, II. 3) at its beginning lies at the side of the



root of the nose, where it is accompanied by the terminal portion of the facial artery. It soon, however, leaves the artery, and, pursuing a less tortuous course than it, descends the face beneath the orbicularis palpebrarum; avoids the region of the oral angle, but affects that of the hollow of the cheek. Here it lies beneath the zygomaticus major in front of the parotid duct, is crossed by branches of the facial nerve, and is surrounded by loose connective tissue and fat. It again approximates the facial artery at the mandibular region, lying to its outer side. The facial vein receives numerous tributaries from the nose, lips, and chin. It is important to remember that the vessels of the latter locality pass into the anterior jugular as well.

Of the deep veins we need say little at this time. We have seen how the ophthalmic (Fig. 4, I.) receives most of the blood from the forehead, and are prepared to learn that the internal maxillary, which answers to return the blood of the artery of the same name, will communicate with the facial vein at more than one point, as well as with the ophthalmic vein.

It will be seen that the venous supply of the face differs in some important particulars from that of the trunk or limbs. In the last named localities both deep and superficial currents flow in the same direction towards the heart. But in the veins of the face a marked contrast presents itself. The facial trunk for example is not formed by primal capillary tributaries, as is commonly the case, but by communicating branches (Fig. 4, 1, 4) with the frontal and supra-orbital veins, and a transverse branch found at the bridge of the nose. It is highly probable that much of the blood of the inter-orbital space and the locality about the inner canthus flows through the orbital conduits to the cavernous sinus. Farther down the face we find the infra-orbital artery associated with *venæ comites*. These, which are peculiar, since no other facial vessel possesses symmetrical accompanying veins, promptly join the orbital series, or aid in swelling the volume of the internal maxillary vein. The veins corresponding to the deep parts of the face other than those mentioned also seek outlet in the same trunk, so that much of the superficial blood of the upper part and side face passes *inward* to the brain-case and the interior of the facial region, while the remaining portion only flows *downward* to join the superficial jugulars.

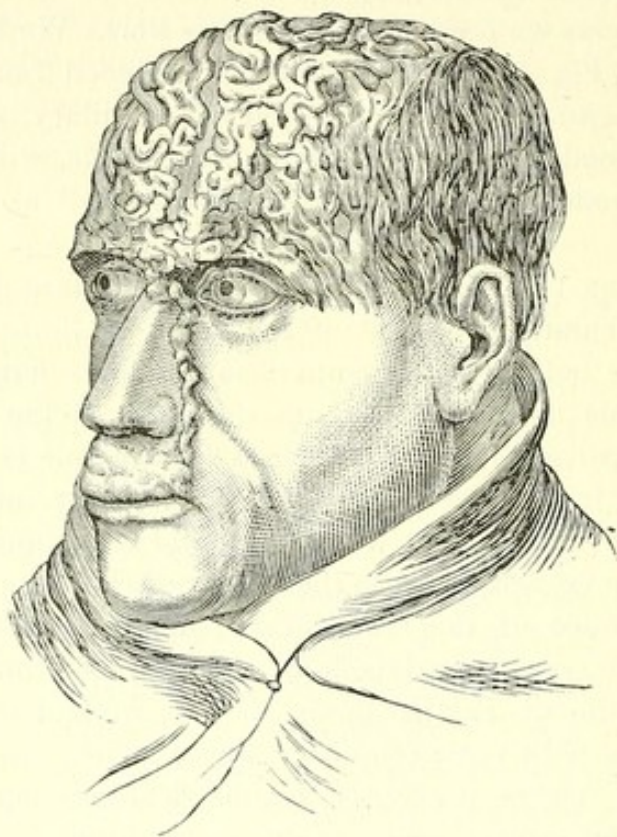Viewing the subject from a clinical aspect, which is the one which we as professional men will naturally select, we cannot fail to note that in cases of inflammation of the veins of the face the spread of the disease is *upward*, except when the disease originates in the lower lip, when, as a rule, it is downward. We can explain these phenomena in no other way than by stating that the venous blood naturally flows upward from the upper lip and sides of the nose, and downward from the lower lip and



chin. The absence of valves in the veins of the face explains the rapid spread of facial phlebitis when it has once been fairly inaugurated.

The most fertile cause of phlebitis is a peculiar pustular affection which has received the name of *facial carbuncle*. An outline of its symptoms is something as follows: A pimple forms at about the alæ of the nose and upper lip, although it may be seen in the lower, which is only remarkable for the pain which accompanies it. By the third day it is matured, and on the following day, if the disease takes a light phase, desquamation may be announced without apparent formation of pus.

FIG. 5.—MR. SYLVESTER'S CASE OF FACIAL PHLEBITIS (see page 19).



But, as a rule, pus forms in small quantity with or without an accompanying rigor, and the surrounding integument becomes brawny and of stony hardness. By the fifth day the eye is suffused and sensitive to light, and tender on pressure. At the end of the week it protrudes, and the vision is lost; or the lids are firmly closed and œdematous. The frontal veins may be involved, when the skin of the forehead will be swollen and reddened. Agonizing pain is now suffered; delirium happily ensues, and death ends the scene. Examination of the parts after death shows the facial vein *above* the pustule filled with pus, and the cavernous and circular sinuses occupied with a soft reddish clot; secondary abscesses may be found in other parts of the body. When the lower lip is affected, the swelling is apt to extend either laterally



from the side of the pustule to the ear, and downward along the neck. Death in such cases is due to exhaustion or to pyæmia.\*

Facial phlebitis, while a frequent result of carbuncular inflammation, is not dependent upon it. It may be excited by the bite of a dog or sting of an insect. Rarely it is of idiopathic origin. Of this the following case is an example: A soldier,† aged forty-two, was attacked with fever, followed by redness and slight swelling of the forehead. This swelling soon became more pronounced along the course of the fronto-temporal veins, which were hard, prominent, and of a violet color. The eyelids were œdematous, and the conjunctiva chemosed. The symptoms as described above followed, and the patient died about the seventh day.

A case (Fig. 5) recorded by Mr. T. H. Sylvester‡ is interesting, from the fact that the orbital veins escaped, and the frontals determined the extent of the inflamed tract. A puncture of the lip excited the phlebitis, which extended to a small vein at the outer side of the nose, thence to the inner canthus, and from that point along the frontal vein to the scalp, which became extensively infiltrated with pus. The case terminated fatally at the end of five weeks.

*The Lymphatics.*—The lymphatics of the region of expression lie for the most part along the junction of the cheek with the nose. They are received at this point from the central portions of the forehead, and pass downward over the face, thence into the submaxillary lymphatic glands. It is exceptional to find glands upon the face. A small one is rarely seen at the side of the root of the nose, and another about the size of a pea we have recognized, when enlarged, in a case of syphilis involving the jaws. Velpeau speaks decidedly of the median parts of the forehead and eyebrow being drained by a set of vessels distinct from those supplying the outer part in common with the temple and side of the face. If this be the case, we may expect diseases of the outer portion of the forehead to involve the lymphatic glands at the angle of the jaw, and those of the median portion the glands about the chin.

*The Porta.*—We have observed that the facial artery, vein, and some of the lymphatics cross the lower jaw between the anterior margin of the masseter muscle and the lateral margin of the depressor anguli oris. Here the parts are superficial, and being covered with the thin platysmus myoid muscle, fascia, and skin, can be readily compressed in the living subject. An appropriate name for this space is the *porta*,

---

\* In three cases recorded by Prof. Parker (New York Med. Journ., vol. xii. 368), all began at the lower lip. The upper lip became involved in two of them, with the head symptoms as above given. In two the lower lip sloughed.

† M. Blachez, Gaz. Heb., 1863, 716.

‡ Med. Chir. Trans., xxiv. 36.



since it is truly the gateway to the region of expression from the neck. If in burrowing of pus about the supra-hyoid space the face is involved, it is by means of pus entering the region of expression through the porta.

There is a point worthy of consideration in this connection, namely, the almost exact limitation of the branches of the artery and vein to the median side of their respective trunks. The only exceptions we recall to this are two in number, the masseteric branch of the artery and the palpebral branch of the vein, both of which are small. In the absence of other vascular structures to the outer side of the vessels, it at once suggests itself to the mind that an incision could be made here with less damage to important parts than any other in the region. If in the subject the integument over the porta is made tense by being drawn inward, an incision is made through the skin over the anterior edge of the masseter muscle, and extended thence upward and inward to the distance of one and a half inches,—the platysmus myoid is brought to view at the lower part, and the fat of the cheek fairly entered at the upper. The former structure being now divided, the jaw is at once exposed; the artery and vein are drawn well to the inner side and are not seen. With the aid of a little dissection, the handle of the scalpel can push the edge of the masseter a little backward, and the vessels well forward, so that the porta can be easily displayed. If the subject be emaciated the skin can be readily stretched backward completely over the angle; the masseter can be lifted a little at the middle of the anterior edge, and the scalpel with ease explore the parts beneath it as far as the base of the coronoid process and the glistening fibers of insertion of the tendon of the temporal as they pass down along the edge of this process. In the same manner the cheek can be pushed upward and inward, and display the deep fat in the hollow. The finger can now be readily passed upward behind the zygoma into the temporal fossa. An incision such as this, without wounding a single vessel, and dividing no part of importance (save the filaments of the facial nerve crossing the porta), affords an easy access to many remote points of the side of the face. Were such an incision made on the living subject, the only probable complication occurring would be the rigidity of the masseter muscle.

*Facial Edema.*—The effusion of serum into the tissues of the region of expression will be naturally determined by the distribution of the fat and connective tissue. Thus we find the lower eyelid a favorite locality for such collections when the fat is absent and the connective tissue is loose. In determining the degree of impairment in the return of the venous blood, the physician finds the amount of œdema present in the lower eyelid of great value.

Every dentist will at once recognize that the examples of swollen



faces coming under his notice are purely local in their origin, and are almost always due to irritation within, in the mucous lining of the mouth. We will instance the usual swelling accompanying the formation of an alveolar abscess. Here the transmission of diseased action is mediately from the tooth to the alveolus, and thence to the gum. Under aggravating causes this soon involves the mucous tissues. Having arrived at such a point, we can readily explain the subsequent enlargement of the side of the face, on the general principle which has been firmly established, viz., that inflammation of mucous surfaces tends to submucous œdema. This is subject to no exception where a serous or tracheal covering is absent from the mucous tract.\*

We expect, therefore, that the buccal and labial tissues will be first affected. The lips will be everted and thickened, and the eye will be closed—more, however, by the pushing upward of the lower eyelid by the engorged buccal tissues than by proper infiltration.

Another example of submucous œdema is seen in the conjunctiva. A very slight irritation will cause protrusion of this membrane; and when excessive, is seen to escape from the palpebral chamber and lie as a red and thickened fold between the lids. This condition is recognized as *chemosis*. Persistent chemosis leads to general infiltration of the structures of the lids when the subcutaneous tissues become involved. This, however, is not common except in severe general ophthalmia. The fact that a subcutaneous œdema may arise is an interesting fact, though it be dependent upon one which primarily is of submucous origin. In erysipelas of the face the swelling is from the first subcutaneous. Here we have a diffused redness commonly of a brilliant color, which may extend from the scalp downward, or, though less frequently, from the face upward. The greatest swelling occurs where the connective tissue is the least compact, as at the lower eyelid and the comparatively well-defined subcutaneous layer about the ear.

In the swelling which arises from blows on the face we expect some of it to be due to the effused blood from lacerated capillaries. It tends, however, to become submucous. An easy way of estimating the amount of swelling present in the cheek tissues is to pass the index finger of the right hand within the mouth, and the other on the skin without.†

---

\* In the latter case, as shown in the intestines, the presence of a serous covering materially modifies the process, and, indeed, forces the fluid, through increased activity of the follicular glands, directly into the alimentary canal; or in the trachea and bronchia (when the resistance of the bronchial and tracheal walls correspond to the serous membrane already mentioned), into the respiratory tract. But in the mouth, nose, pharynx, and the parts about the glottis, there is no such limitation, and an œdema is developed at once in the submucous tissues.

† In the swelling of decomposition the lips become greatly everted, and the lower eyelid puffed up. These are from both the above causes combined.



The position of local œdema of the forehead is determined as follows : The resistance on both sides of the thin and compact layer of tissue,—the skin without, and the pericranium within,—is so great that the swelling assumes a flattened form, and gravity will aid it in taking a position below the cause engendering it. Thus a person stung on the forehead by a bee will have the greater amount of swelling take place *below* the injured point. In a case of necrosis of the frontal bone, where the offending fragment was situated near the frontal eminence, we found the associated œdema near the median line at the brows. These collections are very deceptive. Their resisting boundaries give to the fluid the physical signs of an abscess, and if there be associated redness of the skin the incautious may needlessly open them.

*Inflammation.*—Inflammation in the face is, as a rule, circumscribed. This can readily be accounted for by the close connection existing between the skin and the subjacent parts. When it becomes diffuse, as in erysipelas and phlebitis, we are exceedingly liable to encounter systemic causes operating through and beyond the merely local manifestation. Abscesses of the face are, as a rule, small. They are commonly the result of acniform inflammation. Persons the subjects of chronic acne will occasionally present small abscesses, which may be mistaken for sebaceous tumors. The happiest results are obtained in their treatment by making a minute opening into the collection, and maintaining the patulency of the orifice, while a thick layer of collodion is applied to the skin.

*Gangrene.*—Notwithstanding the richness of its vascular supply, the face is at times the seat of mortification. This, however, is not the result of a purely local cause, except in the intense engorgement of the parts seen in cancrum oris, but is the result of arterial obstruction. Mr. W. Savory\* has narrated an example of this disease occurring in a male subject but thirty-six years of age. The disease began in the lower eyelid. Thence it passed to the eyeball, and afterward downward, exposing the malar, maxillary, and nasal bones, which crumbled away in successive small sequestra. The disease eventually attacked the base of the skull, and caused death by intra-cranial inflammation.

At times, pressure from an adventitious mass will cause sloughing, as occurred in a case mentioned by Mr. John Birkett:† a naso-pharyngeal tumor invading the face from behind induced sloughing of the cheek.

*Carcinoma.*—Cancerous disease of the face presents itself in three forms: epithelioma, the rodent ulcer, and encephaloid. Studying these diseases from an anatomical point of view, we find that epithelioma is found most frequently at the junction of skin and mucous surfaces,

---

\* Med. Chir. Trans., xxxix.

† Brit. Med. Journ. i., 1858, p. 119.



such as the edges of the eyelids, the nostrils, and the lips. Why it is so common on the lower lip and almost unknown on the upper, why rodent ulcer is more frequent at the outer canthus of the eye than the inner, we cannot explain. It is worth mentioning, however, that the lower lip and the outer canthus are more moveable than their opposites, and, therefore, less able to resist the localization of morbid action. Encephaloid disease of the region of expression is always secondary to its more deeply-seated origin. In obedience to the principles announced under the head of œdema, it is apt to spread along the mucous tissues before involving the skin, and occupies the loose subcutaneous structures of the lower lip to a remarkable extent.

Lardaceous cancer may also involve the face as a complication of malignant polypus. Mr. Collis\* has given us an example of this rare disease. A baker, aged eighteen, after an attack of measles, complained of difficulty of breathing through the right nostril. A polypus quickly made its appearance in this situation. "The skin of the nose, forehead, and face, became rapidly infiltrated with cancer-cells, giving the skin an appearance as if seen through a pocket lens. This condition extended over all the face and neck, the glands became distorted beyond belief, his breathing became affected, and finally he died exhausted by pain, dyspnœa, and difficulty in swallowing, in a year and a half after the first symptom of polypus."

*Chancres* of the face are exceedingly rare. Bumstead† asserts that the soft sore is here unknown. Indurated chancres of the lips are occasionally seen, and present appearances so closely resembling cancerous infiltration as to have deceived experienced observers.

## II.

### THE REGION OF THE TEMPLE AND "THE ANGLE OF THE LOWER JAW."

The region thus named is commonly included in that of the "side of the face." We think this is unfortunate, inasmuch as this term is synonymous with "profile," and the "profile" in its turn is inclusive of the region above named, with one-half of the region of expression. The North American Indians say of a portrait drawn in profile, that it represents but half a man. We may in the same way deprecate the use of the term "side of the face," as representing but half a region.

The region of the temple and the "angle of the jaw" is bounded anteriorly by a line dropped from the external lateral process of the frontal bone to the inferior border of the lower jaw, posteriorly by a line answering to the front edge of the external auditory meatus, supe-

\* Cancers and Tumors analogous to it. By M. H. Collis, p. 112.

† On Venereal Disease.



riorly by the temple, and inferiorly by the angle of the lower jaw. Were we called upon to define this region by a physiological test, we would say it is *the region of the distribution of the motor branch of the inferior maxillary nerve.*

*The Muscles.*—The muscles of the region are four in number,—the temporal, masseter, and the internal and external pterygoid. These are the masticatory muscles, so-called; but properly speaking they are the elevators and rotators of the lower jaw.

The *temporal* muscle, apart from its origin from the temporal fossa, has an important connection with the temporal aponeurosis. The latter membrane extends from the semicircular line to the zygomatic arch. It is thin and weak at its origin, but increases in thickness as it descends, and divides immediately above the zygoma into two leaflets, one of which is inserted upon the outer, the other upon the inner margin of the bone. Between the layers there is found a small quantity of compact adipose tissue. This, the description given in the books, it is necessary to repeat, to emphasize what follows. The muscular fibres arising from the aponeurosis take their origin from its upper third only. The remaining two-thirds are separated from the muscle by an increasingly wide space, which is continuous with the hollow of the cheek. It is filled with delicate, almost diffuent fat. It will be seen that the temporal fossa when the aponeurosis is in position forms a pocket with its mouth directed downward. The upper third of the pocket is entirely occupied with the muscle, the lower part only partially so. A moment's reflection will teach us the significance of this arrangement. The temporal muscle, while firmly fixed above, is very movable below. Not only from below downwards, as when the jaw is depressed, but from within outwards, as when this bone is elevated and semi-rotated, as in the act of chewing. It is necessary, therefore, that while the aponeurosis is firm below and its upper part fixed, that the loose fat should lie between it and the muscle to lessen friction. This is one of the few instances in the body where adipose tissue is used as a lubricator. Ordinarily this function devolves upon synovia either within sheaths, embracing the tendinous tracts their entire length, or bursæ, distributed at points of the greatest friction.

The tendon of the temporal muscle begins about midway between the zygoma and the semicircular line, and is entirely concealed by the fibres of origin from the aponeurosis. Some of the fibres of the muscle would appear to be inserted into the zygoma, and lie on the same plane with the fibres of origin of the inner division of the masseter.

An additional slip of origin arises from the lower edge of the temporal fossa to effect an insertion distinct from the main tendon, viz., into the *inner side* of the coronoid process. This is best displayed in a dissection of the pterygoids. Thus, after the pterygoids have



been removed, and the pterygoid process and the alveolar process of the superior maxilla sawn off, the inner surface of the masseter muscle will be displayed, together with these temporal fibres above named.

We can thus describe, in addition to the main radiating set of fibres inserted into the coronoid process, a set of fibres acting with the masseter, and another smaller set lying parallel to the line of action of the internal pterygoid muscle.

The *masseter muscle* is composed of two layers, an inner and an outer. The outer is tendinous at its origin from the superior maxilla and the malar bone, and muscular at its insertion into the lower jaw. The inner is muscular, tendinous at its origin, and chiefly tendinous at its insertion into the lower jaw. It is covered for the most part by the outer plane. The direction of the fibres of the first set is oblique downward and backward, that of the second nearly vertical. Both sets join at the anterior border of the muscle, so that a pocket is formed between them which opens backward. Monro described a bursa lying within this pouch. When it is remembered that bursæ are found in connection with parts which are subjected to friction, the presence of one in the above locality is suggestive that the two layers of the muscle must have distinct lines of action. The outer layer would appear to initiate the act of elevation of the lower jaw,—the shorter inner fibres to complete the act. The fact that the latter are on the same plane with the aponeurotic fibres of the temporal would indicate that these fibres act together.

The anterior border of the masseter is formed by a doubling of the two layers forming the pocket. It presents a thick columnar edge of fibrous tissue, which is seen to better advantage from the inner than the outer surface of the muscle. This border can be readily felt by the finger inserted between the cheek and the malar bone. Division of the masseter for false ankylosis of the temporo-maxillary articulation can be best effected by making a submucous rather than a subcutaneous tenotomy. It will, in all cases, be well to observe the effect produced in simply dividing the tendinous border before resorting to a free incision. Chattering of the teeth is caused by a peculiar state of innervation of this muscle, which differs in this regard from others. In tetanus it is among the first muscles to be affected, and is also instrumental in the mechanism of trismus. Mr. Dixon\* has described an instance of sloughing of this muscle in a young man. It followed intense inflammation, excited by a blow received upon the part a fortnight previously.

The *internal pterygoid* muscle is the complement to the outer fibres of the masseter. It is thick, and for the most part tendinous at its origin, and presents at that point on transverse section two imperfectly

---

\* Trans. Path. Soc. Lond., ii. 276.



defined cylinders of fibrous tissue holding a few muscular fibres within them. The fibres are inserted "dispersedly" upon the inner side of the angle and ascending ramus, muscular on its buccal free surface, tendino-muscular on its outer maxillary surface. Sappey compares the outer fibres of the masseter and those of the internal pterygoid to a penniform muscle. It is well to associate this arrangement with the relative positions of the two muscles as an aid to the memory, although it is without any real significance.

The *external pterygoid* muscle is smaller and more delicately composed than the preceding. It is divided both structurally and functionally into two portions. The superior of these arises from the base of the skull, and is remarkable in being the only muscle, save the anterior straight muscle of the neck, that has such connection. It is a little fleshy slip which passes outward and a little backward to be inserted into the capsule and inter-articular cartilage of the temporo-maxillary articulation. The inferior slip is the smaller of the two; it is inserted into the neck of the lower jaw.

The actions of the pterygoids are complicated. The massive internal pterygoid and the masseter act together in directly raising the lower jaw. But before it can do this the condyloid process, which has been tilted out of the glenoid fossa and rests upon the articular eminence, must be replaced. This is done by the external pterygoid; the larger slip operating on the jaw, the lesser one adjusting the capsule and the inter-articular disc. The external pterygoid holds to the temporo-maxillary articulation the same relation held by the popliteal muscle to the knee-joint.

It is worth mentioning in this connection that cancer of the facial region, after involving the bones at the origin of the masticatory muscle, will use the tendon of the muscle as a guide along which the infiltration will take place. A specimen of carcinoma of the superior maxilla is preserved in the Philadelphia Hospital, in which the disease, after involving the malar bone, spread thence along the masseter and the internal pterygoid muscles, to their complete destruction.

*The Fascia.*—Immediately beneath the skin of the temple is a well-defined, though thin layer of fat, which is continuous with that covering the parotid gland. On the temple this fat is in intimate association with the superficial temporal fascia and its continuation downward into the so-called parotid fascia. The manner of its connection with the tendon of the occipito-frontalis and auricular muscles is familiar to all students of anatomy. With a little care this fascia can be lifted from the parotid gland so as to include within it the superficial lamina of the masseteric fascia, the deep lamina being continuous with the cervical fascia. This arrangement would point to the conclusion that the masseteric fascia is derived from below (deep



layer) as well as from above (superficial layer). Between them passes the transverse facial branch of the temporal artery. Filaments of the facial nerve lie also in this position. By tracing the latter structure backward, or by freely elevating the fascia and the superficial lobules of the parotid gland from the position of the venules which are constantly found lying directly in front of the auditory meatus, the entire *pes anserinus* can be displayed.

The position of the firm masseteric fascia prevents the masseter muscle receiving its arteries and nerves from in front. The entrance of the artery into the muscle at the sigmoid notch caused Velpeau\* to assert that in dislocation of the lower jaw it is of necessity compressed.

*The Arteries.*—These are the branches of the *temporal*, and the origin of the *internal maxillary*. The temporal branches are three in number: the *anterior* and *posterior branches* of the superficial temporal proper, and the *middle branch*, which lies upon the outer side of the temporal muscle beneath the aponeurosis, which it pierces.

The pulsation of the anterior temporal is felt readily by the finger. It is said to be more conspicuous in the aged.

The remarkable position of the middle temporal artery is the same as that of the middle temporal vein. It is difficult to understand why parts so near the internal maxillary should have been directed inward from a superficial trunk, and compelled in order so to do to perforate an unusually resisting aponeurosis. It is probable that so significant a feature will be explicable only when the development of the parts is studied.

The deep temporal arteries, branches of the internal maxillary, pass upward along the floor of the temporal fossa, and supply the deeper parts of the muscle of the same name.

The great meningeal artery, usually not associated with the temple, may at times enter into an important surgical question. The vessel may not simply lie in a groove upon the inner surface of the parietal bone, but may be inclosed in a canal, which, as it passes upwards, approaches the outer wall of the skull. It follows that wounds of the scalp in the temporal region may be followed by hemorrhage from this artery without implying a fracture or other lesion of the skull. Begin and Krimer† have recorded a case of aneurism of this artery.

*The Veins.*—The names of the veins of the temple are the same as those just given to the arteries, and answer to them in position.

The union of the *internal maxillary vein* (Fig. 6) with the *temporal*, constitutes the *temporo-maxillary vein*. This lies within the parotid gland, about on a level with the ascending ramus of the lower jaw.

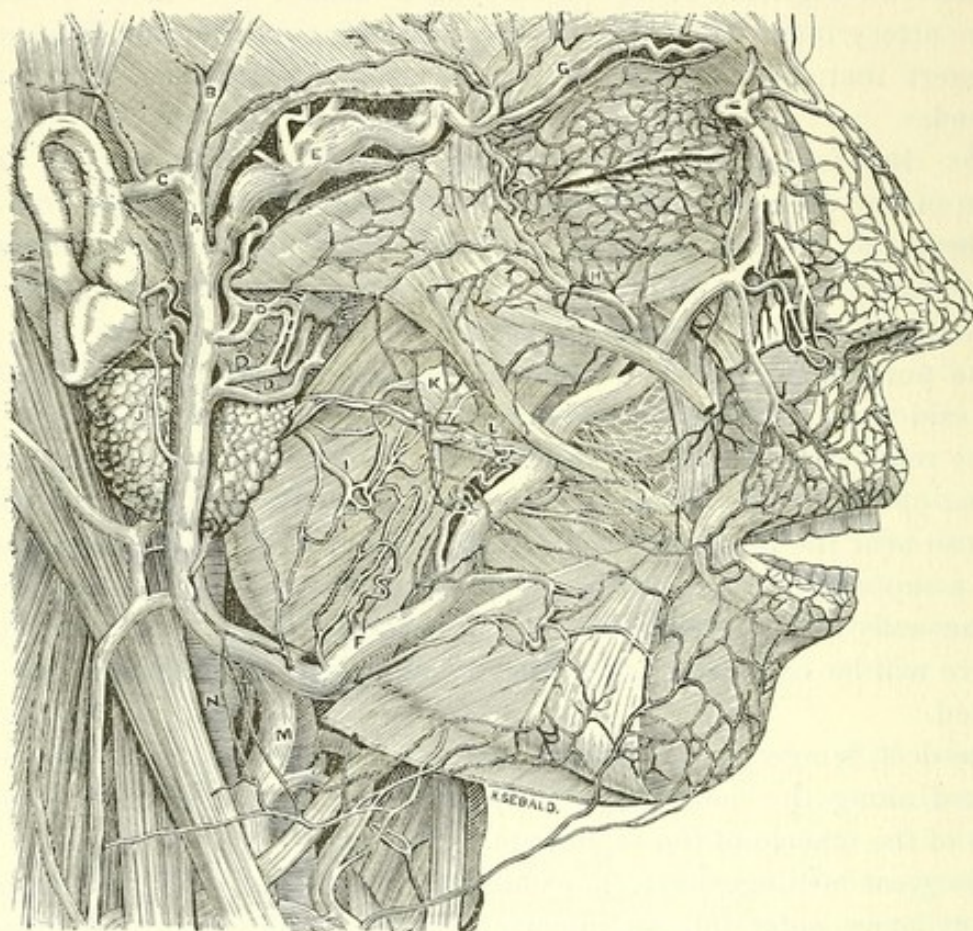
\* Chir. Anat., i. 80.

† Gazette Medicale, 1843, 530.



As is commonly the case within the facial region, the venous anastomosis is very free. We see for example the veins communicating with the *facial*, *ophthalmic*, *frontal*, and *occipital* veins, while numerous subordinate branches unite with one another on the face. A glance at the Fig. (6) will give a proper estimate of the degree of this anastomosis better than can be done by an elaborate description.

FIG. 6.—THE VEINS OF THE REGION OF THE TEMPLE, ETC., DESIGNED ESPECIALLY TO SHOW THE TEMPORO-MAXILLARY VEIN AND ITS TRIBUTARIES.



A, temporal vein receiving the anterior and posterior temporal (B, C); D, D, the internal maxillary veins, emptying into the temporal to form the temporo-maxillary vein; E, the middle temporal vein (slightly enlarged), to display which the deep temporal fascia over it has been removed; F, the facial vein; G, the supra-orbital branch, uniting with the middle temporal vein; H, the inferior palpebral vein, uniting with the same; I, the masseteric vein; J, the parotid gland; K, the socia parotidis; L, the parotid duct; M, the external jugular vein; N, the temporal artery.

We would invite particular attention to the intimate connections seen between the branches of the internal maxillary vein. The main trunk, as it approaches the temporal vein, may assume a plexiform appearance, best seen in the zygomatic fossa between the temporal and pterygoid muscles. It is a cavernous plexus, which surrounds the branches of the inferior maxillary nerve, and which communicates with veins passing through the oral foramen from the encranial cavernous sinus.



The pharyngeal vein, with the return blood from the soft palate, lies along the course of the pharyngeal artery. It receives some tributaries from the spinous and oval foramina, and empties into the external jugular at the lower end of the gland.

The minute vein found lying along the parotid duct is a good guide, since it is constantly seen in dissection, as the *temporo-facial* vein near the angle of the jaw is a good point to remember in studying the relations of the cervical lobule of the parotid.

Noticeable among the many striking features of the venous supply of the temple and the parotid region is the *middle temporal vein*, already mentioned in speaking of the artery of the same name.

It will be observed (Fig. 6) that this vessel is of relatively large calibre, and is in direct continuity with the supra-orbital vein.

This circumstance, in connection with its method of termination through the temporal aponeurosis, renders it liable in inflammation at the lids, particularly the upper, to become engorged. Hence the fullness about the brow in ophthalmia, and the indication for local depletion at the temple for some phases of this disease.

M. Billroth has described\* an example of a congenital plexiform "neurofibromatous" tumor of the "upper eyelid and temple." The patient, a young man about eighteen years old, occupation that of a waiter, exhibited an obtuse swelling of the left temple, which extended thence to the upper eyelid, completely closing and distorting the palpebral fissure. When the lid was elevated by the hand the vision was observed to be normal, and the motions of the ball perfect. The swelling was not abruptly defined, but involved to a slight degree the fat of the orbit and temporal fossa. The diseased growth was associated with a small point of defective ossification in the left parietal bone. The tumor was successfully removed, and did not recur. Here we have, undoubtedly, a congenital growth extending along the course of the middle temporal vein (although the fact is not mentioned by the recorder) and is an instance of an abnormal process depending for its interpretation upon a knowledge of anatomy.

Plexiform nævus of the parotid gland is sometimes seen. It is always a serious disease, not only from the difficulties attending an operation for its removal, but in consequence of the pressure often exerted upon the pharynx and associated parts. Mr. Gascoyont† has recorded a case of this disease which caused death by suffocation.

*The Lymphatics.*—The lymphatic glands of this region are of two sets: the superficial and deep. Those within the parotid gland are of

\* Beiträge zur Geschwulstlehre Langenbeck's Archiv für klinische Chirurgie, 1869, 232.

† Trans. Path. Soc. Lond., 1860, xi. 267.



the most importance. They are found along the course of the temporo-facial vein, the upper portion of the external carotid artery, and between the gland and the side of the pharynx. Their liability to enlargement and the important element thereby introduced into the study of parotid tumors are acknowledged.

They are subject to the secondary engorgement common to lymphatic glands elsewhere. Thus Humphry\* mentions epithelial cancer of the temple enlarging the glands within the parotid and about the angle of the jaw.

Hyrtil describes one or two which are constantly present near the *socia parotidis*.

### THE PAROTID REGION.

This is perhaps better called the retro-maxillary space,—a name proposed for it by recent German writers. It is an innovation we must be prepared to accept. For the nonce we will retain the old name, and define it as follows: It is bounded anteriorly by the ascending ramus of the lower jaw, posteriorly by the external ear and the pars tympanica of the temporal bone, superiorly by the convergence of the above-named lines, and inferiorly by a line drawn from the mastoid process to the angle of the lower jaw. This answers to the anterior border of the sterno-cleido-mastoideus, and the posterior belly of the digastric muscle. The floor of the space is crossed by the styloid process and its muscles; beyond these lies the lateral wall of the pharynx, toward which a process of the parotid gland is directed but does not quite reach.† That part of the space occupied by the parotid gland is known as the "bed of the parotid," and is in addition to the above limits defined externally at a level of the ascending ramus of the lower jaw. It will be remembered that it is at this point that the temporal vessels are found, together with the branches of the facial

---

\* Med. Times and Gazette, 1861, 522.

† Extirpation of parotid. Beclard. *Archiv. Général*, March, 1824. Trans. in *Lancet*, Feb. 29th, 1824.

The following is an account of bed after removal of tumor: The masseter dissected, facial artery bare, but not opened, was pulsating in front of lower part of masseter: the mastoid process and the sterno-cleido-mastoideus cut in front and on its inner surface, formed the posterior part of wound. Internally the styloid process, the external carotid, secured by two ligatures, the stylo-hyoideus, digastricus, and a little lower, the small portion of the tumor that was tied, formed the floor of the wound, which opened into the meatus auditorius externus. Patient died three weeks after operation. Post-mortem appearances: external carotid lost in fibrous tissue, the result of the cicatrix, which occupied the region of the parotid; there was no vestige of the gland. Internal jugular vein obliterated at the same height, but it was discovered a little lower down, communicating with the superficial branches.



nerve. It is convenient to speak of that portion of the gland *below* the parts mentioned as the deep-seated, and those *above* as the superficial. The superficial part is in contact externally with the parotido-masseteric fascia, and extends over the posterior fifth of the masseter muscle. The deep-seated part occupies the "bed" above described, and adjusts itself accurately to its walls.

In health the parotid cannot be said to have a well-defined capsule. But in diseased conditions a capsule is formed which enables the operator to enucleate the gland with comparative ease,—the situation of the gland and the important vessels traversing it, however, at all times making it a serious undertaking.

It is important for several reasons to remember the bearings of the parotido-masseteric fascia. When a swelling forms beneath it, as in mumps, it is prevented from appearing on the surface, and the turgescence is seen to best advantage upon the neck below the angle of the jaw,\* or more rarely within the pharynx, where it interferes with deglutition and the depression and elevation of the lower jaw. Pus forming beneath the fascia gives little or no evidence of its presence. If a swelling due to it be present, it is of a flattened form.† Sometimes the fluid, not finding vent externally, passes posteriorly, and effects exit into the external auditory meatus, as narrated by Velpeau.‡

The extension of a parotid growth may be reasonably expected from the position of the fascia in question to be less apparent on the face than about the angle of the lower jaw. Now it is here that the inferior lobule of the gland is found, which is much more free than the remainder of the gland, and often holds intimately within it the external carotid artery prior to its becoming the temporal. It follows that extirpation of the parotid in such cases becomes as much a cervical as a facial operation.

When a tumor is removed it also follows that the parotido-masseteric fascia is destroyed; and should the growth recur, it will from this fact be more conspicuous upon the face, since it no longer is resisted by the fascia, as has been observed by Schuh.§

The free inferior lobe of the parotid may be the seat of separate diseased action. Access from this point to that overlying the wall of the pharynx is easy, and it is not without surprise, therefore, that we learn that growths from this portion of the gland may affect the pharynx indirectly by pressure or directly by transmitted diseased action.

\* According to Monteggia (Malgaigne, Chir. Anat., i. 455), the swelling of the parotid gland in inflammation may press the condyloid process forward, thus simulating dislocation of the lower jaw.

† Hyrtl, Topog. Anat., i. 331.

‡ Velpeau, Chir. Anat., i. 26.

§ Hyrtl, Topog. Anat., i. 338.



Allan Burns\* long ago pointed out a sacculated condition of the lobe, which originated from behind the lower jaw and spread downward and laterally upon the neck. It lay beneath the deep fascia and fluctuated obscurely.

In the following case a congenital tumor, from about the angle, extended upward and inward to involve the pharynx. It is especially instructive in showing the lines of probable complications of tumors in this position. A child of two years of age came under the notice of an English surgeon, with a tumor under the left angle of the lower jaw. It had caused dysphagia and dyspnoea by its pressure inwards, for which tracheotomy was performed: several abscesses subsequently formed about the neck. The child finally died from suffocation. At the autopsy a fibrous tumor was found extending from the region of the angle to the pharynx, from the side of which it passed across the pharynx, occluded the right posterior nares, and distended the inter-tonsillar space. Erosions of the transverse process of the atlas and the angle of the lower jaw were seen.

Aneurismal conditions of the gland may from similar causes produce symptoms of suffocation and pulsating tumors in the region of the tonsil.

The superficial portion is rarely the seat of cancer. It almost invariably begins in the deep portion of the gland, and early involves the facial nerve by pressure. This fact may be of great use in the diagnosis of the early stage of parotid cancer.

Cystic tumors, on the other hand, may be found only within the superficial portion. Fergusson has given us a good rule on the subject of parotid tumor. According to this eminent authority, if the skin can be freely lifted from over the tumor it is probable that the tumor can be removed, whether cystic or otherwise, without necessitating the removal of the entire gland; but if the skin is tense, infiltrated, and fixed, it indicates that the entire gland is involved, and, as a rule, it is best not to operate.

Tumors may arise within that portion of the gland over the masseter muscle; these may be due to engorgement of the socia parotidis or the result of occlusion of one of the accessory ducts. They are freely movable at first, painless, and excite at times an increased flow of saliva. It is important to discriminate between these swellings and enlargement of the lymphatic glands of this region, or incipient enchondromata. The latter tumors are elastic, and resemble small cysts, for which they have often been mistaken.

Inflammatory obstruction of the parotid duct will cause intumescence of the gland, yielding unusual symptoms. Since the duct of

---

\* Surgical Anatomy of the Neck, Baltimore, 1823, 303.



Steno cannot be traced deep within the body of the gland, the swelling will be confined to the superficial portion. The mass differs from other swellings of the region by the presence of a ridge (seen within the mouth) placed between the masseter and the cheek. There is sometimes little or no pain, at others a sense of soreness only. This rare condition was first accurately described by Allan Burns (*loc. cit.*).

Calculus of the parotid duct has been described. Mr. Burton Shillito\* discovered in such a case an impervious duct, which was swollen and felt like a hard cord along the cheek. Suppuration in the body of the gland ensued, with the escape of the pus externally.

As an addendum to the region of "the temple and angle of the jaw," we may state that the relations between the lower lobe of the parotid gland and the transverse process of the atlas are of peculiar significance, not so much from a structural as a clinical point of view.

In emaciated subjects the transverse process of the atlas can be distinctly felt beneath the integument. The distance between the transverse process and the angle of the lower jaw is not greater than half an inch. The process, however, is not visible until the anterior tendinous margin of the sterno-cleido-mastoid muscle is raised from over it, the abundant tough fibrous tissue which underlies the muscle at that point is removed, and a deep-seated lymphatic gland which is lodged below the process is pressed aside. We now see the process, with its relation to the levator anguli scapulæ and the splenius colli muscles. We are not apt to associate the atlas as a part of the region about the angle of the jaw; yet that it is to be so cannot be ignored. Dr. H. J. Bigelow,\* than whom there are few more sagacious observers, has given as his belief that cystic tumors of the neck *almost always* arise from the parts about the transverse process of the atlas and the styloid process of the temporal bone.

### III.

#### THE REGION OF THE EAR.

The region of the ear presents two features for examination,—the *auricle* or *external ear* and the *post-auricular space*.

The connections of the *auricle* with the external meatus and thence with the middle ear are such that many conditions of the latter chamber may have clinical relations with the region under consideration. The same remark is true of the entire *pars tympanica* of the temporal bone, which in reality is part and parcel in structural unity with the external ear.

With respect to the *post-auricular space* we have always to remem-

---

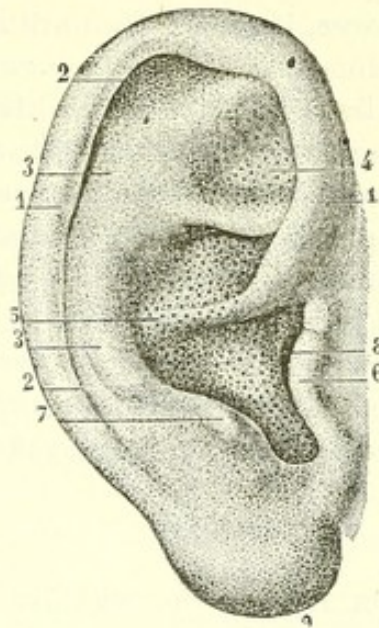
\* Trans. Path. Soc. London, 1865, xiv. 158.



ber its intimate relations with the mastoid cells,—the mere mention of the name of which is sufficient to indorse the grouping under one head the post-auricular space with the external ear. The post-auricular space in addition suggests independent occipital and cervical reciprocities.

*The Auricle.*—The *external ear*, or *auricle*, is an appendage to the side of the head, designed for the reception of waves of sound. It is of a sub-elliptical figure, and placed between two horizontal lines, one running backward from the eyebrow, the other backward from the level of the nostril. Its main axis is nearly vertical, and, at least in the male, parallel with the ascending ramus of the lower jaw. It is composed of an irregular, sculptured lamina of fibro-cartilage, to which is attached inferiorly a pendant of delicate fat termed the lobe, the whole structure being inclosed in skin. The lobe is often spoken of as a *pouch* containing fat and connective tissue; more properly it is a *fold* of skin, for a pouch implies an open sac or cavity, which the lobe is not. The external ear presents for examination an anterior and posterior surface.

FIG. 7.



The following are the main points in the nomenclature of the external ear. An outer border termed the *helix* (1), beginning as a thin elevated central root (5), sharply limited above and in front, but becoming more obtuse along its outer border, and finally lost before reaching the lobe. Within the periphery of the helix is a second eminence, the *anti-helix* (3). Starting below the root of the helix, it describes a shorter curve to terminate in two fork-like processes, the upper blunt, the lower sharp, which are lost behind the acute anterior border of the helix. The depression between the helix and antihelix is termed the *fossa of the helix* (2), that between the forks of the antihelix the *fossa*



of the *antihelix* (4). The *antihelix* is continuous below with the *antitragus* (7), and thence through the line of the *intertragic notch* with the *tragus* (6). The space between the *antihelix*, *antitragus*, and *tragus* is called the *conch*, which is crossed along its floor by the root of the *helix*.

These names have been so long fixed to the several parts of the ear that it would be folly now to attempt to change them. It is needless to say that they have not been happily selected.

The following points in the general plan of an external ear may be worth considering. Every ear yields on examination three curves, which may be defined as the *curve of the helix*, the *curve of the lobe*, and the *curve of the conch*.

The curve of the *helix* begins at the *upper* margin of the root of the *helix*, and is continuous with the *inner* border of the *helix*. The curve of the lobe answers to the *outer* margin of the lobe, and thence to the outer margin of the *helix*. These two curves pass and are lost in one another along the posterior border of the auricle. The curve of the *conch* begins at the *lower* margin of the root of the *helix*, can be traced thence along the border of the *tragus*, *intertragic notch*, *antitragus* and *antihelix*, and thence to the lower fork of its division below the fossa of the *antihelix*. The form resulting from the union of these three curves gives a true outline of the organ. It will be observed that the axis of the first curve is inclined a little upward and forward, and that of the second a little downward and forward. It follows that the produced axes of these two curves will intersect at about the axis of the root of the *helix*. The root of the *helix*, therefore, divides the auricle into two parts, an upper and lower. The upper is set at a greater angle to the side of the head than the lower, the angle representing, according to Gruber,  $45^{\circ}$ .

The *fibro cartilage* of the auricle can for the most part be felt through the skin. Its depressions and elevations answer to those seen in the auricle as a whole. The eminence on the anterior surface answers to depressions on the posterior surface, and *vice versa*. The features of the fibro-cartilage not seen from without are the *cauda heliis*, a tapering process of inconstant proportions which passes down into the base of the lobe of the ear, a small process answering to the external free margin of the *helix*, known as the *process or spine of the helix*, and the various slits or fissures which are inconspicuous in the body of the cartilage, but are well seen between the *tragus* and *helix*, and between the ring-like fissures of the *conch* (*fissuræ Santorini*) as it approaches the *pars tympanica*. Gruber\* mentions a case in which the *cauda heliis* passed some distance into the lobe. It had been per-

---

\* Lehrbuch die Ohrenheilkunde, 1870-71.



forated in the procedure of piercing the ear. Severe inflammation of the auricle supervened, which extended to the retro-maxillary space, where an abscess formed demanding active treatment.

The skin of the anterior surface of the auricle is held firmly to the perichondrium without the supervention of fat. This, according to Luschka, is to prevent any accidental accumulation of fat interfering with the reception of waves of sound. Fat is present in small quantity on the posterior surface of the auricle, where, towards its base, the skin is not firmly fixed to the perichondrium, although some authorities so affirm. In the ears of many healthy persons well-defined folds of skin extend from the post-auricular space to the hinder surface of the auricle. We have on a previous page stated the ease with which the posterior surface of the auricle becomes swollen in erysipelas. Infiltration may occur in the sparse sub-dermic connective tissue here appreciable.

Kramer elaborates a distinct variety of inflammation of the auricle, which he would diagnose as follows:

"A slightly-painful tumor appears, equal in size to a hen's egg, which, however, does not open spontaneously. Fluctuation is very evident from the commencement. When opened, fluid, dark blood flows out, which collects again, requiring reopening and evacuation. In the sac fresh cartilage forms, which ultimately unites with the old cartilage with great disfigurement of the ear."

Ossifications of the cartilage are occasionally seen, not, however, as a result of advancing years so much as the effect, according to Garrod,\* of gout. According to Toynbee† a similar deposit is seen in auricles following othæmatoma in the insane. The description of Kramer's inflammation of the cartilage would apply to those blood-tumors of the auricle, regarding the connection of which to any essential conditions of the nervous system grave doubts have been freely expressed.

The presence of a point or process upon the anterior border of the cartilage of the helix, "a little blunt point projecting from the inwardly-folded margin of the helix, variable in size and sometimes occurring in one ear and not in the other," has been recently attracting considerable attention, from the fact that Mr. Darwin‡ ascribes to it a peculiar significance, nothing less indeed than as constituting the rudiment of a structure which answers to the pointed ear of the lower animals. Luca§ would explain the appearance of this point by a much simpler process, viz., as the result of inter-uterine inflammation and pressure.

\* Nature and Treatment of Gout, 1859.

† Trans. Path. Soc. Lond., 1860, xi. 225.

‡ Descent of Man, 1871, 22.      § Virchow's Archiv, xxix. 62.



Dr. C. H. Burnett has lately published\* his convictions that the functions of the ensculpturings of the fibro-cartilage are of great value in preserving to the auditory sense the discrimination of musical tones.

The muscles of the auricle, both *intrinsic* and *extrinsic*, are of little or no importance, and we therefore omit description of them. It may be simply remarked, in passing, that the *retrahens aurem* would appear to belong to the occipital set of muscles, and to have little or nothing in common with the *attrahens* and *attollens aurem*.

The *arteries* of the auricle are derived from the external carotid, viz., from its auricular and sup.-temporal branches. It is an interesting fact that the branch of the post-auricular artery which passes to the front part of the auricle effects entrance from below through the fissure of fibro-cartilage between the helix and conch. Its *veins* empty into the external jugular,—small venules join the temporo-maxillary vein.

The *nerves* are derived from the superficial cervical plexus through the auricularis magnus, the auricular branch of the trifacial, and posteriorly from the facial nerve. Arnold's nerve, a branch of the pneumogastric, also sends a branch to the auricle. This—the last mentioned—is a feature of marked significance it has been thought in connection with the respiratory character of the mucous passages of the ear, and the fact that the position at which the nerve effects entrance into the temporal bone, namely, “at the outer border of the jugular foramen to an opening near the styloid process,” is the region corresponding to the first visceral cleft of the embryo.

The exact areas of distribution of the above nerves can sometimes be determined in paralysis of some of the branches.

The varieties in the form of the auricle are very numerous. The conformity between the ear and other features has not been made of the importance it would appear to deserve. It is certain that in questions of identity it may prove of value. Many instances have been given of the permanence of a given shape of the auricle as a family characteristic. According to Gruber (*loc. cit.*), Hoppe has observed a congenital deformity in the auricle in a Swiss family, which descended through many generations.

What we may term the generalized outline of the auricle, such as is seen in drawing-books and in anatomical figures, as, for example, that used in illustrating our pages, gives the student but a limited notion of the *portrait* of the ear as found in the living subject. The above figure might stand as a type of an ideal ear to which individual ears may conform, but few in reality do. As we speak of a classic or pure countenance, we may speak of a classic or pure ear-form. We find evidences in studying

---

\* “The External Ear as a Synthetic Resonator,” Phila. Med. Times, Oct. 4, 1873, p. 3.



the antique ear that close attention has been given to the conformation of the external shape to the idea which it was designed to convey through the shape. No one can doubt in comparing the ears of the classic head that the outlines were in every instance carefully harmonized with the other proportions. The ear of the Farnese Hercules, for example, is angular, and the eminences of the antihelix and antitragus exaggerated. In the Juno the curves are retained and emphasized, the lobe hanging like a jewel, in exact harmony with the treatment of the hair. In the Clytie the ear is as small and elegant as the other features of this exquisite head. In the ear of the Roman bust the attempt to preserve a portrait of this organ as well as of the countenance is very apparent. A curious contrast between an antique ear and the modern one is seen in the statue of the gladiator. The right ear is lost in the original of this statue, and has been restored by an Italian sculptor. But the artist, neglecting to preserve an equation between the antique ear and its modern fellow, has given us, as an opposite to the compressed, solid ear demanded by the crisp, short hair characteristic of the gladiatorial (*i.e.* pugilistic) head, an out-of-door realism as commonplace as the mind of the man who carved it.

The varieties of the lobe of the ear are very curious. It is usually pendulous, with a free anterior border. Occasionally it is without this border, when the lobe appears confluent with the lines of the face and neck. Some of the members of the Cabanos tribe of Indians, inhabiting the valley of the Amazon, possess lobes to their ears of enormous proportions, if we are to credit the account of Marcoy,\* according to which they reach the shoulders, and are bifid nearly their entire length. The large ear with long lobe is often seen in Buddhistic idols, and is doubtless regarded by the votaries as an object of beauty.

According to Laycock,† the lobe of the ear is confluent in melancholia and absent in dementia. Dr. L. V. Dodge, Assistant Physician to the Insane Department of the Philadelphia Hospital, has kindly examined the ears of the inmates of that institution, with a view of determining the frequency of occurrence of such peculiarity. Out of one thousand and twenty-five patients examined, but one hundred and eighty-four exhibited the confluent lobe. What Laycock calls the "absent" lobe is to be included in this number. When it is remembered that a large proportion of our insane are sufferers from dementia and melancholia, it will be seen that Laycock's statement has not been confirmed. It is a curious fact that of the one hundred and eighty-four ears marked by the confluent lobe, one hundred and fourteen were from females.

\* Voyage à travers l'Amerique du Sud de l'Océan Pacifique à l'Océan Atlantique, vol. ii. 13, Paris, 1869.

† "Physiognomy in Mental Disease," Medical Times and Gazette, 1862.

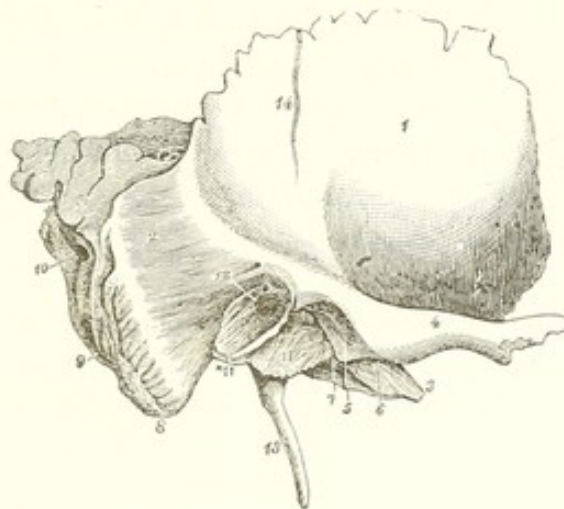


It has been asserted that there is a difference between the ear of the male and female; that the axis of the male ear answers to that of the ascending ramus of the lower jaw, or to a line running parallel with it. The axis of the female ear, on the other hand, responds to the produced curve formed by the lower jaw with the neck. From our own observation, the ear of the young female is less inclined than that of the male.

*The Post-Auricular Space.*—The relations have been sufficiently suggested at the beginning of this paper to require no extended recital in this place. The locality is really defined in the name. Below it extends upon the neck, above it is lost within the scalp. The skin covering it is smooth, and between it and the mastoid portion of the temporal bone is a sparse connective tissue containing a few lymphatic glands, and crossed by minute vessels and branches of the second occipital nerve, and according to Hirschfield, a "mastoid, or second small occipital nerve."

The mastoid process, from its important relations with the occiput, yields points of interest with the post-cervical muscles, notably the splenius and trachelo-mastoid. An aponeurotic slip from the sternocleido-mastoid muscle passes upward over the root of the process

FIG. 8.—EXTERNAL VIEW OF THE TEMPORAL BONE OF THE RIGHT SIDE.



- 1, squamous portion; 2, mastoid portion; 3, apex of the petrous portion; 4, zygomatic process; 5, glenoid cavity; 6, glenoid tubercle; 7, glenoid fissure; 8, mastoid process; 9, back part of digastric groove; 10, mastoid foramen; 11, auditory process, by extension inwardly, forming the vaginal process; 12, external auditory meatus; 13, styloid process; 14, slight impression of the deep temporal artery.

externally. The deeper parts about the mastoid process belong to the base of the skull, and are thus manifestly excluded from the space under consideration.

Engorgement of the lymphatic glands here situated is not infrequently seen in cases of diseases of the external auditory meatus.

When inflammation of the mastoid cells exists there is usually

brownness of the integument of the post-auricular space, and always tenderness on pressure. Very rarely the pus may effect an outlet through the mastoid foramen, which as is known is of variable size, and sometimes may aid the jugular foramen in carrying venous blood *from* the lateral sinus. Dr. F. Buszard\* gives an interesting account of a case of this kind. The patient, after suffering for eleven months, during the latter part of which time drowsiness and vomiting were symptoms, submitted to an operation in which the bone was trephined over the position of the foramen. An ounce of viscid pus escaped, and the patient made a good recovery.

The writer has seen two cases of encephaloid disease of the post-auricular space, one of which had been mistaken by experienced surgeons for caries of the temporal bone. The glandular involvement in both cases was strikingly exhibited. In one of these the outer border of the auricle and the lobe escaped the otherwise complete destruction of the auricle. Inflammatory trismus and dysphagia were in both cases conspicuous symptoms.

Wilde† mentions a case of aneurism of the post-auricular artery.

The external auditory canal, as already mentioned, may become the outlet of a collection of pus in the parotid region. In another way it may be involved in a question of facial relations. As will hereafter be mentioned at greater length, the condyloid process of the lower jaw is in intimate relation with the *pars tympanica* of the temporal bone and the external auditory canal. In some of the conditions of the lower jaw in edentulous old people this process tends to slip a little backward, and helps to close the canal from before backwards. Deafness may arise from this cause. This fact is well known to aurists, who, in introducing the speculum into the ear of an old and toothless person, may request that the mouth be opened, thus depressing the jaw, if any difficulty be encountered. The first dentist who appears to have noticed the beneficial effect of a full set of artificial teeth in relieving deafness arising from this cause, was Mr. Jacob Gilliams,‡ of Philadelphia.

#### IV.

##### THE REGION OF THE LOWER JAW.

This region is defined by the inferior maxilla, which it is necessary to describe before passing to those divisions of our subject based upon its structure.

The inferior maxilla or lower jaw is the largest and most massive bone of the face. It forms the boundary of the under part of the ante-

---

\* Brit. Med. Journ., 1871, 89.

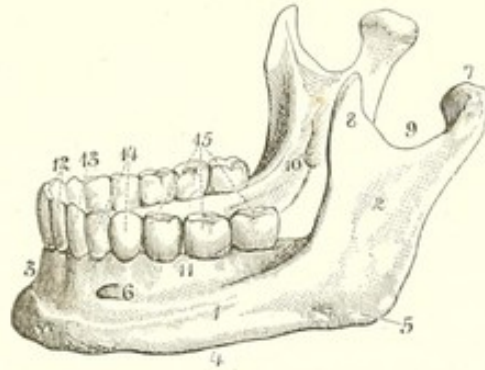
† Treatise on Diseases of the Ear, 175.

‡ Mütter's Liston, 304.



rior and lateral region of the face, where its lower border can be defined under the skin. It consists of a horizontal arch, with its curves directed in front and its sides elevated at an angle behind. The bone is moved on the base of the skull at the temporal bone by powerful muscles.

FIG. 9.—INFERIOR MAXILLARY BONE.



1, body; 2, ramus; 3, symphysis; 4, base; 5, angle; 6, mental foramen; 7, condyle; 8, coronoid process; 9, semilunar notch; 10, inferior dental foramen, the entrance of the corresponding canal; 11, alveolar border; 12, incisor teeth; 13, canine tooth; 14, premolars; 15, large molars.

The lower jaw is composed of two halves; after their union it is convenient to divide the bone into a body or horizontal portion, and two ascending portions or rami. The body of the bone is marked above by the edge of the alveolar process, and below by a thickened, rounded border. In the median line at the point of union of the primitive halves is a linear ridge,—the symphysis. The widened and projecting basal extremity of this line is called the mental process. At the side of the symphysis, on a line with the lateral incisor tooth, is the incisor fossa, from which the *levator labii inferioris* arises. Below this point, and to its outer side, is a shallow depression for the *depressor anguli oris* muscle. The line of insertion of the *platysmus myoid* muscle lies below the latter, on the basal border. Opposite and below the insertion of the interspace between the second molar and first bicuspid, and about midway between the basal border and the teeth, is seen the anterior dental foramen, which affords exit to the inferior dental nerve and artery. The basal border of the body near the ramus is grooved for the reception of the facial artery. Extending obliquely upward and backward to the anterior root of the coronoid process is the external oblique line.

The inner side of the body is conspicuously divided by an oblique ridge, which extends from the base of the coronoid process downward and forward. This has received the name of the mylo-hyoid ridge, and serves for the origin of the *mylo-hyoid* muscle. Between this ridge and the molar teeth slips of the *buccinator* and *superior constrictor* muscles are attached.

At a point below the canine teeth, a smooth depression supports the anterior border of the sublingual salivary gland. Below the ridge, a



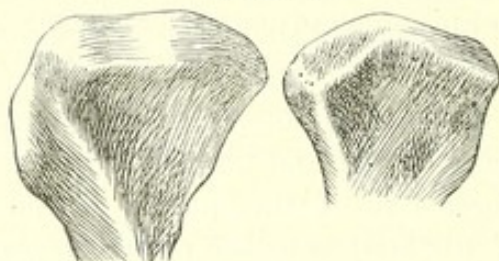
small groove running nearly parallel therewith receives the mylo-hyoid nerve and artery. A well-marked oval depression near the basal border anteriorly is for the insertion of the *digastric* muscle. At the lower part of the symphysis are the genial tubercles, ordinarily composed of four processes,—two on either side of the median line. The superior process is for the origin of the *genio-hyoid glossus*, and the inferior for the *genio-hyoid* muscle.

The ascending portion, or ramus, is imperfectly defined from the body anteriorly. Posteriorly it presents a robust, rounded border, which is separated from the basal portion of the body by the angle. The outer surface of the ramus is in great part roughened for the attachment of the *masseter* muscle. It presents two conspicuous processes, the coronoid in front and the condyloid behind. Between them is a deep hollow, the sigmoid notch.

The inner aspect of the ramus is conspicuously marked by the dental foramen, for the entrance of the inferior dental nerve and artery. The anterior margin of this opening is produced into a thin plate of bone, pointing backward, which gives attachment to the deep fold of deep fascia known as the internal lateral ligament.

The coronoid process is flat and pointed. It is directed slightly backward. It is thin at its upper portion, but thicker below. Its front edge is nearly straight, and presents at its base behind the thin molar tooth a groove, within which is held a slip of the *temporal* muscle, as well as the buccinator muscle. Its posterior edge is thin, and continuous with the curve of the sigmoid notch. The outer surface is devoted to the insertion of the temporal and masseter muscles, and the inner to the temporal alone.

FIG. 10.



The condyloid process, more massive than the coronoid, is a continuation of the posterior free margin of the ramus. It presents for examination a neck and the articular surface. The neck corresponds to that portion of the process directly below the articular. It is compressed from behind forward, and receives at its inner portion a shallow depression for the external *pterygoid* muscle. The outer margin of the neck is marked by a minute rounded process, the tubercle for attachment of the external lateral ligament. The articular surface is convex from before backwards, abruptly arched from within outwards. It is



often angulated at a point answering to the axis of the ramus. The articular surface is not directed transversely, but somewhat backward. The production of the lines of inclination of the two surfaces would intersect at the anterior margin of the foramen magnum.

*Dental Canal.*—We have noted for each side of the body two foramina, the dental or posterior, and the mental or anterior. The canal between these two points is termed the dental canal. It passes beneath the alveolar process, and sends veins and blood-vessels to the teeth. At its beginning it lies near the inner surface of the bone, but towards the first molar it holds a more central position, and ends abruptly externally at the mental foramen.

We propose studying the lower jaw from the following points of view: (*a*) As divided into a right and a left half; (*b*) as divided into the alveolar as one part and the remainder of the bone as another; (*c*) as divided into muscular impressions as one part and the remaining non-muscular part as the other; (*d*) as divided by the mylo-hyoid ridge into *facial* relations (*i.e.* all the parts above the ridge and the entire outer surface of the bone) and the *cervical* (*i.e.* all the parts below the ridge); (*e*) as compared with a long bone; (*f*) as determining the localization of tumors.

(*a*) *The lower jaw as divided into a right and a left half.*—The lower jaw, in common with other symmetrical parts of the skeleton, exhibits those curious manifestations of physiological and morbid action (which have been so admirably described by Paget), but in a much weaker degree than in the bones of the extremities. Seeking for a reason for this, it is found in the impairment of the physiological identities of the halves by their union at the symphysis. It is probable that in lower mammals, such as the ruminants and marsupials, in whom the halves never unite, that the law of symmetrical distribution of disease might be found better expressed.

The following instances may be cited to show that disease tends to occupy the *sides* of the jaw rather than the median line, and excesses of nutrition are apt to occur on either side of the symphysis to an equal degree. In confirmation of the latter statement, we may refer to those extraordinary developments of symmetrical hyperostosis recorded by Lebert\* and Murchison;† and for the former, the clinical fact that growths of all kinds are vastly more common on the sides than the median portion of jaw,—that the only examples recalled by us of a growth beginning on one side, passing across the median line, are, first, the case termed by Prof. Gross‡ hematoid tumor, which began on left side

\* Atlas, pl. xxxii. fig. 1.

† Trans. Path. Soc. London, xvii. 243, pl. 10, xii.

‡ System of Surgery, i. 485.

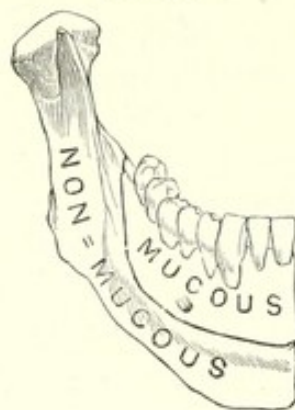


just behind cuspid tooth, and passed across the line of symphysis as far as the lateral incisor of the right; and second, the one described by Mutter,\* which occupied the symphysis and about two-thirds of the left ramus of the bone. Hyrtl† alludes to a case of exostosis of the symphysis.

(b) *The lower jaw as divided into the alveolus as one part and the remainder of the bone as another.*—This division is an important one to remember, for the following reasons: The alveolus is developed with the teeth and disappears with the teeth; it is an outgrowth from the jaw for a specific temporary purpose. Jno. Hunter‡ declared that the “alveolar processes of both jaws should rather be considered as belonging to the teeth than as parts of the jaws.”

It will follow that all diseases of the alveolus are to be considered as dental in their significance. Thus epulis is peculiarly an alveolar disease. A tooth in any portion of the jaw other than that of the alveolus is as much out of place as though it were lodged in another bone. There is little doubt that the position so often assumed by the third permanent molar at the end of the alveolus, half within and half without the dental arch, with its roots, it may be, deflected within the compact and resisting tissue of the base of the coronoid process (see Fig. 12, *a, b*), acts there as a foreign body; and as a splinter in the flesh provokes inflammation, so such a tooth is of necessity a fertile cause of diseased action about the angle of the jaw. Should a tooth be lodged

FIG. 11.



beneath the alveolus, as in the encysted form, it either gives rise to chronic abscess or provokes those common tumors, the odontomes, which frequently are of such fearful import. Cystic disease about the angle of the jaw is so often excited by a malplaced third molar that the teeth should always be examined in diagnosing this condition. In a case mentioned by Bordenave,§ foetid matter from the collection escaped after removal of the second and third molars.

\* Amer. ed. of Liston's Surgery, 299.

† Topog. Anatomie, i. 324.

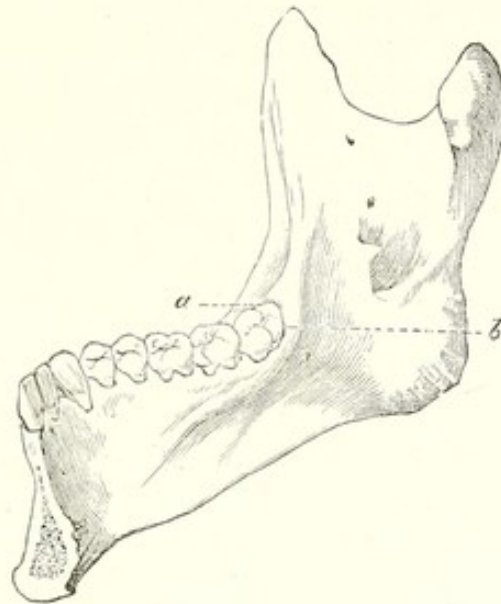
‡ Palmer's Hunter, i. 4.

§ Surgical Essays, Sydenham Series.



Dr. Mason Warren\* has described a number of cases of cystic tumor of the angle of the jaw. In one of these the growth began by a swelling at the root of the third molar of the right side. By the end of several years it involved the whole right ascending ramus. It was of a globular shape, extended back under the lobe of the ear, and forward, to encroach upon the cavity of the mouth. In another the growth extended backward into the parotid region, upwards upon the face, "inwards to involve the right half of the palate, where it was covered by a highly irritable œdematous mucous membrane resembling that covering malignant growths in the same locality." There was a slight discharge of fluid through the remains of the socket of the last molar. This being enlarged, the cystic character of the growth was made clear. In a third instance, a growth of six years' duration, which attained the size of a hen's egg, began in the socket of the third molar.

FIG. 12.



It would be interesting to trace the connection between defects of the teeth-germs and congenital cystic tumor of the lower jaw, such as is described by Coate,† occurring on the right side of the lower jaw of an infant three months of age. It was operated upon. Death ensued from exhaustion.‡

That the body of the jaw is a distinct growth from the alveolus is shown in the study of cases of congenital defects of the bone. In the following rare manifestation of imperfect development characterized by

\* Surgical Observations, with Cases and Operations. Boston, 1867, 72.

† Syd. Retrospect, 1861.

‡ For a cystic tumor not apparently connected with the teeth, yet apparently strictly alveolar, see R. Adams, Med. Times and Gazette, 1857, 484.



permanent fixation of the two halves of the bone, we have, as the adult condition is attained, the jaw preserving the proportions of the infant so far as the body is concerned, while the teeth and alveolus are as well pronounced as in a normal jaw. Mr. Humphry\* describes the case as follows:

"The lower jaw is almost completely fixed, with the molar teeth clinched against the upper, so that there is no perceptible interval between them. The jaw is broad or natural at the angles, and the angular parts have descended nearly to their proper level; but the arch formed between the two angles is extremely small. Indeed, the body and the mental portions of jaw run forward scarcely at all, and do little more than pass from one angle to the other. The chin is in a plane two inches behind the alveolar edge of the upper jaw, instead of being a little in front of it. There has been, therefore, a failure, amounting to at least two inches, in the growth of the body of the jaw in length; and it is also less deep than natural. The failure, however, has not been shared in quite an equal degree by the alveolar portion. This forms a segment of a larger circle, taking a wider sweep, and, consequently, overhanging the lower part of the body of the jaw. By this means greater room is given for the teeth, which are as numerous and *as large as natural*; and they are disposed in a slanting fan-like manner, so as to bring the crowns of the molars and hinder bicuspid into contact with those of the upper jaw."

(c) *The lower jaw divided into muscular impressions as one part, and the rest of the bone as the remaining part.*—Both sides of each ascending ramus may be said to be large muscular impressions,—the outer for the masseter, the inner (less completely covered) for the pterygoid muscles, while the tendon of the temporal muscle embraces the coronoid process. The arch of the bone can be called, for the most part, a non-muscular area; for with the exception of the insertion of the digastric muscle at the small digastric fossa, and genio-hyoid group at the genial spine, the muscles here (*viz*, the mylo-hyoid muscle within, at the ridge of the same name, and the depressor anguli oris and the platysmus myoid muscle at the mental process *without*) constitute an unimportant element.

It is particularly with the ascending ramus that we find the muscular impressions of value in the study of lesions and diseased actions. In the first place, the masseters act as external cushions protecting the jaw from direct violence, while the pterygoids act as internal cushions to prevent bilateral dislocation. In the second, the direct influence exerted on the shape of the angle by the internal pterygoid is often very marked. A condition known as incurvation of the angle is fre-

---

\* Med.-Chir. Rev., 2d series, vol. xxvii., 1862, 288.



quently seen in well-marked lower jaws. It was at one time thought that this peculiarity stamped the individual as an example of a low type of man. It is a curious fact (only noteworthy from its liability to deceive in attempting such generalizations) that the same incurvation of the angle should be a constant character in the jaw of the marsupials,—the lowest group of the mammalia.

Another feature of importance is the fixity of the ascending ramus by the contraction of the masticatory muscles. All things being equal, the position of elevation or depression of the lower jaw will make the difference between a dislocation and a fracture. If the jaw is elevated, the bone is apt to be broken by direct violence applied to it; if, however, it is depressed, it is more apt to be dislocated. The ensuing case is of value in illustration of the above principle, since the lines of fracture were doubtless determined by the fixed position of the jaw. It is recorded by Mr. J. Thomson.\*

A young man whilst plowing was thrown down by his bullocks running away, and the coulter, catching his throat, tore away the entire horizontal portion, and more than half of the right ramus of the lower jaw.

"A lacerated wound extended from the right mastoid process across the throat to nearly the left angle of the jaw; this at its posterior origin had entirely divided the whole breadth of the sterno-mastoid muscle; from the right angle of the jaw to near the chin it divided the floor of the mouth. It was also met by an oblique laceration from the left commissure of the lips, which had quite torn through and divided the cheek. The inferior maxilla was fractured on both sides, on the right more than half way up the ramus. The bone thus broken and torn out of the face was very much denuded of soft parts, and at each fractured extremity was, to some extent, laid bare of periosteum."

Six weeks after injury, the right side of face was paralyzed; the eye could not be closed, nor the mouth entirely.

The specimen embraced the entire horizontal portion of jaw, and more than half of the ramus of right side. The ramus had been fractured obliquely backwards and downwards from the root of the coronoid process to the middle of the posterior edge. On the left side the fracture extended obliquely across the angle, from behind the socket of the second molar tooth to just in front of the posterior part of the angle of the jaw.

According to Hamilton,† fracture of the condyloid process almost always occurs just below the insertion of the external pterygoid muscle.

---

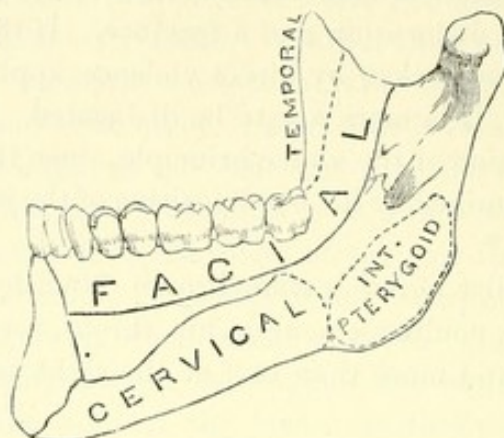
\* Edin. Med. Journal, 1861, vii. 587.

† Treatise on Fracture and Dislocation.



(d) *The lower jaw as divided by the mylo-hyoid ridge into two groups of relationships—one above (facial), the other below (cervical).*—The mylo-hyoid muscle is the floor of the mouth, and abruptly separates the inner aspect of the curve of the body (from the free inferior border to the ridge) from the rest of the bone. The relations of this region are entirely with the neck. We will resume its consideration under the caption of the supra-hyoid space.

FIG. 13.



(e) *The lower jaw yields certain points of comparison with a long bone.*—The lower jaw resembles a long bone in having compact bone *without* and cancelli *within*,—in having a well-defined canal (somewhat comparable to a nutritive foramen) entering it obliquely, and, moreover, it has an active periosteum, which tends in necrosis to produce an involucrum.

It conspicuously differs from a long bone in the absence of an epiphysis. The bone is thus deprived of an epiphysal period, which is so prolific in morbid processes. The *ends* of the lower jaw (*i.e.* the articular surfaces) are peculiarly exempt from disease, the very opposite to what is seen in long bones. The only instance of restricted disease at these points known to us is in a specimen of caries, with subsequent hyperostosis, preserved in the collection of the Philadelphia Dental College. Hydrarthrosis is equally rare. Mr. Tatum\* briefly describes a *unique* case of fluid in the temporo-maxillary articulation escaping into the external meatus following a lesion of the latter.

The lower jaw also differs from a long bone in its contact with mucous membrane. When in fractures of the lower jaw the gum is deeply lacerated, the fracture at once becomes compound. The ease with which this can occur, and the consequent frequency of this occurrence, places maxillary fractures in a group entirely distinct from those of other bones. It has been asserted (and on good grounds) that the con-

\* Lancet, 1860, ii. 536.



tact of the air and saliva between the ends of the broken bone tends to provoke ostitis, suppuration, with their sequelæ, constitutional disturbance and increased risk of pyæmia.

Again, the methods of securing vascular and nervous supply are widely remote from one another. In the lower jaw it is by a canal which is primarily a groove in the embryonic bone, and which in necrosis is probably included in great part within the thickened osteogenetic periosteum. The dental nerve and vessel are designed, in a word, for a special object within the jaw, as well as giving blood and nerve-supply to the bone; thus holding the same relation to the jaw that the hepatic artery and nerve hold to the liver. The lower jaw is, independently of the teeth, not a very vascular bone. It succumbs readily to attacks of necrosis, as much from this cause as from its peculiarly exposed situation.

The ostitis preceding necrosis of the lower jaw is almost always more marked than in a long bone, and the pain is greater. The latter symptom often resembles that of intermittent toothache,\* thus complicating the diagnosis. The swelling of the cheek and gums, the difficulty in mastication, and the dysphagia, as well as the increased activity of the mucous and salivary glands, are distinctive symptoms. The presence of a sequestrum may, according to Butcher,† induce vomiting and difficulty in speech and swallowing. In a word, we have as a result of a branch of a cranial nerve being held in connection with the products of inflammation,—if it be not itself inflamed,—an excitation of a larger circle of sympathies than is possible within a long bone.

T. Holmes‡ mentions the occurrence of fatal hemorrhage from the lingual artery excited by a maxillary sequestrum.

The position of necrosis of the lower jaw, as a sequela of diseases such as measles, scarlet fever, smallpox, and typhoid fever,—diseases whose lesions are for the most part splanchnic,—are in themselves of supreme significance, compared to which nothing can be seen in the long bones. The same remark is true of that disease, now fortunately rare, phosphor-necrosis. It will be remembered that this disease always invades the jaw through a carious tooth or open socket,—proving not only that the direct contact of the poisonous agent with the cancelli is requisite, but that such contact is *possible* only in the jaws; for no such relationship of cancelli to an open surface is ever seen in a long bone. A transverse section of the compact structure of the jaw may be compared to a vase. The base of the vase is firm and thick; the sides become thin as they approach the brim, while the upper surface is open. The vase is

\* Howship, Pract. Surg., 1816, 17.

† Essays and Reports on Operative and Conservative Surgery. R. G. Butcher. Dublin, 1865, 307.

‡ Holmes's System of Surgery, iii. 645.



occupied by teeth and adjacent cancelli. If a tooth is removed, the cancelli are at once exposed. Applying this explanation to the shape of sequestra, it will be seen that a sequestrum of the lower jaw or an exfoliation from the ends of a broken bone must be more or less U-shaped, as the same specimens from a long bone are more or less cylindrical. This rule does not apply to syphilitic necrosis.

According to Stanley,\* nine months are required to restore a lower jaw through the activity of its periosteum after the bone has been destroyed by necrosis.

The comparison between the lower jaw and a long bone is interesting in studying the subject of amputation. The wide range of sympathies seen in osteitis and necrosis of the lower jaw is to be expected in excision of that bone. In the event of amputation of a limb proving fatal, we commonly find pyæmia or secondary hemorrhage playing a ghastly rôle. While these prodromes to fatal disaster are unfortunately not wanting in the other operation, we more frequently find erysipelas and shock the exciting-cause to sudden death. In summing up the experience gained in seven amputations, J. W. Casack† says: "Fatal cases of diffused inflammation succeeding to operations in the vicinity of the base of the lower jaw are by no means unfrequent." In one of his cases, the erysipelatous inflammation involved the parts about the larynx, death ensuing on the ninth day after the operation. Mr. Symes‡ narrates a case of excision which proved inexplicably fatal on the second day.

(f) *The lower jaw as determining the localization of tumors.*—From an anatomical standard, this subject, of great intricacy in other relations, resolves itself into a few simple propositions.

1st. When a tumor originates within or beneath the gum and involves the cancelli secondarily, it indubitably belongs to the alveolar group of morbid growths. The different varieties of epulis are thus anatomically restricted.

2d. Fibrous tumors, according to Nélaton, may either arise within the body of the bone, when by their growth they will encompass the bone, or, taking their origin beneath the periosteum, they protrude toward the affected side. The same writer affirms that they tend to develop toward the cutaneous rather than the mucous (oral) aspect of the bone. Fergusson§ describes a fibrous tumor which lay enclosed within the expanded and attenuated tables of the jaw. The central encapsulating fibrous tumor may involve the dental nerve, as described by T. Bryant|| in a tumor which was removed from the left side of the

\* Trans. Path. Soc. London, iii. 169. † Dub. Hosp. Rep., iv., 1827, 1.

‡ Surg. Contributions, 21.

§ Medical Times and Gazette, 1865, 141.

|| Trans. Path. Soc. London, 1858, 352.



body of the lower jaw of a boy nine years of age. It was of two years' duration, and followed a blow received six months before. The nerve was found running through the center of the growth. It would appear that encephaloid disease may originate in the dental canal, judging by the case reported by Nunneley,\* in which the disease was ushered in by numbness of the left side of the lower lip. This was followed by varying pains in the canine and two adjoining teeth of the same side. The last molar was extracted with a view of relieving the toothache. The nature of the case now became evident, and it progressed rapidly to a fatal termination.

3d. The lower jaw being in the line of growth of epithelial tumors of the lower lip, secondary cancers from that source are not infrequently seen. In a case coming under our notice in private practice, the disease had progressed from the lip along the line of the right side of the horizontal portion, opening the oral cavity from the side and destroying the alveoli. The tongue, thus deprived of lateral support, lolled outward, and the saliva dropped continually upon the neck. Fortunately, these extreme degrees of destructiveness are rare, but the probability of secondary involvements of the lower jaw from neglected epithelial cancer should never be overlooked.

#### THE UPPER JAW.

In a surgical sense, the upper jaw is not synonymous with the upper jaw-bone. The latter is the same as the superior maxilla; but the former not only excludes part of the maxilla, but includes other parts belonging to adjacent bones. Thus, when the section included in an excision of the upper jaw is examined, the nasal or ascending process of the superior maxilla is absent (being retained in position in the inter-orbital space), while portions of the palatal and malar bones and the turbinated bones are seen in position. Such an excision implies in reality a section of one-half of the face, excepting those small portions entering into the space between the eyes. Indeed, while the superior maxillæ, like the inferior, are retainers of teeth, they differ in this regard,—that in mastication, the two superior maxillæ unite to form a passive, while the single inferior maxilla is an active factor. The superior *must* be held in intimate association with other parts to successfully resist the blows dealt upon it from beneath. Hence the necessity of considering neighboring bones in connection with it.

Let us glance for a moment at some of these relations. The immobility of the upper jaw rests upon three buttresses,—the nasal, the zygomatic, and the pterygoid processes. These cannot be separated without violence in an excision. The nasal and zygomatic processes

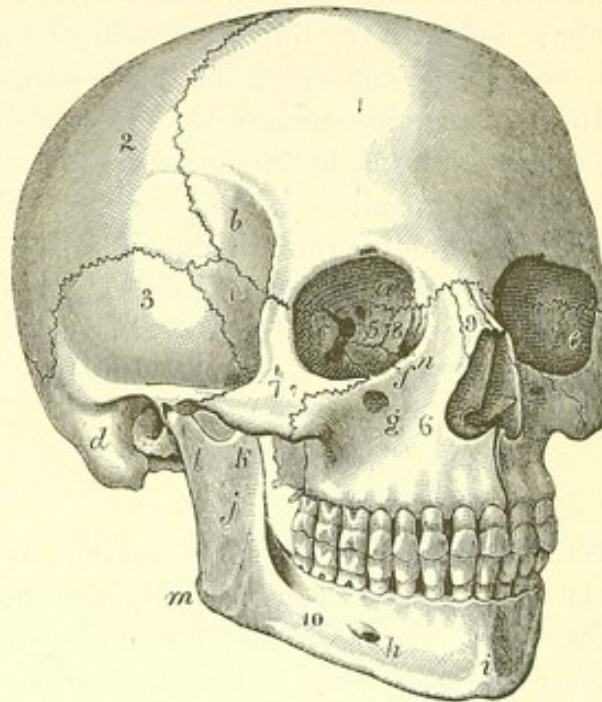
---

\* Trans. Path. Soc. London, xiii., 1862, 215.



are at once sawn through, and the frequently ossified junction at the pterygoid process depends as much on the pyramidal process of the palatal bone as the maxilla. Humphry\* informs us that the hinder wall of the superior maxilla is liable to give way and remain behind in the operation for the removal of the upper jaw, particularly when it is the seat of malignant disease. Now, it is a pregnant fact that the malar bone is perforated by branches of the superior maxillary nerve. If we are to apply here the law already announced, that areas supplied

FIG. 14.—THE SKULL, SEEN PARTLY IN FRONT AND ON THE RIGHT SIDE.



1, frontal bone; 2, parietal bone; 3, temporal bone, its squamous portion; 4, the sphenoid bone, temporal surface of its great wing; 5, ethmoid bone, its orbital surface; 6, superior maxillary bone; 7, malar bone; 8, lachrymal bone; 9, nasal bone; 10, inferior maxillary bone. *a*, orbital plate of the frontal bone; *b*, temporal surface; *c*, orbital surface of the great wing of the sphenoid bone; *d*, mastoid portion of the temporal bone; *e*, orbital surface of the malar bone; *f*, orbital plate of the superior maxillary bone; *g*, infra-orbital foramen; *h*, mental foramen; *i*, symphysis; *j*, ramus; *k*, coronoid process; *l*, neck supporting the condyle; *m*, angle; *n*, lacrymo-nasal duct.

by branches of the same nerve are co-associated in function, we will see at once that the malar is functionally in harmony with the maxilla,—a truth in no way dissonant with the relations of the same bone with the temporal and masseteric muscles, when the masticatory significance of the entire region is remembered.

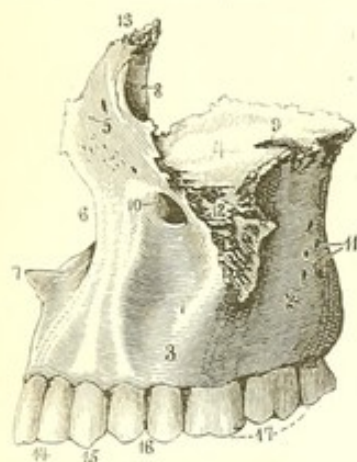
The mechanism of the occlusion of the lower jaw against the upper is briefly as follows: The fixed upper jaw is forcibly struck in every act of elevation of the lower jaw along the line of the dental arch. To distribute this force, we have on either side two osseous pillars,—the root of the malar process for the molar teeth, and the ascending process

\* The Human Skeleton, p. 280.



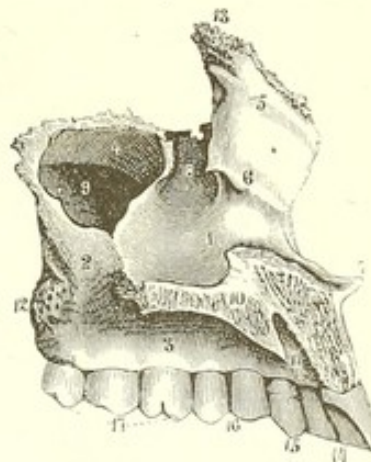
for the canine tooth. These, however, are not of equal value, for the act of striking is not a simple one. The lower jaw being composed of two curved levers uniting at a symphysis, the side of each lever is seen to be stronger than its curved incisorial end. It is actually strongest at the position of the canine and first bicuspid tooth. It is at this point—the seat of prehension—that the main shock of “the bite” is received, and thence distributed along the axis of the canine tooth to the anterior border of the lachrymo-nasal groove (turbinated crest), which in turn transmits it to the outer and thickened border of the ascending process to the inter-orbital space, where it is broken up, the main portion continuing along the anterior wall of the frontal sinus to the vertex of the skull. The main line answering to the direction here described may be called the *canine pillar*. The *malar pillar*, judging

FIG. 15.—SUPERIOR MAXILLA OF THE LEFT SIDE, OUTER VIEW.



1, body; 2, tuberosity; 3, alveolar border; 4, orbital plate; 5, nasal process; 6, nasal notch; 7, nasal spine; 8, lachrymal groove; 9, entrance of the infra-orbital canal; 10, infra-orbital foramen; 11, orifices of the posterior dental canals; 12, malar process; 13, articulation for the internal angular process of the frontal bone; 14, incisor teeth; 15, canine tooth; 16, premolar teeth; 17, large molar teeth.

FIG. 16.—SUPERIOR MAXILLA OF THE LEFT SIDE, INNER VIEW.



1, nasal surface of the body; 2, surface of the palate bone; 3, alveolar border; 4, orbital plate; 5, nasal process; 6, ridge for the articulation of the turbinated bone; 7, nasal spine; 8, groove contributing to form the lachrymo-nasal duct; 9, maxillary sinus; 10, palate plate, its articulating border for the right maxillary bone; 11, incisive foramen continuous with the naso-palatine canals; 12, tuberosity; 13, articular extremity for the internal angular process of the frontal bone; 14, incisor teeth; 15, canine tooth; 16, premolar teeth; 17, large molar teeth.

from the force of occlusion of the jaws at its site, would at first sight appear to be stronger than the former. But this is not the case. A moment's consideration of the shape of each molar tooth with its three divergent fangs is conclusive that the force of “the bite” here is diffused, thus having but a remote relation with the malar process. Besides, the “grinders” do not require the same axial support as the “seizers.” The “cutting” series, in its turn, is weak,—the lower teeth slipping behind the upper. The unpleasant sensation when these



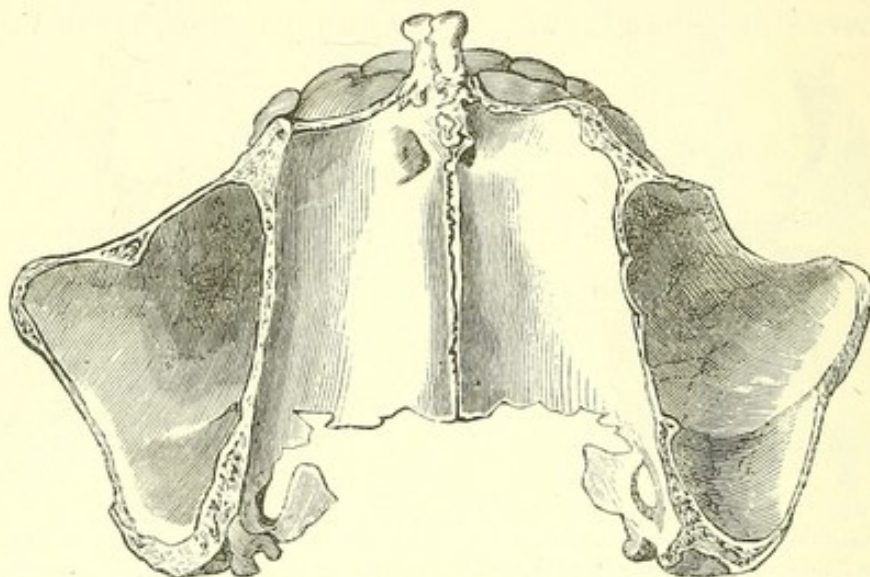
teeth are "put on edge" is due to the inefficient support secured from the incisorial portion of the upper jaw.

With the understanding, therefore, that for a satisfactory study of the upper jaw some account of the malar and palatal bones is required, we will describe these after the superior maxilla,—leaving the turbinated bones for another division of our subject.

*The Superior Maxilla.*—The superior maxilla presents a very irregular form. It occupies the space between the orbit and the mouth,—the zygomatic fossa externally, and the outer wall of the nose internally. It assists in forming the floor of the orbit, the outer side and floor of the nose, the anterior nares, and affords lodgment for teeth.

It presents for examination a central portion or body, and the nasal, palatal, malar, and alveolar processes.

FIG. 17.



Section of the two superior maxillæ near the level of the floor of the nose, showing sections of both sinuses.

*The Body.*—The boundaries of the body correspond pretty accurately to the shape of a large cavity—the maxillary sinus. The antero-posterior section of the body bisects the sinus at the position of the first molar tooth. It is thus seen to be more or less triangular. One side of the triangle forms the floor of the orbit; another imperfect one, the nasal border. Between the nasal and the orbital borders lies the facial border. A horizontal section just below the infra-orbital canal yields the nasal and facial borders as before. The posterior border is now seen as a convexity directed toward the zygomatic fossa, hence its name, the zygomatic surface. The size of the maxillary sinus is subject to great variation. It may extend into the malar bone. It is occasionally divided into compartments by incomplete vertical septa.

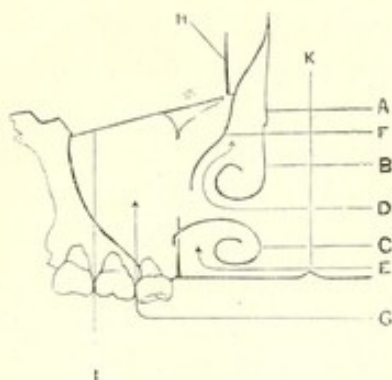
The *orbital* surface of the body is a nearly smooth plane, slightly



oblique from within outward. Its inner edge articulates with the lachrymal bone and the os planum of the ethmoid. Its outer edge joins the malar bone at its anterior half, and forms the inner border of the spheeno-maxillary fissure at its posterior half. It is marked by a groove running from behind forward, which terminates in a canal near the front edge. This is the infra-orbital groove and canal for the transmission of the infra-orbital nerve and artery. The orbital surface may serve to cover in the nasal chamber above the middle meatus.

The *inner* or *nasal* surface is imperfect. It presents an upper and a lower plate, with a large irregular opening between them. When the bones of the face are in position, this opening is partially closed by the palatal bone, the ethmoidal process of the inferior turbinated, and the uncinat process of the ethmoid.

FIG. 18.—DIAGRAM OF THE RELATION OF THE SUPERIOR MAXILLA WITH THE  
INTERNAL NASAL CHAMBER



*A*, *B*, the nasal lamella of the ethmoid bone. *A*, the superior turbinated scroll. *B*, the middle turbinated scroll. *C*, the inferior turbinated bone. *D*, the middle meatus, leading upward to the space between the uncinate process and the nasal lamella of the ethmoid bone. *E*, the inferior meatus. *F*, the uncinate process of the ethmoid bone. *G*, the maxillary sinus. *H*, the os planum of the ethmoid bone. *I*, the orbital plate of the superior maxilla. *K*, the nasal septum. \*, the portion of the orbital plate lying to the inner side of the opening of the maxillary sinus.

The *outer* or *facial* border is concave, and extends from the root of the malar process forwards to the median line at the anterior nares. Its junction with the orbital plate is marked by a thickened border,—the *infra-orbital ridge*,—which is continued a short distance upon the ascending process (*q. v.*). Directly below it is seen the infra-orbital foramen for the nerve and artery of the same name. Extending from the infra-orbital foramen to the alveolar process—to the outer side of the eminence—of the socket for the root of the canine tooth, is a depression known as the *canine fossa*. Above the incisor teeth is seen a smaller depression,—the *myrtiform fossa*.

The posterior or zygomatic surface is convex. It extends from the base of the malar process to the nasal aspect of the bone, where it joins the vertical plate of the palatal bone. It is separated from the orbital



plate of its own bone by a sharp line at the inner border of the sphenomaxillary fissure.

The zygomatic surface presents a rounded eminence above the alveolus for the last molar tooth, termed the *tuberosity*. Above it a short distance lie the posterior dental foramina for the transmission of the posterior dental artery and nerves. The surface presents internally an articular surface for the pyramidal process of the palatal bone.

*The Nasal Process.*—This is the stoutest in the region of the face. It is broader below than above, and is inclined upward and slightly forward and backward to articulate by a broad, jagged extremity with the frontal bone. The origin of the nasal process is best seen from within the nasal chamber; it here presents a smooth concave surface defined in front by the sharp compressed edge of the outer border of the anterior nares, and behind by the thickened anterior border of the lachrymal groove. This border is traceable upward to appear at the outer aspect of the bone on the inner wall of the orbit in front of the lachrymal bone, so that the lachrymal groove lies upon the inner side of the nasal process below and terminates at its outer side above. The nasal process is marked within by two transverse ridges, the lower for the inferior turbinated bone, the upper for the middle turbinated. The outer or facial surface may be divided at the level of the infra-orbital ridge into an upper and a lower portion. The upper portion is slightly concave externally, and marked by minute depressions thought to be traces of the development of the bone. Its anterior edge is articulated with the nasal bone. The infra-orbital ridge is here observed to form the anterior border of the lachrymal groove.

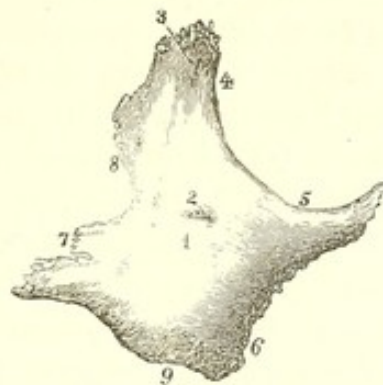
The *palatal* process is a horizontal plate of bone extending the entire length of the oral aspect of the superior maxilla. It is thinner at its middle than at either border. It is best defined opposite the second molar tooth, where it arises from the alveolar process and presents a thin transverse border for union with the palatal process of the palatal bone. It joins its fellow of the opposite side at the median line by a vertically serrate border; the upper edge of which, termed the *crest*, is produced to articulate with the vomer. The internal border of the palatal process is broader in front than behind, and it is continuous with the mesial border of the alveolar process at about the site of the anterior palatine canal. This foramen is best seen from beneath when the superior maxillæ are in position. It then presents an ovoidal depression, at the base of which is seen the median suture. Lying within this suture are the two minute naso-palatine canals. At its sides are seen the incisorial foramina. These two sets of canals transmit the terminal branches of the naso-palatine nerves from the nasal chambers to the roof of the mouth. The palatal process is smooth and concave above to enter into the floor of the nose, and roughened below for the



attachment of the mucous membrane of the roof of the mouth. The lateral border of this surface is grooved for the posterior palatine artery and nerve.

The *alveolar* process extends along the under margins of the facial and zygomatic surfaces. It is a stout curved mass of spongy bone, placed at the sides of the hard palate and curved forward at the incisorial region to join its fellow of the opposite side at the median line. It is well defined within the cavity of the mouth, where it forms an angle to the palatal process. On the facial and zygomatic aspects it is continuous with the body of the bone. The alveolar process is divided into eight sockets or alveoli, corresponding in size and shape to the teeth; those of the molar teeth being broad, the canine circular, and the incisors somewhat compressed from side to side. The base of the sockets for the roots of the first and second molars may appear as eminences within the maxillary sinus. That of the canine tooth is the deepest, and forms an eminence (canine eminence) on the facial border, reaching half-way to the orbit.

FIG. 19.—OUTER VIEW OF THE RIGHT MALAR BONE.



1, external or facial surface; 2, malar foramen; 3, frontal process; 4, 5, orbital border; 6, maxillary border; 7, zygomatic process; 8, temporal border; 9, inferior border.

The malar process is broad, and seen at the junction of the facial and zygomatic surfaces. It is directed horizontally outwards, and articulates with the malar bone. It is occupied by a small portion of the maxillary sinus.

*The Malar Bone.*—The malar bone is situated at the side of the face, where it joins the cranium. It forms part of the temporal fossa and the anterior portion of the outer border of the orbit. It is associated with the zygomatic process of the temporal bone to form the zygomatic arch. It presents for examination a maxillary, zygomatic, and frontal processes.

The *maxillary* process is broad and irregular. It articulates with the malar process of the superior maxilla. The *frontal* process forms the latter inferior third of the edge of the orbital margin, to articulate at the external lateral process of the frontal bone. A thin plate is directed



inward from the frontal process its entire length, to join the great wing of the sphenoid bone. It is called the *orbital plate*, and helps to separate the orbit from the temporal fossa. A small portion of the orbital process ordinarily remains free, and enters into the outer border of the sphenomaxillary fissure.

The *zygomatic* process is a broad thick plate of bone passing backwards from the side of the face. Its upper margin is horizontal, continuous with the frontal process to form the fronto-jugal border. Its course is oblique and continuous with the malar ridge of the superior maxilla, to form the maxillo-jugal border. The zygomatic process is received by the corresponding process of the temporal bone through a serrate suture.

The malar bone presents a *subcutaneous* or facial surface which can be defined beneath the skin. It is smooth, somewhat convex, and furnished with several minute foramina for the malar branches of the ophthalmic nerve. A *temporal* surface is formed by the temporal aspects of the zygomatic and frontal processes, and an orbital surface by the orbital aspects of the frontal and malar processes.

*The Palatal Bone.*—The palatal bone occupies the space which would otherwise exist between the superior maxilla and the pterygoid process. It is placed to the outer side of the nasal chamber and the posterior part of the floor of the nose and roof of the mouth. It enters also into the composition of the floor of the orbit,—assists in closing the posterior ethmoidal cells, and the inner border of the sphenomaxillary space and fissure. It is in the form of the letter L, with the angle produced downwards and the vertical member notched above. In addition to a horizontal or vertical plate, it presents a pyramidal, orbital, and a sphenoidal process.

The *horizontal* plate corresponds to the plate of the same name of the superior maxilla. It is concave above to form part of the floor of the nose, and is nearly flat below, but smooth to enter into the construction of the roof of the mouth. Its anterior border is serrated for articulation with the horizontal plate of the superior maxilla; the posterior is concave, to form the posterior border of the hard palate. Its inner border, when united with that of the opposite side, is produced posteriorly to form the posterior nasal spine. The junction of the horizontal and vertical portions of the bone is marked by an opening—the posterior palatine canal—and by a sharp ledge of bone extending inwards from the base of the pyramidal process, to give attachment to the palatal aponeurosis.

The *vertical* plate extends from the floor of the nose to the level of the sphenopalatine notch. It is smooth externally, when it forms the internal boundary of the sphenomaxillary fossa. Internally it is

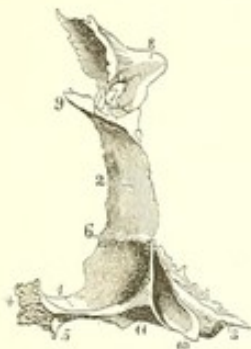

marked by two crests,—the upper for the middle turbinated, the lower for the inferior turbinated bone. It is grooved along its posterior border (forming the posterior palatine groove) for the posterior palatine artery and nerve.

Two processes arise from the termination of the vertical plate—the sphenoidal and the orbital. Of these, the *sphenoidal* would appear to be the continuation of the vertical plate. It passes upward and backward as a thin wafer-like lamella, and, curving inward at its extremity, lies along the inner border of the base of the internal pterygoid plate to join the vomer. It thus may be said to enter into the construction of the roof of the nose.

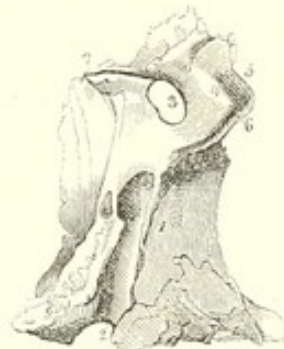The *orbital* process is more robust. It forms the anterior boundary of the sphenopalatine notch, and enters into the floor of the orbit and the sphenomaxillary fossa. It articulates with the superior maxilla, the sphenoidal turbinated, and the ethmoid bones.

FIG. 20.—POSTERIOR VIEW OF THE RIGHT PALATAL BONE.



1, palate plate; 2, nasal plate; 3, pyramidal process; 4, articular border for the left palate bone; 5, palate spine; 6, ridge for junction with the turbinated bone; 7, sphenopalatine notch, between 8, the orbital, and 9, the sphenoidal process; 10, groove for the internal pterygoid process of the sphenoid bone; 11, position of the posterior palatine foramen.

FIG. 21.—EXTERIOR VIEW OF THE RIGHT PALATAL BONE.



1, rough surface articulating with the superior maxilla, and diminishing the aperture of the maxillary sinus; 2, posterior palatine canal, completed by the tuberosity of the superior maxilla; 3, sphenopalatine notch; 4, 5, 6, orbital process; 4, surface directed toward the pterygomaxillary fossa; 5, orbital surface; 6, maxillary border; 7, sphenoidal process; 8, pyramidal process.

The *pyramidal* process or tuberosity is an elongated wedge arising at the union of the vertical with the horizontal plates. It is directed outwards and backwards to be received into the pterygoid notch of the sphenoid bone. It is marked for articulation with the internal and external pterygoid plates. Between these is a smooth surface which enters into the pterygoid fossa.

The sphenopalatine notch, which lies between the orbital and sphenoidal processes, is connected into a foramen by the sphenoidal turbinated bone of its own side.

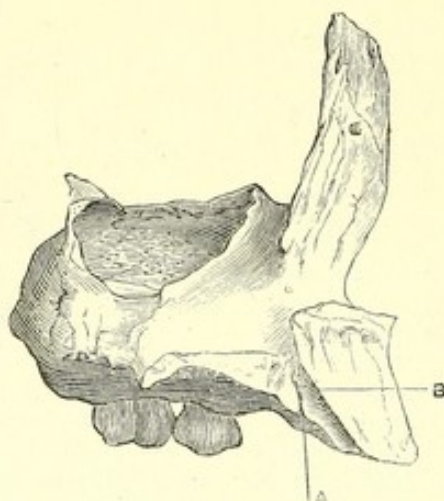
We propose dividing the surgical portion of our subject as follows :



(a) The morbid processes of the upper jaw as influenced by its development; (b) by the relations of the upper jaw to mucous membrane; (c) by the localization of diseased action.

(a) *Development and growth.*—The palatal and malar bones each arise from a single center of ossification; the superior maxilla arises from a number, possibly seven. It does not concern us to recall more than two of these, the one for that portion of the bone supporting the canine, bicuspid, and molar teeth, the other that carrying the incisor teeth. The former may be called the *maxilla* proper, the latter the *premaxilla*. When the premaxillæ unite at the median line, the pair of premaxillæ may be denominated the *intermaxillary bone*. But the fact that it is a symmetrical growth, analogous to such structures as the uvula and external nose, should never be forgotten. The suture denoting the nature of the premaxillæ as distinct from the maxillæ proper can be seen at the median line as late as the sixth year (see Fig. 22 A ;

FIG. 22.—PROFILE VIEW OF LEFT SUPERIOR MAXILLA AT ABOUT THE SIXTH YEAR.



A, the remains of the suture between maxilla and premaxilla; B, the premaxilla.

also Fig. 23) and sometimes on the palatal face until the adult condition is attained. But in diseased conditions the identity of the premaxilla is occasionally made very evident. Mr. Hughlings Jackson\* describes a case of a boy three years of age, who suffered from severe inflammation of the mouth followed by the exfoliation of the right premaxilla. The bone contained two incisor teeth, the maxilla proper not being affected. Mr. Bryant† gives an instance of the same disease in an adult aged forty-four, from whom an exfoliation was secured which corresponded to the premaxilla.

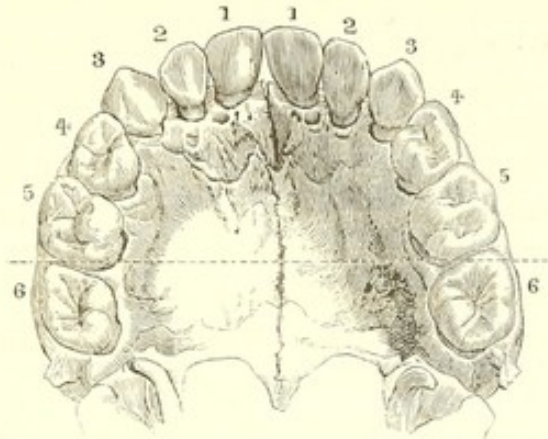
\* Med. Times and Gazette, 681, 1862, part 2.

† Trans. Path. Soc. London, 1868; also Lancet, 1864, 153.



The following is an exceedingly interesting case in this connection. M. C., aged sixty, came under our notice for a defect which prevented his dentist fitting a plate for artificial teeth. He was edentulous, and had from early childhood a cleft in the incisorial portion of the

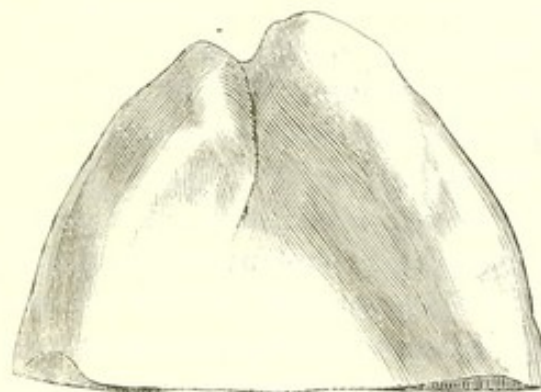
FIG. 23.—THE HARD PALATE AND SUPERIOR DENTAL ARCH, WITH THE TEETH IN POSITION.



From the skull of a child about six years of age. The suture between the right superior maxilla and the right premaxilla is distinctly seen.

upper jaw, which, as he had been informed by his parents, had been caused by the loss of bone following an attack of measles. The cleft was a little to the right of the median line, and extended upward to the floor of the nose and backward along the roof of the mouth about

FIG. 24.—CAST OF HARD PALATE, SHOWING ACQUIRED ABSENCE OF LEFT PREMAXILLA.



an inch. The sides of the cleft were for some distance in contact; they parted a little in front; posteriorly a delicate probe could be introduced into the nose. The entire right side of the dental arch was more incurved than the left (Fig. 24).

Here was evidently a case of acquired malformation of the hard palate, the result of early loss of the left premaxilla. After many



attempts to retain a plate in position, Dr. J. N. Wunderlich overcame the difficulty by an ingenious contrivance placed on the upper surface of the plate, by means of which the passage between the nose and mouth was plugged when the plate was in position.

The fact that both upper and lower jaws are derived from membrane, would apparently explain the rarity of cartilaginous tumors, and equally make clear the meaning of the fact expressed by Gross,\* as follows:

"Pure fibrous tumors of the upper jaw are not very common, but in connection with the lower maxilla they constitute the larger proportion of all fibromas in the osseous system."

The case described by Mr. Hutchinson,† in which a cartilaginous tumor of the upper jaw occupied the canine fossa, but did not grow from the bone, must be considered in every way anomalous.

The law of symmetrical distribution of diseased action is not without example in the upper jaw, though expressions of it are rare. The cases of Lebert and Murchison, cited in the section on the lower jaw, also included lesions of the upper jaw. Fergusson,‡ in commenting on a case of tumor in the alveolus and median line of the upper jaw, says that disease in one maxilla is common, but it is rare to find it implicating both. An instance in which the lesion crossed the median line is described in the same journal, 1859, p. 230.

The *growth* of the palatal and malar bones is consonant with, and dependent upon, the growth of the maxilla proper, and in the malar bone particularly since this bone has intimate associations with the temporal and masseter muscles, it depends in great part upon the growth of the lower jaw as well. Thus we find in the infant the facial proportions are small compared with those of the head, because the dental (masticatorial) proportions of both upper and lower jaws have not pronounced themselves.§

(b) *The relations of the upper jaw to mucous membrane.*—The significance of a mucous membrane remaining in contact with bone has been touched upon in the lower jaw. The phenomenon of a mucous membrane bearing special organs of great complexity (the teeth), and securing support by implantation in a bone, is a very curious one. If the hairs of the scalp were to be inserted into the skull, or the moustache in the upper jaw, we would express great astonishment; yet such an extreme proposition is no more remarkable than what is seen to take place in the jaws.||

---

\* System of Surgery, ii. 467.

† Med. Times and Gazette, 1850, 231, part 2.

‡ Ibid., 1860, 35.

§ Mr. Hilton (Notes on the Cranium, etc., 1855) regards the palatal bone as an epiphysis (!) to the superior maxilla.

|| The whalebone pendant from the roof of the mouth, the feathers of certain



Such association must modify both normal and abnormal nutrition of the bones. Are we to say less of the palatal process of the superior maxilla and palatal bone or of the maxillary sinus? We would not be going far from the direct line by asserting that the majority of the errors of nutrition of the upper jaw are of mucous origin. Not that elements of disease originate directly within mucous membrane; for we know that the immediate elements of this membrane do not tend either to start or to extend diseased action. But we do believe that the glandular element of mucous tissue may modify diseased action whenever such membrane is in contact with bone. Thus, cystic tumors of the maxillary sinus are vastly more frequent than in other portions of the body. They arise, according to Giralès, from enlargement of the glandular follicles which stud the mucous membrane, and are especially conspicuous on the inner wall of the chamber in the vicinity of the outlet.\*

It would be entering too completely the domain of pathology to pursue this subject further, and we must content ourselves with an outline of the deformity arising from cystic distention of the sinus.

A tumor growing in all directions from the sinus would encroach within on the nasal chamber, above on the orbit, without and forward on the face, and downward into the mouth. The most common form of distortion, or at least the most noticeable and valuable form, is the obliteration of the canine fossa. At times the bone becomes thinned, and will crackle under the finger like a piece of parchment. Rarely, as in a case mentioned by C. H. Moore,† a tumor of the right superior maxilla of about two years' duration, a conspicuous thinning of the wall about the position of the canine fossa occurred, which eventually gave way, and the fluid contained in the sinus escaped into the mouth. In other instances, a fistule on the cheek will lead up to the collection, as occurred in a case described by J. H. Howard.‡ In a later stage of cystic distention, the entire anterior wall of the sinus bulges forward and gives rise to deformity.

After the anterior, the most yielding wall of the sinus is the orbital. As a result of pressure in this direction, the eyeball is displaced and often protrudes, the conjunctiva becoming thickened and inflamed. Pressure toward the nose and toward the hard palate are relatively infrequent. Mr. J. H. Howard (*loc. cit.*) mentions a case in which the nostril was thus encroached upon. The trickling of a fluid from the nostril of the affected side, one would suppose from the communication

---

birds making impressions on the radius, are examples of the same association of integumental and mucous appendages with the skeleton.

\* Gross, *loc. cit.*, ii. 465.

† Trans. Clinical Society of London, iii. 39.

‡ *Ibid.*, v. 131.



between the sinus and the nose to be a common sign. Experience teaches us, however, that this opening is often closed in cystic distention.

It is a curious fact that this disease does not involve the lachrymal duct. Tumors of a fibrous and encephaloid nature, on the other hand, may cause overflowing of the tears from such pressure,\* as well as paralysis of sensation in the affected part, as witnessed by Fergusson.†

(c) *The localization of diseased action.*—The origin of solid tumors involving the upper jaw is so obscurely localized that little of definite value can be written of it.

That *necrosis* of so vascular a group of bones as those composing the upper jaw should occur in a degree seen in the following case is certainly very exceptional.

In a male child, aged four years, a month after he had recovered from an attack of measles an offensive discharge was announced from the right nostril. The right eye became prominent, and finally protruded conspicuously. The cornea sloughed, and the globe gave way. The right maxilla, malar, and part of sphenoid bone necrosed. The child died at the end of eleven weeks, of phlebitis of ophthalmic vein involving the base of the brain.

## THE NOSE.

### I.

The nose has been divided conveniently into the nose proper, or *external nose*, and the internal nose, or *nasal chamber*.

Analogy would suggest that the external nose holds to the nasal chambers the same relation the external ear holds to the middle ear. In the case of the ear, the mucous and labyrinthian divisions are separate; but in the nasal chambers they are commingled. Were we to reserve the term *vestibule* to the external apparatus of each, and to the remaining portion the title of the *essential chamber*, the analogy between the external nose and the auricle for a *vestibule*, and the nasal chambers and the *middle ear* (plus the *labyrinth*) for an essential chamber, would be complete.

The external nose is a rudimentary proboscis. It has nerves of common sensation only. At the same time it is not so much a true integer to the face as an organ intimately associated with it. The man who invented the phrase that a certain thing "is as plain as the nose on one's face," evidently was no anatomist. He unconsciously accepted a very intricate form as a type of a simple proposition.

\* Dr. Mason Warren, Surgical Contributions; also, Heath on Diseases of the Jaws, p. 256.

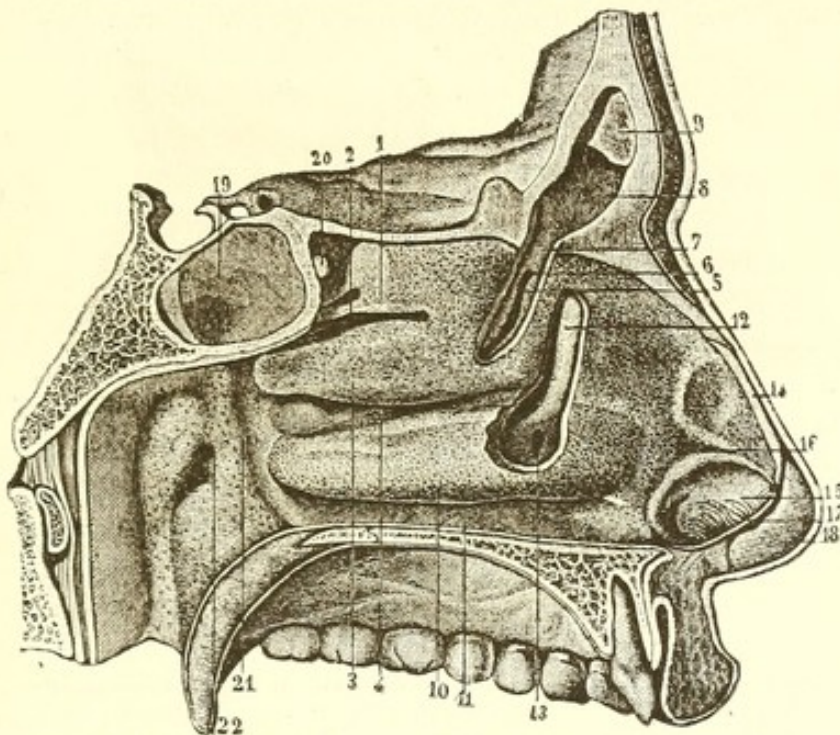
† Lancet, 1861.



The nose is a strictly symmetrical organ, a fact apparently overlooked by the student. The ethmoid bone is a union of two distinct sense capsules, as would be a bone which would unite the petrous portions of both temporal bones.

*The Nasal Chambers.*—These are, from what has preceded, two in number, a right and left, with a portion of the ethmoid bone presenting in each. It is evident that that portion of the nasal chamber presided over by the ethmoid must have an *olfactory significance*. It is far different, however, with the *turbinated bone*, which is not supplied by filaments of the olfactory nerve, and which is directly within the respi-

FIG. 25.—OUTER WALL OF THE LEFT NASAL CAVITY.



1, superior turbinated process; 2, superior meatus; 3, inferior turbinated process; 4, middle meatus; 5, portion of the turbinated processes of the ethmoid bone, removed to exhibit the orifice of communication, 6, with the anterior ethmoidal sinuses; 7 communication with the frontal sinus; 8, left frontal sinus; 9, part of the unsymmetrical partition which separates the frontal sinuses; 10, turbinated bone; 11, inferior meatus; 12, lachrymo-nasal duct exposed by removing a portion of the bones; 13, its termination; 14, edge of the upper lateral cartilage; 15, outer part of the left nostril; 17, cut edge of the cartilage of the partition; 18, inner portion of the left lower lateral cartilage; 19, sphenoidal sinus; 20, its orifice; 21, pharynx; 22, orifice of the Eustachian tube.

ratory tract. An arrow placed vertically upon the surface of the ethmoid bone in the nasal chamber will indicate the position of the *olfactory* division of the nose; a second placed horizontally below the turbinated will represent the *respiratory* division; and a third placed in the axis of the plane of the nostril will represent the *vestibule*. It will be observed that the vestibule is supplied by the nasal branch of the ophthalmic nerve; the olfactory by its own special nerve; while both the olfactory and respiratory divisions receive common sensation from

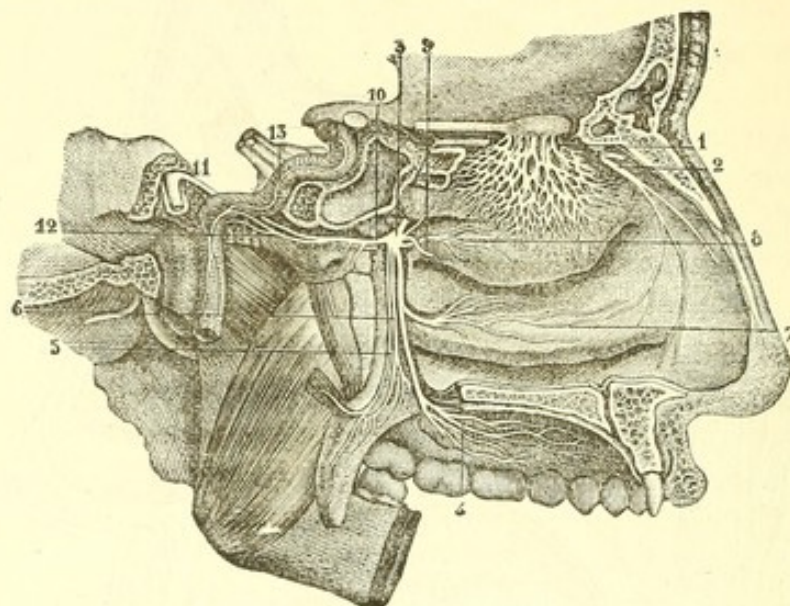


branches of the superior maxillary and the ganglion of Meckel (Fig. 26.)

We will first treat of the olfactory and respiratory divisions, and describe the bones entering into them.

*The Ethmoid Bone.*—The ethmoid bone is situated for the most part in the face. It is held within the ethmoid notch of the frontal bone by its superficial surface only. The bone is of papyraceous consistence,—being compact only where the uncinate process arises in common with the nasal lamella anteriorly. It is composed of a *vertical* and a *horizontal plate* and the *lateral masses*.

FIG. 26.—VIEW OF THE SPHENO-PALATINE GANGLION, THE OUTER WALL OF THE LEFT NASAL CAVITY, AND THE OLFACTORY NERVE.



1, olfactory nerve; 2, nasal branch of the ophthalmic nerve; 3, sphenopalatine ganglion; 4, 5, 6, palatine nerves; 7, branch of the nose; 8, nasal nerve to the outer wall of the nose; 9, do. to the inner wall; 10, pterygoid nerve; 11, facial nerve; 12, deep petrosal nerve joining the carotid plexus; 13, the other branch of the pterygoid is the larger petrosal nerve, which joins the facial.

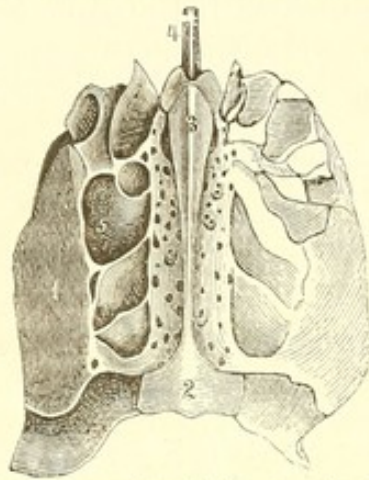
The vertical plate is a thin lamina of bone extending downward in the median line from the horizontal plate to form the upper third of the nasal septum. Its anterior boundary is inclined forward, and articulates with the nasal spine of the frontal and the crest of the nasal bones. The posterior joins the sphenoidal crest of the sphenoid bone; the inferior presents a border which is angulated at its posterior third. The portion sloping upward and forward, in front of the angle, articulates with the triangular cartilage of the nose, that behind inclining upward and backward to join the vomer. The sides of the vertical plate are grooved for the reception of filaments of the olfactory nerve. The vertical plate projects beyond the horizontal plate to appear within the brain-case. It is here termed the *crista galli*. Seen from above it



appears to arise from the middle of the horizontal plate. It is a robust, angulated ridge, whose anterior border is nearly vertical, and provided at its base with two lateral flanges, the ethmoidal alæ. Immediately in front of this surface is the foramen cæcum. The posterior border is more sloped. The crista galli is designed for the insertion of the great longitudinal falx: it is occasionally hollow.

*The Horizontal Plate.*—The crista galli, already mentioned, lies upon the horizontal plate at the extremity of the vertical lamella. On either side of it are seen the cribriform plates, which are transverse septa, consti-

FIG. 27.—UPPER VIEW OF THE ETHMOID BONE.



1, orbital surface of the lateral mass; 2, posterior extremity of the cribriform plate, which unites the lateral masses, and is depressed and perforated with numerous foramina on each side of the ethmoidal crest 3; the two oblique processes in advance of the latter are the ethmoidal wings; 4, anterior extremity of the nasal plate; 5, the ethmoidal sinuses.

tuting the floor of the cerebral fossa and the roofs of the nasal chambers. They are sometimes termed the olfactory grooves. Each groove is perforated by three rows of openings, the middle of which are simple perforations of the roof of the nasal chambers of its own side, while the inner and outer are the openings of minute canals which lie upon the vertical lamina, and the nasal side of the lateral mass. At the anterior part of each olfactory groove a slit is seen for the escape of the nasal branch of the ophthalmic nerve into the nose.

*The Lateral Masses.*—These are two in number, one on either side of the vertical lamina. Each lateral mass is of a cuboidal figure, to the inner border of which is attached the olfactory groove, thus uniting it to the vertical lamina.

It presents three divisions: the *nasal*, *uncinate*, and *orbital*.

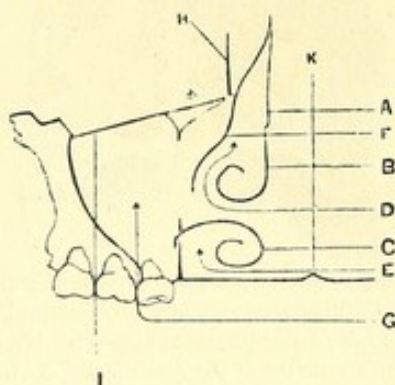
The *nasal* may be said to descend from the horizontal plate, where it is grooved for filaments of the olfactory nerve. It defines the inner aspect of the lateral mass its entire length, and constitutes the upper two-thirds of the outer wall of the nasal chamber. Anteriorly it forms an attachment to the frontal bone at the outer side of the frontal spine.



Thence it passes downward a little outward and forward, to lie in contact with the nasal aspect of the ascending process of the superior maxilla. It is imperfectly divided by a narrow sulcus (the superior meatus) into two portions. The superior meatus is, as a rule, continuous with the sphenoidal margin of the bone which it deeply notches. The space above this meatus and its overhanging, curved border is termed the superior turbinated process. It articulates posteriorly with the sphenoidal crest. That below it is termed the middle turbinated process, and articulates with the palatal bone at its upper crest.

Arising from the anterior margin of the nasal plate is the *uncinate lamina*, commonly called the uncinat process, or the process of Blumenbach. This is a thin extension of bone backward and outward. Often scythe-shaped, it may be irregularly square. It lies to the inner side of the ascending process of the superior maxilla, which it may

FIG. 28.—DIAGRAM OF THE RELATION OF THE SUPERIOR MAXILLA WITH THE INTERNAL NASAL CHAMBER.



A, B, the nasal lamella of the ethmoid bone. A, the superior turbinated scroll. B, the middle turbinated scroll. C, the inferior turbinated bone. D, the middle meatus, leading upward to the space between the uncinat process and the nasal lamella of the ethmoid bone. E, the inferior meatus. F, the uncinat process of the ethmoid bone. G, the maxillary sinus. H, the os planum of the ethmoid bone. I, the orbital plate of the superior maxilla. K, the nasal septum. \*, the portion of the orbital plate lying to the inner side of the opening of the maxillary sinus.

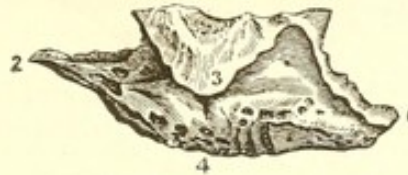touch. It thence passes behind the lachrymal bone, where it sends a small process downward, to articulate with the lachrymal process of the turbinated bone. The uncinat process terminates in an irregular margin, which aids in closing the large orifice of the maxillary sinus. It articulates in part with the ethmoidal process of the turbinated bone, and in part, at times, with the superior maxilla. This process is of much greater importance than the student may imagine. He should remember its position and its use in strengthening the inner wall of the maxillary sinus. When the rarity of cystic distension inward of the sinus, and the great frequency of deflection of the nasal septum under slight pressure, are considered, it will be seen that the uncinat process is structurally the stronger of the two.

. The *orbital division* of the lateral mass is connected to the nasal sur-



face by transverse septa, but is occasionally free. It is cellular, and divided into an anterior and a posterior set of cells. It presents an inner surface, just mentioned, an outer surface (*os planum*), smooth and quadrangular, which is exposed within the orbit. It lies between the lachrymal bone in front, the orbital process of the palatal behind, the frontal above, and the orbital plate of the superior maxilla below. The *upper* surface of the orbital portion is imperfect, and is covered in by the frontal bone. The hinder surface is continuous with the sphenoidal turbinates and the palatino-maxillary cells. It communicates with the posterior group of cells through the superior meatus. The *anterior* surface is narrower, and, by removing the lachrymal bone, observed in part to terminate upon the root of the uncinat process, and is in part continuous with the frontal sinus and the anterior ethmoid cells.

FIG. 29.—EXTERNAL VIEW OF THE RIGHT TURBINATED BONE.



1, anterior extremity articulating with the superior maxillary bone; 2, posterior extremity articulating with the palate bone; 3, hook-like plate overhanging the lower border of the maxillary sinus. The process in advance of it above joins the lachrymal bone to contribute in the formation of the lachrymo-nasal duct. 4, inferior, obtuse border.

*The Turbinated Bone.*—The turbinated bone is an elongated scroll of bone appended by its outer border to the inner wall of the maxillary sinus, and to the lower crest of the palatal bone. It consists of a body and three processes, the *maxillary*, the *lachrymal*, and the *ethmoidal*. Its inner border, at its anterior edge, is fixed to the inferior crest of the nasal process of the superior maxilla. The bone is curved from within outward, presenting a convexity toward the nasal chamber, grooved for vessels and nerves. The entire bone is of papery consistency, and is marked by minute depressions and elevations for the retention of the mucous membrane.

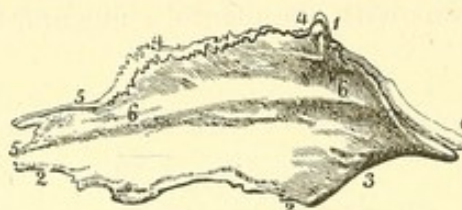
The *maxillary* process is a hook-like process of a hemicircular shape. Hence its name, sometimes given it, of the auricular process. It is applied to the inner wall of the maxillary sinus, and serves to maintain the bone in position. The *lachrymal* process passes upward and forward to articulate with the inner portion of the lachrymal bone. The *ethmoidal* process arises in the same plane a little farther back, to effect a junction with the uncinat process of the ethmoid bone. The lachrymal and ethmoidal processes aid in defining the nasal wall of the maxillary sinus.

*The Vomer.*—The vomer is a thin, rhomboid lamina of bone, having



its upper and lower borders nearly horizontal; the anterior part sloping from above downward and forward, extending from the median line of the body of the sphenoid bone to the hard palate from above along its entire length. Its lower margin is, therefore, longer than the upper. Its sphenoidal surface is furnished with a V-shaped depression, with stoutish, everted lips for the insertion of the rostrum. The lateral edge of the lip unites with the sphenoidal process of the palatal bone. Its *palatal* surface is broad and even anteriorly, sharp and thin posteriorly, for articulation with the crests of the superior maxillæ and the palatal bones. Its *ethmoidal* surface is grooved for the reception of the vertical

FIG. 30.—LEFT SIDE OF THE VOMER.



1, 1, broad groove receiving the rostrum of the sphenoid bone; 2, 2, inferior border articulating with the palate plates of the superior maxillary and palate bone; 3, 3, posterior border, the dividing line of the posterior nares; 4, 4, grooved border receiving a narrow slip of cartilage, situated between the vomer and the nasal plate of the ethmoid bone; 5, 5, border for the cartilaginous septum of the nose; 6, 6, nasal surface.

plate of the ethmoid bone. In advance of the ethmoid surface is a thin, compressed margin for union with the septal cartilage. The posterior surface is free. The sides of the vomer are smooth, save where they are grooved for the naso-palatine vessels and nerves. The sides of the alæ are marked by a ridge of minute points, which serve to limit the plane of the posterior nares superiorly. The vomer is composed of two layers which slightly diverge at the anterior border. A thin rod of cartilage, continuous with the cartilage of the septum, is, as a rule, found in the space between the two vomerine layers.

In reviewing the osseous frame-work of the nasal chamber, excluding that portion pertaining to the vestibule, we find that one-half of the cribriform plate of the ethmoid bone constitutes the *roof* of the chamber, aided by the sphenoidal turbinated bones; that the vertical plate of the ethmoid bone and vomer constitutes the *inner* wall; the palatal plates of the superior maxilla and the palatal bone the *floor*, and the nasal lamella of the ethmoid bone and the convex surface of the turbinated bone its *outer* wall. We have already said that the sulcus on the nasal lamella of the ethmoid bone is called the *superior meatus*; that between the lamella and the turbinated bone, the *middle meatus*; while the space between the turbinated and the floor of the nose is the *inferior meatus*.

It is a noticeable fact that the mucus of the frontal, maxillary and



sphenoidal sinuses, as well as the tears, flow into the nasal chamber in such a way as to be diverted downward and backward. The constant seeping of mucus over the turbinated scrolls tends to bring the fluid towards the pharynx, in which it is lost. But while the sense of smell requires the olfactory area to be constantly bathed in moisture, an excess of fluid would be destructive of this sense. Thus we find that the secretion from the above sources flows in the depressions (meatus) of the outer wall, and not on the convexities of the scrolls,—an observation original, we believe, with Dr. J. G. Guiteras.\*

In common with other parts, the *floor* of the nose is sloped a little downward, so that the tears entering the inferior meatus also tend backward. In extremes of excess only, as in violent weeping, do the tears flow forward on the face. The secretion from the maxillary sinus cannot escape while the erect position is maintained, unless the fluid is raised to the level of the nasal orifice. As a rule, we may say that the sinus of one side empties itself while the subject is lying prone on the opposite side.

The communication of the nose with the pharynx is called the posterior naris. But we should not forget that this term applies to the *skull* rather than the parts in the living subject,—for we find its equivalent, the anterior naris, confined to the aperture of the nostril. The anterior orifice of the nasal chamber is more comparable to the posterior naris. It is unfortunate that these terms are not more carefully distinguished. Many persons apply the term "*nostril*" to any or all parts of the nasal chamber. Others call the nostril the "*anterior nares*." It should be remembered that the nostril belongs to the external nose; is an orifice, not a chamber; that both nares are also orifices. A better term than posterior naris to express the parts as seen in the living subject would be *choana*, a term already in use by continental writers. The parts, as seen by reflected light within the choana, form the rhinal image. The lateral opening of the nasal chamber is the sphenopalatine foramen. This is occupied in life by the sphenopalatine vessels and nerves. In certain morbid conditions tumors within the sphenomaxillary space may enter the nasal chamber, or, on the other hand, arising within the nasal chamber, a tumor may pass outward through the foramen.† Polypus of the nasal chamber may extend into the orbit, as occurred in a case recorded by Skey.‡ In consequence of the relative large size of this foramen to the structures passing through it, neuralgia of the nasal chamber is an unknown affection.

---

\* An inaugural thesis for the degree of doctor of medicine in the University of Pennsylvania, entitled "The Development of the Skeleton as influenced by Functional Activity," 1873.

† Chir. Anat. Blandin, Doane's Trans., p. 68; Chir. Anat., Velpeau, i. 84.

‡ Lancet, 1860, i. 118.



The *mucous membrane* lining the nasal chamber is very thin, and comparatively free from glands, as seen in the vestibule and the inner wall; but is thicker, more vascular, and yields a larger number of glands, where it covers the scrolls. In the latter place it is furnished with plexiform arrangements of veins, which, according to Dr. Cohen,\* favor the sudden stoppage of the nose, occurring in catarrhal affections of the nasal mucous membrane, and permit as prompt a subsidence, under the use of remedies which constrict the blood-vessels. The membrane where it overlies the turbinated bones is thicker than elsewhere, and subject to an œdematous condition which may be mistaken for polypus. A similar appearance may arise from chronic inflammation of the mucous membrane.

*Inflammation.*—The anatomical relations of the mucous membrane with the bones are, in the nasal chamber, something of the same kind witnessed between the gum-tissue and the adjacent bone. They are less pronounced, however, and in a healthy condition are scarcely evident. But in the engorgement accompanying an acute attack of inflammation, particularly in the type which is not relieved by simple flushing of the mucous follicles, but which promotes free exudation of serum from the blood-vessels, the underlying periosteal layer becomes involved, and in specific inflammation the bone itself speedily affected. Hence the early losses of the turbinated bones from necrosis in syphilis. Many phases of ozæna exhibit a necrotic tendency of the turbinates, to account for their persistency.

*Localization of Diseased Action.*—The nasal chamber is bounded by such natural parts, that we can best divide this portion of our subject by (a) the roof, (b) the floor, (c) the inner wall, and (d) the outer wall.

(a) The narrow cribriform plate forming the greater part of the roof of the chamber is, in cases of its insufficient development in the acephala, converted into a few large holes.† At times, in subjects in other ways well formed, the cribriform plate is weak, and permits the brain to form a hernial protrusion into the nose, as defined by Velpeau‡ and Spring.§ Prof. Retzius|| refers to a case of simple congenital meningocele at the root of the nose in a woman aged twenty-five. It is in confirmation of the sequestered position of the nasal chamber that so thin a plate of bone should be all that intervenes between the brain-case and the surrounding air. That so slight a barrier to serious encranial involvement exists should certainly always be remembered, not only in treating

---

\* Diseases of the Throat, etc. Dr. J. Solis Cohen, 243.

† Otto, Path. Anat., 176.

‡ Chirurg. Anatomie, i. 104.

§ Hernie du Cerveau, Brussels, 1855.

|| Med. Times and Gazette, 1860, 180.



diseases, but in detecting crime. It is well known that a favorite means of committing infanticide is by thrusting a long bodkin or wire up the nose from in front. The ancient Egyptians removed the brains of the bodies of their dead through the laceration of the cribriform plate in their process of embalment. But, unfortunately, we cannot leave the record at this point. Sir Charles Bell mentions, in his *Surgery*, a case where the operator, in attempting to remove a nasal polypus, destroyed the cribriform plate and excited meningitis, which proved fatal on the sixth day. According to J. Cooper Forster,\* disease of the bones within the nose can involve the base of the skull, and continue thence through the cribriform plate to the membranes of the brain. Fibrous polypus not unfrequently arises from the sphenoidal turbinates, as in a noted case recorded by Demarquay.†

(b) The *floor* of the nasal chamber may be said to present few or no peculiarities of diseased action which are not in common with those of the upper jaw. The most common lesion is specific necrosis; and occasionally a fibrous tumor appearing—within the mouth. These have been mentioned in the preceding chapter. In a case of fibrous polypus operated upon by Dr. Mott, two distinct tumors were discovered adhering by separate peduncles to the floor of the nasal chamber, one of them projecting forward, the other backward, into the pharynx, winding around the posterior edge of the septum.‡

(c) The *inner* or septal wall. The mucous membrane covering the septum is less adherent posteriorly than anteriorly, and is apt to form at that point œdematous swellings. These were first described by Dr. J. Solis Cohen (*loc. cit.*, p. 297), under the name of submucous infiltration. Fergusson§ mentions a case of nasal polypus which originated from the ethmoid bone, and extended thence to the occipital condyles, and was attached to both sides of the septum. Of the rare lesion, congenital deficiency of the vomer, we have observed the following: G. S., aged 24, came under our notice August, 1870, complaining of fluids and solids occasionally passing up into the nose during deglutition. He was subject to a laryngeal cough, the cause of which was not detected. His speech resembled that of a person having cleft palate,—a peculiar nasal sniff preceded each expiratory sound. He was slow in learning to talk, and does not pronounce the letters C, S, and X clearly. Upon rhinoscopic examination the vomer was found deficient at its posterior part at its lower third. The left naris was contracted. The middle turbinated was imperfectly developed.

---

\* Tr. Clin. Soc. London, iv. 162.

† Le Mouvement Médical, 1869, 19, 221.

‡ Watson. Am. Jour. Med. Sci., 1842, 325.

§ System of Practical Surgery, 433.



(d) The *outer wall*. This is the most fertile region for the development of nasal polypus, if, indeed, it is not its true seat. As is well known, gelatinous or typical polypus consists of crypt-like sacs, as was probably first announced by Watson (*loc. cit.*), which, by the weight of the mass, is pendent by a more or less narrowed pedicle. This pedicle is almost invariably attached to the nasal lamella of the ethmoid bone. When multiple, the ethmoid cells, lachrymal and turbinated bones yield points of attachment as well. The fibrous polypus is not a product of the mucous membrane, but of the subjacent connective tissue. It has a wider range of origin, and may arise from other parts than the outer wall, as already mentioned. Many instances of so-called multiple fibrous polypus arising from the frontal sinus, lachrymal bone, and sphenoidal sinus are, no doubt, members of the group of round-celled sarcomes.

## II.

### THE EXTERNAL NOSE.

This has already been spoken of in the preceding chapter as a proboscis. The proboscis of an animal is a development from the parts found in the external nose of man, although we do not find all the parts present in the one produced in the other. Thus, the nasal bones are negative agents in shaping a proboscis; they are large in the hog, in which the proboscis is small, and small in the elephant, in which the proboscis is large.

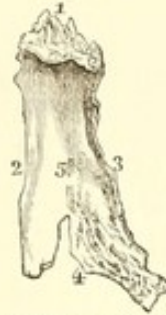The true way of studying the external nose is to view it as an appendage to the organ of smelling,—as the outer and middle ear are appendages to the organ of hearing. As a *vestibule* to the internal nose, we find each *nasal bone* of importance, holding fixed proportions to the size of the vestibule of its own side, to which it is the operculum or roof. The anterior orifice to the vestibule is the nostril, and is defined by the *cartilages of the nose*; we thus come naturally to the outline of our subject: (1) the nasal bone; (2) the cartilages and skin; (3) the interior of the vestibule.

(1) *The Nasal Bone*.—The nasal bone is situated upon the face, wedged in between its fellow of the opposite side internally, the nasal process of the superior maxilla externally, and the nasal notch of the frontal bone superiorly. The length, breadth, and degree of inclination of the nasal bones determine the shape of the nose. The inferior margin is continuous with the upper lateral cartilage of the nose, and is marked in the middle by a notch for the transmission of the nasal branch of the ophthalmic nerve. The nasal bone is composed chiefly of compact tissue. It is thick and narrow above, thinner and widened below to form the upper boundary of the anterior aperture of the vestibule of its own side. Directly behind the median line is the vertical plate of the ethmoid bone and the nasal spine of the frontal bone. The nasal bones concur



to form the bridge of the nose, and slant obliquely downward and forward. The anterior surface is concave from above downward, and convex transversely, and marked by a minute foramen. The internal border is produced posteriorly. The two bones thus form a groove for

FIG. 31.—ANTERIOR VIEW OF THE LEFT NASAL BONE.



1, frontal border; 2, nasal border; 3, maxillary border; 4, lower border; 5, nasal foramen.

the reception of the vertical plate of the ethmoid bone. The outer border is serrate at the expense of the internal surface above and the external below.

The union of the nasal bones with the ascending processes of the superior maxillæ, the frontal, and ethmoid is one of immense strength, and enables the parts to preserve their continuity, except under extraordinary combinations of attack. It is impossible to fracture the nasal bones transversely, without injuring the frontal spine and nasal septum as well. It should be always remembered that emphysema may occur after fracture of the nasal bones,—a complication due to blowing the nose, thus forcing air through the ruptured mucous membrane. Emphysema from this cause may extend beneath the eyelid.

(2) *The Nasal Cartilages and Skin.*—The cartilaginous portion of the external nose is composed of two pairs of cartilages, the cartilage of the septum, and a few isolated sesamoids. The main cartilages are divided into the upper lateral and lower lateral.

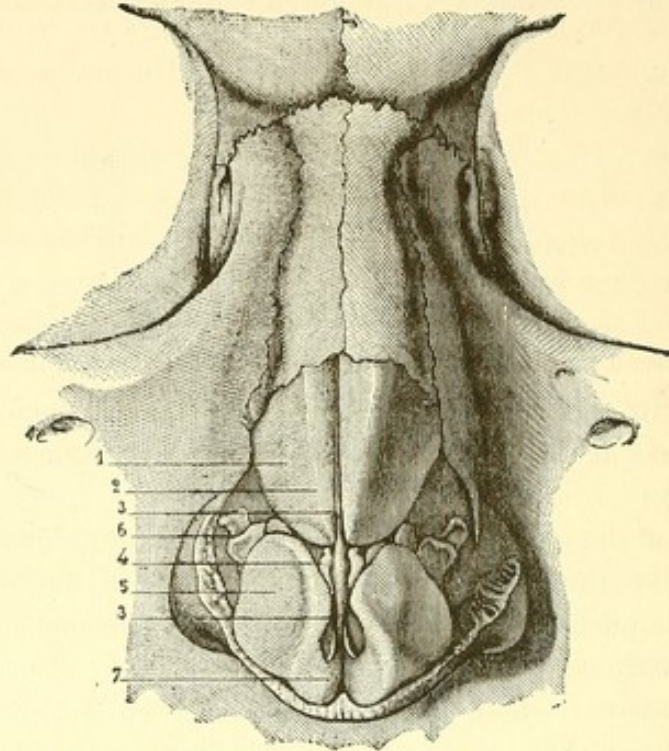
Each *upper lateral cartilage* is triangular, and continuous with the cartilage of the septum as a wing-like expansion. The anterior margin is thicker than the posterior. The cartilage meets its fellow of the opposite side above, but is closely united to the septum below. It is inserted into the ascending nasal process of the maxilla and the nasal bone. The outer border in some measure projects towards the interior of the vestibule, and is seen in faint relief beneath the mucous surface.

The *lower lateral cartilage* enters into the outer and anterior circumference of the tip of the nose. It is distinct from the septum, but does not enter the wings; hence the term sometimes applied to it, the cartilage of the wing, is erroneous. Each cartilage is acutely flexed in the middle, with the outer surface of the angle lodged in the tip of the nose. A depression is felt and often seen at the interval between the tips of the two cartilages. The two arms formed by the flexure pass



backward ; one towards the septum, the other towards the wing,—thus allowing the plane of the nostril to be shaped between. The inner arm is much the smaller, and lies under the border of the septum, in union

FIG. 32.—CARTILAGES OF THE NOSE.



1, upper lateral cartilage; 2, its anterior border; 3, anterior margin of the cartilage of the septum appearing between the lateral cartilages; 4, vomerine cartilage; 5, lower lateral cartilage, back of which is the wing of the nose; 6, accessory cartilages; 7, tip of the nose where the lower lateral cartilages are bent inwardly along the column.

with the corresponding arm of the opposite side. They do not reach the anterior nasal spine, but terminate abruptly in advance of it. Any one can satisfy himself of the close juxtaposition of the inner arms, as well as their independence of the septal cartilage and the anterior nasal spine, by manipulating the structure of the septum of the nostrils between the thumb and index-finger. The outer arm is broad and flat; at times somewhat arched, at others plane, according as the nose is broad or small at the tip. Huxley has called the rudimentary external ear of the crocodile the ear-lid. Let us call the lower lateral cartilage of man the nose-lid.

The sesamoid cartilages are three to four in number, although there may be more. They are flat, rounded nodules placed in the wings of the nose, though one conspicuous pair is placed on either side of the nasal septum. These are named the right and left vomerine cartilages.

The wings of the nose are composed of sesamoids, some fibrous tissue, and fat. The septal cartilage has already been mentioned as continuing the septum in advance of the vomer and the vertical plate of the ethmoid bone. Between it and the inner arms of the lower lateral



cartilages is a membranous space which is continuous with the skin between the nostrils. Hyrtl\* informs us that a cancerous tumor has been removed from the floor of the nose by dividing the septum in the median line, but without opening either vestibule. According to Blumenbach (Hyrtl, *l. c.*), a strong process of the membranous septum is characteristic of Jewish heads.

It will be thus seen that the cartilages are the main support of the lower part of the organ. They give expression to the organ and to the entire face. High noses are likely to have thin cartilages with narrow nostrils; small flat noses, on the other hand, have large, rounded nostrils. The muscles moving the cartilages are rudimentary members of the group of facial muscles, and need not be here described. They are accessory to respiration, as can readily be seen in facial paralysis, or as was notably observed by Sir Charles Bell in sections of the facial nerve in the horse. The inability of the surgeon to reproduce cartilage in the tip of a restored nose, must always cause the operation of rhinoplasty to be an inartistic makeshift.

*The Skin Surface of the External Nose.*—This is thin on the bridge and the sides, where it is easily moved and wrinkled. Beneath the skin at these points a loose connective tissue is found, containing little or no fat. Toward the cartilages, the skin can be raised with difficulty, and toward the sides and tip not at all. We thus find two distinct regions of the nose mapped out. The thumb and index-finger can define them by lifting up a fold of skin over the bridge and between the eyes, beneath the line of the brow. The point at which a fold ceases to be defined as the fingers approach the tip of the nose, separates the tip or lobe of the nose from the remaining parts. Sebaceous glands are abundant in the tip, wings, and in the furrow (naso-labial groove) between the wings and the cheek. Hairs are occasionally seen growing from about these follicles.

The *form* of the external nose necessarily depends upon the proportions preserved between the skin-fold and the lobe, as above indicated.

There are a hundred pretty mouths and eyes, says Thomas Hardy, for one pretty nose. A pronounced bridge is common among the white race, while a depressed bridge is the rule among Asiatic people. The negro is remarkable for the depressed bridge, and enormous expanse of tip and wings. When the bridge is well seen, the nostrils are of course thrown downward, but in less evident expressions are more conspicuous from in front; so that in children with whom the bridge is undeveloped, and in the adult Asiatic, the nostrils are alike inclined forward and upward. The pug nose is often associated with a similar condition of the bridge. Such realistic Watteaus upon faces appro-

---

\* Topog. Anat., i. 289.



priate thereto are not without their own attraction. The Chinese mother entertains a yet nobler sentiment with respect to them: "When the tip of the nose turns up," says she, "it is a sign that you will go to heaven; but if it should chance to turn down, it is a sign that you will go straight to hell!"\* So that it becomes important that we should look after the shapes of our noses.

(3) *The Interior of the Vestibule.*—The mucous lining really defines the vestibule, which may roughly be said to be the interior of the external nose. Beginning in advance of the line of the extremity of the middle turbinated scroll and the inferior turbinated bone, the mucous lining extends forward on either side of the septal cartilage and on the sides of the vestibule, lining the groove-like depression on the hinder side of the nasal bones, superior lateral cartilages, and the angle of the inferior lateral cartilage; thence, to form a pocket above and in front of the anterior margin of the nostril.

At the lower fourth of the septum, and at both inner and outer wall, the mucous tissue becomes more derm-like, and is then continuous with the outer skin.

Each vestibule has the shape of a flask, flattened on one side like a urinal, with the neck prolonged, compressed, and directed upward. The inner wall is formed below by the inner arm of the lower lateral cartilage,—a groove answering to the membranous septum, and above by the septal cartilage. The outer wall is formed by the outer arm of the lower lateral cartilage, and a depression behind it formed by fibro-adipose tissue of the wing. The roof is continuous with that of the nasal chamber. The floor is depressed a little below the level of that of the nasal chamber, so that such an instrument as a Eustachian catheter is best introduced by first elevating the tip of the nose. The superior orifice of the vestibule is a mere chink, and in consequence affords little or no aid in the introduction of instruments into the nasal chamber for the removal of morbid growths. The inferior orifice (the nostril) is an ellipse, whose internal border is nearly straight, and whose external border describes a curve with the posterior extremity, as a rule, more rounded than the anterior.

Both outer and inner aspects of the vestibule near the nostril, as well as the pocket at the tip, are furnished with stiff hairs in patches.

Looking in the nostril by aid of a strong light when the head is thrown back, one sees the following points: 1st, a darkish chink, far within which is the posterior orifice of the vestibule; 2d, on the outer side, the ridge formed by the inferior border of the upper lateral cartilage; 3d, on the same side, a ridge formed by the outer limb of the lower lateral cartilage.

---

\* Travels in the Central Parts of Indo-China, Cambodia and Laos. By Henri Mouhot, ii. 199.



At a point answering to the posterior border of the outer arm of the lower lateral cartilage we have a voluntary contraction possible by the tilting of this border inward towards the septum, at the same time that the wing of the nose is depressed and abducted. This action, incomplete in man, is pronounced in many quadrupeds, in which we may presume occlusion of the vestibules may be announced by the powerful adduction of the cartilages of the wing directly to the septal cartilage.

*The Blood-vessels.*—The arteries are placed for the most part between the skin and the muscles. Most of the branches are derived from the facial, although the internal maxillary give some branches through the infra-orbital, while some, to the bridge, are derived from the ophthalmic. The veins lie nearer the skin than the arteries, hence they are more conspicuous in hyperæmia of the organ. The veins are emptied for the most part either in the tributaries to the superior labial vein, and thence into the facial, or else into the network within the nose, which may communicate with the internal maxillary vein or the ophthalmic. The latter is a feature of great significance, as insisted upon by German writers, who have directed attention to the remarkable appearance of the nose resulting from cerebral engorgement, as in acute mania. Every one is familiar with the reddened nose of the toper, and every physician is aware of the value of this symptom in relation to endangered conditions of the cerebral circulation.

The *nerves* consist of motor twigs to the muscles and sensitive branches from the fifth pair. The *naso-ciliaris* of the anterior ethmoidal passes between the septal cartilage and the inferior border of the nasal bone, and goes to the skin of the tip of the nose. Branches from the infra-trochlear nerve supply the most of the nose, those from the infra-orbital the sides and the wings; a large branch therefrom pierces the *depressor nasi muscle* to supply the membranous part of the septum, and is lost in the skin-covering of the tip.

Owing to the free blood-supply to the nose, wounds of the organ readily heal. Instances are on record where the entire nose has been cut off from the face, yet upon accurate adjustment the severed organ has become reunited. Larrey\* gives two cases of soldiers who had their noses divided from the root to the base by the sabre, so that they were attached only by the septum and a small portion of the alæ. Seven interrupted sutures, with a supporting bandage, were sufficient to produce union. A cicatrix in each case resulted, which was so inconspicuous that no deformity ensued.

Errors or excess of nutrition affect the nose very conspicuously, as in lipoma, in which disease enormous masses of fibrous and follicular tissue may form about the lower part of the organ.

---

\* Memoirs, ii. 280.



*Inflammation.*—We have repeatedly observed periostitis and ostitis of the nasal bones from syphilis; but always dependent upon deep-seated nasal disease. Entire loss of the organ may occur in the course of erosive ulcerations, as in the last-mentioned disease, as well as in lupus and epithelioma.

*Hemorrhage.*—It is well to remember that hemorrhage very often is restricted to points within the vestibule. In the event of its being so located, direct treatment by carrying a probe, armed with a pledget of cotton, carrying a styptic *upward* through the nostril, may promptly check a bleeding for which other means have failed.\*

John R. Begg† has narrated a case of that extremely rare disease, idiopathic gangrene of the external nose and ears. A somewhat similar condition has recently been observed at the Philadelphia Hospital, by Dr. H. C. Wood.

### THE MOUTH.

We divide this section of the facial region into the *mouth proper*, and its *vestibule*.

The *mouth* is the cleft formed by the absence of union between those portions of the first (maxillary) and second (mandibular) visceral arches of the embryo as they appear within the facial region, and closed laterally by the buccinator muscles. Above, it is limited by the maxillary arch; below, by the mandibular arch. The floor of the mouth is intruded upon by the lingual apparatus. At the sides, the mouth is enclosed by the teeth and the alveolar processes. The mouth communicates with the pharynx and the vestibule.

The *vestibule* is confined within by the teeth and the alveolar processes; without, by the cheeks and lips. It joins the mouth internally through a space on either side, in front of the coronoid process and behind the last molar tooth. When the lower jaw is elevated, the mouth is separated from the vestibule, but when depressed, the vestibule and the mouth form a common chamber.

We will speak first of the *mouth*, reserving the floor of the mouth for our remarks on the tongue, and the teeth and gums to another section. We have now but to treat of the *roof*.

The limits of the *roof of the mouth* are those of the hard palate, and are defined by the upper alveolar processes and teeth in front and at the side. Behind, the limit may be said to answer to the posterior margin of the palatal bones. In the living subject, of course, this distinction between the roof and the soft palate is not apparent. Its largest diameter is transverse,—ovoidal, with the smaller extremity

---

\* Dr. R. G. Curtin, in Phil. Medical Times.

† Lancet, September, 1870, 397.



behind. The slope of the roof is liable to extreme variety. The antero-posterior contour is generally at first flat, viz., as it is seen directly behind the incisor teeth. Thence, it somewhat abruptly arches upward and backward, to become again nearly plane at the middle line of the horizontal plate of the palatal bone. The transverse contour at the incisorial region is nearly flat; but at the region of the molar teeth it presents abrupt lateral borders and a shallow transverse arch. The latter may, however, be pronounced or produced.

The arch is much modified by age, being shallow in edentulous conditions, and is best developed when the dental armature of the adult is complete. The median ridge seen in the roof of the mouth of most subjects is due to the downward pressure of the nasal septum. At the point at which the incisorial portion joins the region of the horizontal plate (of both maxillary and palatal bones) there is seen a number of irregular crescentic lines, arranged with their curves directed forward in concentric rows on either side of the median line. These are termed the *rugæ*. They are the rudiments of the more extensive complement found in lower animals, with whom a distinct series is seen pertaining to the region of the incisors as distinct from the rest of the roof. It will be observed that the surface between that of the *rugæ* and the teeth is almost smooth. It is against the latter surface that the tip of the tongue rests in repose, and not withdrawn to the floor of the mouth, as is seen when the lower jaw is depressed. The lower jaw being slightly depressed, the tip of the tongue is abruptly withdrawn from the space in producing the sound of the letter *t*. The *rugæ* are of use as accessories of taste by the rasping of the tip of the tongue backward over them. The restriction of this region to that of the intermaxillary bone is significant. The region of the horizontal plate is unable to bear any but very slight pressure from below upward, except at the median ridge.

The space between the vertical alveolar borders at the side of the hard palate is occupied by the posterior palatal vessels and nerves, as that of the central incisorial region receives the anterior vessels and nerves. Hence, abscesses in the sides and anterior aspect of the roof of the mouth are more vascular than those placed toward the center.

Tumors of the roof of the mouth are rare which do not involve the floor of the nose (*q. v.*). The most frequent lesion recognized is perforation from syphilitic necrosis. Cases of fibrous tumors have been recorded, and epithelial cancer is relatively not unfrequent.

The following rare form of papillary tumor is recorded by Jas. S. A. Salter.\*

In a male of fifty-seven years, six months after extraction of the

---

\* Guy's Hosp. Reports, 3d series, vol. xii., 1866, 365.



first right bicuspid, a swelling on the inside of the palate appeared, extending from the inner border of the alveolus toward the vault of the palate; in one year the wart-like growth had become as large as a split chestnut, and was of a creamy-white color. It was extirpated successfully by Mr. Cock.

The *vestibule* is necessarily a narrow chamber, and when the parts are at rest can scarcely be said to be a chamber in any other sense than that of a mucous-lined space placed in advance of the true mouth. The angles of the mouth being adapted somewhat firmly to the canine teeth, we have the labial portion separated in a sense from the buccal, or cheek portion. The labial portion is again distinguished by the upper and lower fræna. About the position of the upper first bicuspid tooth, a second fold of membrane is seen.

The buccal division of the vestibule determines the position of the cheek. It is defined by the *buccinator* muscle, a structure remarkable for being a member of the pharyngeal-constrictor group projected into the face, and inserted in part among the muscles of the skin-layer. It is somewhat loosely fasciculated, and permits some of the glands of the mucous membrane (the molar glands) to penetrate its fibers from within, and the buccinator nerve from without. It is covered by a distinct though delicate aponeurosis, a feature distinguishing it from any of the skin group.

The mucous lining of the vestibule is smoother in the buccal than in the labial division, due to the sparse distribution of the glands,—the latter being thickly studded with glands of the racemose type. These are abundant about both the lips, particularly the upper. They are of a rounded shape, and large enough to have the outline perceived beneath the mucous membrane. The point at which the parotid duct is received by the vestibule is about the second upper molar. The mucous membrane in the vicinity of this duct is more intimately held to the buccinator muscle than elsewhere. The veins about this point and behind it are conspicuous.

*The Præ-coronoid Space.*—We have ventured to name the orifice of communication between the vestibule and the true oral chamber by this name. It is the mucous surface extending between the dental arches, in front of the coronoid process, and behind the third molar tooth in either jaw. The space has been briefly indicated by others. Kohn\* describes it as a broad surface of mucous membrane extending across the space between the wisdom-tooth and the anterior edge of the coronoid process, and representing the union between the muco-periosteum (gum) and the membrane of the general oral cavity. Sappey†

---

\* Die Syphilis der Schleimhaut, etc., 1866, 380.

† Traité d'Anatomie, iv. 40.



alludes to it as the tract by which the glandular layer of the buccal chamber joins that of the soft palate. The space is due to and continuous with the soft palate. It is remarkable for the changes occurring in its relations during the acts of depression and elevation of the lower jaw. When the mandible is elevated the space is shortened,—the portion about the lower wisdom-tooth is brought up to the level of the body of the soft palate, and the posterior end of the ridge upon the mucous membrane of the cheek tends to plug up the space from without. As the jaw is depressed, the fold disappears. This mobility is associated with a layer of loose connective tissue between the mucous membrane and the basal portion of the coronoid process which it covers. The relation between the mucous layer and the bone is somewhat analogous to that seen between the pharynx and the vertebral column. The præ-coronoid space has exact clinical value. Through it, when the teeth are clinched, as in convulsions or in tetanus, fluids can be administered by a tube which has been inserted in this space. The præ-coronoid space has certain clinical bearings of interest. Observant dentists have long been aware that an incautious application of arsenical paste to an exposed pulp of the terminal lower molar is productive oftentimes of an early and general diffused inflammation of the soft palate. This has been known to extend from the buccal around to the lingual aspect of the tooth by its cingulum of gum, thence, when the jaw is closed, to find easy access by general relaxation of the part directly to the soft palate. An experienced operator has informed us that while engaged, on one occasion, in preparing the lower wisdom-tooth prior to filling, his instrument slipped and caused a slight punctured wound of the mucous membrane of the præ-coronoid space. This apparently insignificant lesion caused in the course of a few hours a general tonsillitis and staphylitis, which terminated in suppuration. Before the abscess opened, which it did spontaneously, dyspnœa with profound prostration were announced. On the other hand, this space may be involved directly from the palate. The point where the buccal ridge of mucous membrane adjoins the space is not infrequently the site of mucous patches. When submucous infiltration of this region occurs, may not its influence upon the internal pterygoid muscle furnish a more satisfactory solution of the origin of direct trismus than we have hitherto had?

*The Cheek.*—This is the skin-layer marking the limits of the buccal chamber, and presents few features of value. The suffusion of arterial blood through the cheek in blushing shows how delicate is the vaso-motor apparatus of this region, a fact which may also explain the evanescent herpetic eruption seen on the cheek from dental or other irritation. The venules of the cheek often become slightly enlarged in middle life.

*The Lips.*—The lips are equally an adjunct to the region of expres-



sion, but inasmuch as their physiological relations are with the mouth, they have been here considered. The lips represent the inner borders of the *orbicularis oris* muscle. When this muscle is contracted, and the lips are pursed, its duty as a labial sphincter is at once recognized. At rest it is much modified from the sphincter shape by the elevators and depressors of the oral angle, as well as the buccinator muscle. In this position the lips extend from canine to canine of either jaw. While recognizing this as the main idea of their construction, we find that the agents giving general form to the lips reside in the alveolar processes and the teeth. Thus the upper lip conforms to the general outline of the incisorial alveolar process. Its curve is continuous with that of the cheek, and it projects a little in advance of the lower, as the upper alveolar process is in advance of the lower. This is conspicuous in infants, with whom the lower jaw is less developed than in the adult, and is marked in strumous subjects. The moderate projection of a short upper lip is essential to beauty. These relations of the upper lip with the jaw are such that we are not surprised to see congenital cleft or clefts of the lip associated with a similar condition of the palate.

The upper lip is marked by a median vertical groove, the *philtrum*. The line of demarkation between the skin and mucous membrane is more sharply defined in the upper than in the lower lip.

The lower lip is much more mobile than the upper. We never by inadvertence bite the upper lip in chewing, but often the lower. It presents a fullness in the center which more or less abruptly declines toward the angles, where its line lies a little receding beneath the upper. Perhaps the most beautiful lips in the antique are those of the Venus of Milo. When viewed from in front they are cold and calm; but seen from the side, "her lips' sweet fold" is wreathed in a faint smile.

Beneath the center of the lower lip, and limiting its mobility, is a marked depression, the mento-labial groove. When the dental arches touch, the lips touch, except in subjects with protrusion of the lower jaw, with whom the lower lip is thrown in advance of the upper, the upper is apt to be short, and the teeth large. The mechanism of closing the mouth is here a painful process to witness, and the result, when accomplished, is, on the whole, not pleasing. Persons noted for their facial power not unfrequently have small lips. Sir Joshua Reynolds,\* in speaking of the actor Matthews, says, "He had no regular mouth, but spoke through a little hole in his cheek." The loss of teeth in the aged naturally increases the mobility of both lips, but particularly the lower. The upper lip sags inward, and the lower outward. When the mandible is raised, it pushes the upper lip slightly

---

\* Representative Actors, 110.



outward. An aged inmate of the Philadelphia Hospital possesses the knack of forcing the lower lip entirely over the upper, including in its ascent the tip of the nose. The protrusion of the lower lip is with some barbarous people thought a sufficiently beautiful feature to be artificially exaggerated by the insertion of pieces of wood and bone.

The labial borders of the lips, or the lips proper of common language, are of a red color in health, and of a brighter hue in children and females than in males. This coloration is due not so much to the presence of blood as to the muscular layer, which is here superficial. Luschka\* affirms that the surface of the lips in children becomes dry and of a brown color after death. It is, indeed, a sign of death of exact value.

Chapped lips consist in fissures through the epidermic lining of the lip. They are more common toward the middle of the lip than elsewhere. They are generally superficial, and of no surgical importance. Sappey† announces the hypothesis that this condition is often a predisposing cause to epithelial cancer. He finds cancer and the fissures only in the lower lip, and that in cases of cancer, a marked tendency to fissuring pre-exists for a long time.

The epithelial layer of the lip, although thin and delicate, may serve as a nidus for a distinct horny growth, as was witnessed by Dr. L. A. Sawyer.‡ The growth obtained a length of half an inch. Kölliker§ has found rudimentary hairs on the labial borders.

The arteries and veins are those of the region of expression. In cases of hemorrhage from the lip (which, since it occurs chiefly from the inner side, is difficult to control), it is recommended by McClellan|| to insert a pin, as after the operation for hare-lip.

We may here note the exceedingly rich nerve-supply of the two lips. The large, tassel-like dispersements of terminal branches of sensory nerves (the infra-orbital and mental) within the small areas of the lips are without parallel in the body. The lips are thus exquisitely-endowed monitors to the alimentary canal, to say nothing of their importance in any discussion of the theme suggested by what Hyrtl terms sexual polarity.

The mobility of the lower lip, already mentioned, is in part dependent on the connection between it, the chin, and the superficial tissues of the neck. When the lip is forcibly raised, the chin becomes corrugated, showing that here is a more or less fixed point; but at the side no corrugations occur, but the platysmus layer ascends to the lip,—a

\* Der Kopf, 1867, 305.

† Traité d'Anatomie, iv., 1873, 37.

‡ N. Y. Jour. of Medicine, 1851, 92.

§ Zeitschrift für wissenschaft. Zool., xi.

|| Surgery, 199.



small part only being inserted into the lower jaw. We will then have a line of *fixation* at the base of jaw, about the chin, and a line of *mobility* at the sides. The recognition of this fact is of great importance in plastic surgery. Dr. David Prince\* describes a fixed line which can be made after great destruction of normal structure by forming a curved incision across the neck far enough below the chin to allow pushing up of a flap from the neck, and determining the point of the desired immobility by scraping away the periosteum along the base of the jaw, so that the lower edge of the flap must adapt itself to the bone. It has also been determined that the success of a plastic operation *par glissement* is at times impaired by the immobile nature of the mucous layer. It is in consequence recommended that incisions about the lips and cheeks should be made from within perpendicular to the direction of the external ones. Great stress is laid upon incision of the mucous membrane in attempts to restore the lower lip after great loss of tissue from cauterization.

Dr. G. Buck,† of New York, divides the buccal mucous membrane along the line where it leaves the lower jaw, and severs the cheek-layer as far back as the last molar tooth, and even beyond it. All the subjacent coverings are then to be dissected from the periosteum, and the detachment continued on the same level below the edge of the jaw. This permits the two edges of the destroyed area to come together.

The lip is often involved in contractions from maxillary necrosis. The affected side is drawn up. This, fortunately, is remediable, as is shown in many results of operation. See in this connection a case recorded by T. Bryant.‡

#### THE REGION OF THE TONGUE.

This region is divided into (1) the *tongue*, and (2) the *alveo-lingual* groove.

(1) *The Tongue*.—The tongue is a symmetrical organ developed on either side of a median fibrous layer, which arises from the hyoid bone. In the majority of vertebrates, the tongue is in the main composed of the bony equivalent of this fibrous extension, which belongs to the hyoid apparatus, and is intruded thence between the halves of the inferior maxilla. In the higher animals only is there a marked accession of muscular fibers, constituting the familiar anatomical figure.

The tongue has, when released, an ovoidal form, slightly wider behind than in front, with a median groove—the *raphé*—extending along its anterior two-thirds, and answering in position to the central median septum.

---

\* American Practitioner, 1871, 225.

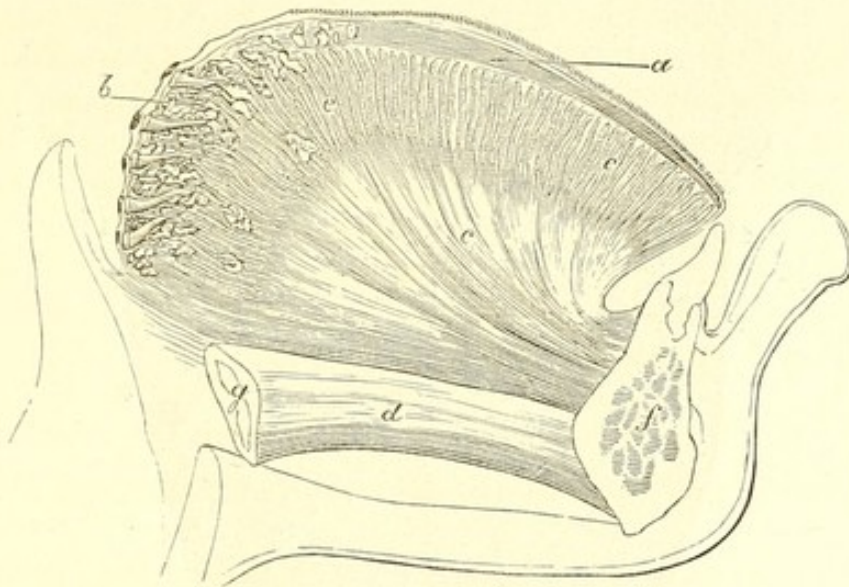
† Trans. Am. Med. Assoc., 1868, 377.

‡ Guy's Hosp. Rep., 1862, viii., N. S., 289.



The power possessed by the tongue to change its shape is remarkable, and almost defies analysis. A transverse section of the organ, when the organ is studied at rest, is more or less mushroom shaped,—the pedicle answering to the entering fibers of the *genio-hyo-glossus* muscle. The position assumed by the tongue when the lower jaw is elevated is as follows: the tip is raised to the level of the incisors, within whose curve it lies. The apical part of the dorsum rests on the pad of the roof of the mouth behind the incisors. The rest of the dorsum does not lie in contact with the hard palate, though it probably permits the soft palate to lie gently across the posterior part, and the uvula to rest in a slight median depression thereof. The anterior and lateral borders of the tongue are free, while the base and the greater part of the under surface are fixed. The under surface is smaller than the upper, and the structure of the base of the organ, while more capacious, is less compact than the anterior.

FIG. 33.—ANTERO-POSTERIOR SECTION IN MEDIAN LINE OF THE TONGUE.



*a*, cortical portion; *b*, glandular portion; *c*, genio-hyo-glossus muscle; *d*, genio-hyoid muscle; *e, e*, transverse lingual fibers divided vertically; *f*, inferior maxilla; *g*, hyoid bone.

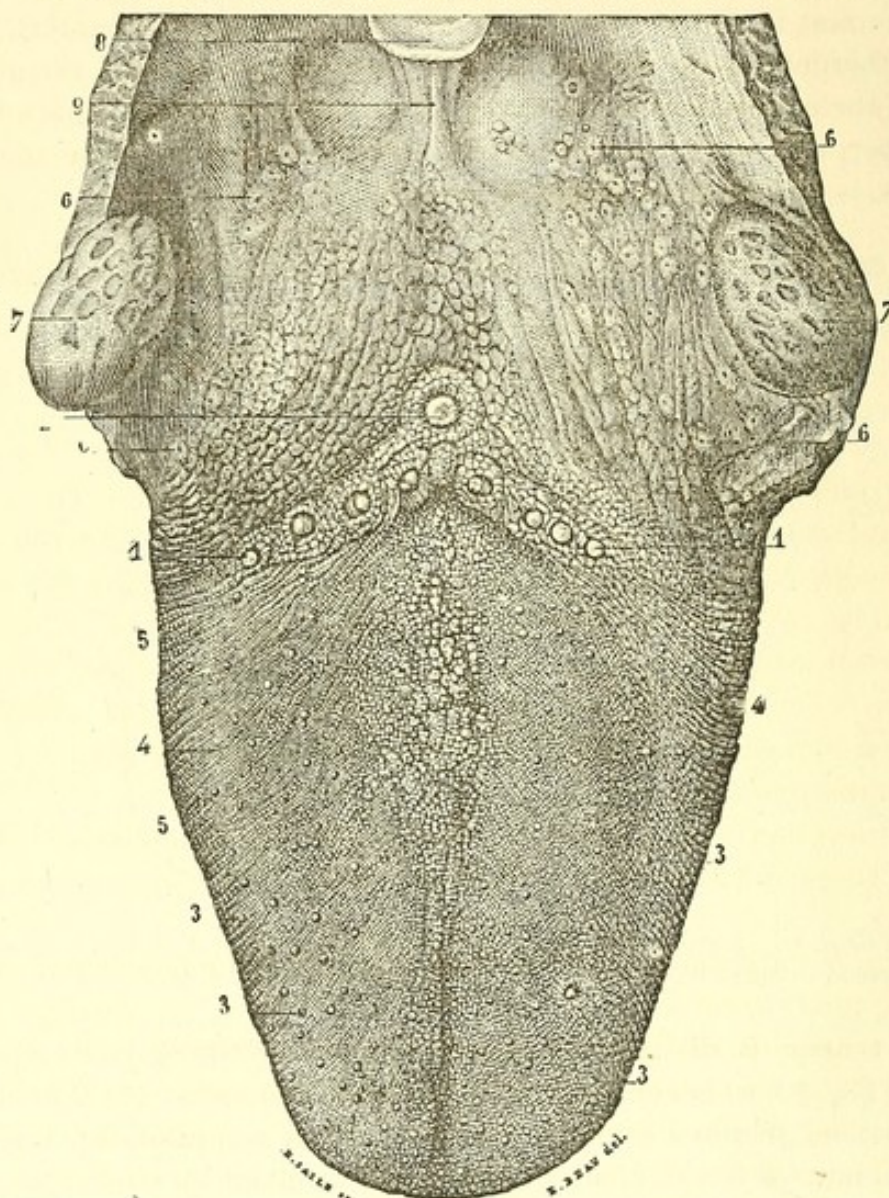
The tongue is divided into a *cortex* and *medullary portion*. The cortex (Fig. 33, *a*) is complete at the dorsum and sides. It is absent at the position of the muscular pedicle. It is composed of a special arrangement of fibers of distribution of the *palato-glossus* and *stylo-glossus* muscles from above, and the *genio-hyo-glossus* muscle beneath. At the point where these fibers are best seen, as at the anterior two-thirds, the cortex is also best developed; where they are sparsely seen, and some of them absent, as at the basal third, the cortex is but slightly expressed. It thus may be said to extend from the palato-glossal folds forward to the tip.



The medullary portion is all that part of the tongue within the embrace of the cortex. It is composed of loosely-packed muscular fibers of the *transverse* (Fig. 33, *b*) and the *vertical* set (Fig. 33, *e*). The interstices between them are occupied with fat, which is more abundant toward the base of the organ than elsewhere.

The *mucous membrane* as it is applied to the tongue is seen to correspond to the cortex. It presents some extraordinary modifications of structure, which will now be considered.

FIG. 34.—VIEW OF THE UPPER SURFACE OF THE TONGUE.



1, 2, V-like row of the vallate papillæ; 3, capitate papillæ; 4, 5, conical papillæ; 6, 6, floor of the inter-tonsillarspace, with numerous simple follicular glands; 7, tonsils; 8, summit of the epiglottis; 9, the middle glosso-epiglottic frænum, with depressions on each side bounded externally by the lateral fræna.

Unlike other mucous surfaces, the tongue possesses a fibrous investment over its dorsal surface which is analogous to the derm. It is



composed of fibrous laminæ, with some addition of elastic fibers. Beneath it is received a great number of ultimate muscular fibers, and arranged upon it are papillæ in every way representative of the papillæ of the skin. Covering the fibrous layer is the epithelial layer, composed of squamous cells, and so greatly modified in some respects as to recall the structure of hair rather than an ordinary outgrowth from a mucous surface.

This peculiar modification is more marked in the oral or anterior two-thirds of the organ than in the pharyngeal or posterior third, where the glandular element is exceedingly well developed. The glands at the beginning of the basal third are arranged in oblique lines directed outward and forward from a median line, but as they approach the epiglottis they are more irregularly distributed. The glands are, for the most part, of the racemose type, and extend thence but sparsely along the edges of the tongue; and, in a marked degree of development, a minute cluster is placed between the stylo-glossus and inferior lingual muscles beneath the tip of the tongue. The latter group, generally known as the glands of Nuhn, was well described before him by Blandin, and, according to Hyde Salter,\* were in reality discovered by Nuck in 1690.

*The Papillæ.*—The lingual papillæ are of two kinds,—the true skin papillæ, and those common to the fibrous investment. The latter are the most numerous, and are distributed everywhere. At the sides of the tongue, toward the palato-glossal fold, these papillæ are hemispherical or rounded tubercles, which arrange themselves in more or less vertical ridges. These gradually become interrupted and diminish as the tip of the tongue is reached. These, the simplest forms of papillæ, have been termed the *secondaries*, and are seen aiding in giving prominence to the *primaries*.

The true or primary papillæ have been variously described. They present three different kinds, viz., the *vallate*, the *capitate*, and the *conical*.

The *vallate* are the largest, and placed at the boundary between the oral and pharyngeal division of the dorsum. They are distinguished from other papillæ, as the name indicates, by being walled in by a prominent circle of secondary papillæ. They are arranged in two oblique lines directed forward and outward in such a way that the lines diverge. They vary in number from seven to twelve. A median papilla, larger than the others, is sometimes denominated the *foramen cæcum*. This may be absent or axially duplicated. A number of racemose glands may open in or about it.

The *capitate* papillæ are small and rounded, and scattered on the

---

\* Cyclop. of Anat. and Physiology, iv., part ii. p. 1122.



tongue without special regularity, faintly preserving the oblique direction behind, but slightly aggregated toward the tip. It is thought that within these chiefly reside the tactile sense of the tongue.

The *conical* papillæ are the most numerous of the three. They are arranged in lines parallel to those of the vallate papillæ, in the neighborhood of these structures, but gradually become more transverse as they approach the tip. They are covered with hair-like extensions of epithelial cells, hence the appellation often given them of the filiform papillæ. The fur of the tongue is due to changes in these accretions.

The *arteries* of the tongue are derived from the lingual branches of the external carotid. The vessels are remarkable for their size compared to the organ to which they are distributed, and for the limited communication between the branches of the right and left vessels. Hyrtl, indeed, demonstrates but two points of this anastomosis: one at the position of the vallate papillæ, and the other toward the tip. An insignificant superficial vessel lies along the line of the raphé, which would be the only vascular structure divided by a median incision upon the dorsum. The extreme vascularity of the tongue has been the occasion of frightful loss of blood when the vessels have been opened in the course of the sloughing of cancer, as well as in non-malignant ulcerations extending into the tongue from the throat.\* In that usually unnecessary operation of snipping the *linguæ frænum*, the *ranines*, by which name the abrupt terminal branches of the linguals are known, may be divided. Cruikshank is quoted in Bell's "Institutes of Surgery" as dividing the *frænum* in a child, whose mother, after some time, discovered it to be dead from loss of blood. An enormous coagulum was found in the child's stomach. Under guidance, operations on the tongue may be undertaken without fearing loss of blood; this feature being, in the estimation of Paget,† much overrated. It is certain, however, that in the early cases of partial excision of the tongue before the days of associated ligation, the patient sustained alarming loss by hemorrhage.

It is interesting in connection with the distribution of the lingual arteries to learn that unilateral glossitis is not uncommon. Dr. Graves‡ has recorded a typical instance of the kind, occurring in a medical student. The left half of the tongue was affected, and was so enlarged that the mouth could scarcely be closed, while the right side of the organ was in all respects normal.

The *veins* of the tongue accompany the arteries, and descend to join the internal jugular vein. The branches beneath the tongue are es-

---

\* Am Journ. of Med. Sci., 1st series, 26, 193.

† Med. Times and Gazette, Feb. 10th, 1866.

‡ Dublin Hosp. Reports, iv. 43.



pecially conspicuous when the tip is directed to the roof of the mouth. In injection of a solution of perchloride of iron into an epulis growing from the gum of the lower jaw, acute phlebitis of the superficial veins has been excited. The numerous instances of rapid serous infiltration about the supra-hyoid space can be accounted for only when we recall the course of the lingual veins. See in this connection a case by Mr. Holthouse.\*

*The Localization of Diseased Action.*—We divide this portion of our subject into four portions: (a) diseases confined to or appearing on the mucous or epithelial surface; (b) those appearing in the sub-mucous or muscular tissues; (c) diseases of the anterior two-thirds of the dorsum, as contrasted with the posterior third; (d) diseases as influenced by symmetry.

(a) *The diseases limited to the epithelial covering of the tongue.* These are analogous to or at least mimetic of conditions of the epithelium of the integument, such as *psoriasis*, *ichthyosis*, and *keloid*. The first-mentioned disease as witnessed in the tongue is popularly known as "bald tongue." According to Paget,† it is recognized by smooth patches, which are glossy and remarkable for the absence of the fur which may coat elsewhere the entire dorsal surface. It is commonly of a syphilitic origin.

The next-mentioned disease (ichthyosis) is a rarer manifestation. It consists of a thickening of the epithelium so as to form a white, skin-like layer presenting an uneven surface, which has been compared to a kid glove, wet leather, or a thin film of boiled white of egg. It is of wide extent. In a case reported by Hulke,‡ a man aged forty-three exhibited the disease, which first presented itself as a patch  $1\frac{1}{2}$ " long in the middle line of the tongue. A little less than six years after an operation for its removal, during which interval it had once recurred, epithelial cancer was developed. In a case of Paget's,§ a woman, aged forty-two, with a hereditary tendency to cancer, exhibited patches of ichthyosis on the right side of the tongue, involving the papillary layer only. Its duration before the appearance of epithelioma was about a year. Dr. Nelégan|| has noticed the same connection between ichthyosis and epithelioma in a well-nourished man with whom the inside of the cheek as well as the tongue were involved. The epithelioma was not developed until over five years from the appearance of the first disease. A somewhat similar case is recorded by T. W. Cooke.¶

\* Tr. Clin. Soc. Lond., ii. 140.

† Med. Times and Gaz., 1858, vol. xvii.

‡ Tr. Clin. Soc., ii. 1.

§ Ibid., iii. 88.

|| Dub. Quart. Journ. Med. Sci., Aug. 1862.

¶ Cancer and its Allies.



It would thus appear that of the above affections of the mucous covering of the tongue, one is an accompaniment of syphilis and the other a prodrome of cancer.

The single example of keloid of the tongue known to us is recorded by Mr. Sedgwick.\*

*The Fur.*—Coming clearly within the limits of this section is the consideration of the fur of the tongue. The physician finds in the varieties of this condition valuable symptoms of systemic disturbance. The surgeon in no less degree detects numbers of signs of local trouble. We will confine our remarks to the latter group of indications.

The fur is always due to an opacity of the cells of the filiform papillæ. According to Hyde Salter,† “it is most abundant where these papillæ are most plentiful, and it will be found, by closely inspecting a furred tongue, that the fungiform papillæ have undergone very little if any change.” While it is true that for local lesions the tongue is seldom acutely furred with that dense mat of white on which, as a witty writer has said, one could slide down-hill, it nevertheless often presents some striking features. The chief cause of a localized fur is to be sought for in the area of distribution of a nerve. Thus Hilton‡ has described a case of a female in which a fur was confined to the anterior two-thirds of the dorsum of one side, and held to be due to irritation of the second division of the fifth pair of nerves. The patient had had hemicrania for years. After death from acute myelitis and “spine-lesion,” a scrofulous deposit was found upon the convex portion of the Gasserian ganglion of the opposite side. The same writer mentions a local furring dependent upon an aching tooth. We have seen several cases of acute furring in which the tip of the tongue answering to the incisorial pad was always free.

The glossitis of scarlet fever presents a striking appearance, the result of the contrast seen between the thick, cream-like fur and the enlarged and reddened fungiform papillæ. The latter are compared by Hyde Salter§ to the achænia scattered on the surface of a strawberry.

*Papillary Hypertrophy.*—The vallate papillæ are often enlarged in strumous subjects, particularly in the negro, affected with scrofulous enlargement of the cervical and pharyngeal lymphatics. Exaggerations of the filiform papillæ take on a hair-like appearance. They have been rarely recognized in old debilitated patients. In a case recorded by Dr. Beer,|| however, the patient was a dyspeptic medical

\* Trans. Path. Soc. London, xii. 234.

† Loc. cit., 1161.

‡ Lectures on Rest and Pain. Lecture ix. p. 196.

§ Loc. cit., 1160.

|| Oesterreichische Med. Wochenschrift, July 16th, 1842.



student. True verrucæ, or warts of the tongue, are rare. Syphilitic condylomes are distinguished from other growths by presenting a pale whitish surface on a gradual and nearly level elevation.

*Dry tongue*, usually due to grave systemic disturbance, may have a purely mechanical origin, as in the case recorded by Dr. Bentley,\* in which it was symptomatic of nasal polypus. In a male, thirty-two years of age, a polypus in the right nasal chamber caused dryness of the tongue for a few lines on either side of the center, extending from the tip almost to the base. The patient kept his mouth habitually open. The dryness disappeared after removal of the polypus.

*Cancer*.—Since it has been generally accepted that cancer of the tongue is always of the epithelial variety, we find it beginning at the epithelial covering of the tongue. Hutchinson,† from a study of nineteen cases, determined lingual cancer to be acute in its character,—a feature which can be explained by the “succulent structure of the tongue, and the facilities thereby offered for growth by infiltration and for rapidity of absorption.” T. W. Cooke‡ concludes that perhaps the worst form of cancer is that which begins at the frænum. Its progress here is very rapid. The ulceration extends through the muscles which connect the tongue with the hyoid bone and inferior maxilla, and these being largely supplied with arteries, much hemorrhage ensues.

*Fissure*.—Fissure of the tongue, although generally correctly so denominated, is often covered throughout by epithelial cells, when it would appear to be simply hypertrophy of the papillæ defining the oblique lines. Especially is this the case at the sides toward the region of the vallate papillæ. When denuded at their bases, fissures are often the result of irritation from a sharp angle of a tooth, and in this condition may prove the exciting cause of cancerous deposition. Care should be taken not to confound the undenuded depression with fissure. It is recommended to stretch the tongue during examination. If the depression becomes unfolded and disappears by this manipulation, no fissure exists.§

(b) *Those diseases appearing in the submucous or muscular tissues.* This, although surgically an important subject, is restricted in localization to the *fibrous tumor*, *syphilitic gumma*, and the *tubercular deposit*. Fibrous tumor presents no anatomical feature of interest. *Syphilitic gumma*, according to Cooke,|| generally appears in the center of the organ, whilst cancer has its usual primary seat at one side. With

---

\* Med. Times and Gazette, vol. x., 1855, 212.

† Ibid., 1860, ii. 404.

‡ Loc. cit., 154.

§ The Tongue and its Diseases, W. Fairlie Clark, 1873, 150.

|| Loc. cit.



reference to that rare disease, *tubercular deposit*, we can confirm the statement of Paget,\* that it affects the lateral surfaces mainly.

(c) *The diseases of the anterior two-thirds of the dorsum as contrasted with the posterior third.*

The vallate papillæ divide the tongue into two natural regions, that in front receiving the lingual nerve, and that behind the glosso-pharyngeal. That in front is covered by a derm-like involucre closely held to the muscle; that behind is loosely covered with its thin, smooth mucous membrane; that in front lies within the mouth, and is almost without glands; that behind lies within the pharynx, and is rich in glands.

We have already seen that cancer begins at the anterior division of the tongue. Now, when the disease is wide-spread, it is observed that it tends to involve parts directly beneath its nidus, then only to pass beyond the vallate papillæ. The reason of this is made clear when we recall the disposition of the *lymphatics*. These are numerous on the dorsum of the tongue, and are especially so, according to Sappey, until the line of the vallate papillæ is reached, when they abruptly cease, and a few only pass thence to the pharyngeal portion. The bulk of them are known to form on either side a main vessel of descent, which passes vertically through the muscular structure, and joins its special gland near the anterior belly of the digastric muscle. It is not to be inferred from the above that malignant disease may not involve the pharyngeal region from in front, though its most conspicuous involvements are as stated. The following is an instance of the passage of diseased action beyond the usual barrier. Hilton† divided the lingual nerve for the relief of pain accompanying carcinoma of the tongue. The relief was permanent so far as the nerve was concerned; but when the disease invaded the area of the glosso-pharyngeal nerve the pain recurred.

The presence of large numbers of glands in the pharyngeal portion of the tongue would lead the student to infer that distinct glandular lesions would be often detected. These are, however, rare. And even in those examples of cystic disease which have been recorded, no mention is made by writers of the strictly local character our knowledge of anatomy would infer this disease to assume. It is, however, in every way likely that a cyst forming at the base of the tongue would find less resistance toward the fatty center of the "medulla" of the tongue than it would toward the pharyngeal contour,—a view which would harmonize with Salter's observation, that the branches of the follicle are often lodged in the parenchyma fully one-half to three-quarters of an inch from the orifice of the gland. That the glands at the basal third of the tongue are productive of a free secretion of thick mucus is evi-

---

\* Med. Times and Gazette, 1858.

† Proc. Medico-Chir. Soc., 1862.



dent. The following case is given in exemplification of this fact, and also to show how long sustained pressure can be borne in a locality noted for its resistance to slight intrusions. A male, aged sixty, had for three months secretion of abundance of tenacious mucus from the pharynx, with hacking cough and some dysphagia. He occasionally vomited after taking food. After many attempts to relieve the symptoms, the patient applied for relief to Sir James Paget, who extracted from the base of the pharynx (indeed, resting directly upon the base of the tongue) an upper set of artificial teeth.\* Fibrous tumors are of rare appearance, but tend to be developed toward the pharyngeal portion. Dr. W. Hunt, of Philadelphia, operated on a girl of sixteen years, the basal portion of whose tongue was entirely occupied by a large fibrous tumor. The patient died suddenly, on the third day.

*Inflammation.*—This in the tongue is rarely an idiopathic affection. It may follow the bite of a serpent or sting of an insect. It is remarkable for the rapidity and extent of the infiltration, a feature which is at once explained by our knowledge of the character of the medulla. The danger from pressure of the mass against the larynx demands free superficial incision. It has been happily said by Holme Coote,† that these incisions should be made exactly on the dorsum, “for œdema may so far involve only one side of the tongue as to cause the lower surface, which yields the more readily, to be turned directly upward. Mr. Wormald, in observing this condition, found that, upon the subsidence of the swelling, the incision made above gradually acquired a directly inferior position.”

The tongue is singularly free from liabilities of invasion of diseased action from other organs. The superficies of the face may be literally destroyed by cancer, the jaws involved, and yet the tongue will remain not only free from disease, but not even dried or furred. The palate and uvula may be destroyed by syphilitic disease, which will not on that account descend to the tongue; although in these cases the tongue will become dry.

*Abscess*, as may be expected, may occasionally form in the loose “medullary” tissue, and make little external manifestation. The “cortex” must be divided before the pus escapes. The so-called strumous ulcer of the tongue would appear to be simply the result of the breaking down of a diffused inflammation. It differs, therefore, says Paget,‡ from both syphilis and cancer, “by the ulceration being always preceded by distinct suppuration. The induration that accompanies or precedes the ulcer is never intense or well defined; it is rather a

---

\* Med. Times and Gazette, January 18, 1862, 59.

† Holmes's Sys. of Surg., iii. 901.

‡ Loc. cit.



toughness with diffuse enlargement." *Sloughing*, on the other hand, is almost unknown in syphilis, while it is a frequent attendant upon cancer in this situation. On the whole, notwithstanding the number of nerves and the size of the arteries supplying the tongue, destructive results of inflammation are singularly rare. Indeed, the organ is passive to many kinds of lesion. There is on record\* a curious example of the crown of the second molar tooth being lodged in the tongue thirty-two years. The patient had been a soldier in the Napoleonic wars, and had been wounded in the face. Hyrtl mentions somewhat similar cases where musket-balls have been so retained.

*Wounds* of the tongue would be of easy occurrence were the organ not so well protected. Hyrtl† has described an instance of severe wound of the tongue in a butcher-boy, who, while holding a knife edge inward between his teeth, was run against. In children who, by falling, or in epileptics, who wound the tongue with their teeth, it frequently becomes necessary to reunite the lips of the wound. This, owing to the extreme softness of the tissue, is exceedingly difficult to accomplish, particularly with the young. We have to our cost known what it is to place interrupted sutures in a wound of the tongue only to have them cut themselves out. Vincent‡ long ago pointed out the proper way to treat this lesion. He advises to keep the patient's tongue quiet by placing a bandage about the jaws. This places the tongue at rest between the sides of the lower jaw, the lips of the wound being thus adjusted by the lateral pressure.

The following cases are entirely exceptional.

(1) A boy, while sitting on the shaft of a wagon, was jerked off, and his face crushed by one of the wheels. He received a compound fracture of the inferior maxilla, and the edge of the bone, turning inwards, completely amputated the tongue at its base, with the exception of a few shreds of tissue.§

(2) A sailor, while smoking, fell. His pipe was driven into his tongue and broken; suppurative glossitis ensued, and, after extraction of the fragment of pipe-stem, almost instant death followed, by hemorrhage from the left internal carotid artery, which had been transfixed by the missile.||

*Errors of Nutrition.*—Hypertrophy of the tongue is one of the most marked tendencies of this organ. The condition may be congenital, as noted by Dr. Thomas Harris¶ in a lad of nineteen. The organ, in this case, measured six inches, and projected three inches from the mouth.

\* Amer. Journ. of Med. Sci., April, 1846, 503.

† Topog. Anatomie, i. 409.

‡ Obs. on Surgical Practice, 1847, 118.

§ Lancet, ii. 1864, 631.

|| Ibid., 1837.

¶ Am. Journ. Med. Sci., xx., old series, 15.



Such a mass must pull the hyoid apparatus upward and forward, and, by exerting constant pressure upon the alveoli of the incisor teeth, will push them forward.\*

Atrophy of the tongue, without pressure or lesion of the trunk of the hypoglossal nerve, is rare. Dupuytren's† famous case of paralysis of the left hypoglossal nerve with atrophy of the corresponding side of the organ, exhibited the feature which we are prepared to learn of being confined entirely to the oral division of the organ. Death ensued at the end of two years. At the autopsy, it was discovered that of a mass of hydatids lying in the cerebellar fossa, one had intruded itself into the anterior condyloid foramen and compressed the hypoglossal nerve. Paget‡ has reported a similar case of pressure of the nerve from a piece of dead bone near the anterior condyloid foramen. Removal of the fragment resulted in recovery.

We have recognized unilateral atrophy, the result of traumatic division of the hypoglossal nerve. A female, aged twenty years, had an abscess under the left side of the lower jaw. The physician employed at the time opened it, and in so doing must have divided the nerve; for, from that time, a deflection and atrophy of the corresponding half of the organ was observed. When seen twenty-five years afterward, the tongue was found deflected and atrophied. The affected side was fissured extensively transversely. W. Fairlie Clark§ has detailed a case in which a patient suffering from carcinoma of the breast exhibited atrophy of the right half of the tongue, confined to the anterior two-thirds of the organ.

The following is an example of unilateral paralysis followed by sloughing. A male, aged seventy-eight years, suffered from a neuralgic affection of the occiput. He at the same time complained of dysphagia, and excessive flow of saliva. By the eighteenth day the tongue became flabby, insensible, and began to mortify. By the thirty-first day, a line of demarkation was formed, which included the entire right half of the tongue and the tip of the left. The patient recovered.||

*The Alveolo-lingual Groove.*—When the tongue is at rest, there lies between it and the gum of the lower jaw a groove, which has a variable size, according to the position of the tongue. Beneath the tip of the tongue this space is incompletely divided by the lingual frænum. The base of the groove is distinguished by its whitish color, and has commonly upon its surfaces a vein whose thickest portion is directed from

---

\* For other cases, with bibliography, see Humphry, *Med.-Chir. Trans.*, xxxvi. 114.

† *Leçons Oral*, i. 493.

‡ *Trans. Clin. Soc.*, iii. 238.

§ *Med.-Chir. Trans.*, xxxvii., 1872, 91.

|| Dr. E. Ballard, *Med. Times and Gazette*, March, 1869, 296.



behind. Beneath it lies the mylo-hyoid muscle, which here, from its analogy with the buccinator and constrictor muscles, may be considered a submucous structure. The mucous membrane, however, is but loosely united to it. The groove is marked on either side by a fimbriated line answering to the position of the sublingual glands. Beneath the tongue on either side of the frænum is seen the opening of the duct of the submaxillary gland, which forms for itself a little elevation, which has been called the sublingual caruncle. The alveo-lingual groove is best developed in the negro.

Among the diseased conditions affecting the groove may be mentioned (1) those pressing upon it from without, as in the deformation following fibrous and other tumors; and (2) those arising from the base of the groove, either from the jaw or through pressure exerted from the supra-hyoid space upward. Conspicuous among the former are *foreign bodies* and *calculi* of the duct of Wharton. Of the first of these, pins incautiously held in the mouth have been known to slip head foremost into the duct, and require slitting of the parts to remove them. Calculi of the duct are occasionally met with, which from their peculiar position may give rise to symptoms of suffocation. Mr. Jessop\* mentions a case in a male, aged twenty-four, in which the calculi had been noticed in the mouth for a year. Suddenly a swelling made its appearance, which so rapidly increased in size as to form by the fourth day a mass as large as a hen's-egg in the alveolo-lingual groove. The patient suffered pain in the neck, and had difficulty in breathing and swallowing. Two calculi, each the size of a pea, were removed from the right submaxillary gland, when a gush of retained saliva followed, and the symptoms subsided.

The other conspicuous lesion is *cystic tumor*, to say nothing here of the *fatty tumor*, which is rare. Cystic tumor in this position has long had the reputation of being the result of obstruction of the duct of Wharton. But recent writers have more than suspected the validity of this claim. In 1854, Dr. C. D. Weber† definitely proved that the chief locality for cystic tumor is not in the duct of Wharton, but the synovial sac described by Fleishman in 1841,—lying close to the frænum on the outer side of the *genio-hyo-glossus* muscle, beneath the mucous membrane of the tongue. It would be well if the old term *ranula* as applied to these growths were discontinued. The word itself is an absurd one, and the condition expressed by it has been inextricably associated with a false pathology.

The pressure on the hyoid apparatus by means of a large cystic tumor is often sufficient to threaten apnœa. Bransby Cooper narrates

---

\* Br. Med. Journ., 1871, 120.

† Virchow's Archiv, Bd. vi. Heft 27.



a case where a prompt opening of the cyst was required to save the life of the patient.

Another form of cystic tumor distinct from the foregoing lies deeper than Fleishman's cyst, and in developing makes little or no impression within the alveolo-lingual groove; but instead, expands within the supra-hyoid space. This has been well described by Bell.\*

Later, Erichsen† recorded a case which has been reproduced in the work on surgery by the same author. These contained pultaceous, caseous matter, and were doubtless sebaceous cysts. Dr. James E. Garretson‡ operated upon a cyst similarly located, which contained a thin, jelly-like fluid. Bryant§ believes the sebaceous variety to be always congenital. In the two cases coming under his observation, both patients were under twenty years of age. The practice of opening cysts so located, by incision through the integument, has been generally discountenanced.

The sublingual fold is often extraordinarily enlarged as a complication of glossitis. In an instance of this mentioned by Dr. Davies,|| the sublingual mucous membrane was raised, as it were, into a second gum by serous infiltration.

W. Fairlie Clark¶ narrates a case in which the symmetrical enlargement of the sub-lingual folds, due to the irritation of a carious tooth, simulated cystic tumor. They formed a tumor of a horseshoe-shape round the free portion of the tongue.

### THE PHARYNX.

The pharynx is a muscular pouch or bag bounded posteriorly and laterally by the constrictor muscles, and superiorly by the base of the skull. It has no true anterior boundary—through its anterior limit—at the plane of the pterygo-maxillary ligament. The parts in front of this ligament constitute the oral region,—bounded laterally by the buccinator muscles,—the parts behind it lie within the pharynx. It is thus seen that the palate is within the pharynx.

The pharynx is widest at the line of the production of the hard palate backwards; it is narrowest below at the cricoid cartilage. It communicates with the mouth and nose in front, the larynx and œsophagus below, and the Eustachian tubes at the sides. Behind the latter is a depression called the fossa of Rosenmüller.

\* Principles of Surgery.

† Lancet, 1856, ii. 619, where two by Fergusson are also mentioned.

‡ Diseases of Mouth, Jaws, etc.

§ Med. Times and Gaz., 1860.

|| Surgery, 242.

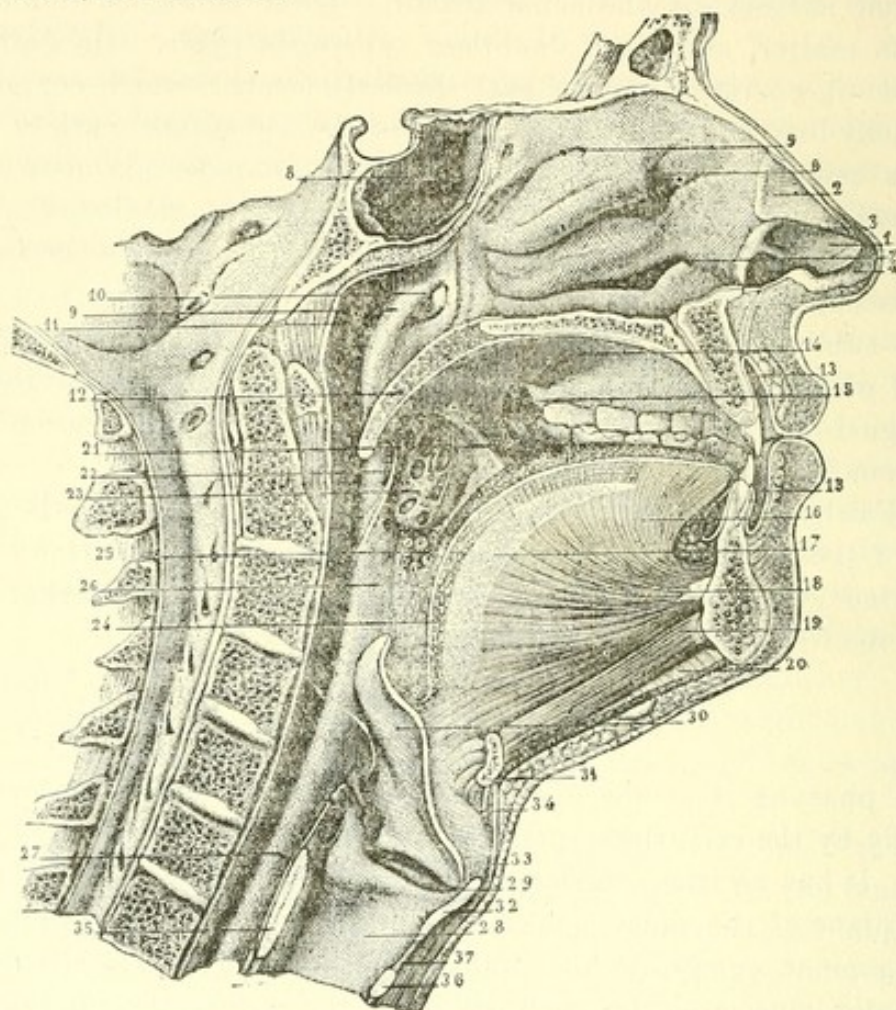
¶ Loc. cit., 220.



(1) *General remarks on the pharynx as inspected in the living subject.*

The *soft palate*, while within the pharynx, is so intimately involved in important functions that a separate statement concerning it is neces-

FIG. 35.—VERTICAL SECTION OF THE FACE AND NECK, THROUGH THE MEDIAN LINE ANTERO-POSTERIORLY, EXPOSING TO VIEW THE NOSE, MOUTH, PHARYNX, AND LARYNX.



1, oval cartilage of the left nostril; 2, triangular cartilage; 3, line of separation between the two; 4, prolongation of the oval cartilage along the column of the nose; 5, superior meatus of the nose; 6, middle meatus; 7, inferior meatus; 8, sphenoidal sinus; 9, posterior part of the left nasal cavity, communicating with the pharynx; 10, orifice of the Eustachian tube; 11, upper extremity of the pharynx; 12, soft palate, ending below in the uvula; 13, interval of the mouth between the lips and jaws; 14, roof of the mouth, or hard palate; 15, communication of the cavity of the mouth with the interval between the jaws and cheek; 16, tongue; 17, fibrous partition in the median line of the latter; 18, genio-glossal muscle; 19, genio-hyoid muscle; 20, mylo-hyoid muscle; 21, palato-glossal fold; 22, palato-pharyngeal fold; 23, tonsil; 24, base of tongue; 25, infra-tonsillar glands; 26, 27, pharynx; 28, cavity of the larynx; 29, ventricle of the larynx; 30, epiglottis; 31, hyoid bone; 32, 33, thyroid cartilage; 34, thyro-hyoid membrane; 35, 36, cricoid cartilage; 37, vocal membrane.

sary. The soft palate, as defined long ago by Cuvier, is a musculo-membranous valve suspended to the posterior border of the palatal



ledge, and elevated toward the posterior nares at the moment of the passage of the food from the mouth.

The soft palate presents for examination two surfaces: antero-inferior (glandular), presenting toward the oral cavity; the second, postero-superior, within the naso-pharynx.

The valve-like function of the soft palate is performed as follows: The *levator-palati* muscles,—power, short,—pull it upward and backward.\* This action is the most important feature to study in the soft palate. The muscles are at all times sufficiently pronounced to project into the pharynx as a pair of thick pillars covered with a delicate red mucous membrane. These pillars may be called the *salpingo-palatal* folds. They extend from in front of the orifice of the Eustachian tube downwards and inwards. They are always conspicuous objects in the image of the rhinal mirror, and in conditions of turgescence may obscure the view of the posterior nares. In the introduction of the Eustachian catheter, the involuntary contraction of these muscles may be sensibly felt on the shaft of the instrument.

The muscles acting upon the soft palate from beneath are much less significant than the foregoing, though forming conspicuous folds during the oro-pharyngeal inspection. These folds are usually known under the names of the half arches of the palate. We believe a decided advantage may accrue by ignoring this name, and substituting for the so-called anterior half arch the name *palato-glossal* fold, and for the posterior half arch the name *palato-pharyngeal* fold,—the muscle beneath each suggesting the name.

These folds can be best studied when the soft palate is at rest, as in expiration. It is now held in its position (obliquely downwards and backwards) by two pairs of tractors, the *palato-glossal* and the *palato-pharyngeal* muscles. A marked change occurs in the appearance of the folds in inspiration, or in a greater degree in the first stage of deglutition. Studying this process at the point when the *levator-palatal* muscles have already firmly raised the palate, it is observed that the *palato-pharyngeal* are now thrown into a nearly vertical position along the postero-lateral border of the pharynx. The *palato-pharyngeal* muscles answering to these folds by contracting, initiate the second stage of deglutition by elevating the pharynx toward the fixed point.

It will be seen that the chief use of this muscle is to elevate the lower pharynx, as the *levator palati* is to elevate the soft palate. Indeed, the

---

\* The upward and backward traction of these muscles causes the great breadth of the congenital fissure of the soft palate, and, as is well known, the muscles are divided prior to the performance of staphyloraphy. It has occurred to us that in early infancy, when an attempt at staphyloraphy would be unjustifiable, much could be done to preserve the soft palate in good condition (*i.e.* prevent widening of the fissure) by one or more thorough divisions of the muscles in question.



only depressors of the palate are the small *palato-glossal* muscles, whose folds are placed well in advance of the palato-pharyngeal.

The purposes of the soft palate require extensive muscular attachments, extending along the entire length of the pharynx,—a nasopharyngeal tractor in the *levator-palatal*, an oro-pharyngeal tractor in the *palato-pharyngeal*, and an oral tractor in the *palato-glossal* muscle.

The uvula is an appendage apparently to the median line of the posterior border of the soft palate. It exists only in man and monkeys. It is a symmetrical teat-like organ; containing, as in a finger-stall, a pair of minute muscles, the so-called *azygos uvulæ*. At the close of the second stage of deglutition the uvula contracts, and becomes in consequence transversely wrinkled, most probably to plug up the opening which otherwise might exist during the elevation of the palate between the posterior margin of the soft palate and the posterior wall of the pharynx.

In our remarks on the region before us the following terms will be used:

The portion of the pharynx below the soft palate is termed the *oropharynx*, as that portion above the soft palate is the *nasopharynx*. The space between the palato-glossal folds laterally and the uvula superiorly and the dorsum of the tongue inferiorly is the *oro-pharyngeal orifice*. The space between the palato-pharyngeal folds and the uvula is the *nasopharyngeal orifice*. The space between the *palato-glossal* and *palato-pharyngeal* folds on either side is the *tonsillar space*. The space between the tonsillars is the *inter-tonsillar space*.

All these technical terms are descriptive of planes across the axis of the mucous tract, excepting the tonsillar spaces, which are lateral.

It will be noticed that the word *fauces* finds no place in this terminology. Nothing but confusion can arise from the use of a term such as this, and it is better in consequence to avoid it.\*

---

\* It would be a thankless task to examine the synonymy of the word *fauces*, as employed by teachers and practitioners. It may fairly be stated that the term has been applied to almost every part of the mucous tract lying between the palatal bone and the œsophagus. A very common belief is entertained, that the *fauces* is that part of the pharynx and soft palate, which can be seen when the mouth is open,—a conception justifying the student, who in response to the question, "Where is the *fauces*?" placed his fore-finger far within his open mouth and "guessed it was somewhere in there."

We learn from Innes' "Description of the Human Muscles," a book which embodies the teachings of the elder Monroe, that in 1777,—the date of the publication of the book,—the Edinburgh plan of teaching was to consider the *fauces* the same as the *nasopharynx*, restricting the *pharynx* to the lower part of the *oropharynx*.

The passage is as follows: "The common opening between the anterior arch may be termed *fauces*, or *top of the throat*, from which there are six passages, viz.:



The mucous membrane lining the pharynx is in close union with the base of the skull and the orifices of the Eustachian tubes above, and on the posterior surface of the cricoid cartilage below. Along the posterior wall the membrane, on the other hand, is very loose, and permits a quantity of exceedingly delicate connective tissue to lie between. In front, the mucous membrane is continuous with the nasal passages and mouth, presenting features distinguishing the membrane in these localities.

Racemose glands are conspicuously developed on the anterior aspect of the soft palate, and, in a less degree, upon the posterior pharyngeal wall. The closed glands are met with on the roof of the pharynx and at its postero-superior junction (pharyngeal tonsil). The most remarkable example of aggregation of bodies of a closed-gland type are the *tonsils*. Each of these two organs is of an almond shape, somewhat flattened on the outer fixed surface but convex on the inner. Between the tonsil and the base of the tongue a number of small bodies of the same character are seen, which may be termed the *infra-tonsillar* glands. The *fovea ovalis* is a term proposed by Tourtual\* to express the non-glandular space existing between the lower border of the tonsil and first infra-tonsillar gland.

Glands are more abundant in the naso-pharynx than in the oropharynx.

(2) *The Pharynx as studied by Dissection.*

The constrictor muscles form (with aid derived from the pharyngeal aponeurosis) the frame-work of the pharynx. They form the lateral and posterior walls of the chamber, and are three in number: the *superior*, *middle*, and *inferior*. Without entering into an elaborate description of these muscles, which would be foreign to our object, we may briefly anticipate that they are arranged in a lamelliform manner to one another,—the inferior being the most exposed from behind and overlapping the middle, which in turn covers in part the superior.

The *superior constrictor* arises from the hamular process of the sphenoid bone, the pterygo-maxillary ligament, and by a small slip from both superior and inferior maxilla. Hyrtl in addition gives a slip from the side of the tongue as well. The muscle is inserted into the raphé upon the posterior surface of the pharynx. The upper free border of

---

two upwards, being one to each nostril; two at the sides, or one to each ear, called the Eustachian tubes; two downwards: the anterior is the passage through the *glottis* and *larynx* into the *trachea*, which terminates in the lungs; the posterior is the largest, named the *pharynx*, or *top of the œsophagus*, which leads to the stomach."

\* Neue Untersuchungen über den Bau des Menschlichen Schlund, etc., 1846.



the muscle hangs like a curtain-edge between its outer and posterior points of attachment. The function of this muscle is obscurely understood. It must assist the action of the other constrictors, according to the law that of a natural group of muscles the one nearest the source of nerve-supply will contract in advance of others more remotely placed. It may also aid the purchase of the buccinator in making tense the pterygo-maxillary ligament.

The *middle constrictor* arises by two fascicles,—from the greater and lesser horns of the hyoid bone. Its fibers effect a fan-like dispersion to be inserted in the raphé.

The *inferior constrictor* arises from the sides of the thyroid and cricoid cartilages, whence its fibers pass to be inserted in the raphé. These two muscles are the most effective of the constrictors, and are efficient by involuntary contraction in forcing the bolus of food through the narrow orifice of the œsophagus.

The pharyngeal aponeurosis is a firm layer of fibrous tissue placed between the muscular and mucous layers. It arises from the pharyngeal spine of the occipital bone, and is inserted into the petrous portion of the temporal bone where it is lost in the fibro-cartilage occupying the middle lacerated foramen. It seems to strengthen the pharynx at this point, but gradually diminishes as it passes downward, and is not discernible beyond the pharyngeal limits.

A second fibrous layer belonging to this region is the palatal aponeurosis. This structure lies intermediate to the posterior free edge of the hard palate and the free portion of the soft palate. It is the fibrous part of this fibro-muscular valve. It is composed of delicate glistening fibers extending from about the hamular process of the sphenoid bone, and expands from this point as a firm sheet of membrane. It receives at its side the tendon of the so-called *tensor-palati* muscle.\*

The arterial supply of the pharynx is derived from inconstant twigs from branches of the external carotid, notably the ascending pharyngeal and pharyngeal branch of the facial. The veins are tributary to the facial trunks anteriorly, and to the internal jugular vein and post-cervical trunks posteriorly. Hence cupping at the nape of the neck may determine blood from the pharynx.

The nerves of the pharynx are derived from the glosso-pharyngeal and pneumogastric nerves, with branches from the sphenomaxillary ganglion.

(3) *Localization of Diseased Action.*—Our remarks under this head

---

\* Since this muscle, more properly termed the *spheno-salpingo staphylinus*, has been shown by L. Mayer to be part of the same stock with the *tensor tympani*, it must be removed from the pharyngeal group and placed with the muscles of the mucous tract of the ear.



will be divided into—(a) oro-pharynx, (b) naso-pharynx, (c) the soft palate.

(a) *The Oro-Pharynx*.—The portion of the pharynx seen through the oro-pharyngeal orifice is often the seat of diseased action more or less distinct from the other divisions. This can be explained as follows: The palato-pharyngeal muscles take their origin here, and in contraction are seen exerting a powerful action on the lower half and posterior wall of the pharynx. It will be remembered that at the time of this contraction the soft palate is elevated, and the oro-pharynx, therefore, cut off from the naso-pharynx.

Now, in chronic pharyngitis there is often seen submucous infiltration about these folds, which often assume such proportions as to lead the incautious to mistake them for engorged tonsils. By the constant teasing and pinching that the space between the two muscles, when chronically inflamed, must be continually subjected to, sloughing—at this point extending through the entire thickness of the pharynx—is not unfrequently seen.

The palato-glossal fold is often pushed forward by an engorged tonsil, which may from the front view be more or less covered. As a rule, however, the fold is not adherent to the tonsil, but permits a probe to pass between with facility. But at times the fold becomes fixed, and may require division to overcome a distressing strangulation of the tonsil.

Persistent inflammation often lingers about this fold after all signs of angina may have elsewhere disappeared. The tonsil holds important relations both with deglutition and the mucous tract of the ear. With the former it is observed that towards the close of the second act of deglutition it is drawn well back toward the vertebral column. The infra-tonsillar glands, when engorged, may project against the tongue, and maintain marked irritation, necessitating their excision.

The pressure upward toward the naso-pharynx, however, is often exerted most disastrously. Here, by impairing the tonicity of the muscles about the Eustachian tube, particularly it is thought by exciting irregular action in all the muscles of the otic group, which are supplied by branches of the otic ganglion, deafness is a frequent sequela. When the tonsil grows inward and tends to obliterate the inter-tonsillar space, this danger is averted. It is not, therefore, the fact of engorgement so much as the direction of the extension of the tonsillar mass that may prove mischievous.

After excision, œdema of both sides of the neck has been known to supervene,\* which, fortunately, in the instances recorded subsided by the fifth day.

---

\* Dr. Williams, Amer. Jour. of Med. Sci., July, 1853, 225.



(b) The naso-pharynx can be studied only by the rhinal mirror. The chief influences exerted by diseased action as distinct from those in other portions of the region are due either to the muco-perichondrium characterizing the mucous tissue about the Eustachian tube and at the roof of the pharynx, or to the peculiar tendency of its glandular secretion.

To the first-mentioned cause is to be assigned the obstinacy of inflammation here, and to the second the extraordinary engorgement of the pharyngeal tonsil, and particularly the growth (elaborately described by Meyer\*) pendent from the roof of the pharynx, sometimes to almost entirely occupy the naso-pharyngeal space. We have had several opportunities of confirming Dr. Echeveria's† observation, that women with irritable ovaries are liable to a peculiar, obstinate inflammation of the naso-pharynx.

(c) The *soft palate*, as already observed, must follow in many respects the tendencies of the pharynx within which it lies. If the tone of one is impaired, the other suffers. In inflammation both are commonly involved. The depth of the glandular layer on the anterior surface of the soft palate prevents any deep flush attending turgescence, unless the type of disease is severe. The superficial veins, however, upon the palate are often conspicuous, and may be arranged as follows :

(1) A group of radiated venules situated on either side of the raphé of the soft palate, at a point midway between a hypothetical line connecting the prominence of the hamular processes and the base of the uvula. Branches from this point running parallel with the raphé may occasionally be united, thus making an H-shaped figure.

(2) A small vein crossing the raphé at a point a little in front of the preceding, and probably corresponding to the limit of the palatal aponeurosis.

(3) Another small vein is often seen at a point answering to the band of fibers belonging to the palatal portion of the palato-glossus muscle, where it joins its fellow across the median line.

When the palate is moderately elevated, the outer border of the elevating surface corresponds almost exactly to the second raphéal vein. The lateral contraction is that induced by the palato-pharyngeals as announced at the point corresponding to the *first* vein. It will follow that, the position of the vein given, the lines of flexion of the soft palate may be determined. It is instructive in studying diseased action of the soft palate that ulcerated patches are occasionally seen at points on the raphé answering with exactness to the above points of flexion.‡

\* For an English translation of Meyer's original memoir, see Med.-Chir. Trans., 1870, 191.

† N. Y. Med. Journal, 1865.

‡ Remarks on Soft Palate, etc., nob., Trans. Am. Med. Assoc., 1872, 555.



The liability of ulceration to appear on the posterior surface of the soft palate is acknowledged. It will be seen that every act of elevation of the palate will bring the ulcer in contact with the posterior pharyngeal wall. This explains the cases of stricture or atresia of the naso-pharyngeal orifice due to syphilitic angina.\*

Fibrous tumor of the soft palate is of unfrequent occurrence. Mr. Kelbourne King† has described a case observed in a man twenty-eight years of age. The tumor had been growing for three months. It was situated on the left side, and entirely filled the oro-pharyngeal orifice. It projected upward into the naso-pharynx and thence into the nasal chamber. It also grew backward into the oro-pharynx, nearly filling it. The growth was excised, but the patient died on the sixth day of erysipelas.

Hypertrophy of the papillæ on the soft palate has been observed by Andrew Clark.‡ Nitric acid was successfully employed in its removal.

Hypertrophy of the glands was described by Nélaton as long ago as 1847.§ It is of slow growth, and requires from five to fourteen years to develop to obstructive size. "The mass may be contained in a separate compartment, circumscribed, distinctly limited, spheroidal, and only very slightly connected with the adjacent parts, so that when its capsule is excised it may be easily enucleated with the finger." The protrusile tumors sometimes described as "flat polypoid growths" are probably examples of glandular hypertrophy.

Carcinoma of the soft palate is always medullary. It may begin something after the same method adopted by lingual cancer, viz., in first infiltrating the sub-epithelial cells. In a case recorded,|| the disease appeared as a thickened spot. In another case, narrated by Birkett,¶ a so-called polypus of the parts, in a man aged thirty-four, was excised, when cancerous infiltration ensued, and death occurred nine months after the first appearance of the polypus.

Prof. Joseph Pancoast\*\* has removed a medullary cancer, the size of an egg, from the soft palate. It had been twice operated upon.

*Post-pharyngeal Abscess.*—Cognate to our theme is the collection of pus behind the pharynx, viz., in the connective tissue between the pharynx and the vertebral column. The pus in this locality pushes the pharynx forward, with consequent impending aphagia and apnoea. Under some conditions the pus gravitates and causes a deep collection of pus to form at the side of the neck, as observed in a typical case by Hilton. Post-pharyngeal abscess is at times caused by strumous caries

\* For a well-reported case with dissection, see Wm. Turner, Edin. Med. Journ., 1860, lv. 612.

† Lancet, 1871, 264.

‡ Lond. Hosp. Reports, 1864, 209.

§ See Syd. Retrospect, 1862, 299.

|| Med. Times and Gazette, 1859.

¶ Tr. Path. Soc. London, 1860, xl. 233.

\*\* Med. and Surg. Rep., 1861, 248.



of the cervical vertebræ. Generally, however, it arises from an intense sub-pharyngeal infiltration, or from inflammation of the mucous surface.

#### THE SPHENO-MAXILLARY REGION.

The posterior central portion of the facial region is united to the brain-case through the ethmoido-sphenoidal junction, and the vomero-sphenoidal, the palato-sphenoidal, the maxillo-ptyergoid, and the palato-ptyergoid sutures. The space between these points of union is a very irregular one, and has been called the sphenomaxillary fossa or space. From a structural point of view, this space is of great importance. In its surgical relations it has little which is not entertained in common with the zygomatic and pterygoid spaces; so that we have thought best to include it within the large irregular area,—the sphenomaxillary region.

This region is imperfectly defined in the skeleton. Its limits cannot be given by means of the hard parts alone. In a general way, it may be said to be that space intervening between the cranium and the face in front, the under surface of the greater wings of the sphenoid bone, the squamous portion of the temporal bone, and the inner aspect of the ascending ramus of the lower jaw, at the side. Within it are received the pterygoid muscles, the trunk of the internal maxillary artery, the maxillary nerves; while it is in relation, externally, with the articulation of the lower jaw.

When the skull is placed upon its side, and the lower jaw is removed, a good view of the superior and anterior surfaces is obtained. We then notice a *superior* surface bounded by the glenoid cavity, the small portion of the squamous portion in advance of it, the under surface of the great wing of the sphenoid bone. It is crossed from within outward by the squamo-sphenoidal suture. The *anterior* border is the posterior edge of the sphenomaxillary, and the pterygo-maxillary fissure and the corresponding surface to the tuberosity of the superior maxilla. The *posterior* border is the squamo-tympanic suture. The *internal* border is the sphenotympanic suture, the Eustachian tube, and the outer edge of the scaphoid fossa of the sphenoid bone.

The *external* border is the pterygoid ridge, and a line extending thence backward to the articular eminence and the post-glenoid tubercle.

When the lower jaw and its chief elevator, the temporal muscle, are in position (the way in which the student must in practice restore it), the external surface of the region is incomplete at the sigmoid notch,—a deficiency made good by the masseter muscle lying over its outer side.

The internal surface is complicated by the direction of the internal pterygoid muscle, and the inferior surface answers to the insertion of this muscle.



The speno-maxillary region yields the orifices of the round, pterygoid, oval, speno-palatine, and spinous foramina, and the pterygo-maxillary and speno-maxillary fissures. It communicates with the nose through the speno-palatine foramen, with the orbit through the speno-maxillary fissure, and with the temporal fossa.

The region presents for examination three fossæ: the speno-maxillary, the zygomatic, and the pterygoid.

The first of these—the speno-maxillary—need alone take our attention here. It is bounded posteriorly by the anterior surface of the root of the great wing of the sphenoid bone, the anterior aspect of the pterygoid process toward its base, and anteriorly, by the orbital process of the palatal bone and the tuberosity of the superior maxilla. It is bounded internally by the vertical plate of the palatal bone, and is conspicuously marked by the speno-palatine foramen. Externally it communicates with the zygomatic fossa through the pterygo-maxillary fissure; and superiorly, with the orbit through the speno-maxillary fissure. We have on several occasions mentioned tumors encroaching within the speno-maxillary fossa, and need not now repeat our observations. For our present purpose it will suffice to mention a very remarkable case recorded by Langenbeck,\* of which the following is an abstract:

A boy, aged about fifteen years, suffered at thirteen with occlusion of the left side of the nose. About eighteen months afterward the left cheek and eye began to protrude, and the sight was soon lost. No tumor was visible from either nose or mouth, but in the middle of the left palatine process was a soft elastic swelling, and a firm lobulated tumor could be felt in the left choana, with displacement of the septum to the right. An additional mass of small size could be felt externally between the masseter muscle and the upper jaw, causing slight prominence of the left cheek, and fullness in the lower part of the left temporal fossa, and prominence of the left malar bone. Langenbeck diagnosed a fibroid tumor of the speno-maxillary fossa,† growing inward through the speno-palatine foramen into the naso-pharynx, extending outward, traversing the entire speno-maxillary region, and protruding between the tuberosity of the superior maxilla and the masseter muscle. The procedure original with Langenbeck—the osteoplastic operation, which consists in separating the halves of the face, removing the tumor, and restoring the parts to their normal relations—was successfully essayed. The tumor, of the size of a fowl's egg, was

\* For a transcript of Langenbeck's memoir (Deutsche Klinik, 1861), see Med. Times and Gazette, 1861.

† The account in the journal above quoted says *pterygo-palatine fossa*. This we venture to discard. It is included within the speno-maxillary fossa of our text.



found in the locality previously indicated by Langenbeck. The sphenopalatine foramen and the sphenomaxillary fossa were enlarged to three times their normal size.

### THE SUPRA-HYOID REGION.

This region, usually placed with the neck, has so many physiological relations with the face,—thus, for example, its muscles affect the position of the lower jaw and tongue,—that it is convenient to include it for the nonce within a group of studies of the facial region. It need be here lightly touched, however, as one in painting a miniature treats details less elaborately the farther he withdraws from the features.

The region before us is in brief the space extending from the hyoid bone to the lower jaw. According to Luschka, its lateral limits between the ends of the greater horns of the hyoid bone and the lower jaw are not vertical but inclined, and answer pretty nearly to the line of the stylo-hyoid muscle. The region is naturally best defined in lean persons, and those with large inferior maxillæ. In the aged the platysma-myoid muscle throws the skin toward the chin into vertical folds, which are often conspicuous. Beneath the skin is a layer of fat, and beneath it in turn is the muscular group, composed as follows:

1st. The anterior belly of the digastric muscle lying upon the mylo-hyoid muscle, and ascending from the dense aponeurotic tissue above the greater cornu toward the chin.

2d. The mylo-hyoid muscles, stretching, in reality as one muscle, from side to side.

3d. The genio-hyoid, a closely approximated pair of cordiform bundles, passing between the points named.

4th. The genio-hyo-glossus muscles, extending forward from the hyoid bone to the chin, and backward along the entire length of the tongue.

The deep fascia of this space is well defined, and remarkable as it approaches the region of the angle of the jaw for sending a thin layer backward toward the insertion of the internal pterygoid muscle, and which serves to separate the bed of the parotid from that of the submaxillary gland. This partition is pierced by the facial artery, the stylo-glossus muscle, and lower down by the glosso-pharyngeal nerve. In addition to this the fascia nearly envelops the submaxillary gland, and in consequence fixes it, so that enlargements of this body are not mobile, thus distinguishing them from engorged conditions of the overlying submaxillary lymphatic gland.

The position of the head will determine the relations of the submaxillary salivary gland. When, for example, the head is erect, the gland is nearly concealed behind the jaw; but when the head is thrown



back, the gland assumes cervical relations, and is for the most part superficial.

In our description of the lower jaw it will be remembered that it was stated that the inner side of the horizontal portion below the oblique line belongs to the neck. Now, the gland in question lies below this line, and has all its surgical relations with the neck, affecting the alveolo-lingual groove by pressure from below only.

In the same way the teeth, which at first sight are above the line, and, therefore, oral in their relations, nevertheless affect the relations of the supra-hyoid space by involvements originating above.

It is particularly the molar teeth whose roots may involve this space, since they approach more nearly the inner compact layer of the horizontal portion of the jaw than do the other teeth. Cases are on record in which a periodontitis has excited a secondary (maxillary) periostitis at a point opposite thereto. A striking example of the danger attending the announcement of such a complication will appear in the following history: The case came under our own observation. A young man in whom the roots of a lower wisdom-tooth had been prematurely filled, was attacked with acute periodontitis, ostitis, and maxillary periostitis as above described. This was sufficiently severe to excite inflammation in the loose connective tissue between the mylo-hyoid muscle and the jaw. An abscess followed here, and the pus gravitated to form a collection about the hyoid bone, and from that point passed upward upon the face along the line of the facial artery. The abscess in addition pressed directly upward against the floor of the mouth, and caused unilateral glossitis, from the mechanical effects of which upon the organs of respiration the patient died. The duration of the extra-maxillary complication was but four days.

#### THE NOMENCLATURE OF THE TEETH.

We propose as a concluding theme to invite attention to the arrangement of the cusps of the teeth, and hope thereby to correct what we believe to be erroneous opinions hitherto held respecting them. So far as we know, the method suggested by the principles of evolution has never been applied to the study of teeth in a single dental formula. It is probably owing to this fact that the value of observations upon the variations of the tooth-form has been underrated.

We have thought it best to first state our impressions in the shape of propositions, and after so doing describe briefly a few examples of teeth illustrating them.

(1) Since the cusps exist before the roots, the latter may be said to be conformed to the cusps. So that to every cusp there is a tendency to form a distinct root. It is best, therefore, to study teeth by their cusps.



(2) A tendency exists in all cusps to assume the conical form, which is modified by the presence of one or more rounded eminences,—generally from the palatal surface near the neck. These may be inconspicuous, of moderate size, or pronounced. The inflections between the conical crown and the eminence just named are sufficient to describe every possible modification of form.

(3) Since in the carnivorous and insectivorous quadrupeds we often have present a ridge-like form below the cutting surface called the *cingulum*, we are led to accept the eminence in question as having the same value in kind with it, but exhibited as a rudiment, and would propose for it the term *cingule*.

(4) Thus prepared, we would say, in applying in practice the above proposition, that an incisor and a canine tooth are composed respectively of one cusp and a small cingule; that a bicuspid is composed of a cusp and a large cingule, which participates in forming the triturating surface; that a molar is composed of three cusps and a cingule, which in the lower teeth becomes co-equal to the cusps, but in the upper is smaller, and is imperfectly used in grinding.

(5) That a true development occurs from the canine and incisor series toward the molar, by means of which the cingule of the canine becomes the cusp of the bicuspid; that should a new cingule be developed from the bicuspid it becomes in the molar the third cusp; and that should the molar possess more than four tubercles, three of them will be cusps, the remainder will be cingules.

(6) The peculiarities of the wisdom-teeth are best explained by the multiplication of cingules with corresponding repression of the cusps (notably the antero-internal), or by reversion of the molar to that of the bicuspidate type. In the first group (seen oftenest in the lower jaw) we place those examples of multicuspidate teeth, and in the other, those with diminutive crowns (seen oftenest in the upper jaw), which present cusps as in a bicuspid tooth, with, it may be, an additional cingule.

(7) In describing a normal upper bicuspid we would state that its single buccal cusp is the "canine" cusp, and its palatal its true "bicuspid" cusp (*i.e.* the cusp which creates a bicuspid tooth out of a canine). In a normal upper molar its antero-buccal cusp is the "canine"; the antero-palatal its "bicuspid"; the postero-buccal its true "molar" cusp; and the so-called postero-palatal is but a cingule. In a lower bicuspid the relations are the same as in the upper tooth. But the lower molar differs from the upper in the possession of a cusp in the place of the cingule. So that the upper molar has three cusps and a cingule, while the lower has four true cusps.

(8) It will follow from the foregoing that the lower molar is more highly developed than the upper; that the simplest expression of a cone is exhibited in the incisors and canines, which may be said to be the



lowest of the series; and that the highest expression anywhere seen is in the lower formula,—say the second molar, since here no tendency to reversion to the “bicuspid” type is seen.

(9) The above propositions may prove of value in studying deformations and in establishing a law of dental variation.

With these remarks we will content ourselves in naming the parts as they are exhibited in the following figures:

Throughout, c = “cuspid” cusp; b = “bicuspid” cusp; m = “molar” cusp; cg = cingule.

Fig. 36 (No. 64, Morton Coll.\* The upper incisors and left canine). These teeth show well-developed cingules, somewhat trifoliated. We may here remark that the tendency to a trilobed appearance of both cusps and cingules is often very marked.

FIG. 36.

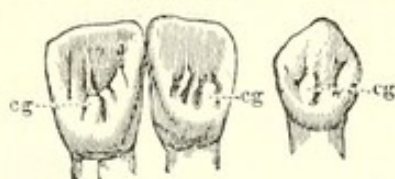


Fig. 37 (No. 1327, M. C. Right upper). A series from the skull of an Australian, which is remarkable for possessing four molar teeth. The first bicuspid presents a cingule. Each of the molars exhibits a cingule except the last, which is seen to revert to a bicuspidate type, and to closely resemble the first bicuspid.

FIG. 37.

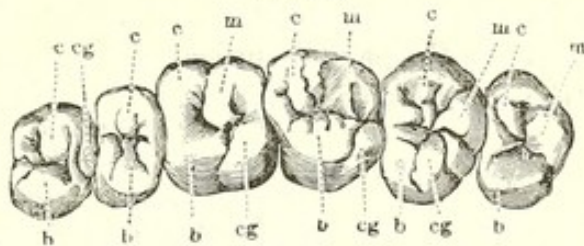


FIG. 38.

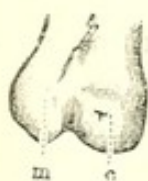

FIG. 39.

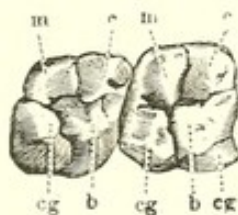


FIG. 40.



FIG. 41.

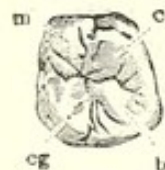


FIG. 42.



Fig. 38. This is the second molar of the above series seen in profile, showing that the “molar” cusp may be also shorter than the “canine” cusp.

Fig. 39 (No. 1342, M. C. First and second left upper molars). The first tooth here exhibits a cingule upon the bicuspid cusp, in addition to the one commonly seen on the palatal surface.

\* The abbreviation M. C. will indicate that the number so distinguished answers to a specimen in the Morton Collection in the museum of the Academy of Natural Sciences of Philadelphia.



Fig. 40 (No. 133, M. C. Third molar, left upper). A good example of reversion of a wisdom-tooth to a tricuspidate type.

FIG. 43.

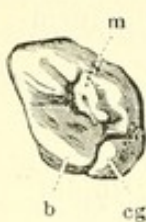

Fig. 41 (No. 64, M. C. Left upper molar). The enfolding trilobed appearance in each of the cusps and cingules is unusually pronounced.

Fig. 42 (No. 1328, M. C. First molar, upper, left). A remarkable example, in which, in addition to the arrangement above given, a large cingule is developed upon the palatal surface of the "bicuspid" cusp.

Fig. 43 (No. 55, M. C. Third molar, upper, left). This tooth shows an elongation forward and outward,\* chiefly due to the change in shape of the "canine" cusp.

FIG. 44.

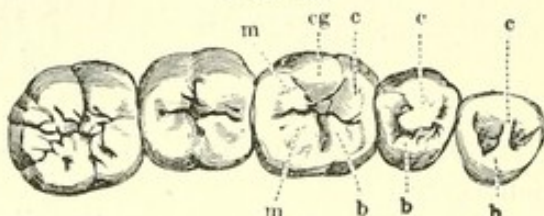


Fig. 44 (No. 1327, M. C. Left lower). This series exhibits a cingule upon the palatal surface of the first molar, which is not repeated in the other molars.

FIG. 45.

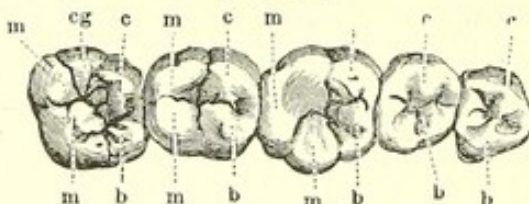


Fig. 45 (No. 1342, M. C. Right lower). A series somewhat similar to the preceding, showing in the third molar two distinct molar cusps and a cingule. In this tooth the posterior roots were divergent and distinct, and suggesting a positive relation between the development of the cusps and the juxtaposed roots.

FIG. 46.

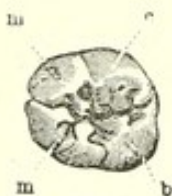

FIG. 47.

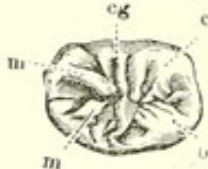


FIG. 48.

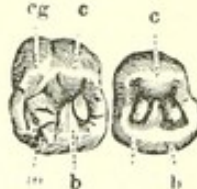


FIG. 49.

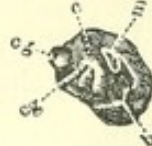

Fig. 46 (No. 1343, M. C. Third lower molar, left). This tooth shows unusual development of the enamel foldings.

\* The "canine" cusp in this figure is not indicated by the letter c as in the others.



Fig. 47 (No. 64, M. C. Third molar, left lower). This tooth shows a well-marked cingule. All the teeth of the series exhibit the same peculiarity. The several cusps are markedly trilobed.

Fig. 48 (No. 1467, M. C. First and second deciduous molar, upper, left side). The first molar is the common form of a deciduous tooth. It is to be observed that the canine and molar cusps have united. In the second molar the form is different, for here a well-defined sulcus exists between the canine and the molar cusps. A good example of a cingule lies toward the palatal side. The second molar is thus seen to closely resemble a permanent molar, while the first molar bears an intimate resemblance to a permanent bicuspid.

Fig. 49 (No. 760, M. C. First upper, left, deciduous). In this tooth the bicuspid cusp is separated from the canine cusp by a sulcus, and a cingule is present upon the latter. Thus the first molar of this series more closely resembles a molar of the permanent set than the corresponding tooth in Fig. 48, which recalls the form of the permanent bicuspid.

In the event of the first deciduous lower molar being found with but two roots, we would expect its crown to correspond with the outline of Fig. 48 rather than the one in Fig. 49.

Fig. 50 (No. 140, M. C. First and second left upper molars, deciduous). The first tooth here exhibits less enfolding about the "cuspid" and "molar" cusps than is ordinarily seen; and the second molar shows a tendency to duplication of the cingule.

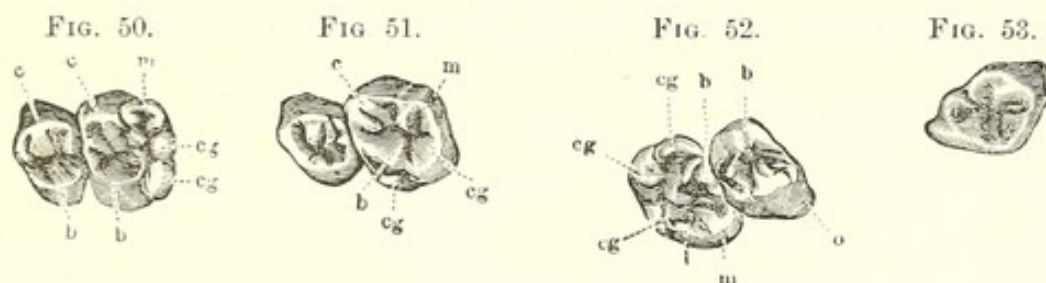


Fig. 51 (No. 828, M. C. First and second molars, upper, left, deciduous). The second molar exhibits a cingule upon the palatal aspect of the bicuspid cusp.

Fig. 52 (No. 1488, M. C. First and second molar, upper, left, deciduous). These are remarkable tooth-forms. In the first molar tooth, the "molar" cusp of the permanent molar type is present here in the deciduous tooth as a minute cingule. In the second, the cingules are three in number, and have crowded in the "bicuspid" cusp, so that this prominence is no longer a participant of the surface toward the palate. (This figure has been carelessly cut. In the original the fact as above described is more evident.)

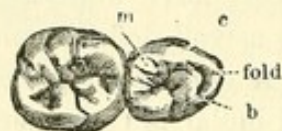Fig. 53 (No. 29, M. C. The first molar, right upper deciduous). This figure is designed to show the marked development of the enamel



prominence characteristic of the buccal face of this cusp. It should not be confounded with a cingule.

Fig. 54 (No. 1466, M. C. First and second deciduous molars, lower, left). The first molar exhibits a feature often seen, namely, the pro-

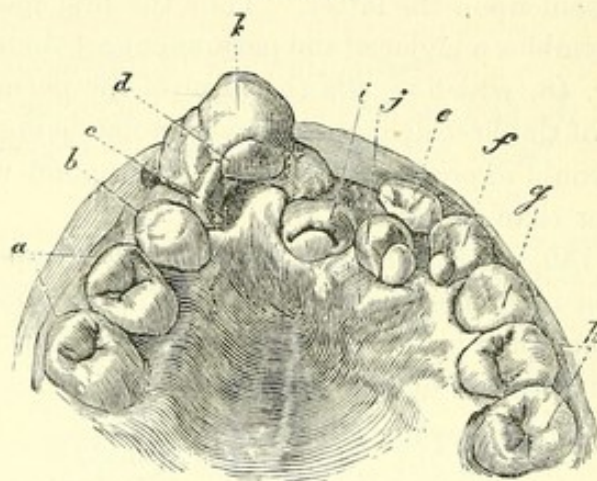
FIG. 54.



longation inward from the "cuspid" cusp as a thin enamel fold, which constitutes the anterior border of the grinding surface. The bicuspid cusp is partially inclosed by this fold. A little triangular pocket is by this arrangement left between the enamel fold and the bicuspid cusp.

Fig. 55 is taken from a plaster cast of the hard palate with the dental arch, secured from the mouth of a young girl, the subject of nævus of

FIG. 55.

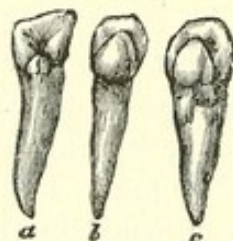

*a*, r. bicuspid; *b*, r. canine; *c*, r. lateral incisor; *d*, r. central incisor; *e*, l. central incisor; *f*, l. lateral; *g*, l. canine; *h*, l. bicuspid; *i*, *j*, supernumerary teeth; *k*, nævus.

the gum, operated upon at the clinic of the Philadelphia Dental College, in August, 1874.

The teeth marked *f*, *i*, *j*, were extracted, and are figured separately in Fig. 56. It will be observed that all three of these teeth are of the incisor

FIG. 56.



*a*, the lateral incisor; *b*, *c*, supernumerary teeth; marked in Fig. 55 *f*, *i*, *j*.

group,—that is to say, they are developed from the incisorial portion of the maxilla. It is of interest to observe that the deformation in each case is the same, namely, an exaggeration of the cingule. In the lateral



incisor it is conspicuous, but in the supernumerary teeth the cingule in each is so large that at first sight these teeth would be taken for bicuspid. Indeed, they are such, in a morphic sense, if we accept the fifth proposition as above defined. But since they are confined within the space of the inter-maxilla, we prefer designating them deformed incisors.

We desire to mention yet another point before leaving this subject. It will have been observed in the upper permanent teeth and the second deciduous molars, both above and below, and to a less constant degree in other teeth of the molar series, that the "bicuspid" cusp tends to extend obliquely across the tooth to join a corresponding prolongation of the "molar." This forms a ridge, which is very characteristic of the human molar tooth within the range above mentioned. It is not a little singular that this evident arrangement should have so long escaped notice. Professor Owen, in his "Odontography," and Mivart, in his "Elements of Anatomy," are the only systematic writers who mention it. So far as we have learned, but little attention has been directed to it in teaching.

---

ERRATUM.—On page 33, omit \* after name of Dr. H. J. Bigelow, and substitute †, with the following reference: Boston Med. and Surg. Journ., vol. lxxxvii. 279.



























