Histological studies on the localisation of cerebral function / by Alfred W. Campbell. Pub. by aid of a subsidy from the Royal Society of L ondon.

Contributors

Campbell, Alfred Walter.
Harvey Cushing/John Hay Whitney Medical Library

Publication/Creation

Cambridge : University Press, 1905.

Persistent URL

https://wellcomecollection.org/works/nwfhf845

License and attribution

This material has been provided by This material has been provided by the Harvey Cushing/John Hay Whitney Medical Library at Yale University, through the Medical Heritage Library. The original may be consulted at the Harvey Cushing/John Hay Whitney Medical Library at Yale University. where the originals may be consulted.
This work has been identified as being free of known restrictions under copyright law, including all related and neighbouring rights and is being made available under the Creative Commons, Public Domain Mark.

You can copy, modify, distribute and perform the work, even for commercial purposes, without asking permission.

Wellcome Collection
183 Euston Road
London NW1 2BE UK
T +44 (0)20 7611 8722
E library@wellcomecollection.org
https://wellcomecollection.org

YALE
UNIVERSITY

CUSHING/WHITNEY
MEDICAL LIBRARY

Digitized by the Internet Archive
in 2012 with funding from
Open Knowledge Commons and Yale University, Cushing/Whitney Medical Library

http://archive.org/details/histologicalstud1905camp

HISTOLOGICAL STUDIES

ON THE

LOCALISATION OF CEREBRAL FUNCTION

CAMBRIDGE UNIVERSITY PRESS WAREHOUSE,
C. F. CLAY, MANAGER.
London: FETTER LANE, E.C.
Glasgow: 50, WELLINGTON STREET.

ALSO

London: H. K. LEWIS, 136, GOWER STREET, W.C.
Leipzig: F. A. BROCKHAUS.
New York: THE MACMILLAN COMPANY.
Bombay and Calcutta: MACMILLAN AND CO., LTD.

[*All Rights reserved.*]

HISTOLOGICAL STUDIES

ON THE

LOCALISATION OF CEREBRAL FUNCTION

BY

ALFRED W. CAMPBELL, M.D.,

PATHOLOGIST TO THE ASYLUMS BOARD OF THE COUNTY OF LANCASTER.

PUBLISHED BY AID OF A SUBSIDY FROM THE ROYAL SOCIETY OF LONDON.

CAMBRIDGE:
at the University Press
1905

CAMBRIDGE:
PRINTED BY JOHN CLAY, M.A.
AT THE UNIVERSITY PRESS.

YALE MEDICAL LIBRARY
OCT 29 1997

Med Lib
QP385
.C2
1905
(locked)

PREFACE.

THE major part of the present work was communicated to the Royal Society of London by Professor Sherrington of Liverpool University in November, 1903, the remainder a few months later. It was prepared for publication in the Philosophical Transactions, but the manuscript, when laid before the Council, was adjudged of inordinate length and the alternative proposal to issue it in book form, with the aid of a special grant, was made and accepted. For such generous treatment I am unable adequately to express my sense of gratitude.

The research covers a wide field and the preparation of material has absorbed so much time and labour, that single-handed it could not have been accomplished; I have to acknowledge occasional help from my medical colleagues, but in particular I have appreciated the patient industry of my laboratory assistants.

Many of the microscopic drawings which illustrate the text were made, with infinite care, by Dr A. C. Wilson, and the drawings for Plate 3 *a* were prepared by Mr F. J. Abram, who also kindly undertook most of the photographic work incidental to the research. The beautiful clearness with which their drawings are reproduced will be as much a source of pleasure to these gentlemen as it is a tribute to the painstaking methods and enterprise of the publishers.

Means for the research have been supplied by the Lancashire Asylums Board, and it has been wholly conducted in their laboratory at Rainhill Asylum.

For special material I am indebted to my friends Dr F. W. Mott and Dr Nathan Raw, and to Professor Sherrington I am more than grateful not only for the presentation of several valuable specimens, but for counsel when in doubt, for encouragement when energy flagged and for many other kind offices.

A. W. C.

September, 1905.

CONTENTS.

INTRODUCTION.

CHAPTER I.

PAGE

MATERIAL AND METHODS OF EXAMINATION 1

CHAPTER II.

GENERAL REMARKS ON CELL LAMINATION AND THE ARRANGEMENT OF NERVE FIBRES IN THE CEREBRAL CORTEX 6

List of references 17

CHAPTER III.

THE PRECENTRAL OR MOTOR AREA.

Introductory remarks 20

Observations on structure.

Some points touching the anatomy of the fissure of Rolando 21

Arrangement of nerve fibres in the precentral cortex (*a*) of man, (*b*) of the anthropoid ape . 24

Distribution of the precentral area 27

Cell lamination in man and ape 29

Special account of the giant cells of Betz 31

Considerations on function.

The precentral cortex in amyotrophic lateral sclerosis 38

Post-amputation changes in the precentral cortex 47

Clinical evidence touching the effects of lesions of the precentral area 62

Summary 63

List of references 65

CHAPTER IV.

THE POSTCENTRAL OR SENSORY AREA AND THE INTERMEDIATE POSTCENTRAL AREA.

Introductory remarks 67

Histological observations.

Arrangement of cortical nerve fibres in the postcentral area 68

Cell lamination in the postcentral area 71

Distribution of the postcentral area 75

The postcentral area in the anthropoid ape 75

Structure and distribution of the intermediate postcentral cortex 76

PAGE

On the function of the postcentral areas 78
Anatomical and histological considerations 80
Points in the myelinisation of the sensory tracts 83
The postcentral cortex in tabes dorsalis 85
The postcentral cortex in cases of old-standing lesions of the internal capsule . . . 94
The postcentral cortex in cases of amputation 96
Doctrines of clinical medicine and experimental physiology 97
Reflections on "common sensation" 102
Summary 107
List of references 110

CHAPTER V.

THE VISUO-SENSORY AND VISUO-PSYCHIC AREAS.

Histological observations.
Arrangement of nerve fibres in the visuo-sensory cortex 112
Cell lamination 115
Distribution of the visuo-sensory cortex 118
The visuo-sensory area in the manlike ape 121
Arrangement of nerve fibres in the visuo-psychic cortex 126
Cell lamination in the visuo-psychic cortex 128
Distribution of the visuo-psychic cortex 129
The visuo-psychic area in the manlike ape 130
On the function of these areas.
Consideration of the experimental evidence 132
Consideration of the clinico-pathological evidence 135
Consideration of the anatomical and developmental evidence 139
Summary and conclusions 144
List of references 147

CHAPTER VI.

THE TEMPORAL LOBE AND THE AUDITORY AREAS.

Histological observations.
The fibre arrangement in the cortex of the transverse temporal gyri (audito-sensory area) 149
The fibre arrangement in the cortex of the superior temporal gyrus (audito-psychic area) 151
The fibre arrangement in the cortex of the rest of the temporal lobe 152
The cell lamination in the transverse temporal gyri 153
The cell lamination in the superior temporal gyrus 155
The cell lamination in the rest of the temporal lobe 157
The distribution of the different types of cortex 157
The temporal cortex in the anthropoid ape 160
A general consideration of function.
The experimental evidence 161
The clinico-pathological evidence 162
The anatomical evidence 166
Summary and conclusions 169
List of references 173

CHAPTER VII.

THE LIMBIC LOBE.

PAGE

Histological observations.
The cortex covering the lobus pyriformis: its fibre arrangement, cell lamination and distribution . . . 176
The cortex lining the fissura hippocampi . . . 181
The gyrus dentatus . . . 182
The striae longitudinales mediales . . . 182
The gyrus subcallosus . . . 183
The cortex of the gyrus fornicatus . . . 184
The cortex of the limbic lobe in the anthropoid ape . . . 188
A general consideration of function . . . 189
The results of experiment . . . 190
Clinico-pathological data . . . 190
The teachings of comparative anatomy . . . 191
Points in development . . . 192
The histological evidence . . . 193
Summary and conclusions . . . 195
List of references . . . 197

CHAPTER VIII.

THE PARIETAL AREA.

Introductory remarks . . . 199
Histology.
Arrangement of cortical nerve fibres . . . 199
Cell lamination . . . 201
Topical variations in structure . . . 202
Distribution . . . 203
Condition in the anthropoid ape . . . 204
Considerations on function.
Physiological teaching . . . 205
Clinical evidence . . . 205
Deductions from phylogeny . . . 206
Developmental truths . . . 206
Summary . . . 207
List of references . . . 207

CHAPTER IX.

THE INTERMEDIATE PRECENTRAL AREA.

Introductory remarks . . . 209
Histological observations.
Type of arrangement of cortical nerve fibres . . . 209
Type of cell lamination . . . 211
Distribution . . . 213
Condition in the anthropoid ape and comments on certain frontal fissures in simiadae . 214

PAGE

Considerations on function.
The representation of movement in the cerebral cortex 217
The doctrines of experimental physiology 218
Embryological data 218
On certain association tracts of fibres 219
The clinical evidence 221
Motor aphasia and the motor speech mechanism 221
Agraphia 225
High and low evolutionary movements 226
Summary 227
List of references 229

CHAPTER X.

THE FRONTAL AND PREFRONTAL AREAS.

Introductory remarks 231
Histology.
Type of arrangement of cortical nerve fibres 231
Type of cell lamination 234
Distribution 236
The corresponding areas in the anthropoid brain 236
A consideration of function 238
Experimental data 239
Clinical observations 241
Embryological evidence 243
Deductions from histology 244
Deductions from comparative anatomy 246
Summary 247
List of references 249

CHAPTER XI.

THE ISLAND OF REIL.

Introduction and remarks on anatomy 250
Histology.
Types of arrangement of cortical nerve fibres 251
Types of cell lamination 253
Distribution of types of cortical structure 255
Condition in the manlike ape 256
A consideration of function.
Points in phylogeny 256
Clinical doctrines 257
The insula as a gustatory centre 259
Summary 259
List of references 260

ADDENDUM.

FURTHER HISTOLOGICAL STUDIES ON THE LOCALISATION OF CEREBRAL FUNCTION. THE BRAINS OF FELIS, CANIS AND SUS COMPARED WITH THAT OF HOMO.

PART I.

HISTOLOGY.

Method of examination 261
The subdivisions of cortex recognised 261
Felis domesticus 262
The crucial or motor area, its structure and distribution 262
The visual area, its structure and distribution 263
The postcrucial or sensory area, its structure and distribution 264
The parietal area, its structure and distribution 265
The ectosylvian area (A), its structure and distribution 266
,, ,, (B), its structure and distribution 266
The extrarhinic area, its structure and distribution 267
The limbic area, its structure and distribution 267
The prefrontal area, its structure and distribution 268
The lobus pyriformis, its structure and distribution 268
Canis familiaris.
Structure and distribution of areas corresponding to those defined in felis . . . 269
Sus communis.
Idem 272

PART II.

A CONSIDERATION OF THE FUNCTIONS AND HOMOLOGIES OF THE AREAS DEFINED.

The crucial area as the equivalent of the precentral area 276
The homologies of the fissure of Rolando 277
The visual area 279
The homologies of the fissura calcarina 279
The lobus pyriformis and hippocampal region 282
The limbic area 282
The postcrucial area as the homologue of the postcentral area 283
The parietal area 286
The ectosylvian area as the homologue of the insula and of parts of the temporal lobe . 286
The frontal area 288
General reflections and conclusions 288
List of references 291
Description of Plates 292
Indices of authors and subjects 350

LIST OF ILLUSTRATIONS IN THE TEXT.

		PAGE
Fig. 1.	Nerve fibres in the radiary zone of the precentral area	25
Fig. 2.	Nerve fibres in the radiary zone of the prefrontal area	26
Fig. 3.	Giant cells of Betz showing post-amputation changes (réaction à distance)	52
Fig. 4.	Composite diagrams illustrating the distribution of post-amputation changes in the cortex cerebri in a series of cases	54
Fig. 5.	Nerve fibres in the radiary zone of the postcentral area	69
Fig. 6.	Giant cells of Betz from the precentral area represented beside the largest post-central cells	74
Fig. 7.	Nerve fibres in the radiary zone of the intermediate postcentral area	76
Fig. 8.	Changes in the nerve cells of the postcentral area in tabes dorsalis	90
Fig. 9.	A representation of normal postcentral cortex for comparison with that shown in the last figure	91
Fig. 10.	Nerve fibres in the radiary zone of the visuo-sensory cortex	113
Fig. 11.	Diagrams to illustrate the distribution of the visuo-sensory and visuo-psychic areas in the human being and anthropoid ape	119
Fig. 12.	Nerve fibres in the radiary zone of the visuo-psychic cortex	127
Fig. 13.	Drawings of large external pyramidal cells from the transverse temporal gyri (audito-sensory area)	154
Fig. 14.	Drawings of large external pyramidal cells from the superior temporal gyrus (audito-psychic area) and from the common temporal cortex	156
Fig. 15.	Diagram illustrating the distribution of the different types of cortex in the temporal lobe and insula	158
Fig. 16.	Drawings to explain some points in the anatomy of the hippocampal region	177
Fig. 17.	Nerve fibres in the radiary zone of the cortex covering the lobus pyriformis	178
Fig. 18.	Nerve fibres in the radiary zone of the gyrus fornicatus	185
Fig. 19.	Chromophilous cells in the prelimbic cortex	187
Fig. 20.	Nerve fibres in the radiary zone of the parietal area	200
Fig. 21.	" " " " intermediate precentral area	210
Fig. 22.	" " " " frontal area	233
Fig. 23.	" " " " cortex covering the anterior half of the insula	252

LIST OF PLATES AND LEGENDS.

PAGE

1. General scheme of areas, human brain, outer and inner surfaces 293
2. General scheme of areas, anthropoid ape's brains, outer, inner, upper and lower surfaces . 295
3. Fig. 1. Arrangement of nerve fibres in precentral area. Fig 2. Cell lamination in precentral area 297
4. Fig. 1. The precentral cell lamination as it appears in amyotrophic lateral sclerosis. Fig. 2. The normal lamination for comparison 299
5. Fig. 1. Arrangement of nerve fibres in postcentral area. Fig. 2. Arrangement of nerve fibres in intermediate postcentral area 301
6. Fig. 1. Cell lamination in postcentral area. Fig. 2. Cell lamination in intermediate postcentral area 303
7. The postcentral cell lamination as it appears in tabes dorsalis, (1) in a diseased part, (2) in a normal part, low power 305
8. Do., more highly magnified 307
9. The distribution of (*a*) the cortical changes in tabes dorsalis, (*b*) the giant cells of Betz 309
10. Fig. 1. Arrangement of nerve fibres in visuo-sensory area. Fig. 2. Arrangement of nerve fibres in visuo-psychic area 311
11. Fig. 1. Cell lamination in visuo-sensory area. Fig. 2. Cell lamination in visuo-psychic area 313
12. Fig. 1. Arrangement of nerve fibres in audito-sensory area. Fig. 2. Arrangement of nerve fibres in audito-psychic area 315
13. Fig. 1. Nerve fibres of the radiary zone in the audito-sensory area. Fig. 2. Nerve fibres of the radiary zone in the audito-psychic area. Fig. 3. Nerve fibres of the radiary zone in the common temporal area. Fig. 4. Nerve fibres of the radiary zone in the gyrus angularis 317
14. Fig. 1. Arrangement of nerve fibres in the common temporal area. Fig. 2. Arrangement of nerve fibres in the gyrus angularis 319
15. Fig. 1. Cell lamination in the audito-sensory area. Fig. 2. Cell lamination in the audito-psychic area 321
16. Fig. 1. Cell lamination in the common temporal area. Fig. 2. Cell lamination in the gyrus angularis 323
17. Fig. 1. Arrangement of nerve fibres in cortex of lobus pyriformis. Fig. 2. Cell lamination in cortex of lobus pyriformis 325
18. Fig. 1. Arrangement of nerve fibres in cortex of fissura hippocampi. Fig. 2. Cell lamination in cortex of fissura hippocampi 327

PAGE

19. Fig. 1. Arrangement of nerve fibres in limbic area A. Fig. 2. Cell lamination in limbic area A 329
20. Fig. 1. Arrangement of nerve fibres in the parietal area. Fig. 2. Cell lamination in the parietal area 331
21. Fig. 1. Arrangement of nerve fibres in the intermediate precentral area. Fig. 2. Cell lamination in the intermediate precentral area 333
22. Representation of the areas mapped out in the frontal lobes of man and the anthropoid ape 335
23. Fig. 1. Arrangement of nerve fibres in the frontal area. Fig. 2. Arrangement of nerve fibres in the prefrontal area 337
24. Fig. 1. Cell lamination in the frontal area. Fig. 2. Cell lamination in the prefrontal area 339
25. Fig. 1. Arrangement of nerve fibres in the insula. Fig. 2. Cell lamination in the insula . 341

PLATES IN THE ADDENDUM.

1 and 2. Maps of the various areas defined in the brains of felis, canis and sus . . 343
3. To illustrate the sulcus cruciatus hominis 345
4. Photomicrographs of (1) the second layer of nerve cells in sus, $\times \frac{80}{1}$; (2) do., $\times \frac{300}{1}$; (3) the curious band of nerve fibres in the visual cortex of sus, $\times \frac{30}{1}$; (4) do., $\times \frac{300}{1}$. 347

CORRIGENDA.

For "word-hearing" *read* "word-seeing," p. 173.

For Wylie *read* Wyllie, pp. 225 and 230.

INTRODUCTION.

THE process leading to the accomplishment of functional localisation in the cerebral cortex is such a complicated one, and involves so many side issues, that perfection cannot be attained or even hoped for until the fruits of investigation in a number of departments are thoroughly weighed, sifted and assorted. It is anticipated that the observations set forth in this research will help to establish the value of histological work as an auxiliary force in the final settlement of that functional subdivision of the cerebral cortex at which we aim.

Methods of Histological Research.

There are many directions in which the talents of the histologist may be exercised, and these can be arranged in a triad constituted as follows, the study of the brain (1) during development, (2) in conditions of disease, and (3) in the normal state.

1. *The Study of the Brain in Phases of Development.*

The value of embryological researches has already been proved, at any rate in one direction, by taking advantage of the natural law that the maturation or myelinisation of the various tracts of fibres standing in relation with various functions does not occur coincidentally but follows a set sequence. Observing the tenets of this law the surface of the brain can be subdivided in accordance with the different times at which the medullated constituents become apparent. In addition, the embryologist is in the happy position of being able to amplify and confirm assumptions concerning surface realms so demarcated, by his ability to trace the subcortical paths followed by the related axones. To exemplify my meaning I have merely to point to the visuo-sensory area; the calcarine cortex, in which the seeing function concentrates itself, is found to contain myelinised fibres at a relatively early date, certainly at a time when such fibres are absent from the surrounding field, hence its surface distribution is readily determined; and as the band of fibres bringing this area into association with intermediate visual stations in the thalamic region matures at a corresponding time, its course can be followed with equal facility. In this manner an irrefragable chain of evidence can be welded.

But unfortunately all tracts and all centres are not so readily determined by developmental methods, also conclusions must be drawn with caution; indeed, judging from the storm of criticism deluged on the writings of the foremost worker in this province (Flechsig), it seems that the embryologist, almost more than anyone else, must pay the fullest possible regard to the findings of those who have investigated localisation on other lines.

Another direction in which developmental studies may prove serviceable, is the determination of the time at which other cortical elements, to wit the nerve cells, make their appearance; because, it seems reasonable to assume that these follow the same sequence as the nerve fibres; taking an instance, there is full likelihood that in the case of those animals which at the time of birth are incapable of locomotion, man is of course one, sensory cells develop in advance of motor cells, and in this way light might be thrown on at all events one very vexed question. Probably on account of the fact that our methods for the study of developmental cytology are as yet imperfect, practically no work has been done on this subject.

2. *The Histological Study of the Brain in Conditions of Disease.*

There are two important methods under this heading by which cerebral localisation can be, and has been forwarded; one is by taking notice of the course and destination of secondary degenerations, either of experimental production or arising in nature, and it supplies a means for securing information concerning the various sensory areas and the motor field, as well as certain subcortical association tracts. The second method, in my opinion of greater value and insufficiently exploited, is based on the principle that division of a nerve is followed, not only by central, but by peripheral changes, changes which are not confined to the divided segment but affect all links and all stations in the neuronic chain of which it may form a part. The principle of course embodies Wallerian degeneration and Gudden's atrophy, and issues have already proved that the application of the method is correct in foundation; thus, Bolton has successfully utilised cases of old-standing blindness of peripheral origin in defining the exact limits of the visual area; and in the present work full advantage is being taken, for the first time, so far as I am aware, of the changes which occur in the motor area, in cases of amputation of extremities, and, in what I believe to be the sensory area, in cases of Tabes Dorsalis. As many years have elapsed since Gudden published the accounts of his experiments on retrograde degeneration, and we have been familiar with Wallerian degeneration and its effects on structures at the end of the conduction stream for an even longer period, it is surprising that these teachings have not been more frequently applied to cortical localisation, and it can only be imagined that they have not been on account of imperfections in our knowledge of the topographic distribution of the various types of cortical cell lamination and fibre arrangement, and because in the vastness of the human cerebral surface observers have not known where to start and look for reactive changes.

In addition to the conditions mentioned, others which occur to one as being suitable for investigation and which come in this category are cases of prolonged deafness, anosmia and ageusia of peripheral origin[1], and they would certainly have been made use of in this research had they been available. Finally, the morbid histologist has at his disposal the brains of individuals who have suffered from some disability of central origin, I refer to cases of congenital mutism and deafness, as typical examples; and there are many other kindred conditions to be sought which must of necessity be associated with mal-development, direct or indirect atrophy, or disintegration of cortical elements, and which would afford profitable material, just as Amyotrophic Lateral Sclerosis—a disease which may be included in this class—has proved serviceable in my hands (*vide* chapter on the motor area).

[1] For localisation of the sense of taste, about which our information is so meagre, an examination of the hippocampal region and insula in cases of excision of the tongue is to be thought of.

3. *The Study of the Cortex Cerebri in the Normal State.*

We come next to the study of the cortex cerebri in the normal state. This constitutes the basis of the present research and is so important that it may be regarded as the corner stone in the histological foundation upon which the superstructure of cerebral localisation may be reared by workers in other departments. Of the cortical components, two, the nerve fibres and the nerve cells, act as bases for investigation, and the topical variations exhibited by these elements serve as certain guides to the creation of a subdivisional map of the brain surface. As to the nerve fibres, it has been known for some years that these are subject to variations in size, arrangement and number or wealth in different situations; but, up to the present, advantage has not been taken of these variations in making a careful and comprehensive survey of the surface, with the end expressly and constantly in view of endeavouring to ascertain whether or not fields having established connections with different physiological functions are characterised by the possession of some specific fibre arrangement, which will render their correct delineation possible. I am hoping that proof of the unvarying exercise of this fundamental aim will heighten interest in, and add to the appreciation of my individual labours, for I feel that I shall be able to show that most valuable and significant results are obtainable in this manner, and I will also venture the opinion, that others who have applied themselves with undeniable industry to a histological study of these fibres have failed to elicit information bearing on the localisation of function, solely because their methods have been uninfluenced and undirected by the above-mentioned fundamental principle. Similar remarks apply, but not so forcibly, concerning the second cortical constituent, the nerve cell. Starting from the year 1872, when Meynert's classical research saw light, the literature has been enriched by a steady and constant stream of observations dealing with variations in the architectural as well as the intimate structure of these highly important elements. But with rare exceptions these observations have been founded on what may be called piecemeal work, at the most two functional areas, the motor[1] and the visuo-sensory, can be pointed to as having had their boundaries accurately delineated by cytological methods, and it is plain that observers have previously baulked an attempt to explore the whole surface in a comprehensive and complete manner on account of the magnitude of the task. To the accomplishment of this undertaking I now lay claim; and its independent value is materially enhanced by the fact that it has enabled me to make a collateral comparison of cell lamination and fibre arrangement in section after section and millimetre by millimetre over the entire surface of the human cerebrum[2]. Indeed, not only has this been done in the case of the human subject but an identical plan of research has been extended to the brains of those members of the ape family which come second to man in the scale of phylogeny, and this branch of the research, which may be included under the heading of normal histology, can also be proved to be productive of gain. Before leaving this subject reference may be made to two other cortical components about which our knowledge is scanty at present but which may in the future serve as checks to perfect localisation; of these, the first is what is commonly known by the term neuroglia, and it is conceivable that this exhibits morphological, numerical, developmental, and possibly functional variations in different areas, in the same

[1] The motor area was virtually defined by Bevan Lewis and Henry Clarke in 1879 (*vide* chapter on motor area).

[2] In more than one case I have converted an entire cerebral hemisphere into serial sections and alternately stained these for the display of nerve cells and nerve fibres.

way as the nerve cells and fibres do. The second component forms that cortical "terra incognita" which remains over when cells, fibres, and neuroglia, are subtracted, and the evident truth that its bulk must vary in proportion with the representation of the other elements may be significant.

Hitherto means to localisation restricted entirely to the domain of histology have been spoken of; it is now to be mentioned that facts pertaining to the kindred science, anatomy, and more especially the findings of the comparative anatomist have already assisted us to some extent, and may guide us a great deal further in the final determination of many points bearing on localisation in the human being. Passing through the phylogenic scale from the invertebrata upwards, we have watched with interest the progressive development of the nervous system from a rudimentary chain of ganglia to the highly elaborated and extremely complex human organ; we have observed that in the lowest mammals the brain is developed only to that degree which will meet and ensure existence, that is to say, it is simply composed of centres for the control of motion and intrinsic physical functions; we have also been taught that the representation of these essential centres, common to all animals, undergoes changes in accordance with environmental circumstances, that, for instance, the centres for smell, sight, hearing, touch and motion, exhibit developmental variations in relation to the degree in which the animal relies upon any one of these functions for its well-being or self-preservation. Therefore by carefully observing the area supposed to preside over any one of these functions, watching its behaviour in order after order, and eventually making comparisons with the human being, invaluable clues to localisation should be forthcoming. Indeed in this very way, we have already derived the most important and direct information we possess on the localisation of one primary sense, that pertaining to smell, and although homologies in regard to other senses and functions are not yet satisfactorily established, I would point out that this is a branch of study which is as yet in its infancy, and I venture to predict that the examination of a series of animal brains in the comprehensive manner advocated in these pages will serve to settle many points which at the present moment rest on inference and form matter for argument.

So much for comparative histology. We have next to consider whether any structural features, gross and macroscopic in character, may be taken as finger-posts to the orientation of function. It appears that some can, but at the same time their utility is restricted. The guides alluded to consist of fissures. It will be noticed on consulting the map of localisation submitted herewith that the fields of cortex dominating the primary and essential functions are all deposited in relation to important fissures; thus the visual area is associated in the closest manner possible with the calcarine fissure, the olfactory with the hippocampal, the motor and the common sensory with the Rolandic and the auditory with the Sylvian; and it may be further observed that all these fissures, with one exception, are admitted, by those who have studied the developing brain, into the category of "primary" fissures; the exception is the Sylvian fissure, and about this opinions are divided, some—including His—advocating, and others—including Cunningham—denying its "primary" character. This seems to be a deliberately planned ontogenetic result more than an accidental occurrence, to those interested in homologies it is a relation worthy of further study, and so also is the subject of the influence of phylogenesis in the production of fissural limits. Save these "primary" fissures there is really no practical naked-eye guide to the localisation of the different areas, for all the "so-called" secondary fissures bear a very inconstant relation to given fields and cannot be utilised as fixed boundary lines.

We have now passed in review all the methods open to the histologist and anatomist as aids to the localisation of cerebral function, and if I seem to have painted the advantages of these methods in too bright a colour, and if also I have conveyed the idea that histological research is the most potent force in the solution of problems concerning localisation, let me dispel that conception by stating that I yield to none in my admiration of the succession of classical original researches coming from the pens of Ferrier, Schäfer, Beevor, Horsley, Sherrington, Mott and Ballance in this country; of Hitzig, Goltz, Munk and Bechterew on the continent, and of others whose names inspire an equal amount of respect, and who might be worthily included in this list of pioneers in the field of experimental neurology and physiology; let me also state that I should be totally lacking in my sense of esteem if I failed to take respectful cognisance of the ever-memorable labours of a second honoured coterie of observers who, following in Broca's footsteps, have taken the human subject as their study, and consummated the aim of the experimenter by bedside investigation. And in continuation let me unreservedly grant, in reference to the process or chain of events which ultimately leads to the final localisation of function, that not until the ground is prospected and prepared by the physiologist and clinician can the histologist hope to step in and work with any real measure of success; but when given guiding lines by preliminary exploration, I maintain that the microscopist will probably succeed in defining and rubbing the corners off the boundaries of the productive field with an accuracy and certainty which with one exception is denied to his predecessors. The exception is the motor area, for it seems that by improved methods, the outlines of this centre can be determined to a hair's breadth; with other fields, notably those which we regard as sensory stations, the case is different. Their position can be only roughly indicated by experimental ablation or a natural lesion, and histology alone can give their precise extent and limits.

Perhaps enough has been said to justify my opening remark to the effect that to the satisfactory accomplishment of cortical localisation a free and harmonious collaboration between workers in the several provinces is an essential postulate, and I hope in the following pages to indicate the exact areas of cortex which we can now point to and set aside as being of known function. It will be seen that these areas embrace all those functions which we may regard as primary, common to all animals and necessary in some way to natural existence; there only remain over those "silent" stretches of cortex the superior development of which marks the human brain, and which may have for their rôle the maintenance of those intellectual attributes which place man above all other animals. Although at the present day we have no sure grounds for the subdivision and separate allotment of higher functions in these comparatively unknown territories, and the significance of the few histological lines which I have drawn across them is perfectly obscure, yet I hope that good will result from the survey alone. Particularly do I hope that those who, like myself, have pledged their energies to the apparently hopeless task of elucidating problems connected with mental disease will derive benefit from this research, for it was only after several valuable years had been spent in the cause of scientific research in a laboratory attached to an asylum for the insane that I recognised that it was necessary for some worker to begin at the beginning, and attempt to piece together our disjointed knowledge of the structure of the cortex, and now that a large extent of the brain surface can be eliminated as being of known function, and the ground we tread has grown firmer, we can return with accentuated zeal to grapple with these practical problems.

CHAPTER I.

MATERIAL AND METHODS OF EXAMINATION.

Material.

It was my original intention when this investigation was begun to rely solely on normal material, but as the work grew and points bearing on cortical localisation multiplied, it became more and more plain that the value of the research would be immeasurably increased, if as many points as possible concerning individual areas, and suggested by the normal appearances, were amplified and verified by an examination of the brain in diseased conditions which might be supposed to occasion alterations in those areas; this has been done, and I hope it will be agreed that the results more than justify the additional labour expended. Further, at the time when I was devoting attention to the motor area, some brains from the anthropoid ape family came to hand and their examination has supplied a useful and instructive check to many of the findings in the human subject.

The material, therefore, is divisible into three categories, namely, normal human, normal comparative, and pathological.

A. The Normal Human Material consisted of three cerebral hemispheres completely examined for both nerve cells and nerve fibres, three hemispheres completely examined for fibres only and two hemispheres partially examined for nerve fibres and nerve cells.

The ages of the individuals ranged from 19 to 48 years.

I must explain that six of the above-mentioned hemispheres were taken from persons who died while of unsound mind in Rainhill Asylum; two only came from a sane individual, and were supplied from Mill Road Infirmary by the courtesy of Dr Nathan Raw, they were removed from a male aged 36, certified as being of the average standard intellectually and physically, and as dying from acute lobar pneumonia after an illness of seven days. It may be urged that the mere fact of a person having suffered from insanity is sufficient in itself to condemn the brain as unsuitable material for an investigation of this description. In reply to this, while I confess on looking back that I should have preferred that more brains in the series were from individuals free from mental disorder, it is almost needless for me to say that I should not have continued to employ the insane brain had I not felt that the objections to its use were based more on sentiment than reality, and had I not convinced myself from a lengthy experience in the pathological laboratory attached to

Rainhill Asylum that, in a large proportion of cases dying insane, all the microscopic methods at our disposal will fail to disclose changes, either in the nerve cells or fibres, which we can refer to their altered mental condition; and that in other cases in which the mental disorder is more advanced or of a graver nature, while we may be able to discover alterations in the nerve cells,—thanks to the marked advance which has been made of late years in this province of histology,—yet the present state of our knowledge will not allow us to make any definite declaration concerning attendant changes in the nerve fibres. And I am able to speak without reservation of the difficulties which beset the detection of morbid changes in the nerve fibres in the cerebral cortex, because for several years prior to the inception of the present investigation I devoted much time to a study of this subject. I am of course well aware that in grave forms of mental disease, such for instance as general paralysis of the insane, the fibres undergo serious alterations, but in choosing material for this work I have naturally avoided such cases and been careful to select individuals in whom the mental disorder was one of the simpler forms unaccompanied by other disease of the nervous system; in whom the attack of insanity had not been of longer duration than one month; who prior to its onset had given evidence of average intellectual ability; whose final illness was not associated with prolonged failure of general nutrition; who were of standard physical development and free from deformity, and whose brains were up to the average weight, free from wasting, and in every respect normal to the naked eye. Such brains I have obtained from cases of puerperal insanity and simple mania, and to prove that they form safe material for investigation, I have carefully compared the sections of them with those of the normal brain and satisfied myself that no obvious differences exist to invalidate the results and certainly nothing that would deter one from using them restrictedly, as in mapping out the general distribution of the various types of arrangement of nerve fibres.

B. Normal Comparative Material.

1. Right cerebral hemisphere of a Chimpanzee, completely examined for nerve fibres and partially investigated for nerve cells.
2. Left hemisphere of a Chimpanzee (another animal), completely examined for fibres only.
3. Right hemisphere of an Orang, completely examined for fibres only.

For these anthropoid brains I am indebted to Professor C. S. Sherrington of Liverpool. They were taken from animals previously utilised by that gentleman in his experimental researches (in collaboration with Professor Grünbaum) on the motor area in the higher apes, and it has been satisfactory to find that the delicate method of electrical excitation employed in stimulating the cortex in those researches has not in any way damaged the brains for histological purposes.

C. Pathological Material.

Two brains from cases of Amyotrophic Lateral Sclerosis, seven from cases of amputation of one or other extremity, three from cases of Tabes Dorsalis and one from a case of old-standing capsular lesion were examined, in the manner described hereafter, to determine certain points bearing on the functions of the central convolutions and parietal lobe; and the occipital lobe was completely examined in two cases of old-standing blindness.

Methods of Examination.

All the normal human and the anthropoid brains were hardened in Müller's fluid or in Orth's solution,—a mixture of Müller's fluid and Formalin; after fixation, orthogonal tracings were drawn, showing the exact disposition of the convolutions and sulci on the various surfaces, and to confirm the correctness of these tracings the same surfaces were photographed. In the case of the anthropoid brains a plaster of Paris cast was always made, and proved of great assistance in facilitating orientation when the preparations were ready for microscopic examination.

With the hemispheres which were examined completely, the following was the plan of procedure. They were first divided into portions of suitable size for section on the microtome, for this purpose blocks of a length of 5 ctm. were found most convenient: sections of pieces of a greater size are not only difficult to manipulate, but the necessary addition to their thickness impairs their utility as microscopic specimens; furthermore, it is always a distinct advantage to carry the line of cleavage as near as possible at right angles to the main sulci, so that the adjoining convolutions may be viewed in transverse section, an advantage which is sacrificed when very large blocks are taken. Division of the brain so as to give a view of all the principal gyri on transverse section in this manner is not an easy matter, each line of incision has to be carefully thought out and eventually one is left with about 50 blocks for section; and though labour is multiplied in the preparation of specimens from such a number of pieces the result justifies the expenditure of time, because the discernment and definition of changes in type of structure are facilitated, and also because oblique sections of the convolutions, and especially of the cortex lining sulci, which detract from the value of specimens in a marked degree, are avoided. In the next place, in order that precise orientation and accurate identification of the different sulci and convolutions in the finished sections might be ensured, the lines of cleavage between the blocks were carefully and correctly indicated on the original tracings and photographs. Then the blocks, being numbered, were placed in separate bottles, after-hardened in increasing strengths of alcohol, and imbedded and cut in Celloidin on a Jung Microtome. The sections, of a thickness of 25 μ, were taken at intervals of 1 mm. and preserved in strict serial order between sheets of paper and subsequently mounted and stained; and so in the case of the central convolutions, for instance, sections were obtained showing their structure at about a hundred different levels.

As to the method of staining employed, a lengthy experience of processes for the demonstration of cortical nerve fibres has convinced me, that for a faithful display of the more delicate fibrils, a sharp delineation of the larger fibres and the production of a deep coloration of the myelin rendering the specimen alike suitable for drawing purposes and photomicrography, the method known as that of Wolters-Kulschitzky, although a tedious one, stands ahead of all others in the certainty of its results; and this method has accordingly been adhered to throughout.

Then as to nerve cells, one frequently reads statements to the effect that "no attempt was made to examine nerve cells" in such and such a case, "because the brain had been preliminarily hardened in Müller's chrome solution," but I overcame this difficulty by employing Thionin $\frac{1}{4}$ % as my stain. And in spite of the thickness of the sections I was able to see the Nissl bodies clearly, and, what was more important for my purpose, the cell morphology

and lamination were shown to perfection. I cannot too strongly emphasise the advantage in time-saving and general convenience secured by the possibility of staining first cells and then fibres in successive series of large sections, for apart from the obvious advantage in obtaining a ready comparison between cell and fibre constituents in given parts, it converts a comprehensive investigation of cortical cell lamination from a gigantic and almost impossible task, when small sections are employed, into one of easy accomplishment[1].

In those cases in which portions only of the brain were examined, orthogonal tracings of the various surfaces of the hemisphere were made in the same way, and then small transverse sections of gyri, showing not more than 2 ctm. of cortex, were taken from 50 or 60 different situations. The exact position from which these blocks were taken was again carefully indicated in the tracings. The sections from these blocks were made at a thickness of 15 μ only, and it is from them that the account of the more minute details in the histology of the nerve fibres and cells has been compiled, and the microscopic drawings made.

I am indebted to my colleague Doctor Wilson for nearly all the microscopic drawings which accompany this work, and would say that before deciding on a method of illustration we tested several mechanical contrivances. First, the projection apparatus recommended by Hammarberg, but though we recognised the usefulness of this apparatus in displaying isolated objects lying on a pale ground, such as nerve cells in Nissl specimens, we found that in sections stained for nerve fibres the plexus was too dense and many of the fibres too delicate to be clearly seen; secondly, the distortion of the image given by the drawing apparatus of Abbé, in spite of the employment with it of Edinger's table, condemned that instrument, and finally we selected the eye-piece drawing apparatus of Leitz. Since drawing with the aid of this apparatus is merely a mechanical task consisting of tracing over the image of the structure, reflected on to the underlying paper, it is possible to obtain perfectly accurate drawings free from the prejudicial effect of the personal equation, and it is claimed for the lower power drawings submitted herewith, that the position of every fibre, at any rate, in the outer two-thirds of the cortex, is faithfully shown, and that in the high power figures the calibre as well as the relation of the fibres one to another is accurately represented, and that as regards the cells, size, position and number are faithfully shown.

All the drawings have been made to scale, the low power ones at a magnification of $\frac{80}{1}$, the high power at $\frac{480}{1}$.

It may be asked why photographic representations have not been resorted to, and in replying to this I would say that, while I yield to none in my admiration of the general utility of photography for purposes of reproduction, yet when we come to giving representations of the nerve fibres of the cortex the camera must yield to the drawing pen. To photograph small fields is of course a simple matter, the difficulty arises when an attempt is made to show the structure of the cortex in the whole of its depth in one view, all efforts in this direction are bound to be unsuccessful because a lens which will embrace a view of the whole cortex must be of such low magnifying power as to fail in displaying any but the fibres of large calibre, and the resulting picture is obviously incomplete. Then when a stronger lens which will give a clear and satisfactory view of fine as well as large

[1] By this method the examination of a whole human hemisphere can be accomplished in six months, whereas to go over it thoroughly in small blocks would absorb at least two years.

fibres is substituted, it becomes necessary to take more than one photograph—sometimes as many as four—of the cortex before the structure of the whole depth is completely shown, and the subsequent joining together of the several prints is difficult and unsatisfactory.

There is a strong demand for the reproduction of a series of drawings showing types of fibre arrangement in various cortical regions, not only because our knowledge of cortical fibre arrangement deserves to be placed on an equal footing with that of the nerve cells, but because all the efforts which have been made hitherto in this direction have been of a crude description. Even the plates published by Kaes are no more convincing than diagrams, a figure of Passow's is very rough, in Obersteiner's text-book there is but one exceedingly exaggerated figure of the cortical fibres, a drawing of Andriezen's, compounded from Golgi and Weigert-Pal specimens, is extremely diagrammatic although it has been copied into several text-books, and in Ramón y Cajal's work on the auditory area is the only passable representation of the nerve fibres in a Weigert-Pal specimen of the cerebral cortex, which I have come across, and concerning this drawing we are not enlightened as to the exact part from which it was taken; and this leads up to a point which requires special emphasis, namely, that it is of essential importance in any anatomical or pathological dissertation, illustrated by drawings or microphotographs showing the lamination or condition of nerve fibres or nerve cells in the cerebral cortex, to indicate, by a diagram or a carefully worded description, the precise spot from which the specimen represented was taken, so that if at any time a subsequent worker may wish to examine the cortex, he may take sections from corresponding positions and utilise the illustrations as standards of comparison. It is unfortunate that the beautiful illustrations of nerve cell lamination for which we are indebted to the late Carl Hammarberg fail in this respect.

CHAPTER II.

SOME HISTORICAL AND GENERAL CONSIDERATIONS ON CORTICAL FIBRE ARRANGEMENT AND NERVE CELL LAMINATION.

BEFORE embarking on a detailed consideration of the various cortical subdivisions which histological processes enable us to define, I should like to make preliminary reference to some writings of others who have investigated the cerebral cortex, and whose teachings have done much to smooth my labours; and perhaps as the study of fibre arrangement has been prosecuted with less industry and attracted far less attention than cell-lamination, it will be a gain to punctuate and advance the first and lesser known theme, leaving a knowledge of cortical cytology more or less on trust. Also, future explanations may be saved if a few pages are devoted to a general consideration of the arrangement of cortical nerve fibres and cells.

On February 2nd, 1776, Gennari saw, and described with remarkable exactitude, the "lineola albidior admodum eleganter," in the calcarine region, with which his name is now associated. Vicq d'Azyr, evidently unacquainted with Gennari's writings, redescribed the structure 16 years later. The discovery of this line constituted an opening move in the exploration of that delicate network of nerve fibres which has its seat in the cerebral cortex, but lack of methods of coloration proved an effectual bar to further progress, until Weigert and Exner elaborated their processes for the display of nerve fibres and gave to the neuro-histologist the means for a material advance.

Just as the discovery by Nissl and Golgi of their respective methods for staining the nerve cell, marks an era in the advancement of our knowledge of nervous cytology, so the publication of the above-mentioned processes for the coloration of nerve fibres was a signal for the commencement of a number of brilliant researches on the histology of the nerve fibre constituents of the cerebral cortex, and the result has been an enormous addition to our knowledge of these elements.

Though we owe much to Exner, yet his method has been overshadowed by the superlativeness of that of the Frankfurt professor, and of recent years all workers on this subject, while they may not have adhered to Weigert's original process in detail, have adopted a working technique based on the principles which it embodies, and foremost amongst such investigators must be mentioned the names of Theodor Kaes, S. Ramón y Cajal, Flechsig, Vulpius, Zacher, Passow, Edinger and Vogt.

The work of Theodor Kaes, of Hamburg, on the medullated nerve fibres of the cortex, is such a monument of patient industry, that in a retrospective view of the literature it is entitled to the place of honour. Up to the present he has contributed four papers; the first, a relatively unimportant one, consists mainly of a recommendation of the method of Wolters

—a modification of Weigert's original hematoxylin process—a method which he adhered to faithfully throughout his researches and which I also have adopted. In his second paper he gives details of an exhaustive examination of the brains of two males, aged 18 and 38 respectively, and supplies an excellent account of the developmental differences which are to be met with in the cortex at these two periods of life. An analysis of sections of no less than seven brains forms the basis of his third paper, and in it the appearances presented by the brain of an infant aged one and a quarter years are compared with those in adolescence, the prime of life, and old age. In his final paper, he discusses the cortical nerve fibres in the brains of two idiots. Kaes' method of procedure was an extremely thorough one. The hemisphere for examination was first sliced vertically into 12 blocks of equal thickness; each block was then cut seriatim on a large microtome, so that eventually a series of complete coronal sections[1] of the hemisphere was obtained, displaying the structure of the cortex in every part. The measure of praise which Kaes' labours deserve may be gauged from the fact that he devoted one and a half years' incessant toil to the preparation of sections of each hemisphere examined, but for this, the honour of being the first to have made a survey of the medullated fibres over the whole cerebral surface is some recompense. The expense of reproduction has unfortunately prevented him from publishing the series of drawings, which he has prepared for exhibition at meetings of various German Neurological Societies, and his papers are only illustrated by a few freehand sketches, and some diagrams, in which he attempts to show by means of coloured lines the degree of development of the medullated nerve fibres and their richness of representation in the various layers, etc., throughout the cortex. These diagrams only serve their purpose in a rough manner, for the investigator desirous either of checking the results or of prosecuting further research will find them wanting in precise points of orientation; points which must be so carefully observed in work of this nature, and which an outline drawing of the hemisphere, giving the exact relation of the different types of structure to the fissures, would better afford. The second and most serious criticism which I have to offer is that the lines on which the work has been conducted have been too narrow; in particular, neglect of the underlying principle, that differences in physiological function are probably correlated with variations in structure, detracts from its value in the eyes of those interested in localisation.

S. Ramón y Cajal's recent publications must next be referred to. I understand that the great Spanish histologist has determined to carry his investigations over the entire cortex, but hitherto the German translations of his works on the cortex of the visual, motor, auditory and olfactory areas, respectively, published for the benefit of those who, like myself, are not familiar with Spanish, have alone appeared. But these papers in themselves are of immense value, for with his unequalled knowledge of histological technique as applied to the nervous system, he has made free use of the principles involved in the method of Golgi, Nissl, and Weigert, and has been enabled to give a clearer account of the composition of the cerebral cortex, and a more satisfactory explanation of the physiological significance of the contained nervous elements, than any other writer on the subject. His papers are profusely illustrated, chiefly with drawings from Golgi preparations, and all four are models of scientific thoroughness. When Ramón y Cajal published his work on the motor area, Sherrington and Grünbaum's investigations were not made known, hence he has included the post-central convolution in

[1] Latterly he found it more advantageous to cut the central convolutions in a sagittal direction, *i.e.* at right angles to the fissure of Rolando.

that region. The paper on the visual area deals with the cortex of "the calcarine fissure and its precincts." His researches on the auditory area have been restricted to an examination of the first temporal convolution, and of the Insula, a part which some include in the auditory sphere. The study of the olfactory region embraces an account of the cortical structure and connections of all the subdivisions of the great limbic lobe. In each branch of the investigation the brains of infants as well as of adults were examined, and for comparative study, brains of some of the lower animals were employed. Ramón y Cajal's work shows blemishes similar to Kaes', for although he describes the histology of these parts in a degree of detail which is almost bewildering, he either gives no boundaries at all, or only draws vague lines round the areas which he has examined with such extraordinary minuteness.

Passow, who pays a tribute to Kaes' work and follows his methods, has contributed a useful paper on the nerve fibre supply of the two central convolutions (Ascending Frontal and Ascending Parietal). Removing these two convolutions *en bloc*, he divided them into six equal parts and made serial horizontal sections from top to bottom of each. He states, that proceeding from above downwards, the general fibre wealth of both convolutions gradually increased, reaching a culminating point in the fourth block, it then progressively diminished down to the operculum. He also observed that, in the fourth block, the anterior convolution had a marked advantage over the posterior one in regard to its general supply of fibres. These findings will be criticised later. Two drawings, stated to have been made with the assistance of an ocular micrometer, illustrate Passow's paper, but, being merely composed of a series of vertical and horizontal lines, they are exceedingly diagrammatic.

Another paper on the central convolutions, most instructive from the localisation point of view, was published as far back as 1879, by Bevan Lewis and Henry Clarke. It dealt with nerve cells, and, as I shall mention later (motor area), these observers seem to have been the first to succeed in defining a functional area on histological grounds.

Vulpius studied the tangential or association system of fibres in the cortex, and gave an excellent *résumé* of the literature on the subject available at the time he wrote—1892. He recorded the results of an examination of a number of brains taken from persons of varying ages—new-born child to old age—and the points which he drew attention to were mainly of developmental interest and may be briefly summarised as follows. In the brain of the foetus, born at full time, no medullated nerve fibres are present, excepting in the white substance of the ascending frontal convolution. "Tangential" or association fibres appear in the inner and outer layers of the cortex, at the fourth month, and in the middle layer, at the eighth month. At the 17th year, the development of these fibres is still incomplete, but with the advent of old age they appear to diminish in numerical representation. In criticising this paper, Kaes observes that its value is minimised by the fact that the examination in each instance was so limited—the condition of the cortex being studied in six places only—this condemnation I am compelled to endorse.

Frequently quoted as it has been, I cannot refrain from praising the classical work of the late Professor Meynert, published exactly 30 years ago. Although in that paper he dealt more especially with nerve cell lamination, and in it one recognises the original prints of diagrams, which even at the present day find a place in some text-books on the anatomy of the nervous system, yet his researches did include a study of the medullated nerve fibres,

indeed, he was the first to indicate the existence of a great system of intergyral association fibres, and to his enlightened reasoning we owe much of our present knowledge of this system.

We come next to the researches and the extensive publications of Flechsig on the development of the medullated nerve fibres of the cortex; a work almost as important as his epoch-making discoveries concerning the myelinisation of the spinal cord. After examining many foetal brains, he has arrived at the conclusion that cortical territories may be divided into three groups, according to their term of development.

(*a*) Primordial regions, which become myelinised before the complete maturation of the foetus; in this group are included both central convolutions, the lips of the calcarine fissure, the first occipital convolution, the uncinate gyrus, the internal olfactory convolution, the cornu ammonis, the gyrus fornicatus (especially its middle third), the transverse temporal gyri (gyri of Heschl), and what he calls the supra-angular gyrus.

(*b*) Intermediate areas, which develop one month after birth, and embrace the base of the first frontal convolution, the orbital portion and base of the third frontal convolution, and the gyrus sub-angularis.

(*c*) Terminal areas, in which the fibres assume their myelinic investment later than one month after birth; such regions include the first and second frontal, the inferior parietal and second and third temporal convolutions, and a portion of the gyrus fornicatus. These convolutions, he states, are the ones which distinguish the human from the anthropoid brain.

On developmental grounds, Flechsig now describes 40, instead of 9 originally localised fields, and thinks that further researches will lead to the discovery of even more. This remarkable subdivision of the cortex and the attendant conclusions have been severely criticised by continental workers; Nissl, Muratoff, Dejerine and many others joining hands in indicating that Flechsig has been too sweepingly disregardless of the observations of his brother labourers in the realms of physiology, histology and pathology. I shall have frequent occasion to refer to Flechsig's work in later chapters.

Of researches on cell-lamination one of the most brilliant is that which we owe to the late Carl Hammarberg, a Swedish observer, and to Berger and Henschen who are responsible for its posthumous publication. Although Hammarberg only examined the cortex in a partial manner, that is to say he confined his inspection to pieces taken here and there, every line of his work is stamped with thoroughness and reliability; depending chiefly on cell measurements and cell counts, and sparing no pains, he was rewarded by establishing the existence of many remarkable territorial variations in structure previously unsuspected. The points he made are shown in beautiful and obviously faithful illustrations, and these alone will stand as a lasting monument to one whose early death we all lament.

Finally, I have to mention that Professor and Madame Vogt have for some time been carrying on a most elaborate series of histological observations, in the Neurobiological Institute of Berlin, and I understand that they intend including in their comprehensive programme, an investigation of the cortex, virtually on the same lines as those laid down in the present research. Up to date, their efforts have resulted in the production of an extensive atlas of admirable drawings, demonstrating many points bearing on cerebral myelinisation; but unfortunately the publication of the illustrations has preceded the major—and for me the most valuable—part of the letterpress, so that I have not been able to take advantage of it as much as I have wished. I have also lying in front of me, a

short paper by Professor Vogt, giving the aims of his further researches and containing some excellent microphotographic illustrations[1] of certain types of cell-lamination, for the preparation of which, Brodmann, a worker in the same laboratory, is given credit, and it appears that Brodmann is taking over, or at any rate sharing, the cytological work in this undertaking.

In addition to those mentioned, advantage has been taken of the pathological and histological investigations on cortical structure of the following; Brückner, Kölliker, Edinger, Obersteiner, Goodall and MacLulich, Tuczek, Zacher, Mott, and Schaffer, all of whom have paid attention to the medullated nerve fibres; and of Apathy, Bethe, Donaggio, van Gehuchten, Goldscheider and Flatau, Held, Hoche, Lenhossék, Marinesco, and Nissl, who rank high among those who have advanced our knowledge of neuro-cytology.

A GENERAL CONSIDERATION OF THE ARRANGEMENT OF MEDULLATED NERVE FIBRES IN THE CEREBRAL CORTEX, WITH SPECIAL REFERENCE TO TERMINOLOGY.

Since the nomenclature applied to the fibre constituents of the cortex promises to become as bewildering as the various classifications applied to nerve cell-lamination, it is necessary, in approaching a discussion on the arrangement of these fibres, to have a clear understanding of the terminology employed by previous workers.

Outermost Fibreless Layer.

In sections of the cortex stained for the display of nerve fibres, a shallow, pale, superficial layer, forming a delicate margin, can be invariably seen. In this a few isolated fibres of extremely fine calibre, running in all directions, but chiefly vertically or obliquely, are generally recognisable; Ramón y Cajal suggests that they are collaterals from larger fibres in subjacent layers. The layer owes its pallid appearance to the fact that it is mainly composed of glia cells, and as it possesses little importance, in so far as nerve fibres are concerned, it can be dismissed without further remark.

Zonal Layer.

Synonyms—Tangentiale Randzone, Zonal Fibres, Tangential Band, Plexus Externus, Plexiform Layer, Deckschicht, Lamina Medullaris Externa. These are some of the names which have been applied to a readily-recognised layer of nerve fibres, which is situated immediately beneath the outermost fibreless layer, and envelops the convolutions in bandlike fashion. Following Kaes' lead, I shall refer to this band, hereafter, as the zonal layer, and discard the designation "tangential band" commonly used by writers in this country. That the latter name is expressive, there is no denying, but at the same time the term "tangential" has been applied to the so-called association fibres lying in deeper planes of the cortex, and to avoid confusion it is preferable to dispense with its use altogether. I

[1] These are low power views apparently made with a projection apparatus. They illustrate a few different types of cell-lamination and seem to have been published in justification of the extension of the work.

notice that Ramón y Cajal does not employ the name zonal layer, but speaks of "the tangential and other fibres in the plexiform layer," meaning by the latter the first or molecular cell layer of other authors.

The zonal layer varies greatly in depth, in fibre wealth, and in essential constitution, in different regions; further, its representation varies with the age of the individual. Its outer margin is usually sharp and definite, but the inner limit is often less distinct; and, as Kaes and Ramón y Cajal have pointed out, it frequently rests upon or is succeeded by a thin zone pallid and poorly supplied with fibres. Fibres placed obliquely or vertically, making connection with subjacent layers, are numerous, some of these may be descending collaterals of autochthonous fibres, others ascending axis cylinders of Martinotti cells[1].

It is composed of parallel rows of fibres among which three types may be distinguished, viz. (1) large, non-varicose, distinctly medullated tubes, (2) large, and (3) small varicose fibres, but the large varicose fibres generally predominate, and it is to their presence that the band formation owes most of its distinctness. Ramón y Cajal believes that the largest fibres of all are axis cylinders of cells special to the first layer, and both he and Exner indicate that they are more or less confined to the outer parts of the layer. When we come to discuss regional variations, I shall show that these gross fibres are only present in certain situations.

The fibres of the zonal layer are said to constitute part of the so-called association system, by which we have to infer that their function is to connect, or bring into association, cells in convolutions or parts more or less widely separated from one another; but, as I shall indicate presently, in the case of the precentral gyrus, there is an isolated rich development of the zonal layer quite confined to that gyrus and showing no tendency to spread to convolutions either before or behind, and surely this hardly agrees with its supposed function as an association tract. Kaes likewise questions the associating function of the zonal layer, and points out in addition that the layer is better developed in sulcal walls than on the free surface of gyri. Now in most cases there is little doubt that the fact just stated is a manifestation of condensation, the result of pressure; this explanation, however, will not apply to the precentral gyrus, for here the rich tangential formation is almost as well-marked on the free surface as on the covered part of the convolution; here also, and this is a point which needs emphasising, there is an extremely strong development of all the systems of fibres in the deeper parts of the cortex, and it seems unquestionable that these superficial and deep systems are essentially correlated, and that the zonal band is nothing but an expression or a reflection on the surface of the dense formation of fibres in subjacent parts.

Line of Baillarger.

We will discuss this line next because it constitutes an important stratification landmark in the cerebral cortex. The writer whose name it bears recognised its presence with the naked eye and had little knowledge of its composition.

Roughly speaking, the formation is to be sought about mid-way between the surface and the white substance. In no part of the brain is it better developed than along the calcarine fissure; indeed in this situation no lens or microscope is needed to detect its presence, a fact which did not escape the notice of Gennari and Vicq d'Azyr; but to

[1] Large pyramidal cells of which the axis cylinder, instead of proceeding downwards, turns and runs up to the surface.

avoid confusion, it is important to remember that the line of Gennari or Vicq d'Azyr is nothing but a line of Baillarger exaggerated in the visual or calcarine area.

In certain regions, for instance the superior parietal lobule, the line of Baillarger has the appearance of being reduplicated; the additional streak shows itself at a somewhat deeper level and is, occasionally, the more obvious of the two.

As to the composition of this line, it is, as Exner, Kaes and others have indicated, principally made up of a plexus of delicate fibres of which the individuals can only be followed for a short distance. It is more than probable that the chief components of this plexus are the axis cylinders of small autochthonous cells, but it may also receive collaterals from fibres of other layers. In addition to these delicate elements, fibres of stronger calibre running in all directions, and also a few stout fibres, placed parallel with the surface of the cortex, and traceable for a considerable distance, hold a position in the line and assist in giving it prominence. The latter are akin to long association fibres which run horizontally across the radiations at all levels and really pertain to the association system of Meynert, while the irregularly placed stout fibres seem to be connected with the large external pyramidal cells resident at this level.

Kaes states that age has no appreciable influence on the development and representation of the line of Baillarger, but I gather from Vulpius' remarks that its development proceeds hand in hand with that of the fibres of other layers.

Parts between the Zonal Layer and the Line of Baillarger.

Synonyms — Superradiäre Faserwerk of Edinger, Faserarme Mittelschicht of Vulpius, Meynert's 2nd and 3rd layers (Kaes).

It is difficult to find a name which will designate this part satisfactorily; in position, it of course corresponds with the lower part of the first or molecular layer and with the layers of small and large pyramidal cells, superficial to the granular layer or layer of small stellate cells, and some writers, including Kaes and Ramón y Cajal, wisely describe it, according to its cytological relations, as "the zone corresponding to Meynert's second and third layers of nerve cells," and, cumbersome as it is, this designation certainly possesses the advantage of clearness.

In Edinger's classification it becomes the superradiary network (superradiäre Faserwerk), distinguished from the interradiary plexus (interradiäre Flechtwerk). This is an expressive designation, but one which is not altogether free from objection on account of the varying length of the radiations of Meynert; for in some parts it is true that the radiations do not project above the level of the line of Baillarger, and then a distinct and definite superradiary zone can be determined: but in other regions, notably the temporal, the radiations project far above this limit, indeed, many fibres make for and reach the zonal layer and obviously a supraradiary layer, in the strict sense of the designation, must cease to exist. Still, of the designations for this part, that of Edinger seems to have met with most approval and is coming into general use in this country. I shall therefore adhere to it, but instead of speaking of the supraradiary network, I shall call it the supraradiary layer.

Concerning the nature and arrangement of fibres in this layer; it varies considerably in depth and in fibre wealth, in different parts of the cortex, and at different periods of life; the fibres which it contains are almost all of fine calibre, sparsely scattered, and placed

in all directions, and must be the axis cylinders and collaterals of the small and medium-sized pyramidal cells placed hereabouts. Immediately beneath the zonal layer the fibres are usually least numerous, and the network which they form increases in complexity as the line of Baillarger is approached. As has been mentioned already, the lower part of the layer is penetrated by the upper extremities of the fibres contained in the radiary projections, and these fibres along with the collaterals of axis cylinders of the larger pyramidal cells, add to the richness of the plexus in the deeper levels. I have also mentioned in my description of the zonal layer, that certain fibres, coupled with the name of Martinotti, reached it from subjacent parts, and I may now add, that in their passage through the supraradiary layer these may be recognised by their direct vertical course and by having a greater calibre than the generality of fibres found in this situation.

In addition to the fibres of Martinotti, others of like size but having a horizontal direction are to be alluded to. Such fibres were first noted by Emminghaus, but they are now associated with the names of Kaes and Bechterew and constitute what are known as Kaes' and Bechterew's lines. Kaes' line is not easily identified as such, but has been described as being composed of thick medullated fibres, closely applied to one another, lying at the level where the first and second layers of nerve cells join, and having the nature of association fibres. Kaes has seen his line in many regions and believes that it indicates one of the final phases in developmental organisation. Bechterew's line is placed immediately below the zonal layer and is composed of thick medullated fibres; apparently it is not found in the normal subject, but Kaes has recognised it twice in the brains of Epileptics[1].

Apart from Bechterew's line, the lower part of the supraradiary layer contains a varying number of long, horizontally-directed, coarse fibres, which pertain to the association system of Meynert.

Radiations of Meynert.

The radiary fasciculi, constituting the cortical portion of Meynert's projection system, stand out so distinctly in sections stained for medullated nerve fibres that there is no possibility of confusing them with anything else, hence their nomenclature remains simple.

An analysis of their composition proves that they contain three varieties of fibres, viz. large medullated ones with even contours, coarse varicose fibres and varicose fibrils; and the relative proportion of these varies in different parts of the hemisphere, as does also the stoutness of the individual bundles; and these variations seem to bear a relation to the wealth of representation of large pyramidal cells, the axis cylinders of which descend in the radiations.

We have Kaes' authority for the statement that the radiations are more numerous in some parts of the hemisphere than in others, but my observations have led me to believe that the difference is insignificant and of minor importance.

One constantly finds that the radiations are much shorter and generally more slender in the cortex lining sulci than in that on the free surface, and as Wundt showed they are entirely wanting in the sulci of the brains of some of the lower animals.

Interradiary Plexus.

This designation, for which we are indebted to Edinger, is applied to an extremely intricate and dense plexus of fibres, which exists in the spaces between the radiary fasciculi,

[1] I have seen a modified line of Bechterew in what I take to be the visual cortex of the Pig.

and is largely responsible for the depth of colour, noticeable in the radiary field, when it is examined under a low power of the microscope.

Its constituents bear subdivision into, first, an intricate meshwork of fibres of delicate calibre, the course of which it is impossible to trace for any distance and which are probably collaterals of projection fibres; and secondly, long coarse fibres which run obliquely or transversely and weave themselves in among the radiary bundles. It seems correct to assume that the latter pertain to the association system, and that the term interradiary plexus should be applied and confined to the plexus of delicate fibres.

I shall have occasion to mention that the interradiary plexus is subject to instructive variations in density in different parts of the cortex.

Association Fibres of Meynert.

"Bogen Systeme" or Laminae Arcuatae of Arnold. By this we understand the system composed of fibres of considerable size and great length, situated within the radiary zone, running in arcuate fashion round the white projection and intersecting the radiary fasciculi at right angles. The system is always easy to identify along the floor and walls of sulci and just as difficult to follow round the convexity of the gyrus.

Many writers describe the system as consisting of an external and an internal layer, the latter being named the fibrae propriae of Meynert, but to my mind the differentiation is an artificial one and uncalled for. Along the walls and floor of sulci the fibres form a compact and solid lamina, which it is impossible to split up, and, as Kaes correctly describes, in their course upwards the innermost fibres gradually become incorporated with the radiary fasciculi and so cease to exist as a transverse layer; the outermost fibres, on the other hand, are not interrupted in this manner, but arch in the form of a continuous band round the summits of the radiations at the level of, and above and below, the line of Baillarger, with which they are more or less incorporated.

According to Vulpius the fibres of this system do not attain their full development until after the 17th year, and Kaes states that they are seen at their best in the most highly evolved parts of the brains, but to this I shall return later.

From Vulpius' paper we gather that the fibres were recognised by Remak in 1840, again mentioned by Arndt in 1868, and further described by Exner, Tuczek, Fuchs, Edinger, Vignal, Henle, Meynert, etc., but none of these observers seem to have discovered adequate reasons for gracing the system with a physiological title.

Feltwork or Filz of Kaes.

This may be described as the dense plexiform arrangement along the margin of the white substance, which results from the fusion of the association and projection fibres.

White or Medullary Projection.

This term is employed in describing the appearance which the white substance presents in a transverse section of a gyrus; it of course projects upwards more or less in the form of a sugar loaf.

General Remarks on Cell Lamination.

It is not for me to enter upon a historical narrative telling of studies on cell-lamination, nor to criticise the classifications suggested by Kölliker, Remak, Berlin, Arndt, Meynert, Betz, Bevan Lewis, Baillarger, Golgi, Schwalbe, and others whose names are equally familiar, because that has already formed a theme for the abler pens of Hammarberg and Ramón y Cajal. It is, however, of the greatest importance that there shall be no misunderstanding concerning the different laminae of which I shall write hereafter, and that the classification I propose to follow shall be plainly indicated. Hence for purposes of identification more than anything else, I give the following brief explanatory description, in which histological details are avoided, in order that points of interest from the localisation standpoint may be emphasised. Also, it will clear the ground if I incidentally and summarily point out what layers, in sections stained for nerve fibres, correspond with the various cell-laminae.

The following is the classification and nomenclature to which I propose to adhere, and the lamination is one which is recognisable or definable over almost the entire cortex, the visual and olfactory areas being variants.

Plexiform Layer.
Layer of Small Pyramidal Cells.
Layer of Medium-Sized Pyramidal Cells.
External Layer of Large Pyramidal Cells.
Layer of Stellate Cells.
Internal Layer of Large Pyramidal Cells.
Layer of Spindle-Shaped Cells.

From the above it may be gathered that the thin superficial coat corresponding with the outermost fibreless layer will not be taken into account. It has little cytological interest and is chiefly composed of a fine neuroglial network.

Plexiform Layer. I

The term "plexiform" is borrowed from Ramón y Cajal. The layer is equally well-known as the "molecular" or "first layer." As its cell constituents are small and sparsely-scattered and not displayed to advantage in Nissl specimens, it possesses little value for the student of localisation, and even the variations in depth which it exhibits have to be viewed with caution, for not only do these alter in different parts of one gyrus, but measurements are falsified by the least obliquity of the section.

The zonal layer and the more pallid external part of the supraradiary layer, in sections stained for nerve fibres, are the equivalents of this lamina.

Layer of Small Pyramidal Cells. II

This is sometimes spoken of as the "second layer," but the fuller title is less misleading. Its depth varies in different situations, but is approximately equal to that of the plexiform layer; the lower border, however, is by no means easy to define, and therefore systematic measurements of the lamina are unpracticable. It consists of small elements (average diameter 8—10 μ) of which most are truly pyramidal in form, while some are polymorphous; and though their number is less in some parts than in others, they always have the appearance of being closely-packed, in comparison with the cells of the underlying stratum.

They lie on a level with that part of the supraradiary layer in which the plexus of fibres begins to show an increase in wealth.

Layer of Medium-Sized Pyramidal Cells.

Many authors do not approve of this subdivision. But in almost any part of the cortex, on descending from the layer of small pyramidal cells, an increase in size and a widening of the interval between the individual elements become plainly visible, and the reverse, when we ascend from the subjacent layer; hence it seems justifiable to grant independence to the lamina. Being a very equally represented and constant layer it cannot be made much use of in forming judgment on topographical variations. Also, as its boundaries are elastic it cannot be satisfactorily measured, but it is considerably deeper than the overlying layer of small pyramidal cells. The constituent cells show a progressive increase in diameter from above downwards, but they invariably preserve a uniform elongated pyramidal shape.

The regional variations presented by this layer are unimportant and it corresponds with the supraradiary layer of nerve fibres.

External Layer of Large Pyramidal Cells.

Meynert and others have included this with the foregoing lamina, and distinguished the combination by the term "third layer," but to this I strongly object. True it is that these cells bear a morphological resemblance to those above, but no one will deny that the volumetric augmentation occurs rapidly, nor will it be contended that the increase in bulk is not attended by an equally sudden accession of chromophilic elements (Nissl bodies). Moreover, the alterations in size and to a less extent the variations in shape, exhibited by these cells, constitute one of our most important criteria in dividing the brain surface into different histological territories. But these are points which will be dilated upon when these areas are discussed; for the moment, let it suffice that there are strong reasons for placing the lamina on a separate standing.

The fact that these cells lie on a level with the line of Baillarger and the dense lower part of the interradiary plexus goes to show that they contribute in no small measure to the fibre density of this level, and strengthens the plea for their independent consideration. It might be also noted here, that in those situations where the line of Baillarger is reduplicated, the inner streak coincides with a well-developed internal layer of large pyramidal cells.

Layer of Stellate Cells.

Known also as the fourth layer, the granule layer or Körnerschicht (in Germany), this is another valuable guide to the delineation of histological subdivisions, because it is subject to very remarkable variations in representation. In regions where it is well-developed it stands out plainly under a low microscopic power, in the form of a streak, situated a little more than half-way down the cortex; on further magnification, it is found to consist of closely packed, minute (5 by 8 μ), polymorphous elements, mingled with which a few small pyramidal cells arrest attention. Curiously enough this lamina is best represented in the calcarine cortex, and there lies in association with the accentuated line of Baillarger (Gennari). This observation caused me to start originally with the belief that the layer of stellate cells corresponded in position with the line of Baillarger, and that the two were mutually interdependent. But this was soon proved to be a fallacy, and we now know that if

sections of the calcarine cortex stained for nerve cells be superimposed on ones stained for fibres, the main bulk of the Baillargic line will be seen lying above the stellate cell collection; and in other regions of the brain, a faint, pallid zone, situated immediately below the line of Baillarger, usually denotes the position of this lamina. Furthermore, a reduplicated line of Baillarger is not the outcome of a reduplicated stellate layer.

Internal Layer of Large Pyramidal Cells. V

Sometimes called the "ganglionic" layer, this is another lamina which will claim a large share of interest in later chapters, for its constituents are the subject of most profound and interesting changes in different cortical territories. In fact it seems that these cells play a direct rôle in both motor and sensory functions, that they are capable of serving either as projecting stations for efferent impulses, or as receptacles for incoming stimuli. And although I cannot enter into the question here, it is reasonably maintained by some, that the giant cells in the motor area are the homologues of the "solitary" cells in the visual area; and the homology is capable of extension. The absence or relatively feeble development of these elements in "silent" unknown fields is significant in this connection. It must be mentioned that this lamina is never pure in constitution, it is contaminated by cells of varied shape and size. Its constituents undoubtedly bear a direct relation to the fibre wealth in the radiary zone.

Layer of Spindle-Shaped or Fusiform Cells. VI

The last and lowermost layer is soon dismissed. The shape of its cells is well-expressed by the title. It seems to be a fundamental layer, is represented over the entire cerebrum and does not show pronounced topical differences. As others have pointed out, on the walls and floor of sulci, these cells come to lie with their long axis parallel with instead of at right angles to the surface. Nestling among the radiations of Meynert, a columnar arrangement is commonly forced upon them.

It might be finally pointed out that, if the depth and general appearances of these combined strata be inspected, first on the wall, then on the lip, and finally on the crown, in a section of any individual gyrus, variations will be observed, attributable to influences of compression or expansion in the process of cerebral development, and so, in comparing the cell structure of different gyri or parts, it is essential to confine attention to corresponding sectional parts.

REFERENCES.

Adolf Passow. Ueber den Markfasergehalt der Centralwindungen eines normalen männlichen Individuums. *Neurolog. Centralb.*, No. 6, 1898.

Oscar Vulpius. Ueber die Entwicklung und Ausbreitung der Tangentialfasern in der menschlichen Grosshirnrinde während verschiedener Altersperioden. *Arch. f. Psych. u. Nervenkr.*, Bd XXIII, Heft 3, 1892.

Th. Meynert. Der Bau der Grosshirnrinde und seine örtlichen Verschiedenheiten nebst einem pathologisch-anatomischen Corollarium. *Vierteljahrschr. f. Psych.*, 1872.

P. Flechsig. 1. Neue Untersuchungen über die Markbildung in den menschlichen Grosshirnlappen. *Neurolog. Centralb.*, No. 21, 1898.

2. Weitere Mittheilungen über die entwickelungsgeschichtlichen (myelogenetischen) Felder in der menschlichen Grosshirnrinde. *Neurol. Centralb.*, No. 5, 1903.

Theodor Kaes. 1. Die Anwendung der Wolterschen Methode auf die feinen Fasern der Hirnrinde. *Neurolog. Centralb.*, No. 15, 1891.

2. Beiträge zur Kenntniss des Reichthums der Grosshirnrinde des Menschen an markhältigen Nervenfasern. *Arch. f. Psych. u. Nervenkr.*, Bd xxv, Heft 3, 1893. See also Neurol. Centralb.

3. Über den Markfasergehalt der Grosshirnrinde eines 1¼ jährigen männlichen Kindes. *Jahrbücher der Hamburg Stadtskrankenanstalten*, Bd iv, 1893—1894.

4. Beiträge zur Kenntniss des Markfasergehaltes der Grosshirnrinde bei Idioten mit vergleichenden Rindenmessungen. *Monatschr. f. Psych. u. Neurologie*, Bd i, Heft 4 and 5, 1897.

5. Ueber die markhältigen Nervenfasern in der Grosshirnrinde des Menschen. *Neurol. Centralb.*, No. 11, 1894.

Ramón y Cajal. Studien über die Hirnrinde des Menschen, Die Sehrinde, Heft 1. Die Bewegungsrinde, Heft 2. Die Hörrinde, Heft 3. Die Riechrinde, Heft 4. German Translation by Doctor Johannes Bresler. Leipzig, 1900–3.

C. Hammarberg. Studien über Klinik und Pathologie der Idiotie nebst Untersuchungen über die normale Anatomie der Hirnrinde. Upsala, 1895. (Translated from Swedish into German by Walter Berger and published by S. E. Henschen.)

W. Bevan Lewis and Henry Clarke. The Cortical Localisation of the Motor Area of the Brain. *Proc. Roy. Soc.*, No. 185, 1878.

W. Bevan Lewis. On the Comparative Structure of the Cortex Cerebri. *Brain*, Vol. i. 1879. See also *Textbook of Mental Diseases* by the same author.

O. and C. Vogt. Neurobiologische Arbeiten. Beiträge zur Hirnfaserlehre. Leipzig (G. Fischer), Bd i, 1902.

O. Vogt. Zur anatomischen Gliederung des Cortex Cerebri. *Journal f. Psychol. und Neurol.* Leipzig, Bd ii, Heft 4, 1903.

K. Brodmann. Beiträge zur histologischen Localisation der Grosshirnrinde. *Journal f. Psychol. und Neurol.*, Bd ii, 1903.

St. v. Apathy. Über Neurofibrillen. *Proc. of Internat. Congress of Zoology.* Cambridge, 1898, and other papers.

A. Bethe. Allgemeine Anatomie und Physiologie des Nervensystems. Leipzig (Thieme), 1903.

A. Donaggio. Contributo alla conoscenza dell' intima struttura della cellula nervosa nei vertebrati. *Riv. Sper. di Freniatria*, Vol. xxiv, 1898.

A. van Gehuchten. Anatomie du Système Nerveux de l'homme. Louvain, 1897, and several other papers.

A. Goldscheider and E. Flatau. Normale und pathologische Anatomie der Nervenzellen. Berlin, 1898.

A. Kölliker. Handbuch der Gewebelehre des Menschen. Leipzig, 1896.

L. Edinger. Nervöse Centralorgane. 1896.

H. Obersteiner. Nervöse Centralorgane. Wien, 3 Aufl.

E. Goodall and P. MacLulich. The Condition of the Medullated Fibres of the Cortex Cerebri in Insanity. *Brain*, Vol. xxiii.

Tuczek. Beiträge zur pathologischen Anatomie und zur Pathologie der Dementia paralytica. Berlin, 1884.

Zacher. Ueber das Verhalten der markhältigen Nervenfasern in der Hirnrinde bei der progressiven Paralyse und anderen Geisteskrankheiten. *Arch. f. Psych.*, Bd xviii.

K. Schaffer. Ueber Markfasergehalt eines normalen und eines paralytischen Gehirns. *Neurol. Centralb.*, No. 17, 1903.

F. W. Mott. *Archives of Neurology.* London, Vol. i. and ii.

H. Held. Beiträge zur Struktur der Nervenzellen und ihrer Fortsatze. *Arch. f. Anat.*, 1895, 1897, and 1902.

A. Hoche. Die Neuronenlehre und ihre Gegner. Berlin, 1899.

M. von Lenhossék. Der feinere Bau des Nervensystems im Lichte neuester Forschungen. Berlin, 1895.

G. Marinesco. Recherches sur la biologie de la cellule nerveuse. *Arch. f. Physiol.*, Sep., 1899, and other papers.

F. Nissl. Die Neuronenlehre und ihre Anhänger. Jena, 1903, and several other papers.

E. L. F. S. Brückner. Zur weiteren Kenntniss des Reichthums der Grosshirnrinde des Menschen an markhältigen Fasern. *Monatschr. f. Psych. u. Neurol.*, Bd xiii, 1903.

CHAPTER III.

PRECENTRAL OR MOTOR AREA.

In November 1901, Professors Sherrington and Grünbaum published their preliminary account of some experiments conducted on all the known species of anthropoid apes, and expressed the conviction that previously accepted views on the topographical distribution of the motor area needed extensive modification. The results of these experiments may be briefly stated as follows. Employing unipolar faradisation as the method of cortical excitation, it was discovered that the responsive area was confined to the precentral convolution, and, to a small coterminous portion of the paracentral lobule, on the mesial surface of the hemisphere. The area included the whole length of the precentral convolution, extending over its free width and continuously round into, and to the bottom of the fissure of Rolando.

Obviously the most noteworthy and in fact the fundamental discrepancy between these results, and those of others who have worked in the domain of experimental neurology, is the reversal of the doctrine concerning the activity of the post-central gyrus, for neither did stimulation—even with relatively strong currents—of the cortex of this gyrus excite movements, nor was an ablation of the same convolution, or, I should say, parts thereof, followed by any motor paralysis; moreover, the application of the same method to members of lower ape families was attended by precisely similar results. Another difference, of less importance, is that according to these experiments the excitable area in an anterior direction is much less than the results of previous workers led us to suppose.

A full and detailed account of these extremely important and valuable investigations will appear shortly in the Transactions of the Royal Society, and therein will be found a conclusive and almost incontrovertible array of supplementary evidence in support of the conviction expressed in the preliminary communication.

I have made special reference to this research of Professors Sherrington and Grünbaum, because their results have a very important bearing on the histological studies which form the groundwork of my observations on this area; moreover, I am responsible for the addendum embodied in their publication, which gives a short account of a histological examination of the brains of some of the animals which they experimented upon. This histological investigation I undertook with the object of ascertaining whether the cortex of the parts which responded to electrical excitation could be differentiated from the "silent" parts, by the possession of any distinctive histological structure; and, leaving details for later reference, I may here mention that no small measure of success attended the effort, for I think I was able to prove to Professor Sherrington and Doctor Grünbaum's satisfaction, that it is just as possible to define the motor area on the histological bench, as on the operating table.

A considerable time having elapsed since the completion of the examination of these anthropoid brains, I am now enabled to offer more mature considerations of the results obtained. Further, the experience gained in the earlier work has been made full use of in the more important section of this investigation, namely, the application of these results to the human brain and an attempt to determine the area which in man dominates the motor function.

By way of introducing this subject I would here mention that the employment of similar methods to those adopted in the anthropoid work, that is, the examination of carefully-prepared serial sections of the cortex of the central convolutions, stained on the one hand for nerve fibres and on the other for nerve cells, demonstrates the fact that in the human being a histological area can be defined which corresponds remarkably closely with that existent in the anthropoid cerebrum.

Convinced of the importance of the giant cells of Betz—ganglionic cells of Bevan Lewis—as determinants in the histological definition of the motor area, I have, in addition to the material mentioned in the previous section, made a careful study of these elements in several other normal brains. Then, in further confirmation of the accuracy of the results derived from a study of the normal cortex, I have resorted to pathological material, and in this connection I shall have some interesting remarks to make, first, on the changes found in the cortex cerebri of two cases of Amyotrophic Lateral Sclerosis; and, secondly, on the reactive alterations occurring in the cortex in consequence of amputation of one or other extremity, alterations which have been studied in seven instances.

Points on the Anatomy of the Fissure of Rolando.

Facts to be mentioned hereafter make it clear that the distribution of those elements, on the integrity of which the motor function depends, is directly influenced by the position and course of the fissure of Rolando; in fact, this interdependence seems to be so mutual that anatomical variants in the disposition of the Rolandic fissure are in all likelihood associated with corresponding variations in the allocation of the motor area. This being so it becomes necessary to refer to some structural peculiarities and anatomical variations which may influence motor localisation.

To begin with, it is reasonable to assume that the upper part of the motor area is liable to variations in accordance with variations in the position of the upper end of the fissure, for although, as Cunningham has pointed out, in 60 °/₀ of cases the fissure incises the upper border of the hemisphere and appears on the inner surface, in about 20 °/₀ it only just reaches the upper margin, and in other 20 °/₀ it falls short by an appreciable distance.

Then as to the lower extremity, Cunningham tells us that in 19 °/₀ (a high proportion in my opinion) of cases it forms a connection with the "inferior transverse furrow of the fissure of Rolando," and through this with the fissure of Sylvius. But I do not think that connection has the effect of depressing the motor area, for in such cases an annectant gyrus marks the union of the two fissures and acts as a lower boundary for the motor field, just as the inferior transverse furrow usually lies immediately below the motor area. In those cases, however, in which the fissures of Rolando and Sylvius do not join, the interval separating them is very variable, and the coincident shortening or lengthening of the Rolandic fissure may affect the disposition of the motor elements.

In regard to the superior genu, Professors Sherrington and Grünbaum have already insisted upon its constancy as a divisional landmark between the leg and arm areas; my histological studies also show that there is a curious structural transition at this level; it is therefore important that we should examine the morphology of the flexure closely.

Now, it is a fact known to anatomists, and one which I have verified by the examination of several hundreds of brains and casts which I have placed in the museum at Rainhill Asylum, that when the lips of the fissure of Rolando are drawn apart, a deep annectant gyrus, giving rise to some shallowing of the fissure, is displayed in the vicinity of the upper genu; inspected more minutely, it is found that this formation may be correctly described as consisting of interdigitating gyri, or buttresses, springing from the apposed walls of the fissure, and, in by far the majority of brains, the most constant, the most prominent, and in my opinion the most important element in the formation, is the large bulging buttress on the precentral wall, for the accommodation of which the post-central wall suffers indentation. Occasionally, the frontal buttress is reduplicated by a vertical fissure, but this does not diminish its relative prominence, which is always obviously greater than that of the one or more parietal buttresses with which it interlocks. Studied in its relation to other parts, we notice that it is invariably placed on a level with, or, more correctly speaking, slightly above the superior genu, and, furthermore, there is not the slightest doubt that, at any rate in the human brain, this upper, backward curve in the fissure of Rolando is entirely attributable to the presence of the great precentral buttress, and, when that genu occupies an abnormally high or low position, the buttress is correspondingly changed. Another fairly constant guide to the localisation of the buttress is the hinder extremity of the superior frontal sulcus, which is commonly placed on the same horizontal level and serves as a pointer.

Proving the morphological importance of this buttress, I may further mention that, not uncommonly, it is so strongly developed as to almost reach the surface, and occasionally it rises completely and divides the fissure of Rolando into two distinct and separate parts. The latter condition is regarded by Cunningham as one of "extreme rarity," but this expression does not tally with my observations, for in a routine examination of 1400 brains I have noticed the formation in 13 instances, approximately 1 %[1].

Associated with the extraordinary development of the annectant gyrus, an unusual disposition of adjacent sulci was commonly noticed, but these need not be detailed.

In considering the significance of an interrupted fissure of Rolando it is interesting to learn what happens in course of development, and to hear that Professor Cunningham, after examining numerous foetal brains, has arrived at the conclusion that the fissure is originally laid down in two separate pieces, and that the joining of these two elements is indicated in the mature brain by the annectant gyrus under consideration. Now if this view of the development of the Rolandic fissure be correct, it obviously follows that the presence of the annectant on the surface is nothing more than an expression of the remains of a foetal condition, and this sequence gains in likelihood when it is mentioned that no less than 4 out of the 13 brains exhibiting the anomaly which I have collected were obtained from cases of idiocy and cases in which the gyral disposition followed a simple plan.

[1] Eight of these cases were males and five females, in seven instances the arrangement occurred in the right hemisphere, in five it affected the left, and in one case, a male, it was bilateral.

Next, concerning the representation of this annectant in the ape, by Professor Sherrington's kindness, I have been permitted to examine all the anthropoid brains in his possession, which include specimens taken from the gorilla, orang and chimpanzee. Unfortunately several of these had been hardened for other purposes, and it was therefore impossible to open up the Rolandic fissure without injuring the specimen; still, in every instance in which a view of the fissural wall could be obtained, an elevation was invariably identified on the frontal side homologous with that in the human being; the buttress, however, was relatively slender, and the degree of shallowing which it gave rise to comparatively slight, and in no case was there anything further than a very slight attempt at an interruption of the fissure; I further satisfied myself that it had a constant relation to the upper genu, and that it was mainly responsible for the production of this bend: I also noticed that its position was rather variable, and especially that it had a tendency to slide down the lateral face of the hemisphere somewhat further than it does in the human brain, so that it would be more exact to say that on the average it lay slightly below rather than at the junction of the upper and middle thirds of the fissure.

Cunningham also has observed this buttress in the brains of the chimpanzee and orang, but states that it is not very distinct in the latter.

Not having examined a sufficiency of specimens, I do not feel entitled to give a description of variations in the buttress formation which probably exist in the different members of the anthropoid family: for the present, let the statement suffice that such a structure does exist, and later on, when we consider the histology and function of the part, I may be able to show that the anatomical parallelism is produced by the operation of similar factors in both man and ape. Without further comparative investigation I also withhold an opinion as to whether the interrupted fissure of Rolando is a phylogenetic relic, as well as an expression of imperfect development.

Concerning other annectant gyri or buttresses in the fissure of Rolando, I need only mention that such do exist towards the lower end of the fissure, but they do not require special description; they are not anything like so prominent as the upper buttress, they do not rise to the surface, and they are very inconsistent in both number and position, all apparently due to the fact that they are infoldings of the fissural wall, dependent on the presence of surrounding sulci. Just as these buttresses vary, so also the inferior genu, compared with the superior, is a very unstable element.

It would be interesting to know whether any structure can be defined in animals lower in the mammalian series, which might be considered the homologue of the large upper Rolandic annectant. Physiology has of course suggested that the *sulcus cruciatus* of the dog is the equivalent of the Rolandic fissure, but Elliot Smith has come to the conclusion that the crucial sulcus (not only of the dog but other animals) is the homologue of the upper or dorsal part of the central sulcus, and that the lower or ventral part of the latter is formed either from, or at the expense of, the caudal extremity of the coronal sulcus, in which case the large field between the cruciate and coronal sulci (in the dog) would have to be regarded as the equivalent of the annectant[1].

[1] Since this was written, I have made a complete examination of the brains of Canis and Felis, and, as a fissuret on the hinder limb of the sigmoid gyrus, known as the compensatory ansate fissure, forms a dividing line between Betz cells and what I take to be post-central or sensory cortex, I now regard this element, and not the sulcus cruciatus, as the equivalent of the upper segment of Rolando. (Vide addendum.)

PRECENTRAL AREA.

DETAILED ACCOUNT OF STRUCTURE.

The type of structure present in the "precentral" area is of such a special and distinctive character as to afford an index of the possession by the area of a special function, and I shall now proceed to describe it in detail.

TYPE OF ARRANGEMENT OF NERVE FIBRES. (Plate III. Fig. 1.)

Fibreless Layer.

The fibres it contains are few in number, delicate in calibre, placed in all directions and non-varicose.

Zonal Layer.

The zonal layer is remarkably well-developed over the whole "precentral" area, being recognisable even with the naked eye. It measures about 68 μ in depth, is sharply defined as regards its lower border, and is composed of several layers of closely packed fibres of which delicate varicose fibrils form the predominating element; coarse varicose fibres are, however, present in considerable abundance and evenly medullated fibres of large size are likewise seen. The latter are usually situated along the inner border of the band, and an idea of their frequency may be obtained from the fact that one can generally be found in each high power field of the microscope. In a transverse section of the precentral gyrus it is to be observed that the zonal layer is more strongly developed on the Rolandic side than along the crest of the convolution, and more on the crest than on the anterior side.

Supraradiary Layer.

Compared with other convolutions, the fibre wealth of this layer is great, although to the naked eye it has quite a pallid, almost white appearance. Roughly speaking, the supply of fibres is equally distributed over the layer. The majority of the fibres have a transverse trend, but vertical and oblique ones are present.

The transverse fibres are almost all of fine calibre and varicose, only in the lower parts are ones of larger size noticeable, and in all likelihood these pertain to the association system. Those fibres which are arranged vertically or obliquely are usually of greater size than the transverse ones, but it is uncommon to find a typical large medullated fibre in this layer. Neither a definite line of Bechterew nor a line of Kaes can be identified.

In this layer the superiority of fibre wealth on the Rolandic side of the section is not so pronounced as it is in the case of the zonal layer.

Line of Baillarger.

A line of Baillarger is distinctly difficult to define, but to say that the fibres which constitute the linear formation are not represented would be wide of the truth; a statement, however, to the effect that it is obscured and its elements hidden in the wealth of neighbouring

fibres, meets the case. Thus, examination shows that from the summits of the radiary projections downwards, the cortex is so equally and richly stocked with fibres, that it is almost impossible to break it up into laminae; one can merely say that at or towards the upper extremity of the radiating fasciculi, the plexus seems to be especially rich in small fibres. Towards the anterior wall of the convolution, on the other hand, where the type of arrangement assumes an intermediate character and the interradiary elements become less numerous, a line of Baillarger gains in distinctness.

Radiations of Meynert:—Interradiary Plexus and Association Fibres.

Although the rich supply of fibres in the zonal layer and supraradiary field is a striking feature, it is the extraordinary development of the fibre constituents in the deeper levels which above all gives character to the precentral cortex. Not only is the process of white substance which forms a foundation for the cortex and from which the bundles of projection

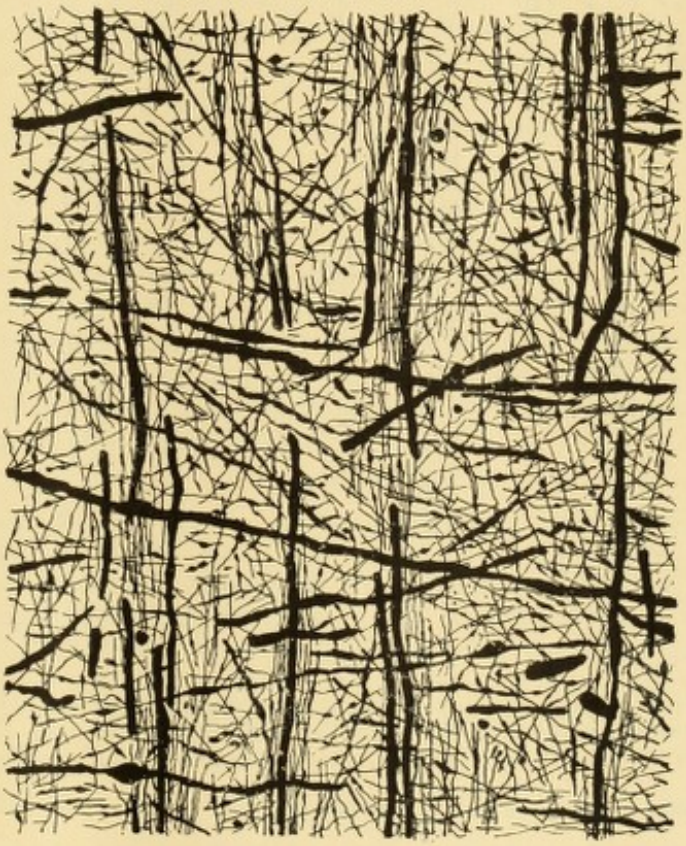

FIG. 1. The radiary zone in the precentral cortex, $\times \frac{850}{1}$.

The extraordinary fibre wealth comes out very plainly in a high power drawing. Numbers of fibres of large calibre are seen both in the radiary bundles and crossing the interradiary spaces. It must be remembered that the portion drawn is about on a level with the giant cells of Betz. Compare with the drawing of the post-central cortex, text figure 5. The fine wavy elements in the radiations and intervening parts are common constituents to be seen in any part of the brain.

fibres radiate, thick and stout, but the zone of substance, the so-called radiary zone, capping that process, is of outstanding depth and richly coloured on account of its immense fibre wealth. Analysing its constituents more closely, we find that it owes its density to a remarkable development of all the systems of fibres which it contains: thus, the large association fibres which intersect the radiations at all levels are more numerous and of greater size than they are in any other part of the cortex; the radiary projections themselves form stout bundles, and are richly stocked with fibres of every calibre, but especially with ones of large size; and the collaterals of axis cylinders of large nerve cells, situated in the deeper parts of the cortex, are very numerous and aid in increasing the density of the interradiary plexus.

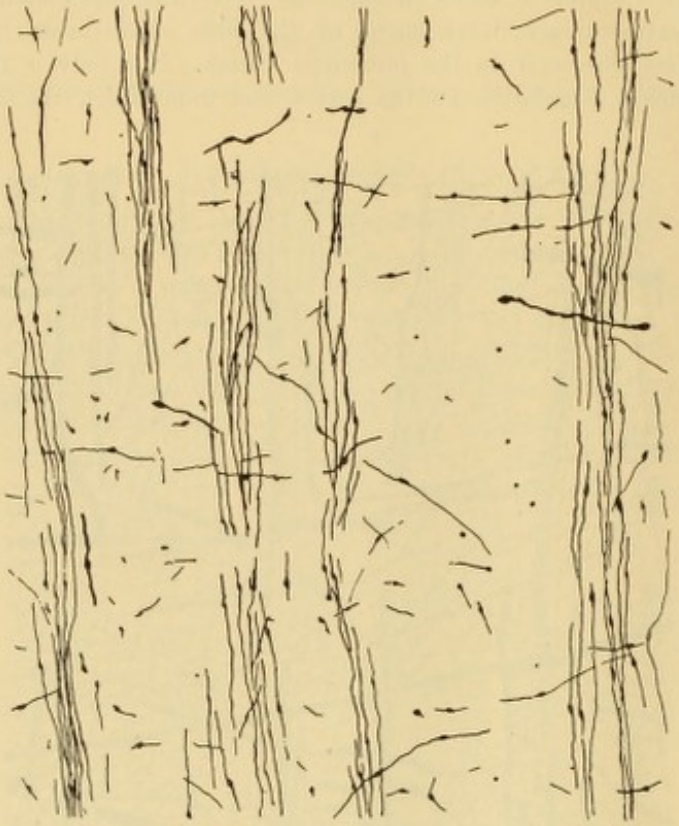

FIG. 2. Radiary zone in the prefrontal cortex at a magnification of $\times \frac{45}{1}\frac{0}{0}$.

Notice that there are absolutely no fibres of large calibre and almost none which we can call of medium-size. The slender radiations are composed of fine wavy fibres, and the interradiary plexus only contains a few of the same elements.

To see two extremes of fibre representation contrast this with figure 1.

Difficulties at once arise when we attempt to attach physiological significance to the individual constituents of the radiary zone; for as the plexus of fibres is such an exceedingly dense one, it is impossible to trace even the larger fibres for any distance: we can only say, in the first place, that physiological experiment warrants the assumption that the majority of the fibres in the radiating fasciculi are endogenous and convey centrifugal

impulses, and, secondly, that the richness of the interradiary plexus is dependent upon the large size of the nerve cells met with in this situation. In support of the latter statement, we have the knowledge that the axis cylinder processes of these giant cells are not only of large calibre, but that their collateral offshoots are numerous, and furthermore, we have a definite statement amounting to a law, from S. Ramón y Cajal, to the effect that the density of the intercellular network is directly proportionate to the diameter of the bodies of the nerve cells present.

Variations in Type of Arrangement in Different Parts of the Area.

It must not be supposed that the type of arrangement just described remains absolutely constant over the whole of the area; on the contrary, certain variations occur of which it is important to give an account.

Disregarding details and speaking in general terms, it must be noted that the point which strikes one most in an examination of seriatim sections is that, proceeding from above downwards, there occurs a gradually progressive diminution in the fibre wealth of all the systems of fibres, and possibly also a reduction in the calibre of the large fibres. Thus, the fibre wealth is seen at its greatest in the vicinity of the upper margin of the hemisphere, while towards the lower end of the fissure of Rolando the cortex assumes an intermediate type of arrangement.

From the foregoing it may be gathered that it is impossible to subdivide the field according to structural variations in such a way as to correspond with the physiological subdivisions: we can only say that in the area, which is credited with the control of movements of the leg and body, the nerve fibre plexus is denser than it is in the arm area; while in the arm area it is denser than in the face and neck area; but there is nothing approaching an abrupt change in fibre richness, or anything in the shape of an alteration in general arrangement, at the lines of contact of the various physiological areas, which will admit of a corresponding anatomical subdivision.

Arrangement of Nerve Fibres in the Precentral Area of the Anthropoid Ape.

I have made an exhaustive examination of this area in the brains of three apes, and compared the sections most carefully with those from the human brain, but have discovered no fundamental difference in fibre constitution, so that the description already given of the human "precentral" area may be applied to the anthropoid brain, with this addition only, that, in the ape, the fibres in general are of distinctly smaller calibre.

Distribution of the Precentral Type of Cortex. (Plate I.)

On the lateral surface of the hemisphere, the area embraces practically the whole of the wall of the fissure of Rolando, and from the lip of the fissure extends forwards over rather more than half of the exposed surface of the precentral or ascending frontal convolution,—the Sylvian opercular portion being excepted,—and, on the mesial surface, it is confined to a small coterminous portion of the paracentral lobule, lying anterior to the fissure of Rolando.

In discussing the boundaries of the area in detail, we will begin with the posterior one. This is perfectly sharp and definite and is soon described, as it is formed by the fissure of Rolando in its whole length, but it is important to note that the cortex under consideration does not extend quite to the floor of the fissure, in any part.

Passing next to the exact limits of the small area on the mesial surface of the hemisphere, we find that the posterior boundary of the field is almost as definite as it is on the lateral surface,—it is marked, namely, by the upper extremity of the fissure of Rolando; and in those cases in which the upper extremity of this fissure stops short of the upper margin of the hemisphere and fails to gain the mesial surface, a peninsula of "precentral" cortex is still carried over, and is then bounded by a line dropped down in continuation with the fissure of Rolando and parallel with the upturned tail of the calloso-marginal fissure. From which it may be gathered, that that part of the paracentral lobule which lies behind the line of the fissure of Rolando is devoid of motor characters, and as a matter of fact it is covered by a totally different type of cortex, which I have designated "post-central." Just as the fissure of Rolando does not, as a rule, descend the mesial surface for more than 1 to 1·5 ctm., so also the "precentral" cortex soon stops short and does not seem ever to extend more than half-way down the paracentral lobule, remaining separated from the calloso-marginal fissure by a fairly broad zone of cortex, in which "intermediate precentral" and "post-central" characters are commingled. The anterior border of the area curves upwards and forwards to reach the margin of the hemisphere at a point 1·5 to 2 ctm. anterior to the fissure of Rolando. (For further particulars vide appendix.)

Turning next to the anterior boundary on the lateral surface, it may at once be mentioned that this is tortuous and does not appear to be influenced by fissures[1], and, furthermore, that the transition from what is taken to be the "motor" to the next type, is much less abrupt than it is posteriorly; indeed, I think it more correct to state that the area showing a "motor" type of arrangement of fibres is fringed by a definite zone in which the formation is intermediate in character.

The points which guide one in determining this line of demarcation are as follows: (1) in the examination of a transverse section of the anterior central convolution from any part, it matters not whether it be from the upper or lower end, if the radiary zone be carefully traced round, it will be observed to suffer a diminution in fibre wealth. This is neither a very distinct nor abrupt change, and a coincident reduction in the depth of the cortex is barely noticeable, but visible and obvious proof of the transition in type is afforded by the fact that the radiate fasciculi begin to stand out with greater boldness, and the general coloration of the zone becomes fainter, appearances which are to be accounted for by the loss of fibres in the interradiary plexus, and also the disappearance of fibres of large calibre. (2) The fibres of the zonal layer thin out and the formation loses its band-like character. (3) The plexus of fibres in the supraradiary field becomes less intricate, and, lastly, if the white substance immediately subjacent to the cortex be inspected, the onset of a less intense purple staining, pointing to an inferiority in fibre strength, will be observed.

[1] To explain the fact that the position of the anterior line of demarcation of the motor area is not influenced or determined by the presence of fissures, while the posterior boundary is, the surmise seems tenable that the elements, from which the motor nerve cells and fibres spring, are deposited, either synchronously with, or after the formation of the "primary fissures," but prior to the development of "the secondary sulci." In accordance with this view the fissure of Rolando, being, as we know, a "primary fissure," forms a fixed boundary, while the precentral sulci, being "secondary" ones, bear an inconstant relation to the area.

The line along which this change of character takes place varies in different brains, but striking an average from the hemispheres which I have examined it may be located as follows; coming over the upper margin of the hemisphere, at a point 1·5 to 2 ctm. anterior to the upper extremity of the fissure of Rolando, it drops vertically downwards to the sulcus precentralis superior, which goes to form a boundary; the "precentral" features do not cross this sulcus, and although in some cases the arrangement does not reach so far forward, the usual thing is for it to just touch the sulcus and extend down the anterior wall for a short distance.

In this, its upper third, the area has its greatest sagittal breadth, for after quitting the level of the sulcus precentralis superior the field in its further course downwards undergoes a progressive narrowing, and thinning away to a point, ceases opposite the lower extremity of the fissure of Rolando. It seems to be uncommon for the area to be limited by the sulcus precentralis inferior, and as a rule, in this situation, the anterior limit runs mid-way down the ascending frontal gyrus.

The downward extent of the area appears to be dependent on the fissure of Rolando; thus in one case, where the fissure of Rolando was a short one, the "precentral" type of cortex stopped a considerable distance above the operculum, while in other cases, where the fissure was of normal length and came close to Sylvius, the area followed suit, so that on the whole we may say that the lower limit is coterminous with the lower extremity of the fissure of Rolando.

DISTRIBUTION OF THE PRECENTRAL TYPE OF CORTEX IN THE HIGHER APES. (Plate II.)

If the human and anthropoid areas be examined side by side, a most striking resemblance will be observed; thus in both, the fissure of Rolando forms a fixed and definite boundary; on the mesial surface the area is insignificant in extent; and, anteriorly, the limits bear a like relation to the precentral sulci. The only obvious point of difference between the two is that the human area, relative to the entire cortical surface, is less extensive than that of the anthropoid, and this only illustrates a fact which others have drawn attention to, viz., that the higher we progress in the animal scale, the smaller does the motor area become, relative to the whole surface.

TYPE OF CELL LAMINATION IN THE MOTOR AREA. (Plate III., Fig. 2.)

As this work deals solely with the topographical distribution of variations in cortical structure, in describing the constituents of the various laminae, I shall disregard minute detail, in order that points of differentiation may be fully emphasised.

Plexiform Layer.

The plexiform layer has an advantage in depth over most other cortical regions. In association with this it is to be remembered that it has to accommodate a heavy zonal layer of nerve fibres, also, that this is a situation in which the apical extensions of the subjacent giant cells ramify and terminate (Ramón y Cajal and Bevan Lewis). In the adult

brain the method of Nissl shows only a few small cells, and although Ramón y Cajal and others have described several varieties in their silver preparations, we do not know what physiological importance is to be attached to them.

Layer of Small Pyramidal Cells.

This is another layer which for us possesses minor interest; its component cells are not so numerous as they are in some other parts of the brain, and the layer they form is neither deep nor sharply differentiated from the subjacent one.

Layer of Medium-Sized Pyramidal Cells.

Although forming a lamina of considerable depth, these cells do not differ markedly from those of the corresponding layer in most other parts of the brain, and they follow the usual rule in growing larger as the cortex is descended. In the depths of the layer small stellate cells are dotted about.

External Layer of Large Pyramidal Cells.

The line of demarcation between this and the last layer is not a sharp one. In shape the cells are distinctly pyramidal or pyriform, and they range in size from 15 to 20 by 25 to 30 μ; in the cell-substance chromophilic particles are certainly distinguishable, but these are by no means so obvious as in the giant cells to be described hereafter; the nucleus is large in proportion to the cell body; even in Nissl specimens a long apical and several basal processes can be distinguished, and, according to S. Ramón y Cajal, the shaft may be seen in silver preparations to reach the surface, while the thick and numerous basal dendrites form a dense and striking plexus; Ramón y Cajal furthermore states that in general shape these cells resemble the cells of Betz, but this comparison is somewhat far-fetched.

The probable importance of these cells in the "precentral" area cannot be denied; at the same time, from the histological standpoint, they do not constitute a distinctive feature, for a layer, similar in almost every respect, may be seen over the extensive area, which I shall describe later as the "intermediate precentral."

The Layer of Stellate Cells.

It is an important distinguishing feature of the "precentral" cortex that the layer of small stellate cells, which we see so constantly and so well-represented in most other cortical regions, is of such rudimentary constitution that it almost defies definition. All we can say in regard to the layer is that it is just recognisable, and that minute elements of stellate or pyramidal form, apparently pertaining to it, may be seen sparsely scattered among the immediately adjacent external and internal large pyramidal cells.

Layer of Giant Cells.

It is these cells, known as the giant cells of Betz or ganglionic cells of Bevan Lewis, or, as the latter observer would prefer to call them, "motor cells," which absolutely stamp this type of cortex and form a certain guide to the territorial demarcation of the area.

As the histology of these cells has been described with perfect accuracy and in full detail by numerous other workers, and, since every neurologist is familiar with their appearances, I need only shortly recapitulate previous observations and mention that their size exceeds that of any other cells to be met with in the whole cerebral cortex; that the word "pyriform" best describes their shape; that they throw off a number of stout lateral and basal processes and hence are deserving of the name "multipolar," which has been applied to them; that their main apical dendron can be traced vertically upwards to the first layer, while their axis cylinder drops directly into the white substance; that the cell body contains abundant large masses of chromophilic material (Nissl bodies); and that the nucleus which is oval in shape is, on comparison with that of other cells, small in proportion to the cell body.

Leaving the distribution, arrangement and topical variations exhibited by Betz cells for later consideration, I may lastly point out that this stratum is not occupied by such cells alone, but that scattered about among them is a goodly number of large pyramidal cells, similar to those seen overlying the rudimentary stellate layer.

Layer of Spindle-Shaped Cells.

This, the last layer, is an unimportant one and not worthy of special description: it contains spindle-shaped, polymorphous, and triangular cells, similar to those met with in the same layer in other regions.

ARRANGEMENT, TOPICAL VARIATIONS AND DISTRIBUTION OF THE CELLS OF BETZ.

It did not escape the observation of Betz, their original describer, that these giant cells favoured a peculiar clustered arrangement, but in a paper by Bevan Lewis and Henry Clarke, published in the Transactions of the Royal Society in 1878, an account of the arrangement of these bodies will be found which lacks nothing in completeness and accuracy and supplies many details which Betz did not touch upon. As a result of the examination of the central convolutions of eight human brains, cut seriatim on a freezing microtome, these two observers concluded that the cell clusters or nests could be further compressed into groups, and these groups of nests were found to favour definite areas, areas the extent of which did not vary very markedly in different brains. From their descriptions and diagrams we gather that the areas were distributed in series over the precentral area as follows: one occupied the "posterior two-thirds" of the paracentral lobule, and contained nests of enormous cells; a second and important group containing perfect and dense clusters of large cells was situated at the broad upper extremity of the precentral gyrus, close to but without the margin of the hemisphere, and was largely represented on the anterior wall of the Rolandic fissure; the third group lay more or less on the free surface of the precentral gyrus, opposite the lower end of the base of the superior frontal gyrus; the next group seems to have been placed immediately above the level of the genu; and after this there came a barren area (evidently on a level with the great annectant buttress previously alluded to); the next group lay immediately below the level of the upper genu, partly on the free surface and partly within the Rolandic fissure, and was the last important group noticed, for, although two others are described opposite the base of the middle frontal gyrus, they are said to be subject to

variations. (The position of these cell groups is roughly indicated by the black circles in text figure 4.) Bevan Lewis and Clarke further pointed out that these cells, be they large or small, lose their nest-like arrangement towards every sulcus, and at the base of the sulcus always form up in an extended single file, spoken of as the solitary type of arrangement.

Although I have acquired considerable familiarity with these elements from a study of the same in cases of Amyotrophic Lateral Sclerosis and Amputation, as well as from a serial examination of the central convolutions from three additional cases, which I have deemed it necessary to make as a control to the results obtained from this pathological material, and which I have carried out over and above my routine examination of the entire cerebral surface, I wish to add nothing to the above-mentioned description of the arrangement of these cells.

Supplementary remarks are, however, justifiable concerning the significance of the topical variations in cell magnitude, number, arrangement, and distribution, which occur along this stretch of cortex, and a question which I am particularly anxious to explain is whether all or any of these variations can be pointed to as the histological expression of an alteration in function, whether, in other words, the different points, where the areas for the control of the arm, trunk, leg, etc., meet, are marked by a corresponding change in histological structure, and it is to an elucidation of this subject that my examination has been particularly directed.

In discussing the question I shall first offer a few remarks on the cell-lamination of the upper precentral buttress. Finding that the cells in this formation could not be studied satisfactorily in transverse sections, as the cortex on the sides of the projection was always cut obliquely and its structure thereby obscured, I removed the precentral gyrus from one hemisphere and examined the Rolandic surface in a series of sections running in a vertical instead of the usual transverse direction. Instructive in other ways, these gave an excellent view of the cell-lamination of the buttress in question, and on the previously-observed relative barrenness of this part as regards giant cells one now obtained proof which was wholly convincing. For in proceeding from above downwards it was noticed that the moment the upper margin of the buttress was reached, the nests of Betz cells, which had been previously rich and numerous, abruptly ceased. While in crossing the buttress it was observed not only that there was a complete absence of nests of large cells, but, also, the solitary individuals present were separated from one another by a distance of 2 to 3 mm. Scattered over the buttress, however, numerous cells were seen, which in regard to configuration and staining reaction certainly resembled Betz cells, but which one hesitated to include in that category on account of their infinitely smaller size. Below the buttress the cluster arrangement recommenced, although the appearances presented by the cortex above were, as I shall mention presently, not altogether repeated.

Histologically, therefore, this annectant can be proved to be an important interrupting barrier, and reference to Bevan Lewis and Henry Clarke's articles on the topographical distribution of the Betz cells discloses the interesting fact that the barren area they describe virtually agrees in position with this buttress.

In discussing the topographic distribution of function in the motor area, I shall have occasion to mention that this buttress probably constitutes one important line of demarcation between physiological subdivisions.

We have next to consider the variations in magnitude exhibited by cells in different parts of this field. That such variations do occur is well known, and the disparities have been carefully dealt with by Bevan Lewis, Hammarberg, Betz, and others. From measurements of a number of cells in sections taken from the fresh unhardened brain and stained by his own method, one which can be highly commended for the purpose, Bevan Lewis has compiled the following dimensional averages: for cells at the upper extremity of the precentral gyrus, 60 μ by 25 μ; opposite the superior frontal gyrus, 45 μ by 20 μ; at the lower extremity of the area, 35 μ by 17 μ. And these measurements may be accepted as substantially correct, and as giving a fair idea of the changes in volume to which the elements are subject.

Not satisfied, however, with the statement which is generally given, that the size of the cells progressively diminishes from above downward, and thinking that the parallelism between the magnitude of the cell and physiological function might be made nearer than it is at present, I have investigated this matter very closely. And, in making a comparison of the cells in various localities, I have not based my judgments on measurements, a method to which there are obvious objections, but on drawings, that is to say, whenever I have seen a cell of which I have desired to ascertain the comparative size, I have always traced its outlines and processes on to paper, with a camera lucida; and in this manner I have obtained a series of figures all made to the same scale, which admit of a correct and ready judgment on both cell-size and configuration. An analysis of my results shows that previous observers are perfectly correct in saying that the largest cells of all are to be discovered on that part of the mesial surface of the hemisphere coterminous with the precentral gyrus. Proceeding from here on to the dorso-lateral surface of the hemisphere, I find that the cells of all the groups which lie above the annectant buttress are also of great size; indeed individual members can be picked out, which are quite as large as any in the paracentral lobule; but, judged as a whole, I venture to say that the cells in the group immediately above the buttress are appreciably smaller than those of the mesial surface, and also that as we proceed outwards there is a gradual, although slight, diminution in the average volume of the cell. On the buttress itself, as I have previously mentioned, the prevalent large cells are pigmies by comparison with the giants above. Below the buttress, where the group formation recommences, we come upon a chain of cells of quite another size, distinctly larger than the prevalent buttress cell, but from 30 to 40 p.c. smaller than those which lie above the buttress. Such cells extend almost to the lower extremity of the fissure of Rolando, and, be it noted, do not lose markedly in magnitude as they descend. Following on these, that is in the lower part of the Rolandic fissure, and also mixed up to a certain extent with the cells of the last mentioned variety, we come upon elements which, although again pigmies in point of size, resemble giant cells in configuration, and in wealth of chromophilic particles.

In explanation of these variations in cell magnitude, I shall, in a later section, produce evidence to support the belief that they may be taken advantage of as a histological basis for determining the exact situation of the different areas of cortex which preside over different muscle groups: thus, I hope to be able to show that the large cells on the mesial surface of the hemisphere control movements of the foot and lower leg; that movements of the thigh and buttock are governed by the groups of cells on the dorso-lateral surface of the hemisphere above the great Rolandic buttress; that the cells of this buttress stand related to trunk muscles; that the groups of moderately large giant cells below this level dominate movements of the shoulder, arm and neck; and, that the smaller cells at the lower extremity

of the Rolandic fissure correspond to the cortical distribution of the facial nerve. If this localisation of the cortical representation of movement be correct, it will go far to explain the significance of the variations in size of these "motor" cells, and especially will it strengthen the thesis expressed in Bevan Lewis' words that "the greater the distance along which a nerve cell has to transmit its energy the larger will that nerve cell probably be"; for the largest cells are exactly those whose impulses have to travel down to the muscles of the lower extremity, those for the arm being quite a third smaller; and while the cells for the control of trunk muscles are so small that doubt is necessarily thrown on the thesis, it must be pointed out that the whole mechanism affecting these muscles is not so highly specialised as that of the extremities; also that the intermediaries in the neuronic chains which govern the trunk, viz. the anterior cornual cells in the dorsal region, are very insignificant compared with analogous cells in the cervical and lumbar enlargements; and furthermore, that the muscles in which the issuing nerve terminates are but slightly removed from their point of origin. That the cells in the face region should be small is also not surprising.

Before dismissing this question I must mention that Dr Hughlings Jackson has promulgated the belief that the magnitude of the cell varies in proportion to the size of the muscle it controls, or as he prefers to call it, "the size of the movement"; thus, the "small movements" of the hand require small cells and the "large movements" of the shoulder large cells. But in my belief this ingeniously conceived principle, tenable in all other respects, fails in one important particular, it fails as regards trunk representation; for I take it that the movements in which the trunk muscles engage are essentially "large movements," and therefore the trunk area should harbour large cells; if, however, my localisation of that area be correct, this is not the case.

Other factors supposed to have some influence on the size of the nerve cell and considered by Bevan Lewis are the age of the cell and the complexity of its surrounding connections, but in my opinion these have little physiological importance. Likewise, some observations of Betz's to the effect that these cells are larger and more numerous in the right hemisphere than in the left, and also that their number is lacking in young individuals, are open to grave doubt.

The Number of Giant Cells in the Precentral Region. (Plate IX.)

Although, at first thought it might seem foolish to attempt an enumeration of the giant cells present in the human motor area, yet on account of the prominent manner in which they stand out in sections specially prepared for their display, this is really not so difficult of accomplishment; and in the case of one hemisphere, of which the central convolutions were cut strictly seriatim in celloidin, I stained and counted the cells in every fifth section which came off the microtome and the resulting estimate of the total number of giant cells I put down as approximately 25,000. Of course it must be admitted that such a calculation can only be roughly accurate, but in compiling it I endeavoured to avoid error as much as possible by including in the count only those cells which showed a nucleus and nucleolus.

To illustrate the numerical display of these cells at different levels in the precentral gyrus, I cannot do better than give a table showing the numbers of cells counted in a series of sections cut at right angles to the fissure of Rolando and taken at intervals of 5 mm. all the way along its course.

TABLE

Upper Extremity of Fissure.....	2 cells	Mesial surface.
5 mm.	19 „	
10 „	30 „	
15 „	32 „	
20 „	30 „	Margin of hemisphere to buttress.
25 „	41 „	
30 „	20 „	
35 „	6 „	
40 „	9 „	
45 „	3 „	Buttress.
50 „	3 „	
55 „	17 „	Opposite middle frontal gyrus.
60 „	5 „	
65 „	10 „	
70 „	11 „	
75 „	3 „	
80 „	4 „	
85 „	4 „	
90 „	0 „	Opposite 2nd frontal fissure.
Lower Extremity of Fissure.....	0 „	

From this table it is evident that the majority of the cells, certainly more than half, reside above the level of the annectant buttress; the barrenness of the buttress is clearly indicated; then, after a long stretch, also relatively poor in cells, it is seen how they rapidly disappear as the lower end of the fissure is approached.

In this enumeration, those small multipolar cells, which I pointed out in the cortex of the annectant buttress and elsewhere, were not taken into account.

Boundaries of the Area containing Giant Cells. (Plate IX.)

The limits of the cortex containing these cells can be soon dismissed, because they tally almost exactly with the boundaries of the "precentral" type of arrangement of nerve fibres, and these have already been given. A discrepancy which must be mentioned, however, is that the fibre area is one or two millimetres more extensive than the cell area; to understand this difference we have only to take note of the size and extensive ramifications of the enormous dendrons possessed by these cells, as well as the numerous collaterals given off by their axis cylinder processes, and also remember that the existence of cells of great size has a marked influence on the fibre wealth of the part and apparently makes its presence felt at a considerable distance.

Looking upon the Betz cells as discharging elements for motor impulses, it would be interesting to know, along what path or channel the current passes when the cortex is stimulated by unipolar faradisation. Three questions arise. Does the current diffuse through overlying strata to excite the cell body directly? Can it be picked up by superficial cells and passed on indirectly? Or, falling upon surface ramifications, is it directly led from these to the apical extension of the cell? This is admittedly a difficult problem, but the last seems to be the most likely hypothesis, and the histological proof of an increase in the size

and number of fibres in the zonal layer above these cells, and of an extension of the fibre wealth beyond the limits of the cell deposit, accords with a physiological fact—one which I do not think I have mentioned hitherto—that the excitory field exceeds the Betz cell area.

In reference to the limits of the Betz cell area on the mesial surface of the hemisphere, and the question of the spread of Betz cells over the contiguous part of the ascending parietal convolution, I think Betz is responsible for the statement, that the distribution of the cells here is not influenced by the upper extremity of the fissure of Rolando, more, that such cells are to be found in the upper sixth of the ascending parietal convolution; but in my opinion, Betz, and others who have followed his lead on this point, are in error. It is not to be denied that remarkably large cells are present in the cortex coating this part, but when we arrive at a consideration of the "postcentral" cortex, I shall point out striking differences between these and Betz cells, I shall also show that a coexistent stellate layer can be clearly defined, and that the fibre arrangement is of a "postcentral" and not of a "precentral" type; and while admitting that at the exact line where the "precentral" and "postcentral types" of cortex join, there is a confusion of cortical elements, I think it correct to say that Betz cells are not to be found in the hindmost part of the paracentral lobule, that is, the part lying posterior to the upper extremity of the fissure of Rolando, and coterminous with the postcentral gyrus.

Since the annectant Rolandic gyrus or buttress is relatively barren as regards Betz cells, it might be supposed that its fibre endowment would be on a similar poor scale, but in point of fact the interruption in fibre wealth, if existent, is not at all obvious.

The floor of the fissure of Rolando is again a posterior limit, and Betz cells can generally be traced down the length of the fissure to within about 10 mm. of the inferior extremity.

The anterior limit is not definitely related to any of the frontal fissures, and, in the lower third of the area, the genuine Betz cells are almost entirely concealed in the Rolandic wall[1].

Cell Lamination of the Precentral Cortex in the Anthropoid Ape.

My remarks under this heading are founded on a full examination of the central convolutions of one chimpanzee, and, in taking my observations I employed thionin-stained duplicates of serial sections of a brain which had been previously made use of in investigating the cortical nerve fibre arrangement. The employment of such duplicate sections proved doubly advantageous, for not only was I able to study the cell characters, but an easy and accurate comparison between the topographic distribution of "motor" fibre formation and "motor" cells was rendered possible.

Disregarding minor differences and confining my remarks exclusively to the large "motor" cells, I find, in the first place, that in the ape's cortex these elements stand out with even greater prominence than they do in that of the human being, a fact which I unhesitatingly ascribe to the comparative smallness and paucity in chromophilic constituents of the surrounding "large" pyramidal cells; for this reason, their number and distribution can be determined with great ease. I might also mention, in regard to configuration, that the typical anthropoid giant cell is more elongated and has more the appearance of an attenuated pear, than the human

[1] Since writing the above I have received a paper published recently by Karl Brodmann and dealing with the Betz cells. Working in Professor Vogt's laboratory in Berlin, he has examined the central convolutions seriatim in Nissl specimens, and although he does not enter into topical variations, he gives the cells a distribution agreeing exactly with that described above.

cell; and in this connection it is of some interest to know that the same morphological peculiarity is to be observed in corresponding cells of the brains of several other mammals lower down in the scale (*vide* Addendum). Furthermore, it is interesting to learn that the clustered or nest-like arrangement of giant cells is a probable index of high development, because this arrangement, although not altogether unrecognisable in the ape, is not nearly so well-exemplified as in man. And here again we have a reproduction of a lower animal characteristic.

In point of size, the human plan is followed, for, in the leg area, larger cells are found than in the arm area; and those in the trunk area are smaller still. I have also noted the presence of particularly small elements, which we might call borderland cells, all along the anterior margin of the area, and were it not for their typical shape and their richness in chromophilic granules I would have hesitated to include them in the Betz cell category.

Taking next their distribution, it is found, in regard to the small giant cell area on the mesial surface of the hemisphere, that man and ape agree perfectly; and in further support of my previously expressed opinion, that the hinder or post-Rolandic portion of the paracentral lobule is non-motor, I can now say that, in this chimpanzee's brain, nothing resembling a giant cell was discovered behind an imaginary line, extended upwards and over the margin, in continuation with the fissure of Rolando.

Again, also, it is observed that that portion of the area lying above the level of the upper genu holds an immense advantage in cell number over other regions, and I also notice that on the convexity of the hemisphere the cells extend further forward on to the base of the superior frontal convolution, and the area consequently attains an appreciably greater breadth than it does in the human brain, in a corresponding situation. On arriving at the superior genu a sudden fall in cell-representation occurs, but the barrenness at this level is not nearly so pronounced as in the human brain, probably owing to the fact that the annectant gyrus is only poorly developed. Immediately after passing the genu a second and more marked reduction in numbers takes place, and down to the lower extremity of the area which we believe to preside over arm movements, and on into the neck area, the cells continue to be scanty. And, lastly, I have to mention that no cells, which can be called true "giant cells" in point of size, are discoverable in the face area.

To illustrate the foregoing, I will here insert a list showing the number of cells counted in successive transverse sections taken at intervals of 3 mm., proceeding from the margin of the hemisphere downwards.

	1.	Section	3 mm.	distant from	margin of	hemisphere.	51 cells.
	2.	„	6	„	„		49 „
	3.	„	9	„	„		60 „
	4.	„	12	„	„		53 „
	5.	„	15	„	„		53 „
Superior Genu.	6.	„	18	„	„		17 „
	7.	„	21	„	„		28 „
	8.	„	24	„	„		13 „
	9.	„	27	„	„		12 „
	10.	„	30	„	„		10 „
	11.	„	33	„	„		15 „
	12.	„	36	„	„		4 „
	13.	„	39	„	„		5 „
	14.	„	42	„	„		3 „
1 cm. above end of Rolando.	15.	„	45	„	„		0 „

The estimated total number of giant cells in this hemisphere is 13,000.

Finally, when the area containing giant cells is compared with that in which a motor type of fibre arrangement obtains, we find that the latter overlaps the cell area to the extent of about 2 mm., and so we have another repetition of the human arrangement.

LOCALISATION EVIDENCE SUPPLIED BY AN EXAMINATION OF PATHOLOGICAL MATERIAL.

A. *The Central Cortex in Amyotrophic Lateral Sclerosis.*

In its clinical as well as its pathological manifestations, Amyotrophic Lateral Sclerosis is essentially a disease of the muscular system and the motor system of neurones, and since a preliminary examination of the muscles, peripheral nerves, spinal cord and medulla oblongata in the two cases affording the material for this branch of my investigation revealed profound alterations, it occurred to me that time spent in making an exhaustive examination of the cortex of the central convolutions might be repaid by the discovery of changes in the cortical neurones which would throw light on the question of motor localisation. In this I have not been disappointed, and, in my opinion, the results I am about to relate constitute the strongest confirmatory evidence yet adduced to support the assumption that, in man, as well as in the anthropoid ape, the elements acting for the direct control of muscular movements are confined to the precentral gyrus and its paracentral annexe, and lie entirely in front of the line of the fissure of Rolando.

On the constancy of changes in the cortical neuronic elements in Amyotrophic Lateral Sclerosis, there seems to be a division of opinion, for some who have examined the brain in such cases have stated that it was free from change, while others have produced evidence to the contrary. Of the positive evidence at our disposal, an observation recorded by Marinesco, of Bucharest, is the first deserving of quotation. In his case the giant cells of the upper third of the precentral gyrus ("im oberen Drittel der vorderen Centralwindung") had almost entirely disappeared, only a few extremely atrophied members remaining. Collections of granular cells could be seen occupying the position formerly held by some of the giant cells, and these were presumed to be glial cells which had absorbed yellow pigment granules. The report next credits him with a half-hearted and ambiguous statement to the effect that the Betz cells in the postcentral gyri were more or less atrophied ("in den hinteren Centralwindungen waren die Betz'chen Zellen mehr oder weniger atrophisch"). The latter statement I do not consider worthy of serious consideration, and in reference to the limitation of the changes in the precentral gyrus to the "upper third," I would mention that in giving accounts of alterations in the giant cells in other conditions, Marinesco exhibits a noticeable tendency to limit the affection to the same division, and he thereby gives one the impression that he denies the existence of Betz cells at a lower level.

Of other findings in the brain in such cases the following may be mentioned. In a case of Mott's, admirably recorded on the pathological side, sections of the central convolutions revealed absence of large pyramidal cells, but it is unfortunately not stated from what level the sections were taken. In a more recent paper by the same writer in conjunction with Tredgold, giving an account of five cases, the condition of the cortex is not specially gone into.

Charcot and Marie noted a disappearance of giant cells from the paracentral lobule.

In addition to these observers, who confined their attention to the nerve cell, others, employing the method of Marchi, have seen degeneration in nerve fibres in the white substance underlying the central convolutions; indeed, Kowjewnikoff, of Moscow, has succeeded in tracing degeneration from cortex to internal capsule.

I have no doubt that other publications could be referred to bearing on this topic, but I hope I have cited enough to show that the occurrence of cortical changes in Amyotrophic Lateral Sclerosis, in some cases, at any rate, is well established.

I can now proceed with the account of the two cases which I have investigated, and to remove doubt concerning the correctness of the diagnosis, I will briefly narrate the clinical and pathological data on which that diagnosis was based.

CASE No. 1.

Clinical History.

J. S., male, aet. 24, was admitted into Rainhill Asylum in March, 1889.

In April, 1898, nine years after admission, it was reported that he was "losing weight and apparently failing in general health," he also complained of vague muscular pains (evidently cramp) and of weakness, but the cause of these was not then discovered. He was kept under observation, however, and, in July, developed the first signs of Amyotrophic Lateral Sclerosis, for in both hands, flattening of the thenar eminence, undue prominence of the metacarpal bones, and hollowing between the same bones on the dorsum of the hand, all pointing to wasting of the thenar muscles and interossei, were noticed.

In October, the wasting had spread to all the muscles of the fore-arm, upper arm and shoulder, the trapezius was likewise affected, and in some of these muscles fibrillary switchings were observed. The head of the humerus and spine of the scapula were beginning to stand out prominently and he was barely able to flex his arm at the elbow or elevate his shoulders. At this period, also, the gait was unsteady, but although the legs were thin in general, no muscle, or group of muscles, could be pointed to as specially affected. The knee jerks were active, ankle clonus present, and wrist tap contractions obtainable. There was no impairment of sensation to touch and pain, or to heat and cold. The pupils reacted normally to light and accommodation, and sight, hearing, smell and taste seemed acute. Examination of the thoracic and abdominal organs brought no positive result.

Six months later—March, 1899—the patient had lost the power to walk, and the atrophy to a further degree had invaded the leg muscles, especially the extensors of the knee and foot, and the reflexes were not so active. There were signs also of an involvement of trunk muscles, but those of the neck were intact.

At this time, the electrical reactions were carefully tested, but unfortunately the details of this examination have been lost, and my notes only contain a brief statement to the effect that there was a moderate diminution of the excitability of many of the leg muscles, while in the case of some of the arm muscles the change had gone on to extinction.

The further history of the case is uninteresting; he remained bedridden and, month by month, as the atrophy progressed, grew more powerless. When addressed he could generally give an intelligent reply, and this was spoken in a clear voice. He wore a drawn, haggard expression, but there was no paralysis of facial or ocular muscles. Not until the later part of his illness did he lose control over his sphincters. He suffered from no trophic lesions at any time and, so far as could be judged, no sensory troubles. Towards the end, atrophy of the intercostal muscles impeded respiration, and on January 29th, 1899, eighteen months after the first muscular atrophy was noticed and the disease positively diagnosed, the supervention of deglutitory troubles brought about a fatal termination.

Autopsy.

The autopsy was made 12 hours after death.

Claw hand existed on both sides, and a rough dissection of the muscular system showed that all the muscles of both hands, fore-arms, and upper arms, including the deltoids, pectorales majores and trapezii, were profoundly atrophied, pale in colour and fibrous; at the same time, wasted as these muscles were, in none of them was it impossible to detect a few remaining strands of healthy tissue. The intercostal muscles, particularly those of the right side, were also wasted.

While the spinal, abdominal, hip and leg muscles were all appreciably attenuated, in none was the affection so obvious as in those of the upper extremity, and one was unable to single out any particular muscle on which the atrophy had specially fallen.

The diaphragm looked normal.

The encephalon weighed 1370 grammes, but no gross lesion of any kind was discovered, either on the surface or on section, and while the gyri in general were attenuated and the sulci gaped somewhat on that account, no special localised atrophy was noticed.

The spinal cord was small.

A great number of peripheral nerves were exposed but none of these showed any alteration, excepting the 6th, 7th, 8th and 9th dorsal of the left side, and the 7th dorsal of the right side, and on the trunks of these, about 4 cm. distal to the posterior root ganglia, were curious oval swellings, from 5 to 15 mm. in length, these swellings were gelatinous in appearance and consistence, and on section did not subside but showed the individual fasciculi of fibres widely dissociated.

No disease of importance was found in the thoracic and abdominal viscera.

Microscopic Examination.

Muscles. Portions of the deltoid, pectoralis major, biceps, opponens pollicis, gluteus maximus, adductor longus, and tibialis anticus muscles were stained by the method of Marchi for the demonstration of acute degeneration, as well as by ordinary methods.

The Marchi preparations were very interesting in proving that muscles like the adductor longus and other leg muscles, which did not show pronounced naked-eye changes, were yet extensively affected, although the change was evidently in an early stage. For, in these muscles, any amount of fibres could be seen blurred and swollen, and thickly dotted over with minute black-stained particles, which, on longitudinal section, ran in parallel rows and are typical of acute degeneration. Of course, in addition to these fibres, many others in a condition of extreme atrophy, practically converted into fibro-cellular material, were noticed.

In the opponens pollicis and some of the arm muscles, the muscular fibre destruction was almost absolute, and even the few fibres which had preserved their shape and volume were in a condition of fatty degeneration. In spite of these very severe changes it was interesting to notice that the muscle spindles, bodies which are supposed to preside over the muscle sense, seemed to be intact. This was particularly noticeable in the sections of the opponens pollicis, wherein at least a dozen of these structures could be counted every time. Of course I am aware that these muscle spindles are more numerous in certain muscles than in others, and that they are particularly frequent in the hand muscles, but I do not think it alters the case concerning their integrity in this condition.

Peripheral Nerves. The most important point gathered from an examination of the ulnar, radial, median, sciatic, popliteal and peroneal nerves was that few or none showed acute degeneration, but practically all gave evidence of atrophy and disappearance of a certain number of fibres, the radial and peroneal being most affected. In the intramuscular fasciculi also, acute degeneration was wanting, but at the same time healthy fibres of any description were hard to find.

An examination of the bulbous swellings on the dorsal nerves only showed the fasciculi widely separated and the spaces occupied by a few leucocytes. In the original state, apparently, the swelling was due to fluid.

The vagi nerves seemed healthy.

Sections of several posterior root ganglia showed integrity of the intraganglionic cells and sensory fibres, but pronounced sclerosis and lack of fibres in the anterior or motor roots.

Spinal Cord. Every alternate spinal segment was examined by three methods, viz. those of Pal, Marchi, and Nissl, for the display of normal fibres, degenerated fibres, and nerve cells, respectively.

The sections stained by the method of Pal were instructive in showing all the tract-changes typical of this disease. Throughout the cord the field covered by the lateral pyramidal tracts, the anterior root zone and the ventral pyramidal bundles presented a pallid look, due to a wholesale disappearance of fibres, and the sclerosis was most marked (although not complete) in the position of the lateral pyramidal tracts. This vast pale area in the lateral columns was fringed by a belt of healthy fibres corresponding to the ventral and dorsal cerebellar tracts. The fine myelinic plexus, normally present in the anterior cornua, was almost unrecognisable.

The anterior root bundles were gravely diseased, their intraspinal course was either obliterated or merely indicated by a line of sclerosis, and the extraspinal fasciculi were almost completely bereft of healthy fibres.

The posterior columns were quite normal.

In Marchi specimens the above-mentioned changes were repeated, and, in addition, the existence of a considerable number of acutely degenerated fibres distributed over the entire pallid area, but especially numerous along the outer margin of the posterior cornu, was disclosed. In the same area numbers of blackened compound granular cells were seen accompanying the blood vessels.

As to cell changes revealed by the method of Nissl, throughout the cord the destruction and disappearance of large anterior cornual cells reached an extreme degree, and in the few cells remaining degeneration could be studied in all its phases.

The cells of the columns of Clarke seemed well-preserved, and also the small group of cells, seen throughout the dorsal region in the lateral projection of the anterior cornu, was intact.

The foregoing much abbreviated account of the examination of the spinal cord shows how severe and complete the involvement of the motor neurones in their spinal course was. Unfortunately the cranial nerve nuclei were not specially examined, but a pronounced and unmistakeable pallor or partial sclerosis of the pyramidal system of fibres was observed in transverse sections of the crus, pons, and medulla, stained by the method of Pal.

Microscopic Examination of the Brain[1].

The examination was confined to the central convolutions of the left hemisphere and the method was as follows.

After prolonged hardening in formalin, 5 °/₀, drawings and photographs showing the disposition of convolutions and sulci on the various surfaces of the hemisphere were made.

The central convolutions were next carefully cut out and divided into blocks, of a size suitable for section on a freezing microtome, and of a thickness of 3 mm. In slicing the convolutions, an effort was made to carry the plane of section at right angles to the fissure of Rolando, and so free the sections from the spoiling effect of obliquity.

For purposes of orientation, the exact position from which each block came was most carefully indicated on the outline drawings or photographs of the hemisphere, and further to prevent confusion when the time for examination of the finished specimens arrived, an exact copy of the portion of the block which remained on the disc of the microtome, after section, was made on paper, and the different landmarks in it indicated.

Eight to ten sections from each block were stained in thionin, ¼ °/₀, differentiated in alcohol, cleared in origanum oil and mounted in balsam dissolved in chloroform.

[1] For the preparation of most of the cortical sections of this, and also of the next case, I have to express my indebtedness to Doctor H. E. Brown, and I have also to thank Doctor A. C. Wilson for his kindness in making a counter-examination of these sections and so checking the accuracy of my own observations.

In this manner serial sections of specimens were obtained, illustrating the condition of the cortical nerve cells of the central convolutions from top to bottom, at intervals of three millimetres.

As to the postcentral gyrus, this is soon dismissed, as nothing marked in the shape of abnormality or disease was detected in its contained cells.

With the precentral gyrus, however, it was otherwise, and the alteration which at once caught the eye was the scarcity of giant cells. Deferring, for the moment, the topographical distribution of the giant cell affection, I shall begin by giving a general description of the appearances. (Plate IV., Figs. 1 and 2.)

In the first place, a shallowness of the cortex was obvious, and, secondly, there was such a disturbance of the general columnar formation, and such a distorted arrangement of the individual cell elements, that it was almost impossible to identify or differentiate the various laminae which normally exist. Indeed, the only laminae which preserved an approximately normal appearance were the relatively unimportant plexiform layer and the layer of small pyramidal cells; and even in the former there was a reduction in depth, probably due to the disappearance of apical dendritic terminations of the giant and other pyramidal cells. A differentiation into layers of the middle-sized and external large pyramidal cells was almost impossible, and the impression was given that most of the latter cells had disappeared, or at any rate been reduced to shapeless, processless masses, no larger than the ordinary middle-sized pyramidal cell. It was also observed that the elements remaining had dropped out of their normal position and lying at all angles to the surface created great confusion of arrangement. Not only was the appearance of a stellate layer wanting, but the position which it should have occupied defied orientation. The large pyramidal cells in the depth of the cortex showed atrophy and distortion similar to that noticed in the external layer.

Coming now to the giant cells of Betz, I have already mentioned that these elements were scarce, but I can illustrate my point better by mentioning the results of a comparison between sections taken from the top of the precentral gyrus in this brain, and ones of the same size taken from a corresponding position in a normal brain. Now for this comparison I purposely chose this part, because it is one in which one invariably finds giant cells in greatest abundance; and whereas an enumeration of the cells in the series of normal sections gave an average of 40 per section, those from the diseased brain yielded a bare average of 5, that is to say, there was a deficiency of 87·5 p.c. Although, as I shall presently point out, there were areas from which the giant cells had entirely vanished, these figures may be accepted as indicating the general average shortage, and, if they err at all, it is on the side of under-representation of the deficiency. In the next place, when we examined the few remaining Betz cells, we found that hardly any would pass the normal standard, and as indications of degeneration or atrophy we noticed a distinct degree of chromatolysis, a dislocation of the nucleus, a swelling of the cell body, and malrepresentation of the dendrites. Further, when search was made for the remains of degenerated cells, nothing could be found excepting some insignificant-looking collections of small round cells, and that these marked the position of pre-existent cells was uncertain.

In addition to these profound changes affecting cell-lamination, coexistent vascular affection is to be mentioned. All over the diseased field the blood vessels were extremely dilated and congested, and hence stood out very prominently, but, in association with this, a slight thickening of the wall was the only condition which could be called pathological.

Condition of the Nerve Fibres.

The nerve fibres were not examined in serial sections, but some of the blocks which showed the cell alterations to perfection were treated with a chrome salt and stained by the method of Wolters-Kulschitzky.

The most manifest change was a general lowering of the fibre wealth. The zonal layer, which stands out so distinctly in the normal condition, was only a shadow of what it should have been (atrophy of the zonal layer in this disease has been previously remarked upon by Mott). The supraradiary field was not much changed. The line of Baillarger was given a prominence it does not normally possess, due to the reduction in fibre wealth affecting subjacent parts. In the radiary zone, the fasciculi of Meynert had not only lost an appreciable number of their large fibre constituents, but exhibited a wavy, collapsed appearance. A numerical deficiency in interradiary large "association" fibres was pronounced, but at the same time many healthy elements remained.

The above changes are interesting concomitants of the nerve cell alterations, and remind me of what I have seen in the cortex of the same area in cases of old-standing capsular lesion, with hemiplegia.

Distribution of the Affection.

Taking advantage of my knowledge of the distribution of the giant cells in the healthy brain, I next instituted a comparison between the normal cell grouping and what I discovered in this case.

Beginning with the small portion of the area found on the mesial surface of the hemisphere, that is, the subdivision containing an extensive group of the largest variety of Betz cells, the important fact was discovered that in the case under consideration quite 85 °/₀ of the cells had been completely swept away, and of the small remainder very few indeed could be described as healthy. It must also be mentioned that the destructive process was equally distributed over the field, and it might here be added that in those sections lying behind the upper limit of the Rolandic fissure, the large cells which I believe to have no connection with the motor area were present in normal numbers and were perfectly healthy.

Passing on to the two very large and important groups of cells occupying the upper extremity of the precentral gyrus on the convexity of the hemisphere we found changes entirely on a line with those seen on the mesial surface, and my only noteworthy remark is that while a few cells persisted in the Rolandic wall, the cell destruction on the exposed surface of the gyrus was practically complete, section after section showing absolutely no giant cells in this situation, and yet we know that, in the normal brain, hundreds of cells are contained in the same part.

At the level of the annectant buttress, and immediately above and below it, a like condition held.

From here down to the lower genu, over a stretch of cortex about 4 cm. in length, block after block was carefully examined and not a single Betz cell found in any of the sections. But a short distance below the inferior genu, at a point about 10 mm. above the lower extremity of Rolando, one suddenly came upon about 4 mm. of cortex where Betz cells

reappeared and looked quite healthy both as regards number and intimate structure. These cells corresponded in position with the very lowest cells found in the normal brain.

Below this level, no pathological alteration was discovered.

To complete the description, I would say that the general interference with cell-lamination, and likewise the vascular changes previously referred to, were constant accompaniments of the Betz cell destruction. Furthermore, the area of destruction along with its accompaniments was sharply circumscribed, that is to say, posteriorly, it did not overstep the floor of the fissure of Rolando, and, anteriorly, it did not extend more than 2 or 3 mm. beyond the normal giant cell limit.

CASE No. 2.

Clinical History.

(From notes kindly supplied by Doctor Guy Wood.)

E. B., a male, aet. 27. Admitted to Rainhill Asylum September 16th, 1897, died June 2nd, 1898.

From information given by his mother, it was ascertained that the patient was of temperate habits, and up to 18 months previous to admission had industriously followed the occupation of a worker in a chemical factory. At that time he began to complain of pains and weakness in the legs, as these continued he was obliged to give up work, and six months later he became bedridden. No definite cause could be assigned for the illness. While in bed, signs of mental disease developed, he became childish in his behaviour and at times was so unmanageable, owing to attacks of excitement, that it was deemed advisable to have him removed to this asylum.

On admission, he was found to be very poorly nourished, weighing only 7 stone 3 lbs. On account of rigidity and apparent leg weakness, he was unable to walk without support. The lower extremities were thin, but no muscle group seemed specially wasted. The knee jerks were brisk and ankle clonus readily obtainable.

Inspection of the hands showed obvious flattening of the thenar eminence and wasting of the interossei muscles, also the fore-arms were thin, and the hand grip weak. The wrist and elbow reflexes could be elicited without any difficulty. The upper arm and shoulder muscles were normal in appearance. The neck muscles were healthy, and he could raise and lower himself in bed without trouble.

There was no facial, ocular or lingual paralysis. Speech also was unimpaired. Sight, smell, hearing and taste were acute, and he was normally sensitive to touch, pain, heat and cold.

Mentally he seemed childish and made incoherent replies to questions, and he alternately laughed and cried for no obvious reason.

Three months later, the condition had become aggravated, the hands were fixed in the claw position; the shoulder muscles, particularly the deltoid and pectoralis major, were attacked, and the legs were more wasted but less rigid. Mentally he was dull and listless, and he exercised no control over his bladder and rectum. He went from bad to worse and eventually lay in bed almost completely paralysed. Nine months after admission, and two years and three months after the commencement of the illness, an attack of pneumonia hastened his death.

Autopsy.

The autopsy was made 15 hours after death, but permission could only be obtained to examine the central nervous system. The marked general emaciation was not associated with any trophic lesions.

Surface inspection of the muscles left no doubt on the question of wasting, but it was noted that the leg muscles were more involved than those of the arm, and that the extensor muscles on the front and side of the lower leg, and the extensor muscles of the knee were particularly attacked. In each hand the thenar eminence was markedly flattened, prominence of the bases of the first metacarpal bones was pronounced and there was a distinct degree of clawing. Then, although wasting of the fore-arm and shoulder muscles was obvious, the biceps and triceps were fairly well represented.

The cerebro-spinal fluid was increased in quantity. Distinct thickening and oedema of the pia-arachnoid was evident, but it was free from undue opacity.

The encephalon weighed 1178 grammes, the right hemisphere, unstripped, 495 grammes, the same hemisphere, stripped, 455 grammes, the left hemisphere, unstripped, 493 grammes, the cerebellum, along with the pons and medulla, 152 grammes.

These weights are obviously not up to standard, and in accordance with this it was further noticed that the convolutions in general were wasted and that the cortex was pale and thin, but, at the autopsy, no special atrophy localised to the precentral gyrus was recorded.

Microscopic Examination.

Sections of the spinal cord taken from a number of different levels, and stained by the method of Pal, showed partial but not complete sclerosis of the direct and lateral pyramidal tracts in the whole of their course, but the extension of the sclerosis to the anterior root zones was not so marked as in case No. 1.

The anterior cornual myelinic plexus was reduced in density. An examination of the anterior cornual cells, in carmine preparations, revealed a pronounced numerical deficiency. Marchi preparations disclosed the existence of a few acutely diseased fibres in the pyramidal tracts, of many in the anterior root zone, and of a few in the issuing anterior roots.

The posterior columns and sensory roots were normal.

A similar sclerosis of the motor tract was observed in the crus, pons and medulla, but there was less acute degeneration.

Judging from the appearances of the spinal cord, it might be said that, in this case, the morbid process generally was in a less advanced condition.

Microscopic Examination of the Brain.

The method of examination was identical with that adopted in case No. 1, and as the changes discovered are on all fours with those previously observed, we can proceed at once with the feature of most importance, namely, the topographic distribution of the Betz cell destruction. Commencing again with the small area on the mesial surface of the hemisphere, we found an almost complete absence of giant cells and it was obvious that the destruction was even greater than it was in case No. 1.

On the free surface of the convexity of the hemisphere, it was again noticed that absolutely no cells remained, but on the wall of the Rolandic fissure, especially in that part lying immediately above the buttress, a few cells were discovered—three or four per section—of which some were healthy and others diseased.

Some of the small Betz cells peculiar to the buttress remained, and also, in three blocks immediately below the buttress (9 mm. of cortex), a fair proportion of giant cells could be seen, but the majority were distinctly degenerated.

Then followed several blocks in which there were no giant cells whatever, but on arrival at the level of the lower genu they reappeared and resumed their normal state.

In this case there was a repetition of the accompanying general cell disturbance, but the vascular alteration was not so obvious; again, also, the postcentral lamination was undisturbed, and, in the anterior direction, the changes did not transgress the Betz cell boundary to any extent.

Summary.

Summing up these observations, we see that in two typical cases of Amyotrophic Lateral Sclerosis a thorough examination of the cerebral cortex has disclosed extremely interesting and very remarkable changes, changes absolutely confined to the area over which the cells of Betz are distributed, and consisting chiefly of a destruction and removal of the cells named. In each case the general nature of the alteration was alike, both as regards the severity of the destruction and its distribution; only a few cells remained quite undisturbed, at the lower end of the area, in the first case, while in the second, considerably more untouched cells persisted and were found chiefly in the neighbourhood of the great annectant gyrus.

The concurrence of these remarkable alterations with clinical phenomena, pointing to an affection of muscular and motor systems solely, is, in itself, a matter of great pathological interest, and one which provides food for reflection on the pathology and especially on the question of the starting point of the mischief which is at the bottom of this disease. In an anatomical paper, however, it would be out of place to open a discussion on this question, and we can well avoid it because from our standpoint, as students of localisation, it is more interesting to find that these changes are absolutely limited to the area which recent experimental and these histological researches point to as the correct motor area. Indeed, I feel quite convinced that the facts disclosed by an examination of the brains in these two cases can be held up as the strongest proof we can produce to the effect that in man, as in the anthropoid ape, the motor area lies anterior to the fissure of Rolando, and that we have been completely in error in believing that the postcentral gyrus shared the motor function. Not least in importance is the point that these observations invest the position held by the Betz cells as heads of the primary motor neurones with a definiteness and security stronger than that offered by any previous observation.

Although, with such definite results before us, it is a matter of slight moment that others have stated that they have failed to find any cortical changes in cases of Amyotrophic Lateral Sclerosis, I cannot refrain from expressing the opinion that that failure has been due to lack of knowledge of the anatomical disposition of the true motor elements; and if, as is most probable, portions only of the cortex were looked into, the probability of a misconception would be increased tenfold, because, in the first instance, one knows from one's own experience how easy it is, in removing a portion of the precentral gyrus for section, to miss the part containing motor elements, and secondly, in accordance with previous doctrines, the integrity of cells in the postcentral gyri might readily have been mistaken for normality of the motor zone; and even if healthy Betz cells were found in isolated localities it does not follow that this was their condition all over the field. Of course the corollary is, that to obtain an accurate and convincing record of the cortical changes in such cases, it is essential that the motor area be examined from end to end, and until by such examination we derive a great deal more information than we at present possess, the results of piecemeal work must be taken no notice of.

B. *The Cortex in cases of Amputation of Extremities.*

On running through the literature dealing with the changes in the central nervous system of individuals who have been disabled by amputation of one or other extremity, records of several cases will be discovered in which the observers claim to have seen a naked-eye atrophy of portions of the central convolutions, and the presence of these changes has even been advanced to support physiological findings and throw light on the question of cerebral localisation. I need hardly say, however, that observations of this nature are unreliable, and if any doubt on the point still remains, I may mention that I have now had the advantage of inspecting quite a large series of hemispheres from such cases, 22 to be exact, and in none have I been able to satisfy myself of the existence of a definite, localised, macroscopic atrophy which could be referred to the amputation; and as a matter of fact one knows now that although the microscope brings to light histological alterations in certain elements in such cases, these changes are decidedly not so gross as to occasion a positive macroscopic shrinkage of the gyrus.

Therefore, I cannot help thinking that the observers referred to, paying too little heed to the general instability of gyral conformation, have mistaken natural localised attenuations of convolutions for atrophy. The correctness of my assumption gains in probability from the statement made in more than one of these records that microscopic examination yielded no confirmation of the apparent atrophy.

Now, as to my reasons for examining the brain in cases of amputation, and the nature of the resulting change which I expected to find therein, it may be explained that it is a long-known and well-established fact that in consequence of such a lesion alterations occur in the spinal cord, and these in course of time occasion striking and characteristic appearances. In long-standing cases the predominant change is a homolateral atrophy, represented by a general reduction in volume of white and grey matter alike, and involving those particular segments of the cord which receive and give off the sensory and motor nerves which originally supplied the skin and muscles of the amputated member. Wasting of the grey substance is accompanied by a numerical reduction of its contained nerve cells, both large and small, and while all the cell collections in the anterior cornu suffer, one special group may be singled out as being specially prone to atrophy, namely, the postero-lateral. As to the white substance, it is a remarkable fact that in spite of this cell atrophy, the pyramidal tract, beyond being reduced in size, does not exhibit any marked change in staining reaction, and only a very minute fraction of the well-known sclerosis which we see left in it by a previous descending degeneration.

Arising from the discovery of these cell changes in the anterior cornu in cases of amputation, a vigorous investigation of the whole subject concerning the reaction following interference with the motor neuronic system, either by section, excision or evulsion of nerves, has been carried out from the experimental side, and of the many workers in this field, Homén, Marinesco, Lugaro, van Gehuchten and Warrington may be specially named.

A title which has been applied to the various changes which have formed the subject of these studies is "retrograde degeneration," but expressive and suitable as this designation

is, it is only fair to Gudden to mention that he, many years ago, initiated a number of valuable researches in the same direction, and that the form of atrophy, which many still associate with his name, and which formed the keynote of his work, is identical with the change we are now considering. As other writers have reviewed the whole subject of retrograde degeneration, a histological account is not called for here; nor is it necessary to consider anything further than the change as it affects the nerve cell. This change is perhaps best known by Marinesco's name "réaction à distance," and it differs from the Wallerian reaction in ascending the physiological stream of conduction and affecting the cell at the central end of the cut nerve, instead of descending and attacking the peripheral end. The condition is described in Marinesco's words as follows.

"La première altération, après la section d'un nerf, est la désintégration ou, comme je l'ai appelée, la chromatolyse des corpuscules chromatiques.

Cette lésion commence tout près du cylindraxe. La chromatolyse peut gagner tout le corps de la cellule nerveuse, mais, une chose essentielle à noter, c'est que le noyau qui, à l'état normal, occupe le centre de la cellule, émigre à ce moment vers la periphérie.

Quand la plus grande partie de la substance chromatique est ainsi désintégrée, le centre de la cellule présente un fond plus ou moins uniforme dans lequel sont disséminées de fines granulations.

Cette désintégration de la substance chromatique permet quelquefois d'entrevoir dans le cytoplasma un réseau trabéculaire, qui n'est autre chose que la substance achromatique, organisée, c'est-à-dire celle qui se continue directement avec les fibrilles du cylindraxe.

Les modifications de réaction à distance que je viens de décrire peuvent, dans une deuxième phase, rétrocéder, et la cellule récupère un aspect normal; cette deuxième phase est la phase de réparation. Pour connaître exactement ce qui se passe dans la cellule nerveuse pendant la phase de réparation, il faut laisser les animaux vivre pendant un, deux, trois ou quatre mois. On voit bien alors que la cellule, avant de revenir à son aspect normal, presente une hypertrophie considérable, qui s'accroît jusqu'à 90 jours après la section, et qui intéresse à la fois le volume général de la cellule et celui des éléments chromatophiles. Ceux-ci acquièrent de grandes dimensions, se colorent d'une manière plus foncée; ainsi la cellule présente, d'une part, une augmentation de volume, et d'autre part, une coloration plus intense."

The "phase de réparation" last-mentioned seems to be a manifestation of nerve reunion; for in accordance with our experience of the changes in the human spinal cord in cases of limb amputation, destruction and total disappearance seem to be the final ending of the affected cell, and I make this statement in full knowledge of the controversies which surround the question.

Without differing materially from the above, the accounts given by others show that this reaction varies considerably in accordance with different conditions, for example, the age and variety of the animal experimented with, the nature of the lesion and its distance from the centre.

So far I have only alluded to the change as it affects cells in the spinal cord or cranial nerve nuclei; I have next to mention that changes of an analogous description have been found by Marinesco, and others, in the cortex cerebri; and, what is to us of more importance, such alterations have been observed, not as a product of experiment in lower animals, but as a result of natural lesions in the human being. In the first place, Marinesco examined the Rolandic area in six cases of hemiplegia, due to more or less old-standing lesions of the internal capsule, and, in the paracentral lobule, on the same side as the destructive focus, he invariably found alterations confined to the giant cells. These he describes as follows.

"Ces cellules, très atrophiées, ne presentent pas la moindre trace d'éléments chromatophiles. À l'intérieur du protoplasme, on voit une masse, variable comme étendue, constituée par le soi-disant pigment de la cellule nerveuse. Parfois, lorsque le pigment occupe tout l'intérieur de la cellule, celle-ci se présente sous l'aspect d'un bloc jaunâtre dépourvu presque complètement de prolongements, ou bien n'en possédant qu'un, deux, trois tout au plus, et étant aussi très courts. Le noyau et le nucléole sont très atrophiées et occupent, tantôt l'extrémité supérieure, celle qui regarde vers la surface du cerveau, tantôt la base, ou même encore l'un des prolongements."

"La vésicule nucléaire, réduite de volume, présente une membrane à contour plus ou moins irrégulier, repliée parfois sur elle-même; le nucléole, très-pâle, est petit, et d'autres fois au contraire bien coloré. Sa forme est variable, rond, ovale, réniform."

"Les prolongements protoplasmiques ont disparu à peu près complètement; ceux qui restent sont amincis, effilés et très courts. Le cylindraxe présente les mêmes altérations et sa colline d'origine est peu apparente."

While Marinesco figures and evidently attaches much importance to this condition, he is unable to tell us in exact terms how long after the initial lesion it appears, and also how long it lasts; the only information he supplies is that in his cases of old-standing lesion the giant cells had entirely disappeared, and that in one case of capsular destruction of nine weeks' duration signs of reaction were already apparent.

In concluding the paper containing these observations Marinesco generously credits von Monakow with the prior discovery of similar changes, he also mentions that Dotto and Pusateri obtained like results in the examination of a brain showing an old capsular lesion, and that Ballet and Faure produced similar effects by experimental section of the motor projection fibres in their cerebral course.

That changes of this kind should occur in the motor cells, in cases of severance of their axons at a point so little removed as the internal capsule, and that they should supervene rapidly, is only what we might expect, but the result of Marinesco's next series of observations is more remarkable. He examined the Rolandic area in six cases of lesion of the spinal cord with secondary descending degeneration of the pyramidal tracts, the duration of the disease varying between 4 and 24 months, and in every case similar alterations were found, affecting the giant cells in the upper third of the precentral gyrus and paracentral lobule. In those cases in which the disease had only lasted a few months, early signs of "réaction à distance," viz. simple swelling of the cell body, central chromatolysis and slight nuclear dislocation, were alone observed, but in cases of older duration the alteration was much more pronounced and actual atrophy of the cell body was seen. Further, in a case of syringomyelia with descending degeneration, which had been going on for several years, in addition to atrophy, a distinct reduction in number of the giant cells had occurred. In none of these cases were cells seen exhibiting the phenomena of reparation.

Reviewing the situation as it now stands, we find that "réaction à distance" has been seen in the giant cells of Betz in consequence of severance of the axonal prolongation, either in its encephalic or its spinal course; it may also be stated as a law, that the intensity and precocity of the reaction vary according to the position of the neuronic interruption, being greater, for instance, when the lesion is in the internal capsule than when it occurs in the spinal cord.

In all the conditions mentioned in the preceding paragraphs, we have had to deal with an interruption of the primary motor neurone, that is, the connecting link between the cortical motor cell and the anterior cornual cell of the spinal cord; and not only may we say that

the occurrence of retrograde degeneration of the central portion of the divided neurone is an invariable and necessary sequence, but also the change in these cases is on all fours with that which affects the anterior cornual nerve cell and the central portion of the peripheral nerve standing in connection with it, after a section such as occurs in an amputation; the only difference being, that in the latter instance we have to deal with an interruption of the second instead of the first link in the neurone.

We have now to enquire whether the retrograde degeneration, initiated in the second neurone by section of the peripheral nerve, can overstep the anterior cornual cell, and, proceeding along the primary neurone to the cortex, cause degeneration of the presiding body; in other words, whether, in the case of the cortical motor element, suppression of the discharge of energy which it elaborates, by division of the second link in the neuronic system, results in corporeal disintegration. I think we can prove that it does.

So far as I am aware, Acquisto and Pusateri, working in conjunction, and Peli are the only observers who have recorded positive post-amputation changes in the cortex cerebri, and as their findings are of great importance, I shall quote their cases.

(1) Acquisto and Pusateri's case concerned a man, act. 48, who 29 years previously had had his left thigh amputated through the upper third. Serial sections of the central convolutions do not seem to have been made, but a careful microscopic examination revealed the following changes: "In tutte le sezioni appartenenti al terzo superiori delle circonvoluzioni rolandiche di destra, notavansi delle alterazioni notevoli nel terzo strato della corteccia cerebrale. Le grandi cellule piramidali erano in grandissima parte scomparse, rari erano gli elementi superstiti."

"Di questi alcuni si presentavano normali, in altri invece, e questi erano in maggior numero, notavasi un fatto assai caratteristico. Per lo più nella parte basale della cellula osservansi delle grosse zolle formate da globuli giallastri fittamente stipati gli uni agli altri di aspetto vitreo (vescicole globulari di Colucci). In corrispondenza di queste vescicole globulari e per un certo tratto attorno ad esse la sostanza cromatica presentavasi disgregata in piccoli granuli mentre era normale in tutto il resto del corpo cellulare."

In this description it will be observed that no reference is made to the cells of Betz, but I take it that the "grandi cellule piramidali nel terzo strato" are their equivalents.

(2) The second case is quoted by Acquisto and Pusateri but is from the pen of Peli, another Italian. It is stated that it showed confirmatory changes.

Now although not so fully recorded as one would wish, these cases suffice in the first place to indicate that post-amputation alterations may arise in the cortex, and I can now remove all doubt on the point by stating in positive terms and from my own experience that changes do occur. For during the past few years I have obtained and examined the brains of seven individuals, disabled for a varying period of time by amputation of one or other extremity, and in none have I missed finding microscopic changes, akin to, if not absolutely identical with those to which Marinesco has given the name "réaction à distance."

Not satisfied with the mere discovery of the cortical change, I have proceeded further and exercising every caution mapped out its exact distribution, as a result of which I am now able to advance some evidence which is specially valuable in enabling us to effect a differential or divisional localisation in the motor area, evidence which at any rate enables us to put our finger on the spot where the cells for the control of arm and leg

movements lie; and, having gained this much information, we can, from our knowledge of localisation in the anthropoid brain, form a fairly correct idea concerning the disposition of cells controlling other movements.

And provided sufficient care be exercised in the examination of such material, there seems to be no method applicable to the human brain, with the exception of electrical excitation of the cortex, and chances for practising this rarely occur, which is better adapted for purposes of precise and correct localisation. Comparing it for instance with other means to localisation, it of course cannot be denied that we have derived valuable information from a clinical study of the effects produced by natural lesions, such as cerebral softening, cerebral tumour, traumata, etc., but it is equally true that the proportion of cases in which any of the above-mentioned lesions have been so limited in extent and so pure in effect, as to admit of a precise judgment concerning delicate points in differential localisation, is exceedingly low. Given, on the other hand, a case of section of the nerves supplying even a single group of muscles, for instance, the extensors of the foot, I maintain that it would be quite possible from a careful examination of the cortex and a study of the resulting "réaction à distance" to determine the exact distribution of the motor elements, on the integrity of which, movements of that particular group of muscles depended, and, by collecting and examining a selected series of similar cases and collating the results with the findings of the physiologist, the clinician, and embryologist, we may eventually hope to draw on the surface of the human brain a detailed map of motor localisation, so definite and so exact, that it will not require alteration and revision at the hands of our successors.

Method of Examination.

In case No. 2, the brain was hardened in Orth's solution and the entire Rolandic area cut seriatim into sections, 15 μ in thickness, and every fifth specimen was stained with thionin and examined. In the remaining instances, the brain was hardened in formol and the method for the examination of the brains from the cases of amyotrophic lateral sclerosis followed[1].

CASES OF AMPUTATION OF THE LOWER EXTREMITY.

CASE No. 1.

The first case I have to record is that of a female, aet. 67, whose left leg had been amputated at the knee joint; the date of the operation was not ascertained and is merely indicated in the clinical notes to which I have had access by the remark "some years."

Both hemispheres were examined, and whereas the left was normal, no difficulty was experienced in defining an area of degeneration in the right.

In those sections of the affected hemisphere which passed through the small area of motor cortex, on the mesial surface, and also the coterminous portion of the same field, at the margin and on the convexity

[1] In the examination of two of these hemispheres I was fortunate in securing the cooperation of my two colleagues, Doctors A. C. Wilson and H. E. Brown, and it was a great source of satisfaction to obtain by this means an independent confirmation of the correctness of my results, for following my methods, these gentlemen, in both specimens, easily recognised the characteristic cell changes and succeeded in mapping out fields which agreed, in the minutest particular, with the ones I had defined.

of the hemisphere, cells were seen, which we had not the slightest hesitation in calling most exquisite examples of the condition "réaction à distance."

Some of these cells have been faithfully drawn with a Leitz apparatus and are illustrated in figure 3. On looking at sections in which such cells were present, they immediately arrested attention, even under

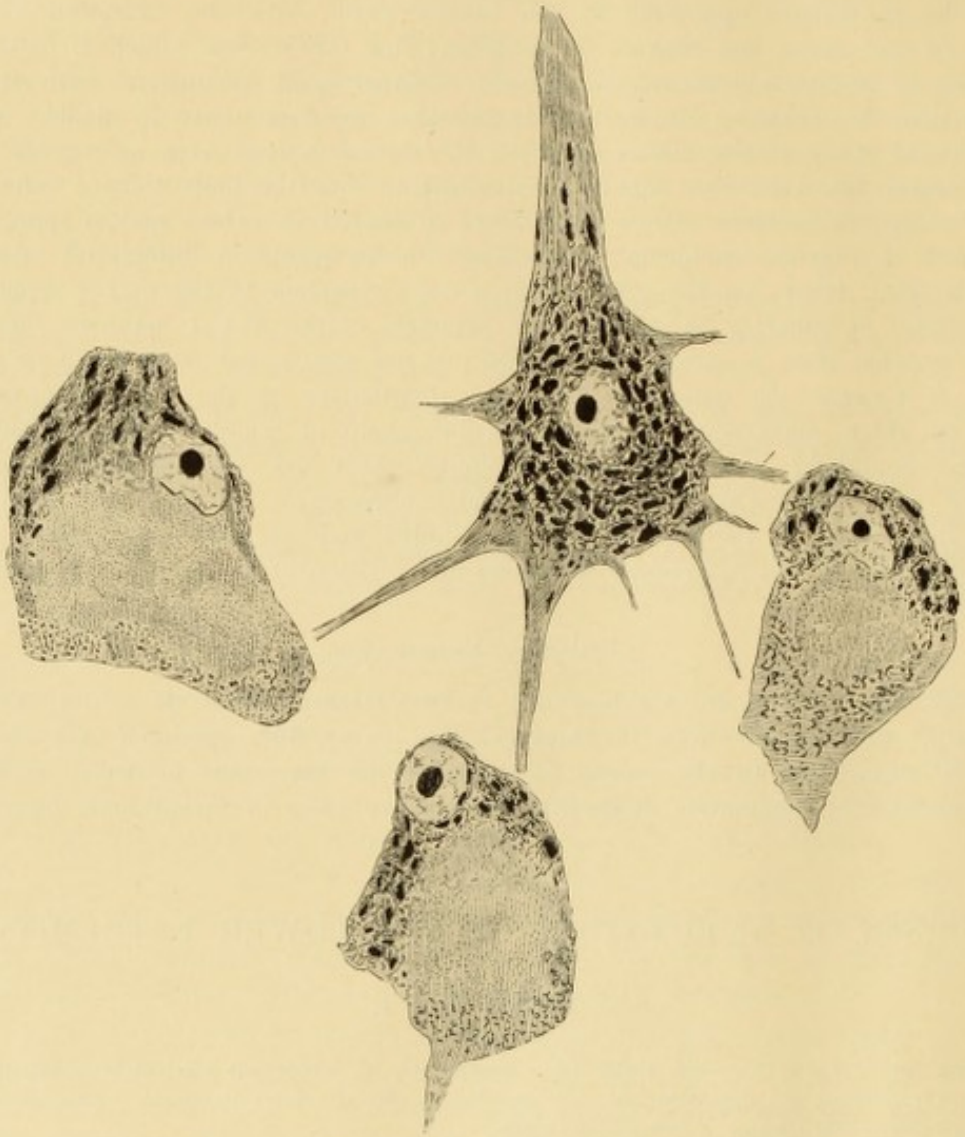

FIG. 3. Réaction à distance.
Three cells showing réaction à distance in typical form, with a normal giant cell from the same region for comparison. The dislocation of the nucleus, the persistence of chromophilic elements at the upper end of the cell and destruction of the same bodies elsewhere, the alteration in shape, and the loss of processes, are points to be specially noticed. The dotted mass extending across the base of each cell is pigment.
Zeiss Apochrom, 2 mm. and Leitz drawing apparatus.

a low power lens, by their relatively large size, their curious shape and their general pallor. Examined more closely under a high power, they were found to present the following characters. Disintegration of the chromophilic elements was pronounced, and the place of the large, richly-stained, deep purple elements,

characterising the normal cell, was taken by exceedingly fine dust-like granules, which, in thionin preparations, gave the substance of the cell a pale greyish-purple, or when there was an excess of pigment, a greyish-green colour. In some instances, the chromatolysis, for such it undoubtedly was, was general in distribution, but it was commoner to find just a few chromophilic elements remaining and resisting the disintegration, at the origin of the apical shaft, that is, in the uppermost part of the cell body; and, from an examination of many cells, we satisfied ourselves that the process of destruction commenced in the neighbourhood of the point of origin of the axon, and spread from there upwards; and we were also convinced that the immediate surroundings of the nucleus constituted a specially vulnerable area, for so-called central chromatolysis, which we took to be an indication of minor or commencing "réaction," was frequently observed It is a somewhat curious fact that the destructive process seemed to leave the normal pigment of the cell intact, for even in bodies which had reacted to an extreme degree this material could be seen extending in the shape of a dense, sharply-defined cloud across the basal part of the cell, or lying in a clump at the apex, and indeed it was more clearly visible in these degenerated elements, and especially when the sections had faded with keeping, than in the normal cell. On account of this individual's age —67 years—the conditions for the study of this pigment were of course exceptionally favourable.

Comparing tracings of these degenerated elements with ones of normal cells from the same situation, it was at once noticed that enlargement had occurred, not a great amount but a degree which we could fairly estimate at 20 %, and quite enough to impart to the cell a globose, swollen, inflated appearance. The outline of the body was regular, that is to say, free from serration or indentation, but the array of long and stout lateral projections, normally existent, was greatly reduced, and those remaining were short, attenuated and pale from loss of chromatic elements. An excess of pericellular small nucleated bodies was occasionally seen.

Dislocation of the nucleus was a very constant accompaniment of the chromatolysis, and this structure was usually seen lying at the periphery of the cell above the equatorial line, although it did occupy other positions. A certain amount of enlargement of the nucleus also occurred, and one or more indentations were sometimes seen to cause bights in its normal circular or oval outline. A nucleolus was almost invariably recognisable and occasionally enlarged.

From this description, it is evident that the cytological conditions we had to deal with in this case were identical with Marinesco's "réaction à distance," and it is from a study of elements unmistakeably diseased and showing a fully-developed degree of reaction, that the area which I shall now describe has been mapped out. Vide text-figure 4.

The affected field was situated at the upper end of the motor territory. On the mesial surface of the hemisphere, the distribution of Betz cells followed the usual plan and altered members were found throughout this part of the area[1]. On the coterminous upper part of the ascending frontal convolution they were again found, and the degenerated area descended this gyrus for a distance of about 2 cm., stopping at a point above the level of the superior frontal sulcus and about 2 cm. above the great annectant Rolandic gyrus. In the anterior direction a shallow fissuret, which might have been the sulcus precentralis marginalis, formed a limit, and posteriorly, diseased cells descended to the floor of the fissure of Rolando.

Concerning the number of degenerated cells in this area, although a very large percentage of the total showed the reaction, it could not be said that there had been a clean sweep, for while in some sections it could be truly stated that not a single normal cell remained, in others a few isolated members escaped and preserved a perfectly healthy appearance.

Next when we compared the diseased area with the cell groups which Bevan Lewis and Henry Clarke have described and which I have previously referred to, we were struck by several points of interest. We found that the degeneration was confined to three groups of cell nests, viz. the group on the mesial surface of the hemisphere, the large collection on the convexity close to the upper margin of the hemisphere, and the next small group which lies more or less on the free surface of the convolution; all these groups had suffered severely, and there was scarcely a cell nest to be found in any of them in which one or more members were not affected, in fact, in many nests not a single cell remained healthy. And as to the

[1] It must be mentioned here that while elements showing a similar kind of degeneration were found in the hinder part of the paracentral lobule, these elements differed from Betz cells, the cortex they occupied was not of a motor type, and, in short, they probably represented sensory termini and will be discussed under the postcentral gyrus.

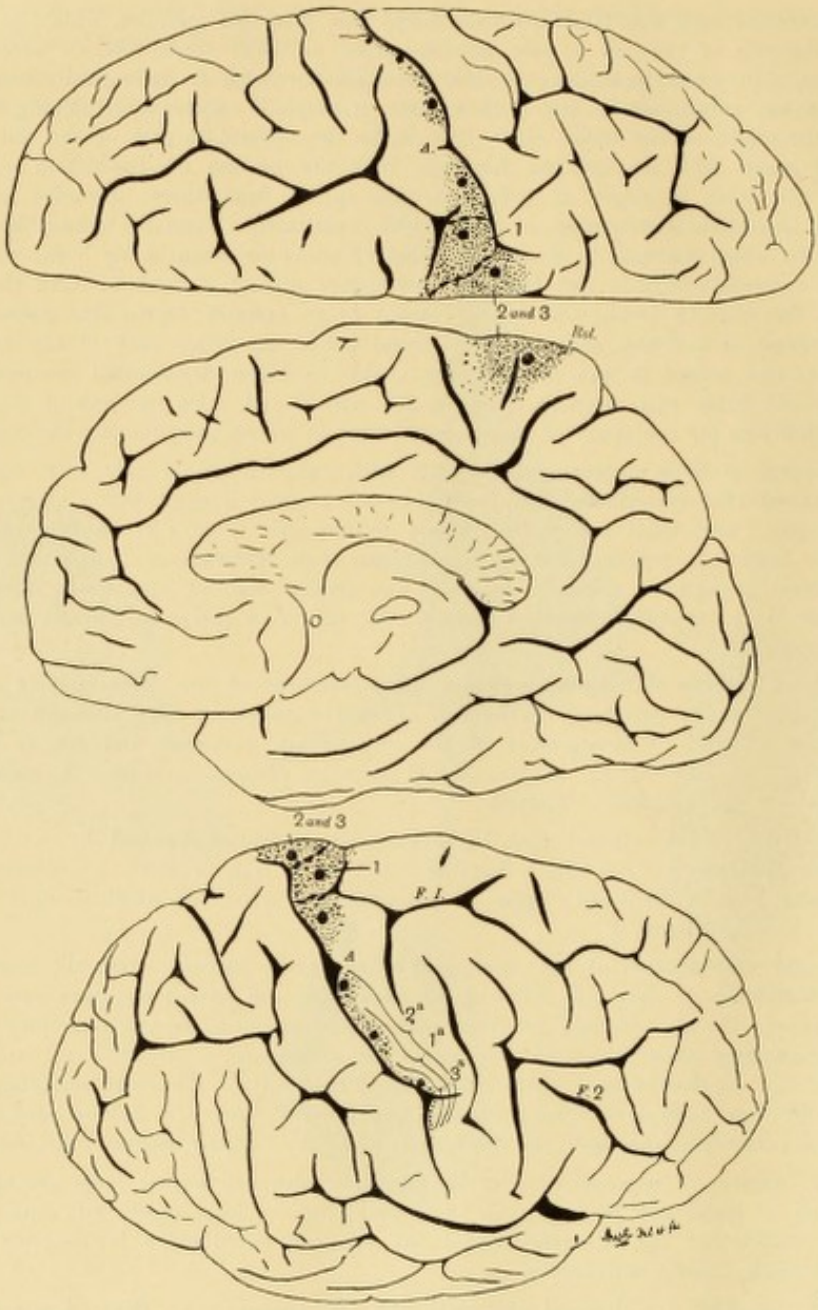

FIG. 4. Amputations.

Composite diagram to show the distribution of the giant cell changes in the six cases of amputation submitted to examination.

The numbers 2 and 3 are placed in connection with the area on the mesial surface and margin of the hemisphere, which suffered in two instances of amputation of the leg below the knee (cases 2 and 3). The number 1 points to the additional field which suffered when the amputation was through the knee joint and the thigh muscles were thrown out of action (case 1). We presume that the rich area below this controls hip muscles.

A is placed opposite the great annectant gyrus or buttress, invariably barren as regards giant cells.

The bracket 2*a* shows the extent of the affected field in case 2 (arm), amputation through upper arm with great wasting of shoulder muscles; 1*a*, amputation at same level but no shoulder atrophy (case 1); 3*a*, amputation of hand (case 3).

The black circles roughly indicate the position of the groups of cells referred to in the text.

lowermost cell group, it might have been expected that the degeneration in it would have been tailing off; this, however, was not the case, for it was as much as or even more affected than the others. After this, there was a very abrupt return to the normal condition, the next group, that lying just above the annectant gyrus, being almost completely untouched, and all the cortex below this normal.

In finishing off the account of this case I would repeat that "réaction à distance," in its most typical form, was unquestionably the predominating cell change, and this change alone we took as our guide, and a certain one too, to the differentiation of the area. It might be pointed out further that a careful search for shrivelled up and pigmented remains of cells in the ultimate stage of dissolution, and also for cells reduced in size, but intensely though homogeneously stained—a condition which others have described as one of atrophy—proved fruitless. I might also say that as the task of examining into the condition of the giant cells alone was such a time-absorbing and laborious one, and also because the changes found in them were so convincing, particular attention was not paid to the condition of other cell layers, and although we think that the large pyramidal cells had suffered a reduction in numerical strength, we cannot attach much importance to the observation because we did not verify it by making careful enumerations and drawings. I can, however, definitely state that the general cell atrophy, the distortion and the loss of the normal columnar arrangement, which figured so prominently in the case of amyotrophic lateral sclerosis, was absent in this, and in fact all the cases of amputation which I have examined.

CASE No. 2.

A male, aet. 41, both of whose legs were amputated at a point 6 inches below the knee joint, 2½ years prior to death. The left hemisphere was hardened in Orth's mixture of Müller's fluid and formalin and the central convolutions cut seriatim in celloidin. Pairs of sections were taken at intervals of 1 mm., and one set was successfully stained with thionin, to ascertain the condition of the nerve cells, and the other by the method of Wolters-Kulschitzky, for the display of nerve fibres.

As to the nerve cells, instances of "réaction à distance," just as beautiful and in every way similar to those found in case No. 1, were again seen, in fact as regards the condition of the giant cells and the general appearances of the cortex these two cases seem to be on all fours. Slight differences, however, regarding the distribution of the affection must be referred to (text-figure 4).

As in case No. 1, the group of giant cells on the mesial surface came in for severe affection, in fact hardly a single cell could be found in this situation which could be described as perfectly healthy. With the two upper groups on the convexity of the hemisphere it was different, for here the affection was not nearly so extensive, and while in nearly all the sections which displayed these groups, the degenerated cells could be seen at some point, the reaction was not so advanced and the major proportion of cells remained intact, and speaking in general terms it may be said that the cells on the free surface of the gyrus were least, and those lying on the wall of the fissure of Rolando most, involved. In case No. 1 the cells were equally involved in both situations, and this therefore constitutes an important point of difference and shows a pretty variation in result, according as to whether the leg is amputated above or below the knee.

Examination of the sections stained for nerve fibres proved entirely negative, for I was unable to detect the slightest difference between these sections and those from a normal brain; it is clear, therefore, either that nerve fibre changes, if they occur, are very slow in supervening, or else changes are present for the display of which some other method—probably the method of Marchi—is needed.

CASE No. 3.

A male, aet. 45, with amputations of the right and left legs, at points 14 cm. and 21·5 cm. below the head of the tibia, respectively.

The exact date of the amputation was not ascertained but it was an old-standing one, because he was an inmate of Rainhill Asylum for 12 years, and, prior to that, had taken advantage of his disability, to practise the calling of a beggar, on the sands of Blackpool.

The right and left hemispheres were examined and both displayed the same changes. On account of the greater length of time which had elapsed after the amputation, it is not surprising that the changes found differed materially from those observed in the two previous cases. Three varieties of altered cells were noticed. (1) A few showed an absence of chromophilic elements, a dislocated nucleus, a rotund figure and an absence of all processes, save the apical, and so far agreed with cells noticed in previous cases, but they differed in one important respect, instead of being swollen they were reduced in size. Now this reduction in volume I am forced to regard as a manifestation of post-reactive atrophy and a change of more recent date than that represented by the next variety. (2) These were shrunken, pallid but heavily pigmented objects, having an irregular contour, present in abundance and plainly representing the last stage of giant cell destruction. (3) A number of giant cells were observed which were obviously reduced in size, which had a serrated contour and short, sinuous and attenuated processes, and which were specially curious in staining very intensely, so intensely and universally that it was quite impossible to recognise Nissl bodies, nucleus or nucleolus in them. To my mind there can be little doubt that these represented another condition of late atrophy, and the opinion which I would venture to offer concerning them is that they pertained to nerve fibres proceeding to some muscles situated above the amputated level, muscles which had become atrophied from disuse, in spite of integrity of their nervous supply.

In point of numbers, I must say that there was not so great a reduction in the cell aggregate as I expected, and this in spite of the very severe character of the degenerative changes shown. It is also to be mentioned that destruction of cells in other laminae, and interference with the columnar arrangement, though noticeable to a certain extent, were not nearly so obvious as they were in the cases of Amyotrophic Lateral Sclerosis.

The distribution of the affected area closely resembled that observed in case No. 2, in which the amputation was at the same level (text-figure 4). As specially involved parts, the whole of the area on the mesial surface, that part lying exactly along the upper margin of the hemisphere, and the cortex on the anterior wall of the upper centimetre of the fissure of Rolando, were singled out. The giant cells on the free surface of the upper extremity of the precentral gyrus, that is, the external members of Bevan Lewis and Clarke's large uppermost group, had in large measure escaped, as also had the cells of the smaller group a little lower down. From which it would appear that these two groups are mainly concerned with the control of thigh movements; for it is to be remembered that in case No. 1, where the flexors and extensors of the knee were thrown out of action by amputation at that joint, these groups showed marked signs of retrograde degeneration.

CASES OF AMPUTATION OF THE UPPER EXTREMITY.

CASE No. 1.

Male, aet. 63. Amputation of the right upper arm at the junction of the lower and middle thirds, two years prior to death.

Examination of the paracentral lobule and of the precentral gyrus, as far down as the great annectant buttress, was not attended by positive results, only occasionally a giant cell was seen showing changes suggestive of "réaction à distance," and this scattered degeneration may be more reasonably regarded as senile and physiological in character than as having anything to do with the amputation.

At the buttress, also, no pathological change was observed. On coming, however, to the group of cells which lay immediately below, a large number of elements were seen which, although they did not exhibit the changes of "réaction à distance," were yet reduced in size and stained so uniformly and intensely that their intimate structure could not be made out.

There next came a long series of sections reaching from here to within a few millimetres of the lower genu (in this brain placed on a level with the inferior frontal sulcus) in which there was much more evidence of disease, at the same time the changes were not nearly so pronounced as in the cases of leg amputation, for only about 20 °/₀ of the cells exhibited the change "réaction à distance" in its typical fully-developed form; 50 °/₀, however, presented appearances which I took to be indicative of immature

degeneration, that is to say, the globose swelling of the cell body was only moderate, Nissl bodies were present in the upper half instead of at the apex only, and the nucleus instead of being moved quite to the periphery was only eccentric; associated with these changes there was a great excess of pigment at the base of the cell. The remaining 30 % of cells were healthy. The remnants of completely atrophied cells were absent and there was no evidence of a numerical reduction. Approximately speaking, the diseased area had a vertical extent of 3 cm., the affected cells were confined entirely to the frontal wall and lip of the Rolandic fissure, and more were seen in the lower than in the upper half of the field (text-figure 4, 1 *a*).

Following on this was a short stretch about a centimetre in length, in which no degeneration was found, and then the Betz cells ceased.

CASE No. 2.

Male, aet. 16. Amputation of the right arm, 10 cm. below the head of the humerus. The date of the operation was not ascertained but it was evidently old-standing as the shoulder muscles were greatly atrophied.

The upper half of the Betz cell area, including the annectant buttress, was healthy.

In a well-marked group of cells lying just below the buttress some excellent examples of "réaction à distance" were found. From this position down to a point about 1·5 cm. above the lower extremity of the fissure of Rolando (text-figure 4, 2 *a*) typical "réaction à distance" was not common, but numbers of cells exhibited the following condition: the whole body of the cell possessed a curious pallid, finely granular or reticulate appearance and the usual chromophilic elements absolutely defied definition; the nucleus was distinctly swollen, frequently but not always eccentric, and its outline was occasionally indented; the cell body in general was increased in size, and its margins often irregular, but globosity was not a marked feature; the cells had lost their lateral processes but one or more could generally be seen springing from the base, these, however, were of extraordinary thickness and very palely stained. There was no increase in the amount of pigment, in fact, by far the majority of cells contained none at all.

As in Case No. 1, the degenerated cells were equally distributed over the affected area, but I am inclined to think that a larger proportion of elements suffered in this instance.

Again the lower extremity of the Betz cell area contained normal elements, but it has to be noted that these were of rather small size.

CASE No. 3.

Female, aet. 26, with an old-standing amputation of the right hand, one inch above the wrist joint.

The central convolutions, from both hemispheres, were submitted to a thorough examination, and numerous cell counts and drawings were made, to illustrate the condition of affairs in both the precentral and postcentral gyri. The changes present in the postcentral gyrus will be referred to in the section dealing with the postcentral area, here I will confine my remarks to the state of the Betz cells.

These cells showed unmistakeable alterations in the left hemisphere. Proceeding from above downwards, signs of disease made their appearance at a point about 3 cm. below the superior annectant gyrus and about 2 cm. above the level of the inferior frontal sulcus, and they continued to show themselves over a stretch of cortex measuring 15 mm. in the vertical direction, ceasing at a point a few millimetres below the level of the inferior frontal sulcus, and some distance above the lower extremity of the Rolandic fissure. The changes affecting the Betz cells consisted of shrinkage, stunting of the apical and complete loss of the basal processes, almost universal chromatolysis, and nuclear dislocation. In addition to this there was an obvious reduction in the number of the cells, only two or three being visible per section, and there seemed little doubt that a good many had disappeared. Furthermore, when the layer of external large pyramidal cells was compared with the same layer in the normal hemisphere there was a manifest reduction in their number.

Below the affected area, the extent and position of which is indicated in figure 4, 3 *a*, the lamination reassumed a normal appearance.

It was interesting to find in this case that the groups of cells higher up, but below the buttress, which may be looked upon as controlling shoulder and elbow movements, were, with rare exceptions, absolutely healthy.

CONCLUSIONS DERIVED FROM THE EXAMINATION OF THE BRAIN IN THESE CASES OF AMPUTATION.

It can scarcely be denied that the predominant change in the Betz cells in these cases, and the change by which we are able to map out definite areas, is identical with the reactive alteration Marinesco has described, at least that is the conclusion I have arrived at, after a most minute examination of many hundreds of sections of the cortex, showing the change; after comparison of these with sections of the spinal cord from more or less recent cases of amputation which have come under my own observation, and which show the change to perfection in certain segments (these specimens were exhibited at a meeting of the Liverpool Medical Institution several years ago); and after a perusal of the accounts and an inspection of the drawings published by others who, in addition to Marinesco, have studied the change.

The question of the period of time which must elapse before the cells undergo this particular alteration is of some importance, but unfortunately it is one upon which I cannot write definitely on account of lack of information and experience. From experimental researches we learn that changes arise in the anterior cornual cells of the spinal cord a very short time—20 days—after section of a peripheral motor nerve, but since before it reaches the brain the retrograde alteration has a greater distance to travel and also a second neuron to ascend, it stands to reason that the cortical changes must be of slower development than the spinal. However, to settle this point, either some experiments on lower animals, or an examination of more recent cases of amputation than those which have come under my notice, will have to be carried out. I can only say that in my most recent case, namely, one in which only two years had passed since the amputation, the change was seen to perfection, and I therefore think that cases of this age are most suitable for purposes of localisation. I also believe that, at this period, only those cells show degeneration which are connected with the fibres contained in the severed nerve trunk, that is to say, the brain is free from the confusing coexistence of changes of a purely atrophic nature, affecting cells for the control of muscles above the level of the amputation, muscles which, without having their nervous supply cut off, undergo wasting and shrinkage from want of use.

Next concerning the duration of the alteration after it has once made its appearance, I am convinced that a long period, not only months but even years, may pass by before complete dissolution, which we are compelled to regard as the ultimate fate of the cells, supervenes. This point is well exemplified in Case 3, for, notwithstanding the fact that at least twelve years had elapsed after removal of the individual's legs, numbers of degenerated cells could be seen persisting in the affected cerebral area, having only reached what one might call the penultimate stage of retrograde destruction; furthermore, proving that not many had completely broken up and disappeared, a cell count did not reveal a very pronounced numerical reduction, compared with the normal brain.

Taking now the facts bearing on localisation gleaned from these cases, and setting them in order, we find: (1) that in three cases of amputation of the leg, two of them below the knee, the cell changes were most intense in the group situated on the mesial surface of the hemisphere, and that they also affected, although to a minor extent, the large marginal group on the convexity; it therefore follows that this part may be marked down as the centre for movements of the foot and ankle. (2) In one of these leg cases the amputation was made above the knee, and since, in addition to the above-mentioned groups, degeneration was also found in the next group lower down on the convexity, that is the relatively small cluster lying more or less on the free surface of the ascending frontal convolution, above the level of the superior frontal sulcus, we may conclude that the cells of this group, as well as some proportion of cells in the overlying large marginal cluster, dominate muscles acting on the knee joint. (3) Reasoning by deduction we may assume that the centre for the representation of thigh movements lies in the next cluster of cells, situated immediately above the annectant buttress or gyrus. (4) Since the scattered cells existent in the annectant buttress have not shown any signs of degeneration, either in the cases of amputation of the leg or arm, and since we have reason for supposing that shoulder movements are presided over by the group of cells lying immediately below this level, we are left to conclude that the cortex of this buttress is the trunk centre. This view gains in credence from the fact that, in the anthropoid ape, trunk movements have been constantly elicited by excitation of cortex at the level of the upper genu; indeed, to the physiologist, this flexure is a very important dividing landmark between arm and leg centres, and, as I have previously mentioned, in both man and ape the bend in the Rolandic fissure is nothing more than the surface expression of the underlying buttress. (5) My reason for believing that the cluster of cells situated immediately below the annectant gyrus may deal with shoulder movements is that in one case of amputation of the arm close up to the shoulder joint, which was associated with extreme atrophy of the shoulder muscles, this cluster showed pronounced degeneration; whereas, in another case in which the amputation was near to the elbow joint, and the shoulder muscles had preserved much of their normal size and tone, the same cluster was intact[1]. (6) A study of degeneration present in these brains favours the belief that movements of the arm (elbow, finger, and wrist) have a relatively extensive representation in the cortex. For in the two cases of amputation through the upper arm, just alluded to, diseased cells were found along the stretch of cortex reaching from the shoulder cluster I have indicated to within 10 or 15 mm. of the lower extremity of the fissure of Rolando, but not quite to the lower extremity of the Betz cell area. (7) In one case of amputation at the wrist joint degeneration was found only at the lower extremity of the above-mentioned arm field, so in a normal human brain I would locate wrist and finger movements slightly above an imaginary line continued backwards from the inferior or second frontal sulcus. (8) The few giant cells lying below this level, which have remained intact in all these instances and which constitute the lower extremity of the Betz cell area, must govern neck movements. (9) Applying Professors Sherrington and Grünbaum's anthropoid ape scheme to the human brain, it is found that there is close agreement on all the above-mentioned points, but when we try to fit on the area, excitation of which produced movements of facial muscles—those of the jaw, eyelids, nose and ears—we find that there are no true giant cells which we can look upon as presiding elements resident in the homologous area. We do, however,

[1] In connection with this it may be remembered that in my second case of Amyotrophic Lateral Sclerosis the upper arm muscles had escaped wasting and the cluster of cells here indicated was preserved.

come across scattered nests of large pyramidal cells, which differ from those common to the whole precentral cortex in being more attenuated and in having longer processes and larger and more distinct chromophilic elements, and although these cells have to be very carefully sought for, and it is correspondingly difficult to define their exact location, I yet think it possible that they represent the cortical origin of the fibres contained in the cerebral root of the fifth nerve (mastication), and also of the fibres proceeding to the nucleus of the seventh nerve.

ON THE EVIDENCE DERIVED FROM A CLINICAL STUDY OF LESIONS OF THE MOTOR AREA IN THE HUMAN BEING.

Putting together the results of Professors Sherrington and Grünbaum's elaborate experiments on the anthropoid ape, the facts brought to light by a full histological examination of the Rolandic cortex in the normal subject, and the evidence derived from a study of the same part in cases of Amyotrophic Lateral Sclerosis and Amputation, the case for the direct connection between the pre-Rolandic cortex and the motor function appears practically complete.

And yet, when we take up clinical records for further evidence on the question of the limitation of this function, we at once receive a check by being confronted with this serious difficulty, namely, that, from the very beginning observers have been firmly imbued with the belief that the entire Rolandic region, so called, is "motor," and the obvious result is that the baneful influence of this preconceived notion has made itself felt throughout the whole of the very extensive literature on the subject. This being so, it is profitless to analyse recorded cases for confirmatory evidence on the point under consideration, for, although no doubt many cases could be adduced in support of the new localisation, many others would appear to favour the old, and the result would be inextricable confusion.

But apart from the assumption that experimenters gave the clinician what we now believe to be a false lead, there are other factors which may have contributed to erroneous conceptions on the function of the two central convolutions. Firstly, the simple anatomical truth is not sufficiently recognised that the bases of the medullary projections of these two gyri are separated from one another at most by the mere width of cortex on the apposed walls of the Rolandic fissure, and that consequently the efferent and afferent fibres which proceed to and from these gyri strike the centrum ovale side by side, and of course preserve this contiguity in the path which they follow to the internal capsule. Bearing this in mind, to those familiar with the morbid anatomy of the brain it is plain, that a lesion which would destroy the whole or even a portion of one of these convolutions, without injuring fibres pertaining to the opposite side, would be an anatomical rarity, and accordingly, whether the lesion be in the postcentral or precentral gyrus, the resulting phenomena as regards paralysis would be the same. And as a matter of fact when we consider the lesions from which clinical deductions have been drawn, we find that they practically all come under the heading of cerebral softening, tumour, haemorrhage, meningitis, or traumatism, and of these, softening following embolism or thrombosis has been the agent in by far the majority of instances. As to cerebral softening, it can hardly be maintained that an arterial occlusion is the most desirable agent for the production of a lesion, which will give us the minimum of destruction with a maximum effect so far as motor symptoms are concerned; for from my own experience of over two hundred examples of this condition, occurring in various parts of the brain, I can safely say that an occlusion giving rise to destruction of the cortex alone without involving the white substance is extremely uncommon; further, in the instances which I have seen of stoppage of those

offshoots of the middle cerebral artery which supply the lower two-thirds, or thereabouts, of the central gyri, and of those terminal twigs of the anterior cerebral artery which run to the paracentral lobule and upper third of the central gyri, there have been none which have not penetrated so deeply into the white substance as to affect fibres pertaining to both gyri. Frequently, also, I have been struck with a point, to which Monakow draws attention, namely, that in some cases, when the patch of cortical destruction has appeared small and insignificant from the surface, more minute inspection, especially after hardening, has revealed an unexpected widespread destruction of the subjacent white substance; and further I cannot help agreeing with the same writer when he says that the arterial supply of the cortex is such that the production of a so-called pure cortical lesion is an anatomical impossibility. Of course the same objections, as regards limitation of effect, may be urged against cases of cerebral tumour, haemorrhage, and trauma.

From the foregoing it is not surprising that mixed conclusions have been drawn from a study of such lesions, and I may also venture to say, that it is not altogether safe to utilise such material for purposes of localisation until we acquire more certain information concerning the anatomical distribution of the strands of nerve fibres pertaining to this part and running in the subjacent white substance. For instance, as the centres for the leg, trunk, arm, and face, etc., are separated from one another on the surface, it is more than likely that the strands of fibres conveying impulses from these various areas likewise follow separate paths to the internal capsule, but the exact course which these different strands of fibres pursue, and also the path followed by fibres pertaining to the postcentral gyrus, are unknown to us; hence it necessarily follows that until we possess this information, and until we can prove by microscopic examination of the brain, in cases of cortical lesion, that the destruction and attendant degeneration is or has been limited to a given set of neurones, clinical observations are bound to be imperfect and inexact.

In discussing the functions of the postcentral gyrus, further reasons will be advanced for believing that it has nothing to do with the motor function. Here I would say, however, in case the results of the few experimental excitations of the cortex which have been carried out in the human being in bygone years may be brought up in support of the hypothesis of the unity of function of the central gyri, that Professor Sherrington will tell us that in the course of operations which have been recently performed by two surgeons in Berlin and Chicago respectively, stimulation of the cortex by unipolar faradisation has been attended by results which, as regards inexcitability of the postcentral cortex, agree absolutely with those of the anthropoid experiments[1].

I have now to mention that although points gleaned from a study of cases at the bedside are inadequate for purposes of precise localisation, information derived in this way has been extremely valuable in assisting us to determine the sequence of representation as regards localisation along the surface extent of the motor area; indeed, it is from careful analysis of such cases that we can now with full certainty state that the sequence in man is identical, for all practical purposes, with that which obtains in the ape. For instance, in the case of the human being, numerous instances of tumour at the vertex and of softening from occlusion of the terminals of the anterior cerebral artery have been collected, during the past five-and-twenty years, in which destruction of the paracentral lobule and upper fourth of the Rolandic cortex has been adequate to the production of crural monoplegia.

[1] The cases referred to have been quoted in recent papers by Brodmann and Mills.

Instances of lesions which have been so limited in their effects as to produce paralysis of the trunk muscles only, are not quoted by any of the authorities I have consulted, and there is no clinical evidence to show whether or not the centre for the control of these muscles lies, as I have already suggested, at the level of the annectant Rolandic gyrus.

But that the arm centre lies below the level of this gyrus there is abundant proof. The majority of the reported cases of brachial monoplegia have been the result of occlusion of twigs of the ascending frontal branch of the middle cerebral artery, though some excellent cases have followed injuries of the parietal bone, and the area accepted by clinicians as the arm centre occupies the middle two-fourths of the Rolandic cortex.

An isolated cortical facial paralysis seems to be extremely uncommon, but a facio-brachial or a facio-lingual palsy is frequent, and a lesion of the inferior fourth of the central convolutions along with the opercular portions of the third frontal convolution is described as equivalent to its production. Of course when such a lesion occurs in the left hemisphere it is associated with motor aphasia.

To put the matter briefly, we have the satisfaction of knowing that the facts derived from these sources, an investigation of clinical cases, an examination of the special pathological material which I have dealt with, and experimental research are all in harmony in regard to the sequence of motor representation on the cortical surface.

There are other points of interest having a bearing on the motor function, such as the question of restitution of function after destruction of a part of the motor cortex; the difference in the results attending lesions of the cortex and of the motor tract in its intracerebral course; the various degenerations following such lesions; the pathogenesis of spasmodic muscular affections, etc., but these questions do not come within my province and so far as localisation is concerned little is to be gained by discussing them. The more important question of the localisation of skilled movements will be considered in the chapter on the "intermediate precentral" area.

Points in the Development of the Motor Cortex.

It seems that a study of the developing cortex affords little information on the question of the difference in function between the precentral and postcentral gyri. If our view on the limitation of the motor function to the precentral gyrus be correct, we would expect, in accordance with what we know of the tardy development of the motor tract in the spinal cord, that the myelinisation of the cortex of that convolution would be deferred in a corresponding manner. But on this point the evidence is contradictory, for while Vogt figures and describes a special band of fibres proceeding to the postcentral gyrus, which he says is medullated in advance of others in this region, Flechsig, even in his most recent paper (March 1903), mentions no difference as regards the period of maturation of the fibres of the two central gyri, stating merely that the fibres of both, with the exception of fibres in the olfactory regions, are the first in the whole cerebral cortex to acquire a medullated sheath. In course of time, however, Flechsig may modify his views on this point[1].

[1] In a paper by Hösel, which has appeared since this was written, it is stated that the first medullated fibres received by the central gyri come from the ventral nucleus of the optic thalamus (fibres of the Ruban de Reil).

Summary.

1. Making use of various members of the anthropoid ape family as material for experiment, Professors Sherrington and Grünbaum in collaboration have arrived at the conclusion, that the motor area is, roughly speaking, limited to the precentral convolution, and in this chapter a quantity of histological evidence is advanced to show that the same localisation probably obtains in the case of the human being.

2. Examining the arrangement of nerve fibres and the types of cell-lamination in the brains of some of the animals which Professors Sherrington and Grünbaum had previously operated upon, I found that it was possible to map out a histological area which agreed very closely with that which responded to electrical excitation.

3. Extending my observations to the human brain I have discovered that a similar arrangement and disposition of elements obtain therein.

4. The cortex of the excitable area in the anthropoid ape, and of what I take to be the analogous area in the human being, are distinguished by a wealth of nerve fibres, noticeable in all layers or systems, which is infinitely greater than that possessed by any other part of the brain surface.

5. The area exhibiting this type of fibre arrangement is practically confined to the precentral gyrus and to a portion of the paracentral lobule, and it is important to notice that the floor of the fissure of Rolando forms a very definite and constant posterior limit.

6. The same area corresponds approximately with the distribution of the giant or "motor" cells of Betz and Bevan Lewis, the chief difference being that it is somewhat more extensive.

7. I have been able to confirm Bevan Lewis's observations concerning the variations in arrangement, numerical representation and size exhibited by the giant cells at different levels, but I cannot agree that the cells found in the hinder part of the paracentral lobule, and in the upper sixth of the postcentral gyrus, pertain to the "motor" cell category.

8. I have found that the area described by Bevan Lewis and Henry Clarke as being barren of "motor" cells corresponds in position with the structure known as the superior deep annectant gyrus of the fissure of Rolando, and I have come to the conclusion that a great deal of importance is to be attached to this structure. It marks the point of union of the two original foetal subdivisions of the fissure; it is invariably present and, more frequently than is supposed, rises to the surface and interrupts the fissure; the superior genu is merely its expression on the surface; it is present in the anthropoid brain, but is more variable in position; and physiologically it seems to be an important guide to the point where the trunk area intervenes between the leg and arm areas.

9. Strong confirmatory evidence in support of the assumption that, in man as well as in the man-like ape, the elements controlling volitional muscular movements are confined to the precentral gyrus and its paracentral annex, is afforded by an examination of the brain in cases of Amyotrophic Lateral Sclerosis, a disease limited in its affection to the muscular system and to the motor system of neurones. From cursory examinations of the cortex by previous observers we have learned that the "motor" cells are liable to destruction in this

disease. This evidence I can now supplement, by stating that in two cases which I have examined exhaustively, I have observed a wholesale disappearance of these elements throughout their normal area of occupation, and while there was a coexistent disturbance of other elements in the precentral cortex the postcentral gyrus entirely escaped affection.

10. Valuable material for the determination of differential localisation in the motor field is provided by the brains of individuals who have been disabled by amputation of one or other extremity, for in due course, either as a result of section of the fibres with which they stand connected, or of suppression of the energy which they elaborate, the cortical "motor" cells controlling muscles in the amputated member undergo the change described by Marinesco under the name "réaction à distance," and from a careful examination of the distribution of these changes important results are forthcoming.

In two cases of amputation of the leg a short distance below the knee, I have found changes limited to the upper extremity of the precentral gyrus and its paracentral annex, in other words to the part which in the case of the higher ape seems to control movements of the toes and ankle. In another case of amputation at the knee joint, associated with great atrophy of the thigh muscles, the changes extended further outwards, but numerous cells above the superior annectant gyrus remained intact; the latter probably govern hip movements. In two cases of amputation of the arm through the humerus, degenerated cells were found over an extended area corresponding very closely with Professors Sherrington and Grünbaum's experimentally located areas for finger, wrist, and elbow movements; and in one of these cases, which was associated with extreme wasting of the shoulder muscles, a large group of cells lying immediately below the superior annectant gyrus, was affected. In a case of amputation of the hand the changes were limited to the lowermost part of the last-mentioned area.

11. It is impossible to reconcile these findings with the long list of clinical observations, adduced in the past to support the view that the two central convolutions have an equal share in the control of volitional movements, and it is suggested that natural lesions such as cerebral softening, cerebral tumour, and cerebral trauma, which form the basis of most of those observations, are only in rare instances sufficiently limited in their effects to allow of safe judgment on this question, hence errors have arisen.

12. The conclusions deduced from clinical observations, from experimentation and from histological investigation, are completely in agreement concerning the sequence of representation of movement along the course of the motor area.

13. The giant cells disappear before the lower extremity of the fissure of Rolando is reached, and are consequently not found over that cortex which we regard as the face area; in this area, however, large cells are found differing from the large pyramidal cells common to the whole precentral area and these are possibly special presiding elements.

14. It is probable that the fibres of the postcentral gyrus acquire their medullated sheath before those of the precentral, but a final statement on this point is required from those who have made a special study of the developing brain.

REFERENCES.

1. Hitzig. Untersuchungen über das Gehirn. Berlin, 1874. And also various other publications.
2. Ferrier. The Functions of the Brain. London, 2nd edition. See also article by the same author in Clifford Allbutt's *System of Medicine*.
3. Sherrington and Grünbaum. Observations on the Physiology of the Cerebral Cortex of some of the Higher Apes. *Proc. Roy. Soc.*, Vol. lxix, 1901. See also a forthcoming number of the *Phil. Trans. Roy. Soc.*
4. Wagner. Quoted by Cunningham.
5. Elliot Smith. Catalogue of Comparative Anatomy, Museum of Royal College of Surgeons, England. Vol. ii, 1892.
6. S. Ramón y Cajal. Studien über die Hirnrinde des Menschen. Heft 2, Die Bewegungsrinde. Leipzig, 1902.
7. Hammarberg. Studien über Klinik und Pathologie der Idiotie. Upsala, 1895.
8. Betz. Anatomischer Nachweis zweier Gehirncentren. *Centralb. f. med. Wissensch.*, Aug., 1884.
9. Bevan Lewis and Henry Clarke. The Cortical Localisation of the Motor Area of the Brain. *Proc. Roy. Soc.*, No. 185, 1878.
10. Bevan Lewis. On the Comparative Structure of the Cortex Cerebri. *Brain*, Vol. i, 1879. See also *Textbook of Mental Diseases*, by the same author.
11. Marinesco. Neue Beobachtungen über die Veränderungen der Pyramidenzellen im Verlauf der Paraplegieen. Abst. in *Neurol. Centralb.*, p. 899, 1900.
12. Mott. A Case of Amyotrophic Lateral Sclerosis with Degeneration of the Motor Path from the Cortex to the Periphery. *Brain*, Vol. xviii, 1895.
13. Mott and Tredgold. Some Observations on Primary Lateral Sclerosis of the Motor Tract. *Brain*, Part iv, 1902.
14. Charcot et Marie. Deux nouveaux cas de sclérose latérale amyotrophique. *Archives de Neurologie*, Tome x, 1885.
15. Kowjewnikoff. Quoted by Mott.
16. Acquisto e Pusateri. Sul centro motore corticale dell' arto inferiore dell' uomo. *Riv. di Patologia, nervosa e mentale*, Vol. xviii, F. 2, 1897.
17. Homén. Veränderungen des Nervensystems nach Amputationen. *Beiträge zur path. Anat.* (Ziegler), Band viii, 1890.
18. Marinesco. Sur les altérations des grandes cellules pyramidales, consécutives aux lésions de la capsule interne. *Revue Neurologique*, p. 358, 1899. And several other papers in the same Review.
19. Lugaro. Sulle alterazioni delle cellule nervose per mutilazioni del prolungamento nervoso. *Riv. di Patologia, nervosa e mentale*, Fasc. xi, 1896.
20. Van Gehuchten. La dégénérescence dite rétrograde ou dégénérescence Wallérienne indirecte. *Le Nevraxe*, Vol. v, Fasc. 1, 1903.

21. WARRINGTON. On the Structural Alterations observed in Nerve Cells. *Journ. of Phys.*, Vol. XXIII, Cambridge, 1898.

22. VON MONAKOW. Gehirnpathologie. Wien, 1897.

23. DOTTO e PUSATERI. Sulle alterazioni degli elementi della corteccia cerebrale, etc. *Riv. di Patol., nerv. e men.*, Jan., 1897.

24. BALLET et FAURE. Atrophie des grandes cellules pyramidales dans la zone motrice de l'écorce cérébrale, etc. Société médicale des Hôpitaux. Séance du 30 Mars, 1899.

25. P. FLECHSIG. Weitere Mittheilungen über die entwickelungsgeschichtlichen (myelogenetischen) Felder in der menschlichen Grosshirnrinde. *Neurol. Centralb.*, Mar. 1, 1903.

26. O. and C. VOGT. Neurobiologische Arbeiten. Beiträge zur Hirnfaserlehre. Bd. I. Leipzig, 1902.

27. D. J. CUNNINGHAM. Contribution to the Surface Anatomy of the Cerebral Hemispheres. Dublin, 1892.

28. K. BRODMANN. Beiträge zur histologischen Lokalisation der Grosshirnrinde. *Journal f. Psychol. und Neurol.*, Band II, 1903. Also *Neurol. Centralb.*, No. 14, p. 669, 1904.

29. R. WEINBERG. Die Intercentralbrücke der Carnivoren und der Sulcus Rolandii. *Anat. Anzeiger*, 13, 1902.

30. W. KOLMER. Beitrag zur Kenntniss der "motorischen" Hirnrindenregion. *Arch. f. mikr. Anat.*, ~~LVIII,~~ 1901.

LVII

31. J. HUGHLINGS JACKSON. On Convulsive Seizures. (Lumleian Lectures.) *British Medical Journal*, Vol. I, 1890.

32. ROTHMANN. Ueber elektrische Reizung der Extremitäten-region. *Neurol. Centralb.*, No. 14, 1904.

33. MILLS. The Physiological Areas and Centres of the Cerebral Cortex of Man, with new diagrammatic Schemes. *Univ. of Pennsylvania Med. Bulletin*, May, 1904. And other papers.

34. HÖSEL. Ueber die Markreifung der sogenannten Körperfühlssphäre. *Arch. f. Psychiatrie*, Bd. XXXIX, H. 1, 1904.

CHAPTER IV.

POSTCENTRAL AND INTERMEDIATE POSTCENTRAL AREAS.

Introductory Remarks.

It seems that behind the fissure of Rolando types of cortex exist, having a distribution which forms a counterpart to that observed in the pre-Rolandic area, for just as the posterior or Rolandic half of the precentral or ascending frontal convolution is found to be coated by a special type of cortex, and invested in the frontal direction by another type intermediate in character, so also the anterior or Rolandic half of the postcentral or ascending parietal gyrus is covered by a special type, which in turn is invested in the parietal direction by an intermediate arrangement. But with distribution the analogy ceases, for, as I shall show in the immediately following pages, the structure of the postcentral cortex, not only in the human being, but also in the anthropoid ape, differs in many essential points from that of the precentral; indeed, the histological disagreement is so pronounced as to suggest in itself a difference in function.

Reflecting on the *rôle* probably played by this area, it seemed that profit might be gained by directing further investigations towards proving whether or not it represented the cortical terminus for common sensation; accordingly, it became part of my programme to procure suitable material and make an exhaustive microscopic examination of the ascending parietal gyrus in diseased conditions, involving a severance of the chain of sensory neurones at various levels; thus, instances of severance of the tract in its intracerebral course were supplied by cases of old-standing capsular lesion, instances of interruption at the level of the spinal cord by cases of *Tabes dorsalis*, and instances of peripheral section by cases of amputation. This branch of the research has furnished results having a most important bearing on the question of sensory localisation, those dealing with *Tabes dorsalis* being of special interest.

Then, since much of the evidence I have to bring forward is out of harmony with current doctrines, it has been deemed necessary to give due consideration to the conflict of views on the function of the postcentral region, and on the question of the cortical localisation of common sensation in particular, and to this the concluding section of my chapter is allotted.

STRUCTURE OF THE POSTCENTRAL AREA.

To the two vertical parallel-lying areas (*vide* Plate I) into which the postcentral or ascending parietal cortex is divisible, the names "postcentral" and "intermediate postcentral" are respectively applicable. It will be convenient to consider these two areas separately, and we will take the "postcentral" field first, and open with a description of the arrangement of fibres, incidentally pointing out the manner in which the arrangement differs from that of the "precentral" area.

A. ARRANGEMENT OF NERVE FIBRES. (Plate V, fig. 1.)

Zonal layer.

If sections comprising a view of the cortex on both walls of the Rolandic fissure be examined, and the zonal layer of the two compared, it will be seen that it lacks representation on the postcentral side, and this weak development of the zonal layer, found over the whole extent of the postcentral area, is the first point of distinction between postcentral and precentral cortex (cf. Plate III, fig. 1). The layer is composed, mainly, of varicose fibrils, with which larger varicose fibres are intermingled. Coarse medullated fibres are present, but they have to be carefully sought for and are not found in every section.

Supraradiary layer.

In depth, this layer is approximately equal to the same layer in the precentral cortex, and the general arrangement of elements is similar, but a pronounced inferiority in fibre wealth constitutes an outstanding point of difference.

Line of Baillarger.

In thick sections this line is plainly visible with the naked eye, and assumes the form of a dark broad band, but in thin preparations, the microscope is required to disclose it, and when so examined it is found to be composed mainly of small fibres, interlacing and intertwining in all directions, mingled with which is an appreciable number of horizontally directed fibres of medium size; to the latter the line in a large measure owes its depth of colour, in thick sections.

Radiary Zone. (Text figs. 1 and 5.)

It is the appearance presented by the radiating fasciculi of projection fibres, the interradiary plexus, and the association fibres, in short the combined radiary zone, which above all gives character to the postcentral cortex and distinguishes it from that of any other field in the brain.

In describing the precentral cortex it was stated that the radiate fasciculi were numerous, richly stocked with fibres and voluminous, that the interradiary collaterals were extremely abundant, that the association system of fibres was particularly well-represented, and that these sets of fibres altogether combined to form a zone of great depth, and of such density and bewildering complexity that it could be readily recognised with the naked eye by the attendant intensification of colour. Contrasting this with the arrangement in the postcentral cortex, we find that the radiate fasciculi are attenuated instead of voluminous; the plexus formed by the association fibres and interradiary collaterals combined, open instead of dense; and no dark-stained zone, but only a relatively thin and pallid band is seen capping the medullary projection. In the walls of the Rolandic fissure, these differences are quite as marked as they are along the crown of the convolutions, and taken altogether a single glance serves to distinguish one gyrus from the other.

(*a*) *Radiations of Meynert.*

Analysing more closely the component parts of the postcentral radiary zone, we find, in regard to the radiations of Meynert, that two or three fibres of large size constitute the main support of each fasciculus, and around these fibres of medium size are clustered. In

FIG. 5. Radiary Zone in the Postcentral Cortex $\times \frac{45}{1}$.

Compared with figure 1 (precentral area) the disparity in fibre wealth is obvious. Some of the large fibres characterising this cortex are shown, and it will be seen that they have a larger calibre than those in the precentral cortex, and that they tend to avoid the radiations of Meynert.

the fissure of Rolando the radiations are short and stumpy, but still they contain large fibres. It appears that as many large fibres are present in the postcentral radiations as in the precentral, but the latter have the advantage in regard to the number of fibres of medium size they accommodate.

(*b*) *The Interradiary Plexus.*

We now come to a formation the fibre characters of which are so peculiar, that, even if the section were unlabelled, a single glance would enable one to declare that it came from the "postcentral" area. It is not the appearance of the delicate fibres, constituting

the interradiary plexus proper, which is striking, but the presence throughout the radiary zone of an abundance of fibres of large calibre, the majority of which run horizontally or obliquely; these are seen to perfection at the lip of the Rolandic fissure, where they form a coarse and rich plexus; but further along the crown of the convolution, and also in the Rolandic wall they are not so numerous. The oblique course which these fibres follow is to be specially noted, because, having discovered that such fibres frequent known sensory areas, *e.g.* the primary visual and auditory centres, I venture to assume that their obliquity of position signifies that they are designed for the conveyance of centripetal impulses, and that they impinge on cells deep down in the cortex. This point will again be introduced when the function of this area is discussed.

In addition to these fibres running in the plane of section many others of equal size are visible, which have been cut transversely and form perfect rings, and which, therefore, must be ascending the convolution in a vertical direction.

(c) *Association Fibres.*

Anatomically speaking, the large fibres just described pertain to the association system, because in some part of their course they seem to occupy the position where the so-called association fibres—Meynert's *fibrae propriae*—are to be sought, namely, along the margin of the white substance; hence it is impossible to pick out the latter for analysis.

With regard to intergyral connections, I have closely examined the floor of the fissure of Rolando in a great number of sections, with the view of ascertaining whether any of these large, deeply-placed fibres could be traced definitely and continuously from the postcentral to the precentral side, but always without success, and the conclusion I have arrived at is, that if that association is consummated the path followed does not lie in the cortex; I would not say, however, that the white substance immediately below the cortex does not constitute the medium of conveyance, but in point of fact there is such a confusion of fibres in this situation that it is impossible to trace individuals for any distance, and one cannot speak definitely on the point.

One point stands out clearly—the floor of the fissure of Rolando forms a definite boundary for a change in type.

Medullary Projection.

If a fair transverse section of the two central convolutions be inspected with the naked eye, it will be at once noticed that while the outline or figure of the anterior projection is stout, rounded, and voluminous, that of the posterior is thin, drawn out, and pedunculated; and another point of some importance is, that in thin transverse sections of the postcentral medullary projection, numbers of large fibres, cut transversely, may be seen, and these occupy a certain position, namely, the anterior half, that is to say, the half which underlies the cortex just described.

Topical Variations in the Postcentral Type of Fibre Arrangement.

We found that topical variations occurred in the "precentral" area; it is the same in the "postcentral" field.

To begin with, a section from the upper end of the area is easily distinguishable from one from the lower extremity, and this is so principally because, proceeding from above downwards, there occurs a gradual and progressive diminution in the number, and also in the calibre, of those large fibres which have been described under the headings of interradiary plexus and association fibres. It so comes about, that a section from the lower end of the "postcentral" area bears a resemblance to one from the upper end of the "intermediate postcentral," for the same change takes place in the latter field.

According to Passow, the general fibre wealth of the cortex of the postcentral convolution begins by increasing from above downwards, it reaches a culminating point about two-thirds of the way down, and then gradually diminishes again. But this certainly does not apply to the large fibres to which I have referred, for I can state, without hesitation, that they exhibit their best development in the small portion of the "postcentral" area on the mesial surface, and along the upper third of the area on the lateral surface of the hemisphere, and the diminution in wealth is, as I have said, progressive from the beginning.

In its bearing on other layers and systems of fibres I am also inclined to doubt the correctness of Passow's statement; in the zonal layer for instance, it is in the upper part of the area, and here alone, that large medullated fibres are recognisable; again, the richness of the plexus in the supraradiary layer diminishes without intermission from above downwards; and, finally, there is no question that the line of Baillarger is denser in the upper part of the area than in the lower, although its breadth remains stationary in all parts.

In connection with this line, I may mention incidentally, that in the brain of the female, aet. 37, it formed a much more prominent band than it did in the brain of the male, aet. 29, or of the female, aet. 21, and as the sections in all cases were stained in precisely the same manner, confirmation is given to Kaes' statement that its development proceeds progressively up to the age of maturity.

B. TYPE OF CELL LAMINATION IN THE POSTCENTRAL AREA. (Plate III, fig. 2.)

Plexiform Layer.

The plexiform layer looks shallow when compared with that of the "precentral" cortex, but Nissl specimens reveal no noteworthy differences of constitution.

Layer of Small Pyramidal Cells.

This layer seems to possess a slight advantage over the "precentral" layer in point of depth, likewise the cells are more numerous and give the lamina a crowded appearance, but in regard to cell size and shape there is no noteworthy difference.

Layer of Medium-sized Pyramidal Cells.

These cells closely resemble those of the "precentral" cortex, but the lamina they form is appreciably shallower, apparently owing to the better development of the next layer.

External Layer of Large Pyramidal Cells.

The appearance presented by this layer constitutes an important point of distinction between the "postcentral" and "precentral" types of lamination. In the former the cells are much larger and more numerous, and they form a well-marked, almost prominent lamina, ·40 mm. in depth, showing several superimposed rows of elements. Here, the cells average 22 by 43 μ in diameter, and have a nucleus measuring $10 \times 7\,\mu$. In shape they are elongated and pyriform, and not so plump as the corresponding cells in the precentral cortex; three or more distinct processes spring from the lower angles and sides of the body, and the apical process, which becomes attenuated very gradually as it leaves the body, is of such length that, even in Nissl specimens, it can be traced for a distance of 200 μ. In the substance of the cell chromophilic elements can be recognised, but they are not sufficiently numerous to give much depth of staining to the body. On enumeration 35 to 40 of these cells are found per transverse millimetre of cortex, but while this number is maintained throughout the gyrus, they suffer a reduction in size as the convolution is descended. While the cells just described constitute the predominant element in this lamina, others of a different character have to be mentioned. These cells are similar in shape but of larger size, a feature which proclaims itself clearly when they are examined, and especially when they are drawn, under a high magnification. Along with the increase in size a greater prominence of the nucleus and the nucleolus is noticeable. Further, the substance of the cell is now packed with large chromophilic elements, so that altogether it comes to resemble an elongated but miniature Betz cell. Their average measurement is 30 by 75 μ. Such cells exist in greatest abundance on the paracentral portion of the gyrus, where one is found for every five other large pyramidal cells of the same layer; on the convexity they are much less numerous, 1 to 20, and they gradually disappear as the convolution is descended.

Layer of Stellate Cells.

The remarkably good development of this layer enables one to distinguish postcentral from precentral cortex at a glance. Sharply defined, intercalated between the two laminae of large pyramidal cells, ·23 mm. in depth, and packed with small deeply-stained elements, the layer stands out very distinctly; and in the paracentral region, where there is no fissure of Rolando to act as a divisional guide between the two areas, the advent of this lamina immediately proclaims a change in type. Just in the same way, when the Rolandic cortex is inspected, this lamina is always plainly demonstrable, descending the posterior wall in band form, but ceasing the moment the floor is touched.

Internal Layer of Large Pyramidal Cells.

It has been stated by S. Ramón y Cajal that this layer is equivalent in general representation to the external layer of corresponding cells, but this is an error. To satisfy myself on this point I have made drawings of sections taken at intervals of 1 cm. all the way

down the postcentral gyrus, representing in each the number of cells present in the respective layers in a transverse millimetre of substance, the result being that for every one cell seen in the internal layer, close on three can be found in the external, and this preponderance is maintained with slight variations throughout the whole extent of the gyrus. In size and general appearance, these cells resemble the common type of suprastellate, large pyramidal cell, and accordingly do not call for special description.

But just as cells of a special character are interspersed among the external large pyramidal cells, so it is again with this lamina. Now the cells to which I refer are in all probability the elements which Betz and others have seen and regarded as identical with the giant cells of the precentral area, and as I am convinced of the incorrectness of this assumption, it is important that I should describe their characters in detail.

First, as regards size, it is perfectly true that they are considerably larger than any other cells in the postcentral region, but, as may be observed in figure 6, when they are drawn under a high power and represented beside precentral Betz cells, drawn at the same magnification, the difference between the two becomes very obvious; indeed the diameters of the largest postcentral cell, which may be put down as $20 \times 50\ \mu$, fall well below the diameters of even an average-sized precentral giant cell.

There are also differences in sectional outline. In describing the conformation of the precentral giant cell it was soon decided that the term pyriform was the most applicable, here after looking very carefully at a number of these postcentral cells I have come to the conclusion that the expression pyramidal is the best. I have also noticed that the apical extension tapers away very gradually, and the point where it joins the body proper, not being marked by any more or less sudden attenuation, as it is in the case of the precentral cell, is difficult to determine.

Another reason why these cells stand out prominently is that they are richly supplied with chromophilic elements; in this respect they resemble the precentral giants. For the same reason the outline of the nucleus is obscured, and in consequence this structure looks small.

Unlike the typical cells of Betz these elements are not found lying in nests or clusters, but prefer the solitary arrangement.

Concerning distribution, these cells are practically confined to the paracentral extension and the upper sixth of the lateral portion of the postcentral gyrus, and they are undoubtedly seen at their best, both as regards number and magnitude, in the first-mentioned situation; crossing on to the lateral surface of the hemisphere they suffer a reduction in size, at the same time becoming scarcer; then, when the upper sixth of the gyrus is passed, they rapidly give way to much smaller chromophilic elements, not unlike those already noted as constituents of the external layer of large pyramidal cells, and they finally disappear altogether before the lower extremity of the convolution is reached.

In conjunction with the fact that these large cells occur in a part where the remainder of the lamination is essentially of a postcentral type, it is to be observed that they occupy that particular cortex, wherein the plexus of coarse medullated postcentral nerve fibres is richest. And, in addition to normal histological differences, their behaviour in certain pathological conditions leaves no doubt that we have previously been in error in including them in the category of motor cells, because when we discuss their function, I shall point out that they are not included in the giant cell destruction seen in cases of amyotrophic lateral

sclerosis, but that, on the other hand, in diseases involving the sensory neurones, such as *Tabes dorsalis*, and after amputations, they undergo profound changes.

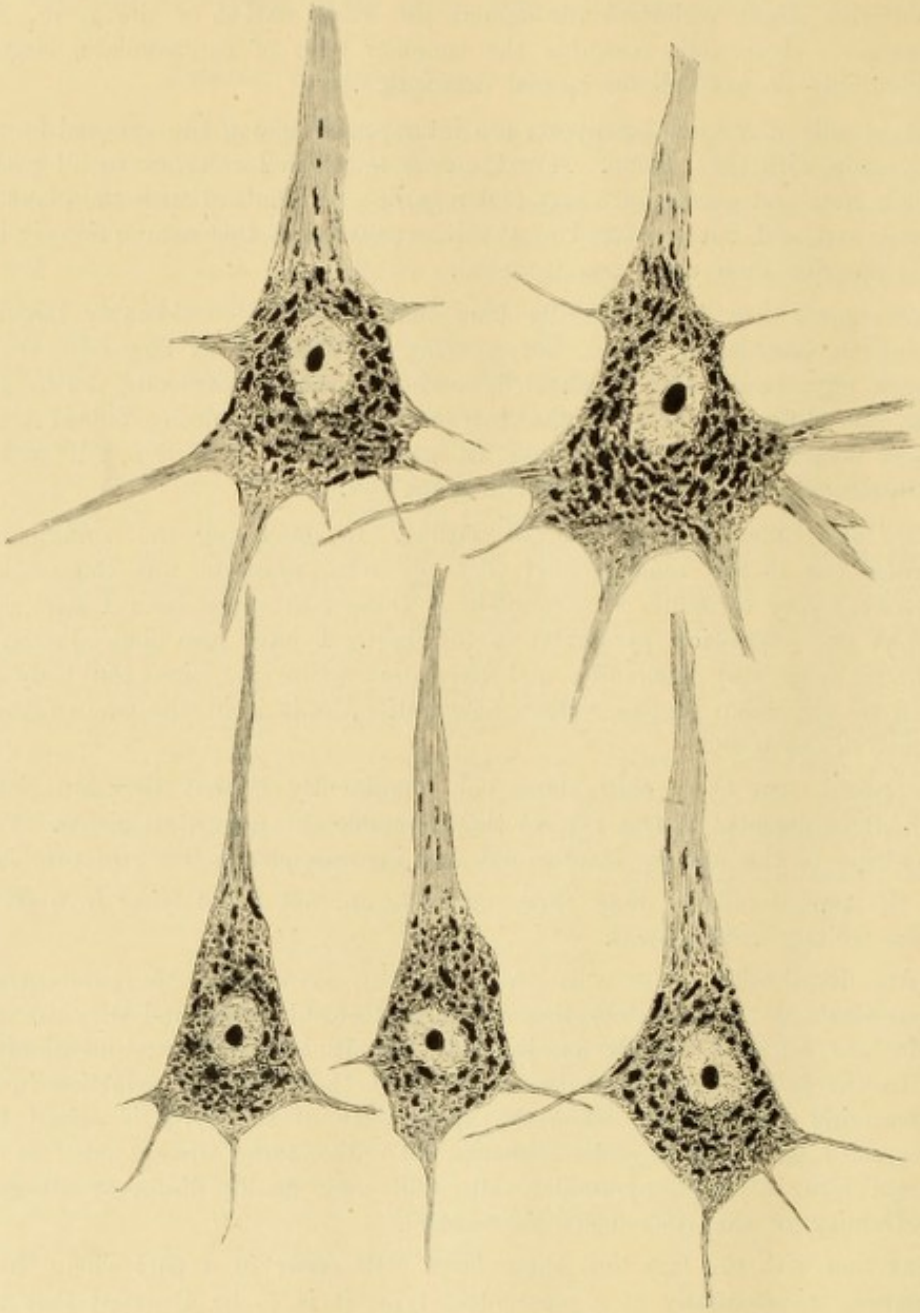

FIG. 6. Drawings of two small precentral giant cells (the upper ones in the figure) can here be compared with drawings of three of the largest cells to be found in the postcentral gyrus.

The difference is mainly one of size but other points of distinction are alluded to in the text.

Both sets of cells come from the mesial surface of the hemisphere (paracentral lobule), the precentral cells from before, the postcentral from behind, the level of the fissure of Rolando.

Crush specimens, thionin staining. Leitz ocular drawing apparatus. Zeiss apochromatic oil immersion 2 mm. lens.

Layer of Fusiform Cells.

This layer does not call for special comment, as the elements it contains resemble those met with in most other parts of the cortex.

Distribution of the Postcentral Area. (Plate I.)

Roughly speaking, the postcentral type of cortex is distributed over the anterior half of the postcentral convolution on the convex surface of the hemisphere, and like the precentral formation it crosses the upper margin of the hemisphere on to the mesial surface, to cover a small tongue-like area situated on the paracentral lobule, immediately behind the upper extremity of the fissure of Rolando. Anteriorly (on the mesial aspect) it lies in contact with the upper extremity of the "precentral" area; and, below and behind, it is enclosed by the "intermediate postcentral" area, which in turn is limited by the calloso-marginal fissure.

In those brains in which the fissure of Rolando does not cross the upper margin a postcentral strip of cortex is still found on the mesial surface, and its anterior boundary is then formed by a line drawn downwards, continuous with that fissure, and parallel with the calloso-marginal tailpiece. We thus see, that on the mesial surface the position and extent of the area is directly influenced by the upper extremity of the fissure of Rolando.

At the upper margin of the hemisphere the area is slightly narrower than it is elsewhere.

On the lateral surface, the fissure of Rolando again forms a most important and definite boundary, for the whole of the anterior wall of the postcentral gyrus, down to the very floor of that fissure, is covered by "postcentral" cortex. On the free surface of the gyrus the change in character from "postcentral" to "intermediate postcentral" cortex does not take place abruptly, still it is approximately correct to describe the dividing line as running down the centre of the gyrus. Inferiorly, however, while cortex having "postcentral" characters can be followed on the posterior wall of the fissure of Rolando down to its extremity, it generally recedes from the surface about a centimetre above this point, so leaving the exposed part of the lower end of the ascending parietal gyrus covered by "intermediate postcentral" cortex.

From the above account it is quite obvious that as the major portion of the "postcentral" cortex lies concealed within the fissure of Rolando, it is impossible to give a correct representation of its distribution in a surface diagram.

The Postcentral Cortex in the Anthropoid Ape. (Plate II.)

As regards character, a type of cortex can be made out in the brain of the man-like ape which bears an extraordinary resemblance to that obtaining in the human being; in fact, the appearances may be briefly described as being a reproduction in miniature of the human features.

The same similarity holds in regard to distribution, and in all three brains examined the area has stood in the closest relation to the fissure of Rolando.

STRUCTURE OF THE INTERMEDIATE POSTCENTRAL AREA.

A. TYPE OF ARRANGEMENT OF FIBRES.

(Plate I and Plate V, fig. 2.)

As is the case in the "precentral" area, so also in the "postcentral" region, the transition from the "typical" to the "intermediate" type of arrangement takes place gradually; however, if in a transverse section of the postcentral gyrus the arrangement of fibres in the cortex be carefully traced round from the Rolandic to the parietal side, the following changes will be found to occur. (1) The zonal layer, which is poorly developed to begin with, becomes fainter still, and those large medullated fibres, which were described as being

FIG. 7. Radiary zone in intermediate postcentral area $\times \frac{45}{1}$.
Under a high power the fibres of large size seen in the postcentral area proper (Figure 5) have to a great extent vanished.

occasionally present at this level on the Rolandic side of the gyrus, vanish altogether; (2) in like manner, the supraradiary plexus loses in wealth of fibre representation. (3) The line of Baillarger, while retaining its width and position, becomes obviously less dense, and owing to the relative paucity of fibres of medium calibre its depth of staining is not so intense. (4) Since the radiations of Meynert cease to contain coarse medullated fibres, the fasciculi lose their bold

appearance. (5) The interradiary field undergoes important changes, and in fact assumes an entirely different aspect, for although the fibres of delicate calibre remain as before, those large medullated fibres which cross the radiations at all angles and form such a prominent and characteristic feature of the typical postcentral cortex disappear, to be replaced by sparsely distributed fibres of medium size only. (6) Large fibres are absent from the white substance immediately underlying the cortex.

In the lower parts of this "intermediate postcentral" field, the fibres generally suffer a reduction in calibre, a change which accentuates the difficulty of defining its lower boundaries.

In the anthropoid brain, the "postcentral" area is bounded behind by an "intermediate" zone of cortex, of which the characters are uncommonly like those described above.

B. TYPE OF CELL LAMINATION. (Plate VI, fig. 2.)

Judgment on the differences between the primary and intermediate types of postcentral cortex is not made so readily from sections stained for nerve cells as from sections showing the fibres, still there are a few points worthy of mention.

On following round the layers of large pyramidal cells, both external and internal, it is of importance to notice that the moment the intermediate field is reached those larger chromophilous elements, which were described at length in discussing the postcentral area proper, cease to be represented, while at the same time the common remaining constituents undergo a slight reduction in size and number. It may also be observed that the inequality of representation between these two large cell laminae becomes more decided, and on account of the relative paucity of large substellate elements an appearance of advanced development is imparted to the underlying fusiform layer. In this respect the "intermediate" type assumes a feature which will be seen to be possessed by the ordinary "parietal cortex."

The lamina of stellate cells in the "intermediate" field seems to be of greater depth, but not so closely packed as it is in the primary area.

Not so obvious on simple microscopic inspection, all the above-mentioned points come out plainly when camera lucida drawings of cells from the two areas are made and compared.

Distribution of the Intermediate Postcentral Cortex. (Plate I.)

The definition of the boundaries of this area does not present much difficulty. Anteriorly it merges with the "typical postcentral" field. On the mesial surface it occupies the hinder part of the paracentral lobule, being limited by the calloso-marginal fissure, it thus forms a bed for the diverticulum of postcentral cortex situated here. Below this it usually comes in contact with the "intermediate precentral" area, but the dividing line here is by no means definite. At the upper margin of the hemisphere the upper extremity of the calloso-marginal fissure forms a constant posterior limit. The next link in the boundary is formed by a line dropped from the calloso-marginal incisure to the sulcus postcentralis superior, and this sulcus and the sulcus postcentralis inferior both form limits. In some cases the intermediate arrangement of fibres extends down the anterior wall of the postcentral sulci for some distance, but it never seems to cross them, hence the calloso-marginal and the postcentral sulci may be regarded as fixed boundaries.

It has been noted already, that although cortex having typical postcentral characters can be followed along the posterior wall of the fissure of Rolando down to its lower extremity, it usually recedes from the surface a centimetre or more above this point, so leaving the whole of the superficial part of the lower end of the ascending parietal gyrus covered by intermediate cortex. And, such cortex extends a short distance below the extremity of the fissure of Rolando, but apparently not on to the operculum, although in this situation, on account of the fusion of the intermediate pre- and post-central types, the definition of the boundary is difficult.

Distribution of the Intermediate Postcentral type in the Anthropoid Ape. (Plate II.)

In the brain of the first chimpanzee examined, in which the calloso-marginal fissure followed a course like that in the human brain, this area also had a human distribution, but in the case of the second chimpanzee and also in the orang, an irregular arrangement of the tail of the calloso-marginal fissure made it difficult to locate the posterior limit of the field on the mesial surface, and also along the upper margin of the hemisphere.

FUNCTIONS OF THE POSTCENTRAL AREAS.

While from the functional point of view our knowledge of the postcentral region is wrapt in obscurity, the road to its further consideration and investigation has been cleared, although in a negative manner, by the experimental researches of Professors Sherrington and Grünbaum, referred to in the preceding chapter; because these researches clearly show that the postcentral gyrus, whatever else its function may be, must be ousted from the position it has held for so many years as part of the motor area.

Briefly recapitulating the evidence on this point, we find that in the long series of experiments conducted on anthropoid apes by the above-mentioned observers, never, save under exceptional circumstances[1], were responsive movements obtained from electrical excitation of the postcentral gyrus; again, not only was this convolution "silent" when exposed to the influence of electrical stimulation, but ablation measures proved as negative in the production of motor paralysis as similar measures had proved positive in the case of the precentral gyrus. Moreover, on extending their experiments to lower members of the ape family—the animals, be it noted, which afforded material for earlier workers in this province—there was a repetition of the negative results, thus annulling the possible contention which might be exploited by previous experimenters that the anthropoid differs from the lower ape in regard to the distribution of its motor area. It is unnecessary for me to pursue this question

[1] On account of the cost and difficulty attending the obtainment of anthropoid apes Professors Sherrington and Grünbaum spared no effort to make full use of the animals which came into their possession, accordingly after they had served their immediate purpose as means to the determination of the motor area they were always further employed as material for other scientific investigations. Now one animal, in which the influence of the typhoid bacillus was being studied, developed typical meningitis over the cortical area previously laid bare, and I am informed that a repetition of the stimulation measures on the cortex so inflamed produced responsive movements not only from the precentral but also from the postcentral gyrus. But this result, which must be looked upon as an extraordinary one, is fully commented upon in Professors Sherrington and Grünbaum's paper.

In other cases the interesting fact was disclosed that movements ordinarily obtained by excitation of the precentral gyrus were elicited more readily when the postcentral gyrus was coincidently stimulated at the same horizontal level.

further, as it is fully and most ably dealt with by Professors Sherrington and Grünbaum—suffice it to say that I accept the finding of these observers as correct.

Assuming, therefore, that in the ape family and more particularly in that class in the phylogenetic series which approaches most closely to the human being, the postcentral gyrus is devoid of motor function, we have next to consider whether a parallelism with man exists.

While the evidence on this point is hardly conclusive, reasons are not wanting for believing that it does. In the first place, the facts brought to light by histological research are, to say the least of them, cogent, because it can be demonstrated with unequivocal certainty that in both man and the anthropoid ape the postcentral gyrus possesses a remarkable similarity of structure; moreover, in both cases the structure of the convolution differs entirely from that of the precentral. Next, in regard to the effects of electrical excitation of the human brain, it is of course information under this heading which would prove most valuable in obtaining a conviction concerning the above-mentioned parallelism, but unfortunately such a short period has elapsed since the publication of Professors Sherrington and Grünbaum's researches, that their discoveries have hardly become sufficiently well-known for surgeons to take full advantage of them, and at the present moment I am not aware of any published account giving the results of the application of the necessary special method of excitation to the human brain; however, from private information received, I understand that two well-known surgeons during the performance of operations on the brain have had occasion to put this method to the test, and contrary to previous experience in the human subject, have found the postcentral gyrus as inexcitable as it is in the ape. I am also led to believe that one of these operations involved a partial ablation of the postcentral gyrus, and this procedure was likewise unattended by any motor paralysis. Of ordinary clinical observations bearing on this question I shall have occasion to write later, here I would merely mention that this is the only case, so far as I know, in which the effects of a localised lesion in the postcentral gyrus have been carefully studied, since the publication of Professors Sherrington and Grünbaum's work.

From the foregoing it is plain that I am strongly impressed with the idea that as in the ape, so also in the human being, the postcentral gyrus is to be excluded from the motor area, and I am also satisfied that it only needs a few more observations on the human brain firmly to establish the existence of this parallelism.

Taking it for granted then that the postcentral gyrus plays no direct part in the control of volitional movement, the way is now cleared for a consideration of the function which this field possibly subserves, and that a field equipped with such a distinctive fibre arrangement and cell lamination does not stand related with some special and important function it is impossible to believe.

To simplify matters I might at the outset state that as a result of histological and pathological studies coupled with a general consideration of the work of others, and particularly that of clinical observers, I have become impressed with the idea that it is in the postcentral gyrus that we have to look for the centre, or arrival platform, for the reception of sensory stimuli of the common order which have travelled up from peripheral parts; consequently, the line of argument taken in the following pages will be directed to the question of the cortical localisation of "common sensation."

Now it must be patent to all who are interested in questions of cerebral localisation, that on account of the prevailing diversity of opinion, and the remarkable paucity of definite

information which we can command concerning the localisation of "common sensation," the investigation of this subject is beset with unusual difficulties. I shall mention later that the knowledge which we have obtained from an accumulation of clinical observations on the human subject needs revision, and that as far as experiment on lower animals goes, the information gained is so inadequate that most physiologists have temporarily abandoned hope of further gain from this method of investigation. To my mind, however, this unsettled state of affairs is in large measure attributable to two causes: one is the long-standing and firmly rooted but erroneous belief, that the two central gyri are both motor in function, and the second is that too little regard has been paid to a thorough preliminary investigation of the anatomical pathway and cortical connections of the main sensory tract. The first of these causes has already been removed, and I should like now to draw attention to some points in anatomy and histology, normal and morbid, bearing on this subject, which may be of service to the experimenter and clinician in the execution of future observations, and which in my opinion favour the assumption that the cortex of the postcentral gyrus is as strictly a sensory centre as is the visual or auditory area.

ANATOMICAL AND HISTOLOGICAL CONSIDERATIONS.

From studies of secondary degenerations and retrograde atrophies and from observations on the developing brain, it is now definitely settled that the sensory tracts of fibres in the spinal cord, after being interrupted in the nuclei of Goll and Burdach, are continued onwards in the medial lemniscus[1]; and, that just as the motor fibres, or at any rate a major proportion thereof, decussate at the lower end of the medulla, so also these sensory fibres cross over in the decussatio lemniscorum. The further course of these fibres has been studied in both man and the lower animals by von Gudden, Flechsig and Hösel, Monakow, Mahaim, Mott, Tschermak and many others, and it is now believed that save minor connections, for instance with the superior colliculus, which need not be considered here, the bulk of the fibres gain and are interrupted in the optic thalamus. This conclusion, however, has not been reached without a considerable amount of discussion, for certain writers maintained for a long time that most of the fibres composing the medial lemniscus proceeded without interruption through the internal capsule and out in the corona radiata to the cortex cerebri; and even though it is now admitted that this was a false belief, so far as the bulk of the fibres is concerned, it is still considered probable that a certain number do follow this uninterrupted course. But to us this is a point of minor interest compared with a consideration of the course and destination of the next link in the system, that extending from the region of the thalamus to the cortical surface.

This collection of neurones is best known as the "cortical lemniscus" and is usually associated with the name of von Monakow, because that observer was not only the first to describe it, but has also supplied us with more information concerning it than any other writer. The term owes its introduction to von Monakow's discovery that ablation of that portion of the parietal lobe in the cat which corresponds to Munk's zone F, was followed by changes

[1] This is not to be confused with two other tracts of fibres bearing the name lemniscus, viz., the lateral lemniscus, which has been proved to be a pathway for centripetal auditory impulses; and the medial accessory lemniscus, which is to be distinguished because it has been proved that its fibres are late in acquiring their myelinic sheath and also degenerate in a descending direction.

in the hypothalamic region, as well as by pronounced atrophy of the medial lemniscus; and although he has not been able to give us a clear idea of the course of the cortical division of this fibre system, he has established its existence by proving that the integrity of the ponto-bulbar division of the same system is dependent upon a sound condition of the cortex.

Attempts to trace the "cortical lemniscus" by degenerative methods in the lower animals (dog, cat and monkey) have not been wholly successful. Von Monakow, Mott, and others, after division of the lemniscus in its pontine or medullary course, were unable to follow the subsequent ascending degeneration beyond the hypothalamic station, and Tschermak alone has obtained positive results. The cat was the animal chosen by Tschermak, and after describing the degeneration up to and about the thalamic region in the greatest detail, he goes on to say that a number of scattered degenerated fibres passed out through the internal capsule and the laminae medullares of the lenticular nucleus into the corona radiata, to finally stream up to the cortex over an area of considerable extent lying behind the fissura coronalis. This area Tschermak looks upon as the equivalent of the human gyrus postcentralis, in accordance with Meynert's contention that in the cat, the sulcus coronalis, and not the sulcus cruciatus, is the homologue of the fissure of Rolando. Tschermak's work bears the stamp of thoroughness and is favourably commented upon by those qualified to criticise, and it would suit my views to accept his results without reserve. At the same time, however, we must remember that the human being is a long way removed from the cat, and though it may be true that in this animal a large proportion of fillet fibres proceed direct from the posterior column nuclei to the cortex, without interruption in the thalamic region, it would be unsafe to infer that the same obtains in the human being; indeed Mott's contrary experience in the case of the monkey and also Horsley's go some way towards preventing this assumption. The work of von Vejas, and Singer and Münzer might be quoted in this connection, but I think enough has been said to show that, up to date, the study of degenerations in the lower animals has been inadequate to the determination of the exact course of Monakow's "cortical lemniscus."

We are therefore obliged to turn for information to accounts of degenerations affecting this region in the human being, and fortunately there are cases on record, now almost classical, which afford instruction. Foremost we have the well-known case worked up by Hösel in Flechsig's laboratory, one of a porencephalic lesion chiefly involving the postcentral gyrus of the left hemisphere, in which the discovery of secondary changes in the medial lemniscus, traceable downwards as far as the posterior column nuclei, originated Flechsig and Hösel's now exploded view that these nuclei were brought into relation with the postcentral cortex by a single, that is to say, uninterrupted tract of neurones. Now it is interesting to find that Tschermak, to whose experimental work in this direction I have already referred, was given the advantage of restudying Hösel's original specimen, and as he paid particular attention to the supposed connections of the "cortical lemniscus" his observations are well worthy of special notice. The old-standing surface lesion is described as involving the whole of the ascending parietal convolution, spreading upwards over the paracentral lobule, and reaching as far as the insula in the downward direction, and also extending slightly on to the upper extremity of the ascending frontal and superior parietal gyri; in association with this there was some destruction of the underlying white substance. From this lesion a strand of degenerated fibres proceeded down to the internal capsule, there to split into two parts, one of which was destined for the pes pedunculi and was evidently a part of the motor tract (the corresponding motor bundles in the pons, medulla and spinal cord had undergone degeneration), while the other of larger size

and representing the "cortical lemniscus" was followed mainly into the ventral half of the nucleus lateralis thalami, which was profoundly atrophied. Of course, as has already been mentioned, the corresponding medial lemniscus was also atrophied.

This very carefully studied case is of the greatest interest to us, not only because it gives us much-needed information about the "cortical lemniscus" but because it strongly suggests that the cortex of the postcentral gyrus is the end station of the sensory system of neurones, and also that this station is much more limited in extent than others would have us believe.

Other cases bearing on the subject are those recorded by Mahaim, the Dejerines, and Jakob. In Mahaim's frequently quoted case, and also in Jakob's, the lesion was a primary defect of both central convolutions; while the Dejerines examined nineteen hemispheres in which there was an old-standing destructive lesion in the Rolandic area[1]. In all these instances, more or less profound alterations affected the lateral hypothalamic nuclei, and, in most, a secondary retrograde atrophy of the medial lemniscus was observed. But while they all afford satisfactory confirmation of the existence of an interrupting station in the thalamic region, they do not satisfy our demand for knowledge concerning the course of the fillet from the thalamus to the surface; and since in all, the lesion was distributed over both central gyri, they cannot be used either for or against Tschermak's contention that this system of fibres is destined for the postcentral gyrus only.

Reflecting on the information concerning the pathway and destination of the "cortical lemniscus" supplied by these studies of degenerations in both human being and lower animals, one cannot refrain from expressing regret that the evidence is not more conclusive than it is, and also that in previous years one has allowed to slip through one's hands material which might have proved valuable in solving our problem. For although we have still to consider the results of developmental findings, I feel sure that the path followed by this particular link in the sensory chain will not be finally settled, until it is carefully studied in cases in which it is in an active stage of degeneration. Now since it seems undeniable that the cells whose axons compose this tract reside in the hypothalamic region, or more accurately speaking in the ventro-lateral group of nuclei of the optic thalamus; and since for reasons some of which have been already stated and others of which I shall emphasise later, it appears that the post-central gyrus and particularly the Rolandic face of that gyrus is the cortical terminus of those axons, it follows that the ideal lesion for the study of the degeneration would be one localised in the ventro-lateral nuclei of the thalamus. But unfortunately the chance of obtaining a case, say of softening, tumour formation or haemorrhage in the human subject, so limited as to involve this part without complicating other structures is almost as remote as the possibility of producing the necessary lesion artificially in one of the lower animals; baulked in this direction, however, we could still turn and study the effects of a lesion in the opposite extremity of the neuronic link, that is to say, in the postcentral gyrus. Of course in this case we should have to produce a degeneration proceeding against the stream of physiological conduction, which, if Waller's law were wholly true, would be impossible, but it was proved by

[1] It is mentioned by the Dejerines that atrophy of the medial lemniscus was not invariably present in their cases, but it seems that the occurrence of such an atrophy is merely a question of time, for in several cases of similar lesions of old-standing which have come under my own observation, and also in other cases recorded in the medical press, reduction in volume of the medial lemniscus, wasting of internal arciform fibres, etc. have been outstanding features. The atrophy is of course of a retrograde nature, affecting fibres thrown out of activity by the destruction of the terminus on which the impulses they convey are projected, and its onset is quite in accordance with what we know of retrograde degenerative manifestations affecting other systems of nerve fibres.

Darkschewitch ten years ago and it has been confirmed by Bregmann, Klippel and Durante, van Gehuchten, and many others since, that the negative proposition contained in the law of Waller, namely, that a nerve fibre separated from its trophic centre does not degenerate in its proximal end, is a false one; and, in fact, this retrograde or indirect Wallerian degeneration, as it is called, is histologically indistinguishable from the true and originally described form, but differs pathologically in being more tardy in making its appearance; for whereas the true Wallerian degeneration manifests itself six, seven, or eight days after the lesion, the indirect form is not evident until about the twentieth day. Therefore, since much valuable work has been done by this method and it seems thoroughly reliable for tracing tracts of fibres, it only remains for us to try to work out the course of the "cortical lemniscus" by studying the degenerations running in association with lesions of the postcentral gyrus; for this, lesions produced experimentally in lower animals, preferably the ape, or natural lesions in the human brain would be suitable, but as it seems impossible to cause destruction of a large portion of the postcentral, or any other gyrus, without injury to neighbouring convolutions and other tracts of fibres than the one it is desired to investigate, I would suggest that limited lesions, if possible confined to the cortex only, be made or chosen for the purpose.

Points in the Development of the Sensory Tracts.

As Flechsig was able to demonstrate with such clearness and certainty, that the fibres in the posterior columns of the spinal cord standing in connection with the posterior roots are distinguishable from all the other long systems of fibres inasmuch as they acquire their myelinic investment at a remarkably early period, it might be supposed that the course of the upper segments of the same neuronic chain could for a like reason be readily picked out; but although this may be said to apply to the bulbo-thalamic segment, it does not appear to hold in the case of the thalamo-cortical. There are, however, several reasons why the pursuit of this upper portion of the sensory tract should be attended with difficulty, and perhaps the most important is, that in this particular region, and certainly in the vicinity of the thalamus and internal capsule, the arrangement of structures is of an exceedingly complex nature; and apart from this serious impediment we have to bear in mind that with an increase in the size of the section the troubles in regard to orientation are proportionately amplified. What I mean to say is that while it may be a simple matter to follow parallel-lying tracts of fibres in a small area like that covered by a transverse section of the spinal cord, it is otherwise when we have to explore complete sections of a cerebral hemisphere, wherein the direction of the fibre bundles is one of infinite disorder; add to this the fact that developmental workers have been exposed to the liability of being led astray by having to take notice of the belief that both the central gyri were motor in function, and the shortcomings in this connection of which we may have to complain will be understood.

Now as Flechsig stands preeminent among neurologists who have devoted their attention to embryological research, it is necessary that we should first enquire into his findings and conclusions concerning the tract of immediate interest, the "cortical lemniscus." In his great work, he tells us that the centripetal or sensory fibres are found more or less "en masse" in the posterior portion of the pars occipitalis of the internal capsule, and that they are divisible into three sets, according to the different periods at which they maturate. The first set appears at about the beginning of the ninth month of foetal life, and is said to spring from the nucleus

lateralis of the thalamus and from Flechsig's cup-shaped body (schalenförmiger Körper), and to terminate exclusively in the two central gyri (*vide infra*). This set is recognisable immediately behind the place to be filled later by the fibres of the pyramidal tract, and some offshoots course in the external capsule and lamina medullaris externa of the lenticular nucleus. The second set becomes medullated a month later and its fibres, derived from both the nucleus lateralis of the thalamus and the "centre médian" of Luys, chiefly proceed to the central gyri, the paracentral lobule and the base of the superior frontal convolution, while some bend round into the gyrus fornicatus and cornu ammonis. The third set runs in the middle of the internal capsule and is destined for the inferior frontal convolution, the gyrus fornicatus, the anterior half of the upper frontal and the base of the middle frontal gyri.

Of these sets of fibres, the first is the only one which need concern us here, because although Flechsig is evidently unable to describe its origin definitely and apart from other sets of fibres arising from the red nucleus and from other structures in this situation, and can only give us a diagrammatic representation of its course, there seems no doubt that he regards it as the main continuation of the lemniscus proper, and that it is to these fibres he refers when he says that "the lemniscus (Hauptschleife) terminates in the central convolutions and exceptionally in the anterior portion of the superior parietal gyrus"; and, further, "that, in man, many more sensory fibres proceed to the ascending parietal than to the ascending frontal gyrus."

In spite of his pointed remark to the effect that the postcentral gyrus is the receiver of more sensory fibres than the precentral, Flechsig has firmly advanced his histological results in support of the hypothesis of the functional unity of the two central convolutions, but it will be interesting to hear whether, in face of Professors Sherrington and Grünbaum's findings, further observations or a re-examination of his specimens will cause him to modify his statements.

Another worker whose developmental studies have received attention is Döllken, but he has only made use of the brains of the dog and cat, and his observations, although interesting from the phylogenetic standpoint, do not assist us in solving the question at issue. Similarly, as I mentioned in my last chapter, the more recent work of Hösel has not enlightened us.

Professor and Madame Vogt also are including in their programme a research on the medullated nerve fibres in the developing brain of the human being as well as other animals, and recently have published an atlas giving faithful reproductions of many of their specimens. Unfortunately the letterpress of this work, or rather that pertaining to the sections of the human foetal brain, is not yet completed, and consequently I am unable to refer in detail to a special band of fibres figured in their drawings and evidently standing in close relation with the postcentral gyrus. But this band of fibres is of special interest to me, because it looks as if it might possibly give us a clue to the true distribution of the "cortical lemniscus." In sagittal sections of the foetal brain of a suitable age the fibres to which I refer appear as a rather thin but compact dense band, springing from the centrum ovale and climbing up the Rolandic side of the medullary projection of the postcentral gyrus; and in a conversation which I had recently with Professor and Madame Vogt, I was led to understand that this strange band becomes medullated at a relatively early period, and on that account can be distinguished from the mass of fibres pertaining to the precentral gyrus, with which it runs parallel and in close connection; furthermore, the individual fibres of this tract are of large calibre, and there seems no doubt that their presence explains the large fibres which I have described as

being so abundant in the radiary zone on the Rolandic face of the gyrus in question, in the adult cortex. Apprised of this band of fibres at the time when the postcentral gyrus was being ousted from the motor area, and associating their existence with my knowledge of the peculiar cortical structure of the postcentral gyrus, I was not long in formulating the idea that this gyrus was to be marked as a sensory centre, and I would now say, that if the belief that this tract maturates prior to the motor tract be correct, and if also it can be proved to be the continuation of the "cortical lemniscus," the histological evidence to the effect that the two central gyri subserve different functions will approach completeness. And surely such a separation of function is one which we would look for on *a priori* anatomical grounds, for when we reflect that, at the level of the spinal cord, the cell stations for the respective links in the sensory and motor neuronic chains are separately situated in the posterior root ganglia and anterior cornua, and, that all along the cord, medulla, and pons they pursue distinct paths, and again in the internal capsule occupy different compartments, we naturally hesitate to believe that a similar separate arrangement does not obtain regarding the departure and arrival platform—to quote Mott's apt simile—of these systems of fibres on the surface of the brain.

EXAMINATION OF THE POSTCENTRAL GYRUS IN CERTAIN DISEASED CONDITIONS.

I have now to record some results which I have obtained from the examination of the cortex of the postcentral gyrus in cases in which there has been some antecedent destructive interference with the main system of sensory neurones at a lower level, for early in this research it occurred to me that such material would prove valuable for the determination of postcentral function, and the special cases which I have selected to meet the purposes of my investigation have been ones of Tabes Dorsalis, of amputation of one or other extremity, and of small lesions cutting the sensory path in its course through the internal capsule.

The Postcentral Gyrus in Tabes Dorsalis.

Tabes Dorsalis supplies us with a most exquisite natural destruction, virtually limited in its effects to the main chain of sensory neurones, and I have long been of opinion that no better disease, or purer condition, could be chosen to assist us in the determination of the area in the cerebral cortex which we are to regard as the sensory terminus; because, practically, we can look upon the tabetic process in the spinal cord as a progressive and eventually comprehensive degeneration, following the stream of physiological conduction and complying with all the postulates of the law of Waller; and although, on account of the interposition of a stop in the nuclei of Goll and Burdach, the more obvious histological manifestations of that degeneration cannot be displayed above this level, it is hard to believe that its effects, and especially the complete interruption of physiological impulses which it involves, are not carried over into the succeeding higher neurones, and above all that reactive changes do not occur in the cortical cells cut off from the impact of these stimuli.

To my mind, the several reasons why the changes to which I allude have not been previously discovered, or even investigated, are that we have not had any clear idea of the residence of these cortical terminals; our knowledge of the normal histology of the cortex, as regards the distribution of topographic variations in structure, has been imperfect; our views concerning sensory localisation have been confused by erroneous conceptions regarding the

motor area; and, altogether, the guiding conditions which would enable an observer to light upon the area exhibiting the more or less delicate reactive cortical alterations consequent upon a tabetic degeneration have been so shadowy, that any undertaking in this direction has been shunned as hopeless. However, having acquired more definite information concerning the functions and histology of the cortex of the central convolutions, and especially having found not only that the cortex of the postcentral gyrus is entirely different from that of the precentral, but that it presents certain features which seem to be possessed by sensory realms in common, and also having learned from piecing together the evidence supplied by studies in degeneration and development, that the cortical segment of the sensory tracts probably aims for the postcentral gyrus, it seemed reasonable in searching over the cortex to pay special attention to the condition of the postcentral gyrus, for here if anywhere changes would in all likelihood be found. This I have done, and the data set forth in the following pages, to my mind, carry great weight.

Unfortunately the second and third cases of which I have to give an account are not instances of Tabes in the pure form, but are complicated with General Paralysis of the Insane. However, as a set-off to the disfiguring histological complications of the latter disease, I may say that a prolonged experience of the histology of the general paralytic cortex, and the possession of an abundance of sections of the central convolutions from non-tabetic cases of that affection have been taken advantage of in making comparisons and eliminations, hence, I hope it will be allowed that the value of my observations is increased.

CASE No. 1.

For the hemisphere forming the subject of the following remarks I am indebted to Doctor F. W. Mott, Pathologist to the London County Asylums, and I consider that I have been exceedingly fortunate in obtaining it, as the individual from whom it was taken provided an uncommonly pure case of Tabes and at the same time a severe one. True it is that he was an inmate of Colney Hatch for many years and died therein; but against this it can be shown that the mental aberration from which he suffered was slight in character, in fact, merely sufficient to justify his detention, and certainly not of a kind to occasion disturbances of cell lamination, or other changes, which would impair the value of the brain as a means to the determination of the alterations therein which I believe to stand in direct association with the spinal disease. And the results of the histological examination to be presently described are quite in accord with this surmise.

The clinical history of the case and the account of the examination of the spinal cord, etc. are reported at length in the *Archives of Neurology*, Vol. II, page 123, case 28; it formed one of the series of cases of which Doctor Mott made use in his study of "Tabes in Asylum and Hospital Practice," and the following *résumé* is copied from that work.

"*Case* 28. Tabes of 16 years' duration, commencing with optic atrophy, followed soon after by mania with delusions of persecution; subsidence of acute mental symptoms and gradual development of spinal symptoms, which after 10 years led to helpless ataxy; mental enfeeblement, but no progressive dementia. Death from acute dysentery. Tabic lesion of spinal cord and roots, in cervical and lumbo-sacral region, especially; affection of both exogenous and endogenous posterior spinal systems; marked patchy thickening over prefrontal, frontal and central convolutions; chronic atrophy of superficial layers of fibres and cells of cortex in these regions, without vascular changes. Was this a case of mania and tabes, or tabetic general paralysis with arrest of mental symptoms?"

When the specimen, a left cerebral hemisphere, reached me, it had already been fixed by immersion first in Formalin and then in Müller's fluid. It was in excellent condition for section and on superficial naked eye inspection exhibited no localised atrophy in the Rolandic region, and only a moderate degree of general wasting.

Examination of Nerve Cells.

The examination was conducted on my usual plan, and the field inspected embraced the paracentral lobule and entire "Rolandic area," the whole of the parietal lobe, the precuneus, and the posterior half of the gyrus fornicatus (*vide* Plate IX), and a perfect display of the nerve cells was obtained in spite of the fact that the brain had been treated with a chrome salt.

It will be convenient to begin with a detailed account of the cortical changes which I take to be peculiar to this disease; these were found on the Rolandic wall and edge of the postcentral gyrus, and the following description refers to parts in which the alterations were seen in their most typical form.

Under a low power of the microscope, attention was attracted to the affected field by the following general changes. An extraordinary condensation or huddling together and distorted arrangement of cells, a difficulty in defining the various laminae, and a remarkable deficiency in cells of large size, added to which was a noticeable reduction in cortical depth. (Plates VII and VIII.)

Inspecting the laminae seriatim:—

The plexiform layer perhaps contained an excess of nucleated elements but did not seem to be the seat of special disturbance.

The cells in the second layer were numerous but many of them had lost their pyramidal shape and the main process instead of looking upwards pointed in any direction; also the lamina was unduly beset by small round cells.

It was the same with the medium-sized pyramidal cells. Although elements pertaining to this category were present in abundance, their columnar arrangement was disturbed, and their processes in the majority of instances stunted, and again small round cells were superabundant. When compared with the normal part one further noticed that the matrix intervening between the individual cells was greatly reduced in extent, and this it was that accounted for the huddled-up appearance of cells above-mentioned. Now this alteration, not confined, by the way, to the layer under consideration, is one of great interest and importance, but to what the apparent condensation was due it was not easy to say. It was not altogether the result of disappearance of medullated nerve fibres, because these, as I shall show later, were fairly well represented; but that the absorption and disappearance of dendritic processes, the finer extensions of which are unstainable by the Nissl method, had a lot to do with it, there could be no doubt; for these, as we know, weave their way in and about the matrix and must contribute in no small measure to its general stability. Whether the condensation was associated with neuroglia changes I cannot tell, because I did not stain specially for these bodies; also the influence of possible changes in the substance remaining, when neuroglia, nerve cells and fibres are abstracted, can only be surmised.

Of the large external pyramidal cells, not only were there none in a normal condition, but few of any kind could be identified. The cells which one took to be the remnants of this lamina were deprived of processes, of irregular shape and chiefly composed of a persistent nucleus, which in some instances stained as deeply as the scanty surrounding protoplasm. At this level there was again an excess of small round cells. Taking all in all, the disappearance of these large external pyramidal cells may be regarded as the most important of all the cortical alterations.

The lamina of stellate cells had lost definition, not so much because of a reduction of its normal cell-wealth, but on account of changes in the layers immediately above and below, and especially because the latter layers contained such a number of altered elements of the same size as stellate cells.

The internal layer of large pyramidal cells, like the outer layer, suffered severely, but at the same time normal elements were discoverable in it, albeit at rare intervals.

The layer of fusiform cells appeared to share the general changes.

In regard to the sectional extent of the diseased cortex, it is very important to mention that it was practically confined to the Rolandic wall and edge of the gyrus. It rarely reached quite to the floor of the sulcus; and when the inspection was carried surfacewards on to the crown of the gyrus and to the intermediate postcentral cortex, it was interesting to see how the lamination rapidly assumed a normal character. (Plate IX.)

Distribution of the Changes.

We now come to the general distribution of the affected cortex, and as it is essential that this should be plainly indicated, I give, in Plate IX, a plan of the hemisphere and outlines of a number of the sections, with the exact position of the diseased cortex shown by crosses. From which it will be seen that, on the mesial surface of the hemisphere, the area was confined to the cortex lying immediately behind the tail of the Rolandic fissure. (The Betz cells seen to perfection and in great numbers in the sections of the mesial surface were perfectly healthy.) The diagram further shows how in passing down the lateral surface the affected field was limited to the Rolandic wall and lip of the postcentral gyrus, but I must here mention that the area could not be described as a continuous and uninterrupted strip of diseased cortex. Because more or less healthy patches running through two to three sections were come across here and there, and occasionally, even in an individual section, one saw an isolated healthy spot in the midst of the diseased field; these healthy islets, I take it, corresponded with healthy spinal nerve roots, and seemed to be more numerous in the lower than in the upper extent of the area; but the laborious nature of the task prevented me from working out their position in detail, and although it would have been interesting to have done so it is sufficient in the meantime to have shown that the tabic cortical degeneration is limited to the main field under consideration. In regard to the lower limit of the diseased area, it may be said that the changes ceased at the lower extremity of the fissure of Rolando and that the cortex of the parietal operculum was healthy.

Search throughout the remaining parts indicated in the diagram, namely, the precentral region, the posterior half of the gyrus fornicatus, the precuneus and the whole of the parietal lobe, failed to disclose noteworthy change, not even anything pathognomonic of general paralysis and absolutely no disturbance of cell-lamination on a line with that above-described and which one could attribute to the tabetic process; and in confirmation of this it may be mentioned, that although Doctor Mott, in his examination of portions of the opposite hemisphere (apparently a piece of the Ascending Parietal Gyrus was not examined for cells, although it was for fibres), saw minor alterations in the superficial layers, a photograph of a portion of a section of the ascending frontal convolution which he reproduces shows medium-sized pyramidal cells of good shape, arranged in columns and having long and erect apical processes.

Examination of Nerve Fibres.

Those who have examined the medulla and pons, even in cases of very severe tabes, will know that it is exceedingly difficult, almost impossible, to trace the sclerosis beyond the posterior column nuclei, and bearing this in mind we would not expect to find marked changes in the fibre elements at the cortical terminus. However, alterations do occur, although not nearly on a par with those in the nerve cells, and in this case they were as follows. The radiations of Meynert were of average strength but slightly wavy, and they did not stand so erect as in the normal state. As might have been anticipated, considering the severe destruction of the external layer of large pyramidal cells, the line of Baillarger had lost in distinctness; in fact, this was the most pronounced alteration noticed. The zonal layer and the fine elements in the supra-radiary and interradiary plexus suffered slightly, but the large medullated fibres in the radiary zone, which above all things characterise the postcentral area proper, were present in normal abundance.

In further reference to the nerve fibre changes, I would mention that Doctor Mott in a "preliminary" examination of portions of the first frontal, ascending frontal and ascending parietal convolutions of the right hemisphere, saw "a considerable degree of atrophy of the tangential and supraradial and interradial fibres, quite as marked as in a case of fairly advanced general paralysis," but I imagine that this only applies to the ascending parietal sections, for in the illustration which he gives (Plate II, page 125) that gyrus is shown to suffer out of proportion to the ascending frontal.

I might add that I am acquainted with Jendrassik's observations on the occurrence of changes in the cortical nerve fibres in cases of Tabes Dorsalis, but I venture to say that these were different from the changes I have found, in particular I would emphasise the fact that they were not localised. It is admitted by Jendrassik that they were general alterations, of a similar nature to the familiar changes first described by Tuczek in the cortex in cases of General Paralysis; indeed, it is maintained by some, that Jendrassik's cases were ones of Tabo-Paralysis and therefore his findings cannot be held to influence my case.

CASE No. 2.

Clinical History.

M. A., aged 35. Admitted to Rainhill Asylum, October 25th, 1895, died December 11th, 1897.

The following particulars were supplied by his brother. There was nothing in the family history which had any bearing on this, his first attack of insanity. He entered the Navy at the age of 18, and after serving for a period of eleven years received his discharge as an invalid. At that time—six years before admission to Rainhill—difficulty in walking appeared, and gradually increased. He had frequently complained of attacks of sudden shooting pain in the legs, especially on sitting down. There was no history of injury to account for the disease, but infection with syphilis was admitted by the patient, who also stated that he had lost all sexual power.

State on Admission.

There was definite brachial ataxy, so marked that he was quite unable to touch his nose with his finger tips when the eyes were closed, his gait was also decidedly ataxic and he swayed and was in danger of falling when placed in the erect posture with shut eyes. The knee jerks were entirely abolished, but many of the superficial reflexes could be elicited. The right pupil was larger than the left, each reacted slightly to accommodation, and the light reflex was abolished. The tongue was protruded straight and was free from tremor. Mentally, no obvious delusions or hallucinations were discovered, his answers to questions were coherent and he was quiet and orderly in his behaviour.

Progress.

For two or three months after admission his condition remained more or less stationary. At the end of this period he began to develop signs of general paralysis, and six months later he was described as undoubtedly suffering from that disease, but it is interesting to mention that there was an entire absence of grandiose delusions. It is unnecessary to add more details concerning the case; the physical signs of general paralysis associated with those of Tabes gradually advanced, and he died 8 years after the onset of the first indications of the latter disease and 17 months after the physical and mental signs of general paralysis declared themselves, and throughout there was not the slightest doubt concerning the correctness of the diagnosis.

Examination of the Spinal Cord.

Even to the naked eye the signs of Tabes were evident, the cord was small and flattened from before backwards owing to contraction of the posterior columns, the pia-arachnoid membrane on the dorsal aspect was thickened, opaque, and adherent in places to the dura, and all the posterior roots presented a more or less withered appearance.

A series of microscopic sections made at the level of each spinal segment clearly demonstrated the severity and extensive nature of the posterior root and column affection. Without entering into details, it may be said that in specimens stained by a modification of the method of Weigert-Pal applied to formol hardened tissues, which I formerly adopted, the posterior columns exhibited pronounced sclerosis and shrinkage throughout the whole length of the cord; in the lower cervical and upper dorsal and in the lower lumbar and sacral regions, where the stress of this affection usually falls heaviest, the destruction of posterior root fibres was virtually total and absolute, and even in the remaining upper cervical and upper lumbar regions the affection had not descended lightly. From the negative point of view the only fibres remaining healthy in the posterior columns were a few pertaining to posterior roots in the upper cervical and upper lumbar regions, along with certain small endogenous, descending and internuncial systems which seem to escape even in the most advanced cases of this disease.

In the nuclei of Goll and Burdach there was an obvious thinning of the myelinic plexus; but specimens of the medulla showed no obvious change in the internal arciform fibres and fillet.

Examination of the Cerebral Cortex.

Portions of the 1st, 2nd, and 3rd frontal, the precentral and postcentral, superior temporal, external occipital and mid-limbic convolutions were cut and stained by the fresh method of Bevan Lewis, and corresponding portions were examined by the method of Nissl.

In all these sections abundant evidence of the changes peculiar to general paralysis was found, namely, thickening of the pia-arachnoid membrane, increased density of epicerebral fibrillation, the prevalence of hypertrophied glia cells, particularly in the first layer and along the course of the blood vessels, thickening and over-cellularity of blood vessels together with the presence in their neighbourhood of the cells which we now associate with the name of Marschalko, various forms of nerve cell disintegration and a distortion of their normal columnar arrangement.

All these changes were general, but, with the exception of the ascending parietal gyrus, which I shall describe separately, were more marked in the occipital and anterior frontal regions than elsewhere.

Coming now to the ascending parietal gyrus, of which sections were obtained at three different levels, close to the upper margin of the hemisphere, at the middle, and near the lower extremity, the alterations were of a most profound description and entirely out of proportion to those in other parts. In the fresh

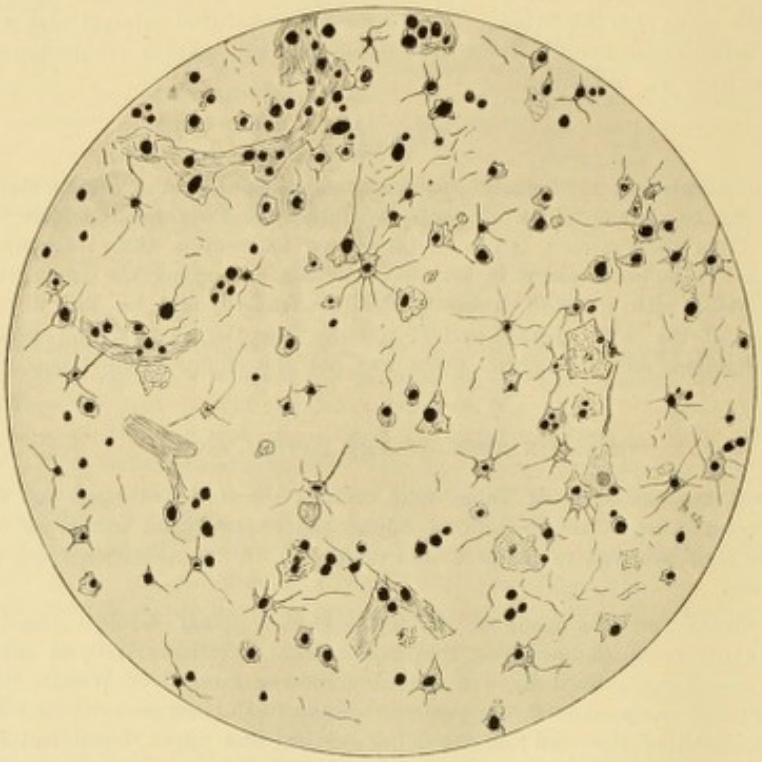

Fig. 8. Tabes Dorsalis, Case II.

From a section of the postcentral gyrus taken from a point midway between the upper margin of the hemisphere and the Sylvian fissure. The drawing has been made from the cortex on the Rolandic side and shows the condition of affairs at the level of the external layer of large pyramidal cells. The disintegrated remains of three or more of these large cells are seen as shapeless masses deprived of nucleus and processes. Only a few nerve cells, of a smaller variety, persist. The neuroglia overgrowth is manifest; and no part could be found in which the blood vessels did not stand out as they do here; one vessel, in particular, may be noted at the top of the field. Cf. fig. 9.

sections stained with aniline blue black great numbers of enormous neuroglia cells with huge vascular processes were seen throughout the cortex, and even in the white substance below, in fact the glial hypertrophy and proliferation was far greater than any I had seen before, even in the most advanced cases of general paralysis. Thickening and over-cellularity of the blood vessels were seen on a similar scale.

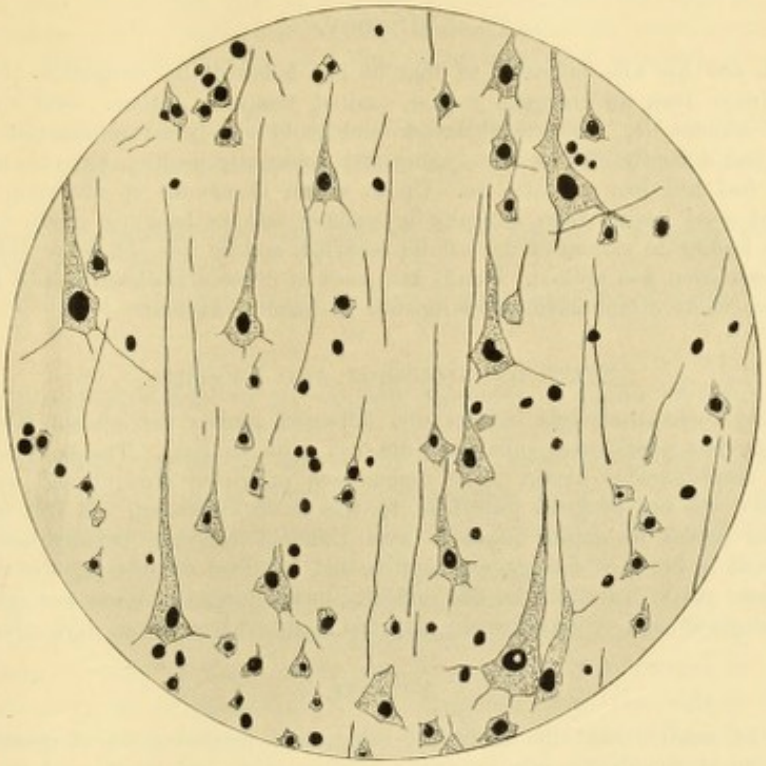

FIG. 9.

A drawing from a corresponding situation in a normal brain, for comparison with figure 8.
Both these sections were stained with aniline blue black (fresh method of Bevan Lewis). Leitz eyepiece drawing apparatus. Zeiss apochromatic lens, 4 mm.

The layer of small pyramidal cells was recognisable and contained some healthy elements.

The layers of medium sized, and large external and internal pyramidal cells had suffered destruction, which was extreme in degree. On the Rolandic side of the sections it was impossible to find a single cell belonging to these laminae which had preserved its normal form, and only a few indefinite pale-stained masses remained to indicate the position of cells in the ultimate stage of disintegration (text figures 8 and 9). On the crown of the convolution, however, a few normal elements appeared, and still more were evident on the posterior side.

The position of the layer of stellate cells could be determined, but the band formation characterising the normal condition was far from distinct.

No normal elements could be seen in the fusiform layer, only sunken, processless elements.

The sections stained by the method of Nissl amply confirmed the foregoing.

CASE No. 3.

J. M., aged 36. Admitted to Rainhill Asylum, March 16th, 1899. Died March 26th, 1899.

History.

He was married, and his wife informed us that he had followed the occupation of a railway porter all his life, and had always been an energetic worker, and of temperate habits. She knew of no illness or injury which could account for the present attack and could supply no information concerning infection with syphilis. She had a family of two, both young and apparently healthy, but one other child had been born dead and she had had four miscarriages. Up to within 14 months of admission she stated that her husband had enjoyed good health, then difficulty in walking and in handling goods, and also an affection of the eye, gradually leading to closure of the left lid occurred, and he was obliged to abandon his occupation. No seizure of any description was noticed. Finally the onset of dulness, restlessness, and other signs of mental disorder compelled her to have him certified for removal to Rainhill Asylum.

State on Admission and Progress.

There was bilateral ophthalmoplegia externa and left-sided ptosis; the left superior oblique muscle was intact on both sides. The pupils were equal but did not react to light. The knee jerks were absent and the gait feeble and unmistakeably ataxic. The tongue was protruded straight and was free from tremor. His general appearance was one of great feebleness, he was much emaciated, and had trophic sores over the sacrum. Mentally his replies to simple questions were coherent but his memory was very defective; he seemed to be indifferent to his surroundings, was restless and exhibited distinct signs of dementia. His speech was thick and suggested palatal paralysis, he had difficulty in swallowing and was wet and dirty in his habits. He showed not the slightest sign of improvement and died from exhaustion ten days after admission.

Autopsy.

It is important to mention that the brain did not exhibit marked signs of general paralysis; true it is that the pia-arachnoid membrane was somewhat opaque, thick and tough, and its removal occasioned some decortication, but wasting had not occurred to any great extent, as evidenced by the fact that the encephalon weighed no less than 1560 grammes. The ventricles also were not dilated and the ependyma only slightly granular. The oculo-motor nerves were attenuated and grey in colour (microscopic examination revealed serious changes in the nuclei of these nerves).

To the naked eye the spinal cord showed sclerosis of the posterior columns and withering of many posterior nerve roots.

The only other point of interest to be mentioned is that a suspicious scar was seen on the penis, and the discovery of arterial changes in the subsequent microscopic examination is almost convincing proof that he must have suffered from syphilis.

Microscopic Examination of the Brain.

The brain was hardened in formol 5 %. Blocks were taken from both central convolutions at intervals of 1 cm. and cut and stained by the method of Nissl for nerve cells and by a special process for nerve fibres, also a number of blocks from other regions were examined for purposes of comparison.

It may be at once stated that the classical signs of general paralysis although present, were not advanced, and that the postcentral gyrus was singled out for specific affection. The changes therein I shall now describe.

In the first layer there was no alteration of special importance, only glial proliferation and some thickening of vessels indicative of general paralysis were noticed.

The small pyramidal cells appeared orderly and well formed, but were not so numerous as they should have been.

The medium sized pyramidal cells had suffered a more manifest reduction in number, and their arrangement was disturbed; furthermore, elements of good shape normally endowed with processes were uncommon.

It was, however, on the layer of large pyramidal cells so prominent in the normal brain that the chief stress of the affection had fallen. A numerical deficiency was most obvious, fully 50 °/₀ of the cells having vanished altogether, and of those that remained only occasionally was one seen which could be described as normal, nearly all were of rounded, oval or irregular shape, and had lost their processes, and although they contained a dislocated nucleus and nucleolus, they appeared pale and homogeneous from loss of their chromophilic particles; furthermore, they lay scattered about with what appeared to be their apical end pointing in any direction.

The layer of stellate cells had also suffered severely, not standing out nearly so plainly as it should.

Not numerous in the normal condition the substellate large pyramidal cells were in this brain practically non-existent.

The normal columns of fusiform cells were also not to be defined, their place having been taken by atrophied and irregularly placed elements.

In the sections stained for nerve fibres I could not make sure of definite alteration[1].

General Remarks on the Cortical Changes in Tabes Dorsalis.

I have now examined the cortex cerebri in three cases of Tabes Dorsalis in somewhat close detail, and in all three I have discovered important changes, almost gross in character. Having hitherto escaped notice at the hands of other observers, these changes, in themselves, constitute an interesting addition to our knowledge of the pathology of this disease, and would prove a fruitful topic for discussion in that light. Here, however, I am only concerned with cerebral localisation, and to this my comments must be restricted. Now, to my mind, the evidence derived from a study of these cases may be confidently advanced as stronger than any which has yet been adduced in favour of the assumption that the cortex of the postcentral gyrus, and it alone, is the primary terminus or arrival platform for nerve fibres conveying impulses having to do with "common sensation"; the data are so clear that they speak for themselves and need little in the way of introduction. For, just as we saw, in the last chapter, that Amyotrophic Lateral Sclerosis, a disease confined exclusively to the muscles and the motor system of neurones, provided a convincing demonstration to the effect that the resulting cortical changes are limited in their distribution to what we may in the future call the "precentral or motor area"; so we see in Tabes Dorsalis, a disease which is essentially a sensory one, and in typical cases exclusively confined to the sensory system of neurones, just as sharp a limitation of the associated cortical changes to the opposite bank of the Rolandic fissure, to what we may now designate the "postcentral or sensory area." And, conscious as I am that the histological findings on which this weighty statement rests will need to be carefully checked and confirmed by others before it can be considered final, I give it in the firm belief that the portrait received from the microscope is a correct one, and that the solution of a vexatious problem, which has baffled the neurologist for a number of years, is at hand.

The limitation of the alteration to the postcentral gyrus is the feature of predominant interest, but there are several points of minor importance which arise for consideration in this discussion. The first is that the alterations are still further limited to a certain part of the

[1] In another case of Tabes Dorsalis which has come to hand more recently and presents a repetition of all the cell changes described, examination by the osmium-bichromate method of Marchi has disclosed many acutely degenerated fibres leading to the altered cortex and running in the subjacent white substance.

postcentral gyrus, to the Rolandic wall and lip, to the field which was mapped out long before this pathological investigation was thought of, by its possession of a very curious and destructive structure, the field which I have sometimes distinguished by the name postcentral area proper. Out of this the question arises, Does this small and narrow strip of cortex represent all the brain surface which has to deal with the reception and final elaboration of common sensory impulses? The reply is in the negative, for, in discussing the various factors which contribute to the perfection of "common sensation," it will be pointed out that these components are divisible into two categories, the first of which we will for convenience call fundamental components, and the second psychic; and reasons will be given for believing that the cortex behind the postcentral area proper—that is, the cortex of the intermediate postcentral area, and possibly of the parietal lobe—bears a psychic function. But this introduces a difficulty, because in Tabes Dorsalis we know that sensation is impaired in all its components, psychic as well as fundamental, and, this being so, why does not the supposed psychic cortex also undergo changes? In endeavouring to explain this apparent anomaly we must turn to other sensory areas and see what takes place in them in cases of peripheral interruption of the conducting path for their stimuli. Take the visual area as an instance: in cases of blindness from any cause, the part on which the cortical change falls with greatest intensity is the calcarine area, the field on which visual impressions are believed to primarily impinge, and which we call visuo-sensory; and it also appears, although it cannot be taken as proved, that the change begins in this area, and that the alterations which affect cells in the investing visuo-psychic cortex follow at a much later date, in addition to being less severe and less readily demonstrated. Now I venture to think that the analogy can be extended to the changes in the postcentral cortex in Tabes Dorsalis. Destruction of terminal and fundamental cells, which the sensory neurones first strike in the postcentral area proper, occasions loss or impairment of all forms of sensation, but the cells subserving a psychic function, placed in areas further back, only having indirect associations with these neurones, are more resistive to decay, also, not being so concentrated in their deposition as the primary sensory elements, their degeneration does not bring in its train such a manifest general disturbance of cell-lamination.

Another question arising from the findings in Tabes Dorsalis is whether common sensations emanating from different parts of the body are delivered at levels in the postcentral gyrus which correspond in position and in sequence with those which are known to dominate movements of given groups of muscles. From clinical experience, and from some evidence which I shall bring forward in describing the cortical changes in cases of amputation, it seems that this is the case, and I have little doubt that tabetic material could be used to advantage in the settlement of the point. Thus it is conceivable that many interesting details would be forthcoming from an examination of the brain in a series of cases exhibiting stress of spinal affection at different levels. For a rougher localisation, cases of transverse myelitis might prove valuable.

Postcentral Gyrus in a Case of Old-standing Capsular Lesion.

In the following case the microscopic examination aimed at the display of the cortical changes arising from interruption of the sensory chain of neurones at the level of the internal capsule, as well as the determination of the distribution of the same on the surface of the brain.

The patient was a female, aged 20, hemiplegic from childhood.

The left arm was absolutely paralysed, shortened by one and a half inches, contractured and held across the chest in the flexed position, and the muscles from the shoulder downwards were all profoundly atrophied. The triceps and wrist jerks could not be elicited. Sensation, save the faint and delayed recognition of pain, on the inner side of the arm only, was abolished.

The left leg was shortened by one inch and the foot fixed in the equino-varus position. Muscle weakness and wasting were pronounced but the paralysis was not complete, and she could walk a short distance without assistance. A knee jerk was obtainable but only just perceptible; there was no ankle clonus nor phenomenon of Babinski. Tactile sensibility and the muscle sense were in abeyance, but sensations of pain and heat were appreciated, though imperfectly localised.

The extremities of the right side were normal in every respect.

At the autopsy a disparity in cerebral weight of 45 grammes, the existence of contra-lateral atrophy of the cerebellum and wasting of the right pyramidal tract and medial lemniscus in the crus, pons, and medulla led one to suspect that the cause of the whole mischief was a central lesion in the right cerebral hemisphere, and on making sections of the brain after fixation in formol this suspicion was found to be correct. The lesion on horizontal section appeared as a slit, about 1½ inches long, between the optic thalamus and claustrum; it was evidently the remains of an old-standing softening due to embolism. (In the heart signs of preexisting mitral endocarditis were seen.)

The parts destroyed included the whole internal capsule, the outer half of the optic thalamus and all three segments of the lenticular nucleus.

Paying further attention to the surface of the brain, after the discovery of this lesion, one noticed a distinct amount of atrophy localised in the Rolandic area, and this was especially noticeable in naked eye transverse sections of the two central gyri.

Microscopic examination of the crus, pons, and medulla showed among other changes complete sclerosis of the right pyramidal tract, and very obvious atrophy without sclerosis of the medial lemniscus.

Microscopic Examination of the Cortex.

Sections of the two central convolutions were made at intervals of 1 cm. and stained by the method of Nissl and Wolters-Kulschitzky. The changes in the precentral gyrus I need not describe at length, they consisted essentially of destruction and disappearance of the cells of Betz throughout their area of allocation and a corresponding diminution in the associated fibre wealth.

In the postcentral gyrus, in which we are particularly interested, important and striking cortical changes were discovered, neatly distributed all along the Rolandic side of the gyrus, not confined to any layer in particular, they consisted for the most part of cell destruction. The general cell lamination was greatly disturbed, and even the position of the stellate lamina was not easy to define, at the same time the cortex altogether was greatly reduced in depth. It seemed that the lower two-thirds of the gyrus had suffered more than the upper third, for in the first position hardly a single cell of normal size and configuration could be made out in any of the laminae, and the elements that remained, numerous though they were, refused to stain deeply, exhibited no internal chromophilic particles, were mostly of rounded or oval form, small in size, and their normal columnar arrangement was entirely lost. In the upper third of the gyrus and on the mesial surface of the hemisphere, behind the fissure of Rolando, the changes in regard to columnar disturbance were similar, but here a considerable number of healthy cells was dotted about.

I wish to emphasize the fact that the affection fell chiefly on the Rolandic side of the gyrus, for as one passed to the crown the cortex began to assume a healthier appearance, and this was maintained on the parietal side.

Changes in the Cortical Nerve Fibres.

One would have expected, with such a complete destruction of the sensory tract in the capsular region, to have found very distinct changes in the cortical fibres. This, however, was not the case; moreover, the

easy detection of the alteration about to be described was negatived because, as far as could be judged, it was limited to the Rolandic wall and lip of the postcentral gyrus, and confined in its general distribution to the postcentral area proper.

Under a low power of the microscope the first points to strike one were the shallowness and pallor of the cortex here and also the pallor of the immediately subjacent white substance, pointing to a loss in fibre wealth; further one noticed especially that the line of Baillarger, usually prominent, lacked distinctness. Under a higher power of the microscope it seemed that the stress of affection had fallen on the line just mentioned and on the radiations of Meynert. The latter bundles were deprived in great measure of their large fibres and presented an attenuated as well as a sinuous appearance, like that seen in the cortex in many other atrophic conditions. The large fibres characterising the interradiary field of the normal postcentral gyrus were also markedly deficient, but the finer plexus of fibres situated here, and the supraradiary plexus were fairly well preserved. As the zonal layer is weakly developed in the healthy condition any changes which might have been present in it did not attract attention.

There was some difficulty in deciding whether all these changes were more pronounced in one situation than in another, and it was only after examining many sections that I decided on making a statement to the effect that the lower half of the field had suffered more than the upper.

The interest in this case lies chiefly in the evidence it provides that interruption of the sensory tract at the level of the internal capsule is attended by changes in the cortex of the postcentral gyrus similar in nature and distribution to those found in Tabes Dorsalis, and I record it because I think it increases the importance of the latter as an argumentative basis in the question of sensory localisation.

The fact that the sensory disturbance was incomplete in the leg, and that the upper part of the precentral area suffered less in comparison with the lower is significant.

The Postcentral Gyrus in Cases of Amputation.

In making the observations which are now to be recorded some of those brains used for the determination of points in the differential localisation of the motor area were again employed. But, whereas in the case of the motor area one was guided by the occurrence of a positive alteration ("réaction à distance") in cells still in existence, the conditions in the case of the postcentral gyrus were negative. In discussing the reactive changes occurring in the dominant cells of the motor neurones subsequent to section of the peripheral nerve, it was pointed out that those alterations were slow in supervention, and that the delay was probably due to the fact that the degenerating influence had to stem the stream of physiological conduction. But in the case of the cortical sensory termini the conditions are reversed, and *à priori* we would expect—in spite of the interposition of stops in the sensory neuronic chain to be mentioned hereafter—that in them degenerative changes would manifest themselves more rapidly and the resulting disintegrative process soon be accomplished. Hence, in an old-standing case of amputation with signs of "réaction à distance" still persisting in the giant cells of the motor area, we should find in the cortical platform pertaining to the severed sensory nerve, not active change, but evidence of previous affection, betrayed by a disappearance of a certain number of cell elements. This I firmly believe to be the case. But at the risk of weakening the force of my argument I must now point out that, while a statement may appear readily credible that a numerical deficiency in cells exists in a given part, it is not so easy to supply direct proof of the correctness of such a statement, especially when the enumeration concerns relatively small and closely-packed cells, like those in the postcentral gyrus; nor is

the conclusion to be arrived at until a laborious examination and comparison of the sound and diseased hemispheres have been made. Now the cases which I have subjected to examination are two in number, one of amputation of the leg, and one of amputation of the hand (Cases 1 and 3 *a*, Precentral Area), and the method followed was this. Corresponding portions of the postcentral gyrus were taken from the right and left hemispheres, and serial sections of a thickness of 20 μ cut on a freezing microtome and stained for nerve cells. In successive series of not less than 10 sections, fields measuring 1 mm. in the horizontal direction were taken and the contained large pyramidal cells counted, the enumeration was extended to both layers of large pyramidal elements, and those cells only which showed a clear nucleus and nucleolus were included. Counts were made in this way from three parts of the section, the Rolandic wall, the free surface, and the posterior wall.

In both these cases the enumeration revealed a deficiency in one sectional situation only, viz., on the wall of the Rolandic fissure—of course in the hemisphere opposite to the amputation—the reduction in number affected both layers of large pyramidal cells, and the loss varied between 30 and 45 per cent.

Concerning the distribution of this change it was interesting to find that it lay approximately on the same horizontal level as the part in which the giant cells of the cortex exhibited "réaction à distance." That is to say, in the case of amputation of the leg at the knee joint the affected field embraced the hinder part of the paracentral lobule and about the upper sixth of the postcentral gyrus, while in the case of amputation of the hand it involved, roughly speaking, the lower third of the same gyrus.

I should be going too far if I founded conclusions on these two cases alone, but in combination with other evidence, and especially with the disclosures in cases of Tabes, they must be considered worthy of record and favourable to my general thesis. In particular they strengthen my statement that the cortical sensory areas for different parts of the body lie on a level with the motor fields controlling muscles in corresponding parts.

A DISCUSSION OF THE CLINICAL AND EXPERIMENTAL FINDINGS BEARING ON THE FUNCTIONS OF THE POSTCENTRAL GYRUS.

The extended reign of the doctrine of former experimenters to the effect that the two central gyri share the same office has resulted in such an entanglement of the evidence available for the purpose of explaining the functions of one or the other of these gyri individually, that it is quite impossible to unravel it and consider that pertaining to either separately and on its own platform.

Having already mentioned that numerous speculations have been made and advocated on the question of the cortical localisation of sensation, I can now add that, roughly speaking, present-day opinions are divided between two schools of observers; the first of these, led by Munk, Luciani and Seppilli, Bechterew, Dejerine, Long, and Mott, maintain that the zone which responds to electrical excitation is at the same time the seat of sensory functions, in other words, that the two functions are commingled in the one area; the second school, headed by von Monakow, Mills, Redlich, Charcot, and Pitres, and including Ferrier, Horsley, and Schäfer, argue that motion and sensation have distinct and separate representation.

From the evidence brought forward in the preceding section, and the general tenor of my incidental comments thereon, it is patent that I am no believer in the view that the central convolutions have a mixed function, and although in rejecting that belief I feel that I am running the risk of being accused by the physiologist and the clinician of reasoning beyond my facts, I hope that my stand will receive the support of the anatomist.

Discussing the evidence which has been advanced in favour of the view that the sensory and motor functions are coincident, notice must first be taken of the arguments of those who have relied upon facts supplied by the study of diseased conditions in the central gyri in the human being, because, for reasons which are apparent, it is to observations on the human subject that we must look for final and conclusive information on this question. Now, although numbers of cases have been recorded in the literature—I do not pretend to have read more than a fraction of them—of lesions in the Rolandic zone in which the resulting motor paralysis has been definitely associated with sensory disorder in some of its forms, it cannot be denied that recent researches render a very large proportion of these cases useless as evidence either for or against the point under discussion. I refer, of course, to Professors Sherrington and Grünbaum's discovery that the whole of the "so-called" Rolandic zone is not to be included in the motor area, and naturally maintain that before the information obtainable from a study of the results of pathological conditions in the human brain can be regarded as trustworthy, the findings in all previously published cases will have to be thoroughly and carefully revised; not only so, cases of lesions absolutely confined to one or other of the central gyri and their effects will have to be studied anew and with infinite exactitude; and as an insufficient period of time has elapsed to allow of a wide propagation of the results of the discovery just referred to, and also to admit of the revision and confirmation necessary to meet it, all our clinico-pathological evidence bearing on the question must for the time being stand in abeyance. Here also I would repeat my caution to the clinico-pathologists, as to the extreme care which must be exercised in the future in selecting cases which are to be utilised for the purpose of throwing light on this subject; and for reasons detailed in the chapter on the motor area I would urge them to carry out a painstaking examination of the lesion in the Rolandic area which they believe to have been the source of the previously-observed clinical manifestations; for clearly it is essential that, if it is to be proved that the anterior central gyrus possesses sensory as well as motor functions, only the effects of lesions strictly confined to that gyrus, and preferably to the cortex alone, can be taken into account; and if, on the other hand, it is to be proved that the posterior central gyrus has to do with sensation only, the lesion must be similarly confined to this gyrus.

It would be presumption on my part also to warn clinical observers against arriving at hasty conclusions concerning the sensory effects of such lesions, if there be any, but I take the liberty of quoting on the subject from von Monakow's personal experiences. This accomplished clinician writes, "that in testing sensation it is essential to carry out not only prolonged, but repeated observations by the most delicate methods, because frequently the sensory changes resulting from a cortical lesion undergo pronounced variations, and in course of time clear up to a remarkable degree."

Just as it is with the clinical evidence, so also in the case of experimental observations on lower animals, the results which have been set on record in support of the "sensori-motor" hypothesis prove nothing one way or the other; for obviously the wholesale ablations of both central gyri which have been practised must of necessity have occasioned mixed motor

and sensory troubles, while the reports of the results of limited lesions are not free from the objection that the microscope might have revealed injury to the fibres pertaining to both gyri, and this all apart from the acknowledged difficulties besetting the experimenter in detecting and forming accurate judgments upon delicate sensory disturbances in dumb creatures.

Among histologists, Flechsig makes a bolder stand than any in favour of the double function of the central gyri, but at the present time his statement that the fibres of his sensory system marked No. 1, and these are the first to develop, are chiefly distributed in the cortex of the posterior central gyrus might be taken up by his opponents as one of the strongest arguments against that view; however, as I have said before, we await further details concerning the course of the developing "cortical lemniscus" from Professor and Madame Vogt, and it will be wiser not to lay stress on Flechsig's finding until these are forthcoming.

Turning next to a consideration of the arguments which have been used in support of the contrary view that the motor and sensory areas are not coincident, we find that this cause is espoused in no hesitating manner by von Monakow. This writer maintains that to produce hemianaesthesia, and likewise degeneration of the lemniscus, an extension of the lesion from the "motor zone" into the parietal lobe is a *sine quâ non*, and this view, originally developed from experimental studies, he believes to be confirmed by observations on the human subject. When von Monakow wrote it was taken for granted that the postcentral gyrus was motor, and I am curious to know whether he has now modified his views. To me it seems that the conclusions he has drawn are on the whole sounder and more approximately correct than any which have hitherto been offered, but I prefer to reason that the crossed anaesthesia, in the condition referred to, is purely attributable to the destruction of the postcentral gyrus, although I look upon his statement emphasising the necessity of an extension of the lesion into the parietal lobe as one full of significance. And, concerning his inference that a specific sensory centre exists in the parietal lobe proper, my histological researches, as I shall show in the next chapter, lend no colour to such an assumption; I would also say that if sensory disturbances should be noted in consequence of a lesion in this situation, it would be very necessary, in weighing up the case, to eliminate a probable complicating contingency in the shape of an interruption of the sensory fibres which I believe make for the postcentral gyrus. But this is one of the many problems connected with sensory localisation which must be set aside for future solution.

Of others who argue that sensation has a separate representation in the cortex, Durante, Walton, and Paul look favourably upon the parietal lobe as its residence; but, as these observers also have not been given the opportunity of adjusting their views in accordance with our present knowledge, nothing is to be gained by discussing what they have written.

It would likewise be purposeless for me to advance the array of cases published to support the view that the postcentral gyrus is a sensory centre of prime importance, for the objection concerning reconsideration and reexamination lodged against cases advanced for the contrary is equally in force.

It may be indicated that the observers just quoted, while maintaining that the so-called Rolandic zone has not a mixed sensori-motor function, still argue that the paths for the transmission of sensory impulses impinge on the parietal cortex in close proximity to that zone.

I have next to mention that there are other eminent neurologists who hold not only that the Rolandic zone has no connection with sensation at all, but that the sensory centre

occupies a more or less remote and isolated area: foremost among these we find Ferrier, and Schäfer and Horsley.

In reference to Ferrier's work, many years ago he ventured on the statement that because experimentally-produced destruction of the gyrus hippocampi occasioned impairment or abolition of tactile and general sensibility, together with a condition of the limbs which indicated loss of the sense of movement without motor paralysis, therefore that part was to be regarded as serving a sensory function. Finding, however, that the effects on sensation following the hippocampal lesion were not lasting, he took one of the animals previously operated upon and excised the gyrus fornicatus in the whole of its course round the corpus callosum, and so succeeded in producing "temporary total contralateral analgesia and lasting insensibility to all milder forms of tactile stimulation." As a result of this operation, he stated that "in addition to the hippocampal region proper, we must include the callosal gyrus as forming part of the common sensory centre"; this statement he still adheres to, and from further work done in collaboration with Turner he believes that his results are in harmony with those published by Horsley and Schäfer.

Horsley and Schäfer, like Ferrier, experimented upon lower members of the ape family, and found that any extensive lesion of the gyrus fornicatus was followed by more or less marked hemianaesthesia, but in no case could they produce permanent loss of all forms of sensibility, nor were they able to establish a relationship between special parts of the gyrus and special regions of the body.

Coming from writers whose eminence entitles them to great respect, the statement that the gyrus fornicatus is endowed with high functional importance is unpleasant to combat, especially by those who, like myself, are unpractised in experimental work, and whose only weapons are the results of clinico-pathological and histological research; still, as I shall now indicate, there are several important facts in the hands of investigators in the latter domain which can be advanced in opposition to the statement. The first, and I think I may say the most important, of these pertains to the structural composition of the limbic cortex. Now it is a point which I shall emphasise strongly, when considering the structure of known sensory cortical realms—those for the reception of impressions of sight, hearing, and smell—that they are one and all characterised by the possession of elements of an outstanding nature, differing in some striking manner from those found in what one may call the general or common type of cortex; thus, some of the nerve fibres which they harbour strike the eye on account of their great size and unusual arrangement, while the nerve cells to which we suppose these fibres proceed are curious either on account of their great size, their reaction to various stains, or their conformation. A like remark applies to the histological appearances presented by the various known centres (posterior root ganglia, posterior column nuclei, ventro-lateral thalamic nuclei) in the chain of neurones laid down for the conveyance of common sensory impressions from the limbs and other peripheral parts. But the same can certainly not be said of the cortex of the gyrus fornicatus, at any rate, the cortex of that part lying above the corpus callosum; for when I describe the post-limbic and mid-limbic cortex I will point out that it does not contain a single fibre of large size, nor indeed one of a kind not to be found in any other part of the whole cortex, also that the largest of its nerve cells are, comparatively speaking, small and not marked by any peculiarity in form, arrangement or staining reaction, which suggests special physiological function. For these reasons it is hard for the histologist to entertain the suggestion that the cortex of these parts is endowed with such an important

attribute as a capacity for the primary reception, elaboration and interpretation of sensory stimuli streaming in from all parts of the body.

Then, in regard to the opinion expressed by Ferrier, that the true sensory path lies in system No. 2 of Flechsig's corticipetal fibres, it may be pointed out that, although some of these fibres may proceed to the falciform lobe, many form elaborate connections with other parts of the brain, parts which there is not the slightest reason for supposing subserve a sensory function, excepting in a most indirect and subsidiary manner; further, in discussing the development of the sensory system of fibres I have already mentioned that, although the time is not ripe for drawing definite conclusions from published researches on this subject, there are yet significant reasons for believing that Flechsig's system No. 1, which develops first, is of more importance than system No. 2, and that it probably represents the continuation of the main chain of sensory neurones, that is to say, the so-called "cortical lemniscus" of von Monakow. Now it appears to me that Ferrier and Horsley and Schäfer take insufficient notice of this tract, and if the present view concerning its course be correct, namely, that it ascends directly from the thalamic region to the postcentral gyrus, it obviously does not lie far removed from the point of junction between the posterior and middle divisions of the limbic gyrus—a part, by the way, which these observers admit to be especially vulnerable—and it is quite inconceivable how it can escape injury in such a radical procedure as removal of that gyrus, and I think others will support my belief that the sensory disorders attending such an operation are attributable to this complication rather than to any special virtue possessed by the gyrus fornicatus. Clearly the foregoing objections also apply to certain cases of tumour and haemorrhage involving either the anterior portion of the precuneus, the hinder division of the paracentral lobule, or the subjacent and contiguous gyrus fornicatus, which have been pointed to as favouring the view we combat.

In his attempt to prove that sensation is centred in the limbic lobe to the exclusion of the Rolandic zone, Ferrier brings forward an analysis of a series of 284 cases of lesion in the latter region which he has collected from various sources, but the conclusion deduced from these cases is criticised by von Monakow as follows: "since the majority of the observations were made many years ago, and an exact description of the extent of the lesion is not forthcoming, and since the methods by which the sensibility was tested leave something to be desired, these statistics are to be received with caution"; and it may be gathered from remarks made elsewhere that I consider von Monakow's criticism justified.

But, although I disagree with those observers who maintain that the centre for "common sensation" is far removed from the central region, there is no getting away from the fact that cases of superficial lesions in the central convolutions have been recorded and apparently carefully tested, and yet no direct evidence of persistent sensory disability has been elicited, and hence it is not surprising that Charcot and Pitres regarded the sensory changes which occur in cases of lesion of the central convolutions as accidental and unessential phenomena, and that Ferrier, Nothnagel, and others should be of the same opinion. At the same time we cannot consider this question closed until we are provided with confirmatory results from an analysis of a fresh series of cases; for, as von Monakow has pointed out, and as even Ferrier's words[1] support, a lesion in the Rolandic area will be more likely to bring about impairment of

[1] Of the 284 cases of lesion of the Rolandic zone collected by Ferrier, the state of the sensibility was not mentioned in 100, in 121 it was said to be intact, and in 63 there was some impairment; "in 28 of these, however, the lesion was not strictly confined to the Rolandic area, but implicated the adjacent lobes, especially the parietal."

sensibility if it involves the parietal side of that area, and for this reason it is permissible to assume that the so-called "accidental" sensory phenomena have not been the product of chance, but due to implication of the postcentral gyrus and its connected system of fibres[1].

Setting aside this question, it has been thoroughly proved, not only that the cortical localisation of sensation is attended with extreme difficulty, but that the detection of an impairment of sensibility in consequence of a cortical lesion is no easy matter. To explain the relatively slight sensory disorder in comparison with the severe motor paralysis which follows lesions of the central gyri, the unlikely hypothesis has been set up that the sensory zone must be more widely distributed than the motor, but to those who support this view the condition of affairs attending spinal lesions might be pointed out. A minute focus of inflammation situated in the anterior cornu of a portion of one spinal segment will suffice to produce an amount of muscular atrophy which is unfortunately too plainly visible and permanent; destroy, on the other hand, one posterior root ganglion, and there will be no complete anaesthesia and only a temporary and trifling diminution of sensation, so little that it will take all the skill of a practised observer to detect it. In these two instances, instead of the cause and effect being unequal, it is far likelier that the effect is more readily discerned in the one case than the other; so it may be also in the case of the central gyri; a lesion sufficient in extent to produce paralysis of a group of muscles may not be adequate to the production of a discernible equivalent in the shape of sensory disorder. Apart from this, we have to take into consideration a difference in the arrangement of components of the respective neuronic systems; the motor chain is composed of two links with but one interruption, whereas the sensory system is interrupted at no less than three points, and the influence of this factor may not be inconsiderable.

The interrupted anatomical arrangement just alluded to may also have some bearing on confusing results regarding restitution of function, for, whereas in the case of the anthropoid ape and other animals—evidently more so than in the human subject—recovery of power after lesions of the motor area occurs to a remarkable extent, the recovery from an experimentally-produced disorder of sensation is even more rapid and complete. Of the many neurological problems awaiting solution this question of the restitution of function is one of the most interesting and, in spite of the various hypotheses which have been advanced to meet it, most unintelligible.

REMARKS ON THE VARIETIES OF COMMON SENSATION[2].

Up to the present I have referred to the postcentral area, either as a terminus for the main tract of common sensory fibres, as a centre for common sensation or as the part of the brain surface on which common sensory impressions impinge, and I have purposely employed these loose and general terms to avoid complications and to keep within the bounds of histological license. Now, however, I must directly trespass for a short time on clinical and physiological

[1] It is weak to contend that the occasional occurrence of hemiopia, loss of hearing, taste, or smell, in combination with hemianaesthesia, is important, because it can be proved that in all the cases so complicated the lesion has been either very extensive or deep-seated, and, to my mind, these are true instances of dynamic influence and of the very class of case which we have to guard against and eliminate in forming judgment on points in localisation.

[2] I may be taken to task for including the tactile sense in "common sensation," but I understand that "common sensation," although a loose term, is the equivalent of the German "Körpersensibilität," that it denotes the several cutaneous and other sensory impulses conveyed by the common nerves of the body as distinguished from those passing along special nerves, or parts thereof, and that it has a narrower signification than "general sensibility," the faculty by which we are informed in a general way of corporeal changes in condition and circumstance.

ground and offer some remarks on the varieties of common sensation believed to exist and to contribute, either alone or in combination, to the registration of a conscious sensory perception. I must also point out the parts of the cortex which are supposed to be concerned in the elaboration and interpretation of these several kinds of sensations.

The Tactile Sense[1].

It would appear at first sight that, since impairment of the primary component in the mechanism of the tactile sense, the power of recognising cutaneous pressure, is such a simple clinical phenomenon that the cortical area acting as a register for this particular sense would be readily discovered. But how far this is from the truth is proved by the reality that we are no nearer our goal to-day than we were twenty years ago, and that the question is becoming more and more beset by bewildering theories.

Avoiding as far as possible a discussion of different doctrines, we will enquire how far the findings set forth in this research assist us in the localisation of this sense. Now, if the data concerning the pathway for sensory impulses already detailed be correct, it necessarily follows that the first part of the cerebral cortex to be influenced by a tactile impression must be that of the postcentral gyrus, and particularly that on the Rolandic side, and in accordance with our knowledge of other sensory areas we should expect that destruction of this part would at least give rise to abolition of the power of recognising touch[2]. For proof on this point, however, we are compelled to turn to the clinical observer; but, as I have already stated, the evidence derived from observations on the human subject is, as it now stands, weak. For, although clinicians have provided us with a lengthy array of cases in which unequivocal sensory disorder of some kind has been found in association with lesions of the Rolandic or "centro-parietal" (von Monakow) cortex, the information bearing on the sense which specially forms the subject of the present discussion is admittedly insufficient. Looking around for an explanation of this apparent breakdown in the clinical evidence, several suggestive circumstances come to mind: above all things we have to reflect on the *rôle*, in regard to registration, played by the subordinate centres which the sensory impulse has to traverse in its upward course, and in so doing take cognisance of the explanatory consideration exploited by Hitzig that the tactile impression may be registered in subcortical centres before being passed on to the brain surface for complete interpretation: or, modifying Hitzig's view, we have to consider whether these intermediate stations do not exert some influence in dulling the intensity of the stimulus, and so increasing the difficulty of the clinician in providing a positive demonstration of tactile sensory disability from cortical lesion. Concerning this difficulty of recognition, clinical observers seem unanimous in stating that extreme care must be exercised in the examination of individuals for disorder of the tactile sense, and they also tell us that on account of the fugacity or variant nature of the disability these examinations must be frequently and patiently repeated.

[1] The tactile sense is made up of three components, the recognition of cutaneous pressure, the orientation of the same, and the power of discriminating points in contact. Of these the first is undoubtedly the simplest, and the second, because it involves a more complex psychic process, is higher than the third.

[2] After removal of the sensory centre of a dumb animal it is difficult to tell whether it feels or not and impossible to say in what manner it feels, because our chief criterion of its power of tactile recognition is the responsive muscle movement, and as Munk long ago indicated there is no knowing whether this is not of reflex nature. Experiment, therefore, cannot assist us much in the elucidation of this problem.

Having offered these explanatory remarks, we can now enquire what evidence on tactile localisation clinical observation has supplied. Now, for reasons previously mentioned, it would be profitless to select for analysis those cases of lesions in the Rolandic zone which, according to records, are believed to have been limited to the postcentral gyrus; but I must say that in a comprehensive survey of a number of instances finding a place in the literature, I have been struck by reading that when a lesion causing motor palsy has been so situated as to attack the motor (precentral) area from the frontal side there has been an entire absence of sensory change; when, again, the lesion has been placed in the parietal lobe away from the postcentral area the simple recognition of touch has been uninfluenced (the same does not apply to the localisation of the same); but when, on the other hand, the lesion has directly involved the postcentral gyrus, the sensory defect has been plainly in evidence.

And, while the question is far from closed, and I shall be much interested to hear the result of more thorough investigation on this point, it cannot be denied that this evidence, along with the histological data already set forth, favour the assumption that the arrival platform for the tactile impression is the postcentral gyrus, and, introducing an analogy, I would compare the tactile with the visual centre, and as this centre is divided into a primary sensory, and psychic part, so also I would divide that; and I would regard the cortex covering the wall and lip of the Rolandic fissure as a primary field for the reception, and the reception only, of crude sensory impulses (modified, perhaps, by passage through subordinate nuclei, just as visual impressions may be modified by passage through the internal geniculate bodies); then the further elaboration of the crude tactile stimulus, that is, the psychic process involved in its localisation and the formation of a judgment as to its nature, and of other more involved senses (stereognosis and the muscle sense), in which the tactile sense forms part of a combination, I would delegate to the investing intermediate postcentral cortex and parietal lobe. In accordance with this view, it would follow as a matter of necessity that destruction of the primary centre (the postcentral area proper in my scheme) would bring in its train impairment, not only of the tactile sense, but also of the other senses which it assists to perfect, and, on the other hand, a lesion outside the postcentral area proper would evoke disturbances of the psychic component in the various senses without interfering with the simple component in tactile sense. While some few clinical cases may be found to contradict this hypothesis, I think it harmonises with the generality of observations. It also seems to be in agreement with my cortical findings in Tabes Dorsalis, because, although in this disease there is no variety of common sensibility which does not suffer impairment as the condition advances, anaesthesia to tactile impressions is the opening phenomenon in the train of sensory changes[1], and, as I have already described, the cortical changes are concentrated in the cortex of the postcentral area proper.

The Muscular Sense[2].

This sense, so necessary to the coordination of voluntary movement, because it is the sense by which we appreciate the position and condition of our muscles, is of special interest to the student of localisation, because its disturbance causes a readily recognised disability, and its impairment has been noted over and over again in cases of surface lesion. Now

[1] According to Mott "trunk anaesthesia to light tactile impressions is the earliest and most constant sensory disturbance," and fails in the preataxic stage only.

In not one of the 49 cases examined by Förster and Fränkel was skin sensibility normal.

[2] The muscle sense must be a combination of the sensations proceeding from skin, muscles, tendons, and joints.

although much attention has been paid to these disturbances, clinicians are still in doubt as to the exact portion of the brain on the integrity of which the muscle sense depends for its normal interpretation; indeed it has been localised variously, some maintaining that it is represented along with motion in the central convolutions, others that it finds a place in the parietal lobe, and others that it is situated in more distant regions. It will be interesting to analyse the grounds on which these different views have been built up, and to ascertain which of them fits in most with histological findings and the foregoing remarks.

Out of the enticing suggestion that the cells for the reception of sensations originating in muscle must lie in close association with the cells designed for the excitation of movements of the same, the idea has arisen that the muscle sense must be represented in the centres directly governing motion (Bastian, Munk, Mott, etc.). And this view has gained in favour from the remarkable frequency with which an ataxic condition of the muscles, an inability to indicate the position passively communicated to an affected limb, and other signs pointing to loss of this sense, have been found to accompany a motor paralysis. In case after case such associations have been noticed and described; indeed von Monakow, writing only a few years ago, states that but three instances of loss of the muscular sense stand recorded in the literature, in which the central convolutions were found intact. But the validity of this argument entirely depends on whether it can be proved that a lesion limited to the precentral division of the Rolandic area, that is, the part which we now believe truly to govern the motor function, is alone adequate to the production of paralysis of the muscle sense, and this I believe is beyond the power of the upholders of the view. Another impediment prohibiting the acceptance of this thesis is that we are not aware of any pathway by which impressions of muscle sense can be conveyed to the cortex excepting the so-called "cortical lemniscus," and I have already explained that we have strong reasons on the one hand for believing that this tract proceeds to the postcentral cortex, and no evidence on the other side to show that it makes for the precentral or motor area[1].

While abolition or dulling of the muscle sense is usually associated with or complicated by motor paralysis, the combination is not an invariable one, for cases of destructive cortical lesion have been recorded in which loss of the "muscle sense" has been the sole disability; and as in all these cases the lesion has been situated in some part of the parietal lobe, they have been fully exploited by those who give their adherence to the belief that the apparatus for the reception and interpretation of the muscle sense is resident in this part (Nothnagel, Redlich, von Monakow, Durante, etc.). The upholders of this view also emphasize the point that in cases of lesion in the parietal lobe the interference with the muscle sense is much more complete than it is in the majority of cases of lesion involving the central convolutions; further, they bring proof to show that in the latter cases, when the destruction spreads in the parietal direction, the sensory disability is increased.

[1] By those who would still uphold the duality of function of the motor area as now defined, it might be argued with some effect that abolition of the muscle sense in a case of lesion in the postcentral division of the Rolandic zone is due to severance of association fibres connecting the central gyri. But the speculation favoured in certain quarters, that in the motor cortex the laminae of cells are so divided functionally that some are designed for the origin of motor stimuli and others for the reception of sensory impressions, rests on such a frail base that it cannot be countenanced.

The evidence brought forward in support of the localisation of the muscle sense in parts adjoining the postcentral gyrus has a most important and direct bearing on the thesis I have submitted that the latter gyrus is a centre for "common sensation," and to my mind strengthens that thesis; for I can only think that the incongruity concerning the loss of muscle sense, both after a lesion in the Rolandic area and after one in the parietal region, is to be explained by an involvement of my postcentral area, an area which has been neglected previously on account of its supposed motor function, an area, the curious cortical structure of which has not received due notice, and an area which, in spite of what von Monakow says to the contrary, has the closest connections with the "cortical lemniscus." Moreover, the general agreement that a lesion situated primarily in the central gyri, but extending backwards into the parietal lobe, is most favourable for the production of this disability seems very suggestive. As to those cases of pure loss of the muscle sense in consequence of lesions confined to parts of the parietal lobe (superior parietal and supramarginal gyri), after considering them very carefully, I have come to the conclusion that they do not invalidate my thesis, and for the following reasons; first, it is difficult to conceive how a deep-seated lesion in the superior parietal or supramarginal gyrus can avoid implicating the tracts of fibres making for the postcentral gyrus, and especially those which are destined for the posterior side of that gyrus; secondly, the area, which I have defined as having histological characters intermediate between those of the postcentral area proper and the parietal area, extends in some cases for an appreciable distance on to the gyri in question, and probably to its obliteration the impairment of the muscle sense in these cases is to be attributed.

Of those who oppose the localisation of the muscle sense, either in the Rolandic zone or in the parietal region, Ferrier may be taken as the leader, and he maintains that the affection of that sense in cases of lesion in these situations is the outcome of coincident disturbance of the functions of sensory tracts and centres situated elsewhere than in the parts actually diseased. But his doctrine of sensory localisation has been already discussed and the criticism need not be repeated.

Stereognostic Sense.

The loss of the faculty of distinguishing the form, consistence, etc., of objects is one of those phenomena which certain observers formerly regarded in the light of an accidental accompaniment of a lesion in the Rolandic zone, but as our knowledge of sensation in general and of this sense in particular has advanced, the disability has been placed on a firmer footing and is now recognised as one of common occurrence. As Walton and Paul affirm, the stereognostic faculty must depend upon the integrity of a high combination of senses (the muscle and pressure senses, the power of discriminating points in contact, etc.), and to explain why an individual capable of appreciating the slightest touch may at the same time be unable to distinguish the form and consistence of an article (for instance, a coin, which is the commonest test object) placed in his hand, we can only suppose that an interruption of psychic and associative processes is an essential superadded condition. Being such a complex sense it is readily understood that its localisation is hard to determine; it has of course only been studied in the human subject, and has been placed by most writers in the Rolandic zone, by others in the parietal lobe, while, in accordance with my view, a destructive lesion in either of these situations would be adequate to its production.

Senses of Pain and Temperature.

We have now discussed the senses which are most commonly the subject of affection, which are frequently involved in association with one another, and which may in certain instances be totally in abeyance. The two remaining senses, those for the recognition of impressions of pain, and of heat and cold, differ from the foregoing in being never completely lost—although liable to impairment—in cases of cortical lesion.

In reference to the sense of pain, Goltz demonstrated, many years ago, that even in a decerebrate condition an animal reacted with livelier movements than before to stimuli normally provocative of pain, and he formulated untenable views which need not be entered into here. Munk, pursuing the subject further, found that after removal of the regio sigmoidea in the dog and the production of loss of general sensibility, the animal still appreciated painful stimuli; he so confirmed Goltz's observation; but in explaining his finding he maintained that although the dog felt pain it was unable to locate the irritant or tell its nature, in other words, the disability affected conscious perception and not common sensibility. It appears that the same holds good in the human being, for it is a well-recognised truth that hemianaesthetic individuals in whom the sense of touch is almost abolished are still susceptible to pain, but do not orientate it correctly.

The part of the brain surface serving for the direct reception of sensations of pain and temperature is no more definitely known than that standing in relation with the other senses, but as they, like the first component in the tactile sense, are simple in character, it is probable that they are primarily represented in the postcentral area proper; it is also likely that they undergo modification in the intermediate stations of the sensory chain of neurones.

Summary.

The line of argument throughout this chapter is directed towards proving that the postcentral gyrus constitutes the terminus where the main system of fibres for the conveyance of impressions pertaining to tactile and allied forms of sensation primarily impinges.

Structurally it differs entirely from the precentral gyrus, and from the superior parietal and supramarginal convolutions; and its definition as a distinctive area is accomplished without the slightest difficulty. Concerning its supply of nerve fibres, it is not nearly so richly endowed as is the precentral gyrus, and a most important distinguishing feature is the presence in the interradiary plexus of fibres of even larger calibre than those seen in the precentral convolution, fibres which are curious inasmuch as they run obliquely or at right angles to the radiating fasciculi.

Such fibres recall some met with in known sensory regions, for instance, the visual, auditory, and olfactory centres. They are not seen in either the precentral convolution or the parietal lobe proper, they seem to concentrate themselves on the Rolandic side of the gyrus, and their curious oblique course gives rise to the assumption that they are centripetal fibres making for cells resident in this situation.

In reference to nerve cells the lamination differs from that of the precentral gyrus, first, in showing no true cells of Betz; and, secondly, in exhibiting a most pronounced layer of

stellate cells; and it differs from that of the remaining parietal region in containing pyramidal cells of larger dimensions.

Proceeding along the postcentral gyrus from above downwards there occurs a gradual diminution in the size of the large pyramidal cells, and in the number of large fibres.

Two types of cortex can be discriminated, one I distinguish by the name postcentral, the other by the name intermediate postcentral.

The area covered by the postcentral type of cortex is distributed over the anterior half of the postcentral convolution on the convex surface of the hemisphere, and, like the precentral field, it crosses the margin to coat a small area situated on the hinder part of the paracentral lobule.

I have called the narrow zone of cortex which forms a posterior buffer to the postcentral area proper "intermediate postcentral" because it bears some structural resemblance to the first and more important field, but it differs, inasmuch as the very large nerve fibres and the specially large pyramidal cells are wanting.

In reference to function, not once in the experience of Professors Sherrington and Grünbaum were movements obtained by excitation of the normal anthropoid postcentral gyrus with unipolar faradisation, nor was experimental ablation of portions of the same convolution attended by any positive interference with motion; and as the same results were obtained in the case of lower members of the ape family the postcentral gyrus is ousted from the position it formerly held as part of the motor area.

To establish the existence of an analogous physiological condition in the human brain a few excitation experiments in the course of operations on the brain will be alone necessary, and I am led to believe that confirmatory observations of the kind desired will shortly be published.

As to the grounds for assuming that the cortex of the postcentral gyrus constitutes a terminus for the reception of common sensory impressions, it seems to have been definitely proved that the tract of fibres known as von Monakow's "cortical lemniscus" is the cerebral continuation of the main system of sensory neurones; and from comparative studies in secondary degeneration it has been surmised that this tract proceeds to the parietal lobe (Tschermak and von Monakow), and particularly to the postcentral gyrus (Tschermak). From anatomical studies in the human brain this distribution has received partial confirmation (Tschermak). Further, from Professor and Madame Vogt's developmental studies it would appear that the sensory fibres which medullate first proceed almost exclusively to the postcentral gyrus. A study of the degeneration (retrograde) resulting from limited lesions in the postcentral gyrus, either in the human being or lower animals, might provide the further information we require on this point.

From an investigation of the changes occurring as a result of old-standing, restricted lesions in the internal capsule I have proved that serious alterations occur not only in the motor area, but also in the postcentral gyrus. The changes in the latter gyrus consist of a wholesale destruction of large medullated fibres in the cortex on the Rolandic side, and of almost all the large pyramidal cells in the same cortex. These are alterations resulting from a combined destruction of sensory and motor tracts. Looking round for a disease which might

be expected to occasion an isolated affection of sensory cortex I settled upon Tabes Dorsalis, and an examination of the brain in three instances of this disease has disclosed changes limited to the postcentral gyrus, and very similar to those I have described as the result of old-standing lesions in the internal capsule. The discovery of such changes in Tabes Dorsalis is, in my opinion, of the greatest possible significance, and one of the strongest points which can be advanced in favour of the view I am advocating.

In the brains of individuals disabled by amputation of one or other extremity reactive alterations have also been found in the postcentral gyrus, and these correspond in point of level with those which I have previously described in the precentral or motor area. The alteration resulting from amputation is not so marked as that seen in Tabes, or as that resulting from a capsular lesion, and, so far as I can judge, consists of a reduction in number of large pyramidal cells without much concomitant general distortion of the cell lamination.

In cases of capsular lesion, in Tabes Dorsalis and after amputations, the resulting changes appear to concentrate themselves on the anterior or Rolandic side of the postcentral convolution, and if any change does occur in the parietal cortex behind, it is of a kind which cannot be displayed by the methods of histological research at command.

The value of previously collected clinico-pathological and experimental observations has suffered depreciation owing to the preexisting erroneous and confusing supposition that the postcentral gyrus formed part of the motor area, and all data will have to be subjected to revision. In the study of future cases observers will have to be specially cautious in satisfying themselves that the lesion on which they base their conclusions is limited in extent to the postcentral gyrus. Everything considered, there seems to be nothing in recorded cases which can be used to overthrow the view that this gyrus is a sensory centre.

In regard to Ferrier and Horsley and Schäfer's statement that the gyrus fornicatus is a sensory centre, it will be shown in a later chapter that histological study lends no colour to such an assumption, and I can only think that in the operation which they practised, removal of that gyrus, they injured the fibres of the "cortical lemniscus" on its way to the postcentral convolution.

The separate localisation of the various components combining to produce "common sensation" is beset with difficulties. However, the view is promulgated here that the postcentral area, like better-known sensory realms, is divisible into a purely sensory part, to which all impressions primarily pass, and an investing psychic part. The former occupies the postcentral area proper and, in accordance with my thesis, its destruction should lead to abolition of psychic, as well as impairment of fundamental sensory components; the latter covers the intermediate postcentral field and may extend further back in the parietal direction; its destruction should lead to isolated disturbance of psychic sensory attributes. Some clinical and pathological findings substantiate this view. The fact that fundamental attributes, such as the simple recognition of touch, pain, heat, and cold, are only dulled and rarely or never abolished in cases of cortical lesions, is probably due to the participation of subcortical intermediate stations in the receptive act.

REFERENCES.

A. Passow. *Loc. cit.*

Th. Kaes. Beiträge zur Kenntniss des Reichthums der Grosshirnrinde des Menschen an markhaltigen Nervenfasern. *Arch. f. Psych. und Nervenkr.* Bd. xxv, Heft 3, 1893.

S. Ramón y Cajal. Studien über die Hirnrinde des Menschen. Heft ii. Die Bewegungsrinde. German Translation by Bresler. Leipzig, 1900.

C. S. Sherrington and A. S. F. Grünbaum. Observations on the Physiology of the Cerebral Cortex of some of the Higher Apes. *Proc. Roy. Soc.*, Vol. lxix, 1901, and lxxi, 1903.

L. F. Barker. The Nervous System and its Constituent Neurones. 1902.

B. von Gudden. Beitrag zur Kenntniss des Corpus mammillare und der sogenannten Schenkel des Fornix. *Arch. f. Psych. u. Nervenkr.*, Bd. xi, 1881.

P. Flechsig. 1. Die Localisation der geistigen Vorgänge mit besonderer Berücksichtigung der Sinnesempfindungen des Menschen. Leipzig, 1896.

2. Gehirn und Seele. Leipzig, 1896.

3. Weitere Mittheilungen über die entwickelungsgeschichtlichen (myelogenetischen) Felder in der menschlichen Grosshirnrinde. *Neurol. Centralb.*, Mar. 1, 1903.

Hösel. Beiträge zur Anatomie der Schleifen. *Neurol. Centralb.*, Leipzig, Band xiii, 1894.

C. von Monakow. Gehirnpathologie. Wien, 1897. Experimentelle Beiträge zur Kenntniss der Pyramiden- und Schleifenbahne. *Corresp. Blatt. f. schweiz. Aerzte*, Basel, Bd. xiv, 1884.

A. Mahaim. Ein Fall von secundärer Erkrankung des Thalamus opticus und der Regio subthalamica. *Arch. f. Psych. u. Nervenkr.*, Berlin, Bd. xxv, 1893.

F. W. Mott. Experimental Inquiry on the Afferent Tracts of the Central Nervous System of the Monkey. *Brain*, Vol. xviii, 1895. See also *Journal of Physiology*, 1894.

A. Tschermak. 1. Ueber die Folgen der Durchschneidung des Trapezkörpers bei der Katze. *Neurol. Centralb.*, Nos. 15 and 16, 1899.

2. Notiz betreffs des Rindenfeldes der Hinterstrangbahnen. *Neurol. Centralb.*, No. 4, 1898.

P. Vejas. Experimentelle Beiträge zur Kenntniss der Verbindungsbahnen des Kleinhirns und des Verlaufs der Funiculi graciles und cuneati. *Arch. f. Psych.*, Bd. xvi, 1885.

J. Singer and E. Münzer. Beiträge zur Anatomie des Centralnervensystems insbesondere des Rückenmarkes. *Denkschr. d. Akad. d. Wissensch.*, Wien, Bd. lvii, 1890.

J. et Madame J. Dejerine. Sur les connexions du ruban de Reil avec la corticalité cérébrale. *Compt. Rend. de la Soc. Biol.*, Paris, Tome ii, 1895.

C. Jakob. Ein Beitrag zur Lehre vom Schleifenverlauf (obere, Rinden-, Thalamusschleife). *Neurol. Centralb.*, No. xiv. 1895.

Darkschewitch. Ueber die Veränderungen im Centralen Stumpf eines motorischen Nerven bei Verletzung eines peripherischen Abschnittes. *Neurol. Centralb.*, p. 490, 1892.

A. Van Gehuchten. La dégénérescence dite rétrograde ou dégénérescence Wallérienne indirecte. *Le Nevraxe*, Vol. v, Fasc. 1, 1903.

Bregmann. Ueber experimentelle aufsteigende Degeneration motorischer und sensibler Hirnnerven. *Obersteiners' Arbeiten.* Wien, 1892.

KLIPPEL and DURANTE. Les dégénérescences rétrogrades dans les nerfs périphériques et les centres nervaux. *Revue de Médecine*, Vol. 15, 1895.

DÖLLKEN. Die Reifung der Leitungsbahnen im Thiergehirn. *Neurol. Centralb.*, No. 21, 1898.

C. and MADAME VOGT. Neurobiologische Arbeiten I. Jena, 1902.

H. MUNK. Ueber die Fühlsphäre der Grosshirnrinde. *Sitzungsber. d. k. pr. Akad.*, 1893—95.

LUCIANI and SEPPILLI. The Localisation of Function in the Brain. Abstract in *Brain*, Vol. I.

W. VON BECHTEREW. Die Leitungsbahnen im Gehirn und Rückenmark. German Translation by Weinberg. 2nd Edition. Leipzig, 1899.

J. DEJERINE. *Centres Nerveux*, Vol. II.

EDWARD LONG. Les voies centrales de la sensibilité générale. *Étude anatomo-clinique.* Paris [Steinheil], 1899.

W. BEVAN LEWIS. *Textbook of Mental Diseases.* London, 2nd Edition.

C. K. MILLS. Cerebral Localisation in its Practical Relations. *Brain*, Vol. XII. And several recent papers in American Journals.

E. REDLICH. Ueber Störungen des Muskelsinnes bei der cerebrale Hemiplegie. *Wiener klin. Wochenschr.* June, 1893.

CHARCOT and PITRES. 1. Contribution à l'étude des localisations dans l'écorce des hémisphères cérébraux. *Revue Mensuelle*, I, 1877.

2. Les centres moteurs corticaux chez l'homme. Paris, 1895.

D. FERRIER. 1. The Functions of the Brain. London, 1886, 2nd Edition.

2. Article on "The Regional Diagnosis of Cerebral Disease" in Allbutt's *System of Medicine.* London, 1901.

V. HORSLEY and E. A. SCHÄFER. A Record of Experiments upon the Functions of the Cerebral Cortex. *Phil. Trans.*, Vol. CLXXIX, 1888.

F. DURANTE. Observations on Certain Localisations. *Brit. Med. Journ.*, Dec. 13, 1902.

G. L. WALTON and E. PAUL. 1. Contribution to the Study of the Cortical Sensory Areas. *Brain*, Autumn Number, 1901.

2. The Clinical Value of Astereognosis and its bearing upon Cerebral Localisation. *Journ. of Nerv. and Ment. Dis.*, April, 1901.

D. FERRIER and W. TURNER. Clifford Allbutt's *System of Medicine*, and papers in *Phil. Trans.*, Vol. CLXXV, 1894; *Proc. Roy. Soc.* Vol. LXII, 1897.

K. BRODMANN. Beiträge zur histologischen Lokalisation der Grosshirnrinde. Erste Mitteilung; die Regio rolandica. *Journal f. Psychol. und Neurol.*, Bd. II, 1903.

CHAPTER V.

VISUO-SENSORY AND VISUO-PSYCHIC AREAS.

Visuo-Sensory or Calcarine Area.

In the cortex of those convolutions which bound and form the walls of the calcarine fissure there exists a prominent lamina with which all anatomists are familiar; it is known by the name "line of Gennari." This lamina can be easily recognised with the naked eye in slices of a fresh brain, and appears as a distinct white line situated midway between the surface and the white substance; its white colour in the fresh condition suggests that nerve fibres enter largely into its constitution, and that this is so, treatment with a stain which will display nerve fibres unquestionably proves.

Recent researches afford indisputable grounds for believing that the area of cortex, characterised by the possession of this lamina, is the chief end-station of the optic radiations, and therefore constitutes the cortical centre for the primary reception of visual sensations; hence particular interest attaches to a detailed examination of its constituents.

TYPE OF ARRANGEMENT OF NERVE FIBRES. (Plate X, fig. 1.)

Concerning medullated nerve fibres, the following description of the type of arrangement has been facilitated by reference to the writings of other workers, notably Kaes, Botazzi, and Kölliker, who have given excellent accounts of these fibres, and whose observations I have been able to check and to confirm in almost every particular, because they happen to have displayed the fibres by methods resembling that which I myself have employed. I have also found it a great advantage to be able to consult Ramón y Cajal's extremely thorough description of the appearances presented by his chrome silver preparations of the visual cortex.

Passing to a consideration of the individual layers:—

Zonal Layer.

Compared with most other parts of the brain this layer is relatively well-developed; at the same time it is not nearly so prominent as it is, for instance, in the precentral cortex, also its lower border is lacking in sharpness of definition. While it is chiefly composed of varicose fibrils, it is important to notice that it contains a few evenly medullated fibres of moderately large size and some coarse varicose fibres. Kaes mentions the existence of these large fibres, and an examination of chrome silver preparations seems to prove that they represent the radial prolongations of the subjacent giant cells or solitary cells of Meynert (Ramón y Cajal).

Supraradiary Layer.

The supraradiary layer is occupied by a comparatively dense plexus of fibres most of which are of delicate calibre, but, here and there, fibres of Martinotti of coarser type are seen running up to end in the zonal layer. It is also to be observed that this is one of the regions in which the fibres composing the radiary fasciculi pierce the line of Baillarger (Gennari) and project well into the supraradiary layer; in some measure this accounts for the fact that the plexus in the upper half of the layer is much sparser than it is in the lower.

The Line of Gennari.

This line is composed of an extremely dense network of fibres of fine calibre, interlacing and intertwining in all directions, mingled with which are a few long, horizontal, or oblique fibres of medium calibre. In the same network, especially in the lower part, spaces are left which correspond in size with the small stellate cells seen at this level, for the accommodation of which the lacunae are evidently intended.



FIG. 10. Radiary zone in the calcarine or visuo-sensory area. $\times \frac{850}{1}$.

The drawing has been made from a part deep down, next the white substance, in order to bring in some of the large obliquely or transversely directed fibres to which special reference is made in the text. These are probably the optic fibres of Ramón y Cajal. It will be noticed that for cortex having such important functional attributes the radiations are not strong, and the interradiary plexus not particularly rich.

The Radiations of Meynert.

The individual bundles are by no means voluminous, and they are composed mainly of fine or medium-sized fibres, those of large calibre being distinctly uncommon.

Interradiary Plexus and Association Fibres.

Immediately beneath the line of Gennari there occurs a zone of considerable depth in which both the interradiary plexus proper and the association system are poorly represented; hence this part has a pallid appearance, and in consequence the line of Gennari is given a clearness of definition which it would not otherwise possess. Under a low power of the microscope this pallid zone forms quite a striking feature, and it evidently corresponds in position with the lamina of small stellate cells to be noted hereafter.

In the remaining portion of the radiary zone, that is in the part lying between this pallid lamina and the white substance, the fibre wealth is great; not only do the fibres of delicate calibre show a numerical increase, but evenly-medullated fibres of gross calibre make their appearance. These are placed either obliquely or horizontally, and are most numerous in the immediate neighbourhood of the white substance; and it is important to mention that they do not tend to join the radiary fasciculi, but on the contrary cross them at all angles. (Text figure 10.)

Now to my mind the presence of these fibres constitutes almost as important a feature of the calcarine type of cortex as does the line of Gennari; their great size, their oblique or horizontal direction, and the more or less open formation of the layer which they traverse, are all striking characters, and a similar appearance is seen only in two other parts of the cortex, viz. in the postcentral area (along the parietal wall of the fissure of Rolando), and in the transverse temporal gyri.

It is impossible to trace these large fibres to their destination, or speak concerning their intimate cortical connections from an examination of specimens stained for medullated fibres only, but Ramón y Cajal gives a very full and lucid description of them, and rightly credits them with much importance. He distinguishes them by the name "optic fibres," and his figures, drawn from chrome-silver preparations, clearly represent that the majority of their terminal branches end in and have important connections with the elements of the stellate layer and line of Gennari. "Bei weitem die meisten der aus den Opticusfasern hervorgehenden Aeste vertheilen sich also in den Schichten der Sternzellen und man muss folglich diese Schichten als den Hauptort der grauen Substanz bezeichnen, in welchem sich das optische Bild projicirt und an dem die optische Empfindung vor sich geht."

Concerning the central course of these fibres all my sections show their presence in great numbers in the white substance immediately subjacent to the calcarine cortex, some cut obliquely, some transversely, and some horizontally, and the specimens as plainly demonstrate that they constitute the cortical projections of the radiations of Gratiolet; hence I am compelled to agree with every word which Ramón y Cajal says concerning their physiological significance as conductors of visual impulses.

TYPE OF ARRANGEMENT OF NERVE CELLS. (Plate XI, fig. 1.)

Just as the arrangement of nerve fibres in this area is absolutely distinctive, so also it is characterised by quite a special type of nerve cell lamination, indeed it is as easy to map out the area, in serial sections stained according to the method of Nissl, as it is in those stained for the display of nerve fibres.

But since this type of cell lamination has been examined with extreme thoroughness by other observers (notably Ramón y Cajal and Bolton) the following remarks must necessarily be of a recapitulatory nature; they will also be framed to emphasise the features which interest the topographist rather than the minute histologist.

That there may be no confusion concerning the different laminae to which I shall allude, I would at once mention that I am following the classification adopted by Ramón y Cajal; and I would refer those who desire details on the relation of this classification to others published, to Bolton's paper, where the arrangements adopted by himself are compared in tabular form with those of Meynert, Krause, Betz, Leonova, Hammarberg, Schlapp, and Ramón y Cajal.

Plexiform Layer.

While affording no indication that special elements reside in this layer, Nissl specimens clearly show that its total depth is less than in other cortical regions, a fact which did not escape the notice of Meynert, and which, as Ramón y Cajal points out, is probably due to the relatively small number of medium-sized and large pyramidal cells present in subjacent parts.

From an examination of his chrome-silver preparations Ramón y Cajal draws attention to the existence of certain special, horizontally-directed cells in this layer, cells which he thinks act as a medium in bringing the large association fibres of this layer into dynamic relation with the pyramidal cells of neighbouring convolutions.

Layer of Small Pyramidal Cells.

From the topographic point of view the only feature of interest presented by this layer is the close manner in which its constituent cells are arranged.

Layer of Medium-sized Pyramidal Cells.

The shape of these cells is similar to that of the cells immediately above, but their size is greater and they stand further apart from one another. It is also to be noticed that in the lower part of the layer small stellate cells are dotted about, and that larger pyramidal cells, in which distinct chromophilic particles may be seen in the protoplasm of the cell-body, are occasionally present.

Layer of Large Stellate Cells.

The nature and arrangement of the cell elements in this lamina are so distinctive that they must be described at length.

The layer is a broad one, measuring about ·3 mm., and the large pyramidal cells which occupy a homologous position in other cortical territories are almost entirely absent; their place being taken by curious large stellate cells, intermingled with which are smaller bodies resembling those seen in the subjacent stellate layer proper.

Concerning the larger variety of stellate cells, they lie chiefly in the outer zone of the lamina, and are of curious, triangular, or quadrilateral form; they have three or four stout processes pointing in no definite direction, and they contain scattered clumps of chromophilic material. They are not of great size, only measuring about 25 μ in diameter, nor are they specially numerous, hence they do not form a prominent lamina when viewed under a low power of the microscope, and as a matter of fact the whole layer has a pallid appearance in comparison with the layer of medium-sized pyramidal cells above and the dense stellate layer below. In seeking an explanation of this pallid appearance we have merely to turn to our specimens stained for nerve fibres, wherein we shall find that a large part of the corresponding zone is occupied by the dense plexus of fibres which we described under the name of the line of Gennari. Moreover, we have Ramón y Cajal's evidence that in Golgi preparations the above-mentioned large stellate cells and a variety of the same cells which he finds at this level, have strong, horizontally directed dendrites which branch frequently and extend long distances, also axis-cylinder processes which send out stout collaterals to ramify in the vicinity of the cell itself and in the immediately subjacent stellate layer, and clearly these add to the density of the fibre plexus in the line of Gennari and help to increase the pallor of the field in Nissl preparations.

Layer of Small Stellate Cells.

Bounded above, and, as we shall presently see, below also, by a pallid zone, the stellate layer, which is about ·17 mm. deep and heavily stocked with cell elements, forms a prominent lamina.

In Nissl specimens the component cells appear as minute angular bodies with a relatively large nucleus, and they are separated into vertical columns by the fasciculi of radiating fibres which pierce the layer.

It seems that in Golgi preparations several varieties of stellate cells may be proved to exist, but for details concerning these the reader is referred to Ramón y Cajal's work.

Layer of Small Pyramidal Cells with an Ascending Axis-Cylinder.

Ramón y Cajal is responsible for the differentiation of this layer of small pyramidal cells, for which he finds a place immediately below the stellate layer, and about which he says, that as the morphology of the cells is so peculiar (the method of Golgi shows that they have an ascending axis-cylinder process and that they may be egg-shaped, stellate or strictly pyramidal in form) their recognition as a separate layer is warranted. But in point of fact it can hardly be said that they form a distinct lamina, because they are sparsely scattered over an otherwise pallid area, at the bottom of which lie the great pyramidal cells or solitary cells of Meynert, and in Nissl specimens they exhibit no features of special interest.

Layer of Giant Pyramidal Cells (Solitary Cells of Meynert).

These solitary cells of Meynert constitute another very important and distinctive feature of the calcarine cortex.

Their number is not great, in a single low power microscopic field one can seldom see more than half-a-dozen, and they are best described as lying in a single row from ·2 to ·3 mm. below the stellate layer, although dislocated members often lie at a higher or lower level.

In shape they are triangular or stellate, and they possess large bodies from 25 to 30μ in diameter, in which chromophilic particles are distinctly evident. According to Ramón y Cajal, the radiary or apical process of these cells, although relatively speaking more delicate than the same process in giant pyramidal cells of other regions, is still of great length and reaches up to the plexiform layer: further, the basilar processes are very numerous and thick, and so peculiar that they serve to distinguish these cells from homonymous cells in any other portion of the brain; thus in addition to being thick and numerous they run almost exclusively in a horizontal direction, giving off branches as they go, while their length often exceeds that of the apical process.

Ramón y Cajal has seen similar cells in the visual cortex of the cat and dog, and I will now add that such cells are also recognisable in the Orang and Chimpanzee.

Layer of Medium-sized Pyramidal Cells.

This layer is best seen in those parts of the calcarine cortex which lie on the free surface; they form a fairly definite lamina, and the component cells, which are triangular or fusiform, are separated into columns by the intervening radiations of Meynert.

Layer of Fusiform and Triangular Cells.

The cells of this lamina are triangular, ovoid or fusiform, and few in number. Along the walls of the calcarine fissure they, together with the overlying medium-sized pyramids, are compressed within a very narrow compass and are flattened so that their main processes point in a horizontal direction, in consequence of which that part of the cortex lying between the solitary giant cells and the white substance has a very curious packed appearance.

Summary.

Briefly put, the characters which distinguish the calcarine type of cell lamination are, first, the almost unique external layer of large stellate cells usurping the position occupied by the external layer of large pyramidal cells in other regions; secondly, the existence of pale-stained zones above and below the uncommonly well-marked layer of stellate cells, the upper of which marks the position of the line of Gennari; thirdly, the presence in the depths of the cortex of the layer of solitary cells of Meynert, cells which differ from homonymous cells in any other part of the brain.

DISTRIBUTION OF THE CALCARINE TYPE OF CORTEX. (Text figure 11.)

As this type of cortex has such important relations with the calcarine fissure it is necessary before discussing its limits that we should have a clear understanding concerning some points in the anatomy of this fissure. A close examination of several hundreds of brains and casts which I have prepared for the museum at Rainhill Asylum convinces me that there is no reason for departing from the description of the fissure given by Professor Cunningham in the *Memoirs* which he published in 1892, and the following remarks have been abstracted from his work.

He divides the fissure into two portions, an anterior part, or stem, which he would call the fissura calcarina anterior and a posterior part, or fissura calcarina posterior. The fissura calcarina anterior, or stem, is that part of the fissure which lies anterior to the junction with the parieto-occipital fissure, and it differs from the posterior portion in being much deeper and in being a "complete" fissure.

The stem is separated from the parieto-occipital fissure by the deep annectant gyrus (the gyrus cunei of Ecker or inferior internal pli de passage of Gratiolet).

A deep annectant gyrus is likewise interposed between the stem and the posterior portion of the calcarine fissure. This barrier may generally be found at a short distance behind the apex of the cuneus, and as it connects the cuneus and lingual lobule it has been named the anterior deep cuneo-lingual gyrus.

The posterior calcarine fissure in addition to being shallower is also somewhat shorter than the anterior, its average length being 35 mm. against 40 mm.; furthermore, it is divided into two parts posteriorly, by a deep annectant gyrus which traverses its floor and connects the cuneus with the posterior part of the gyrus lingualis. This is called the posterior deep cuneo-lingual gyrus.

It is common to find this annectant reaching the surface (according to Cunningham, in 20 °/₀ of cases) and completely cutting off the posterior forked extremity of the fissure, a vertically placed subdivision which also goes by the name of the fissura extrema of Seitz or retrocalcarine fissure of Monakow.

In regard to the position of this vertical offshoot it is to be noticed that although it lies close upon the margin of the hemisphere it usually remains confined to the mesial surface, in other words it does not extend to the convexity of the hemisphere[1].

Now concerning the distribution of the field of cortex bearing a line of Gennari, reference to fig. 11 will show how its position is influenced directly by the calcarine fissure and how it follows closely every bend and branch of this sulcus.

In describing its distribution in detail it will be convenient to refer to the appearances presented by a series of sections made at right angles to the calcarine fissure. In such sections it is found that the arrangement does not reach quite to the anterior extremity of the stem or anterior calcarine fissure but commences at a point from 5 to 10 mm. further back. It first shows itself on the lower wall of the sulcus about half way down, and as we proceed backwards, it gradually spreads over the lip of the sulcus on to the lingual lobule, in the outward or surface direction, and down to the floor of the sulcus, in the downward or central direction. From this the important point may be gathered that the cortex clothing the upper, or more correctly speaking, the limbic wall of the stem of the calcarine fissure does not possess the peculiar lamination under consideration, and

[1] In an important paper on the anatomy of the occipital region published by Dr Elliot Smith as this passes through the press, these fissures and parts receive other names, thus, the stem or anterior calcarine fissure is called the *sulcus calcarinus proprius*, the posterior calcarine fissure with its posterior vertical subdivision the *sulcus retro-calcarinus* (*vel intrastriatus mesialis*), and the field bearing the line of Gennari the *area striata*.

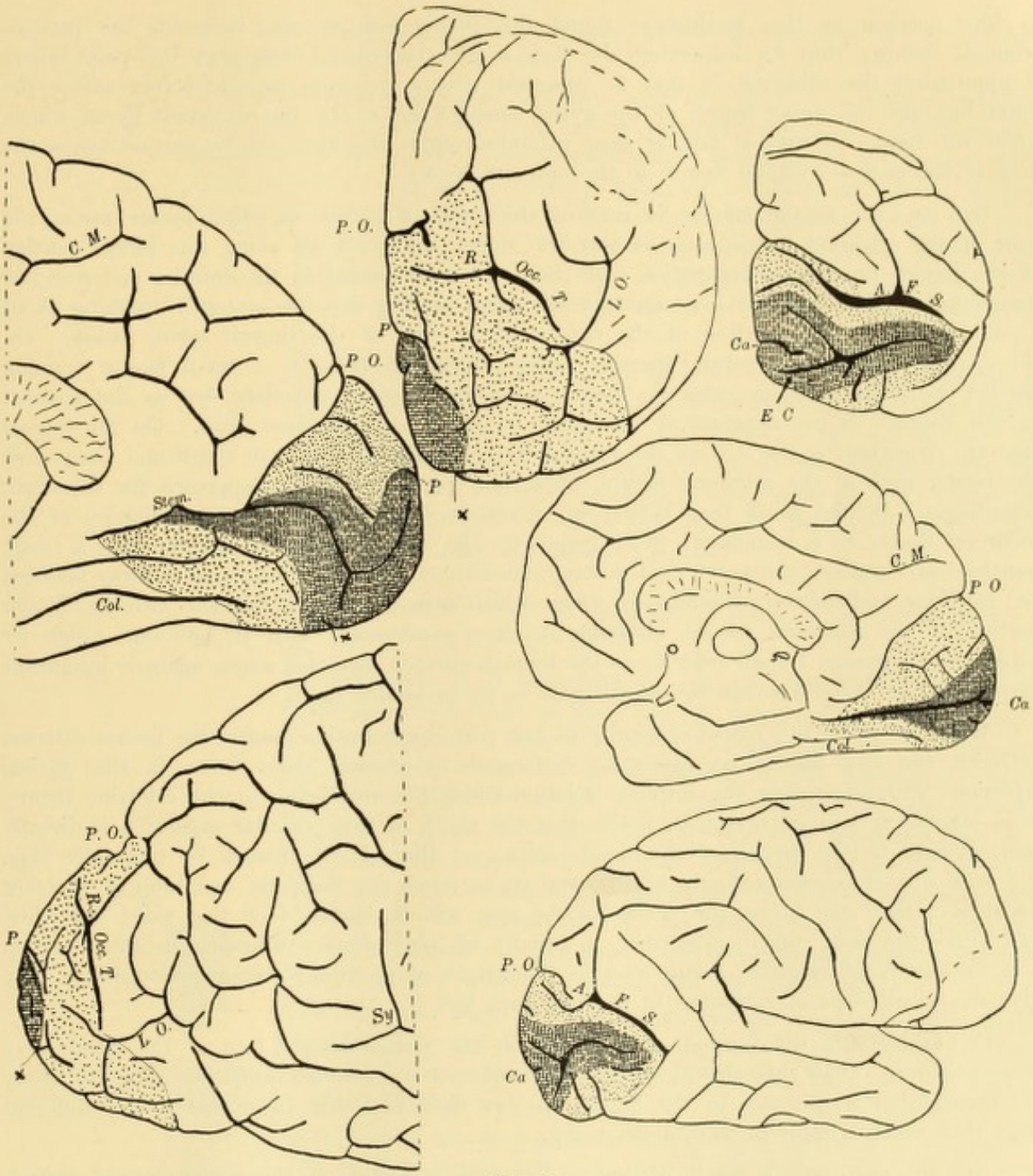

FIG. 11.

Drawings to illustrate the distribution of the visuo-sensory (cross-hatched) and visuo-psychic (dotted) areas in the human being and orang. The three figures to the right are from the ape, and the wide lateral extension is to be specially noticed; observe, also, that the visuo-sensory area closely follows the fissure marked *E. C.*, the so-called "external calcarine" fissure (the sulcus intrastriatus lateralis of Elliot Smith), and that the visuo-psychic field is closely related to the "Affenspalte" (*A. F. S.*). In the human brain the ramus occipitalis transversus (*R. Occ. T.*) seems to form a corresponding visuo-psychic limit.

Ca. = calcarine fissure. *Stem* is placed above the division distinguished by that name. *Col.* = collateral fissure. *P. O.* = parieto-occipital fissure. *C. M.* = calloso-marginal fissure. *L. O.* = lateral occipital fissure of Eberstaller. *Sy.* = Sylvan fissure. *P.* = superior polar fissure of Bolton. × = inferior polar fissure of same writer.

in like manner as this lamination shuns the limbic wall so also it avoids the parieto-occipital fissure; thus on inspecting the floor of the last-named sulcus at the point where it approaches the calcarine, it may be observed that a calcarine type of cortex covers the lower but not the upper aspect of the gyrus cunei of Ecker (*i.e.* the annectant gyrus, which, when the fissure is opened out, is seen extending from the apex of the cuneus across the floor of the parieto-occipital fissure to the opposite bank).

But as soon as the cuneus is reached this type of cortex at once passes across the floor of the calcarine fissure and ascends the upper wall, and all along this hinder portion of the fissure the special lamination coats both its walls (including the anterior and posterior cuneo-lingual annectant gyri), it also spreads for a varying distance—roughly speaking about 1 cm.—on to the free surface of the cuneus above, and of the lingual lobule below. On the cuneus, the cuneal sulcus (parallel cuneal sulcus of Bolton[1]), a small fissure running parallel with the posterior calcarine fissure, commonly forms a boundary, but as the position of this fissuret is not constant it must not be regarded as a fixed limit. On the lingual side the boundary is not always determined by sulci, although it may touch and even cross the hinder limb of the collateral fissure, when this sulcus happens to approach the calcarine; accordingly I do not think that Bolton is correct in describing the posterior division of the collateral fissure as a boundary. More frequently the area comes into relation with a small, unnamed and shallow sulcus which lies longitudinally on the gyrus lingualis, midway between the calcarine and collateral fissures; a sulcus which is not to be confounded with the hinder portion of the collateral fissure, although it often anastomoses with it, and one which for explanatory purposes I shall refer to as the lingual sulcus[2]. But this sulcus again is inconstant in position and must also not be looked upon as an invariable limit.

When we reach the forked extremity of the posterior calcarine fissure, the fissura extrema of Seitz, the area attains its maximum dimensions, measuring about 3 cm. in the vertical direction; and, as proving the intimate relation which the area bears to the calcarine fissure, it is interesting and important to notice that the width of this posterior expansion is directly proportionate to the length of the fissura extrema; thus, if the fissura be unusually long, the area will be correspondingly broad; and if, as sometimes happens, one limb of the fork be shorter than the other, the extent of the area will be curtailed on that side; and while as a rule the area taken altogether is usually of pear shape, variations in the direction and curves of the calcarine fissure and in the length of its two posterior prolongations, may give rise to all sorts of variations in the boundary line.

Concerning the distribution of the area on the postero-lateral face of the hemisphere it is important that this should be specially referred to, because when we come to study the distribution of the area in the higher ape, we shall find that its extent is very different from that which obtains in the human being.

Now in man, only a small portion of the area is found on the postero-lateral surface. In a view of the lateral aspect of the hemisphere the field is just visible as a narrow crescent peeping round the tip of the occipital pole, and viewed in full from the occipital aspect it is not usually continued outwards for a distance of much more than 1 cm. And close examination will invariably show that the lateral limit runs in line with and bears a direct relation to the length and position of the fissura extrema of Seitz, again substantiating

[1] Elliot Smith, who appears not to have read Bolton's paper, calls this the sulcus limitans superior areae striatae.
[2] This sulcus has been recognised by Elliot Smith and named the sulcus limitans inferior areae striatae.

what has been said already concerning the influence which the position of the calcarine fissure exercises over the distribution of the area.

In his paper on the exact histological localisation of the visual area, Bolton mentions the presence of two polar sulci, which he describes in the following words, "small, more or less semilunar fissures, which are invariably found surrounding the posterior extremities of the calcarine fissure and which are frequently distinct from the anterior and lateral occipital fissures," and he states further that these fissures form constant boundary lines for the visual area. Since the publication of Bolton's work I have repeatedly defined these fissurets, also I am able to endorse his statement that they form constant limits for the visual area, that is, provided the field over which a calcarine type of cortex is distributed be considered synonymous with that area.

But with the exception of these fissurets, there is certainly no sulcus on the postero-lateral surface of the human brain which seems to exert a constant influence on the disposition of the area; its relation to the lateral occipital sulcus of Eberstaller is as uncertain as the distribution of that sulcus is variable, a wide zone separates it from the transverse occipital sulcus of Ecker, and as the "external" calcarine fissure, which according to Cunningham is present in the foetal brain, defies definition in at any rate the majority of adult brains, it cannot be said to be related to it. (See also footnote p. 125.)

DISTRIBUTION OF THE CALCARINE TYPE OF CORTEX IN THE ANTHROPOID APE.

(Text-figure 11.)

From the phylogenetic standpoint it is important to compare the distribution of this type of cortex in the higher apes with that in man, and on doing so it is interesting to find that in the brains of both the same type of structure clings closely to the calcarine fissure, and that, in consequence, a view of the mesial surface of the hemispheres shows a marked resemblance between the respective areas. It is more interesting to discover that on the postero-lateral surface there is a vast difference, the anthropoid area being infinitely more extensive than the human; while a further and a still more important distinction, to which I shall have to allude in detail presently, is that in the higher ape the distribution of the area is definitely influenced by and related to certain sulci on the external surface of the occipital lobe, sulci which in themselves as anatomical units constitute distinguishing features between the two brains; I refer to the "external calcarine fissure" and the "Affenspalte."

Since the distribution of the area which I have mapped out in the brains of the chimpanzees submitted to examination does not differ materially from that which I have defined in the orang, separate descriptions are unnecessary, and the following lines will embody an account of the delimitation of the area in both animals.

Starting with the anterior part of the area, again we find that the special type of structure does not reach quite to the anterior extremity of the "stem" of the calcarine fissure, and that it first makes its appearance on the lower or lingual wall of the sulcus; so far resembling the human arrangement; but it very rapidly crosses the floor and climbs the upper wall, and in this respect the anthropoid and human brains differ; for it will be remembered that in the latter the calcarine type of cortex, as a rule, is confined entirely to the inferior wall and lip of the "stem" of the fissure.

An explanation of this deviation in the delimitation of the calcarine cortex in the anthropoid brain is not far to seek, for in all three specimens which I have examined the annectant

gyrus cunei, joining the cuneus to the post-limbic convolution, has come to the surface and completely separated the parieto-occipital from the calcarine fissure. I have stated already that in the human subject this annectant lies at a deep level and is seen only when the lips of the fissure are thrown widely apart, also I have pointed out that the calcarine type of cortex is to be found on the lower or calcarine, but not on the upper or parieto-occipital half of this annectant. Now in some cases in the human being—3·9 per cent. according to Cunningham—the gyrus cunei comes to the surface in anthropoid fashion, and it is likely that in these instances the calcarine type of cortex is drawn up to a corresponding degree and that it may cover some of the upper wall of the "stem" of the fissure, as it does in the case of the ape.

Before considering the relation of this type of cortex to the fissura calcarina posterior, I have to mention that, in the memoir already quoted from, Cunningham maintained that this division of the fissure, fundamentally distinct from the anterior division in the human brain, is not represented in the ape. His grounds for this statement are as follows, "throughout its whole length the calcarine fissure in both the chimpanzee and the orang presents very nearly the same depth. Its walls are smooth, and there is not a vestige of a deep annectant gyrus to be seen crossing its bottom at any point to connect its opposite banks with each other. Further, when we study the relation which this fissure presents to the calcar avis, we observe that the entire length of this ventricular eminence corresponds with that portion of the sulcus which lies opposite to it." Hence he believes that the entire length of the precursor of the calcarine fissure in the early human foetus is the equivalent of the calcarine fissure of the ape, that in the ape the original fissure persists in its entirety, and that the posterior portion does not become obliterated, to be replaced at a later date by the secondary posterior calcarine fissure, as happens in man.

I shall have occasion to return to this question of the development of the calcarine fissure, I mention it here before I describe the relation which the calcarine type of cortex bears to it, only to indicate that a certain element of dubiety surrounds the morphological representation of the fissura calcarina posterior.

Now we find this type of cortex clothing the floor and both the cuneal and the lingual walls of this portion of the sulcal complex, also we see it spreading for a distance of 3—5 mm. on to the exposed surface of the cuneus above and of the lingual lobule below. Further, as the pole of the hemisphere is approached the area undergoes a marked expansion. In all these respects we have a reproduction of the human arrangement, and I may say that in the second chimpanzee's brain which I examined the arrangement is extremely like that seen in the human being.

But when we reach the margin of the hemisphere the resemblance ceases, for instead of curving round the hinder margin of the hemisphere for a distance of about 1 cm. and then ceasing, as it does in the human brain, the area is carried on for at least 4 cm. in the horizontal plane, terminating only a short distance behind the lower extremity of the "Affenspalte"; and the field which it covers is by no means a narrow strip, for, viewed from behind, it must be described as occupying the major part of the postero-lateral surface of the occipital lobe.

And next the question arises, how far can the disagreement in territorial distribution of this type of cortex in the human and anthropoid brains be made to coincide with the anatomical discrepancies which apparently exist?

Analysing these discrepancies we find, first, that the mode of termination of the calcarine fissure in the anthropoid brain is peculiar; for in both my chimpanzee hemispheres there is no sign of bifurcation at the posterior extremity, and in the orang's hemisphere only the slightest suspicion of a fork is noticeable, hence we see no fissura extrema of Seitz. Secondly, as Cunningham indicates, the tail of the fissure instead of pointing straight to the occipital pole, as in the human brain, is directed more forwards so as to form a sharper angle with the parieto-occipital fissure (in one of my chimpanzee hemispheres, however, the direction of the fissure exactly resembles that in the human brain). In the third place, we observe on the postero-lateral surface of the hemisphere a sulcus from 3 to 4 cm. long, which lies in the same plane and is almost continuous with the calcarine fissure; it is a sulcus of considerable depth and obviously has a special significance, not only because it is deposited almost exactly in the middle of the field showing a calcarine type of cortex, but because the distribution of this type of cortex seems to bear a close relation to and to be influenced by the position of this sulcus, just as its distribution on the mesial surface of the hemisphere is influenced by the calcarine fissure. At first I was inclined to regard this sulcus as the homologue of the human sulcus lateralis occipitalis of Eberstaller, but further investigation and above all things a knowledge of the histology of the cortex of these parts caused me to demur from that view, and I now think that the fissure is either the equivalent of a sulcus known as the "external calcarine fissure," or, and this is more likely, it represents a dislocated "fissura calcarina posterior."

Of the external calcarine fissure Cunningham gives the following account:

"It is placed very obliquely along the lower border of the cerebrum, and corresponds on the outer surface of the hemisphere with the calcarine fissure on the mesial face. When transverse sections are made through the occipital part of the cerebral hemisphere, the external calcarine fissure is seen to be a deep infolding of the hemisphere wall, and the bulging which it forms into the ventricular cavity lies exactly opposite, and may be actually in contact with the calcar avis. The external calcarine fissure appears very early. It can be distinguished in a large number of cases amongst the primitive transitory furrows, and at this period it is sometimes continuous around the occipital pole of the hemisphere with the precursor of the true calcarine fissure. This connection, where it exists, is always obliterated about the fourth month. In the human brain the external fissure is transitory. It is effaced towards the end of the fifth month. It is not so constant as the external perpendicular fissure of Bischoff and in many cases it fails completely.

Although evanescent in the brain of man, there is some reason to believe that it has a permanent representative in the brain of the ape. On the outer surface of the occipital lobe of most apes a deep fissure runs horizontally forwards from the occipital pole, and comes to an end a short distance behind the free anterior lip of the occipital operculum. This fissure is placed on the outer face of the hemisphere in an exactly corresponding position to the calcarine fissure, and its anterior end, in most of the numerous specimens which I have examined, just falls short of the posterior horn of the lateral ventricle[1]."

While the histological evidence which I can now supply lends some support to Cunningham's reasoning that the transitory external calcarine fissure of the human cerebrum is homologous to the permanent, deep, horizontal fissure on the outer face of the occipital lobe in the anthropoid ape, it does not wholly prove the correctness of his argument, simply because the external calcarine fissure is unrepresented in the adult human brain. One point,

[1] I observe that Elliot Smith in his earlier papers speaks of this simian external calcarine fissure as the lateral occipital, but it is not to be confused with the human lateral occipital sulcus of Eberstaller, which is quite another element. In his later papers Elliot Smith removes the confusion by introducing the name sulcus intrastriatus lateralis.

however, which I think this histological investigation definitely settles is the debated question of the affinity between the sulcus occipitalis secundus vel sulcus occipitalis lateralis of Eberstaller and this anthropoid fissure, for a close comparison of these two sulci proves that with the single exception of agreeing roughly in regard to position they have no correspondence whatever. Thus, we find, first, that the anthropoid fissure is not only a relatively deep one but its course and position appear to be fixed, definite, and invariable. And while Eberstaller gives the sulcus occipitalis lateralis a position of high importance in the human adult brain and considers that it should be held to form the inferior boundary of the occipital lobe, on the outer surface of the hemisphere, I have convinced myself from a careful examination of over 200 hemispheres that this limit, on account of the extreme variability of the position and general representation of the fissure, is an unsatisfactory one, added to which there is no gainsaying the observation that in all cases the sulcus is relatively shallow. But my second reason for discrediting the homology between the two fissures is that which to my mind dispels all doubt on the point, it is the histological truth that what I have called the calcarine type of cortex closely follows the anthropoid fissure, while in the human cerebrum the sulcus lateralis occipitalis lies well without the area covered by a similar type of cortex, in fact its walls and the convolutions which border it are clothed by a totally dissimilar type, and this it must be granted is an extremely important point of difference.

Having arrived at the decision that this curious simian fissure does not correspond with the human lateral occipital sulcus, and that its affinity with the transitory human external calcarine fissure is not wholly proved, we have next to consider whether evidence exists to suggest that it has any other human equivalent.

In this connection there is one point which occurs to me and it bears upon the "Affenspalte." Now it is not my desire to enter the arena with those who have studied and discussed the vexed question of the homology of this great and important fissure; I wish merely to submit a hypothesis and indicate what might happen if, in the human brain, the convolutions and sulci were to be so altered as to allow of the deposition of a fissure corresponding in length, depth, and position with the "Affenspalte."

In this event I venture to say that it would be surprising if all the occipital fissures, and the calcarine fissure in particular, did not undergo marked alterations in arrangement, and one could imagine that the sequence of events would be as follows. To supply a covering for the deep opercular posterior wall of the "Affenspalte," the external occipital convolutions would be drawn forward and absorbed, the posterior calcarine fissure, along with the fissura extrema of Seitz, would be pulled out on to the convexity of the hemisphere, the cuneo-lingual gyrus would share the change and be brought to the surface, and the general tension would impart a smooth and flattened appearance to the occipital lobe on its external face. In this way we should obtain a simian distribution of the calcarine type of cortex, and the flattened appearance which is so characteristic of the ape's cerebrum in this part.

The alternative suggestion, therefore, which I have to offer in explanation of the singular distribution of the calcarine type of cortex in the anthropoid cerebrum is, that the deep horizontal sulcus on the outer surface of the occipital lobe in the higher apes, and possibly in other varieties of simiadae, may represent the dislocated fissura calcarina posterior of the human brain.

To meet this hypothesis Cunningham's view that the human posterior calcarine fissure has no equivalent in the anthropoid brain, of course, must be discarded[1].

OCCIPITAL OR VISUO-PSYCHIC TYPE OF CORTEX.

I am attaching the designation "occipital" or "visuo-psychic" to a readily-defined field of cortex which immediately adjoins and almost surrounds the calcarine or visuo-sensory area. The term visuo-psychic is of course not of new coinage; it has been employed by many writers in contradistinction to the term visuo-sensory. The employment of such distinguishing terms is rendered necessary because the pathological, the experimental, and the anatomical and embryological researches which have been undertaken to determine the precise regions of the cortex in which visual sensations are centred and elaborated, afford grounds for believing that cortical visual representation is of twofold character; that it consists of a primary station in each hemisphere for the direct reception of impressions derived from homonymous halves of both retinal fields—a centre known by the name visuo-sensory and definitely proved to exist—and a secondary centre which probably serves for the further treatment of the rough impressions, a centre which is probably of psychic nature and hence has been called visuo-psychic. Although this centre, unlike the visuo-sensory, is doubtfully existent and doubtfully located, yet the distinctive histological structure of the field of cortex, which I am about to describe, strongly suggests that it possesses a special physiological function. Further, its close relation to the visuo-sensory or calcarine area, and other points to which I shall have occasion to refer, suggest in equal measure that it is the cortical centre for psychic visual representation; accordingly it seems justifiable in the meantime to apply to it the designation visuo-psychic.

[1] Since writing the above my attention has been directed to some papers on the "Occipital Region" by Elliot Smith, and as this writer's more important conclusions are drawn from facts of histology I embrace the opportunity of referring to his work. The main point at issue is the question of the possibility of identifying the "Affenspalte" in the Human Brain. Elliot Smith maintains that a study of the distribution of the cortex bearing a line of Gennari affords an infallible solution of this notoriously controversial problem. He states that in a considerable proportion of African and in some European human brains there exists on the lateral surface of the occipital lobe an indenture which he calls the "sulcus lunatus," and he holds that as the "calcarine" area or area striata bears the same relation to this indenture—stopping abruptly on its free edge—as the same area does to the "Affenspalte" in the ape, therefore the two fissures are homologous.

At first I was inclined to doubt whether the facts of histology could be reconciled with this view, but a further examination of the brains and casts in my collection and a reconsideration of the facts set forth in this research convinces me that Elliot Smith's contention, or, I should say, the histological basis on which it rests, is perfectly stable. If I read his work correctly a typical "sulcus lunatus" is to be located by its relation to the fissura extrema of Seitz, it will run parallel with that fissure and be the next indenture in the lateral direction; moreover, the line of Gennari will be seen to creep out of the fissura extrema and end on the free surface a few millimetres before the lunate indenture is reached. In short, using Bolton's anatomical terminology—and, by the way, it is surprising that Elliot Smith has overlooked this author's work—the "sulcus lunatus" will become an external polar sulcus, and in conjunction with Bolton's superior and inferior polar sulci will complete a lateral polar arc. Now on taking observations with these guides I think I have identified the sulcus lunatus in a considerable number of my specimens, and what is more to the point I am prepared to endorse all that Elliot Smith writes on the similarity of relationship of the area striata to this fissure and to the "Affenspalte," in man and the manlike ape, respectively. But here I must quit this subject, leaving it to others to comment on the instability of the sulcus lunatus and other points bearing on the homology under consideration. From the standpoint of functional localisation there is no question that the fissure to which the area striata stands fundamentally related is not the "Affenspalte" or its human equivalent, but the calcarine, therefore nothing which I have previously written calls for alteration. It is still correct to say that in the human brain, save the superior and inferior sulci of Bolton, there is no constant fissural boundary to the "calcarine" area on the lateral surface of the hemisphere.

TYPE OF ARRANGEMENT OF NERVE FIBRES.

In regard to fibre arrangement this field of cortex is distinguished by the following features. (Plate X, fig. 2, and text-figure 12.)

Zonal Layer.

The zonal layer is well-developed—better than in the calcarine region—and its lower margin is distinctly defined. Large medullated fibres are found only occasionally, but fibres of the coarse varicose type are present in abundance and account in large measure for the distinctness of the stratum. The remainder of the layer is composed of fine varicose fibres like those found in this layer in all other parts of the cortex.

Supraradiary Layer.

A moderately dense network of fine fibres occupies the whole of the supraradiary field. This network follows the usual rule in being of increased density in the part adjoining the line of Baillarger, and it is composed mainly of short, irregularly placed fibres. Fibres of medium size and of greater length are seen also; a few of these are placed vertically and may be regarded as fibres of Martinotti; others have a transverse direction, and in certain parts aggregate at a point midway between the surface and the line of Baillarger, so forming a line of Kaes. This formation, better seen in thick than in thin sections, is to be sought round the lips of sulci, for as the wall of the sulcus is descended the fibres composing the line seem to commingle with the more deeply situated association fibres, while in ascending, the linear formation loses in distinctness as the crest of the convolution is approached.

The fibre wealth of this layer is greater than it is in the calcarine area or in the adjoining parietal and temporal cortex.

Line of Baillarger.

The appearance presented by the line of Baillarger is not the least important feature of this type of cortex. Its breadth is great, greater than that of the corresponding line of Gennari in the calcarine area, its fibre wealth also is considerable; but instead of being sharply defined and compact like the calcarine line, it here tends to spread upwards and downwards into adjoining layers, hence its margins are blurred; furthermore, the absence of the underlying pallid zone, noted in the calcarine region, accentuates the indistinctness of its lower edge.

In constitution it resembles the calcarine line in being mainly composed of short fibres of delicate calibre, but it differs in containing many more long, transverse fibres of medium calibre.

Radiations of Meynert.

The projection bundles form prominent objects, and on analysing their constituents we find that in addition to ordinary fine wavy fibres each fasciculus contains one or more coarse evenly-medullated fibres, and it is to the presence of these large fibres that the fasciculi principally owe their distinctness. The bundles tend to pierce the line of Baillarger so as to reach the supraradiary layer.

Interradiary Plexus and Association Fibres.

The great fibre wealth of the whole radiary zone is perhaps the most noteworthy feature of this type of cortex. Not only are the delicate fibrils constituting the interradiary plexus proper numerous, but there is an extraordinary abundance of long association fibres which cross the radiations and interradiary spaces in every direction. These fibres have a preference for that part of the radiary zone which immediately adjoins the white substance, but at the same time they are to be found close up under the line of Baillarger, and even within that line, and as I have mentioned already the upper part of the radiary zone has not that pallid appearance which was observed in the calcarine region.

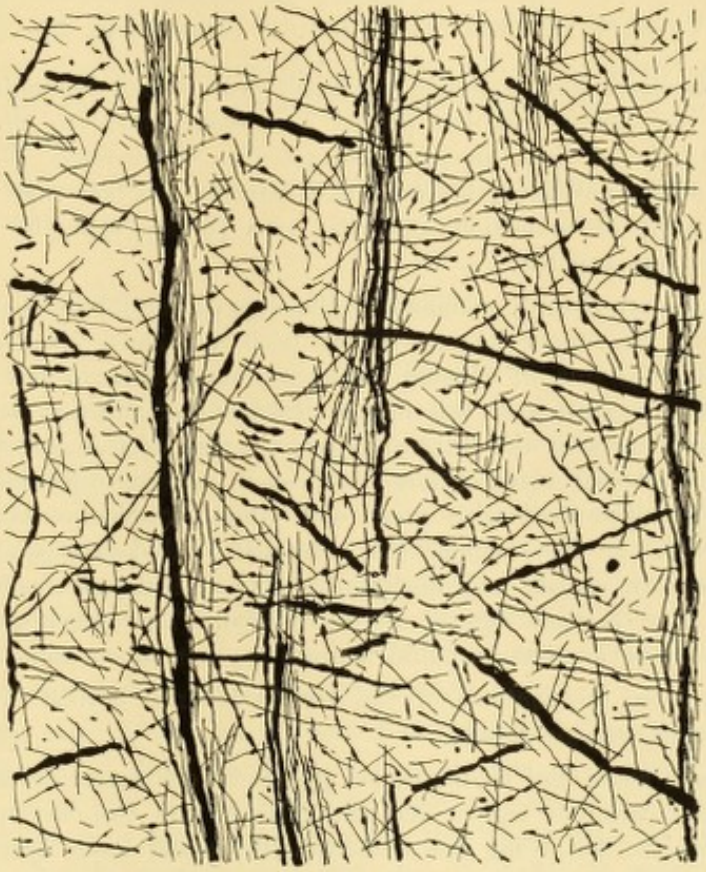

FIG. 12. Radiary zone in the occipital or visuo-psychic cortex. $\times \frac{425}{1}$.

The features of this cortex are best brought out by comparing it with that of surrounding parts, for instance the common temporal cortex (Plate XIII, fig. 3). Then the large medullated fibres, which are undoubtedly of great importance, and the general fibre richness will be noticed.

Comparing the calibre of these large association fibres with that of the fibres in the calcarine cortex, which we made special reference to under the name of the optic fibres of Ramón y Cajal, we find that the latter have a slight advantage in point of size.

White Projection.

When the white projection of the "visuo-psychic" cortex is compared with that of the coterminous parietal and temporal regions, it is noticed at once that the former presents an intensity of staining, which is a certain indication of an advantage in fibre wealth, and especially in fibres of large size; and, in thin specimens and in specimens in which the process of differentiation has been carried to excess, such fibres can be seen distinctly, spreading out in all directions and apparently running in connection with the optic radiations. From which it may be gathered that an inspection of serial sections of the substance of the occipital lobe offers strong reason for assuming that those fibres of the optic radiations, not specially destined for the calcarine region, come into relation with cells in the visuo-psychic cortex.

TYPE OF CELL LAMINATION. (Plate XI, fig. 2.)

As this field of cortex also possesses a distinct type of cell lamination, the examination of sections stained for nerve cells has proved a valuable check to the correctness of the topographic details gathered from an inspection of the nerve fibres, but before proceeding with the analysis of the individual layers, I will describe the behaviour of the visuo-sensory lamination at the point of transition into the visuo-psychic type, for it presents features as interesting as they are peculiar.

The change is almost entirely confined to the supra- and infra-stellate laminae and their contents. Taking first the upper lamina, it has been mentioned already that in great part this corresponds with the line of Gennari; also we have seen, in our sections stained for nerve fibres, an abrupt cessation of this line at the point of junction between the two types of cortex. Now coincident with the interruption of the line of Gennari there occurs a sudden disappearance of the external layer of large and small stellate cells, and the pallid lamina gives place to one richly-stocked with giant and other pyramidal cells, particulars of which will be presently given. In like manner the substellate pallid zone along with the layer of solitary cells of Meynert vanish, and medium-sized pyramidal and fusiform cells like those common to many other cortical regions are introduced. The closely-packed layer of small stellate cells interposed between these pallid laminae remains much as it was before.

We will now analyse the contents of the various laminae beyond the point of transition, *i.e.* in the visuo-psychic area, in detail.

The plexiform and small and medium-sized pyramidal cell layers are all appreciably deeper than they are in the calcarine region, and the cells in the two last-mentioned layers show a uniform increase in size, but being less numerous they stand wider apart from one another.

The most important layer in this area is unquestionably the external layer of large pyramidal cells. These cells do not occupy a stratum to themselves, because mixed with them are numerous medium-sized pyramids and some small stellate cells, nor is their number great, but at the same time ten or more may be seen in every low-power field of the microscope. In regard to size they must be included in the giant cell category, for they measure 25 by 30 μ, and are obviously larger than the solitary cells of Meynert in the calcarine area. They stand erect, have a long apical dendrite and a pyramidal or pyriform body, from the base of which two or three delicate processes project. The chromophilic particles recognisable are of large size, but are scattered about and do not fill the cell.

Unfortunately I am unable to give an account of the appearances presented by these cells in Golgi specimens, because Ramón y Cajal does not figure or describe them in his work and I have not been able to undertake the preparation of such specimens myself; their great size, however, and their limited distribution suggest that they are of functional importance. Their presence accounts in a large measure for the abundant plexus of large nerve fibres which I have described as an important character of this area, and there can be little doubt that they stand in relation to subjacent fibres pertaining to the optic radiations.

The layer of stellate cells is of like depth and contains elements similar in appearance to those noted in the same layer in the calcarine area.

It is difficult to divide the remainder of the cortex into layers; medium-sized pyramidal and ordinary fusiform cells are present in abundance, and the former preponderate in the outer and the latter in the inner part.

It is important to notice that with the exception of an occasional large cell, possibly a dislocated solitary cell of Meynert, no cells of large dimensions are to be found in the deeper layers of this cortex.

In conclusion I have to mention that the aggregate depth of this cortex is greater than that of the calcarine type.

DISTRIBUTION OF THE VISUO-PSYCHIC TYPE OF CORTEX. (Text-figure 11.)

Although this type of cortex has decided and distinctive characters in the central parts of the field the exact demarcation of its distribution is not accomplished without difficulty; first, because the disappearance of large fibres and the general transitional changes which the area undergoes at its borders are gradual instead of abrupt: especially is this the case where the field joins the parietal and temporal areas; and, secondly, because the occipital lobe is of such an awkward shape, that it is almost impossible to divide it into a series of sections, all of which will show the cortex cut at right angles to the plane surface and free from the damaging effect of obliquity. However, having examined so great a number of brains, and having followed different lines of section in different cases, I think I have arrived at a definition of the area which is more than approximately correct.

Starting with that part of the area situated on the mesial surface of the hemisphere, above the calcarine fissure, it is to be observed that it does not extend on to any part of the gyrus fornicatus, or of the precuneus, lying above the anterior division or stem of the fissure indicated; indeed, it is not found even on the upper wall of this portion of the fissure. Proceeding backwards, however, we find that it makes an appearance on the gyrus cunei (*i.e.* the deep cuneo-limbic annectant gyrus found at the point of junction of the parieto-occipital and calcarine fissures); and above this point the floor of the parieto-occipital fossa, not in its entire extent, but almost as far up as the margin of the hemisphere, may be described as a boundary. From which it follows, that all that portion of the cuneus which remains uncovered by a visuo-sensory type of cortex is occupied by a visuo-psychic type.

This distribution, however, does not obtain invariably, because in one of the brains which I examined a considerable extent of the surface of the cuneus, lying in the angle formed

by the margin of the hemisphere and the parieto-occipital fossa, was left uncovered, in fact it seems to be the rule for this type of cortex to recede from the parieto-occipital fossa in this situation. And, as a further consequence, when we inspect the margin of the hemisphere from the dorsal aspect, we find that the external prolongation of the parieto-occipital fossa lies in some cases anterior and in others posterior to the margin of the area, therefore, it also cannot be regarded as a fixed boundary.

Continuing our examination of the distribution of the area on the postero-lateral surface of the hemisphere, we find that the outer edge assumes the form of a curve, running more or less parallel with and at a distance of 1·4 to 2 cms. from the margin of the calcarine or visuo-sensory area.

To the visuo-sensory area, therefore, it bears a definite relation, but it cannot be said that its distribution in like manner is influenced or regulated, with any degree of constancy, by the fissures which cut up this portion of the occipital surface; thus, concerning its relation to the ramus occipitalis transversus of Ecker, anteriorly the area usually crosses the upper half of that sulcus and spreads for a varying extent over the convolution which is known by the name of the superior parieto-occipital annectant gyrus, while lower down the border does not reach so far forwards as the lower half of the same sulcus, accordingly the area does not touch the inferior parietal lobule. And concerning its relations to the lateral occipital sulcus of Eberstaller, when this sulcus is present in typical form, the line of demarcation merely cuts across its posterior extremity.

Coming lastly to the under surface of the hemisphere, we find that the boundary of the area still closely follows the visuo-sensory outline. Posteriorly it lies lateral to the hinder extremity of the collateral fissure, but it soon crosses this fissure and curves upwards to end in the stem of the calcarine fissure, at a point a few mm. anterior to the commencement of the visuo-sensory area; and here it may be noted, that although the visuo-psychic and hippocampal fields converge at this point, there is not the least difficulty in discriminating between the two types of cortex.

Summed up, therefore, the visuo-psychic area may be described as a zone of cortex from 1·3 to 2 cms. broad, investing the visuo-sensory area on all sides, that part above the stem of the calcarine fissure excepted.

STRUCTURE AND DISTRIBUTION OF THE VISUO-PSYCHIC CORTEX IN THE ANTHROPOID BRAIN. (Text-figure 11.)

It is unnecessary to enter into details concerning the structure of the visuo-psychic cortex in the anthropoid ape's brain, because here again we have a reproduction of the human arrangement. The subject can be dismissed with the statement that the grouping and formation of the elements follow the human plan, but on a reduced scale, and that the presence of an abundance of large fibres in the radiary zone again constitutes the most important guide in defining the area.

The distribution of the area, also, need not be discussed at length, because it, likewise, resembles the human arrangement in forming a border zone for the visuo-sensory area, also, because many of the topographical peculiarities which I referred to when discussing the anthropoid visuo-sensory field may be reapplied.

Inspection of the diagrams in figure 11 representing the extent of the area on the mesial and inferior surfaces of the brains of a chimpanzee and an orang, will show how closely the anthropoid resembles the human arrangement; over the cuneus and along the lower and anterior borders the agreement is exact; and again the visuo-psychic cortex, although it may just spread over the upper lip of the stem of the calcarine fissure, does not extend for any distance on to the free surface of the gyrus fornicatus.

On the lateral surface, this type of cortex closely embraces the visuo-sensory area, but its relative width is not so great as it is in the human brain. The anterior boundary, on account of its relation to the "Affenspalte," is the only limit which calls for special description. Now along the dorsal margin of the hemisphere, it must be observed that the area is found spreading on to the gyrus lying between the external prolongation of the parieto-occipital fossa and the upper extremity of the "Affenspalte," a gyrus which seems to be the equivalent of the human superior parieto-occipital annectant and which, in the case of the orang's hemisphere represented, is curiously elongated, on account of the wide projection of the parieto-occipital fossa. In thus spreading on to the superior parieto-occipital annectant gyrus the human arrangement is copied, but here the resemblance ceases, for instead of avoiding a definite and fixed relationship to named fissures, which we saw to be the case in the human being, the anthropoid visuo-psychic area is given a sharp and definite boundary in the great "Affenspalte." In all the three brains which I have submitted to examination I have been careful to cut my serial sections of this region in the sagittal direction, in order that the cortex coating the walls of the "Affenspalte" might be accurately studied; and in regard to the limits of the visuo-psychic type of cortex I have elicited the following points of interest. In the upper half of the "Affenspalte," that is, in the portion lying central to its junction with the ramus occipitalis of the intraparietal fissure, this type of cortex clothes both walls and exhibits an inclination to spread forward over the anterior lip of the fissure; but in the lower or external half of the fissure, it is found only on the posterior wall and does not reach to the floor.

The lower or temporal division of the area presents no features of special importance, it is not related to any fissures in particular and simply forms a skirt to the visuo-sensory field.

THE FUNCTIONS OF THE CALCARINE OR VISUO-SENSORY AND THE OCCIPITAL OR VISUO-PSYCHIC FIELDS OF CORTEX.

In the preceding pages, a detailed account of two types of cortical structure to be found in the occipital lobe of both the human being and the anthropoid ape has been given, also the exact limits and extent of the fields covered by these types of cortex have been described, and since there is an abundance of experimental and clinical evidence to prove that the visual function is localised in the occipital lobe, more especially in the region of the calcarine fissure, it now remains for us to review this evidence with the object of determining whether the areas, which I have mapped out on histological grounds, represent the exact topography of the centres where visual sensations are received and interpreted.

For the sake of clearness, it will be advisable to consider the work which has been done on visual localisation under three different headings, viz. (1) the experimental, (2) the

clinical and pathological, and (3) the embryological and anatomical, and here let me say that there is such a wealth of literature on this subject that a complete retrospect is out of the question. Of many articles I have been able to procure only an epitomised account, and I fear that some which may have appeared in the lesser known journals have escaped notice altogether.

A. *The Experimental Evidence.*

Much as we are indebted to experimental methods in helping us to advance our knowledge of the topographical distribution of the cortical visual area, it is fairly obvious that even the most ardent experimenter will refuse to maintain that the means which have been employed hitherto, namely, ablation or destruction of given portions of the brain, can possibly lead to a precise and exact definition of the area. The discrepancies, contradictions, and want of accordance concerning the limits of the area, which appear in the accounts presented by different experimenters, are sufficient proof of the dangerous inaccuracy of ablation methods in determining the mere outside limits of the field; and if, as we have reason for supposing is the case, the cortical visual area be divisible into districts, each having a distinct function to perform, how much more hopeless it is for us to expect to receive much assistance from experiment by ablation in effecting a territorial subdivision of the area! The obstacles which confront the experimenter are to a large extent anatomical in kind; if, for example, a removal of the field of cortex, bearing what I have called a calcarine type of structure, were decided upon, and even supposing the operator to be perfectly familiar with the anatomical distribution of that cortex, it would still be quite impossible for him to ablate it without the contaminating influence of injury to extraneous and contiguous structures. Thus, how is the cortex from the stem of the calcarine fissure to be removed, first, without occlusion of the branch of the posterior cerebral artery running therein and carrying the blood supply, not only to the convolutions forming the calcarine walls, but also to those on both sides of the parieto-occipital fissure? and secondly, without opening into the posterior horn of the lateral ventricle? And how, also, in the destruction of any part of the visual cortex, is it possible to avoid injury to subjacent strands of fibres, which may have an important physiological significance and yet not be connected with the part which is being operated upon? In addition to these difficulties, serious enough in themselves, it is to be remembered that such experiments have to be carried out on the lower animals, and that even in the most intelligent and suitable species it is almost impossible to conduct the psychical analysis which is necessary before the visual condition subsequent to operation can be interpreted, and a decision arrived at as to whether the resulting disturbance is due to a primary blunting of the sensations or to some secondary failure in their psychical appreciation.

The foregoing considerations indicate what extreme caution must be exercised in drawing conclusions from experiments alone, and unfortunately the same considerations apply to all operations dealing with sensory areas. However, although our knowledge of cerebral localisation has advanced to such an extent that we are now able to pick holes in the observations of earlier experimental workers, we never shall forget that the labours of these pioneers in an extremely difficult branch of research have served as a guiding light, leading our knowledge of cortical localisation to its present state.

Now since accounts of the recorded experiments on the cortical localisation of vision cover familiar pages of all text-books of neurology, it will be unnecessary for me to discuss them at any length. Suffice it to say that while Hitzig is to be credited with first having indicated the probability of the existence of the visual centre in the hinder part of the cerebrum, Munk was the first to attempt to locate it by experiment. The majority of Munk's operations were performed on dogs, but he also employed some monkeys; and the conclusions he arrived at concerning the location of the visual sense in the occipital lobe were either wholly or partially substantiated by Schäfer, Horsley, Vitzou, Sanger-Brown, and other observers who repeated his experiments. One point gathered from these experiments has a special bearing on the present research. It is that, in the case of the ape, Munk and Schäfer agree in stating that, in order to produce blindness, it is necessary to extend the field of ablation on to the lateral surface of the hemisphere and as far forward as the "Affenspalte." This statement is of particular interest to me, because it agrees with my statement that, in the anthropoid, the type of cortex to which I have assigned visual characters has a similarly wide distribution, and on looking through the literature for confirmation of this anatomical truth, I find that Schlapp, in the case of the lower apes, has subdivided the cerebral cortex into three types, the posterior of which corresponds approximately with Munk and Schäfer's field, and his observations coupled with mine must be accepted as very strong proof of the accuracy of the broad results of these particular experiments.

Ferrier, whose researches are so well known in this country, combatted Munk's views and extended the visual area to the angular gyrus, and in doing so received support from Lannegrace, but now it is believed almost universally that the blindness which Ferrier produced by destruction of the angular gyrus was due to severance of or interference with the occipito-thalamic fibres which underlie this region and which are bound to suffer in such an ablation. In like manner the temporary interference with vision recorded by Goltz and Hitzig, after ablation of the frontal lobe in dogs, is more reasonably ascribed to accidental disturbance of the vascular apparatus of the optic nerve, or of the primary visual centres, than to a direct association between the frontal lobes and the visual sense; although it is to be remembered in this connection that Sherrington and Grünbaum figure a somewhat extensive area on the lateral surface of the frontal lobes of the higher apes, faradisation of which yielded conjugate movements of the eyeballs, an area spatially separated from the Rolandic "motor" area by a field of inexcitable cortex.

And concerning the effects of cortical stimulation, it is further to be observed that movements of the eyeballs attend faradisation of other parts of the cortex; thus Ferrier obtained lateral movements of the eye (and also of the head?) towards the opposite side by stimulation of the angular gyrus. Schäfer produced associated movements of the eyes from stimulation of all parts of the occipital lobe, viz., movements downward and to the opposite side from the upper part, upward movements from the posterior part, and pure lateral movements from the middle part. In reference to the last-mentioned result, it is to be noted that Munk and Obregia obtained fixation of the eyes in the middle line, plus slight convergence, by stimulation of the corresponding area.

Gerwer writing in 1899 states that, in the ape, eye movements are obtainable by stimulation of three areas, the posterior portion of the frontal lobe, the occipital lobe, and the angular gyrus; and that while extirpation of the first-named area is followed by lateral

deviation of the eye and paralysis of lateral movements, no paralysis attends destructive interference with the other areas. Accordingly he looks upon these excitation eye movements, those obtainable from stimulation of the frontal lobe excepted, as reflex.

Sherrington and Grünbaum, in their experiments on the higher apes, did not find that the angular gyrus responded in any way to electrical excitation; and with regard to the occipital lobe, it was only at the extreme posterior apex and along the calcarine region that faradisation yielded any result, and then not easily.

Interesting as it undoubtedly is that electrical stimulation of different parts should excite such ocular movements, the value of the observations from the localisation standpoint is admittedly doubtful.

Having determined within rough limits the topography of the visual area in the occipital lobe, experimenters next devoted themselves to the elucidation of other points bearing upon the subject; in this way, the correlation between various parts of the retina and various districts of the visual area, the possible amount of recovery of function after occipital ablations, and the degree of blindness resulting from operative interference in turn received attention, but as might have been expected, on none of these points has unanimity been arrived at.

Regarding the question of definite retinal localisation in the occipital lobe, it seems patent when three authorities such as Munk, Schäfer, and von Monakow all uphold different views, that the subject must be hedged in with difficulty, and that a solution is hardly to be expected from experimental observation; hence I can gain nothing by pursuing the question here.

In the next place, concerning the question of the degree of blindness which has attended operations on the area of cortex in the occipital region which is believed to stand in relation to the visual function; the first general result of such operations to be mentioned is the well-known truth that destruction of that area on one side gives rise to crossed hemianopsia. In like manner, extension of the destructive process to both occipital lobes apparently results in total blindness, at least that is the view held by Munk, Schäfer, and most experimenters, for it must be mentioned that the totality of the blindness is denied by Goltz, who believes that a monkey or a dog deprived of its cortical visual area still can orientate its position in space, to a certain extent, by means of the retina. But it is a question whether the slight amount of vision which may remain in such cases is not due to the unimpaired activity of what German writers call the "primary optic centres," viz., the corpora quadrigemina anteriora vel colliculi superiores, the corpora geniculata lateralia, and the pulvinaria. Concerning these centres, there exists an abundance of anatomical and pathological evidence—to some of which I shall have occasion to refer later—proving that they stand in the closest relation with the optic nerves, and from the phylogenetic point of view it is interesting to recall the facts emphasised by Edinger and others, that in forms low in the animal scale, such as fishes, the corpora quadrigemina or optic lobes are the chief visual organs, sight not being represented in the cerebral cortex. But in higher animals, the external geniculate bodies and pulvinaria progressively assume the upper hand over the quadrigeminal bodies and act as way-stations in the visual track from the retina to the occipital cortex. And the deduction follows that certainly in the frog and pigeon, animals which when completely decerebrated still show signs of being able to see, probably in the rabbit, cat, dog, and ape, and possibly in man, any trace of the power of vision

which remains after destruction of the occipital lobes is attributable to the activity of these subcortical centres. But be it noted, in man and in the higher animals, the pulvinaria and external geniculate bodies are much more important than the anterior corpora quadrigemina, for while injury to the former produces marked effects, the latter bodies have been destroyed without any resulting impairment of light or colour vision.

The question of the restitution of vision after removal of the occipital cortex is one to which the older experimenters gave much attention, and recently the point has been revived by Vitzou, who reports an extraordinary case in a young ape, in which a complete (?) removal of the occipital lobes resulted in total blindness. This blindness, however, began to pass off at the end of a few months, and at the end of two years and two months vision was apparently restored. Operating again he found the gap filled up with what he took to be nervous tissue, and on removing this he finally rendered the animal permanently and totally blind. To explain this remarkable case Vitzou resorts to the regeneration or rather the neoformation hypothesis, but it seems more probable, as Bolton suggests, that at the primary operation the anterior parts of the visual area, which extend forward in advance of the splenium of the corpus callosum, were left intact and afforded the animal a certain amount of visual power.

Having alluded briefly to these side-issues in the cortical representation of vision, we may sum up the situation by saying, that experimentation on the ape, dog, and other animals proves that there exists in the occipital lobe a field of cortex removal of which is followed by blindness, but that a definition of the exact limits of this area is beyond the scope of the experimenter.

B. *The Clinical and Pathological Evidence.*

Taking another view of the subject we have now to ascertain in what respects the clinical can be brought into line with the experimental evidence, to what extent clinical cases have assisted us to arrive at a precise orientation of the cortical visual area in the human brain, and how far they warrant a subdivision of the area.

Considering that well over 200 cases of cortical or subcortical hemianopsia, in which the diagnosis has been verified by post-mortem examination, have been recorded in the literature since Chaillou published his first case, in 1863, and that in spite of this accumulation of knowledge, not only are many pathological disorders of vision far from being understood clearly, but also the very confines of the area concerned with sight are not yet decided, we may take it for granted, first, that the processes concerned with vision in the human subject are of inconceivable complexity, and secondly, that natural lesions are no better adapted than experimental for the exact determination of the limits of the area.

The chief reason why a study of lesions in the human brain cannot be productive of results which will lead to an accurate determination of topographic distribution again turns on anatomy. Of course the cases studied in this connection have been cases of cerebral softening, tumour, haemorrhage, or abscess, and of these, cases of cerebral softening have constituted by far the majority. Now when we examine the blood supply of the convolutions on the inner and posterior surfaces of the occipital lobe, we soon discover reasons why cases of arterial thrombosis or embolism should be inadequate for purposes of exact cortical localisation; we find that all these convolutions are supplied by branches derived from one common trunk, the occipital artery of Duret, which in its turn springs from the

posterior cerebral artery[1], but neither the distribution of the whole of this vessel nor of any given branch or branches exactly corresponds to the distribution of what we believe to be the visual area. In other words, when the occipital artery is occluded by thrombosis or embolism, other parts in addition to the visual cortex are obliterated; not only this, but when the same artery or any of its branches, and particularly the calcarine branch, is occluded, incalculable damage is done to the occipito-thalamic and other fibres radiating to all parts of the occipital cortex. The truth of this is emphasised by von Monakow, and is illustrated fully by a number of specimens which I have collected from patients who have died at Rainhill. Accordingly we are forced to conclude that the lesions produced by arterial occlusion, cerebral tumour, abscess formation, haemorrhage, or by any other destructive agent, are of too gross a nature to allow of precise localisation, and the corollary follows that as the result of a natural process we can never hope to obtain an example of an obliterative destruction confined exactly to the visual area and involving the cortex only, for such a lesion is an anatomical impossibility.

Although faced by such difficulties it is gratifying to find that, as the number of reported cases increases and positive and negative evidence is accumulated and carefully assimilated, the limitations of the area become gradually more restricted and definite, and so experimental, clinical, and anatomical differences progressively diminish.

Attempting a brief summary of the data adduced from the clinico-pathological side, we find that there is considerable agreement in opinion on the point that a lasting hemianopic condition is produced most readily by a lesion in the neighbourhood of the calcarine fissure; thus Henschen, basing his conclusions on forty cases of hemianopsia collected in Upsala, states that a lesion involving the cortex of the calcarine fissure—particularly of its anterior two-thirds—alone will suffice to bring about lasting hemianopsia, and that the remainder of the occipital lobe is of no consequence in so far as the production of such a visual defect is concerned.

Huguenin, who wrote before Henschen, also confined the visual area within similar narrow limits, but apparently attached more importance to the posterior than the anterior calcarine cortex.

Hun published an important case in which destruction of the cuneus bordering on the calcarine fissure produced a hemianopic defect limited to the upper right quadrant of each retina, and accepting this as a direct example of cause and effect, he assumed that the fibres from the lower right quadrant must proceed to the cortex of the lingual lobule, immediately underlying the posterior limb of the calcarine fissure.

Cases of bilateral hemianopsia seem to be decidedly uncommon, and apparently only five are to be found in the literature (Förster, Berger, Schweigger, Kaesterman, von Monakow

[1] Figures correctly indicating the occipital distribution of the posterior cerebral artery are given in von Monakow's admirable text-book and in Bolton's paper, and further injections and dissections carried out by Doctor H. A. Robinson and myself show that there is nothing to add to the description given by the observers named. Like all other arteries these are subject to variations and irregularities, but the following may be looked upon as the commonest arrangement: after giving off an ascending twig to the splenium and a descending twig to the lingual lobule the occipital artery (Duret) dips down into the stem of the calcarine fissure and divides into two branches, which have received the names parieto-occipital and calcarine respectively. The former ascends the fissure after which it is named; it gives off, first, a twig called the cuneal for the supply of the cuneus, secondly, twigs for the bounding convolutions of the fissure, and, finally, it ends by ramifying on the convexity of the hemisphere. The calcarine artery follows the calcarine fissure, supplying both its walls and ending on the posterior surface of the occipital lobe.

two). The case recorded by Förster bears signs of thorough investigation and has been quoted frequently. The destruction was of course bilateral, approximately symmetrical and chiefly confined to the mesial surface of the occipital lobe. Microscopic examination of serial sections showed that all the bands of fibres lying internal to and below the lateral ventricle, including the inferior longitudinal bundle, were destroyed. A small portion of the apex of the cuneus and the cortex surrounding the hinder end of the calcarine fissure were left intact.

In criticising this case von Monakow says that the most remarkable clinical feature was, that in spite of the bilateral destruction of the mesially placed occipital convolutions, central vision was retained; and he makes full use of the case to substantiate a view which he promulgates with some emphasis, viz., that there exists no part of the occipital cortex, and possibly none of the cortex of the angular gyrus, with which the macula lutea is unconnected. In other words, the macular field extends widely beyond the limits of the generally accepted visual cortical area. But I cannot help thinking that von Monakow is much too generous in regard to the reliance which he places on the case quoted, and that more evidence is needed before we can consider this particular matter settled. And yet, other observers who have worked at this subject do not enclose the visual area within our narrow limits, although they include the calcarine cortex within their field. For instance Seguin, who analysed 40 cases, in all of which, be it noted, the lesion was in the region of the fissura calcarina, roughly locates the visual centre on the inner surface of the occipital lobe. Starr, from an examination of 27 cases, concludes that clinico-pathological material does not allow of exact localisation, since a destructive lesion on either the inner or the outer surface of the occipital lobe may occasion hemianopia. Vialet, who has contributed useful papers on the cerebral centres of vision, containing accounts of eight cases all fully worked out, assigns the following limits to the area, the parieto-occipital fissure in front, the margin of the hemisphere above and behind, the inferior border of the third occipital convolution below; in other words, his field embraces the whole of the cuneus and the subjacent parts of the lingual and fusiform lobules.

Other writers extend the visual area on to the external occipital gyri, and even as far as the angular gyrus, after the doctrine of Ferrier; and finally von Monakow, whose clinico-pathological studies entitle him to first place amongst continental authorities on cerebral localisation, and particularly on visual localisation, sums up the question in the following words[1]: "Die Frage nach der wirklichen Ausdehnung der menschlichen Sehsphäre lässt sich durch klinische Beobachtungen mit nachfolgendem Sectionsbefund allein nicht lösen, dies einerseits wegen Circulationsverhältnisse, anderseits wegen der Möglichkeit, neue Bahnen in dienst zu stellen (Moment der Restitution). Aber gerade die Erfahrungen hinsichtlich des letzterwähnten Punktes, sowie hinsichtlich des Freibleibens der Macula selbst bei doppelseitigem Ausfall beider Hinterhauptslappen in engeren Sinne, endlich die Resultate des Studiums secundärer Veränderungen sprechen mit Nothwendigkeit dafür, dass die Sehsphäre ausser der gesammten Rinde der eigentlichen Occipitalwindungen (Cuneus, Lobus lingualis, Gyrus descendens, $O._1$—$O._3$) mindestens noch die hintere Partie des Gyr. angul. in sich schliesst."

[1] "Clinical observations with subsequent autopsies cannot alone decide the question of the real extent of the human visual area, on account of peculiarities in its blood-supply on the one hand, and on account of the possibility of new tracts being brought into operation on the other. But the evidence concerning the last-mentioned point, along with that showing that the macula remains intact even after bilateral destruction of the occipital lobes in the narrow sense, and finally the results of the study of secondary changes, necessarily suggest, that the visual area occupies, in addition to the entire cortex of the individual occipital gyri (Cuneus, Lobus Lingualis, Gyrus Descendens, Occ. 1—Occ. 3), at least the hinder part of the gyrus angularis." *Gehirnpathologie*, p. 468.

Next we have to analyse the literature with the view of ascertaining to what extent other varieties of visual disturbance, well known to the clinical observer, can be placed on an anatomical basis, and whether data exist to justify a corresponding subdivision of the visual area. The list of disorders includes such conditions as psychic blindness, alexia, optic aphasia, colour blindness, stereoscopic vision, etc., and of these psychic blindness first demands consideration.

Psychic Blindness.

Psychic blindness or "Seelenblindheit" is a name for which, of course, we are indebted to Munk, and which arose out of his experiments on the lower animals. In defining the condition I cannot do better than quote the appearances presented by one of Munk's dogs, "while the animal exhibited no abnormalities regarding the functions of hearing, smell, taste, motion, and sensation, and was able to move about a room without colliding with any of the objects therein, it yet showed pronounced impairment of the visual sense and this defect was of a psychic nature. Thus, even when the dog was hungry and thirsty it would pass food and water unnoticed; it snapped at morsels of meat only when it smelt them; to everything which it saw it was indifferent; threatening movements with a whip did not disturb it, a bright light brought close to its eyes did not cause it to wink, and the presence of its master and of other dogs created no impression." This condition resulted when circular portions, 1½ cm. in diameter, were removed from the centre of Munk's visual area, in both hemispheres; it did not last more than four or five weeks, and was accompanied by central blindness.

Now, in man, numerous instances of precisely similar, psychic visual disturbance have been observed, but its degree has varied; it has been represented by some increased difficulty of orientation in space, by some diminution of the perceptive faculty, by a certain inability to read, or, finally, by a complete failure to recognise and interpret any objects seen; and the question we have to consider is, what is the necessary situation for the lesion which will produce these phenomena? Now, in spite of the fact that over 30 cases followed by a post-mortem have been reported, we cannot yet say that the cortex which dominates these specialised psychic processes is definitely localised. I have mentioned already, however, that a destructive process confined to the calcarine cortex is probably sufficient to induce simple unmodified blindness, and it appears that for the production of the superadded psychic element it is only necessary that the destruction shall be distributed more widely.

Von Monakow, who has made a special study of the recorded instances of mind blindness, insists strongly on the necessity for this widespread lesion, pointing out that the further the destruction advances into the white substance of the parieto-occipital lobe, the more are long tracts of association fibres involved and connections with other cortical centres interrupted. And in support of this statement, we find in the majority of recorded cases that the lesion has been deep-seated and that it has involved, not only the occipito-thalamic radiations proceeding to the calcarine region, but also other association bands of fibres, to which we shall have occasion to refer when we discuss some anatomical details bearing on visual localisation. And unlike the lesions in cases of uncomplicated cortical blindness, we find here that the destruction frequently has been asymmetrical, and a further point of importance is that a deep lesion in the left occipital lobe seems more likely to bring psychic defects in its train than one affecting the right.

Alexia.

The next variety of psychical visual defect to which I shall refer has been described by Kussmaul as "Wortblindheit," by Dejerine as "Cécité verbale pure," by Wernicke as "subcortical alexia," and by others simply as "alexia"; the condition is one which has been widely recognised, and, briefly defined, it consists of an inability to comprehend written or printed language, although the letters may be clearly seen and vision generally may be unimpaired.

Clinically, many degrees and varieties of this affection may appear, but fortunately there is almost unanimous agreement concerning its pathological anatomy. In ten or more cases which have been carefully examined (those of Monakow, Redlich, Verrey, etc.) the surface lesion has been confined to the region of the left angular gyrus and the second occipital convolution, and usually has spread sufficiently deeply into the underlying white substance to include the fasciculus longitudinalis inferior, an important band of fibres the connections of which we shall have to mention presently. And although, in some instances, other bands, viz., the fasciculus longitudinalis superior, the occipito-thalamic radiations of Gratiolet, the forceps major, and in a few cases fibres pertaining to the splenium of the corpus callosum have been involved, the stress of the injury seems always to have fallen on the band first alluded to. Also it is becoming an established doctrine that destruction of the cortex in the region of the angular gyrus by itself, or of the fasciculus longitudinalis inferior by itself, is insufficient to produce alexia; the two must go together, and for the production of the clinical manifestation long and short systems of association fibres necessarily must be destroyed.

Colour Blindness.

A few cases have been recorded in which colour blindness, or more correctly speaking hemi-achromatopsia, has followed a circumscribed lesion in the occipital lobe, and in three of these, published by Henschen, Verrey, and Dejerine, the destruction has been confined, more or less, to the hinder end of the lingual lobule: hence it seems likely that the cortex in this situation is associated with colour perception. At the same time we must be cautious in arriving at any definite conclusion on this point, because in all these cases the inability to recognise colours has been complicated by hemiopia, or other visual defect.

Optic Aphasia.

Optic aphasia is another variety of mind blindness and was described first by Freund. An individual so affected, in spite of unimpaired vision and intellectual faculty, and notwithstanding that he may recognise objects presented to his vision, is yet unable to give them their correct name without calling into play other senses, such as that of touch.

From the few cases that have been published we gather that the lesion underlying this condition is to be sought in the white substance of the left occipital lobe, but pure cases, that is, cases uncomplicated by other visual defect, are evidently uncommon.

C. *The Anatomical and Embryological Evidence.*

When the anatomical evidence which we have now collected is given full consideration, I think it will be granted that this is the only path by which we may hope finally to

arrive at the precise localisation of the visual centre, of course provided that full and due regard be paid to the rough guides afforded by the previous findings of the physiologist and the clinician.

The anatomical researches which have been undertaken with the view of determining the position of the visual area may be divided into three categories; first, those dealing with the degenerative changes which result from experimental interference with the visual apparatus; secondly, those in which the course of the various tracts of fibres bearing visual impulses have been studied by the developmental method; and, lastly, those in which the human brain has been examined, to display degenerative changes in cases of old-standing blindness, to determine the normal histological appearances of the area believed to be concerned with sight, or to fix the course and distribution of bands of visual neurones.

It cannot be said that the anatomical observations recorded some years ago by von Monakow have assisted in lending preciseness to the definition of the visual area, but at the same time they have no mean value, because they clinched the accuracy of Munk's statement that the visual sense was centred in the occipital lobe, and they gave us much information concerning the path followed by visual impulses in their course from retina to cortex. Thus his enucleations of the eyes of new-born puppies with the subsequent discovery of degenerative alterations in the corpora geniculata externa, the pulvinaria, and the anterior corpora quadrigemina were valuable in proving that the cells in these nuclei formed units of an intermediate station in the visual pathway; the evidence which he produced to the effect that the same nuclei underwent secondary degeneration in consequence of ablation of the cortical visual area was of importance, inasmuch as it definitely settled the point that the occipital cortex presided over vision; and it is of even greater interest that von Monakow was able to prove that the human brain resembled that of the lower animal, inasmuch as lesions of the occipital cortex in the calcarine region produced a similar degeneration of the cells of the lateral geniculate body. Further, from von Monakow's studies it would appear that the cells of the lateral geniculate bodies serve different functions and therefore are divisible into two categories; for he has proved clearly that the changes which occur in those bodies after a cortical lesion affect different parts from those involved in disease of or injury to the optic nerve. In the former case, it is the ganglion cells of the lateral geniculate body and the white matter of Wernicke which suffer, while in the latter, it is the fibres of the optic tract and their terminals in the substantia gelatinosa which disappear.

Other experimental researches having a similar bearing, and also some purely histological observations on the lower animals have been put on record, but I think it unnecessary to discuss them here, because the morphological differences between the brain of any lower animal and that of man in large measure nullify their value as guides to cortical localisation in the human subject.

We have next to indicate the extent to which developmental researches have added to our knowledge of visual localisation, and I would state at once that although I have little personal experience of this method, yet, when the area to be mapped out contains medullated fibres of large calibre, as does the visual field, it appears to be well-suited for purposes of surface delimitation. For example, if figures 7 and 8, plate IV, in Flechsig's *Gehirn und Seele* be compared with my figures, a remarkable correspondence will be seen; his closely-dotted calcarine area agreeing well with my visuo-sensory area, and his more

openly dotted field being not unlike my visuo-psychic area. And apart from the value of developmental methods in determining surface areas, a glance at Flechsig's illustrations, and at the beautiful reproductions in Vogt's recently published work, suffices to show that this method has no equal in giving a demonstration of the subcortical bands of fibres running in connection with the surface field. As a guide to cortical localisation a clear display of these subcortical bands is of extreme value, and of the highest importance is the fact that developmental studies have supplied one of the strongest links in the chain of evidence which we can now adduce in support of the limited sensory localisation in the calcarine region. I refer to the appearances presented by the radiations of Gratiolet. Preparations of the foetal brain stained for medullated nerve fibres conclusively prove that, at birth, only a portion of these radiating fibres have acquired their myelinic investment, namely, those related to the lateral geniculate bodies; all the other fibres of Gratiolet's radiation remain unmedullated, and this early-medullated band of fibres can be distinctly followed to that part of the occipital cortex which coats the calcarine fissure. Flechsig, who was the first to describe this band, speaks of it as "the optic radiation in the narrow sense," in contradistinction to the remaining fibres of Gratiolet which he calls "the optic radiation in the wider sense," and which he regards as corticifugal instead of corticipetal in direction. It seems that this band of fibres (the optic radiation in the narrow sense) was that along which von Monakow traced acute degeneration after lesions in the occipital cortex in man, and it is evidently of important functional significance, since it constitutes a direct line of communication between the calcarine cortex and the lateral geniculate bodies.

Of the remaining fibres of the radiation of Gratiolet (Flechsig's radiations in the wider sense) we do not possess such definite information, but apparently the majority originate in the pulvinar, and at first occupying a position dorsal to those derived from the lateral geniculate bodies, are distributed ultimately to the occipital cortex outside the calcarine region.

Of the function of other bands of nerve fibres discoverable in the white substance of this region, some of which are autochthonous and may serve to bring different gyri of the occipital lobe into association with one another, while others seem to connect the occipital gyri with parts of the brain lying further afield, our knowledge is still less certain. But as their anatomical position is more or less definite, a short description of them will be necessary to complete this section.

Taking first the autochthonous bands, or as Barker calls them, the short association neurones. These bands correspond with the fibrae arcuatae of Arnold and the U-shaped fibres of Meynert, and the following systems have been identified in the occipital lobe.

(1) The stratum calcarinum is figured and described by Dejerine and Sachs as curving round the floor of the calcarine fissure, for the purpose of uniting the cortex of the convolutions lying immediately above and below that fissure. But while the appearance of a band in this situation is undeniable, and while some of the fibres are undoubtedly of associative nature, I cannot help thinking that the appearance is due mainly to the presence of the terminal portions of the calcarine division of the optic radiations arching up to the cortex.

(2) The stratum proprium cunei is a bundle recognised by Sachs as consisting of vertical fibres issuing from the upper wall of the calcarine fissure and spreading up in the cuneus in radiate fashion to terminate along the margin of the hemisphere, and viewed

in the light of my researches on cortical structure it seems likely that these fibres bring into relation the visuo-sensory and visuo-psychic areas.

A similar function might be ascribed to (3) the fasciculus occipitalis transversus cunei of Dejerine, and (4) the fasciculus occipitalis transversus gyri longitudinalis of Vialet and Sachs, which seem to connect the cortex of the upper and lower lips of the calcarine fissure respectively, with that of more outlying fields of the occipital cortex.

(5) The fasciculus occipitalis verticalis or perpendicularis of Wernicke—stratum proprium convexitatis of Sachs—lies beneath the cortex on the lateral surface of the lobe, and is said to unite the gyri above with those below, but as a matter of fact the definition of this band is difficult, and we cannot attach much importance to it.

Passing next to the long association neurones, three bands call for special mention, the fasciculus longitudinalis superior, the fasciculus longitudinalis inferior, and the tapetum.

1. The fasciculus longitudinalis superior—fasciculus arcuatus of Burdach—is a bundle of fibres lying lateral to and above the other long occipital bundles, which, according to Dejerine and others who have attempted to trace it, connects the occipital with the frontal lobe; but as in its course forwards it is constantly giving off and receiving fibres and at the same time is a difficult bundle to follow, it is impossible to make any positive declaration about its associations and functions; I may mention, however, that it is supposed to make connections with the auditory area in the temporal and with the motor speech-centre (Broca's convolution) in the frontal lobe.

2. The fasciculus longitudinalis inferior—stratum sagittale externum (Sachs)—faisceau sensitif (Charcot)—constitutes a uniting band between the occipital and temporal lobes. Running in a sagittal direction, it lies lateral to the optic radiations, and in the first part of its course is a massive and well-differentiated bundle, but more anteriorly its fibres become confused with those emerging from the internal geniculate bodies, and with others in the thalamic region. However, it is the general belief that the majority of its fibres terminate in the temporal lobe, particularly in the first temporal convolution; it is an equally general assumption that it constitutes the main path of association between the visual and auditory areas, and that its destruction lies at the bottom of that variety of mind blindness which we have referred to under the name alexia. But here let me say that Flechsig dissents from the general belief, contending that the bundle consists of projection and not association fibres.

3. Opinions seem to be divided concerning the tapetum. For long it was regarded as a part of the radiation of the corpus callosum, but since it has been found to be perfectly preserved in cases of congenital absence of this body, that view has to a large extent fallen to the ground, and Fovel, who has given one of the best reports of a case of this deformity to be found in the literature, thinks that the tapetum pertains to the fasciculus longitudinalis superior. Dejerine, on the other hand, to whom we must pay respect as an authority in this province of cerebral anatomy, considers that the tapetum is a perfectly independent sagittal fasciculus, pertaining neither to the corpus callosum nor to the fasciculus longitudinalis superior, but arising from the cortex of the frontal lobe, and after passing through the corona radiata, being distributed over the lateral surface and inferior border of the occipital lobe. Having these views concerning its origin, course, and destination, Dejerine reasonably prefers to call it the fasciculus occipito-frontalis.

Taken altogether there can be little doubt that these long tracts play an important part as adjuvants in the elaboration and interpretation of visual impulses received by the occipital lobe.

We will pass on now to those observations which have aimed at the localisation of the visual area in the human brain from the purely histological point of view, and under this heading the research which first calls for notice is that published by Dr Bolton.

Examining in serial sections the occipital lobes of the brains of five cases of old-standing total blindness and one of anophthalmos, and using as a criterion the atrophy and disappearance of certain nerve cell and fibre elements, Dr Bolton was able to map out with the greatest distinctness an area which corresponds in all important respects with that which clinico-pathological, developmental, and experimental researches have indicated as the visuo-sensory area.

Stated briefly, the histological alterations which served him as a restrictive guide, were a diminution in thickness of the line of Gennari by almost 50 per cent. and of the outer granule layer of nerve cells by almost 10 per cent.[1], and I can personally testify to the extreme thoroughness of his work, because his observations were begun in the laboratory over which I have control, and as he progressed I had numerous opportunities of seeing his preparations and of judging his methods of investigation.

It will be unnecessary for me to describe the limits of the area defined by Dr Bolton, for, on referring to his diagrams and descriptions, it may be found that if I did so, I should merely reiterate what I have said already regarding the limits of my visuo-sensory area; but as we agree that the area over which the line of Gennari is distributed represents the cortical visuo-sensory centre, it obviously follows that it is unnecessary to resort to pathological material for a definition of the field, and as a matter of fact it can be determined in a normal brain even without the aid of a microscope.

It is to be regretted that Dr Bolton did not add to his research the examination of a brain from a case in which the blindness had not been of such long-standing, for manifestly the gross alterations which he has noted partake of the nature of secondary atrophy—the form of atrophy to which Gudden drew attention years ago—and it would be interesting not only to study the phases of atrophy exhibited by the affected cells, but also to acquire more precise knowledge concerning the particular cells which are involved in the process, and specially to learn whether we should be correct in assuming that the laminar thinning, which Dr Bolton describes, is to a great extent ascribable to an atrophy of the large stellate cells situated above and below the line of Gennari, along with their numerous long processes.

Also it is disappointing to find that Dr Bolton says so little about the visuo-psychic area, for, although he clearly recognises and indeed accurately figures the type of cell-lamination in the parts bordering on the visuo-sensory area, he makes no attempt to define the limits of the field bearing this type and dismisses the subject with the remark that "in the visuo-psychic region surrounding the area of special lamination, old-standing optic atrophy causes no modification of the lamination." But my histological observations compel me to doubt whether this remark is wholly true, for I strongly suspect, as a result of the "partial" examination

[1] Bolton's outer granule layer of nerve cells corresponds to the lower part of S. Ramón y Cajal's layer 3.

of the occipital lobe in two cases of blindness, that the large and prominent pyramidal cells which I have noticed as characterising the visuo-psychic field undergo regressive changes in such cases; also I venture to say that the atrophy and disappearance of a considerable number might occur without occasioning a laminar alteration demonstrable by a relatively coarse method such as that of measurement. Here, however, we tread on debatable ground, for it is really not known what cortical cells constitute the termini of the optic radiations, and although S. Ramón y Cajal, von Monakow, Leonowa, Tanzi and others have made propositions on this point, it cannot be denied that it is one on which we require further enlightenment.

With the exception of this work of Dr Bolton I can find none giving a definition of the visual area on a histological basis, for while many writers—I need only mention Meynert, Betz, S. Ramón y Cajal, and the late Carl Hammarberg—present excellent accounts of the cell-lamination in this district, none of them have approached the subject from the localisation point of view. So likewise with the admirable monographs of Kaes on the medullated nerve fibres of the human cerebral cortex, it is impossible to glean from his diagrams the exact distribution of the occipital types of cortex to which he alludes.

Berger also, who has examined portions of the calcarine cortex from cases of blindness, does not assist us in localisation, and as regards the pathological changes found, he seems only to have confirmed Bolton's work.

Summary and Conclusions.

Convinced from my histological investigations that two definite and distinct areas, each bearing a specialised type of cortex, can be mapped out in the occipital lobe, I am now satisfied, after a consideration of most of the recorded work on this subject, that these two fields have different physiological functions to perform. And joining hands with those who hold the belief that in the occipital lobe there exist two distinct cortical centres, one specialised for the primary reception of visual sensations, the other constituted for the final elaboration and interpretation of these sensations, I would go a step further and affirm that the area of cortex in the calcarine region, which I have mapped out and termed visuo-sensory, represents the exact limits of the first-mentioned centre, while the investing field, which I have designated visuo-psychic, represents the precise extent of the second centre.

In previous sections, I have alluded casually to most of the grounds for assuming that the area in the calcarine region represents the part where visual sensations first impinge, and here I will offer a collective recapitulation of this evidence.

From the records of experiments on the lower animals there is nothing to be gained in favour of the point in question, but at the same time I find little that can be urged as antagonistic. The reasons why such experiments must yield negative or doubtful results concerning differential localisation are several; to begin with, ablational procedures are, of necessity, coarse; in the second place, it is difficult, almost impossible, to effect a psychic analysis of the conscious perceptions of dumb animals, which will be sufficiently thorough to meet the demands of scientific accuracy; thirdly, caution must be exercised in deriving conclusions, applicable to the human being, from operations on creatures the brains of which are morphologically different (this even applies to the brains of the higher apes); and, lastly, the calcarine area is so awkwardly placed (judging from the arrangement in the chimpanzee and

orang) that its satisfactory ablation without injury to other structures would baffle the skill of the most dexterous operator.

Analysing the clinico-pathological records, we find that, although the evidence concerning the delimitation of the visuo-sensory area is perhaps not so conclusive as it might be, there still exists a sufficiency of data to justify the statement that a pure, unmixed hemianopic condition is most readily brought about by a lesion in the neighbourhood of the calcarine fissure. At least this is the impression which we receive from a perusal of cases reported by Henschen, Huguenin, Hun, and other authorities; and while, on the contrary, Monakow, Starr, Vialet, Mills, and others would not confine the visuo-sensory area within such narrow limits, they unanimously recognise the calcarine fissure and its lips as an essential part of their field.

But, of course, the same difficulties concerning precise differential localisation which beset the experimental investigator prove a stumbling-block to the clinico-pathologist; for the arrangement of parts is such that it is almost impossible for nature to restrict a damaging lesion to the cortex, and the cortex only, of the area in question. Hence definite confirmation or refutation of this point will not be forthcoming until the positive and negative facts adduced from the careful analysis and digestion of many more cases are weighed and sifted.

It seems to me that one of the strongest pieces of evidence in favour of a limitation of the visuo-sensory area to the calcarine region is that provided by the embryological studies of Flechsig.

According to the Leipzig professor the only fibres in the optic radiations, and even in the whole occipital lobe, which have acquired their myelinic investment at the time of full foetal maturation are those derived from the corpora geniculata externa, and it is plainly and unequivocally demonstrable that these fibres are distributed to the cortex coating the lips and walls of the calcarine fissure.

Needless to say this is in agreement with physiological fact; for in early infancy the tracts for the conveyance of visual impulses to the primary cortical centre are obviously active, but visuo-psychic processes being in abeyance, there is no demand for association fibres.

There is a point in the behaviour of the large medullated fibres in the radiary zone of the calcarine cortex which lends support to the thesis that this region constitutes the arrival platform—to use Mott's expressive simile—for visuo-sensory impulses, it is that in specimens treated for the display of nerve fibres, the above-mentioned large tubules, after gaining the cortex, pursue a curious oblique course, crossing and tending to avoid the vertically-placed radiations of Meynert instead of finding a place in these bundles. Now S. Ramón y Cajal has already drawn attention to this feature in his examination of the calcarine cortex, and I have noticed its occurrence in two other parts of the brain besides the calcarine region, namely, the transverse temporal and the postcentral convolutions; and having strong reasons for believing that the two last-named parts constitute cortical stations for sensory impulses, I am led to assume that the oblique course of a large fibre in the radiary zone is an index of its corticipetal character, and that in the case of the calcarine cortex these fibres are probably seeking the large supra- and sub-stellate cells. On the other hand, in fields of cortex such as that coating the precentral convolution, in which we suppose that the large fibres

present are corticifugal or efferent, it is interesting to find that the radiations of Meynert form their chief track to the white substance; also, it is important to notice that in the visuo-psychic cortex where large fibres are even more abundant than in the visuo-sensory cortex, many exhibit the corticifugal peculiarity.

The concluding evidence in support of a separate functional standing for the visuo-sensory area is the proof adduced by Dr Bolton that in old-standing cases of optic atrophy the whole of the calcarine cortex undergoes distinct secondary alterations allied in kind to Gudden's atrophy, alterations by which the exact histological localisation of what he also calls the visuo-sensory area can be determined.

The grounds for a similar succinct delimitation of an area wherein visual impressions are further dealt with in the process of elaboration and intellectual interpretation can hardly be called definite; at the same time we have now elicited a considerable amount of evidence, both direct and indirect, which points to this simplified arrangement.

That one or more fields exist in the occipital lobe for carrying out these psychic processes concerned with vision has been amply proved by the results of experiment and clinico-pathological observation, but the extreme complexity of psychic visual processes along with the extreme difficulty attending the precise localisation of psychic perceptions generally, has necessarily prevented the experimenter and the clinician from arriving at an exact judgment concerning the orientation of this particular function.

From the histological point of view, however, the differentiation of such an area presents less difficulty; to begin with, my own observations have definitely proved that immediately investing the visuo-sensory area there exists a moderately extensive field of cortex, possessing a specialised type of arrangement of nerve cells and nerve fibres, entirely different both from that in the visuo-sensory area and that in the more outlying parts: and granted that the calcarine area is solely devoted to the reception of primary visual stimuli, the mere existence of a second area placed in such immediate contiguity suggests the likelihood that it is concerned with the sorting out and further elaboration of these stimuli.

More than this, the arrangement of fibres in this investing area suggests that they carry corticifugal instead of corticipetal impressions, that they are the fibres, in other words, which combine to form the strands joining the visual with other centres and helping to make the visual function so complex. Then, notwithstanding that the cortical connections of the strands of fibres to which I allude have not been fully worked out, yet arguing on the supposition which is almost equivalent to a truth that large fibres take origin from large cells, it is reasonable to assume that the fibres of these bands are derived from the giant cells which form such a characteristic feature of the visuo-psychic cortex.

Again, we can adduce Flechsig's evidence to the effect that in the newborn child none of these fibres pertaining to association tracts possess a medullated sheath, indicating that their development is delayed until the child is capable of interpreting sight stimuli. Lastly, we have the extremely important information gained from clinical observation of various psychic visual defects, that for the production of a psychic element in the blindness, it is necessary for the occipital lesion to be widespread and not confined to the calcarine region.

REFERENCES.

1. Kaes. *Loc. cit.*
2. Botazzi. Intorno alle corteccia cerebrale especialmente intorno alle fibre nervose intracorticali dei vertebrati. 1893.
3. Kölliker. Handbuch der Gewebelehre des Menschen. Leipzig, 1896.
4. S. Ramón y Cajal. Studien über die Hirnrinde des Menschen. Heft I. Die Sehrinde. Translation from the Spanish by Bresler. Leipzig (Barth), 1900.
5. Bolton. The Exact Histological Localisation of the Visual Area of the Human Cerebral Cortex. *Phil. Trans.*, Vol. 193, 1900.
6. Cunningham. *Loc. cit.*
7. Eberstaller. Zur oberflächen Anatomie der Grosshirn-Hemisphären. *Wiener med. Blätter*, 1884.
8. Munk. Die Functionen der Grosshirnrinde. Berlin, 1881.
9. Schäfer and Sanger-Brown. Experiments on Special Localisations in the Cortex Cerebri of the Monkey. *Brain*, Vol. X, 1888.
10. Horsley and Schäfer. A Record of Experiments upon the Functions of the Cerebral Cortex. *Phil. Trans.*, 1888.
11. Vitzou. La néoformation des cellules nerveuses dans le cerveau du singe consécutives à l'ablation complète des lobes occipitaux. *Arch. de Phys.*, Tome IX, No. 1, 1897.
12. Ferrier. The Functions of the Brain. London (Smith, Elder & Co.), 2nd Edition. See also *Phil. Trans.*, 1884, *Brain*, Vol. VII, and Croonian Lectures.
13. Lannegrace. Influence des lésions corticales sur la vue. *Arch. de méd. expér. et d'anat. path.*, 1889.
14. Goltz. Ueber die Verrichtungen des Grosshirns. Bonn, 1881.
15. Hitzig. Untersuchungen über das Gehirn. Berlin, 1874; and several other articles.
16. Sherrington and Grünbaum. *Loc. cit.*
17. Gerwer. Ueber die Gehirncentren der Augenbewegungen. Abstr. in *Neurol. Centralblatt*, p. 165, 1900.
18. Henschen. Ueber Localisation innerhalb des äusseren Knieganglions. *Neurol. Centralb.*, No. 5, 1898.
19. Edinger. Vorlesungen über den Bau der nervösen Centralorgane. IV Aufl., Leipzig, 1896.
20. Henschen. Klinische und pathologische Beiträge zur Pathologie des Gehirns. 3 parts. Upsala, 1890, 1892, 1894.
21. Huguenin. Pathologisch-diagnostische Bemerkungen zu den Herderkrankungen des Hirns, welche von den Gefässen ausgehen. *Amtl. Bericht über die Verwaltung des Medicinalwesens.* Zurich, 1876.
22. Hun. A Clinical Study of Cerebral Localisation illustrated by Seven Cases. *Amer. Journ. of the Med. Sci.*, Vol. 93, 1887.
23. Förster. *Arch. für Ophthalmologie.* Berlin, Bd. XXXVI.

24. SACHS. Das Gehirn eines Förster'schen Rindenblinden. *Arb. aus der psych. Klinik in Breslau*, 1895.

25. KAESTERMANN. Ueber doppelseitige homonyme Hemianopsie und ihre begleitenden Symptome. *Monatschr. f. Psych. u. Neurol.*, Band 2, 1897.

26. VON MONAKOW. Gehirnpathologie. Wien (Holder), 1897; and numerous other papers, chiefly in *Arch. f. Psych. u. Nervenkr.*

27. ALLEN STARR. Cortical Lesions of the Brain. *Amer. Journ. of the Med. Sci.*, 1884.

28. VIALET. Les centres cérébraux de la vision. Paris (Alcan), 1893.

29. REDLICH. Ueber die sogenannte subcorticale Alexie. *Jahrb. f. Psych.*, Band 13.

30. SEGUIN. Contribution à l'étude de l'hémianopsie d'origine corticale. *Arch. de Neurol.*, Tome XI, 1886.

31. FLECHSIG. *Loc. cit.*

32. BARKER. *Loc. cit.*

33. SACHS. Das Hemisphärenmark des menschlichen Grosshirns. 1. Der Hinterhauptlappen. *Arbeiten aus d. psych. Klin. in Breslau.* Leipzig, 1892.

34. DÉJERINE. Anatomie des centres nerveux. Paris, 1895.

35. LEONOWA. Beiträge zur Kenntniss der secundären Veränderungen der primären optischen Centren und Bahnen in Fällen von congenitäler Anophthalmie und Bulbusatrophie bei neugeborenen Kindern. *Arch. f. Psych. und Nervenkr.*, Band XXVIII. Berlin, 1896.

36. TANZI. Sull' atrofia secondaria indiretta degli elementi nervosi. *Riv. di Patol. nerv. e ment.*, F. 8, 1902.

37. HAMMARBERG. *Loc. cit.*

38. ST BERNHEIMER. Die corticalen Sehcentren. *Wiener klin. Wochenscft.*, No. 42, 1900.

39. PROBST. Ueber den Verlauf der centralen Sehfasern, etc. *Arch. für Psych.*, Vol. XXV.

40. BERGER. Beiträge zur feineren Anatomie der Grosshirnrinde. *Monatschr. für Psych. und Neurol.*, Band VI, 1899.

41. SCHWEIGGER. Case of Bilateral Hemianopsia. Quoted by von Monakow.

42. ELLIOT SMITH. 1. The Morphology of the Retro-calcarine Region of the Cortex Cerebri. *Proc. Roy. Soc.*, Vol. LXXIII, 1904.

2. Studies in the Morphology of the Human Brain, with special reference to that of the Egyptians: No. 1, The Occipital Region. *Records of the Egyptian Government School of Medicine*, Vol. II, 1904.

43. MILLS. A new Scheme of the Zones and Centers of the Human Cerebrum. *Journal of Amer. Med. Assoc.*, Oct. 4, 1902.

CHAPTER VI.

TEMPORAL LOBE.

TYPES OF FIBRE ARRANGEMENT.

If a vertical transverse section of the temporal convolutions, taken from about the middle of the lobe, so as to include a view of the transverse temporal gyri of Heschl[1], be stained for nerve fibres and examined, it may be observed even with the naked eye that the cortex presents different degrees of intensity of coloration. Beginning with the cortex coating the upper surface of the superior or first temporal convolution, that is to say the surface bearing the gyri of Heschl, the depth of coloration is great; passing to the exposed lateral surface of the same convolution we find an obvious reduction in tone; and descending to the underlying second and third temporal convolutions we notice that the pallor is still more decided. Further examination with the microscope confirms the difference in structure suggested by the naked eye appearances, and in point of fact, three distinct types of fibre arrangement are here represented; of these I shall now point out the distinguishing features, leaving their distribution and also an account of the co-existent type of cell-lamination to another section.

I shall begin with the cortex covering the transverse temporal gyri of Heschl.

Fibre arrangement in the cortex of the transverse temporal gyri of Heschl. Type No. 1.

The intense colour tone of the cortex covering these gyri is a feature which our study of the cortex in other parts of the brain has taught us to associate with profound fibre wealth. But although the fibre-endowment here is unquestionably great it cannot be said that there is a corresponding increase in the total depth of the cortex; this we may

[1] On that portion of the superior temporal gyrus concealed within the Sylvian fissure, the surface of which looks upwards and inwards towards the insula, several parallel gyri—sometimes as many as five—may be distinguished, running from before and laterally backwards toward the middle line. They have been termed by Heschl the transverse temporal gyri. Of these the most constant and best developed is the anterior. It springs from the superior temporal gyrus at about the middle of the fissure of Sylvius, and the sulcus which divides it from the succeeding transverse gyrus behind is often of great depth, and of such extent that it appears on the lateral surface, where it may not only indent but even bisect the superior temporal gyrus. This arrangement is commoner in the left hemisphere than in the right, and in males than in females.

The anterior gyrus is distinguishable at a time when none of the other transverse gyri are recognisable, and even at the beginning of the fifth month it may be seen plainly as a gentle elevation on the lower margin of the still open Sylvian fissure.

safely ascribe to the fact that lying within the fissure of Sylvius it has been denied any chance of expansion.

Let us next examine the various layers *seriatim*. (Plate XII. fig. 1.)

Zonal Layer.

Although evenly-medullated coarse fibres like those found in the precentral cortex are rarely seen, still the layer must be described as well-developed, and it is also more distinct here than in other parts of the temporal lobe. An abundance of fibres of the fine varicose type and members of the coarse variety constitute the layer, and a direct continuity between some of the latter and vertically placed fibres in the immediately subjacent layers can be proved.

Supraradiary Layer.

Commensurate with the prominence of the zonal layer, the supraradiary field is richly-stocked with fibres, and it is interesting to notice that this is one of the few regions in which one can make out a special collection of fibres lying midway between the surface and the line of Baillarger, sufficiently obvious to constitute what is called a line of Kaes. Delicate and medium-sized fibres running parallel with the surface chiefly make up the line, but occasionally an isolated coarse medullated fibre is included.

Line of Baillarger.

The line of Baillarger is of great breadth and distinctly visible with the naked eye, but on account of the great fibre wealth of the parts immediately above and below, its limits are not clearly definable under the microscope. It is chiefly composed of fibres of medium size, the majority of which run in the horizontal direction, but its prominence is accentuated by the presence of numbers of long coarse fibres running in the same plane.

Radiations of Meynert.

The radiations form stout bundles and contain many fibres of gross size in addition to the usual smaller elements. They do not exhibit a tendency to pierce the line of Baillarger as they do in other parts of the temporal lobe.

Interradiary Plexus and Association Fibres.

We come now to a layer the characters of which absolutely stamp this field of cortex and in great measure explain the intensity of coloration noticed with the naked eye. It is not so much the density of the interradiary plexus proper which calls for special remark, as the presence in great abundance of long fibres, of great size, which intersect the radiations at all angles and at all levels (Plate XIII, fig. 1). The horizontal or oblique position of these fibres as seen in transverse sections of the temporal gyri, coupled with the point that they decrease in number as the free surface of the convolution is approached, seem to indicate that, emanating from the white substance, they become concentrated along the innermost part of the gyri of Heschl, prior to their further distribution on the surface of the brain;

and *vice versâ*, if they are to be regarded as running in the opposite direction, that is to say if they be corticifugal fibres. But on this point I shall have more to say further on. Although scattered members of this system of fibres are present in the line of Baillarger and even in the supraradiary field, yet they are distinctly more numerous in the depths of the cortex immediately overlying the white substance, and in thin sections they may be seen in the white substance itself. Another noteworthy point is that though some of them directly join the radiating fasciculi the majority pass straight across. Finally, I would say, that their actual calibre is hardly so great as that of similar large fibres seen in the postcentral and calcarine cortex.

Briefly stated, the distinctive features of this type of cortex are the presence in the radiary zone of numerous large fibres, the existence of a line of Kaes, and the general wealth of fibres in all layers.

Fibre arrangement in the first temporal gyrus (hinder part). Type No. 2. (Plate XII, fig. 2.)

The type of fibre arrangement in this area is homologous to that found on the outskirts of other regions, such as the precentral and visuo-sensory, and the term "intermediate" is the best expression applicable to its characters. In describing its features it will be convenient to draw comparisons between it and the other two temporal types.

Zonal Layer.

The zonal layer must be described as being above the average development, but while it is better represented here than in the general temporal field, it is not so dense as in the concealed area just described, and fibres of large size are distinctly uncommon.

Supraradiary Layer.

Here again, while the general wealth of fibres is obviously greater than in the general temporal region, it is not so profound as in the transverse temporal convolutions; further, the line of Kaes noted as present in the latter region is now scarcely discernible.

Line of Baillarger.

This line is distinctly seen with the naked eye and is of considerable breadth, but it does not contain so many fibres of large calibre as it did in the part previously described, and hence loses in prominence. There is only a faint attempt at a reduplication of the line.

Radiations of Meynert.

The volume of the radiations is intermediate between that of the transverse temporal and common temporal bundles. The individual fasciculi are of great length, and exhibit a tendency to pierce the line of Baillarger and spread out in the supraradiary layer; they are also fairly rich in coarse fibres.

Interradiary Plexus and Association Fibres. (Plate XIII, fig. 2.)

The long, stout fibres which constitute such an important feature of the radiary zone in the transverse temporal gyri are not nearly so obvious on the exposed surface of the first temporal convolution, at the same time they are present in considerable number and they also show an inclination to join and proceed surfacewards in the radiary fasciculi.

The radiary zone has great general depth, and when compared with the same zone in the more outlying convolutions a difference in the general fibre-wealth is manifest.

White Substance.

Another point of difference between this intermediate field and more outlying parts is that the depth of staining of the medullary projection immediately underlying the cortex is great, a feature which agrees with its superiority in fibre-wealth.

Summing up the characters of the fibre-arrangement in this part, we may say that, compared with the transverse temporal area, while the cortical depth is greater, it is above all things wanting in large deeply-placed association fibres, and that compared with more outlying regions, it possesses a pronounced superiority in general fibre-wealth.

GENERAL FIBRE ARRANGEMENT IN THE TEMPORAL LOBE. TYPE NO. 3. (Plate XIV, fig. 1.)

The types of arrangement above mentioned are quite special, and pertain, as I shall presently show, to definite areas; I have now to describe the formation which is present in other parts of the temporal lobe, and which we are to regard as the general type.

Zonal Layer.

This layer is poorly developed compared with the same layer in the areas previously described; it is made up of delicate fibrils, coarse varicose fibres are only occasionally seen, and large medullated fibres are absent.

Supraradiary Layer.

The outer third of the layer is pale and badly supplied with fibres, but in the inner two-thirds there is a thin plexus of delicate fibrils in the midst of which run a few long fibres almost of medium size, so adding to its density. No line of Kaes is recognisable.

Line of Baillarger.

The line of Baillarger though plainly visible cannot be described as well-developed; a few long medium-sized fibres are recognised in it, but it is mainly composed of short fibres delicate in calibre.

Radiations of Meynert.

These are peculiar, inasmuch as they frequently pierce the line of Baillarger and spread up into the supraradiary layer; otherwise they are thin and slender, and the entire absence of fibres of large calibre is an important feature.

Interradiary Plexus and Association Fibres (Plate XIII, fig. 3).

The whole radiary zone has a pallid appearance because the interradiary plexus proper is composed of very thin and delicate fibres, and the association system is not well represented. The few association fibres present are only of medium size and lie in the immediate neighbourhood of the white substance, which in turn is pale-stained on account of its poor fibre-wealth and especially its poverty in fibres of large calibre.

Topical Variations.

The various series of sections have been searched very carefully to ascertain whether this large area (*vide* fig. 15) can be further split up on the basis of additional variations in the arrangement of cortical fibres but this has been found to be impossible, because although slight differences are noticeable these are merely undecided changes in density, and over all the absence of fibres of large calibre is the dominant feature and has been the main guide in settling the limits of the field. Special interest accrues to the discovery that the angular gyrus, which is supposed to possess special functions, does not differ structurally from other parts of the area (Plate XIV, fig. 2 and Plate XIII, fig. 4).

TYPES OF CELL LAMINATION.

It is possible to distinguish three types, but the topical variations in cell lamination are not equivalent in degree to the differences in fibre-arrangement, also the intervening gradations are by no means abrupt: hence the extent and limits of these types of lamination are by no means easy to define; however, I may say that the following description has been built up on a particularly full and careful examination of the lobe, and above all things I would mention that judgments concerning the size, number, and general disposition of cells in various parts have been based not upon mere microscopic inspection, but upon the comparative results given by a great number of camera lucida drawings made at various magnifications. This statement is necessary because experience gained in this work has proved to me over and over again that the eye cannot be trusted to make reliable comparisons, especially when the matter concerns the relative magnitude, or the number of given cells in different sections: accordingly when any doubt has existed on these points I have always settled the matter by making a drawing; and tedious as this procedure undoubtedly is, it is a very necessary, indeed an essential, safeguard in work of this description.

THE TRANSVERSE TEMPORAL GYRI. TYPE NO. 1 (Plate XV, fig. 1).

The plexiform layer calls for no special remark; it is about ·29 mm. deep.

The average depth of the layer of small pyramidal cells is nearly ·20 mm., and it is noticed that the cells are very numerous and have a closely-packed appearance. This, as I shall presently mention, seems to be a somewhat important feature.

It is not easy to estimate the depth of the lamina of medium-sized pyramidal cells because it merges with the succeeding layer of large pyramidal cells. But the number of the

medium-sized cells is again great, and the individual members are possibly a trifle larger than in other temporal regions.

I must direct special attention to the condition of the external layer of large pyramidal cells, because it is the appearance presented by them which constitutes the chief distinguishing feature of this area. Present in great numbers they form a particularly prominent lamina, but among them three types of cells are distinguishable, small, or medium-sized

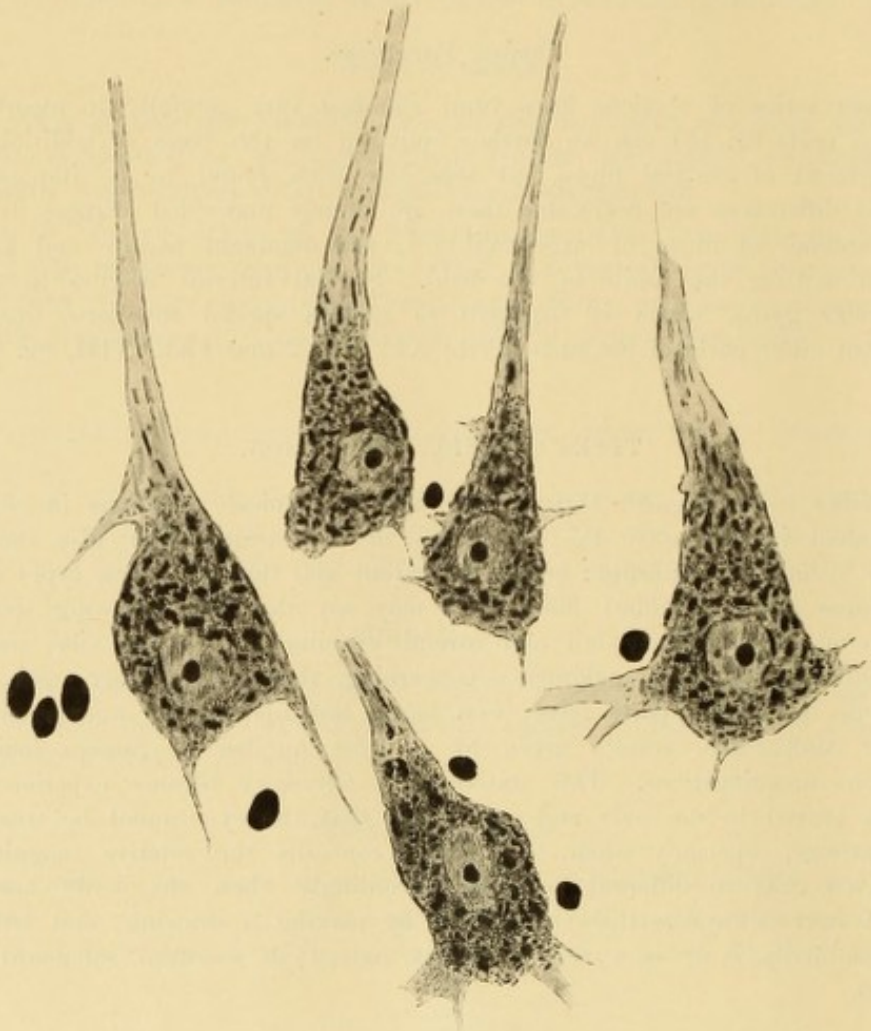

FIG. 13.

Five of the "giant" elements in the layer of large external pyramidal cells of the transverse temporal gyri. From a crush specimen stained with thionin. Zeiss apochromatic oil-immersion lens, 2 mm. Compare the size and structure of these with cells represented in figure 14, prepared in the same way and drawn at a like magnification.

pyramidal cells, others of such dimensions that the designation large is applicable, and others again which, for differential purposes, may be called giant cells. It is to the last-mentioned cells that most importance is to be attached (text-figure 13); an idea of their

number may be gained from the statement that every transverse mm. of substance contains from 8 to 12; the position they prefer is the immediate neighbourhood of the layer of stellate cells, but they may be found nearer the surface and occasionally they lie within or even below the stellate lamina; they measure from 45 to 50 μ in length by from 25 to 40 μ in breadth; their form varies, at times being pyramidal, at other times stellate, and the majority are a cross between the two; they possess a stout apical process which, however, often proceeds obliquely towards the surface; their basilar dendrons are also stout, and there may be more than two, and it is not uncommon to see dendrons issuing from well up the side of the cell-body; the axon is usually found on the basilar surface. The protoplasm of the cell contains large chromophilic particles; these are separated from one another by distinct intervals, but all the same they impart a general depth of coloration to the body which is greater than that of other large temporal cells. Relative to the general size of the cells the nucleus is small. The position occupied by these cells is indicated in figure 15 by the shaded (audito-sensory) area. The other large pyramidal cells possess the same characters as those in other parts of the temporal lobe, but the presence of abundant small pyramidal cells dotted about at this level seems peculiar to the area.

The layer of stellate cells is approximately ·30 mm. in depth, the component cells are divided into columns by the radiary fasciculi, and they occur in such numbers that the band forms a very prominent object.

It is rather curious that no distinct internal lamina of large pyramidal cells is to be made out in this cortex; in the position which they should occupy only a few pale-stained but fairly large cells are visible.

The layer of fusiform cells is deep (quite 1 mm.) and richly-stocked, but the arrangement differs from that in other parts in being distinctly less columnar, and also the processes of the individual elements point in all directions instead of uniformly up and down. This appearance is no doubt attributable to the confused arrangement of nerve fibres in the same situation. No large cells, corresponding to the solitary cells of Meynert in the visual area, are found in the depths of the cortex.

From the foregoing it may be gathered that the leading features of this type of cortex are (1) the general rich supply of cells, and (2) the presence of numbers of curious giant cells above the well-developed stellate layer: and I may here say in regard to distribution that it corresponds exactly with the area mapped out by fibre-arrangement.

Superior temporal convolution. Type No. 2 (Plate XV, fig. 2).

Over that part of the crown and lower wall of the superior temporal convolution, which constitutes the second field of special fibre-arrangement, the following cell lamination obtains and as closely marks its external limits.

The plexiform layer is similar to that in the transverse temporal gyri.

The layer of small pyramidal cells may be a trifle deeper but does not seem to be so densely packed with cells.

The pyramidal cells of medium size are also not so numerous and the combined depth of this and the giant cell layer is less.

The appearances which serve specially to distinguish this field of cortex are those presented by the giant cell layer. Compared with the transverse temporal gyri the extra large cells noted there have suffered a very pronounced reduction in number, instead of from 8 to 12 being visible in every transverse mm. of substance, there are but 3 to 5. The prevailing

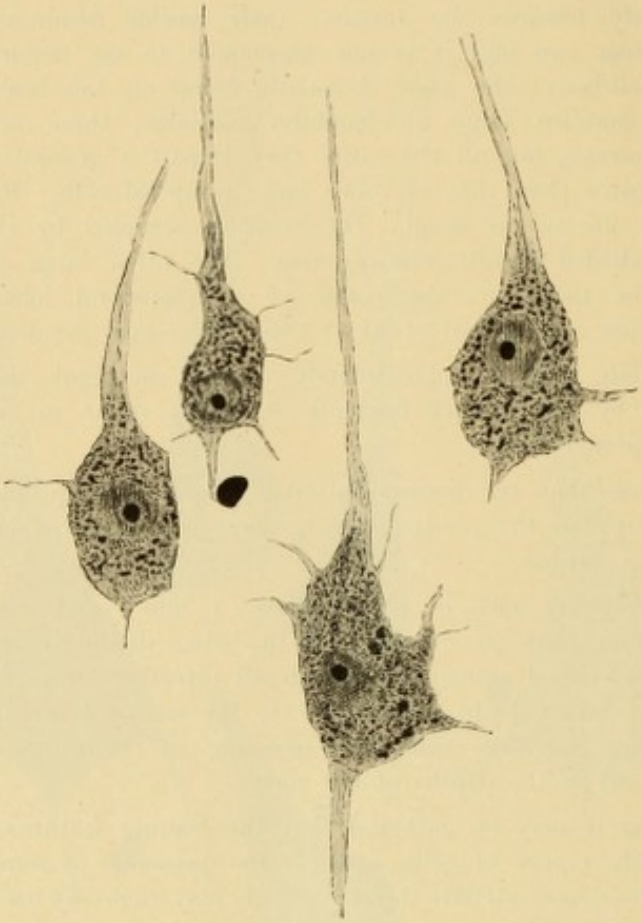

Fig. 14.

Some of the largest cells to be found in area No. 2, that is on the free surface of the superior temporal convolution. Compared with corresponding cells in area No. 1, figure 13, they are much smaller and more poorly represented as regards chromophilic elements.

The smaller cell, lying in the upper part of the figure, may be taken as representative of the size of the largest pyramidal elements distributed over the general temporal cortex; area No. 3.

From a crush specimen; thionin staining; Zeiss oil-immersion apochromatic lens, 2 mm.

cells are those which I have alluded to under the name large pyramidal, and these are appreciably more numerous than they were in the transverse gyri (text-figure 14). Small pyramidal cells are also dotted about here and there.

No differences can be made out between the stellate layer here and in the transverse temporal gyri.

The internal layer of large pyramidal cells is again poorly represented, but when we come to the fusiform layer we find not only that the cells are less numerous but their columnar arrangement is perfect.

It must be admitted that the differences in cell lamination between these two parts are not so great as the differences in fibre-arrangement would lead one to expect, and the only point to which I am inclined to attach real significance is that concerning the giant cells.

Other parts of the temporal lobe. Type No. 3 (Plate XVI, fig. 1).

The remaining part of the temporal field shows the following lamination which, like the fibre-arrangement, is uniformly distributed over the whole of the area represented by small dots in diagram 15.

Compared with the other areas there is a pronounced diminution in the wealth of cells in all layers, but this is not associated with a reduction in depth.

Of special importance is the point that no "giant" cells are discoverable, and although the external layer of large pyramidal cells is well-defined, the individual members are uniformly smaller than corresponding cells in the first temporal gyrus and they are also more pyriform; they average $40 \times 20\ \mu$ in diameter, and a feature which drawings show is that they are all more or less equal in size and not mixed up with small cells.

The layer of stellate cells is again a good one, although perhaps not so prominent as in the special areas above-mentioned.

A distinct internal layer of large pyramidal cells is now found immediately below the stellate layer; the individual cells measure only $17 \times 30\ \mu$ and are pale-stained and less numerous than in the external layer.

Cells in the fusiform layer are relatively scanty.

DISTRIBUTION OF THE THREE TEMPORAL TYPES OF CORTEX. (Text-figure 15.)

Type I. Taking the concealed area first, we see, as I have already indicated, that this is confined in a remarkable manner to the transverse temporal gyri or gyri of Heschl; in the anterior direction the dense fibre-formation is sharply and definitely limited by the line of junction between the most anterior of Heschl's gyri and the relatively flat and deeper-lying surface of the insula proper.

In the lateral direction it shows signs of coming to the surface at the point where the anterior gyrus of Heschl springs from the superior or first temporal gyrus, and behind this the Sylvian lip of the posterior half of the first temporal gyrus may be regarded as a boundary. While in some brains the coarse fibre-arrangement is completely concealed, in others it is found peeping over the lip of the fissure on to the free surface of the first temporal convolution.

Posteriorly the area is again submerged and the special fibre-arrangement is only found on the walls of the hinder, forked extremity of the fissure of Sylvius.

In the inner or central direction the area comes to a point where the transverse temporal gyri converge, and the important point is noticed that the arrangement does not show any indication of ascending the parietal operculum.

It is difficult to give a clear diagrammatic representation of the distribution of this type of arrangement, but in the accompanying figure, the area has been transferred to a brain in which the Sylvian fissure has been opened out.

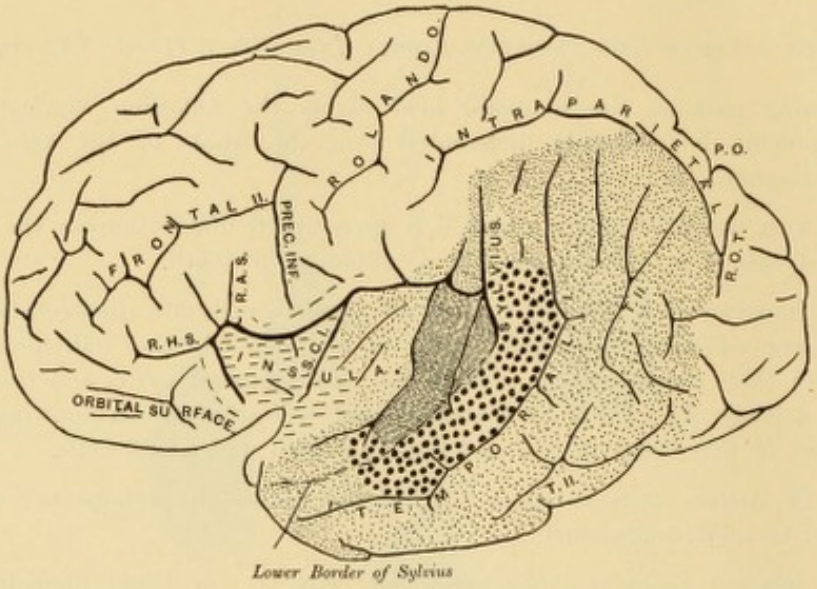

FIG. 15. Drawing of left cerebral hemisphere (human) with Sylvian fissure opened out.
Showing (1) the audito-sensory area (shaded) confined to the two transverse temporal gyri and not extending on to the insula; (2) the audito-psychic area (large dots) on the free surface of the posterior three-fifths of the first temporal gyrus; (3) the extent, on the lateral surface of the hemisphere, of the common temporal cortex (small dots). *S. C. I.* = sulcus centralis insulae; *R. H. S.* = ramus horizontalis Sylvii; *R. A. S.* = ramus ascendens Sylvii; *Prec. Inf.* = sulcus precentralis inferior; *P. O.* = parieto-occipital fissure; *R. O. T.* = ramus occipitalis transversus; *T. II.* = sulcus temporalis secundus.

Type II. Coming next to the area over which cortex showing an intermediate degree of fibre-wealth is distributed, this is soon described as it forms a broad skirt or margin to the concealed area above-mentioned. It is also almost entirely confined to the first temporal convolution.

I cannot indicate its anterior limit on the free surface better than by saying that it corresponds to the point where an imaginary line made continuous with the lower extremity of the fissure of Rolando would cross the temporal lobe, but I should add that this line of demarcation is not a sharp one.

Inferiorly, the first temporal sulcus forms a good boundary, and I must not forget to mention that transverse sections show that this type of arrangement does not extend more than about half-way down the upper wall of the sulcus.

In the posterior direction the area tends to broaden slightly, and it might either be described as investing the downward prolongation of the fissure of Sylvius, or as being

limited again by the first temporal sulcus. I must further point out that in this position the area is subject to slight variations, one of which is an extension on to the second temporal gyrus, but on the whole these variations may be regarded as due to changes in form of the hinder extremity of the Sylvian fissure, which in turn are dependent upon variations in the development and representation of the gyri of Heschl.

Lastly, I think that some of this cortex spreads on to the insula and covers parts of the gyrus longus and gyrus posterior secundus (*vide* Chapter XI.).

Type III. Again referring to diagram 15 and also to Plate I, it may be seen that in its upper part this area of cortex is contiguous with the field which I shall describe later under the designation "parietal," and the dividing line between the two areas corresponds approximately but not absolutely with the disposition of the horizontal and occipital rami of the intraparietal fissure[1]. The relation to the ramus occipitalis appears to be more definite than that to the ramus horizontalis, for while temporal characters usually reach up as far as the ramus occipitalis (so covering the angular gyrus), they exhibit an inclination to stop some distance short of the ramus horizontalis; at the same time I must mention that, all along the line, the change in type from temporal to parietal cortex takes place gradually, the only points to be relied on in deciding the transition are the appearance of fibres and cells of greater size than those usually present in the common temporal cortex, and it is really impossible to lay down a sharp line of demarcation.

The anterior boundary is also an unsatisfactory one, but it to some extent follows the sulcus postcentralis inferior and along this line the temporal gradually passes into the postcentral arrangement.

Posteriorly, I regard the lower division of the ramus occipitalis transversus as a constant boundary, but below this the outskirt of the area is related to no definite fissure and one can only say that it merges with the visuo-psychic cortex, and the point where this junction takes place is roughly indicated by Ecker's suggested anterior limit of the occipital lobe, viz., an imaginary line drawn from the outer extremity of the parieto-occipital fissure to the point on the lower surface of the hemisphere where it is indented by the upper angle of the petrous portion of the temporal bone. The occipital cortex differs so markedly from the temporal that this boundary is readily defined. Coming lastly to the distribution of this area on the temporal lobe proper, it is found that it covers almost the whole of the second and third temporal, and much of the fourth temporal or fusiform gyrus, then spreading on to the inferior and mesial surface it does not cease until the collateral fissure is reached, but as the diagrams show this fissure is not a good boundary. The same type of cortex encircles the tip of the temporal lobe, but behind this a portion of the uncinate gyrus is reserved for the hippocampal type, and the hinder parts of the lingual and fusiform gyri are occupied by visual cortex.

[1] When speaking of the intraparietal fissure I shall always adhere to the subdivisions described by Professor Cunningham; these are the sulcus postcentralis inferior, with the disrupted sulcus postcentralis superior, the ramus horizontalis (commonly joined to the sulcus postcentralis inferior and also known as the sulcus interparietalis of Ecker), the ramus occipitalis (sulcus longitudinalis occipitalis superior of Ecker) and its posterior vertically placed offshoot called by Ecker the ramus occipitalis transversus.

REMARKS ON THE TEMPORAL CORTEX IN THE ANTHROPOID BRAIN. (Plate II.)

It is remarkable how closely the distribution of these areas in the brains of the higher ape resembles that found in the human being; indeed, it was while examining this region in the brain of the orang that my attention was first directed to the existence of the extraordinary fibre-wealth of the cortex at the hinder end of the Sylvian fissure, and it was this discovery which led me to make a thorough investigation of the same region in the human brain.

Concerning the naked eye appearance of the anthropoid brain I have satisfied myself that in the orang and chimpanzee elevations exist on the Sylvian side of the first temporal convolution which are homologous with the transverse temporal gyri of the human brain. These gyri may not stand out so prominently as they do in the human brain, but they can be readily distinguished, supporting the hinder end of the superior temporal gyrus after the fashion of buttresses, and lying at a distinctly higher level than the more anteriorly placed insula proper. Further, microscopic examination absolutely settles the homology, for in the case of the anthropoid brain the area of cortex characterised by the possession of a special wealth of fibres of large calibre, is confined in an exactly homologous manner to the above-mentioned transverse gyri, and is again practically entirely submerged in the hinder half of the Sylvian fissure, only just peeping out on to the surface at the posterior extremity.

Also the external field of cortex, alluded to as possessing an intermediate type of arrangement, is in its main extent again confined to the first temporal gyrus; but anteriorly it seems to extend slightly further forwards than it does in the human brain, and posteriorly it tends to ascend on to the opercular part of the supramarginal gyrus lying immediately above the posterior extremity of the Sylvian fissure.

I can conclude by saying that these fields are more readily differentiated and mapped out in the anthropoid than in the human brain, not only because the brain is smaller, but because there is less confusion of the gyral arrangement in the posterior corners of the Sylvian fissure, making the part difficult to examine in serial section.

FUNCTIONS OF THE TEMPORAL LOBE.

It has been proved beyond doubt that auditory impulses are first received as crude sensations and then converted into conscious perceptions in some part of the temporal lobe, and it also appears that the part principally concerned in this process is the first or superior temporal gyrus; but as yet, no worker, whether in the domain of experimental physiology, pathology, or anatomy, has succeeded in assigning sharp limits to the auditory area; nor have successful efforts been made to divide the auditory, like the visual field, into two distinct territories, one adapted for the primary reception of crude sensations, the other for the further elaboration and transmutation of these impulses into conscious psychic perceptions.

For the purpose of ascertaining whether previous results can be correlated with the facts of histology set forth in this research, we will next take a general survey of the literature on the subject and consider it under three headings, (1) the experimental, (2) the clinico-pathological, and (3) the embryological and anatomical.

A. The Experimental Evidence.

On reviewing the experimental researches aiming at the exact localisation of the auditory function one is forced to the conclusion that information which has been gained in this manner is not wholly reliable; for while some observers have stated with full confidence that certain operative procedures are followed by definite phenomena, others claiming to have performed identical operations have stated with an equal degree of assurance that the results are entirely negative; and in the face of so much that is contradictory and discrepant, it is not to be wondered at that the results of experiments dealing with the auditory sense in the lower animals are viewed with suspicion.

Munk is again to be credited with the first positive experimental results. Bilateral extirpation of the temporal lobes in his dogs was followed by complete "cortical deafness," and at the same time the functions of taste, smell, and sight were preserved intact. Furthermore, removal of a circular piece 1·2 cm. in diameter from the middle of his primary area produced changes which Munk called "mind-deafness" (Seelentaubheit); in this condition the hearing of the animal was intact, but it was unable to put an interpretation on special sounds which it heard; for instance, it was irresponsive to calls from its master, and in other ways gave evidence of this particular form of deafness; but the change was not permanent, passing off in about five weeks' time.

Luciani and Tamburini, Seppilli, and Goltz's recorded experiments agree approximately with those of Munk.

Ferrier produced strong evidence to the effect that the centre for auditory perception is situated in the superior temporal gyrus, for in the case of the monkey not only did electrical irritation of the superior temporal gyrus cause sudden movements of the ear, head, and eyes, such as are indicative of perception of sound in the opposite ear, but destruction of this gyrus on both sides caused total deafness.

Unfortunately the operations which in the hands of Ferrier yielded such positive results, proved negative when repeated by Schäfer. Schäfer experimented on no less than six monkeys, more or less completely destroying the superior temporal gyrus on both sides, and yet in not a single instance was hearing permanently affected.

Now discrepant results like those just mentioned are extremely difficult to understand. To my mind the only way of explaining Professor Schäfer's negative results is by supposing that his ablation of the superior temporal gyrus was not quite so complete as he imagined and that he left behind part of the transverse temporal gyri of Heschl. In regard to these gyri, I have already indicated that in the cases of the human being and the anthropoid ape they possess a special structure, and that they are the parts which the auditory fibres first strike on their way outwards, and I shall have occasion to mention presently that they probably stand in relation to the auditory function in the same way as the calcarine region does to the visual, and are accordingly of prime importance as a centre for the primary reception of auditory stimuli. Reasoning by analogy, it is extremely probable that these transverse gyri are represented in the lower forms of apes upon which Schäfer operated, and if their anatomical disposition is anything like that seen in the anthropoid species one can readily imagine how difficult it would be to include them in an extirpation of the first temporal gyrus: for apart from the truth that they lie deeply,

extending right to the floor of the hinder end of the Sylvian fissure, they are crossed by a number of important Sylvian branches of the middle cerebral artery which the experimenter would probably be desirous of leaving uninjured: and, granted that these gyri possess the importance suggested, it is obvious that if they were not entirely removed the animal would still retain a certain amount of power of auditory perception.

Unpractised in experimental physiology, needless to say I venture with diffidence on a criticism of the results of such experienced observers as Ferrier and Schäfer; however, it does seem that the explanation just offered is the only one which will reconcile such pronounced discrepancies. As to Munk's suggestion that Schäfer's animals reacted because the sounds made to attract them were so loud that they were appreciated by the sense of feeling and not that of hearing, we would merely say that we give Schäfer credit for being too experienced an investigator to be misled in this manner.

Some more recently published experiments of Larionow's on dogs have elicited several points of interest. In the first place, he combats Munk's statement, that each centre has a crossed connection with the opposite ear only, and holds that each ear is related to both cortical centres; he finds further that slight lesions of the auditory cortex are followed by a loss of appreciation of single tones without impairment of common hearing, and he has produced movements of both ears by faradisation of the angular gyrus, as well as of the temporal lobe.

Larionow is the first to have tried a novel and ingenious method of determining auditory localisation, that is by obtaining galvanometric measurements of the current in the cortex of the temporal lobes during stimulation of the peripheral organs of hearing with tuning-forks; but though it appears that variations in reaction are exhibited by different parts of the temporal lobe, an unpreventable diffusion of the current, apparently along association tracts, defeats the accuracy of the method.

Triwus has conducted experiments of a similar nature.

Summing up the experimental evidence which has been adduced, we arrive at the conclusion that, although it is difficult in the case of the lower animals to judge correctly of the effects of operations on the responses made by the nervous system to auditory stimuli, yet the balance of evidence is in favour of the assertion that removal of the superior temporal convolutions abolishes the receptivity of auditory sensations.

B. The Clinico-Pathological Evidence.

A careful study of cases of softening, abscess and tumour affecting the temporal lobe, is gradually enabling us to draw a close line round the area dominating the function of hearing in the human brain; and such cases have also shown us that lesions affecting the temporal lobe may give rise, not only to complete deafness, but to groups of symptoms of an extremely complex nature of which word-deafness (word-blindness), psychic deafness, and amusia are examples. Analysing the published accounts of such cases for the purpose of seeing how far they assist us in arriving at the exact topographical distribution of the auditory function, we will first review the instances of total deafness.

Cases of Total Deafness.

A perusal of the literature shows that instances of total deafness established on an anatomical base, by a careful examination of the brain after death, are few and far between; in the works to which I have had access I cannot find more than five cases, and of these the following is an abstracted account.

In a well-known case reported by Friedländer and Wernicke, a gummatous lesion destroyed the posterior part of the temporal lobe (including the first temporal gyrus) in the left hemisphere, and a similar lesion in the right hemisphere invaded the most posterior portion of the first temporal gyrus, the whole of the supramarginal and the adjacent part of the angular gyrus.

In a case recorded by Pick, the first temporal gyrus, along with the angular and supramarginal gyri and the insula, on the left side, were obliterated; and in the right hemisphere, a destructive process extending from the insula further into the substance of the brain, probably destroyed the auditory tract and so helped to make the deafness complete.

Sérieux and Mignot report a case in which the presence of hydatid cysts in both temporal lobes gave rise to complete deafness.

In a case of Anton's, bilateral patches of softening destroyed the first and second temporal gyri, and from there extended in the direction of the occipital lobe and inferior parietal lobule.

Lastly, a carefully observed case has been put on record by Mills. In the left hemisphere, the posterior two-thirds of the first temporal convolution were reduced to a thin strip, and the posterior fourth of the second temporal gyrus partly destroyed by an old embolic softening: in the right hemisphere, the first and second temporal gyri, the insula and the lower end of the central gyri, along with the lenticular nucleus and external capsule, had been wiped out by an old haemorrhagic process.

Although on account of the extensiveness of the lesion, all of these cases were complicated by other symptoms, such as paraphasia, paragraphia, word-blindness, paresis, etc., yet the most prominent manifestation was the condition of absolute deafness and irresponsiveness to sounds of any description; again, although as guides to localisation they are necessarily rough and inexact, it cannot be denied that they still further strengthen the evidence gained from experiments on apes, to the effect that destruction of the superior temporal gyri, and particularly of their hinder half, is adequate to the production of complete deafness; and, lastly, although they do not tell us in so many words that the transverse gyri of Heschl form a fundamental part of the auditory area, the fact that the lesions have always been at the hinder end of the first temporal gyrus points in favour of this supposition.

Cases of Deafness due to Unilateral Lesions.

In face of the evidence given above we should naturally expect that destruction of the superior temporal gyrus on one side would occasion either unilateral deafness,—crossed or on the same side,—or bilateral deafness corresponding to hemianopia; but it is a remarkable thing that the information which we have on this point is of an extremely indefinite and indeterminate character. True it is, that cases have been recorded in which bilateral

dulling of the sharpness of hearing, of sudden onset, has been attributed to lesions in one temporal lobe and so given support to the anatomical supposition that each ear is connected with both cortical centres; but on the other hand there are cases on record (Kaufmann and Ferguson) of unilateral deafness which seem to have been dependent on lesions of the first temporal gyrus of the opposite side; furthermore, there is a gradually increasing number of cases in which extensive lesions of the right temporal lobe have given rise to no discoverable impairment of hearing at all. In view of such conflicting evidence confusion reigns on this point; nevertheless I feel confident that a closer examination, in future cases, of the extent of the destruction not only in the superior temporal convolution but in the adjoining transverse temporal gyri will shed light on the question.

The Lesions in Cases of Word-Deafness.

We now come to a consideration of several extremely complex phenomena which attend lesions of the left temporal lobe in particular, and the most important is that which we understand by the name "word-deafness." In dealing with this symptom-complex it is not my intention to enter into the various views upheld by the host of observers who have recorded cases, my remarks will be narrowed down to an account of the facts bearing on cortical localisation supplied by the autopsies in such cases.

Simple uncomplicated word-deafness—Lichtheim's "isolated speech-deafness," Wernicke's "subcortical word-deafness," Déjerine's "pure word-deafness,"—that is, the condition in which the disabilities are a failure to comprehend spoken words, and a consequent failure either to repeat words, or to write from dictation, and which was supposed by Lichtheim to be due to an isolation of the left auditory word-centre, by the cutting off of all its afferent fibres, is evidently of rare occurrence; for Bastian, writing in 1901, states that he knows of only three cases. In two of the cases referred to, those of Lichtheim and Sérieux, there is no account of a necropsy, but in the third, which has been well reported by Pick, the autopsy revealed an old softening of the first and second temporal gyri, of the insula, and of the opercular portion of the ascending and third frontal gyri on the right side, and a less extensive softening of the first temporal and supramarginal gyri on the left side.

In addition to these, I have found a case published by Déjerine and Sérieux which is claimed to be the first instance of "pure word-deafness" checked and made complete by an exact macroscopic and microscopic examination of the brain. For a period of five years the patient exhibited the symptoms of "pure word-deafness," that is to say, integrity of the power of spontaneous speech, of spontaneous writing and copying, and of reading aloud, along with an inability to comprehend, repeat or write down words heard. Then the condition became complicated and during the last two or three years of life, paraphasia and paragraphia, finally amounting to complete loss of the power of interpreting writing, gradually appeared, and also the general intelligence and sharpness of hearing suffered. At the autopsy, pronounced bilateral atrophy of the temporal lobes, particularly of the upper gyri, was found, but the insula, be it noted, was intact.

Microscopically the changes seem to have been those of simple atrophy from localised defective nutrition, or what these observers call "poliencephalitis chronica"; and the view is put forward that "pure word-deafness" is referable to cortical affection of the auditory area,—not to an interruption of the connections between the centres for hearing and

word-memory, as Lichtheim and others suppose;—and that it is necessary for the affection to be bilateral.

From the foregoing it is manifest that "word-deafness" in its pure and uncomplicated form does not yet rest on a substantial anatomical basis; in only two cases has the clinical condition been checked by a post-mortem examination, and in both of these a bilateral affection of the superior temporal gyri was observed; the facts supplied do not go far in enabling us to place our finger on the exact area of cortex, obliteration of which will be followed by this condition in all its purity and simplicity; and although bilaterality of lesion would appear to be a *sine quâ non*, the fact that a similar condition, although complicated by other symptoms, is known to have resulted from a one-sided lesion, shakes one's faith in the double relation.

We will now consider the variety of "word-deafness" which results from a one-sided lesion; of this form numerous instances have been recorded, and the destructive area has almost invariably[1] been situated in or about the first temporal convolution of the left hemisphere, exceptional cases being those which have occurred in left-handed individuals. But although it appears that complete "word-deafness" may result from a lesion in the above-mentioned region, the clinical picture is generally complicated by the presence of other phenomena. From the writings of Bastian, Ferrier, von Monakow, and Miraillié, all of whom have collected and analysed cases recorded in the literature and compared them with personally-observed instances, we find that the following additional disabilities may arise, (1) a disturbance of voluntary speech, which may amount to "complete aphemia" (Bastian), or, and this is much more common, it may be a degree of paraphasia; (2) a marked interference with the capacity for reading aloud; (3) an inability to write spontaneously, either complete or partial (agraphia or paragraphia); (4) occasionally an inability to copy correctly; (5) a varying amount of "word-blindness"; (6) some loss of the musical faculty.

So much for the possible complications which may attend lesions in the first temporal gyrus of the left side; let us now attempt a closer investigation of the pathological anatomy of these conditions. In the first place, according to Bastian, slight lesions of the gyrus give rise to corresponding slight functional disability without any of the above complications, a condition in which various words fail to be recalled as they are needed in ordinary speech and to which he considers the term "amnesia verbalis" specially applicable; but, so far as I can ascertain, the anatomical grounds for this assumption are not so firmly established as they might be, although clinical data are all in favour of such a possibility; and in fact this condemnation might be extended further and applied to the pathology of word-deafness generally. For notwithstanding that so many dozens of cases stand recorded in the literature, it is still plain that a complete macroscopic and microscopic examination of the brains of many more will have to be made before the anatomical deficiencies upon which this exceedingly complex condition depends will be thoroughly and satisfactorily demonstrated. Von Monakow, who is of the same opinion, might be quoted here. The view which this observer favoured, after a close analysis of nearly forty cases of "word-deafness"—including an examination in serial sections of the brains of several cases which came under his own notice—was, that this clinical manifestation depended on the existence

[1] It is unfortunate that we cannot say that "word-deafness" is invariably due to a lesion of the left superior temporal gyrus. Authentic cases have been recorded in which there has been no affection of this convolution, and these of course increase our difficulty in interpreting the condition.

of a widespread lesion, one which brought in its train, not the interruption of a single tract of fibres only, but of a whole series of hitherto unexplored bands, among which projection fibres from the "secondary" auditory centres (to be mentioned hereafter) and the receptive apparatus in the auditory area were to be included. Moreover, he believed that in "word-deafness" the defect was of an associative nature, for on no other supposition could the ability of the patient to hear ordinary sounds with both ears be explained; at the same time he could give no definite and concise statement as to the particular tracts which were involved, and the same remarks might be applied to the writings of others who have helped to swell the stream of controversy on this subject.

Amusia.

Musical or tone deafness may be one of two kinds, of a perceptive nature and indicated by an inability to recognise familiar tunes, or of an expressive kind causing the loss of singing and playing accomplishments; of these the former variety is the commoner but the two may coexist. Again, so far as I am aware, cases of pure "amusia" have not been recorded; some complication, of which "word-deafness" is the most frequent, always being present.

As is the case with "word-deafness," so here, the area of cortex presiding over this faculty and also the special routes along which musical stimuli pass—if such exist—has not yet been made clear; all that we can say is, that instances have been recorded, notably by Edgren, suggesting that bilateral disease of the first temporal lobes is accountable for the disability. In Edgren's case there was an extensive defect in the anterior division of the first and third temporal gyri of the left side, and an area of softening at the posterior end of the Sylvian fissure, involving portions of the superior temporal and supramarginal convolutions.

Psychic Deafness.

That some dulling of the intellectual faculty should arise, as a secondary result of the cutting off of such an important channel of communication as that for spoken words, is readily supposed, and in point of fact some degree of mental impairment has attended most cases of "word-deafness." This, however, is not the condition to which the term "psychic-deafness" alludes. The term applies to a state, allied to "mind-blindness," in which the individual is unable to interpret or recognise ordinary sounds correctly, thus, a dog's bark cannot be differentiated from a cock's crow, and neither will convey any meaning. But although this condition may exist clinically we are in the dark concerning its anatomical substratum.

Finally, with regard to the facts gleaned from cases of tumour and abscess of the temporal lobe, in many such cases rough localisation has been determined by an epileptic aura of an auditory character, or by ringing or buzzing sounds in the ears, etc., but as means to the precise delimitation of the auditory area they possess little value.

C. The Anatomical Evidence.

In opening our remarks on the anatomical and histological evidence bearing on the localisation of the auditory area, it will be advisable to state briefly what the auditory neuronic chain consists of.

First, concerning the peripheral and lower neurones; the connections of these are of the greatest possible complexity, and much study has been needed for their unravelment; however, from the researches on degeneration carried out by von Monakow, Ferrier and Turner, and Wyrubow, the developmental studies of Flechsig and Bechterew, and those of von Kölliker, Ramón y Cajal, Held and others, on histological lines, we conclude that the elucidation of the course and connections of these lower neurones is now practically complete and that the track travelled by auditory impulses is as follows.

From the organ of Corti they pass along the cochlear nerve to the ventral and dorsal cochlear nuclei, the latter of which is better known by the name tuberculum acusticum. This constitutes the first link in the chain.

From here, some fibres of the second system of neurones are led, by way of the striae medullares or striae acusticae and corpus trapezoideum, to the superior olivary bodies on both sides and to nuclei in the trapezoid body; while others proceed, by way of the lemniscus lateralis, to the posterior corpora quadrigemina and the middle geniculate bodies.

Lastly, fibres leave these bodies to pass through the retrolentiform portion of the internal capsule and make their way along the corona radiata to the temporal cortex.

For proof of the correctness of this statement in so far as the two lower links in this chain are concerned the reader is referred to special works; here allusion need only be made to the upper link. As Barker remarks, no better demonstration of this section can be obtained than by an examination of foetal brains, and in the illustrations published by Flechsig, and by Cecile and Oskar Vogt, these fibres are indicated with unsurpassed clearness. I have already mentioned that these fibres pass out through the retrolentiform portion of the internal capsule, and I can now add that, according to Flechsig, they are divisible into two bundles, one of which ascends near the external capsule and gains the auditory cortex from the posterior and superior side, while the other courses for some distance in company with the occipito-thalamic radiations, and then passing behind and below the fossa Sylvii pierces the bases of the second and third temporal convolutions to gain the transverse temporal gyri. The information derived from a study of the times at which these fibres become myelinated is full of interest; in the first place the fibres to the auditory area become medullated later than those from the external geniculate bodies destined for the visual area; secondly Flechsig has proved that the fibres from the middle geniculate body proceed to the anterior transverse temporal gyrus, and as they become medullated before the fibres from the posterior quadrigeminal bodies, he believes that the same gyrus represents the cortical end-station of the cochlear nerve.

As to the exact limits of the cortical area to which these fibres traceable by embryological methods pass, Flechsig describes the field as consisting of the two transverse temporal gyri, particularly the anterior, and that division of the first temporal gyrus immediately adjacent, that is to say, the third and fourth fifths reckoned from its anterior extremity; and on inspecting his diagram, Tafel IV, Figur 7 (Gehirn und Seele), it is extremely satisfactory to find that the auditory area there figured agrees remarkably with that which I have defined on other lines.

The work on secondary degenerations by von Monakow, Ferrier and Turner, and Déjerine might be urged in favour of these findings.

We have next to consider the work of those who have attempted a subdivision of cortical areas according to structural peculiarities, but unfortunately the evidence obtained in this manner is quite fragmentary in character. For instance, localisation is not assisted to any extent by Hammarberg's work, because all that he tells us is that the structure of the superior temporal convolution differs from that of the remainder of the temporal lobe, inasmuch as the cells of the layer of medium-sized pyramids and ganglion cells are smaller, and isolated larger cells are present; of the recognition of definite areas there is no note.

Similarly, although S. Ramón y Cajal has supplied us with a fund of details on the fine histology of the individual elements of the temporal lobe, his work yields little or no information concerning topical variations. Also concerning the drawings reproduced by both Hammarberg and Ramón y Cajal we are given only a rough idea as to the position from which the sections represented were taken; Hammarberg merely states that his drawing is from about the middle of the first temporal gyrus, whether from the crown lip or side is not mentioned; and Ramón y Cajal's figure is vaguely described as having been taken from a section of the first temporal gyrus.

Also Kaes, who has examined the fibre-constituents in the cortex of all parts of the brain, does not give a clear account of the territorial differences in the temporal lobe, although he evidently recognised the exceptionally large association fibres in the transverse temporal gyri to which I have drawn attention.

Judging from the fruitful results which attended Bolton's examination of brains from cases of old-standing blindness, one would imagine that a similar examination of the transverse and superior temporal convolutions in cases of deaf-mutism and long-standing deafness of peripheral origin would prove equally profitable, but so far as I am aware this is a task which nobody has hitherto attempted, and the sole information which we can fall back on at present is the fact that in some cases of deaf-mutism the superior temporal gyri have exhibited a certain amount of atrophy to the naked eye. (Mills and Broadbent.) Of the importance of naked eye shrinkage, however, we have strong reasons for being sceptical, and I fear that the information demanded on this point cannot be forthcoming until serial sections of the auditory cortex, demonstrating the condition of both nerve cells and nerve fibres, are made[1].

Lastly, I have to refer to certain subcortical bands which are supposed to possess the function of uniting different parts of the temporal lobe with one another and with other cortical centres. Of such bands the fasciculus longitudinalis inferior seems to be the most important. It has already been alluded to in the chapter on the visual area, and probably constitutes a band of association between the auditory and the visual areas; at the same

[1] Since writing the above the brain of a man, aet. 40, who had been deaf from birth, has come into my hands, and I have taken the opportunity of examining the temporal lobe in serial sections. The results are most gratifying, because the sections stained with thionin show exquisite changes clearly concentrated on the gyri of Heschl, although distributed to a certain degree and extent over the "psychic" field of cortex, and the posterior insula.

A general disturbance of lamination, an absence of large pyramidal cells, and the predominance of numbers of round nucleated elements looking like nerve cells deprived of body substance and processes, are the prevailing features, and on the whole the changes closely resemble those I have seen and previously described in the post-central gyrus in cases of Tabes Dorsalis.

To this I might add, that what appear to be similar changes have been recently observed by Strohmayer in a case of Congenital Deafness, but unfortunately I have been able to procure only an abstract of his report.

time there is some lack of unanimity on this point. By another long band of fibres, the fasciculus longitudinalis superior, which has also been previously mentioned, the superior temporal gyrus is supposed to have connections with the insula and the inferior frontal convolution. Other fibres are said to pass to the opposite hemisphere, by way of the corpus callosum, and connect the auditory areas of the two sides; and lastly sets of short autochthonous neurones serve to bring different parts of the auditory area into relation, while others proceed to gyri in the immediate neighbourhood. But in the words of Barker, who has collected all the available data on these neurones, "a vast deal of research will be required before very definite statements concerning them can be made."

Conclusions and Considerations.

The first and perhaps the most firmly-grounded conclusion derived from this research is, that the area of cortex laid down for the primary reception of simple auditory stimuli is that which I have mapped out and described as mainly covering the transverse temporal gyri of Heschl.

The reasons for this conclusion are as follows: (1) Microscopic examination proves that the area possesses a type of histological structure entirely different from that of any other part of the temporal lobe; not only so, the type of arrangement of medullated nerve fibres is peculiar inasmuch as the fibres of large calibre, which are present in great abundance, have the appearance which has been noted elsewhere as characteristic of corticipetal fibres; that is to say, instead of descending in the radiary fasciculi and striking the white substance more or less at a right angle, they seem to issue from the white substance at an acute angle and then cross obliquely for some distance in the radiary zone, as if seeking one of the large nerve cells which constitute another distinguishing feature of this area. To these fibres therefore I attach great importance.

(2) If the area mapped out on embryological lines by Flechsig be compared with that which I have defined independently by an examination of the adult cortex, it will be found that the outlines of the two fields exhibit a singular agreement, an agreement which must be regarded as more than accidental; the reason why such a correspondence should exist is not far to seek, for, as we all know, Flechsig's area was determined by noting the field of impact of strands of fibres, which are of early development, and in suitable fœtal brains may be seen streaming out from the median geniculate bodies and posterior corpora quadrigemina, and traversing the white substance in the direction of this special field of cortex.

Judged by their developmental peculiarity, by their degenerative reactions, and by their peripheral connections, there seems to be no doubt that these fibres represent the uppermost link in the chain of auditory neurones.

It is equally probable that the fibres which I have recognised in the cortex of this region, and by the presence of which it has been possible for me to map out a definite area, in both the human and the anthropoid brain, are the cortical continuations of the fibres which Flechsig's embryological studies have displayed.

So that just as in the central visual apparatus we find fibres in band form, acquiring their medullated sheath at an early date, restricted in their distribution to a limited area, namely, the walls and lips of the calcarine fissure, an area further characterised by the

possession of a specialised cell lamination, so also in the central auditory mechanism we find a similar tract of fibres limited in its distribution to the transverse temporal gyri of Heschl and their immediate neighbourhood, a part also containing cell-elements differing from those found in any other temporal convolution. In the case of the visual function, valid reasons have been produced for assuming that the restricted calcarine area is that to which sight stimuli primarily pass; and since in the area of cortex believed to preside over audition, we have an arrangement which from the anatomical point of view is closely homologous, the deduction necessarily follows that the restricted transverse temporal area is the part of the temporal lobe on which auditory stimuli first impinge.

(3) If the assumption be correct that this area forms the arrival platform of auditory stimuli, it of necessity follows that total deafness should attend either its bilateral obliteration or a bilateral interruption of the system of fibres leading to it. It is to be regretted that the clinico-pathological evidence which we are able to adduce on this point is not so sufficing and convincing as it might be. The hindrances to the obtainment of the necessary information are again of an anatomical character, for in nature we have to depend on obstructive vascular lesions, tumours, subcortical haemorrhages and the like, to supply us with our focus of destruction: but unfortunately a destructive process which will comply exactly with localisation in regard to extent must be looked upon as an anatomical rarity, and it is vain to hope that by a happy combination of circumstances such a case will fall into the hands of one competent to report on it, both clinically and anatomically.

Since cases showing the lesion we desire are denied to us, we are obliged to fall back on cases which approximate thereto, and for support on my point I have gone through the reports of five instances recorded in the literature of cases of complete cortical deafness followed by an autopsy. And although the anatomical accounts of some of these cases do not contain all the details one desires, the broad fact remains that in all, more or less widespread bilateral lesions existed, having the hinder part of the superior temporal convolution as a centre; again, although it is not always stated that the transverse temporal gyri were involved in the destruction, still observations to the effect that neighbouring parts, like the insula, the supramarginal gyri, or the opercular part of the ascending parietal convolutions, were included in the loss of substance, render it likely that this was the case.

It is also unfortunate that the experiments which have been recorded do not assist to any appreciable extent in enabling us to arrive at a definite conclusion on this point, but, as already indicated, I think that if those experimenters who attempted to ablate the auditory area had centred their operation on a destruction of the transverse temporal gyri the results would have been less contradictory.

Likewise no evidence one way or the other is to be obtained from a study of cases of unilateral lesions of the special area under consideration, for here again opinions differ. However, since an examination of published cases of unilateral lesions shows that those in which a bilateral dulling of the sharpness of hearing was noted outweigh those in which complete contralateral deafness has been reported, I am inclined to follow writers who believe that each cortical auditory centre is connected with both ears and that an arrangement exists analogous to that which obtains in the case of the visual apparatus. Although it is difficult, almost impossible, to prove that one centre is more directly concerned with the reception of stimuli from one ear than the other, yet the possibility of a preponderant crossed association is not to be lost sight of; if, however, this crossed association be absolute,

as some assume, it may be taken for granted that more proved cases of complete one-sided deafness in consequence of a contralateral temporal lesion would have been reported, but as it is, the paucity of such cases and the unreliable nature of the few that have been published is a weighty negative point against that assumption.

Leaving the transverse temporal gyri we have now to deal with the question of the existence of a second centre, specialised for the interpretation and further elaboration of primary stimuli; and in the next few lines I shall indicate not only that such a centre probably exists, but that in all likelihood it is distributed over the area already described as forming a skirt for the audito-sensory area. Now the truth that this field possesses a special structure resembling but not identical with that of the audito-sensory cortex, and one which makes it readily distinguishable from that of more outlying parts, seems to me to be one of the strongest reasons for supposing that it is endowed with a specific function; and since in our examination of the visual, and also of the motor area, we found that the primary centre was invested or fringed in a similar manner by a belt of cortex to which we assigned psychic properties, so also in the case of the auditory area it should not be considered a transgression of the bounds of ordinary possibility to assume that the investing field has a psychic function.

Without an inspection of numerous sections stained by the method of Golgi and other processes, a task which I have been unable to undertake, as all my time has been occupied in studying the cortex from the topographic standpoint; also without an examination of the brain in favourable cases of deaf-mutism, and under conditions in which an interference with the chain of auditory neurones somewhere in its central course has given rise to degeneration, or retrograde atrophy, of the nerve fibres leading to the auditory area and the cortical cells with which they form connections, it would be premature to offer any statement concerning any special elements in this investing field of cortex, which may be singled out as bearing a direct relation to the psychic function; at the same time it may not be out of place to note some of the probabilities which the appearances presented by my sections suggest.

In referring to the outstanding histological characters of the cortex covering the transverse temporal gyri, I have mentioned that an homologous structure exists in another sensory centre with the histology of which we are more familiar, namely, the visual. The question then arises whether the homology can be extended to the investing or audito-psychic area, and I think it can: for just as in the visuo-psychic area, the large, deeply-placed, oblique fibres lose in prominence, so it is in the audito-psychic; and just as in the visuo-psychic area the fibres of large calibre tend to be incorporated in the radiary fasciculi and the whole interradiary field shows a fibre-wealth which is infinitely greater than that of more outlying parts, so it is also in the audito-psychic area. But when we come to a comparison of the cell-arrangement, the homology is not so satisfactory; for although the large supra-stellate pyramidal cells, which I look upon as possessing a special significance, are on the whole markedly larger and possess a different form and staining reaction from the same cells in more outlying fields, they do not stand out so prominently as the large cells noted in the visuo-psychic area; nor again is the general cell-arrangement very different from that met with in the transverse temporal gyri; however, it must be noted that scattered along the external layer of large pyramidal cells there do exist cells of outstanding size,

which may possibly be homonymous with corresponding cells in the visuo-psychic area, and it is possible that they have an analogous function.

Unfortunately, neither in S. Ramón y Cajal's work, nor in any other publication that I know of, is allusion made to topical differences in the histological structure of the external temporal gyri, so that we can look for no help in this direction; for the present we must rest content with hypothesis, hoping that the cortical findings in cases of peripheral deafness may throw further light on the question.

From the clinical and experimental sides also grounds are not wanting for inferring that there exists a separate audito-psychic area, for in spite of the divergent opinions concerning the results of operative measures in this region, we can quote Munk's classical experiments to the effect that removal of a small circle of cortex from the centre of the auditory sphere as defined by him in the dog, produced what he called "mind-deafness"; we also have Larionow's experiments showing that minor destructive lesions in the auditory area give rise to a loss of appreciation of single tones without interference with common hearing. Then, in the human being, we know, first, that limited lesions of the superior temporal gyrus occasion slight functional disorder, which is dependent upon some degree of psychic disability more than upon actual dulling of acuity of hearing; and, secondly, we can point to the well-known clinical phenomenon of "word-deafness," which more than any other must be due to the obliteration of a psychic realm, and which can yet exist in company with undiminished common audition.

On these grounds therefore the existence of a special audito-psychic area, located apart from the common audito-sensory area, can hardly be gainsaid, and I submit that the second histological area which I have drawn attention to represents the limits and extent of this field.

Taking for granted the correctness of the assumption, that the existence of a separate psychic area has to be taken into account, the next point arising for discussion is the degree of representation of that function in the two hemispheres. Are we to believe that the psychic function is equally represented in the two halves of the brain, or has that in the left half a dominant operative capacity? As regards the interpretation of ordinary sound stimuli (spoken words are of course excluded here) our clinical and physiological experience leaves little doubt that both hemispheres are equally active, and that just as ordinary visual stimuli are being constantly received and interpreted in both occipital lobes with equal facility, so it is also with ordinary auditory stimuli; but when we come to consider the question of the interpretation of spoken language it is another matter, for so many cases are on record which seem to prove that the left hemisphere is specially endowed or educated for this purpose that it is fruitless to deny its superiority. At the same time although clinical facts make it obvious that the left hemisphere is mainly adapted for the interpretation of language, it can hardly be maintained that in this respect it is entirely independent of the right hemisphere, because in the only cases of unmixed, complete, and lasting word-deafness on record the lesion has been bilateral; also cases of word-deafness have been met with in which the lesion has been confined to the right hemisphere; furthermore—and this is a very important point,—in those cases of word-deafness resulting from a lesion in the left hemisphere, neither has the disability ever been described as having been definitely total, nor have indications of partial recovery ever been wanting, and surely it is logical to infer that the faculty of interpreting spoken language, although dominant

in the left hemisphere, is not wholly confined to that side, and that the incompleteness of the disability, and possibly also some of the apparent recovery, is due to the fact that the intact right hemisphere has to some extent shared the special education.

On the question of the separate cortical localisation of a "word-hearing" centre in the left gyrus angularis histology affords negative information; for although I have subjected both hemispheres to examination I have been unable to detect any appreciable difference in the two sides, either in regard to the arrangement of nerve fibres or nerve cells. Similarly concerning a differentiation of the auditory area in correspondence with other faculties, such as the recognition of tones of high and low pitch and of musical sounds, histology cannot be of any assistance until more guiding clinical data are forthcoming.

REFERENCES.

1. Pick. Beiträge zur Lehre von den Störungen der Sprache. *Arch. für Psychiatrie*, Bd. XXIII und XXVIII.
2. Anton. Ueber die Selbstwahrnehmung der Herderkrankungen des Gehirns bei Rindentaubheit. *Arch. f. Psych. u. Nervenkrankh.*, Bd. XXXII, 1899.
3. Sérieux et Mignot. Cortical Deafness with Paralexia and Auditory Hallucinations in consequence of Echinococci in the Brain. Abstract in *Neurolog. Centralblatt.*, p. 495, 1901.
4. Mills. *Brain*, p. 468, 1891.
5. Kaufmann. Quoted by Ferrier. *Berlin. klin. Wochenschr.*, p. 541, 1886.
6. Ferguson. *Journ. Anat. and Phys.*, p. 292, 1890.
7. Lichtheim. Ueber Aphasie. *Deutsch. Arch. f. klin. Med.*, Bd. 36.
8. Sérieux. *Revue de Méd.*, p. 733, 1893.
9. Déjerine. Contribution à l'étude anatomo-pathologique et clinique des différentes variétés de cécité verbale. *Mém. de la Soc. de Biologie*, 1892.
10. Munk. Ueber die Fuhlsphäre der Grosshirnrinde. *Sitzungsber. d. k. pr. Akad.*, 1893—1896.
11. Luciani e Tamburini. Sui centri psico-sensori cerebrali. *Rivista sperimentale*, 1879.
12. Seppilli. *Rivista sperimentale di Freniatria*, Vol. x, 1884.
13. Goltz. Ueber die Verrichtungen des Grosshirns. Bonn, 1881.
14. Ferrier. The Functions of the Brain. London, 2nd edition. See also Article on Regional Diagnosis of Cerebral Disease, in Clifford Allbutt's *System of Medicine*.
15. Schäfer. Experiments on special localisation in the cortex cerebri of the monkey. *Brain*, 1888.
16. Larionow. Ueber galvanometrische Messungen der Ströme in der Rinde der Schläfenwindungen bei Reizung der peripherischen Gehör-organe. Abstract in *Neurolog. Centralb.*, p. 767, 1899.
17. Larionow. Ueber corticale Gehörscentren bei Hunden. Abstract in *Neurolog. Centralb.*, p. 137, 1898.
18. Wernicke and Friedländer. Ein Fall von Taubheit infolge doppelseitiger Läsion des Schläfenlappens. *Fortschr. der Med.*, I, No. 6, 1883.

19. Déjerine et Sérieux. Un cas de surdité verbale pure terminée par aphasie sensorielle suivi d'autopsie. *Compt. rend. de la Soc. de Biologie*, Dec. 18, 1897.

20. Miraillié. De l'aphasie sensorielle. *Travail du laborat. du Dr Déjerine.* Paris, 1896.

21. Edgren. Amusie (musikalische Aphasie). *Deutsche Zeitschr. f. Nervenheilk.*, Bd. VI.

22. Thomas. Les terminations centrales de la racine labyrinthique. *Compt. rendus de la Soc. de Biol.*, 1898.

23. Liebenmann. Ueber die centrale Hörbahn und ueber ihre Schädigung durch Geschwulste des Mittelhirns, speciell der Vierhügelgegend und der Haube. *Zeitschr. f. Ohrenheilk.* Wiesbaden, 1896.

24. Weinland. Quoted by Ferrier. *System of Medicine.* Allbutt.

25. Beevor and Horsley. On the Pallio-tectal or Cortico-Mesencephalic System of Fibres. *Brain*, p. 436, Winter, 1902.

26. Bastian. Aphasia and other Speech Defects. Article in Clifford Allbutt's *System of Medicine.* 1901.

27. Triwus. *Neurol. Centralb.*, p. 991, 1900.

28. W. Strohmayer. Anatomische Untersuchung der Hörsphare beim Menschen. *Monatschr. f. Psych. u. Neurol.*, x, 1901.

CHAPTER VII.

LIMBIC LOBE.

CONSTRUING the word limbic in the wide sense given it by Broca, I shall now describe the cortical structure of the various subdivisions which comparative anatomy and other studies have suggested as constituents of Broca's "grande lobe limbique." In this conception of the lobe the following parts are embraced, the olfactory lobe, the whole gyrus hippocampi (including the dentate gyrus, uncus, and pyriform lobe), the entire gyrus fornicatus, and other subsidiary structures which will be referred to in the course of our description.

Chiefly from studies in comparative anatomy the conclusion has been arrived at that certain portions of the limbic lobe govern the olfactory sense; it has also been assumed, on less secure grounds, that other portions preside over the sense of taste, but whether the whole limbic lobe subserves these functions, and exactly how the functions are distributed, are still unknown. However, as we possess more knowledge regarding olfactory than gustatory localisation, I shall open my remarks with an account of the cortex which in all probability governs the former sense.

It is not my intention to deal with the structure of the olfactory bulb and peduncle, as this is a part of the olfactory apparatus which has received thorough attention at the hands of many other observers, but it will be useful for future guidance to give a brief outline of the apparent destination of the various sets of fibres arising from cells in the olfactory bulb and proceeding in the olfactory peduncle towards the brain. The distribution of these fibres has been studied chiefly in lower animals, but we have no reason for believing that the arrangement is not homologous in man, and the fibres may be described as issuing in three sets.

(1) One fasciculus passes deeply beneath the mesial root to gain the anterior commissure and proceed to the opposite hemisphere.

(2) Another set enters the mesial root and soon sinking into the cortex splits up to gain the following parts, (*a*) the grey substance of the trigonum olfactorium (Calleja) (a part rudimentary in man but well-developed in many other mammalia and known as the tuberculum olfactorium or tubercle of the olfactory tract), (*b*) the gyrus subcallosus and anterior or pregenual part of the gyrus fornicatus, (*c*) the area parolfactoria of Broca, and (*d*) the septum pellucidum.

(3) The third set passes along the lateral root and sinks into the anterior end of the lobulus pyriformis (Ramón y Cajal) to form connections with cells to be described hereafter. According to Flechsig these fibres end in the superficial large cells here situated, but according

to Ramón y Cajal, while they break up into collaterals in this superficial part of the cortex, the impulses they convey proceed further to the deep pyramidal cells, *viâ* the long apical shafts of these cells. Barker is of opinion that these fibres are principally destined for the gyri semilunaris et circumambiens of Retzius, but he does not support his statement with strong reasons, and as I shall show later he seems to overestimate the importance of the gyrus semilunaris.

Ramón y Cajal attributes no importance to the second set of fibres above-mentioned, nor does he consider the occasional middle root proceeding to the tuberculum olfactorium of any consequence. In his opinion the lateral root is of main importance.

Structure of the Cortex covering the Lobus Pyriformis.

The cortex of the Lobus Pyriformis is rightly regarded as the chief destination of the lateral olfactory root, and although in its passage backwards this root first comes into relation with the posterior olfactory lobule or anterior perforated space, we need not discuss this crossway seriously, because in the human brain the surface is so broken up by entering blood-vessels and a confusion of strands of fibres that it can hardly be described as cortex[1]; a little further back, however, where the root strikes the inner edge of the tip of the temporal lobe, there exists a fissuret coupled with the name of Zuckerkandl and known as the "scissura limbica," or "fissura rhinica." This fissuret will call for further remarks when we discuss the comparative anatomy of this region; here I desire to mention that for the histologist it constitutes a most valuable and important landmark, for on studying the cortex of this part in a series of transverse, or better still, horizontal sections, it may be seen that while that anterior to the fissura rhinica resembles the common temporal type, that behind it is entirely different, and in fact exhibits the type of formation which I now wish to describe in detail.

Type of Fibre-Arrangement. (Plate XVII, Figure 1.)

The superficial fibreless layer calls for no special comment.

The zonal layer is well-developed and composed of a dense band of fine and coarse varicose fibres, and it is important to notice that it is joined by numerous fibres which are continuous with the radiations of Meynert. We have seen fibres running into the zonal layer elsewhere and referred to them under the name of fibres of Martinotti, but I may here affirm that in no part of the brain are such fibres so numerous as in this region.

In describing the cell lamination of this part I shall have occasion to mention that curious groups or nests of cells are to be found on the surface of the cortex at the point where the plexiform and small pyramidal layers join, and in sections stained for nerve fibres it may be seen that circular areas, sparsely supplied with fibres, mark the position of these nests; it may further be noticed that the upward continuations of the radiations are forced to circumvent these clusters in their passage to the zonal layer, and the resulting appearance is very curious and unusual.

[1] This is the part which in certain lower animals stands out prominently and is called the tuberculum olfactorium; in such brains it has a more definite structure, being characterised, as Calleja and Ramón y Cajal have pointed out, by curious islets of nerve cells, but in man its structure is certainly rudimentary.

The line of Baillarger is a broad one, but it does not contain any fibres of large calibre; the elements present have an irregular course and do not tend to run so parallel to the surface as one would expect.

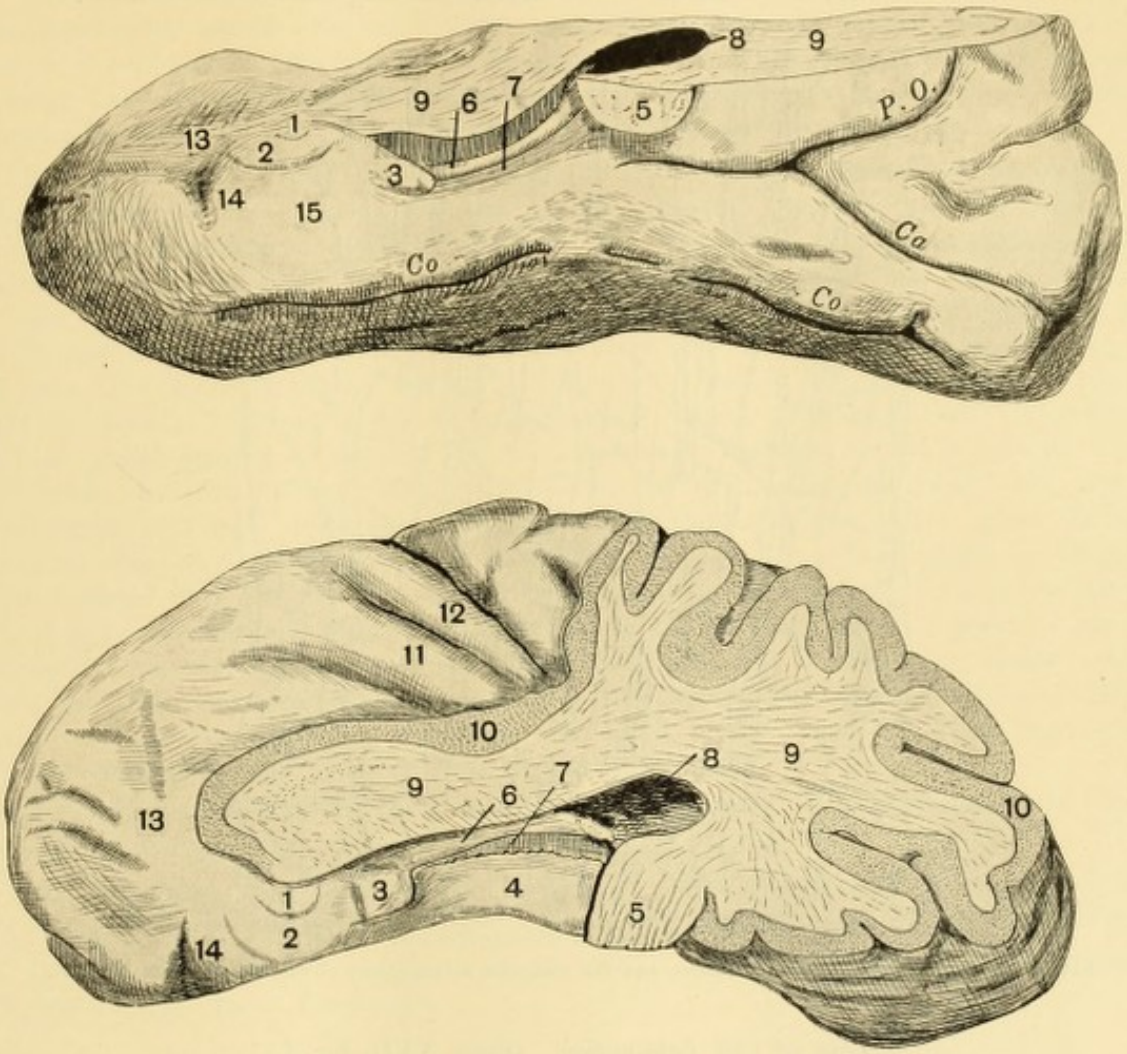

Fig. 16. Drawings to explain some anatomical points in the hippocampal area alluded to in the text. They show the inner and cut surfaces of a hemisphere from which everything above the level of the temporal lobe and cuneus has been removed. 1. Gyrus semilunaris. 2. Gyrus circumambiens. 3. Uncus. 4. Wall of fissura hippocampi (subiculum). 5. Corpus callosum. 6. Fornix. 7. Dentate gyrus at bottom of fissura hippocampi. 8. Ventricle. 9. Cut white matter. 10. Cut cortex. 11 and 12. Gyri of Heschl (transverse temporal). 13. Upper concealed surface of temporal lobe. 14. Groove representing the fissura rhinica. 15. In centre of lobus pyriformis. *Co.* collateral, *Ca.* calcarine, and *P.O.* parieto-occipital fissure.

The projection fibres of Meynert are not arranged in such composite bundles as in other parts, and many individual stragglers are to be seen. In form the constituent fibres are cylindrical and free from varicosities, and in point of size they do not approach those which we have already seen in the motor and visual cortex; and again I would state that these

fibres pierce the line of Baillarger and supraradiary layer and have intimate connections with the zonal layer. (Text-figure 17.)

There is not a dense interradiary plexus and the fibres of the association system are few in number, medium in size, and confined to the depths touching the white substance.

FIG. 17. Radiary zone in lobus pyriformis. $\times \frac{85}{1}$.
Note the absence of fibres of large calibre and the straggled arrangement of the radiations of Meynert.

Type of Cell Lamination. (Plate XVII, fig. 2.)

The plexiform layer is of unusually great depth, and a remarkable arrangement is found at the point where it should give way to the layer of small pyramidal cells. Practically none of the last-mentioned elements can be identified, their place being taken by curious cell nests or groups, which give a bizarre appearance to the cortex and require careful description. Two different varieties of nests exist: the more prominent are made up of large elements, called by S. Ramón y Cajal polymorphous giant cells, and alternate with the lesser groups, made up of small cells pyramidal in form. Taking the large polymorphous cells first, it is found that they have an average diameter of 28 μ; they favour a stellate form, and show four or five thick processes issuing in all directions. The nucleus is small and located near the centre of the body. Any chromophilic elements which they may possess are of small size, and do not give depth of colour to the body in Nissl preparations. The cells forming the

intervening nests are of such small size that it is impossible to make much of their intimate structure, and the only point we need note about them is that they are much more numerous than the large cells.

The presence of these superficially-placed cell nests has been recognised by several other neuro-histologists, notably Ramón y Cajal and Hammarberg; the former gives an excellent account of the appearances presented by the two varieties of cell when treated by the method of Golgi, and furthermore attaches such functional importance to the area over which the formation is distributed that he distinguishes it by the name "regio olfactiva[1]."

Passing on to the next layer we search in vain for the medium-sized pyramidal cells which characterise other regions, and also a layer of giant pyramidal cells is wanting, the place of these two laminae being filled by a deep stratum of cells of approximately equal size, having an average diameter of 20—25 μ and belonging to neither of the above classes. As seen in Nissl preparations these cells are distinctly pyramidal, with an elongated apical process and two or more short basal dendrites; the chromophilic elements are not large, at the same time the body plasma accepts the stain fairly readily, and on this account the cells stand out plainly. The nucleus is of ordinary size. Another feature of some importance is that the apical process, as often as not, points obliquely upwards instead of directly towards the surface, and this coupled with their staining reaction makes one think that they are homonymous with cells which one finds at a similar level throughout the gyrus fornicatus. But from Ramón y Cajal's researches it appears that the true morphology of these cells is not revealed until they are impregnated with silver by the method of Golgi, for when so treated it is seen that the basal dendrites break up into an extraordinary number of processes and hang down very much after the manner of a tassel, and judging from Ramón y Cajal's figure the name tassel cell (Quastzellen) seems very appropriate; another noteworthy feature is that while a few collaterals issue from the apical process, none are to be seen coming from the sides of the cell body, which is distinctly unusual.

Following on this lamina is a pale strip corresponding in position with the line of Baillarger and almost bare of nerve cells.

We next come to a layer of large fusiform or triangular cells which are chromophilous and in many respects similar to cells which will be described at length in the prelimbic cortex.

Beneath this layer and partly mixed up with it are numbers of typical small fusiform cells requiring no special description.

Distribution of the above-described Type of Cortex. (Plate I.)

Writers on comparative anatomy have shown us, that in animals with a well-developed sense of smell the anterior end of the gyrus hippocampi swells into a large pear-shaped lobe, which they have designated the lobus pyriformis; and this lobe is separated from the temporal pole by a deep and extensive fissure, which they call the scissura limbica or fissura rhinica. Now I have already alluded to the existence in the human brain of a comparatively

[1] Flechsig has also recognised these cells and regards them as the termini of the fibres of the lateral olfactory root. He further mentions that they agree in structure with the cells of the stratum cellularum pyramidalium of the cornu ammonis, and indeed are a lateral extension of that lamina. With this statement I was inclined to agree until I read Ramón y Cajal's work, which, with later observations of my own, has convinced me that Flechsig is wrong on both issues (see pp. 176 and 181).

rudimentary fissura rhinica (present according to Zuckerkandl in 86 per cent. of human brains); I may further mention that in man the homologue of a lobus pyriformis has long been recognised; and I would here say that the distribution of the histological area bearing the type of cortex just described is closely determined by the extent and limits of this lobe, but with two exceptions, the account of which must be prefaced by an anatomical explanation (see figure 16).

First, Retzius, of Stockholm, has pointed out that on the upper part of the human pyriform lobe there exists a small, shallow and apparently insignificant sulcus of crescentic form with the convexity pointing upwards; this he names the sulcus semilunaris, the small stretch of substance between it and the anterior end of the hippocampal fissure he calls the gyrus semilunaris, and the larger, laterally-placed and more prominent part investing the gyrus semilunaris he designates the gyrus circumambiens. Satisfied as to the constant presence of these small gyri I have paid special attention to the microscopic characters of the part, and my conclusion is that while the gyrus circumambiens forms a portion of the hippocampal area, the smaller gyrus semilunaris is to be excluded. My reasons are as follows: its surface structure is of quite a special kind and bears little resemblance to cortex; the nerve fibres it contains are arranged in all ways, chiefly in irregular whorls; the nerve cells are all of small size, irregular in shape and scattered about in an aimless fashion, indeed they suggest the appearance seen in the basal nuclei rather than that of cortex; and lastly, none of the superficial cell nests which we must regard as essential constituents of the hippocampic cortex are discernible. On the whole I am inclined to believe that this gyrus semilunaris is nothing more than the surface projection of the subjacent nucleus amygdalaris.

The second exception to which I have to refer is the cortex of the uncus proper, and by the uncus proper I mean the small, free projection known as the gyrus Giacomini, which is divided from the gyrus circumambiens by the annular band of fibres representing the anterior extremity of the gyrus dentatus (Luschka, Giacomini). This free projection contains cells like those to be described in the cornu ammonis, and hence has to be excluded from the area under consideration.

So much then for the anterior extent of this area: let us next turn to the lower border. In describing this, notice has to be taken of some anatomical points bearing on the collateral fissure; and following those who recognise three different constituents in this fissure, an anterior, a middle, and a posterior portion, I would state that the anterior portion, or rather that part of it which lies below the lobus pyriformis, is an important and constant boundary for our area; behind this the lower limit gradually slopes upwards, and while at first the line may touch the middle division of the collateral fissure it soon leaves it to pass obliquely across the gyrus hippocampi, and making for the anterior extremity of the calcarine fissure it is there arrested by coming into contact with the visuo-psychic area; or the area may be described as coming to a point and terminating on the isthmus of the gyrus fornicatus.

As to the sharpness of this boundary, I may say that the superficial islets of large stellate cells lose in distinctness, the arrangement of fibres begins to assume a common temporal appearance, and the chromophilic deeply-placed cells undergo a reduction in number as the lower border is approached; hence the change from the hippocampal to the common temporal type is not abrupt.

It only remains for me to describe the extent of this type of cortex in the upward direction, that is in the direction of the fissura hippocampi. The determination of this limit

is no easy matter. At first I was doubtful whether or not to extend it to the floor of the fissura hippocampi, but as the fissural or subicular portion of the hippocampus shows certain peculiarities of structure I have decided on a subdivision of the area; this differentiation will be found to be in accord with Ramón y Cajal's observations, and the dividing line lies along the lip of the hippocampal fissure and corresponds with the periphery of the thick superficial layer of nerve fibres known to histologists as the lamina medullaris externa, or lamina medullaris involuta. This leads up to an account of the fissural cortex of the hippocampus.

CORTEX OF THE FISSURA HIPPOCAMPI.

Arrangement of Nerve Fibres. (Plate XVIII, fig. 1.)

By far the most important feature of this region is the extraordinary development of the zonal layer, giving rise to the dense and thick lamina medullaris externa just alluded to. Thickest at the floor of the fissure where it is in contact with the alveus, this lamina gradually loses in depth as it creeps upwards, and soon fades away after crossing the lip and reaching the free surface of the gyrus. In the subjacent cortex it is impossible to define the usual layers; it is all richly filled with fibres interlacing and intertwining in every direction, and it is divided into panels by broad pillars or bands of fibres which extend from the outer lamina to the white substance, bands which might be the equivalents of the projection bundles of Meynert.

From the general trend of fibres in this part it is evident that it has intimate connections with the area last described and also with the cornu ammonis.

Cell Lamination. (Plate XVIII, fig. 2.)

Two features characterise the cell lamination of this part: one is the presence of curious independent islets of minute cells in the plexiform layer, and the other is the distinctive arrangement and appearances of the deep layer of large pyramidal cells.

The islets find a place in the extremely deep plexiform layer and are composed of a hundred or more minute, deeply-stained, triangular cells with a diameter of about 5 μ. These extraordinary cell-groups are not numerous, only two or three being visible in each section, and there appear to be more of them in the anterior part of the area than in that adjoining the splenium. What lamina they represent it is impossible to say, unless they are the equivalent of the layer of small pyramidal cells.

The nests of large polymorphous cells noted in the last region examined are not discoverable; at the same time in parts of the area one does see a few cells which, as far as one can judge from Nissl specimens, belong to the large polymorphic variety; and they are occasionally converted into groups by the broad bands of medullated nerve fibres which unite the lamina medullaris and the white substance.

As for the rest of the cortex it is occupied by one deep layer of rather large pyramidal cells, pyramids which are elongated in form and have a particularly long apical process; being arranged in regular parallel rows, the layer they form has accordingly been given the name "*stratum radiatum.*" Traced in the central direction this layer seems continuous with the prominent layer of pyramidal cells which is to be found in the cornu ammonis, and at first

sight it might be supposed that the two sets of cells are identical; but closer inspection proves this to be incorrect, for the cells of the subicular region not only differ in form, being much longer, but the body is distinctly smaller, also the substance of the cells stains much more intensely, and the nucleus is smaller.

Distribution.

Being coterminous with the cortex of the lobus pyriformis on the one hand, and with that of the gyrus dentatus on the other, the distribution of this type of arrangement is best described as covering the wall and lip of the fissura hippocampi. It only remains to be observed that in the posterior direction it continues well up behind the splenium, there to join the post-limbic cortex; and concerning the latter, it is important to mention that it also is characterised by a remarkably deep and well-developed zonal layer, especially in the immediate neighbourhood of the corpus callosum.

STRUCTURE OF THE GYRUS DENTATUS.

The structure of the invaginated cortex of the gyrus dentatus has been studied carefully by various histologists, and a faithful account of the curious arrangement of its contained elements is to be found in any text-book of histology, hence there is no necessity for me to describe it at length. I need only mention that the most important elements in this region are unquestionably the large pyramidal cells to which I have already briefly alluded, and that the minute cells of the well-known stratum granulosum constitute a remarkable but less important feature.

One or two points of interest concerning the distribution of the curious large pyramidal cells must be mentioned. In the first place, inspection of serial sections shows that they extend all along the part known to anatomists as the gyrus dentatus; then in the anterior direction, as I have already indicated, such cells find a place in the substance of the recurved uncus proper; posteriorly also they have an interesting distribution, for they do not end in the subsplenial part of the gyrus dentatus, but are continued round the splenium corporis callosi, and gradually becoming reduced in numbers and also in size they finally seem to pass on into the striae longitudinales mediales.

STRIAE LONGITUDINALES MEDIALES OR NERVI LANCISII.

I include a reference to these striae, not because of any supposed functional value they possess, but on account of the supposition that they represent the undeveloped remains of what is cortex in the brains of osmatic animals[1].

In the human brain transverse sections show that the cortex of the gyrus fornicatus is continued in the mesial direction over the surface of the corpus callosum in the form of an exceedingly thin lamina known to anatomists as the indusium griseum; at the angle of junction a slight and unimportant elevation composed of nerve fibres, the ligamentum

[1] From Zuckerkandl and other comparative anatomists we learn that these striae are the relics of two superadded gyri arranged concentrically round the corpus callosum, between it and the gyrus fornicatus; the first of these placed on the dorsum of the corpus callosum is called the gyrus supracallosus, and it is said that with the naked eye it may be seen to be continuous with the gyrus dentatus; the second envelops the genu, it is known as the gyrus geniculi, and is said to be connected with the septum lucidum.

tectum or stria longitudinalis lateralis, may be seen, but the larger elevation of the indusium forming the stria medialis is found nearer the middle line, and is that with which we are concerned.

A microscopic examination of these mesial striae is not devoid of interest; we find that for groundwork they have a band of longitudinally directed medullated nerve fibres of medium size, upon which rests a strip of curious nerve cells. The presence of these cells was chronicled years ago by Valentin, and they have since been described by Ramón y Cajal and others. In Nissl specimens they appear as medium-sized pyramids with short processes, and they are arranged in an irregular manner and poorly supplied with chromophilic elements; serial sections prove that posteriorly they can be traced round in continuation with the layer of pyramidal cells in the dentate gyrus[1]. The latter connection appears to be of some importance, because one can think of no cells with which these can be homologous except those of the gyrus dentatus, and a certain resemblance in shape and staining reaction gives colour to the idea that they form part of one original deposit of cell-elements, altered in position by the growth and expansion of the corpus callosum. Followed in the frontal direction the cells of these striae, after showing a gradual reduction in size, cease at about the middle of the corpus callosum, but although the cells disappear, the band of fibres still continues and can be plainly traced round into the septum lucidum, further than which I have made no attempt to follow it[2]. It seems therefore that this forward extension represents the rudiments of the gyrus geniculi, just as the hinder part is the equivalent of the gyrus supracallosus.

PEDUNCLE OF THE CORPUS CALLOSUM—GYRUS SUBCALLOSUS OF ZUCKERKANDL.

Having completed our study of the cortex of the hippocampal portion of the "grande lobe limbique" we will now turn to a consideration of the small field of substance into which the mesial root of the olfactory nerve seems to penetrate, viz., the peduncle of the corpus callosum, and finally we shall discuss the structure of the gyrus fornicatus.

By the peduncle of the corpus callosum is meant that strip of substance which is bounded above and behind by the rostrum, in front by the upper extremity of the shallow fissura prima of His, and which broadening as it descends terminates at the base of the brain, behind the anterior perforated space. Histologically its structure suggests that it is an undeveloped area.

In the part immediately underlying the rostrum a strongly developed zonal layer is seen streaming out from the striae longitudinales mediales for a distance of 3 or 4 mm., but in other parts of the surface this layer is feebly represented.

The supraradiary layer is poor in nerve fibres.

A line of Baillarger cannot be distinctly defined, but in the position which it usually occupies, and also above and below it, there is a fair number of small or medium-sized fibres apparently derived from the mesial olfactory root.

[1] Other observers (Giacomini, Golgi, Ramón y Cajal) have traced fibres pertaining to these striae to the fascia dentata, but whether the hippocampus represents their origin or their termination is not known. The fibres of the external striae also probably end in the dentate gyrus (Zuckerkandl, Ramón y Cajal).

[2] Blumenau, Déjerine, and Ramón y Cajal give these fibres a similar distribution, and it seems not improbable that they establish connections with the fibres of the inner olfactory root.

The radiations of Meynert do not form composite bundles but leave the white substance in a more or less continuous extended line.

The association system of fibres and interradiary plexus are not well represented; in short the general fibre-wealth of the part is much below par, the general plan of arrangement is upset, the cortex altogether is shallow, and no fibres of large size are to be found.

As to nerve cells general mal-representation is again evident.

A plexiform layer is recognisable, but the remaining cortex is made up of a continuous lamina of rather closely-packed, irregularly arranged, medium-sized pyramidal cells, not unlike those to be noted as occupants of the third and fourth layers of the gyrus fornicatus above the corpus callosum, only smaller, not so deeply stained, and especially indistinct as regards their processes. In the depths of the cortex there are just a few intensely-stained elongated pyramidal cells similar to cells to which I shall presently make special reference.

As we pass towards the base of the brain the surface structure of this gyrus gradually loses the appearance of cortex.

The small olfactory area of Broca lying immediately internal and anterior to the mesial olfactory root is covered by an undeveloped type of cortex like that described above, and its fibre-arrangement is broken up by offshoots from the root.

GYRUS FORNICATUS OR GYRUS CINGULI.

I have found that the structure of the gyrus fornicatus can be most conveniently studied in a series of sections extending in radiate fashion from the corpus callosum to the margin of the hemisphere. Such sections show the structure of the gyrus in question and the more peripheral convolutions lying side by side; and when those sections, stained for nerve fibres, which pass through the paracentral lobule and allow of a contrast between the dense and deeply stained motor and the pallid fornicate cortex, are inspected, it will be granted immediately that the latter is deserving of separate representation on a cerebral map.

Arrangement of Nerve Fibres. (Plate XIX, fig. 1.)

Perhaps the chief distinguishing feature of this type of cortex is that it contains absolutely no large evenly-medullated fibres like those seen in the central convolutions and calcarine region, and indeed practically none of medium calibre; they are all fine and wavy, and in most cases varicose, hence the pallor of the cortex when compared with that of adjoining fields. It is also to be noted that this region does not present the bizarre features seen in the hippocampus.

The zonal layer, as might be expected, is sparsely supplied and indistinct; the supraradiary field is fairly rich in fibrils running in all directions; a line of Baillarger can always be made out, but it has no striking constituents; the radiations of Meynert lack solidity on account of the absence of large fibres, but they contain an abundance of wavy fibrils; (Text-figure 18) in the spaces between the radiating fasciculi there is a rich enough plexus, but the component fibres are only discernible with the stronger lenses ($+\frac{300}{1}$). The system of association fibres is not well represented, and the white substance immediately underlying the cortex has a pallid look, which it also owes to the absence of large fibres.

Topical Variations.

This may be taken as describing the general type of fibre-arrangement in the cortex of the gyrus fornicatus, but certain topical variations must here be referred to. It may be noticed as we proceed backwards that after the middle of the convolution is passed there begins a pronounced general increase in the fibre-wealth; at first the increase is confined to the cortex immediately overlying the corpus callosum, but the strip gradually widens, until behind the splenium it attains a breadth of 5 to 10 mm. (*vide* Plate I. C).

FIG. 18. Radiary zone in the cortex of the gyrus fornicatus. $\times \frac{450}{1}$.
Coincident with the small size of the resident nerve cells the nerve fibres are fine.

Concerning individual elements there are no differences to record between this strip and the rest of the area, the fibres remain small in calibre and wavy in outline, and are only greatly increased in number. One point, however, deserves special recognition: it is that in the cortex in contact with the corpus callosum—that is the cortex of the callosal fissure—the zonal layer is so dense and prominent that it resembles the lamina medullaris externa of the hippocampal region, and it tails off in a similar way as it passes outwards. As the diagram shows, the part exhibiting this formation is coterminous posteriorly with the subicular hippocampal region already described.

TYPE OF CELL LAMINATION. (Plate XIX, fig. 2.)

The type of cell lamination is more peculiar than the fibre-arrangement and a good many points call for special notice. Two are of particular importance: first, the elements corresponding to the large pyramidal cells in other regions have, in addition to other peculiarities, a remarkable affinity for the stain, and secondly there is a complete absence of cells of large size. Coupled with the absence of large medullated fibres, the latter truth is in agreement with what has been noted elsewhere to the effect that such fibres do not exist in regions where the cells are small.

Considering the various laminae in detail we find that, (1) the plexiform layer calls for no special notice. (2) The small pyramidal cells do not form a marked lamina, that is to say, not being numerous they do not present the aggregated appearance seen in other regions; this specially refers to the part of the gyrus next the corpus callosum. (3) The layer of medium-sized pyramidal cells is hard to define, in fact the best way to describe this and the succeeding layer is to say that the usual place of the medium-sized and large pyramidal cells is occupied by a single deep lamina composed of cells of approximately equal size but slightly larger in the lower parts. These cells vary in measurement between 15 by 30 and 20 by 37 μ, they have the form of an equilateral triangle, with one fairly stout apical and two or three delicate basal processes, and it is important to notice that the general arrangement is disorderly, and that the apical process as often as not points obliquely instead of directly towards the surface: in this way they differ markedly from pyramidal cells in most other parts. Then again, although the individual chromophilic elements in the bodies of these cells are very difficult to define, the plasma possesses some property which causes it to retain the stain firmly and hence they stand out with unusual boldness. As the drawings show, the number of these cells is great. (4) In addition to the curious cells just described, an even more important feature to be taken as characteristic of this cortex is that the layer of stellate cells, a most constant constituent of other fields, here defies definition. Only in the more peripheral parts of the area are a few small cells seen in this position, gradually increasing in number as the investing convolutions are approached. (5) There is also no internal layer of larger pyramidal cells. (6) The arrangement of cells in the deeper parts is not alike all over the field, for a certain special feature exists by which the area can be subdivided into an anterior and a posterior portion.

In the anterior portion lie specific chromophilous cells. They occupy the upper part of the fusiform layer, and although at first glance they might be taken for fusiform cells, closer inspection will show that their real shape is comparable with that of an elongated pyramid or pear; especially is the length of the apical process out of all proportion to the size of the cell-body, and from the base two or three slender processes extend. The general shape and the relative size of these cells are illustrated in text-figure 19, and it may be therein further noted that they are considerably larger than the fusiform cells, which we are familiar with in other parts, and of which we see typical examples lower down in this very cortex. But not only is the shape of these cells peculiar, they have an affinity for the dye which is greater than that exhibited by any other cells in the entire cerebral cortex, and much greater than that of the overlying pyramidal cells, which, as I have already stated, also possess this peculiarity; on this account they stand out with remarkable prominence, and their processes even in Nissl specimens are traceable for a great distance.

As to the nucleus it is of small size, and its outline is obscured by the general intense and diffuse coloration of the cell plasma.

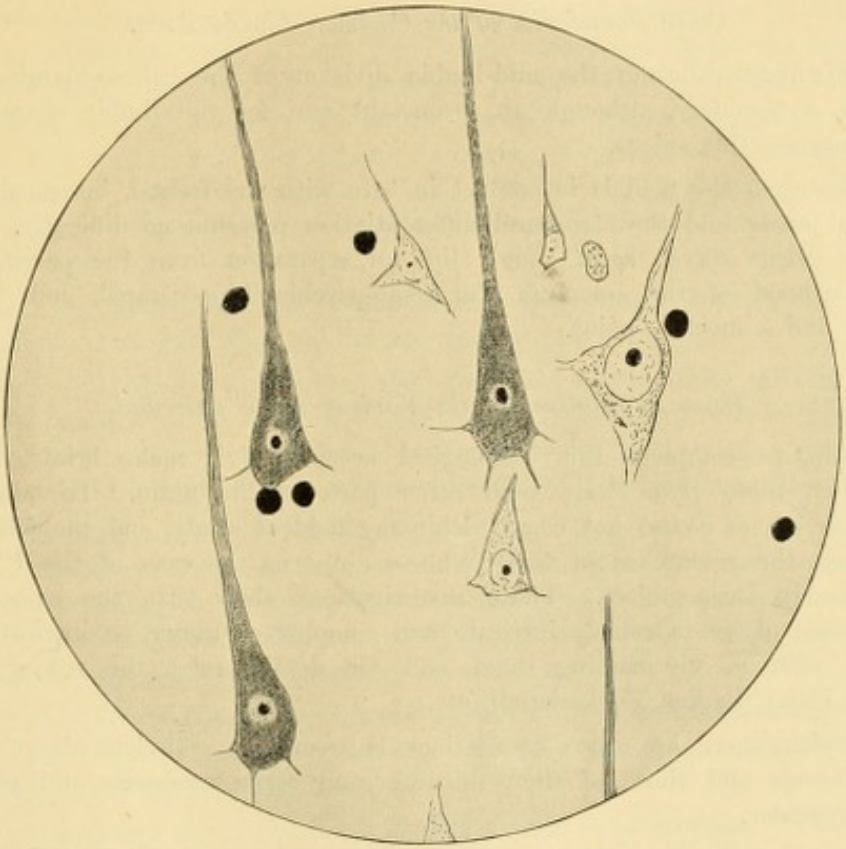

FIG. 19. Showing some of the deeply stained pregenual cells of the limbic cortex. $\times \frac{5}{1}\frac{0}{0}$.

Distribution of the above-described Chromophilous Cells.

Being so very different from any other cells on this surface of the frontal lobe it is easily possible to map out their particular area of occupation. (Plate I, Limbic B.) The field is entirely confined to the gyrus fornicatus; curving round the genu in the form of a strip 5 to 10 mm. broad, it tails off posteriorly and ceases above the middle of the convexity of the corpus callosum. Below the rostrum and in front of the genu it comes into contact anteriorly with the prefrontal area; in this brain the mid-limbic division of the calloso-marginal sulcus forms a rough boundary, and it is to be noticed that in the upper three-fourths of its extent the strip is separated from the apposed prefrontal and frontal areas by a buffer of cortex showing the general limbic type of arrangement. Lastly, I would emphasise the point that its relation to the corpus callosum appears to be more important and constant than that which it bears to any of the sulci on the mesial surface of the frontal lobe, I would also give it as my belief that it owes its position to the growth of the corpus callosum, and that at an early period of development it forms a part of the deposit which is used in the construction of at any rate the anterior portion of the hippocampus,

and my chief reason for this assumption is that cells of a similar description are to be found, as I have already mentioned, in the lobus pyriformis.

Other Boundaries of the Common Limbic Area.

Above the corpus callosum the mid-limbic division of the calloso-marginal sulcus may be regarded as a boundary, although an inconstant one, for the limbic characters may fall short of or transgress this sulcus.

Along this stretch the field is in contact in turn with the frontal, intermediate precentral and post-central areas and the structural differentiation presents no difficulty. Further back the post-limbic sulcus serves as a rough line of separation from the parietal cortex, and in the neighbourhood of the splenium the visuo-psychic, hippocampal, and fornicate types of arrangement find a meeting-point.

Some Associations of the Various Areas described.

It may help to complete this histological account if I make brief allusion to the connections which these parts have with other parts of the brain. The determination of these connections has of course not come within my field of study, and the following remarks are derived from the researches of those who—mainly in the case of the lower animals—have given time to this subject. These investigations show that the associations formed by these fields are of an extremely intricate and complex character, so intricate that I must content myself with merely naming them, and for details refer the reader to the works of S. Ramón y Cajal, Barker, Zuckerkandl, etc.

To begin with, there are close associations between the cell-elements of the cortex of the lobus pyriformis and those of the subiculum and cornu ammonis, and possibly also of the nucleus amygdalae.

In the posterior direction the cornu ammonis receives or gives off fibres which find a pathway, first, in the occipital end of the striae supracallosae (Ramón y Cajal), and secondly, in the posterior prolongation of the cingulum (the band of fibres which, underlying the gyrus fornicatus, appears to unite cells in that gyrus with those of the cornu ammonis). Further, the cornua ammonis of the two hemispheres seem to be united by means of the psalterium. Then by way of the fornix the cornu ammonis, and indirectly the lobus pyriformis, establishes connections with the corpora mammillaria, the nucleus habenulae, the optic thalami, and septum pellucidum. I have already mentioned that through the anterior commissure primary olfactory neurones gain associations with the structures of the opposite hemisphere, and there are many further complicated connections which it would be purposeless to mention here.

EXAMINATION OF THE LIMBIC CORTEX IN THE ANTHROPOID BRAIN. (Plate II.)

Before proceeding to a discussion of the functions of the various areas dealt with in the foregoing pages I shall here intercalate a brief reference to the structure of the same parts in the anthropoid brain, viz., that of the chimpanzee and orang.

As the anthropoidae resemble man in possessing an olfactory apparatus which has dwindled down to a mere fraction of what exists in lower mammals, it is not surprising

that a comparison of the histological structure of the limbic lobe in the simian and human brains fails to disclose differences of marked importance.

As regards the structure of the lobus pyriformis we have already emphasised the importance of the rudimentary fissura rhinica as a histological boundary in the human brain. Now comparative anatomists have shown that in the anthropoid brain this fissure is retained in its entirety—a truth which is amply confirmed by the three specimens which have come into my possession—and on examination of the cortex we get a repetition of the proof of the stability of this fissure as a histological landmark. In structure the cortex of the lobus pyriformis also has a human appearance; just beneath the surface the groups of large polymorphous cells are reproduced and the fibre-elements exhibit a similarity of arrangement in support of the homology.

The lamina medullaris externa of the fissura hippocampi appears to be deeper and denser, and perhaps more extensive, in the ape than in man.

The difference in character between the deep, large, pyramidal cells of the cortex of the fissura hippocampi and the large cells of the gyrus dentatus is more clearly illustrated, and it seems that the latter cells, and certainly those of the stratum granulosum of the cornu ammonis, exhibit a higher pitch of development in these animals than they do in man.

As the gyrus semilunaris of Retzius is concealed from view by the infolding of the brain in this situation and as all these specimens had been hardened before reaching my hands, I have been unable to determine whether this gyrus is represented in the anthropoid[1], and lacking orientation details afforded by a preliminary anatomical examination, I am obliged to withhold any statement concerning its structure.

The striae medullares appear to possess a degree of representation equivalent to that of man, and they have similar connections anteriorly and posteriorly with the septum pellucidum and gyrus dentatus respectively.

The gyrus subcallosus is a trifle richer in fibres than it is in man.

The gyrus fornicatus is again distinguishable by the relatively small size of its contained nerve fibres and cells, a feature which is especially noticed in the cortex of the callosal lip and wall. On the floor of the callosal fissure around the splenium there is a localised thickening of the zonal layer, but it is more restricted in extent than the corresponding topical variation in the human brain.

Without examining more material I should not like to say whether the perigenual area which in the human being is characterised by the presence of moderately large and deeply placed chromophilic cells, is represented in the anthropoid. As the cortical cells of the anthropoid are, relatively speaking, all small, judgment concerning their colour-reaction is made difficult.

A GENERAL CONSIDERATION OF THE FUNCTIONS OF THE LIMBIC LOBE.

Clinico-pathologists, experimenters, and comparative anatomists have all in turn attempted to decide the functions of the various parts included in Broca's limbic lobe, and the broad results to be gathered from their researches collectively are that certain parts of the lobe preside over the functions of taste and smell, but it is still a debateable matter what parts

[1] The gyri semilunaris and circumambiens have been seen in some of the lower apes (Gustav Retzius and Elliot Smith).

exactly dominate the sense of smell, and as to the localisation of the gustatory function the knowledge we possess is even less secure. However, now that we have a clearer idea of the structure of the cortex covering these parts, it will be interesting to see whether the truths revealed by the microscope are of any assistance in enabling us to arrive at a closer understanding of their function, and especially whether subdivisions disclosed by histology can be fitted to physiological doctrine.

Experimental Evidence.

It might be expected that experiment would not be likely to afford much information concerning the localisation of a sense so obviously difficult to test as the olfactory; however, attempts have been made to throw light on the subject by this method, and the first we have to refer to are those of Ferrier. Ferrier found that by electrical irritation of the anterior extremity of the hippocampus in the lower ape, it was possible to excite movements of the nostril, particularly on the same side, which suggested subjective olfactory sensation. He also observed that an ablation of this region was followed by loss of the power of perception of odours and of recognition of tastes, and he held, as an outcome of these experiments, that the olfactory and gustatory cortical centres were located at the lower extremity of the temporal lobe.

More recently, Gorschkow, working in Professor Bechterew's laboratory, has published an account of a number of experiments on dogs which in some measure confirm Professor Ferrier's findings. For he arrives at the conclusion that ablation of the lobus pyriformis is attended by loss of the sense of smell on the same side and diminution on the opposite side.

This, and other experimental work which might be quoted, affords confirmation of the localisation of the olfactory sense somewhere in the hippocampal lobe, but, as I shall point out further on, it is not the best proof that can be produced, and indeed skilled experimenters admit that the method is crude for the purpose and can never lead to the precise localisation of a sense with such complex associations and so difficult to test.

Mention must here be made of some remarkable results obtained by Professor Ferrier in consequence of destructive lesions of the hippocampus; these were an impairment or abolition of tactile and general sensibility associated with a condition of the limbs which pointed to loss of the sense of movement without actual motor paralysis. Such results are difficult to explain because they cannot be brought into line with known facts concerning the course and destination of the tracts of fibres which convey impressions of common sensation, and from the anatomical standpoint one might hazard the opinion that the disturbances were attributable to an accidental implication of the tract of sensory fibres running close at hand in the crus cerebri. Other experiments assigning a sensory function to the gyrus fornicatus are discussed in the chapter on the postcentral area.

Clinico-Pathological Data.

The proof supplied by an examination of patients at the bedside followed by an autopsy is likewise of an unconvincing and unsatisfactory nature, but at the same time cases have been put on record which are, to say the least, suggestive; of these the following may be mentioned. In a case of tumour of the base of the right temporal lobe destroying the uncus and gyrus hippocampi, recorded by Siebert, substances employed to test the sense

of smell were falsely interpreted. In Jackson and Beevor's case of tumour of the tip of the temporal lobe involving the anterior end of the lobus pyriformis and the nucleus amygdalae the patient was constantly afflicted with "a sense of horrid smell," and the authors are probably correct both in regarding the disturbance as an irritative phenomenon and in surmising that if the growth had been so extensive as completely to destroy the lobus pyriformis, the sense of smell would have been altogether abolished, at any rate on that side. Cases recorded by Churton and Griffiths, James Anderson and others point to a similar conclusion, and also to the likelihood that the sense of taste is located in the precincts of the same region. Bechterew, however, relates a case in which destruction of the uncinate gyrus and cornu ammonis was not associated with any disturbance of the gustatory sense, and he consequently states that the hippocampal lobe cannot contain the taste centre, and gives it as his opinion that this function is located on the outer surface of the operculum, a view which he shares with one of his pupils, Gorschkow. Here, however, reference must be made to an early negative case recorded by Bartels; it was one of sarcoma of the brain: and although the anterior two-thirds of the first, second and third temporal and occipito-temporal gyrus (lobus pyriformis) along with the hippocampus and uncus in the left hemisphere were destroyed, there was no noticeable impairment of the sense of smell.

A critical analysis of these clinical cases shows that while they provide confirmatory evidence of the localisation of the olfactory sense in the gyrus hippocampi, they admit of no conclusions as to the precise position of the olfactory centre, and the information they supply concerning the gustatory centre is still more meagre.

Teachings of Comparative Anatomy.

There is little doubt that studies in comparative anatomy, in showing the phylogenetic importance of the lobus pyriformis, originally provided one of the strongest clues to the localisation of the olfactory sense.

It is many years since Broca and also Zuckerkandl demonstrated that in animals with a highly-developed sense of smell this division of the hippocampus swells into a large pear-shaped lobe, that in some animals (the horse, tapir, and rhinoceros) it is slightly fissured, and that in all it is divided off from the rest of the temporal lobe by the fissura rhinica, which although small and insignificant in the human brain is of great length and depth in these osmatic animals. Both Broca and Zuckerkandl also extended the olfactory area to the gyrus fornicatus, on account of the relatively strong development of this part in osmatics; and in support of this localisation Zuckerkandl relates how an examination of the brains of two infants born without olfactory lobes revealed arrested development of the uncinate gyrus, the cornu ammonis, and the anterior part of the gyrus fornicatus.

It is unfortunate, however, that all comparative anatomists are not in agreement regarding the localisation of this function; thus Hill, who has written authoritative papers on the subject, is careful to point out that in some anosmatic animals—for instance, the Narwhal, an animal entirely devoid of the sense of smell—the lobus hippocampi attains a moderate degree of development, and on the strength of this he believes, and his argument seems a fair one, that this lobe cannot exist for the control of this function solely. In this relation Hill attaches far more importance to the fascia dentata (gyrus dentatus) of the cornu ammonis, stating that it is the only structure in this region which is wholly wanting

in the anosmatic brain, and that its development varies directly with the development of the olfactory apparatus; he also mentions that the anterior commissure and fornix are developed proportionately with the fascia dentata.

S. Ramón y Cajal from a histological study of the brains of the dog, cat, guinea-pig, rabbit, rat, and mouse, as well as that of the human being, arrives at the following conclusions. "1. Wir müssen als secundäre Riechcentren alle diejenigen betrachten, welche unzweifelhaft Fasern der äusseren, mittleren oder oberen Wurzeln aufnehmen. Diese Centren besitzen die gleiche Structur; es sind die Rinde des Lobulus olfactivus (Pedunculus bulbaris), die frontale, unter der äusseren Wurzel liegende, und die äussere Gegend der Sphenoidalrinde. 2. Der Focus spheno-occipitalis, das Subiculum, der Focus präsubicularis und das Ammonshorn scheinen keine directen Olfactoriusfasern zu besitzen. Vielleicht stellen sie tertiäre Riechcentren dar. 3. Die Amygdala, das Septum pellucidum, die limbischen Windungen, und die Zwischenhemisphärenrinde, die Striae supracallosae, die prächiasmatische Fissurrinde, etc., entbehren anscheinend directer olfactiver Verbindungen[1]."

Summarising the deductions drawn from studies in comparative anatomy and applying them to the human brain we gather that the lobus pyriformis must almost certainly be regarded as the chief olfactory centre, but opinions are divided concerning the functional importance of other parts of the cortex, that is, the cornu ammonis, gyrus fornicatus, and other subsidiary structures.

Points in the Development of the Olfactory Lobe.

The development of the various parts of the cerebrum concerned with the olfactory sense has been studied or described with infinite thoroughness, by His, Sir William Turner, Gustav Retzius, Ferrier, Edinger, Elliot Smith, and others, and the results of these researches are so well-known that it is unnecessary for me to discuss them; I will mention only that to the student of localisation, points of special interest are the clearness with which it may be seen that in the foetal brain the olfactory lobe has connections with the lobulus pyriformis, and particularly with the gyrus circumambiens of Retzius; and in what a definite manner the fissura rhinica divides the posterior olfactory from the temporal lobe. It is also interesting to know that the gyrus subcallosus of Zuckerkandl is a more prominent object in the foetal than in the adult brain.

Added to these anatomical researches we also have the advantage of referring to the histological investigations of Flechsig and others, who have aimed at recording the period and manner in which the nerve fibres derived from the olfactory roots become developed.

Although in his original publications Flechsig was responsible for the statement that the cortical fibres of the central convolutions were the first to acquire a myelinic investment, and that the olfactory fibres came second, in a more recent paper giving the results of

[1] "1. As secondary olfactory centres we must regard all those parts which undoubtedly receive fibres from the external, middle, or upper roots. These centres possess a like structure; they are the cortex of the lobulus olfactivus (pedunculus bulbaris), the frontal cortex underlying the external root and the external part of the sphenoidal cortex. (*By the latter the lobus pyriformis is meant.*)

"2. The focus spheno-occipitalis (*of lower animals*), the subiculum, the focus presubicularis, and the cornu ammonis seem to receive no direct olfactory fibres. Perhaps they represent tertiary centres of smell.

"3. The amygdala, the septum pellucidum, the limbic gyri, and the inter-hemispheric cortex, the striae supracallosae, the prechiasmic fissural cortex, etc., are apparently deprived of direct olfactory associations."

further researches he seems inclined to reverse the order; relating how in the brain of a foetus 34 cm. long he found the central convolutions quite unmedullated, while some fibres could be made out in the cortex of the uncinate gyrus (lobus pyriformis) and in the anterior perforated spot close to the beginning of the fossa Sylvii. A little further on, however, he states that when medullation does begin in the central gyri it proceeds rapidly and soon outstrips that in the olfactory region. In the same paper he indicates how this early development of cortical olfactory fibres harmonises with previous observations of his own, to the effect that the ganglion cells resident in the lobus pyriformis are the first of all in the human brain to assume a definite form.

Concerning other parts of the limbic lobe, Flechsig tells us that the fibre development of the cornu ammonis and subiculum follows closely on that of the above-mentioned areas; also that the gyrus fornicatus, especially its middle third, does not come far behind and is to be included among the areas which he has designated primordial. Other points in regard to the gyrus fornicatus which interest me particularly are that the parts numbered 8 and 8 *a*, in Flechsig's older diagrams, approximately correspond with the pregenual field which my observations prove to be the seat of the curious large and deeply-placed chromophilic cells already described; and also that the number 11 is placed over the splenial part of the same gyrus, which I find to be distinguished by a special arrangement of fibres.

In addition to these observations on the human brain, some carried out by Döllken, Ramón y Cajal, and others, can be referred to, which, according to Flechsig, substantiate his findings. And, taken all in all, a study of the developing brain strongly emphasises the importance of the lobus pyriformis as an olfactory centre; it also suggests that other parts of the limbic lobe have a bearing on this function, so harmonising with the findings of histology.

Histological Evidence.

At the present day it cannot be said that we lack information concerning the normal histology of the various subdivisions of the limbic lobe, for the work, begun by Arnold, Meynert and Betz, and carried on by Bevan Lewis, Obersteiner, Hammarberg, Kaes, and Kölliker, has been finally rendered so complete by the researches of Calleja and S. Ramón y Cajal that there seems practically nothing further to be learnt concerning the actual morphology and arrangement of the cell and fibre elements resident in the cortex of these parts; not only so, my humble researches, coupled with those of others, have plainly disclosed the territorial distribution of the variations in structure to be met with.

But much as has been achieved in the direction of histology, the crowning point of our labours, namely, the ability to make a correct and definite statement concerning the part performed by the different areas which we have defined, is far removed, information either confirmatory or refutatory which will enable us to form a precise judgment regarding the function of these structures, and help us in the exact cortical localisation of the olfactory and gustatory centres, is sadly wanting. Above all things we seem to lack the knowledge which in the case of some other cortical regions has proved so valuable, I refer to that derived from studies in pathological histology; for instance, we have much to learn of the cortical changes attending uncomplicated atrophy or lesion of the olfactory bulb and peduncle, and have virtually no conception as to what subdivisions such changes would be distributed over.

In the literature to which I have had access evidence of this nature is very scanty, in fact, I can only refer to the previously mentioned naked-eye observation of Zuckerkandl, and to some experimental researches of Löwenthal. Löwenthal in a number of instances divided the olfactory bulb either near its entry to the olfactory lobe, or where it lies over the tip of the frontal lobe, and after examining the brain by the method of Marchi arrived at the following conclusions: (1) The tractus olfactorius lateralis is to be regarded exclusively as a tract of the second order. (2) Fibres of the mesial olfactory tract springing from cells of the anterior olfactory lobe pertain to the third and higher order, and they end in the lobus pyriformis and cornu ammonis of both hemispheres, and partly in the bulbus olfactorius of the opposite side. (3) There is a partial decussation of tracts of the higher order. (4) The anterior commissure conveys a number of such fibres. (Probst and Ramón y Cajal have conducted researches of a similar but less comprehensive nature.)

Although carried out in the lower animals, experimental observations like those of Löwenthal's help to elucidate this difficult subject, but at the same time it can hardly be denied that a determination of the distribution of scattered degenerated fibres is less likely to lead to exact information on localisation in this region than an analysis of the reactive degeneration, which will probably be found to occur in the cells which serve for the reception or interpretation of olfactory sensations, when these cells are cut off from the influence of such impulses.

Reviewing the situation from the histological standpoint, we are driven to confess that while our knowledge of the normal histology of the olfactory apparatus and of the parts which probably govern this function is very complete, more pathological evidence of a definite and confirmatory character would be gladly welcomed.

The Localisation of the Sense of Taste.

The sense of taste differs from that of smell in that the nerves concerned in its conveyance pertain to the category of cranial nerves, whereas, strictly speaking, those for the conduct of olfactory stimuli do not. With the auditory nerves, however, the nerves of taste are analogous, but while our knowledge of the central course and connections of the auditory nerves is almost complete, it is quite the reverse with those of taste. True it is that we have abundant evidence to the effect that peripheral severance of the glossopharyngeal nerve, and of the trigeminal nerve after it has been joined by the chorda tympani, is followed by loss of the sense of taste in certain divisions of the tongue, but as to the cerebral connections and destinations of these nerves we are almost completely in the dark.

It is assumed that the cortical centre for taste is located in the lobus hippocampi in the neighbourhood of the olfactory centre, but the grounds for this assumption are hypothetical, and no clinical or experimental observations sufficiently precise to prove it have been recorded; in fact, Gorschkow on experimental and Bechterew on clinical grounds have deserted the hippocampus and locate this function in some part of the operculum. In discussing the Insula I shall return to the findings of these observers.

Summary and Conclusions.

(1) The parts studied in this section include all the constituents of Broca's "grande lobe limbique," viz. the olfactory lobe (excluding the olfactory bulb and peduncle), the whole gyrus hippocampi (including the cornu ammonis and subiculum, the uncus and lobus pyriformis), the entire gyrus fornicatus, and other subsidiary structures.

(2) Histology supports comparative anatomy in suggesting that, in the human brain, the lobus pyriformis must be regarded as the principal cortical centre, although not the sole one, governing the olfactory sense. Structurally the cortex of this lobe is not built up on the usual plan, and its chief distinguishing features are (*a*) curious clusters or nests of giant polymorphous cells which occupy a unique position close beneath the surface, (*b*) a deep succeeding layer of pyramidal cells approximately equal to one another in size (S. Ramón y Cajal's tassel cells), (*c*) a correspondingly peculiar arrangement of cortical nerve fibres, of which the presence of projection bundles reaching right up to the zonal layer constitutes a prominent feature.

This type of cortex occupies a pear-shaped area practically corresponding with the lobus pyriformis. It is a point of special phylogenetic interest that the rudimentary but constant fissura rhinica constitutes an absolutely definite and fixed anterior boundary. Of other limits the anterior division of the collateral sulcus is the lower one, and the lip of the fissura hippocampi, where the area merges with another type of arrangement, is the upper.

In addition to the remarkable development of this lobe in osmatic animals the following facts enhance its physiological importance: not only in the lower animals but in man also it has been proved to be the terminus of the lateral olfactory root fibres; in the developing human brain it is one of the first, if not the first area to become medullated; in the ape and dog it has been shown that an experimental ablation of the lobe results in loss of the sense of smell; and, lastly, the balance of evidence derived from a study of natural lesions of the lobe in the human brain supports experimental and other deductions.

Ferrier's conclusion that common sensation is centred in the hippocampal region appears to be unsupported.

(3) On histological grounds it seems permissible to assign independence to the area of cortex covering the wall and lip of the fissura hippocampi, a subdivision which receives S. Ramón y Cajal's acquiescence. Features peculiar to this cortex are the greatly-developed zonal layer or lamina medullaris externa, the complicated arrangement of fibres in the deeper parts, the existence of extensive islets of diminutive triangular cells situated immediately beneath the zonal layer, and the deep subjacent layer of elongated large pyramidal cells, which apparently differ from corresponding cells in the cornu ammonis and lobus pyriformis; not to mention the absence of the superficial nests of large polymorphous cells found in the lobus pyriformis.

There is really no satisfactory evidence to guide us in a determination of the physiological part played by this area; that it has close internuncial relations with both the lobus pyriformis and the cornu ammonis is undoubted, but whether S. Ramón y Cajal is right in regarding it as a tertiary olfactory centre—the olfactory bulb and lobus pyriformis being primary and secondary centres respectively—or whether it is part of the gustatory centre, remains to be proved. When we recall that the hippocampal fissure has extraordinary

phylogenic stability, being found in all mammalian brains from Ornithorhynchus to Homo, our disappointment at being unable to say more about its function is accentuated.

(4) The most important elements in the gyrus dentatus of the cornu ammonis are the large pyramidal cells forming the prominent lamina, with which previous researches have made us familiar. It is interesting to find that these cells extend forward into the hook or uncus of the so-called uncinate lobe, and that in the posterior direction they are apparently continued into the striae longitudinales mediales.

Although possessing such a distinctive structure the physiological significance of the cornu ammonis is but little understood. Some credit it with a gustatory function; others regard it as an additional, tertiary, olfactory centre; and Alexander Hill's observation that it is the only structure which is wholly wanting in the anosmatic brain renders the latter the more credible assumption.

(5) The cortical elements recognisable in the striae longitudinales mediales, the gyrus subcallosus, and the olfactory trigone are all of a vestigial character.

(6) In addition to other peculiarities of fibre arrangement and cell lamination the cortex of the gyrus fornicatus is remarkable for being completely destitute of fibres, and also cells of large size.

In two parts the structure diverges from the common type:

(*a*) A strip of cortex, 5 to 10 mm. broad, bordering the posterior half of the corpus callosum, exhibits a pronounced superiority in general fibre wealth; and it is especially noteworthy that the cortex of the callosal fissure in this situation shows a dense and prominent zonal layer, which not only resembles but seems to be continuous with the lamina medullaris externa of the fissura hippocampi.

(*b*) Another strip of cortex, 5 to 10 mm. broad, investing the genu of the corpus callosum, can be differentiated by the presence of elongated pyriform cells of medium size, which occupy the position usually taken by the internal layer of large pyramidal cells, and are remarkable in possessing an affinity for methylene dyes far greater than that exhibited by any other cells in the whole cerebral cortex. The lower extent of this area is really continuous with the gyrus subcallosus, and is placed significantly close to the inner root of the olfactory tract, hence giving rise to the idea that this root establishes connections with the chromophilous cells above mentioned. There are three facts which favour this assumption: many comparative anatomists have emphasised the relatively great development of the gyrus fornicatus in osmatic mammals; Zuckerkandl noticed mal-development of this particular area in cases of congenital absence of the olfactory bulb; and thirdly Flechsig shows that it is one of the early medullated fields. S. Ramón y Cajal, however, shakes our assurance in this belief by stating that the gyrus fornicatus apparently has no direct olfactory associations, and, although he does not seem over-confident on this point, further investigation will be needed before the function of the part can be considered settled.

(7) This research does not deal with the internuncial connections of the various constituents of the limbic lobe, but from numerous investigations which have been carried out we learn that connections of a most intricate nature do exist, and these suggest that before an olfactory stimulus can be received and converted into a conscious sensation it must traverse a pathway of bewildering complexity.

(8) Definite information concerning gustatory localisation in the cortex cerebri is wanting.

(9) In the limbic cortex of the anthropoid ape human characters are closely followed.

REFERENCES.

1. P. Broca. Localisations cérébrales; recherches sur les centres olfactifs. *Revue d'anthropologie.* Paris, Tome 2, 1879.
2. C. Calleja. La región olfactoria del cerebro. Madrid, 1903.
3. S. Ramón y Cajal. Studien über die Hirnrinde des Menschen. Heft 4. Die Riechrinde beim Menschen und Säugetier. Leipzig, 1903.
4. P. Flechsig. Neue Untersuchungen über die Markbildung in den menschlichen Grosshirnlappen. *Neurol. Centralb.*, No. 23, 1895.
5. L. F. Barker. The Nervous System and its Constituent Neurones. London, 1902.
6. Gustav Retzius. Das Menschenhirn. Stockholm, 1896.
7. E. Zuckerkandl. Ueber das Riechcentrum. Stuttgart, 1887.
8. H. Obersteiner. Anleitung beim Studium des Baues der nervösen Centralorgane. Leipzig, 1896.
9. C. Hammarberg. Studien über Klinik und Pathologie der Idiotie. Upsala, 1895.
10. L. Blumenau. Zur Entwickelungsgeschichte und feineren Anatomie des Hirnbalkens. *Arch. f. mikrosk. Anat.*, Band 37, 1890.
11. J. Déjerine. Anatomie des centres nerveux. Paris, 1901.
12. W. His. Die Formentwickelung des menschlichen Vorderhirns vom Ende des ersten zum Beginn des dritten Monats. *Abhandl. Gesellsch. d. Wissensch. Leipzig*, 1899.
13. D. Ferrier. The Functions of the Brain. London, 2nd edition. See also Article in Clifford Allbutt's *System of Medicine.*
14. Gorschkow. Ueber Geschmacks- und Geruchscentren in der Hirnrinde. Inaug. Dissert. St Petersburg, 1901. Abstract in *Neurol. Centralb.*, 1901.
15. W. von Bechterew. Demonstration eines Gehirns mit Zerstörung der vorderen und inneren Theile der Hirnrinde beider Schläfenlappen. *Neurol. Centralb.*, p. 990, 1900.
16. V. Horsley and E. A. Schäfer. A Record of Experiments upon the Functions of the Cerebral Cortex. *Phil. Trans.* London, Vol. clxxix, 1888.
17. O. and C. Vogt. Neurobiologische Arbeiten. Beiträge zur Hirnfaserlehre. Leipzig, Band 1, 1902.
18. Siebert. Ein Fall von Hirntumor mit Geruchstäuschungen. *Monatschr. f. Psych. u. Neurol.*, Band vi, 1899.
19. J. Hughlings Jackson and C. E. Beevor. Case of Tumour of the Right Temporo-Sphenoidal Lobe bearing on the Localisation of the Sense of Smell and on the Interpretation of a particular variety of Epilepsy. *Brain*, Vol. xii.
20. Churton and Griffiths. Quoted by Ferrier.
21. James Anderson. Quoted by Ferrier.

22. Bartels. Myxosarcom des linken Schläfenlappens ausgehend vom Ammonshorn; Zerstörung des Uncus, Gyrus Hippocampi u. s. w. ohne Aufhebung des Geruchs. Abstract in *Neurol. Centralb.*, p. 632, 1902.

23. Alexander Hill. The Hippocampus. *Phil. Trans.*, Vol. 184, 1893.

24. Sir William Turner. The Convolutions of the Human Brain; a Study in Comparative Anatomy. *Journ. Anat. and Physiol.*, Vol. xxv, 1890–1891.

25. L. Edinger. Vorlesungen über den Bau der nervösen Centralorgane. Leipzig, 1900.

26. Elliot Smith. Catalogue of Comparative Anatomy. Museum of Royal College of Surgeons, England. Vol. ii, 1892.

27. Döllken. Die Reifung der Leitungsbahnen im Thiergehirn. *Neurolog. Centralb.*, No. 21, 1898.

28. W. Bevan Lewis. A Textbook of Mental Diseases. London, 2nd edition. See also various other papers by the same author.

29. Theodor Kaes. Beiträge zur Kenntniss des Reichthums der Grosshirnrinde des Menschen an markhaltigen Nervenfasern. *Arch. f. Psych. u. Nervenkr.*, Band xxv, Heft 3, 1893.

30. A. von Kölliker. Lehrbuch der Gewebelehre. Leipzig, 1896.

31. S. Löwenthal. Ueber das Riechcentrum der Säugethiere. Abstract in *Neurol. Centralb.*, p. 409, 1898.

32. Probst. Zur Kenntniss des Faserverlaufes des Temporallappens des Bulbus olfactorius. *Arch. f. Anat. u. Physiol.*, Heft 6, 1901.

33. W. A. Turner. The Cranial Connections and Relations of the Trigeminal, Vago-glossopharyngeal, Vago-accessory, and Hypoglossal Nerves. *Journal of Anat. and Phys.* London, Vol. xxix, 1894–1895.

CHAPTER VIII.

PARIETAL AREA.

We saw that the anterior half of the postcentral gyrus was covered by a specialised type of cortex to which the name "postcentral" was affixed. We also found that the posterior half—speaking roughly—of the same gyrus presented a structural arrangement of a similar but less developed and less complex nature, and this was distinguished by the name "intermediate postcentral." Now on passing further back, into the superior parietal lobule, it may be noticed that while certain postcentral characters still remain, the disposition of both cell and fibre constituents is, by comparison, one of another grade; and since the formation also differs from that in other investing areas, I have decided to give it and the field it covers independent consideration. But I must explain that this step is not being taken without some misgivings, because when the function of the part is discussed, physiology will be found to give meagre support to the separation.

Reference to Plate I, in which the distribution of this area is represented by short vertical lines, will show that the term "parietal" is being employed, not because the area corresponds to the portion of the brain which the anatomist distinguishes by that name, but for convenience in indication. At the same time while the field does not cover the whole parietal lobe it is distributed over parts of it, and hence in some measure the designation is justifiable.

Analysing the structure of the enveloping grey matter we will first consider the type of fibre arrangement, pointing out incidentally the manner in which it differs from the formation in surrounding areas.

TYPE OF FIBRE ARRANGEMENT. (Plate XX, fig. 1.)

Zonal Layer.

The zonal layer must be described as being of weak development. It is made up for the most part of fine varicose fibrils, and contains only a few large varicose elements. Large evenly-medullated fibres are entirely wanting, and the inferior border of the layer is indefinite.

Supraradiary Layer.

Immediately below the zonal layer the fibres are scanty, but elsewhere the display is one of average richness, and this, as usual, increases towards the line of Baillarger. The contained fibres are nearly all of fine calibre and form an irregular network; only occasionally a vertical fibre of Martinotti, which may be said to be of medium size, is seen.

Line of Baillarger.

It is important to notice that this is one of the areas where the line of Baillarger is reduplicated[1], a point which did not escape the notice of Kaes; and, as that writer has further indicated, the inner stria is not only equal to but in places thicker than the outer one. The second line is situated in the radiary zone midway between the external stria and the white substance, and, as will be mentioned in describing the cell lamination, it corresponds in position with the internal layer of large pyramidal cells. As to composition, each line contains numerous short, delicate, irregularly-placed fibrils; among which are a few fibres, longer, transversely-directed and medium-sized, and now and then a large fibre.

The plainness of this doubling of Baillarger's line is not the least important distinguishing feature of the "parietal" cortex.

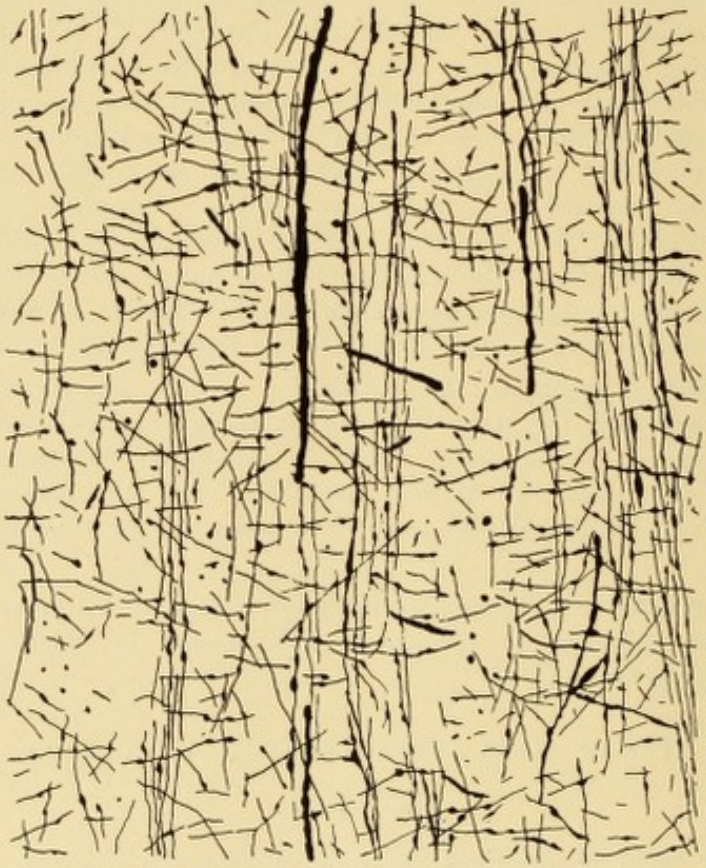

FIG. 20. Radiary zone in the parietal area. $\times \frac{4}{1}\frac{3}{2}$.

The fibre wealth is less than in the intermediate postcentral cortex (figure 5, page 69). Fibres of medium size are scarce, and fibres of large calibre almost entirely wanting.

Radiations of Meynert.

The fibres composing these fasciculi are mostly of fine and medium size, but occasionally a fibre which must be included in the coarse medullated variety adds to the volume of

[1] A faint attempt at a reduplication of the line of Baillarger has been recognised in the cortex of the gyrus fornicatus and in the temporal lobe.

a bundle. None of the fibres seem to project higher than the inner part of the supra-radiary field.

Radiary Zone.

In describing the radiary zone it is best to compare it with that of surrounding areas. Now in the adjoining gyrus fornicatus and in the "common temporal" area we noticed that this zone was palely stained, and especially that it was lacking in long fibres of medium size and entirely wanting in fibres which could be called large. In this area, on the contrary, fibres of medium size are present in considerable abundance; moreover, large fibres are occasionally seen. But the latter are less numerous than they are in the "intermediate postcentral" area and infinitely less abundant than in the contiguous "visuo-psychic" cortex.

The fibres of the interradiary plexus are difficult to dissociate from those which may more properly be regarded as pertaining to the inner line of Baillarger.

Easily defined on the limbic and occipital sides, the postcentral and temporal boundaries are not so readily determined; however, placed in order of sequence as regards fibre wealth in the radiary zone, it may safely be said that the "intermediate postcentral" cortex comes first, then the "parietal," and the "common temporal" last. It is chiefly by judgment on this general fibre representation in the radiary zone that the area can be differentiated.

TYPE OF CELL LAMINATION. (Plate XX, fig. 2.)

Plexiform Layer.

Not differing markedly from that of surrounding fields this layer calls for no special comment.

Layer of Small Pyramidal Cells.

So far as can be judged from Nissl preparations this layer also exhibits no feature which can be considered characteristic.

Layer of Medium-Sized Pyramidal Cells.

The constituents of this lamina resemble those seen in the postcentral areas and are present in about the same number.

External Layer of Large Pyramidal Cells.

As the determination of the topography of the "parietal" field is assisted by comparing these cells with corresponding cells in adjacent areas, it is important that they should be fully considered.

The size and number of the contained elements and its general depth are sufficiently great to confer easy definition on the lamina.

Comparing it first with the corresponding layer in the "intermediate postcentral" area, it must be admitted that the difference is not a great one; nevertheless, on careful inspection, and especially on making a series of camera lucida drawings of cells under a high

power, it can be shown that the passage from "intermediate postcentral" to "parietal" cortex is attended by an appreciable reduction in size of the contained cells. It likewise appears that the larger elements, those especially rich in chromophilic particles, diminish in number.

The distinction between the cells of this layer and those in the "general temporal" area is also not easily made out; still, after many observations I am satisfied, as regards the latter area, that while the cells may possibly have an advantage in point of number, they are distinctly smaller in size. Moreover, cells of the larger order, evenly supplied with Nissl bodies, although by no means frequent in the "parietal" cortex, are virtually non-existent in the "common temporal" region, and this, in my opinion, is a very important point of difference.

The appearance of the peculiar, large external pyramidal cells, described in the "visuo-psychic" cortex, proclaims the occipital boundary as clearly as the sudden diminution in size of homonymous elements marks the "limbic" cortex.

Layer of Stellate Cells.

In common with that of the postcentral, temporal, and occipital regions the "parietal" cortex possesses a well-developed and prominent stellate layer; this, therefore, cannot be used as a means to topographic differentiation.

Internal Layer of Large Pyramidal Cells.

Although this lamina is quite easily defined, its cells are neither so large nor so numerous as those in the external layer (4). A comparison of the lamina with that of surrounding regions is not instructive; for while it differs from the "occipital" and "limbic" formations, it has points in common with the "intermediate postcentral" and "temporal," and in regard to relative size and number of contained cells it can only be said that the statement concerning the external layer (4) holds here also[1].

Layer of Fusiform Cells.

The layer of fusiform cells is a deep one; and since the cells in the upper part are larger and more triangular than those in the lower, it might be divided into two, but seeing that the same arrangement is found in the temporal and parietal regions, and also that the appearances do not assist us in furthering our territorial subdivision, it is preferable in the mean time not to invest them with importance.

In total depth, the "parietal" cortex does not differ from that of the "temporal" and "postcentral" areas.

Topical Variations.

There are no local variations of importance to be described. It need only be said that the type of fibre arrangement and cell lamination is seen at its best in the middle of the superior parietal gyrus, that is in the centre of the area, for towards the periphery it takes on the appearances of the various types of cortex which surround it.

[1] As previously mentioned this layer is placed on a level with the inner line of Baillarger and there can be little doubt that the two are interdependent.

Special remarks are called for concerning the structure of that portion of the superior parietal gyrus lying immediately anterior to the upper extremity of the parieto-occipital fissure, because it is one which has been recently singled out by Flechsig for special description. Overlooked in his earlier observations, Flechsig now asserts that this part takes a high position in the myelogenetic sequence and he numbers it 14 instead of 22, as he did in 1901. He further distinguishes the field by the name "supraangular," on account of its relation to the angular gyrus.

Now it seems to be a fundamental rule, that those parts of the cortex which receive their medullated fibres at an early date are exactly those which harbour a great wealth of fibres of large calibre; they thus prove interesting fields for examination in the adult brain, because their boundaries are easily determined and their structure usually departs from the common plan. For this reason I have been attracted to this part and have examined it most carefully in a number of brains, but unfortunately my conclusions do not altogether harmonise with those of Flechsig, and in particular I object to granting independence to his "supraangular" field. What I would say is that the structure here is subject to variation, in some cases it is endowed with a great wealth of fibres, and in others it shows the ordinary "parietal" formation. Then in those instances in which the fibre supply is great, on tracing the area backward, it can always be found to be continuous with the field of cortex to which I have given the name "visuo-psychic," indeed the type of arrangement it presents is actually the "visuo-psychic" type; hence I maintain that in these cases we have merely to deal with a forward extension of the visual area[1]. But what the cause of the variation in distribution is, I am not at the present prepared to say; I am, however, under the impression that variations in depth and extent of sulci situated hereabout, in particular the parieto-occipital fissure and the ramus occipitalis transversus of Ecker, are not unimportant.

In further substantiation of my statement that in these cases we have to deal with a forward prolongation of the "visuo-psychic" area, I would add that an examination of the cell lamination fully bears it out, for the superiority in fibre wealth is invariably associated with the presence of those curious large pyramidal cells for which I have claimed so much attention, and in short with a "visuo-psychic" type of lamination. Furthermore, in the anthropoid ape the same area is subject to similar variations, and in this animal the distribution seems to be distinctly influenced by the position of the upper extremities of the parieto-occipital fissure and the "Affenspalte."

Other sub-areas made out by Flechsig are undefinable in the fully-developed brain.

Distribution of the parietal area.

As may be gathered from what has been already said, the "parietal" area may be briefly described as covering the precuneus, the superior parietal gyrus, and the anterior part of the supramarginal gyrus.

Concerning boundaries on the mesial surface of the hemisphere, the upturned tail of the calloso-marginal fissure, and the parieto-occipital fissure may be looked upon as constant anterior and posterior limits. Inferiorly it comes into relation with the limbic area. and the line of

[1] Anatomically the part in question is nothing more than the superior parieto-occipital annectant gyrus, the gyrus which arches round the upper extremity of the parieto-occipital fissure, and one which we know is inconstant in size and position.

the sulcus post-limbicus (sulcus subparietalis) may be taken as the division between the two, although in different cases either type may overstep this sulcus for a short distance.

On the convexity and lateral surface of the hemisphere the boundaries are less determinate. In the anterior direction it comes in contact with the "intermediate postcentral" area, and the superior division of the postcentral sulcus may be called a limit. Posteriorly it joins the "visuo-psychic" area, and the variations in this position have already been mentioned.

The inferior boundary on this surface is the hardest of all to settle; approximately the ramus horizontalis (interparietal fissure) along with the ramus occipitalis of the intraparietal fissure form a dividing line, but these sulci certainly do not constitute a precise limit, for although it is exceedingly difficult, almost impossible, to determine the exact point where "parietal" cortex ends and "temporal" begins, on account of confusion of type, yet I think it correct to say that the "parietal" type tends to cross the horizontal sulcal line and to trespass on the upper part of the angular gyrus, as well as on the upper and anterior part of the supramarginal convolution.

Parietal area in the anthropoid ape. (Plate II.)

It is interesting to find that an area bearing topographical and structural resemblances to that in man can be made out in the parietal lobe of the anthropoid ape.

In reference to boundaries several points of considerable importance have to be mentioned. Thus, on the outer surface of the hemisphere, the great "Affenspalte" and the deep and apparently constant ramus horizontalis of the intraparietal sulcus, coupling the "Affenspalte" with the sulcus postcentralis, form occipital and temporal limits much more definite than the corresponding limits in the human brain. Then, on the mesial surface, the posterior boundary gives no trouble, as it is formed by the upper end of the parieto-occipital fissure; but the lower or limbic boundary is of a less determined character, for the sulci in the anthropoid quadrate lobe differ from corresponding sulci in the human cerebrum in being irregularly placed, and especially in inclining to assume a radiate instead of an arcuate position in relation to the corpus callosum; therefore they cannot be used as limits, and in consequence an imaginary arcuate line placed between the corpus callosum and the surface of the hemisphere, somewhat nearer the latter than the former, has to be thought of as a division.

There is a further variation which concerns the extent of the area on the mesial surface. In the three anthropoid brains which I have examined, a relative shortening of the interval between the hinder upturned part of the calloso-marginal fissure and the parieto-occipital fissure has produced a corresponding narrowing of the quadrate lobule, and in association with this the extent of the parietal area on the mesial surface has presented a pronounced diminution in comparison with the human arrangement.

As structural guides to differentiation the features which serve in the human brain can again be used. Passing backwards from the intermediate postcentral area there is a marked drop in the number of large medullated fibres, and as soon as the "Affenspalte" is reached unmistakeable visual characters appear. The absence of large fibres in the "common temporal" and in the "limbic" cortex proclaim these types.

A CONSIDERATION OF THE FUNCTION OF THE PARIETAL AREA.

Stimulation experiments supply negative information only concerning the function of the parietal cortex. According to those physiologists from whose observations our original plans of the surface localisation of the motor function were drawn, the excitable area extends backwards on to the superior parietal gyrus, and therefore into the histological field forming the subject of these remarks; but in the chapters on the "precentral" and "postcentral" areas the accuracy of this localisation has been called in question and contradicted, and in my opinion it may now be taken as proved that the area enveloped by a "parietal" type of cortex forms a part of the extensive territory distinguished by its "silence" under the influence of special electrical stimulation.

As to the information forthcoming from a study of experimentally-produced secondary degenerations, this also is not enlightening. The chief question which has claimed attention is, whether or not the parietal lobe is the end-station for the cortical lemniscus, and, as has been mentioned in the discussion on the functions of the "postcentral" area, the evidence on this point is contradictory, von Monakow answering the question in the affirmative, while Tschermak writes to the contrary. Which of the two is correct it is impossible to say definitely, but I have already given many reasons for believing, along with Tschermak, that the postcentral gyrus, and not the parietal lobe, is the main sensory goal; still, a certain structural resemblance between the "parietal" and the "postcentral" cortex and other evidence, chiefly clinical and to be presently mentioned, stand in von Monakow's support and make it appear that at any rate some centripetal sensory fibres gain the cortex of the "parietal" area, even though the mass makes for the postcentral gyrus.

Let us take next the information derived from a study of the clinical effects of lesions in the "parietal" area. The records contain several instructive reports of such cases, and, as I have previously stated (postcentral area), if these be analysed, a consensus of opinion will be noticed to the effect that damage to this part of the brain is attended by disorder of high and combined forms of sensation, such as the muscle sense and that of stereognosis (Durante, Walton and Paul, von Monakow, Redlich and many others). Analysed more closely, we find that if the lesion be in the precuneus, or in the superior parietal gyrus, the sensory impairment will be confined to the lower extremity (observations of Bernhardt, Westphal, Henschen, etc.), and if, on the other hand, the supramarginal gyrus be destroyed the affection will be restricted to the upper extremity (cases of von Monakow, Vetter, etc.). For the clinician, therefore, the field which I have mapped out and called "parietal" represents a high sensory centre, a centre for the recognition of complex impressions embodied in the muscle sense and that of stereognosis. And this is a view which, after my histological investigations, I should have least compunction in endorsing. For although it has been upheld in a previous chapter that the cortex of the area designated "intermediate postcentral" is chiefly constituted for the elaboration of sensory psychic attributes, it has also been conceded that this function might be shared by cortex situated further back in the parietal lobe, and the part to which I referred in making that concession was the special "parietal" field now under discussion. And my principal reason for that statement was the histological knowledge that the cortex of this particular area had a distinct resemblance to that of the "intermediate postcentral,"—it differs only in point of degree of representation of certain elements,—now also it may be understood why I was diffident in giving this area independence.

But we are still far from being out of the wood, for not only is the proof which we are able to provide on the above-mentioned preliminary point quite inadequate to the suppression of speculation, but also we have to bear in mind that the physiological process composing sensation does not end with the mere reception and interpretation of the stimulus; we still have to reckon with the higher faculty of which sensations are the essential basis, consciousness.

Now, however, we reach a particularly thorny part, one where speculation completely masters proof and one which I must refrain from entering because my only weapon, the microscope, is of little service as an aid to argument. I will indicate only that, reasoning on lines suggested by Hughlings Jackson's master mind, it may be contended that common sensation is first represented in the cortex of the "postcentral" area proper, and that after being re-represented in the "intermediate postcentral" area it has a still further representation in the physical basis of consciousness, and this may be situated in the "parietal" area. In this connection it is interesting to observe that the area designated "parietal" lies wholly within the field mapped out by Flechsig from studies on myelogenesis and called by him on hypothetical grounds the "great posterior association centre."

I will close this chapter with a reference to the parietal region in animals lower than man in the vertebrate scale; for although studies in comparative anatomy do not assist us in determining its function it will still be interesting to obtain a view of the part from the standpoint of homology.

Taking the phylogenetic history of the principal fissures hereabouts, there seems to be no doubt that the ansate fissure in lower animals becomes the postcentral in primates, while the lateral and post-lateral fissures become the ramus horizontalis and ramus occipitalis of the intraparietal fissure respectively (Elliot Smith). Then on the mesial surface, part of the intercalary sulcus may become the post-limbic. Between these different fissures, therefore, exists the homology of the superior parietal lobe.

Histologically it has been found by Professor and Madame Vogt in a developmental study of the brains of the domestic cat and dog, that the surface can be subdivided into three different areas, in accordance with the period at which the cortical fibres receive their myelinic investment, viz. precocious, intermediate, and late regions (regiones precoces, intermediae et tardivae). Two chief precocious areas are found, one anteriorly in the region of the cruciate sulcus, the other towards and on the occipital pole; between these precocious regions, bounded internally by the splenial or intercalary sulcus and externally by the suprasylvian sulcus, lies the intermediate region. The rest of the cortex, that which would correspond to the common temporal and common limbic areas of man, is late in maturing.

Now in the anterior precocious region Professor and Madame Vogt do not, so far as I am aware, make any subdivision, but from an examination of the brain of the adult cat, dog, and pig, carried out in my laboratory, I am of opinion that the field can be broken up into two, representing the primate "precentral" and "postcentral" areas respectively. Concerning the posterior precocious region there seems little doubt that it represents the visual area.

Therefore, just as in man and the manlike ape the "parietal" area is neatly intercalated between the central and visual fields, so it is also in the case of these lower animals.

A question which has formed the subject of a considerable amount of debate is that concerning the relative size of the parietal lobe in man and in the mammalian series, and it is now virtually decided that a high development of this lobe is one of the most important superior characteristics of the human brain. Taking this for granted the point does not help us in settling its function, but whatever this be, the existence of a homologous area practically throughout the phylogenetic mammalian series makes it certain, or at least extremely probable, that the function likewise has its representation.

Summary.

1. The term "parietal" is being applied to an area which may be briefly described as covering the precuneus, the superior parietal gyrus, and the anterior part of the supramarginal gyrus.

2. Structurally its cortex possesses all the cell laminae of and a similar arrangement of nerve fibres to the "intermediate postcentral" area, but it differs in containing a smaller number of special large pyramidal cells and of large medullated nerve fibres; it is also peculiar in showing a more perfect reduplication of the line of Baillarger.

3. In the adult brain no important topical variations can be defined in the area. The richness in nerve fibres of the superior parieto-occipital annectant gyrus (Flechsig's supraangular area) has been noticed, but only occasionally and then in association with a forward extension of the "visuo-psychic" area, of which it forms a part.

4. A similar cortical formation in and distribution of this area obtain in the anthropoid ape, but the field suffers a reduction in extent in the region of the precuneus.

5. A homologous area can be traced phylogenetically throughout the vertebrate series.

6. To electrical excitation the area is irresponsive, and histology seems to favour the clinical doctrine that it shares with the "intermediate postcentral" cortex the function of elaborating complex impressions embodied in the muscular and stereognostic senses. Here, however, the localisation of the higher faculty of which sensations are the essential basis, consciousness, has to be borne in mind, but being wrapt in speculation this difficult question is not entered into.

REFERENCES.

Theodor Kaes. Beiträge zur Kenntniss des Reichthums der Grosshirnrinde des Menschen an markhaltigen Nervenfasern. *Archiv f. Psych. u. Nervenkr.*, Band xxv, Heft 3, 1893.

Carl Hammarberg. *Loc. cit.*

P. Flechsig. Developmental (myelogenetic) Localisation of the Cerebral Cortex in the Human Subject. *Lancet*, Vol. ii, p. 1027, 1901. Other papers already quoted.

O. and C. Vogt. *Loc. cit.*

C. von Monakow. *Loc. cit.*

A. Tschermak. *Loc. cit.*

J. Hughlings Jackson. The Lumleian Lectures on Convulsive Seizures. *Lancet*, Vol. I, 1890.

Elliot Smith. *Loc. cit.*

Durante. *Loc. cit.*

Walton and Paul. *Loc. cit.*

Redlich. *Loc. cit.*

Bernhardt. *Loc. cit.*

Westphal. *Loc. cit.*

Henschen. *Loc. cit.*

Vetter. *Loc. cit.*

CHAPTER IX.

THE INTERMEDIATE PRECENTRAL AREA.

THE necessity for contrasting the structure and discussing the function of the pre- and post-Rolandic cortex conjunctively was so strong, that I have been prevented from considering the area for which I now claim attention in its proper place, in connection with the "precentral" or motor area. That it bears a structural likeness to the "precentral" cortex I hope to place beyond question, and that physiological affinities likewise exist seems extremely probable. Indeed the principal themes arising for discussion in this chapter all bear on the motor function; they include a consideration of the possible share taken by this cortex in the execution of what we understand by skilled movements, of the stability of the term "psycho-motor," and of the exact localisation of the cortical realm dominating the motor speech mechanism. And in reference to the last topic it is interesting to know that the "intermediate precentral" field embraces the classical area of Broca.

TYPE OF FIBRE-ARRANGEMENT. (Plate XXI, fig. 1.)

On examining with the naked eye a transverse section of the "precentral" and "intermediate precentral" cortex, stained for the display of its contained nerve fibres, it may be noticed, on passing from behind forwards, that although the transition in character from one type to the other is by no means abrupt, still a diminution in the intensity of coloration of the cortex, particularly of the radiary zone, signals the advent of the "intermediate" arrangement. This change in the colour-tone betokens a decrease in the general fibre-wealth, and as a result the line of Baillarger acquires a distinctness it did not have before, and, moreover, becomes reduplicated. But it is curious to observe that the general fibre-loss is not accompanied by a noticeable reduction in cortical depth.

Examined under a microscope the following details become apparent.

Zonal Layer.

The passage from typical "motor" to "intermediate" cortex is marked by a distinct deterioration in the representation of the zonal layer. The band formation loses in density and its lower border becomes ill-defined.

The layer is mainly composed of delicate varicose fibrils, only a few varicose fibres of the coarse variety are recognisable, and the large evenly-medullated elements so characteristic of the typical motor cortex are decidedly scarce. These observations apply to appearances seen in the middle of the area, for the representation is better in the immediate neighbourhood of

the "precentral" area proper and worse along the anterior margin: in other words, it shows a gradual falling off from behind forwards.

Supraradiary Layer.

Compared with the same layer in the "precentral" area, this is poorly supplied with nerve fibres, the difference being specially noticed at the level corresponding with the second layer of nerve cells (small pyramids). The field is occupied mainly by fine short fibres, lying in all directions but mostly having a transverse trend. An occasional ascending fibre of Martinotti stands out on account of its larger calibre; and in the lower parts, where the fibre-wealth increases, long transverse fibres of medium size, which probably belong to the association system, are recognised.

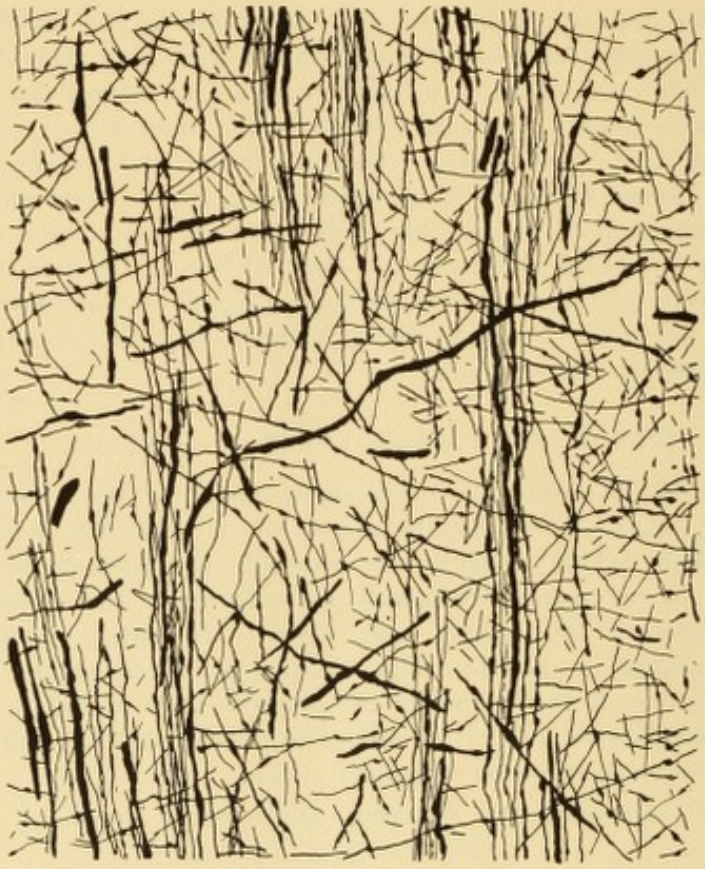

FIG. 21. The radiary zone in the intermediate precentral cortex at a magnification of $\frac{42}{1}$.

Compared with the corresponding drawing from the precentral area, figure 1, page 25, a great reduction in number of large medullated fibres will be noticed; some of these fibres are however still present in the radiating fasciculi and interradiary plexus, but fine wavy varicose fibres predominate.

The Line of Baillarger.

Although its upper and lower boundaries defy accurate definition, yet the line is well represented and is of great breadth. Its principal constituents are short, delicate, transverse fibres, but some long, medium-sized, non-varicose members give prominence to the band.

The doubling of the line, previously alluded to, occurs half-way down the radiary zone, but the second line is not nearly so broad or so prominent as the first.

Radiations of Meynert.

The fibre-strength of the radiations must be described as good, for each contains a number of fine wavy varicose fibres, and two or three evenly-medullated fibres of medium size help to strengthen the individual fasciculi. But medullated fibres of great size, like those found in the "precentral" cortex proper, are present only in the hinder parts of the area, and even here are not numerous.

Interradiary Plexus.

The interradiary plexus proper is composed of an abundance of fine fibres, and on examination under a high power most are seen to be varicose.

Association Fibres.

We have seen that in the "precentral" area the whole radiary zone is filled by an extremely rich plexus of large medullated fibres running in all directions. In the "intermediate" area, remnants of that plexus are visible and the constituents are similar as regards size and position, but there is an enormous reduction in their number, for proof of which one has only to take a single glance at sections showing the two fields.

I would here say that poor though the association system—in fact the whole radiary zone—is by comparison with that in the "precentral" area, it is still rich by comparison with the same zone in the cortex of other regions: for instance, the remainder of the frontal lobe, the "parietal," "temporal," and "limbic" areas; indeed its fibre-wealth, in this particular position, does not fall far short of that observed in the "postcentral" and "visuo-psychic" areas, two fields which have been described as particularly well-endowed in this respect. I would further add, that in the position of the inner line of Baillarger there is an appreciable increment of large "association" fibres, and that such fibres are, as usual, more numerous in the immediate vicinity of the white substance than elsewhere. Some of these fibres can be traced for a long distance, and considerable importance is to be attached to their presence, as they may be conveyers of impulses concerned in the execution of movements of an associative kind, to be mentioned hereafter. I might finally state that the total depth of the radiary zone is great, almost equal to that in the precentral area proper; and that, as in the latter, the fibres exhibit an appreciable numerical and volumetrical diminution as the area is descended.

TYPE OF CELL LAMINATION. (Plate XXI, fig. 2.)

In describing the type of cell lamination covering this area, I shall again emphasise the features which distinguish it from the "precentral" type.

The cell architecture has been studied in serial sections, which, in the case of the extent of the area on the mesial surface, ran vertically, and, on the lateral surface, transversely; in this way, the most satisfactory display of the transition from primary to intermediate type is obtained.

Plexiform Layer.

This lamina may be slightly shallower and may contain a few less nerve cell elements, but it does not differ markedly from the same layer in the "precentral" area.

Layer of Small Pyramidal Cells.

Morphologically the cells in this layer resemble those in the "precentral" area. A comparative cell count has not been made, but in the "intermediate" field a more closely packed appearance suggests a numerical increase.

Layer of Medium-sized Pyramidal Cells.

There is no point of distinctive value to be noted concerning this layer. In the "intermediate" field there is an apparent increase in depth but it carries little importance.

External Layer of Large Pyramidal Cells.

It is an interesting truth that throughout the "intermediate" cortex pyramidal cells are to be found at this level, equal in size, similar as regards chromophilic elements, and as strong in point of number as in the "precentral" area; in fact the layer exhibits no feature sufficiently distinctive to be made use of in formulating a differential judgment between the two fields. Topographic variations, however, have to be noted; in that part immediately bordering the "precentral" area, the cells are appreciably larger than they are towards the opposite margin, and it may be added here, that the cells undergo some diminution in volume as the area is descended.

Although alike in these two subdivisions, the same cells constitute a reliable guide in distinguishing this cortex from that of the more anteriorly-placed frontal convolutions, as well as from that of other regions; for with the exception of the "postcentral," the "visuo-psychic" and the "auditory temporal" cortex, there is none accommodating cells of equal size and number at this particular cortical level. And another feature peculiar to the "intermediate" and to the typical "precentral" cortex is that the cell constituents of this lamina strive to preserve an equality in size, that is to say, they do not commingle with cells of smaller diameter to the extent obtaining in most other parts of the brain.

On comparing sections stained for nerve cells with sections which display the nerve fibres, it may be observed that the chief or outer line of Baillarger occupies a level corresponding identically with these large pyramidal cells, and there seems to be no doubt that extensions or collaterals of the same elements augment the prominence of the line.

Layer of Stellate Cells.

In sections stained for nerve fibres there is a narrow pallid zone, immediately underlying the outer line of Baillarger, which marks the position of the stellate lamina. But when we come to examine sections treated for the demonstration of nerve cells, we find that this layer, although easy to orientate, is poorly supplied with constituent elements, and therefore does not appear as a composite line; indeed, we can only say that between the large external pyramidal cells and the deep layer of large pyramids, to be next referred to, there is a clear

interval or break in which a few minute stellate, pyramidal, or polymorphous cells are dotted about, and some of these elements encroach upon the pyramidal layers above and below, just as they do in the case of the "precentral" cortex.

The layer is perhaps defined with greater facility in the intermediate than in the typical "precentral" field, but its poor development compared with other regions is a noteworthy feature of the combined "precentral" areas[1].

Internal Layer of Large Pyramidal Cells.

Here the resemblance between the "precentral" and "intermediate" types of cortex ceases. The presence of the giant cells of Betz in the former and their complete absence in the latter constitutes a fundamental point of difference. Cells of pyramidal or pear form to which the designation "large" is applicable are present, however, in the "intermediate" cortex, but these do not approach the cells of Betz in size and are even appreciably smaller than the elements in the fourth or outer layer of large pyramidal cells: they are likewise distinctly less numerous than the latter cells, although they are possessed of chromophilic elements arranged in a similar manner, and again tend to preserve a uniformity of size; all features serving further to distinguish this part from the remaining anterior frontal cortex.

It was noted in the description of the fibre-arrangement that the "intermediate precentral" cortex shared with other regions a reduplication of the line of Baillarger: this line is now found to correspond in point of level with the deep layer of large pyramidal cells, just in the same way as the outer line corresponds with the external large cell layer.

Layer of Fusiform Cells.

Following the deep layer of large pyramidal cells is a distinct and deep stratum of fusiform or polymorphous elements, arranged as usual in columns determined by the radiations of Meynert, but possessing no distinctive characters.

DISTRIBUTION. (Plate XXII.)

The field covered by the type of cortex of which the fibre and cell characters have been just described ranges as a zone between 3·5 and 1 cm. in width, placed after the manner of a buffer in front of the "precentral" area proper. In addition, and this is a point of special importance, it reaches downwards and forwards to the orbital surface of the hemisphere.

The distribution of the area is never exactly alike in any two brains, nor does the anterior boundary always pursue the same course, but the following description is compounded from the examination of all the human brains employed in this investigation and may convey an idea of its average extent.

Starting with that part on the mesial surface of the hemisphere; the area here attains great breadth, usually the line of its anterior limit lies in the hinder part of the marginal gyrus and may be placed quite three centimetres in advance of the "precentral" area. The lower boundary (on the same surface) is generally formed by the calloso-marginal fissure, but in the

[1] A well-developed stellate layer is found throughout the parietal, temporal, and occipital lobes, and, as I shall mention later, the same layer increases in representation as we proceed forward in the frontal lobe. The limbic lobe and parts of the insula may be pointed to as regions in which the layer is either absent or very difficult to define.

frontal direction it leaves this fissure to pass obliquely upwards and forwards to the margin of the hemisphere. Below the "precentral" area (still on the same surface) it merges with the "intermediate postcentral" field.

Along the upper surface of the hemisphere the area is again extensive, reaching well forwards on to the superior frontal gyrus, and it is interesting to notice that it resembles the "precentral" field in attaining its greatest breadth in this its uppermost division

Below the level of the superior frontal gyrus the zone rapidly narrows and becomes confined to the anterior half of the ascending frontal or anterior central gyrus and to a small portion of the base of the middle frontal gyrus.

The behaviour of the area in its further course downwards is distinctly peculiar; instead of ceasing as the "precentral" cortex does towards the lower end of the fissure of Rolando, it sweeps forwards across the deep sulcus precentralis inferior, then after covering most of the surface of the inferior frontal gyrus, including some but not all of the pars basilaris, and the whole of the pars triangularis[1], it turns inwards and creeping along the orbital operculum is not arrested until the sulcus transversus orbitalis is reached.

The sulcus transversus orbitalis and the calloso-marginal fissures, at the upper and lower extremities of the area, respectively, seem to be fixed limits, but excepting these, the boundaries of the field are not determined or even directly influenced by any fissures, and particularly not by the system of precentral sulci, save the upper part of the inferior precentral element. It will be remembered that the anterior boundary of the "precentral" area proper was similarly independent.

The extent of this area on the lateral and mesial surfaces may be seen in Plates I and XXII, and its distribution on the orbital surface is specially indicated in the latter Plate. To prevent misconception I would add that the area never extends on to the insula proper.

INTERMEDIATE PRECENTRAL AREA IN THE ANTHROPOID APE. (Plates II and XXII.)

As the "intermediate precentral" area forms an integral part of the frontal lobe, and as the condition of the frontal lobe is one of our best criteria in estimating comparative grades of cerebral organisation, the study of this area in the anthropoid brain is full of interest. Being but one step down in the phylogenetic scale and having, as we already know, a "precentral" area remarkably akin to that in the human being, it would be strange if the development of the "intermediate" area in these animals exhibited a pronounced departure from the human state: and in the following lines I hope to show that, so far as the representation of the field is concerned, the resemblance is maintained, and that thereby the name anthropoid applied to these beings receives further justification; also, in describing the area I shall give more details than I have in the case of most other areas in the ape.

First, with regard to structure: in this respect it bears a pronounced resemblance to the human cortex, and the same cell and fibre characters can be made use of in determining its boundaries. But as all these features are reproduced on a small scale,

[1] The tendency seems to be for the "intermediate" type to cease along the lip of the Sylvian fissure; in this way the exposed part of the frontal operculum comes within the area, while the covered part takes on the characters of the insular cortex. In some cases the insular type appears to creep up and cover an appreciable extent of the exposed part of the pars triangularis. It will be noticed that in the anthropoid brain much more insular cortex lies exposed than in man.

judgments on cell size and cell lamination are thereby rendered more difficult. I have found my sections stained for nerve fibres preferable for general working purposes, and in these the points which have served best as guides are (1) a wealth of fibres in the radiary zone strictly intermediate between that seen in the "precentral" area behind and that in the area next in front, (2) the presence in the radiary zone of fibres of the large evenly-medullated type, and particularly of such fibres placed in a horizontal position, (3) a zonal layer also of intermediate representation and containing some fibres of larger calibre than any seen in more frontally-placed areas, and (4) a general depth of cortex, not less than that in the "precentral" field, but greater than the same in the prefrontal area.

But it is the distribution more than the histological structure of this area which is so interesting.

Starting with its extent on the mesial surface of the hemisphere. Here the human plan is closely followed: behind, it is of course in contact with the "precentral" area; below, the calloso-marginal sulcus forms a definite boundary, for there is no mistaking the difference between this cortex and that of the subjacent calloso-marginal or fornicate gyrus; anteriorly I can find no named sulcus or part which can be used for purposes of delimitation, the margin curves upwards and crosses the border of the hemisphere at a point about 2 cm. in front of the "precentral" area and about 3·5 cm. in advance of the upper extremity of the fissure of Rolando, at least that is what happens in the case of the chimpanzee, in the orang the extent is somewhat greater.

On the convexity, the great breadth of the area, as seen on the mesial surface, is preserved only for a short distance; at first the anterior border lies about 15 mm. in front of the sulcus precentralis superior, a sulcus easily defined in all three specimens submitted to examination, but instead of proceeding downwards parallel to the fissure of Rolando, the margin crosses the upper frontal tiers of convolutions more or less vertically, and the next landmark we can make use of is the upper extremity of the sulcus arcuatus, or as I shall speak of it hereafter, the sulcus precentralis inferior[1]. Now to this furrow the area evidently bears the same relation as in the human being, only in all these specimens the intermediate characters seem to cross the fissure and spread on to its anterior lip, while in man they remain behind. In this position, opposite to the so-called horizontal ramus of the inferior precentral furrow, the area is seen at its narrowest.

My description of the remainder of the area must be prefaced with some explanatory anatomical observations, for the disposition of sulci and gyri in the lower frontal region is distinctly confusing to those unfamiliar with the anthropoid brain, and as views on their homologies are discordant it is essential that my description shall be free from ambiguity. Now in addition to the sulcus arcuatus, to which reference has already been made, there are four furrows to which I invite attention: the inferior transverse sulcus of the fissure of Rolando, the sulcus rectus, the anterior Sylvian and the fronto-orbital fissures.

The inferior transverse sulcus of the fissure of Rolando is soon dismissed, for it holds an almost identical position with the human element having the same name. It is present in all my specimens, in one chimpanzee's hemisphere (right side) it is isolated, but in the other and also in the orang's it effects a shallow junction with the lower extremity of the sulcus precentralis inferior, the union being marked by a submerged annectant gyrus.

[1] Differences of opinion have been expressed on the homology between the sulcus arcuatus of the ape and the human sulcus precentralis inferior, but it is satisfactory to know that Eberstaller, Waldeyer, Cunningham, and Elliot Smith are now unanimous in supporting the correspondence.

The sulcus rectus is of greater importance. A furrow constantly present in the ape's brain, traversing the frontal lobe in a horizontal direction, its homology is not so clear. According to some (Eberstaller and Hervé) it is the equivalent of the human sulcus frontalis medius, according to others (Cunningham, Gratiolet) it represents the sulcus frontalis inferior. Into this discussion, even if I were qualified, I have no desire to enter. The sulcus is clearly subject to great variations and I merely wish, for purposes of orientation, to give an account of the parts as they appear in my three specimens. Now in all three hemispheres, a deep sulcus is seen springing from the vertical portion of the sulcus precentralis inferior and occupying a position and following a course which certainly corresponds very closely with that taken by the sulcus frontalis inferior, or sulcus frontalis secundus as it is sometimes called, of the human brain. For this and other reasons, I look upon and shall hereafter call this sulcus, the sulcus frontalis inferior. In the orang's hemisphere and in the chimpanzee's hemisphere of the right side, this sulcus runs forwards for about 2 cm. and terminates blindly. The main division of the sulcus rectus lies at a higher level, and, in my opinion, just in the position which the sulcus frontalis medius would occupy in the human brain. In the left chimpanzee hemisphere my sulcus frontalis inferior is not isolated but forms the hinder portion of one long continuous sulcus rectus. It will thus be apparent that if I were driven to give an opinion on the homologies of the simian sulcus rectus, I would take a middle course and say, that the hinder part, perhaps a third, represents the sulcus frontalis inferior, and the remainder the sulcus frontalis medius.

Concerning the so-called anterior limb of the Sylvian fissure, it has been unequivocally demonstrated by Cunningham and Elliot Smith on ontogenetic and phylogenetic grounds which there is no occasion for me to repeat, that an anterior limb of the Sylvian fissure, *sensu stricto*, does not and cannot exist in the anthropoid brain; the furrow commonly mistaken for such is nothing but the superior limiting sulcus of the island of Reil. In all my specimens, this sulcus is seen peeping out on to the surface immediately anterior to the frontal operculum and, as I shall presently show, histology suggests that the view concerning its homology just given is correct.

The long sulcus fronto-orbitalis so well-marked in all the higher apes is also clearly seen in my specimens and cannot be mistaken for anything else. It is a fissure which for me possesses great interest, but in the meantime I would merely say that I have become convinced of the anatomical correctness of regarding it, or at any rate its lower half, as the anterior limiting sulcus of the island of Reil. It therefore follows that for a proper understanding of this part we must bear in mind that the exposed surface in the anthropoid brain, lying between the anterior limiting sulcus (fronto-orbital) and the superior limiting fissure (so-called anterior Sylvian), becomes submerged and forms a part of the insula in the human being.

Continuing my description of the "intermediate precentral" area I will now show that the distribution of this cortex is influenced in a remarkable manner by the disposition of sulci. As may be seen in Plate XXII, the intermediate cortex after covering the lower end of the ascending frontal gyrus spreads forwards and crosses the inferior precentral and inferior transverse fissures, enveloping the whole of that block of substance included between what I am calling the sulcus frontalis inferior above, and the superior limiting sulcus of the island of Reil below. As this block seems to represent the pars basilaris of the frontal operculum, we accordingly have a human reproduction. It is the further distribution which is peculiarly interesting, and which helps to establish some of the above-mentioned homologies. Instead of curling round the superior limiting fissure of the insula and covering the substance intervening between this fissure and the sulcus fronto-orbitalis, it leaves this small area entirely alone, and passing upwards and forwards invests the upper end of the fronto-orbital sulcus; then turning abruptly downwards, and still following the fronto-orbital sulcus, it coats the convolution forming its anterior wall, and is finally arrested well down on the inferior surface by the sulcus orbitalis.

Having expended much time and trouble over this undoubtedly difficult area, I think I have given a correct account of the nature of its enveloping cortex, and curious though the distribution at first sight may appear, all is readily explained if we view the parts from the standpoint

of homology and at the same time bear in mind how this type of cortex is distributed in the human being. Now as I have already mentioned the simian fronto-orbital sulcus is the supposed, and I believe the actual, homologue of the anterior limiting sulcus of the Island of Reil; this being so, the convolution bounding it in front must be the equivalent of the human orbital operculum; in man the orbital operculum is covered by an "intermediate precentral" type of cortex; in the ape, therefore, we find a corresponding state of affairs, only our opercular strip of "intermediate" cortex is thrown forwards. Further, the small area of cortex intervening between the superior limiting sulcus of the insula ("anterior Sylvian") and the fronto-orbital sulcus is not enveloped by an "intermediate precentral" type of cortex, because, as Cunningham and others have pointed out, it is homologous with the anterior end of the insula, it is the relic of the exposed insula prevalent in animals lower down in the scale, and the histological examination of its cortex gives full support to this belief.

FUNCTIONS OF THE "INTERMEDIATE PRECENTRAL" AREA.

In previous chapters the doctrine of Munk, Bastian, Mott, and others that the so-called regio Rolandica bears a mixed sensori-motor function has been contested, and allegiance given to the teaching of Ferrier, Schäfer, and more recently, Sherrington and Grünbaum, that motion and sensation have separate and independent cortical representation. Similarly in the case of the area which I have defined and called "intermediate precentral," I refuse to believe, as some maintain, that it has a dual function in the narrow sense of the term.

Turning for a moment to the masterly considerations of Hughlings Jackson, we find it suggested that movement is represented at three levels of the central nervous system. The first or lowest level consists of the cord, medulla and pons, it represents simplest movements. The second or middle level is composed of the "so-called" motor region of the cerebral cortex, it represents complex movements (re-represents). The third or highest level is composed of centres occupying the frontal lobes, it represents most complex movements (re-re-represents). Proof in support of this hypothesis—and proof of the strongest character—has been adduced by Hughlings Jackson himself, and the evidence gathered in the years which have passed since his view was expressed, only necessitates slight modifications, without in the least affecting its main basis. One modification which I would suggest concerns localisation and receives justification in some observations set forth here and elsewhere; it is that instead of localising the middle or second level in the old "motor region," which embraced the whole Rolandic zone, I would place it in the restricted area which I believe to have structural characters of an essentially motor kind, and to which I have given the name "precentral." Now if we regard the "precentral" area proper as the "middle or second level," I think that more can be said in accordance with Hughlings Jackson's reasoning, and I will submit that the "intermediate precentral" cortex, now under consideration, forms a very important part (I should be going beyond bounds if I said the whole) of "the highest or third level." I am of opinion that this particular stretch of cortex is specially designed for the execution of complex movements of an associated kind, of skilled movements, of movements in which consciousness or volition takes an active part, as opposed to automatic movements, and my remarks will now be devoted to the development of this thesis.

First, looking at the area from the histologist's point of view. Not only is it deposited in close relation to the "precentral," or as we may now call it the "primary" cortical motor area, but it possesses structural characters which betoken physiological kinship. Thus in

comparing the cell lamination in the two parts, merely leave the giant cells of Betz out of consideration, and the differentiation of the two types becomes a matter of appreciable difficulty. Similarly with the nerve fibres, the difference is only one of degree of fibre-wealth, the plan of arrangement is alike, and both contain constituents of the same nature: indeed, so great is the likeness that in sections stained for nerve fibres, in which the cells of Betz are not apparent and cannot be used as guides, it is impossible to say with absolute accuracy where one type terminates and the other begins. I repeat, therefore, that these histological resemblances suggest a physiological relation, and knowing beforehand what intimate connections exist between the Betz cell area and the system of lower motor neurones, it is impossible for the histologist to believe that the "intermediate" area with its kindred structure does not take a share of some kind in the conduct of motor performances.

Let us think next of what experiment teaches concerning this area. Let us recall for a moment the extent of the field found susceptible to electrical excitation by observers who experimented prior to Sherrington and Grünbaum and who gave us our original maps of motor localisation, and let us compare those maps with the scheme which I have drawn up on a histological basis. In particular let the comparison be applied to the brain of the anthropoid ape, and for this purpose the investigation conducted on the brain of the orang (Simia Satyrus) by Beevor and Horsley may be specially chosen, because this is an animal of which I have made collateral histological use. It is the anterior border of their area which interests us most; along the upper part of this, excitation produced movements of the neck, along the lower part, movements of the eyes; and on looking at its position in Horsley and Beevor's figures I think it will be agreed that it coincides, perhaps not precisely, but remarkably closely, with my line of histological demarcation: indeed, excepting the part behind the Rolandic fissure[1], their whole area is practically identical with my combined "precentral" and "intermediate precentral" fields. So much for the orang; on broader lines the comparison is capable of extension to the lower apes, but not having examined the brains of one of these animals I am of course unable to say whether the agreement is equally close. Nevertheless, I think the assertion justifiable that just as the effects of unipolar faradisation as employed by Sherrington and Grünbaum are limited to the field of cortex distinguished by what I have called the "precentral" type, so also the effects of faradic excitation as employed by earlier experimenters do not extend beyond the limits of the field of cortex possessing what I have called an "intermediate precentral" type of structure. In other words, coupled with the structural differences which I have described, there are in the two precentral fields, differences in reaction to faradism by which their extent can also be determined. Now it seems idle to suppose that the invariable reaction to strong faradism of the anterior part of this field and the remarkable agreement between its physiological and histological extent means nothing: on the contrary it suggests in no weak manner that this cortex possesses some motor property, and so an opening is made for further argument.

It is interesting in the next place to compare my "intermediate precentral" area with Flechsig's topographic schemes drawn up on the basis of myelogenic development. This comparison affects the human brain. In Tafel IV of "Gehirn und Seele" (1896) repre-

[1] In the chapter on the "postcentral" area sufficient grounds have been given for believing that the postcentral cortex is non-motor, and bearing on the point, it is interesting to find Beevor and Horsley stating that it was much more difficult to excite movements from the postcentral than from the precentral cortex.

sentations of the extent of what Flechsig calls the "sensory projection centres" are given, and I would draw attention to the anterior portion of the great central field, and particularly to the more sparsely dotted zone lying in front of the ascending frontal convolution and its paracentral annexe. Now the area which Flechsig indicates on the mesial surface of the hemisphere cannot be said to coincide with mine; his field proceeds considerably further forwards and he also extends it on to the subjacent gyrus fornicatus; but on the lateral surface the agreement, so far as the anterior border is concerned, is extraordinary: broad over the upper frontal gyrus, the area rapidly narrows at the level of the inferior precentral fissure, and finally sweeps forward to cover the frontal and orbital opercula, in just the same manner as my "intermediate precentral" type does; indeed, his diagram might almost be used to illustrate the points in topography which I have previously emphasised. When we give further thought to the working basis on which the embryologist has to rely in defining his cortical areas, we soon discover the reason why results are obtained on all fours with those forthcoming from an analysis of nerve fibres in the adult cortex. It is, that if any of the areas mapped out by Flechsig in the developing human brain, or by Vogt and Döllken in the brains of lower animals, be examined in the adult condition they will be found to be characterised one and all by the possession of fibres of large calibre, not always arranged in the same manner and not to be seen in equal abundance, but always present. And I think Flechsig will admit that the principal working guide in his classical research has been the developmental peculiarities and the appearances in general exhibited by these larger elements; a point which favours the correctness of this surmise is that the method of staining employed by Flechsig, that of Pal, while admirably adapted for the demonstration of fibres of large and medium size is of little value, and certainly far behind the method of Wolters-Kulschitzky, for displaying the more delicate fibre constituents. If then these large fibres have the importance here suggested we have the key to the situation, for the same fibres have also served as one of my guides; but not the only one, for I have also taken full notice of the accompanying type of cell lamination; and as to my area on the mesial surface, the confines of which disagree with those laid down by Flechsig, having mapped it out by both its fibre and cell characters I am more than satisfied that it would be incorrect for me to extend it across the calloso-marginal sulcus and on to the gyrus fornicatus, as Flechsig does his.

ON SOME ASSOCIATION TRACTS OF FIBRES.

Before proceeding to the consideration of what clinical medicine teaches us of the functions of this area it will be necessary to intercalate something of its anatomical connections. For there is no question that by means of subcortical tracts of fibres this region forms important connections with other parts of the brain, and I think this statement is justified notwithstanding that the exact origin, course, and function of these tracts is not established and our general knowledge of them not so complete as might be wished.

The Frontal Pontine Tract.

Deserving of mention in the first place is the frontal cerebrocorticopontal path (Barker)—frontale Grosshirnrinde Brückenbahn of Flechsig. Flechsig, who studied this tract in the developing brain and proved that it became medullated later than the main motor tract, maintains that its fibres are centrifugal; having origin in the large pyramidal cells situated in the hinder portion of the three tiers of frontal convolutions (and possibly also in the middle portion of the gyrus fornicatus), its fibres, having collected, enter

and occupy the frontal division of the internal capsule near the genu; and then, having passed through the crus cerebri, internal to the main motor tract, they terminate in the pons. As to the impulses conveyed by the tract, Flechsig is of opinion that it is concerned with the movements of bilaterally innervated muscles, and that it includes motor speech fibres[1].

To me the feature of greatest interest concerning this tract, as described by Flechsig, is the assigned field of origin, the hinder portion of the three frontal gyri and perhaps the middle of the gyrus fornicatus, for one is immediately struck with the point that, leaving out the gyrus fornicatus, it virtually coincides with the extent of the "intermediate precentral" field of cortex. Bearing in mind the histological structure of this part with its large pyramidal cells and large nerve fibres, one cannot fail to appreciate the force of Flechsig's statement that the tract originates from the large cells here situated and is composed of their axons; and von Monakow's well-known example of degeneration of the tract secondary to a lesion of the hinder part of the middle and lower frontal gyri must be acknowledged in favour of this assumption. Nevertheless it has to be mentioned that this origin is not generally accepted, for Déjerine excludes the upper part and confines the source to the Rolandic and adjacent frontal operculum, while Zacher attaches importance to the cortex of the insula; their respective grounds for doing so, however, need not be detailed.

Looking upon the above-described fasciculus as a projection tract, I have now to mention some bands of an associating nature.

The Tapetum.

The best account of the connections of the tapetum is that given by Déjerine; by this observer it is called the fasciculus occipito-frontalis, the whole cortex of the frontal lobe is said to give origin to it and passing backwards in a position mesial to the corona radiata it is said to be distributed to the cortex covering the lateral surface and inferior border of the occipital lobe, a field corresponding, by the way, with that which I have called "visuo-psychic." But although Muratow has seen degeneration in the tapetum after lesions of the frontal lobe, and although the whole of the frontal lobe is given as its source, I do not know of any evidence, one way or the other, to show that it has special connections with the area in which we are at present interested; still we are compelled to take notice of it because it is such a well-known tract. The controversial question of the relation of the tapetum to the corpus callosum does not concern us.

The Fasciculus Longitudinalis Superior.

Like the tapetum, the fasciculus longitudinalis superior is supposed to couple the frontal and occipital lobes, but it lies lateral instead of medial to the corona radiata. Its fibres are said to vary in length and to be for the most part short. A portion of the tract is figured as following an arciform pathway, placed above the level of the insula, by which the lower frontal cortex becomes connected with the upper temporal; and in the left hemisphere, in connection with the function of speech, much importance is attached to this association.

Fasciculus Uncinatus.

The exact origin and destination and likewise the functions of the fasciculus so named are obscure; curving beneath the limen insulae, by some it is said to pertain to the rhinencephalon, while others assert that it associates the tip of the temporal with the base of the frontal lobe.

Short Association Tracts.

In addition to these long association tracts possibly having connections with the "intermediate precentral" area, short bands, the fibrae propriae, are to be reckoned with as connecting adjacent convolutions and parts; thus by means of commissural horizontal fibres corresponding levels of the "intermediate" and "precentral" areas are brought into association, and in the same way the "intermediate" cortex is connected with more anterior parts. Similarly, vertically-placed fibres couple different levels.

[1] A further supposition is that, by means of an extension of neurones from the pontine nuclei to the cerebellum, it serves to throw the latter under the influence of the opposite cerebral hemisphere.

Summing up what has been written in the foregoing paragraphs we find that it is possible to determine the limits and extent of the strip of cortex to which I have given the name "intermediate precentral" by no less than three methods, viz., by experimentation, by developmental investigation, and by histological examination in the adult condition. And although, if we except the results of experiment, this does not bring us much nearer our explanation of its function, still the coincidence of results is full of suggestion, particularly when considered along with what we already know of the contiguous "precentral" area proper, and above all when taken in conjunction with the teachings of clinical medicine. Having also seen that this field has important associations and connections, the ground is now cleared for the further pursuit of evidence which will help to prove that its enveloping cortex is specially designed for the control of skilled movements of an associated kind.

MOTOR APHASIA.

In view of my thesis, the most suggestive fact brought out by histology is that the "intermediate precentral" field embraces the classical area which we associate with the name of Broca, the centre for speech, the centre for a faculty which is a skilled movement in the highest degree. We can now discuss this function, and while I must digress to a certain extent to do this I would point out that I do not propose to give a full analysis of the highly developed sensori-motor combination involved in the faculty of speech; I shall not follow up the complex theories expressed by authorities on this subject, and I shall pass over the various associative and perceptive components supposed to combine in perfecting this function, in order that my remarks may be confined to the motor element in the faculty and to the localisation of the same component, and that the thread of my argument may not be completely broken.

Since the year 1861 when Broca published his cases of motor aphasia and indicated the association between the power of articulate speech and the posterior part—the pars basilaris—of the left inferior frontal convolution, numerous cases of a confirmatory nature have been recorded, all proving that here we have an exceedingly vulnerable area. But although it is established beyond doubt that a maximum effect is produced by a minimum lesion in this situation, it is not yet proved with equal clearness and with a sufficient degree of exactitude upon what structure, what particular collection of neurones, the integrity of the high motor mechanism involved in articulate speech essentially rests. In plainer terms, in the numerous cases of motor aphasia resulting from beautifully localised lesions which have been recorded, and in the instances which many of us have seen in our own practice, it is not known whether destruction of the cortex, and of the cortex only, of the pars basilaris has been the essential lesion in the production of the speech defect, or whether it has been due to interruption of subjacent associating or centrifugal neurones, and in what degree either of these has shared in bringing about the disability; in short the essential link in this mechanism still remains to be decided.

Recalling what we have learned from experiment and clinical experience concerning localisation of the cortical elements primarily governing movements of the larynx, tongue, mouth, and lips, we may assume, and I think reasonably, that as in the anthropoid ape the elements I have named are deposited in the ascending frontal gyrus in the precincts of the lower end of the fissure of Rolando, so is it also in the human being. But on topographical and clinical grounds we know that this particular part does not represent the

higher speech centre; although in close apposition and without doubt possessing associations of the highest importance it does not form an integral part of Broca's area, as is clearly proved by the fact that motor aphasia is not accompanied by actual paralysis of the muscles concerned in articulation. For motor aphasia is definable as an annihilation of the power to call into action and execute the complex associated series of oral, lingual, and laryngeal movements resulting in articulate speech; it is a case of the motive power for special, combined, skilled movements being in abeyance, while the muscular mechanism for simple movements remains intact; and the centre, evidently a combined one, for this higher function lies apart from the several primary centres.

Now most clinicians insist that in the lesion limited to the area of Broca, so commonly productive of motor aphasia, destruction of the cortex alone is the essential factor, but this is an assumption against which I must protest, and on the following grounds.

In the first place, if an isolated patch of cortex like that covering the pars basilaris of the lower frontal gyrus be so specialised as regards its function it is surely reasonable to expect that its structure would be likewise specialised, but to the best of my knowledge this is not the case. On account of its physiological importance it is a part to which I have paid most careful attention, and although its peculiar conformation renders its microscopic examination in serial sections difficult, I have now been over the field so repeatedly that I think I can say with safety that I have not overlooked any gross peculiarity of fibre arrangement or cell lamination, and I will repeat that histologically the area of Broca pertains to the "intermediate precentral" field; its type of cortex, as displayed by the methods I have employed, does not differ from that situated immediately above, nor from that extending in continuation with it forwards and round to the orbital operculum; also, so far as I am aware, no other histologist has discovered any special formation in this particular cortical subdivision.

This is of course negative evidence, but it gains in significance when all the data of clinical experience, both the positive and the negative, are considered together with it. Thus in cases of tumour, meningitis, and allied conditions in which the lesion though accurately localised is irritative and superficial in kind, it is a matter of common knowledge that if aphasia results, it is of a transient nature. On the contrary, in cases of lesion extending to the underlying parts the disability is permanent. Now the condition which in the majority of cases is responsible for permanent motor aphasia is the occlusion of a twig from the anterior frontal branch of the middle cerebral artery specially destined for this part[1], an occlusion which may be of thrombotic or embolic origin; and as von Monakow points out, and as I have seen on careful examination of the left hemisphere of two perfect cases coming under my own observation, not only is the cortex destroyed by this occlusion but the necrotic disintegration penetrates deeply into the subjacent white substance placed anterior to the lenticular nuclei and internal capsule, and in my opinion it there interrupts fibres of the highest importance, but obviously not coming entirely from the cortex of the area of Broca, because as I have just said a surface lesion limited to this area is inadequate to the production of complete and permanent aphasia.

[1] The anterior frontal is usually the second branch given off by the middle cerebral artery, one to the orbital lobe being the first and another to the ascending frontal gyrus the third. But the distribution of these vessels is very irregular, and occasionally the twig to Broca's area is a special one, arising independently instead of from the anterior frontal branch.

A third cerebral hemisphere which I have placed in the museum at Rainhill Asylum and carefully examined is illustrative on the negative side of this question. The individual (a middle-aged man) from whom it was taken, was twice an inmate of the institution named. On his first admission he had complete motor aphasia; this, however, proved to be transitory and he was discharged at the end of a few months recovered in all respects. He remained out for twelve years and then returned suffering from alcoholic insanity, but he now had no speech defect nor had he been troubled all these years by a recurrence of the old disability. He died suddenly from a perforated duodenal ulcer. At the autopsy an old-standing patch of softening was found in the left hemisphere, and this we attributed to embolism, because there were coexisting signs of old mitral endocarditis; the distribution of the lesion was curious, the lower two-thirds of the pars basilaris were completely destroyed, but on making a series of horizontal sections we found that the destruction did not extend inwards beyond the plane of the surface of the insula: it thus left the white substance anterior to the lenticular nucleus and internal capsule—destroyed in the other cases—intact; some of the fronto-parietal operculum further back, and a portion of the temporal operculum, and also some of the cortex of the insula was obliterated, but the orbital operculum and the pars triangularis were quite untouched. Now I am quite certain that anyone inspecting this specimen would at once say that the individual must have suffered from permanent motor aphasia; placed beside the two hemispheres from cases of complete motor aphasia already alluded to, the area of destruction, as seen from the surface, is quite correctly placed, and indeed more extensive. There being an old-standing anatomical defect we are forced to assume that it was the cause of the transient motor aphasia from which this person suffered earlier in life, and we are also compelled to accept the illustration provided by the case on the striking difference in effect between a superficial and a penetrating lesion. These were cases which came under my own observation; many others telling the same story could be cited from the records.

Naturally, therefore, we must assume from clinical evidence that the cortex covering the small area of Broca does not wholly represent the seat of government of the motor element in speech.

Secondly, the inference which one derives from a complete histological study of the cortex in this situation is that since the cortex of the inferior frontal convolution anterior to the pars basilaris, and also that of the orbital operculum, is identical in structure with that of Broca's field, and since also the presence of an abundance of intra-cortical association fibres is a character common to these parts, therefore this anterior prolongation of the "intermediate precentral" formation may share with the cortex of Broca's area the higher function of exciting the primary oral, lingual, and laryngeal centres, lying more posteriorly, to the production of the complex system of movements adequate to articulation. In accordance with this hypothesis, if speech is to be abolished by a superficial lesion confined to cortex that lesion must affect the whole of the combined area indicated.

Thirdly, the reason which can be advanced to explain why a limited but penetrating lesion in the area of Broca produces motor aphasia in its complete form is that the associations between all this cortex and the direct oral, lingual, and laryngeal centres placed along the lower end of the ascending frontal convolution suffer interruption.

Unfortunately I am acquainted with no clinical evidence which can be advanced either for or against the view that the speech area has the extended distribution here suggested, although possibly such evidence may exist. A lesion strictly confined to the cortex only of the

area indicated, and leaving the lower end of the ascending frontal convolution intact, would be an anatomical rarity; a case of localised meningitis might supply the needed condition, but the arterial supply of the parts is such that we could not expect it from a case of occlusion by thrombosis or embolism, or from a haemorrhage.

Also experiment is silent on the question. The region has been carefully explored by Sherrington and Grünbaum in the anthropoid ape, and they state that "faradisation of the cortex of the inferior frontal convolution has failed so far to elicit movements of any satisfactory degree of regularity or constancy; and this even under use of currents much stronger than those which suffice when applied to the 'motor' cortex proper. From the posterior region of the convolution, at scattered points, and without constancy even at them, strong faradisation occasionally seemed to induce movements in the larynx, distinguishable from the rhythmic of respiratory origin." And they conclude "that either (1) no Broca 'speech centre' at all foreshadowing the human exists in these brains, or (2) that direct faradisation of the Broca speech cortex is inefficient in itself to evoke vocalisation."

These results are disappointing, for although speech is denied them it seems right to suppose that the vocal sounds which the ape is capable of uttering, and indeed likewise many of the calls and cries of other vertebrates lower in the scale, are to them as speech is to the human being, and that the nervous mechanism concerned in their production is of a kindred nature. Reasoning therefore by analogy, I would certainly anticipate that stimulation by strong currents, not by weak ones, would produce laryngeal or even oral and lingual movements suggestive of vocalisation when applied to the lower part of the "intermediate precentral" area; and with reference to Sherrington and Grünbaum's statement that suggestive movements of the vocal cords were obtained at scattered points in the lower frontal gyrus, I shall be interested to read further details in their full paper; because, as I have mentioned previously, the distribution of this cortex in the manlike ape is very peculiar in the preinsular region, and if histology is a reliable guide, I would expect to find only that curiously distributed strip of cortex excitable, which I believe to be the homologue of the "intermediate precentral" cortex in man; from all that exposed cortex specially referred to as really pertaining to the insula, no result would be anticipated.

Bearing in mind that psychical components exercise a still higher control over the speech area, not to mention the exceedingly complex nature of the motor mechanism, it is impossible to imagine how physical stimulation of the human speech area at a single point could be productive of vocalisation; isolated laryngeal, lingual, or labial movements might follow, perhaps, but nothing further.

And this leads up to another question bearing on speech which seems worthy of mention, but upon which lack of evidence prevents discussion. It is whether there is any possibility of effecting a further subdivision of the speech area, whether the elements in the "intermediate precentral" area for the higher control of the respective primary oral, labial, lingual and laryngeal elements in the "precentral" area, are like the latter deposited in separate compartments, and whether in course of time we shall be able to point to a given subdivision of this area and say that its destruction would, for instance, be followed by an inability to pronounce labials, and so on. To my mind the anticipation is rational.

AGRAPHIA.

By most neurologists writing is regarded as a skilled act, to a certain extent comparable with speaking, and Bastian maintains that a cheirographic centre exists as certainly as does that for articulate speech, and in the corresponding hemisphere. The condition is neither so common nor so clearly defined as aphasia, and accordingly an insufficiency of cases has been observed to allow of a satisfactory and precise localisation of the area to which it is related; still, judging from cases which have been published and from the diagrams of Bastian, Wylie, and others who have made a special study of this subject, we may place the centre at the base of the middle frontal gyrus, immediately above the hinder extremity of the inferior frontal sulcus, and at any rate regard this part as one of particular vulnerability.

Involving as it does the power of spontaneous writing, writing from dictation and copying, this faculty, like speech, is exceedingly complex, and one in which the motor component is associated with intricate psychic agencies, but again it is of the motor element alone that I propose to write.

Now to me it is a point of special interest that the supposed cheirographic centre, like the centre for speech, forms a part of the "intermediate precentral" cortex, and more interesting still to find that it is located exactly on a level with that part of the "precentral" strip of cortex which I believe to stand in direct relation with the hand muscles. (See chapter III, case of amputation of the hand.) This, I think, is an association of the highest significance, but not to labour the point I will say only that much of what has been written on the function of the cortex of Broca's area in its relation to the so-called primary centres probably applies here, and that by means of the cells and fibres in the cheirographic centre a higher control is exercised over the more direct motor elements resident in the hand centre of the "precentral" area.

But it cannot be said that writing is the only accomplishment depending on the integrity of the "intermediate" cortex lying anterior to the hand area; there are numerous other skilled movements, such as knitting, sewing, type-setting, the fingering of musical instruments, &c., which the hand muscles must be specially educated to perform and which require the exercise of a higher volition, and in the execution of these a varying extent of the "lower" field of cortex and also of that at the "higher" level, in proportion to the degree in which the different muscles participate in the particular act, must be called into play.

ON HIGH AND LOW EVOLUTIONARY MOVEMENTS.

The development of what practically amounts to a law is now seen. This law may be stated as follows, *in the "intermediate precentral" cortex there is a sequential deposition of centres for the control of higher evolutionary movements, following the same order from above downwards as that observed in the "precentral" area proper.* There is the highest probability that corresponding centres in each area are associated by commissural fibres, and that corresponding centres lie approximately on the same level, and at all events in juxtaposition.

Viewed in this light the field of "intermediate" cortex lying frontal to the leg area should likewise possess a higher function, and I see no reason why it should not. True it is that no clinical data can be adduced which provide information regarding the effects of a destructive lesion restricted to this particular stretch of cortex, but I venture to say

that the question is one worthy of further research. Of course, for many reasons, the chief of which is that they are constantly in use for purposes of locomotion, the number and variety of skilled movements capable of execution by the muscles of the lower extremity are small by comparison with those performed by the hand and arm, but we can think of some, and proof that many more remain in abeyance and are capable of being developed to a high pitch of perfection is afforded by the cases of individuals deprived of the use of their arms at an early age; by these "armless wonders," writing, needlework, and other complex and essentially skilled acts are performed by the foot muscles without any difficulty[1], and in such cases it is surely absurd to suppose that in, for instance, writing, the cheirographic centre of ordinary individuals is called into play. It is far more likely, after the doctrine of Bastian, that in every normal brain the common sensory, the visuo-psychic, and the audito-psychic centres, probably by means of the tapetum and the fasciculus longitudinalis superior, have extensive connections with all the higher centres for muscular movements, and that many associations usually not exerted may be called up in educating little-used muscles to perform special skilled movements.

If then we are correct in assuming that the cortex of the "intermediate precentral" area exercises control over what in the terms of Hughlings Jackson we may call higher evolutionary movements, and thus has a more or less restricted motor function, it remains for us to explain the origin of movements of a lower order, movements which are perhaps most suitably expressed by the term automatic, and of such those employed in progression are typical examples[2]. And in regard to these the proposition which appears most tenable is that they are dependent upon impulses arising primarily in the giant cells of Betz occupying the "precentral" area proper; but it must be admitted that direct proof on this point will be long in coming, because the organisation of the motor area with reference to the representation of the different groups of muscles in the various forms of movement is so infinitely complex, and also because it is almost impossible in the course of experiment or in nature to obtain and observe the results of a lesion so restricted anatomically as to throw light on the question; and, again, restitution of function is a stumbling-block, for we know that almost invariably in the case of lower animals and occasionally in human beings (cases of porencephaly), obliteration of the motor cortex, Betz cells and all, is followed sooner or later by recuperation of movement. Still for one thing the condition of affairs seen in cases of motor aphasia, and presumably also in agraphia, where with paralysis of higher movement, primary or automatic movement of the muscles concerned is left intact, is very significant, and seems capable of explanation on no other ground. Further we have been told (Foster) that by carrying a vertical incision through the depth of the grey matter, and so isolating a motor field, no alteration of stimulative effects is obtained, but paralysis of movement ensues, and this has been explained by a severance of nervous ties. And although this operation was performed prior to the new definition of the motor area and therefore cannot be used in support of the present argument, the finding is, still, of the greatest interest; and in spite of the complicated effect of nutritive changes necessarily brought about by injury to the pial blood vessels, it would be instructive to watch the effect of the purer operation of isolating the Betz cells by carrying a similar incision down the line of demarcation between the "precentral" and "intermediate precentral" areas.

[1] The education of the left hand by right-sided hemiplegics is on all fours with this.

[2] The movements called by Broadbent "bilaterally associated," that is, movements dependent on muscles which are bilaterally excitable, such as those of the trunk, leg, larynx, and jaw, might be included in this category.

Another point, this time of a histological nature, which one has had in mind in formulating the proposition under consideration, is the remarkable variation in number of the Betz cells in different divisions of the "precentral" area. As has been shown in a former chapter, the total number of these elements in the arm area, speaking collectively, is infinitely smaller than the same in the leg area. Of course this applies to man,—in the anthropoid ape the disparity is also marked but hardly so great,—and the question at once arises, whether there is any connection between this extraordinary fact and the assumption of the erect posture? To clear this point we shall have to see what the ratio is in pure quadrupeds. But while the cortical cell lamination has been investigated in some of the desired animals, for instance, the sheep and cat, by Bevan Lewis[1], neither has the motor area in these animals been mapped out by approved methods, nor have the giant "motor" cells been counted in serial sections, accordingly precise information on the point is wanting; still it will be surprising if with the increased use of the anterior extremity in the automatic movements involved in progression, there is no corresponding addition to the number of giant cells in the forelimb area.

In this view of the part played by the cells of Betz in the motor act certain peculiarities in their histological constitution and the position they occupy must be taken into account. Thus their position in point of lamination is most peculiar, and it is for this reason that Bolton argues, and I think with justice, that we cannot class them in the same category as ordinary pyramidal cells. In the solitary cells of Meynert peculiar to the "visuo-sensory" area Bolton sees homologous elements, and with this I also agree, but into the class I would admit the large sub-stellate cells I have pointed out in the "audito-sensory" and "postcentral" areas and perhaps deep-seated and special elements in the pyriform lobe and cornu ammonis. According to this, homologous cells having remarkable histological peculiarities occupy the depths of the cortex, not only in the motor area but in all the primary centres controlling the functions by means of which the competition for life is maintained; these centres and probably kindred cells are necessarily represented, although in varying degrees of perfection, throughout the vertebrate series, and it follows that the cells peculiar to these centres must take first place in the procession of phylogenetic development. Now in the lowest vertebrates it is probable that the crude automatic movements of which they are alone capable are actuated by stimuli proceeding from a primitive cortical collection of Betz cells, and taking a step lower, the chain of ganglia composing the invertebrate nervous system may be likened to the combination of the Betz cells with the "motor" cells in the pons, medulla, and cord, and I may here say that in man, the ape, and lower animals many structural characters of the Betz cell are repeated in the anterior cornual cell of the spinal cord.

SUMMARY.

1. The cortical field to which the name "intermediate precentral" is attached, ranges as a zone between 3·5 and 1 cm. in width, placed after the manner of a buffer in front of the "precentral" area proper and showing an additional extension downwards on to the orbital surface of the hemisphere. Broadest above, the area becomes constricted at its middle and then expands again below.

[1] In Bevan Lewis's account of the examination of the Betz cells in the cortex cerebri of the cat and sheep it is stated that compared with other parts the clusters are especially large and dense in that portion of the sigmoid gyrus enveloping the lateral extremity of the cruciate sulcus, and this is the part supposed to control forelimb movements. (Further observations in this direction will be offered in the Addendum.)

2. Briefly put, it covers the base of the upper and middle frontal gyri, some of the ascending frontal (that not coated by the "precentral" type), a considerable portion of the inferior frontal, including the pars basilaris (area of Broca), the pars triangularis (sometimes), and the pars orbitalis of the frontal operculum.

3. The calloso-marginal and transverse orbital fissures, at the upper and lower extremities of the area, respectively, form fixed limits, but the anterior boundary is not regularly determined by sulci.

4. Histologically many of the structural characters noted in the "precentral" cortex are repeated, thus, the general depth is preserved, the difference in regard to nerve fibres chiefly affects the degree of fibre wealth, and save for the giant cells of Betz the cell lamination is remarkably alike. These resemblances suggest a physiological kinship between the two parts.

5. In the anthropoid ape's brain an "intermediate precentral" area can be defined without any difficulty, but the curious simian disposition of sulci in the lower parts of the frontal lobe accounts for an interesting variation in distribution. Compared with the human brain the orbital extension of the area appears to be dislocated forwards, due to the fact that the "intermediate" cortex insists on passing forwards to cover the gyrus forming the anterior wall of the fronto-orbital sulcus, at the same time avoiding the field interposed between this sulcus and the apparent insula. At first sight peculiar, this variation is readily explained if we accept the fronto-orbital sulcus of the ape as the equivalent of the human anterior limiting sulcus of the insula, a homology advanced by comparative anatomists and supported by these findings.

6. Having regard to the discoveries (1) that this cortex bears a structural resemblance as well as a topographic relation to the "precentral" cortex, (2) that the field corresponds in distribution with the area found excitable in the simian brain by experimenters prior to Sherrington and Grünbaum, and (3) that its anterior boundary agrees to a marked extent with the so-called "sensory projection centre" worked out by Flechsig on developmental lines, the proposition is favoured that it participates in the motor function; and it is submitted that it may represent a higher centre presiding over elements in the "precentral area" proper, in short, that it is designed for the execution of skilled, as opposed to crude and automatic movements.

7. In the development of this argument the motor components in speech and writing are discussed, as these are acts calling for the exercise of movements skilled in the highest degree and it is most significant that their supposed centres lie within the limits of this field.

8. Digressing to consider the localisation of the motor speech centre it is submitted that this is probably not so restricted as previously supposed, and that the forward extension of the "intermediate precentral" cortex on the inferior frontal gyrus may have the same function as the cortex of Broca's area. In support of this assumption it is pointed out, in the first place, that histologically the cortex of all this part of the "intermediate precentral" area is alike, that is to say, the area of Broca is not distinguishable by any localised specialisation of structure; and, secondly, that it is a common matter of clinical experience that a superficial lesion confined to the cortex of Broca's area, is not wholly effective in the production of motor aphasia; in other words, if the disability is to be permanent the

lesion must be deep and penetrating. The explanation given for the occurrence of complete and permanent motor aphasia after a deep-seated lesion in the pars basilaris is that all connections between the "intermediate" cortex and the direct labial, lingual and laryngeal centres occupying the lower end of the precentral area proper—and by the way remaining intact—are severed. Such a lesion therefore produces an effect equivalent to destruction of the whole of the "intermediate precentral" cortex coating the inferior frontal gyrus.

9. In regard to agraphia it is interesting to find that those authorities who favour the existence of a separate writing or cheirographic centre locate it at the base of the middle frontal gyrus, exactly on a level with that part of the "precentral" cortex which I have found altered in a case of amputation of the hand.

10. From this and from what we know regarding motor aphasia it is inferred that the "intermediate precentral" cortex harbours a sequence of centres for the control of skilled movements, following the same order, deposited more or less on the same horizontal level, and connected by commissural fibres with the series of "primary" centres existing in the "precentral" area.

11. As cells in the "intermediate precentral" area may control higher evolutionary movements, so the Betz cells may govern primary automatic movements. That the oro-lingual and laryngeal muscles are left unparalysed when speech is abolished is significant in this respect. The disparity in number of Betz cells in the arm and leg areas of the human brain is also hard to explain unless on these grounds, and it is probable that the disparity is not maintained in quadrupeds.

12. It is surmised that the automatic movements of which the lower animals are alone capable are directly actuated by the equivalents of Betz cells, and from the phylogenetic point of view such cells are probably of great age.

REFERENCES.

EBERSTALLER. Das Stirnhirn. Leipzig, 1890.

WALDEYER. Das Gibbon-Hirn. Quoted by Cunningham.

CUNNINGHAM. *Loc. cit.*

ELLIOT SMITH. Catalogue of the Royal College of Surgeons' Museum. London, 1902.

HERVÉ. La circonvolution de Broca. Paris, 1888.

GRATIOLET. Quoted by Cunningham.

J. HUGHLINGS JACKSON. On Convulsive Seizures. Lumleian Lectures, delivered before the Royal College of Physicians of London. *British Medical Journal*, Vol. I, 1890; and other papers.

BEEVOR and HORSLEY. A Record of the Results obtained by Electrical Excitation of the so-called Motor Cortex and Internal Capsule in the Orang-Outang (Simia Satyrus). *Phil. Trans. Roy. Soc.*, Vol. CLXXI, B. London, 1890.

P. FLECHSIG. *Loc. cit.*

VON MONAKOW. *Loc. cit.*

J. Déjerine. Sur les fibres de projection et d'association des hemisphères cérébraux. *Compt. rendus de la Soc. de Biol.*, 1897.

L. Zacher. Beiträge zur Kenntniss des Faserverlaufes im Pes Pedunculi sowie ueber die corticalen Beziehungen des Corpus geniculatum internum. *Arch. f. Psych.*, B. XXII, 1890–91.

Barker. *Loc. cit.*

A. S. F. Grünbaum and C. S. Sherrington. Observations on the Physiology of the Cerebral Cortex of the Anthropoid Apes. *Proc. Roy. Soc.*, Vols. I, LXXI.

H. C. Bastian. A Treatise on Aphasia and other Speech Defects. London, 1898. See also Article in Clifford Allbutt's *System of Medicine.*

J. Wylie. The Disorders of Speech. *Edinburgh Medical Journal*, 1895.

W. Bevan Lewis. On the Comparative Structure of the Cortex Cerebri. *Brain*, Vol. I, 1879.

E. Klemperer. Experimentelle Untersuchung ueber Phonationscentren im Gehirn. *Ref. in Neurol. Centralb.*, 1895.

J. S. Bolton. The Functions of the Frontal Lobes. *Brain*, Summer, 1903.

CHAPTER X.

FRONTAL AND PREFRONTAL AREAS.

Of the frontal lobe there still remains for consideration that part uncovered by "intermediate precentral" and "limbic" cortex; this comprises the anterior half of the marginal gyrus, on the mesial surface of the hemisphere, much of the superior, middle, and inferior frontal convolutions, on the lateral surface, and their downward extensions on the orbital face. Although this expanse is covered all over by cortex showing a type of fibre arrangement and cell lamination approximately uniform in character, it is nevertheless possible to split it up into two fields, the hinder of which forms a skirt to the "intermediate precentral" area and will for convenience be called "frontal," while the anterior, centred on the tip of the frontal lobe, will be designated "prefrontal."

TYPE OF FIBRE ARRANGEMENT. (Plate XXIII, figs. 1 and 2.)

Since it is impossible to localise any minor areas in the frontal lobe which are marked by a specialised cortical structure, and since the variations of which I have to write affect degree more than kind, I will not describe the formation in each of these subdivisions separately, but will take a comprehensive view of the frontal cortex from the "intermediate precentral" area forwards, making incidental comparisons of the structural grades by which each is characterised.

Zonal Layer.

The "precentral" area has been pointed to as a part in which the zonal layer reaches a maximum of representation, gaining a superiority in fibre wealth over all other regions; in the "intermediate precentral" field we noticed a decided fall in the density and definition of the layer, but it still contained large varicose fibres; in the "frontal" area the deterioration is more marked and the large varicose fibres disappear; and, finally, in the "prefrontal area" the development is so poor that a few scattered short wavy fibrils alone remain to denote the existence of the layer.

Supraradiary Layer.

A like description holds for the supraradiary layer; in the "intermediate precentral" cortex the general fibre supply was relatively speaking rich, moreover, long, ascending fibres of Martinotti, and long, horizontally-placed, association fibres of medium size occasionally traversed the layer; in the "frontal" cortex the general supply is distinctly less and the long medium-sized elements are virtually absent, and when we come to the "prefrontal" area only a few

short and irregularly scattered fibres can be seen. But since nerve cells, although small, are present in abundance in the same situation, and it is impossible to think of nerve cells without accompanying nerve fibres, I should qualify my statement by saying that scarcely any fibres are present which even a delicate method, like that which we owe to the ingenuity of Wolters and Kulschitzky, will reveal. I might add that this layer does not depart from the usual rule in being richer in fibres in the lower than in the upper parts.

Line of Baillarger.

It has been noted elsewhere that the distinctness of the line of Baillarger may depend more on imperfect representation of contiguous strata than on constitutional strength of the linear formation itself, and this is well exemplified in the frontal lobe. Thus, in the "prefrontal" area the stripe is visible, even to the naked eye, and at the lip of the convolutions has the appearance of being reduplicated, but on microscopic examination the formation is found to be very weak, it contains no large fibres at all, scarcely any which can be designated medium-sized, and the delicate elements which do compose it are both short and scarce.

In the "frontal" area the line is again visible to the naked eye, but on microscopic examination it is found to contain considerably more fibres and occasionally a long one of medium size. Its general representation, however, is a distinct grade below that of the "intermediate precentral" field.

Presumably on account of the weakly developed internal layer of large pyramidal cells there is no true reduplication of the line[1].

Radiations of Meynert.

Interesting variations are seen in these radiations. In the "intermediate precentral" area they formed stout fasciculi, and fibres of the large evenly-medullated variety helped to strengthen each column. In the "frontal" area there is an appreciable attenuation of the bundles, and fibres of the large order are rare, but those of medium size common. Coming to the "prefrontal" cortex the attenuation is more pronounced, and large and medium-sized fibres having disappeared the fasciculi are composed entirely of delicate varicose elements.

This change in the constitution of the radiations is a useful guide to territorial differentiation and must have some functional significance.

Although I have made counts of the number of radiations in a transverse millimetre of substance, I cannot say that the different regions show variations in this respect.

[1] I have stated that in the "prefrontal" cortex a reduplication of the stripe of Baillarger is noticed at the lip of the convolutions. But this appearance is not peculiar to the "prefrontal" cortex, and is, moreover, a spurious formation. In studying the lamination of a given part, the typical arrangement is always to be looked for along the crown or down the wall of the gyrus, never at the lip, for here, probably owing to physical causes, the stratification suffers disturbance; in particular it may be noticed that the layer of large external pyramidal cells becomes drawn out and acquires an abnormal depth, and believing that the line of Baillarger is in large measure composed of offshoots of the large pyramidal cells I also think that this disturbance accounts for the spurious reduplication of the line in question.

Interradiary Plexus and Association Fibres.

Very interesting variations in the behaviour of the elements pertaining to these systems are to be observed. We saw that the radiary zone of the "precentral" area proper (text-figure 1) was packed with large medullated fibres running in all directions and supported by a dense plexus of fibres; we also saw that the "intermediate precentral" cortex (text-figure 21), while poorly supplied in comparison with the "precentral," was rich in comparison with most other fields. Now in the "frontal" area (text-figure 22) there is a still further reduction in

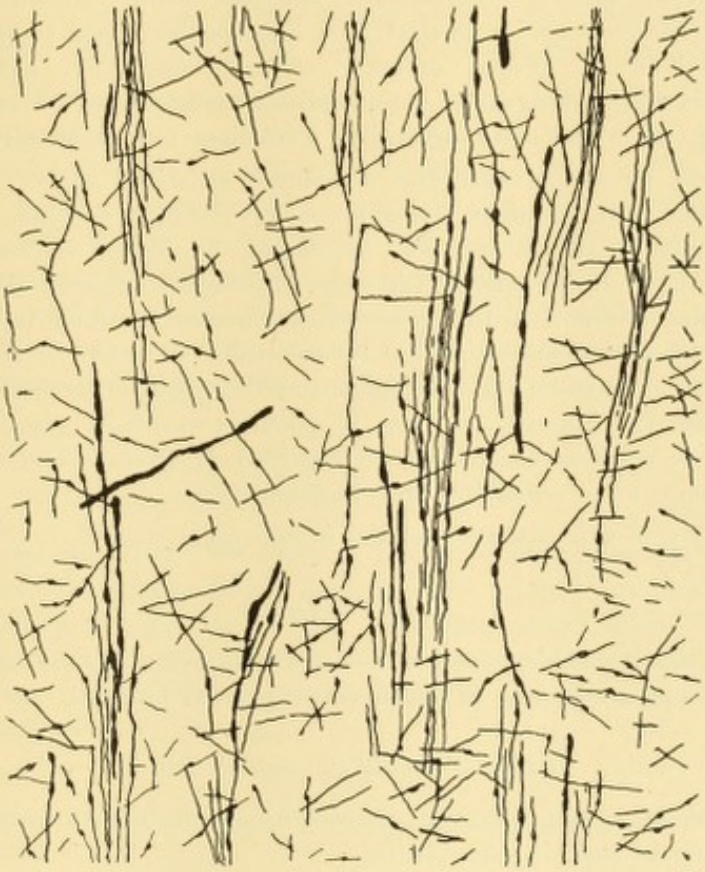

Fig. 22. Radiary zone in the cortex of the frontal area at a magnification of $\frac{1}{1}\frac{1}{2}$.

Comparing it with the drawing of the same part in the intermediate precentral cortex, figure 21, page 210, a loss in fibre strength is manifest. The radiary projections are less prominent, and fibres of large size have almost disappeared.

the general wealth, but it is important to mention that long and moderately stout fibres of the "association" order are occasionally met with; the "prefrontal" plexus (text-figure 2) in turn differs from the "frontal," in being still more open, and in containing no fibres of large calibre. The latter feature is one which I regard as of great histological importance.

I would add in conclusion that all the above-mentioned gradations fade insensibly into one another, that the diminution in fibre wealth is accompanied, first, by a general

reduction in depth, most marked when "precentral" and "prefrontal" sections are compared; and, secondly, by a lowering of the intensity of coloration, a feature recognisable with the naked eye. Lastly, I would say that for purposes of demonstration I am in the habit of showing sections from the upper end of the "precentral" area alongside sections of the "prefrontal" cortex and remarking that they represent extremes of cortical fibre wealth.

TYPES OF CELL LAMINATION. (Plate XXIV, figs. 1 and 2.)

The reason for separating this division of the frontal lobe from the "intermediate precentral" area and for further subdividing it into two main territories, arising out of the examination of the characters of its cortical fibre arrangement, finds support and confirmation when sections stained for the display of nerve cells are inspected; indeed, the manner in which each change in fibre arrangement is immediately followed by a corresponding alteration in cell lamination is one of the most instructive revelations of cortical histology.

But it is not to be denied that the structural variations are of a subtle description and only discoverable by a cautious examination of a large expanse of cortex in serial sections; for not only is the entire field enveloped by cortex showing the usual seven laminae to which I have made constant reference throughout this research, but the changes affecting these laminae are not of the gross character seen in other regions; moreover, the several subdividing lines of demarcation are by no means so sharp as the diagram indicates. Therefore in putting an account of the lamination on paper it becomes necessary to use as a descriptive basis the appearances seen in portions of cortex lying towards the centre of each area,—that is portions which may be regarded as typical,—and to give point to the survey by adding comparative remarks concerning each type.

The individual layers will now be analysed in the usual way.

Plexiform Layer.

For purposes of territorial demarcation the plexiform layer is again of little use; all that I will say is that it appears to lose in depth as we proceed forwards.

Layer of Small Pyramidal Cells.

This layer also shows nothing peculiar; its constituents are numerous and closely aggregated but only slightly more so than in other parts.

Layer of Medium-sized Pyramidal Cells.

The arrangement of these cells also follows the common type; they form a layer of good depth, the upper and lower borders of which are indefinite, and although my observations on this point do not pretend to be exact I believe that they suffer a reduction in size as we go in the frontal direction.

External Layer of Large Pyramidal Cells.

The changes affecting this layer are of undoubted importance and constitute our chief guide to regional differentiation. We have seen that in the "intermediate precentral" area there is a well-constituted layer containing numerous cells of large size, pear-shaped, and

having a few distinct chromophilic particles; and it may be stated in general terms that proceeding from here forwards there occurs a steplike numerical and volumetrical diminution of these elements. Thus, in the region labelled "frontal," although the lamina is still readily defined, and although the constituents compared with those above-mentioned look similar in shape and under a good lens a few chromophilic particles can be identified, still when a series of cells is taken and outlined with the camera lucida, the relative difference in size becomes patent; moreover the cells of outstanding size become as uncommon as the large medullated fibre has been seen to be. There are other differences of a minor character, for instance the layer becomes contaminated with other cells of a like shape but much smaller diameter, and also, on account of the closer approximation in size the upper elements are difficult to distinguish from those pertaining to the layer of medium-sized pyramidal cells.

Advancing next to the "prefrontal" area it is noticed that the cells lose their plump figure and assume an elongated pyramidal form, that even under the highest powers of the microscope chromophilic elements are difficult to detect in them, and that the diminution in size as well as in number is pronounced; associated with this the layer exhibits a manifest reduction in depth, and indeed, the "prefrontal" cortex can be pointed to as that in which the general representation and the process of specialisation in the external layer of pyramidal cells are far behind that seen in any other part of the brain surface. And on coupling these appearances with what has been said regarding fibre arrangement it will be realised how well the law expressed elsewhere is borne out, that small cells and small fibres always run in association.

The Layer of Stellate Cells.

The point of interest about this layer is that it gains in breadth and definition as we proceed forwards; thus, from being almost unrecognisable in the "intermediate precentral" area it becomes a distinct lamina in the "frontal" and "prefrontal" fields; at the same time it cannot be said to equal what we have seen, for instance, in the temporal and parietal regions, it may have the same breadth, but its constituents are not nearly so closely aggregated, nor is the columnar arrangement so obvious.

Internal Layer of Large Pyramidal Cells.

The representation of this layer suffers in much the same way as the corresponding external layer. In the "frontal" region the component cells are very obviously less numerous and also smaller than they are in the "intermediate precentral" area, while in the "prefrontal" field the deterioration is profound, so much so that the largest cells seen are only equal in size to the elements in the layer of medium-sized pyramidal cells of other regions, and altogether they form a very indefinite layer.

Layer of Fusiform Cells.

A fusiform layer is plainly discernible throughout the frontal lobe but in the "prefrontal" region the contained cells are all exceedingly small and delicate.

DISTRIBUTION OF THE "FRONTAL" AND "PREFRONTAL" AREAS. (Plate XXII.)

The distribution of these areas was roughly indicated at the beginning of this chapter, and now reference to the diagrams on Plate XXII will assist the interpretation of the following details.

A. "*Frontal*" *Area.*

First, taking the part marked "frontal": on the mesial surface of the hemisphere, it occupies a small portion of the marginal gyrus, lying anterior to that covered by the "intermediate precentral" type and above the level of the callosal genu.

On the lateral surface it is wide in extent. The posterior boundary need not concern us, because it has already been described in connection with the "intermediate precentral" area. Confining our attention therefore to the anterior limit, we see that it crosses the upper margin of the hemisphere about 4 cm. above the fronto-orbital border, that is, close to the point where the sulcus frontalis superior vel primus usually ends. From this point it pursues a sinuous course downwards, first crossing the sulcus frontalis medius and then making for the fronto-orbital margin of the hemisphere near the most lateral part of the sulcus frontalis marginalis of Wernicke. From here it passes on to the orbital surface, where the external sagittal branch of the orbital sulcus first forms part of the boundary, but as the sulcus orbitalis transversus is approached, it crosses the first named fissure and then arching round in front of the latter it ends close up to the root of the sulcus olfactorius.

Therefore on the lateral surface the area covers roughly-speaking the anterior half of the superior frontal gyrus, nearly the whole of the middle frontal gyrus (the most anterior and most posterior portions being excluded), and that portion of the inferior frontal gyrus lying between the anterior vertical portion of the sulcus frontalis inferior and the lateral extremity of the sulcus frontalis marginalis of Wernicke.

On the orbital surface it covers a small area lying lateral to the external sagittal sulcus and a thin strip anterior to the sulcus orbitalis transversus.

B. "*Prefrontal*" *Area.*

The remainder of the frontal lobe, excluding that covered by the "limbic" type, belongs to the "prefrontal" area.

On the mesial surface of the hemisphere it comprises that portion of the marginal gyrus lying anterior and ventral to the callosal genu, or to the prelimbic division of the calloso-marginal fissure.

On the lateral or frontal surface, the field is small and only takes in the most anterior portion of the middle frontal gyrus.

On the orbital surface it is extensive, it virtually covers all save that behind the sulcus orbitalis transversus and that without the external sagittal sulcus.

FRONTAL AND PREFRONTAL AREAS IN THE ANTHROPOID APE. (Plate XXII.)

Having given particular care to the examination of this part of the frontal lobe in the anthropoid ape, I am able to say without any hesitation that it is histologically divisible in the same way as is the corresponding field in the human brain. Also, I may mention

that as the simian brain is so much smaller, and the arrangement of elements less complicated, the differentiation of the types is considerably easier.

Since the human architectural plan is to a great extent repeated, it will be superfluous to describe the structure in detail. I will merely state that although the differentiation can be effected by an examination of cell elements and has been checked by such examination, still sections stained for nerve fibres are more useful for working purposes. When in the latter sections, the "frontal" is compared with the "intermediate precentral" cortex a general reduction in fibre wealth is first observed, but more important than this the "frontal" cortex is to be distinguished by a complete absence of coarse medullated fibres, both in the radiary projections and association systems. At the same time it must be expressly stated that fibres of medium calibre persist and appear in appreciable numbers.

Comparing the "prefrontal" with the "frontal" cortex a still further reduction in the general fibre wealth is found. The fibres of medium size are now wanting and none but delicate wavy fibrils are seen in any of the systems, the radiations have grown more slender, the association system is distinctly deficient, and the subjacent white substance—indeed the whole cortex—has a pallid, ill-developed look. If we pass into the sulci in the same area we may see a very shallow radiary zone, composed of stunted radiary fasciculi and a delicate interradiary plexus, fringing the white substance; and while in most other parts of the brain on examining the white substance carefully with a high power objective it is possible to discover large medullated fibres, scarcely any can be found here.

DISTRIBUTION.

A. *"Frontal" Area.*

On the mesial aspect a human feature is repeated, for this type of cortex again covers a small portion of the marginal gyrus lying above the level of the genu of the corpus callosum. And I might mention that in one of my chimpanzees' and in the orang's hemisphere, the field is limited anteriorly by a frontal offshoot of the prelimbic division of the calloso-marginal fissure, which runs obliquely forwards and upwards to incise the margin of the hemisphere. Of the constancy of this offshoot I am unable to speak.

On the lateral surface the area appears to be relatively less extensive than it is in the human brain. Viewing the hemisphere from the front I should describe the anterior border as crossing from the inner to the outer surface at a point about 4 cm. above the junction of the internal and orbital margins, that is 4 cm. above the lowest part of the keel-shaped orbital projection, so characteristic of the simian brain. From here our anterior border runs vertically downwards, parallel to the "intermediate precentral" area, until it reaches the middle of the sulcus rectus, or as I prefer to call it the sulcus frontalis medius. It then takes a short turn forwards and drops on to the orbital surface, where it runs parallel to and a few millimetres in advance of the "intermediate precentral" area, and on this surface the human distribution is copied.

Returning to compare the extent of the field on the lateral surface of the hemisphere with what we have seen in the human subject, the first point which strikes us is that while the area retains its sagittal breadth it shows a pronounced reduction in vertical depth; and looking for an explanation of this very important difference we soon recognise that it is attributable to, first, the inferior volume of the superior and middle frontal convolutions,

and secondly, the curious way in which the "intermediate precentral" area is pushed upwards by the fronto-orbital sulcus. The distribution of the area on this surface is of further interest because it seems to throw a certain amount of light on the homologies of the part and in particular it explains the sulcus rectus. It will be remembered that in man the anterior border of the field crosses the middle of the sulcus frontalis medius, and now in the ape it similarly bisects the anterior portion of the sulcus rectus, that portion which in two of my specimens is isolated. Then just as in man part of the postero-inferior boundary is made up of the sides of the angle formed by the sulcus precentralis inferior and the sulcus frontalis secundus, so also in the ape it is the angle between the former fissure and the hinder division of the sulcus rectus which forms the corresponding limit. I think, therefore, that these additional facts of histology add weight to my previously expressed supposition (Chapter on "Intermediate Precentral" Area) that the posterior and anterior portions of the simian sulcus rectus are the equivalents of the human sulcus frontalis secundus and sulcus frontalis medius respectively.

B. "*Prefrontal*" *Area.*

The "prefrontal" cortex in the ape is mainly confined to the deep keel-shaped orbital projection of the frontal lobe. Viewed from the mesial surface the anthropoid area looks equal to that in man, but taken altogether its extent is less.

FUNCTIONS OF THE FRONTAL AND PREFRONTAL AREAS.

The portions of the frontal lobe which I have just defined comprise a territory the functions of which are but little known, it is a part where theory holds the major hand, one which has proved most resistive to workers in the several departments of experimental physiology and pathology, clinical medicine, embryology, anatomy and histology, both human and comparative, and about which the little knowledge we do possess has only been acquired by negative and roundabout processes of reasoning; further, as others have rightly observed, it is a realm where localisation, in so much as this applies to the definition of fields having a specific function and a specialised structure, seems unattainable.

Having always insisted that histological examination of the cortex is to be regarded as an auxiliary force only to be brought into action after a preliminary exploration of the ground has been made by prospectors in other departments, it cannot be expected, now that all other methods of research have proved comparatively unproductive, that microscopic inspection will materially further our knowledge of the function of these parts. Still the modest share taken by the microscope is not to be despised even here. To have obtained a comprehensive view of the cortex investing this region is an advantage, and it is a still further advantage to have reduced the dimensions of the field marked on our map of the frontal lobe as of uncertain function. As we all know not many years ago this field reached as far back as the fissure of Rolando, whereas now we can exclude the greater part of the ascending frontal or precentral gyrus (that covered by the precentral type of cortex), and strong reasons have been advanced for striking out the wider expanse of cortex having "intermediate precentral" characters, so that although we may receive credit for nothing else we have done good in narrowing the field left for further investigation. But in addition to this the complete survey of the area which I have accomplished sheds a brighter

light on a number of observations made by previous writers on the functions of the frontal lobe, and in the following discussion some profit may accrue from viewing these observations in the new light.

Experimental Data.

Taking a short retrospect of the work of experimenters, we soon see from the contradictory results arrived at, that only a limited amount of gain is to be obtained by study in this direction.

First concerning the influence of faradic stimulation, there is almost complete unanimity among experimenters that the anterior part of the frontal lobe, the region which they have distinguished by the name "prefrontal" and that which in all likelihood corresponds to my "prefrontal" area, is electrically "silent"; indeed, by some who have had the widest experience in this class of research, it is said that in the case of the ape,—and this is particularly interesting, because of all animals its frontal lobe resembles that of man most,—it is possible by judiciously applied stimulation to obtain a reaction from any part of the cerebral cortex save this. On pausing for a moment to reflect on such a remarkable fact the histological appearances offered by the field at once come to mind, it is remembered that it is a part in which the fibre endowment reaches its lowest ebb, and in particular it is one in which the fibres of even medium size are scanty and those of large calibre entirely wanting; further, it is a field where the largest cells are by comparison with those in other regions puny and where the cell representation in general is seen at its worst; and without opening up physiological controversies on cortical excitation it is to my mind not so singular, when we take these histological data into consideration, that it should exhibit negative reactive qualities.

With the hinder part of this region, that which might correspond in part to my "frontal" area, it is different. For Ferrier firmly maintains that certain movements of the facial and ocular muscles, as well as dilation of the pupil, may be evoked by local stimulation; also in Sherrington and Grünbaum's figure published in their first paper, the frontal area marked "eyes" and indicated by vertical lines seems to lie partly within my "frontal" area, and the experiments of others, notably Beevor and Horsley, on the orang, point in a similar direction. In looking for an explanation of these interesting points I would suggest that the "frontal" strip of cortex may have some of the higher motor properties possessed by the "intermediate precentral" area; this, however, is a point to which I shall return again.

Of experimenters who would ascribe motor functions of a more direct character to the frontal lobe, there is one whose views cannot be passed over, I refer to Munk, who sees in the frontal lobe, or in an inexactly defined part of it, the motor area for trunk muscles, because its extirpation, both in the dog and in the monkey, in his hands produced a certain amount of trunk paralysis (abnormal arching of the back, &c.) which was of long duration. But positive as the terms are in which Munk expresses his convictions it is extraordinary that no other experimenter of note has been able to confirm his results.

So much for the effects of stimulation and for the supposed rôle which the "frontal" lobe bears in regard to motion; we have now to turn to a series of experiments designed for the purpose of throwing light on the much more important question of the activity of the frontal lobe in relation to intellectual faculties. But here the narrative is made up of a series of contradictions still more confusing in their effect.

We will begin for convenience with Bianchi's research. Dogs and monkeys formed his material, and ablation of the portion of the frontal lobe initially found irresponsive to electrical stimulation may be mentioned as his chief operative proceeding. Now in my opinion Bianchi's work carries a lot of conviction because his operations seem to have been most carefully performed, his observations on the resulting phenomena studiously carried out and judiciously weighed, and his intercurrent comments written in an impartial spirit. That his results were positive may be gathered from the frequent occurrence in the accounts of his different cases of expressions, such as "the animal is in a condition of automatism, semiconsciousness, indifference, stupidity, terrorism," &c. After carefully recording his experiments he states his conclusions as follows, "the frontal lobes are the seat of co-ordination and fusion of the incoming and outgoing products of the several sensory areas of the cortex." "The frontal lobes would thus sum up into series the products of the sensori-motor regions, as well as the emotive states which accompany all the perceptions, the fusion of which constitutes what has been called the *psychical tone* of the individual. Removal of the frontal lobes does not so much interfere with the perceptions taken singly, as it does disaggregate the personality, and incapacitate for serialising and synthesising groups of representations. The actual impressions which serve to revive these groups thus succeed one another disconnectedly under the influence of fortuitous external stimuli, and disappear without giving rise to associational processes in varied and rapid succession. With the organ for the physiological fusion which forms the basis of association, disappear also the physical conditions underlying reminiscence, judgment and discrimination, as is well shown in mutilated animals." ... "Fear is an immediate result of psychical disaggregation from defective sense of personality, and unbalanced perception and judgment. Courage rests upon the treble basis of self-conscious force, rapid perception of the enemy's powers for offence or defence in relation to one's own, and the influence of certain feelings; our animals show an absence of all these characteristics."

And in a modest tone Bianchi concludes his paper by saying that "even should a more acceptable hypothesis to explain the facts observed be hereafter framed, I feel at any rate certain of the accuracy of the observations themselves."

Ferrier is another observer who obtained positive intellectual interferences after lesions of the frontal lobe; in his animals, removal of the part found insusceptible to electrical excitation occasioned curious alterations in temper and behaviour, apathy and indifference. But Ferrier is severely criticised by Bianchi in attributing motor functions to the frontal lobes on account of their supposed connections with the corpus striatum, and likewise in stating that the same lobes are inhibitory centres and therefore centres for attention.

The list of physiologists who have obtained positive results in this direction could be added to, but perhaps in indicating the symptoms observed and the inferences drawn by these two workers I have said enough.

Approaching the question with an open mind we have now to take evidence on the opposite side. To begin with we are told by Horsley and Schäfer, two trusted experimental physiologists, that mutilation of the anterior third or fourth of the frontal lobe of seven lower apes, one after the other, produced no disturbance whatever of special sensation or intellect. Bianchi argues that Horsley and Schäfer obtained negative results because the mutilation, in being confined to the anterior third or fourth of the frontal lobes, was too small in extent; and having regard to the weak development of the "prefrontal" cortex

I think Bianchi's point is well founded, and I think further that the same evidence will strengthen a contention of mine, to be considered hereafter, that the "prefrontal" cortex is of low functional importance compared with the "frontal."

In the next place Hitzig[1] and Munk make equally emphatic statements to the effect that the dogs from which they removed the frontal lobes never showed any signs of intellectual impairment.

It is unfortunate that the above-mentioned observations on the effects of experimentally produced lesions of the frontal lobe should be so full of discrepancies, as the only conclusion possible after reading the controversy is in accordance with my opening statement, that we cannot hope for definite information regarding the higher functions of the frontal lobes from operations on low animals.

CLINICAL DATA.

Passing on to the teachings of clinical experience, we will first consider the suggestion, that in the human brain the motor act is represented in front of the "intermediate precentral" area.

As to the occurrence of trunk paralysis analogous to that described by Munk in the dog and monkey, the collected evidence may be said to be definitely negative, indeed this applies to all gross forms of paralysis, for although in not a few instances of frontal lesion some degree of hemiplegia or monoplegia has been noticed, authorities tell us that in none has it been possible to exclude involvement of the precentral region or of the motor tracts.

In reference to special movements of the eyes and head, similar to those obtained by Ferrier and others in the lower ape, and by Grünbaum and Sherrington[2] in anthropoids, the evidence is different and the case extremely interesting. In a large number of recorded instances, as Ferrier has pointed out, conjugate deviation of the eyes and a movement of the head, both towards the side of the lesion, have been observed, while not so commonly weakness of the superior rectus, abducens paralysis, and diplopia have been complications, and taking an average of the cases in which localisation has been possible, the part of cortex destruction of which seems specially liable to bring about these phenomena is that lying towards the hinder end of the middle frontal gyrus. In an endeavour to bring this into correlation with what we know of cortical histology, two suggestive coincidences occur to us: first, although the active area indicated by Grünbaum and Sherrington covers a large portion of the outer surface of the frontal lobe, its centre lies at about the middle of the sulcus rectus (I would say that the corresponding spot in the human brain is towards the hinder end of the sulcus frontalis medius), and this comes partly within the area in the anthropoid ape to which I have assigned "frontal" characters: secondly, the part found vulnerable in the human being (the posterior part of the middle frontal gyrus) is also enclosed within

[1] Hitzig, in believing that the frontal lobes are the seat of the highest intellectual faculties, really supports Bianchi's view, but his conclusions are based on the lesson of comparative anatomy, that the development of the frontal lobe keeps pace with that of the intellect. His experiments did not confirm his plausible argument.

[2] The experience of these writers is as follows: "Our observations indicate that the frontal region, yielding conjugate deviation of the eyeballs, presents such marked differences of reaction from the 'motor' area in the Rolandic region that we hesitate to include it with the so-called 'motor' cortex; it seems necessary to distinguish it in a physiological category separate from that. Spatially it is wholly separated from the Rolandic 'motor' area by a field of 'inexcitable' cortex."

my "frontal" area. Now it has been demonstrated that the "frontal" cortex possesses histological characters to some extent resembling those of the "intermediate precentral" cortex, and from this the question arises, is there a functional correspondence? The solution to the problem is not forthcoming. This "eye area" apparently does not exhibit any specialisation of structure, and it is most difficult to say why its stimulation or destruction affects ocular muscles. If the existence of a primary eye movement centre, analogous to the various centres in the "precentral" area and located in the precentral neighbourhood, were only proved, we might reasonably conclude that this "frontal" area represents a higher centre of control and all would be plain, but that primary area is wanting. We are left therefore to take our choice of two flimsy hypotheses: we must either conclude that the "frontal" area contains a combined ocular centre for automatic and volitional movements, or, since stimulation of the calcarine cortex produces ocular movements and this and the frontal cortex are united by subcortical bands, we must assume that the ocular paralysis and the movement consequent on frontal destruction and stimulation, respectively, are referred effects.

The head movements mentioned as occurring in these cases of frontal lesion I prefer to explain by involvement of the higher centres controlling neck muscles, placed as I believe in the "intermediate precentral" area in advance of the primary "precentral" area.

To pass in review all the clinical evidence bearing on the supposed psychical faculties possessed by the frontal lobe, and arising out of Meynert's original contention that it is a centre for abstract thought, would be a profitless undertaking, as from the point of view of localisation a large proportion of the published cases are valueless on account of the gross nature of the lesion, and because extraneous conditions cannot be excluded as causes of the observed mental changes; moreover, it has been shown by Williamson, Welt, and others, who have collected and analysed series of cases, that the products of clinical medicine are almost as discrepant and contradictory as those of experiment.

I shall therefore confine myself to some brief comments on the symptoms of frontal lesions to which authorities attach most importance.

In the first place it seems agreed that a defect involving both frontal lobes, whether the result of atrophy, non-development, or destructive lesion, is invariably accompanied by intellectual deficiencies of a gross character, ranging from imbecility to complete idiocy.

Secondly, it appears clear that unilateral lesions, if slight in extent, may remain latent as regards the display of symptoms.

Thirdly, although a large number of cases of extensive unilateral lesions has been recorded, similarly void in effect, in a majority of instances, and especially when the lesions have been left-sided, a peculiar form of mental disturbance has been observed. The disturbance has been commonly described as an alteration in character. Jastrowitz, who has seen many examples of the condition, names it "Witzelsucht[1]," and the English equivalent seems to be "moral insanity." A low sense of honour, a delight in causing annoyance, and in making malicious attacks on individuals not in a position to retaliate, a tendency to be violent when their childish waywardness is opposed, a lack of all feelings of gratitude, and an inefficient control over their animal passions are samples of the mental changes to which these subjects seem to be liable, and no better illustration of the condition is on record than that afforded by the well-known case in which a crowbar entering the cranium

[1] Witzeln = to make a false display of wit.

beside the angle of the lower jaw on the left side, and emerging at the sagittal structure, did not prove fatal but changed an intelligent and industrious artisan into an altogether depraved being[1].

As this disturbance seems to be such a well-established result of frontal lesion it would be extremely interesting to learn with exactitude the extent of cortex or the nature of the tracts on the destruction of which it depends; above all things I am curious to know whether obliteration of my "prefrontal" area and its relations would suffice for the change, or whether it is necessary for the lesion to extend into the "frontal" area, but these of course are questions to which a reply is at present impossible. Indeed our general knowledge of the real functions of the frontal lobes is in an extremely unsatisfactory condition.

EMBRYOLOGICAL DATA.

As with other fields so again here it is interesting to compare the results bearing on territorial demarcation which I have obtained with the results arrived at by Flechsig.

So far as I have observed Flechsig does not indicate in any of his schemes a subdivision of this part into fields corresponding with my "frontal" and "prefrontal" areas, but while he appears to classify the whole area as pertaining to terminal regions, "that is, regions acquiring their medullated fibres later than one month after the normal period of birth," one gets the impression from his figures of 1898 and later publications, showing by numbers the succession of myelinisation in different parts of the cortex, that he might have done so; at any rate he might have so divided the cortex on the mesial surface of the hemisphere; because in his 1898 figure (I only take this for convenience, the others are similar), the number 1 is placed in the paracentral lobule over what I take to be the mesial annex of the "precentral" or perhaps the "postcentral" area, it is a matter of no consequence; proceeding forwards the number 9 falls close to the middle of my "intermediate precentral" area; next over the part which I would call "frontal" the figures 17 and 17*a* occur, while in the pregenual region and also by the way on the orbital surface (all part of my "prefrontal" area) the figures 36, 37 and 40 are scattered. But as I have indicated the agreement cannot be carried satisfactorily over the lateral surface; it is true that Flechsig's figures 17 and 17*a* again lie in my "frontal" area, Flechsig also excludes the inferior frontal convolution, or at least the major part of it, from his terminal regions (10 is placed on the orbital operculum, which most anatomists include in the inferior frontal gyrus), and so far we are in unison, but in regard to the middle frontal gyrus we fall out, for the numbers 30 and 36 occupy cortex which I believe to be of the "frontal" type and very different from that over which Flechsig's other high figures are placed. Yet taking everything into consideration it cannot be denied that there is a strong suggestion of correspondence between Flechsig's findings and mine, and this in itself is a point of interest. It is also instructive to find that the highest number in Flechsig's series, 40, is placed on parts of the "prefrontal" area, showing that in his opinion it is the last to myelinate.

[1] Failure of memory, hebetude, apathy, vague indifference, somnolence, and inability to concentrate the attention have all been described as accompaniments of frontal tumour or abscess, but these are likewise manifestations of increased intracranial pressure, and may arise in cases of tumour, etc., far away from the frontal lobe. The disturbances of smell and sight which have been reported are admitted to be extraneous effects, and the form of ataxia described by Bruns has been attributed to pressure exerted backwards on the cerebellum in the line of thrust.

So much for histology and topography. Functionally, according to Flechsig, this portion of the brain forms a "great anterior centre of association," analogous to his "great posterior centre of association" in the parieto-temporal region; further, its central part, namely the anterior half of the middle frontal convolution, constitutes a nodal point for the long systems of association linking it with numerous sensorial zones; the peripheral portion is less active. The anterior centre is not so important as the posterior, but like the latter it controls the association of ideas, it is a "Denkorgan," and has a high psychic function; it contains the mechanism which exercises a higher control over the various "Sinnesorgane," and having specially intimate connections with the great central "projection centre," which includes the motor area, it may particularly serve for storing up memories of volitional movements.

Very briefly and imperfectly stated these are Flechsig's chief conclusions regarding the *rôle* played by this cortex. I do not enter into them fully because it is the basis upon which the conclusions are founded more than the conclusions themselves which interests me, nor shall I embark on a summary of the criticism—mostly hostile—with which the views have met.

HISTOLOGICAL DATA.

It is evident from Kaes' descriptions, that in the very careful and comprehensive examination of the cortex which he made, many of the peculiarities of fibre arrangement which I have detailed were noticed, but as I have said elsewhere, his diagrams fail to convey a clear idea of the topographical distribution of the variations, hence his work is being left out of consideration. Hammarberg's work too on the cell lamination, although most thorough in detail, and for that reason valuable, is wanting in the same respect as Kaes'.

Of researches on the histology of the frontal cortex in conditions of disease, most of those which I have had the opportunity of reading are too fragmentary to merit discussion, but there are two, one recently, and the other comparatively recently published, to which special mention must be made, those of Bolton and Schäffer.

The former chose for investigation the brains of individuals mentally afflicted. First studying the naked-eye appearances of 200 cases of dementia, he came to the conclusion that the amount of cerebral wasting varied directly with the amount of existing dementia: concerning the important point of the regional distribution of the wasting, he wrote that, "(1) The greatest amount occurs in the prefrontal region (anterior two-thirds or so of the first and second frontal convolutions, including the neighbouring mesial surface, and the anterior third also of the third frontal convolution). (2) The wasting is next most marked in the remainder of the first and second convolutions," and so on. He next gave an account of the microscopic examination of the prefrontal cortex at a fixed point (the anterior pole of the hemisphere in the region of the second frontal convolution, and at right angles to the transverse fissure of Wernicke) in a series of cases, and finding that in dementia the layer which wasted most was the second or pyramidal layer (Bolton's second layer includes the small and medium-sized pyramids and the external layer of large pyramids), he finally concluded that these cells subserve the psychic functions of the cerebrum, and that "the anterior centre of association" of Flechsig is the region concerned with attention and the general orderly co-ordination of psychic processes.

Without for a moment discrediting the accuracy of Bolton's observations, and while admiring the work for the care bestowed upon it, I must nevertheless say that his arguments seem to rest on frail premises. It is agreed from personal experience that the regions he indicates are those which apparently present the greatest atrophy in dementia, and that the prefrontal region suffers in particular, but it is not granted that the cerebral changes of dementia are confined to these parts and that there are not grave changes in other regions upon which the mental condition may in equal degree rest. Indeed in the dementia of general paralysis, one of the conditions which he has selected for study, we have very good reasons for supposing that the morbid process has a tendency to be ubiquitous, and yet in given cases of this disease in which our microscopic examination proves the universality of the cortical affection, we might still be correct in describing the prefrontal region, etc., as the parts which to the naked eye exhibit most atrophy, and the same might apply to ordinary forms of dementia. Now my major point is that a fundamental physical reason may be brought forward to explain this anomaly, and it deserves most careful consideration in the process of formulating conclusions on naked-eye appearances. It turns on the architecture of the cortex, and particularly on the framework of nerve fibres upon which the cortex is built; thus, viewed in relation to structure those convolutions having cortex supported by stout radiary projections and a strong interradiary plexus, for instance, the precentral and occipital gyri, will naturally exhibit least macroscopic change, whereas those with attenuated and collapsible radiations and an interradiary network untraversed by strong fibres,—the "prefrontal" region more than any other possesses these characters,—will on the contrary show most. Long before Bolton's paper appeared I was struck with this association, and had even seen it illustrated, but of course not to a grave extent, in the brains of individuals who had suffered from a minimum of mental disease, but in whom death was brought about by physical disease causing general bodily emaciation. Indeed, proof on this point could be multiplied interminably. My contention therefore is, that given a morbid process universally distributed over the cortex, and affecting the pyramidal cells or any other system equally throughout, then the parts showing most atrophy to the naked eye will be those of weak architecture, and exactly those to which Bolton has specially drawn attention.

In the next place it cannot be conceded that cortical measurements in themselves supply an accurate means for estimating degrees of structural disintegration. Bolton leads us to assume that the reduction in depth of the conjoint layers of pyramidal cells external to the stellate layer is the result of disappearance of these cells, but he does not prove this, and cannot until he supplements his measurements by comparative cell counts (an enormous task, almost impossible to perform thoroughly), and so excludes the effects of condensation. For surely condensation is an important factor to reckon with; moreover, for the structural reasons mentioned above, we should expect the same change to be specially pronounced in the "prefrontal" area and in others built on a frail plan.

Mention of condensation makes one think too of what happens, in the process of cortical wasting, to that substance remaining over when cells, fibres, and neuroglia are removed. Also, of other agencies which may influence the topographical distribution of cerebral atrophy and which we are compelled to bear in mind in the examination of the brain, the nutritional supply and the influence of gravity are of importance.

Therefore I think that the grounds on which Bolton bases his arguments are untenable, and that the evidence he adduces affords little help in enabling us to arrive at the correct function of the frontal lobes.

The papers of Schäffer, to which I will next refer, deal with the medullated nerve fibres of the cortex, and are based on what appears to have been a careful examination of a series of complete sections of two hemispheres from cases of general paralysis, sections like those which Kaes used in his research. And in both these cases Schäffer thought that the disease fell very heavily on the "association" centres of Flechsig and left the "sensory" centres of the same writer intact. Now these are topographic conclusions which are out of harmony with those of Kaes, who has also examined a general paralytic brain in its entirety and by the same process; they have also been combated by Nissl, and I am sure that there are many in this country familiar with the microscopic experience of the cortex in general paralysis who will support Kaes and Nissl in stating that this disease is ubiquitous, instead of topically distributed in the manner Schäffer supposes. Without seeing Schäffer's specimens it is of course impossible for me to offer a criticism carrying any weight, but having read both his papers carefully I cannot help thinking that some of my remarks made in criticising Bolton's work can be reapplied. It will be observed that the parts which Schäffer believes to have escaped disease are precisely those in which the fibre wealth and especially the wealth of large fibres is greatest; on the contrary, the parts most affected are those most poorly endowed in this respect, and the point to be debated is whether or not Schäffer has been too liberal in his application of the term normal. To me it seems that he has, for the simple reason that these parts are so richly stocked with fibres that they mask conditions of disease and so prevent accurate judgments on their normality, and especially is this the case when the sections are of great thickness, as Schäffer's must have been. And I feel entitled to an expression of opinion on this point because in addition to my experience of the normal brain I have had the cortex of the general paralytic constantly under observation for the past twelve years, and have repeatedly noticed how sections of these parts may show profound changes when stained for the display of nerve cells, blood vessels, and neuroglia, and yet almost nothing when stained for nerve fibres, and like remarks apply to changes in the same centres in other diseases[1]. I repeat therefore that on account of this dense structure and peculiar architecture it is exceedingly difficult to judge from an inspection of nerve fibres only of the normality or morbidity of the fields of cortex which Schäffer has looked upon as sound, and for the same reason it follows that comparisons become ineffectual and unconvincing when the same parts are reached.

I have digressed more than I intended to discuss these conclusions of Bolton and Schäffer, but I have felt that it was important to take more than a passing notice of them, because they might be converted into unsound capital by those, unpractised in histological research, who are investigating the functions of the brain and particularly those of the frontal lobe.

DATA DERIVED FROM COMPARATIVE ANATOMY.

Hitzig's acceptance of the frontal lobe as the centre for higher psychic faculties, because in the phylogenetic tree the development of the intellect proceeds *pari passu* with that of the frontal lobe, is so full of suggestion that we cannot be surprised at the number of adherents it has won.

Since the cortex investing the sulcus cruciatus in some lower vertebrates corresponds structurally and physiologically to the "precentral" area of man, it is clearly seen how

[1] In cases of tabes dorsalis, amputation, sleeping sickness, optic atrophy, deaf mutism, porencephaly and even progressive muscular atrophy the very positive cell changes which I have found in the cortex have never been accompanied by equally striking fibre alterations.

very diminutive the frontal lobe is in these animals. And while the ape shows a marked advance on the lower vertebrate, its frontal development, even in the anthropoid, is still far behind that of man.

But, as was pointed out in describing the histology of the frontal lobe, it is possible in the case of the anthropoid ape to effect a subdivision of the frontal cortex on lines similar to those in the human being, and on further analysing the various areas in the two brains we notice that the chief difference in regard to partition is that in the anthropoid far more of the frontal lobe—in the common sense of the term—is covered by "precentral" and "intermediate precentral" cortex than in man, and *vice versâ*, far less of the frontal lobe is left over. And of the remainder it seems to me that the ape possesses much less "frontal" cortex than man, while with respect to "prefrontal" cortex although the inferiority is not so great it is still apparent. Hence if Hitzig's hypothesis be correct the deduction to be drawn is that the cortex of the "frontal" area constitutes the focus of the intellectual sphere.

Looking from the platform of phylogenesis there is another point which has long had a special fascination for me as a histologist, because I have thought that it might help to explain the structural peculiarities of the frontal lobe. It has reference to the question whether the feeble structural representation and the relative poverty of signs of specialisation in this "prefrontal" region are attributable to the truth that it is the very last to make its appearance in the course of phylogenetic development. The idea seems plausible. It further occurs to one that as the "prefrontal" stretch of cortex is represented in the ape as well as in man, as it is so inferior to other regions in its nerve cell and fibre supply, as it is quite inexcitable by electricity, and as it is doubtful whether lesions confined to it give rise to any symptoms, therefore it cannot share the functional importance of the better developed "frontal" cortex placed further back; in short although it may have a future in front of it, at present its evolution both structural and functional is incomplete.

That the last-named area is of importance there seems little doubt, its major development is the feature which specially distinguishes the human from the ape's brain, and experimental interference as well as natural lesions are followed by positive results. Finally, I anticipate that the facts of histology which I have narrated will prove acceptable evidence to those who maintain that the direction followed by the growth producing the massive frontal lobe of man has been downwards and outwards.

SUMMARY.

1. That part of the frontal lobe uncovered by "intermediate precentral" and "limbic" cortex can be split up into two fields; the hinder of these, forming a skirt to the "intermediate precentral" area, I have called "frontal"; the anterior centred on the frontal pole, I have called "prefrontal."

2. On the mesial surface of the hemisphere the "frontal" area occupies a small portion of the marginal gyrus lying above the level of the callosal genu; on the lateral surface it occupies the anterior half of the superior frontal gyrus, a large slice of the middle frontal and the anterior extremity of the inferior frontal gyrus; on the orbital surface it occupies a small area lateral to the external sagittal sulcus.

3. The general fibre wealth of the "frontal" area is less than that of the "intermediate precentral," but greater than that of the "prefrontal." Constitutionally it differs from the

"intermediate precentral" in the almost complete absence of fibres of large calibre both in the projection and association systems; it, however, contains elements of medium size. The change in cell lamination which I have mostly relied upon in distinguishing the "frontal" from the "intermediate precentral" cortex affects the external and internal layers of large pyramidal cells; in the first-named cortex a reduction in size and number of these elements is apparent.

4. The "prefrontal" area is less extensive than the "frontal," it comprises the pregenual portion of the marginal gyrus, on the mesial surface; the anterior end of the second frontal gyrus, on the outer surface; and all the orbital surface in front of the sulcus orbitalis transversus and within the external sagittal.

5. The structural development of the "prefrontal" cortex is exceedingly low. It presents an extreme of fibre poverty; all its fibre elements are of delicate calibre, and its association system is particularly deficient. Its cell representation is on a similar scale. The cortex is also shallow.

6. "Frontal" and "prefrontal" areas are as readily defined in the anthropoid ape as in the human being. But man has a decided advantage over the ape in regard to the development and extent of the "frontal" area. In the case of the "prefrontal" area the disparity is less marked.

7. Without adding materially to our knowledge of the functions of the frontal lobes histology throws light on some of the observations of previous writers.

8. The prefrontal region is absolutely silent under the influence of faradic excitation, and this is probably accounted for by its poor structural representation.

9. No explanation of the truth that stimulation of the frontal lobe produces eye movements can be given, but the area active in this respect lies within the "frontal" field, and the field has its analogy in the human brain.

10. There is a conflict of evidence on the effect upon intellectual processes of obliteration of the frontal lobe; it is suggested that Bianchi, Ferrier and others obtained positive results because their area of destruction embraced the "frontal" as well as the "prefrontal" area; and Horsley and Schäfer negative results because they ablated the "prefrontal" area alone.

11. As Welt showed, gross lesions of the frontal lobe give rise to curious changes in character, but our knowledge of the psychic functions of the frontal lobe in the human subject is very imperfect.

12. On analysing Flechsig's results obtained from myelogenic research, the maps of the cortex he has drawn do not differ essentially from mine. The "prefrontal" cortex appears to be the last to become medullated.

13. Maintaining on physical grounds that cortex built up on a weak framework of nerve fibres, *e.g.* the "prefrontal" and "frontal," will be the first to show macroscopic change in the course of cerebral wasting, and the contrary, and holding that serious microscopic changes which may be present in stoutly built cortex, *e.g.* the "precentral," are likely to be overlooked because gyri so covered preserve their outward form, I am of opinion that we must for the present refuse to accept Bolton and Schäffer's conclusions concerning the frontal atrophy seen in different forms of dementia, notably that of general paralysis, as evidence either

for or against Flechsig's hypothesis that the frontal lobe is a high associative intellectual centre.

14. Hitzig's argument that the frontal lobes preside over the highest intellectual faculties, because in comparative anatomy the development of the lobes proceeds *pari passu* with that of the intellect, is one of the most plausible yet advanced.

15. The feeble structural representation of the "prefrontal" cortex suggests that it is the last portion of the frontal lobe to make its appearance in the course of phylogeny, and, all things considered, the idea is favoured that its physiological importance as a psychic centre is overestimated; the same does not apply to the "frontal" area.

REFERENCES.

FERRIER. *Loc. cit.*

A. F. S. GRÜNBAUM and C. S. SHERRINGTON. Observations on the Physiology of the Cerebral Cortex of the Anthropoid Apes. *Proc. Roy. Soc.*, Vol. LXXI.

H. MUNK. *Loc. cit.*

L. BIANCHI. The Functions of the Frontal Lobes. *Brain*, Vol. XVIII, 1895.

V. HORSLEY and E. A. SCHÄFER. A Record of Experiments upon the Functions of the Cerebral Cortex. *Phil. Trans. of the Royal Society*, 1887, 1888, and 1890.

FLECHSIG. *Loc. cit.*

TH. KAES. Zur pathologischen Anatomie der Dementia paralytica. *Monatschr. f. Psychologie und Neurologie*, 1892.

HAMMARBERG. *Loc. cit.*

J. S. BOLTON. The Functions of the Frontal Lobes. *Brain*, 1903.

KARL SCHAFFER. 1. Die Topographie der paralytischen Rindendegeneration und deren Verhältniss zu Flechsig's Associationencentren. *Neurol. Centralb.*, No. 2, 1902. 2. Ueber Markfasergehalt eines normalen und eines paralytischen Gehirns. *Neurol. Centralb.*, No. 17, 1903.

F. NISSL. Die Diagnose der progressiven Paralyse. XXXIII. Versammlung der sudwest-deutschen Irrenarzte. *Ref. Neurol. Centralb.*, 1902, und *Centralb. f. Nervenheilk.*, 1902.

BAYERTHAL. Zur Diagnose der Thalamus und Stirnhirntumoren. *Neurol. Centralb.*, No. 13, 1903.

HITZIG. *Loc. cit.*

R. T. WILLIAMSON. Symptomatology of Gross Lesions of the Prefrontal Region of the Brain. *Brain*, Vol. XIX, London, 1896.

L. WELT. Ueber Charakterveränderungen des Menschen infolge Läsionen des Stirnhirns. *Deutsches Zeitschr. f. klin. Med.*, Leipzig, 1888.

M. JASTROWITZ. Beiträge zur Localisation im Grosshirn und ueber deren praktische Verwertung. *Arch. f. Psychiatrie*, Bd. 2 and 3.

L. BRUNS. Ueber Störungen des Gleichgewichtes bei Stirnhirntumor. *Deutsch. med. Wochenschr.*, 1892.

FERRANNINI. On the Physiology of the Orbital Lobe. *La Rif. Med.*, 1903, Nos. 21 and 22. Abstract in *Scottish Review of Neurology and Psychiatry*, 1903.

CHAPTER XI.

THE ISLAND OF REIL.

LARGELY on account of its unapproachable position the insula has not been fully explored by the experimental physiologist and pathologist. From the anatomist and histologist, however, perhaps unworthily, it has received much close attention. But in reference to the histological work which has been centred on it, most seems to have been of the piecemeal order, and although Kaes has investigated its fibre composition in a complete manner, Brodmann its cell lamination equally thoroughly, and Flechsig has described the history of its myelinisation, no individual worker, so far as I know, has carried out a conjunctive and comprehensive study of its fibre and cell structure on the lines followed in the present research. Hence, I think that no apology is needed for completing my survey of the cerebral cortex with a chapter on this region.

In order that my remarks on territorial variations may be free from ambiguity, it is compulsory that I should open with an anatomical explanation, and at the outset let me say that I propose to adhere to the terminology and description of the configuration of the insula given by Eberstaller. As this observer states, the main bulk of the insula is composed of five gyri, arranged in the form of a fan radiating towards the lower part or limen of the island. Down the centre runs our principal and most constant guide, the sulcus centralis insulae, placed in line with the fissure of Rolando above; three of the five gyri above-mentioned lie in front of this sulcus and two behind, they are individually separated by lesser sulci, and are named in order from before backwards, 1. gyrus brevis primus; 2. gyrus brevis secundus; 3. gyrus brevis tertius (gyrus centralis anterior insulae of Cunningham); 4. gyrus longus (gyrus centralis posterior insulae of Cunningham); 5. gyrus posterior secundus.

In addition to these, two minor gyri are described by Eberstaller, the gyrus transversus and the gyrus accessorius, they are both placed in connection with the anterior insula; the gyrus transversus takes the form of an annectant and unites the lower end of the gyrus brevis primus with the under surface of the frontal lobe; the gyrus accessorius lies a little higher and crossing the anterior limiting sulcus connects the insula with the orbital operculum.

As boundaries of the collection of gyri lying on this plane we have the anterior, superior, and posterior limiting sulci, separating the insula from the orbital, fronto-parietal, and temporal opercula, respectively, and in regard to the operculum last mentioned it is important to recollect that the transverse gyri of Heschl do not form a portion of the insula.

The foregoing is a brief description of the conformation in a normal case; of course variations occur, but these I need not enter into.

For the purpose of specially studying the structure of the insula I have removed it entirely from two brains and examined its nerve cells and fibres in serial transverse sections.

And now a word concerning territorial subdivision: I observe that Flechsig splits the insula into four myelogenetic areas, the first lies behind the sulcus centralis insulae and is classified "primordial," of the remaining three (all marked in front of the central sulcus), one, situated towards the lower end of the gyrus centralis anterior, possesses mixed "intermediate" and "terminal" characters, while the other two pertain to the "intermediate" class.

Next Brodmann[1], from studies in cell lamination, divides the insula into three fields, which he states are more readily defined during phases of development than in the adult condition, but since, at the time of writing, Brodmann's full paper has not appeared I cannot give the distribution of his areas.

Lastly from my inspection of the adult cortex I have arrived at the conclusion that although variations in different parts might allow of further subdivision it is sufficient, especially as the structure is in no part particularly interesting, to describe the island as consisting of two areas, an anterior and a posterior, and to make brief reference to variations existing within these main subdivisions.

TYPE OF FIBRE ARRANGEMENT. (Plate XXV, fig. 1.)

In writing of the fibre arrangement of the insula, Kaes refers to it as exhibiting the simplest form of development, and as resembling the formation met with in other parts of the brain during the period of childhood. He incautiously adds that its fibre development is impeded during embryonic growth by physical circumstances. As to the insular cortex showing a simple type of fibre arrangement I am at one with Kaes (on the second point want of experience prevents me from speaking); moreover, I believe that the topical variations in fibre constitution of which I shall write are only slight changes from a main type, and on the whole suggest an invasion of the insula by cortex from surrounding areas. The fundamental formation may be described as follows:

Zonal Layer.

The zonal layer in all parts of the insula has an advantage in point of depth over the layer in most other regions. Constitutionally, however, it is not particularly strong, the great majority of its fibres are very delicate and varicose, coarse varicose fibres are uncommon, and coarse evenly-medullated fibres rare. Representation is slightly better in front of the sulcus centralis than behind; and in the region of the "pole[2]," creeping up from the under surface, indications of the exaggerated zonal layer of the hippocampal region are seen.

[1] From an abstract, in the *Neurologisches Centralblatt*, of his paper read before the Berliner Gesellschaft für Psychiatrie und Nervenkrankheiten.

[2] The term "pole" is applied to the point where the three anterior insular gyri blend inferiorly.

Supraradiary Layer.

In the anterior insular area this layer has a scanty supply of fibres arranged more or less transversely, short in length, and delicate. In the posterior area, also, the supply is not good but there is just a sufficient aggregation of transversely-placed fibres at the level of the junction of the upper and middle thirds of the layer to form a "line of Kaes." In all parts of the insula "fibres of Martinotti" are rare.

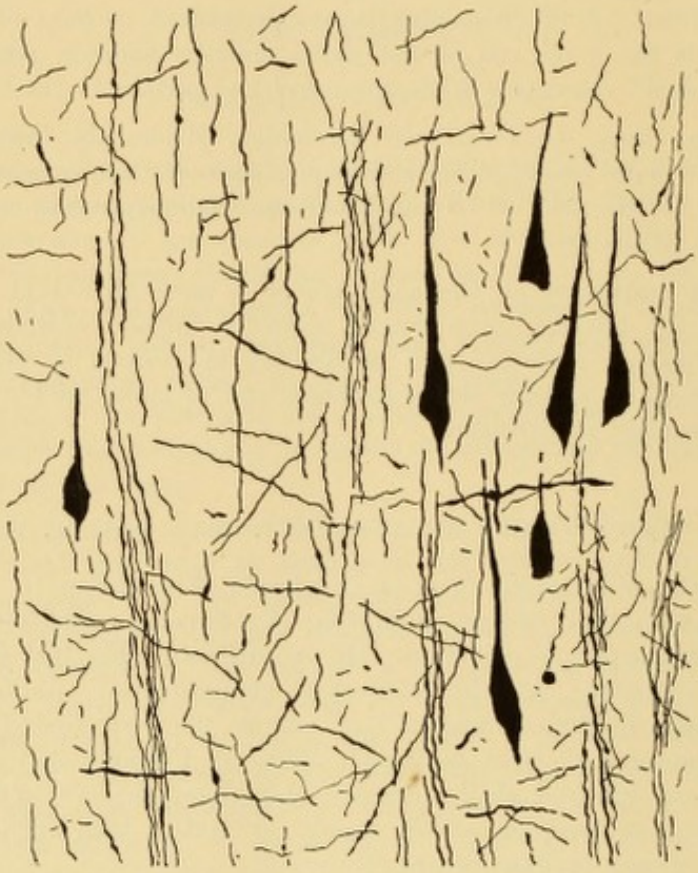

FIG. 23. Radiary zone in the anterior insular region, $\times \frac{480}{1}$.

Fibres of medium size are scarce and fibres of large calibre entirely wanting.

It so happened that in the section from which this drawing was taken the large chromophilous fusiform cells of the sixth layer retained the mordant and they have accordingly been included in the figure.

Illustrating the well-known difficulty of tracing the continuity between nerve cell and nerve fibre, I may mention that in many hundreds of sections of this kind giving a collateral display of cells and fibres I have not once succeeded in tracing that continuity.

The Line of Baillarger.

In the anterior region a line of Baillarger is barely recognisable, just a few fibres, some short and some long, but all of delicate calibre, indicate its position. In the posterior region, on the other hand, the line is quite distinct, it contains a fair number of fibres, some of medium size, and on the whole the condition we saw in the parieto-temporal cortex is approached.

This change in the line of Baillarger has proved a useful corrective in regional differentiation.

Radiations of Meynert.

The fasciculi are all slender and chiefly composed of thin wavy fibrils. In the anterior insular region a coarse medullated fibre is never seen except along the confines of the orbital operculum, and even medium-sized fibres are uncommon, but posteriorly, particularly in the vicinity of the transverse temporal gyri, gross fibres occasionally appear and give prominence to the bundles.

The bundles tend to pierce the line of Baillarger and are infinitely longer over the crowns of the different gyri than in the intervening flat sulcal portions.

Interradiary Plexus and Association System.

The general weakness in fibre wealth extends to the radiary zone, and is more pronounced anteriorly than posteriorly; for whereas in the latter position an appreciable number of long, medium-sized, association fibres traverse the interradiary spaces, in front of the central sulcus such fibres are uncommon and the plexus is almost entirely composed of delicate, wavy, varicose fibrils.

White Projection.

A study of the white substance in over-differentiated specimens is not void of interest, because it can be distinctly proved that while all that lying beneath the limiting sulci is richly supplied with fibres of large calibre, such fibres gradually dwindle away as the centre of the insula is approached.

On the important question of the connection between the claustrum and the cortex of the insula my sections afford little information, only in a few instances have I been able to trace large coupling fibres.

In general terms therefore we may describe the fibre representation of the insula as poor, and the topical variations as being not particularly interesting.

TYPE OF CELL LAMINATION. (Plate XXV, fig. 2.)

The two types of cell lamination which I would describe are as follows:

TYPE NO. 1.

The type which corresponds in distribution to the anterior fibre area.

Plexiform Layer.

This presents no features of interest.

Layer of Small Pyramidal Cells.

This lamina is not so richly endowed with elements as it is in other parts of the brain.

Layer of Medium-sized Pyramidal Cells.

All that I would say about this layer is that it is not up to the average in depth and that it fades insensibly into the subjacent layer.

External Layer of Large Pyramidal Cells.

We now reach a layer of greater interest. The constituent cells being very numerous and staining sharply form a quite prominent lamina. They differ from corresponding cells in other cortical regions (*e.g.* the parietal, temporal, and frontal cortex) in point of size and configuration; thus, they are small, lacking in plumpness, tapering and much elongated, the apical process being drawn out; also the base of the cell is angular instead of rotund and from these angles issue three, four, or even five delicate processes; the body substance stains freely and more or less uniformly; the nucleus inclines to be oval in shape and small, and the nucleolus is distinct.

Descending towards the limen insulae the same cells suffer a reduction in size and number.

In the gyrus brevis primus one occasionally sees in the midst of the layer, looking very much out of place, a larger and plumper cell endowed with distinct chromophilic particles, and I see no other way of explaining these than by regarding them as dislocated members of the orbital extension of the "intermediate precentral" area.

When the posterior insular type is described differences affecting this lamina will be indicated.

Layer of Stellate Cells.

It is a point of some importance that this layer is very indifferently represented, indeed it is hardly recognisable as a lamina, a break in the lamination and the presence of a few typical triangular and polymorphous elements only just mark its position.

Internal Layer of Large Pyramidal Cells.

Here follows another prominent lamina not so deep as the corresponding external layer, but chiefly made up of cells similar in size, shape, and staining properties. In addition, however, and particularly towards the limen one finds very remarkable cells calling for special notice. These are large bipolar cells of spindle form and great length, elements which stain very intensely—in this way reminding one of cells seen in the great limbic lobe—and which are entirely different in shape, size, and staining reaction from the cell with which we are familiar as the common constituent of the fusiform layer. Occasionally the two poles of the cell are of equal length and the nucleus is centrally situated, but more often the lower part is only a fraction of the size of the upper and the nucleus is dropped accordingly. Attention is drawn to these cells in the text-figure 23, and I will end my description of them by saying that the most typical examples are met with in the gyri breves and that they seem to attain their best development along the crown of these gyri; as we proceed downwards over the "pole" of the insula, although they lose in size, they gain in number; and they are particularly numerous in that part where we saw an exaggerated zonal layer, hence the impression is given that they are aberrant elements of the limbic cortex, which have spread up from the inferior surface.

Layer of Fusiform Cells.

This is a deep layer, richly-stocked with medium-sized triangular or spindle-shaped cells, having large nuclei, pale-stained protoplasm and the general characters of the same cells in other regions.

In the lower part there occur some small triradiate elements similar to those seen in the claustrum.

TYPE NO. 2.

This type corresponds in distribution with the posterior fibre area, and in describing it, it will suffice if I show the manner in which it differs from the arrangement just considered. The differences affect the external and internal layers of large pyramidal cells and the stellate layer.

Thus the large external pyramidal cells show a diminution in number and also a reversion to the usual shape. Instead of looking drawn out and laterally compressed, they now present a stouter outline, are more voluminous, and, I think, come to resemble corresponding cells of the audito-psychic cortex. In the parts immediately adjoining the gyri of Heschl a few large chromophilous cells like those characterising the audito-sensory cortex come to view and are no doubt aberrant elements.

Feebly developed in the anterior insula the stellate layer now becomes a definite lamina and its appearance affords a useful help in differentiating the two areas.

In the internal layer of large pyramidal cells there is again a reversion to the temporal arrangement, and it is particularly to be noticed that the large chromophilous fusiform cells, of which special mention was made in describing the lamination of the anterior insula, are absent.

Finally, I would add the general statement that both the fibre arrangement and cell lamination can be satisfactorily seen only in the actual gyri of the insula, in the intervening flat fields the cortical formation exhibits a stunted character like that usually seen in sulci.

DISTRIBUTION. (See text-figure 15, page 158.)

The area covered by the anterior type of cortex is considerably more extensive than that coated by the posterior, it comprises the gyrus brevis primus, gyrus brevis secundus, and the gyrus centralis anterior (gyrus brevis tertius), save the uppermost part of each, and the lower extremity of the gyrus centralis posterior (gyrus longus).

In regard to the uppermost part of the three gyri first-mentioned, the enveloping cortex is of an indiscriminate character; it is a combination of "frontal" and "anterior insular" types and therefore hard to classify. Along the orbital operculum the transition from "anterior insular" to "intermediate precentral" type is abrupt.

Part of the gyrus transversus shows insular characters and part "frontal."

The posterior insular area embraces the whole of the gyrus posterior secundus and the gyrus centralis posterior (gyrus longus), save its upper and lower extremities.

It is thus seen that the sulcus centralis insulae may be regarded as an approximate albeit not an absolute dividing line between the two areas.

Comparing this distribution with Flechsig's findings the most important point noticed is that my posterior area—that be it noted containing large fibres—seems to coincide with his "primordial" posterior field, but I am unable to confirm his division of the anterior insula into three distinct areas.

CONDITION IN THE ANTHROPOID APE.

Unfortunately my examination of the insula in the ape has not been perfect. As pointed out in the chapter on methods it is essential to the accurate survey of any given part that drawings or photographs of the surface morphology be first made, otherwise correct orientation is impossible; and as my material was received in the hardened condition, I was unable to expose and figure the insula in the desired manner without destroying much of the valuable specimen.

Therefore, having no guiding landmarks, my inspection is wanting in topographic accuracy, and particularly I regret that a comparison with the human arrangement has been rendered imperfect by the fact that I have been unable to identify with any degree of certainty the simian sulcus centralis insulae. However, in spite of these deficiencies, one or two points of interest have been observed.

In the hinder part of the insula a large obliquely placed gyrus is observed running parallel with the transverse temporal gyri, this seems to be the large gyrus posterior secundus peculiar to the higher ape, and it is important to notice that it presents a type of structure of a less primitive character than that in the anterior insula, and a type which has temporal features more distinctly marked than in man. This point can be referred to as significant of the probability that the hinder part of the insula in both man and ape has the same function as temporal cortex.

In describing the "intermediate precentral" area it was maintained that the simian fronto-orbital sulcus is the homologue of the anterior limiting sulcus of the insula, and that statement now finds support in the discovery that the primitive cortex of the ape's anterior insula is not wholly operculated as it is in man, but reaches forward to the sulcus first named.

Lastly, the lower part of the insula again exhibits rhinic characters.

FUNCTIONS OF THE INSULA.

Phylogenetically the pallium of the insula is an old creation; in early mammals it envelops a relatively large surface of the cerebral hemisphere[1], not until the higher forms are reached does it give indications of becoming operculated as it is in the human brain, and even in the anthropoid family of apes its concealment is still imperfect in the frontal direction.

Interesting in affording an illustration of the progressive expansion of the neopallium, an expansion which, as seen in the human brain, is universal, the wide extent of the primitive insula is further instructive inasmuch as it suggests a parallelism between its pallium and that of the olfactory region; and whatever the function of the insula may

[1] In most lower animals, according to the comparative anatomist, the suprasylvian, postsylvian and diagonal sulci are the homologues of the human superior, posterior, and anterior limiting sulci of the insula, respectively. In some orders, *e.g.* Canidae, no sulcus diagonalis is present and then the definition of the anterior insular limit becomes arbitrary. The sulcus diagonalis is accepted as the equivalent of the fronto-orbital fissure of higher orders.

be, the impression is given that, although it is a part found necessary to survival in the course of natural selection, it is yet one which, in man, does not play the important rôle it once may have held.

In view of this it is somewhat singular to find that at any rate one anatomist (Spitzka) looks upon a well-grown insula, and one exposed,—the latter condition has been regarded hitherto as a sign of degeneration, and I think rightly so, because it is common in the brains of idiots and then due to opercular deficiency,—as indications of high development.

Experimental physiology and pathology are silent on the functions of the insula: in the anthropoid ape it gives no reaction to electrical excitation, and no attempts have been made to ablate it because its surface is traversed by numerous important branches of the middle cerebral artery, and because it lies immediately over important structures which it would be essential to preserve intact if the operation were to be a truthful record of function.

Varied conclusions have been drawn concerning the effect of destruction of the insula in the human brain, but the most commonly accepted of these is that it harbours a link in the speech mechanism. Déjerine was the first to insist on this, and many others have followed suit. Thus from Pascal's writing we are given to believe that motor aphasia may result from destruction of the left insular cortex alone, and that it is not essential to this disability that the inferior frontal convolution should be included in the obliteration. The majority of authors, however, are not so openly heterodox, only holding that disorders of speech of an incomplete nature may arise; for instance, paraphasia, loss of the power to read aloud, dulling of speech comprehension, and even alexia and agraphia, are variously mentioned as sequels of lesions supposed to have been confined to the cortex of the insula.

The cause of the patent want of unanimity among clinical observers on the effects of insular lesions has to my mind been rightly indicated by von Monakow. The Zurich professor writes "that an unbiassed perusal of recent records of cases of left-sided lesions of the insula fails to suppress the conclusion that 'insular aphasia' is a mixed form of speech defect, in which to a greater or less extent all the components of speech are involved, and in which signs of motor aphasia will predominate if the lesion be in the anterior division of the insula, and signs of sensory aphasia if in the posterior[1]."

Now these are words which harmonise best with the facts brought to light by histology, and since cases can be referred to in which the insula has been stripped of its cortex without obvious clinical manifestation—several cases of the kind have occurred in my own experience—I would go further and say that in those recorded cases of insular lesion in which a positive speech disability has arisen, an unobserved involvement of tracts of fibres pertaining to the frontal operculum, on the one hand, or to the transverse gyri of Heschl, on the other, has been at the bottom of the mischief, an anatomical complication which the vascular supply of the part renders extremely likely, and a complication which from a wide anatomical experience of cases of cerebral softening I know to be particularly common.

[1] Wer in unbefangener Weise die Krankengeschichten der neueren Fälle mit linksseitigen Inselläsion durchliest, der wird sich der Meinung nicht verschliessen können, dass es sich bei der Inselaphasie fast nur um eine gemischte Form von Sprachstörung handelt, bei der mehr oder weniger alle Sprachqualitäten beeinträchtigt sind ("incomplete" Totalaphasie) und bei der, je nachdem der Läsion mehr die vorderen oder mehr die hinteren Abschnitte der Insel ergreift, bald mehr die Erscheinungen der motorischen Aphasie, bald mehr die der sensorischen (aber beide partiell) vorwiegen.

Moreover, in spite of what Pascal says, we have incontestable evidence to the effect that the cortex of the inferior frontal gyrus dominates the motor mechanism in speech, and if the cortex of the insula shares this function, it should surely present a similarity of structure, but this we can now state without a moment's hesitation is not the case; indeed, it is one of the many interesting revelations of cortical histology to see how the cell lamination and fibre arrangement of the fronto-orbital operculum change to an altogether different type almost the moment the insular plane is touched, and this may be upheld as one of our strongest reasons for refusing to abandon our original belief in favour of Pascal's tenet.

With regard to the involvement of the sensory (auditory) factor in speech, I would not state so emphatically that the posterior division of the insula plays no part in audition. As I have already stated, "auditory" cells are to be found in that portion of the insula immediately adjoining the most anterior of the transverse temporal gyri, and the rest of this division exhibits an approximation of structure to that obtaining in the great expanse of the temporal lobe which has remained unspecialised, so that although I should think it extremely unlikely that this particular area of cortex is endowed with important functional attributes, I cannot write as positively regarding it as I can about the cortex of the anterior insula.

To argue as Meynert did, that because the claustrum attains a higher development in man than in any other mammal, therefore this structure and the covering insula have an important bearing on the development of the faculty of speech, is inadmissible in the face of our present knowledge of the cortical localisation and connections of the speech mechanism, and as evidence to the effect that speech is dependent on the integrity of the claustrum is wanting, we cannot suppose that in cases of insular lesion it is involvement of this structure which occasions the speech disabilities.

If then speech can be dismissed as being unrepresented in the insula the question is, what function does it subserve? Although, as I have repeatedly said, histological appearances in themselves form an indifferent support for argument, still in the absence of stronger evidence I venture to say that they are significant on two counts.

In the first place, as the posterior insula is covered by a type of cortex resembling the temporal more than any other, to it I would indefinitely assign auditory attributes.

Secondly, the anterior insula having characters *sui generis* must possess a different and possibly a special function, and a point arising for discussion is whether it is in any way related to the sense of smell or taste. Glancing back at the phylogenesis of this region it seems very difficult to say exactly what parts in the brains of lower animals correspond to the respective anterior and posterior insulae, but one notices several points of interest, and the first is the relation which the insula bears to the fissura rhinica. Thus it has been observed that the Sylvian fissure is at first a most unstable element, only becoming fixed in higher mammals, and that the primitive sulcus which it is customary to call the Sylvian is regarded as being of the nature of a kink mechanically produced by flexure of the hemisphere in the process of serial development. But the point of importance is that when present it springs invariably from the rhinic fissure, and there seems little doubt that this kink or cleft becomes in man the lower end or notched stem of the Sylvian fissure (I am afraid we cannot as yet go so far as to say that it is the homologue of the sulcus

centralis insulae); knowing then how closely olfactory cortex follows the rhinic fissure, and looking upon the first part of the Sylvian fissure as really an offshoot of the rhinic, it does not appear so remarkable that elements similar to those met with in the lobus pyriformis should be found in the lower and anterior part of the insula—I refer to the chromophilous fusiform cells, and particularly the smaller variety noticed in the region of the "pole" of the island—and reasoning on these lines it seems by no means impossible that this is a relic of cortex which in lower creatures served for the treatment of olfactory impressions.

Failing this it is not impossible that the curious structure of the anterior insular cortex as a whole is a display of specialisation for the elaboration of gustatory impressions, and this possibility gains in likelihood when we take some experimental researches of Gorschkow's into consideration, and also the point that the anterior insula is not far removed from the cortex controlling movements of the tongue[1]. Gorschkow's statement based on no less than 40 experiments on dogs, carried out in Professor Bechterew's laboratory, is that the centre for the sense of taste occupies the convolutions lying immediately anterior to the Sylvian fissure (gyrus sylviacus anterior, gyrus ectosylvius anterior, and gyrus compositus anterior); he infers that the centre is isolated, and that when these convolutions are ablated, the sense of taste is abolished quite as purely and completely as is the sense of smell when the destruction affects the lobus pyriformis. Homologising these results Gorschkow places the human gustatory centre "in the region of the operculum" (details are not given in the abstract which I have read). It is questionable, however, whether Gorschkow is quite correct in this homology: unfortunately in the case of the dog there is no sulcus diagonalis or other definable equivalent of the human anterior limiting sulcus of the insula, but from what is known of the brains of other animals I think comparative anatomists would have no hesitation in declaring that the gyri sylviacus and ectosylvius anterior come within the insular limit (about the gyrus compositus anterior there would be doubt), and therefore it would be more correct to say that the corresponding area in the human brain is the anterior insula, not the operculum.

It is freely acknowledged that the reasons for attributing a gustatory function to the anterior insula are far from strong, but the hypothesis is only submitted tentatively, and with the feeling that any data we can collect turning on the localisation of the sense of taste are valuable.

Summary.

1. The general fibre supply of the insular cortex is poor, and it likewise contains no cells of large size. In the adult it is histologically separable into two main regions, an anterior and a posterior, between which the sulcus centralis insulae roughly forms a dividing line.

2. The anterior region is distinguished by a weak definition of the line of Baillarger, an absence of large fibres, two well-marked layers of elongated "large pyramidal cells" separated by a faint stellate layer, and the presence in the inner of these two layers of curious large chromophilous cells, of true spindle form, similar to cells noticed in the lobus pyriformis and gyrus fornicatus.

[1] This implies that the mucous membrane of the tongue is specialised skin, and that the rule for sensory and motor cortical centres for given parts to be deposited in approximation is followed.

3. The posterior region bears a common temporal type of cortex. There is a distinct line of Baillarger and an obvious stellate layer. The large external pyramidal cells reassume their ordinary form, the internal layer of large pyramidal cells becomes weakly represented, and the chromophilous fusiform elements vanish. In the vicinity of the transverse temporal gyri large fibres are noticed.

4. In the anthropoid ape the hinder part of the insula likewise bears temporal characters.

5. It is probable that the insula is "old" in the rank of phylogenesis, and that it plays a more important part in primitive mammals than in man and the higher apes.

6. Histology does not support the view that the insula is endowed with speech functions. In the cases giving rise to this conception an extension of the destroying lesion, either to the inferior frontal gyrus or to the transverse temporal gyri, is suspected.

7. Clothed by temporal cortex, the posterior insula is supposed to pertain to the auditory apparatus.

8. Studies in comparative anatomy show a close topographic relation between the insula and the fissura rhinica, and as the anterior insula contains elements common to the olfactory area, it may have to do with the recognition of smell; or in accordance with Gorschkow's experiments, its specialised cortex may represent the gustatory centre.

REFERENCES.

BRODMANN. Zur histologischen Localisation der Hirnrinde (die Insel). *Neurol. Centralb.*, No. 23, 1903.

P. FLECHSIG. Neue Untersuchungen, etc. *Neurol. Centralb.*, No. 21, p. 983, 1898.

EBERSTALLER. Zur Anatomie und Morphologie der Insula Reilii. *Anatomischer Anzeiger*, No. 24, 1887.

D. J. CUNNINGHAM. *Loc. cit.*

TH. KAES. Beiträge zur Kenntniss des Reichthums der Grosshirnrinde, etc. *Arch. f. Psych. u. Nervenkr.*, Bd. XXV, Heft 3.

A. E. SPITZKA. A Preliminary Communication of a Study of the Brains of two distinguished Physicians, father and son. *Philadelphia Medical Journal*, April, 1901.

PASCAL. Du rôle de l'insula de Reil dans l'aphasie. Bordeaux, 1890.

W. OTUSZEWSKI. Von der Bedeutung der Associationencentren von Flechsig zur Erforschung der Entwickelung des Geistes, der Sprache, der Psychologie der Sprache, wie auch der Lehre von der Sprachlosigkeit. *Neurol. Centralb.*, No. 5, 1898.

C. VON MONAKOW. Gehirnpathologie. Wien, Holder, p. 571, 1897.

P. SAMT. Zur Pathologie der Rinde. *Arch. f. Psych.*, Bd. V.

M. HOLL. Ueber die Insel des Carnivorengehirns. *Arch. f. Anat. u. Phys.*, 1899, *Anat. Abth.*, Heft 3 and 4.

S. RAMÓN Y CAJAL. Studien über die Hirnrinde des Menschen. Die Hörrinde. Leipzig, Barth, 1896.

HAMMARBERG. *Loc. cit.*

A. S. F. GRÜNBAUM and C. S. SHERRINGTON. *Loc. cit.*

TH. MEYNERT. Der Bau der Grosshirnrinde, etc. *Vierteljahrsch. f. Psych.*, etc., p. 57, 1872.

GORSCHKOW. Ueber Geschmacks- und Geruchscentren in der Hirnrinde. Dissert. St Petersburg, 1901. Ref. *Neurol. Centralb.*, p. 1092, 1901.

ADDENDUM.

FURTHER HISTOLOGICAL STUDIES ON THE LOCALISATION OF CEREBRAL FUNCTION. THE BRAINS OF FELIS, CANIS, AND SUS COMPARED WITH THAT OF HOMO.

During the period which has elapsed since the Manuscript of the foregoing work was presented to the Royal Society, my investigation has been extended to the brains of some of the lower animals, and, with the sanction of the Royal Society, the results are offered here in the form of an Addendum.

PART I.

HISTOLOGICAL.

The brains employed were those of the Cat (Felis Domesticus), the Dog (Canis Familiaris) and the Pig (Sus Communis). The chief objects held in view throughout the investigation were as follows: to strengthen the position I have taken up in regard to the localisation of different functions in the human brain; to assist the physiologist in the future performance of experiments aiming at the elucidation of problems still obscure (it was for this special reason that I chose the brains of common animals, like the dog and the cat); and to settle various points bearing on cerebral homologies, which the comparative neurologist has been unable to determine.

Method of Examination.

It is unnecessary to describe the method of examination in detail, as it is practically identical with that previously adopted. The brains were converted into series of complete transverse sections, and pairs of sections, taken at intervals of ·5 mm., were stained alternately, one for nerve fibres by the method of Wolters-Kulschitzky, the other for nerve cells by a modification of the method of Nissl. So, for instance, in the cat's brain, which is 5 cm. long, the arrangement of the cortical nerve fibres and the cell lamination have been examined, side by side, in a series of one hundred sections, equidistant from one another.

Cortical Subdivisions.

The cortex of these animals is subdivisible histologically into areas to which I will assign the following names:

Crucial or Motor,
Postcrucial or Sensory,
Parietal,
Visual,
Ectosylvian,
Limbic,
Rhinic,
Extrarhinic,
Frontal.

I will now offer a detailed account of the structural characters and distribution of all these areas, as they appear in the different brains.

Felis Domesticus.

Crucial or Motor Area.

We are indebted to the experimental physiologist for the information that the motor cortex of the common members of the Carnivore family is deposited in relation to the sulcus cruciatus. Acting on this knowledge, the histologist has already paid attention to this region, and found an arrangement of elements, akin to that present in the "precentral or motor" cortex of man, and, in particular, he has observed that a field can be mapped out, distinguishable in possessing the equivalents of "giant" cells of Betz or "ganglionic" cells of Dr Bevan Lewis[1].

Cell Lamination.

A plexiform layer is present but calls for no special remarks.

The small pyramidal cells are more stunted, and do not form such a distinct layer, as in man.

A layer of mixed medium-sized and small pyramidal cells follows, and, for reasons appearing later, it is important to notice that this layer does not harbour cells of outstanding size.

As to the "giant" cells, I hasten to mention that a most careful histological account of these elements, as they appear in the cat, was written as long ago as the year 1879, by Dr Bevan Lewis, and in regard to their size, number and distribution there is nothing for me to add to that description. The cells are the largest in the whole brain, and immediately remind one of the human precentral "giants"; plump and of oval or pear shape, they issue numerous dendrites radiating downwards and outwards, while their body is well stocked with chromophilic elements. I have not measured many cells, but they vary considerably in size, and, according to Dr Bevan Lewis, range in diameter from $26 \times 14\mu$ to $106 \times 32\mu$, the largest occurring round the lateral end of the crucial sulcus, the next in size on the posterior wall and bank, and the smallest on the anterior wall and bank of the same fissure. Another human peculiarity which we find repeated is the tendency for the cells to be arranged in nests or clusters.

The next layer containing fusiform cells is not of special interest.

Fibre Arrangement.

In the cat the motor area cannot be mapped out with such ease from an examination of the fibres only as in the human being or ape, for, although rich in fibres of medium size, its cortex is wanting in those of large calibre, and does not stain so intensely as some placed further back (postcrucial area).

Briefly stated the composition is as follows:

1. A deep and dense zonal layer, made up for the most part of fine varicose elements, but containing in addition a few medium-sized and some large medullated fibres.

2. A supraradiary layer which seems shallow compared with that of other regions, but which is interesting in showing numerous fibres of Martinotti arching up to join the zonal layer, at a tangent.

3. A deep and well-stained radiary zone, in which the radiary fasciculi are voluminous and compact, but lacking in gross fibres; the same defect applies to the interradiary plexus, whose real fibre wealth is not appreciated until it is examined under a high power lens.

[1] To explain references made hereafter to the comparative sizes of cells, I must state that the term "giant" applies to the great cells of the cruciate cortex; the term "large" to the equivalents of the "large external" and "large internal" pyramidal cells of man; and the terms "medium-sized" and "small" to the cells corresponding with the elements known by those significations in man. In the same way, among nerve fibres, we will find medullated fibres of "large" and "medium" size, varicose fibres, and varicose fibrils.

4. A line of Baillarger, definable as a dark streak lying some distance below the outer margin of the radiary zone, and on a corresponding level with the Betz cells.

A final curious point is, that on the walls of the crucial sulcus where the Betz cells are abundantly deposited, and where one would expect a corresponding richness of fibres, the supply is not so good as on the surrounding free surface.

Distribution. (*Vide* Plates 1 *a* and 2 *a*.)

In the primate brain we found the area covered by the cells of Betz of small extent, so it is again in the cat. On the mesial surface, the area is confined to a small portion of the marginal gyrus, situated immediately behind the sulcus cruciatus, and it is worthy of mention that it does not reach quite to the hinder extremity of the sulcus. In a frontal view, the close relation to the sulcus cruciatus is better displayed (as previously stated, the distinguishing cortex coats both walls of the sulcus, and this, of course, cannot be shown in a surface diagram); then, anteriorly, the area extends downwards and outwards, to be limited in turn by the upper extremity of the orbital and the anterior extremity of the coronal sulcus. Laterally, the sulcus coronalis constitutes a bar, transverse sections showing that the formation reaches to the floor of, but not beyond this sulcus. Posteriorly, the field meets the postcrucial or sensory area midway across the hinder limb of the sigmoid gyrus, and it is most important to observe that the boundary line is constantly related to a shallow depression, placed equidistant from the cruciate and ansate sulci. This depression varies in representation in different brains and even in opposite hemispheres; it may appear as a short transverse fissuret, or merely be a dimple, but it is never entirely absent, and I have little doubt that it is the equivalent of a fissuret, better developed in other animals and known as the "compensatory ansate[1]." Further reference will be made to this fissure when the homology of the part is discussed.

Visual Area.

Fibre Arrangement.

Many of the characters, which served for the identification of the visual area in man and the anthropoid ape, are reproduced.

The zonal layer, while better developed than in surrounding parts, is not so dense as in the motor region. It is chiefly composed of fine varicose elements, but evenly-medullated fibres, of rather large size, are occasionally seen, also fibres from the supraradiary layer run up to end in it (fibres of Martinotti).

The succeeding supraradiary layer is pallid, poorly supplied with fibres in its upper two-thirds, but richer towards the line of Gennari.

The line of Gennari, vel Baillarger, was our surest guide to the localisation of the visual cortex (visuo-sensory) in primates, and, again, it does not fail us in these lower animals; in general composition, moreover, it is unaltered; but it must be pointed out that, by reason of the reduced scale of construction, it is impossible to see the line with the naked eye and define its area of location in unstained sections, as can be done in the human brain.

Below the line of Gennari comes a pallid stripe, corresponding in position with the large nerve cells to be presently mentioned.

The radiary zone is again characteristic; the bundles of Meynert are fairly stout, and are often strengthened by a large medullated fibre; and it is a point of importance that the interradiary spaces are crossed obliquely by numerous stout fibres springing from the white substance, which can only be the terminals of the radiations of Gratiolet (the optic fibres of Ramón y Cajal).

Generally speaking, the visual cortex is rich in fibres, but wanting in depth.

[1] I have taken this name from the Royal College of Surgeons' Catalogue, compiled by Dr Elliot Smith.

Cell Lamination.

A plexiform layer, and layers of small and medium-sized pyramidal cells, can be identified, but they are devoid of special interest.

On a level with the line of Gennari is a good layer of sharply-stained pyramidal cells, not so large as those at the same level in other cortical areas. They seem to correspond with the human external large stellate cells.

Below this comes a fairly broad layer of ill-stained, small cells, and there seems to be no doubt it is a weakly developed homologue of the human stellate layer.

But the cells which most of all characterise the visual cortex are large elements, indubitably corresponding with the large, human, solitary cells of Meynert. They are numerous and form a distinct layer; on the whole their shape is pyramidal, but they may be stellate or polymorphous and they contain numerous chromophilic elements. Along with these one occasionally observes rounded processless elements, of large size, full of pale-stained Nissl particles. They are of doubtful significance.

The last layer, the fusiform, presents no special characters.

Distribution.

The cortex endowed with these qualities bears a close and evidently a very important relation to two deep and constant fissures, situated on the inner and dorsal surfaces of the hemisphere, respectively; they are the calcarine-intercalary complex of Elliot Smith (the splenial of other authors) and the lateral. On referring to the figures reproduced these relations will be clearly understood. It may be noticed that, on the mesial surface, the conjoined calcarine and intercalary fissures form a limit, and an important point, unseen in a surface diagram, is that the visual cortex is confined to the peripheral wall only of the fissural complex, the opposite wall being covered by another type altogether, to be described later under the heading "limbic."

Viewed from the caudal aspect, the lower limit lies level with the lower extremity of the calcarine fissure, and a distinct interval separates it from the hinder extremity of the fissura rhinica and from the occasional posterior offshoot of the same fissure.

From these inner boundaries the area sweeps outwards over the marginal gyrus and round the occipital pole; then, gaining the convexity of the hemisphere, it is not arrested until the hinder part of the sulcus lateralis is reached.

Postcrucial or Sensory Area.

Professor and Madame Vogt, from an examination of the cortical nerve fibres of the kitten and fully grown cat, have mapped out an extensive area in the frontal region, embracing the motor area just defined and spreading from here backwards in the direction of the suprasylvian and lateral sulci; this they designate the "area precox anterior," because it is one of those parts in which the contained fibres acquire their myelinic investment at a comparatively early date, but, and this is a point I wish to emphasise, they seem to have made no serious attempt to effect a further subdivision of the area.

Now I must confess that my preliminary examination of sections stained for nerve fibres did not suggest the existence of two separate areas, but on closer observation, and especially after a collateral inspection of the cell lamination, I have arrived at the conclusion that the field is divisible in much the same way as is the pre- and post-Rolandic cortex of man and the man-like ape.

Type of Cell Lamination.

The cell arrangement is distinguishable from that of the motor area in three ways. First, there is a layer of elements corresponding to the external layer of large pyramidal cells in man, a layer which, as I have mentioned, is absent in the motor area. The cells do not approach the Betz cells in magnitude, but they stand out plainly because they are much larger than the surrounding elements.

In the second place, the layer of giant or Betz cells becomes altered. It is true that cells pertaining to the giant category are still present, and it is remarkable that they can be followed along the floor of the suprasylvian sulcus almost to its posterior extremity, but such cells cease to be arranged in nests; they are of the solitary type. Setting aside these "giant" elements, the fundamental cell in the layer is one similar in size, shape, and general appearance to those noted in the above-mentioned external layer.

Thirdly, between these two layers of pyramidal cells a definite collection of small and indistinctly stained elements, which one is forced to regard as representative of the stellate layer of man, is intercalated.

Fibre Arrangement.

In my examination of the primate cortex I noticed that the postcentral or sensory area was remarkable in containing numbers of fibres in the interradiary plexus, of larger calibre than any to be found in the precentral or motor area, but at the same time the latter cortex had a great advantage in point of general fibre richness. In the cat conditions are quantitatively though not qualitatively changed. If it were possible to enumerate the fibres, the crucial cortex might rise superior to the postcrucial, but in the latter the wealth of gross fibres is so great that, in sections stained for the display of nerve fibres, it stands out more prominently than does any in the rest of the brain; it was for this reason that one first imagined that this strip of territory belonged to the motor area. However, since the fibre of gross size, as in the primate brain, is the dominant constituent in sensory cortex; also, since the fibre arrangement is associated with a special type of cell lamination, I feel justified both in granting independence to the area, and in regarding it as the homologue of the primate postcentral area.

Distribution.

The area is somewhat extensive, and, having no definite relations to named fissures, reference to the figures on Plates 1 *a* and 2 *a* will be necessary to a comprehension of its distribution.

On the mesial surface, it does not appear.

On the dorsal aspect, it forms a posterior buffer to the motor area, it is thin towards the middle line, but externally it expands and oversteps the outer fork of the lateral (ansate) fissure to cover a considerable portion of the suprasylvian gyrus. And, as I have already stated, this type of arrangement runs along the whole length of the floor of the suprasylvian fissure.

Laterally, it covers most of that field of cortex inserted between the coronal and diagonal sulci.

Parietal Area.

The designation "parietal" is being attached to a field centred on the marginal gyrus, and interposed between that just described and the visual area. It is readily defined and has the following distinctive characters:

Fibre Arrangement.

Examining a transverse section passing through the centre of the area, stained for nerve fibres, it is at once noticed that the cortex is pallid compared with that of the postcrucial field—this

pallor of course denotes a diminution in fibre wealth, and the loss affects all layers and systems of fibres—but, and this is of some importance, the radiations of Meynert, although attenuated, still contain a few fibres of fair size, and in the depths, partly in the interradiary plexus and partly in the white substance, fibres of large calibre, many of which seem to be cut transversely, are still present.

The presence of such large fibres serves to distinguish this cortex from the subjacent limbic cortex.

Cell Lamination.

The layer of small pyramidal cells is followed by one of medium-sized elements which increase in magnitude as the layer is descended, but do not attain the size of large pyramidal cells; indeed, it is a noteworthy feature of this cortex that there is no external layer of large cells. A stellate layer, also, is very difficult to define. But there is an important lamina of large internal pyramidal elements; not so large as the average representative of the same layer in the sensory or postcrucial cortex, these cells are curious in being very much elongated and in staining very intensely and uniformly.

A layer of fusiform cells is present but devoid of special interest.

Distribution.

The area occupies all that part of the gyrus marginalis intervening between the sensory and visual areas; it also oversteps the lateral fissure, and, as the diagrams show, runs backwards along the mesial half of the suprasylvian gyrus.

It must finally be mentioned that this cortex presents most typical characters in its anterior half, and that, on the confines of the visual area, the arrangement of the fibres especially undergoes some change—it loses in richness—so that I may be wrong in calling this all one area. (The field marked with dots in the diagrams is here referred to.)

Ectosylvian Region.

The ectosylvian region embraces all those gyri investing the Sylvian fissure and lying within the confines of the suprasylvian sulcus.

The cortex of this part differs from that on the convexity in having no cells of large size, and also an inferior supply of nerve fibres; these are general characters. On closer examination it is divisible into two sub-areas, indicated by vertical streaks and cross-hatching in the figures.

We will take the lower of these areas first.

Ectosylvian Area A.

Fibre Arrangement.

I have given independence to this area chiefly on account of some peculiarities in the fibre arrangement. On examining fibre sections one observes nothing distinctive in the outer layers, but in the depths, streaming up from the white substance and for the greater part obliquely placed, are numbers of fibres of medium size giving rise to quite a dense plexus. It seems clear that these pertain to some fasciculus emerging from the white substance to impinge hereabouts, and that they are destined for cells confined to this part is likely, because the cell lamination exhibits corresponding peculiarities.

Cell Lamination.

There is an ordinary plexiform layer.

A small pyramidal layer is present, but the components are scanty, so also are the medium-sized pyramidal cells, although their shape is perfect.

A layer of large external pyramidal cells is wanting.

The stellate layer is most difficult to define, being represented by a few small triangular cells only.

The layer of internal pyramidal cells is a good one and constitutes a very important feature, because in all likelihood it is to these cells that the large fibres just mentioned come. The cells are of pyramidal form, with an elongated apical and three or four basal processes. They stain sharply, stand erect and are present in considerable numbers; amongst them a larger cell, which might almost be called a "giant," is occasionally seen.

The layer of fusiform cells presents no special features.

The diagram shows better than words can describe the distribution of this area, also that of the field above it, which I shall now consider.

Ectosylvian Area B.

Cell Lamination.

Though there are no large elements, variations in size, shape and arrangement render possible the division into the usual seven layers.

It may be specially noticed that two layers of large pyramidal cells can be identified, but it must be understood that the cells composing these layers are only large by comparison with other autochthonous elements; they are also much elongated, and there are no obvious differences between the two layers individually.

Fibre Arrangement.

The fibre arrangement is uninteresting. Compared with the crucial and postcrucial areas, the cortex is very poorly supplied with fibres and consequently looks pallid. A line of Baillarger is not obvious; the radiations are delicate; there are no fibres of gross size and only a few of medium calibre.

Extrarhinic Area.

By this name I wish to distinguish an area of considerable extent indicated by small circles in the diagrams, and covering the convolutions bounding the rhinic fissure externally.

Its structure does not throw any light on its function.

Fibre Arrangement.

In sections stained from nerve fibres it appears pallid, and under a high power, although there is an abundance of delicate fibres, not one of large or even medium size can be discovered. Still the general arrangement follows the common type and has not the bizarre features of the lobus pyriformis to which it lies so close.

Cell Lamination.

The arrangement is peculiar. All the cells are small or medium-sized, closely packed and deeply stained. An uninteresting plexiform layer is followed by a good layer of small pyramidal cells, and to this succeeds a deep and unbroken layer of pyramidal elements of medium size, remarkable in being all more or less equal in diameter. Below this are some fusiform cells, and in the white substance, scattered, dumpy and rather large stellate cells occur.

Limbic Area.

Broca's "grande lobe limbique" included the hippocampal region as well as the gyrus fornicatus; here the term limbic is used in the narrow sense; it applies to the latter only, or, more correctly speaking, to the gyri surrounding the corpus callosum.

Fibre Arrangement.

It is a part in which the fibre supply is poor, and in which there are no large or even medium-sized constituents.

Cell Lamination.

The cell endowment is likewise on a poor scale. Following an ordinary plexiform layer, come small pyramidal or polymorphous cells, then a deep lamina of pyramids not exceeding medium size, and, finally, a layer of spindle-shaped cells.

This may be taken as the general type: two variations occur.

Variation A.

The part immediately investing the genu and anterior half of the corpus callosum shows a layer of small, but very sharply stained (chromophilous) lanceolate cells, placed on a level corresponding with the inner lamina of large pyramidal cells of other parts. These are reminiscent of similar cells seen in the pregenual area of the human brain; their presence occasions no appreciable alteration in the fibre arrangement.

Variation B.

The second variation occurs behind the splenium. Here, while the fibres remain small, there is a distinct increase in their number, and an especial accumulation at the level of the line of Baillarger.

The cell lamination gives signs of compression by the mid-brain, and is curious. After a deep plexiform layer comes a lamina, eight to ten cells deep, composed of closely packed, small, oval elements, with the long axis placed parallel to the surface. Then follows a layer, in which stunted and indifferently stained pyramidal cells of medium size are mixed with cells, smaller but more deeply stained, and lastly, the fusiform cells are flattened so that their long axis is horizontal instead of vertical.

Prefrontal Area.

This area includes cortex on the mesial surface, in front of the limbic area, and, on the lateral surface, in front of the orbital fissure.

In sections stained for nerve fibres, the general supply is poor, but there are many medium-sized elements which were absent in the limbic area.

The cell lamination is uninteresting. The most prominent elements pertain to the internal layer of large pyramidal cells, but although greater in size than corresponding cells in the limbic area, they are hardly deserving of the name large.

Lobus Pyriformis.

Roughly speaking, the lobus pyriformis is divisible into two fields, an outer and an inner, indicated as Olfactory A and Olfactory B in the figures.

The outer field, Olfactory A, is the more interesting of the two, and its structure corresponds with that found in the pyriform lobe of man.

In sections stained for nerve cells one observes a deep plexiform layer, and then a prominent band of large well-stained, polymorphous cells (fusiform, triangular, stellate, etc.) with sharp processes pointing in all directions. The lamina is not broken up into nests, as it is in primates, but, in the posterior part, shows signs of being irregularly interrupted.

Beneath this, is a deep layer occupied by large, erect and elongated pyramidal elements, clearly stained, and widely separated from one another. They may be the "tassel" cells of S. Ramón y Cajal.

In the depths is a layer of well-stained, small, triangular, or fusiform cells.

In sections stained for nerve fibres, the dense zonal layer—the lamina medullaris externa of other authors—is the feature of greatest interest.

Concerning the rest of this area I feel that nothing is to be gained by describing it in detail, as it seems to be agreed that the whole of the lobus pyriformis subserves the olfactory function. I would only mention that I have observed islets of small cells in the plexiform layer, like those present in the fissura hippocampi of man, also, a layer of cells corresponding to the stratum cellularum pyramidalium.

The histological features of the cornu ammonis and tuberculum olfactorium may also be left out of account.

Canis Familiaris.

In its external morphology, the brain of Canis presents many points of resemblance to that of Felis; it is therefore not surprising that numerous histological features should be repeated, and that the surface maps resulting from an analysis of serial sections should exhibit a general similarity. In view of this the following account will be shorn of detail and devoted chiefly to a comparison of the two brains.

Crucial or Motor Area.

The giant cells form a broad, richly-stocked, outstanding lamina, but the nested arrangement, noticed in Felis and so well-marked in Homo, is less apparent. The motor cells of Canis are also peculiar in being much elongated—a cytological feature observed in many other parts of the same animal's brain;—otherwise they present common characters, thus, numerous processes emerge from the sides as well as the base of each cell, and chromophilic elements pack the body.

In regard to numerical disposition, the postcrucial and lateral parts of the area contain cells in maximum abundance, in the precrucial part there are appreciably less.

I have not attempted an accurate estimate of local variations in magnitude, a laborious undertaking only to be accomplished by making and comparing a large series of outline drawings, but I believe the general statement to be correct, that the largest cells occur where the number is greatest, and reversely; at the same time the difference between the smallest and the largest is not very great, not nearly so pronounced as in Man.

What was written concerning the fibre arrangement of the motor area in Felis will apply to Canis.

Distribution (*vide* Plates 1 *a* and 2 *a*).

On the mesial surface of the hemisphere the area just appears at the upper margin, along the posterior lip of the sulcus cruciatus; and a point which a surface diagram cannot show is that motor cells run along the posterior wall of the same sulcus almost to its hinder extremity.

Viewed from the dorsal aspect the area may be again considered in relation to the sulcus cruciatus, and, it may be at once stated, that it covers both walls of this sulcus, save the innermost part of the anterior bank. In reference to the latter part, I would specially point out that there is no obvious indentation or fissuret to mark the particular spot on the anterior fissural wall where the motor area ceases, but it must be noticed that the sulcus takes a bend at the point; the same obtains in the Cat, and I think comparative anatomists will agree that the flexure corre-

sponds in position with a fissuret, present in other animals, *e.g.* Felis Leo, and most Ursidae and Pinnipedia, known as the precrucial fissure.

The remainder of the anterior boundary slopes forwards and outwards across the free surface of the anterior limb of the sigmoid gyrus to reach the upper extremity of the orbital fissure, and the latter completes the limit.

In the lateral direction the area does not extend beyond the line of the coronal fissure.

Reference to the figures will show the position of the posterior limit. In particular, I would draw attention to the point that motor cortex does not reach as far back as the ansate fissure, and that it is limited in a remarkable manner by the small and insignificant looking "compensatory ansate" fissuret, marked "homologue of Rolando" in the diagram. This fissuret has been previously alluded to (motor area, Felis) as the probable homologue of the primate sulcus centralis.

Postcrucial or Sensory Area.

This field is perhaps more readily defined in Canis than Felis. Reference to the figures will show how it forms a posterior buffer zone to the motor area. It just appears on the inner surface; on the dorsal aspect it lies anterior to the ansate fissure, and, laterally, it covers the caudal two-thirds of the gyrus coronalis.

As in Felis, the distinguishing cell feature is the existence of two layers of large pyramidal cells, separated by a lamina of stellate elements. In examining the part care must be exercised not to confuse it with motor cortex, for the internal large pyramidal cells have some of the shape and appearance of Betz cells, and one is apt not to recognise that they are of smaller size; again, as the large cells of the outer layer are not numerous, they may be overlooked.

This lamination is accompanied by a remarkable arrangement of fibres. Without doubt there is no part of the cortex in which the fibre wealth is greater, and the apparent density is intensified by the presence of an extraordinary abundance of fibres of large calibre. This feature was marked in Felis, but it is even more pronounced in Canis.

Concerning that part of the gyrus suprasylvius lying just behind the junction with the gyrus coronalis, and also that part external to the ectolateral gyrus (marked by coarse dots in the diagram), I am doubtful whether to include them in the postcrucial area or not. In a transverse section stained for nerve fibres the cortex is obviously denser than that of the gyri above and below, and it also contains a few large medullated fibres, but, at the same time, its general wealth is certainly less than that of the field just described. Moreover, while there is no doubt of the existence of two layers of large pyramidal cells, the individual cells are distinctly smaller than they were anteriorly.

Parietal Area.

This area has a distribution resembling that in Felis, and its microscopic appearances are equally distinctive.

In sections stained for nerve fibres, its cortex looks pallid, the radiations are slender, and the only large fibres present are cut transversely and lie in the depths of the cortex adjoining the white substance.

In reference to cells, the absence of large internal pyramids is a negative point of some importance, while the presence of a substellate layer of rather large, elongated, intensely stained and prominent pyramidal cells, is a positive differential character.

Visual Area.

The visual cortex presents such a remarkable arrangement of cell and fibre elements that it can be identified, and its distribution defined with perfect exactitude by simple histological methods.

Turning to the figures, I would first draw attention to the relation of the area to the combined intercalary and calcarine fissures. Visual cortex again coats only the outer walls of these sulci; and it is interesting to observe that, in front, the area begins at the junction of the cruciate and intercalary fissures, a junction which seems to be associated with the presence of a concealed annectant gyrus; and that below the area ends exactly along with the calcarine fissure; and, further, that this lower limit lies several millimetres above the level of the posterior offshoot of the fissura rhinica. Sweeping over the hinder part of the gyrus marginalis and the occipital pole the area finds external limits, first, in the hinder part of the lateral sulcus, and then in the shallow postlateral fissure, and it must be mentioned that visual cortex clothes the inner walls only of the last-named fissures.

One is struck by the great extent of the area relative to the rest of the surface. I have made no accurate estimate, but in rough terms it occupies quite one-sixth of the dorsal and mesial surfaces of the hemisphere; a very different state of affairs from that obtaining in primates.

Strongly reminiscent of what one has seen in the visuo-sensory cortex of man and the ape, the microscopic characters are unmistakeable. In fibre-stained sections a line of Gennari is visible to the naked eye (N.B. the line is not similarly visible in unstained sections), and microscopically is composed of the usual plexus of fine fibres. In the radiary zone there is an abundance of large fibres, most of them cut obliquely and deeply placed.

The cell lamination is worth putting down in detail: it is made up of, (1) An uninteresting plexiform layer. (2) A somewhat closely-packed layer of small polymorphous cells. (3) A layer of well-stained, erect, medium-sized pyramidal cells, among which lie some specially important larger elements, endowed with Nissl bodies. Such cells occur at all parts of the layer, but are not numerous, and it is curious that they are seen at their best along the lateral outskirts of the area. The suggestion has occurred to me that they are representative of the large external pyramidal cells of the visuo-pyschic cortex of Homo. (4) There follows a pallid, rather broad stratum, containing elements reminding one of stellate cells, but they are indifferently stained. (5) Then more medium-sized cells, and mixed with them some solitary cells of Meynert, the latter being of pyramid form, erect, and intensely stained. (6) Some small fusiform cells complete the lamination.

Ectosylvian Region.

The ectosylvian sulcal arc is much more perfect in Canis than Felis, and forms a clear boundary to a singular type of cortex, occupying what I am calling Ectosylvian Area A (cf. Felis).

Roughly speaking, it covers the first arcuate gyrus of Leuret, and it has the following nerve fibre characters; the general wealth is not at all good; for instance, compared with the convolutions above, the radiary zone is relatively pallid. In the depths, streaming out from the medullary projection are numbers of fibres almost gross in calibre, confined in their distribution to the neighbourhood of the white substance, and running for the most part obliquely or parallel to the surface. I believe that the majority of these fibres strike the cortex towards the hinder end of the area, because, in the frontal direction they gradually lose in number.

The nerve cell arrangement is equally peculiar. A plexiform layer, and layers of small and medium-sized pyramidal cells, can be identified; but there are no large external cells. A paler stratum, containing rounded and ill-stained elements, follows, and then come the cells which give character

to the field; these are lanceolate in form, just more than medium size, intensely chromophilous, and sufficiently numerous to form a distinct layer. Below this, ordinary long fusiform cells occur.

Ectosylvian Area B.

This is the field lying between the suprasylvian and ectosylvian sulci, and occupying the second arcuate gyrus of Leuret.

As regards nerve fibre arrangement, it differs from the "sensory" cortex above in not showing the great wealth of large fibres throughout the radiary zone, and, from the cortex of the underlying first arcuate gyrus, in not harbouring the peculiar collection of large, deep fibres.

The arrangement of cells follows the common plan. External as well as internal layers of large pyramidal cells are recognised (in the gyrus arcuatus primus there is no external layer). There is nothing remarkable in the shape or staining reaction of the outer cells, but they are not so large as corresponding elements in the postcrucial cortex, nor are they numerous. The inner cells are not so chromophilous as those to which I drew special attention in describing Area No. 1.

Limbic Area.

The limbic area has a similar distribution, and exhibits variations similar to those observed in Felis.

In the specially marked pregenual area (Limbic, A) are chromophilous, elongated cells, strongly mindful of the elements to be found in the same situation in Homo.

Frontal Area.

In transverse sections through the frontal lobe it is not easy to distinguish between anterior limbic cortex and that marked frontal in the diagrams. Still, in sections stained for nerve fibres there is an appreciable increase in calibre of some of the projection fibres, and also some of the pyramidal cells show enlargement; but apart from this, neither the fibre arrangement nor the cell lamination presents any striking peculiarity.

Extrarhinic Cortex.

The strip of cortex running along the lower margin of the hemisphere, immediately outside the fissura rhinica, shows features akin to those observed in Felis.

Lobus Pyriformis.

The territorial subdivision of the lobus pyriformis shown in the diagram has been effected on the same grounds as in Felis.

Sus Communis.

General Observations.

The absence of a sulcus cruciatus and other peculiarities in the external morphology of the pig's cerebrum add to the interest of its microscopic examination, but increase our difficulties in orientating the various areas representing those seen in the brains of other animals.

In addition to its distinctive external configuration, unnecessary for me to describe, as it has been fully dealt with by others, the pig's brain exhibits several microscopic features unlike any observed in the brains of Felis and Canis; to these I shall briefly allude before offering details of my examination.

In the first place, the layer of small pyramidal cells exhibits a curious departure from the condition we are familiar with in the brains of man and many other animals; it appears as a prominent layer, visible under a very low power of the microscope, composed of deeply-stained and rather large polymorphous (fusiform, triangular, quadrilateral, stellate) elements, with short processes pointing in no particular direction. Cells to which they can be compared are those occupying the prominent second layer in the lobus pyriformis of most mammals; it must be understood, however, that, in Sus, this formation is not confined to any special part, but has a universal distribution.

Secondly, in describing the motor area, I shall have to mention that no real "giant" cells of Betz exist.

Another peculiarity is the prevalence of cells in all parts of the cortex, which are rounded or oval in form, processless, and faintly stained. Whether these are to be regarded as undeveloped elements, or as cells of a low type, it is difficult to say, but I may mention that as the pig from which this brain came was twelve months old and almost fully grown it is not likely that they are undeveloped cells.

In the next place, I have noted outlying cells in the white substance beneath the cortex in practically every convolution.

Lastly, in the visual area, extraordinary superficially-placed bands of fibres, unlike anything I have seen in the brain of Homo or any other animal, will call for special remark.

Motor Area.

With no sulcus cruciatus to serve as an anatomical finger-post, and no typical "giant" cells for a microscopic guide, I naturally have some misgivings about the correctness of my designation of this field. But the area marked "motor" in the figures, bounded internally by the so-called "coronal" sulcus, and externally by a cross-shaped presylvian sulcus, is coated by the nearest approach to the motor cortex of other animals, and, in order that judgment may be passed on this conclusion, I will give the structural characters at length.

Cell Lamination.

The plexiform layer may be slightly shallower than it is elsewhere and the succeeding stripe of polymorphous cells less prominent.

The third layer is deep and made up of clearly-outlined and sharply-stained medium-sized pyramidal cells.

A stratum containing numerous ill-stained, small, round or oval elements follows.

Then comes the layer showing cells which I believe to be the equivalents of the giant cells of Betz. Although these are relatively much smaller than the Betz cells of Felis and Canis, they are still the largest present in the cerebral cortex of Sus; they are pyramidal or pyriform, they show three or four basal dendrites and a stout apical extension, they contain fine Nissl bodies, they tend to occur in groups of two or three, and the layer they form collectively is not a prominent one.

Below this is another lamina of indefinitely-stained, small, rounded elements, and lastly, a layer of fusiform cells the processes of which do not stain sharply.

Fibre Arrangement.

Although the cell lamination is not entirely what we expect in motor cortex the fibre arrangement favours what we know of the localisation of this function. It is exactly like what has been described in Felis and Canis.

Visual Area.

The visual area of the pig is distributed in the usual way over the upper segment of the occipital lobe. On the mesial surface, the conjoint calcarine and intercalary sulci form a long boundary, and looking in the frontal direction, it is interesting to notice that the area is directed on to the convexity by the intercalary offshoot proceeding to join the "suprasylvian" fissure; inferiorly, visual cortex shuns the rhinic and postrhinic fissures. Sweeping out on to the convex surface, the area disregards the isolated, so-called "lateral" sulcus, and assumes the same relation to the so-called "suprasylvian" sulcus, that it has to the lateral in the case of Canis and Felis—an important variation in distribution calling for comment later.

Concerning the histological characters by which this cortex is recognised, one feature of particular interest, and one by which the area can be mapped out alone, is the extraordinary linear formation to be seen in nerve fibre sections, to which I referred in my opening remarks. This is represented in the accompanying microphotographs, and although I personally have seen nothing like it in the human brain, it may be indicated by calling it a very much modified line of Kaes (*vide* figure 3, in a recent paper by that author, *Neurol. Centralbl.*, 1904). Studied in a fair transverse section of a gyrus the formation lies about a third of the way down between the surface and the line of Gennari; it thus differs from the line of Bechterew which is placed near the surface close below the zonal layer, it appears as a compact fasciculus made up of a dozen or more commingled fine medullated and coarse varicose fibres, and is alike at all parts of the gyrus, crown, lips, and sulcal walls. It is remarkable that the line appears interrupted, and this calls for explanation. Clearly we cannot regard the formation as a stratum or layer in the strict sense of the term, for if it were such the line would not be broken on transverse section; to an understanding of the structure it is necessary to imagine what a section made parallel to the surface might display. Now although I have not prepared such sections, yet, judging from what I have seen in portions of cortex cut obliquely, I think we should find a series of separate fasciculi running parallel to one another, not in straight lines, but sinuously, hence the apparent interruption, investing the gyri somewhat like hoops round a barrel. The connections of these fasciculi for the present remain obscure, nor would I hazard an opinion on the function they subserve; I will only repeat that they traverse the visual cortex in its whole extent and that they are most readily studied in the sulcus lateralis? (suprasplenialis).

In other respects the fibre arrangement resembles that found in the other animals examined. There is a distinct line of Gennari, but it is rather a thin one, and not nearly so marked as in man or the ape; it also lies closer to the white substance, separated by a zone containing the usual large, obliquely-placed optic fibres.

The cell lamination does not show any departure from the common formation. Pyramidal or pyriform, pale-stained, but large solitary cells of Meynert are present in the depths. There is an equivalent of the stellate layer, and above this a layer of medium-sized, erect, and well-defined pyramidal cells.

Search for something special in the cell lamination to fit in with the curious line I have described proves fruitless.

Sensory Area.

If the so-called "suprasylvian" sulcus be followed from behind forwards, it will be seen to fork anteriorly; the area partially enclosed by these two frontal limbs, crosshatched in the diagrams, is covered by cortex which I look upon as representing the "sensory" cortex of other animals. The peculiar fibre arrangement constitutes my chief ground for this assumption; it is quite different from that of surrounding parts, and, in particular, it is distinguishable from that obtaining in the motor cortex, in presenting a far greater wealth of gross fibres running in all directions, an arrangement

characterising sensory cortex in other animals. Furthermore, there is an absence of those large cells which we saw in the motor area.

Parietal Area.

The area I have now to describe possesses such distinctive cortex that it is defined with the greatest readiness; it is not so easy to determine, however, to what part it corresponds in other animals.

It is the field placed mesial to the motor area, confined to the marginal gyrus, and shown by short horizontal lines in the diagrams.

By its cell lamination the area is most readily mapped out; I shall, therefore, describe this first. Following on an uninteresting plexiform layer is a layer of polymorphs, more prominent than in the surrounding fields. Then follows a deep layer of medium-sized pyramidal cells, of which the individual members are neither numerous, nor well-stained, and this layer leads without break or interval into a stratum of large pyramidal cells calling for special consideration. These cells, although not nearly equal in diameter to the "motor" cells, must still be classed as of large size, they have the form of elongated pears, a dozen or more can be found in a single low power field, they stand erect and in line, and being distinctly chromophilous (it is not so with the "motor" cells) they constitute the most prominent feature in the section, and afford a ready guide to the definition of the area. This layer is directly followed by one containing well-stained fusiform cells.

Now when I first saw the cells to which I have just made special reference, and took note of the part over which they are distributed, I imagined I had located the motor area, but an examination of the sections stained for nerve fibres at once dispelled this idea. For in such specimens the cortex appeared quite pallid, betraying a degree of fibre poverty inconsistent with motor cortex. Then, under a high power, I found that the radiations were long and attenuated, and contained only a few fibres of medium size, and that the interradiary plexus was very deficient in density; in short, it presented an arrangement like that in the area labelled "parietal" in Canis and Felis, and as in these animals, large, deep-seated, chromophilous elements are the principal cell representatives of the area, one is forced to believe that the chromophilous cells, distinguishing the same area in Sus, are the homologues of these, but for some reason better developed.

Limbic Area.

The limbic area presents no difficulties, but, in Sus, the pregenual and postsplenial variations cover a greater extent of the limbic gyrus; especially does this apply to the posterior field.

As in the brains of other animals, the cortex is weakly supplied with nerve fibres, there is a total absence of those of large calibre, and similarly, the cells are all of small size. The field investing the genu is only interesting in accommodating a well-marked, deep layer of small chromophilous lanceolate cells, very like those to be found in the same area in Homo; and, in regard to the postsplenial area, care must be exercised not to confound it with the visual, for in sections stained for nerve fibres, a linear arrangement occurs, which a superficial observer might mistake for a line of Gennari.

Ectosylvian Region.

Just behind the long Sylvian fissure, a considerable collection of large fibres is seen in the depths of the cortex, and the cell lamination is slightly different from that of the neighbouring parts, so that it probably represents the Ectosylvian Area A of Canis and Felis, but it obviously deviates in respect to its small extent. One point of special interest, to be commented upon later, is that the area stops short of the "sulcus ectosylvius," and another is that similar cortex is found concealed in the upper half of the well-developed "Sylvian" fissure.

The cortex marked Ectosylvian B is of another type; it is possessed of a fair fibre-wealth, but contains no elements of large size. Its cells are divisible into the standard seven laminae, and layers of moderately large external and internal pyramidal cells are discernible.

Frontal Cortex.

The area marked frontal does not exhibit any special features, and it is not easy to find the boundary between it and the other areas, save the motor, with which it comes in contact.

Lobus Pyriformis.

In the lobus pyriformis I have mapped out that cortex covered by a lamina medullaris externa, and the layer of large polymorphous elements we are familiar with from our study of the brains of other animals.

PART II.

A CONSIDERATION OF THE FUNCTIONS AND HOMOLOGIES OF THE AREAS HEREIN DESCRIBED.

Motor or Crucial Cortex.

In discussing the area designated crucial or motor, two important points stand out for consideration; one turns on experimental physiology and the question whether this field is the functional equivalent of the motor area, as defined by Professors Sherrington and Grünbaum in the anthropoid ape, and by myself in the human being; the other pertains to comparative anatomy, and concerns the fissural and gyral homologies of the cruciate region. These points will be dealt with in turn.

Looking back on the observations of those pioneers in experimental physiology who employed common members of the carnivore family in ascertaining the results of cerebral excitation, we notice, at once, that the cortex they found responsive, belongs to what we may call the cruciate zone; and, needless to add, the discovery of the excitability of this particular cortex was the preliminary step in the acquirement of our present fund of information concerning the motor area. At a later date, the recognition of "giant cells" in the same part brought confirmation, perhaps inadequately acknowledged and appreciated, to the physiological results. But in precision of topographical localisation, I venture to say, these combined results have been left incomplete. In particular, doubt is cast on the correctness of the earlier physiological experiments by the recent researches of Professors Sherrington and Grünbaum, which show that the motor area is less extensive than was previously thought, an amendment we must attribute to the employment of improved methods of excitation. In substantiation of Professors Sherrington and Grünbaum's results I have examined the brains of some of the animals (anthropoid apes) they had previously experimented upon, and I have demonstrated that the excitable cortex is endowed with so many distinctive structural qualities that its extent is as easily defined on the histologist's bench as on the operating-table. Further, I have offered strong reasons for assuming that a similar condition of affairs obtains in the human brain; more, the present research makes it almost certain that the same applies to many lower animals. I submit therefore, that the area I have described, and marked "motor" in the accompanying diagrams, the area which, at any rate, in the case of Felis and Canis possesses "giant" cells homologous to the cells of Betz, as well as a "motor" arrange-

ment of nerve fibres, represents the exact extent of a field functionally analogous as well as structurally homologous to the primate "precentral" or "motor" area.

On the finer differentiation of this area into segmental fields, corresponding with the various groups of muscles, I am not prepared to write, because I feel that the intraterritorial structural variations are insufficiently pronounced to make a statement from the student of normal histology of any value. I am sure, however, that just as an examination of the Betz cells for "réaction à distance," in cases of amputation, proved of great service to me in subdividing the area in the human brain, so experimental study on similar lines, should anybody care to undertake it, will tell us more about the area in the lower animal. Yet, even as it is, we have a sufficiency of experimental evidence to justify the belief that, from within outwards, the sequence of representation follows the same order as in primates, namely, lower extremity, trunk, upper extremity, etc.

Since the Betz cells suddenly diminish in number on the inner wall of the sulcus coronalis, and almost stop at the floor, one cannot help looking upon this fissure as a boundary to the upper extremity and neck areas; but, as movements of the tongue, face, etc., have been so constantly obtained from sub- and post-coronal cortex, it is imaginable that the isolated large cells hereabouts may govern such movements. And yet this is a question of some difficulty, for in the ape and man, the structural peculiarities of the area said to dominate the same movements are not nearly so distinctive as those of the fields governing movements of the extremities.

We can now pass to the homologies of this region, and since in primates, the great central fissure of Rolando bears such important relations to the motor area, we will first attack the vexed problem of the representation of this fissure in lower mammals. Now from a very intimate acquaintance with the microscopic appearances of the Rolandic cortex, I am satisfied that the fullest reliance can be placed on histology as an aid to the determination of the homology in question, and although the pig, with its bizarre arrangement of sulci, gyri, and cortical constituents, presents difficulties, I am convinced that, in the dog and cat, I have found the homologue of, at any rate, the upper half of the Rolandic fissure; and this is not, as is generally maintained, the sulcus cruciatus, but an isolated, shallow, insignificant-looking fissuret, placed between the cruciate and ansate sulci, indenting the posterior limb of the gyrus sigmoideus not far from its middle, and known as the "compensatory ansate" (in the diagrams it is marked "homologue of Rolando"). In the dog, the fissuret is obliquely placed, running from behind forwards and inwards, and is better developed than in the cat. In the latter animal, the indentation runs more nearly parallel to the sulcus cruciatus, and from a special examination of a number of brains, I have ascertained that it may be represented in one hemisphere and not in the other; I have also noticed, in those cases in which the formation does not appear as a fissure, that a slight dimple invariably indicates the point where it should be. As to reasons for regarding this sulcus as the representative of the fissure of Rolando, or a part thereof; in describing the histology of the human and anthropoid cortex, I pointed out that the structure of the precentral cortex was totally dissimilar from that of the postcentral, so unlike, that in itself it suggested a difference in function between the two gyri, and I also showed that the floor of the fissure of Rolando formed the dividing line between these two types. Brodmann's independent study of the cell lamination of the same gyri in man has produced a like declaration. And now, in the dog and cat, to see the Betz cells ceasing, and the fibre arrangement undergoing a change, the moment the fissuret under consideration is reached—it is beautifully demonstrated in sections cutting the fissure at right angles—is not only a most interesting and instructive histological revelation, but so strongly reminiscent of what one has seen in man and the ape, that one is forced to offer it as proof, and as convincing proof, of the correctness of the thesis here submitted.

We have next to enquire whether the fissuret, just described, is the homologue of the whole, or of a part only of the fissure of Rolando. I believe the latter to be the case. We know that, on developmental, and I may say, also on physiological grounds, the Rolandic sulcus is divisible into two portions, an upper and a lower, that the division is marked by the superior annectant gyrus or buttress, and that the gyrus sometimes remains on the surface and makes the separation morphologically complete in extrauterine life. And as what I take to be typical motor cortex ceases on reaching the floor of the coronal fissure, and as also the results of experiment favour the assumption, I would join forces with those who look upon the coronal fissure as the antecedent of the lower portion of the fissure of Rolando.

Supposing then that we are construing matters aright, we get a reproduction in phylogeny, of an ontogenetic condition in the immature primate brain, namely, a separation of the great central fissure into two discrete portions; and, summarising the homology, the "compensatory ansate fissure" of Carnivorae[1] becomes the upper Rolandic segment of man, and the coronal fissure the lower segment, while the intervening substance is moulded into the superior annectant gyrus or buttress.

It still remains for me to state reasons for refusing to believe that the sulcus cruciatus is the forerunner of the fissure of Rolando. My strongest objection is again founded on histology. We have gathered from our study of the human brain that the fields governing those functions we have hitherto succeeded in locating, are all deposited in direct relation to some important sulcus, which in one direction, at any rate, forms a sharp and perfect boundary; thus, the olfactory area is restricted in its spread by the fissura rhinica; the "stem," which we may consider the fundamental component of the calcarine fissure, prevents the expansion of visual cortex on to the postlimbic gyrus; the auditory area is closely related to a portion of the Sylvian fissure; and, lastly, there are strong grounds for assuming that the fissure of Rolando acts as a dividing line between motor and sensory cortex. Obviously, in the case of all these limits, two totally different types of cortex are found on the apposed walls of the fissure. And so far as my study of the lower animal brain has gone, I see no cause for doubting the occurrence of a repetition of this association between external morphology and functional distribution. But, when we proceed to apply our experience to the sulcus now holding our attention, the sulcus cruciatus, we soon find in regard to its covering of grey matter, that it differs entirely from the fissure of Rolando, inasmuch as both walls, instead of only one, are coated by motor cortex; in brief, it has none of the characters of a dividing line.

Discarding then the Rolandic fissure as the homologue of the cruciate, we have now to examine the human brain and differentiate the remains of the latter fissure. For my own part I believe that a remnant exists: indeed, considering the prominence of the sulcus in the lower animal brain it would be remarkable if it did not. The fissure I have in view is to be sought on the oval or paracentral lobule, it is placed immediately below and on the frontal side of the upper extremity of the fissure of Rolando, or of a line drawn on in continuation with that extremity; it is so small that it is perhaps better described as a fissuret, and, it is not to be confounded with the anterior boundary of the paracentral lobule, namely, the preoval or paracentral fissure, nor with the inconstant sulcus precentralis marginalis. From an inspection of the large collection of brains and casts in our museum at Rainhill, I am satisfied of its stability, but, as is the case with every other fissural element, its appearance is rarely the same in any two specimens; in its commonest form it is an isolated, vertical, or oblique furrow, but occasionally it lies hori-

[1] I have not been afforded an opportunity of examining a series of brains to determine the constancy of this fissuret in other animals, but in the very instructive figures reproduced in the Catalogue of the Royal College of Surgeons Museum, a corresponding indentation is illustrated in the brains of Ursidae, Otariidae, Mustelidae, and other Carnivores.

zontally, and not infrequently, instead of being isolated, it is joined to the calloso-marginal fissure; at times it is triradiate, or it may be represented by a dimple only, but, in any case, the truth remains that it is never absent. In the anthropoid specimens I have examined (chimpanzee and orang), a corresponding furrow has also been recognised.

But while the morphological relations of the fissure just described are in harmony with the suggested homology, it is the microscopic structure of the investing cortex, which, to my mind, almost places the matter beyond doubt. For just as in the lower animals, the deposit of giant cells clings to the sulcus cruciatus, so it is with this fissuret; in mapping out the distribution of the motor area, I have, in all, examined the paracentral lobule in serial sections quite a dozen times in man, and three times in the anthropoid ape, and I have invariably detected clusters of giant cells in the walls of the fissuret, not all along it perhaps, but always in its upper part; indeed, so constant is the relation, that this incisure, insignificant though it may appear, can always be taken as a guide to the distribution of the giant cells on the mesial surface of the hemisphere; when the lower margin of the giant cell area is depressed, the fissure falls with it, and reversely.

Visual Area.

There is no cerebral area possessing a greater interest for the student of homologies than the occipital lobe. Indeed, so numerous are the publications contributing to our knowledge of the calcarine and parieto-occipital fissures, the "Affenspalte" and the sulcus splenialis, in short, the system of fissures traversing or bounding the occipital lobe, in both primate and lower vertebrate, that not without strong feelings of diffidence I approach this undoubtedly thorny field. And yet, the very warmth of the discussions which have taken place, and are even now proceeding, makes it evident that much still remains to be placed outside the pale of controversy, and since I am breaking new ground, in advancing a thorough histological examination of the grey covering of the brain, over and above naked-eye inspection, as a basis of judgment, my compunction in publishing the ideas set forth in the following paragraphs is relieved.

It is fortunate that the visual cortex[1], throughout the whole series of brains coming under my inspection, from the quadruped upwards, offers so many histological points of resemblance and a general structure so distinctive from that of surrounding parts, that its area of location can be defined with absolute exactitude, for this allows me to open with the asset that my map of the distribution of this cortex is correct. Touching this asset, in my opinion, it is one the value of which cannot be overestimated, it has already proved of signal service in the motor region, it will be found equally useful in others: in fact, I am convinced that if on our naked-eye series of cerebral plans, we could only superimpose another, giving the results of histological examination, this as a preliminary to the final localisation of functional attributes by the physiologist and workers in other departments, all existing doubt concerning various homologies would be summarily removed.

In discussing homologies associated with the visual area, interest focuses on the calcarine fissure. In Homo, this fissure is usually described as being made up of three constituents, (1) an anterior, deep, fundamental portion, also known as the "stem" or "true calcarine" fissure; (2) a shallower and shorter posterior limb, the fissura calcarina posterior; and (3) a terminal cross-piece placed on the occipital pole, the fissura extrema of Seitz. We will consider each of these in turn, and begin with the "true calcarine" fissure, one which the comparative anatomist informs us is the most primitive and widely-spread neopallial sulcus in the mammalian brain. And here let me make

[1] Since the particular cortex here referred to corresponds in point of structure with that which I have called "visuo-sensory" in Homo, it might be given that designation; or, since it harbours the line of Gennari, there is no objection to naming it, as others do, the "area striata."

the preliminary statement that I accept Dr Elliot Smith's definition of the same fissure, as seen in the brains of lower animals, and by the "true calcarine" fissure understand the sulcus which limits the area striata anteriorly (sulcus "praestriatus"), and which corresponds to or produces the calcar avis[1]. In the brains of the animals I have examined, the interesting observations have been made that this fissure forms a constant limit to the spread of the visual area, that the downward or caudal extent of the area is coterminous with the lower extremity of the fissure and, further, that one wall only, the posterior, peripheral or outer, is coated by visual cortex. Proceeding forwards, I have next noticed that the boundary on the mesial surface of the hemisphere is completed by the intercalary fissure, in fact, this forms as definite a limit as does the calcarine.

The truth that the combined calcarine and intercalary sulci form a continuous limit, and that individually considered both constituents of the complex have a similar relation to the visual area, is one of great significance in throwing light on the subsequent history of these fissures. First, as to the "true calcarine" fissure, the collateral histological study of its investing cortex in lower mammals and in Anthropoidea supplies further proof of the contention, first suggested to us by its anatomical relation to the calcar avis, that this portion of the complex becomes the "stem" of the calcarine fissure in Homo. The histological proof is this: in man, as Bolton first showed, and in the man-like ape as I have indicated and as Elliot Smith has since emphasised, the "stem" of the calcarine fissure, like the "true calcarine" fissure of lower animals, is only covered by visual cortex on that wall furthest removed from the splenium; the inner wall forms part of the limbic area.

With this point settled, we have next to determine what happens to the intercalary fissure. According to Elliot Smith, as a result of the prolongation of the hemisphere, the calcarine fissure becomes widely separated from the intercalary and the latter eventuates in the calloso-marginal. But this is an interpretation of events to which histology not only gives no support, but is directly antagonistic. Obviously the great stumblingblock to the suggestion is the truth that in Carnivorae and Suidae, animals in which the intercalary sulcus is well represented, this sulcus stands in close relation to visual cortex, whereas in the brains of those members of the simian family which I have examined, as in man, even the tail of the calloso-marginal fissure, is widely removed from the visual area. If then the intercalary sulcus becomes the calloso-marginal, we must necessarily regard the remarkable relation between the former and the visual area, in lower orders, as a purely fortuitous circumstance, but lessons taught us by similar relations between sulci and functional areas in other regions render this impossible.

A final solution of the difficulty may not be arrived at until the brains of intermediate orders are examined, but, for the present, I prefer to believe that the calloso-marginal fissure is formed at the expense of some other sulcus, probably the genual; that the vertical clefts resulting from the occipital prolongation of the hemisphere, represented by the parieto-occipital fissure and "Affenspalte," occur on the frontal side of the visual area, and of all the fissures to which it is related; and that, in this process, the intercalary sulcus, instead of increasing in length and importance, becomes attenuated, and, finally, in Homo, is swallowed up in the lower extremity of the parieto-occipital fissure and either wholly lost or but feebly preserved as the lower boundary of the submerged gyrus intercuneatus.

[1] In Sus, Felis, Canis, and many other animals, a long and continuous fissure indents the mesial surface of the brain, above and behind the splenium corporis callosi; Elliot Smith speaks of this as the "calcarine complex"; in the hinder portion he sees the "true calcarine" fissure, and for the anterior portion he has coined the term "intercalary." In many German monographs the same complex is called the "sulcus splenialis" and the word "calcarine" does not appear.

We have now to consider that backward extension of the calcarine fissure known as the posterior calcarine (Cunningham) and by Elliot Smith burdened with the name sulcus occipitalis intrastriatus mesialis. As others have indicated, it is a fissural unit of minor morphological importance, and unstable. In Man and in the Anthropoid Ape both its walls and the free surface of the bounding gyri are covered by visual cortex, and it is the rule for the fissure to be fused with the "stem." Its homologue lower down the animal scale seems to be, as Elliot Smith tells us, a small isolated fissure which has received the same name and is seen to advantage in certain Carnivore and Ungulate brains. In Canis the sulcus is plainly seen and undoubtedly lies surrounded by visual cortex, so fulfilling one postulate. Next it appears that when in course of cerebral expansion the complex assumes a horizontal position, this previously isolated element fuses with the hinder extremity of the "true calcarine," that is, with the end formerly uppermost. *Per contra*, even if we are at fault in supposing that the posterior calcarine fissure of the lower orders acquires permanence in this manner, it is easy to believe, as an alternative, that the "true calcarine" sends a branch backwards to develop into the posterior calcarine (*hominis*), because in many of the lower mammalian brains exhibiting the calcarine-intercalary combination one notices a distinct backward offshoot, a tendency to bifurcate, at the point where the two main constituents unite.

It remains for us to determine the homologue of the third and last constituent of the calcarine complex of Homo, the fissura extrema of Seitz, a short vertical fissure running behind and at right angles to the posterior calcarine, to which though at times isolated it is usually joined, a fissure the walls of which are invariably covered by visual cortex, and one which forms an absolutely reliable anatomical guide to the posterior boundary of the primary sight area. In an earlier chapter (p. 121) I maintained that in the Anthropoid, as the result of altered mechanical conditions, this constituent finds itself dislocated outwards to become the Simian external calcarine fissure, or sulcus intrastriatus lateralis (Elliot Smith); to this homology I still adhere, and I need not repeat my reasons. But what the homologue is in lower animals is more difficult to decide. A clue is offered by the subsequent history of an outside fissure, the lateral. Elliot Smith, whose unequalled experience in the comparative anatomy of the brain entitles his opinion to profound respect, maintains that the lateral sulcus is converted into the intraparietal sulcus of Man; and if I read his meaning correctly, in further detail, the lateral sulcus proper and the postlateral sulcus—as seen in Felis and Canis—are respectively interchangeable with the ramus horizontalis and the ramus occipitalis transversus of the intraparietal fissure of Homo. Accepting these homologies as true, it follows that the antecedent of the fissura extrema vel calcarina externa, if present, must lie somewhere between the lateral and "true calcarine" fissures, but on searching the brains of Felis and Canis for a fissure in this situation, with an undetermined homology, the only one we can find is that recognised by the name marginal or suprasplenial, and the question is, will this fulfil our requisition? I believe it will. The fissure is a well-defined one in the two animals just mentioned; it seems to be represented with a considerable degree of constancy in other natural orders; it is situated in the midst of cortex having visual characters; and although in Carnivorae, etc., it lies towards the upper margin of the hemisphere, it is still placed, as in Homo, more or less at right angles to the "true calcarine" fissure, a relation we would expect it to maintain as the occipital lobe tilted backwards. On these grounds, therefore, I submit that the sulcus suprasplenialis and the fissura extrema of Seitz are homologous.

Here attention must be directed to the arrangement of the sulci and the disposition of the cortex in Sus. In figures of this animal's brain which I have seen one is led to suppose that there is no suprasplenial sulcus, but on the other hand a well-defined lateral sulcus is indicated, placed, however, remarkably close to the margin of the hemisphere, and, moreover, isolated. Now, on referring to my drawings of the visual area in the pig, it will be seen that

this so-called "lateral" sulcus, instead of forming a rough outer boundary to the area, as it does in Felis and Canis, lies wholly within the field. For this reason I cannot help thinking that it is the direct homologue of the marginal or suprasplenial fissure in other animals, and that to label it lateral is an error.

So far as I can judge, the study of the occipital lobe in these animals provides no direct information on the genesis of the "Affenspalte."

I feel that little is to be gained by comparing the histological results bearing on the cortical localisation of the visual function with those obtained by the experimenter. Invaluable service was rendered by the physiologist when he indicated that sight was centred in the occipital lobe, but his methods were necessarily crude—I refer particularly to ablations—and now that we have such strong proof that the cortex, to which visual impulses stream, is possessed of a distinctive structure, I am sure the advantage held by the microscope over the scalpel, as a discriminating agent, will be allowed. Only one point calls for comment. In the brain of Homo and the higher ape I have mapped out an area investing the visuo-sensory field, or area striata, to which I have given the designation visuo-psychic, in the belief that it is intended for the further elaboration of impulses primarily received in the first-named area. But, distinctive as the structure of this cortex is in Primates, it is a remarkable truth that a corresponding area baffles definition in the lower animals; only in Canis, and then along the very outskirts of the area striata, have I seen a structural arrangement reminding me of such cortex[1].

It appears therefore that this cortex is almost entirely a neopallic formation.

Lobus Pyriformis.

Hippocampal region.

The changes undergone by the lobus pyriformis, in its passage from the macrosmatic to the microsmatic condition, have been so thoughtfully and accurately studied by comparative anatomists that my histological examination of the part, complete as it has been, only yields a confirmatory repetition of previously published results. With the elongation and attenuation of the olfactory peduncle, the deepening of the sulcus olfactorius, the flattening and reduction in size of the tuberculum olfactorium, the disappearance of the anterior limb of the rhinal fissure, the bending of the pyriform lobe to produce the vallecula Sylvii, the diminution in relative bulk of the caudal portion of the pyriform lobe, we are familiar, as well as satisfied that all these events have been given a correct interpretation. And although I have been successful in identifying the various types of cortex previously seen and studied in the human brain, and have added something to our knowledge, by showing their exact distribution in some macrosmatic brains, the result unfortunately does not bring us any nearer understanding the true physiological significance of these remarkable territorial variations in structure[2].

Limbic Cortex.

As with the lobus pyriformis, so with the gyrus fornicatus, the facts point to its being invested by cortex of great phylogenic age. It seems to have an advantage over the lobus pyriformis, inasmuch as it has maintained a better pitch of morphological representation through the different cycles of brain growth.

[1] It is of some interest to note that the circle of cortex, destruction of which gave rise to "psychical blindness" (Seelenblindheit) in the dogs operated upon by Munk, takes in the outskirts of the area striata.

[2] The types of cortex to which I drew attention were, (1) that on the lobus pyriformis, (2) that covering the wall of the fissura hippocampi, (3) that seen in the gyrus dentatus, and (4) the rudimentary cortex on the tuberculum olfactorium.

A full histological examination has revealed several points of more than passing interest. Thus it is important to have again recognised in all these lower animals that strip of cortex immediately investing the genu corporis callosi (Limbic A), possessed of special structural features, to wit, the deep layer of peculiar chromophilous cells, so strongly reminiscent of what one saw in the brain of man. We likewise again meet with the second variation, that in the postsplenial region (Limbic B). In regard to both these sub-areas, I think it correct to say that the cortical constituents present a better aspect of development in the lower animal than in Homo, and, further, there seems to be no doubt that they are better represented in Sus than in either Canis or Felis.

In the foregoing work I inclined to the belief that there was more truth than is generally supposed, in the suggestion credited to Broca, that the gyrus fornicatus may play some *rôle* in association with the olfactory sense, and going more into detail, I gave it as my opinion that, at any rate, the pregenual strip of cortex probably stood in direct connection with the inner olfactory root. I think it will now be conceded, that to have proved the better development of the same cortex in the macrosmatic brain is a point in favour of this belief.

In reference to the remaining limbic cortex, as in Homo, it is readily recognised by its relative poverty in nerve fibres and its correspondingly weak nerve cell representation, features which lead to its easy differentiation from neighbouring areas.

On the homologies of fissures traversing or bounding the limbic area there is little to write. When discussing the intercalary sulcus I ventured the opinion that it was a fissure which had undergone retrograde changes in the course of cerebral growth, and I opposed Dr Elliot Smith's statement, that it develops into the calloso-marginal. The genual fissure, rudimentary and inconstant as it is in the brains of lower animals, is the one, as I have said, which I believe to be the antecedent of the calloso-marginal; while as regards the remaining sulcus on the mesial surface, the rostral, it may either continue as such, or become the anterior portion of the calloso-marginal, the so-called prelimbic sulcus.

In the brain of Sus a small and very shallow sulcus may be observed, limiting the sub-area of cortex marked Limbic A in the diagram; this is known as the sub-limbic sulcus of Guldberg, or the sub-singular arc, it seems to be specially characteristic of the Ungulate group, and in some families forms a complete arc. The sulcus is not well seen in Carnivores, and it is doubtful whether its remains can be identified in Homo.

Finally, as the striae longitudinales mediales are not very much larger in these animals than in Man, it is plain that they must have had their supposed existence as gyri very far back in the phylogenetic scale.

Postcrucial or Sensory Area.

As an addition to the histological homologies already detailed, I have now to mention some results gained from a study of secondary degeneration, which, to my mind, further strengthen the contention that the area, which I have called "Postcrucial or Sensory," is the equivalent of the "Postcentral or Sensory" area in Primates. The results to which I refer were obtained by Tschermak, from experiments on cats. The research consisted of tracing, by the method of Marchi, the secondary degeneration following destruction of the nuclei gracilis et cuneatus, at the lower end of the medulla. Since, for us, the chief interest in Tschermak's work centres on the fact that he succeeded—where others failed—in following degenerated fibres right up to the cortex cerebri, we can pass over his detailed and thorough account of the degeneration seen at lower levels, and confine ourselves to the cerebral findings. He states that a number of diseased fibres enter the corona radiata, principally *viâ* the internal capsule, and, streaming outwards, impinge mainly on the cortex of the gyrus coronalis and adjacent parts of the gyrus ectosylvius (pars anterior),

and, to a lesser extent, on the contiguous gyrus marginalis. Now, although Tschermak's figure of the surface distribution of this degeneration is diagrammatic, and also wanting in detail (for instance, he does not indicate the compensatory ansate depression), yet anyone on comparing his plan with mine will be struck by the general resemblance; thus, in the lower two-thirds of the field (that which Tschermak has cross-hatched, and a part in which I find the structure most typical) we agree absolutely; only in regard to the upper extent (Tschermak indicates it by vertical lines) do we differ, Tschermak making his field cover more of the marginal gyrus than I do mine. Lastly, Tschermak is emphatic in declaring that no diseased fibres proceed, either to the gyrus fornicatus, or to the gyrus sigmoideus.

The correlation of evidence brought out by these totally different and independent methods of research is so remarkable, that even by the greatest sceptic it cannot be regarded as fortuitous. My reasons for believing that, in Man and the man-like ape, the postcentral gyrus is an end-station for impressions of common sensation, have been set forth at length already, but I may here repeat that one of my grounds for that assumption was the widely different nature of the cortex covering the same gyrus. Summed up, therefore, the position is as follows: utilising one's knowledge of the histology of the Primate cortex, one has found that an area, bearing similar architectural characters, can be mapped out in the brains of three members of different lower animal families; not only so, the area, in the case of the cat, agrees very closely with the field to which Tschermak traced secondary degeneration, after experimental interruption of the sensory tract in the same animal.

The evidence on this point would be perfect were it not that a discordant note is struck by the embryologist. From what we know of the sequence of maturation of different groups, or tracts, of medullated nerve fibres, we would expect that those pertaining to this particular area, being sensory, would show their myelin at an earlier date than those of surrounding parts, especially than those of the motor area, and yet the researches of Professor and Madame Vogt, on the brain of the puppy and kitten, give meagre support to our anticipation. They only tell us that the earliest and richest myelinisation occurs in the gyrus coronalis and in the postcrucial gyrus, while the anterior cruciate limb, the oral part of the gyrus marginalis and the remaining components of their "regio precox anterior" do not show so many fibres at the same period. I also observe, in Döllken's maturation table, that although the cortex of the gyrus coronalis is placed first, it is bracketed with the crucial cortex.

This discrepancy in the evidence is of course worthy of serious consideration, but it does not as yet overthrow our view. Those of us who have undertaken the task of following variations in structure from section to section, in successive series, are mindful of the extreme caution we had to exercise in the avoidance of error, and this was particularly the case when we had to deal with a field of cortex about which preconceived ideas had taken firm root, such as that surrounding the fissure of Rolando or its homologue; and I may remind the reader that the particular area in the cat we are discussing did not definitely reveal itself to me until I had cross-examined sections stained for nerve cells. Therefore I think it possible, that if the embryologists named will reexamine their sections in the light of what has been set forth in more recent publications they may be induced to alter their cerebral maps.

Apart from this, it appears that the rules governing maturation of nerve fibres do not apply so rigidly to those resident in the cortex as in the spinal cord; or, perhaps it is more correct to say, that the sequential variations in myelinisation of different tracts of fibres, in particular the variation between motor and sensory developments, are more difficult to determine by cortical than by spinal examination. For instance, we know that in the spinal cord of the newly-born cat and dog the sensory tracts are already developed while the myelinisation of the motor tracts is still imperfect, and yet the Vogts and Döllken all tell us that not a single medullated fibre of

any description is to be seen throughout the cortex of either of these animals until about the eighth day of life. Further, in the human body, the fibres of the pyramidal tract, in its spinal course, do not acquire their sheath of medulla until long after the posterior column fibres, and one would have thought that this sequence of events would have enabled Flechsig and the Vogts to distinguish readily between sensory and motor fibres in the developing human cortex. This, apparently, was not the case. The probable key to the difficulty is to be found in the assumption, that the process of medullation in any given fibre does not arise simultaneously along its whole length, but begins at the end next the cell giving origin to it, and from there spreads onwards —(I understand that this is an accepted belief)—and so, on inspecting cortex from the Rolandic region in Man, or the cruciate zone in lower animals, the embryologist might confuse the first segment of a motor fibre, beginning to myelinate, with the terminal of a sensory fibre, just being completed.

We can now turn to the fissural homologies connected with this area. The supposed antecedents of the fissure of Rolando have already been considered under the motor area, but I would here add that Tschermak's investigations make him a firm supporter of Meynert's old-standing contention, that the sulcus coronalis is the homologue of the fissure of Rolando. With this, as already mentioned, I can only agree in part, believing that the sulcus coronalis is the antecedent of the lower segment only of Rolando, and the compensatory fissure—unnoticed by Tschermak—the representative of the upper segment. To Tschermak's contingent assertion, however, that the field behind, the area which forms the subject of this discussion, is homologous with the gyrus centralis posterior hominis, I unreservedly give support.

We have next to find the forerunner of the postcentral fissural system. This is not easy. In the summarised account of his examination of the magnificent collection of brains in the Royal College of Surgeons' Museum, I notice that Dr Elliot Smith credits the ansate fissure with becoming the sulcus postcentralis superior, and it is given as a moot point, whether the sulcus coronalis is the antecedent of the sulcus postcentralis inferior. But from what is written in the foregoing paragraphs, neither does histology allot a place in the formation to the sulcus coronalis, nor do I see the necessity for giving the upper constituent of the fissure preeminence and regarding it as the sole derivative of the ansate sulcus. The question is, without doubt, one of considerable difficulty, and, to my mind, as yet insufficiently studied, but judging from its relation to "sensory" cortex, and its apparently intimate connection with the lateral fissure, I prefer to regard the ansate sulcus mainly as the forerunner of the inferior segment, or possibly of the united system, since, in Man and the higher apes, both constituents are more often than not continuous.

The peculiar arrangement of parts in the brain of Sus calls for special consideration. For if in our attempt to adjust the physiological findings we follow the recognised sulcal nomenclature, we soon find ourselves in inextricable confusion. The first point to be called in question is whether the fissure, accepted by the comparative anatomist as the coronal (marked Coronal ? in my figures), is correctly so named. I think not. Its relation to what I take to be the motor and sensory areas, its dorsal position on the hemisphere, its position in relation to other fissures, notably the intercalary and orbital, might all be used in arguing against such an homology. The pig's is a highly macrosmatic as well as a strong visual brain, it likewise has a bulky gyrus fornicatus, and one consequence of these combined properties is that all those sulci, and the contingent functional areas, on the dorsum and convexity of the hemisphere, have the appearance of being rotated outwards on the sagittal axis. The coronal sulcus, instead of being brought closer to the upper margin of the hemisphere, is further removed. For this and other reasons mentioned, I venture to say that the cross-shaped fissure (marked coronal, with a note of interrogation) in my diagram of the lateral surface of the pig's brain is the true coronal, while in the sulcus of other authors I see one which might be the homologue of the sulcus cruciatus. Of course, I am aware

that in endowing the Ungulate brain with a crucial fissure, I place myself at variance with, at any rate, most comparative anatomists, but, at the same time, I see no other way of explaining these findings.

Parietal Area.

In Primates I have given the name parietal to the field of cortex intercalated between the postcentral or sensory and the visual areas, and I believe that a corresponding area is definable in the brains of lower animals. In the case of Felis, Canis, and Sus it is similarly interposed between the above-mentioned areas, it occupies the middle portion of the marginal gyrus (*vide* diagrams), it comes in contact with limbic cortex on the mesial surface, and in the outward direction tends to spread beyond the sulcus lateralis. In Man similar anatomical relations have been observed and a resemblance of special interest is that the ramus horizontalis of the intraparietal fissure, like the sulcus lateralis, does not form a constant boundary; there is a tendency to overlap.

Considered spatially, there is little doubt that the area in Man is proportionately much greater than in the lower animals; further, it appears that the field is somewhat more extensive in both Felis and Canis than in Sus. The disparity is perhaps best demonstrated by comparing the space intervening between the sensory or, better still, the motor and the visual areas in the different animals. But it must be added that although spatially inferior in Sus the structural components by which the same cortex is recognised are just as well if not better developed than in the Carnivorae.

From the point of view of homology, the distribution of this area is entirely favourable to the commonly accepted deduction that the lateral sulcus of lower orders is the equivalent of the Primate ramus horizontalis of the intraparietal fissure.

Further, in the cerebrum of the pig the distribution favours the suggestion, hinted at in an earlier section, that the fissure usually called suprasylvian (I have labelled it suprasylvian with a note of interrogation in my diagrams), and not that lying in the midst of the visual area, is the true sulcus lateralis. This construction also fits in with what has been written on the homologies of the sulcus coronalis.

The function of the parietal area, even in Homo, is very imperfectly understood, and unfortunately the present research, so far as I can see, does not add to our knowledge of the subject. Let us hope it may be of help in the future.

Ectosylvian Region.

Though the steps in such a metamorphosis are by no means easy to trace, there exist good reasons for upholding, that out of the ectosylvian region of lower mammals is developed the Sylvian region, including the Insula, and much of the temporal lobe of Homo. Before setting down my own histological deductions it will be useful to employ a few words in pointing out the local homologies which have been formulated for us by the comparative anatomist.

We are told that in Man alone the Sylvian fissure is seen in its complete form. In the animals with which I am dealing the fissure called "Sylvius" is so named merely for descriptive convenience; in reality it is but a shallow kink in the hemisphere produced by the downward expansion of pallium placed more posteriorly. The human fissure is evolved from the operculation of the outer walls of three sulci, each having a distinct phylogenic origin. The contributing sulci in the process are the suprasylvian, the so-called "Sylvian," and the Primate fronto-orbital[1];

[1] It must be explained, in reference to the fronto-orbital sulcus, that its equivalent in the lower animal brain, unless it be the sulcus diagonalis of Felidae, is undetermined.

and these are the supposed derivatives of the superior, inferior, and anterior limiting sulci of the Insula, respectively. Lastly, the postsylvian sulcus is looked upon as the aboriginal of the parallel or superior temporal sulcus. Next taking the gyral instead of the fissural homologies, we are given to understand that in the Carnivore brain, for example, virtually the whole of the first, and about the anterior half of the second arcuate gyrus, along with the ectosylvian sulci, become submerged as the Insula; while the anterior wall of the Sylvian fissure is formed from, or at the expense of, parts in front of the anterior limbs of gyri arcuati primus et secundus, the convexity of gyrus arcuatus tertius supplies the upper wall, and the posterior half of gyrus arcuatus secundus provides a nucleus for the growth of the first temporal convolution.

Trusting that this construction of the teachings of the comparative anatomist is correct we will now view the parts in the light of my histological findings. It is satisfactory to be able to open with the statement that no important discrepancies have been revealed. My chief guide to the subsequent history and relation of the parts is the disposition of the area marked by cross-hatching in my diagrams and called Ectosylvian Area A.

Histologically this field is stamped by a peculiar cortical structure, a structure which I have previously recognised in the transverse temporal gyri (Heschl) of the human brain, and one which I associate with the surface impingement of the central auditory tract. Therefore without preamble, which would consist of repetition of my previous writings, let me unburden my belief that this particular field of cortex represents that area which, in Man and the Anthropoid, I have called "audito-sensory." From this, as a basis, important deductions can be drawn. To begin with, it is obvious that the so-called Sylvian fissure of Carnivores, at any rate, is the equivalent of the vallecula only of the human Sylvian fissure; it is equally clear that the gyrus arcuatus primus, along with the ectosylvian sulcal arc, are converted into the transverse temporal gyri, rotating backwards and downwards in the process; the hinder limb of the gyrus arcuatus secundus, and the sulcus postsylvius, are transformed into the gyrus and sulcus temporalis primus, respectively; the remainder of the temporal lobe grows out of the parts interposed between the sulcus postsylvius and the visual area; the anterior limb of the gyrus arcuatus secundus, along with some "extrarhinic" cortex surrounding the so-called Sylvian fissure, contribute to the formation of the Insula proper.

It is thus seen that histology can be strongly urged in support of anatomical doctrines, but before leaving the question I must point out that difficulties—not quite insurmountable—are presented by the arrangement of parts in the brain of the pig. In this animal, and apparently in all Ungulates, the "Sylvian" fissure has the appearance of being unusually well-developed, but in reality, according to Holl, it is a complex fissure, and contains the ectosylvian arc of Carnivorae, along with the gyrus arcuatus primus, submerged within its walls. Does histology confirm this supposition? Yes, because in Sus much of the cortex having "audito-sensory" characters lies concealed within the "Sylvian" fissure, particularly its upper part, and it also does not spread backwards as far as the fissure marked ectosylvius in my diagram. This leads up to another question, viz., whether the ectosylvian fissure, here indicated, is not really the postsylvian. I have already given reasons for thinking that the sulcus in this animal, commonly accepted as the suprasylvian, is, in all likelihood, the lateral fissure of other orders, and this being so, where is the former fissure? It is unlikely that it can be wholly unrepresented, for it is said to be one of the most stable of mammalian sulci; and, if present, it must lie somewhere between the lateral and rhinic fissures, but the only fissures in this situation are, first, two dimples lying above the level of the so-called "Sylvian," and secondly, the above-mentioned ectosylvian fissure. Nevertheless, after duly considering the evidence bearing on this and other investing areas, the only conclusion I can arrive at is that these constituents, scattered and rudimentary as they appear to be, represent the suprasylvian sulcus of other orders.

As it may be asked why I have not made use of the claustrum in working out the homologies of this region in general, and of the Insula in particular, I would mention that I have not wholly disregarded this structure. In fact, in every brain examined I have endeavoured to make a surface projection drawing of the nucleus. Of course such a drawing is apt to be inexact, on account of the depth at which the claustrum is placed, but on the whole I find that the anterior limb of the gyrus arcuatus, and the extrarhinic cortex immediately behind "Sylvius," commonly overlie this body, and this is the area of cortex, as I have mentioned, which I regard as the forerunner of the Insula.

Frontal Lobe.

In practically all the regions we have discussed some feature has been detected, either with the unaided eye or with the microscope, which in being reproduced in the human organ has yielded some insight to the course of events attending the phylogenetic development of the part. But, in the case of the frontal lobe, if we except the orbital sulcus, not a single surface depression, which we can look upon as the original of any sulcus in the human lobe, is recognisable, nor does a careful collateral and comparative examination of the lobe under the microscope enable us to decide, with any measure of assurance, that it is covered by a kindred type of cortex. This lack of resemblance lightens our remarks on the homologies of the lobe, for the orbital sulcus is alone left for consideration, and it is soon dismissed, because earlier writers appear to be correct in correlating it with the sulcus orbitalis transversus of Homo. At the same time some general reflections bearing on the question of cerebral ontogeny and phylogeny, and of sufficient importance to commit to paper, are engendered.

General Reflections.

When we take account of the composition of the lower mammalian brain, and compare it with that of Homo, we are immediately struck by the truth that the surface of the former is almost entirely occupied by cortex dominating those simple functions, which, in the case of a lowly terrestrial animal, are essential to survival, inasmuch as they provide avenues of information, either for the obtainment of prey and pabulum, or for escape from oppressing foes. Of course the same functions exhibit varying degrees of importance in different animals, but named in approximate order of value, they are those of smell, sight, hearing, common sensation, and locomotion. It is also interesting to have abundant proof of the fact, that when as a result of the mode of life it adopts in the combat for existence a given animal is forced to place special reliance on some particular function, then at the expense of the remainder a relatively greater extent of pallium is allotted to that function. This cannot be better exemplified, although the illustration is an old one, than by noting the large proportion of brain devoted to the olfactory sense, in macrosmatic animals. In Man the case is widely different, for, while retaining possession of all these fields of primitive cortex dominating simple functions, he has risen superior to the necessity of relying upon the specialisation of one or more of these functions, or even of adopting a safe mode of life, by developing cortex for the government of those high psychic processes which make him preeminent among beings.

Thanks to the discriminating powers of the microscope, guided by the researches of workers in the departments of comparative anatomy, physiology, pathology, and embryology, we are now able to draw a map of the brain indicating the precise extent and distribution of most of the areas of cortex governing these primitive and higher functions, respectively. And, in reference to the primary and essential areas, it is extremely interesting to find that, when a type of cortex pertaining to one of these senses once has its architecture established, there is a remarkable leaning towards the preservation of the original structural plan, and this in spite of the specialisation or degradation

to which the senses are liable, in the course of phylogeny. For instance, although the sense of smell is to Man of minor importance, and the lobus pyriformis has dwindled down to a fraction of its earlier representation—its representation, let us say, in Sus—yet, on making a microscopic comparison of the lobe in the two animals, such a pronounced reproduction of the primitive formation is observable, that a superficial inspection will fail to distinguish sections of one from the other. And, in the case of all the other primary areas, a corresponding condition of affairs holds, but to a graded extent; thus, from my examination of these areas, I should say that the structure of the visual cortex stood next to the olfactory in stability, while the auditory and common sensory cortex I should bracket together last.

From this it appears that a proposition can be formulated to the following effect: the stability of the architectural plan of any given field of cortex is directly related to the age of that cortex, and to the importance, as a means to survival, of the function it subserves. The corollary to be drawn from the foregoing proposition is that by utilising the discriminating powers of the microscope it is possible to estimate and graduate, to a certain extent, the phylogenetic age of the various functional territories.

Contradictions assert themselves when we attempt to apply this rule to the history of the motor cortex. One matter calling for explanation is that whereas in Carnivorae, Anthropoidea, and Homo what we must regard as the principal element, the giant cell of Betz or ganglionic cell of Bevan Lewis, is well represented, in the pig and other animals the same element is undeveloped. In the case of Sus communis we might suppose, and not be altogether wrong in doing so, that the particular cells to which I have drawn attention in the belief that they are homologous with the motor cells of Homo, have undergone retrograde changes, that they are relatively small in size and otherwise atypical, as a result, to some extent, of the confined life the species has been forced to lead through countless generations. But the condition of affairs in the rabbit forces us to pause; we are told that in the cortex of this animal not a single Betz cell is recognisable[1], and yet hardly any mammal makes fuller use of motor activity as a means to escape from its enemies. Contradictions in nature such as this are, to say the least of them, puzzling, and apt to lead us away from the truth; still, after giving the whole matter full consideration, and in spite of these contradictions, there seems to me to be only one conclusion, and it is that the motor function is late in being represented—"re-represented," in Dr Hughlings Jackson's words—in the upper or cortical level. Pursuing this point further, we cannot doubt that the movements of all non-mammalian vertebrates (Pisces, Amphibia, Reptilia, Aves), despite their activity, must necessarily be generated in the spinal cord, probably coordinated by the well-developed cerebellum. Then, even among mammals, it is as likely that there are many low down in the scale in which movement is either not at all, or only indifferently, "re-represented" in the cortex cerebri. Such a supposition would explain the locomotor activity of the rabbit. Ascending the scale we arrive at the condition exemplified in the pig, where an advance in cortical representation is indicated by the deposition of germinal elements, and so onwards through Carnivorae, Simiadae, and up to Homo, there occurs a gradual perfection of the representation in both the physical and the psychic sense. Reasoning inversely, the proposition is forced upon us, that since among the primary functions motion lags behind in obtaining cerebral government, so the giant cells characterising motor cortex are comparatively late in being added to the pallium.

So far one has written only of the fields of cortex dominating primary functions more or less common to all vertebrata. A few remarks, comparative in nature, will now be offered on that

[1] Kolmer has made serial sections of the crucial region of the Bat, Hedgehog, Rabbit, Mouse, Rat, Guinea-pig, Ox, and Pig, and states that not a single "motor" cell is to be found. It is evident, however, that in the case of the Pig he has overlooked the elements I regard as the homologues of giant or motor cells, cells, by the way, which Dr Bevan Lewis has also seen and figured (*Text-book of Mental Diseases*).

pallium which marks the superiority of Man, and is the last to appear in the phylogenic progress of cerebral growth. Interest centres mainly on its extent, and although the subject has been freely discussed by others with a riper experience than mine, I have no compunction in reopening the question, because I am sure it will be conceded by all that microscopic examination is the most accurate gauge we can employ for the exact determination of the areal limitations about which we are doubtful.

Beginning with the frontal lobe, we at once notice that the lobe in Man has undergone great expansion, evident enough on the mesial surface, plainer on the orbital face, and more pronounced still on the convexity; further, we learn from the microscope, that this expansion, this new formation, is associated with the deposition of fresh types of cortex, types we failed to recognise in the lower animal. Just along the anterior margin of the Carnivore motor area, it is true, there does exist a fringe of cortex bearing a slight resemblance, a very slight one, to that of the extensive "intermediate precentral" area of Man; in front of this, however, it is impossible to see any similarity between the undeveloped-looking grey mantle of the lower animal and the definitely constituted, but perhaps still incomplete, "frontal" and "prefrontal" cortex of both Man and the Anthropoid.

Passing on to the parietal lobe we again find evidence of superior development; and perhaps the clearest conception of this is obtained by viewing the dorsal surface, and noticing the space intervening between the combined motor and sensory areas in front, and the visual area behind. In Man, the visual area is drawn backwards and downwards, and almost pushed off the horizon: in the lower animal, on the contrary, the same area is not only mainly resident on the dorsal surface, but is separated by a short interval only from the sensory and motor fields. In anatomical terms, the precuneus, and the superior and posterior parietal lobules suffer in the comparison. And it is of further interest to observe that in Sus this space is distinctly less than it is in either Felis or Canis. From the structural aspect, the differences are less pronounced than they were in the case of the frontal lobe: the "intermediate precentral" and "parietal" types of Homo are not repeated, but nevertheless the existing cortex is well constructed. This discloses a comparative distinction between parietal and frontal cortex which might be dilated upon, but as space forbids, I will merely express the opinion that it suggests an earlier phylogenesis for the former than the latter.

The truth that the visual area occupies virtually the whole of the occipital lobe, roughly estimated at about one-sixth of the entire cortex, sufficiently emphasises the value of this sense to the lower animal. But in a comparative examination it is interesting to notice that the investing zone of cortex we saw in Man, and to which we assigned a psychic function, is almost wholly unrepresented in the lower mammal; only in Canis was a trace of homologous cortex observed.

In the temporal lobe, again, the brain of Man shows to enormous advantage, indeed, the homologue of the second, third, and fourth temporal gyri is undefinable in the lower animal. Further, I have failed to differentiate a specialised field of cortex to compare with the "audito-psychic" area.

Others have written in thoughtful detail of the changes leading to the operculation of the Insula; I can only add that histology yields proof of the stability of the covering cortex through the phylogenetic series, an attribute which indirectly confirms the opinion I have given elsewhere, that the insular cortex may deal with the elaboration of gustatory impressions.

From what is written in the foregoing paragraphs it is plain that I share the opinion of those who maintain, that while the human brain shows signs of having expanded more decisively in some parts than in others, yet that expansion, if we except the olfactory and visuo-sensory areas, has been general in kind.

REFERENCES.

W. Bevan Lewis. On the Comparative Structure of the Cortex Cerebri. *Brain, a Journal of Neurology*, Vol. I, 1878—1879.

O. and C. Vogt. *Op. cit.*

S. Ramón y Cajal. *Op. cit.*

Theodor Kaes. Ueber Markfaserbefunde in der Hirnrinde bei Epileptikern, besonders in der äusseren (zonalen) Associationsschicht. *Neurol. Centralb.*, No. 11, 1904.

A. S. F. Grünbaum and C. S. Sherrington. *Op. cit.*

G. Elliot Smith. Studies in the Morphology of the Human Brain, with special reference to that of the Egyptians. No. 1, The Occipital Region. Records Egyptian Government School of Medicine, 1904.

G. Elliot Smith. The Morphology of the Retrocalcarine Region of the Cortex Cerebri. *Proc. of Roy. Soc.*, Vol. LXXIII, 1904.
Also *Anatom. Anzeiger*, Bd. XXIV, 1904, and *Review of Neurology and Psychiatry*, Vol. VI, 1904.

K. Brodmann. *Op. cit.*

K. Brodmann. Demonstrationen aus Cytoarchitectonik der Grosshirnrinde mit besonderer Berücksichtigung der histologischen Localisation bei einigen Säugetieren. *Allg. Zeitschr. f. Psychiatr.*, Bd. LXI, H. 5, 1904.

Walther Kolmer. Beitrag zur Kenntniss der "motorische" Hirnrindenregion. *Arch. f. mikros. Anat. u. Entw.-Gesch.*, LVII, 1904.

D. J. Cunningham. *Op. cit.*

J. S. Bolton. *Op. cit.*

A. Tschermak. Notiz betreffs des Rindenfeldes der Hinterstrangbahnen. *Neurol. Centralb.*, No. 4, 1898.

H. Munk. *Op. cit.*

P. Flechsig. *Op. cit.*

H. Döllken. Die Reifung der Leitungsbahnen in Thiergehirn. *Neurol. Centralb.*, No. 21, 1898.

M. Holl. Ueber die Insel des Ungulatengehirns. *Archiv f. Anat. u. Phys.*, 1900. *Anat. Abth.*

M. Holl. Zur Morphologie der menschlichen Insel. *Ibid.*, 1902.

PLATE I.

Human brain, M., aet. 41. Orthogonal tracings of the lateral and mesial surfaces (the former somewhat tilted to show the convexity) of the left cerebral hemisphere, with a representation of the extent of the various areas defined therein from an examination of cortical nerve fibres and nerve cells.

In a surface diagram it is impossible to give a true idea of the extent of many of these fields, because cortex concealed within fissures cannot be indicated, and unfortunately the figures are especially misleading in regard to some of the most important areas; thus the floor, not the lip, of the fissure of Rolando is the boundary between the precentral and postcentral fields, and accordingly the concealed portion of these areas is almost equivalent to that exposed: the same applies to the calcarine or visuo-sensory field, while that marked "audito-sensory" is almost completely hidden in the Sylvian fissure.

PLATE I

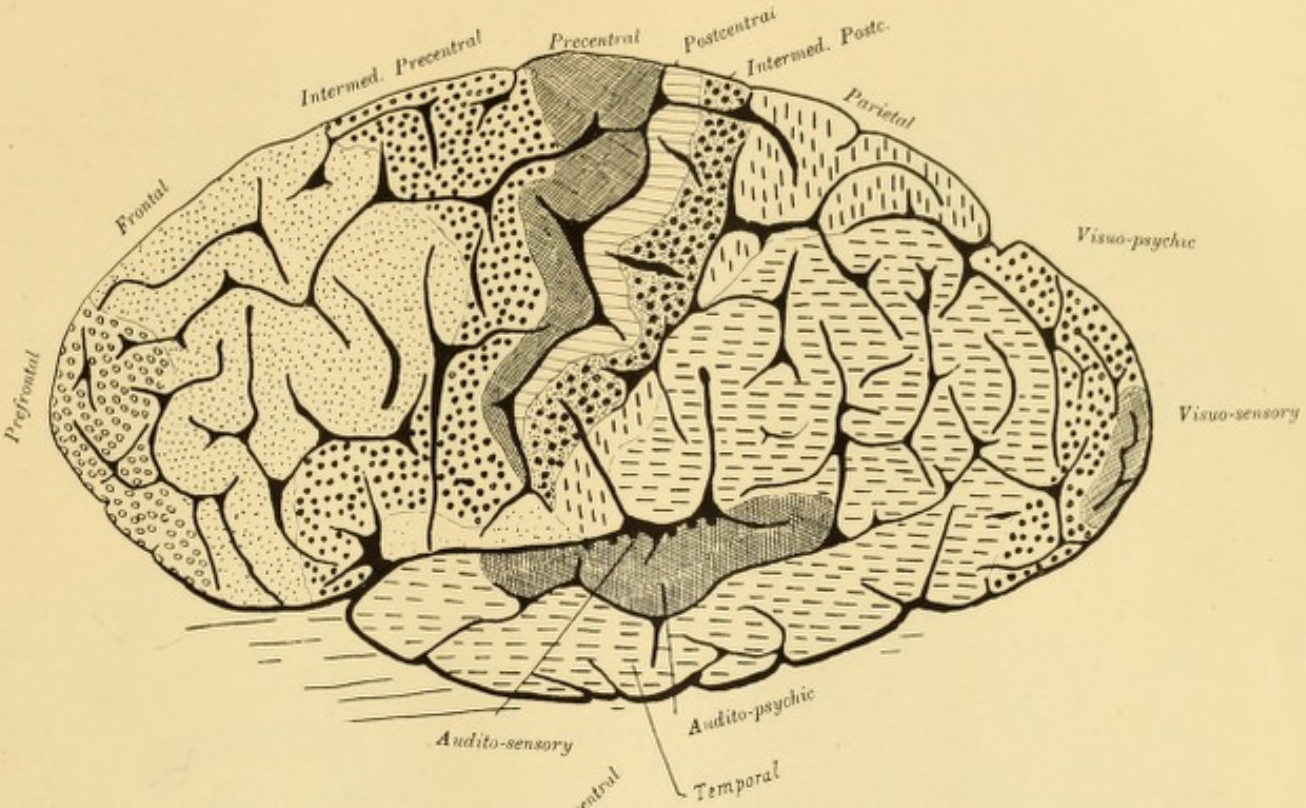
Intermed. Precentral
Precentral
Postcentral
Intermed. Postc.
Parietal
Frontal
Visuo-psychic
Prefrontal
Visuo-sensory
Audito-sensory
Audito-psychic
Temporal

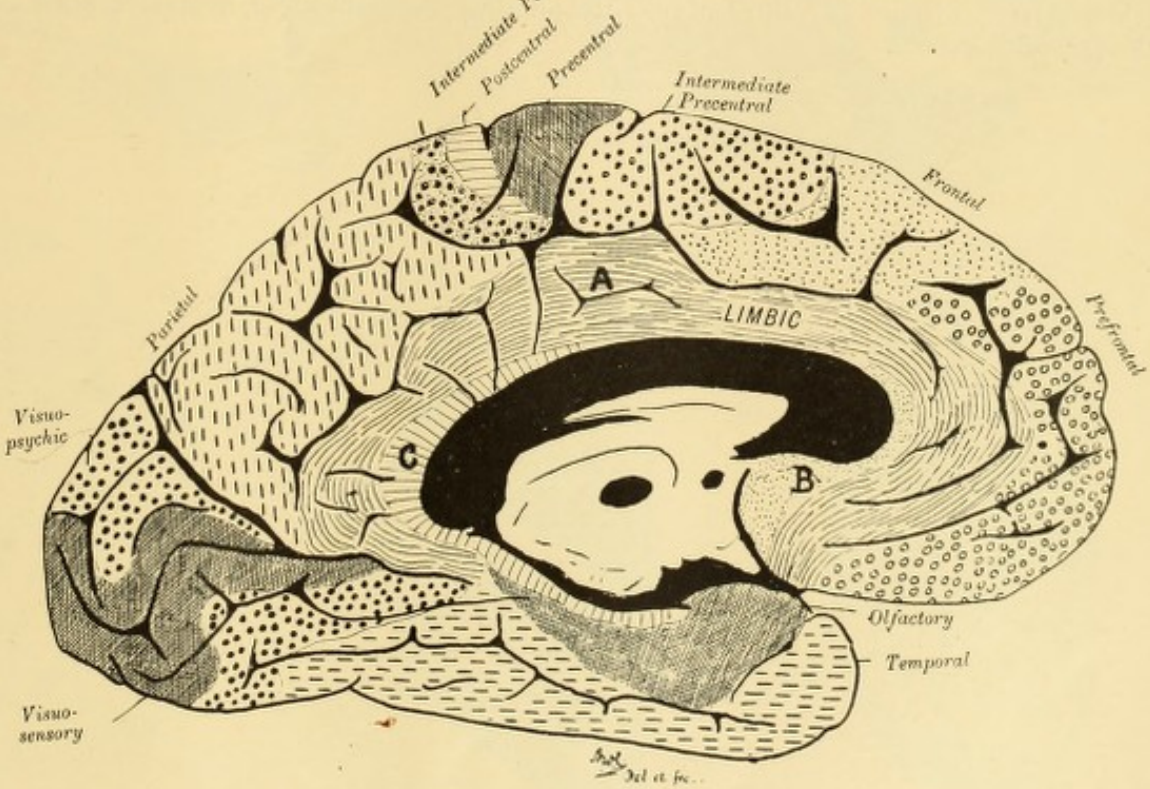
Intermediate Postcentral
Postcentral
Precentral
Intermediate Precentral
Frontal
A
LIMBIC
Parietal
Prefrontal
Visuo-psychic
C
B
Olfactory
Temporal
Visuo-sensory

PLATE II.

Drawings of the left hemispheres of a Chimpanzee (Anthropopithecus troglodytes) and an Orang (Simia satyrus) to show the distribution of the principal areas which can be defined histologically. Compare with Plate I.

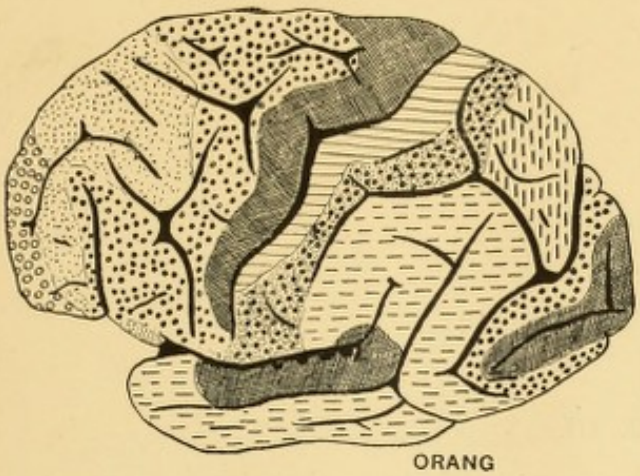

ORANG

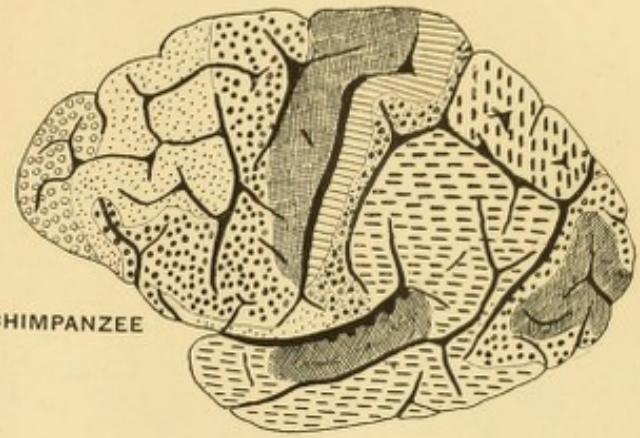

CHIMPANZEE

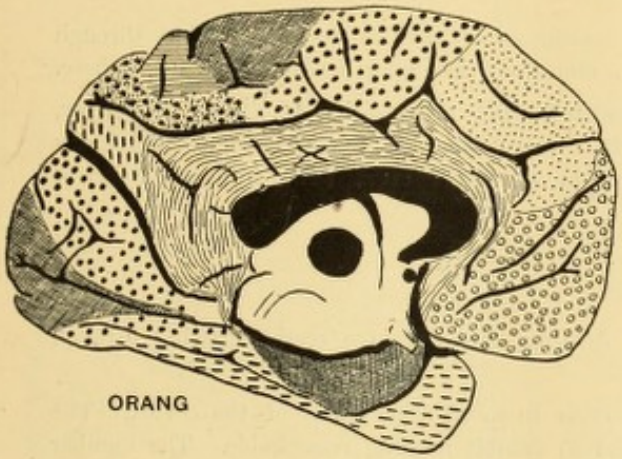

ORANG

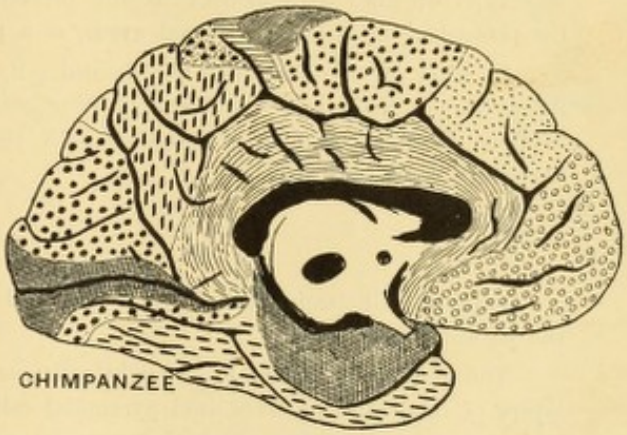

CHIMPANZEE

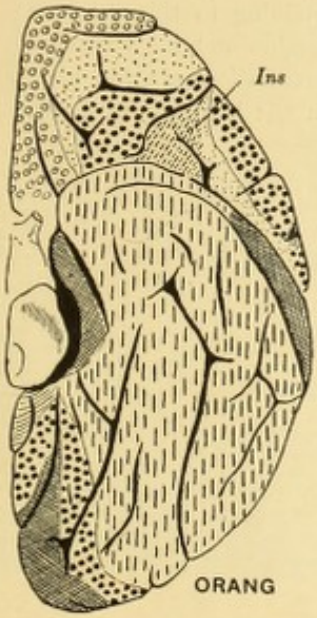

ORANG

ORANG

CHIMPANZEE

PLATE III.

Figure 1.

Type of fibre arrangement in the precentral or motor area. Drawn from a section through the precentral or ascending frontal gyrus, at a point 15 mm. from the upper border of the hemisphere.

Z, zonal layer, dense and well-defined. S, supraradiary layer. B, position of line of Baillarger, its position obscured by surrounding fibre wealth. R, radiary zone. Note the general superiority in fibre representation in comparison with the cortex in any other area. The numbers refer to nerve cell laminae. $\times \frac{80}{1}$.

Figure 2.

Type of cell lamination in the precentral area; drawing taken from a section passing through the paracentral lobule.

The plexiform layer (1) is slightly deeper than it is in most other parts of the cortex. The layers of small and medium-sized pyramidal cells (2 and 3) exhibit nothing remarkable. The number and shape of the large external pyramidal cells (4) are worth nothing. There is an exceedingly indistinct lamina of stellate cells (5), but it may be seen that elements pertaining to this category encroach upon the layers above and below. The poor development of this lamina and the enormous cells of Betz (6) are the most important cytological guides to the differentiation of this area. The layer of fusiform cells (7) shows nothing of special interest. Low power, $\times \frac{80}{1}$; high power, $\times \frac{480}{1}$.

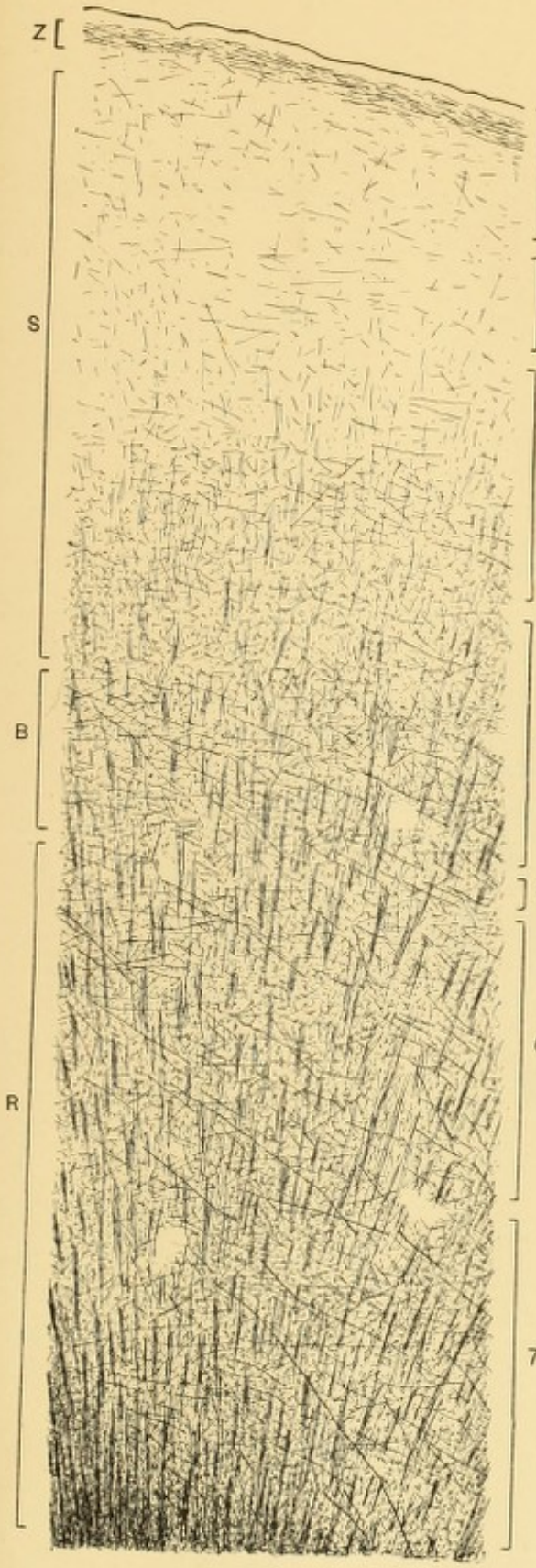

Fig. 1.

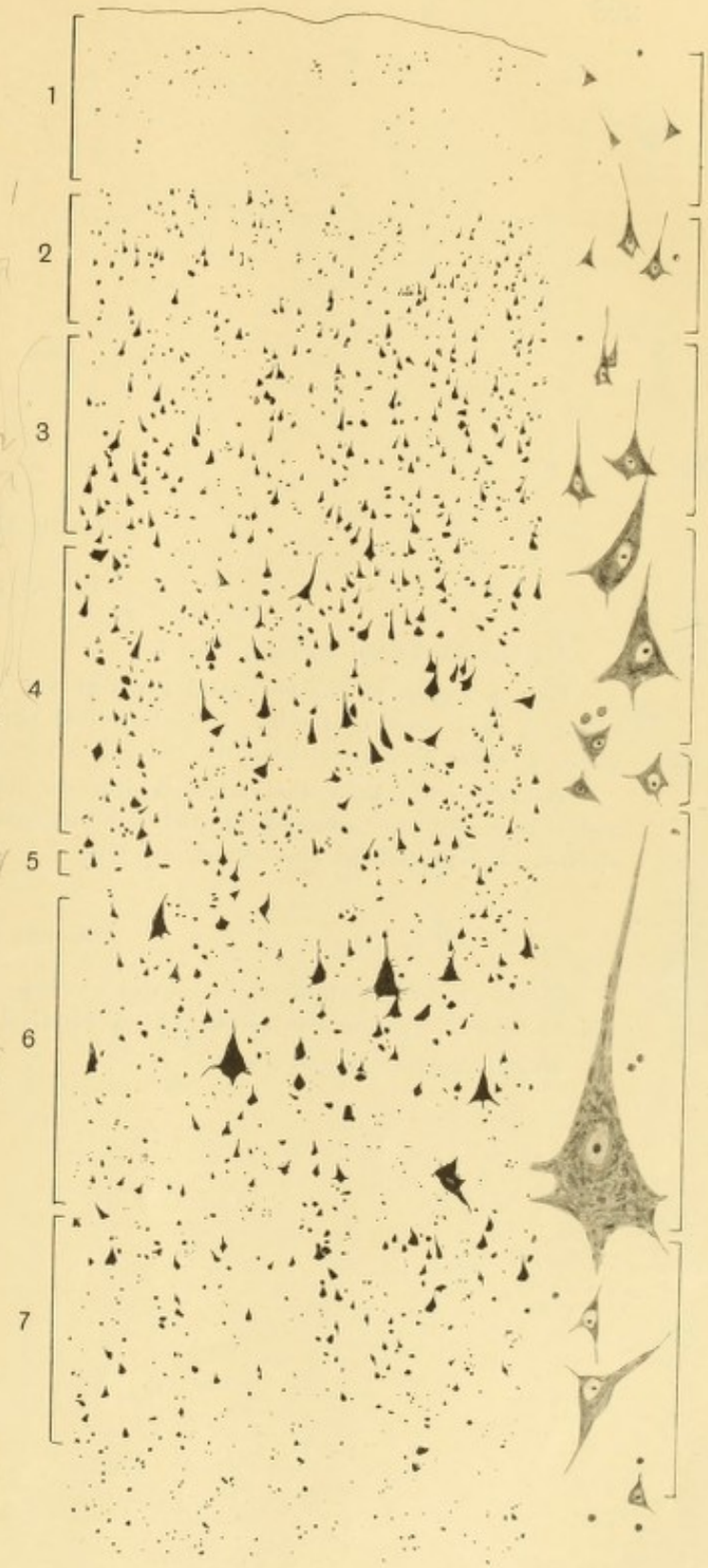

Fig. 2.

PLATE IV.

Figure 1.

Amyotrophic lateral sclerosis, Case I.

From a section of the precentral gyrus at the upper margin of the hemisphere. 1, plexiform layer. 2, small pyramidal cells. 3, medium-sized pyramids. 4, large external pyramids. 5, stellate cells. 6, where giant cells should be seen. 7, layer of fusiform cells.

The cortex is shallow, the various laminae are difficult to define, the cells in general are stunted and show a distorted arrangement, and, most important of all, giant cells are remarkable for their absence. Some distended blood-vessels are seen.

Figure 2.

To be compared with Figure 1. From a section of a normal brain, cut of the same thickness, stained by a like process and taken from an identical position.

Magnifications $\times \frac{80}{1}$ and $\times \frac{480}{1}$.

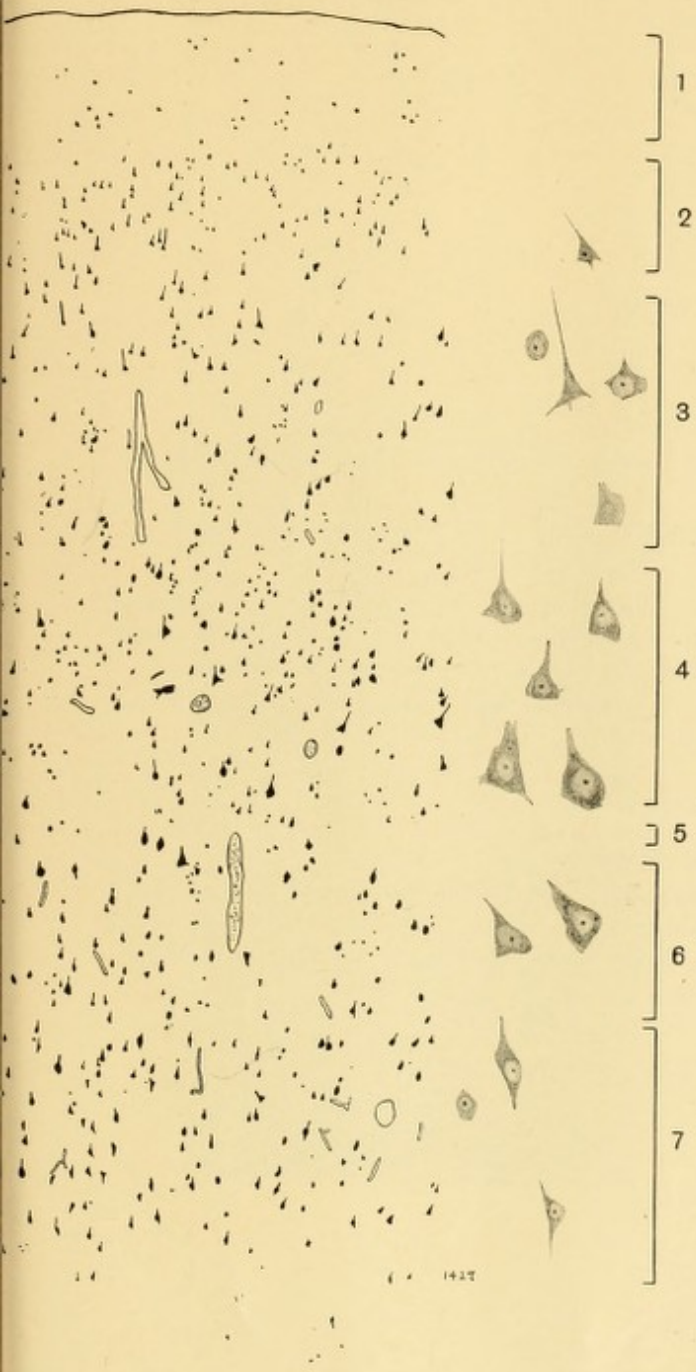

Fig. 1.

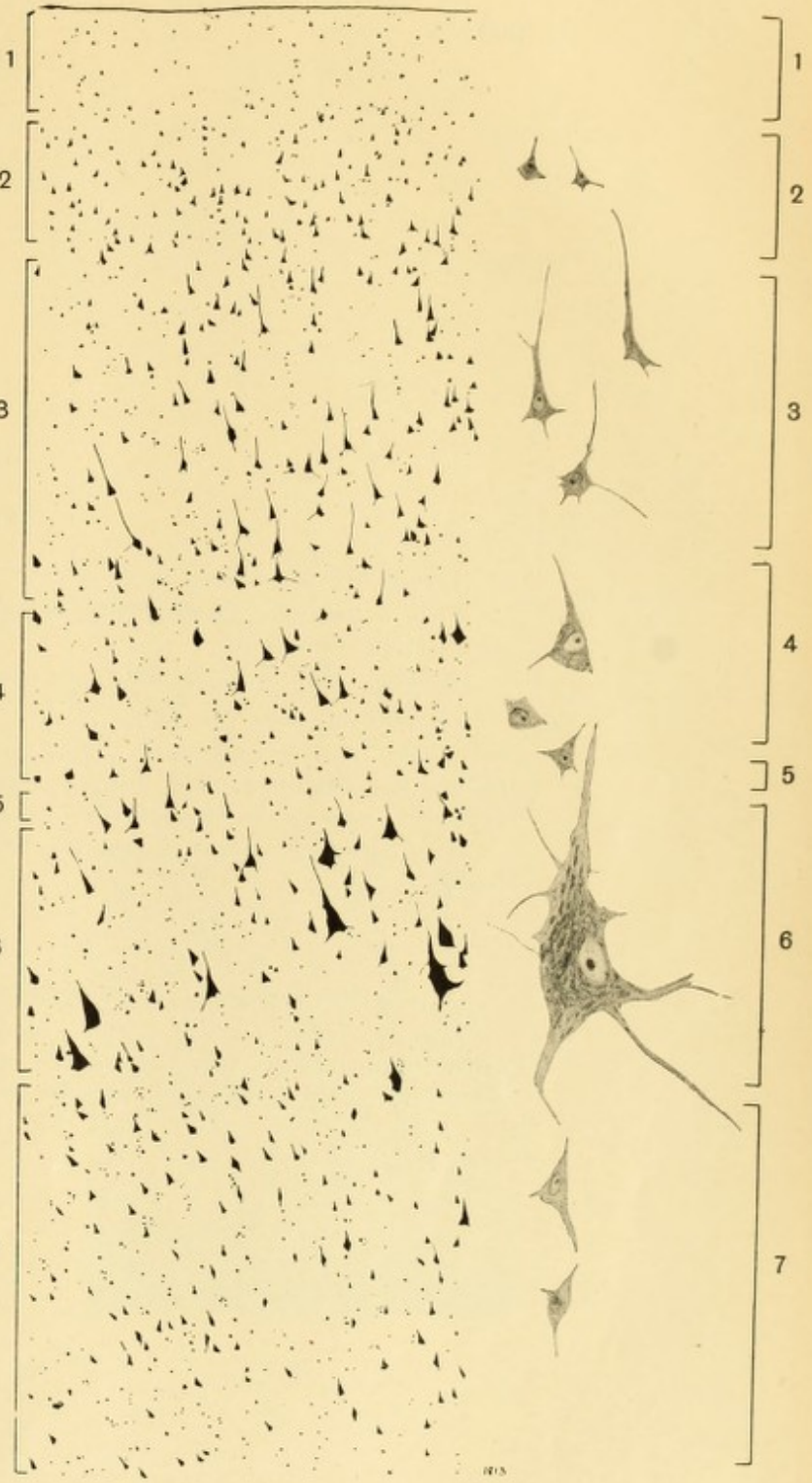

Fig. 2.

PLATE V.

Figure 1.

Type of fibre arrangement in the postcentral area.

From a transverse section of the ascending parietal or postcentral gyrus, 15 mm. from the margin of the hemisphere.

Z = zonal layer. S = supraradiary zone. B = position of line of Baillarger. R = radiary zone.

Compare with Plate III. figure 1.

A low power drawing gives a disappointing display of the differences in fibre arrangement between this and motor cortex, but the disparity in depth and in general fibre wealth, the latter particularly noticeable in the zonal layer and radiary zone, are points which may be observed.

The right-hand figures and brackets refer to and show the corresponding position of cell laminae. $\times \frac{80}{1}$.

Figure 2.

Type of fibre arrangement in the intermediate postcentral area. $\times \frac{80}{1}$.

From a drawing half-way down the postcentral gyrus and towards the parietal side. Z = zonal layer. S = supraradiary layer. B = line of Baillarger. R = radiary zone. The right-hand figures and brackets refer to cell layers. Compare with Figure 1 and note the reduction in fibre wealth.

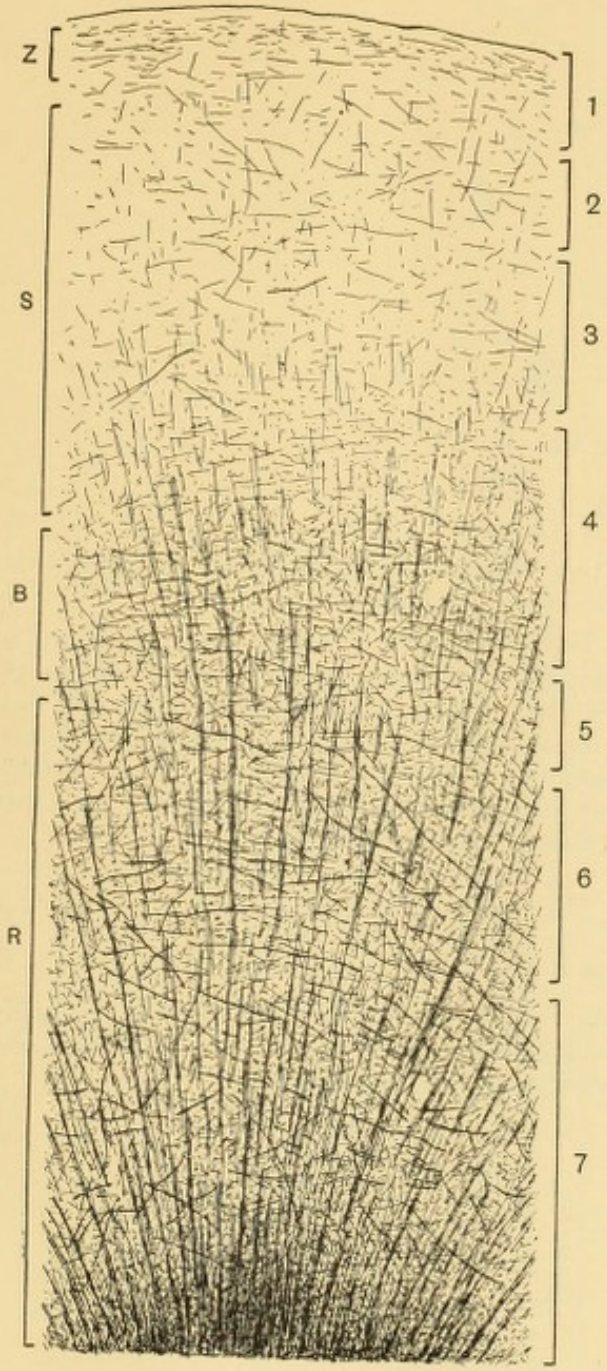

Fig. 1.

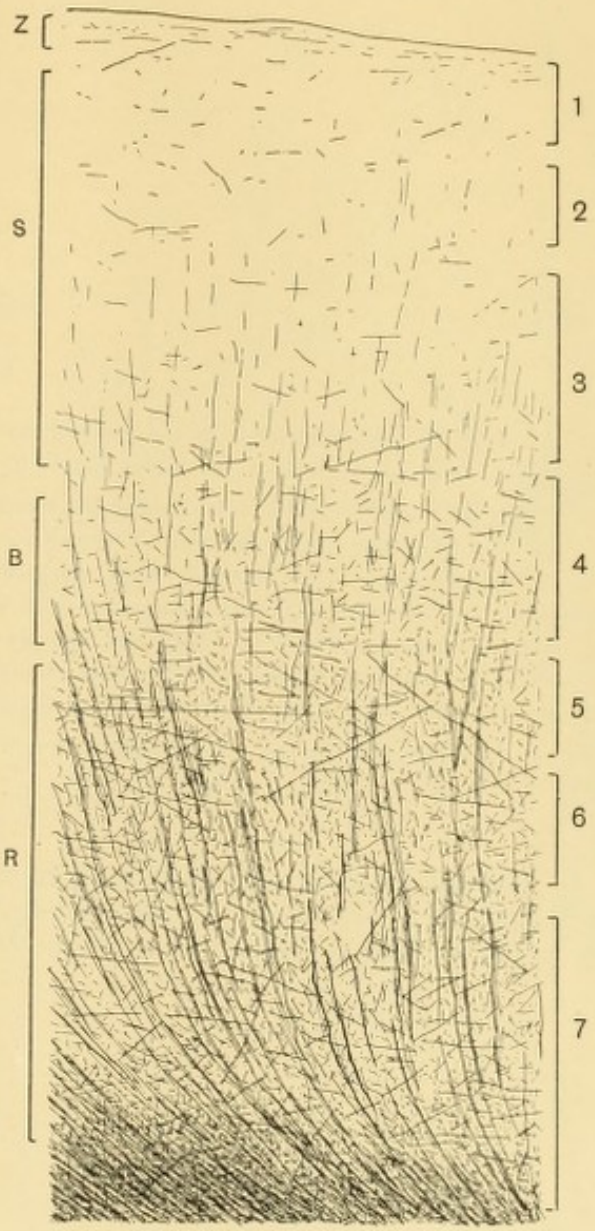

Fig. 2.

PLATE VI.

Figure 1.

Type of cell lamination in the postcentral area; drawing from a section through the paracentral lobule, immediately behind the upper extremity of the fissure of Rolando.

It is important that this should be compared with the precentral drawing, Plate III. figure 2, and the following points noticed. The plexiform layer (1) is shallower. 2 and 3 show no differences of consequence. The external large pyramidal cells (4) form a more prominent layer, and the individual members are more elongated and more richly supplied with chromophilic material. The layer of stellate cells (5) is deep and sharply defined. At 6 there is an entire absence of "giant" cells, but elements similar in size and structure to those found at 4 are recognisable; they are, however, not so numerous. The fusiform layer (7) does not call for comment.

Low power drawing, $\times \frac{80}{1}$; high power, $\times \frac{480}{1}$.

Figure 2.

Intermediate postcentral type of cell lamination. $\times \frac{80}{1}$. From a section half-way down the postcentral gyrus and towards the posterior edge. The layers of large pyramidal cells at 4 and 6 are weakly represented compared with those in the postcentral area proper, Figure 1.

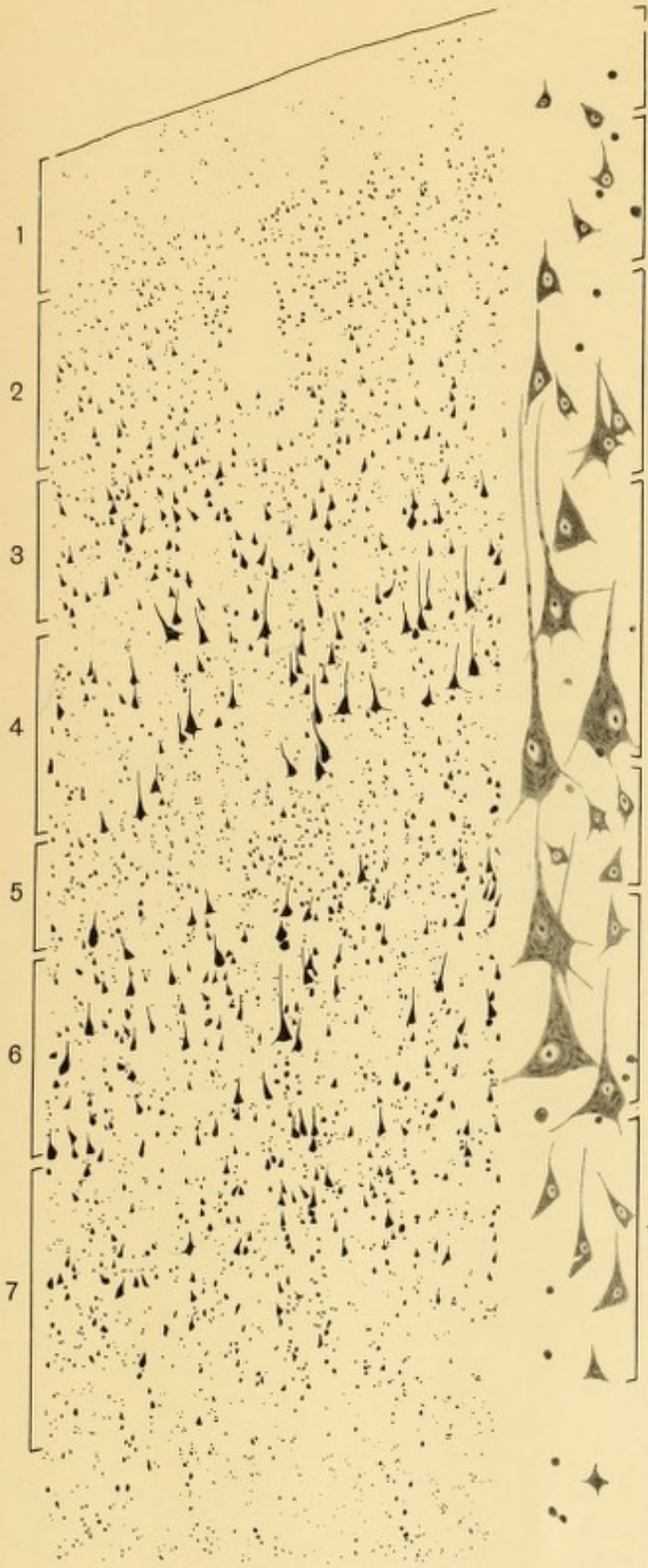

Fig. 1.

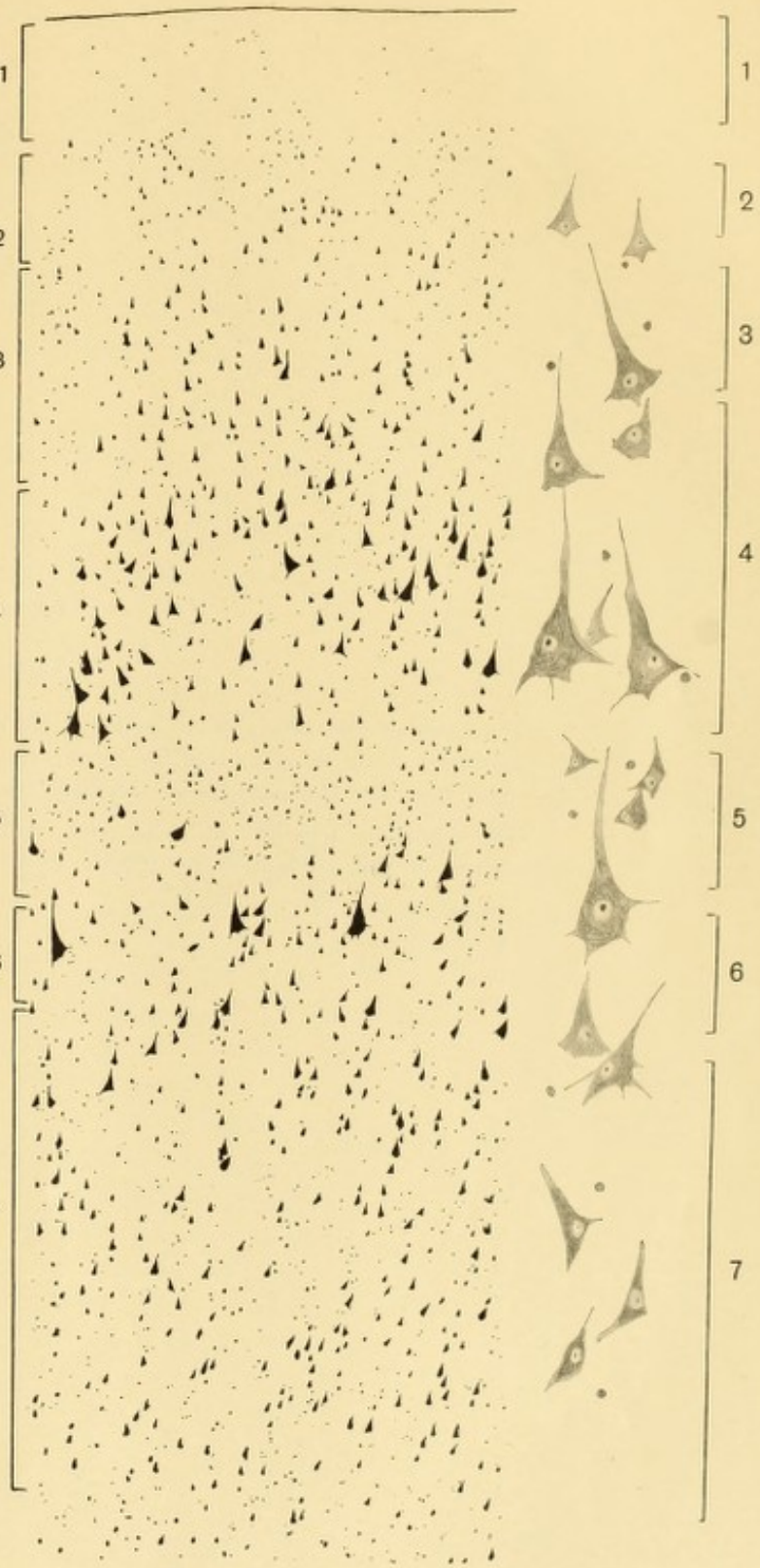

Fig. 2.

PLATE VII.

Tabes Case I.

Drawings of the cortex from section 7 in Plate IX.; that to the left is from the middle of the affected tabetic area, *i.e.* half-way down the Rolandic side of the postcentral gyrus; that to the right, from the Rolandic lip of the same convolution.

The huddling together of cells, the changes in the pyramidal elements, and the general disturbance of cell lamination are points to be noticed in the left-hand drawing.

Magnification $\times \frac{80}{1}$.

1
2
3
4
5
6
7
1
2
3
4
5
6
7
1
2
3
4
5
6
7
1
2
3
4
5
6
7

PLATE VIII.

Tabes Dorsalis.

Drawings from section 7, Plate IX.

The one to the right is from the affected area on the Rolandic wall of the postcentral gyrus, that to the left from the posterior wall at a corresponding level.

The layers of large pyramidal cells and the intervening lamina of stellate cells are represented.

The atrophic condition of the large pyramidal cells (they should stand out more plainly on the front than on the back wall of this gyrus), the superabundance of small round cells, and other changes referred to in the text are plainly seen.

The figures were most carefully made with a Leitz eye-piece drawing apparatus and a Zeiss 4 mm. apochromatic objective, and objects lying in one focus only are represented.

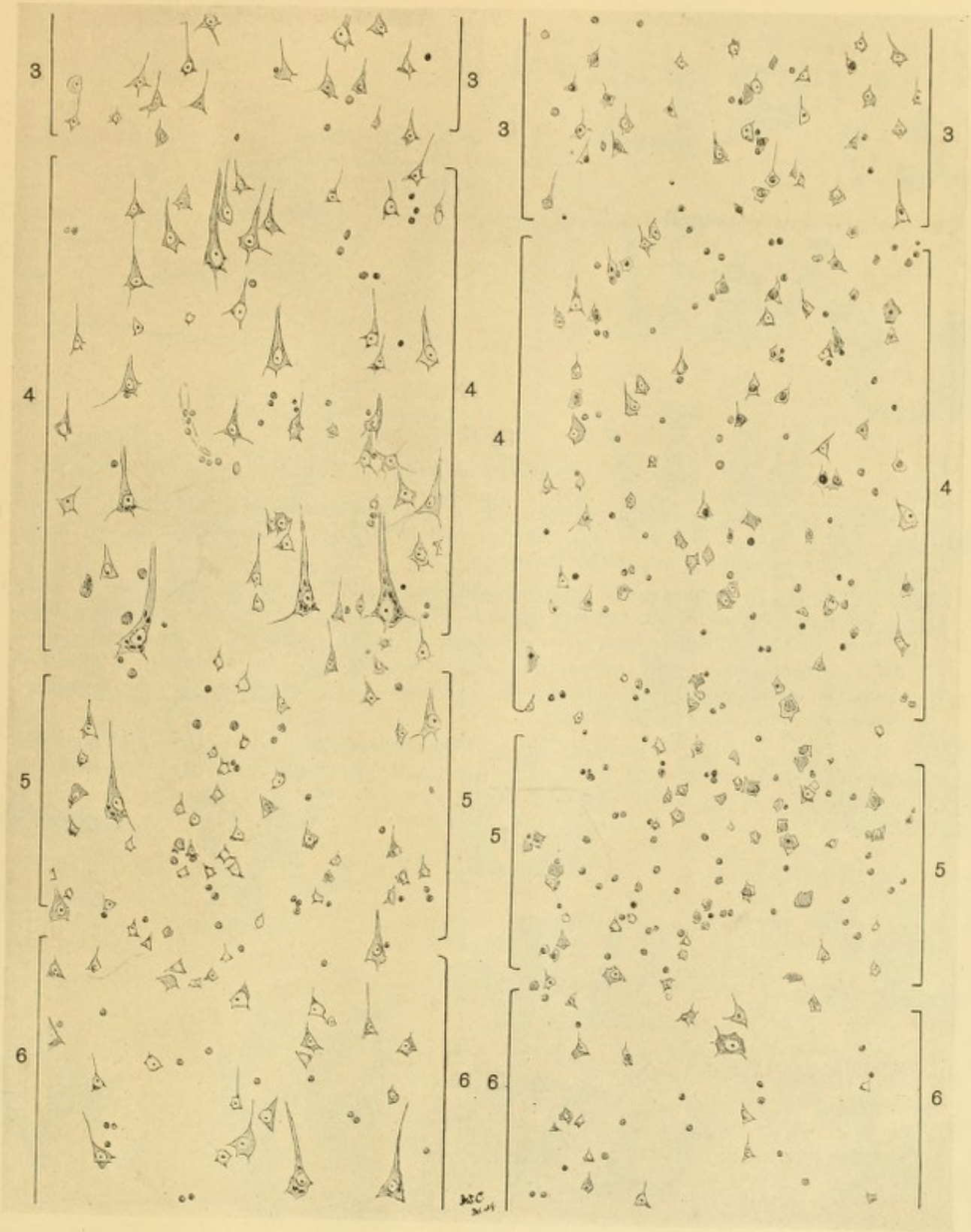
3
3
3
3
4
4
4
4
5
5
5
5
6
6
6
6

PLATE IX.

Tabes Dorsalis.

A series of transverse sections of the central gyri showing the exact distribution of the tabetic cortical changes in Case I. The affected part is indicated by crosses and is seen to be almost entirely confined to the posterior Rolandic wall.

The diagram is further utilised in illustrating the distribution of the giant cells of Betz. In the sectional but not in the surface drawings, each dot represents a cell. Respecting these cells, it is not usual to find them so numerous nor so widely distributed on the mesial surface of the hemisphere; a commoner arrangement is seen in text figure 4. The sudden fall in numerical representation seen in Section 9 and continued in Section 10 is coincident with the appearance of the superior annectant gyrus or buttress.

The lines of cleavage between the different blocks, and also the extent of the field submitted to examination, are indicated by lines of short rods; the fine dotted transverse lines show the plane and position of the sections figured.

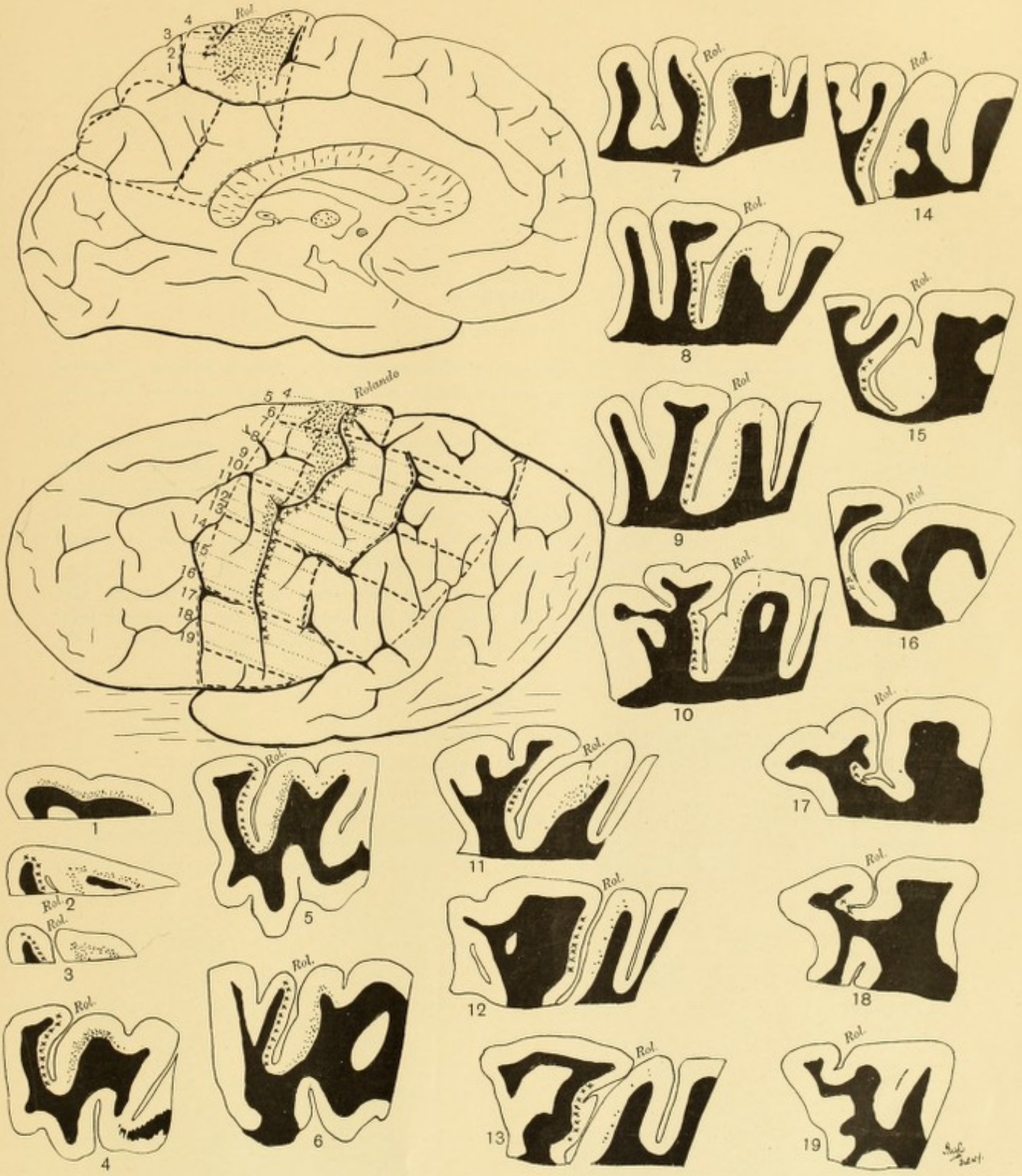
Rol.
Rolando
1
2
3
4
5
6
7
8
9
10
11
12
13
14
15
16
17
18
19

PLATE X.

Figure 1.

Type of fibre arrangement in the calcarine or visuo-sensory area. Drawn from a transverse section through the middle of the posterior calcarine fissure, and from the inferior wall of the same fissure.

Z = zonal layer. S = supraradiary layer. G = line of Gennari or Baillarger. R = radiary zone. The right-hand numbers and brackets indicate the corresponding position occupied by the various nerve cell laminae. 1 = plexiform layer. 2 = layer of small pyramids. 3 = layer of medium-sized pyramids. 4 = large stellate cells. 5 = small stellate cells. 6 = solitary cells of Meynert. 7 = fusiform cells. The cortex is shallow because the drawing is from the sulcal wall. The fibre wealth in general is not great. The zonal and supraradiary layers are uninteresting.

The prominent line of Gennari is seen to occupy the same level as the 4th layer of cells, the upper third excepted. The relatively pallid zone below corresponds with the pronounced layer of small stellate cells. The long fibres in the radiary zone are most numerous at the level of the solitary cells of Meynert. $\times \frac{80}{1}$.

Figure 2.

Type of fibre arrangement in the occipital or visuo-psychic area.

From a section of the superior occipital gyrus 2 cm. anterior to the tip of the lobe.

Z = zonal layer. S = supraradiary layer. B = line of Baillarger. R = radiary zone. The right-hand figures and brackets indicate the corresponding position held by the cell layers. The fibre wealth of the part is great. (Compare it with the common temporal type, Plate XIV. figure 1.) The dense line of Gennari has vanished. Note the wealth of transverse fibres in the radiary zone. $\times \frac{80}{1}$.

PLATE X

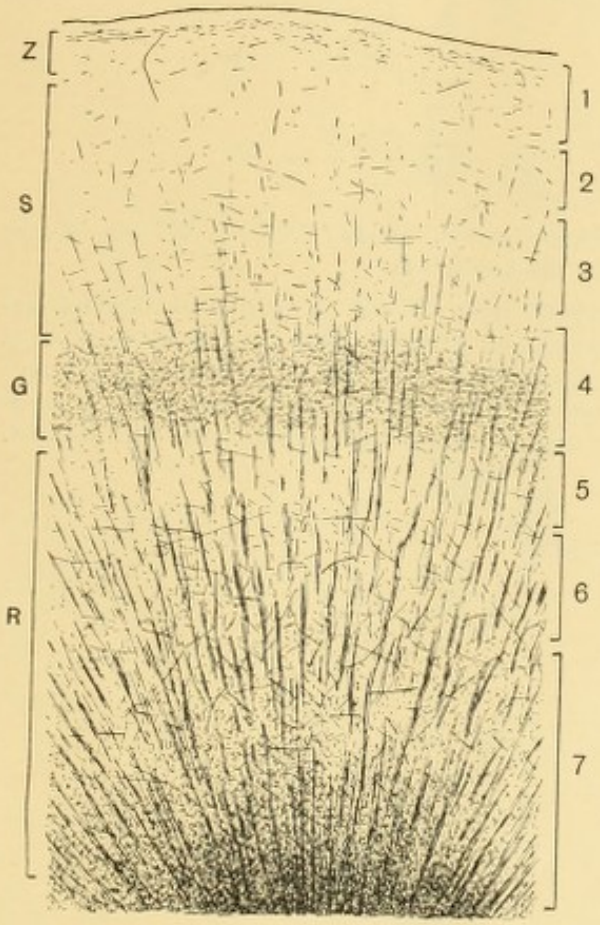

Fig. 1.

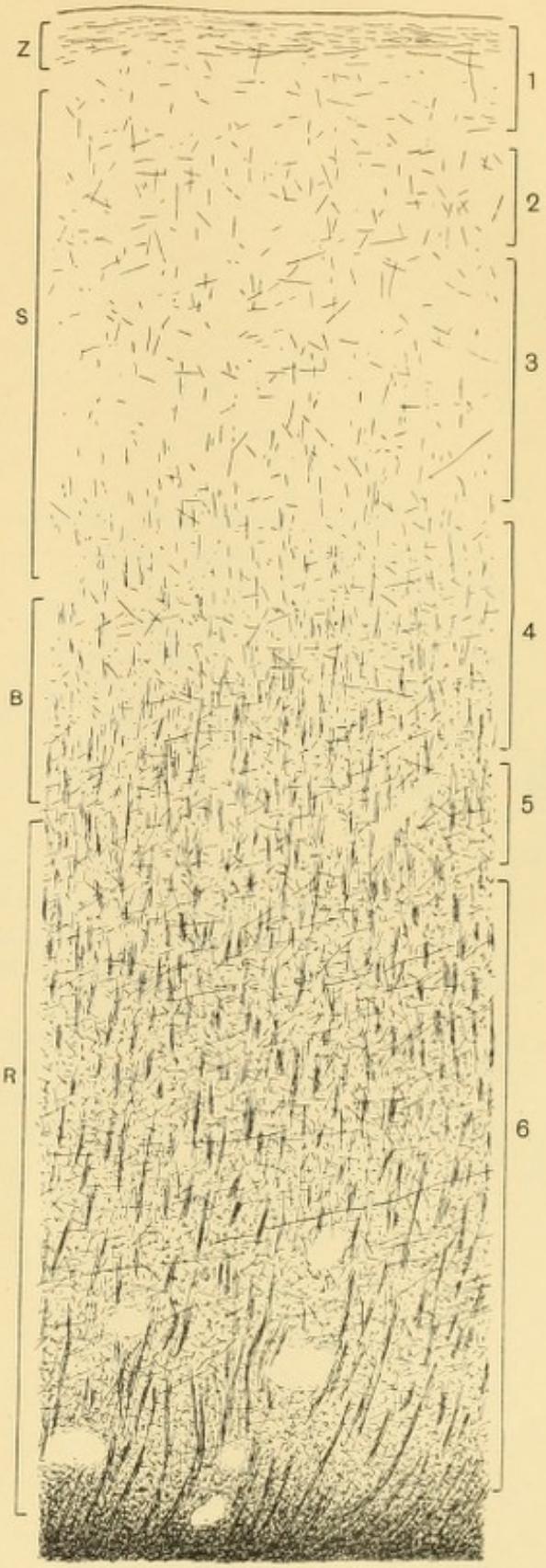

Fig. 2.

PLATE XI.

Figure 1.

Type of cell lamination in the visuo-sensory or calcarine area.

Drawing from a section through the middle of the posterior calcarine fissure and from the wall of that sulcus.

1, plexiform layer. 2, layer of small pyramidal cells. 3, layer of medium-sized pyramidal cells. 4, layer of large stellate cells; these lie in the upper part, and the pale zone in the lower half corresponds in position with the line of Gennari. 5, well-marked layer of small stellate cells. 6, layer of giant cells, the solitary cells of Meynert, which are seen to be sparsely scattered. 7, layer of spindle-shaped cells.

Low power drawing $\times \frac{80}{1}$; high power $\times \frac{480}{1}$.

Figure 2.

Type of cell lamination in visuo-psychic area.

Drawing from a section of the superior occipital gyrus, midway between the top of the parieto-occipital fissure and the posterior extremity of the hemisphere.

The general cell wealth is striking. 1, plexiform layer. 2 and 3, small and medium-sized pyramids. At 4 the numerous large external pyramidal or pyriform cells, specially referred to in the text, are seen. There is a deep and sharply defined layer of stellate cells but no pallid zone is seen above and below it, as in the calcarine cortex. Note also that the internal layer of large pyramidal cells is wanting and that there is a complete absence of solitary cells of Meynert. The fusiform layer (6) looks deep.

Low power drawing $\times \frac{80}{1}$; high power $\times \frac{480}{1}$.

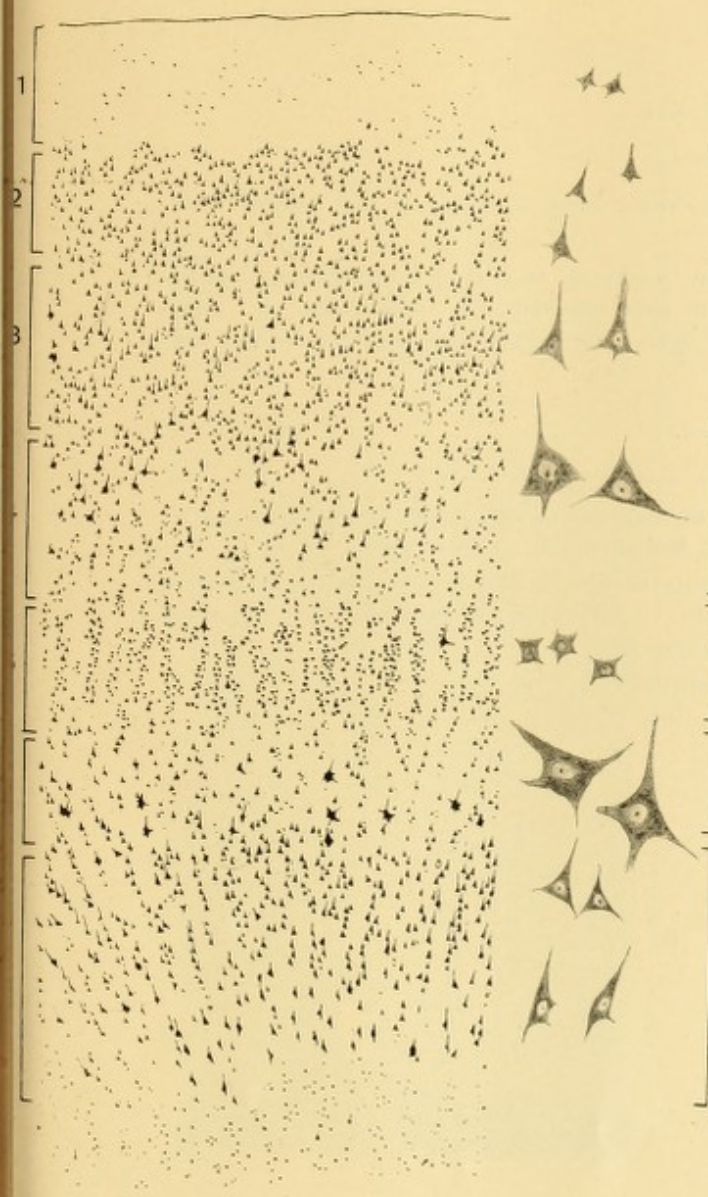

Fig. 1.

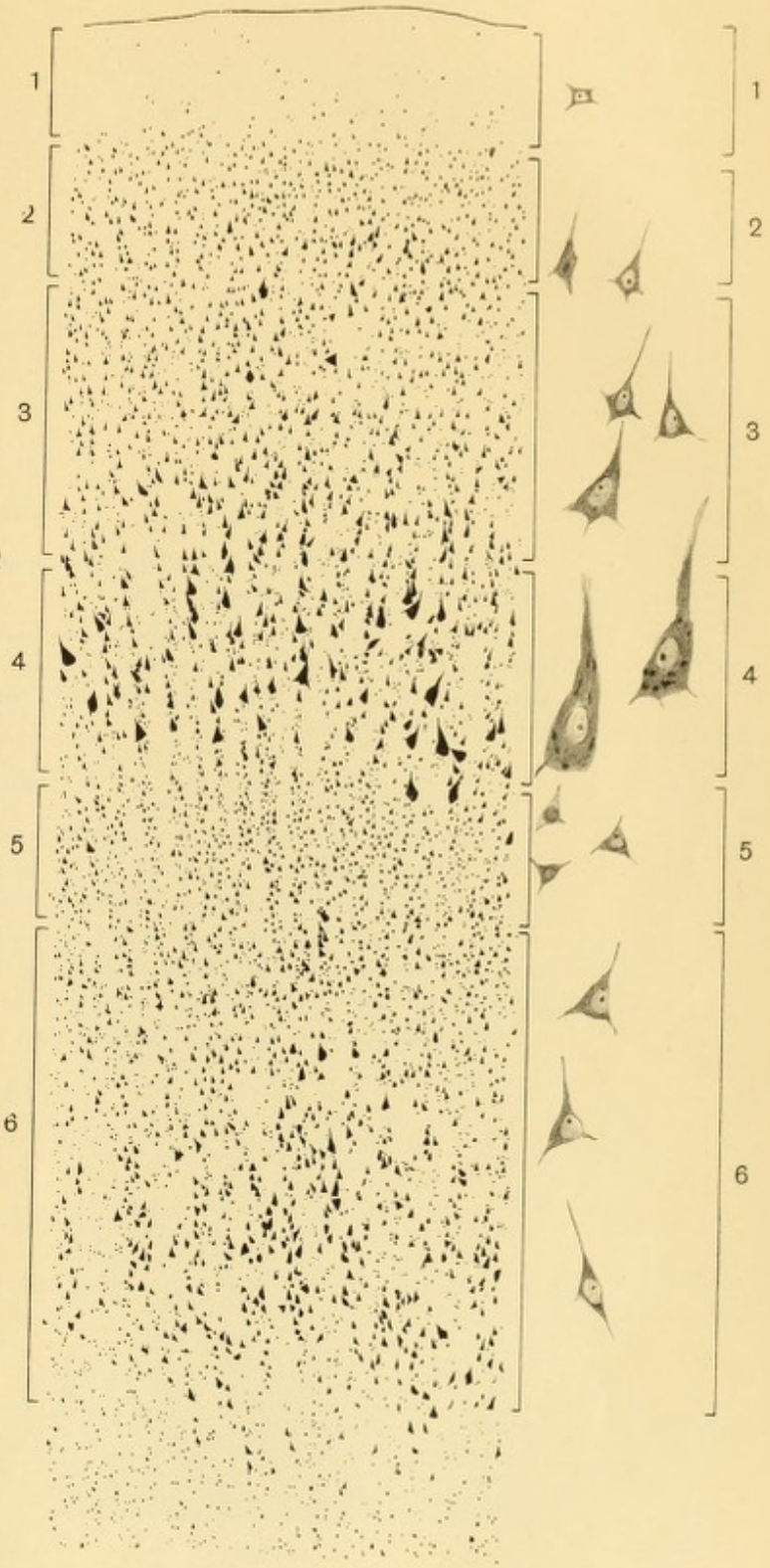

Fig. 2.

PLATE XII.

Figure 1.

Type of fibre arrangement in the Audito-sensory area. From a section of the anterior transverse temporal gyrus of Heschl. $\times \frac{80}{1}$.

Compare with figure 2 and note that the fibre wealth is very much greater and especially that long stout fibres in the radiary zone are much more numerous. Z = zonal layer. S = supraradiary layer. B = line of Baillarger. R = radiary zone. The figures and brackets to the right refer to cell layers.

Figure 2.

Type of fibre arrangement in Temporal Area No. 2 (audito-psychic).

From the free surface of a transverse section through the middle of the first temporal gyrus. Z = zonal layer. S = supraradiary layer. B = line of Baillarger. R = radiary zone.

The drawing illustrates the pronounced superiority in fibre wealth of this area in comparison with the general temporal region (Plate XIV. figure 1). The line of Baillarger does not stand out plainly owing to the rich fibre supply of surrounding parts.

The numbers and right-hand brackets refer to cell laminae. $\times \frac{80}{1}$.

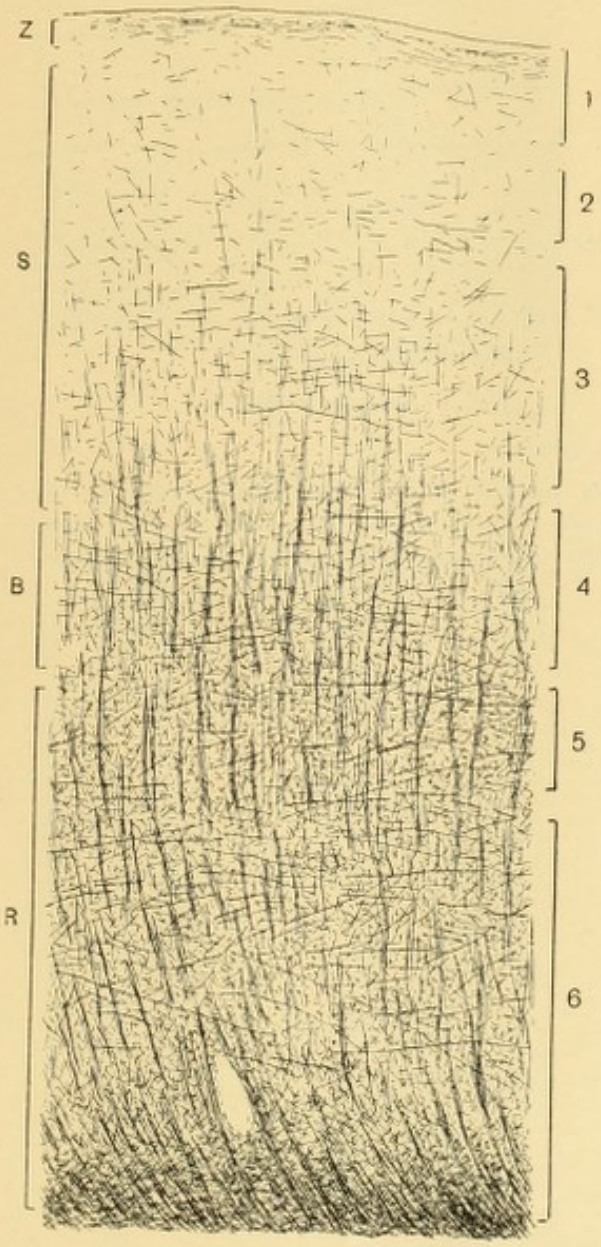

Fig. 1.

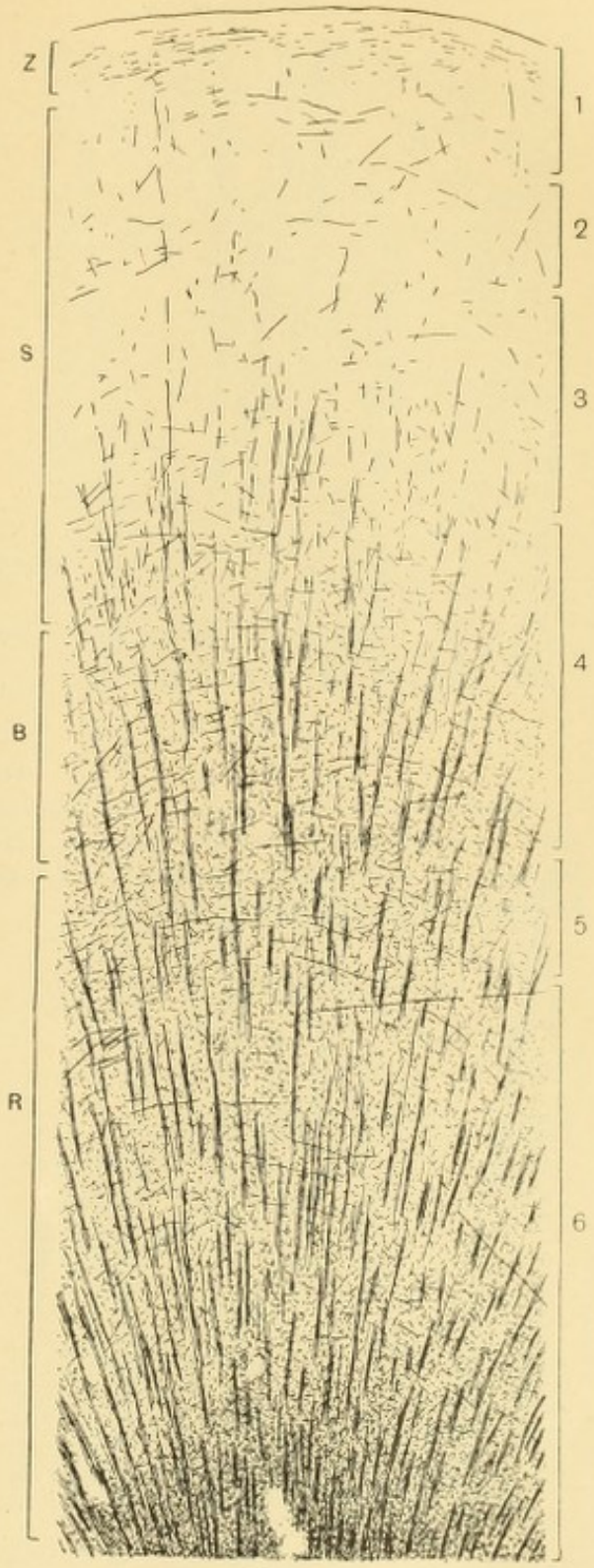

Fig. 2.

PLATE XIII.

Figure 1. Radiary zone in temporal area No. 1 (audito-sensory).
" 2. " " " " No. 2 (audito-psychic).
" 3. " " " " No. 3 (common temporal).
" 4. " " angular gyrus.

Figure 1 gives some idea of the position and number of the large fibres special to this area. Note that they shun the radiations. In figure 2 there is still a wealth of small fibres but more of large calibre. Figures 3 and 4 are alike in showing both general fibre poverty and an absence of large elements. $\times \frac{480}{1}$.

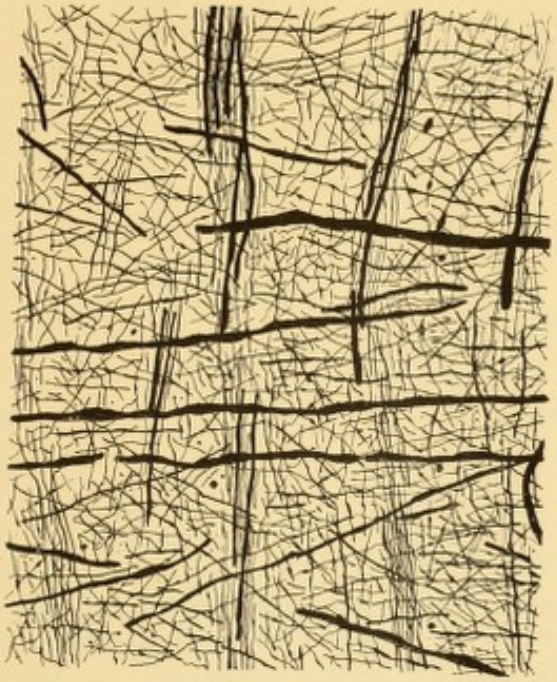

Fig. 1.

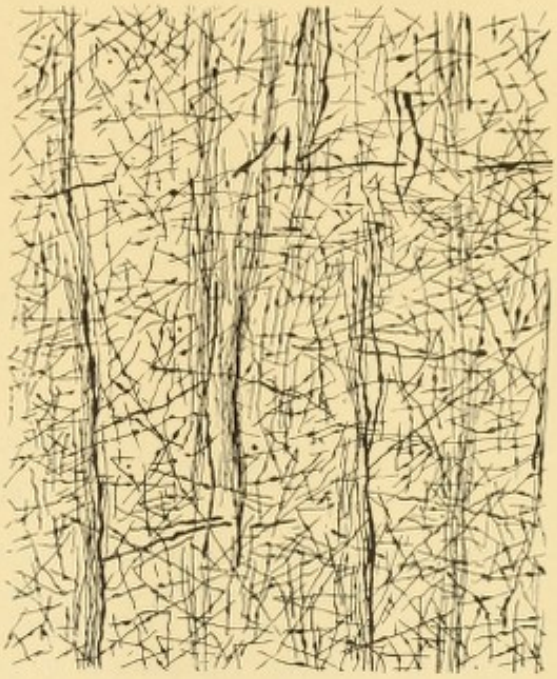

Fig. 2.

Fig. 3.

Fig. 4.

PLATE XIV.

Figure 1.

Common type of fibre arrangement in the temporal lobe.

From a transverse section of the first temporal gyrus, 3 cm. behind the anterior extremity of the lobe. Z = zonal layer. S = supraradiary layer. B = line of Baillarger. R = radiary zone.

Notice the poor fibre representation in general, the slender radiations of Meynert, the lack of medullated elements in the supraradiary layer and interradiary plexus and the absence of long transverse and oblique fibres in the radiary zone.

The right-hand numbers and brackets indicate the corresponding position of cell laminae. $\times \frac{80}{1}$.

Figure 2.

From a section through the middle of the angular gyrus. Z = zonal layer. S = supraradiary layer. B = line of Baillarger. R = radiary zone. The right-hand figures and brackets show the position occupied by corresponding cell laminae.

The arrangement in this part is illustrated to show that it does not differ markedly from the common temporal type. $\times \frac{80}{1}$.

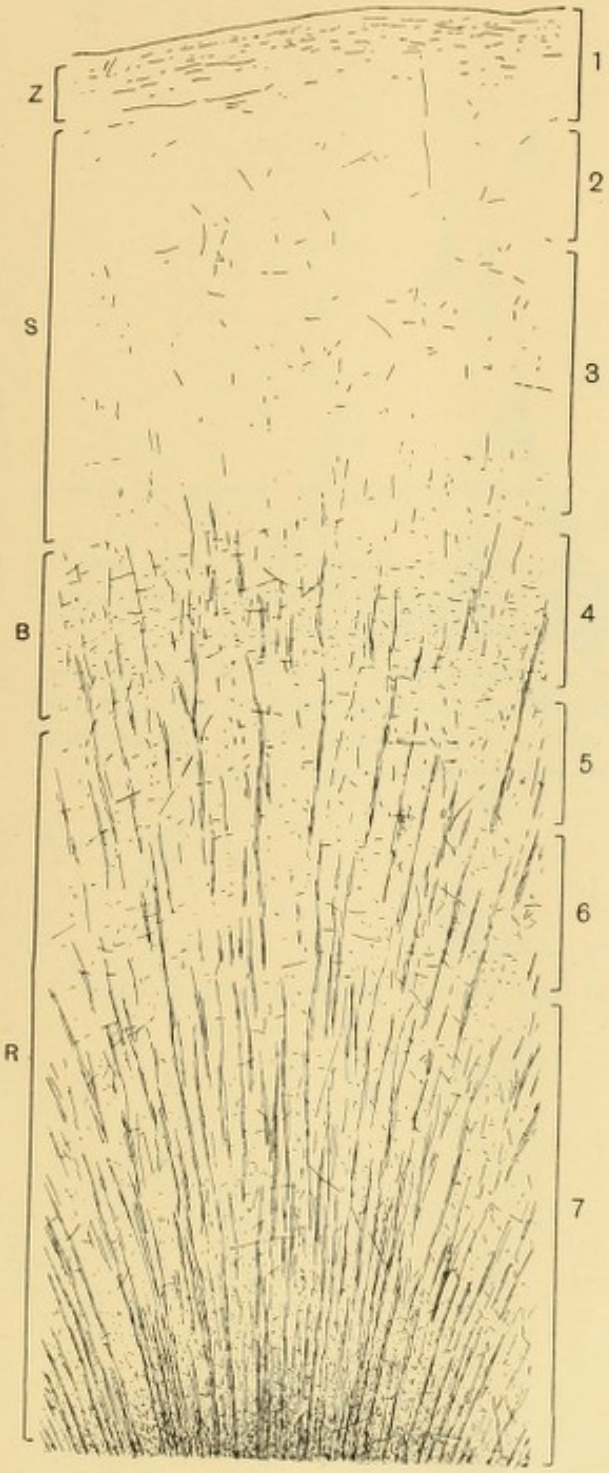

Fig. 1.

Fig. 2.

PLATE XV.

Figure 1.

Type of cell lamination in Temporal Area No. 1 (audito-sensory); the drawing is from a section of the most anterior of the transverse temporal gyri.

Layers 1, 2 and 3 call for no special remark, but attention must be directed to layer 4; it is a prominent lamina containing elements of larger size and more richly endowed with chromophilic particles than cells of the same layer in any other part of the temporal region.

An uncommonly good representation of the layer of stellate cells (5) is a characteristic feature of all temporal cortex and it is well seen here. Special note must be taken of the point that the internal or substellate layer of large pyramidal cells is virtually non-existent in this particular area; in consequence of this the layer of spindle-shaped cells assumes an unusual depth.

Low power drawing, $\times \frac{80}{1}$; high power, $\times \frac{480}{1}$.

Figure 2.

Type of cell lamination in the Audito-psychic area. $\times \frac{80}{1}$.

Compare with figure 1 and notice that the cells in layer 4 are on the whole much smaller.

Fig. 1.

Fig. 2.

PLATE XVI.

Figure 1.

General type of cell lamination in the temporal lobe (area No. 3).

From a section through the middle of the second temporal gyrus.

Compare with Plate XV. figures 1 and 2. At 4 (external layer of large pyramidal cells) the cells have suffered a marked loss in volume and depth of staining. The layer of stellate cells remains unchanged. Poor in area No. 1, better in area No. 2, the internal layer of large pyramidal cells (6) now assumes reasonable proportions; cells pertaining to this lamina are seen extending down into the fusiform layer.

Low power drawing, $\times \frac{50}{1}$; high power, $\times \frac{480}{1}$.

Figure 2.

Cell lamination in the angular gyrus.

Drawn to show that the cortex of this part does not possess a specialised lamination but resembles the common temporal type. $\times \frac{80}{1}$.

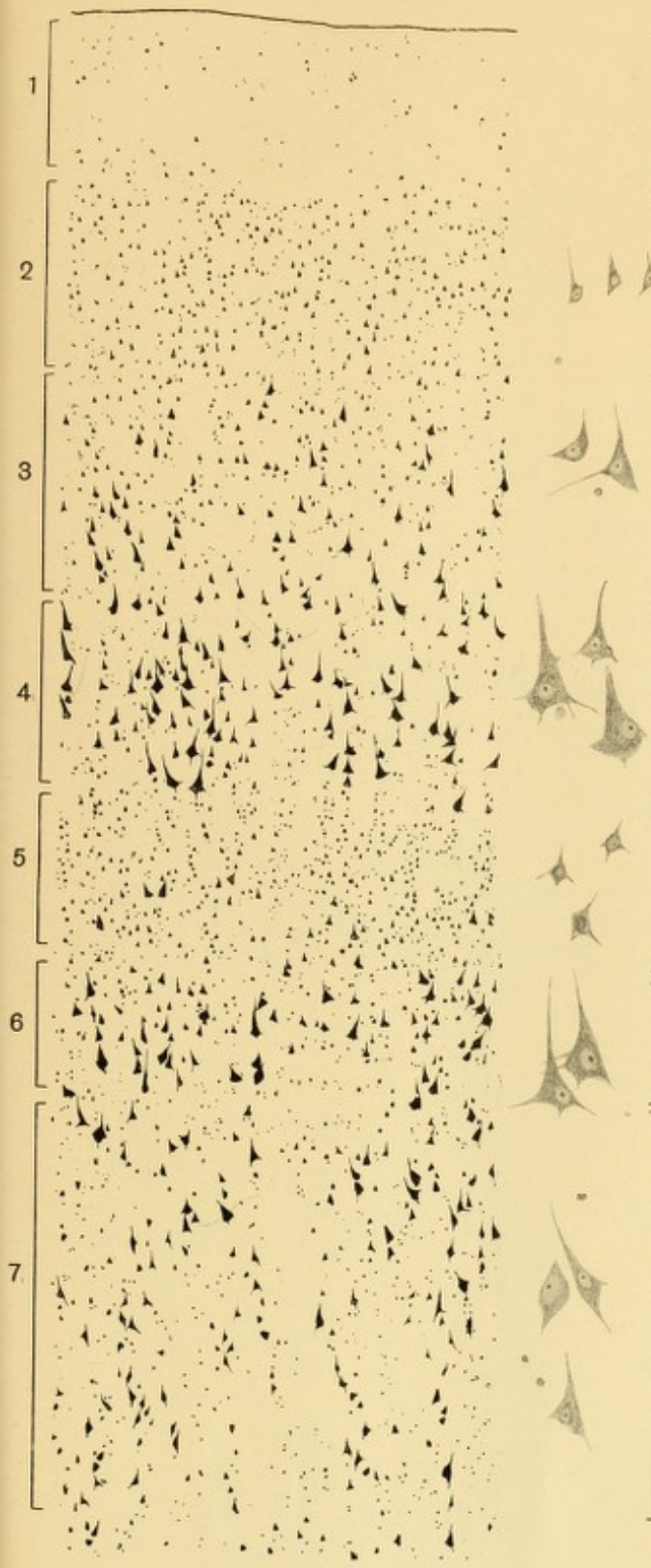

Fig. 1.

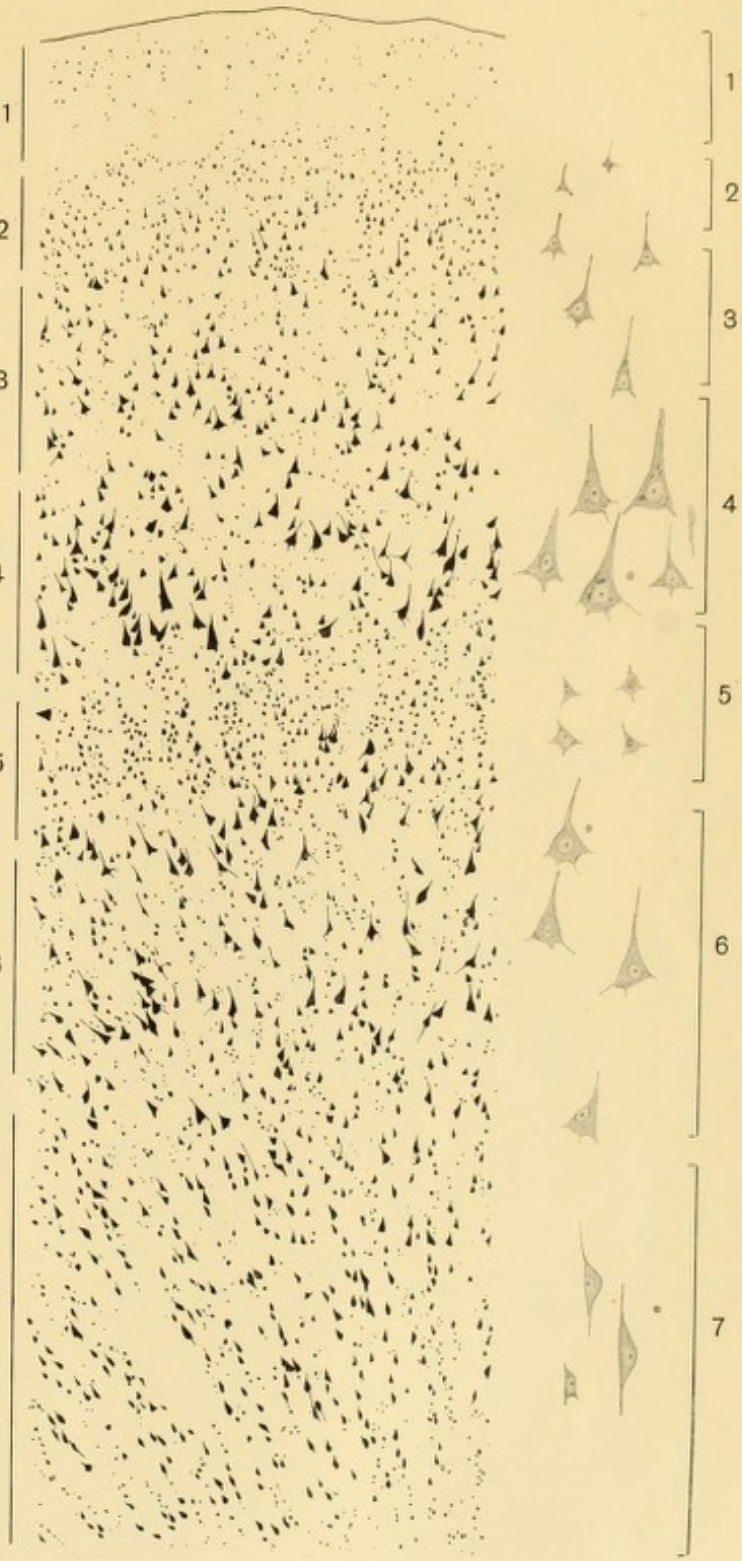

Fig. 2.

PLATE XVII.

Figure 1.

Type of fibre arrangement in the lobus pyriformis. $\times \frac{80}{1}$.

Z = zonal layer. S = supraradiary layer. B = line of Baillarger. R = radiary zone. The figures and brackets to the right indicate the corresponding position of cell layers.

From a section through as near as possible the central point of the lobule.

Figure 2.

Type of cell lamination in the lobus pyriformis.

1, plexiform layer. 2, layer containing clusters of large stellate cells. 3, layer of pyramidal cells, all more or less of equal size. In the centre of this layer a faint lamina of small stellate cells may be seen. 4, layer containing no cells. 5, elongated pyriform cells like those seen in pregenual area. 6, fusiform cells.

Low power, $\times \frac{80}{1}$; high power, $\times \frac{480}{1}$.

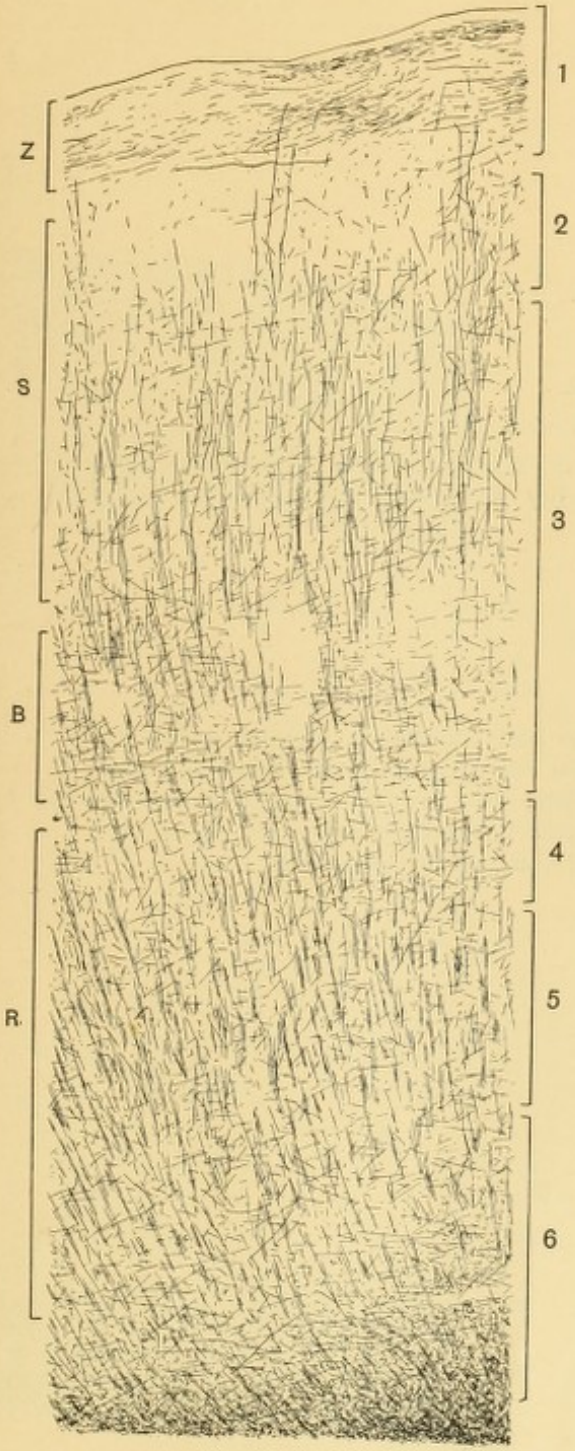

Fig. 1.

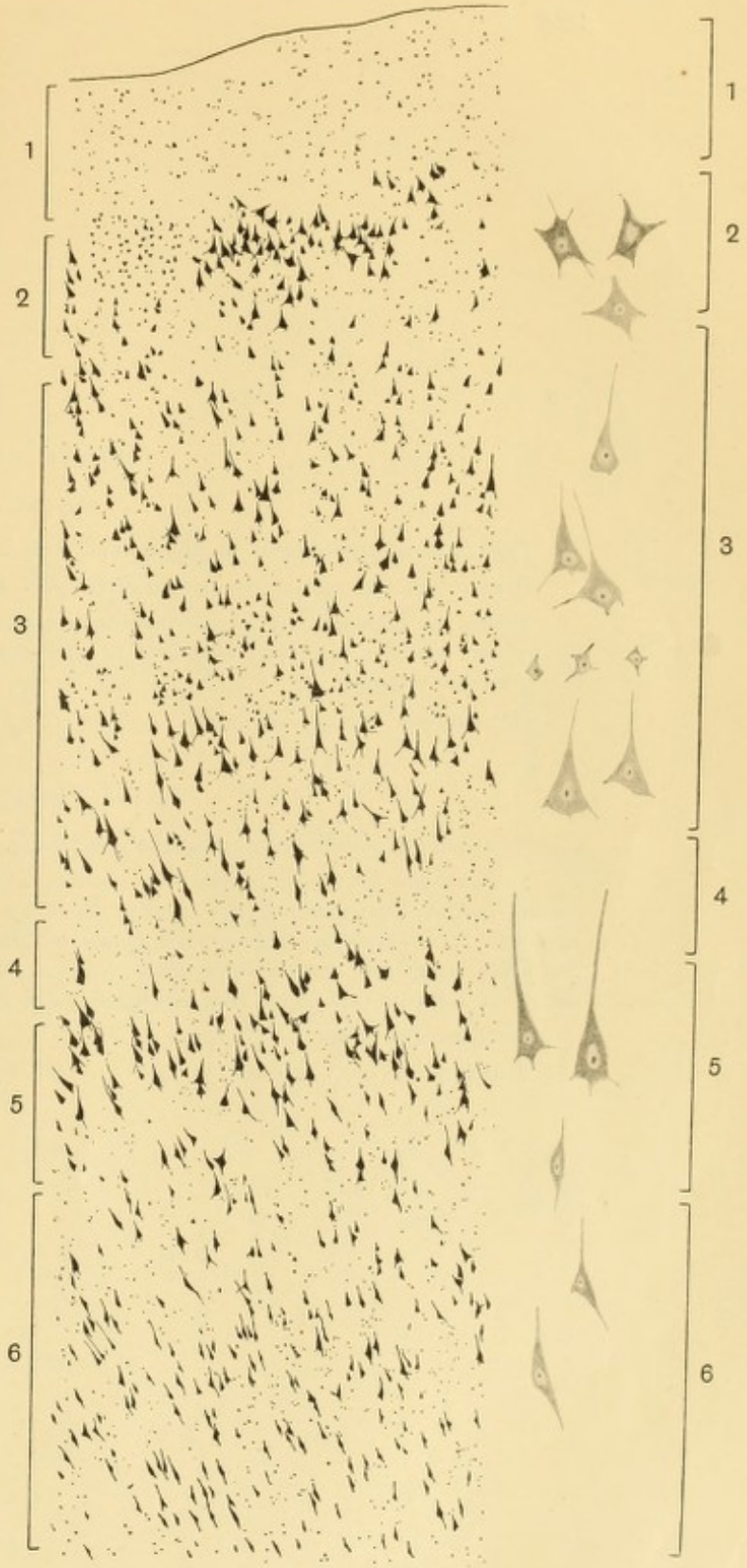

Fig. 2.

PLATE XVIII.

Figure 1.

Type of fibre arrangement in hippocampal area No. 2.

Drawn from the wall of the fissura hippocampi at its middle.

Notice the extraordinary lamina medullaris externa; the slender radiations of Meynert reaching up to that lamina; the open character of the interradiary plexus and the curious bundles of fibres cut transversely.

The numbers refer to cell layers. $\times \frac{80}{1}$.

Figure 2.

Arrangement of cells in hippocampal area No. 2.

1, plexiform layer, corresponding in position with the lamina medullaris externa. 2, described as the possible equivalent of the layer of small pyramidal cells of other parts. Note the "islet" of cells. 3, no layer of medium-sized pyramidal cells exists; their place being taken by numerous large and irregularly disposed pyramidal elements. The cells in the lower two-thirds of this layer are all of approximately equal size, stand erect, and are of elongated pyramidal form.

Compare with Plate XVII. figure 2.

Magnifications $\times \frac{80}{1}$ and $\times \frac{180}{1}$.

Fig. 1.

Fig. 2.

PLATE XIX.

Figure 1.

Common type of fibre arrangement in the gyrus fornicatus.

From a transverse section of that gyrus above the middle of the corpus callosum.

Z = zonal layer. S = supraradiary layer. B = line of Baillarger. R = radiary zone. The brackets and figures to the right indicate the corresponding position held by cell layers.

The general poverty of fibres is evident. $\times \frac{80}{1}$.

Figure 2.

Common type of cell lamination in the gyrus fornicatus.

Drawn from a section of the gyrus fornicatus above the middle of the corpus callosum.

1, plexiform layer. 2, sparsely supplied layer of small pyramidal cells. 3, medium-sized pyramidal cells. 4, large external pyramidal cells. 5, stellate layer almost unrecognisable. 6, internal large pyramidal cells. 7, fusiform cells.

Magnifications $\times \frac{80}{1}$ and $\times \frac{480}{1}$.

FIG. 1.

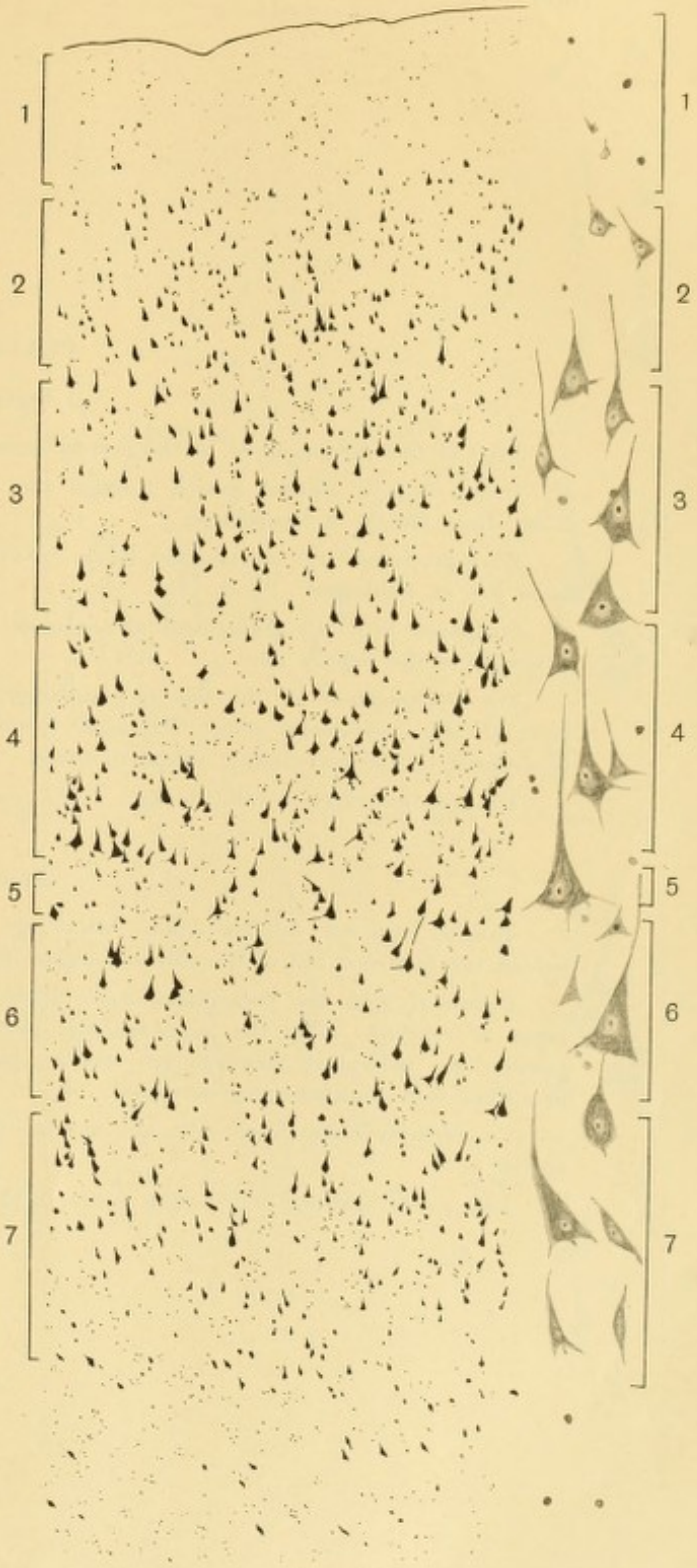

FIG. 2.

PLATE XX.

Figure 1.

Type of fibre arrangement in the parietal area.

Drawn from a sagittal section through the superior parietal gyrus 4 cm. behind Rolando and 2 cm. from margin of hemisphere.

Z = zonal layer. S = supraradiary layer. B = line of Baillarger. R = radiary zone. B 2 = reduplicated line of Baillarger.

Compared with the postcentral arrangement, Plate V., there is an evident poverty of fibres, especially in the radiary zone.

The reduplication of the line of Baillarger runs in association with the well-marked inner layer of large pyramidal cells. The same line is probably present in the postcentral cortex but is obscured by the surrounding wealth of fibres.

The numbers refer to cell-laminae. $\times \frac{80}{1}$.

Figure 2.

Parietal type of cell-lamination. Drawing taken from a section of the precuneus 2 cm. behind the upturned tail of the calloso-marginal fissure.

Compared with the postcentral types, Plate VI., a difference is not observed until the fourth layer is reached. Here the large external pyramidal cells do not form such a marked lamina, because the individual members are smaller, paler and separated by wider intervals. The layer of stellate cells continues well developed.

Considerably fewer large cells are seen at 6 and those present have also suffered in relation to size.

Low power drawing, $\times \frac{80}{1}$; high power, $\times \frac{480}{1}$.

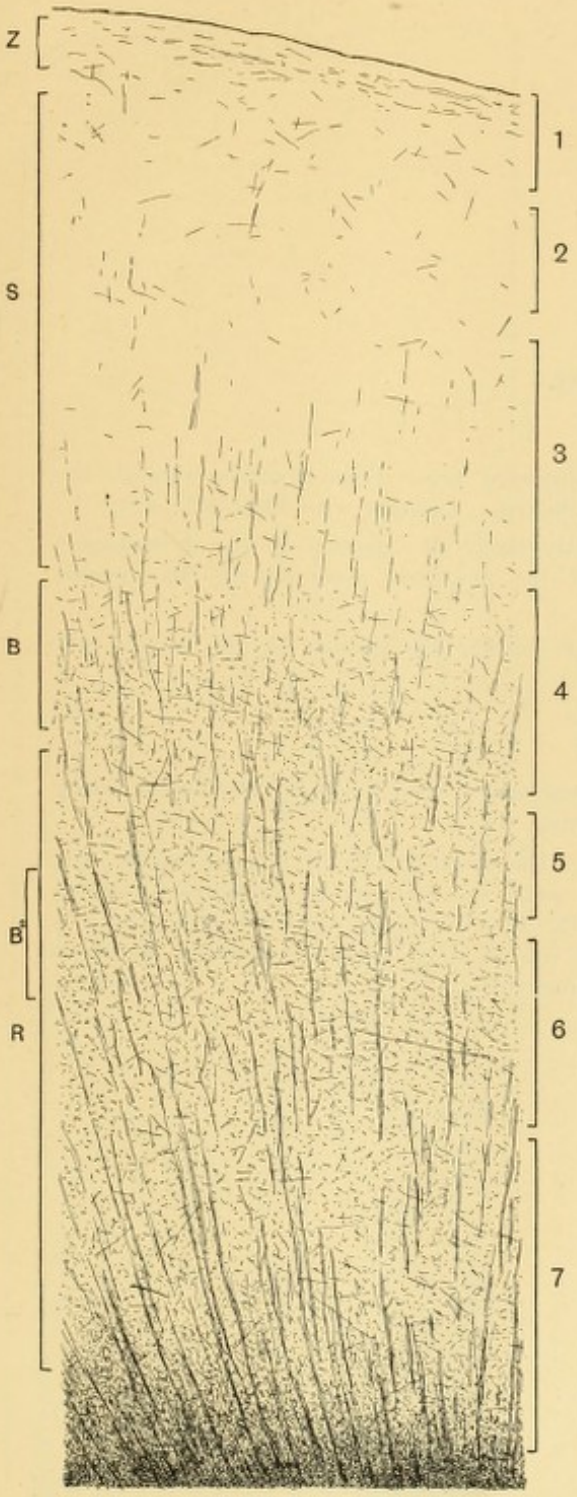

Fig. 1.

Fig. 2.

PLATE XXI.

Figure 1.

Type of fibre arrangement in the intermediate precentral area. From a section through the superior frontal gyrus, 4 cm. anterior to the fissure of Rolando. Compare with Plate III., figure 1.

Z = zonal layer; much less distinct. S = supraradiary layer. B = position of line of Baillarger. R = radiary zone. The arrangement resembles that of the precentral area but the fibre wealth is obviously less.

The right-hand figures and brackets refer to, and indicate the position of, the various cell-laminae. $\times \frac{80}{1}$.

Figure 2.

Type of cell-lamination in the intermediate precentral area. From a section showing the cortex of the base or posterior end of the middle frontal gyrus.

Layers 1, 2 and 3 call for no special comment. The external layer of large pyramidal cells (4) is remarkably well-developed and quite equal to what was seen in the precentral or motor area. As in the precentral area the stellate cells (5) do not form a distinct lamina. At 6 a considerable number of cells can be seen equal in size to those at 4, but there is an entire absence of "giant" cells. The fusiform layer (7) is uninteresting.

Low power drawing, $\times \frac{80}{1}$; high power, $\times \frac{480}{1}$.

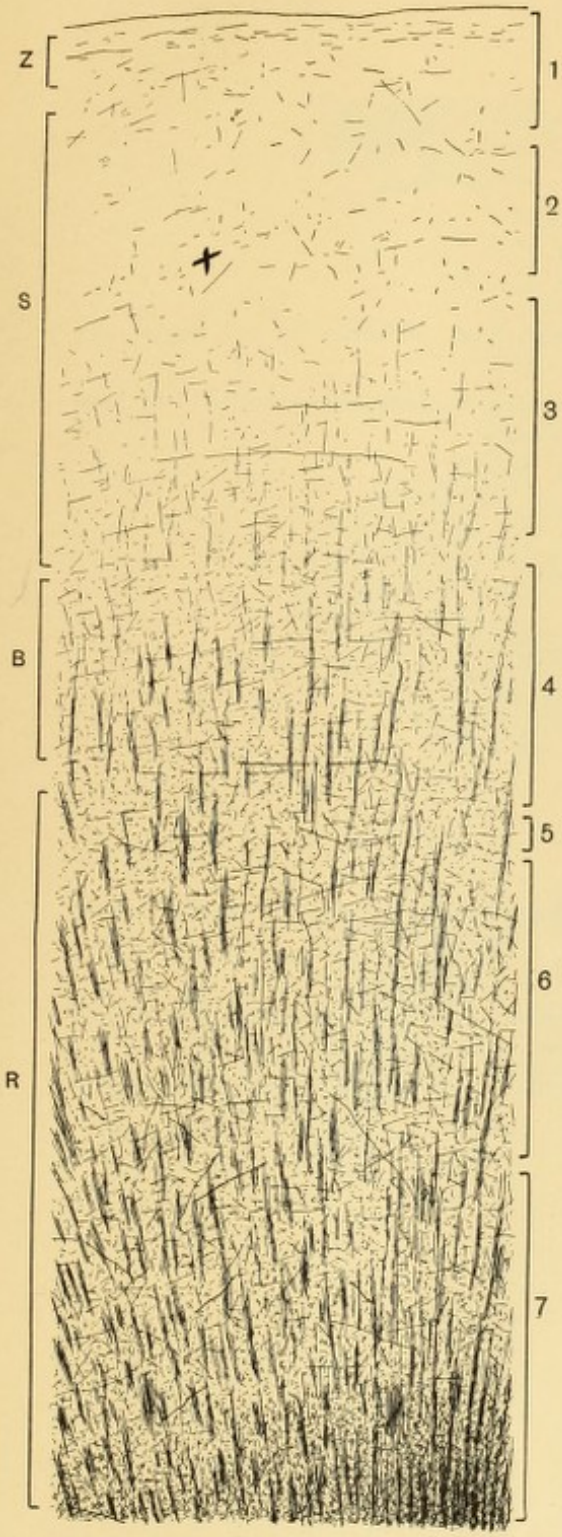

Fig. 1.

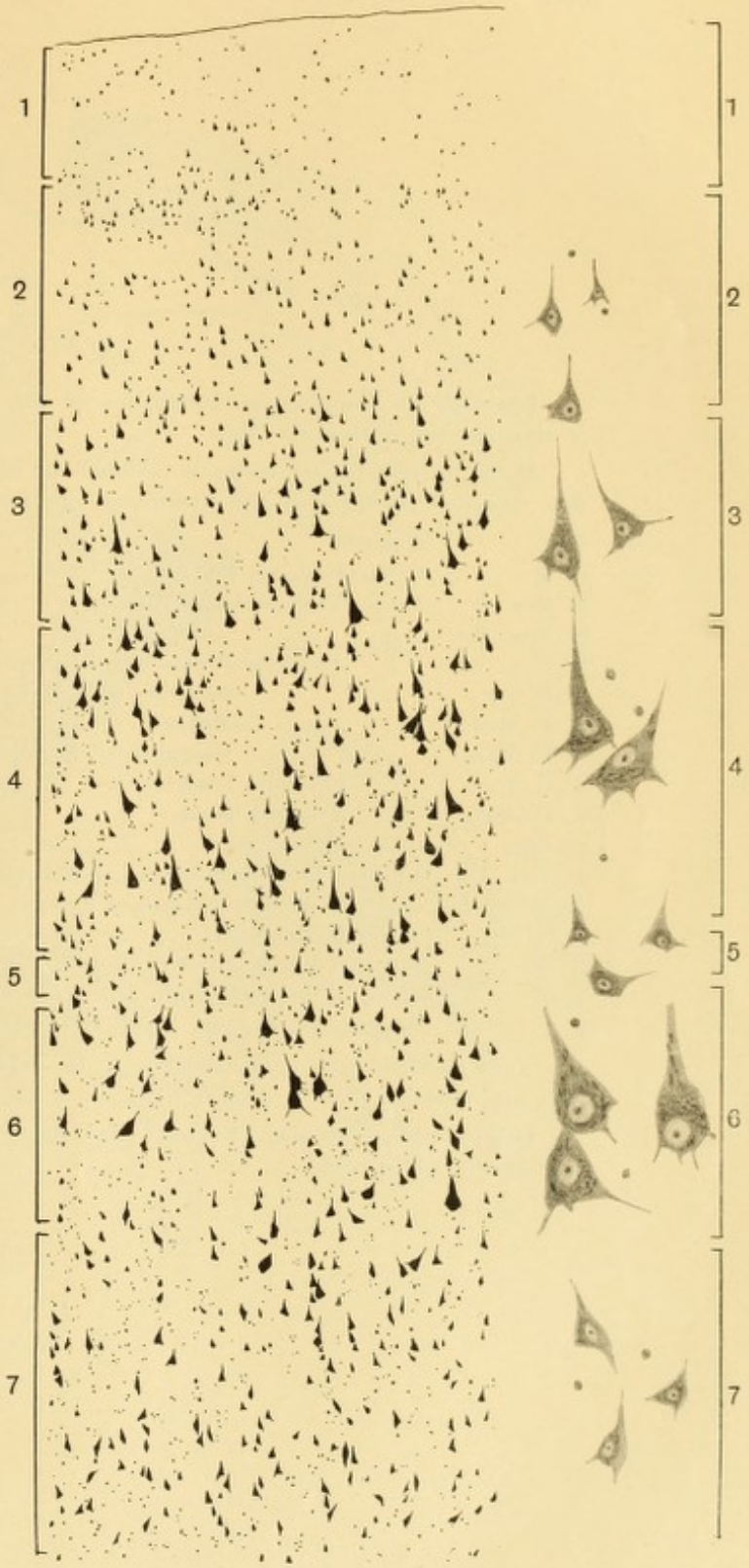

Fig. 2.

PLATE XXII.

Drawings to illustrate the distribution of the different types of cortex in the frontal lobe of Man and the Anthropoid Ape.

Motor or "precentral" cortex is indicated by cross-hatching, "intermediate precentral" by large dots, "frontal" by fine dots and "prefrontal" by small circles.

Rol.	=	Rolando.
C. M.	=	Calloso-marginal Fissure.
S. Prec. S.	=	Sulcus Precentralis Superior.
S. Prec. Inf.	=	,, ,, Inferior.
S. F. 1.	=	,, Frontalis Primus vel Superior.
S. F. 2.	=	,, ,, Secundus vel Inferior.
S. F. Med.	=	,, ,, Medius.
S. F. Marg.	=	,, ,, Marginalis of Wernicke.
S. O. T.	=	,, Orbitalis Transversus.
S. Fr. Orb.	=	,, Fronto-orbitalis.
S. Olf.	=	,, Olfactorius.
I. T. R.	=	Inferior Transverse Fissure of Rolando.
A. A. S.	=	Anterior Ascending Limb of Sylvius.
A. H. S.	=	Anterior Horizontal ,, ,, ,,
A. S.	=	Anterior Sylvian Fissure of Ape. The figures are placed on exposed "insular" cortex.
E. S.	=	External Sagittal Fissure.
C.	=	Suggested homologue of Sulcus Cruciatus.

Note the similarity in distribution of the "Intermediate Precentral" cortex in Man and the Ape, and especially how it spreads down on to the Orbital surface.

Observe that both the "Frontal" and the "Prefrontal" areas are more extensive in Man than in the Anthropoid.

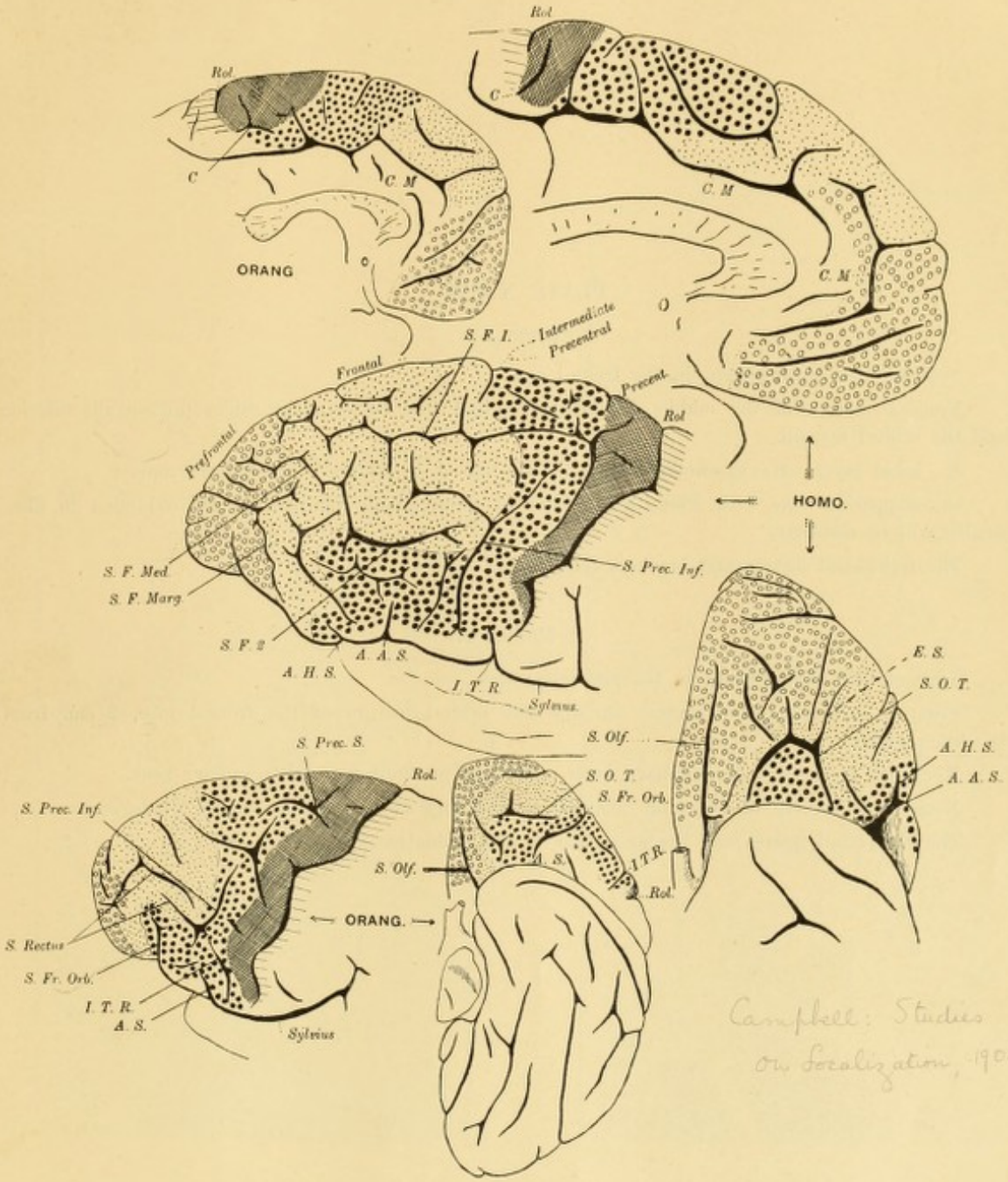

Campbell: Studies on Localization, 1905

PLATE XXIII.

Figure 1.

Type of fibre arrangement in the frontal area.

From a section of the middle frontal gyrus, half way between the sulcus precentralis inferior and the orbital margin.

Z = zonal layer. S = supraradiary layer. B = line of Baillarger. R = radiary zone.

On comparing this with Plate XXI., figure 1 (intermediate precentral), the reduction in fibre wealth will be manifest.

The right-hand figures and brackets refer to cell layers. $\times \frac{80}{1}$.

Figure 2.

Type of fibre arrangement in the prefrontal area.

From a vertical sagittal section through the orbital margin of the frontal lobe, 2 cm. from the inner surface.

Z = zonal layer. S = supraradiary layer. B = line of Baillarger. R = radiary zone.

Notice the poverty of fibres on comparison with any other drawing in the whole series.

The right-hand figures and brackets refer to cell-lamination. $\times \frac{80}{1}$.

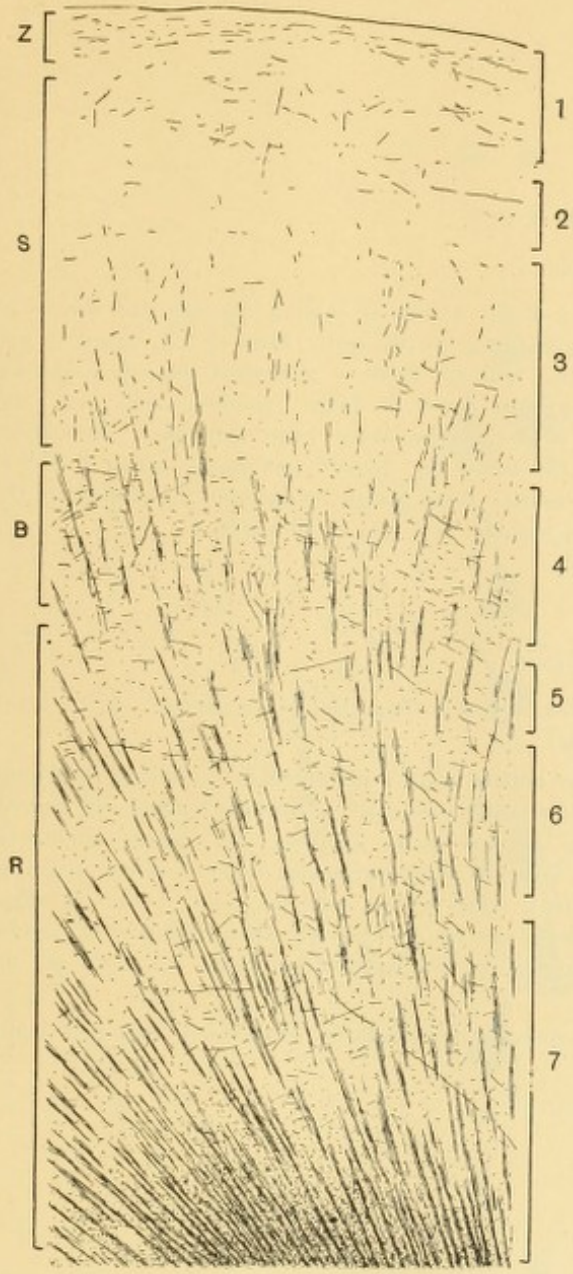

Fig. 1.

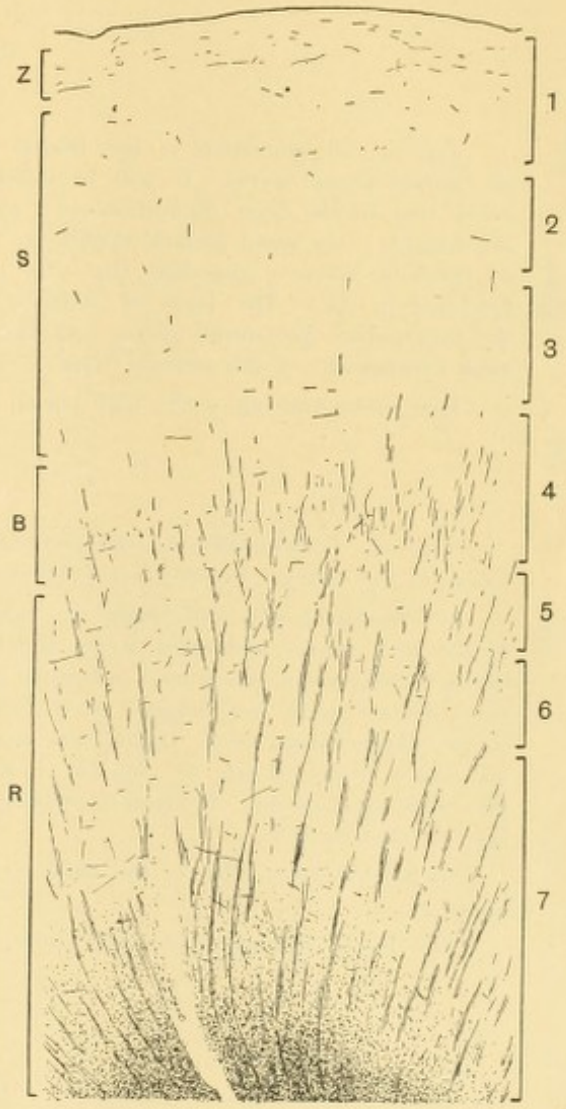

Fig. 2.

PLATE XXIV.

Figure 1.

Type of cell-lamination in the frontal area. From a section passing through the middle of the second frontal gyrus. It will be interesting to compare this with Plate XXI., figure 2, and notice that in the layer of medium-sized pyramidal cells (3) there is a marked numerical increase of elements; the same remark applies to the external layer of large pyramidal cells (4). But it must be specially observed that the cells of the latter layer have suffered a pronounced reduction in size. The layer of stellate cells (5) holds far greater prominence than it did in the intermediate precentral cortex. Another differential point, almost of greater importance, is the weak development of the internal layer of large pyramidal cells (6) in this area.

Low power drawing, $\times \frac{80}{1}$; high power, $\times \frac{480}{1}$.

Figure 2.

Type of cell-lamination in the prefrontal area. Section from the outer surface of the hemisphere at the extreme anterior end. (Frontal pole.)

On comparing this with figure 1, it will be noticed that while there is no obvious difference in the first, second and third layers, the large external pyramidal cells (4) are markedly altered, having undergone a pronounced reduction in size as well as in number. The stellate lamina (4) is as distinct as it was before. At 6 (internal layer of large pyramidal cells) elements deserving of the distinguishing term "large" are non-existent. Still a few cells are seen similar in shape and almost equal in size to those at 4, and these are certainly larger than surrounding bodies. The weak development of layer 6 probably accounts for the apparent increase in depth of the layer of fusiform cells.

Of all the areas, this is the most poorly represented as regards both nerve cells and nerve fibres.

Low power drawing, $\times \frac{80}{1}$; high power, $\times \frac{480}{1}$.

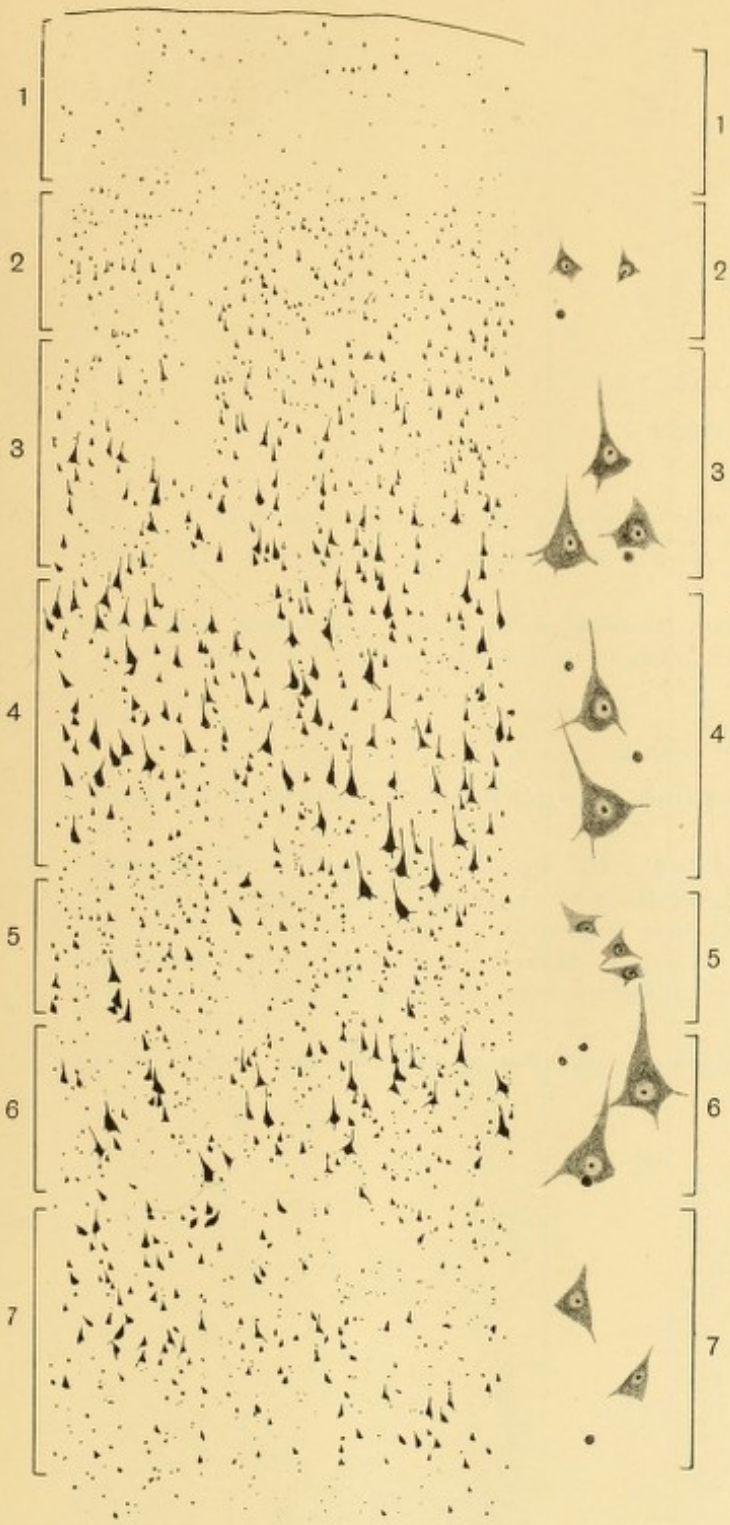

Fig. 1.

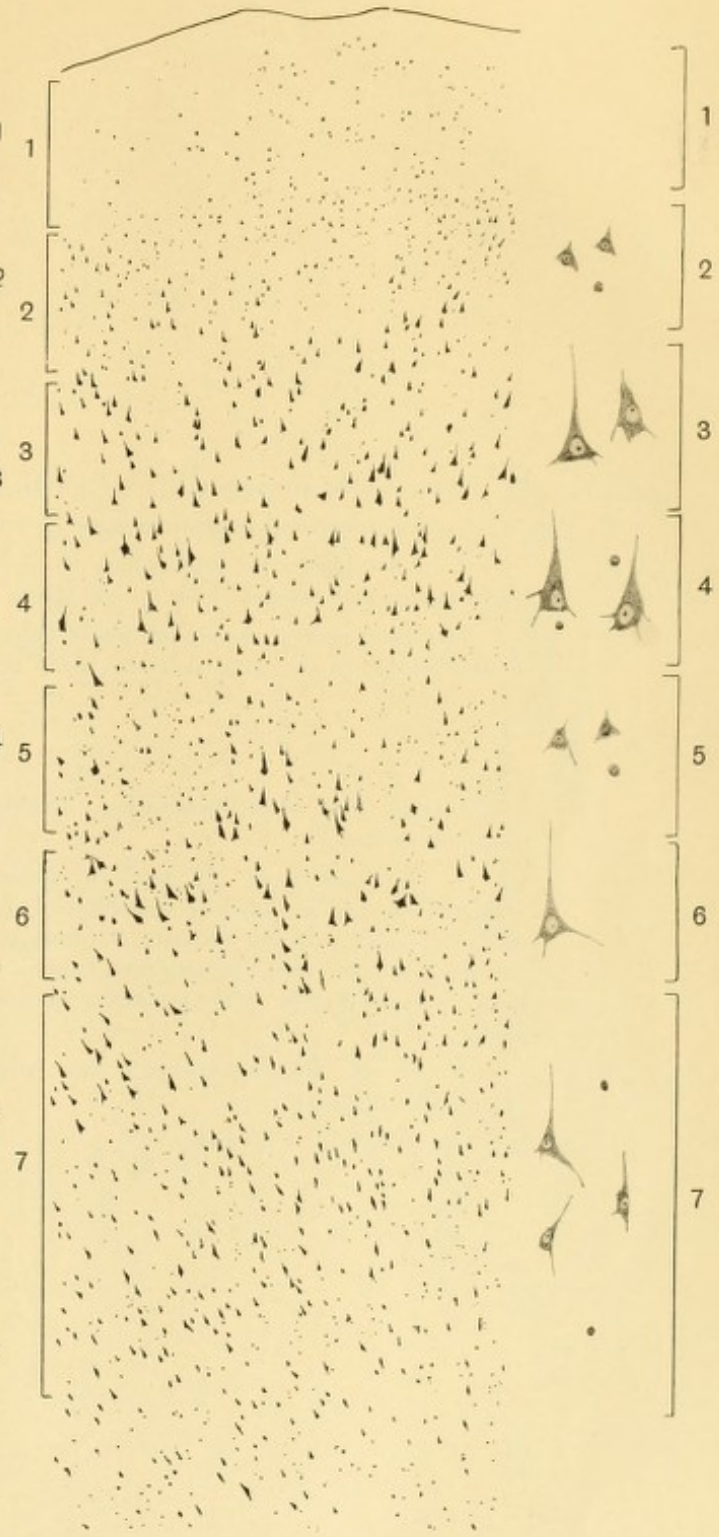

Fig. 2.

PLATE XXV.

Figure 1.

Type of fibre arrangement in the insula.

From a transverse section through the middle of the gyrus centralis anterior insulae.

Z = zonal layer. S = supraradiary layer. B = line of Baillarger. R = radiary zone. The right-hand figures and brackets refer to cell layers.

The poor general supply of fibres suggests functional unimportance. The marked zonal layer is attributable to the truth that the insula is a covered part and comparable with a sulcus. $\times \frac{80}{1}$.

Figure 2.

Insula. Type of cell-lamination. Drawing from a section immediately anterior to the sulcus centralis insulae.

1, plexiform layer. 2, small pyramidal cells. The apparent great depth is due to slight obliquity of the section. 3, medium-sized pyramidal cells. 4, external large pyramidal cells. It may be noted that the majority of these are little larger than the cells in layer 3. 5, the layer of small stellate cells, is indefinite, and its members encroach on adjacent layers. 6, internal large pyramidal cells. The prevailing element is slightly larger than that in layer 4. 7, fusiform cells.

Notice the difference between this arrangement and that in the transverse temporal gyri. Plate XV., figure 1.

Magnifications $\times \frac{80}{1}$ and $\times \frac{480}{1}$.

Fig. 1.

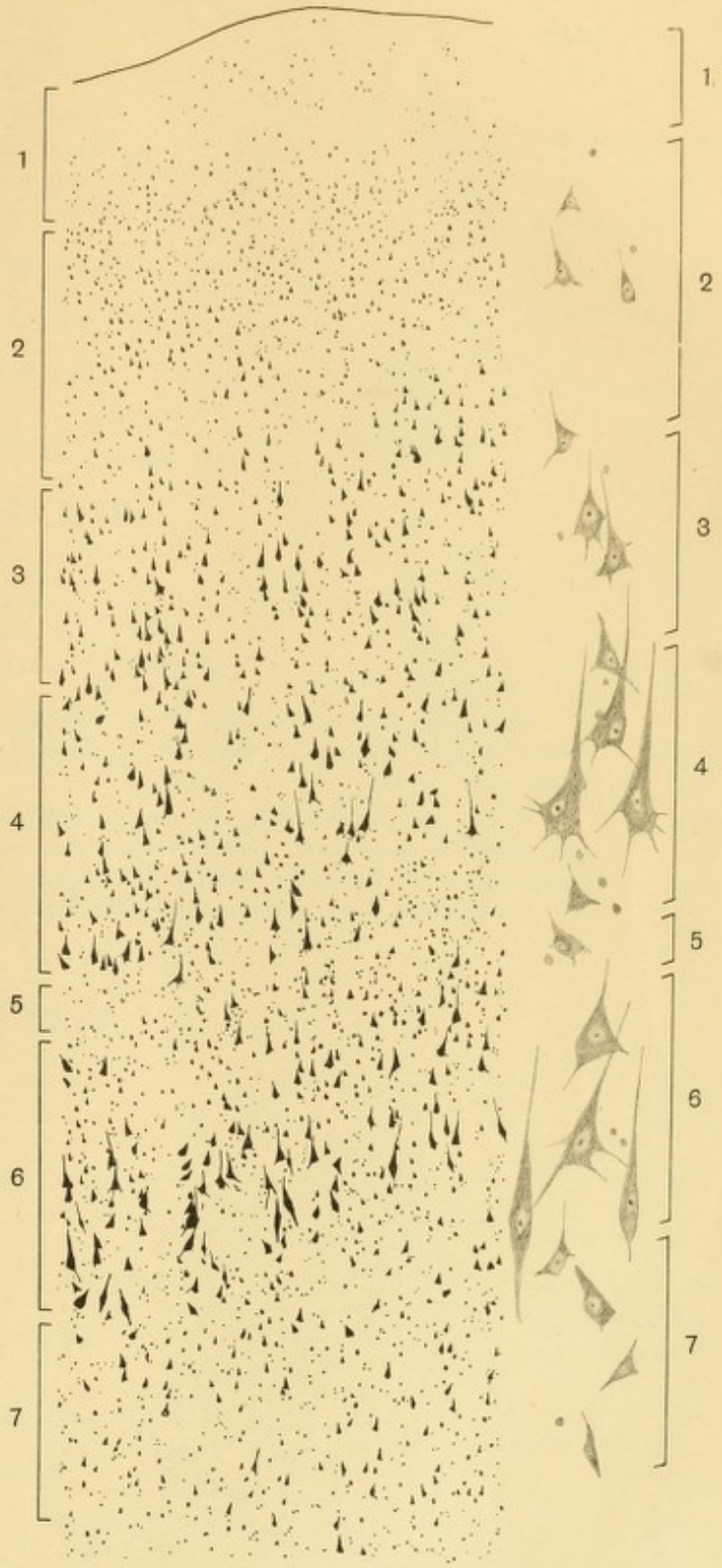

Fig. 2.

PLATES I. AND II. (*Addendum.*)

Orthogonal projection outlines of the external, internal, superior and inferior surfaces of the brains of Felis, Canis, and Sus, with superimposed plans of the distribution of the various areas described in the text.

It must be understood, again, that a surface diagram fails to convey an exact impression of the extent of many areas, because cortex lying within fissures cannot be indicated. This defect applies chiefly to the cortex clothing the calcarine, intercalary, cruciate, coronal and lateral sulci, and for details of these hidden relations the reader is referred to the text.

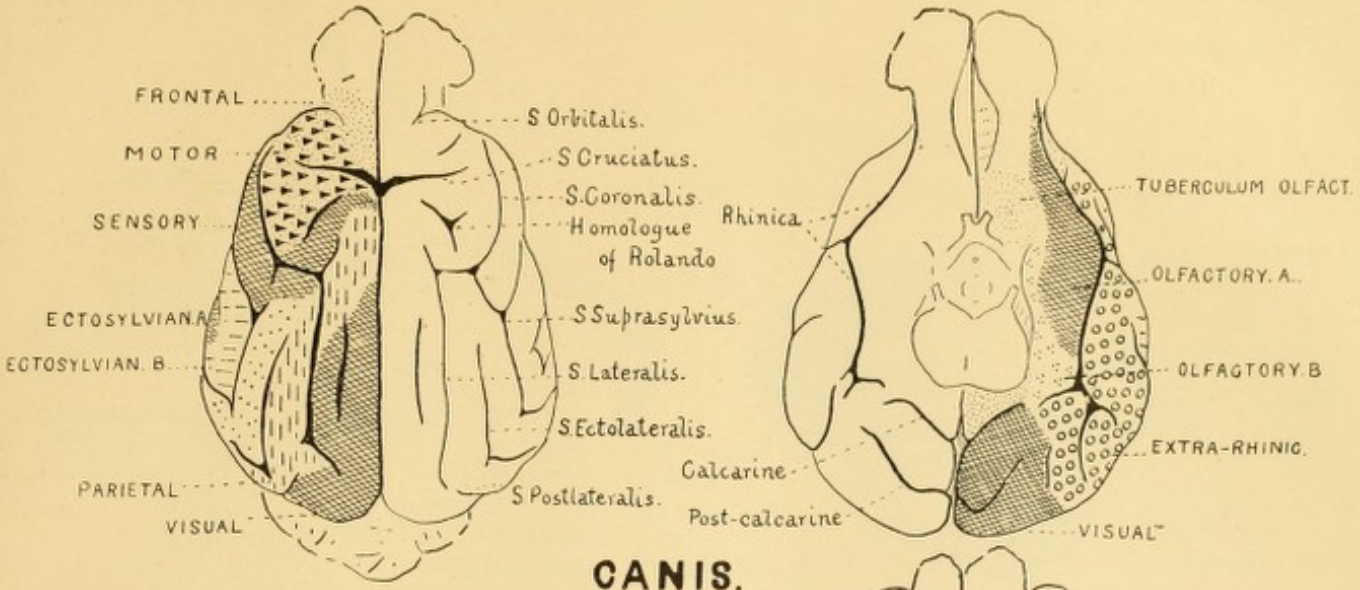

CANIS.

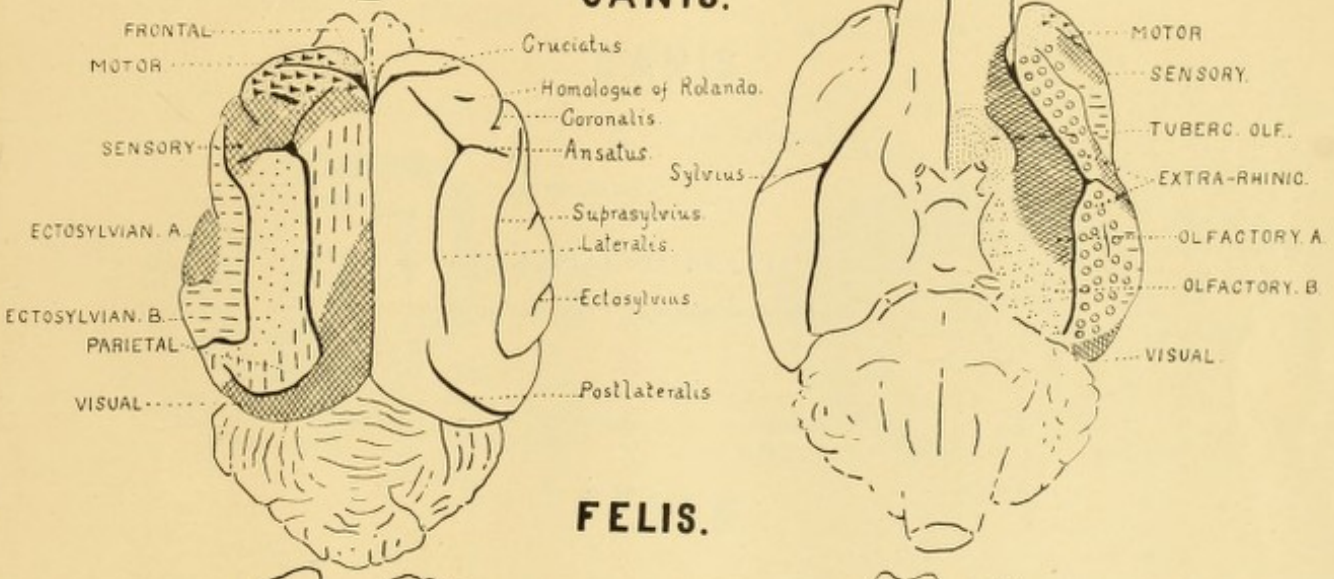

FELIS.

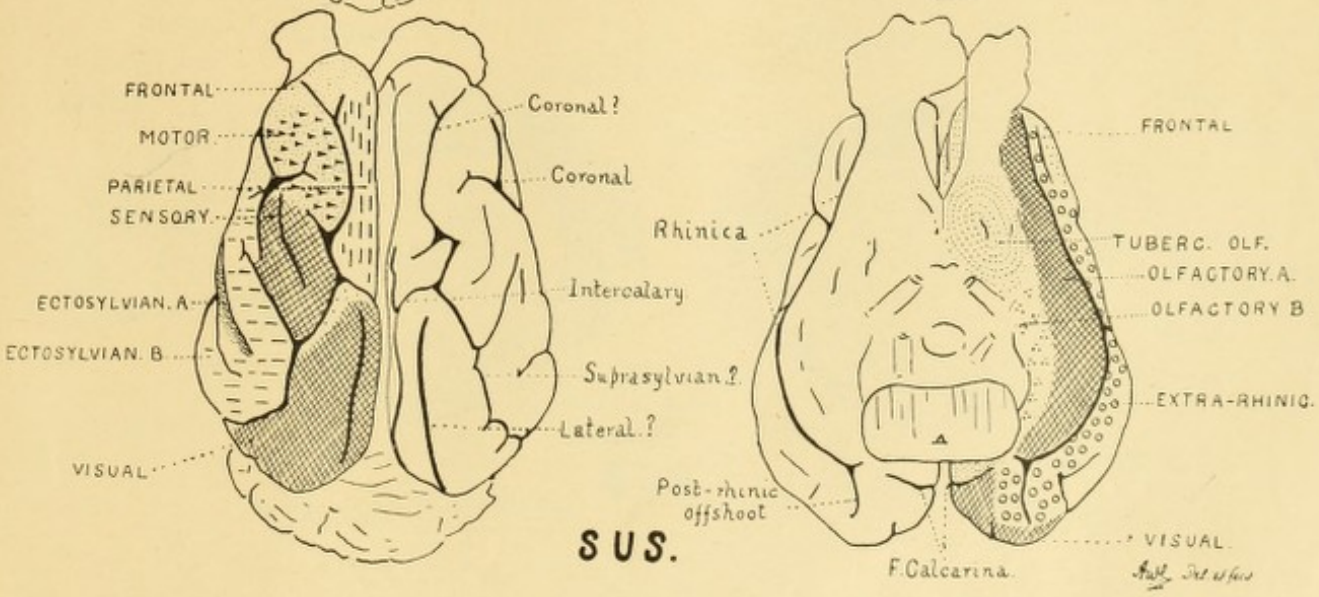

SUS.

PLATE II. (*Addendum.*)

For explanation of Plate, see p. 342.

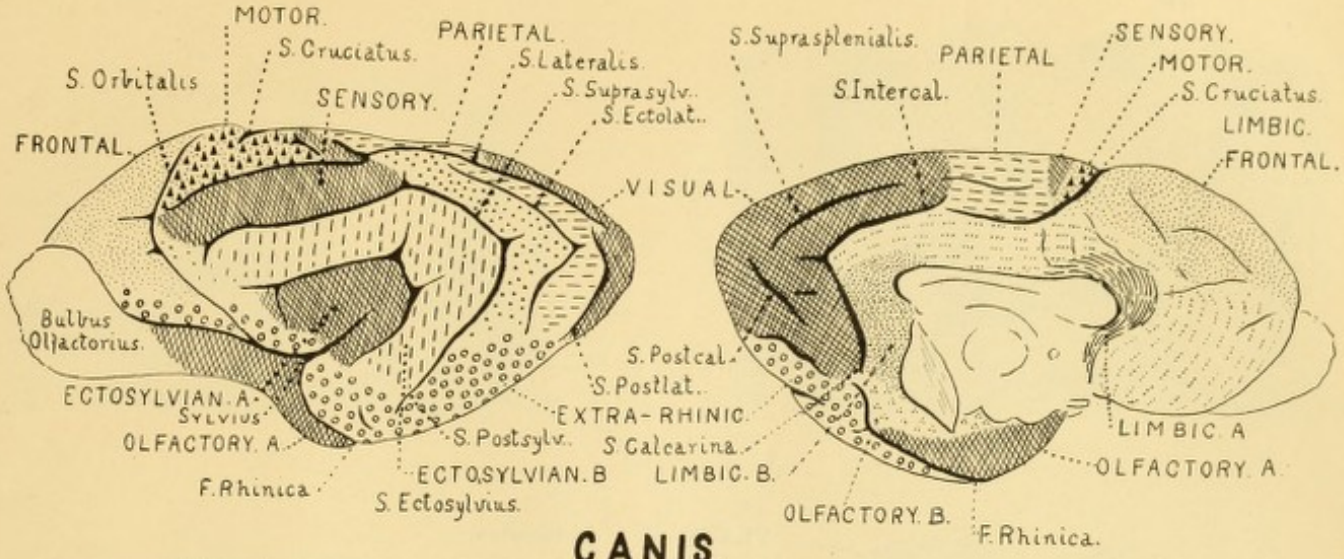

CANIS.

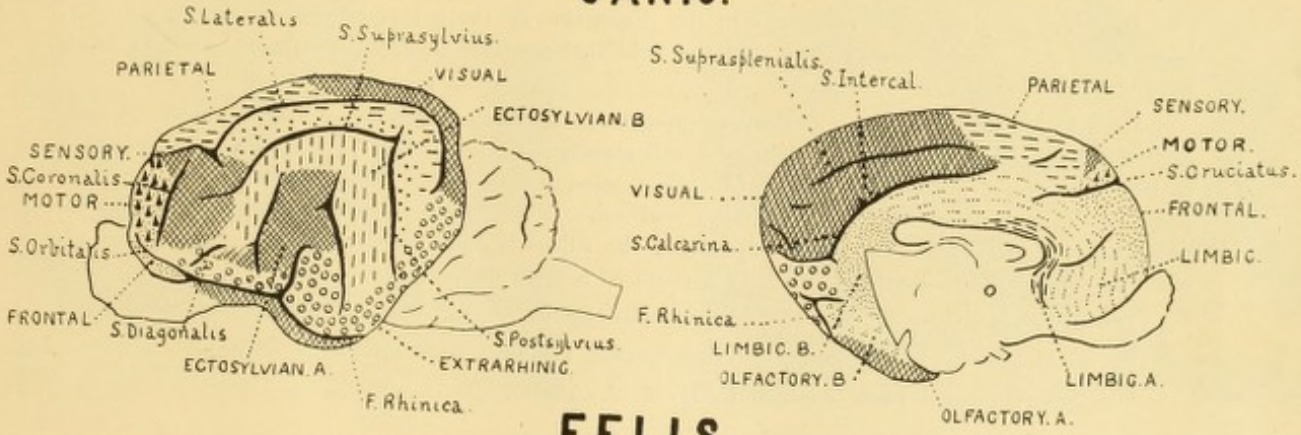

FELIS.

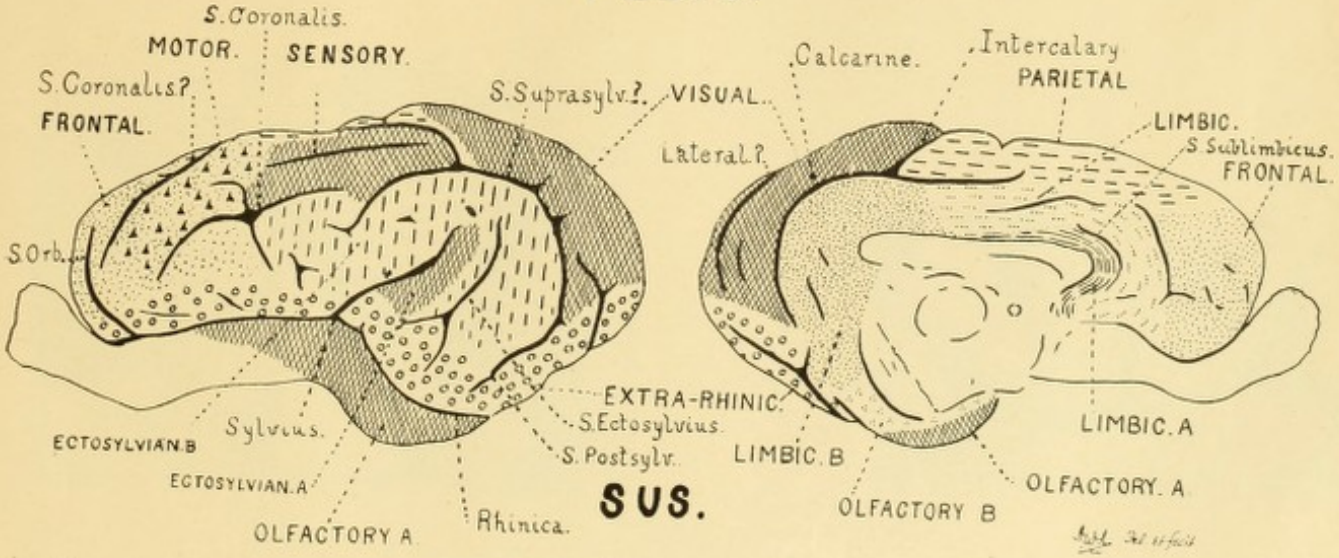

SUS.

C.

PLATE III. (*Addendum.*)

Drawings to show some variations in the disposition of the sulcus cruciatus hominis. All have been made from right hemispheres, and the field includes the lobulus paracentralis and the hinder part of the callosomarginal sulcus.

In drawing 1, the sulcus cruciatus appears as a vertical indenture; in 2, it is triradiate and the lower limb attempts to join the callosomarginal sulcus; in 4, it is long and deep and incises the margin of the hemisphere (doubtless some anatomists will see in this a typical sulcus precentralis marginalis, but as surely they will concede that the marginal constituent in the precentral sulcal system is most unstable); in 5, the sulcus is again deep and effects a true junction with the callosomarginal sulcus; in 6, it appears as a mere dimple.

The interrupted line encloses the area occupied by Betz cells.

By inlaying strips of cotton wool during fixation the sulci were artificially widened.

For these drawings I am indebted to Mr F. J. Abram.

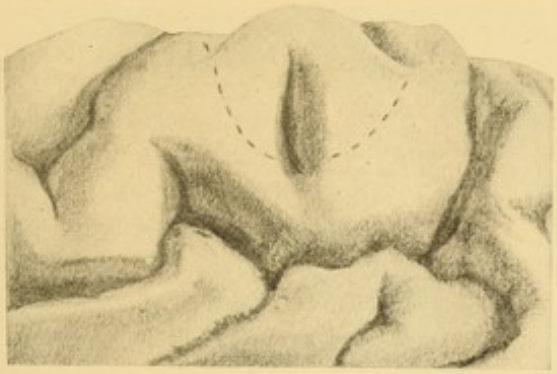

1

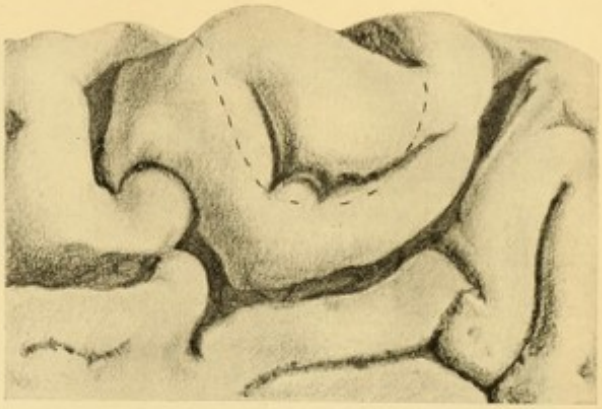

2

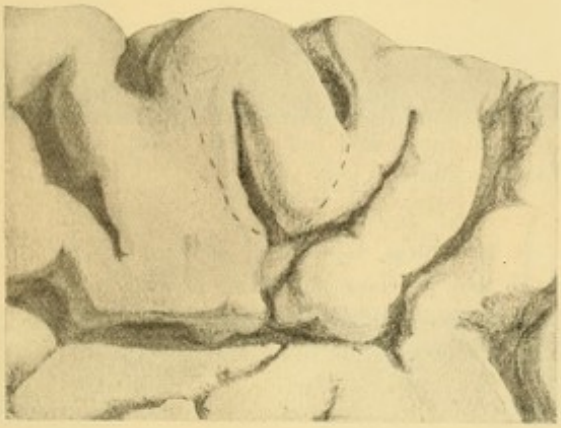

3

4

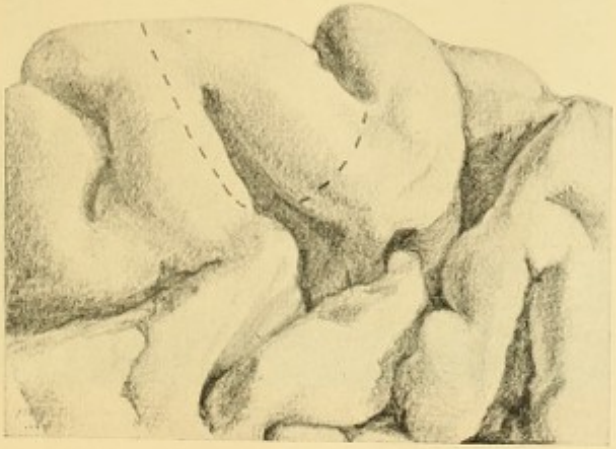

5

6

PLATE IV. (*Addendum.*)

Series of microphotographs.

1. From a section of the marginal gyrus of Sus; to show the prominent layer of polymorphous cells usurping the place usually occupied by small pyramidal cells. The great depth of the first, or plexiform layer may also be noticed. Thionin staining. $\times \frac{80}{1}$.

2. The same layers, more highly magnified. $\times \frac{300}{1}$.

3. From a transverse section of the lower part of the sulcus lateralis (?) of Sus, stained for nerve fibres. Illustrating the modified and interrupted line of Kaes curving in U form round the floor of the sulcus. $\times \frac{80}{1}$.

4. One of the fasciculi illustrated in the last photograph, more highly magnified. $\times \frac{300}{1}$.

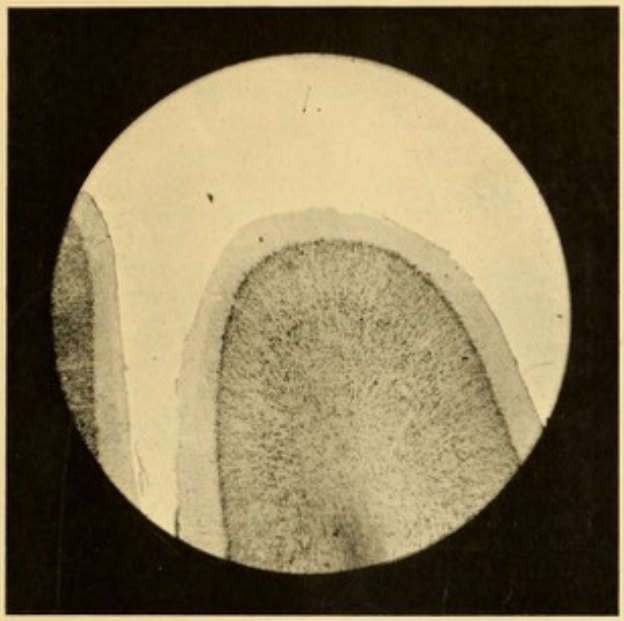

1

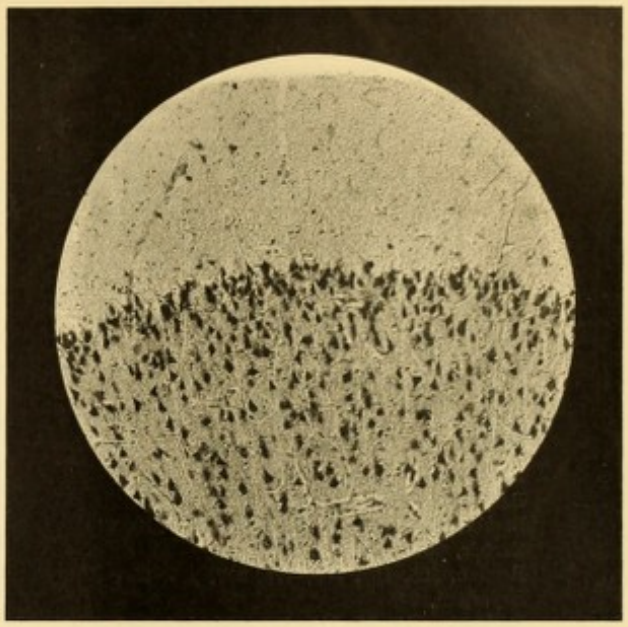

2

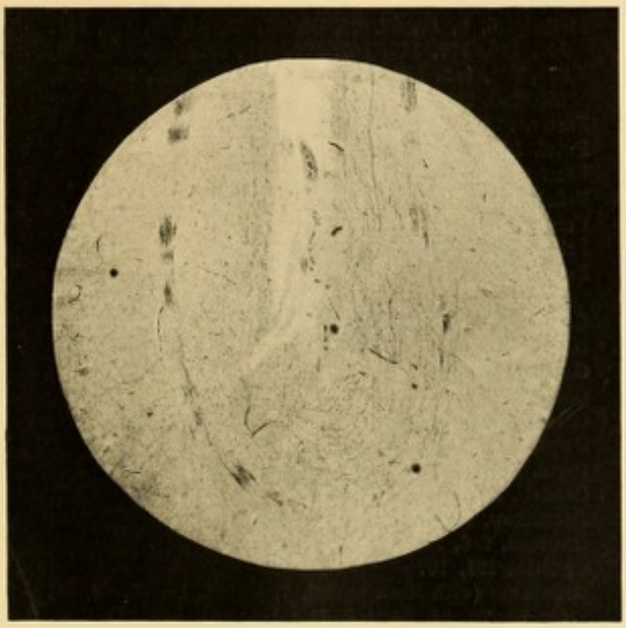

3

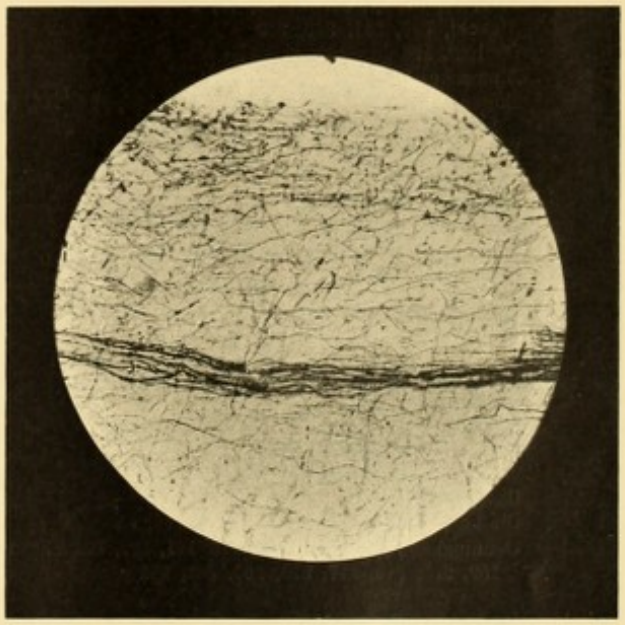

4

INDEX OF AUTHORS.

Acquisto (with Pusateri), 50, 65
Anderson, 191, 197
Andriezen, 5
Anton, 173
Apathy, 10, 18
Arndt, 14, 15
Arnold, 14, 141, 193

Baillarger, 11, 15
Ballet (with Faure), 49, 66
Barker, 110, 141, 148, 167, 176, 197, 219, 230
Bartels, 191, 198
Bastian, 105, 164, 165, 174, 217, 225, 226, 230
Bayerthal, 249
Bechterew, 13, 97, 111, 167, 191, 194, 197, 274
Beevor (with Horsley), 174, 218, 229, 239
,, (with Jackson), 191, 197
Berger, 9, 136, 144, 148
Berlin, 15
Bernhardt, 205
Bethe, 10, 18
Betz, 15, 31, 33, 34, 63, 65, 73, 115, 144, 193
Bianchi, 240, 241, 248, 249
Bischoff, 123
Blumenau, 183, 197
Bolton, 115, 119, 120, 121, 125, 135, 136, 143, 144, 146, 147, 168, 227, 230, 244, 245, 248, 249, 280, 291
Botazzi, 112, 147
Bregmann, 83, 110
Broadbent, 168, 226
Broca, 175, 191, 195, 197, 221, 283
Brodmann, 10, 18, 36, 61, 66, 111, 251, 260, 277, 291
Bruns, 243, 249
Brückner, 10, 19
Burdach, 142

Calleja, 175, 193, 197
Chaillou, 135
Charcot, 142
,, (with Marie), 39, 65
,, (with Pitres), 97, 101, 111
Churton, 191, 197
Clarke (with Lewis), 8, 18, 31, 32, 63, 65
Cunningham, 21, 22, 23, 66, 118, 121, 122, 123, 125, 147, 159, 215, 216, 217, 229, 260, 281, 291

Darkschewitch, 83, 110
Dejerine, 9, 82, 97, 110, 139, 141, 142, 148, 164, 167, 173, 183, 197, 220, 230, 257
,, (with Serieux), 164, 174
Döllken, 84, 111, 198, 219, 284, 291
Donaggio, 10, 18
Dotto (with Pusateri), 49, 66
Durante, 83, 99, 105, 111, 205, 208
Duret, 136

Eberstaller, 119, 121, 123, 124, 130, 147, 215, 216, 229, 260
Ecker, 120, 121, 130, 159, 203
Edgren, 166, 174
Edinger, 4, 6, 10, 12, 13, 14, 19, 147, 192, 198
Emminghaus, 13
Exner, 6, 11, 14

Faure (with Ballet), 49, 66
Ferguson, 164, 173
Ferrannini, 249
Ferrier, 65, 97, 101, 106, 109, 111, 133, 137, 147, 161, 162, 165, 173, 190, 195, 197, 217, 239, 240, 241, 248, 249
,, (with Turner), 100, 111, 167
Flatau, 10, 18
Flechsig, 6, 9, 18, 62, 66, 80, 81, 83, 84, 99, 110, 140, 142, 145, 146, 148, 167, 169, 179, 193, 196, 197, 203, 206, 207, 218, 219, 220, 229, 243, 244, 248, 249, 251, 256, 260, 285, 291
Foster, 226
Fovel, 142
Förster, 104, 136, 137, 147
Fränkel, 104
Freund, 139
Friedländer (with Wernicke), 173
Fuchs, 14

Gehuchten, van, 10, 19, 47, 65, 83, 110
Gennari, 6, 11
Gerwer, 133, 147
Giacomini, 180, 183
Goldscheider, 10, 18
Golgi, 6, 15, 179, 183
Goltz, 107, 133, 134, 147, 161, 173
Goodall, 10, 19
Gorschkow, 190, 191, 194, 197, 259, 260
Gratiolet, 216, 229
Griffiths, 191, 197
Grünbaum (with Sherrington), 7, 20, 21, 59, 60, 63, 64, 65, 78, 79, 84, 98, 108, 110, 133, 134, 147, 217, 218, 224, 228, 230, 239, 241, 249, 260, 276, 291
Gudden, von, 48, 80, 110, 143, 146
Guldberg, 283

Hammarberg, 4, 5, 9, 15, 18, 33, 65, 115, 144, 148, 168, 179, 193, 197, 207, 244, 249, 260
Held, 10, 19, 167
Henle, 14
Henschen, 9, 136, 139, 145, 147, 205, 208
Hervé, 216, 229
Heschl, 149
Hill, 191, 198
His, 192, 197
Hitzig, 65, 103, 133, 147, 241, 249
Hoche, 10, 19
Holl, 260, 291
Homén, 47, 65
Horsley, 81, 97, 100, 101, 109, 111, 133, 147, 197
,, (with Beevor), 174, 218, 229, 239
,, (with Schäfer), 197, 240, 248, 249
Hösel, 62, 66, 80, 81, 84, 110
Huguenin, 136, 145, 147
Hun, 136, 145, 147

Jackson, 34, 66, 206, 208, 217, 226, 229, 289
,, (with Beevor), 191, 197
Jakob, 82, 110
Jastrowitz, 242, 249
Jendrassik, 88

Kaes, 5, 6, 7, 8, 10, 12, 13, 14, 18, 71, 110, 112, 126, 144, 147, 168, 193, 198, 200, 207, 244, 249, 251, 260, 274, 291
Kaestermann, 136, 148
Kaufmann, 164, 173
Klemperer, 230
Klippel, 83, 111
Kolmer, 66, 289, 291
Kowjewnikow, 39, 65
Kölliker, 10, 15, 18, 112, 167, 193, 198
Krause, 115
Kulschitzky, 3
Kussmaul, 139

Lannegrace, 133, 147
Larionow, 162, 172, 173
Lenhossek, 10, 19
Leonowa, von, 115, 144, 148
Leuret, 271, 272
Lewis, 8, 15, 18, 30, 31, 32, 33, 34, 63, 65, 111, 193, 198, 227, 230, 262, 291
Lichtheim, 164, 165, 173
Liebenmann, 174
Long, 97, 111
Löwenthal, 194, 198
Luciani (with Seppilli), 97, 111
,, (with Tamburini), 161, 173
Lugaro, 47, 65
Luschka, 180

MacLulich (with Goodall), 10, 19
Mahaim, 80, 82, 110
Marie (with Charcot), 39, 65
Marinesco, 10, 19, 38, 47, 48, 49, 50, 58, 65
Marschalko, 90
Martinotti, 11, 176
Meynert, 8, 12, 13, 14, 15, 16, 17, 81, 112, 115, 128, 141, 144, 193, 242, 258, 260, 285
Mignot (with Serieux), 173
Mills, 61, 66, 97, 111, 145, 148, 168, 173
Miraillié, 165, 174
Monakow, von, 49, 61, 66, 80, 81, 97, 98, 99, 101, 103, 105, 106, 108, 110, 118, 134, 136, 137, 138, 139, 140, 141, 144, 145, 148, 165, 167, 205, 207, 220, 222, 229, 257, 260
Mott, 10, 19, 38, 43, 65, 80, 81, 86, 88, 97, 104, 105, 110, 145, 217
Munk, 80, 97, 103, 105, 107, 111, 133, 134, 138, 140, 147, 161, 162, 172, 173, 217, 239, 241, 249, 282, 291
Muratoff, 9, 220
Münzer (with Singer), 81, 110

Nothnagel, 101, 105

Obersteiner, 5, 10, 19, 193, 197
Obregia, 133
Orth, 3
Otuszewski, 260

Pascal, 257, 258, 260
Passow, 5, 6, 8, 17, 71, 110
Paul (with Walton), 99, 106, 111, 205, 208
Peli, 50
Pick, 164, 173
Pitres (with Charcot), 97, 101, 111
Probst, 148, 194, 198
Pusateri (with Dotto), 49, 66
,, (with Acquisto), 50, 65

Ramón y Cajal, 5, 6, 7, 8, 10, 11, 12, 15, 18, 27, 30, 65, 72, 110, 112, 114, 115, 116, 117, 127, 129, 144, 145, 147, 167, 168, 172, 175, 176, 178, 179, 181, 183, 192, 193, 194, 195, 196, 197, 260, 291
Redlich, 97, 105, 111, 139, 148, 205, 208
Remak, 14, 15
Retzius, 176, 180, 189, 192, 197
Rothmann, 66

Sachs, 141, 142, 148
Samt, 260
Sanger-Brown, 133, 147
Schaffer, 10, 19, 244, 248, 249
Schäfer, 97, 100, 101, 109, 111, 133, 134, 147, 161, 162, 173, 217
,, (with Horsley), 197, 240, 248, 249
Schlapp, 115, 133
Schwalbe, 15
Schweigger, 136, 148
Seguin, 148
Seitz, 118, 120, 123, 125
Seppilli, 161, 173
,, (with Luciani), 97, 111
Serieux, 164, 173
,, (with Mignot), 173
,, (with Dejerine), 174
Sherrington (with Grünbaum), 7, 20, 21, 22, 59, 60, 61, 63, 64, 65, 78, 79, 84, 98, 108, 110, 133, 134, 147, 217, 218, 224, 228, 230, 239, 241, 249, 260, 276, 291
Siebert, 190, 197

Singer (with Münzer), 81, 110
Smith, Elliot, 23, 65, 118, 119, 120, 123, 125, 148, 189, 192, 198, 206, 208, 215, 216, 229, 263, 264, 280, 281, 283, 285, 291
Spitzka, 257, 260
Starr, 137, 145, 148
St Bernheimer, 148

Tamburini (with Luciani), 161, 173
Tanzi, 144, 148
Thomas, 174
Tredgold, 38, 65
Triwus, 162, 174
Tschermak, 80, 81, 82, 108, 110, 205, 208, 283, 284, 291
Tuczek, 10, 14, 19, 88
Turner, W., 192, 198
Turner, W. A., 198
,, (with Ferrier), 100, 111, 167

Vejas, 81, 110
Verrey, 139
Vetter, 205
Vialet, 137, 142, 145, 148
Vicq d'Azyr, 6, 11
Vignal, 14
Vitzou, 133, 135, 147
Vogt, C. and O., 6, 9, 18, 19, 62, 66, 84, 99, 108, 111, 141, 167, 197, 206, 207, 219, 264, 284, 285, 291
Vulpius, 6, 8, 12, 14, 17

Wagner, 65
Waldeyer, 215, 229
Waller, 82, 83
Walton (with Paul), 99, 106, 111, 205, 208
Warrington, 47, 65, 66
Weigert, 6
Weinberg, 66
Weinland, 174
Welt, 242, 248, 249
Wernicke, 139, 142, 164
,, (with Friedländer), 173
Westphal, 205, 208
Williamson, 242, 249
Wolters, 3, 6
Wundt, 13
Wyllie, 225, 230
Wyrubow, 167

Zacher, 6, 10, 19, 220, 230
Zuckerkandl, 176, 180, 182, 183, 191, 192, 194, 196, 197

INDEX OF SUBJECTS.

Acquisto and Pusateri on the cortex in cases of amputation, 50
Affenspalte, 119, 121, 122, 124, 125, 131, 133, 203, 204, 279, 280
Agraphia, 225, 229, 251
Alexia, 139, 257
Alveus, 181
Amnesia verbalis (Bastian), 165
Amputation, the cortex in cases of, 47–60, 74, 246
Amusia, 162, 166
Amyotrophic lateral sclerosis, the cortex in, 38–46, 59, 73, 93
Ankle, motor centre for, 51–56, 59, 64
Anophthalmos, the brain in, 143
Aphasia, insular, 257
,, motor, 62, 221, 228, 257
Apparatus for micrography, 4, 5
Area parolfactoria, 178, 184
Area striata, 118. *See also* visuo-sensory area
Arm, motor centre for, 33, 56–59, 62, 64
"Armless wonders," 226
Arteries in sylvian fossa, 162
,, occipital, of Duret, 135
,, occlusion of, 60–62, 135, 222
,, posterior cerebral, 136
,, supplying area of Broca, 222
,, supplying visual area, 132, 135, 136
Ascending frontal gyrus, *see* precentral area
,, parietal gyrus, *see* postcentral area
Association centres of Flechsig, 244, 246
Association fibres of Meynert,
general account of 8, 14
in the audito-psychic area, 152
in the audito-sensory area, 150
in the common temporal area, 153
in the frontal and prefrontal areas, 233
in the insula, 253
in the intermediate precentral area, 211
in the limbic area, 184
in the lobus pyriformis, 178
in the postcentral area, 68, 70, 71
in the precentral area, 25
in the visuo-psychic area, 127
in the visuo-sensory area, 114, 141
Association tracts of fibres, 137, 139, 142, 168, 188, 219, 220
Atrophy of brain, regions liable to, 245
Audito-psychic area,
anatomical evidence regarding function, 166
cell lamination in, 155, 171
clinical evidence regarding function, 162, 170, 172
compared with visuo-psychic area, 171
distribution of, 158
experimental evidence regarding function, 161, 170, 172
fibre arrangement in, 151, 171
in anthropoid ape, 160
in lower animals, 287
its homologies, 287
Audito-sensory area,
anatomical evidence regarding function, 161, 170
cell lamination in, 153

clinical evidence regarding function, 162, 170
developmental evidence regarding function, 167, 169
distribution of, 157, 169
experimental evidence regarding function, 161, 170
fibre arrangement in, 149
in anthropoid ape, 160
in cases of deafness, 168
in lower animals, 287
Auditory neurones, 167

Baillarger, line of, development of, 71
,, ,, general account of, 11, 12
,, ,, in audito-psychic area, 151
,, ,, in audito-sensory area, 150
,, ,, in common temporal area, 152
,, ,, in frontal and prefrontal areas, 232
,, ,, in insula, 252
,, ,, in intermediate postcentral area, 76
,, ,, in intermediate precentral area, 210
,, ,, in lesions of capsula interna, 96
,, ,, in limbic area, 184
,, ,, in lobus pyriformis, 177
,, ,, in parietal area, 200
,, ,, in postcentral area, 68, 71
,, ,, in precentral area, 24
,, ,, in tabes dorsalis, 88
,, ,, in visuo-psychic area, 126
,, ,, in visuo-sensory area, 112–114, 116
,, ,, reduplication of, 151, 200, 209, 211, 232
,, ,, relation to large pyramidal cells, 16
Bastian on "word deafness," 165
Bechterew, line of, 13, 24, 274
Betz on size and number of giant cells, 34
,, on distribution of giant cells, 36
Bianchi on functions of frontal lobe, 240
Blindness, degrees of, 134
,, cortex in old-standing, 143, 144
Bogensysteme, *see* association fibres of Meynert, 14
Bolton on extent of visuo-sensory area, 121, 143
,, on functions of frontal lobe, 244
Brachial monoplegia, 62
Brain, phylogenic growth of, 288
,, preparation for section, 3
Broca, area of, 221, 222, 223, 228
Brodmann on cell lamination of ascending frontal gyrus, 36
,, ,, ,, ,, insula, 251
Bulbus olfactorius, 175
Buttock, motor centre for, 33

Calcar avis, 122, 123, 280
Calcarine area, *see* visuo-sensory area
Canis, cortex of, 269
Capsula externa, 167
Capsula interna, 83, 85, 108, 163, 167
Cécité verbale pure, 139
Cell lamination, general remarks on, 15
Cell nests in fissura hippocampi, 181, 269
,, in lobus pyriformis, 178, 195
,, in motor area, 31, 269
Centre médian of Luys, 84
Cerebellar symptoms in cases of frontal lesion, 243
Cerebral softening and other lesions in reference to localisation of function, 60, 62, 135, 222
Charcot and Marie on the cortex in amyotrophic sclerosis, 39
Chromophilous nerve cells, 187, 196, 268, 272, 275, 283
Cingulum, 188
Clarke and Bevan Lewis on motor area, 7, 31
Claustrum, 258, 288
Colliculi superiores, *see* corpora quadrigemina anteriora, 134
Consciousness, 206
Cornu ammonis, 179, 181, 188, 189, 191–196, 227, 269
Corpora geniculata externa vel lateralia, 134, 135, 140, 141, 145, 167
,, ,, interna, 104
,, ,, media, 167, 169
,, mammillaria, 188
,, olivaria superiora, 167
,, quadrigemina anteriora, 134, 135, 140
,, ,, posteriora, 167, 169
Corpus trapezoideum, 167
Cortex cerebri, general remarks on structure of, 6
Corti, organ of, 167
Corticifugal fibres, 146
Corticipetal fibres, 145
Crucial area, *see* precentral area in lower animals
Crucial region, homologies of, 276
Crural monoplegia, 61
Cuneus, 118, 120, 122, 129, 131, 136, 137
Cunningham on anatomy of calcarine fissure, 118, 122, 123
,, ,, ,, fissure of Rolando, 21–23

Deafness, cases of total, 162, 170
,, cortex in, 168, 246
,, due to unilateral lesions, 162, 270. *See also* word deafness, psychic deafness, tone deafness and musical deafness
Deckschicht, *see* zonal layer
Degeneration, retrograde or indirect, 47 et seq., 83, 140, 143, 194. See also *réaction à distance*
Dejerine on the lemniscus, 82
,, ,, tapetum, 142
Dejerine's "pure word deafness," 164

Ectosylvian area in canis, 271
,, ,, in felis, 266, 267
,, ,, in sus, 275
,, ,, its homologies, 286
Edinger's *superradiäre Faserwerk*, *see* supraradiary layer
Elbow, motor centre for, 54, 56, 57, 59, 64
Electrical stimulation of frontal lobe, 133, 239, 241
,, ,, of gyrus angularis, 134
,, ,, of hippocampus, 190
,, ,, of intermediate precentral area, 218
,, ,, of occipital lobe, 133
,, ,, of parietal area, 205
,, ,, of precentral area, 20, 226, 276
,, ,, of speech centre, 224
,, ,, of temporal lobe, 161, 162
Emminghaus on cortical nerve fibres, 13
Extrarhinic area in canis, 272
,, ,, in felis, 267

Extrarhinic area, its homologies, 286
Eyeball, centre for movements of, 54, 56, 57, 59, 64

Face, motor centre for, 33, 34, 59, 60, 62, 64, 239
Facial paralysis, 62
Facio-brachial paralysis, 62
Facio-lingual paralysis, 62
Faisceau sensitif, 142
Fasciculus arcuatus, 142
,, longitudinalis inferior, 137, 139, 142, 168
,, ,, superior, 139, 142, 169, 220, 226
,, occipitalis transversus cunei, 142
,, ,, ,, gyri longitudinalis, 142
,, ,, verticalis vel perpendicularis, 142
,, occipito-frontalis, *see* tapetum, 220
,, uncinatus, 220
Felis, cortex of, 262
Feltwork or *Filz* of Kaes, 14
Ferrier on the functions of the frontal lobe, 240
,, ,, localisation of "common sensation," 106
,, ,, ,, of the sense of hearing, 161
,, ,, ,, of the visual area, 133
Fibrae arcuatae of Arnold, 141
,, propriae of Meynert, 14, 70
Fibreless layer, 10, 24
Fingers, motor centre for, 54, 56–59, 64
First layer of nerve cells, *see* plexiform layer
Fissura, *see also* sulcus
,, calcarina, 112, 118, 119, 121, 122, 123, 129, 131, 137, 145, 264, 271, 274, 278, 279
,, calcarina, anterior, 118, 120, 121, 129, 130, 279
,, calcarina, externa, 119, 121, 123, 124, 281
,, calcarina, homologies of, 279, 280
,, calcarina, posterior, 118, 120, 122, 123, 124, 279, 281
,, calloso-marginalis, 28, 75, 77, 78, 188, 213, 228, 236, 279, 283
,, calloso-marginalis, homologue of, 280
,, collateralis, 119, 120, 130, 159, 180, 195
,, corporis callosi, 185, 189
,, extrema of Seitz, 118, 120, 123, 124, 125, 279, 281
,, hippocampi, 177, 180, 181, 189, 195, 269
,, intercalaris, 264, 271, 274, 280
,, intraparietalis, 159, 203
,, ,, its homologies, 281, 286
,, perpendicularis externa of Bischoff, 123
,, postrhinica, 264, 271, 274
,, prima of His, 183
,, retrocalcarina of von Monakow, *see* f. extrema
,, rhinica, 176, 177, 179, 189, 195, 258, 264, 272, 274, 278
,, vel fossa parieto-occipitalis, 119, 120, 122, 123, 129, 130, 137, 203, 204, 279, 280
Fissura Rolandi,
anatomy of, 21
development of, 22
homologies of, 23, 270, 277–279, 284
influence of, on motor area, 21, 28, 60
interruption of, 22
structure of walls, 67–70, 72, 75, 78
superior annectant gyrus of, 22, 31, 32, 278
superior annectant gyrus of, in ape, 22, 23
Fissura Sylvii, 149, 150, 157–160, 166, 214, 258, 266, 275, 278, 286, 287
Flechsig on the cortical lemniscus, 83
,, ,, functions of the central gyri, 99
,, ,, insula, 251
,, ,, myelinisation of cortex, 9, 62, 83, 193
,, ,, visual centre, 140
Foot, motor centre for, 33, 51–56, 59
Forceps major, 139
Fornix, 188
Fourth layer of nerve cells, *see* stellate layer
Fovel on the tapetum, 142
Frontal area, cell lamination in, 234
,, ,, clinical data regarding function, 239
,, ,, distribution of, 236, 247
,, ,, embryological data regarding function, 243
,, ,, experimental data regarding function, 239
,, ,, fibre arrangement in, 231
,, ,, histological data regarding function, 244
,, ,, homologies of, 246, 288
,, ,, in anthropoid ape, 236, 247
,, ,, in canis, 272
,, ,, in felis, 268
,, ,, in sus, 276
Frontal lobe from standpoint of phylogeny, 247, 288, 290
,, ,, results of electrical stimulation, 133
,, ,, supposed relation to vision, 133. *See also* intermediate precentral, frontal and prefrontal areas
Frontal pontine tract, 219
Functions, high evolutionary, 288
,, simple, primary, 288
Fusiform cell layer, 17, 31, 75, 87, 93, 117, 129, 155, 157, 179, 186, 202, 213, 235, 255

Ganglion cell layer, *vide* pyramidal cells, internal large
General paralysis, cortex in, 2, 86, 88, 90, 245, 246
General sensibility, 102
Gennari, line of, 6, 112, 113, 114, 116, 125, 128, 143, 263, 271
Genu corporis callosi, 187, 268
Giant cells of Betz, 30
compared with large postcentral cells, 73
distribution of, 35, 88, 279
enumeration of, 34–37, 227
function of, 226
homologues of, 227, 273, 289
in amyotrophic lateral sclerosis, 38–46
in the anthropoid ape, 36, 37
in canis, 269
in cases of amputation, 47, 58, 96
in felis, 262
in sus, 273, 289
variations in size, 33
Goltz on vision, 134
Gorschkow on the localisation of the sense of taste, 259
Granule layer of nerve cells, *see* stellate layer
Gudden's atrophy, 48, 146. *See also* degeneration, retrograde
Gyri arcuati, 271, 272, 287
,, cuneo-linguales annectantes, 118, 120, 124
,, ectosylvii, 259, 283
,, of Heschl, *see* gyri temporales transversi

Gyri insulae, 250, 251, 255, 256
,, occipitales in the ape, 124
,, occipitales externi, 137, 139
,, temporales transversi, 149, 150, 157, 159–163, 167–170, 177, 250, 257, 287
Gyrus angularis, 133, 134, 137, 139, 153, 162, 163, 173, 203, 204
,, callosus, *see* g. fornicatus
,, cinguli, *see* g. fornicatus
,, circumambiens, 176, 177, 180
,, coronalis, 270, 283–285
,, cunei of Ecker, 120, 122, 129
,, dentatus, 175, 180, 182, 183, 189, 191, 196
,, descendens, 137
,, ectolateralis, 270
,, fornicatus, 100, 109, 129, 131, 175, 184, 189, 191, 193, 196, 215, 219, 220, 267, 275, 282, 283, 285
,, frontalis inferior, 84, 169, 214, 221, 228, 236, 243, 247, 257
,, frontalis medius, 84, 214, 228, 236, 241, 247, 248
,, frontalis superior, 214, 228, 236, 237, 247
,, fusiformis, 137, 159
,, geniculi, 182, 183
,, Giacomini, 180
,, hippocampi, 100, 175
,, intercuneatus, 280
,, lingualis, 118, 120, 122, 136, 137, 159
,, marginalis, 213, 236, 248, 263–266, 271, 275, 284, 285
,, midlimbicus, 100
,, parietalis superior, 106, 107, 199, 202, 203, 205
,, parieto-occipitalis annectans, 130, 131, 203
,, postcentralis, *see* postcentral area
,, posteruciatus, *see* gyrus sigmoideus
,, postlimbicus, 100, 122, 278
,, precentralis, *see* precentral area
,, semilunaris, 176, 177, 180, 189
,, sigmoideus, 107, 227, 263, 270, 277, 284
,, subcallosus, 175, 183, 189, 196
,, supracallosus, 182, 183
,, supramarginalis, 106, 107, 160, 163, 164, 166, 170, 203, 204
,, suprasylvius, 265, 266, 270
,, temporalis primus, 149, 157, 158, 160, 161, 163–170, 172, 287
,, temporalis secundus, 149, 159, 163, 164
,, temporalis tertius, 159, 166
,, uncinatus, *see* lobus pyriformis

Hammarberg, apparatus of, for micrography, 4
,, on cell lamination, 9
Hand, motor centre for, 54, 56, 59, 64, 225
Head, motor centre for, 241. *See also* neck
Hemiopia, 134–136, 145
Henschen on localisation of visual centre, 136
Heschl, gyri of, *see* gyri temporales transversi
Hill on functions of lobus pyriformis and gyrus dentatus, 191
Hip, motor centre for, 33, 54, 59, 64
Hippocampal cortex, *see* lobus pyriformis
Hippocampus, anatomy of, 177
Hitzig on the tactile sense, 103
,, on the localisation of the visual centre, 133
Horsley and Schäfer on sensory localisation, 100
,, ,, on the functions of the frontal lobes, 240
Hösel on cortical localisation, 62
,, on the lemniscus, 81
Huguenin on the localisation of the visual centre, 136
Hun on the localisation of the visual centre, 136

Indusium griseum, 182
Insanity, the cortex in, 1, 2
Insula Reilii, 157, 163, 164, 169, 214, 216, 217, 223, 224, 250
,, anatomy of, 250
,, distribution of types of cortex, 158
,, functions of, 256
,, in anthropoid ape, 256
,, in lower animals, 258, 286, 288
,, results of lesions of, 257
,, subdivisions of, 158, 255
,, types of cell lamination in, 253
,, types of fibre arrangement in, 251
Intermediate postcentral area, 67, 71, 75
cortical structure of, 76, 77, 108
distribution of, 77
function of, 106
in the higher apes, 77, 78
Intermediate precentral area, 62, 67, 77, 87, 209
association tracts of, 218, 219
cell lamination in, 211
development of cortical fibres in, 218
distribution of, 213, 227
electrical stimulation of, 218
fibre arrangement in, 209
functions of, 217
in the anthropoid ape, 214
in lowly mammals, 290
Interradiary plexus, general account of, 13
,, ,, in audito-psychic area, 152
,, ,, in audito-sensory area, 150
,, ,, in cases of capsular lesion, 96
,, ,, in common temporal area, 153
,, ,, in frontal and prefrontal areas, 233
,, ,, in insula Reilii, 253
,, ,, in intermediate postcentral area, 77
,, ,, in intermediate precentral area, 211
,, ,, in limbic area, 184
,, ,, in lobus pyriformis, 178
,, ,, in parietal area, 201
,, ,, in postcentral area, 68, 69, 71
,, ,, in precentral area, 25
,, ,, in tabes dorsalis, 88
,, ,, in visuo-psychic area, 127
,, ,, in visuo-sensory area, 114
Interradiäre Flechtwerk, *see* interradiary plexus
Isthmus of gyrus fornicatus, 180

Jackson, J. Hughlings, on significance of variations in cell size, 34
Jackson, J. Hughlings, on representation of movement, 217
Jendrassik on the cortex in tabes dorsalis, 88

Kaes, line of, 13, 24, 126, 150, 151, 274
,, methods employed by, 7

Kaes on development of line of Baillarger, 71
,, on function of zonal layer, 11
,, on radiations of Meynert, 14
Knee, motor centre for, 51–56, 59, 64
Kowjewnikoff on the brain in amyotrophic lateral sclerosis, 39
Körnerschicht, *see* stellate layer

Lamina medullaris externa, *see* zonal layer
Laminae arcuatae of Arnold, *see* association fibres
Larionow on the localisation of the auditory sense, 162
Larynx, motor centre for, 221, 223, 224, 229
Layer of fusiform cells, *see* fusiform cells
,, of large pyramidal cells, *see* pyramidal cells
,, of medium-sized pyramidal cells, *see* pyramidal cells
,, of small pyramidal cells, *see* pyramidal cells
,, of stellate cells, *see* stellate cells
Leg, motor centre for, 33, 51–56, 61, 64, 225, 226
Lemniscus, cortical, 80–85, 89, 99, 105, 106, 108, 109, 205
,, cortical, in cat, 81
,, lateral, 80, 167
,, medial, 80–82
,, medial accessory, 80
Lewis, Bevan, on significance of variations in cell size, 34
Lewis, Bevan, and Henry Clarke on motor area, 8, 31
Lichtheim's "isolated speech deafness," 164
Ligamentum tectum, 184
Limbic area, cell lamination in, 186
,, development of cortical fibres, 193
,, distribution of, 188
,, fibre arrangement in, 184
,, functions of, 189
,, in anthropoid ape, 188, 196
,, in canis, 272
,, in felis, 267
,, in sus, 275
,, its homologies, 282
Lingual lobule, *see* gyrus lingualis
Lips, motor centre for, 221, 223, 224, 229
Lobulus olfactorius posterior, 176
,, paracentralis, 27, 31, 63, 71, 72, 75, 77, 108, 243, 278
Lobulus paracentralis, lesions of, 61, 101
,, quadratus, 204
Lobus limbicus, 175, 195
Lobus occipitalis, 163
Lobus parietalis, *see* parietal, temporal and postcentral areas
Lobus pyriformis, 175, 176, 177, 188, 289
as a centre for "common sensation," 190
cell lamination in, 178, 179, 227
development of cortical fibres in, 192, 193
fibre arrangement in, 176
functions of, 189
in canis, 272, 282
in felis, 268, 282
in simiadae, 189
in sus, 276, 282, 289
Lobus temporalis, 149
,, ,, common type of cell lamination, 157
,, ,, common type of fibre arrangement, 152
,, ,, distribution of common type, 158, 159
,, ,, in apes, 160
Lobus temporalis in lower animals, 287
Locus perforatus anticus, 176

Macula lutea, 137
Marinesco on cortex in amyotrophic lateral sclerosis, 38
,, on *réaction à distance*, 48, 49
Martinotti, fibres of, 11, 13, 126, 176
Material used in present research, 1
Medullary projection, 14
,, ,, in audito-psychic area, 152
,, ,, in insula Reilii, 253
,, ,, in intermediate postcentral area, 77
,, ,, in limbic area, 184
,, ,, in postcentral area, 70
,, ,, in visuo-psychic area, 128
Medullated nerve fibres, development of, 8, 9, 62, 64, 83, 84, 108, 218, 219, 284, 285
Medullated nerve fibres, general consideration of, 10
Meynert on medullated nerve fibres, 7, 8
,, radiations of, *see* radiations
,, second and third cell layers of, *see* supraradiary layer
,, solitary cells of, 117, 128, 129, 227, 264, 271, 274
Micrography, apparatus for, 4, 5
Mind deafness, 161, 172
Molecular layer of nerve cells, *see* plexiform layer
Monakow, von, on the cortical lemniscus, 80
on Ferrier's doctrine of sensory localisation, 101
on the functions of the insula, 257
on the functions of the postcentral gyrus, 99
on the localisation of the visual centre, 137
on the localisation of the motor centre, 61
on "psychic blindness," 138
on testing sensation, 98
on "word-deafness," 165
Moral sense in lesions of frontal lobe, 242
Motor tract, 60, 61, 102
Mott on the cortex in amyotrophic lateral sclerosis, 38, 43
Movements, bilateral, 226
simple, primary or automatic, 225, 226, 229, 289
skilled or higher evolutionary, 62, 217, 225, 228, 229
Munk on the localisation of the visual centres, 133
,, on "psychic blindness," 138
,, on the sense of hearing, 161
,, on the sense of touch, 103
Muscle sense, 104–106, 205
Musical deafness, 166

Neck, motor centre for, 33, 59
Nerve cell lamination, general remarks on, 6
,, ,, in audito-psychic area, 155
,, ,, in audito-sensory area, 153
,, ,, in canis, felis and sus, 261
,, ,, in common temporal area, 157
,, ,, in frontal and prefrontal areas, 234
,, ,, in insula Reilii, 253
,, ,, in intermediate postcentral area, 71
,, ,, in intermediate precentral area, 211
,, ,, in limbic area, 186
,, ,, in lobus pyriformis, 178
,, ,, in postcentral area, 71
,, ,, in precentral area, 29

Nerve cell lamination in visuo-psychic area, 128
,, ,, in visuo-sensory area, 115
Nerve fibres of cortex, general remarks on, 6
,, ,, in audito-psychic area, 151
,, ,, in audito-sensory area, 149
,, ,, in canis, felis and sus, 261
,, ,, in common temporal area, 152
,, ,, in frontal and prefrontal areas, 231
,, ,, in insula Reilii, 251
,, ,, in intermediate postcentral area, 76
,, ,, in intermediate precentral area, 209
,, ,, in limbic area, 183, 184
,, ,, in lobus pyriformis, 176
,, ,, in postcentral area, 68
,, ,, in precentral area, 24
,, ,, in visuo-psychic area, 126
,, ,, in visuo-sensory area, 112
Nerves, auditory, 194
,, cochlear, 167
,, fifth cranial, 60, 194
,, glosso-pharyngeal, 194
,, of Lancisius, 182
,, seventh cranial, 60
Nucleus amygdalae, 180, 192
,, cochlearis dorsalis, 167
,, cochlearis ventralis, 167
,, habenulae, 188
,, lateralis thalami, 82, 83, 84
,, lenticularis, 163
,, of Goll and Burdach, 80, 85, 89
,, ruber, 84

Occipital area, 125
,, lobes, lesions of, 136
,, lobes, results of electrical stimulation of, 133
Occipito-thalamic fibres, *see* optic radiations
Olfactory cortex, development of, 62. *See also* lobus pyriformis
Olfactory fibres, *see* tractus olfactorius
Operculum, frontal, 164, 194, 214, 216, 221, 223, 228, 250, 257, 258
Operculum, orbital, 214, 216, 223, 228, 250, 255, 258
Operculum, parietal, 78, 158, 170, 250
Operculum, temporal, 223. *See also* gyrus temporalis primus
Optic aphasia, 139
,, atrophy, cortex in, 143, 145, 246
,, centres, primary, 134
,, fibres of R. y Cajal, 114, 127
,, lobe, 134
,, nerve, 133
,, radiations, 112, 114, 128, 129, 136, 138, 139, 140, 141, 144, 145, 167
Osmatic animals, brain in, 191, 195, 282
Outermost fibreless layer, 10, 24

Pain, *see* sense of
Paragraphia, 163
Paraphasia, 163, 257
Parietal area, 199
,, cell lamination in, 201
,, distribution of, 203
Parietal area, fibre arrangement in, 199
,, function of, 205
,, homologue of, 286, 290
,, in ape, 204
,, in canis, 270
,, in felis, 265
,, in sus, 275
Parietal lobe, as a centre for sensation, 99, 104, 105, 106
,, degenerations after destruction of, 80, 108
,, lesions of, 105, 106
Passow on medullated nerve fibres of cortex, 8
,, on structure of postcentral gyrus, 71
Pedunculus corporis callosi, 183
,, olfactorius, 175, 192, 282
Plexiform layer, general account of, 15
,, ,, in audito-psychic area, 155
,, ,, in audito-sensory area, 153
,, ,, in fissura hippocampi, 181
,, ,, in frontal and prefrontal areas, 234
,, ,, in insula Reilii, 253
,, ,, in intermediate precentral area, 212
,, ,, in limbic area, 186
,, ,, in lobus pyriformis, 178
,, ,, in parietal area, 201
,, ,, in postcentral area, 71
,, ,, in precentral area, 29
,, ,, in tabes dorsalis, 87, 92
,, ,, in visuo-psychic area, 128
,, ,, in visuo-sensory area, 115
Plexus externus, *see* zonal layer
Pole of insula, 251
Postcentral or sensory area, 67
development of fibres, 62, 64, 83, 84, 108
distribution of, 75, 108
functions of, 78, 105–109
homologue of, 265, 283
in anthropoid ape, 67, 75, 79, 108
in cases of amputation, 96, 108
in cases of capsular lesion, 94, 108, 109
in canis, 270
in felis, 264
in sus, 274
in tabes dorsalis, 85, 108, 109
lesions of, 79, 81–83, 97, 98, 101, 102
local variations in structure, 71
structure of cortex, 67, 107
structure of cortex compared with that of precentral area, 67, 70–72, 107, 108
structure of cortex compared with that of other regions, 76, 77, 114
Postcrucial area, *see* postcentral area in felis
Precentral or motor area, 20
arrangement of nerve fibres, 24, 63, 262
arterial supply of, 60–62
cell lamination of, 29, 63, 262
development of fibres, 62, 64, 84
distribution of, 27, 63, 67
functions of different cell layers, 105
homologue of, 276
in amyotrophic lateral sclerosis, 42, 63
in anthropoid ape, 27, 29, 36, 49, 59–61, 63
in canis, 269

Precentral or motor area, in cases of amputation, 47–60, 63
in felis, 262
in sus, 273
lesions of, 60–63, 98, 101
local variations in structure, 27
restitution of function, 62
sequence of representation of function, 61, 62, 64, 277
structure compared with postcentral, 68, 70, 107
Precuneus, cortex of, 129, 203, 205
,, lesions of, 101
Prefrontal area, 231
,, ,, cell lamination in, 234
,, ,, clinical data regarding function, 241
,, ,, comparative anatomy of, 246
,, ,, distribution of, 236, 248
,, ,, embryological data regarding function, 243
,, ,, experimental data regarding function, 239
,, ,, function of, 238, 248
,, ,, histological data regarding function, 244
,, ,, in the higher ape, 236, 248
,, ,, in canis, 272
,, ,, in felis, 268
,, ,, in sus, 276
"Psychic blindness," 138
"Psychic deafness," 162, 166
Pulvinar, 134, 135, 140, 141
Pupil, motor centre for, 239
Pyramidal cells, external large, 16
in audito-psychic area, 156
in audito-sensory area, 154
in cases of amputation, 97
in common temporal area, 157
in frontal and prefrontal areas, 234
in insula, 254, 255
in intermediate postcentral area, 77
in intermediate precentral area, 212
in limbic area, 186
in lobus pyriformis, 179
in parietal area, 201
in postcentral area, 72, 91
in precentral area, 30
in tabes dorsalis, 87, 90, 93
in visuo-psychic area, 128, 129
in visuo-sensory area, 116
Pyramidal cells, internal large, 17. *See also* giant cells of Betz
in audito-psychic area, 157
in audito-sensory area, 154
in cases of amputation, 97
in common temporal area, 157
in fissura hippocampi, 181
in frontal and prefrontal areas, 235
in insula, 254, 255
in intermediate postcentral area, 77
in intermediate precentral area, 213
in parietal area, 201
in postcentral area, 72
in precentral area, 30
in tabes dorsalis, 87, 93
in visuo-sensory area, 117
Pyramidal cells, layer of medium-sized, 16, 30, 72, 87, 115, 128, 153, 155, 186, 201, 212, 234, 254
Pyramidal cells, layer of small, 15, 30, 71, 87, 92, 115, 153, 155, 178, 186, 201, 212, 234, 253
Pyramidal cells, layer of small, in sus, 273

Radiations of Gratiolet, *see* optic radiations
Radiations of Meynert, 13
in audito-psychic area, 151
in audito-sensory area, 150
in capsular lesions, 96
in common temporal area, 152
in frontal and prefrontal areas, 232
in gyrus fornicatus, 184, 185
in insula Reilii, 252, 253
in intermediate postcentral area, 76
in intermediate precentral area, 210, 211
in lobus pyriformis, 178
in parietal area, 200, 201
in postcentral area, 68, 85
in precentral area, 25
in tabes dorsalis, 88
in visuo-psychic area, 126
in visuo-sensory area, 113, 150
Ramón y Cajal on cells in precentral gyrus, 30
,, ,, on cells in visuo-sensory cortex, 115–117
,, ,, on localisation of olfactory centre, 192
,, ,, on optic fibres, 114
,, ,, on postcentral cortex, 72
,, ,, on radiations of Meynert, 27
Réaction à distance, 48–50, 52–59, 63, 96, 277
Regio olfactiva, 179
Reil, island of, *see* insula
Restitution of function, 102, 226
Retinal localisation, 134, 136
Retrograde degeneration, *see* degeneration
Roots, olfactory, 175, 179, 183, 192, 196
Rostrum corporis callosi, 183, 187
Ruban de Reil, 62

Schaffer on functions of frontal lobe, 246
Schäfer on localisation of visual centre, 133
,, on localisation of auditory centre, 161
Schlapp on visual cortex in lower ape, 133
Second layer of nerve cells, *see* pyramidal cells, small
Secondary olfactory centres, 192
Seelenblindheit, 138, 282
Seelentaubheit, 161
Seguin on localisation of visual centre, 137
Sensation, "common," components of, 94, 102–107, 109
,, ,, localisation of, 67, 79, 80, 93
Sensations of pain, 106, 107, 109
,, of temperature, 106, 107, 109
,, of touch, 102–104, 109, 190, 195
Sense of smell, localisation of, 190, 283
Sense of taste, localisation of, 190, 259
Sensory projection centres of Flechsig, 228
Sensory tract, 60, 61, 70, 80, 83, 99–102
Septum lucidum, 175, 188
Sherrington and Grünbaum,
on motor area, 20, 78, 108
on speech centre in ape, 224
on stimulation of frontal lobe, 241
Shoulder, motor centre for, 33, 54, 57, 59

Sleeping sickness, cortex in, 246
Smith, Elliot, on the area striata, 118
,, ,, on the *Affenspalte*, 125
Speech centre, 221, 228, 257, 258
Spinal cord in cases of amputation, 47, 58
,, in tabes dorsalis, 89
,, myelinisation of, 284
Spindle-shaped cells, *see* fusiform cells
Splenium, 182, 268, 280
Starr on localisation of visual centre, 137
Stellate cell layer, 16
,, ,, in audito-psychic area, 156
,, ,, in audito-sensory area, 155
,, ,, in frontal and prefrontal areas, 235
,, ,, in insula, 254, 255
,, ,, in intermediate postcentral area, 77
,, ,, in intermediate precentral area, 212
,, ,, in parietal area, 201
,, ,, in postcentral area, 72
,, ,, in precentral area, 30
,, ,, in tabes dorsalis, 87, 93
,, ,, in visuo-psychic area, 128, 129
,, ,, in visuo-sensory area, 115, 116, 143
Stereognosis, 104, 106, 205
Stratum calcarinum, 141
,, cellularum pyramidalium, 179, 269
,, granulosum cornu ammonis, 189
,, proprium cunei, 141
,, radiatum, 181
,, sagittale externum, 142
Striae longitudinales laterales, 183, 188, 192
,, ,, mediales, 182, 183, 185, 192, 196, 283
Striae medullares, 167
Subiculum hippocampi, 177, 181, 188, 192, 193, 195
Sulcus ansatus, 206, 263, 270, 277, 285
,, ansatus compensatorius, 263, 270, 277, 278, 284
,, anterior Sylvii, 215, 216
,, arcuatus, 215
,, calcarinus proprius, *see* fissura calcarina anterior
,, coronalis, 81, 263, 265, 277, 278
,, coronalis in sus, 273, 285
,, cruciatus, 227, 262, 263, 269, 277, 278, 285
,, cruciatus hominis, 278
,, cunealis, 120
,, diagonalis, 256, 265
,, ectosylvius, 272, 275, 287
,, frontalis inferior, 238
,, frontalis marginalis of Wernicke, 236, 244
,, frontalis medius, 216, 236, 237, 238, 241
,, frontalis superior, 236
,, fronto-orbitalis, 215, 216, 217, 238, 256, 286
,, genualis, 280, 283
,, inferior transversus Rolandi, 21, 215, 216
,, insulae, 250, 251, 255, 256, 258
,, interparietalis (Ecker), 159
,, intrastriatus lateralis (Elliot Smith), 123
,, intrastriatus mesialis (Elliot Smith), 118, 281
,, lateralis, 206, 265, 271, 274, 281, 286
,, lateralis, in sus, 274, 281
,, limitans inferior areae striatae, 120
,, limitans insulae anterior, 216, 217, 256, 287
,, limitans insulae posterior, 256, 287
Sulcus limitans insulae superior, 216, 256, 287
,, limitans superior areae striatae, 120
,, lingualis, 120
,, longitudinalis occipitalis superior (Ecker), 159
,, lunatus (Elliot Smith), 125
,, occipitalis anterior, 121
,, occipitalis lateralis (Eberstaller), 119, 121, 123, 124, 130
,, occipitalis transversus (Ecker), 119, 121, 130, 131, 159
,, olfactorius, 236, 282
,, orbitalis, 263, 268, 270, 288
,, orbitalis transversus, 214, 216, 228, 236, 248, 288
,, polaris (Bolton), 119, 121, 125
,, postcentralis inferior, 159, 285
,, postcentralis superior, 77, 159, 204, 258
,, postlateralis, 206, 271
,, postlimbicus, 188, 204
,, postsylvius, 256, 287
,, praestriatus, 280
,, precentralis inferior, 214–216, 238
,, precentralis marginalis, 278
,, precruciatus, 270
,, prelimbicus, 283
,, preovalis, 278
,, rectus, 215, 216, 237, 238, 241
,, rostralis, 283
,, sagittalis externus, 236, 247
,, splenialis, 279, 280
,, sublimbicus, 283
,, subparietalis, 204
,, suprasplenialis, 274, 281
,, suprasylvius, 256, 265, 266, 272, 274, 286
,, suprasylvius, in sus, 287
Supraangular area (Flechsig), 203
Supraradiary layer of nerve fibres, 12, 68, 71, 76, 88, 96, 113, 126, 150, 151, 152, 199, 210, 231, 252
Sus, cortex of, 272

Tabes dorsalis, cortex in, 74, 85, 246
,, sensation in, 104
Tactile sense, *see* sensations of touch
Tangential or association fibres, 8, 11
Tangential band, *see* zonal layer
Tangentiale Randzone, *see* zonal layer
Tapetum, 140, 220, 226
Tassel cells, 179, 195, 269
Taste, localisation of centre for, 190, 259
Temperature, sense of, *see* sense
Thalamus opticus, 188
Third layer of nerve cells, *see* pyramidal cells, medium-sized
"Tone deafness," 166, 172
Tongue, motor centre for, 62, 221, 223, 224, 229
Tract, frontal pontine, 219
,, olfactory, 175, 196
Trigonum olfactorium, 175, 176
Trunk, motor centre for, 33, 54, 59, 62, 239
Tschermak on the cortical lemniscus, 81, 283
Tuberculum acusticum, 167
,, olfactorium, 175, 176, 269, 282

Uncus, 175, 177, 182, 191, 195, 196

Vallecula Sylvii, 282
Vialet on localisation of visual centre, 137
Vision in decerebrate animals, 134
,, in lower animals, 134
,, restitution of, 136
Visuo-psychic area, 125
compared with other areas, 126–129, 171
distribution of, 119, 129, 203
function considered, 131
in anthropoid ape, 130
in old-standing blindness, 144
its homologies, 271, 279, 282
structure of, 126, 146
Visuo-sensory area, 112
anatomical data regarding function, 139
blood supply of, 135, 136
clinical data regarding function, 135
distribution of, 118, 125, 143
electrical excitation of, 133, 134
experimental data regarding function, 132
in anthropoid ape, 117, 121
in canis, 271
in felis, 263, 264
in old-standing blindness, 143, 145
in sus, 274
its homologies, 279
lesions of, 135, 136, 145
structure of, 112, 145, 163
Vitzou on restitution of vision, 135
Vogt on development of medullated fibres, 62, 84
Vulpius on tangential fibres, 8

Waller, law of, 82, 83, 85
Walton and Paul on the stereognostic sense, 106
Wernicke's subcortical word-deafness, 164
Wernicke, white matter of, 140
White or medullary projection, *see* medullary projection
Witzelsucht, 242
"Word-blindness," 139, 163
"Word-deafness," 162, 164–166, 172
"Word-seeing" centre, 173
Wrist, motor centre for, 54, 56–59
Writing centre, 225, 229
Wundt on radiations of Meynert, 13

Zonal layer, 10, 76, 96, 112, 126, 150, 151, 152, 185, 199, 231, 269
,, in amyotrophic lateral sclerosis, 43
,, in fissura hippocampi, 181, 189, 195, 196
,, in insula, 251
,, in intermediate precentral area, 209
,, in lobus pyriformis, 176, 276
,, in postcentral area, 68, 71
, in precentral area, 24

CAMBRIDGE: PRINTED BY JOHN CLAY, M.A. AT THE UNIVERSITY PRESS.

Reprinted from THE LANCET, *Sept. 3rd*, 1938, *p.* 597.

OBITUARY

THE LATE DR. ALFRED CAMPBELL

AN APPRECIATION

"The only really good cytoarchitectonic pictures are those of Campbell, who—let me put it in capital letters—HAS BEEN THE ONLY CYTOARCHITECTONIST WHO HAS DESCRIBED FACTS AND ONLY FACTS. The German cytoarchitectonist has mixed facts with theory in such a manner that nobody can tell where facts end and theories begin. I must state that there are perhaps no more than a dozen photographs out of hundreds in which the layers of the cortex have been properly and consistently labelled. On the other hand, Campbell's ink drawings beside being good, are easily reproduced." [1]

BORN in 1868 on his father's station at Cunningham Plains, near Harden, in Australia, Alfred Walter Campbell received his early education under the headmastership of the son of Robert Southey, the English poet, at Oakland School, near Mittagong. He left Australia in 1885 to enter the medical school at Edinburgh and in 1889 received his M.B. with honours. His attention had early been drawn to mental disease and he soon became one of that still small band who believe that the study of the structure of the brain and its aberrations may one day lead to a deeper understanding of the deranged mentality. He visited various English asylums and later went to Vienna where he was largely influenced by Krafft-Ebing; on leaving Vienna he proceeded to Prague where he served for a time on the staff of the State asylum of the metropolis. On returning to England in 1892 he obtained his M.D. degree (and gold medal) at Edinburgh for a thesis entitled "The Pathology

[1] Lorente de Nó, R., Architectonics and structure of the cerebral cortex. (Reprinted from J. F. Fulton's "Physiology of the Nervous System." London and New York: Oxford University Press. 1938. Pp. 291–327.)

of Alcoholic Insanity." He then accepted a dual appointment as staff member at Lancashire County Asylum and director of the pathological laboratory at Rainhill Asylum, Liverpool. In these capacities he had opportunity to see extraordinarily varied clinical material. The asylum became affiliated under his direction with the University of Liverpool and soon became a mecca for students and visitors from all parts of the world.

While at Liverpool Campbell became associated with Charles Sherrington and under this stimulus began his epoch-making studies on the structure of the cortex. In 1901 Grünbaum and Sherrington had published their physiological studies on the electrical excitability of the cerebral cortex in higher apes. Campbell had opportunity of seeing these experiments and the brains of many of the anthropoids were turned over to him for histological study. In the three years 1900–03 he accomplished the almost incredible task of cutting serial sections of each of twenty-five brains, staining his sections alternately for cells and for fibres, and preparing the material for publication in monographic form. This material was too extensive even for the *Transactions* of the Royal Society, but through Sherrington's influence a grant was made by the Society and the treatise was published by the Cambridge Press as a separate monograph. Campbell was an excellent draughtsman and, while many of his now classic plates were drawn by himself, he also had the assistance of his colleague, Dr. A. C. Wilson of the Rainhill Asylum. Among other things he defined the motor area as well as the premotor area on the histological basis which is now widely recognised. He had opportunity to examine brains of patients who had undergone, some time prior to death, amputation of one or more limbs, and he was able to show that atrophy in the motor region appeared to be restricted largely, if not wholly, to the gigantic cells of Betz. He also examined the post-central region in cases of tabes dorsalis. He recognised all the principal regions which had then, or have since, been recognised as having physiological significance.

After returning to Australia in 1905 Campbell published a number of additional papers on localisation of cerebral function, but the responsibilities of

private practice in Sydney drew him away from investigative work and precluded him from making the contribution he might well have made to scientific neurology. As it was he became one of the most distinguished and respected practitioners in Australia. In 1906 he married Jennie, daughter of David Mackey, of Wallen Been Station, adjoining that on which he was born. There were two daughters of the marriage. In 1914 he volunteered for war service and was sent to Egypt ; on his return to Australia he was appointed to the military hospital at Renwick, holding his post there until the time of his death, although he retired from practice early in 1937. He was consultant neurologist at the Royal Alexander Hospital for Children, the Coast Hospital, and the Department of Repatriation in Australia.

Campbell was a man of powerful Scottish physique who had always taken a keen interest in sport, especially golf and cricket, and was also a good marksman, a keen and well-informed ornithologist, and a botanist of distinction. He had a large library of works in the field of general history as well as in the history of medicine and science. All neurologists will wish to extend their sympathy to his family and to all his colleagues in Australia.

J. F. F.

Printed in Great Britain. The Lancet Office, 7, Adam Street, Adelphi, London, W.C.2.

CYTOARCHITECTURE OF THE GORILLA BRAIN

The late Alfred W. Campbell (1868-1937) made one of the first, and certainly the most adequate, comparative studies of cytoarchitecture of the anthropoid cortex. His well-known book, Histological studies on the localisation of cerebral function (1905), was based upon brains of the chimpanzee and the orang which had been supplied to him by Sherrington and Grünbaum. He had not had opportunity at this time to take up the gorilla, and since it is generally believed that the cytoarchitecture of the gorilla brain has never been studied, it seemed worth while to direct attention to a little known paper on the subject published by Campbell in 1916 after he returned to Australia. In it, incidentally he modified his earlier views on the olfactory fields. The reference is as follows:

> ALFRED W. CAMPBELL. Histological studies on the localisation of cerebral function.- The brain of the gorilla. Reports from the Pathological Laboratory of the Lunacy Department, New South Wales Government, 1916, 3, 20-35.

A copy of this report has just been sent to the writer of this note by the Inspector-General of Mental Hospitals at Sydney and I shall be glad to make it available through photographic reproduction to any student of cytoarchitecture. The entire hemisphere was analyzed and the paper is illustrated with five excellent plates. Campbell's first paragraph reads as follows:

CYTOARCHITECTURE OF THE GORILLA BRAIN

The late Alfred R. Campbell (1868-1957) made one of the first, and certainly the most adequate, comparative studies of cytoarchitecture of the anthropoid cortex. His well-known book, *Histological studies on the localization of cerebral function* (1905), was based upon brains of the chimpanzee and the orang which had been supplied to him by Sherrington and Graham. He had not had opportunity at this time to take up the gorilla, and since it is generally believed that the cytoarchitecture of the gorilla brain has never been studied, it seemed worth while to direct attention to a little known paper on the subject published by Campbell in 1916 after he returned to Australia. In it, he substantially he modified his earlier views on the olfactory fields. The reference is as follows:

ALFRED R. CAMPBELL. Histological studies on the localization of cerebral function.- The brain of the gorilla. Reports from the Pathological Laboratory of the Lunacy Department, New South Wales Service, 1916, 2, 20-28.

A copy of this report has just been sent to the writer of this note by the Inspector-General of Mental Hospitals at Sydney and I shall be glad to make it available through photographic reproduction to any student of cytoarchitecture. The entire hemisphere was analyzed and the paper is illustrated with five additional plates. Campbell's first paragraph reads as follows:

In my work on the localisation of cerebral function, published in the year 1905, it formed part of my task to compare the cortex cerebri of homo with that of two members of the anthropoid ape family, namely, the chimpanzee (anthropopithecus troglodytes) and the orang-outang (simia satyrus). Through the kindness of Professor C. S. Sherrington, of Liverpool University, I have since been provided with the right cerebral hemisphere of a gorilla (anthropopithecus gorilla*), which

---

*The animal was young, almost a baby, accordingly the myelinisation of the cortical nerve fibres was incomplete and imperfectly developed nerve cells (neuroblasts), especially in the deeper parts, were abundant. But, although the specimen differed in this way from those of the other apes examined, the determination of the various areas in which we are interested was not interfered with.

I have examined on lines similar to those followed in the original investigation, and as such specimens are difficult to obtain, and I believe this is the first to be submitted to such examination, I am prompted to offer the following report and ask that it be taken as an addendum to what I have already written.

In my work on the localisation of cerebral function, published in the year 1906, it formed part of my task to compare the cortex cerebri of homo with that of two members of the anthropoid ape family, namely, the chimpanzee (*anthropopithecus troglodytes*) and the orang-outang (*simia satyrus*). Through the kindness of Professor C. S. Sherrington, of Liverpool University, I have been provided with the right cerebral hemisphere of a gorilla (*anthropopithecus gorilla**), which

---

*The animal was young, almost a baby, accordingly the myelinisation of the cortical nerve fibres was incomplete and imperfectly developed nerve cells (*neuroblasts*), especially in the deeper parts, were abundant. But, although the specimen differed in this way from those of the other apes examined, the determination of the various areas in which we are interested was not interfered with.

I have examined on lines similar to those followed in the original investigation, and as such specimens are difficult to obtain, and I believe this is the first to be submitted to such examination, I am prompted to offer the following report and ask that it be taken as an addendum to what I have already written.

Dr. T. C. Ruch whose forthcoming bibliography of all primate literature is being made ready for press informs me that Campbell's study of the gorilla brain is the only complete survey to be found in the literature. An account of Campbell's life will be found in the Archives of Neurology and Psychiatry, 1938, 40, 566-568.

J. F. FULTON.

Laboratory of Physiology,
Yale University School of Medicine.

YALE MEDICAL LIBRARY
3 9002 01067 3573