

Diseases of the throat and nasal passages : a guide to the diagnosis and treatment of affections of the pharynx, sophagus, trachea, larynx, and nares / by J. Solis Cohen.

Contributors

Cohen, J. Solis 1838-1927.

Harvey Cushing/John Hay Whitney Medical Library

Publication/Creation

New York : W. Wood & Company, 1879.

Persistent URL

<https://wellcomecollection.org/works/p7c72yup>

License and attribution

This material has been provided by This material has been provided by the Harvey Cushing/John Hay Whitney Medical Library at Yale University, through the Medical Heritage Library. The original may be consulted at the Harvey Cushing/John Hay Whitney Medical Library at Yale University. where the originals may be consulted.


This work has been identified as being free of known restrictions under copyright law, including all related and neighbouring rights and is being made available under the Creative Commons, Public Domain Mark.

You can copy, modify, distribute and perform the work, even for commercial purposes, without asking permission.



Wellcome Collection
183 Euston Road
London NW1 2BE UK
T +44 (0)20 7611 8722
E library@wellcomecollection.org
<https://wellcomecollection.org>







TRANSFERRED TO
YALE MEDICAL LIBRARY


1840

1840, 1841, 1842, 1843

1844, 1845







J. H. Chapman
1879
DISEASES OF THE THROAT

AND

NASAL PASSAGES

A GUIDE TO THE

DIAGNOSIS AND TREATMENT OF AFFECTIONS

OF THE

PHARYNX, ŒSOPHAGUS, TRACHEA,
LARYNX, AND NARES

By J. SOLIS COHEN, M.D.

LECTURER ON LARYNGOSCOPY AND DISEASES OF THE THROAT AND CHEST, IN JEFFERSON MEDICAL
COLLEGE, PHILADELPHIA; LATE MÜTTER LECTURER BEFORE THE COLLEGE OF
PHYSICIANS, PHILADELPHIA; PHYSICIAN TO JEFFERSON MEDICAL COLLEGE
HOSPITAL, AND TO THE GERMAN HOSPITAL OF PHILADELPHIA,
ETC., ETC., ETC.

Second Edition, Revised and Amended

WITH TWO HUNDRED AND EIGHT ILLUSTRATIONS

NEW YORK
WILLIAM WOOD & COMPANY

1879

Entered according to Act of Congress, in the year 1879,
By WILLIAM WOOD & CO.,
In the Office of the Librarian of Congress, at Washington, D. C.

RF40
879C

TROW'S
PRINTING AND BOOKBINDING CO.,
205-213 East 12th St.,
NEW YORK.

TO THE PRESIDENT
OF THE
American Laryngological Association,

LOUIS ELSBERG, M.D.,

Professor of Laryngology and Diseases of the Throat, Medical Department of the
University of New York; and the most accomplished Laryngoscopist
in America:

This Work is again Affectionately Inscribed

BY

The Author.



PREFACE TO THE SECOND EDITION.

A SECOND edition of *Diseases of the Throat* would have appeared several years ago, according to announcement, had not its preparation been interrupted by a series of circumstances over which the author had no control. It is to be hoped that it will be none the worse for having been some time out of print. To the reader familiar with the first edition, considerable change will be apparent in the present one. Some material has been suppressed, some modified or augmented, and some added. Certain illustrations have been discarded, and others introduced. The bibliography has not been reprinted, because it would have sacrificed many pages devoted to clinical use, and has become the less necessary on account of the appearance of copious references in the collateral portions of Ziemssen's *Cyclopædia*, and the current reports on Laryngology and allied topics supplied for some years by Dr. Knight to the columns of the *Boston Medical and Surgical Journal*, and by Prof. Lefferts to those of the *New York Medical Journal*; while more recent serial contributions of a similar character by Dr. Porter to the *St. Louis Medical and Surgical Journal*, and by Dr. Semon to the *London Medical Record*, and the admirable *Index Medicus* of Drs. Billings and Fletcher, are additional assurances that there shall be no lack of indicators to sources of information in this branch of professional study. Anatomical considerations of special clinical significance have been introduced into the text, as before, at points deemed most useful, and have been still more closely confined to matters as yet unincorporated in the most accessible text-books. Those who read German will find copious clinical disquisitions in the various anatomical works of Prof. Luschka; and those who do not, will soon find the deficiency supplied to some extent in the forthcoming treatise of Prof. Allen. Special manipulations, operations, and therapeutic measures are described either when first alluded to, or in connection with the subject matter to which they are most applicable, instead of being consolidated in a separate chapter, as has been done by other writers ;—a plan less systematic, to be sure, but not less likely to

elicit clinical interest. The nomenclature of the most recently published edition of the Pharmacopœia of the United States has been employed, as best in accord with the present requirements of the American reader. The great majority of illustrations of appliances are reproductions from the woodcuts of Mr. G. H. Gemrig, of Philadelphia, so long and so favorably known for the accuracy and quality of his work. The publishers have kindly allowed a reproduction of many original and selected illustrations prepared for their edition of Ziemssen's Cyclopædia.

The author's Lectures on The Surgery of the Larynx, Nares, and Trachea, delivered before the College of Physicians of Philadelphia (1872), and those on Fetid Coryza (1873), on Sore Throat, and on Diphtheria (1874), before the classes in Jefferson Medical College, and published respectively in the Philadelphia Medical Times, Philadelphia Medical and Surgical Reporter, and New York Medical Record, have been substantially incorporated into the present edition.

1431 WALNUT ST., PHILADELPHIA, March, 1879.

PREFACE TO THE FIRST EDITION.

THE preparation of the following pages has been no holiday task on the part of the author. Only such irregular intervals as could be snatched from the requirements of an unusually arduous practice could be devoted to the purpose. Hence there has ensued an inequality in composition, of which the writer is sensibly cognizant. Some subjects have had to be discussed in a manner rather different from that originally contemplated, and the context of numerous references, toilsomely collected for their elucidation, has remained unincorporated.

With the exception of a few hospital and dispensary patients, seen from time to time at the request of his professional friends, the author's entire experience has been confined to his own private and consultation practice. This has debarred him from much opportunity for personal pathological research; but it has facilitated the description of morbid processes as they are met with in the ordinary routine of practice, a matter of no slight recommendation to the general professional reader, and one which it is hoped will compensate, at least in part, for deficiencies in other directions.

The limits of a moderate-sized volume preclude the composition of an exhaustive treatise on the subject of Diseases of the Throat. It has been thought advisable, therefore, while presenting a comprehensive view of the entire field, to dwell longer upon subjects which are important by their frequency and by the fresh light shed upon them by recent investigation; and to treat concisely of those points which by their infrequency on the one hand, or their thorough discussion in the standard medical works of the day on the other, seem less to call for amplification.

It is impossible to furnish an explicit and perfect description of a disease so as to afford a complete and satisfactory mental picture of the condition of every example of it which may come under notice. Each case exhibits some special phenomena of severity or of mildness; or is different in some other particular from every other case with the same general aspect. All that a writer can do is to mention the characteris-

tics which determine the nature of the diseased action going on, to designate the elements of danger and of safety, and to indicate the methods of management which reason and experience have proven to be most adequate for relief, or best productive of cure. In attempting this, much has to be said which others have said already, and often in better language; but this repetition is sometimes necessary to complete the outline of a subject, or to convey intelligence for the first time to those who have not had access to original sources of information.

Due consideration has been given, in the subject-matter of the volume, to modern developments in the diagnosis and treatment of affections of the throat, especially those occupying the trachea, larynx, upper pharynx, and nasal passages. Here the author's experience has been ample; and if his record differs in some respects from the records of others, it does so by reason of an honest endeavor to interpret facts and observations as they appeared in the light of his own understanding. The articles on laryngoscopy, rhinoscopy, and surgical manipulations by their aid, are, with some additions, modifications, and omissions, essentially reprints of those contributed by the author, a few years ago, to the columns of *The Medical Record*, of New York, and to the second American edition of Mackenzie on the Use of the Laryngoscope.

The author has availed himself of the labors of his predecessors and contemporaries, in the production of this volume, as freely as he has resorted to them for his own instruction. He has endeavored, except in so far as certain general matters have long become the common property of the profession, to give due credit to his sources of information.

For the use of the studious and the curious, he has appended a bibliographical record, culled from his own index-rerum; and this has been distributed under catch-heads, as being more convenient for consultation than a purely alphabetical list of authors, or a mere chronological arrangement.

Acknowledgment is made to Mr. G. H. Gemrig, of Philadelphia, for many illustrations of surgical instruments; and also to Messrs. Otto & Reynders, and to Messrs. Tiemann & Co., of New York, for like favors. All the original woodcuts in the volume, and many of the copied ones, were engraved by Mr. Sebal, of Philadelphia.

PHILADELPHIA, May, 1872.

TABLE OF CONTENTS.

CHAPTER I.

	PAGE
DISEASES OF THE THROAT IN GENERAL.....	1

CHAPTER II.

EXAMINATION OF THE THROAT AND NASAL PASSAGES.....	9
---	---

DIRECT INSPECTION OF THE THROAT.—DIRECT INSPECTION OF THE NASAL PASSAGES; ANTERIOR RHINOSCOPY.—LARYNGOSCOPY.—AUTO-LARYNGOSCOPY.—DEMONSTRO-LARYNGOSCOPY.—INFRA-GLOTTIC LARYNGOSCOPY AND TRACHEOSCOPY.—ŒSOPHAGOSCOPY.—PHARYNGEAL RHINOSCOPY; RETRONASAL RHINOSCOPY; POSTERIOR RHINOSCOPY.—AUTO-RHINOSCOPY.—DEMONSTRO-RHINOSCOPY.—PALPATION.—AUSCULTATION.—PERCUSSION.

CHAPTER III.

SORE THROAT.....	83
------------------	----

ACUTE SORE THROAT.—COMMON SORE THROAT.—PHLEGMONOUS SORE THROAT.—ULCEROUS SORE THROAT.—SIMPLE OR COMMON MEMBRANOUS SORE THROAT.—THE SORE THROATS OF THE FEBRILE EXANTHEMATA —ERYSIPELATOUS SORE THROAT.—ACUTE TUBERCULOUS SORE THROAT.—THE SORE THROAT OF GLANDERS.—THE SORE THROAT OF STOMATITIS.

CHAPTER IV.

SYPHILITIC SORE THROAT.....	119
-----------------------------	-----

SYPHILITIC SORE THROAT IN ADULTS.—SYPHILITIC SORE THROAT IN INFANTS.

CHAPTER V.

DIPHTHERIA.....	131
-----------------	-----

CHAPTER VI.

	PAGE
CHRONIC SORE THROAT.....	177
CHRONIC CATARRHAL SORE THROAT.—CHRONIC FOLLICULOUS SORE THROAT.—ATROPHIC PHARYNGITIS.—SCROFULOUS SORE THROAT.—DARTROUS SORE THROAT.	

CHAPTER VII.

SPECIAL AFFECTIONS OF THE SOFT PALATE AND UVULA.....	204
THE PHARYNGO-PALATINE MUSCLES.—INFLAMMATION OF THE PALATE.—LUPUS.—MORBID GROWTHS OF THE PALATE.—DEFORMATIVE ADHESIONS OF THE SOFT PALATE.—CLEFT PALATE.—WOUNDS OF THE SOFT PALATE.—NEUROSES OF THE PALATE.—CHRONIC ELONGATION OF THE UVULA.—EDEMA OF THE UVULA.—MORBID GROWTHS OF THE UVULA.—BIFID UVULA.—PARALYSIS OF THE UVULA.	

CHAPTER VIII.

SPECIAL AFFECTIONS OF THE TONSILS.....	222
CHRONIC INFLAMMATION OF THE TONSILS.—HYPERTROPHY OF THE TONSILS.—ATROPHY OF THE TONSILS.—MORBID GROWTHS OF THE TONSILS.—CALCULI.—FOREIGN BODIES.	

CHAPTER IX.

SPECIAL AFFECTIONS OF THE PHARYNX.....	239
ABSCESS OF THE PHARYNX.—MORBID GROWTHS OF THE PHARYNX.—ADENOMA AT THE VAULT OF THE PHARYNX.—NASO-PHARYNGEAL TUMORS.—WOUNDS OF THE PHARYNX.—FOREIGN BODIES IN THE PHARYNX.—LUXATION OF THE HYOID BONE.—DEFORMITIES OF THE PHARYNX.—FISTULE OF THE PHARYNX.—STENOSIS OF THE PHARYNX.—PHARYNGOCELE.—NEUROSES OF THE PHARYNX.	

CHAPTER X.

SPECIAL AFFECTIONS OF THE ŒSOPHAGUS.....	282
ŒSOPHAGITIS.—IMPERFORATE ŒSOPHAGUS.—FISTULE OF THE ŒSOPHAGUS.—STRICTURE (STENOSIS) OF THE ŒSOPHAGUS.—COMPRESSION OF THE ŒSOPHAGUS.—DILATATION OF THE ŒSOPHAGUS; ŒSOPHAGOCELE.—MORBID GROWTHS IN THE ŒSOPHAGUS.—CARCINOMA OF THE ŒSOPHAGUS.—WOUNDS AND INJURIES OF THE ŒSOPHAGUS.—PERFORATION OF THE ŒSOPHAGUS.—FOREIGN BODIES IN THE PHARYNX AND ŒSOPHAGUS.—FANCIED BODIES IN THE PHARYNX AND ŒSOPHAGUS.—NEUROSES OF THE ŒSOPHAGUS.—(SO-CALLED) PROGRESSIVE BULBAR PARALYSIS.	

CHAPTER XI.

	PAGE
AFFECTIONS OF THE NASAL PASSAGES.....	331

ACUTE CORYZA.—GONORRHEAL CORYZA.—IDIOSYNCRATIC CORYZA.—INFLUENZA. — CHRONIC CORYZA. — NASAL ABSCESS. — EPISTAXIS. — SYPHILITIC AFFECTIONS OF THE NASAL PASSAGES.—STENOSIS OF THE NASAL PASSAGES.—CONGENITAL OCCLUSION OF THE NASAL PASSAGES.—FOREIGN BODIES IN THE NASAL PASSAGES.—CALCAREOUS ACCRETIONS IN THE NASAL FOSSÆ (RHINOLITHS).—TUMORS OF THE NASAL PASSAGES.—NEUROSES OF THE NASAL PASSAGES.

CHAPTER XII.

AFFECTIONS OF THE SEPTUM NARIUM.....	407
--------------------------------------	-----

INFLAMMATION AND ABSCESS OF THE SEPTUM NARIUM.—SUBMUCOUS INFILTRATION AT THE SIDES OF THE VOMER.—DEFLECTION OF SEPTUM FROM MIDDLE LINE.—FRACTURES OF NASAL SEPTUM.—TUMORS OF THE SEPTUM.

CHAPTER XIII.

AFFECTIONS OF THE FRONTAL SINUS.....	414
--------------------------------------	-----

INFLAMMATION AND ABSCESS.—TUMORS OF THE FRONTAL SINUS.—FOREIGN BODIES IN THE FRONTAL SINUSES.

CHAPTER XIV.

AFFECTIONS OF THE LARYNX AND TRACHEA.....	420
---	-----

ACUTE LARYNGITIS. — PHLEGMONOUS LARYNGITIS. — ERYSIPELATOUS LARYNGITIS.—TRAUMATIC LARYNGITIS.—ABSCESS OF THE LARYNX.—CEDEMA OF THE LARYNX.—CROUP.—TRACHEITIS.—CHRONIC LARYNGITIS. — TUBERCULOUS LARYNGITIS. — SYPHILITIC LARYNGITIS. — PRIMARY CHONDritis AND PERICHONDritis.—LUPUS.—LEPRA.—HYPERTROPHY OF THE LARYNX. — MORBID GROWTHS OF THE LARYNX.—EVERSION OF THE VENTRICLE OF THE LARYNX.—MORBID GROWTHS OF THE TRACHEA.—TRACHEOCELE.—CARCINOMA OF THE LARYNX AND TRACHEA. — STENOSIS OF THE LARYNX AND TRACHEA.—FISTULÆ OF THE LARYNX AND TRACHEA.—WOUNDS OF THE LARYNX AND TRACHEA. — FRACTURES OF THE LARYNX AND TRACHEA.—CONTUSIONS OF THE LARYNX AND TRACHEA.—RUPTURE OF THE TRACHEA.—FOREIGN BODIES IN THE LARYNX AND TRACHEA.—NEUROSES OF THE LARYNX.—SPASM OF THE LARYNX.—SPASM OF THE TRACHEA.—IRRITATIVE COUGH.—SPASMODIC COUGH.—MOTOR PARALYSES OF THE LARYNX.

CHAPTER XV.

SURGICAL OPERATIONS UPON THE LARYNX AND TRACHEA.....	PAGE 660
ARTIFICIAL OPENINGS INTO THE LARYNX AND TRACHEA.—CATHETERIZA- TION OF LARYNX AND TRACHEA.—EXSECTION (EXTIRPATION) OF THE LARYNX.	

CHAPTER XVI.

AFFECTIONS OF THE LARYNGO-PHARYNGEAL AND OF THE GLOSSO- EPIGLOTTIC SINUSES.....	686
--	-----

CHAPTER XVII.

EXTERNAL AFFECTIONS OF THE NECK AND THROAT.....	688
DIFFUSE INFLAMMATION OF THE CONNECTIVE TISSUE OF THE NECK.— TUMORS OF THE NECK.—MUMPS.—BURSAL TUMORS OF THE THYRO- HYOID REGION.—AFFECTIONS OF THE THYROID GLAND.—AFFEC- TIONS OF THE PYMUS GLAND.	

LIST OF ILLUSTRATIONS.

FIG.	PAGE
1. Folding tongue-depressors.....	9
2. Tuerck's tongue-depressor.....	10
3. Author's hard-rubber tongue-depressor.....	11
4. Palate elevator.....	12
5. Examination of nasal passage anteriorly, with hair-pin retractor.....	14
6. Duplay's nasal speculum.....	14
7. Elsberg's trivalve nasal speculum.....	15
8. Thudichum's nasal speculum.....	15
9. Fraenkel's nasal speculum.....	15
10. Laryngoscopic mirror of circular form, with thick stem, as used by the author.....	20
11. Circular mirror, with stout shank and flat handle.....	21
12. The laryngoscopic mirror in position, stem to one side.....	22
13. Manner of holding laryngoscopic mirror preparatory to its introduction....	24
14. Relative relations of larynx and its image in the laryngoscopic mirror (stem uppermost).....	25
15. Diagrammatic representation of the reflection of the glottis in the laryngoscopic mirror (altered from Mandl).....	26
16. Dobell's tongue-holder.....	29
17. Bruns' pincette for holding up the epiglottis.....	33
18. Examination by reflection of solar rays (altered from Moura).....	36
19. Examination by diffuse daylight reflected from concave mirror attached to forehead.....	37
20. Perforated reflector attached to Kramer's head-band by a ball-and-socket joint. Shown in position for covering one eye.....	37
21. Examination by direct artificial light (Moura).....	38
22. Krishaber's illuminator.....	39
23. Mackenzie's rack-movement illuminator and bull-eye condenser.....	39
24. Tobold's illuminator and reflector adjusted to a student-lamp (Tobold)....	40
25. Author's arrangement of Tobold's illuminating apparatus; fed with gas; supported from floor; with arm of reflector above the lenses; the whole moving in mass up or down, right or left, by means of a supporting rod sliding in the socket of the stand.....	41
26. Examination by means of Tobold's pocket illuminator (Tobold).....	42
27. Tobold's fenestrated tracheal canula, with small metallic mirror, for infraglottic laryngoscopy.....	49
28. Enlarged sketch of normal laryngoscopic image in respiration, slightly forced to exhibit the chief cardinal points of observation in detail.....	53

FIG.	PAGE
29. Arched epiglottis.....	55
30. Indented epiglottis.....	55
31. Assymetric epiglottis.....	55
32. Depressed epiglottis.....	55
33. Omega-like epiglottis.....	55
34. Pointed and depressed epiglottis of children.....	55
35. Normal larynx during inspiration.....	58
36. The ventricular bands in approximation (Tuerck).....	59
37. Normal larynx in phonation.....	60
38. Normal larynx of the female in respiration.....	61
39. Normal larynx of the female in the formation of head-tones.....	61
40. View of the left side of the larynx (Tuerck).....	67
41. View of right bronchus (Tuerck).....	67
42. View of posterior wall of trachea, and bifurcation of the primitive bronchi.....	68
43. Rhinoscopic mirror with curved shank.....	72
44. Rhinoscopic image.....	74
45. Rhinoscopic image in a case of cleft palate.....	76
46. Case of cleft palate from which rhinoscopic image (Fig. 45) was obtained....	76
47. View of left Eustachian orifice.....	76
48. Author's caustic pencil.....	96
49. Syphilitic ravages in the soft palate, tonsil, and lateral pharyngeal wall....	125
50. Syphilitic ravages in the epiglottis and lateral laryngeal wall (in same case as Fig. 49).....	125
51. Folliculous pharyngitis.....	184
52. Chronic folliculous pharyngitis.....	186
53. Author's forceps for local applications to pharynx.....	194
54. Dr. Mears' toothed forceps.....	194
55. Author's arrangement of metallic spray-producer on Bergson's principle, with duck-bill tubes and reservoir on top; for use with compressed air from air-press or rubber bulb.....	197
56. Author's arrangement of duck-bill glass tubes for sprays, driven by steam, on Siegle's principle.....	197
57. Anterior view of the musculature of the pharynx and palate after removal of tongue, hyoid bone, and larynx, as far as the posterior segment of its thyroid cartilage (Luschka).....	205
58. Posterior view of the palatine muscles (Luschka).....	206
59. Separate investment of the palato-glossi muscles.....	207
60. Gemrig's uvula scissors.....	219
61. Elsberg's uvula sector.....	219
62. Mouth-distender.....	229
63. Physick's amygdalatome.....	230
64. Fahnestock's amygdalatome.....	230
65. Charrière's amygdalatome.....	231
66. Adenoid tissue of vault of pharynx (Luschka).....	254
67. Pharyngeal bursa (Luschka).....	254
68. Glandular tissue at vault of pharynx, in a case of cleft palate.....	256
69. Pharyngeal extremity of left Eustachian tube, as visible in a case of cleft of hard and soft palate.....	257
70. Rhinoscopic view of glandular vegetations at vault of pharynx.....	259
71. Naso-pharyngeal syringe.....	261

LIST OF ILLUSTRATIONS.

XV

FIG.	PAGE
72. Author's (retro-nasal) pharyngeal cutting forceps.....	262
73. Rhinoscopic view of glandular hypertrophy at vault of pharynx.....	262
74. Author's pharyngeal forceps for seizing naso-pharyngeal tumors.....	266
75. Author's naso-pharyngeal electrolytic needle.....	270
76. Graduated œsophageal dilator.....	293
77. Œsophageal dilators.....	294
78. Enormous dilatation of œsophagus (Luschka).....	297
79. Bond's œsophageal forceps.....	315
80. Burge's œsophageal forceps.....	315
81. Horsehair snare and probang for the extraction of foreign bodies from the œsophagus.....	317
82. Pomeroy's nasal inhaler.....	339
83. Living parasites from nasal excreta (Cutter).....	345
84. Syphon nasal douche.....	356
85. Syphon douche with compression-bulb.....	356
86. Manner of arranging syphon nasal douche.....	356
87. Bottle nasal douche.....	357
88. Thudichum's nasal douche (Thudichum).....	357
89. Author's posterior nasal syringe.....	358
90. Fullgraf's retro-nasal douche.....	359
91. Lewin's apparatus for generating nascent chloride of ammonium, as modi- fied by the author, for forcing the nascent vapor forward by compressed air.....	371
92. Canula of Belloeq, for tamponing the posterior nares.....	381
93. Gross's instruments for removal of foreign bodies from the nasal pas- sages.....	389
94. Gross's polypus-forceps.....	396
95. Rhinoscopic image of œdema of nasal septum.....	409
96. Rhinoscopic image of œdema of nasal septum.....	409
97. Submucous infiltration of posterior nasal septum, supposed to be due to mycelium.....	409
98. Gaping of glottis from incomplete tension of vocal cords (Ziemssen).....	426
99. Gaping of arytenoidal portion of glottis (Ziemssen).....	426
100. Erysipelatous laryngitis (Tuerck).....	437
101. Œdema of the larynx.....	449
102. Œdema of the epiglottis.....	450
103. Sub-glottic œdema of the larynx.....	456
104. Enlarged glands at base of the tongue.....	478
105. Chronic tumefaction of the lower surface of the vocal cords, and of the posterior wall of the larynx (Tuerck).....	479
106. Same case as Fig. 105, eight months after tracheotomy; showing the tracheotomy-tube in position, projecting just beneath the posterior portion of the image of the glottis (Tuerck).....	479
107. Laryngeal douche.....	487
108. Tobold's laryngeal syringe.....	488
109. Mackenzie's brush holder.....	490
110. Sponge-holder with bayonet-catch.....	490
111. Author's lateral-spring laryngeal forceps for securing minute fragments of sponge or amadou.....	492
112. Rauchfuss's laryngeal powder-insufflator.....	493

FIG.	PAGE
113. Pyriform tumefaction of supra-arytenoid structures in tuberculous laryngitis; showing also linear ulceration of vocal cords, and ulceration of inter-arytenoid fold.....	501
114. Ulceration on posterior wall of larynx (Tuerck).....	503
115. Ulceration of epiglottis, ventricular bands, vocal cords, and external face of one supra-arytenoid eminence, with denudation of vocal process of same side.....	503
116. Ulceration of epiglottis, ventricular bands, and interior of larynx.....	504
117. Growths on vocal cords and inter-arytenoid fold in a case of phthisis	506
118. Membranous adhesions between ulcerated growths on vocal cords; same case	506
119. Ultimate formation of web of membrane between vocal cords in same case.	506
120. Œdema of larynx in tuberculous phthisis, with central ulceration of lingual face of epiglottis, and linear cicatrix marking previous ulceration of its free edge.....	507
121. Œdema of larynx with ulceration, in the latter stage of phthisis.....	507
122. Extensive destruction of epiglottis (Tuerck).....	508
123. Perichondritis of arytenoid cartilage in tuberculosis. Ulceration in inter-arytenoid fold.....	509
124. Abscess from perichondritis of arytenoid, projecting above the glottis....	509
125. Perichondritis of right arytenoid and right side of cricoid cartilage, with necrosis of latter, and protrusion beneath the displaced vocal cord; ulceration of left vocal cord, and fungus vegetation in the inter-arytenoid fold	510
126. Multiple gummata (Mandl).....	520
127. Gumma on inter-arytenoid fold.....	520
128. Primary perichondritis of cricoid cartilage, abscess unopened. Anchylosis of left arytenoid (Tuerck).....	528
129. Perichondritis of cricoid, with loss of right arytenoid, in a case of typhoid fever (Tuerck)	528
130. Lupus of the larynx (Tuerck).....	529
131. Lupus of larynx (Ziemssen).....	530
132. Syphilis of larynx (Ziemssen).....	530
133. Appearance of larynx in leprosy (Elsberg).....	532
134. Appearance of larynx in leprosy (Elsberg)	532
135. Tumors on both vocal cords, producing sudden death.....	540
136. Tumor on left vocal cord, producing sudden death.....	540
137. Tobold's concealed holder, for molten caustic (Tobold).....	550
138. Excrescence on left vocal cord (destroyed by caustic).....	550
139. Excrescence on right vocal cord (destroyed by caustic).....	550
140. Epithelial growths on both vocal cords, in a case of phthisis.....	551
141. Appearance of cords after destruction of growths with chromic acid.....	551
142. Tobold's laryngeal forceps (Tobold).....	553
143. Fauvel's laryngeal forceps.....	554
144. Cuzco's laryngeal forceps.....	554
145. Luer's laryngeal forceps.....	554
146. Mackenzie's laryngeal forceps (Mackenzie).....	555
147. Mackenzie's laryngeal tube-forceps and scissors (Mackenzie).....	556
148. Durham's flexible forceps.....	557
149. Papillary growths in phthisis.....	557

FIG.	PAGE
150. Papilloma occupying posterior laryngeal wall.....	557
151. Pedunculated neoplasm on vocal cord, in a case of phthisis.....	558
152. Pedunculated fibroma beneath vocal cord.....	558
153. Cyst of vocal cord.....	558
154. Laryngeal growths.....	559
155. Same case as Fig. 154, after removal of growths.....	559
156. Tobold's concealed knife (Tobold).....	560
157. Tobold's lancet-pointed probe (Tobold).....	560
158. Tobold's knife, with single cutting edge (Tobold).....	561
159. Tobold's knife, with double cutting edge (Tobold).....	561
160. Tobold's horizontally cutting scissors (Tobold).....	563
161. Tobold's perpendicularly cutting scissors (Tobold).....	563
162. Stoerck's universal handle for guillotine, etc., with two forms of guillotine shown below.....	563
163. Gibb's wire-snare for dividing laryngeal growths (Gibb).....	564
164. Tobold's wire-snare for dividing laryngeal growths (Tobold).....	564
165. Guarded wheel <i>écraseur</i> (Mackenzie).....	565
166. Tobold's chain <i>écraseur</i> (Tobold).....	566
167. Voltolini's laryngeal galvano-cautery.....	566
168. Author's galvano-cautery for the larynx.....	566
169-174. Von Bruns' instruments for galvano-cautery (Bruns).....	567
175. Neoplasm on epiglottis.....	568
176. Fibroma on right vocal cord, removed after thyrotomy without tracheotomy.....	569
177. Laryngeal growth, for the removal of which thyrotomy was performed after tracheotomy.....	570
178. Appearance of the parts some months after the operation.....	570
179. Appearance of the parts some years after the operation.....	570
180. Tumor of the trachea (Schroetter).....	577
181. Involution of trachea by an aneurism of arch of aorta.....	579
182. Medullary carcinoma of larynx, in early stage.....	583
183. Schroetter's method of dilating stenosis of the larynx (Labus).....	591
184. Mackenzie's dilator, for laryngeal stenosis.....	592
185. Bilateral paralysis of thyro-arytenoids in acute laryngitis (Ziemssen).....	640
186. Unilateral paralysis of (right) thyro-arytenoid (Ziemssen).....	640
187. Bilateral paralysis of thyro-arytenoid, with paresis of arytenoid (Ziemssen).....	641
188. Bilateral paralysis of recurrent nerve, caused by cancer of the <i>œsophagus</i> (Ziemssen).....	644
189. Cadaveric position of the vocal cords, drawn from a larynx removed from a recent cadaver (Ziemssen).....	644
190. Mackenzie's laryngeal electrodes.....	646
191. Ziemssen's double and single electrodes (Ziemssen).....	647
192. Paralysis of left vocal cord in a case of aneurism of the aorta, appearance during respiration.....	651
193. Paralysis of left vocal cord in a case of aneurism of the aorta. Appearance during attempted phonation.....	651
194. Crossing of the supra-arytenoid cartilages (Ziemssen).....	651
195. Paralysis of left vocal cord in a case of phthisis. Appearance during respiration.....	652
196. Paralysis of left vocal cord in a case of phthisis. Appearance during attempt at phonation.....	652

FIG.	PAGE
197. Paralysis of the arytenoid in acute laryngitis (Ziemssen).....	653
198. Bilateral paralysis of the posterior crico-arytenoids. Patient wearing the canula	656
199. Bilateral paralysis of the posterior crico-arytenoids; in the same case as Fig. 198, at a later stage of the affection.....	656
200. Trousseau's double tracheotomy-tube.	663
201. Howard's extemporaneous tracheotomy-tube.....	665
202. Howard's extemporaneous tracheotomy-tube.....	665
203. Trousseau's dilator.....	673
204. Author's rigid conductor, for facilitating introduction of tracheotomy-tube.	673
205. Trousseau's forceps for the tracheal canula.....	676
206. Luer's pea-valved tracheotomy-tube.....	679
207. Great displacement of larynx and trachea by cervical tumor.....	693
208. Laryngoscopic view of horizontal displacement of larynx to the extreme right by cervical tumor.....	693

DISEASES OF THE THROAT.

CHAPTER I.

DISEASES OF THE THROAT IN GENERAL.

DISEASES of the throat do not differ materially in pathology from diseases of like tissues or tissue-elements elsewhere. Inflammations, idiopathic, deuteropathic, and traumatic, occur in various grades, or occur as constituent manifestations or results of systemic affections, such as tuberculosis, scrofulosis, syphilis, cancer, rheumatism, gout, erysipelas and the exanthemata, continued fevers, diseases of the large glands, chronic cutaneous affections, and other maladies. Then we encounter the various products of inflammation—adhesions of tissues, fistulæ, strictures, glandular enlargements, tumors benign and malignant, aneurisms, etc. ; likewise wounds and other local injuries, mechanical and chemical ; foreign bodies, introduced by accident or design ; local results, such as œdema, pustular inflammation and destructive ulceration from the use of certain drugs, such as mercury, antimony, iodine and bromine, belladonna and stramonium, and some others ; and, finally, various disorders of nervous origin.

The mucous membrane of the throat is exceedingly prone to become diseased, partly from its exposure as an inlet to extraneous influences, partly from a special proclivity, the nature of which is but imperfectly comprehended, and partly from extension of disease in adjacent structures, not infrequently the skin, with the affections of which it has much in common, in consequence, likely, of analogous construction, and perhaps of ultimate nervous distribution.

The treatment of diseases of the throat is rendered more

protracted than the treatment of diseases in most other portions of the body, by reason of the difficulty encountered in protecting the affected structures from the contact of the air, and the impracticability of keeping up continuous local medication; circumstances which compel a course of management differing from that which would be employed in analogous affections manifested elsewhere, where we avail ourselves of the plaster and the compress, the poultice and the embrocation. Topical treatment being required in many affections of the throat, the exercise of great care is essential in the selection of local remedial agents, inasmuch as some of them are capable of being promptly absorbed by the nasal and bronchial mucous membrane, and may thus produce objectionable systemic effects; while, for similar reasons, caution is necessary to prevent the deglutition of the local remedy when of such a nature as to induce any deleterious influence from its ingestion, or its presence as a foreign or toxic body.

In almost all diseases of the throat, the secretion from the mucous membrane is affected. Sometimes it is simply diminished in quantity, sometimes it is simply increased; most frequently, however, it is altered in quality as well as in quantity.

The normal secretion of the epithelial cells of the mucous membrane of the throat is seen to be a transparent, slightly viscous, aqueous exhalation, equably diffused over the surface, and giving little or no refractive evidence of its presence. It just serves to keep the parts in the moist, pliable state requisite for comfort; and it protects them from the irritating influence of extraneous matters, whether present in the air, or brought in direct contact under special circumstances of avocation or exposure.

The most common effect of simple irritation of the mucous membrane is the collection of this exhalation into globules or drops, which present, according to their volume and the direction of light under which they are viewed, the appearance of either minute vesicles or papules; and although this is not an evidence of active or serious disease, throats exhibiting this appearance are often denominated granular, not in the sense of description merely, but with the conception that the mucous membrane is deprived of its epithelial coat, and that the globules, papules, or granules are the prominences of enlarged follicles or muciparous glands—a condition which sometimes

exists under circumstances mentioned later in the volume. Under this misapprehension, throats are unhesitatingly cauterized and re-cauterized, and therefore heedlessly subjected to the chance of sustaining permanent injury ; a result, however, which fortunately does not always follow in this class of affections, inasmuch as reparation is prompt, owing to the usually good state of the general health, and the innocuousness of the agent, nitrate of silver, most frequently applied upon the healthy mucous membrane. Sometimes, indeed, it must be acknowledged that such treatment, if not repeated frequently, as is too often the case, seems to rouse up the sluggish vascular action of the part, and conduce to prompt resumption of function.

One of the earliest and most persistent indications of inflammation of the mucous membrane is the secretion or development of mucus. The researches of physiologists teach that healthy mucous membrane does not secrete typical mucus, such as we are accustomed to so term it in diseased conditions of the membrane.

When mucous membrane becomes diseased, the newly formed nuclei, which would normally have been developed into epithelial cells, take on the prolific cell-growth of an organization lower in the scale, and adhere to each other in masses which, with the fluids in which they are suspended, are described as mucus. This increased cell-action is very great, often producing material in much larger abundance than could be furnished by the extent of mucous surface involved, were the entire mass of mucus a mere secretion from that surface. Physiologists account for the copious collections of mucus sometimes encountered on mucous membranes, by the continued development of the nuclei and their offspring, after their deposition upon the exterior surface of the membrane.

In the absence of epithelium from mucous membrane, a superficial excavation is noticed, a mere erosion or abrasion, liable to be mistaken for ulceration involving the proper tissue of the membrane itself. The uneven prominences observed upon the surface of the mucous membrane in the inflammatory condition, is due to the rapid and unequal proliferation of immature epithelium cells, which, in their transformation into mucus, are progressing through the membrane to the surface, pushing it outwards from behind, as it were ; and as this pro-

cess continues in the localities in which it first set up, the enlargements become more or less permanent, until the action is changed by treatment or otherwise. There is by no means a necessary destruction of the superficial epithelium of mucous membranes secreting mucus, as met with even in severe catarrhal inflammations, and even though these may be purulent in character. In fact, experience shows that this condition is exceptional, antecedent to such cases only as evince a disposition to ulceration from their commencement, whether arising from special diathesis, atony of constitution, violence of action, or lack of proper attention at an early period of the disease.

In addition to the mucus found upon the surface of diseased mucous membrane, fibrin is sometimes present in the secretion, small quantities of it having undergone spontaneous coagulation into clots, flocculi, or component texture of adventitious membrane.

In some forms of inflammation of the mucous membrane there is secreted in abundance an albuminous product, which, under certain conditions, entangling the prolific cell-growth simultaneously excited by the inflammatory process, becomes transformed into a thin pellicle or membrane, either from coagulation of the fibrin which it contains, or from evaporation of the watery constituents present at the period of exudation.

The color of the inflamed mucous membrane is some shade of red, the intensity of discoloration varying with the locality of the diseased action, the vascularity of the tissues involved, and the severity of the inflammation. The mucous membrane overlying the soft structures is more vascular than that overlying the hard structures, and hence the color is more vivid. The submucous connective tissue often suffers in inflammations of the mucous membrane, and is liable to tumefaction from accumulation of serum, fibrin, blood, pus, or other products of inflammation; this tumefaction occurring especially over the softer structures, to which the mucous membrane is more or less adherent by lax connective tissue. This condition, beneath the mucous membrane, when in certain localities, becomes a mechanical cause of death by suffocation.

Most of the inflammatory affections of the throat commence in the pharynx, or pharynx and mouth; though not infrequently they begin in the nasal passages. Sometimes the initial

disturbance takes place in the larynx, or even in the trachea or bronchi. Sometimes it begins in the alimentary tract. Although the pharynx is directly continuous with the œsophagus, the extension of the inflammatory process is less apt to proceed along that tube than to extend into the respiratory tract; and this, most probably, because the flaccid œsophagus is normally closed except during the act of deglutition, and thus is less exposed to atmospheric influences than the patulous respiratory tract. The continuity of the pharynx with the rest of the alimentary tract renders it liable, however, to participation in diseases of the digestive apparatus; and hence we frequently meet with pharyngeal disease as a consequence of such disorders, especially when chronic.

Certain anatomical regions of the throat are often diseased together, with comparative or absolute immunity of other anatomical regions. They may be separated into three groups. The first group comprises the anterior surface of the palate, the uvula, tonsils, and anterior palatine folds; the second, the posterior surface of the palate, the posterior nares, and the retro-nasal portion of the pharynx; and the third group comprises the base of the tongue, epiglottis, pharyngeal wall and superior orifice of the larynx, and the infrapalatine portion of the pharynx. Whether this is due to any special anatomical distribution of capillary or lymphatic vessels is not determined.

The direct action of cold upon the heated body, especially when the surface of the skin is in active perspiration, is the most frequent exciting cause of direct irritation leading to inflammatory affections of the pharyngeal mucous membrane, as it is also the most frequent exciting cause of diseases of the respiratory mucous membrane; and instances are not seldom met with in which irritation of this kind leads to the expectoration of more or less translucent sputa, sometimes from the pharynx, sometimes from the larynx, trachea, or bronchi of the perfectly healthy individual, after sudden or unusual exposure to cold during changeable and inclement weather. Such exposure, in a constitution debilitated by overwork, or predisposed to disease of the throat by reason of the scrofulous or tuberculous diathesis, is liable to excite serious disease, often difficult of cure, and sometimes leading to permanent injury and fatal termination.

The next most frequent source of irritation of the mucous

membrane of the throat is the inhalation or inspiration of solid or fluid particles freely present in the atmosphere under certain conditions. These act mechanically or chemically upon the structures with which they come in contact. Artisans exposed to the dust of various workshops, attendants in chemical laboratories, residents in and near factories, and others similarly imperilled, are most apt to suffer in this way.

Another frequent source of irritation, eventuating in inflammation of the throat of a subacute or chronic character, is the inhalation of an atmosphere impregnated with the products of tobacco-smoke. Tobacco-smoking is in itself regarded as an exciting cause of the affection, and, doubtless, is so in many instances; and even when not in itself the initial cause of the disturbance, has a great deal to do with its persistence and chronicity. Sore throats, in every way similar to those attributed to the effects of smoking, are, however, met with in individuals who are not at all addicted to the use of tobacco; and a cause of this kind must be very infrequent in females, even in regions where women smoke. Exposure for hours at a time to the air of an apartment charged with the fumes of tobacco is a much more frequent source of disease in the throat than the mere smoking of tobacco in a private room.

Another apparent cause exists in the promiscuous use of hot and cold food and drink at the same repast. Thus one partakes of hot soup, or drinks hot coffee or tea, and cools the mouth and throat by draughts of ice-water taken at intervals during the meal. Or, after enjoying a warm dinner, one indulges in ice-cream or water-ice, and follows this by a draught of hot coffee. This alternate application of hot and cold to the delicate mucous membrane of the throat, if persisted in, can hardly fail to place it in a condition favorable for the inflammatory process. A similar treatment of the cutaneous integument would be quite apt to induce an inflammatory affection of the skin.

An occasional cause of disease of the throat is overstraining the vocal cords in singing, screaming, public speaking, prolonged reading, talking to the deaf, quarrelling, and so on.

Finally, special diseases of the throat are due to the specific action of deleterious substances accidentally or periodically present in the atmosphere under certain conditions of time or locality, or lack of sanitary precautions.

Diseases of the throat are exceedingly apt to recur, and chronic affections manifest a marked disposition towards long continuance. On this account it is desirable that individuals thus predisposed be encouraged in the habitual use of the cold bath, or, at least, the matutinal sponging of the head, neck, and chest with cold water. This practice induces a certain amount of tolerance of exposure to atmospheric changes, and diminishes the susceptibility of the parts to disease. The cold sponge-bath, where it can be tolerated, is an admirable tonic to the skin, and, by promoting the capillary circulation, through it to the system at large. Its effects may be heightened, where desirable, by friction with a towel after the bath, and sometimes by friction before the bath also. The use of a rough towel or a flesh-brush is hardly requisite for this purpose, unless there be great difficulty in "bringing the blood to the surface," and not even then, unless the attainment of this object is considered sufficiently important to justify the harshness. If the cold bath chills the surface, or does not induce an agreeable glow after it, the specific gravity of the water should be increased by the addition of a due amount of table-, rock-, or sea-salt. In cases where this cannot be borne, local baths of warm water, warm salt and water, or acidulated water, to small portions of the surface at a time, may be substituted, and the system be gradually educated to endure the cold water as improvement progresses. In Germany, the application of the wet sheet on leaving the bed in the morning, followed by friction with a rough towel, and brisk exercise in the open air as soon as the patient is clad, is highly recommended. The systematic and scientific use of water is rarely understood in America.

A patient subject to sore throat should never keep on at night the underclothing worn during the day, but should turn it inside out and hang it up to air, so that it will be well dried and ventilated to resume in the morning. Frequent changes of underclothing are desirable, and woollen or silken fabrics, of texture suited to the season (three varieties of weight at least, for summer, autumn and spring, and depth of winter), are usually preferable to cotton. Two pair of boots or shoes should be in wear on alternate days, inasmuch as they are not likely to be free from moisture and perspiration by a single night's exposure; and an exceptionally well-soled pair should be kept for use in inclement weather. Water-proof shoes, rubbers, furs,

and mufflers for general use are not advisable. Wet garments should be changed for dry ones at the earliest opportunity. A person particularly impressible to draughts of cool air, especially if a confirmed invalid, should wear a respirator, or a folded veil, or some similar contrivance before the mouth when facing the wind, in order that the temperature of the inspired air should be raised by the warmth imparted to the appliance by the breath of expiration.

The management of diseases of the throat has become much more certain and satisfactory of late years by reason of the great assistance afforded by laryngoscopy in recognizing the locality and often the nature of obscure maladies, and in prosecuting certain topical applications and operations otherwise hazardous or impracticable. Physicians should assure themselves by observation of the value of laryngoscopy, and avail themselves of opportunities, as they present, to become familiar with the manipulatory procedure. It is very easily learned under good tuition; and half an hour's demonstration ought certainly to suffice to acquire sufficient skill to use the laryngoscope for diagnostic purposes. Numbers of practitioners and even medical students have learned to make a fairly satisfactory laryngoscopic examination, as far as the mere manipulation of the throat mirror is concerned, at the very first attempt, after having been shown the manœuvre and having it correctly and carefully explained. The importance of laryngoscopy is now generally appreciated in medical schools, many of which are provided with special departments for its study; and some medical centres, notably Vienna and London, have become famous for their throat clinics and the good work that has emanated therefrom.

CHAPTER II.

EXAMINATION OF THE THROAT AND NASAL PASSAGES.

Direct Inspection of the Throat.—In order to recognize diseased throats, frequent opportunities should be taken to observe healthy ones. Descriptions and illustrations are always more or less unsatisfactory.

To obtain a good view of the middle portion of the pharynx, the tonsils, palate, and uvula, it is usually necessary to depress the tongue. The fore-finger answers for this purpose in many instances, especially in children, who are apt to become frightened at the attempt to place instruments in the mouth. It sinks far enough in the tissues to be out of the way of the light. If the finger is objectionable, the handle of a spoon, the blade of a butter-knife, a paper-cutter, a pen-holder, or anything of that kind at hand will often suffice; but a special tongue-depressor with a handle out of the line of vision is the most suitable appliance. Some individuals are able to expose the pharynx so well by voluntary depression of the base of the tongue, that artificial aid is unnecessary for satisfactory inspection. Sets of false teeth should always be removed, in systematic examination of the throat, in order that the palate should be thoroughly exposed to unimpeded inspection, as well as to determine the fact whether an otherwise unaccountable chronic sore throat may not be due to irritation kept up by an ill-fitting plate.

TONGUE-DEPRESSORS.—An ordinary form of tongue-depressor, much used in the United States, is a metal or hard-rubber blade, roughened on its inferior surface, and set in a stout, roughened handle. For convenience of carriage, the tongue-piece is usually attached by hinge to the shank of the handle (Fig. 1). In some individuals, considerable force is requisite to keep a muscular tongue depressed, and in such instances it is often well to press one

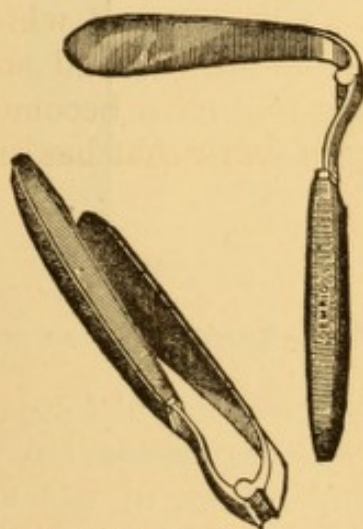


FIG. 1.—Folding tongue-depressors.

lateral half of the tongue down first, and the other afterwards; but usually, if the tongue-piece is lightly laid upon the tongue, and gently but firmly pressed upon the organ, the manipulation is effective in a few seconds. To gain a good view of the pharynx, the tongue-piece should be long enough to reach well the base of the tongue, and should be excavated on its under surface, or else bulged into a sort of pad, and roughened in order to maintain a good hold upon the organ. Smooth-faced tongue-pieces are apt to slip forward.

By gradually pressing the posterior portion of the tongue downward and forward, and at the same time causing the patient to lower the chin more and more upon the breast, the entire lower portion of the pharynx can almost always be exposed, and the free edge of the epiglottis, often with more or less of its lingual face; and sometimes even the upper circumference of the entire larynx, especially if the epiglottis be titillated with the tip of the tongue-depressor so as to excite slight gagging. Some patients depress their tongues and open their mouths so well, that, looking down upon the parts, these

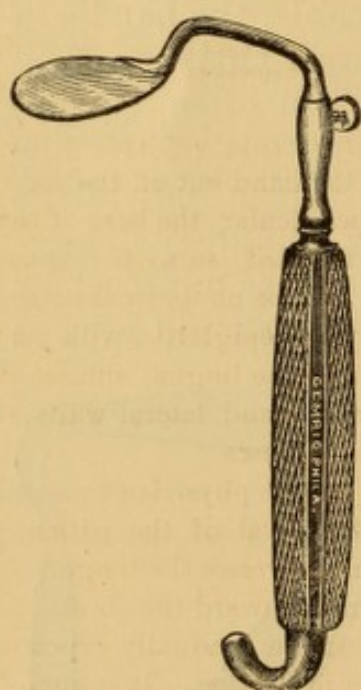

FIG. 2.—Tuerck's tongue-depressor.

structures can be seen without the aid of any mechanical appliance whatever; and a few cases are on record in which by such voluntary effort of the patient a view has been obtained of the interior of the larynx down to the vocal cords. Tobold mentions one¹ in which he was able to see the action of the lips of the glottis in this manner, and also to recognize a papilloma upon the left vocal cord. Dr. Tobold also mentions that, with the assistance of a knee-shaped spatula which he has devised for exposing the pharynx, he has been able on several occasions to remove a fibroid tumor situated in the pharynx at the level of the arytenoid cartilages, and which he could not get at even with the aid of the laryngoscope.

Various useful forms of depressors, especially adapted for forcible depression, have been devised by Church, Tuerck, Tobold, and others, of which Fraenkel's modification of Tuerck's depressor, with the handle to one side, is one of the best (Fig. 2).

¹ Lehrbuch der Laryngoskopie, 2d Edition. Berlin, 1869, p. 43.

Dr. Voltolini¹ recommends drawing the tongue out as far as possible, and then placing the tongue-depressor as far back as practicable for the purpose of inducing retching, which exposes the lower portion of the pharynx to direct though momentary view.

A tongue-depressor devised by myself² (Fig. 3) has some advantages in special cases, and is particularly efficient in exposing the pharynx in the manner already described. It is composed of a single piece of hard rubber, which recommends itself by the facility with which it can be kept clean and sweet—no slight desideratum when an instrument is frequently exposed to the secretions from the mouth, and to contact with the various caustic substances used in the treatment of diseases of the throat. The shape could be readily altered at will to suit any peculiar conformation of tongue, were this ever necessary, by first holding the instrument for a moment or two in boiling water, or over a flame, so as to render it flexible. The lingual portion is five inches in length, curves gently forward, and is considerably bent at its terminal extremity, so as to embrace the posterior portion of the tongue in a shallow depression about an inch in length, scooped out of its lingual surface at this portion, thus affording a sufficiently firm hold upon the organ. The handle, which is of one piece with the blade, is bent downward under the tongue-piece, so that it comes beneath the chin when in use, and thus keeps the hand out of the way; while by drawing the handle forward towards the perpendicular, the base of the tongue is necessarily pressed downward and drawn forward, so as to expose the parts in the freest manner. When well applied, it will be no unusual occurrence to see distinctly the anterior or lingual surface of the epiglottis, with perhaps a portion of its crest, the glosso-epiglottic fold, and the lingual sinuses at either side; and, of course, a large extent of the posterior and lateral walls of the pharynx, and more or less of the laryngo-pharyngeal sinuses.

The best method of fully exposing the pharynx is for the physician to stand on the right side of the patient with his eye above the level of the patient's mouth, so as to look down into it, as it were, and, as he depresses the tongue, to make the patient gradually depress his chin more and more toward the chest. In this manner the posterior wall and sides of the pharynx are gradually exposed lower and lower down, and subjected to more thorough inspection. It is impossible to obtain as extended a view of the parts when standing in front of the patient and looking horizontally into the mouth. In cases of great muscular resistance on the part of the tongue it is well to use a depressor with a roughened oblong pad at its terminal extremity, which is pressed into the substance of the organ, paralyzing its contraction.

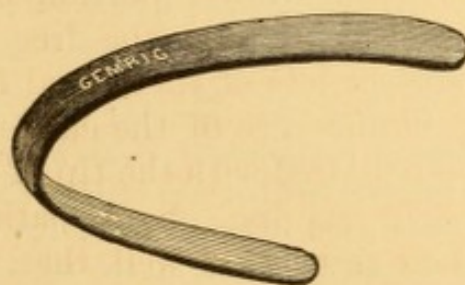


FIG. 3.—Author's hard-rubber tongue-depressor.

¹ Galvanokaustic. Wien, 1872, p. 72.

² The Medical Record, Vol. I., 1866, p. 348.

Examination of the upper portion of the pharynx is much facilitated by lifting the soft palate up gently upon a broad, bent hook (Fig. 4), or wire loop.




FIG. 4.—Palate Elevator.

To examine the contour of the tonsils and the angles of the throat properly, it is often requisite to press the palatine folds gently aside by means of any suitable appliance, as a bent wire, or blunt probe or hook; otherwise foreign bodies, small neoplasms, and slight alterations of tissue will frequently elude detection.

To gain more extended views of the pharynx, especially its roof, as well as views of the posterior surface of the palate, the aid of special reflecting mirrors is requisite (see Laryngoscopy and Rhinoscopy). When the light is not favorable to good illumination of the throat, it is of great advantage to use a reflector as described in the section on Laryngoscopy and Rhinoscopy. An ordinary hand lens, with a focus of from four to six inches, warmed and held in front of the patient's mouth, is often of great service in magnifying points (glands, small excavations, etc.) which are not sufficiently distinct to the unaided eye.

The parts subjected to direct inspection are: the interior of the mouth; the surface of the tongue; the anterior surface of the hard and soft palate and uvula; the palatine folds; the tonsils; more or less of the pharynx; and occasionally the anterior face of the epiglottis, with its lingual and pharyngeal attachments. In order to be able to recognize diseased conditions readily, frequent opportunities should be taken to inspect the normal throat, mere examination of which sometimes flushes it up under the gaze, in certain individuals. In the normal throat, viewed by sunlight, the anterior surface of the palate is of a light salmon-rose color, darker than the hard palate, into which it merges on each side without distinct lines of demarcation, but paler than the anterior palatine folds and the uvula. The palatine folds are sometimes brownish red at their edges. The orifices of the mucous glands of the palate are sometimes visible to the unaided eye as small pin-head elevations, in several more or less transverse rows, less than a line apart, and crossing the raphé. The size and shape of the uvula vary in individuals. The course, shape, and thickness of the palatine folds vary also. The posterior folds are thicker

broad, and more towards the middle line than the anterior pair. Between each pair of folds the tonsil gland appears, of a variable, but generally more or less compressed, ovoidal shape, red or irregularly yellowish red in color, normally of the bulk of a hazel-nut but very variable in size, and projecting beyond the anterior fold into the cavity of the throat. The surface of the tonsil is broken by a dozen or more vertical openings or crypts, orifices of the lacunæ, into which they run in various directions. Very often a mass of glands will lie below the tonsil, and sometimes a mass above it, large enough to look like a small additional tonsil, or a group of lobules detached from the main tonsil. The pharynx is of a deeper or more brownish roseate color, and irregularly bestrewn with nodulated glands, or groups of glands, projecting in eminences varying from the size of a small pin-head to that of a grain of wheat, and particularly liable to undergo hypertrophy as a result of subacute or of chronic inflammation. The mucous membrane sometimes lies in narrow longitudinal folds, and in its lower portion is so little adherent that it can be moved about upon the submucous tissues. The pharynx often appears deeper on one side (usually the right) than the other, owing to a similar conformation of the anterior bodies of the vertebræ. When the constrictor muscles of the pharynx contract, as they often do involuntarily during inspection, they draw the posterior palatine folds, into which they have insertion, towards each other, so that they nearly, or even actually meet, shutting the mouth off from the pharynx. The sensitiveness of the parts, and the amount of mucus and saliva present, vary greatly within normal limits.

Direct Inspection of the Nasal Passages; Anterior Rhinoscopy—A thorough examination of the nasal passages anteriorly is indicated in all diseases implicating the cavity of the nose. It will often suffice to throw the patient's head back so as to get the passages, as much as possible, in a horizontal plane, and let a good, strong light impinge upon them. Reflected daylight or reflected artificial light is often much better than direct sunlight or direct artificial light, as the illumination can be directed along the various surfaces in succession by slight movements of the reflector. The nostril may be pulled aside by means of a hook, bent probe, bent hair-pin or some

other small instrument (Fig. 5). A bright metallic tubular speculum, conical or funnel-shaped (Kramer's aural speculum), as large as can be introduced into the lower nasal meatus, or the middle one, as the case may be, is useful to direct the light

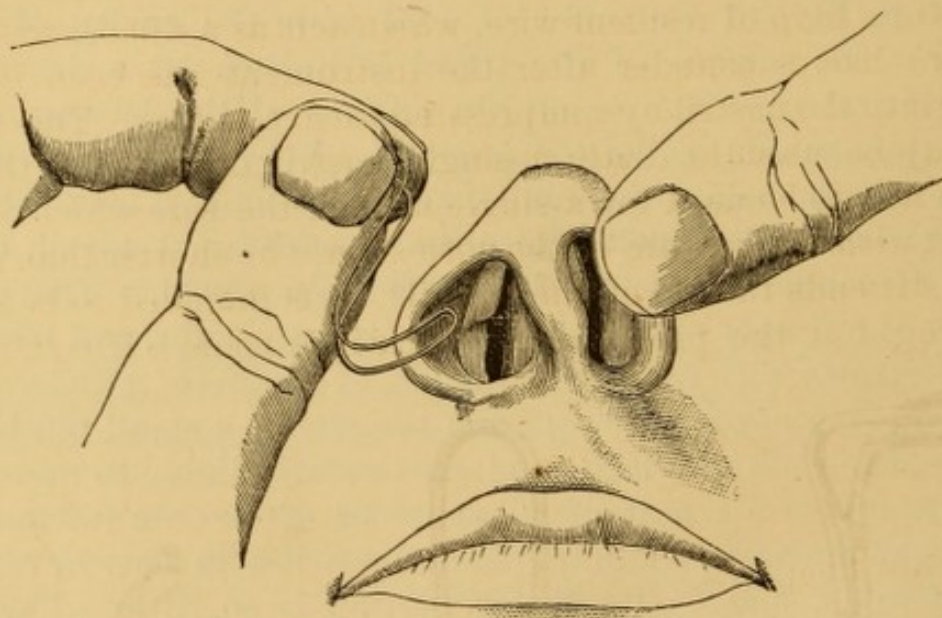


FIG. 5.—Examination of nasal passage anteriorly with hair-pin retractor. (From a drawing by Dr. Praeger.)

in turn on the walls of the passages, little by little. Duplay's bivalve speculum (Fig. 6) is preferred by many. It is pushed as far back as the positions of the nasal bones, so as to dilate the cartilaginous portions of the passage by turning a set-screw.

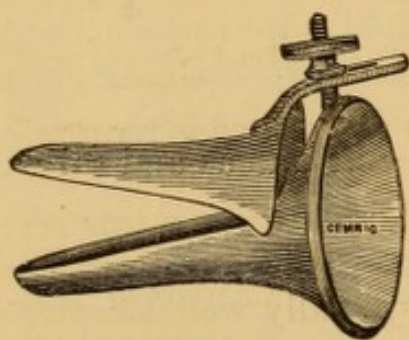


FIG. 6.—Duplay's nasal speculum.

Dr. Zaufal, of Prague, has recently extolled a lengthened speculum, with which he claims to be able to inspect the nasal passages more thoroughly than with any other appliance. He likewise employs a bivalved metallic speculum, two inches in length from the expanded extremity, the two halves being bodily separable by a very ingenious set-screw contrivance. I have no experience with either of these instruments.

In all specula which pass into the osseous portions of the nasal cavity it is requisite to move the patient's head in various directions in order to bring the different portions of surface within successive range of vision.

Dr. Elsberg's steel trivalve dilating speculum (Fig. 7), modelled on Laborde's tracheal dilator, is a very serviceable instrument, dilating the nostril vertically as well as horizontally. Dr. Thudichum's dilating speculum (Fig. 8) is a silver bilateral speculum, the two sides of which are in connection by means of a loop of resilient wire, which acts as a dilator to keep the two halves asunder after the instrument has been introduced into the nostril by compressing them together. This dilator may be used to dilate a single nostril or both of them. When it is to be used for a single nostril, the side which is in contact with the septum of the nose should be shorter than that which distends the ala of the nostril. It is intended to be self-retaining, but the pressure by which it is made self-retaining

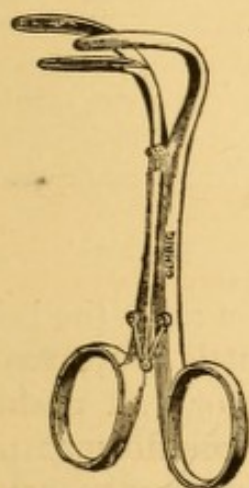


FIG. 7.—Elsberg's trivalve nasal speculum.

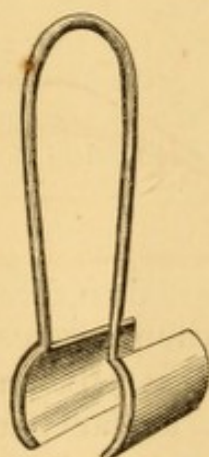


FIG. 8.—Thudichum's nasal speculum.

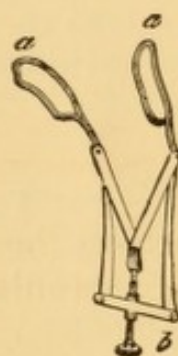


FIG. 9.—Fraenkel nasal speculum.

is usually so painful that the surgeon's assistance is required to compress the spring a little, and take off the tension. Dr. Schell, of Philadelphia, has improved this dilator by adjusting a regulating screw to the dilating spring. This speculum exposes the parts very effectually. It is especially well adapted to facilitate operations interesting the deeper structures. Several sizes are required to suit different sized nostrils. Small wire dilators, similar in configuration to those employed for distending the vagina or separating the eyelids, are used as nasal specula. One of the best of these is the device of Dr. Fraenkel, of Berlin (Fig. 9), which, like Thudichum's, may be introduced into both nostrils or only one. The separation of the fenestrated blades of aluminium or other wire is effected by means of a set-screw, out of the way of hand or light. It is intended to be self-retaining, but I have never seen one which

would not slip out if the blades were freely expanded. Some practitioners prefer single-bladed retractors for dilating the nostrils, which, when made of polished metal, reflect light into the passage.

A number of other specula and dilators have been devised, not differing essentially from those described, and possessing no material advantage over them. In many instances the end of a doubled wire or a flexible hair-pin, bent at a right angle, and used as a retractor to draw the wing of the nostril aside (Fig. 5, p. 14), will answer every purpose of a more complicated appliance, as far as facility of inspection is concerned. Dr. Ephraim Cutter has long used a wire thus bent for inspection of the external auditory canal and the membrane of the tympanum; and the same device is adaptable for all similar purposes of drawing tissues aside, whether normal or wounded. For mere inspection I often prefer the hair-pin, as it occupies less room than anything else; and for operative procedures, practicable with one hand, I like Elsberg's dilator, which Mr. Lennox Browne, of London, has rendered still more serviceable by the addition of a set-screw, to keep it dilated at any given fixed point. Fraenkel's is a very satisfactory appliance when it does not slip, on account of its lightness, and Thudichum's, if kept well polished, is the best to reflect light far back, if its tension can be borne.

The parts thus subjected to direct inspection are: the inferior meatus or floor of each nasal passage; the roof and anterior wall; the inner wall, or the septum; the inferior and middle turbinated bones; the lower nasal meatus; the middle meatus; parts of the posterior and lateral wall of the pharynx, pharyngeal extremity of the Eustachian tube, and superior portion of the posterior surface of the soft palate. Satisfactory inspection of the surfaces of the entire intranasal structures is only occasionally practicable, the deeper portions being entirely out of direct or indirect vision, in most instances. In exceptional instances, as where the septum is deflected to one side, or where the submucous tissues are atrophied, the entire lateral surfaces of the passage can be seen, the whole contour of the posterior nasal outlet, and also part of the posterior wall of the pharynx and part of the pharyngeal extremity of the Eustachian tube, even including a portion of its orifice. In case of loss of a turbinated bone, the parts visible are much greater in extent. Sometimes when the eye cannot gain a position to look deeply into the nasal passage, a position may be taken behind the patient so as to see the image as reflected into a hand mirror held in front of the illuminated passages.

The nostril being retracted and well illuminated, the head of the patient erect, the anterior portions of the middle and inferior turbinated bones come into view on one side, and the lateral wall of the septum on the other. The middle turbinated bone is, of course, further back than the lower one. The amount of surface exposed to vision in the normal subject varies with the varying configuration of the parts. If the light is powerful and well managed, the nostril well retracted, and the turbinated bones small, part of the posterior surface of the pharynx, of the superior surface of the soft palate, and of the projecting wall of the pharyngeal extremity of the Eustachian tube can be recognized in a limited field. By moving the patient's head forward and a little inward, still more of the inferior turbinated bone can be seen; and when the chin is at the breast the inferior meatus comes under inspection. Moving the patient's head backward, the surfaces of the middle turbinated bone come into view, and likewise the roof and anterior wall of the nasal cavity. The color of these parts is a varying grayish red, and they are frequently covered with more or less mucus, which refracts the rays of light considerably. It is only by repeated examinations of healthy parts that an accurate appreciation of their contour and color can be obtained.

INSPECTION BY REFLECTION WITH MIRRORS.—The more remote structures of the throat and nasal passages are examined visually by inspecting an image of the parts, reflected in a small mirror held in the cavity of the mouth, pharynx, or nose, the reflecting surface being directed downward to explore the structures below it, and upward to examine those above it.

With the mirror in the mouth or pharynx, the first of these methods is known as *laryngoscopy*, because chiefly employed in examination of the larynx; and, with the mirror in the pharynx, the second is known as *rhinoscopy*, because chiefly employed in examinations of the posterior nares. The two methods, however, include posterior or pharyngeal rhinoscopy, pharyngoscopy, laryngoscopy, tracheoscopy, and œsophagoscopy.

LARYNGOSCOPY.

Necessity had long been felt for some method of exploring the throat more efficient than that afforded by mere inspection through the open mouth with the tongue depressed; and efforts to this end had been made in various directions, chiefly to adapt for this purpose the mirror used by the dentist, or some other

appliance acting on the principle of reflection. After repeated failures, success culminated in the laryngoscopic mirror now in common use in some one or other of its modifications. Space cannot be spared in this volume for recording more than a few essential facts in the history of the invention of the laryngoscope, but readers are referred below to the best and most accessible sources of information on this point.¹

Though more or less successful efforts to this end, too readily abandoned on the score of apparent impracticability, have been made by various investigators, from time to time, the earliest record of the attempt, according to Mackenzie, having been by Levret in 1743, modern laryngoscopy begins with the first completely satisfactory auto-laryngoscopic demonstrations of Signor Manuel Garcia,² a teacher of vocal music in London, whose experiments and observations were made solely in the interest of his own profession. The publication of Garcia's observations soon attracted the attention of medical men. Professor Ludwig Tuerck, of Vienna, instituted experiments with a view of employing the instrument for medical purposes, but finding difficulty in its application, principally on the score of insufficient illumination, and being occupied at that time by other researches, he abandoned for the time his experiments in this direction. Professor Czermak, of Pesth, studying the mechanism of the utterance of the Arabic gutturals, borrowed Professor Tuerck's mirrors, improved upon their construction, recognized their practical value in the diagnosis of disease, and by adopting the ophthalmoscopic reflector for purposes of better illumination, was enabled to perfect the application of the instrument, the use of which he taught to his professional brethren throughout Europe with such zeal that he is entitled to the fullest honor as the chief promoter of the use of the laryngoscope in medical practice. He also independently recognized the feasibility of reversing the position of the mirror, so as to obtain an image of the posterior nares and retronasal portion of the pharynx, and thus established the sister art of rhinoscopy on an equally firm footing. Dr. Semeleder, Czermak's first student in the new art, and then Dr. Carl Stoerck, both of Vienna, who with Dr. Lewin, of Berlin, and Dr. Elsberg, of New York, comprised Czermak's first class in laryngoscopy, became earnest advocates and teachers of laryngoscopy, which then slowly became established on the European Continent, Great Britain, America, and the far East. In the United States, Dr. Ephraim Cutter, of Boston, in 1858,³ and Dr. G. Troop Maxwell,⁴ of Middletown, Delaware, are credited with having devised the laryngoscopic art independently of the knowledge that others had been doing likewise.

The modern laryngoscope consists essentially of a small mir-

¹ Mackenzie: *The Use of the Laryngoscope*. Second and third editions. London, 1866 and 1871. Tobold: *Lehrbuch der Laryngoscopie*. Second edition. Berlin, 1869. Elsberg: *Meaning and History of Laryngoscopy and Kindred Methods of Examination*. Phila. Med. Times, 1873, Nov. 29th, p. 129.

² *Observations on the Human Voice*. Proc. Royal Soc., London, 1855, VII., p. 399; *Philosophical Magazine and Journ. of Science*, X., p. 218.

³ Elsberg, loc. cit.

⁴ *Med. Record*, N. Y., Jan. 15, 1873, p. 28.

ror with a handle long enough to pass it into the posterior portion of the pharynx, where it is held in such a position that it will reflect an image of the laryngeal structures and parts adjacent. It thus permits the indirect inspection of structures beyond the limit of direct visual examination.

A good light is an indispensable prerequisite to a laryngoscopic examination; and when sunlight is available, the simple mirror is the only appliance required.

When the daylight is too feeble for the purpose, reflectors are employed to concentrate its power; otherwise, resort is had to artificial illumination.

Inasmuch as it is only at certain hours of the day that the sunlight is at convenient disposal, and not every day at that, it has been found expedient, by many who have frequent occasion to use the laryngoscope, to have recourse to artificial illumination at all times. This habitual use of artificial light is the more desirable, because parts appear redder and more yellowish by artificial light than they do by sunlight; and therefore, unless due allowance be made for this difference, it is possible that a condition recognized as normal by sunlight, may appear as if inflamed when examined by gas or lamp light, and a condition considered normal by artificial light, appear anæmic by daylight.

The laryngoscope has, in the most literal sense, thrown light upon many conditions the like of which had hitherto remained unrecognized, and liable to misinterpretation in the uncertainty of subjective investigation alone. In the case of many a despondent and all but abandoned sufferer, it has indicated a means of rescue from the very clutch of impending death; and in many instances by means of operative measures safely conducted under its guidance. The pathology of laryngeal diseases has been studied anew and in the living subject by its aid, and with almost the ease of external pathology, much to the increase of our knowledge, not only of special diseases of the throat, but of diseases of mucous membranes in general.

Brilliant successes in laryngoscopic surgery, duly proclaimed in current medical literature, have encouraged so many professional laborers to engage in the attractive new field of study that before the first decade of laryngoscopic research had been completed, the laurels which it added to the crown of *Æsculapius* were equal in freshness, permanence, and grace to those culled in any other portion of his broad domain.

The literature to which laryngoscopic observation has given rise is very extensive, and the lessons it has taught have won for it a distinguished position among the most valuable records of medical and surgical learning.


As is perhaps but naturally incident to the enthusiastic development of an

attractive novelty, its zealous votaries have coerced an inordinate amount of ingenuity in the invention of appliances for laryngoscopic examination, and still more so in the invention and adaptation of implements for surgical interference by its aid. One who has not followed the subject closely in all its ramifications, from its very inception, can hardly realize the extent to which this instrumento-mania has run rampant.

Almost every ostensibly useful instrument that has been devised in this specialty has been subjected by the author to the actual test of practice. Many have been found superfluous, and not a few are actually impracticable in application, though plausible in theory. Only such appliances as have proved the most useful of their class need be brought to notice in this volume; and while the endeavor will be made to record little that has not a directly practical bearing, care will be taken, as far as possible, to avoid the omission of anything essentially useful.

The Laryngoscopic Mirror.—The form of the laryngoscopic mirror is a matter of little importance. The very best form is that eventually adopted by Tuerck, a circular mirror (Fig. 10), made of the very best glass, mounted in a narrow metallic setting, and attached, at an angle of 120° , to a stout metallic shank, the free end of which is secured into a wooden handle. The glass is one inch in diameter, and the entire instrument is eight inches in length. This mirror will meet almost every indication in the adult. Occasionally, and almost constantly in children, a smaller mirror will be required; while, on the other hand, a much larger mirror can sometimes be very readily employed. It is obvious that the larger the mirror that can be used in any case, the more satisfactory will be the illumination. Enlarged tonsils protruding into the cavity of the pharynx will necessitate the use of a very small circular mirror, or of an elongated or oval one; say a mirror an inch in length and from five-eighths to seven-eighths of an inch in its broadest transverse diameter.

Fig. 10.—Laryngoscopic mirror of circular form, with thick stem, as used by the author.



To examine all classes of cases liable to come under observation, a stock of at least four mirrors is required; three circular ones of five-eighths, three-quarters, and one inch diameter respectively, and one oval one of five-eighths inch transverse diameter. Mirrors of other diameters may be better adapted to exceptional cases, but such cases are rare. Special mirrors should be used for syphilitic subjects. Some practitioners have expressed

a preference for square, lozenge, and dome-shaped mirrors, with the shank soldered at one corner, but, as a rule, the circular mirrors will be found to be better borne by the patient. It has also been recommended to have mirrors at hand soldered to the stem at various angles, as more likely to meet varying indications, but this refinement is altogether unnecessary, as a slight movement of the fingers and wrist will give the mirror any degree of obliquity that may be desirable.

A mirror firmly soldered to its handle is preferable, as a more complete tool, to one in which the stem is made to slide in and out of the handle; and if the handle terminates in a broad, flat surface it forms a convenient tongue-depressor for direct inspection of the parts previous to the laryngoscopic examination.



FIG. 11.—Circular Mirror with Stout Shank and Flat Handle.

A mirror with such a handle and with an unusually thick stem (Fig. 11), I have long found the most satisfactory and time-saving instrument I can use. A flexible stem that can be curved at will is preferable for rhinoscopic purposes, but is often an annoyance in laryngoscopic examinations, because, when held against the palate, as is usual, it can become curved by the resistance of strong palatine muscles, and thus deflect the rays of light in the wrong direction.

Preference has been expressed for a more acute angle of attachment to the shank, but it is really an affair of little moment whether the angle is a little greater or a little less; for it is to be presumed that, once familiar with the use of the instrument, an expert manipulator could employ any mirror to which he might have access.

The quality of the reflecting surface of the mirror, however, is a matter of considerable importance. A laryngoscopic mirror should afford as perfect an image as possible. When held over a piece of white paper, the reflection should be perfectly white; if it be bluish or yellowish, the laryngeal image will be sure to lose its distinctness in proportion to the departure from a pure white, and thus to vary somewhat from the normal color of the parts. The mirrors used by myself are made of the best glass, backed with silver, with jewelled or bevelled rims, so that they can be securely set in the socket, in the manner that a gem is mounted. I have used some of these mirrors dozens of times a day for as many as five or six years in succession without their becoming tarnished by heat, or injured by penetration of water.

Laryngoscopic mirrors have been constructed of highly polished steel and of other metallic surfaces of great lustre. These are very serviceable while new and unscratched, though presenting a violet tinge to the reflection of white paper; but they soon become tarnished by usage, and are kept in order with difficulty. They are applicable only to very rare special cases in which but a very small mirror can be employed, and when it is a matter of some moment to avoid the loss of reflecting surface which even the narrowest setting would sacrifice in the glass mirror; as, for example, when it is necessary to make an examination through an artificial opening in the trachea.

Introduction of the Mirror.—The position of the mirror in the pharynx of the patient, and the general features of the normal image seen upon it in position, is tolerably well depicted in Fig. 12. The mirror is represented as having been placed at an angle of 45° or thereabouts with the plane of the larynx; but its position in practice will vary in different

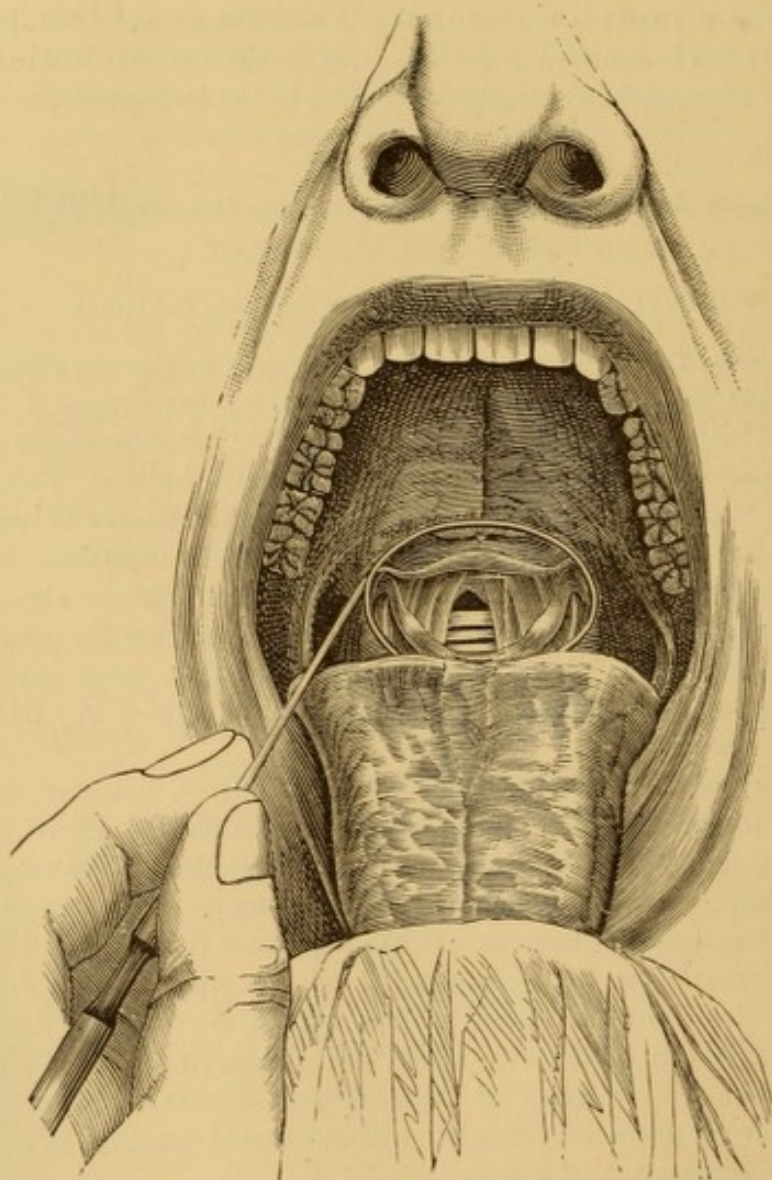


FIG. 12.—The Laryngoscopic Mirror in Position, Stem to one side.

individuals, in consequence of differences of conformation. Much, too, will depend upon the degree of flexion given to the patient's head, the position of the observer's eye, and the normal and abnormal relations of the tissues.

The manner in which the laryngoscopic mirror may be conveniently used is as follows: The patient is placed seated or

standing in such a position that a strong light shall illuminate the pharynx, and especially the lower border of the soft palate.

If the light is too high, it cannot be reflected behind the epiglottis without difficulty; if too low, the mirror will be overshadowed by the base of the tongue.

The examination may be made in the open air or in front of a window, or lamp or other artificial light. The practitioner places himself in front of his patient, at such distance as to obtain distinct and clear vision of the soft palate and the posterior wall of the pharynx. The head of the patient should be held erect, or very slightly bent backwards. The position may have to be varied a little after the mirror has been introduced; but for the majority of cases a favorable position will be such a one as shall place the lower border of the upper incisor teeth upon a horizontal plane with the base of the soft palate. The mouth should be widely distended, and the tongue thrust forward toward the chin with considerable muscular force, its body lying quietly upon the floor of the mouth, and its posterior portion and base rendered as concave as possible. In this position, originally recommended by Dr. Carl Stoerck, of Vienna, it may be enveloped in a handkerchief or napkin, and held by the observer or the patient himself, as most convenient: the cloth being interposed to prevent the tongue slipping back from between the thumb and fingers.

When the patient manages his own tongue, the practitioner has a hand free to grasp the larynx externally, and move it bodily so as to bring the various parts in turn better in the field of illumination. This manœuvre will often be found an invaluable aid in completing or confirming a diagnosis.

The patient should breathe rather deeply, but quietly, synchronously, and without effort.

The stem of the mirror should be taken in hand in the manner of handling a pen or lead-pencil, the wrist being well extended, though not stiffly so, the mirror pointing upward, with its reflecting surface horizontal and looking downward, as depicted in Fig. 13. The stem may be held uppermost or to one side, as suits the fancy of the examiner or the exigencies of the case.

The patient being told to take a deep breath, so as to elevate the soft palate, the laryngoscopic mirror is passed into the

cavity of the mouth, avoiding contact with the tongue, and moved directly backward until it has reached the uvula,

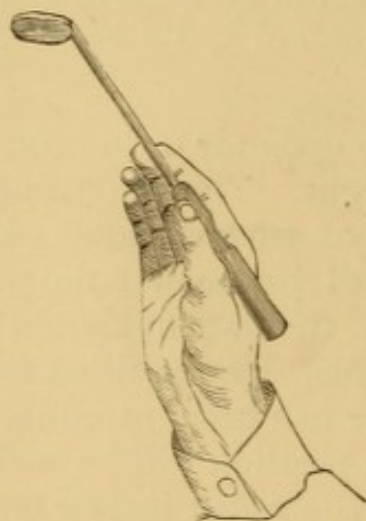

FIG. 13.—Manner of holding laryngoscopic mirror preparatory to its introduction.

beneath which it is placed obliquely, the wrist being flexed at the same moment, and the mirror placed with its lower border on the posterior wall of the pharynx, the uvula and soft palate being pushed backward and somewhat upward in the manœuvre. The stem of the mirror is now horizontal or oblique, according as it is held uppermost or to one side, and the reflecting surface looks obliquely downward and forward.

When the palate is raised very high during a deep inspiration, the mirror can be placed in position without pressing it up, and then the palate will fall gently upon the back of the mirror as expiration is effected. This is a serviceable procedure in the examination of nervous individuals.

If a square mirror is used, its lower border should be kept in a horizontal plane, parallel to that of the tongue, so as to avoid unnecessary contact of the parts with the corners of the mirror.

I have rarely found the pharynx too sensitive to bear the contact of the mirror, but the experience of most writers seems to have been otherwise. If the mirror is not well borne in contact with the pharynx, it must be so moved as just to free it, and then the support for steadiness must come from the terminal phalanx of the little finger, resting against the cheek or jaw of the patient externally.

If the palate is inflamed, ulcerated, or very hypersensitive, the laryngoscopic mirror may be supported against the hard palate, in which case it must be held in a more horizontal plane, and be looked at somewhat from below upward, when it will reflect almost the same image as in the more convenient manipulation described at first. In fact, with a little change of direction of rays of light, position of patient's head, and observer's eye, there are an indefinite number of positions in the mouth and pharynx from which images of the larynx can be inspected. A little practice in this direction now and then is useful, as available for emergencies; and I doubt whether any reiteration of the laws of physics in the reflection of images, illustrated by diagrams or not, will be as good as practical self-demonstration with the mirror in the mouth and pharynx of a docile subject. The laws of optics referred to are described and delineated in all text-books on physics or natural philosophy.

The image of the larynx and adjacent structures requires some little study at first to be accurately comprehended, for

it appears in a plane nearly vertical, while the structures themselves occupy a plane rather horizontal to the vertical axis of the body; hence, there is an apparent antero-posterior reversal of parts, the lateral relations of right and left side, however, being alike in the subject and in the image in the mirror. If it be remembered that the entrance into the larynx presents backward toward the mirror, it will be understood that the reflected image presents forward: the oblique position of the mirror throwing the image of the anterior structures (base of tongue, epiglottis, etc.) to the upper part of the mirror, and the image of those which are posterior (arytenoid cartilages, posterior wall of pharynx) to the lower part of the mirror, a condition of things intelligible at a glance on consulting the accompanying illustration (Fig. 14).

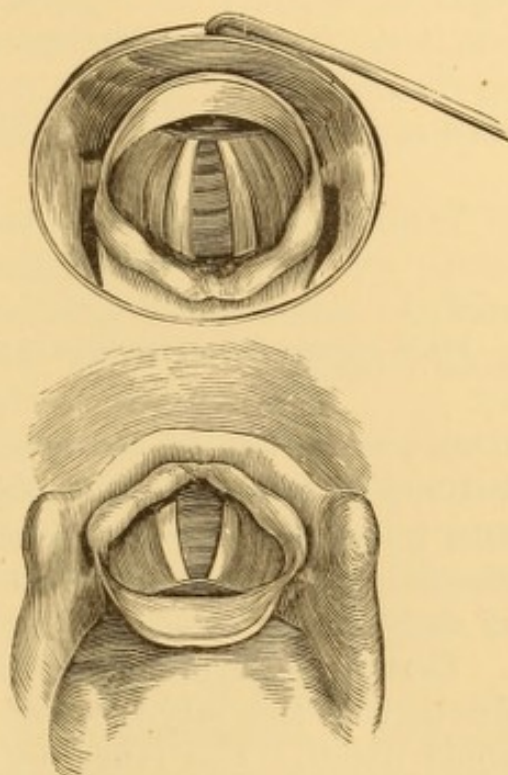


FIG. 14.—Relative relations of larynx and its image in the laryngoscopic mirror (stem uppermost).

The structures (base of tongue, epiglottis, etc.) which are above and in front in the patient, appear above and at greater distances in the mirror; the parts (arytenoid cartilages, etc.) which are below and behind in the patient appear below and least distant in the mirror; but the structures which are in reality on the right hand of the observer in the patient are on his right in the mirror also. In other words, those parts nearest the mirror are seen as if they were nearer the eye of the observer, who views them very much as he would do if he could look down upon them from behind, with his eye in the plane of the laryngoscopic mirror.

The lower figure represents a view, tilted forward, of a cast of the base of the tongue and the larynx in the relative position they bear in the person who is being examined, while the upper figure shows the image as seen in the mirror. If the reader will hold a laryngoscopic mirror (or, in lieu of it, a piece of looking-glass) obliquely above the lower figure and behind it, so as to receive its reflection, he will get some such image as is pictured in the upper figure. This diagram will be found useful in studying the relation of parts in actual practice.

The physical conditions under which this image is reflected

is apparent in the accompanying diagram (Fig. 15), in which the mirror, being at an angle of forty-five degrees with the horizontal line of vision, the rays of light going toward the mirror in the direction of the arrows are reflected upon the glottis, which then appears to the eye of the observer as a vertical

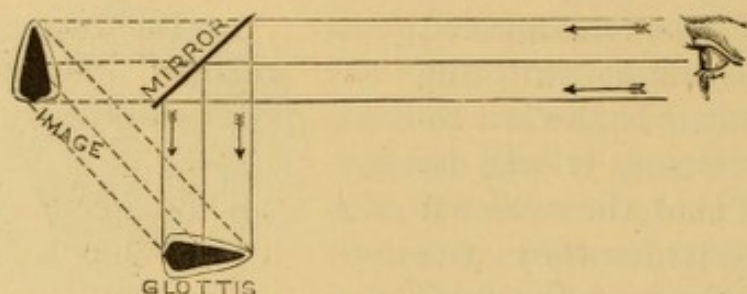


FIG. 15.—Diagrammatic representation of the reflection of the glottis in the laryngoscopic mirror (altered from Mandl).

image, as far behind the reflecting surface of the mirror as that surface is from the real object. A little distortion of object and image has been allowed in the diagram, to give a more characteristic representation of an open glottis with its pair of vocal cords.

Certain important practical points in reference to the introduction of the laryngoscopic mirror require elucidation with some detail. The reflecting surface of the mirror must be warmed before it is passed into the mouth, to prevent it from becoming blurred by the halitus of the breath, and thus reflecting only an intermittent, indistinct image, as each successive inspiration clears the glass of some of the moisture condensed upon it. The best method of warming the mirror is to heat the reflecting surface over a flame, and then the mounting does not become warm enough to burn the tissues. To avoid burning the patient, the back of the mirror may be tested on the hand¹ before it is passed into the pharynx, but if the mirror be carefully watched this will be unnecessary. Care must be taken not to overheat the mirror, lest the amalgam run. All that is required is a gentle warmth, and under such influence the mirror will remain untarnished for several minutes. As first noticed by Elsberg, if a cold mirror is placed over a flame for a few

¹ The usual custom of testing the heat of the mirror on one's own cheek is a bad one, because, as Stoerck has pointed out, one might, from habit, unwittingly place against his cheek a mirror just withdrawn from the ulcerating palate of a syphilitic subject.

moments, the moisture of the apartment condenses on its surface at once, and is immediately afterward evaporated from circumference to centre. The moment the mirror clears it will be fit for use. The time occupied is but a couple of seconds, even in quite cold weather.

A thin film of glycerine, mucilage, or solution of sugar will absorb the condensed moisture of the breath, and thus avoid indistinctness of the image through dispersion of the rays of light, but the image is less perfect optically than when the mirror is simply warmed.

Poorly made mirrors will, after a while, become ruined by the heat to which they are subjected from time to time, particularly quicksilvered mirrors, which are thus soon rendered unfit for use. Well-made mirrors coated with silver will resist daily use for years without becoming tarnished.

The mirror must not be retained too long at a time in the mouth; a minute or two at a time will suffice, as a rule. It is better to reintroduce it several times than to fatigue the parts by keeping them too long in a constrained position. In this way undue congestion, irritability, and spasm are avoided.

If the patient wear false upper teeth, it is prudent to have them removed before the mirror is introduced, not so much that they interfere with the manipulation, though they may do so if poorly fitting, but because the contraction of the muscles of mouth or throat may detach them, and lead to the possibility of their becoming impacted in the pharynx as a foreign body, an accident which I have known to occur during so simple a manipulation as a mere laryngoscopic examination.

Allusion may be made to the fact that prisms have been employed for projecting the laryngoscopic image instead of simple mirrors. I have had no experience with them, and believe, with most laryngoscopists, that the ordinary mirror fills every indication.

Impediments to Laryngoscopic Examination.—With ordinary care and a moderate amount of skill a satisfactory laryngoscopic examination can be immediately made at the first attempt, except in very rare instances and in very young children. Occasionally, however, impediments are presented, a consideration of which is necessary.

There may be unwillingness or inability to open the mouth properly, or to keep it open. In such cases a gag, speculum, or mouth-distender—such as is used in the operation for cleft palate—may be employed, and the laryngoscopic mirror passed

through it. A glass tube, about an inch and an eighth in diameter, will answer the indication, and permit the passage of an inch mirror. Under these circumstances the tongue is to be retained in the mouth, and kept depressed by the speculum. The occasion for any contrivance of this kind, however, is so unfrequent that mere allusion to it is almost unnecessary, though it may be mentioned as a useful device in making applications to the throats of refractory patients.

The management of the tongue occasionally becomes a matter of annoyance. The most favorable position for the examination is secured when it is moderately protruded by the action of its own muscles, its body resting quietly upon the floor of the mouth, and its base guttered into a broad sulcus. It usually requires some effort to maintain the tongue in this position, but the ability to do so is readily acquired by practice, especially if before the looking-glass.

In some individuals the tongue is often elevated involuntarily as soon as any foreign body passes the teeth, and it may rise sufficiently to push the mirror to the very roof of the mouth. It is necessary that the base of the tongue should be directed forward and downward, so as to increase the pharyngeal space, and to draw the epiglottis up by the tension on the glosso-epiglottic ligament; for the epiglottis in most people overhangs the entrance into the larynx obliquely, and, unless moderately erect, it will, to a greater or lesser extent, intercept the view of the intra-laryngeal structures. It is an excellent plan to instruct the patient to hollow his tongue at the base, and then thrust it forcibly forward out of the mouth; when, if he cannot maintain it in this position without aid, it may be held by the thumb and fingers of the disengaged hand of the practitioner, guarded by a glove, handkerchief, or napkin; or, what is more convenient, for many reasons, the tongue may be intrusted to the patient's own fingers. The fingers of the patient in holding his tongue are best applied above and the thumb below, and his right hand should be used when the observer intends to hold the laryngoscopic mirror in his own right hand, and *vice versa*. This will keep the fingers out of the way. The tongue should not be pulled downward with any force, lest the frænum be injured by pressure upon the incisor teeth. Any apprehended result of this kind may be prevented by the interposition of a fold of handkerchief or soft rag.

The thumb-nail may rest on the teeth, or the tongue be slightly elevated by a forward movement of the thumb, for a like purpose. The ingenuity manifested in the invention of tongue depressors and tongue-forceps, for the purpose of retaining the tongue in position, has been wasted. The employment of any mechanical contrivance whatever for holding the tongue is greatly to be deprecated, and should be avoided as a rule. It may occasionally be impossible to get along without something of the kind, but the alternative is to be acknowledged with reluctance. The best tongue-holder I have tried is that of Dobell (Fig. 16), which secures the tongue firmly and without pain between a pair of thin perforated plates of metal. A cloth may be interposed between the blades.

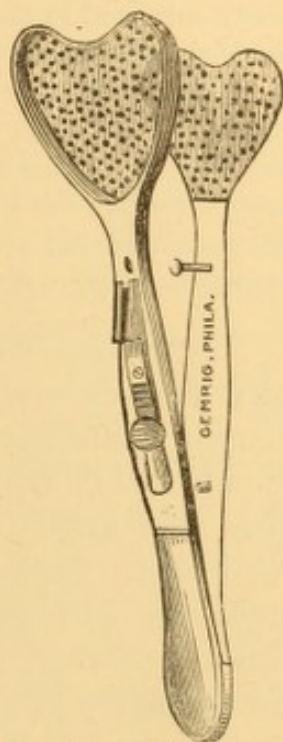


FIG. 16.—Dobell's tongue-holder.

In some cases the tongue is so fleshy that it affords too little space in the cavity of the mouth for the passage of the mirror, or it is so restless that it keeps bobbing about. It is then requisite to press it down or restrain its movements by slight pressure with a pen-handle, pocket probe, or even the forefinger, as a reminder to steady it, as it were.

In rare instances a tongue-depressor is indispensable. The tongue-depressor in ordinary use is not suitable for the purposes of laryngoscopy, inasmuch as it depresses the anterior portion of the tongue merely, forcing the base backward upon the epiglottis—the very effect it is desirable to avoid; while one that is fenestrated permits a portion of the tongue to rise through the fenestrum, thereby intercepting the view. The tongue-depressor pictured in Fig. 3, p. 11, is believed to fill at least every indication claimed for many of the more elaborate and complicated instruments. The handle, being bent upon the tongue portion at an angle, turns in toward the neck when the instrument is applied to the tongue; thus the hand in which it is held is kept out of the observer's way; while, by bringing the handle forward toward the perpendicular, the base of the tongue is necessarily pressed downward and drawn forward, elevating the epiglottis, and securing a favorable position for examination. Any available instrument frequently introduced by the patient at home will overcome sensibility of the base of the tongue, whether preternatural or normal.

With such a tongue-depressor, properly constructed and well applied, it will be no unusual occurrence to expose at once to direct vision the lingual surface of the epiglottis with more or less of its crest, the glosso-epiglottic ligament or fold,

and the lingual sinuses at either side; and, of course, a large extent of the pharynx; occasionally, indeed, part of the laryngeal face of the epiglottis, and the very entrance into the larynx. Once in position, it can be very advantageously entrusted to the management of the patient. It is to be understood, however, that this tongue-depressor is not recommended for habitual use. It is better to avoid every artificial means to depress the tongue, and it can be avoided in nearly every case, if neither party is in a hurry. A little practice will enable the patient to maintain his tongue in a favorable position; and as contact with the organ can be avoided in the introduction of the mirror by the motion of flexion of the wrist, as already described, the tongue-spatula can almost always be dispensed with.

Hypersensitiveness of the palate and pharynx is occasionally encountered. Most unsuccessful attempts at laryngoscopic examination attributed to this cause are due to unsteadiness or nervousness in the hand of the manipulator, and this may arise from lack of skill, and want of control on his own part. This once overcome, undue irritability of palate or pharynx will rarely occasion any embarrassment. In some cases, however, there is real hypersensitiveness of parts, and occasionally to a considerable degree, but the instances are few and far between. This irritability may often be controlled by impressing the patient with the necessity of overcoming it by strong mental effort. Gentle manipulation of the parts with a probe, pen-handle, or something of that kind, will often succeed. If time permit, and there are no contra-indications, a few decided doses (30 to 60 grains) of bromide of potassium taken at intervals of three or four hours will occasionally induce considerable tolerance of manipulation. Astringent and sedative solutions applied locally are rarely successful.

Gargles and sprays of alum, tannin, bromide of potassium, and bromide of ammonium; sprays of sulphuric ether, rhigolene and chimogene; pencillings with astringents and caustics; pencillings with solutions of morphia in chloroform, and solutions of aconite; the local contact of small bits of ice; the inhalation of from ten to twenty drops of chloroform, and various other methods have been recommended for this purpose. Many of the most inefficient of these have been those most highly extolled, perhaps from having chanced to succeed in the only case in which they had been tried. Of all these devices the most effectual are the contact of the nebulized spray of a solution of tannin, the local use of aconite, and the inhalation of a few whiffs of chloroform; but it is more judicious to subdue the sensibility of the parts by repeated contact of the laryngoscopic mirror.

Some years ago I expressed the opinion¹ that this irritability of tongue,

¹ The Medical Record, 1866, vol. i., p. 349.

palate, and pharynx is in the main due to indigestion, and often attendant upon the digestive act itself, and hence adopted the simple plan of deferring the examination in such cases until three or four hours after a meal, an expedient which has answered the purpose in a large proportion of instances. When marked disorder of the digestive apparatus exists, a smart purge administered the night previous will lessen the sensibility of the parts the next morning.

In cases of extreme sensitiveness, the mirror may be placed higher up in the mouth, so that its lower edge shall rest upon the hard palate, or sometimes even its entire back on the roof of the mouth; and thus, by holding its reflecting surface more horizontally, a good view of the larynx can often be obtained without touching the more sensitive soft palate at all. Indeed, in some special conformations of parts, a better view can at times be secured in this manner than by the ordinary position of the mirror. The back or rim of the mirror may be pressed against the soft parts, or be held away from them, the fingers in which the handle is held being supported on the patient's chin. The eye of the examiner should be below the level of the patient's mouth; a very favorable position being secured by resting with one knee on the floor or upon a low stool.

Enlarged tonsils sometimes render the employment of an oval or small circular mirror necessary. If the mirror used be broader than the space between the hypertrophied glands, it is to be pushed right back between them and behind; and, although the side of the mirror is covered somewhat as the tonsils resume their position, sufficient reflecting surface usually remains exposed to afford satisfactory examination. If the movement of passing the tonsils be made with celerity, it is hardly felt by the patient. If the tonsils are so much hypertrophied as to preclude the use of an oval mirror, excision will most likely be required on their own part, and this will afford room for satisfactory laryngoscopic examination subsequently.

An elongated uvula may be a source of embarrassment by hanging below the mirror, so that the reflection of its own image will intercept the view of the parts below. If it cannot be retracted by titillation or by astringent applications, and there are sufficient reasons for the interference, the exuberant portion had best be excised. If this be injudicious, the mirror may be placed against the hard palate, as already described.

With some manipulation, an elongated uvula can often be held up on the back of the mirror. Any one accustomed to laryngoscopic examinations can

make allowance for it in the image, and get views around it, as it were, first on one side and then on the other. Mirrors have been constructed with metallic pockets to slip over the uvula, and so lift it up; but their value is doubtful. I have had no occasion to desire resort to anything of the kind.

An unfavorable position of the epiglottis is often really a serious obstacle to a satisfactory laryngoscopic examination. Whether as a congenital conformation, as the result of cicatrization, or as a defect acquired by a vicious mode of utterance in public speaking, once in a while a depressed epiglottis overhangs the orifice of the larynx to such an extent as to preclude illumination of its interior. When this condition is slight, and more especially in acquired cases, it may be overcome by frequently pulling the epiglottis forward with the finger, a manœuvre which the patient can readily be taught to do for himself. Instead of this, a suitably shaped broad, blunt hook can be passed behind the epiglottis to draw it forward. For this purpose I have long used the blunt hook on the dentist's extension thimble.

Very often a momentary view of the interior of the larynx may be gained by causing the patient to make an inspiratory vocal sound, a sudden inspiration, or to utter the sound *eh* in a very high-pitched tone—exercises by the execution of which the epiglottis is thrown upward for the moment. To make a thorough examination in presence of a depressed epiglottis, or even a superficial examination in some cases, some mechanical contrivance is necessary to raise the epiglottis forcibly, and maintain it in an erect position. One of the best is a stout whalebone or metallic rod (Votolini's staff), bent nearly to a right angle at its extremity for about an inch, with the terminal point turned backward. In making a diagnosis merely, the tongue is confided to the patient himself, and while the laryngoscopic mirror is held with one hand, the other, guided by the reflection in the laryngoscopic mirror, carries this rod or staff beyond the epiglottis, against the laryngeal face of which the bent portion is to be pressed, so that as the rod is drawn forward, the epiglottis will be forcibly raised and held in position. The terminal point of the rod which is turned off from the vertical part of the hooked end cannot press against the epiglottis, and thus the pain of the operation is lessened. A stout whale-bone rod, squared at the bent portion, will answer the purpose admirably. The introduction of this staff requires

a certain amount of skill. The manipulation must be made quietly, but with a firm though gentle touch. The parts are not to be handled roughly just because a decided hold is taken of them.

When, however, an application is to be made within a larynx with a depressed epiglottis, an appliance is occasionally needed which, when in position, can be held by the patient or left to itself, for the operator will have both hands employed with other instruments. For this purpose epiglottic tenacula, pincettes, forceps, hooks, needles, snares, etc., have been devised to seize the epiglottis and hold it up. It is no easy matter to seize the epiglottis with a tenaculum; and to pierce it with a threaded needle, and thus control it is still more difficult, no matter what the appliance used for the purpose. It is not always easy to seize it with toothed forceps, and when seized in this way it is very intolerant of the manipulation. The forceps and pincettes devised for holding the epiglottis are intended to hang on to it during an operation, and keep it erect by their weight. An appliance of Tuerck is much approved for this purpose, but I am not familiar with it. A toothed pincette devised by Von Bruns (Fig. 17) is one which I have found convenient. The edge of the epiglottis is seized between




FIG. 17.—Bruns' pincette for holding up the epiglottis

the serrated blades, which close tightly upon it when pressure is taken from the spring handle. The instrument is allowed to hang out of the mouth during an operation.

These instruments, however, should not be used carelessly or without due discretion, for even under the care of one of the most skilful of laryngoscopists, a case has been lost from extensive laryngeal œdema consequent upon the use of one of the epiglottic pincettes of Von Bruns.¹

The presence of morbid growths within the mouth and pharynx, or of external tumors pressing the tongue, pharynx, or palate extensively out of normal position, or in some instances pushing the larynx itself so far to one side and so much out of

¹ *Medizinische Jahrbücher*, 1868, xv. Bd., p. 72.

the vertical line of the body as to be no longer accessible to rays of light, is an occasional source of mechanical interference with laryngoscopy, in rare instances amounting to absolute preclusion. The same may be said of vicious adhesions.

The manner of respiration sometimes presents an impediment to the examination. Nervous individuals are excited by the paraphernalia incident to laryngoscopy, especially if by artificial light, and are apt to breathe in a hurried, constrained, or spasmodic manner. This irregular respiration must be tranquillized preparatory to a successful result. If necessary, this may be facilitated by breathing one's self in time with the patient; by accompanying the breathing at first with a sound allowed to become less and less audible as respiration progresses; by beating time, or by some similar expedient; and when the excitability of the patient has been controlled, the examination may be quietly and gently pushed to completion. In fact, success in laryngoscopic examination requires patience as well as manual dexterity. It is useless to hurry a patient or to scold him roundly, for this only increases excitement or dread of the manipulation, and thus augments any susceptibility to spasm from the contact of the mirror. If sufficient time cannot be spared for deliberate or systematic work, the attempt had better be postponed to a more convenient period, or the case transferred to a practitioner who has the time at his disposal.

In hopes of overcoming the sensibility of the pharynx and palate—parts which are subjected to pressure during a laryngoscopic examination—and thus securing a more prolonged tolerance of the presence of the mirror, it has been suggested to resort to the induction of anæsthesia. Complete anæsthesia is not applicable to the requirements of laryngoscopic manipulations, because, in order to maintain the head, mouth, and tongue in certain positions, as is necessary in almost every examination, and much more so in the performance of a laryngeal operation through the mouth, the co-operation of the patient is requisite to make certain voluntary physiological movements, to elevate the epiglottis, depress the tongue, approximate or separate the vocal cords, etc., as may be, in order to bring into view certain structures which would otherwise remain out of the line of vision.

The temporary anæsthesia produced by hurried breathing, after the method of Bonwill, has been suggested to the author, but has never been put in practice.

Magnified Images.—Magnified views of the laryngeal image may be obtained by placing lenses of short focus (three to four inches) within the mouth, or of longer focus (six to eight inches) outside the mouth, warmed to blood-heat to avoid condensation of the moisture of the breath, and held at an oblique angle to

the axis of vision. They are difficult of manipulation, and are of course of very low magnifying power. Professor Tuerek, of Vienna, succeeded in adapting a small telescope to the purpose, and Voltolini an opera-glass from which the ocular had been removed. I have no experience with either of these devices. Concave laryngoscopic mirrors, of a focus of four or more inches, as originally suggested by Wertheim, are sometimes useful in getting enlarged views of parts which lie at or very near the focal distance of the mirror, and are reflected from it in its central part, but the distorted images of the other parts of the structures, as reflected near the margin of the mirror, are very perplexing and misleading. Nevertheless an additional examination of special points in the concave laryngoscopic mirror, after the general view has been obtained in the plane laryngoscopic mirror, is sometimes of great advantage, and the manipulation is no more difficult in the one case than in the other.

Multiple Mirrors.—Double mirrors were used at one time by Czermak to try and obtain views of such parts as cannot be well lighted up by the ordinary mirror, particularly the posterior wall of the interior of the larynx. The ordinary mirror has a smaller mirror attached to it by a short shank, at such an angle in front of it that the image of parts reflected on the smaller mirror is thence reflected to the larger one, which at the same time reflects the ordinary laryngoscopic image; so that the superposition of the two images is rather confusing. I have not used these mirrors for many years. Voltolini endeavored to reflect light beneath a depressed epiglottis with a somewhat similar arrangement of mirrors; Wertheim adjusted a narrow strip of mirror at an obtuse angle alongside of an ordinary rectangular one; and recently Lori has recommended the simultaneous use of three mirrors, a double one similar to that of Czermak, and a third mirror held in a reversed position, so as to illuminate the posterior wall of the larynx and reflect the image to the lower one of the pair of mirrors, the upper one in the ordinary position serving merely for illumination.

Accessory Apparatus to Increase the Illumination.—As already stated, a good light is an indispensable prerequisite to laryngoscopy. It is only during a short period of a clear day, while the solar rays incline to the horizontal, that the brightest source of illumination is available. When the time of day or location of the apartment is unfavorable to utilization of the direct light of the sun, the rays may be reflected to any desired point by allowing them to impinge upon a small toilet mirror so arranged as to admit of being tilted obliquely in the desired direction. The glass is placed on a convenient support, as a stand or mantel-piece, in such a position that it will receive the sun's rays upon its surface. A cone of light may thus be reflected to a convenient point of the apartment, say against a wall, and the patient be then seated so that his mouth will intercept the bundle of rays.

On opening the mouth, the pharynx will be brilliantly illu-

minated (Fig. 18). A small opening in the shutter of a closed window affords passage of the rays to the reflecting mirror. As the day advances, the position selected for the patient will

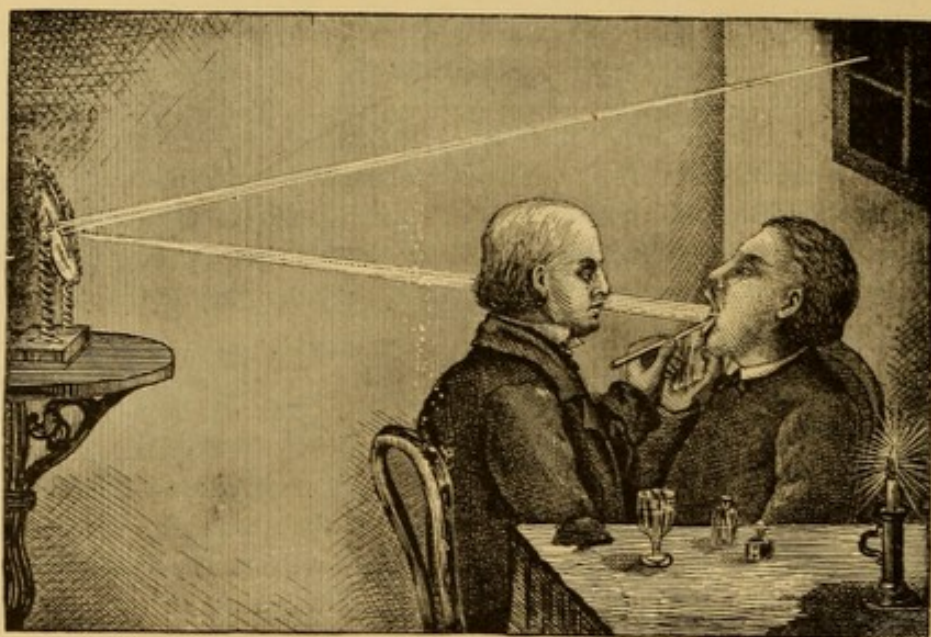


FIG. 18.—Examination by reflection of solar rays (altered from Moura).

have to be altered so as to correspond with the track of the sun, unless the examiner is in possession of a heliostat, or of a large concave mirror which can be placed outside the window so as to reflect condensed rays into the room. Sometimes a plane mirror, attached to the forehead of the observer, is used as a reflector of direct solar light, or, as recommended by Semeleder, of light concentrated by the concave reflector just referred to.

More frequently and more conveniently a concave mirror is used to reflect the diffuse daylight of the apartment. This laryngoscopic reflector of Czermak consists of a circular concave mirror about three and a half inches in diameter, with a focus suited to the visual power of the observer. A focus of from eight to twelve inches can be used by the majority of persons; but occasionally a reflector must be selected especially to suit the focal distance of the observer's vision. In employing this reflector the patient is placed so that the light is towards his back or to one side, and the observer opposite to him, with the reflector in his hand, or upon a stand at his side, or attached in some manner to his forehead (Fig. 19). Kramer's elastic head-band, adopted by Czermak, and Semeleder's spectacle frame, in some of its modifications, are the mountings most frequently

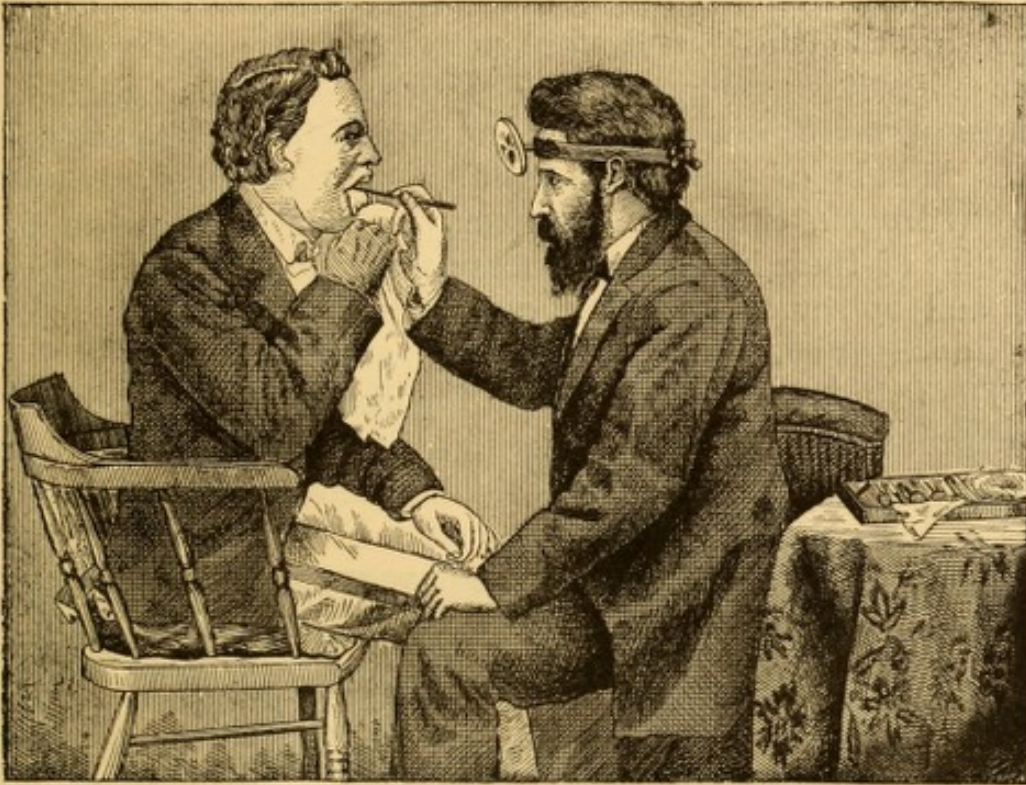

FIG. 19.—Examination by diffuse daylight reflected from concave mirror attached to the forehead.

employed to attach the reflector to the head. — If the reflector be perforated (Fig. 20), it may be placed in front of one eye; if not perforated, it is placed in front of the forehead. Under any circumstance the mirror must be so mounted as to be susceptible of being inclined in any direction. The light is then received upon the reflector, and thence reflected into the mouth, upon the spot to be occupied by the laryngoscopic mirror, say at a distance of about three inches (its average distance from the glottis) from the focal point of the reflector.

Examination by Artificial Light.
—Artificial illumination is used either by direct or by reflected light. Direct light is preferred in France; reflected light in Germany, Great Britain, and the United States.

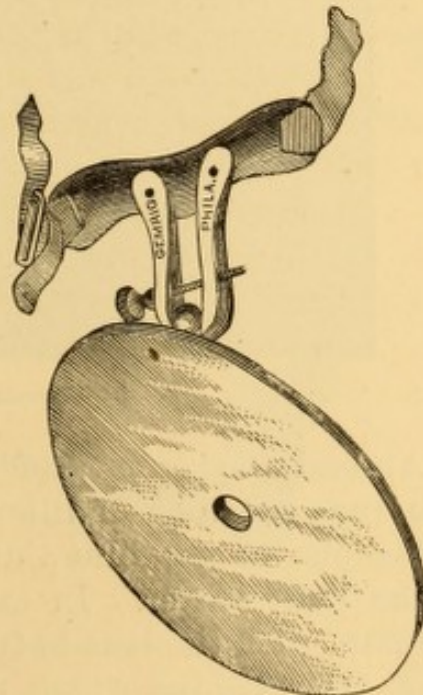


FIG. 20.—Perforated reflector attached to Kramer's head-band by a ball and socket joint. Shown in position for covering one eye.

The best light to use is that of gas, or coal oil. Coal oil furnishes the whiter and more constant light; gas is the more convenient in management. The light from coal oil can be rendered more brilliant by dissolving a little camphor in the oil. Whale oil and even candles may be used, however. Oxyhydrogen, calcium, and even electric lights are used on account of their intensity by some practitioners, chiefly teachers, and by some of them merely for class instruction. They are unnecessary.

The naked flame may be used for illumination, but in order to concentrate the power of the light it is customary to place a condensing lens in front of it. The flame from a circular or

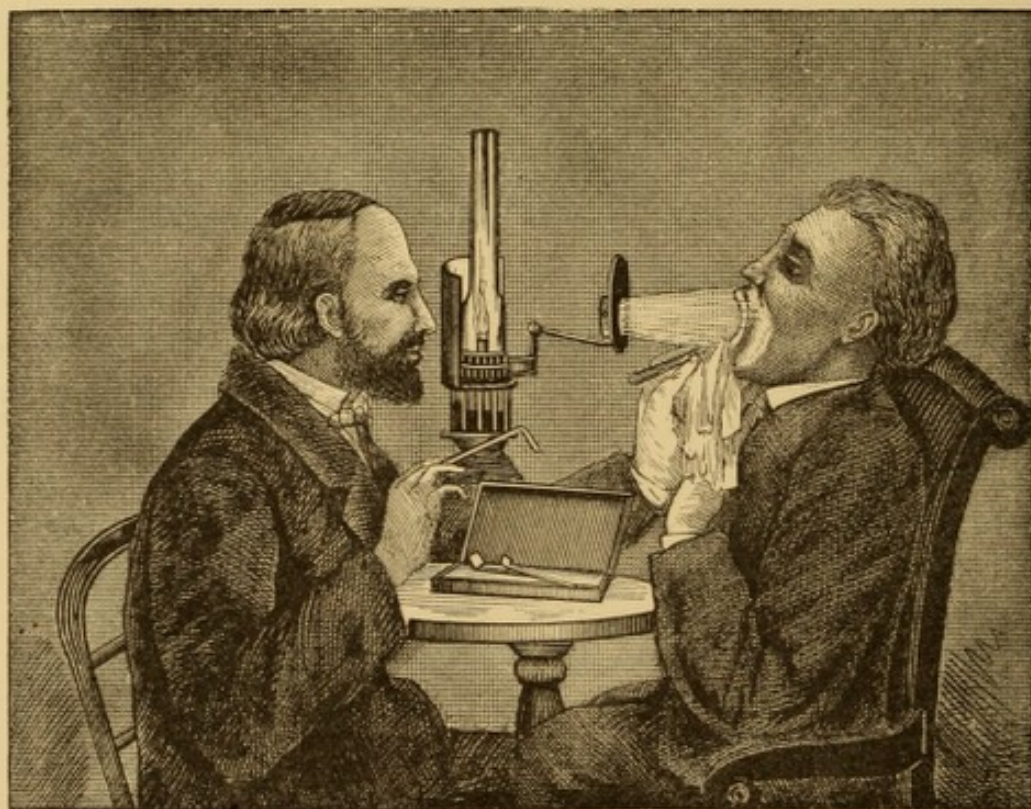


FIG. 21.—Examination by direct artificial light (Moura).

Argand burner is preferable to a flat flame. To reduce the orange-red tone of illumination by artificial light, it is advantageous to use blue-tinted or cobalt chimneys, which render the light whiter. In examining by direct light (Fig. 21), the lamp, with the lens in front of it, is placed upon a small stand or table behind which the observer sits. A shade behind the light protects his eyes from its direct glare. The patient is seated directly in front of the light, which is placed at such

a height that its rays pass straight into his open mouth. The examiner then passes his arm around on one side of the lamp and makes the examination as by solar light. This method requires but little apparatus; but it is slightly awkward, because the light must be placed between patient and observer, and because its direction cannot be changed without suspending the examination.

It is inferior in convenience to examination by reflected light, although, perhaps, occasionally more advantageous in affording a brighter illumination. The apparatus of Krishaber is one of the simplest for increasing the illumination by direct light (Fig. 22).

In examining by reflected light, the lamp is most conveniently located to one side (usually the right side) of the patient, a little behind his head and about the level of his ear, or it may be placed directly behind and above his head; and the rays of light are then received upon a concave reflector, having one-half the focal distance of that with which we work by sunlight. Under these circumstances the disk of light just within or just beyond the inverted image of the flame is used as the illuminating medium, and it affords but a small extent of illumination. A condensing lens placed in front of the light, collects its rays

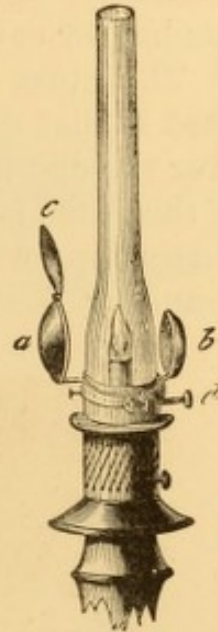


FIG. 22. — Krishaber's illuminator.

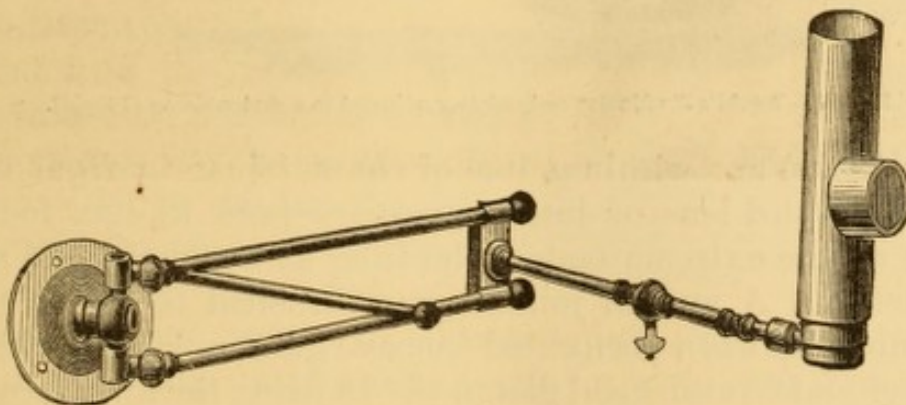


FIG. 23. — Mackenzie's rack-movement bracket, and bull-eye condenser.

and affords a large circle of illumination to cast into the mouth. A tubular tin chimney, with a circular aperture at the brightest part of the flame of an Argand burner, affords a

bright circle of illumination intensified by the reflecting power of the concave surface of the chimney behind the flame.

Mackenzie's rack-movement bracket with bull-eye condenser (Fig. 23) is arranged for attachment to the wall, and is exceedingly convenient for use with the head-reflector, as the gas-burner can be readily adjusted to a convenient position.

The most satisfactory illuminating apparatus that I have used is that of Tobold. It consists of a metallic lantern placed over the chimney of the lamp or gas-burner (Fig. 24). The light of the flame is concentrated by a system of three double convex lenses supported in a metallic tube fitting into the lantern surrounding the flame. Two of these lenses of equal refraction

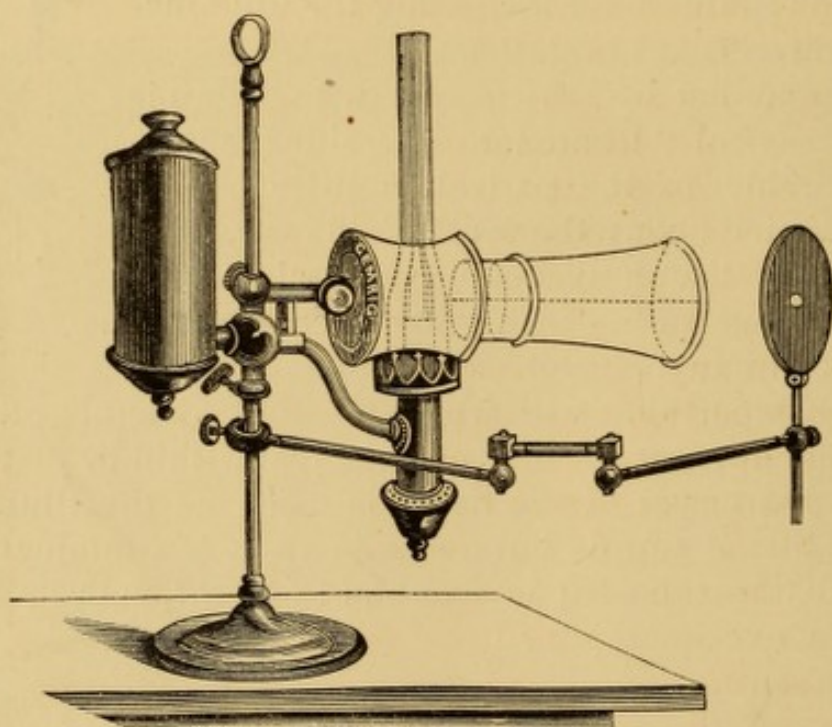


FIG. 24.—Tobold's illuminator and reflector adjusted to a student-lamp (Tobold).

(7 ctm. focus) are within a line of contact just in front of the flame, the third lens of larger aperture (and 13 ctm. focus) is placed at the extreme end of the tube at a distance of about five inches. A special jointed arm attached to the stand of the lamp supports a perforated concave glass reflector of $7\frac{1}{2}$ ctm. diameter and 20 ctm. focal distance. In using the apparatus, the flame is to be adjusted to the level of the patient's mouth, but not near enough to incommode him by its heat. For office use, the rod sustaining lamp, lenses, and reflector is often attached telescopically to a support clamped upon the edge of a table, so that the whole apparatus can be raised or lowered without

detaching any of its parts; and by means of flexible tubing, illuminating gas may be substituted for the lamp.

A more convenient method of using this apparatus is to have it supported telescopically in a stout stand upon the floor, and to suspend the reflector above the lenses (Fig. 25) to keep its supporting arm out of the way of the hand and wrist when both hands are engaged in an operation, as originally arranged for my own use; the source of light being an Argand gas-burner, fed by means of flexible tubing, from any convenient bracket or pendant. This adaptation of the Tobold lamp leaves little to be desired. The entire illuminating apparatus, light, lenses, and reflector, being attached to a rod movable in the socket of the supporting stand, can be adjusted readily at any height, and turned in any direction without moving each portion separately as in the original apparatus. Elsberg and others support the reflector by a rod attached to the top of the free extremity of the tube supporting the lenses, an excellent substitute for the original arm.

Almost all the reflectors formerly furnished by instrument makers were perforated in the centre. This is simply due to the fact that Czermak took the idea of the laryngoscopic reflector from that of the ophthalmoscopic one. It is occasionally advantageous to make use of the perforation, so as to look in the very axis of the rays of light. The perforation is by no means essential. The reflectors attached to the head are sometimes suspended before one eye. In that case the perforation is necessary. A band, pad and spring, or a spectacle frame are the usual means of attaching the reflector to the head. The

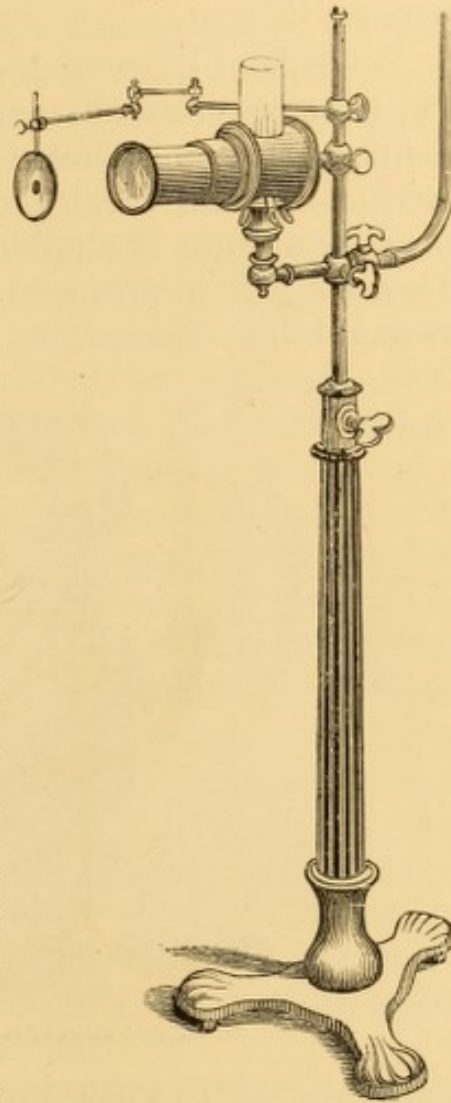


FIG. 25.—Author's arrangement of Tobold's illuminating apparatus; fed with gas, supported from floor, with arm of reflector above the lenses; the whole movable *en masse* up or down, right or left, by means of a supporting rod, sliding in the socket of the stand.

most convenient method is to use a head-band of elastic webbing.

In employing artificial light any excess of daylight should be shut out. A dark shade before the window suffices. It is unnecessary to exclude the sunlight so much as to render it difficult to distinguish objects readily about the room.

Dr. Tobold likewise devised a small pocket illuminator (Fig. 26), for more convenient transportation to the residence of patients. It is constructed on the same principles as the larger instrument, and furnishes just as good an illumination; but the disk of light is smaller, and the operator is much closer to his work. It is arranged for attachment to the student-lamp, as seen in the illustration, but can be very readily adjusted to

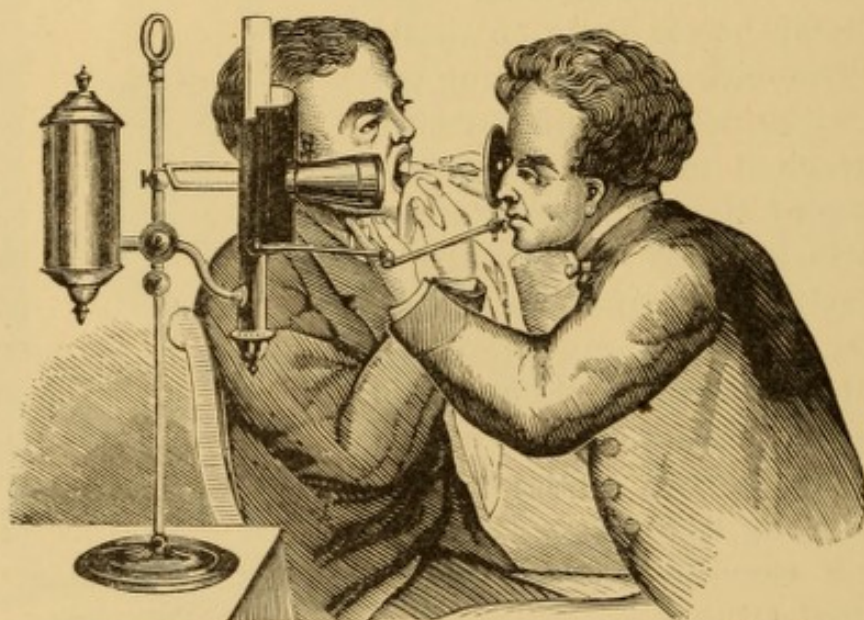


FIG. 26.—Examination by means of Tobold's pocket illuminator (Tobold).

a gas-jet. With the aid of this instrument I have performed many delicate intralaryngeal operations with entire satisfaction.

Various hand-laryngoscopes have been devised for convenient carriage from patient to patient; laryngoscopic mirror and reflector (Elsberg), lamp and reflector, and sometimes even tongue-depressor also, being connected so as to be held in one hand to illuminate the mouth. I have never used them or deemed them essential, having had ample satisfaction in the use of the head-mirror and the light of a good lamp or gas-burner. I sometimes carry an especially good gas-burner with me to screw on to a bracket or pendant if the one furnished me is in poor order. In the absence of a reflector, the bowl of

a small ladle or large spoon can be used, and a candle, or two or three fastened together, be tied to the handle of the spoon, so that the wick, when lighted, will be about the centre of the improvised reflector. The interior of a small, bright metallic basin, or any bright article of similar shape, may serve as an imperfect reflector on emergency.

Auto-Laryngoscopy.—Examination of one's own Larynx.
—Skill in laryngoscopic diagnosis is facilitated by occasional examination of one's own larynx.

Many auto-laryngoscopists have acquired the power of exhibiting their larynges and contents to a wonderful extent. By reason of continued practice, the involuntary muscles move intuitively in obedience to the will, while the operator as intuitively retracts his neck or elongates it, and performs various other movements which would be absolutely impossible in a patient without long training. Auto-laryngoscopy is not of as much service in learning the manipulation upon patients as has been represented; for the movement required to introduce an instrument into one's own throat is entirely different from that employed in inserting it into the throat of another; and furthermore, a patient is rarely encountered whose control over his head, or over his laryngeal and pharyngeal structures, is equal to that of an auto-laryngoscopist. It is rarely, too, that one will be able to demonstrate readily upon a patient all that he can observe in his own person, for the patient has not the practice of the auto-laryngoscopist, nor the same interest in it; while, in addition, his organs are seldom normal, or he would hardly require laryngoscopic examination.

He who would attain skill in examination of patients must therefore commence at once upon a second person, as soon as he has mastered the regional anatomy of the parts concerned; and this he can do all the better if he has had some preliminary practice on the cadaver, a model, or an excised larynx enclosed in a box or attached to a skull. Two or more individuals studying this art together can alternate for each other as object and observer.

But auto-laryngoscopy is of immense value to scientific study, in enabling us to observe the effects, natural and acquired, upon the laryngo-pharyngeal organs, of certain normal and abnormal physiological efforts, such as elongation and

retraction of the pharynx, variations in respiration, intonation, vocalization, and cantation, the phenomena of sighing, coughing, retching, and deglutition, etc., as well as in facilitating the study of the muscular movements necessary to bring into clearer view any particular portion of structure. For such observations the investigator will find no more submissive subject than himself.

There are several modes of auto-laryngoscopy. The easiest is to hold a small hand-mirror before the eyes with one hand, and introduce the laryngoscopic mirror with the other; solar (the original method of Garcia) or artificial light being used as is most convenient. Of course the auto-laryngoscopist must be able to keep his tongue in the proper position without extraneous assistance. This method is simple and convenient for mere examination; but if it is desired to introduce an instrument into one's own larynx, it would be necessary to have the looking-glass supported in the proper position, so that both hands could be employed with instruments. In this way three or four persons, standing in front of the auto-laryngoscopist, behind the mirror in his hand, can look past it at the image in the laryngoscopic mirror, one of them looking through a central opening if it be perforated, while those standing behind him will see the image with him in the hand-mirror. Of course it will be understood without explanation that the differing angles of reflection and vision will prevent all the observers from seeing precisely the same image. Attention is called to the fact that, notwithstanding the laryngeal image receives in auto-laryngoscopy a second reflection before it can meet the eye of the observer, and on that account must be somewhat less distinct than the image observed in the laryngoscopic mirror itself, the auto-laryngoscopist does not use the perforation of his reflector; this being placed a considerable distance in front of him, and the light by which the image is conducted to his eye being first reflected upon the hand-glass from the laryngoscopic mirror, not only at quite a distance from his eye, but totally removed from direct vision, and hidden deep in the cavity of the mouth. This is a strong ocular demonstration that there is no necessity for a perforated reflector. With a perforated mirror before his eye in this method of auto-laryngoscopy, the observer could not obtain a distinct view of the image at all. With the light at the side

of the mirror in which the observer is to see the image of his own larynx, so that its rays fall upon a reflector attached to the head, there is some difference, but he will find looking through the perforation satisfactorily an exceedingly difficult matter.

The method of auto-laryngoscopy practised by Czermak is as follows: The reflector being placed upon a stand eighteen or twenty inches in front of the experimenter's mouth, a quadrilateral mirror, also mounted on a stand, is placed a foot nearer, but in such a manner that its upper edge shall be about level with the lower edge of the reflector behind. The flame of the lamp having been placed near the quadrilateral mirror, the observer throws the light into his mouth with the reflector, and, having introduced the laryngoscopic mirror, sees the image in the quadrilateral one. Previous to his adaptation of the ophthalmoscopic reflector, Czermak performed auto-laryngoscopy by direct light in front of the mouth, holding a plane mirror in such way that the light should pass beneath the mirror and between the hands into the pharynx.

With sunlight the auto-laryngoscopy can be made with the reflector or without it, according to circumstances or convenience.

An ingenious method of auto-laryngoscopy, teaching the observer at the same time the proper management of the light and of the frontal reflector in the examination of patients, is that adopted by Dr. George Johnson. Sitting at a table of convenient height, he places a looking-glass at a distance of about eighteen inches in front of him, and a moderator or gas-lamp on one side of the glass, but two or three inches further back, so that the light may not pass directly from the lamp to the mirror. The reflector being on his forehead, he directs the light, as it were, into the open mouth of his own image in the looking-glass; then introducing the laryngoscopic mirror into his mouth, he sees the reflection of the larynx and trachea, etc., in the glass before him, and any one looking over his shoulder or head can see the image at the same time. In this method of Dr. Johnson the image is not quite as distinct as in the other methods described, because the rays of light do not pass to the laryngoscopic mirror directly from the reflector, but are reflected from the looking-glass in which the image is seen, and upon which the light is directed by the reflector.

Demonstro-Laryngoscopy.—Demonstration of a Laryngoscopic Image to Bystanders.—It is sometimes an object to exhibit the condition of a patient's larynx to one or more persons, either for purposes of consultation or tuition. This is demonstrative laryngoscopy, the recipro-laryngoscopy of Dr. Morell Mackenzie. It is often a difficult manipulation.

A second person—and the difficulty is obviously increased as the number of observers becomes more numerous—in order to see the image which another person is examining, must look by the side of the observer's head, or over his shoulder; consequently, his angle of vision being different, he cannot perceive the relations of the image exactly as they are being described to him; and the operator, in moving his own head a little aside in order to afford this second observer a better view, can hardly avoid changing the position of the mirror a little, and thus it will reflect parts which are not being designedly demonstrated, while other parts of the structures will be entirely beyond the field of reflection.

To overcome this difficulty, and learn how to manage the mirror and one's head, so that those about the observer can be enabled to see distinctly the image of any particular portion of the parts which it is desired to demonstrate, requires a great deal of practice, and often peculiar capabilities in addition; for, owing to a law of physics, from the narration of which, to borrow an expressive phrase from Semeleder, "we will spare the reader," the second observer cannot, simultaneously with the demonstrator, see the whole of the image which is being explained to him.

It must also be remembered, in making a laryngoscopic demonstration, that, as with the beginner's early use of the microscope, persons unaccustomed to the employment of the laryngoscope, and not sufficiently familiar with the regional anatomy of the larynx to comprehend the character of normal image that should be perceived in the different portions of the mirror, will fail to recognize all that is pointed out to them, although it may be distinctly visible. Experience in viewing normal laryngeal images is therefore highly necessary before abnormal conditions and pathological alterations can be detected.

Demonstro-laryngoscopy rarely affords as satisfactory a demonstration as auto-laryngoscopy, because the larynx of a

patient cannot be brought under control equal to that of the interested self-examiner; besides which, the normal relations of the part may have become so changed by disease in a patient, as to render a satisfactory demonstration impossible to those themselves unable to handle the laryngoscopic mirror with the skill of an expert.

The simple placing of a hand-mirror in the grasp of a patient is a good means of demonstro-laryngoscopy; and also placing a toilet-mirror at the proper height by the operator's side. Then several individuals standing behind the patient can see the image he himself sees in the mirror in his hand, while others, looking past his head or over his shoulders, can see the image in the toilet-mirror. In some of my demonstrations the examining table was placed directly in front of a book-case with mirror doors. The observer sitting in front of these mirrors, his back towards them, conducts the examination in the method previously described, and several persons, standing at either side of him, can see the direct image, while a number standing behind the patient can see the reflected operation in the mirrors of the book-case. If, in addition, a mirror is placed by the patient's side, and another in his hand, a still larger class can witness the same demonstration. In addition to all this, if one of a third party of two, three, or four, standing on the left side of the patient, at whose right is stationed the illuminating apparatus, take in his hand a large laryngoscopic mirror and hold it obliquely before the patient's mouth, on his right side, in such way that it receives light reflected from the laryngoscopic mirror within the mouth, he too, and two or three at his side, can see the laryngoscopic image distinctly, without interfering with the other observers. In this way a demonstration can be made at the same time to quite a numerous class. The extra-laryngoscopic mirror intended to be held obliquely in front of the patient's mouth may be permanently attached to the illuminating apparatus by means of a little arm similar to that used for the attachment of Tobold's reflector. As this mirror, too, will become dimmed by the halitus of the breath when held quite near the mouth, it must be heated or otherwise prepared, to prevent condensation of moisture on its surface. When held by the hand from the opposite side, the stem must be placed undermost, so that it be

out of the way of the first laryngoscopic mirror, and beneath it when the latter has been passed to the pharynx.

To a teacher of laryngoscopy, the employment of the second laryngoscopic mirror in this way will enable him to watch and direct the movements of a pupil much more accurately and satisfactorily than by any other method with which the writer is acquainted; while at the same time he will see a similar image to that which is being examined in the mirror in the mouth, and be entirely out of the way of the operator's movements.

Dr. Smyly,¹ of Dublin, has contrived an apparatus for demonstrating to others the larynx of a patient. He uses a frontal band to which is attached a split tube carrying a perforated reflector that is placed over one eye. Attached by a second split tube to a brass rod bent at an angle of 45° is a small square plane glass mirror set in brass, that is placed in front of the other eye; and those observers standing behind the patient see the reflected image in this square mirror. This apparatus is somewhat clumsy and awkward for the operator, necessitating considerable familiarity with its use for its satisfactory employment.

Infra-Glottic Laryngoscopy and Tracheoscopy.—Tracheal Laryngoscopy.—Inspection through a Wound in the Trachea or Larynx.—Dr. Neudörfer² suggested the feasibility of examining the laryngeal and tracheal structures by means of a mirror passed through the wound left after laryngotomy or tracheotomy, and demonstrated its possibility on the cadaver; and Czermak, the great promoter of this whole art, early in 1859 proved the practicability of this method of examination upon the person of a living patient. Von Bruns, of Tübingen, followed in March of the same year, since which time the examination has been frequently repeated.

In this manner the deeper structures of the trachea can be more minutely explored, and inspection be obtained of the lower surface of the vocal cords—an examination otherwise impracticable. This method is, of course, of very limited ap-

¹ Gibb, *Diseases of the Throat and Windpipe*, London, 1864, p. 459; Mackenzie, *The Use of the Laryngoscope in Diseases of the Throat*, London, 2d Ed., 1866, p. 73.

² *Wiener Zeitschrift für prakt. Heilkunde*, Nov. 12, 1858.

plication, from paucity of subjects; but in the laryngeal or tracheal disorders of patients with an artificial opening externally, it affords an additional means of diagnosis of which due avail should be taken. It very often happens that pathological changes following suicidal wounds or the operation of tracheotomy or laryngotomy, will, by tumefaction, or contraction from cicatrization, prevent the possibility of obtaining a good view into the parts from above. Under such circumstances the advantage is afforded of being enabled to introduce instruments under sight, through the exterior opening.

The presence of the ordinary curved tracheotomy tube will interfere with this examination, but the substitution of a canula with a long fenestrum in its upper surface will permit the introduction of a mirror; or, instead, a short, plain, straight tube may be employed (Tuerck); or the edges of the wound may be kept apart by a bivalved dilator or by bent hair-pins, or by hooks attached to a ribbon passing round the back of the neck from one side to the other. The best mirrors for examinations of this kind are those made of thin plates of polished steel; because, as they are necessarily exceedingly small, there is no loss of reflecting surface, as there would be with the narrowest setting. The shape of the mirror may be round or oval. The stem of the mirror must curve strongly downward from its reflecting surface, so that when introduced within the tube, the handle will be considerably below the opening in the structures (Fig. 27). The best results are obtained by direct sunlight. When artificial light is employed it must be reflected horizontally through the axis of the wound to the posterior wall of the tube. As the mirror dims much more quickly than when held in the pharynx, and as heating it in the ordinary mode necessitates its very frequent removal during examination, it is best to protect its surface by spreading over it a delicate layer of gum-water, sugar and water, glycerine, or dissolved caoutchouc. It must be expected to find respiration impeded by the presence of the mirror in the respiratory tube. There is great irritability of

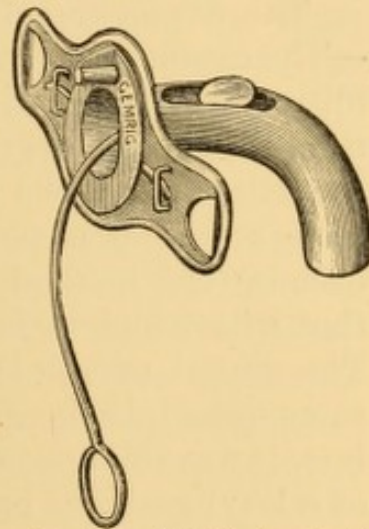


FIG. 27. — Tobold's fenestrated tracheal canula, with small metallic mirror for infra-glottic laryngoscopy.

the structures from the contact of a foreign body, which renders the manipulation by no means an easy one; in addition to which, difficulties will often be encountered from cicatricial and other pathological changes which may have followed the surgical operation.

In this manner we can examine the lower surface of the true vocal cords; the posterior wall of the larynx and trachea; the lower attachment of the epiglottis, and its laryngeal surface from the point of insertion all the way to its free border; and the anterior face of the arytenoid cartilages;—light being thrown through the glottis, when dilated, clear on to the pharynx and velum.

In ordinary supra-glottic laryngoscopy, the vocal cords appear pearly white in color; but in infra-glottic laryngoscopy their lower surface is deep red, like the whole mucous membrane of the larynx; so that at times the cords can only be recognized as such by their movements. Their fibrous portion is usually distinguishable from the muscular portion, and the two cords have a festooned appearance in relaxation, the lower portion of the curtain-like structures coming in juxtaposition during attempted phonation.

The Structures Subjected to Laryngoscopic Examination.
—The obstacles to examination having been overcome, and the mirror introduced without difficulty and placed in proper position, it behooves us to consider what is likely to be reflected in the mirror, that we may be able to recognize the image. A little attention is necessary here, on the part of the beginner, because the method of examination is entirely different from that with which he is wont to examine other parts of the body. The dental mirror is the only instrument constructed on the same principle, longer in use than the laryngoscope, and, in fact, it was the use of the dental mirror that suggested the idea of a laryngoscopic one. It must be remembered, then, that we are to see an image of the parts under examination, in the same way as we would look at the image of anything else in a looking-glass. We do not see the parts themselves. The structures reflected are seen in a reversed direction, that is to say, looking forward instead of backward, but retaining their relative relations with regard to right and left.

The structures most prominent in the mirror are, normally:

the epiglottis, the supra-arytenoid cartilages, and the vocal cords. These are readily recognized; but many other important parts are reflected which are not easily located until some familiarity has been acquired in laryngoscopic inspection. It is the same as in the cultivation of observation under the microscope; many things are recognized, as one grows accustomed to microscopy, which were not seen before; still they were in the field all the time.

The structures thus exposed to inspection are, from before, backward and downward: the posterior portion of the base of the tongue; the posterior surfaces of the anterior palatine folds, and their attachments to the sides of the base of the tongue; the lateral ligaments connecting the tongue with the hyoid bone; the ligaments connecting the tongue with the epiglottis, and the lingual sinuses between the middle glosso-epiglottic ligament and the two lateral ligaments or folds; the tonsil glands; the posterior palatine folds, as they run downward and backward to be lost in the sides of the pharynx; the ligaments connecting the epiglottis and pharynx; the lateral ligaments connecting the epiglottis with the hyoid bone; the epiglottis itself, its anterior or lingual surface, its upper and lateral borders, and its posterior or laryngeal surface; the ligamentous folds of mucous membrane, connecting the sides of the epiglottis with the arytenoid cartilages, and forming the upper portion of the quadrangular membrane or limiting walls of the respiratory tube of the larynx; the arytenoid cartilages, with the supra-arytenoid cartilages (Santorini) at their apices, imbedded in submucous connective tissue; the base of the cuneiform (Wrisberg) cartilages, enclosed within the aryteno-epiglottic folds, a few lines from their arytenoidal extremities; the fold of mucous membrane between the arytenoid cartilages; the pyramidal or pear-shaped (laryngo-pharyngeal) sinuses just outside of the laryngeal cavity, comprising the space between the exterior surface of the quadrangular membrane or respiratory wall of the larynx, and the inner surface of the thyroid cartilage; the posterior wall of the pharynx, as far down as the position of the cricoid cartilage, where the entrance into the œsophagus appears as a narrow groove communicating with the pear-shaped or pyramidal sinuses; the posterior wall of the larynx until hidden by the commencement of the œsophagus; the supra-glottic cavity of the larynx and

its component structures ; the vocal cords, and above them the ventricles (Morgagni) ; the ventricular bands (false vocal cords), above the ventricles, and formed on each side by a duplicature of the laryngeal mucous and elastic membrane ; a portion of the infra-glottic cavity of the larynx, and the internal face of the anterior portion of the thyroid cartilage, crico-thyroid membrane, and cricoid cartilage ; the anterior portion of the trachea, to a greater or less extent, and under very favorable circumstances, clear down to the bifurcation of the tube ; and, in exceptional cases, more or less of the continuity of the right bronchus ; under peculiar circumstances, more or less of the posterior wall of the trachea.

Such are the structures which the laryngoscope reveals to inspection in the living subject. It is impossible to bring all the tissues enumerated into one and the same view, just as it is impossible to see all the parts of any complicated object from one point of view ; but by changing the direction of the mirror, a little forward or backward, to one side or the other, the light can be reflected upon all these structures in succession, so that their condition may be observed. In moving the mirror, or giving it a further inclination to one side or the other, tremulousness must be avoided. It is this constant hitting of the parts that induces hyperæsthesia. A decided, though gentle pressure upon the parts is borne much better. It is for this reason that the recommendation has already been made to let the lower edge of the mirror rest upon the posterior wall of the pharynx. In this way there is no titillation of the parts as is so apt to ensue on endeavoring to avoid touching the soft palate, and particularly the pharynx. The only part to avoid is the base of the tongue, contact with which induces retching. The handle of the mirror may be held in the centre of the mouth, or to one side, as is most convenient, or as the observer falls into the habit of doing.

Description of the Laryngoscopic Image (Fig. 28) in Detail.

—The most conspicuous structure attracting attention in the laryngoscopic image is the epiglottis, whose free portion, jutting upward from behind the base of the tongue, renders it readily recognized. In the upper part of the mirror and behind, we recognize the inferior surface of the posterior palatine folds terminating in the lateral walls of the pharynx ; and in front

of the tonsil the anterior palatine folds terminating in the sides of the base of the tongue, of whose posterior surface with its papillæ, more or less is visible according to the obliquity of the mirror. Directing our attention to the epiglottis, we perceive an anterior (1)¹ and posterior (2) surface, and an upper arching crest, frequently indented (3); from its lateral borders is given off on each side a pharyngo-epiglottic fold (4) of mucous membrane arching upward and forward to join the posterior palatine fold as it terminates in the lateral pharyngeal wall. As this fold leaves the epiglottis we distinguish another and thicker fold leaving the same point at nearly right angles and stretching curvilinearly backward and inward to the arytenoid cartilage. This is the ary-epiglottic fold (5), forming the superior free border of the quadrangular membrane of the larynx. The anterior surface of the projecting portion of the epiglottis is seen to be slightly concave from above downward, and strongly convex from side to side; while its posterior surface is concave and convex in the opposite directions. Upon observing the posterior or laryngeal face of the epiglottis we notice that it swells out more or less abruptly into a considerable belly or pad (6), which tapers down to its point of attachment, and which, in the process of swallowing, etc., becomes pressed down, like the pad of a truss, upon the ventricular bands. This tubercle, or "cushion of the epiglottis," is formed chiefly by an aggregation of mucous glands and adipose tissue. It very often projects sufficiently to cut off the view of the anterior portions of the vocal cords attached to the thyroid cartilage below.

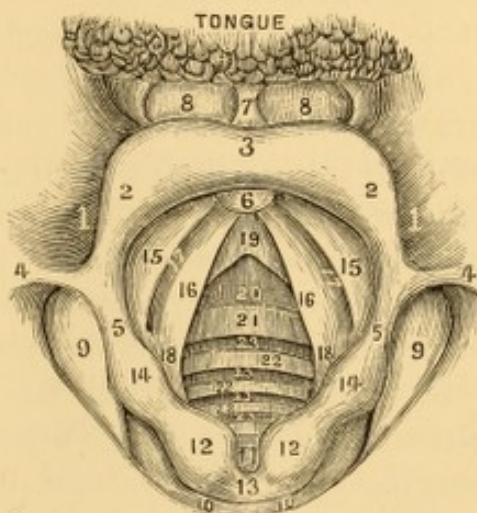


FIG. 28.—Enlarged sketch of normal laryngoscopic image in respiration, slightly forced to exhibit the chief cardinal points of observation in detail. 1, Lingual surface of epiglottis. 2, Laryngeal surface of epiglottis. 3, Indented crest of epiglottis. 4, Pharyngo-epiglottic fold. 5, Ary-epiglottic fold. 6, Pad of epiglottis. 7, Glosso-epiglottic ligament. 8, Lingual sinus. 9, Pharyngo-laryngeal sinus. 10, Posterior laryngeal wall, terminating in a line representing the entrance into the œsophagus. 11, Inter-arytenoid incisure. 12, Supra-arytenoid cartilage (Santorini). 13, Inter-arytenoid fold. 14, Cuneiform cartilage (Wrisberg). 15, Ventricular band. 16, Vocal cord. 17, Ventricle (Morgagni). 18, Posterior vocal process. 19, Thyroid cartilage. 20, Crico-thyroid membrane. 21, Cricoid cartilage. 22, Rings of trachea. 23, Interspaces between the cartilages of the trachea.

¹ The bracketed figures in the text describing the laryngoscopic image refer to Fig. 28.

The normal color of the pad is quite red; and by artificial illumination it will have a deeper color than by sunlight, a point to be borne in mind to avoid an incorrect diagnosis of congestion.

Stretching from the middle line of the anterior and lingual face of the epiglottis to the raphé of the tongue is seen the median glosso-epiglottic fold (7) or frænulum of the epiglottis. It is a small, sharp-edged, membranous fold enclosing the glosso-epiglottic ligament, by means of which the epiglottis is drawn forward when the tongue is protruded.¹ Upon each side of this fold, which is strongly raised when the tongue is protruded, there is seen an indentation (8), sometimes shallow, oftener deeply depressed, presenting in shape and size very much such an appearance as would remain moulded in plastic material after moderate pressure from the tip of the finger. These are the lingual sinuses (glosso-epiglottic fossæ or sinuses, the valleculæ of Tourtual). When shallow they gradually become lost in the lateral border of the tongue; but more frequently they are strongly depressed at the frænal outline, and, becoming less deeply marked on either side, are bounded exteriorly by a sharp fold of the mucous membrane of the side of the tongue, called the lateral glosso-epiglottic fold. These lateral folds do not enclose any ligament, and, though generally found to exist post-mortem, are very frequently absent in the living organ (first laryngoscopically demonstrated by Merkel); and it is affirmed by Luschka that, when they do exist, they join the sides of the pharynx, an anterior leaflet only being continuous with the mucous membrane of the tongue. As first indicated by Bruns, in the floor of these sinuses we are sometimes able, with the laryngoscope, to discern the position of the greater horn of the hyoid bone, which appears as a clear, longish, oval projection behind and extending outward. These lingual sinuses often afford lodgments for articles of food, and other foreign bodies, and are not unfrequently the site of morbid processes, especially of tuberculous, scrofulous, or syphilitic ulceration. Cystic growths have also been seen in them.

Considerable space has been devoted to the description of the apparently unimportant lingual surface of the epiglottis, but the importance of always

¹ Some muscular fibres from the tongue can sometimes be traced in this frænulum, which, in some lower animals, encloses a pair of muscles.

examining it cannot be overestimated, as there are a number of cases on record in which long-continued throat disease had resisted topical applications to the interior of the larynx. Diseases which the laryngoscope revealed to be ulcerations of these sinuses soon healed by proper local treatment.

The height of the projecting portion of the epiglottis will vary, with the size, age, and sex of the individual, from three or four lines to an inch, the average in the adult male being rather more than half an inch; and when erect, part of its laryngeal face will often curl over and present outward (Figs. 29, 30, 31). Its color is a light red veiling a yellowish white, being less pronounced at its edge, where the color of the cartilage is more distinct,—much like the color of the conjunctival membrane of the eyelid, to which it was compared by Stoerck. Posteriorly the red deepens, and the pad, as stated, appears quite red. The thickness of the epiglottis will vary from a sharp, thin edge—hardly a line—to a thick stump of several lines; and when swollen it may be as thick as the finger. It is also very variable in shape.

The following normal variations of configuration may be enumerated: a more or less deep or more or less broad indentation along the free margin of its crest (Fig. 30); an elevation at the middle of its crest with a depression at each side; an irregular prolongation of one side of the crest without a corresponding one at the other (Fig. 31); no depression or elevation whatever—a uniform curve (Fig. 29); a small globular nodule at the centre of the crest, as if to fit some depression behind when it falls in deglutition; long, narrow and

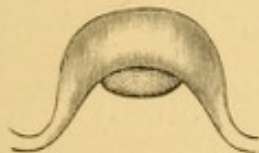

FIG. 29. — Arched epiglottis.



FIG. 30. — Indented epiglottis.

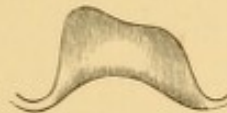

FIG. 31. — Asymmetric epiglottis.

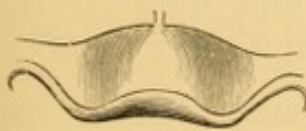

FIG. 32. — Depressed epiglottis.

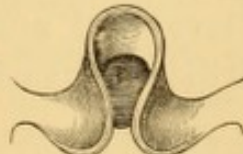

FIG. 33. — Omega-like epiglottis.

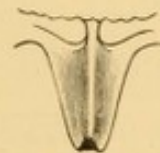

FIG. 34. — Pointed and depressed epiglottis (of children).

pointed, especially in children (Fig. 34); broad and very short; the laryngeal face very much rolled outward; the sides rolled in together posteriorly, till they almost touch; curled posteriorly with a central omega-like contraction, compared by Tuerck to the sides of a jewsharp (Fig. 33). I have gone rather minutely into these points, because anomalies of form have sometimes been mistaken for pathological manifestations; for example, unusual depression for losses of substance, and nodular elevations for morbid growth.

The configurations usually met with are the arched crest (Fig. 29), the indented crest (Fig. 30), the assymetrical crest (Fig. 31), the depressed epiglottis (Fig. 32), the omega-like contraction (Fig. 33), and the long, pointed epiglottis of children chiefly (Fig. 34). The shape of the epiglottis likewise undergoes change as a result of inflammatory and ulcerous processes, becoming adherent to adjacent structures, deformed, compressed, or constricted; and it often retains the altered shape or position after recovery.

The muscles of the epiglottis have sufficient power at times to draw the fibro-cartilage down upon the entrance into the larynx. We can see this movement in imitated deglutition following closure of the glottis and approximation of the ventricular bands. Porter,¹ in experimenting upon the artificial induction of asphyxia in a dog, found the epiglottis shut down like a lid upon a box, so as to close completely the superior aperture of the larynx.

The size of the epiglottis varies in the normal subject, but not so frequently as its shape. I have seen it no larger in a man six feet in height than in an ordinary child of ten years of age. In other instances it is very large, in some so immense as to have been considered pathological.² Ordinarily the epiglottis is quite rigid; sometimes it is flaccid. It is sometimes quite erect, meeting the plane of the tongue at a right angle; sometimes its lingual face will be pressed back upon the base of the tongue; ordinarily it will be found to overlook the laryngeal entrance at an angle of from 40° to 60° , but it is sometimes much more depressed backward (Fig. 32), so that it may shut off a view into the larynx—and all this congenitally. When the tongue remains at rest upon the floor of the mouth, or is only slightly protruded, its base often presses the epiglottis more or less over the laryngeal aperture, and then the free upper border of the cartilage will usually appear as a narrow

¹ On the Larynx and Trachea, London, 1837, p. 232.

² In a case of hysteria occurring in Philadelphia, and supposed to be due to a pedunculated polyp of the pharynx, occasionally making its appearance in the mouth, and said (by physicians who sat by the patient for hours at a time to watch it and try to catch it with forceps) to protrude at times between the teeth, I found on inspection that the offending body was a very long epiglottis, the momentary sight of which, gorged with venous blood, during hysterical or suffocative spasms, had misled the attendants to the supposition that there was either a living foreign body (a water-snake) in the œsophagus occasionally paying a visit to the mouth, or a pedunculated neoplasm in the pharynx thrown forward during the paroxysm.

band or stripe more or less arched. If the glands of the base of the tongue are enlarged, they may hide so much of the epiglottis as to simulate loss of structure; or the epiglottis may get caught beneath the projecting portion of an enlarged gland.

The posterior wall of the pharynx appears beyond the laryngeal structures in the lower portion of the mirror, as a smooth, glistening surface, sometimes striated in appearance, of an ashy-red color, and presenting here and there small rounded or oval elevations, due to large or enlarged follicles; and in some positions of the mirror it can be seen its entire length, so that in the lowest part of the mirror and behind, about the position of the cricoid cartilage, we observe the posterior mucous surface of the larynx closely applied to the mucous membrane of the pharynx, affording no distinctive evidence of the opening into the œsophagus other than a slightly arched transverse furrow, marking, by a dark line, its point of commencement.

Outside the ary-epiglottic fold, between it and the inner face of the wing of the thyroid cartilage, we see the triangular pharyngo-laryngeal sinus (9), (pyriform or pyramidal sinus), which begins on each side of the free border of the ary-epiglottic fold as a small, deep fossa, becoming more and more conical as it descends, until it is finally lost at one end of the transverse furrow marking the commencement of the œsophagus (10). The wall is defined to the outer side by the inner face of the wing of the thyroid cartilage, and above this the hyo-thyroid membrane, and then the hyoid bone; to the inner side, by the quadrangular membrane, which forms a vertical angle anteriorly with the wing of the thyroid; and behind, it is bounded by the posterior wall of the pharynx. It is lined by the common pharyngeal mucous membrane, and along its angular floor there is a chain of glands often involved in disease of these parts. These pyramidal sinuses are sometimes seen entirely empty; sometimes they contain saliva or mucus, and sometimes a sort of caseous deposit. They often afford lodgment for foreign bodies, and they are frequently involved in pharyngeal diseases.

When the epiglottis is well raised (Fig. 35), we gain a view of the whole circumference of the superior laryngeal aperture. This is of a triangular, somewhat cordiform shape, wider in front than behind, sloping downward obliquely, and terminat-

ing behind in the vertical inter-arytenoidal fissure (11).¹ Its anterior border is the free rim of the epiglottis; then, on either side, the ary-epiglottic fold (5), which arches backward and

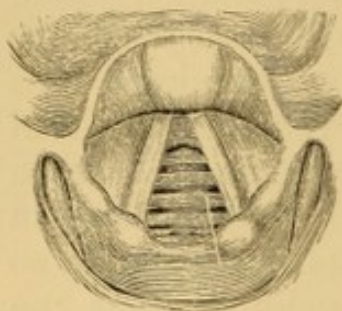


FIG. 35.—Normal larynx during inspiration.

inward in the form of a bow until it reaches its arytenoidal attachment posteriorly, where it surrounds the rounded eminence of the supra-arytenoid cartilage (of Santorini) (12); and the two arytenoids, with their connecting muscle and mucous fold (13), complete the border posteriorly. An enlargement on each side in front of the cartilages of Santorini, and breaking the arch of the ary-epiglottic fold into two unequal festoons, is produced by the enclosed club-shaped extremity of the cuneiform cartilage (of Wrisberg) (14), surrounded with glands and adipose tissue. In many subjects the outline of the supra-arytenoid cartilages is acuminate; and in some the staff-like outline of the cuneiform cartilage is distinctly visible as it descends the lateral wall of the interior of the larynx.

In some subjects the free margin of the aryteno-epiglottic fold is exceedingly tense, forming a very thin, sharp border. In most instances it is quite thick, as depicted in the majority of the illustrations in this volume.

The color of the aryteno-epiglottic fold has been well compared by Stoerck to that of the gums. The eminences of Wrisberg and Santorini are rather lighter in color than the rest of the mucous membrane, on account of its tension at these points.

A reflection of mucous membrane runs from one arytenoid cartilage to the other, which, during ordinary respiration, can be distinctly seen forming the posterior boundary of this superior portion of the larynx; but during vocalization the contraction of the arytenoid muscle causes approximation of the cartilages, and the band of mucous membrane folds up, exposing the vertical fissure. The obliquity of this border renders the thyroïdal wall of the larynx much deeper than the arytenoidal. Dr. Elsberg, of New York, maintains that in this posterior wall he has detected the presence of tubercles long before

the ordinary physical signs of phthisis could be recognized, and that after-results verified this early prognosis;¹ an observation in which he is confirmed by Czermak, Stoerck, Lewin, and others.

Looking down along the inner or laryngeal face of the quadrangular membrane, about half an inch below its superior border, on each side (aryteno-epiglottic fold), the lining membrane of the larynx will be seen folding under on itself, forming the ventricular band, *the false vocal cord* (15), a broad red mucous fold, and leaving an elliptical space between it and the horizontal upper surface of the true vocal cord of the same side, seen immediately below (16) as a white, glistening band, extending from before backward. This space is the entrance into the ventricle of (Morgagni) the larynx (17), and leads up into the laryngeal sac. By means of a deep inspiration, especially if short, sudden, and following vocalization, these ventricles can be rendered more distinct, and a separation of their walls be observed dilating the cavity (17). The size of the ventricles, and of their orifices is variable. Posteriorly the ventricular band is united with the vocal cord just in front of its attachment to the posterior vocal process.

In some cases, where the ventricles are large, the peculiar meat-color of the thyro-arytenoid muscle at the external portion of the vocal cord can be seen to glisten distinctly through the translucent mucous membrane.

The ventricular bands are not merely duplicatures of mucous, or of mucous and elastic tissue, but they are composed in part of ligamentous tissue (superior thyro-arytenoid ligament), and some muscular fibre also. They come in contact in deglutition just before the epiglottis comes down on the larynx, and approximate likewise in spasm of the larynx and in certain voluntary contractions (Fig. 36).

The mucous membrane lining the laryngeal sacs is thickly studded with the openings of numerous small follicular glands, situated in the sub-mucous connective tissue. The laryngeal surface of the sac is covered by the inferior portion of the aryteno-epiglottideus muscle (*compressor sacculi laryngis* of Hilton), which compresses it and discharges its secretions upon the vocal cords, helping to keep them moist and pliable.

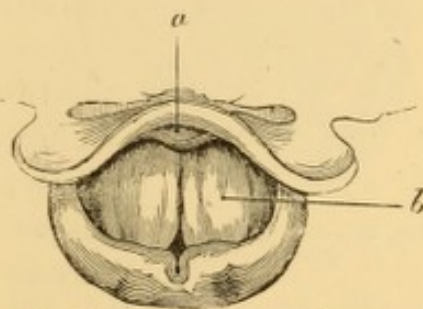


FIG. 36.—The ventricular bands in approximation (Tuerck). *a*, pad of epiglottis; *b*, left ventricular band.

¹ Laryngoscopic Medication, New York, 1864, p. 23.

The floors of the ventricles are formed by the vocal cords, which in health are easily recognized by their rapid movements during phonation, and by their striking, semi-metallic lustre—at times an opalescent white in the female—at times tinged slightly yellowish in the male. Each so-called cord is a strong, thick, fibrous-looking band (the inferior thyro-arytenoid ligament), the sharp and prominent edge of which constitutes the vibrating medium of the voice.

The vocal cord, at least its lower surface, is an extension inward of the vocal membrane, or the middle crico-thyroid ligament. Each cord consists of a compact band of parallel fibres of the thyro-arytenoid muscle, and of elastic and fibrous tissue, arranged in prismatic form, the base presenting outward, so that a vertical section shows the upper surface horizontal, and the lower surface taking an oblique direction downward and outward. This fibrous tissue forms a continuous band anteriorly where it is attached to the thyroid cartilage, while it is broken up into several fasciculi posteriorly, so that it is inserted into the arytenoid cartilage at several points. Firmly imbedded into the elastic fibrous portion of the vocal cords are some short pennated fibres from the vocal muscle, the thyro-arytenoid, which is adherent and parallel to it, attached in front to the receding angle of the thyroid cartilage, and behind to the arytenoid cartilage.

When the two vocal cords are approximated, as in phonation (Fig. 37), their horizontal surface forms a floor to the

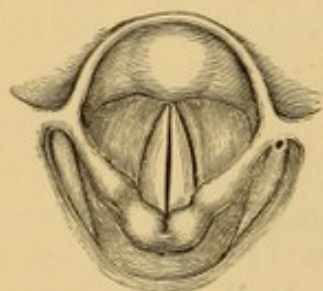


FIG. 37.—Normal larynx in phonation.

upper laryngeal cavity. They form with the space between their free edges *the glottis*; their sharp borders are *the lips of the glottis*, and the chink, fissure, or cleft between these lips is the *rima glottidis*. These terms should not be confounded. The length of the rima in the male varies from ten to thirteen lines; in the female, from seven to ten lines; in children it is much shorter. The space across will vary ordinarily from three to six lines; but when widely dilated by a deep inspiration, it may be from six to ten lines, leaving a space large enough often to admit a good-sized finger. The rima of the glottis is not formed by the vocal cords alone, but also by the inner face of the arytenoids posterior to the points of attachment of the cords; so that we speak of an inter-ligamentous rima (16)¹ corresponding to the length of the cords, say eight

¹ See Fig. 28.

lines, and an inter-cartilaginous rima posteriorly (18), about three lines.

Luschka is disposed to decry this division, which is due in appearance to the knuckling inward of the posterior attachments of the cords when the posterior vocal processes converge inward.

The form of the rima glottidis is not constant. During ordinary respiration it is a pyriform orifice somewhat enlarged and rounded behind, looking not unlike the lozenge-shaped space formed by pressing together the tips of the two thumbs and the tips of the two fore-fingers, and then extending the thumbs rather strongly posteriorly and the fingers anteriorly, when the space between the two thumbs will represent the inter-cartilaginous rima, and the remaining space the inter-ligamentous rima. When fully dilated, the rima assumes rather the form of an isosceles triangle, with the base posteriorly. The form of the rima changes greatly during phonation, and may become elliptical, oval, or closed posteriorly in the production of the various vocal tones, according as the cords are contracted in different degrees by the complex thyro-arytenoid muscle, with portions of which their structure is blended, and by other laryngeal muscles attached to the arytenoids and other laryngeal cartilages.

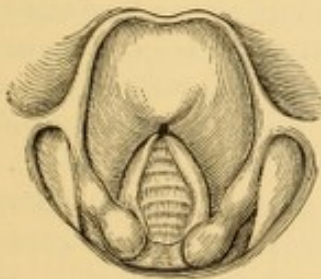


FIG. 38.—Normal larynx of the female in respiration.

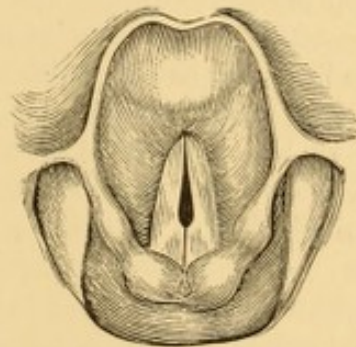


FIG. 39.—Normal larynx of the female in the formation of head tones.

In the production of the head tones, in the larynx of the female (Fig. 39), and exceptionally only (counter-tenor) in that of the male, the vocal processes of the arytenoid cartilages, which are large, strong, and prominent¹ (Figs. 38 and 39), are

¹ In a larynx in my possession secured from the dissecting table a number of years ago, the posterior vocal process shows signs of having been a separate cartilage, with a bulbous articulation into a socket in the arytenoid cartilage, the vertical section through the two looking like a coalesced ball and socket joint.

seen to become pressed together so that only the anterior ligamentous portion of the rima is free to gape (Fig. 39), the vibrating surfaces of the vocal cords being thus considerably diminished, and the pitch of the vocal tone raised accordingly. In the production of the falsetto tones the slit extends the whole length of the cords (Fig. 37, p. 60), but the vibrations are limited to the free margin of the membranous portion.

In the production of the chest tones the same arrangement prevails as in the falsetto, but the cords vibrate their entire breadth. In either register elevation of pitch is produced by progressive shortening of the free space, front and back, by muscular action of the two thyro-arytenoids, the mechanism of which is still undetermined.

LARYNGOSTROBOSCOPY.—The actual vibrations of the vocal cords during the production of sounds have been studied optically by Dr. Oertel, of Munich, by means of what he has termed laryngostroboscopy.¹

The light employed must be of the most powerful character, by preference direct sunlight, or the electric or oxyhydrogen light. The interruptions in the perception of the vibrations are produced by a perforated diaphragm revolving rapidly, and at a rate proportioned to the rapidity of the vibrations of the sounding cord. The perforated card through which the observation is made may be vibrated by a tuning-fork; and if this method is employed, the note of the fork should be the same as that produced by the vocal cord under observation, or an octave from it. The interrupting apparatus must be placed between the light and the laryngoscopic mirror, or between the light and the observer; the latter position being convenient for the revolving diaphragm when a little practice in its use has been obtained; and the diaphragm can be rotated by hand at the rate requisite for observing the vibrations at a given note. According to Oertel, he has demonstrated with this instrument, that when a chest note is uttered, the vibrations of the vocal cord may be seen separated into the movements of which they are made up, the vocal cords vibrating as a whole. When, however, a falsetto note is uttered, the vocal cords are seen to vibrate in sections, two or more, according to the pitch of the note; the sections being divided by nodal points.

This is in accordance with the known physical laws of vibrating strings and tense bands, and would show that the apparent formation of falsetto tones, as described in the text above, in accordance with the results of ordinary inspection, must be deceptive.

THE LARYNGEAL MUSCLES.—It may be as well here to allude to the muscles by which the movable portions of the laryngeal structures are controlled, and to whose contractions are due the various alterations of form observed during respiration and vocalization.

In the first place there are several muscles outside of the laryngeal tube.

¹ Centralblatt f. med. Wiss. 1878, 5 and 6; The Lancet, April 27, 1878, p. 617.

1. *Crico-arytenoideus posticus*, one on each side, occupies the lateral half of the posterior face of the cricoid cartilage, and runs upward and outward to be inserted into the exterior and posterior part of the arytenoid cartilage of that side. *Use*, to rotate the arytenoid cartilage outward and backward, and open or dilate the orifice of the glottis. This muscle may be regarded as the dilator muscle of the respiratory glottis, opening the intercartilaginous rima, antagonizing the arytenoideus.

2. *Crico-arytenoideus lateralis*, one on each side, runs from along the superior margin of the sides of the cricoid cartilage obliquely upward and backward to the outer angle of the base of the arytenoid cartilage, just in front of the insertion of the posterior crico-arytenoid muscle. *Use*, to draw the arytenoid forwards and outwards, turning the posterior vocal processes inwards, and thus contracting the chink of the glottis in vocalization.

3. *Crico-thyroideus*, one on each side, a triangular muscle running from the anterior lateral surface of the cricoid cartilage upward and backward to the inferior edge of the thyroid plate, and into its inferior horn, leaving an interval between itself and fellow occupied by that portion of the vocal membrane called middle crico-thyroid ligament. *Use*, to draw the cricoid cartilage upon the thyroid cartilage with a forward rotary motion, thus carrying the arytenoid cartilages backwards and stretching the vocal cords antero-posteriorly, rendering them tense and contracting the chink of the glottis.

4. *Arytenoideus*, a single muscle, sometimes described as three distinct muscles. A transverse portion, the deepest, goes posteriorly from the whole length of one arytenoid to the other, covering them completely except at the very tip; over this portion two oblique portions cross each other, running respectively from the base of one arytenoid to the apex of the other. Sometimes portions of this muscle are continuous with the thyro-arytenoideus and the aryteno-epiglottideus, one or both, seeming to act in consonance with them in closing the larynx. In fact, there seems to be a guttural communication, right over this muscle, with the posterior portion of the ary-epiglottic fold, leading from the ventricle of Morgagni up the inner posterior wall of the larynx and out into the pharynx behind. This gutter or drain is the *filtrum ventriculi* of Merkel, and seems intended to lead off into the pharynx any accumulating secretion from the laryngeal pouch. *Use*, to bring the two arytenoid cartilages in close apposition, which it does very completely by means of its transverse and oblique fibres, so that the plane surfaces of the posterior vocal processes touch each other, and thus close the posterior portion of the glottis. This muscle may be viewed as the contractor of the respiratory glottis.

The interior of the larynx contains several muscular structures enclosed within the quadrangular membrane. These are on each side:

1. *Thyro-epiglottideus*, the depressor of the epiglottis, a delicate muscle running from the posterior inner face of the thyroid near its reentrant angle, just outside of the thyro-arytenoid, into the side of the epiglottis. *Use*.—To pull the epiglottis down. This it can do ordinarily only when the tongue is relaxed, and, for this reason, the dropping of the epiglottis is usually attributed to backward pressure from the base of the tongue relaxing the middle glosso-epiglottic ligament; but it has been shown by the laryngoscope that some persons can acquire such control over their organs as to drop the epiglottis with the tongue extended;

and this would seem to confirm the ascribed use of this muscle as a true depressor.

2. *Aryteno-epiglottideus*, a still more delicate muscle, running from the superior lateral portion of the arytenoid into the side of the epiglottis, some of its fibres being lost in the ary-epiglottic fold. This muscle is indistinctly defined horizontally into what is sometimes described as a superior and an inferior muscle, the inferior portion of which (compressor sacculi laryngis, *Hilton*) compresses the laryngeal pouch and squeezes its secretion out upon the vocal cords. The superior portion will constrict the upper portion of the quadrangular membrane, and, with the thyro-epiglottic muscle, assist to close the superior laryngeal aperture.

3. *The Vocal Muscle*.—There is still another intrinsic laryngeal muscle on each side meriting a more detailed mention than that of its mere origin and insertion. This is the *thyro-arytenoideus*, lying external to the vocal cord and inseparably attached to it, for which reason some anatomists have regarded the vocal cord as but the tendon of this muscle. It is most usually described as parallel to the outer side of the cord, arising from the lower half of the reentrant angle of the thyroid cartilage and from the middle crico-thyroid ligament, and passing backward and outward to be inserted into the anterior and outer face of the arytenoid cartilage and into its base; its use being to relax the vocal cords and shorten them, thus lessening the length of the chink of the glottis.

The thyro-arytenoid muscle, however, is quite complex in the arrangement of its fibres, and is evidently the chief muscle of modulated phonation, to whose contractions are mainly due the various changes of forms produced in the glottis during speaking, singing, crying, shouting, etc. It has been very thoroughly described by Bataille, who has dissected it minutely, as consisting of three distinct portions, whence he has proposed for it the name *triceps laryngea*.

These three portions are called by Bataille: 1, *faisceau plan*; 2, *faisceau médian ou arciforme*; and 3. *faisceau paraboloid*.

The three heads arise in close propinquity from the reentrant angle of the thyroid. *The first or plain bundle* runs back with long, flat, horizontal fibres, to be inserted into the inferior border of the arytenoid cartilage. *The second or middle portion* forms a triangular pyramid, separable into two flat triangles, the base being inserted into the concave face of the arytenoid cartilage, its internal surface being adherent nearly throughout to the first or flat bundle; and near its arytenoidal attachment it anastomoses again with this flat bundle by short pennate fibres. Its superior surface is concave, and forms the floor of the ventricle. *The third bundle* assumes the form of an irregular parabola, with fibres divisible into superior, middle, and inferior layers, and sends out fibres of attachment to the first and second bundles, and also to the internal wall of the ventricle. The upper edge of the first bundle is intimately incorporated into the tissue of the vocal cords by short pennated fibres, and forms a large portion of the constituent structure of the cord, especially of its inferior surface.

The above *résumé* is but an outline of the minute anatomy of this complex muscle, which makes still further attachments to the epiglottis and other adjacent parts; but it is sufficiently descriptive to show its intricate arrangement and intimate relations with the vocal cord, so that it does not seem irrational to infer that it has no slight participation in the function of producing the various changes

of form and tension in the glottis, by means of which two narrow bands of tissue, each scarce eight lines in length, and barely more than a line in breadth, and with but a single margin free to vibrate, are rendered adequate in response to emotion, or mental conception, to execute the immense variety of sound and modulation of which the human voice is capable. There is but little doubt that the careful study of the mechanical construction of this muscle, coupled with a sufficient number of accurate laryngoscopic observations as to the changes of form in the glottis, and consonant action of other parts attendant upon the production of musical tones in the various registers, will in time disclose to physiology many of the secret mysteries of the most distinctive, persuasive, and suggestive characteristic of humanity—the voice.

When the epiglottis is well erected from the laryngeal aperture, as occurs on the emission of a musical note high in the scale, so that the anterior portions of the vocal cords can be discerned, there is often seen below the small end of the pad of the epiglottis, immediately beneath the junction of that cartilage to the thyroid, and separating the anterior attachments of the ventricular bands, a well-marked, sharply-defined, pin-head-like pit or foramen (*fovea centrale* of Merkel) (Figs. 38, 39) in the mucous membrane. This central depression communicates directly on both sides with the anterior entrance into each laryngeal ventricle, being continuous below with a shallow groove formed by a short fold of the laryngeal mucous membrane which stretches across from the anterior end of one vocal cord to the other, forming the anterior vocal commissure, sometimes very distinct in the laryngoscopic image.

This fovea centrale is one of the chief points of insertion for the elastic membrane forming the framework of the interior of the larynx. It is very small in the human subject, but quite large in some of the lower animals, as in the horse, for example, where it seems to constitute a middle ventricle to the larynx.

The anterior and posterior points of insertion of the vocal cords are seen, with good illumination upon them, as four yellowish spots, the *maculae flavae*, which mark the positions of the vocal processes.

The mucous membrane, as it passes from one arytenoid cartilage to the other, is more or less plicated, and is known as the inter-arytenoidal commissure. It is best examined when the arytenoids are widely separated in deep inspirations. As these cartilages are brought in contact, this commissure becomes folded up, as it were, within the vertical cleft or notch, the arytenoid fissure, formerly improperly termed the posterior glottis.

Under unfavorable circumstances the laryngoscopic view is limited to a portion of the base of the tongue, the edge of the epiglottis, more or less of the arytenoid cartilages, and some portions of the posterior wall of the pharynx.

To examine the whole laryngeal face of the epiglottis and the anterior extremities of the vocal cords, the patient is directed to sound a high note quickly and with a little force; an effort which raises the larynx, approximates the cords, and throws the epiglottis up with a jerk, so that the horizontal surface of the vocal cords can be distinctly seen, as well as the ventricular bands and the ventricles. An inspiration accompanied by sound, or an ironical laugh, will bring the same structures in view. If this does not suffice, some of the instruments described for pulling the epiglottis forward may be employed. When a depressed epiglottis prevents a view of the cords, their mobility may be estimated by the movements of the arytenoids, which can almost always be recognized.

Below the vocal cords is seen the inferior portion of the thyroid cartilage (19), reddish in color, usually recognizable by its shape; below this the reddish crico-thyroid membrane (20); below this the broad yellowish cricoid cartilage (21); below this again, the rings of the trachea (22) elevating the mucous membrane, and the dark interspaces (23) between them. (Fig. 28, p. 53.)

To examine the posterior extremities of the vocal cords, the anterior surfaces of the arytenoid cartilages, the inter-arytenoid commissure, and the inner posterior wall below, the light must be reflected more posteriorly by inclining the mirror towards the horizon during an inspiration. The inspiration opens the glottis and separates the arytenoids, which look upward, backward, and outward, exposing their anterior faces.

To examine the posterior or pharyngeal surface of the arytenoid cartilages down to the cricoid, and obtain a good view into the pyramidal sinuses, the voice is sounded, so as to close the glottis; and in so doing the arytenoid cartilages approach each other, exposing their pharyngeal surface, and separating the quadrangular membranes more widely from the plates of the thyroid. (Figs. 37, 39.)

To examine one side particularly, as the external surface of the laryngeal tube, the inner surface of the wing of the thy-

roid cartilage, the ventricle, the whole of the inner surface of the quadrangular membrane, etc., the laryngoscopic mirror may be placed to the opposite side, the head bent back a little more, and the obliquity of the mirror changed so as to illuminate those parts (Fig. 40).

To obtain an extended view farther down the trachea the mirror must be held more perpendicularly, and a deep inspiration be made, so that the glottis may be dilated to its fullest extent; and then, by a little manipulation, reflecting the light more anteriorly, the image of several tracheal rings comes in view as a series of narrow bands, colored like the conjunctival membrane of the eyelid, arching across with their concavities downward, and becoming narrower and closer as they are more distant, until the foreshortening is such that they cannot be distinctly counted. Sometimes in this way, when the circumstances are favorable, with a good mirror, a steady hand, a well-directed light, a straight tracheal axis, and a wide glottis, a view can be obtained clear down to the bifurcation of the tube. Sometimes, when we fail to obtain such an extended view with the light, patient, eye, and mirror in the ordinary position, we can succeed by elevating the position of the patient so that the eye of the observer shall be below the plane of the patient's mouth; then throwing the light from below upon the laryngoscopic mirror, which is to be held horizontally, the light can be reflected clear down the windpipe, and we can see most distinctly the increasing foreshortening of the tracheal rings; and if the bifurcation be visible, we see behind the last ring (below in the mirror), instead of the com-

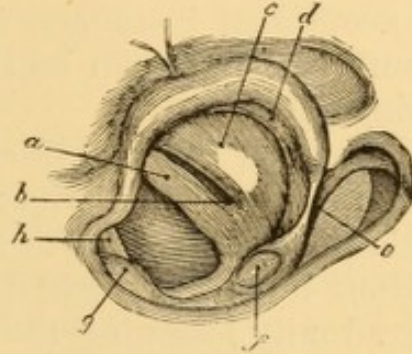


FIG. 40.—View of the left side of the larynx (Tuerck). *a*, left vocal cord; *b*, posterior portion of left ventricle; *c*, left ventricular band; *d*, posterior surface of epiglottis; *e*, free border of left aryteno-epiglottic fold; *f*, left cuneiform cartilage; *g*, right cuneiform cartilage; *h*, right vocal cord.

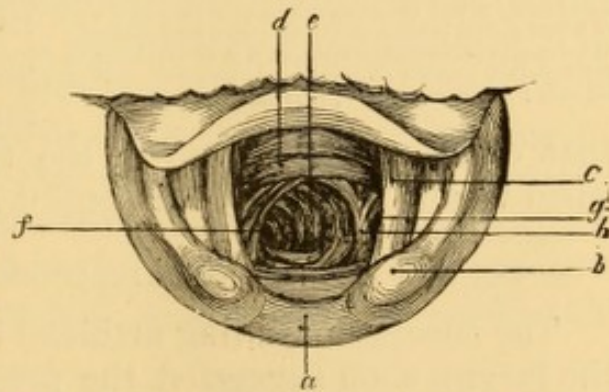


FIG. 41.—View of right bronchus (Tuerck). *a*, inter-arytenoid fold; *b*, left cuneiform cartilage; *c*, left vocal cord; *d*, lower rings of trachea; *e*, all six rings of right bronchus; *f*, inferior wall of right bronchus; *g*, cavity of left bronchus; *h*, bifurcation (septum of bronchi).

plete arch with its concavity downwards, a bright triangular ridge, which often seems to project up into the cavity of the tube; and on either side of this triangular space are seen dark circular discs marking the commencement of the bronchi. In exceptional instances, if the right bronchus is very straight, sufficient light can be thrown in to demonstrate several of its rings (Fig. 41).

A good rule by which to hunt for the image of the bifurcation is, to get a distinct view of the laryngeal face of the epiglottis, and then, with this as a guide, to continue inspection along this plane, right down the anterior surface of the trachea, gradually lessening the obliquity of the mirror as the deeper parts come into sight.

If, when a view of the image of the trachea has been obtained, the mirror is turned a little to one side, a lateral view

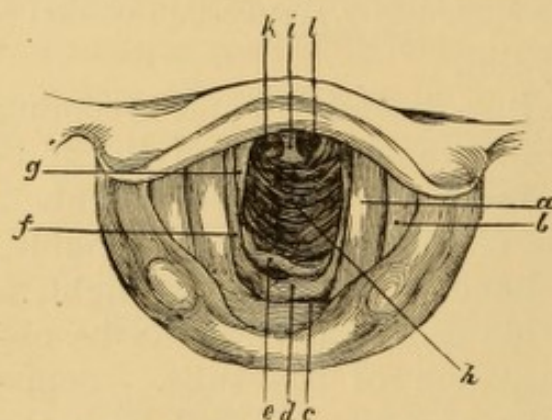


FIG. 42.—View of posterior wall of trachea, and bifurcation of the primitive bronchi (Tuerek). *a*, left vocal cord; *b*, left ventricular band; *c*, posterior wall of supra-glottic portion of larynx; *d*, *e*, posterior wall of infra-glottic portion of larynx; *f*, *g*, lateral walls of infra-glottic portion of larynx; *h*, posterior wall of trachea; *i*, bifurcation; *k*, *l*, primitive bronchi.

of that tube is obtained resembling in appearance the turns of the thread in the nut of a screw.

To obtain a view of the posterior wall of the interior of the larynx and trachea, the patient's head is kept in the middle line, the mirror is held horizontally and the light thrown on it from below. The rings of the trachea being deficient posteriorly the appearance is quite different from

that of the anterior wall of the trachea, and its bifurcation when visible has a different aspect likewise (Fig. 42).

ŒSOPHAGOSCOPY.

The success attending artificial inspection of the interior of the larynx soon suggested the practicability of examining the interior of the œsophagus in a similar manner. Such attempts have been made by Lewin of Berlin, Semeleder of Vienna, Voltolini of Breslau, Waldenberg,¹ Bevan,² and others, but with only partial success.

¹ Berlin. klin. Woch., 1870, vii. 48; *ibid.*, 1871, 44; Schmidt's Jahrb., cxlix., p. 214.

² The Lancet, April 11, 1868, p. 470, illustrated.

Great anatomical obstacles complicate the performance of œsophagoscopy. The larynx and trachea, being cartilaginous in structure, are open tubes. The œsophagus, on the contrary, is a flaccid tube, opened only when an object is presented for entrance; so that it becomes necessary to keep its walls asunder by some mechanical appliance in order to illuminate its interior. The manipulation is difficult and painful. The best description of this manipulation is still that of Semeleder,¹ who has not only practised it upon patients, but has also made a series of instructive experiments upon himself in the presence of distinguished laryngoscopists, for the purpose of demonstrating the value of the operation and studying it thoroughly. It is said to be perfectly feasible, after more or less effort, to explore an inch or two of the œsophagus; and one or two cases are on record in which, examination being made after inserting a stomach-tube of proper dimensions, light was thrown down its entire extent, so as to reveal the condition at the cardiac orifice of the stomach. I have had no experience in œsophagoscopy, and believe that it has been practically abandoned.

PHARYNGEAL RHINOSCOPY; RETRONASAL RHINOSCOPY; POSTERIOR RHINOSCOPY.

Rhinoscopy is the term adopted by Czermak to designate his method of inspecting the posterior region of the nares, and parts immediately adjacent, by reflected light. It suggested itself at an early date to this observer as an outgrowth of laryngoscopy, and he described² it shortly after his name had become familiarly associated with the sister art. Inasmuch as direct inspection of the nostrils anteriorly is also rhinoscopy, it would be as well to call the pharyngeal method posterior rhinoscopy. It includes inspection of the roof of the pharynx, its supra-palatine walls and their contents, and the posterior surface of the soft palate, as well as the posterior portions of the nares.

The laryngoscopic apparatus suffices for pharyngeal rhinoscopy. The principles involved are precisely the same as in laryngoscopy; the chief difference of manipulation being in

¹ Rhinoscopy and Laryngoscopy; Caswell's translation. New York, 1866, p. 97.

² Ueber die Inspektion des Cavum pharyngo-nasale und den Nasenhöhle vermittelst kleiner Spiegel. *Wien. med. Woch.*, Aug. 6, 1859.

the position of the mouth mirror, which is to be placed beneath the soft palate and uvula, or behind them, with its reflecting surface looking upwards and forwards, so as to direct the light upon the posterior openings of the nasal passages and upon the parts in immediate proximity. The image of these parts is then seen in the mirror. The pharynx is to be most strongly illuminated at a point a little lower than that usually selected for laryngoscopic observation.

The primary anatomical requisite to a successful examination is the existence of sufficient space for the mirror between the velum and the posterior wall of the pharynx. When the hard palate extends unusually far back, it may be impossible to make an examination with the mirror, as has happened in one case under my own care. Such cases, however, are altogether exceptional. Vicious adhesions of tongue to palate, and of palate to pharynx may render the examination impracticable if the orifice is of too small dimensions to permit the passage of a very small mirror through it. As a rule, an examination is almost always practicable, though seldom with the facility that attends laryngoscopic examination.

It is essential for the introduction of the mirror, that the soft palate should hang free from the posterior wall of the pharynx. When the mouth is opened for purposes of examination, there is usually an involuntary disposition to breathe through it. This causes the palate to become applied against the posterior wall of the pharynx, and thus shut off direct communication between the mouth and the nares. If the breathing be performed through the nose, the palate drops, and the communication between nose and mouth is then free, as in ordinary respiration with the mouth closed. Hence, avail is taken of this important physiological fact, and the patient is instructed to breathe through his nostrils while his mouth is open. This response of the palate to respiration through mouth or nose, and its play backwards and forwards, can be readily observed in a looking-glass. If the patient cannot succeed in maintaining respiration through the nose, the palate may be forced to fall forward by causing him to emit nasal sounds, such as the French *en*; and, as the respiratory current passes by the nostrils, the palate falls. This plan was suggested by Czermak. Forcible separation of the palate from the pharyngeal wall by means of a broad and flat hook passed under and

behind the velum, and then drawn forwards and upwards by the observer, was at one time extensively employed (Fig. 4, p. 12), but is often only partially successful, inasmuch as it usually induces spasmodic action of the muscles of the palate, the disposition to which spasm is to be overcome only by repeated contact of the instrument until its presence and pressure is tolerated, or until the irritability of the muscles is exhausted. The same amount of time and patience devoted to the proper regulation of the respiration will insure the success of the latter and more desirable expedient. The use of the palate hook or any similar contrivance, has been so rarely requisite in my own practice, that series of years have passed in succession without any necessity presenting for resort to an appliance of the kind.

The difficulties to be overcome in rhinoscopic examination are, with the exception of those of respiration just mentioned, the same as those described under the head of laryngoscopy.

The same mouth mirror may be used for rhinoscopic as for laryngoscopic examinations, but there is more frequent occasion for the employment of a mirror of smaller diameter. There is no necessity for using the mirror attached to its stem at a right angle, as recommended by some authors, nor is such a mirror as conveniently manipulated in my own hands as the ordinary laryngoscopic mirror. If a vertical position of the reflecting surface is desired, it may be obtained very readily by depressing the handle of the mirror. If, on the other hand, it be desired to gain a view of the roof of the nares, or of the vault of the pharynx, the handle can be raised so as to give the mirror a more oblique position. A reflection of the parts, exact as to size and form, such as we obtain of our faces in a toilet mirror, could be obtained only in the absence of necessary structures which prevent our seeing the reflection when the mirror is exactly behind the nares in a vertical plane. It is only an image in perspective of the parts in front of the mirror and above it that can be seen at best, and this we secure with the laryngoscopic mirror in rhinoscopic position much more readily than with the so-called rhinoscopic mirror. There is an advantage however, in many cases, in bending the stem of the mirror somewhat in the form of an italic *S* (Fig. 43), which allows it to be manipulated without getting the hand in the way. For this reason a flexible stem is desirable for the rhi-

noscopy mirror, though not for the laryngoscopic one. If a special mirror is used for rhinoscopy, the handle need not be

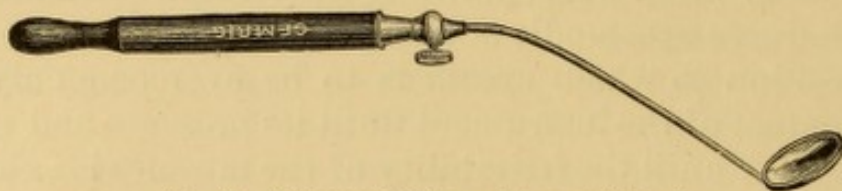


FIG. 43.—Rhinoscopic Mirror, with curved shank.

as long as that of the laryngoscopic mirror, by more than an inch.

In the earlier days of rhinoscopy, it was thought essential to employ some means of drawing the palate upwards and forwards; and various palate-hooks and elevators have been devised for the purpose, some of them combining either tongue depressor or mirror in the same complex instrument, and some of them tongue depressor, mirror, and uvula elevator. Tuerck used a thread noose cast round the uvula by means of a canula. Mr. Alexander Hodgkinson, of Manchester, has devised a very ingenious appliance for noosing the uvula.¹ This want was probably occasioned by the use of the mirror at right angles to its shank. When such a contrivance is requisite, which occurs only occasionally, a flat plate of metal or hard rubber, three or four lines in breadth, terminating in an edge turned up for about one or two lines, and fenestrated or not, according to fancy, will be found serviceable. When the space between velum and pharynx is small, it may sometimes be enlarged by repeatedly drawing the velum forward by means of a blunt hook, these manipulations being repeated at intervals for several days. The space may also be more fully exposed by confining the palate in two soft silk tapes passed through the nostrils, out of the mouth, and tied over the upper lip in front.² A sort of double T-bandage with four tails answers this purpose, and may sometimes be employed in this way for purposes of more thorough examination, or for facilitating operative procedures. These contrivances are not well borne.

The use of a tongue-depressor is almost always necessary in a rhinoscopic examination. It separates the tongue further

¹ Brit. Med. Jour., June 23, 1877, p. 771, illustrated.

² For methods of manipulation, see tamponing the nares, in article on epistaxis.

from the palate, and thus gives additional room for the passage of the mirror. If the tongue-depressor is not used, the stem of the mirror is usually supported on the tongue, so as to keep it from rising, but the image in the mirror is then much more in perspective and much less satisfactory than when the tongue-depressor is used.

When a large mirror cannot be used—and cases are not infrequently met with that permit the use of a mirror an inch and a quarter in diameter—small mirrors are passed, first upon one side and then upon the other, so as to examine the structures of each side successively.

Voltolini describes a method of rhinoscopy with two mirrors:¹ "The mirror first introduced must have a larger handle than the usual one, and be capable of being bent as desirable. A slight curve is given to it at the part next the handle, so that it passes over the tongue easily; and at the part which reaches the posterior pharyngeal wall it is bent at a right angle. The mirror at the end is passed upward to the basis cranii, and so placed opposite the posterior nasal orifices. The second mirror is the usual laryngoscopic mirror, the back of which is pressed against the handle of the other where it first ascends into the pharyngeal space. Light is thrown upon the shorter mirror, which reflects it to the longer one, which again reflects it to the spot to be examined, an image of which is returned the same way." I have never tested this manœuvre. My hands are usually so full with tongue-depressor and one rhinoscopic mirror, that I doubt if I could manipulate two mirrors in the retro-nasal pharyngeal space, even if the patient or an assistant held the tongue down.

Instruments combining tongue-depressor and mirror have been invented by Stoerck, Duplay, and others; but they appear to me altogether superfluous, inasmuch as the management of the tongue can be entrusted to the patient, thus affording the operator a chance to employ with his disengaged hand whatever other instrument may be necessary for treatment.

The impediments to pharyngeal rhinoscopy are similar to some of those discussed in the article on Laryngoscopy.

The accessory illuminating apparatus is the same as for laryngoscopy.

The Structures subjected to Rhinoscopic Inspection are: The posterior surface of the soft palate and the uvula; the posterior and part of the lateral portions of the septum of the

¹ *Monatsschrift für Ohrenheilkunde*, Aug., 1876. *London Medical Record*, Dec. 15, 1876, p. 558.

nose, the turbinated bones, and the nasal meatuses; the pharyngeal walls of the Eustachian tube and its orifice; the vault or roof of the pharynx; the lateral walls of the pharynx; and the upper portion of the posterior wall of the pharynx.

These structures cannot all be examined in one and the same image; but by gently turning the reflecting surface of the mirror toward the different regions a satisfactory survey of the whole in detail can be gradually completed. In some cases, where a large mirror can be used, both posterior nasal outlets, both Eustachian orifices, and the greater portion of the vault of the pharynx can be seen in one and the same image (Fig. 44); and in some instances much more of the surfaces of the turbinated bones can be exposed to inspection than is represented in the illustration.

It is essential to become familiarized with the appearances represented in the rhinoscopic mirror in order to be able to recognize the individual structures; not only because these parts are rarely submitted to dissection, but also because the idea of the relation of parts, as seen in the skull deprived of soft tissue, is not realized in the examination of the living subject.

The Rhinoscopic Image in Detail.—Examining the rhinoscopic image (Fig. 44), we shall find the most prominent object

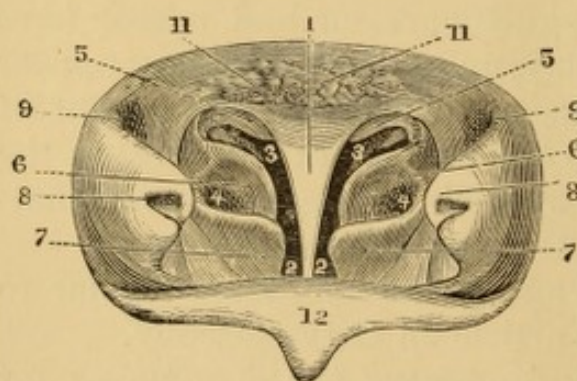


FIG. 44.—Rhinoscopic image. 1, vomer or nasal septum. 2, free space of nasal passages. 3, superior meatus. 4, middle meatus. 5, superior turbinated bone. 6, middle turbinated bone. 7, inferior turbinated bone. 8, pharyngeal orifice of Eustachian tube. 9, upper portion of fossa of Rosenmueller. 10, glandular tissue at the anterior portion of the vault of the pharynx. 12, posterior surface of the velum.

to be a bright columnar ridge in the centre, gradually expanding above. This is the nasal septum. It is, in health, of a pale yellow, or yellowish pink color, at its narrow portion, but as it expands, its color gradually merges into the red of the pharyngeal mucous membrane above it. Following the outline of the expanding portion of the septum, we define upon each side the posterior border of

each corresponding nasal outlet; the lowermost portion of which is cut off from view by a horizontally curved projecting ridge of a red color, which, with as much of it as is reflected

below, is the posterior surface of the velum. Following the inner curve of this velum round on either side, we observe it rising over the outer portion of each nasal opening, and forming a projecting ridge which is formed by the fibres of the levator palati muscle forming the anterior wall of the pharyngeal extremity of the Eustachian tube usually situated on a level with the middle meatus, sometimes lower, and occasionally above it; and we find it continuous on the outside with another projection above, which is the cartilaginous extremity of the Eustachian tube; and between these two projections we observe a considerable depression, of triangular or crescentic outline, which is the pharyngeal orifice of the Eustachian tube, sometimes large enough to admit the end of a little finger, and presenting downward and a little forward and inward. Following the protuberance caused by the Eustachian tube backward, we observe it defining a deep groove or indentation, the terminal fossa of which, as it runs upward and outward, is the fossa of Rosenmueller, lying between this lateral projection and the posterior wall of the pharynx. This is a locality in which the Eustachian catheter is very often engaged by mistake during the use of that instrument. During contraction of the elevator muscle of the palate a portion of the orifice of the Eustachian tube is shut off from view. The mucous membrane at the vault of the pharynx is closely adherent to the fibro-cartilaginous investiture of the basilar process of the occipital bone. Returning to the central portion of the image, the parts in shadow on each side of the septum represent the free cavity of the nose on each side respectively. Following this shadow from below upward on either side, we see it terminate in a large shadow, which represents the upper meatus; the light portion above this, still within the choanum, is the upper turbinated bone, of the lower surface of which a small portion is seen projecting still further into the shadow; the outer portion of the upper turbinated bone turns down and seems to be lost in a central bulbous portion which is the middle turbinated bone; this is partly covered by another prominent object, which is the inferior turbinated bone; and above this and to the outside is a shadow representing what is seen of the middle meatus. Occasionally, but not in the image figured, we can discern the position of the inferior meatus just beneath the lower turbinated bone, only a portion

of which is seen in the drawing; and likewise the upper part of the posterior surface of the soft palate.

At the top of the image, above and behind the expanded portion of the septum, we observe a mass of glandular tissue extending toward each Eustachian outlet. This is the adenoid tissue of the vault of the pharynx, or the pharyngeal tonsil. It is of a deep red color, irregular in outline, and often the seat of disease.

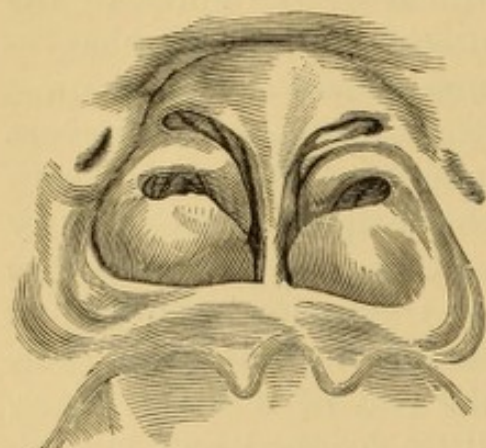

FIG. 45.—Rhinoscopic image in a case of cleft palate. (Drawn by Dr. Packard, of Philadelphia.)

of these structures is occasionally encountered without the pre-existence of any defect in the palate. In the instance referred to, the fissure enabled the mirror to be placed higher up than

can ordinarily be done, and thus secured a better view of the middle and lower turbinated bones, and upper part of the palate. Fig. 47 represents a rhinoscopic image from one of my patients, in which an unusually good view of the pharyngeal orifice of the left Eustachian tube was obtained by slightly rotating the face of the mirror toward that side.

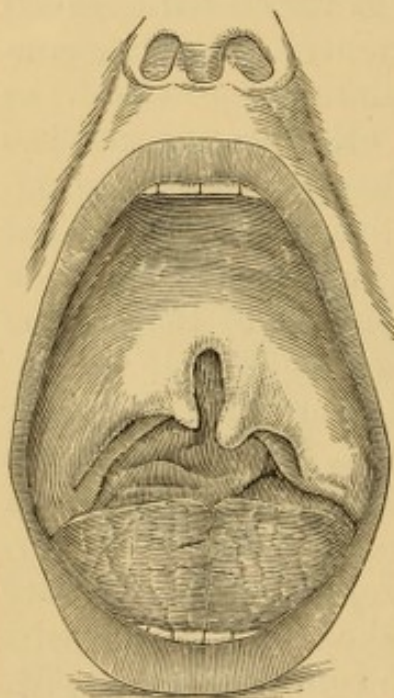


FIG. 46.—Case of cleft palate from which rhinoscopic image (Fig. 45) was obtained. (Drawn by Dr. Packard, of Philadelphia.)

The color of the healthy mucous membrane of the nasal and nasopharyngeal structures, as seen in the rhinoscopic image, varies from a pale grayish-red or yellow, with a mere tinge of pink, to a

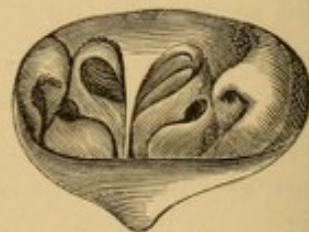

FIG. 47.—View of left Eustachian orifice.

drab, or the more decided red of the pharyngeal mucous membrane. The narrow column of the septum, and the inner or lower walls of the Eustachian orifice, are of a pale pink-

yellow, sometimes decidedly yellow; the projections of the Eustachian tube are red; the superior turbinated bone is a light pink; but any of its lower or lateral surface that may be seen is dark gray; the middle turbinated bone looks gray and is very distinct; the lower turbinated bone is usually still darker and often less distinct; the sides of the septum, when not diseased, are drab or ashy-red; the other structures are red, the reflection of the velum at the Eustachian tube being of a lighter red below than above. The precise tint of each structure varies with the character of the light, its position influencing the shadows; and also with the position of the patient. This description corresponds as near as may be to the tints given by artificial light.

In gaining a view of the posterior nares, the first reflection seen in the mirror as it is passed under the velum is usually the image of the posterior aspect of the uvula, velum, and palatine folds; presenting together, especially when the parts are tense, much the general appearance of the outline of the image of the septum and nasal openings, especially should one of the molar teeth be reflected just to the side of the uvula. When this image of the velum and its folds is seen, the handle of the mirror should be gradually depressed, or its reflecting surface be slipped up further behind the velum, when the latter will be seen gradually extending as it were, and then turning on itself backward at a right angle, looking not unlike a shelf of flesh, on top of which, and somewhat in its rear, we begin to recognize the true image of the septum and nares making its appearance in the mirror.

Anterior Inspection by Mirrors has also been applied to examination of the nasal passages anteriorly, but the amount of reflecting surface is so small that the results can hardly be deemed satisfactory; and in my own hands they have been much inferior to those of direct inspection, as already detailed.

Posterior Rhinoscopy by Mirror passed through the Nasal Passage.—Dr. Rumbold, of St. Louis, has taken occasion, in a patient with a very large nasal passage, and in patients who had lost the septum of the nose, to pass a small mirror through the nostril to the top of the pharynx, so as to study the action of the palate in deglutition, respiration, and phonation.¹ With a calcium light directed

¹ St. Louis Medical and Surgical Journal, Dec., 1876, illustrated.

through the nostril he has been able to inspect the posterior surface of the soft palate and uvula in their entire extent, the base of the tongue, the epiglottis, and the contents of the larynx.

Auto-Rhinoscopy, inspection of one's own posterior nares, is effected in a manner similar to that of auto-laryngoscopy, with the necessary modifications of illumination and position of mirror. It is much more difficult of satisfactory execution.

Demonstro-Rhinoscopy.—The reader is referred to the remarks on demonstro-laryngoscopy, which are applicable, though in a more limited degree, to the demonstration of the rhinoscopic image to bystanders.

PALPATION.

Exploration with the finger and with probes is employed for the purpose of testing the density of structures, determining their extent, form, and so on. It should always be preceded by as thorough inspection as practicable. The nail of the exploring finger should not be long enough to scratch the parts or irritate them unnecessarily. Palpation of the visible portions of the palate, tonsils, and pharynx requires no special description. With a docile adult it is usually effected without difficulty. With children, and adults who cannot be trusted to yield to the manipulation, the jaws must be kept apart by a knife-handle, bit of wood, or something of the kind placed between the back teeth; and the metacarpal phalanx of the exploring finger be protected by a metallic shield ring, or by a few turns of a handkerchief or towel, otherwise it may be severely bitten. In palpation of the tonsils or the lateral parts of the throat, it is well to place one or two fingers of the unengaged hand externally as a counter-support.

The retro-nasal portion of the pharynx, the superior or pharyngeal surface of the soft palate, the posterior outlets of the nasal passages, the pharyngeal orifices of the Eustachian tubes, and the vault of the pharynx, can all be more or less satisfactorily explored with the forefinger. The patient being seated or standing, as is most convenient, the surgeon stands to one side, and carries his forefinger into the mouth, palmar surface upward, until it reaches the soft palate, behind which it is carefully insinuated, and then passed in the various directions

necessary for the purposes required: The exploration with the finger should not be too prolonged at one time, as it is very disagreeable, and liable to induce retching and vomiting. Several introductions may be necessary to complete the examination.

The epiglottis is readily reached by running the palmar surface of the finger along the tongue; and then by gliding it over the epiglottis in such manner as to press that structure forward against the root of the tongue, the finger can be inserted a certain distance into the upper portion of the cavity of the larynx. The aryteno-epiglottic folds and the supra-arytenoid cartilages are reached in a similar manner. The pharyngo-laryngeal sinuses are reached by carrying the finger to one side, and keeping it between the larynx on the inner side and the lateral pharyngeal wall on the outer side. Passing the finger around posteriorly, it comes in contact with the external surface of the arytenoid cartilages and the cricoid cartilage. All these manœuvres require to be executed with promptness and discretion, and to be suspended immediately upon the occurrence of direct or reflex movements of spasm or threatening emesis. If the tongue interfere with the examination, it may be kept down with the middle finger, while the exploration is made with the forefinger.

Parts beyond the reach of the finger may be explored by means of the dentist's extension finger, or by blunt-pointed probes or sounds, suitably bent and held delicately though firmly between the fingers, so that the impressions imparted to them shall be accurately appreciated, without any slipping of the instrument. Delicate manipulations of this kind should be performed under guidance of sight, as far as practicable; and under guidance of the mirror, upon those structures usually subjected to indirect inspection by reflection. The mirror being held in one hand, and the part to be sounded or probed being brought under good illumination, the curved probe is taken in the other hand and carried directly to the reflecting surface of the mirror, so that the image of its terminal extremity becomes visible; and then, without losing sight of the image of the part to be touched, the instrument is to be carried toward it. This manipulation requires some practice, and a good plan of learning how to follow the reflex in the mirror is to hold a mirror over some complex object, and then try

to reach given points upon it, guided solely by the reflection. A little practice soon enables one to execute the necessary movements with his instrument, and carry it forward or backward, upward or downward, or to one side, as the case may require.

External palpation of the sides of the throat and of the larynx does not require special description. The larynx may be seized between the thumb and fingers applied to the two sides of the thyroid cartilage, and moved from side to side, up and down. The normal crepitation produced on rubbing the larynx against the posterior wall of the pharynx must not be mistaken for a pathological manifestation. The finger, placed upon the crico-thyroid membrane, feels the vibrations communicated to it by the voice. These vibrations are less distinctly felt over other parts of the larynx, and over the trachea.

Palpation of the trachea and thyroid gland does not require special description.

Palpation of the nasal passages is practised by oiling the little finger and insinuating it into the nostrils. In this way the position of ulcers, tumors, foreign bodies, and concretions can sometimes be determined, even when they elude detection by anterior inspection with the speculum, or posterior inspection with the rhinoscope. The size, consistence, extent, and mode of attachment of extraneous or morbid objects within the nasal passages can often be correctly estimated by the judicious use of small rigid or flexible probes, wire loops, and the like, introduced under sight through the speculum, or without its aid, as circumstances may dictate.

AUSCULTATION.

The character of the patient's voice is often an indication of value in determining the existence of paralysis, tumefaction, foreign or morbid bodies, occlusion of the nasal passages, and the like. The respiratory sounds, too, indicate obstruction of breathing; and the character of stridor, whether inspiratory, expiratory, or present in both phases, enables us to judge of the character of certain obstructions. Auscultation of the larynx and trachea through a stethoscope placed upon different portions is also of value in determining the location of foreign bodies or morbid products, and estimating their mobility.

Auscultation of the Pharynx and Œsophagus.—Dr. W. Hamberger, of Gabel, Bohemia, has called prominent attention to the value of ausculting¹ the Œsophagus in affections of the pharynx and Œsophagus, especially in locating the position and direction of pathological processes. Auscultation of the Œsophagus is performed by listening to the sound produced by the deglutition of fluid as manifested in the cervical and thoracic region. In ausculting the cervical portion of the Œsophagus, the stethoscope is employed; in ausculting the thoracic portion the ear alone is preferable. If the stethoscope is placed on the neck of a normal subject at the level of the hyoid bone, at the moment of swallowing a mouthful of water, a marked metallic gurgling is heard in the pharynx, due to the commingling of air with the swallowed fluid, the sensation being as though something had been driven through the stethoscope toward the ear of the auscultor. Ausculting the Œsophagus from the level of the cricoid cartilage to that of the eighth rib, a peculiar sound is heard in swallowing, indicative of the rapid and noisy passage of a small, firm, spindle-shaped body compressed by the circular fibres of the muscles of the organ. It may be a smooth, gliding sound, or a loud clucking rendering the entire character of the act indistinct. The ear should be placed on the posterior part of the thorax, just to the left of the vertebral column. The Œsophagus may be ausculted from the right side also, but the sound is dull. The points of diagnostic interest to which Hamberger calls special attention are, the form of the liquid bolus, the deglutition sound, the rapidity of deglutition, and the direction taken by the bolus. These points having been studied in the normal Œsophagus, modifications can be recognized in diseased conditions. Thus, in cases of stricture, obstruction from impaction or any other cause, paralysis, organic dilatation, and so on, the deglutition sound remains distinct as far as a certain point, and cannot be detected below it. The adventitious sounds that occur are described by Hamberger as frictions,

¹ *Wien med. Jahrb.*, 1868, xvi., p. 123; *Medizin. Jahrb.*, 1868, xv., H. 11; *Gaz. hebdom.*, 1868, 50, p. 793; *La France méd.*, 1868, p. 748; *Dublin Qr. Med. Jour.*, May, 1869, p. 423; and *Klinik der Œsophaguskrankheiten mit diagnostischer Verwerthung der Auscultation dieses Organs*, Erlangen, 1872. See also my translations of Von Oppolzer's *Lectures on Diseases of the Œsophagus*, part 1, *Phila. Med. Times*, vol. iii., 1873.

hissing or rustling, spattering, etc., indicative of abnormal slowness of deglutition or of alteration in the shape of the bolus on account of the impediment to its passage. A deviation in the direction of the bolus may be indicative of mechanical displacement of the œsophagus from exostoses of the vertebræ, aneurism of the aorta, or intra-thoracic tumor.¹

PERCUSSION.

In cases of doubt as to the occlusion of the nasal passages, Wintrich has suggested an indirect method of physical diagnosis. The tympanitic sound yielded on percussion of the larynx lowers in pitch when one nostril is closed, and becomes still deeper and weaker in tone when both nostrils are closed. If, now, it is found that no change is effected on the percussion pitch of the larynx by closing one or the other nostril, or both of them, it is inferred that their permeability is occluded by the presence of secretion, tumor, or foreign body in one or the other nostril, or both, as the case may be.

¹ See, also, Morell-Mackenzie, *The Lancet*, May 30, 1874, illustrated; Elsberg, *Trans. Am. Med. Assn.*, 1875, illustrated.

CHAPTER III.

SORE THROAT.

THE acute inflammatory affections of the throat will be discussed under the general head of Sore Throat, differentiating those which evince special characteristics. This is done because it is very rarely that inflammatory action is confined to any one of the anatomical regions of the throat. When the palate is inflamed, for instance, the tonsils and the pharynx may be inflamed also; when the pharynx is inflamed, the palate and tonsils may be inflamed; and when the tonsils are the chief seat of the inflammation, we often find the palate and pharynx involved in the process. There are, however, certain territorial regions which, in consequence of participation in the same vascular, lymphatic, or nervous distribution, are apt to become sore or inflamed together. Thus, the anterior surface of the palate and uvula, the anterior folds of the palate, the tonsils, and sometimes the base of the tongue form one region; the posterior palatine folds, posterior surface of the palate, upper portion and vault of the pharynx, and posterior portions of the nasal fossæ form another; the pharynx, circumvallate papillæ of the tongue, epiglottis, lingual sinuses, and upper portion of the larynx form a third. Hence, therefore, the numerous and often too vague regional *cynanches* and *anginas* by which the different varieties of sore throat have long been designated, do not present those definite ideas which should characterize scientific appellations; and the term sore throat is retained in preference until a better one can be substituted.

The principal structures involved in ordinary sore throat are the base of the tongue, the uvula, soft palate, palatine folds, tonsils, and pharynx. Sometimes the larynx and trachea, and the nares and retronasal cavity are likewise affected.

Sore throat may be acute or chronic; superficial or deep-seated; idiopathic or deuteropathic; toxic or traumatic. There

is often a diathetic predisposition to sore throat (arthritic, scrofulous).

The ordinary exciting causes of sore throat are: sudden or prolonged exposure to inclemency of weather or change of temperature, *i. e.*, "catching cold" when overheated, or becoming overheated after having been chilled; partial exposures (neck, feet, head) of the same kind; the promiscuous use of hot and cold food and drinks during the same repast; exposure to the inhalation or inspiration of deleterious solid, fluid, and gaseous substances in the atmosphere, which act mechanically or chemically on the mucous membrane; the abuse of certain medicinal agents (mercury, iodine, antimony, zinc, belladonna, stramonium); exposure to the fumes of tobacco smoke; excessive use of the voice; abuse in the use of condiments and rich food; reflex influence from distant organs (genito-urinary, heart, intestinal tract, liver, other viscera). Several of these causes may co-operate.

Deuteropathic or secondary sore throat occurs in extension of inflammations from contiguous parts, as the mouth, tongue, nose, larynx; also, as a rule, in the course of the acute exanthemata, scarlatina especially; occasionally in connection with various acute affections—erysipelas, typhoid fever, pneumonia, rheumatism, herpes, pemphigus, and some others; and in many chronic affections also. The causes of the inflammation in the throat in these cases, when not due to slight exposure, as is only unfrequently the case, are not understood.

ACUTE SORE THROAT.

Common Sore Throat. (Simple Inflammatory Sore Throat, Superficial Sore Throat, Erythematous Sore Throat, Catarrhal Sore Throat, Catarrhal Tonsillitis; Angina Simplex, Angina Catarrhalis, Angina Erythematosa; Pharyngitis Simplex, Pharyngitis Catarrhalis, etc.)

The most frequent variety of acute idiopathic sore throat, as a primary affection, is a simple erythematous inflammation of the mucous membrane of the palate, anteriorly and posteriorly, with which there is associated, in most cases, more or less similar inflammation of the mucous membrane of the tonsils and the pharynx; a palato-pharyngitis, therefore, the mucous membrane of the mouth remaining normal. It is most

frequent in children and adolescents, except in adults of mature age especially subject to attack of sore throat. It is sometimes an extension of inflammatory diseases of the mucous membrane of the mouth (stomatitis, thrush, aphthæ). It also occurs in the advanced stage of several disorders of nutrition, in low states of fever, and in convalescence from acute diseases in consequence of accidental or slight exposure to draught or change of temperature.

The manifestations of the affection are very trifling in mild cases; so much so, at times, as to attract but little attention. The first stage is simply active hyperæmia, and this may subside in a day or two without further progress. In cases of moderate severity the mucous membrane of the palate, tonsils, and pharynx becomes congested, uniformly or in patches, and is often swollen; the submucous tissue of the pharynx being, in some cases, greatly relaxed, so that the mucous membrane lies upon the substructure in thick folds; at other times it is more or less œdematous. Sometimes some of the mucous follicles are enlarged; most frequently those of the palatine folds, especially the posterior pair in contiguity with the tonsils; those of the pharynx being less frequently affected. There is an abnormal secretion of viscid mucus, clear or turbid, as may be, from all these structures, though, as a rule, not excessive in amount. The uvula is often swollen, or distended with serum, and its mucous membrane relaxed, so that it may lie on the base of the tongue, or on the posterior wall of the pharynx, or upon the laryngeal surface of the epiglottis, inducing an irritative tickling cough. Sometimes it appears as though pasted to one of the folds of the palate by the viscid secretion that covers it. In some cases the posterior folds of the palate are likewise distended with serum, so that the two appear like wings of a central portion, the body of the uvula, which no longer presents as a free and pendent structure.

Although more or less of the entire superficies of the throat may participate in the inflammation, the tumefaction is, in some instances, confined to the mucous membrane of the tonsils, and sometimes to one tonsil (catarrhal tonsillitis). The engorgement of the blood-vessels of the tonsil excites—by pressure, probably—a condition of hyperæsthesia of the gland, which renders its entire surface exceedingly tender, and often very painful to the touch, and even to the contact of solid

articles of nourishment in deglutition. If the tonsils are only superficially affected, they may, even when somewhat swollen, appear rather smaller than they really are, in contrast to the swelling of the palatine folds.

Symptoms.—There is usually more or less feeling of heat and dryness in the parts, especially at first, with a moderate amount of dysphagia; the latter principally from the pain in swallowing, but sometimes, in part, from actual debility in the muscles of deglutition. Articulation may be difficult, though there is no hoarseness. Cough is rarely present unless the uvula is elongated. There is usually some febrile movement, with acceleration of pulse and respiration.

If the inflammatory action is at all intense, the local and constitutional symptoms soon increase in severity, the temperature of the skin rising to a marked degree, and the pulse registering, in the adult, from 100 to 120, and in some instances even 140 beats in the minute. With this, there will be pain in the nape of the neck, back, and limbs, sometimes severe, and increased by motion. Other symptoms of nervous origin occur likewise.

This variety is sometimes termed *rheumatic*, because it supersedes the usual premonitory manifestations of acute articular rheumatism, subsiding in a few days, and often terminating before the inflammatory process becomes established in the joints or muscles.

In some cases the cervical glands become swollen and painful, but this is not frequent.

In children the constitutional disturbance is greater than in adults.

Occasionally small-sized shallow erosions are formed at points in the epithelial layer, before retrogression commences, but this is by no means constant. When, as is often the case, but one side of the throat has been prominently affected, there will be great liability to similar involvement of the other side, after convalescence of a day or two; and if the patient is careless in exposing himself, the second attack may exceed the first one in severity.¹ Caution against exposure is, therefore, highly important.

¹ Laveran (Bull. gen. de thérap., June 30, 1876. Lefferts' Reports, N. Y. Med. Jour., Oct., 1876) records the case of a soldier who, having resumed duty after several days' treatment for simple sore throat, was seized next morning with rigor, soon fol-

In victims of malarial poisoning, catarrhal sore throat is not unfrequently periodic.

Diagnosis.—This rests on the points already referred to.

Prognosis.—This is almost always favorable in idiopathic cases. The disease usually completes its stages in from four or five to eight or ten days, with gradual subsidence of the inflammatory process back to the normal condition.

Treatment.—Unless the case is so slight that no special medicinal treatment is advisable, the patient should be confined to a bed or a lounge to secure rest, a light coverlid being thrown over the body to equalize the heat of the surface. This will materially shorten the duration of the case, keep the symptoms in moderation, and restrain the liability to a termination in chronic sore throat; a result, often, of imprudence in exposure or employment during one or more acute attacks. An emetic is often of great service if a meal has been recently taken, something merely to empty the stomach and save the labors of digestion, inasmuch as the diet, throughout the attack, should be as unirritating and as digestible as possible. Mustard in water serves the purpose usually better than depressing emetics, as antimony, or even ipecac, or stimulating emetics, as the sulphates. As gentle a laxative as is judicious for the purpose is indicated to facilitate the passage of matters already in the alimentary canal, and castor oil, magnesia, or rhubarb will often answer the purpose. If the patient is of a costive habit, saline purges may be more appropriate, and a drastic in case of actual constipation. If the pain is great, a small amount of morphia may be added to the aperient with advantage; and, if the pulse is frequent, a small amount of aconite also. The free use of demulcent drinks, and of bits of ice,¹ when cold is agreeable, will soothe the pain in the throat, and perhaps repress excessive secretion; and sponging the entire surface of the body with acidulated or alcoholized tepid water will allay intense heat of the skin.

This, with restriction to a very light and easily digestible

lowed by an attack of suffocation, which proved fatal in a quarter of an hour, before there was time to perform tracheotomy. The autopsy revealed occlusion of the glottis from œdema of the aryteno-epiglottic folds.

¹ The local contact of ice retained in the mouth until it melts will sometimes repress the excessive secretion of mucus; acting apparently on the same principle by which cold arrests cell-growth out of the body.

diet for a day or two, will usually comprise all the treatment required, the disease frequently subsiding within the periods indicated. Indeed, in some instances, the use of the emetic alone, with rest in the recumbent posture, will constitute the entire sum of active therapeutical measures required.

In severe cases, when the pulse is frequent, and the other symptoms persistent, the administration of the tincture of aconite root in doses of one, two, or three drops, at intervals of one, two, or three hours, as may seem most desirable in individual instances, will almost always yield satisfactory results; so much so that its use may be discontinued, or at least be distributed between more lengthened intervals as soon as any marked effect has been produced in lowering the rate of the pulse; for the tendency of the disease is to prompt and spontaneous recovery, as soon as the more violent symptoms exhibit evidence of abatement. Periodic manifestations indicate the use of quinine or arsenic.

Patients who are subject to sore throat should wear silk or woollen underclothing, and avoid continuing in wet garments longer than is absolutely necessary, that is, during the exposure itself only. Local treatment has not been mentioned except incidentally in the recommendation of demulcent drinks, and the use of bits of ice in the mouth. This is because the affection, though local, rarely needs topical treatment.

Appropriate local treatment, when requisite, consists, first, in the use of astringent lozenges allowed to dissolve in the mouth; any astringent usually answering an equally good purpose. If the mucous membrane is much relaxed, the frequent propulsion upon it of sprays¹ of diluted solutions of alum, carbolic acid, and the like (one or two grains to the ounce of water), constricts the parts, and usually relieves their uneasiness in a few hours. Tannin, chlorate of potassium, sulphate of copper, etc., are often used for this purpose. In the absence of a spray apparatus an ordinary syringe can be employed as a substitute, the piston being drawn out while there are only a few drops of fluid in the nozzle of the instrument, and then suddenly forced down so as to drive the fluid from the nozzle in the form of a coarse spray.

¹ A full account of spray-apparatus or nebulizers and their use has been inserted in the author's treatise on Inhalation in the Treatment of Disease. Phila., 1867. 2d ed., 1876.

The local application, around the neck, of compresses wrung out of cold or tepid water, as may be most agreeable to the patient, and changed frequently, is often a source of great comfort.

When the uvula is elongated or œdematous, and irritates the parts with which it comes in contact, it often gives occasion to frequent movements of coughing and of incomplete deglutition. Sometimes it is partially drawn into the œsophagus with the alimentary bolus. This condition of uvula usually supervenes rapidly. It is readily recognized, and almost as readily relieved by a few punctures or snips with scissors, which give vent to the effused serum, or by truncating the enveloping mucous membrane at the extremity of the tip of the mass. It is never necessary to excise the organ. Sometimes the entire uvula is enlarged from hemorrhagic stasis, and a few drops of blood may even exude to the surface. This condition is readily relieved by scarification of the mucous membrane.

The tonsils rarely occasion serious trouble in superficial sore throat, but when they do, the same treatment is required as that adopted in acute tonsillitis.

A variety of common sore throat characterized by serous infiltration into the submucous tissue of the pharynx, technically known as *angina pharyngea œdematosa*, is sometimes observed. It is usually developed suddenly; and this circumstance, with the unusual amount of œdematous swelling impeding deglutition and respiration, more or less, distinguishes it from the more ordinary forms of catarrhal sore throat. It is not a serious affection, usually subsiding in about a week or ten days. It is rarely that any special therapeutic interference is indicated, the ordinary treatment for mild sore throat being adequate.

PHLEGMONOUS SORE THROAT.

(Deep-seated Sore Throat; Phlegmonous or Suppurative Pharyngitis; Acute Tonsillitis; Amygdalitis; Quinsy; Angina Tonsillaris, Angina Phlegmonosa.)

Phlegmonous sore throat exhibits a higher grade of inflammatory action than catarrhal sore throat, and involves the submucous structures, including sometimes the fibrous sheaths of the muscles as well as the mucous membrane.

The structures which may be involved are the pharynx, palate, tonsils, base of tongue, and epiglottis, and the contiguous structures connecting these parts. Various changes take place in these tissues,—infiltration with serum; abscess not unfrequently, and that diffuse sometimes, in patients of enfeebled constitution, but more frequently circumscribed in sthenic cases; sometimes single, sometimes multiple, sometimes superficial, sometimes deep-seated or concealed. The tendency of the disease is to termination by suppuration or by abscess, though it often terminates in resolution spontaneously and still more frequently under efficient treatment.

One variety of the disease is essentially a deep-seated pharyngitis, the inflammatory process involving the sub-mucous tissues especially, and exciting infiltration into them. It almost always progresses to suppuration; and the pus, uncircumscribed frequently, sometimes extends downward along the œsophagus, into which the abscess may be discharged, with a result of permanent stricture from the subsequent cicatrization. It may gravitate anteriorly beneath the fascia of the neck. In other instances the infiltration into the connective tissue becomes rapidly purulent under acute phenomena of fever. The pus may gravitate so as to exercise direct pressure upon the upper air-passages, or block up the entrance into the larynx by the mere tumefaction of the pharynx, death resulting in from three to four days, and sometimes suddenly. Even artificial openings into the air-passages rarely afford more than temporary relief. There is a more or less circumscribed tumefaction of the pharynx, which is red, dry, and lustrous. When in the retro-nasal portion of the pharynx, or in the œsophageal extremity, inspection by mirrors, and palpation are necessary to establish the diagnosis. There is pain in swallowing, and some impediment to the passage of the bolus. The prognosis in this variety of sore throat is very unfavorable.

In the more frequent variety of phlegmonous sore throat the tonsils are affected to a greater degree than the contiguous structures; hence the disease is usually designated as tonsillitis. It is less frequent in patients with normal, than in those with morbid tonsils; most frequent in children and young adults; and much more dangerous in children than adults, and in individuals with hypertrophied tonsils.

Phlegmonous sore throat is often ushered in by a distinct

chill, usually followed, within twenty-four hours, by fever and its attendant general phenomena. Pain in the throat with a sensation of dryness and constriction usually appears at an early period, and gradually increases in severity, interfering more and more with deglutition. All the structures of the throat usually present evidence of inflammatory action on inspection, but the tonsils in particular; sometimes both tonsils in an equal degree, sometimes one much more than the other, and often one gland only. The inflamed tonsil is sensitive, discolored, swollen, and irregular in outline, presenting somewhat different appearances according to the peculiar tissue of the tonsil in which the inflammatory process is most active. This may be the parenchymatous or glandular structure itself (acute lymphadinitis), the secretory ducts of the follicles (follicular catarrh), or the connective tissue, the mucous membrane always participating more or less. When the ducts are affected, a whitish or yellowish creamy secretion occupies the surface of the tonsil more or less irregularly; in some instances a discolored cheesy plug of desiccated secretion is adherent to the orifices of the ducts. In other cases the inflammation and tumefaction involves the palatine folds as well as the palate also, forming an angry-looking tumor protruding far into the mouth and pharynx. The swollen tonsil, in many instances, reaches the middle line of the pharynx.

If both tonsils are affected to this extent, the case is very serious, and may terminate fatally by suffocation, if respiration is not relieved by excision of the glands or incision into the air-passage.¹

Occasionally the swollen tonsil encroaches on the pharyngeal orifice of the Eustachian tube, and may thus occasion noises in the ear, and even hardness of hearing. When the posterior palatine fold is inflamed and put on the stretch, the pain is continuous into the ear. If much secretion be present, crackling sounds will be produced on movements of the palate in deglutition and otherwise, on movement of the jaw, and on blowing the nose. Sometimes there is considerable œdematous infiltration into the palate and the uvula, and even into the constrictor muscles of the pharynx. Occasionally, too, there

¹ For a recent example see (Rev. méd. chir., March 15, 1875) *The Lancet*, April 3, 1875, p. 487.

is œdema of the epiglottis and upper margin of the larynx likewise, to a greater or less extent, with dyspnœa and even suffocative paroxysms. The character of the secretion varies: it is sometimes semi-fluid; sometimes soft and cheesy or pul-taceous; sometimes membraniform; sometimes hemorrhagic; sometimes moist and viscid; sometimes very dry; often adherent, and always more or less full of minute vegetable organisms (leptothrix, oïdium albicans, bacteria, micrococci). Collections of caseous matters take place not only in the crypts of the tonsils, but likewise in the follicles of the palatine folds below the tonsil and running towards the base of the tongue.

The submaxillary glands often become engorged, and tender and painful to external manipulation. They may even undergo suppuration. This tumefaction is due to the swollen gland and infiltrated connective tissue around it; but is not unfrequently incorrectly referred to the tonsil itself rather than to the accompanying inflammation of the palate, with the lymphatics of which these glands are more directly connected anatomically. The tonsil is at a considerable distance from the inflamed glands, and cannot, except under unusual circumstances, be felt from the exterior.

As the disease progresses, the pain and local distress become intense in severe cases. Normal movements of the parts are impeded by infiltration of the tissues. In some instances deglutition becomes impossible, and in others so painful that every effort at swallowing will be avoided; and the patient will lean forward, or to one side, so as to favor the escape from the mouth of the increased saliva and other products of secretion. The jaws may be so swollen that the patient can hardly open the mouth widely enough to permit inspection of the parts. Sometimes the pain and swelling are so great that the jaws cannot be separated. The tongue is swollen and covered with a thick, dingy deposit. Taste is impaired, appetite lost, and digestion impeded. The breath is offensive. There is more or less difficulty in respiration. The voice is thick or muffled, and almost always nasal in tone; and there is great difficulty in articulation. The temperature is elevated (100° to 104°), and the pulse accelerated (100). The skin becomes dry; the urine high-colored and diminished in quantity. As the disease progresses, the face becomes flushed, and frontal or general headache supervenes. Sleep becomes difficult or impossible, some-

times from the mechanical impediment to respiration, and sometimes from pure nervous disturbance. In children, delirium and convulsions may take place.

This form of inflammatory sore throat sometimes subsides by resolution, all the structures gradually returning to their normal conditions. More frequently it proceeds to suppuration, the advent of which is sometimes announced by irregular or regular rigors. One or more abscesses are formed more or less superficially, which, if left to themselves, usually become confluent, and eventually rupture spontaneously. The progress of a superficial abscess in the connective tissue between tonsil and palatine fold (pretonsillar abscess) can often be watched by inspection, and the point of imminent rupture, usually the superior angle of the palatine fold, be detected by the sense of fluctuation.

The deeper-seated abscesses (tonsillar and retro-tonsillar) cannot be detected before rupture, as a rule, unless they are unexpectedly discharged during incision into the parts as a therapeutic measure. The abscess frequently ruptures at night, and its contents are then not unfrequently swallowed, sometimes unconsciously. Sometimes it ruptures during a spell of vomiting. Whenever or however it opens, relief is usually immediate, and subsidence of inflammation prompt; the very orifice of rupture becoming obliterated in a few hours. Cases of suffocation have been recorded from passage of the contents into the larynx, usually by spontaneous rupture during sleep; but they are altogether exceptional.¹ The abscess does not always rupture into the mouth. It may burrow beneath the pharyngeal muscles, and present at the external angle of the jaw, or even behind the sterno-mastoid muscle;² or it may pass along the epiglottis-pharyngeal fold, and distend the epiglottis like serous œdema. Even ulceration into the maxillary and carotid artery, and fatal hemorrhage therefrom, have been recorded. The surgical discharge of abscesses of this latter character, therefore, would certainly be followed by death from hemorrhage, unpreventable even were there means

¹ For recent examples, see Stokes, *Med. Times and Gaz.*, Aug. 29, 1874, p. 251; Littlejohn, *Brit. Med. Jour.*, Jan. 2, 1875, p. 16.

² For recent example, see Porter (*Med. Press and Circ.*), *Phila. Med. Times*, 1876, p. 597.

of determining that ulceration had extended into the large arteries.

The causes of phlegmonous inflammation of the throat are various: constitutional proclivity, exposure to cold when overheated or overworked, difficult dentition, organic diseases of mouth, tongue, and jaws, acute febrile movements, scarlatina, diphtheria, syphilis, scrofulosis, tuberculosis.

Symptoms.—The symptoms are various manifestations of fever, pain, impaired deglutition, impeded respiration, defective articulation, local tumefaction, abnormal secretion, disturbed assimilation and excretion, and so on, as described above.

Diagnosis.—This would be based on the appearances and symptoms described.

Prognosis.—The prognosis of the tonsillar variety of phlegmonous sore throat is favorable, as a rule, the attack usually occupying ten days when it runs through all its stages. A certain amount of reserve is necessary, however, in view of the serious complications possible, which may prevent recovery.

Treatment.—It is doubtful whether treatment can effectually shorten the course of the disease. Apart from constitutional requirements, the treatment must be based upon antiphlogistic principles; but it is not advisable, without urgent reason therefor, to employ venesection or even leeching, on account of the difficulty in administering food to repair the loss of blood and to sustain the vital forces. An emetic will render efficient service early in the attack, not only to the system generally, but to the local affection also, especially if the stomach be burdened with undigested food. The mechanism of the act of vomiting may compress the muscles of the palate and pharynx upon the tonsil, and thus favor the onward flow of some of the blood with which it is engorged. A non-depressing emetic, such as mustard, is the most appropriate. A saline laxative (for an adult one drachm of sulphate of magnesia, or its equivalent) may be administered every three or four hours for a day or so, or until an obviously favorable effect has been maintained for some hours, each dose for an adult containing one-eighth of a grain of tartar emetic, and a drop or two of the tincture of aconite root, with the addition of a suitable amount (one-twelfth to one-quarter grain) of a salt of morphia, if indicated by the pain. Guaiacum (three grains every two hours) or its tincture (ten to thirty minims) is useful. The in-

halation of steam from water alone, or from water impregnated with such remedial agents as hops, chamomile flowers, sage, xanthoxylum, or the watery extracts of opium, belladonna, or conium, or with camphor, santal, the camphorated tincture of opium, myrrh, or the compound tincture of benzoin, will soothe the parts a great deal. So also will the frequent projection of sprays of warm water, simple, or slightly aromatically medicated with cologne-water or toilet vinegar; which, when agreeable to the patient, as they almost always are, can be repeated as frequently as desired. The subcutaneous injection of morphia into the swollen structures themselves, or into the swollen lymphatic glands, or the submaxillary region, is said by some authorities¹ to yield excellent results; but I cannot speak of this practice from experience. Professor Mandl, of Paris, extols the application to the angle of the jaw of a fly-blister sprinkled with morphia.² Warm and moist applications externally give considerable relief, especially when the cervical glands are tender and swollen. They should be renewed frequently, so as to maintain equable warmth and moisture.

Gargles are not of much value, principally because their proper use entails too much pain.

It may be as well here to interpolate some remarks concerning gargling. The usual method of retaining a quantity of fluid in the mouth, and keeping it in motion between the base of the tongue and palate by repeatedly forcing an expiratory current of air through it, while the base of the tongue is elevated so as nearly to touch the palate, is not only a painful muscular exercise in severe sore throat, but is inefficient in bringing the fluid in contact with anything else than the palate and root of the tongue. In order to reach the pharynx the fluid must be submitted to the action of the constrictor muscles, but be released without completing the last phase of the act of deglutition—a partial act of swallowing being made, therefore, and frequently repeated; a practice which is often difficult to acquire, and which is also painful in sore throat. A much better and much less painful procedure is to bring the fluid in contact with the sore parts by letting it flow upon them by gravity as the head is turned to one side, backward or forward as the case may be, so as to wash the various portions of the surface in succession. Another method well adapted for bringing the fluid in contact with the epiglottis, the walls of the pharyngo-laryngeal sinuses, the upper and posterior surface of the larynx, and the lower part of the pharynx, is the device suggested by Merkel, which is to carry the fluid in a spoon back to the base of the tongue, and then pour it over the parts as the head is thrown back, which will bring it in contact with the epiglottis and upper and posterior surfaces of the

¹ Schroetter, *Jahresbericht der Klinik für Laryngoskopie*, Wien, 1871, p. 98.

² *Maladies du Larynx et du Pharynx*, Paris, 1872, p. 784.

larynx, and then, by holding the head sidewise, it is brought in contact successively with the lateral walls of the lower pharynx and the surfaces of the pharyngo-laryngeal sinuses; the operation being completed by suddenly bringing the head forward as the fluid is ejected, so as to bathe the posterior surface of the middle portion of the pharynx, the anterior surface of the palate, and the exposed surface of the tonsils and palatine folds.

Medicated sprays, on the contrary, propelled upon the parts every few hours, are very efficient local applications. Aqueous solutions are preferable, containing tolerably large quantities (say twenty grains or more to the ounce) of alum, tannin, sulphate of zinc, or, what I have seen most efficient, sulphate of copper, care being taken to guard against the deglutition of any of these solutions. They may be used by the syringe, in the absence of "spray-machines." Powders of alum, tannin, krameria, etc., in various dilution with althæa, lycopodium, liquorice, bismuth, and the like, may be blown upon the parts by means of a tube of some kind. The topical application of nitrate of silver in stick, or by sponge, mop, or brush, is very rarely practicable in a satisfactory manner, and is just as often unnecessary. Nothing which will excite movements of gagging, hawking, or expectoration should be done without due cause for it. In some cases, however, at an early stage, where the patient will tolerate the manipulation, the local application of the fused nitrate of silver is of immediate and permanent



FIG. 48.—Author's caustic pencil. The lower cut exhibits the caustic exposed on one side only, so as to avoid contact with adjacent structures.

benefit in relief to pain, and subsidence of engorgement. The caustic should be well guarded by a cotton net, or be molten on a roughened probe-point

of platinum or aluminium (Lewin), or, still better, secured in a wooden pencil-frame like a lead-pencil, which can be sharpened to suit with the penknife (Fig. 48).

If the tonsils are much inflamed, and the suffering therefrom intense, great relief will follow efficient scarification or incision, the bleeding being encouraged by mouthfuls of warm water. A narrow, sharp-pointed bistoury, with its edge turned toward the interior of the pharynx, may be thrust into the tonsil so as to cut it transversely toward its free surface, in the withdrawal of the blade, and this may be quickly done at two or more

points in succession. The operation is not very painful, sometimes comparatively painless, and the relief it affords to existing pain and tension is often immediate, while the facilitated circulation in the parts promotes the prompt resolution of the inflammatory process. Sometimes these incisions open abscesses in the interior of the tonsil, the existence of which, though conjecturable, could not have been otherwise determined. If pus exude from the incisions, the tonsil should be gently but firmly compressed between the fingers of the two hands, one within the mouth and the other externally at the angle of the jaw, so as to evacuate the abscess as thoroughly as practicable.

When suppuration is already evident, there can be no doubt as to the propriety of incising the abscess, and this should be practised at the most prominent accessible point, care being taken to keep the edge of the knife directed toward the interior of the mouth, so as to prevent injury from untoward movements of patient or operator. For like reason the knife-blade should be protected by a covering beyond the distance from the point which may be required for penetration. The pus is sanious and usually moderate in quantity. The abscess being discharged, recovery is prompt, unless there are other abscesses, in which case it will be delayed until they have all run through their course.

Accumulations of pus in the loose areolar tissue of the epiglottis or other structures demand prompt evacuation by incision; the operation being performed under guidance of vision where practicable, otherwise under guidance of the finger.

The general treatment is similar to that employed for simple sore throat. Hypnotics are indicated to secure refreshing sleep. The general strength must be conserved as much as possible; and when liquid food cannot be swallowed, nourishment by enema is indicated. Efforts of deglutition should be spared whenever practicable; and, in this view, medicines which can be administered by inhalation, by enema, or by hypodermic injection, should be selected in preference.

When the affection has been limited to one side, the other side not unfrequently becomes affected during convalescence or shortly after. When this is imminent, the administration of tonics and stimulants is indicated to maintain the forces of the patient during the second and sometimes severer attack.

Some individuals are liable to repeated attacks of quinsy of varying severity, recurring every year or few years, or oftener. These persons should be cautioned against exposure, and encouraged to use the daily cold bath or affusion. Frequent attacks may terminate in hyperplasia and induration of the tonsils.

This form of sore throat, like all other severe forms, is sometimes followed by paralysis.

Phlegmonous sore throat of traumatic origin is usually due to burns and scalds, mostly the result of accident, but sometimes the result of design. The parts liable to injury are the mouth, tongue, palate, nares, pharynx, œsophagus, larynx, and trachea. It is often promptly or remotely fatal. Scald throat is not uncommon among the children of the poor, who, being allowed to run about the kitchen without due supervision, attempt to slake their thirst by drinking water from the spout of the hot tea-kettle. In another class of cases caustic acid or alkali is swallowed—a liniment, for example, being mistaken for a mixture. In other cases acid or caustic substances are swallowed with suicidal intent. Burns are most frequently produced from the inhalation of flame, hot steam, or the heated air of burning vessels or buildings. When flame or hot air is inhaled, or when hot or caustic liquid is swallowed involuntarily, the larynx is much more likely to be implicated than when the drink has been taken designedly, and the epiglottis not surprised at its post, as it were; and the injurious effects are therefore manifested principally in the pharynx and œsophagus, and sometimes in the stomach, the act of deglutition having been completed in spite of pain and spasm. When the larynx has been injured, acute laryngitis (combustionis) rapidly supervenes, likely to be attended with severe local œdema, and thus threaten death by asphyxia. Tracheotomy is therefore demanded early, as a rule, after accidents of this sort; but it does not hold out the prospect of success in children that it does in adults. As a rule, the upper portion only of the larynx becomes implicated, the subglottic portion being often found normal on post-mortem examination. In other cases, however, the mucous membrane of the trachea and bronchi has been found congested and swollen; and in some cases there has been evidence of extension of the inflammation to the lungs. These effects, however, are secondary. Tuerck depicts

and describes¹ a case of circumscribed symmetrical cauterization of the outer inferior surface of the arytenoid cartilages from deglutition of dilute nitric acid.

When smoke is inhaled during the conflagration of burning buildings, black sputa are sometimes expectorated for several days.

I have elsewhere instanced² a number of cases which occurred in a family living over a perfumery store which took fire. Ten of them, who came under the care of Dr. W. W. Keen, Jr., and myself, were attacked with severe bronchitis and aphonia, and, for several days subsequent to the accident, expectorated large quantities of black sputa, which were nothing more or less than the carbonaceous matters they were forced to inhale before they could be rescued from the flames. In one of these cases there was œdema of the larynx threatening suffocation. Copious and frequent inhalations of the spray from a solution of the watery extract of opium relieved the suffering, and the patient eventually recovered.³

When hot and caustic fluids are swallowed, regurgitation sometimes takes place during the act of deglutition, and the expelled matters escape in part through the nasal passages, thus injuring the mucous membrane of this region, and that of the retro-nasal portion of the pharynx.

The *diagnosis* of a burn or scald in the throat is usually easy. Severe pain and distress in the part, the accelerated pulse, the dyspnœa and dysphagia, and the history of the case, are sufficient for the purpose. The mouth, root of the tongue, palate, and pharynx, if seen early, are white, often from detachment of the epithelial layer in a membranous form, or from plastic exudation. Patches of the mucous membrane are destroyed, and there is abundant evidence of inflammatory swelling of the mucous membrane and submucous tissues. More immediately after the injury, it is probable that the mucous membrane is lividly red from intense congestion; still it may be at once destroyed. The nervous shock is usually very great, and forms one serious element of danger.

The *prognosis* is grave. If the patient lives long enough, the destroyed portions of mucous membrane (pharynx, œsophagus, larynx) slough, and are thrown off or expectorated. Suppuration is very great, should the patient survive; and

¹ Klinik der Krankheiten des Kehlkopfes und der Luftröhre. Wien, 1866, p. 182.

² Inhalation; its Therapeutics and Practice. Phila., 1867, p. 294.

³ Ibid., p. 139.

chronic laryngitis usually remains, sometimes with stenosis of larynx or trachea, and stricture of œsophagus.

The *treatment* demands the administration of anodynes hypodermically and by inhalation, nourishment and stimulation by enema, and the local application of fragments of ice in the mouth, with cold compresses or ice-bags about the neck; to which is to be added the performance of tracheotomy on the supervention of symptoms of suffocation. Mucilaginous drinks, if they can be swallowed, are very soothing to the parts, and they often effect assuagement of suffering by mere retention in the mouth when deglutition is impracticable. Inhalations of sedative and anodyne sprays are also useful adjuncts to the treatment.

The results of traumatic sore throat require to be treated according to the special indications.

ULCEROUS SORE THROAT.

(Phagedenic Sore Throat, Malignant Sore Throat, Gangrenous Sore Throat; Angina Ulcerosa, Angina Gangrenosa, Angina Maligna; Tonsillitis Maligna, etc.)

The term ulcerous sore throat in the sense here employed has no reference to the superficial ulcerations of the mucous membrane which may occur in ordinary forms of sore throat; but, on the contrary, to a special, and, apparently, inevitable ulceration of tissue which forms the characteristic local lesion of the disease. All sore throats may become phagedenic, but this sore throat is necessarily and essentially phagedenic. It is a disease of low type. It is not of frequent occurrence. Its special cause is often obscure, except when there is some underlying cachexia, or debilitation from acute infectious diseases, including those which are contracted from the lower animals. It not infrequently follows sudden exposure of the body to changes of temperature, such as a cold douche while overheated. Moderately severe, only, in some cases, it exhibits from its commencement, in others, a tendency to phagedenic ulceration of a malignant character, resulting in gangrenous destruction of tissue over a large extent of surface, even involving the blood-vessels, and thus occasioning alarming and sometimes fatal hemorrhage; being attendant upon that low general systemic condition denominated typhoid. It sometimes follows

scarlatina, and is occasionally present in diphtheria. Sometimes it supervenes upon measles, small-pox, dysentery, typhoid fever, erysipelas, malignant pustule, and glanders. It also occurs in syphilitic sore throat, and sometimes in epithelial cancer of the throat; in these instances beginning in the palate usually, and thence extending to the tonsils and the pharynx. At times it occurs in cases of tuberculous phthisis, even in cases in which the larynx and trachea are not involved. It is rarely a sequel of simple inflammatory sore throat, though sometimes preceded by common membranous sore throat. In short, it may ensue upon any form of sore throat.

It is often accompanied by an irregular, erythematous eruption on the skin. There is a low type of fever, with glassy eye, and a haggard expression of countenance. The pain is not severe as a rule, sensation being benumbed. The dysphagia is slight for the same reason. The tongue supports a dark, creamy, pultaceous secretion; and similar masses occasionally occupy other mucous structures of the mouth and throat. The tonsils are swollen and darkly congested. The palate and uvula become swollen and œdematous, and often the pharynx likewise. At an early period, dark, ashy-colored ulcerations, with excavated edges, are to be observed on the tonsils and contiguous surfaces. These soon slough out with more or less of the surrounding tissue; and the ulcers left become covered with a somewhat continuous, sanious, ichorous, fetid secretion. The cervical glands become swollen and tender. Extension to the pharynx and nares is not infrequent; that to the larynx is rare, although the voice becomes weak and muffled. The ulceration extends rapidly, destroying those tissues which are subjected to its ravages. Occasionally the process is limited to the tonsil, but more frequently it extends to the adjacent parts, destroying the uvula, and often more or less of the soft palate. Sometimes it is impossible to arrest the progress of the gangrene, and it spreads from the pharynx to the subjacent structures, whence it is liable to penetrate the carotid artery and produce fatal hemorrhage.

An instance of this nature occurring in a case of phthisis, and recorded by Mr. Robert Grahame,¹ will illustrate this complication. The phagedenic action commenced in the pharynx, and, in spite of active treatment, invaded both

¹ The Lancet, Aug. 27, 1870, p. 290.

tonsils, the uvula, the soft palate, and the lateral walls of the pharynx, producing hemorrhage which required ligation of the common carotid artery. The operation was successful.

Sometimes, in phthisical cases, as in others, repair takes place spontaneously even after local measures have been abandoned. In some cases the ulcerous process begins upon the posterior surface of the soft palate, and great ravages are made before its peculiar nature has been detected; the inflammatory evidences anteriorly being usually such as to indicate imminent ulceration on that surface without directing attention to the posterior surface. Inspection of the posterior surface of the palate by pharyngeal rhinoscopy is therefore indicated in every severe case in which ulceration posteriorly might be suspected.

The secretions and excretions escape by mouth and nose, and they are extremely fetid; so offensive, indeed, that their effluvium has sometimes been compared to that from fæces. Portions, too, are doubtless swallowed, and thus render the system still further depressed. Often toward the last diarrhœa sets in, a precursor of death.

Symptoms.—The symptoms are those of mild sore throat at first, with adynamic febrile manifestations. Later on there are superadded the appearances described above.

Diagnosis.—In the early stages, this is only determinable by the depressed state of the general system, the dark, unhealthy appearance of the structures affected, and the absence of severe pain. After the disease has made some progress, its characteristic ulcerous aspect leaves no doubt as to its nature.

Prognosis.—This is unfavorable, although recovery is not unfrequent. Death may take place by syncope, coma, asthenia, or hemorrhage.

When phagedenic cases recover, a horrible amount of deformity often remains to mark the ravages of the ulcerous process. During cicatrization the positions of contiguous parts become very much changed. The palate may become adherent by its sides, and by more or less of its posterior surface, to the pharynx, in some instances amounting to complete occlusion of the nasal portion of the pharynx. There is a peculiar loss of resonance in the voice, and some difficulty in articulation; often serious impediment to deglutition of solids and even comfortable deglutition of liquids; and more or less difficulty in expelling nasal mucus.

Treatment.—This must be of the most active and supporting character; such, in few words, as is adopted for the arrest of gangrene in any portion of the body. Eggs, milk, cream, and nutritious soups are to be administered as freely as the patient will take them; and quinine in large doses, tincture of the chloride of iron, and alcoholic stimulants in no stinted measure are indicated. As there is usually but little difficulty in swallowing, a sufficient amount of nourishment can almost always be taken by the mouth. If not, nutritious enemata containing quinine and brandy should be administered three or four times a day if practicable.

The topical treatment is very important. While the disease is superficial, bromine, muriatic or nitric acid, acid nitrate of mercury, caustic potassa, or the incandescent cautery, may be employed to destroy the diseased tissue promptly, in the hope of exposing a healthy surface beneath, which will heal up by granulations. When this is unsuccessful, or too dangerous in cases where the blood-vessels are probably involved, it is only possible to palliate the symptoms by weak solutions of acids and astringents, to which opium may be added; the greatest dependence for restraining the process being placed on constitutional measures. Washes and sprays of chlorate of potassium, and the like, impregnated with aromatics, as employed in common sore throat, are often agreeable to the patient; but they have no direct therapeutic influence on the progress of the disease. If the ulceration is extending into the vicinity of the great vessels of the neck, measures for compression should be at hand for the use of the nurse, and instruments accessible with which to secure the carotid artery when called to the case in the contingent emergency.

SIMPLE OR COMMON MEMBRANOUS SORE THROAT.

(Non-malignant Membranous Sore Throat, Herpetic Sore Throat, Aphthous Sore Throat; Angina Membranacea, Angina Aphthosa, Angina Herpetiformis; Herpes Pharyngis, Herpes Gutturalis; Angina Couenneuse Commune [*Fr.*].)

Membranous Sore Throat is characterized by the eventual exudation of a fibrinous material, which coagulates on the surface of the mucous membrane into a pellicle or pseudo-membrane. It is not unfrequent, and occurs at all seasons of the

year. Its tendency is always to recovery, except in rare instances in which the larynx is simultaneously affected, when the danger arises from mechanical obstruction to respiration. Common membranous sore throat is often contracted by susceptible persons during the prevalence of diphtheria, and may then become a starting-point for that disease. Some patients are attacked almost annually. Its most frequent immediate cause is exposure to cold while the body is overheated or in active perspiration. Imperfect drainage, and fetid emanations are often the apparent remote cause.

The peculiar manifestation of the affection is preceded for two or three days by the symptoms of ordinary sore throat, usually supervening upon chill with febrile reaction, and subsequent symptoms of general systemic disturbance. Sometimes the fever is unaccountably severe.

The throat is usually affected on one side only, the corresponding submaxillary, or cervical lymphatic glands, when at all involved, becoming swollen to a very moderate degree. Deglutition is often difficult and painful, and the parts feel dry and hot, the sensation often extending toward the ear, in some instances into the nasal passages, and occasionally into the larynx.

The tonsils are swollen and soon become covered with a whitish or yellowish white pultaceous exudation or deposit, but slightly adherent to the mucous membrane. In addition there is sometimes an accumulation of viscid mucus, more or less ropy, and more or less turbid in appearance. The soft palate, and often its anterior folds, over the swollen tonsils especially, has a fissured or corrugated appearance in many instances, and the membranous coating is distributed more or less irregularly upon it, having often much the appearance of detached layers of epithelium; and when removed by artificial means, at a comparatively early period after its appearance, often reveals an eroded and sometimes slightly hemorrhagic surface. At a later date the mucous membrane appears normal on the removal of the deposit, the erosions having healed up meanwhile. The hard palate is rarely ever covered by the deposit, nor the pharynx either, as a rule.

If the throat is examined within a few hours after the commencement of the disease, its initial form may be detected on the palate and uvula, sometimes on the tonsils, less frequently

on the pharynx, and occasionally on the hard palate, in the form of small vesicles, the size of millet-seeds or somewhat larger, isolated here and there, or in groups, with more or less turbid contents, and surrounded by zones of inflammation. Occasionally, after existing a day or two, these vesicles disappear without traces, in which case the membranous deposit will not be formed. Most frequently, however, these vesicles rupture very soon, leaving small excoriations, which become covered almost immediately with a grayish white plastic exudation. This exudation spreads over the surrounding mucous membrane, and coalesces into similar patches which have commenced in the same way at other portions of the surface. It is very rare, however, that a case is seen at a sufficiently early period to recognize the vesicular nature of the disease.

In many cases a herpetic eruption occupies the corners of the mouth at the same time, or some part of the inner surface of the lips, cheek or tongue, or even the face; under which circumstances there can be no doubt as to the nature of the diagnosis.

Other ulcerated mucous surfaces often become covered with this deposit during an attack of membranous sore throat, and even cutaneous ulcers also; a similarity presenting in this respect to the analogous phenomena in diphtheria, but altogether independent of any toxic evidence of that disease.

A membranous sore throat attends some cases of phthisis and syphilis in their advanced stages; but this subject will not be elaborated here.

Symptoms.—The general subjective symptoms are those of ordinary acute sore throat, with marked febrile disturbance.

Diagnosis.—This is difficult if diphtheria be prevalent.

Prognosis.—This is favorable in common membranous sore throat, recovery being spontaneous, in the majority of cases, in from a week to ten days. It is occasionally fatal, however, chiefly in children, from extension of the pseudo-membrane into the air-passages; death taking place mechanically, by asphyxia. The general impression that this form of local disease never extends into the larynx is erroneous.¹

¹ Prof. Dickson used to mention a fatal case of this kind in a child, in whom, after death, he found the deposit lining the larger and smaller bronchi of the whole of the left lung. The deposit was in a tubular form, and so extensive that he dissected off portions of it as long as his finger. He considered the affection analogous

Paralysis of the palate may follow common membranous sore throat.

Treatment.—This is very simple. Laxatives, anodynes, and demulcents are often indicated. The general treatment, therefore, is similar to that in catarrhal sore throat. Local treatment is rarely requisite, and when called for, can usually be limited to applications of alum, borax, chlorate of potassium, and mild astringents in solution, by brush, syringe, or spray apparatus.

The duration of this disease is not usually more than a week or ten days, as already stated; but in some individuals there appears to be a constitutional proclivity to recurrence or continuance of its peculiar manifestations, extending, with more or less exacerbation and remission, over periods varying from a few weeks to a number of months, especially perhaps in tuberculous and scrofulous subjects. I have seen it recur again and again for more than six months in tuberculous subjects, with immunity from laryngeal inflammation. Under such circumstances more active treatment is demanded locally, and more vigorous therapeutic interference systemically. The dilute acids frequently applied, *i.e.*, every day or so, seem to afford more satisfactory results locally than the ordinary astringent and caustic salts. The internal use of iron and cinchona as tonics, sometimes of opium, not as a narcotic, however, but rather as a special stimulant in small doses, the use of a highly nutritious diet, and the avoidance of unnecessary exposure and exercise, and similar corroborant measures, are indicated to overcome the disposition to its continuance or recurrence.

Common membranous sore throat may become the starting-point of malignant or phagedenic sore throat under debilitated conditions of system. The treatment for ulcerous sore throat is then prominently indicated. It may also invite an attack of diphtheria during the prevalence of that disease, under which circumstances there may reasonably be considerable doubt as to the diagnosis. In case such a doubt should be entertained by the practitioner, his most prudent plan would be to treat the

to a form of tubular diarrhoea described by Good, in which the pseudoplasm forms a tube in the intestines; and referred to a case mentioned by West, in which a membrane of this kind lined the whole œsophagus.

case for diphtheria. An unnecessary activity would do no material injury in a case of common membranous sore throat; and if the sequel should determine the case to be one of diphtheria, it would not have suffered neglect under an impression that it was a much less serious disorder. When these doubtful cases are cured, as they almost always are, care should be taken against recommending for diphtheria any inefficient remedy, during the employment of which a case of common membranous sore throat has recovered spontaneously.

THE SORE THROATS OF THE FEBRILE EXANTHEMATA.

Small-pox, measles, and scarlatina are more or less regularly attended by sore throat, which may be catarrhal, phlegmonous, ulcerous, or membranous.

The Sore Throat of Small-Pox.—The sore throat of small-pox is due to the development of an eruption upon the mucous membrane similar to that which appears upon the skin. It is always, or almost always, present in ordinary cases, but less frequently in hemorrhagic cases, or in varioloid. The eruption, which often appears somewhat earlier than upon the skin, occupies the inside of the cheeks, the palate, uvula, and pharynx, and sometimes the larynx also. The maturation of the pustules and consequent ulceration occur more rapidly than in the skin; and with this, there is more or less purulent infiltration of the submucous connective tissues. The ulceration of the larynx and trachea may be so severe as to terminate fatally. In a case reported by Bernutz there was even perforation of the larynx.

The appearance of the disease in the throat is usually indicated by excessive salivation; the secretion increasing in quantity, and becoming more viscid and offensive. In confluent cases the symptoms are more severe; the salivation may amount to one or two pints in the twenty-four hours; thirst becomes intense, deglutition difficult, and expectoration painful. The involvement of the larynx is indicated by hoarseness, and sometimes more or less dyspnoea from œdema in the aryteno-epiglottic folds, or other structures,¹ conditions which, if

¹ Death from sub-glottic œdema is mentioned by Gibb, *Diseases of Throat and Windpipe*, 2d ed., London, 1864, p. 219; Bernutz, *Gaz. Med.*, 1868, p. 790.

not averted, sometimes prove fatal by suffocation. Laryngoscopic examination reveals the inflammatory condition in these structures. In the exfoliation of the mucous membrane, again, mechanical obstruction to respiration may result in asphyxia.¹

The appearance of variolous pustules, as seen in the larynx, has been depicted by Tuerck, who describes² a case of small-pox in the adult, in which hoarseness occurred on the tenth or eleventh day of the disease. Two or three days after, he made a laryngoscopic examination of the larynx, and discovered a variolous pustule, surrounded with an inflamed areola, upon the upper surface of the anterior portion of the left vocal cord, and two others upon the posterior laryngeal wall, in front of the transverse arytenoid muscle. I have seen them upon the epiglottis, aryteno-epiglottic folds, and upon the ventricular bands. In one case of acute laryngitis accompanying a very severe case of discreet small-pox, aphonia occurred suddenly on the eleventh day, without having been preceded by hoarseness. In order to determine the influence that the throat complication might have on the prognosis of the case, I was asked to examine the patient on the fifteenth day, and found that the aphonia was due to paralysis of the arytenoid muscle. The parts in the neighborhood were slightly œdematous. A favorable prognosis removed the doubts of the parties, and was verified by the result. The voice gradually returned during the convalescence of the patient.

Symptoms and Treatment.—The ordinary phenomena of the sore throat are those already detailed, and the treatment is the same as that indicated for catarrhal sore throat generally. Supporting treatment and frequent local ablutions are required when the discharges of saliva, pus, etc., are copious. In cases of dyspnœa threatening suffocation, tracheotomy may be called for as a means of averting impending death.

The injuries sustained by the larynx during the course of confluent small-pox may be permanent.

In some cases examined by myself, years after the attack of small-pox, the larynx appeared in a state of chronic inflammation, its inner surface studded with permanently enlarged follicles. There were also little elevations upon the surface of the vocal cords, which themselves were much congested. The symptoms complained of by the patients were constant hoarseness, without pain in vocalization, and a frequent subsidence of laryngeal sound on exertion of the voice, or upon exposure to cold; the defect of voice sometimes amounting to absolute aphonia, and lasting for a period varying from several hours, or a day or two, to several days or a few weeks. The voice in these cases was not only hoarse, but sounded like that of a tired and languid convalescent, feeble

¹ (Lyon Méd., Nov. 10, 1872); The Lancet, Nov. 23, 1872, p. 750.

² Klinik der Krankheiten des Kehlkopfes und der Luftröhre, Vienna, 1866, p. 180.

and hesitating, as though the effort to produce it were painful and exhausting. Dr. Gibb¹ relates an interesting case in which one vocal cord appeared to have been destroyed by small-pox; and another in which the patient had been the subject of aphonia, hoarseness, and chronic laryngeal disease for thirty-eight years subsequent to an attack of small-pox. The ventricular bands were very much swollen, and one of them had a small abscess upon it at the time of examination. He also mentions an anatomical preparation from a small-pox case, in which the trachea was studded with distinct elevated spots of coagulable lymph, like the pustules of small-pox.

The Sore Throat of Measles.—The sore throat of measles is a catarrhal inflammation affecting the air-passages, from nostrils to bronchi, rather than the food passages, primarily due to an eruption on the mucous membrane similar to that on the skin; a more or less painful coryza and laryngitis therefore. The inflammatory process is sometimes propagated along the lachrymal duct, producing injection of the conjunctival mucous membrane, lachrymation, and intolerance of light. Its severity is often in direct ratio with the severity of the general affection. The secretions are viscid and acrid, inducing spasms of sternutation, sometimes attended by epistaxis from rupture of the blood-vessels. The Eustachian tubes sometimes become involved in the catarrhal inflammation of measles, and there may thus ensue merely impaired hearing, or even marked deafness, accompanied by acute pain in the ears.

The mucous membranes are often affected before any manifestation of the disease appears on the cutaneous surface; and in some instances evidences of the eruption in the form of small, red points, the size of millet-seed and larger, will be found upon the palate a day or more in advance of its appearance upon the skin; and it can sometimes be thence defined upon the tonsils, posterior palatine folds, and pharynx before it is seen on the external surface. These disappear in the course of a few days, though sometimes, in bad cases, a fibrinous exudation is thrown out upon some portion of the palate or pharynx, and on the upper portion of the larynx. It is less fibrinous than the false membrane of croup and diphtheria, more liable to disintegration, and less equably distributed upon the surface. In other cases, abscess and ulceration take place, chiefly in the larynx; and this organ, in fact, seems to suffer more than the other structures in measles. In some in-

¹ Op. cit., p. 286.

stances the catarrhal laryngitis is extremely severe, hoarseness of voice from chronic inflammation of the vocal cords and other intralaryngeal structures persisting for a long time after subsidence of the original affection. Occasionally the catarrhal infiltrations become organized, and produce chronic hoarseness from that cause. Sometimes they become points of departure for the development of papillomatous excrescences within the larynx, principally upon the vocal cords, or in the ventricles, the same localities in which they occur after membranous croup. These may be so extensive as to demand surgical interference; otherwise, as in a case which came under my own observation in consultation, they may prove fatal by suffocating the patient.

At other times abscess and ulceration of the epiglottis take place, or similar processes occur in the upper portion of the larynx, which may prove fatal. Under conditions of œdema the complication may be mistaken for croup, and the operation of tracheotomy delayed until the onset of fatal cyanosis. Cases of ulceration of the larynx from measles have been recorded by Cruveilhier,¹ Cheyne,² Ryland,³ and others. P. Coyne⁴ describes two varieties of laryngeal ulcerations in measles; necrotic inflammation confined to the mucous membrane of the vocal cords, and suppuration of the mucous glands, especially upon the ventricular bands and along the arytenoid cartilages.

Symptoms and Treatment.—The general symptoms are those of a severe form of catarrhal sore throat, and so far the treatment is to be conducted on the same principles as for that affection. Special indications would require treatment in accordance.

The Sore Throat of Scarlatina.—The sore throat of scarlatina has given the name *anginose* to one of its varieties, and in many instances it forms the chief source of danger in the disease. It is often exceedingly severe in character, and apt to leave permanent injury, especially of the Eustachian tube and

¹ Dict. de Méd., etc., article Laryngite.

² Dict. Pract. Med., article Laryngitis.

³ On the Larynx and Trachea. London, 1837. Case iv.

⁴ Recherches sur l'anatomie normale de la muqueuse du larynx, et sur l'anatomie pathologique des complications laryngées de la rougeole; noticed in Arch. gén. de méd., April, 1874, p. 512.

middle ear. The palate, tonsils, and pharynx suffer, rather than the nasal passages and larynx ; but the larynx is by no means exempt.

Some amount of sore throat exists in every case of scarlatina ; indeed, sore throat is its only manifestation in some very mild cases. Individuals susceptible to sore throat are apt to suffer from it during attendance upon scarlatina patients.

The local manifestations appear upon the mucous membranes a day or two in advance of their appearance on the skin ; the mucous membrane of the palate, tonsils, and pharynx being deeply congested, uniformly or in patches, and sometimes supporting slight papulous elevations. The palate and tonsils soon become swollen, and in the course of a day or two the tonsils become covered with an opalescent or milky deposit, consisting chiefly of detached epithelial scales commingled with an excessive secretion of viscid mucus. The production of this coating has given rise, in part, to the idea of analogy between scarlatina and diphtheria entertained by some observers. Their occasional prevalence at the same time has also given color to this view. On the other hand it must not be forgotten by those who reject this opinion, that during the prevalence of diphtheria the ordinary sore throat of scarlatina may become diphtheritic, without furnishing evidence of diphtheritic poisoning as an essential element of the scarlatina itself.

Symptoms.—The subjective symptoms are those of ordinary sore throat ; and these become more and more severe as the disease progresses. The lymphatic glands, at the angle of the jaw, become swollen and painful. The tumefaction sometimes extends to the deep-seated glands. Sometimes there is serous or sero-fibrinous effusion into the submucous connective tissue, impeding respiration and deglutition ; the latter especially, so that fluids taken into the mouth often run off by the nose. As the cutaneous symptoms abate, the throat symptoms subside likewise. The secretion is cast off from the tonsils, and sometimes desquamation of epithelium from the tongue, palate, and pharynx occurs, just as desquamation of epidermis from the skin.

In the anginose variety proper, of scarlatina, the symptoms of disease in the throat are much more severe than those already described. The hue of the palate, tonsils, and pharynx

is more dusky ; the pseudo-membranous deposit is of a dirtier white, an ash, or even a yellow color. The secretion is less apt to be limited to the tonsils ; accumulating rather on the palate and palatine folds, and upon the posterior wall of the pharynx. The patches are soft, and resemble the patches that gather on the surface of foul ulcers ; they are readily removable, and when removed, are sometimes seen to have really covered ulcerated mucous membrane, and even gangrenous sloughs, in some instances. The general swelling of the parts is much greater than in simple scarlatina ; the tumefaction of the cervical and submaxillary glands and their adjoining connective tissue being so great and so painful, in some instances, as to prevent the opening of the mouth sufficiently to expose the parts to inspection. A viscid and turbid secretion accumulates in the mouth ; and this is expectorated with difficulty. In some cases the nasal secretions desiccate into firm crusts, which obstruct nasal respiration and compel breathing through the mouth. Sometimes purulent inflammation is thus excited, and an acrid, offensive, excoriating secretion is discharged from the nostrils, and from the mouth also, in some instances. In some cases the inflammation extends along the Eustachian tube into the middle ear, when the symptoms of otitis media will be additionally manifest. Suppuration of the drum membrane may ensue with suppurative external otitis ; or the internal ear may become involved with serious cerebral disturbance.

In malignant cases of scarlatina, the mucous membrane is very much swollen and very darkly congested ; and ulceration soon takes place, frequently attended with gangrene of the tissue ; the pseudo-membranous deposit being dark, almost to blackness, from intermingling with extravasated blood. The discharges are sanious and offensive, and not unfrequently contain shreds of the destroyed tissues. The malignancy may be manifest from the outset, or not until an advanced stage of simple or anginose scarlatina, or not even until after the commencement of a period of apparent convalescence.

The tumefaction at the angles of the jaws extends over the neck, the tumefaction internally increasing at the same time ; respiration becoming impeded in some instances so as to threaten suffocation, a condition in which tracheotomy may be demanded. Œdema of the uvula and soft palate occurs, and with it, sometimes, œdema of the epiglottis and aryteno-epi-

glottic folds. These conditions likewise threaten suffocation, and may necessitate tracheotomy.

Treatment.—The special treatment of the case does not vary from that for ordinary inflammatory sore throat. Severe topical measures are rarely indicated. Acidulated sprays to the parts are grateful and soothing; and weak solutions of alum are useful as detergents. These sprays may be applied with benefit as frequently as called for by the patient.

ERYSIPELATOUS SORE THROAT.

Erysipelatous sore throat is infrequent. It occurs, usually, in connection with erysipelas of the head, face, and neck; sometimes as an extension from these surfaces; sometimes appearing primarily in the throat, and thence spreading through nose and mouth to the exterior. Pharyngeal erysipelas may make its way on the face through the lachrymal canal.¹ Sometimes there is an interchange between external erysipelas and erysipelas of the throat in the form of a metastasis. Sometimes it is confined to the pharynx,² running its course to death or recovery within forty-eight hours. I have never seen a case of this kind. When the throat is seriously involved, there is danger of extension of the disease into the larynx; a result apt to be attended with œdema, and thus to threaten death by gradual suffocation or asphyxia.

Erysipelatous laryngitis is likely to occur under unfavorable circumstances. Though there is no doubt that this occasionally presents as an idiopathic affection, most of the cases reported have been encountered in hospital practice; and since the general institution of the hygienic regulations at present in force in every well-conducted hospital, it has been met with less frequently. It is usually attended with erysipelatous inflammation of the palate or pharynx, and sometimes extends outward upon the cheek. Sometimes it follows upon external erysipelas. It is very liable to terminate in œdema of the larynx, and to prove fatal by gradual suffocation, or by sudden asphyxia. Sometimes the inflammation terminates in diffuse abscess of the submucous connective tissue, the sloughs from which, on examination after death, present an appearance simi-

¹ Gallard: (Gaz. des hôp., 47, 1868); Schmidt's Jahrb., Jan., 1869, p. 35.

² Todd: Clinical Lectures, Phila., 1860, p. 151.

lar to that of analogous sloughs from the subcutaneous connective tissue, the result of external erysipelas. The accumulations of purulent products, in these instances, are found upon the external surface of the larynx as well as in its interior, and may involve the epiglottis or any other of the cartilages of the larynx. The trachea, also, is sometimes involved in the inflammatory process.

Erysipelas of the throat, when idiopathic, begins in the guise of an ordinary diffuse inflammation, usually after several days of general malaise, but there is not a very great amount of swelling, and the palate, tonsils, and pharynx are of a very dusky red, sometimes lustrous hue. The submaxillary glands are not much swollen, nor always engaged. There is more or less inability to swallow; but this is not due to swelling or pain, as in ordinary inflammations of the throat, but from actual paralysis of the muscles of deglutition, which do not contract as usual upon contact with foreign substances. Regurgitation takes place through the mouth when the pharyngeal muscles alone are in this condition, and through nose and mouth when the muscles of the palate are similarly affected.

Symptoms.—The general symptoms are those that attend the usual manifestations of external erysipelas, only the febrile phenomena, pain at the epigastrium, nausea, and so on, are more severe; with suffocative symptoms if there be serious œdema and cough, and pain in the throat if there be laryngitis.

Diagnosis.—The diagnosis is often difficult in the absence of evidences of external erysipelas.

Prognosis.—The duration of the disease varies from forty-eight hours to a week, rarely longer. In cases fatal by œdema of the larynx or other cause, frequently undiscernible, death sometimes occurs within two or three days from the commencement of the attack.

The inflammation of the parts usually subsides by resolution. Occasionally, however, it is followed by abscess, but this is rare, and I have seen but one instance of it (pharyngeal abscess in a lady seventy years of age).

The prognosis, as a rule, is not favorable.

Treatment.—The treatment consists in the administration, in part by enema, if necessary, of large doses of quinia, tincture of the chloride of iron, brandy, and diffusible stimulants; with the greatest amount of the most nutritious food procur-

able that the patient can be induced to take by mouth or retain by rectum, as the case may be. The local application of a strong solution of nitrate of silver (60 grains to the ounce), so as to cover some of the unaffected structures, if possible, seems to afford the best means of controlling the local affection. Sedative applications, such as are used to soothe ordinary inflammatory sore throat, are equally serviceable in this variety.

ACUTE TUBERCULOUS SORE THROAT.

This affection I have never seen. Isambert,¹ Fraenkel, and others have described it more or less minutely. According to Isambert it is an acute miliary tuberculosis of the pharynx and larynx, proceeding rapidly to ulceration, and terminating fatally within a few weeks, under farther progress as acute pulmonic phthisis. It is characterized at the start by deposition, in the meshes of the pharyngo-laryngeal mucous membrane, of a very abundant dissemination of semi-transparent gray granulations, analogous in aspect and volume to vermicelli seeds, fish eggs, or the grumous fibrin observed on the intestines in recent peritonitis. They are beneath the epithelium, and bleed freely when touched. These granulations, generally confluent, are usually grouped in patches of irregular configuration, with a chagrinated or mamelonated surface. When these groups are not very abundant, and are very superficial, they can be easily enucleated, the surface appearing eroded as by a nutmeg-grater, not unlike tuberculous erosions of the tongue. When more abundant and prominent they present a great analogy to mucous patches of syphilis, for which they are liable to be mistaken; but they are without the inflammatory aureola of the latter, and have not the same opalescence. The lesion is observed on the palate and anterior folds, the tonsils, and the pharynx; and at an advanced stage on the epiglottis and larynx. As the disease progresses, the granulations increase in number and augment in volume, but do not surpass the volume of hemp-seed, except in certain cases where they become transformed into cheesy nodules. At the same time they lose their transparency, become more and more sanious and painful, and covered with pultaceous and purulent prod-

¹ Conférences cliniques sur les maladies du larynx et des premières voies. Paris, 1877, p. 219.

ucts. Ulceration follows, which seems to enucleate a certain number of granulations, leaving an empty pocket and a more or less deep loss of substance. Death usually ensues before great ravages can be produced.

Symptoms.—The symptoms are those of local pain, with dysphagia augmenting with the proliferation of the granulations, and especially with their softening; greater than that occurring even in cancer of the larynx and phthisis with ulceration and œdema of epiglottis and arytenoids. The pulmonic symptoms are not ordinarily manifested until an advanced stage of the lesion in the throat.

Diagnosis.—The disease may be confounded at first with thrush, simple or scarlatinous pultaceous sore throat, syphilitic sore throat and scrofulous sore throat.

Prognosis.—The disease is fatal, the patients succumbing in from two to six months under manifestations of galloping consumption.

Treatment.—The treatment is that for acute phthisis, with local palliative measures, and alimentation with liquid food as long as it can be swallowed, and then nourishment by enema.

I have seen one case of acute phthisis commencing with acute laryngitis, attended with febrile phenomena of distinctly remittent type, occurring in a sailor, twenty-six years of age, after a few days' exposure to severe weather on shipboard. It terminated fatally in two weeks. The lungs were studded with tubercles, as were the liver and some other organs. The larynx exhibited a series of follicular ulcerations similar to those observed in cases of the ordinary ulcerative laryngitis of tuberculosis; but careful microscopic examination failed to reveal any deposit of tubercle in the larynx. The specimen was examined by Dr. Longstreth, Pathologist to the Pennsylvania Hospital, and is preserved in the museum of the College of Physicians of Philadelphia.

THE SORE THROAT OF GLANDERS.

This I have never seen. It is described as an ulcerous sore throat, and part of the general manifestation of glanders, an occasional disease in the human subject usually acquired by direct infection from the secretions or excretions of glandered animals, or from partaking of their flesh or milk as food, and also transferred directly and indirectly from one human being to a companion. This sore throat may be a primary lesion if the virus happen to be received directly upon the mucous membrane of the mouth or throat from the nostrils of a glan-

dered animal. Acute coryza is a more frequent primary lesion from direct infection in a similar manner, or from inadvertently carrying to the face a cloth or handkerchief which has been in contact with the nostrils of a glandered subject. If the infection take place by a wound in the skin, as is usually the case, or by the digestive tract, as is not infrequent, the manifestations of coryza and sore throat appear during the second or third week, or even later. Coryza usually precedes the sore throat, but is by no means universal. The coryza is often unilateral. The discharge is at first serous, then muco-purulent, purulent and sanious; and it is fetid in odor. The nose is swollen, congested, and painful; and is surrounded by diffuse hyperæmia of the adjoining parts of the face. The sore throat is manifested synchronously with the coryza or quickly follows it; and the inflammation extends over the entire tract of contiguous mucous membrane, from conjunctivæ to larynx. Ulceration soon occurs in the mucous membrane of the mouth, pharynx, and larynx; and the lymphatic glands (sublingual and submaxillary) in anatomical connection with them soon become swollen and tender, and sometimes undergo suppuration which discharges externally by abscess. Gangrene is imminent, and may destroy large portions of the soft and hard tissues of the nose, nasal septum, palate, pharynx, and larynx, with all the concomitant dangers of sudden fatal hemorrhage.

Symptoms.—The symptoms are those of coryza, sore throat, and laryngitis: snuffling, nasal obstruction and discharge, pain and impediment in swallowing, excessive loss of saliva, hoarseness, pain in speaking, dyspnœa, cough, and expectoration.

Diagnosis.—This will be based upon the history of proximity to a glandered animal. The disease may be confounded with syphilis or tuberculosis if mere inspection be relied on.

Prognosis.—This is unfavorable, recovery being rare, and when occurring it is slow, and followed by permanent deformity and increased susceptibility to affections of the throat and air-passages.

Treatment.—This will be the same as for any other form of ulcerous or malignant sore throat.

THE SORE THROAT OF STOMATITIS.

In *acute catarrhal stomatitis* the sore throat is a simple catarrhal inflammation, which may involve the uvula, palate, palatine folds, and tonsils.

In *ulcerous stomatitis* the sore throat is marked by superficial ulcerations (aphthous ulcers), chiefly on the palate.

In *mercurial stomatitis* the sore throat is an ulcerous sore throat, usually confined to the pre-coronoid portion continuous with the gums and floor of the mouth. The ulcerations on the palate and pharynx sometimes seen in mercurial stomatitis are of syphilitic origin, and not the result of hypermercurialization.

In *thrush* the sore throat is chiefly pharyngeal, and the inflamed surface is coated by the same vegetation that coats the mouth. It is said that this fungus forms only on squamous epithelium,¹ which is given as the reason why it is sometimes found in the œsophagus, and never in the larynx and trachea.

¹ Reubold, quoted by Vogel, Ziemssen's Cyclopædia, N. Y., 1876, vi., p. 801.

CHAPTER IV.

SYPHILITIC SORE THROAT.

SYPHILITIC sore throat is usually a deuteropathic manifestation of systemic poisoning ; but it is sometimes the result of direct inoculation from primary chancres on the lips, tongue, cheeks, and hard palate, produced by actual contact. The initial sore has been seen, in some instances, on the tonsils, palatine folds, and even the pharynx, and at least one instance has been recorded of a chancre on the lingual surface of the epiglottis.¹

Secondary symptoms are sometimes communicated by the kisses or bites of infected individuals ; they have been known to follow the drawing out of the nipple of the parturient female, by suction with the mouth of a syphilitic nurse. Children are sometimes contaminated from the nipple of the nurse. Some observers believe that syphilis can be communicated to the mouth of the infant through the medium of the milk,² but it appears doubtful that infection can occur in this way. It is also occasionally propagated by the use of certain instruments placed in the mouth, such as the blowpipe, tobacco-pipe, trumpet, etc., passed from one companion to another, and sometimes by tasting food or drink from a vessel in use by an infected individual. With other observers, I have known it to be communicated by the incautious use of the Eustachian catheter, and have seen fatal ravage in consequence.

Dr. Alfred Fournier, in a lecture on the treatment of syphilis, relates the case of a child inoculated with syphilis in catheterization of the Eustachian tube, and in whom, five years later, a gummy tumor of the velum, and necrosis of the nasal

¹ Krishaber, mentioned by Isambert, *Conférences cliniques sur les maladies du larynx et des premières voies*, Paris, 1877, p. 121.

² A. Drou, *Propagation de la Syphilis par les nourrices. Mode particulier de transmission de la Syphilis au nourrisson par la nourrice dans l'allaitement*, Lyon, 1870, p. 45.

bones were developed. The child lost her velum; and her nose became destroyed and flattened.¹

Chancre on the lip and tongue is usually hard, but soft chancre is also encountered, and cases occur where, lips and tongue being involved, a considerable portion of the latter organ becomes the subject of extensive and loathsome phagedenic ulceration. Chancre on the tonsil is usually soft.

Chancre on the lips and tongue might possibly be confounded with epithelioma and furuncle; but the appearances of the latter are so characteristic that, taken in connection with the sort of individual likely to be the subject of chancre about the mouth, a mistake in diagnosis is hardly probable. These primary manifestations are said to be often difficult of differentiation from tuberculous and cancerous ulcerations, psoriasis of the mouth, and the "milky patches" of smokers.² I have seen tuberculous ulcerations that closely resembled chancre. These cases are not seen early as a usual thing; for shame on the one hand, and ignorance on the other, are likely to deter the patients from applying for medical treatment until they find it absolutely necessary in order to control the ravages of the disease.

Syphilitic diseases of the throat are much more frequently secondary and tertiary manifestations—secondary more especially; although the characteristics of the two forms are less well defined than in other parts of the body. Secondary manifestations are more apt to occupy both sides of the throat, and tertiary manifestations to be unilateral. Where a primary sore is acknowledged, the lapse of time will be an important element in the discrimination, as will also the evidence of syphilitic disease in the skin. Some syphilitic affections of the throat are similar to those of the skin, and others are peculiar to mucous membrane.

The anterior portion of the soft palate is perhaps the earliest and most frequent seat of syphilitic inflammation of the throat, which begins usually near the border of the hard palate and spreads downward upon either side, though sometimes travelling along the hard palate also. It may commence, however, in the posterior surface of the soft palate or in any other portion of the throat or adjacent parts. Separate blotches are

¹ N. Y. Med. Jour., Aug., 1872, p. 149.

² Isambert, *op cit.*, p. 121.

not observed as frequently as a diffused redness without any other distinct line of demarcation than the general circumference of the inflamed tissue. This erythematous condition gradually extends along the palatine folds, presenting the aspect of ordinary catarrhal inflammation, sometimes projecting beyond the general surface. Sometimes it is distributed in irregular patches, the intervening membrane looking normal. At a more advanced stage swelling of the affected parts ensues, with a gradual change to a livid color, the central portion of the circumscribed swelling becoming opalescent from distention of epithelial cells, then opaque, forming a mucous patch resembling a surface which had been subjected to the local action of nitrate of silver. The uvula and posterior palatine folds are apt to become covered more or less irregularly with these patches, but their most frequent seats are the lips, tongue, inside of the cheek, and soft palate, though they may occur on the gums, the surface stretching between the posterior alveoli of the two jaws respectively, the palatine folds, the tonsils, or the pharynx. The movements of the palate become impeded by the interstitial deposit going on in its tissues, so much so, occasionally, as to amount to complete paralysis. The follicular glands of the palate and uvula become enlarged and prominent, and the uvula often markedly œdematous. Sometimes the submaxillary glands become engaged. In some cases the base of the tongue, floor of the mouth, and epiglottis become attacked. In exceptional cases the early secondary manifestation of secondary syphilitic sore throat is an erythematous laryngitis, and is especially encountered in persons who use the voice a great deal. There is often slight infiltration of the mucous membrane of the parts, preventing due tension of the vocal cords, and the voice is restrained almost to a monotone, but this occurs in simple catarrhal laryngitis and is not peculiar to syphilis. Mucous patches have been discerned in the larynx by some observers, while others deny their occurrence absolutely. The tonsils are apt to undergo tumefaction, though not often to a marked extent; but they are red, dense, irregular in outline, and soon become covered with a tenacious secretion that often adheres in strands to their lacunæ. These hypertrophied tonsils are sometimes the seat of condylomata, which often indicate the coexistence of similar vegetations elsewhere. The subjective symptoms at this time are discom-

fort and dryness of throat, hawking and expectoration, moderate pain, and slight dysphagia, with some impairment of voice if the larynx is involved.

In the further progress of the disease the inflamed follicles of palate and tonsils undergo ulceration; separate ulcers coalesce by extension, often rapidly; and the gums, tongue, and epiglottis are sometimes simultaneously in a similar condition. The ulcers are soft, and are usually excavated. Their edges are sharp, their bottoms covered with grayish aplastic lymph, sometimes decidedly pellicular; and they are surrounded by a demarcating border of inflamed membrane. At first they are rather superficial, but they soon implicate the entire mucous membrane and penetrate irregularly into the submucous tissues.

In the acute sore throat of tertiary syphilis, after slight erythematous sore throat, gummous tumors (syphiloma) may form in the connective tissue, break down, suppurate, and give rise to deep-seated ulceration. They often form at the sides of the root of the uvula, and appear as small, inflamed nodules of varying size, from small shot to small peas, eventually acquiring a peculiar lustrous tint, and becoming pustular before they rupture through the tense and translucent mucous membrane. It is conceded that they occur likewise in the tonsil, but the evidence of observers is by no means uniform. They also occur in the pharynx.

Sometimes abscesses are formed, principally in the palate, palatine folds, and tonsils; and these finally rupture and discharge, leaving foul ulcers. The uvula is sometimes destroyed at its root in the ulcerative process; and ulcers in other portions of the palate often penetrate its entire thickness in their ravages; sometimes in its central portion, sometimes to one side or the other, so that not unfrequently comparatively large portions of the folds are destroyed in consequence. In some instances this destructive process proceeds with great rapidity, a period of forty-eight or even twenty-four hours sufficing to complete the perforation. The ulcerated tonsils bleed readily under the finger, and may undergo entire destruction. In addition to this, the pharynx often becomes equally involved, in many instances undergoing ulceration, which, in cicatrization, culminates in permanent adhesion between the sides of the palate or its posterior fold, and the

wall of the pharynx. The stellate form and whitish lustre of these cicatrices are quite characteristic. The occlusion thus produced may shut off the nasal portion of the pharynx entirely, and leave such a small channel of communication between the mouth and lower portion of the pharynx as to prevent the deglutition of solid articles of food. The ulcerative process sometimes extends to the perichondrium of the cervical vertebræ, leading to caries, necrosis, abscess, and exfoliation of dead bone. Even inflammation of the spinal cord has been recorded, producing paralysis of the arm. The tongue, gums, lips and cheeks may also participate in the process, so that there is ulceration of all these parts at once, or in prompt succession. Extending from the pharynx, or from the posterior portion of the velum, the diseased process may involve the pharyngeal extremity of the Eustachian tubes, and not unfrequently continue along the tube into the tympanum. The inflammation thus excited may even be propagated to the intercranial tissues proper, though more frequently rupture of the membrana tympani ensues, giving vent to purulent discharges through the external auditory meatus; at other times, extending up the retro-nasal portion of the pharynx, it may attack the cranial bones, destroy portions of them, and, reaching the inter-cranial organs in that way, excite meningitis or cerebritis. The mucous membrane of the nose is often attacked also, and disease here may implicate the nasal duct and produce specific inflammation of the conjunctival mucous membrane. The affection of the nasal mucous membrane may extend to the cartilages and the bones, and produce caries and necrosis, often followed by permanent deformity. In tertiary syphilis the disease of the bones sometimes precedes the implication of the mucous membrane. The disease in many instances extends to the larynx, which is also often affected primarily and independently.

The larynx usually becomes involved by extension of the disease from the anterior folds of the palate (Figs. 49 and 50), and all the phenomena of syphilitic inflammation may ensue, leading to extensive ulceration and necrosis. The epiglottis is quite prone to suffer, and there may be great loss of its substance, or even entire loss of it. The syphilitic ulcerative process attacks the aryteno-epiglottic and meso-arytenoid folds, the ventricular bands, and the vocal cords, sometimes sepa-

rately, sometimes together. This ulceration may penetrate to the cartilages, bare them, and work their destruction. In other instances the process may begin in syphilitic perichondritis or chondritis, and implicate the mucous membrane during the exfoliation of the necrotic tissues. Large portions of cartilage are sometimes destroyed, and even entire cartilages. During this process œdema of the larynx is very apt to be produced. The cicatrization of laryngeal ulcers often eventuates in permanent constriction of the laryngeal orifice, and sometimes, even though the glottis is not directly implicated, necessitates the operation of tracheotomy, with almost always the permanent use of the canula.

The trachea also is liable to the manifestations of syphilis; and the ulcerative process may involve its cartilages as well as its mucous membrane.

Syphilitic warts and excrescences are often developed in the larynx. They are frequently small, multiple, and sessile; but they may acquire the size of a hickory-nut, almost filling up the upper cavity of the larynx. Sometimes they exist as flat bands hanging into the glottis, or pendent from the vocal cords. They may occupy any portion of the larynx.

I am unable to recognize anything absolutely characteristic in the appearance of syphilitic disease of the larynx, whether simply erythematous or ulcerous. Some authors claim ability to detect syphilitic inflammation by the unaided eye alone. Advanced cases are recognizable, as the irregular aspect of the ulceration is similar to that of syphilitic ravages in the skin; but in cases not far advanced or of moderate severity it is extremely difficult, to say the least, to determine the syphilitic nature of a laryngitis from its mere aspect. A chronic laryngitis in a constitution undoubtedly free from tuberculous disease of the lungs, and especially in the absence of evidence of struma, is almost presumptive evidence of its syphilitic nature. And the same may be said of the ulcerative form, if it can be traced to no other actual cause. There are some cases which simulate cancer in their appearance, but the absence of the lancinating pains attending malignant disease will usually serve to eliminate the latter from the diagnosis.

Sometimes, however, as in a case from my practice (Figs. 49 and 50), the disease not only simulates ulcerative epithelioma in its appearance, but even in the lancinating pains,

which, in the instance referred to, were constant—much more constant than is observed in cancer—causing the patient, a man aged thirty-one years, to twitch his head toward the side affected every few seconds from morning until night, whether talking, eating, or at rest, and this for weeks together; for he did not come under observation until a late period of the affection, after the disease had committed the ravages depicted in the illustrations, ravages which finally destroyed the entire palate and epiglottis.¹

Symptoms.—The symptoms of syphilitic sore throat are those of inflammatory sore throat of like grade, and vary in severity more with the locality of the inflammation than its intensity; pain being severer in inflammation of tonsils and epiglottis than in that of the pharynx; swallowing being most difficult in involvements of the epiglottis, and in ulcerations of the parts engaged in deglutition; hoarseness existing when the interior of the larynx is involved; and the salivation, cough, and character of the expectoration depending upon the sensitiveness of the parts, and the activity and extent of the secretory and suppurative processes, and their admixture with blood from hemorrhage of the small vessels. There is often a peculiar fetor of the breath. The voice acquires a peculiar clang when the soft palate is tumid, the tonsils swollen, and the palate perforated.

The accidents liable to take place in other forms of sore throat—suffocation, hemorrhage from ulceration into large ves-

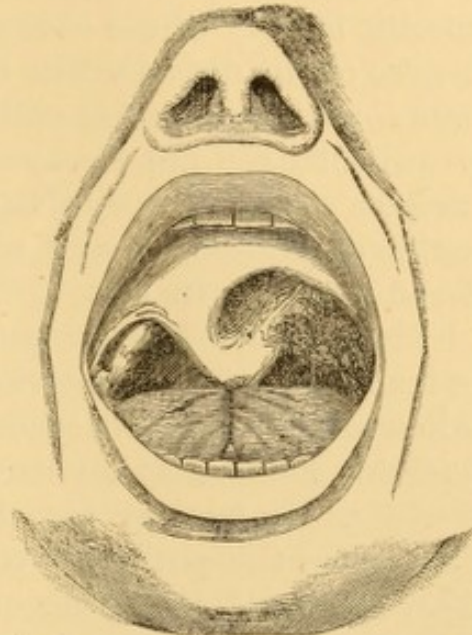


FIG. 49.—Syphilitic ravages in the soft palate, tonsil, and lateral pharyngeal wall.

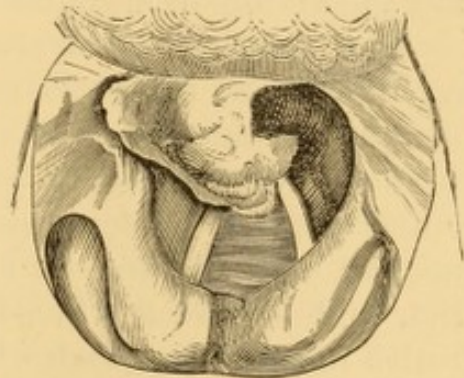

FIG. 50.—Syphilitic ravages in epiglottis, and lateral laryngeal wall (in same case as Fig. 49).

¹ See, in this connection, remarks on a case of inherited syphilis of the nose simulating epithelioma. Prof. Gross' Clinic, Phila. Med. Times, July 15, 1871.

sels, etc.—are imminent in similar grades of syphilitic sore throat also.

Diagnosis.—The diagnosis, except, perhaps, when mucous patches exist upon the tonsils and palate, will depend upon the specific history of the case and the coexistence of external evidences of the disease. The disease may be mistaken for scrofulous sore throat or for epitheliomatous sore throat. Specific treatment does not always clear up the doubt in these cases, because many non-syphilitic sore throats are benefited by iodide of potassium, and some syphilitic sore throats are rendered worse by its use.

Prognosis.—The prognosis is good as to integrity of parts in secondary sore throat, except where extensive ulceration has taken place, in which case there may be sudden fatal or exhausting hemorrhage, vicious adhesions, or permanent imperfections. In tertiary sore throat the prognosis is good as to life, unless the patient is very much debilitated by exhausting discharges and inanition, or there is some serious lesion. The prognosis, as to ultimate integrity of tissue depends upon the extent of lesion, the amount of residuary constitutional vigor, and the ability of specifics to control the morbid processes.

Treatment.—The treatment of the constitutional forms of syphilitic sore throat is very simple, and, if the constitution has not become too debilitated, usually successful, even when the local disease is of great extent and severity. If well nourished, the patient may be placed under specific treatment at once; if not, he should be fed with good, nutritious diet, and be given wine, iron, and quinia until his general health has become somewhat re-established, and then specific treatment may be advantageously instituted. Sometimes these tonic measures are so efficacious that specific treatment is rendered unnecessary. The specific remedy is mercury in secondary cases, and iodide of potassium with small quantities ($\frac{1}{16}$ – $\frac{1}{8}$ grain to the dose) of bichloride of mercury, or its equivalent in tertiary cases. In urgent cases of threatening perforation of the palate, the iodide is required in large doses (30–90 grains at intervals of eight hours) to check it, but the patient must be watched, as œdema of the parts is occasionally produced by large doses of iodide of potassium; and if this involve the larynx, as it sometimes does, asphyxia may prove fatal before there is chance for surgical interference.

As soon as a positive impression is made on the parts, sometimes evident in thirty-six hours, the iodide should be reduced to the medium dose (5-10 grains). Sprays are used to cleanse the parts. The bichloride of mercury (gr. $\frac{1}{4}$ ad f. $\frac{5}{8}$ j.) can be used in aqueous solution for the purpose. Sulphate of copper, in strong solution or in crystals, is an excellent local agent. Locally, daily swabbing the parts with acid nitrate of mercury, pure or reduced, in deep ulcerations, and diluted with four, ten, or twenty parts of water, in superficial ulcerations and in mucous patches, or employed in spray, as circumstances may indicate, will usually be found fully efficient as a topical remedy in those cases in which topical remedies are required, for they are often unnecessary. Pendent portions of the ulcerated uvula should not be unnecessarily excised, even when the connecting tissue is quite delicate, as readhesion often takes place promptly if the system responds to the influence of the iodides. If œdema be present, the parts must be scarified, or ruptured by compression; after which a solution of the nitrate of silver may be employed upon them. Should the œdema recur, it must be treated as before. Should symptoms of suffocation supervene which cannot be subdued by less urgent measures, the operation of tracheotomy is indicated. Necrosed bone or cartilage should be removed. I know of no effectual method of preventing threatening adhesion of contiguous parts in cicatrization. Astringent applications in the form of spray, or washes, should be freely used by the patient if there be a great deal of discomfort from swelling and inflammation of the parts. Fœtor is controlled by the local use of detergents and disinfectants in the same way.

The prolonged and repeated use of iodides is indicated to prevent recurrent tertiary manifestations, the same as in other forms of constitutional syphilis.

SYPHILITIC SORE THROAT IN INFANTS.

Congenital manifestations of syphilitic sore throat in the infant are usually in the form of mucous patches, which occupy the palate, the palatine folds, the tonsils, and sometimes the pharynx; occasionally the larynx also, to judge from the hoarseness of the infant's cry. At the same time the mucous membrane of the mouth generally may be implicated.

Much more frequently, however, the disease is manifested in the form of a fibrinous coryza, which, in accordance with the opinion of Diday and others, is probably due to the development of mucous patches upon the mucous membrane of the nose. The earliest evidence of the disease is then some impediment to free nasal respiration, and consequent embarrassment in nursing; the symptoms being similar at first to those of ordinary coryza. After a short time, a thin serous liquid drips from the nose, soon becoming thicker, purulent, and somewhat sanguinolent. The lips sometimes become excoriated by the acridity of the discharge. The nasal passages become more and more occluded, and as this condition increases, the child, while suckling, is forced to take rapid inspirations through the nose; this dries up portions of the secretions into crusts, which are discharged from time to time with more or less hemorrhage. Finally these crusts accumulate more rapidly than they can be discharged, and complete obstruction of the nose ensues. When this is the case, great difficulty is experienced in nourishing the child, because it is unable to breathe while at the nipple. It seizes the breast eagerly, but is compelled to drop it almost immediately, and is thus rendered cross and fretful. As the disease progresses, specific pustules, fissures, and ulcers become developed upon the alæ of the nose and upon the lips, and at the angles of the mouth, and extend outward upon the cheek along the natural fissures of the skin.

In this manner, sometimes, peculiar striated appearances are produced, which, according to Prof. Trousseau,¹ are characteristic of syphilis, and are true mucous crusts, though not exactly of the same aspect as in the adult; their size being smaller the greater their distance from the mucous membrane of the lips; their edges are finely fringed and blackened by the adherence of coagulated blood; and they have gristly and bleeding bottoms more or less bright red in color. Prof. Trousseau states that they often leave indelible cicatrices after recovery, and that he has seen young men and young women still carrying these scars—stigmata the nature of which they did not suspect.

As the disease of the nasal passages progresses, ulceration takes place in the structures of the nose also, often destroying the cartilages and the bones, fragments of which are thrown off with the crusts. In this way the septum often becomes perforated, and sometimes the nose flattened. Some cases of so-

¹ Clinical Lectures, vol. iv., Sydenham So. Ed.

called scrofulous perforation of the septum in the adult are of infantile specific origin. Sometimes the general system is poisoned by the exhalations of the decomposing secretions in the nose, and death ensues in consequence. This syphilitic coryza is sometimes the only manifestation of hereditary syphilis, and, according to Trousseau, the earliest sign of the disease in almost every instance.

The treatment of syphilitic diseases of the throat in the infant is essentially similar to that of syphilis in the adult. Care must be taken to sustain due nourishment of the child and to place it under favorable hygienic influences. To this end a healthy wet-nurse is a great desideratum. It is conceded on good authority, that a syphilitic wet-nurse is admissible provided she is placed under specific treatment, that is to say, mercurialized. When the child cannot be nursed, the milk of the cow, or other animal, is administered by the spoon. The child should be kept in a warm temperature, be clad with woollen underclothing, and great care should be taken in maintaining cleanliness of the skin and in prompt removal of the secretions. Ablutions should be practised more frequently than with healthy infants. A mercurial course appears to be indispensable, and the most efficient article, as with the adult, is found in the bichloride of mercury, which may be given in solution with syrup, in divided doses, to the amount of one-twelfth of a grain or rather more daily, until some sign of inflammation is observable upon the gums, or until the characteristic odor is perceptible in the breath, at which time the quantity of the mercurial may be slightly diminished, though not to a greater extent than is necessary to maintain evidences of its specific action. Mercurialization may be accelerated by frictions to the chest of the mild mercurial ointment, or by the method of Brodie, which is to smear a flannel jacket with the ointment and wrap it around the thorax, trusting to the natural movements of the child for its friction into the skin. A bath mercurialized by dissolving half a drachm of the bichloride of mercury in it, may be employed every two or three days, according to the indications. If the mercurial irritates the intestinal canal, its administration by the mouth is to be suspended for a while, and more attention paid to its use by the bath. In addition to the mercurial treatment, it is often advantageous to administer the iodide of potassium in some

pleasant syrup, in doses from three-fourths of a grain and upwards, according to the age and strength of the patient and the promptness of its effects. The appearance of albumen in the urine indicates suspension of the iodide.

Local treatment is often requisite in addition, as the infant is unable to free the parts of the secretions. The mouth and throat may be swabbed out with alum or borax, or with honey impregnated with a mineral acid. If this be inefficient, the diseased parts may be gently touched with the nitrate of silver, in stick or in solution, care being taken to avoid too extensive an application at one time; and this application may be repeated at intervals of two or three days, according to the indication.

To free the nasal passages, the syringe or spray-douche should be employed several times a day, and when topical medication is necessary, the warm water for cleansing purposes may be impregnated with bichloride of mercury, chlorinated soda, chlorine water, or carbolic acid. Weak mercurial ointment, and ointment of iodoform (five grains to the ounce), if there be no active inflammation, may be applied locally several times a day, by means of a mop, hair-pencil, or feather.

CHAPTER V.

DIPHTHERIA.

DIPHTHERIA appears to be a systemic disease of adynamic type, with a primary local pathological manifestation consisting in certain more or less characteristic exudative deposits in and upon the mucous membrane common to the alimentary and respiratory tracts. Thence, the local manifestation is apt to extend irregularly, sometimes in a continuous layer, sometimes from separate points of departure, along the larynx, trachea, and bronchi, or along the œsophagus and stomach in one direction; or along the walls of the naso-pharyngeal cavity into the posterior nasal passages, Eustachian tubes, nasal duct, and maxillary and frontal sinuses, in the reverse direction; sometimes, indeed, progressing simultaneously in both directions.

The morbid process is acute in its course, specific in its origin, irregular, though tolerably definite in its duration, and propagable by contagion.

The disease is essentially endemic in character, though sometimes sporadic, and often epidemic. One attack does not insure immunity from subsequent attacks, and the previous existence of any other disease does not afford any immunity from an attack of diphtheria.

The exudative products vary in consistence from a state of translucent diffuence to that of opaque, tough, tense, elastic, continuous pseudo-membrane several lines in thickness—the increase in density being, in most instances, proportionate to the length of time during which they have existed. They vary in extent from minute films or specks to complete casts of more or less of the entire tracts along which they may have become developed; this increase, likewise, being proportionate to their age, to a certain extent. It is but rarely that the deposit is circumscribed; it is almost invariably diffused over a smaller or greater extent of surface.

The same kind of local manifestation of deposit is liable to become developed upon other mucous surfaces, in addition to those mentioned, and furthermore, upon any abraded portions of the cutaneous surface also. It is said even to be found, at times, within the interior of organs which have no communication with the exterior of the body ; such organs for example, as the heart and the spleen, and the brain.

The lymphatic glands, in anatomical connection with the surfaces on which the local manifestation occurs, are always involved in the morbid process, if it is at all active.

The products of decomposition of the exudation in the throat may be absorbed into the system, and occasion septicæmia in some instances.

In cases of unusual virulence there is ulceration, sphacelus, and gangrene of the affected mucous membrane—destructive processes which are liable to involve the contiguous tissues also. Arterial vessels may become perforated thereby, and hemorrhage be thus superadded to the intrinsic dangers of the disease.

The tendency of the disease is to death by asthenia, from the toxic effects of the systemic disorder ; or to death by asphyxia, from accumulation of the exuded products in the respiratory tract, or simply from unfavorable incidental position or detention of these products, even when not present in great quantity.

Certain specific sequelæ of nervous character, though not constant, are apt to follow in diphtheria. These are : paralysis of certain of the muscles concerned in deglutition ; once in a while of the muscles of phonation ; occasionally of the muscles of the heart ; not unfrequently of the muscles of visual accommodation ; and sometimes of the muscles of the limbs, and of other portions of the body ; in some instances amounting to general paralysis—the paralysis following the state of convalescence from the general malady, rather than accompanying the acuter phenomena of its evolution. Some observers recognize a nervous element in the acute phenomena, to which they attribute a portion of the impairment of respiration manifested at a certain stage of the affection.

Many experienced observers consider diphtheria identical with what other experienced observers recognize as acute pseudo-membranous or true croup.

Persons of all ages¹ are liable to the disease, but it is much more frequent in children between the period of weaning and the tenth year of life, than in adolescents and adults. It seldom attacks individuals in absolutely first-rate health, while living under good hygienic influences, unless they have been more or less directly exposed to contagion from contact with a diphtheritic patient, or with emanations from his body, whether contained in clothing, utensils, excretæ, or the exudation itself. It rather attacks individuals debilitated, or in process of debilitation from over-work, excessive mental activity, disease, abstinence, indulgence, neglect, or ochlesis; and especially such as are subject to sore throat, acute or chronic, particularly if the mucous membrane of the throat is in part denuded of epithelium. It seems to be but little influenced by season or sudden change of weather, though damp and raw atmospheres apparently increase its liability to extend to the respiratory tract, or even to make its primary local manifestation in the air-passages proper. It is often present under morbid agencies similar to those that occasion typhoid fever, septicæmia, and other morbid processes of adynamic character.

There seems to be abundant reason to suspect a specific cause of diphtheria; but the nature of this cause is as yet undetermined, despite numerous experimental and clinical investigations undertaken for the purpose of its discovery. This cause is generally believed to be due to contamination of drinking-water and the air of dwellings with the emanations from cesspools, slop-heaps, waste-pipes, and imperfectly ventilated sewers. There is reason to believe that the development of diphtheria is accompanied by, if it is not in part due to, the development of atmospheric cryptogamia poisonous to the human economy, which gain access to the pharyngeal or nasal mucous membrane in the acts of inspiration, or perhaps to the pharyngeal mucous membrane, or even to the epiglottis, in the acts of deglutition. It must be conceded, however, that the fact that the respiratory mucous membrane itself is rarely inoculated in this way, and that the nostrils, though the main respiratory tract, are rarely primarily affected by the exuda-

¹ It has been observed in the new-born babe.—Marshall: Schmidt's Jahrb., civ., p. 324; Jacobi: Contributions to the pathology and therapeutics of diphtheria, Journal of Obstetrics, N. Y., Feb., 1875.

tion, militates against the plausibility of this popular and fascinating theory.

Once transplanted in the warm and moist nidus of the mucous membrane, it is supposed that the rapid self-propagation of the vegetable organism is facilitated; and that the poisonous germs or emanations eventually become absorbed into the blood, or make their way—by actual boring, according to some microscopists—into the lymphatic system, and thence enter the current of the circulation. Once in the blood in sufficient quantity, a systemic poisoning ensues; and this poisoning constitutes the essential element of the diseased actions that subsequently take place. One effect of the poison is the establishment of a low grade of inflammatory action in the mucous membrane, attended with the exudation, deposit, exfoliation, or slough of a fibro-plastic material, similar, as far as has been positively ascertained by microscopic and chemical observation, to the false membrane exuded in croup; similar, too, it is believed by most authorities, to the plastic exudatory slough which follows the local contact of cantharides, ammonia, hydrochloric acid, boiling water, and other vesicants.

If the latter hypothesis be verified, it would favor the inference that the so-called deposit is not altogether an exudation, but rather an exfoliation of destroyed layers or masses of mature and immature epithelial cells. Indeed, Prof. Virchow has maintained the view that the pseudo-deposit is not an exudation, but that it consists of cast-off tissue elements, and especially cells which have become rapidly filled with certain turbid contents, and have then undergone fatty degeneration.

The comparative immunity of children at the breast is attributed by certain observers to the inability of the presumably specific organisms to preserve their viability in the acids continually present in the mouths of nursing infants.

Vegetable organisms were detected in the membrane of diphtheria by Remak (1845), Vogel, Jodin, and many others; and their acceptance as the local cause of the disease is still maintained by more recent authorities, most emphatically by Oertel. It would hardly repay us to enter into any minute discussion on this undecided point. Suffice it to say, that there is no doubt that these vegetable parasites, no matter in what stage of transformation they may be observed, are present in great numbers in diphtheria; although a few authorities

have denied the fact.¹ But bacteria have been known to be normally present in the mouth, since the investigations of Leeuwenhoek (who published an account of them in 1684); and with regard to those forms now termed micrococci, so minutely described of late years, the same sort of bodies have been found² in abundance in all inflammatory products, diphtheritic and non-diphtheritic, which have remained for some time upon the surface of the mucous membrane of the mouth, palate, and pharynx. It is therefore, to say the least, extremely doubtful that the specific cause of diphtheria has yet been detected.

Doubts have been expressed concerning the infectious nature of diphtheria, but fatal proofs of direct contagion have been too frequently recorded in the necrological notices of members of our own profession—and need we go further?—to leave any doubt on that score. From the time of Bretonneau, who, some fifty years ago, first discriminated diphtheria as a distinct affection, hardly an author of note has written upon the subject without mentioning the names of some medical victims, whose memories demand a passing tribute of respect whenever the question of contagion is broached. On the other hand, it must be admitted that a number of careful experimenters, with the illustrious Trousseau at their head, failed utterly in their attempts to infect themselves with the morbid material, whether simply placed upon their own mucous membranes, or deposited beneath them in wounds made for that purpose. Thus, then, though often contagious, the poison of diphtheria is not always inoculable. It would seem that there must be a condition of system favorable to the development of diphtheria; otherwise we can hardly account for the immunity of certain families, or certain individuals, when subjected to conditions apparently identical with those which have been followed by the development of diphtheria in other members of the family, or in other inmates of the household. The more virulent a case of diphtheria, and the more abundant the secretions, the greater the liability to infection. Virulent cases,

¹ Sir William Jenner (*Diphtheria and its Treatment*, London, 1861, p. 58) is certain vegetable growths were not present in several cases he examined.

² Wilks: *Med. Times and Gaz.*, Oct. 2, 1858; Drs. Heitzmann and J. Lewis Smith: *Virginia Medical Monthly*, Feb., 1875.

however, may result from infection originating from mild cases.

Apart from the contagion resident in the exudations themselves, and in the secretions and exhalations generally, diphtheria is also contagious through the atmosphere. Lack of cleanliness increases the liability to contagion. Certain localities, sometimes certain houses, and even certain apartments, seem to retain the contagion, even in the absence of any other evidence of its continuance or existence in the neighborhood. Hence some authorities consider the specific poison to be miasmatic in character. That it may be communicated from one person to another, or from one locality to another by infected individuals, there is abundant evidence; and there is some evidence, to which I might add a few personal observations, of its being propagated from an infected locality or an infected individual, to another locality or to other individuals, through the medium of attendants or visitors who remain uninfected. Thus, though infectious, the virulence of the infection is less than that observed in other infectious disorders.

Though Bretonneau failed in his endeavors to communicate diphtheria to the lower animals, the evidence of competent veterinary surgeons of the present day favors the view that domesticated animals are not unliable to the infection.

Course and Symptoms.—The period of incubation, or the period intervening between exposure to the infection and the manifestation of the disease, varies from two to five days; though some observers have encountered instances in which the period seemed to have extended to ten, twelve, and even fourteen days, and others have reported instances in which the incubatory period was even less than two days.

After the deposit is first seen in the pharynx, its extension to the epiglottis and to the interior of the larynx, in cases in which the air-passages become involved, may usually be observed within twenty-four hours. In twenty-eight out of twenty-nine cases noticed by Bretonneau, the laryngeal symptoms supervened before the end of the first week; and in sixteen of them, on or before the third day of illness. Most authors state that laryngeal symptoms always commence before the expiration of the first week of the disease. Oertel mentions that he has observed this extension in protracted cases even on the thirteenth and fourteenth days.

The constitutional symptoms, when fully developed, are adynamic in character, there being, as a rule, comparatively little febrile excitement, but rather general depression and nervous debility. Initial fever certainly occurs in some instances, previous to the development of the characteristic local phenomena; but in many other instances there is no initial fever whatever, or at least no subjective symptoms indicative of the true febrile condition. The fever is often transient, even in severe cases, and is usually soon followed by evidences of depression. Sometimes the initiatory manifestations are so slight as to attract but little attention, or even none at all. Indeed, cases are not altogether infrequent among adults, in which patients continue engaged in their ordinary avocations during the development of the disease, and during more or less of its progress; the nature of the affection becoming ascertained only at a relatively late period, and often too late for the institution of measures which might otherwise have possibly averted a fatal termination.

In cases in which the initiatory febrile condition exists, there is elevation of the body temperature, greater at night than during the daytime. Marked elevation of temperature (4° – 7° F.) is usually indicative of severity, heralding a case in which the local manifestation is likely to extend to the respiratory tract. A more moderate increase of temperature (3° – 5° F.), on the contrary, is by no means indicative of a milder form of the affection, or of less liability of this extension of the exudation.¹

Wakefulness and restlessness at night is not uncommon, and in young and feeble children may be associated with delirium and convulsions. The pulse is full and abnormally frequent, in some instances amounting to 130–140 beats in the minute, and usually unassociated with corresponding increase in the number of respirations. It is not, however, firm and hard, as is usual in purely inflammatory affections, but is soft and compressible. The skin is sometimes hot and dry, at others moist and cool, or becomes cooler as the disease progresses. The face is congested, and the conjunctivæ are often suffused. The tongue may be moist and but slightly coated, or, as is more frequent, it may be dry and much coated, espe-

¹ See a paper on Clinical Thermometry in Diphtheria, by J. G. Richardson, M.D., Medical Record, N. Y., July 15, 1867, p. 217.

cially posteriorly. The appetite usually fails early, and there may be evidence of gastric and even of intestinal disturbance, sometimes amounting, eventually, to vomiting and diarrhoea. The urine is scanty, of high specific gravity, and acid in reaction, with increase of urea; microscopic examination usually affording evidence of tube-casts, and, in occasional instances, of blood-corpuscles; while uric acid, the urates, oxalates, and sometimes phosphates are to be detected in the sediment. In some instances there is temporary arrest of the secretion. Albuminuria is of frequent, though not constant occurrence. It is usually of early appearance, sometimes first noticed about the time of the onset of the laryngeal symptoms, sometimes not until a later period, even as late as the end of the second or third week. The quantity of albumen often varies greatly from day to day, sometimes amounting to from one to two or three drachms in the twenty-four hours; and although it usually remains throughout the disease, it may disappear and reappear again and again, its traces gradually becoming fainter during convalescence. Other things being equal, the amount of albuminuria may be regarded as proportionally indicative of the severity of the affection and of the probable paralytic sequence. The albuminuria is usually due to renal changes, as well as to changes in the condition of the blood.

There is, as a rule, more or less sore throat, characterized by moderate tumefaction, and more or less vivid congestion of one or more of the following named structures: tonsils, palate, palatine folds, uvula, and pharynx, usually upon one side only, but sometimes upon both. The redness may extend over the entire surface, and may or may not be associated with an excessive accumulation of mucus. If one side is unaffected at first, it is apt to become involved at a subsequent period. The submaxillary and cervical glands of the side affected soon become swollen, and tender or even painful to moderate pressure; but they are not tense and hard, except in very severe cases. This swelling and tenderness is usually altogether greater than would appear explicable simply by the extent and intensity of the inflammatory lesion; but some observers¹ have found that

¹ Among others, Moynier: *Compte rendu des faits de diphthérie*, etc., Paris, 1859, p. 34. Jenner: *Diphtheria; its Symptoms and Treatment*, London, 1861, p. 7. Oertel; *Ziemssen's Cyclopædia*, New York, 1875, vol. ii., p. 600.

the enlargement of the glands has been proportionate to the severity and depth of the local lesion. Sometimes, indeed, as noticed by Bretonneau and Trousseau, the glands suppurate externally. In ulcerative cases there is sometimes serous and even fibrinous infiltration of the connective tissue surrounding the glands, so that the external tumefaction is immense. It has been noticed, in some epidemics, that the tumefaction of the glands has preceded the local manifestations in the throat; a point which is not to be lost sight of in encountering endemic diphtheria.

Deglutition is sometimes painful, but is often unattended with the slightest distress. It becomes difficult in some instances, being followed by cough and regurgitation through the mouth and nostrils.

The acute febrile phenomena often subside in the course of a day or two, even while the local manifestation is rapidly progressing. In some instances they become merged, as it were, into fresh febrile phenomena which seem to be dependent upon the disturbances occasioned by the extension of the local manifestations.

In the majority of instances, after the disease has existed a certain length of time—a few hours in some cases, a day or more in others—an abnormal collection of lymph-like or lymphous material may be noticed upon some portion of the mucous membrane of the tonsils, palatine folds, soft palate, uvula, or pharynx; the healthy mucous membrane immediately surrounding the accumulations being somewhat congested, sometimes, indeed, in vascular lines. The abnormal deposit is usually coagulated in isolated specks or patches, whitish or grayish in color, sometimes soon acquiring a yellow tinge, more or less translucent when recent, and soft in consistence. The specks increase into patches, sometimes arranged in longitudinal streaks. There is great variation, in individual cases, in the shade and consistence of the deposit, and in its degree of cohesion or adherence to the mucous membrane. It increases in thickness and opacity coincidently with its extent in surface, becoming darker with age, and with incorporation of the coloring matters of effused blood. Variations in density and in arrangement of constituents, preponderance here and there of one or another element, differences of refrangibility, the character of the light by means of which it is examined,

and the like, will produce diversifications in color and in lustre due directly to physical causes, and but indirectly to morphological condition.

The deposit may remain limited to a circumscribed locality or a number of circumscribed localities, or it may spread by extension over the entire pharynx; sometimes descending into the larynx, and thence down the trachea, and even along the bronchial tubes; sometimes mounting the pharynx, implicating the glandular tissue at its vault, and entering the nasal passages posteriorly with or without involvement of the pharyngeal surface of the palate and the palatine folds. In some instances the tongue, the gums, and the inside of the cheeks become covered with the characteristic deposit.

Dr. Stokes has related ¹ a fatal case in which the tongue, larynx, trachea, and right bronchus were more or less thickly coated with the deposit, even as far as the fourth or fifth bronchial ramification, while the left bronchus remained quite free from it. Bretonneau,² Dr. Jenner,³ and others have encountered cases in which the exudation had extended into the œsophagus and stomach.

The extension of the local lesion into the nares is usually a manifestation of grave augury, even although there should be little evidence of the disease elsewhere, or but slight indication of constitutional disturbance. This condition may be suspected whenever there are manifestations of coryza and epistaxis. From the posterior nares, or the upper portion of the pharynx, the local process may invade the Eustachian tubes, and even the middle ear. In some cases, too, it reaches the maxillary sinuses, and in all probability the frontal sinuses also.

Bretonneau remarked in his second memoir,⁴ that when the deposit sheaths or envelops the tonsils, instead of being laid, as it were, upon their surface, the liability to extension to the air-passages is rendered greater.

Although the pharynx and the structures immediately contiguous are the usual seat of the deposit, it is also liable to make its appearance upon other mucous surfaces, notably of outlets, and upon the denuded or abraded skin. This latter characteristic is presumed to be, perhaps, an additional argu-

¹ Dublin Journ. Med., Feb., 1863.

² Memoirs on Diphtheria: Sydenham Soc., London, 1859, p. 17.

³ Op. cit., p. 4.

⁴ Op. cit., p. 24.

ment in favor of the local nature of the affection in the first instance.

In some cases the deposit never progresses beyond a pultaceous consistence. These are the cases sometimes denominated catarrhal, and which, usually, do not extend into the larynx. In most instances, however, coagulation takes place into a pellicle or false membrane, the so-called pseudo-membrane which constitutes the fully-formed characteristic local lesion.

The tendency of the pseudo-membrane is to extend from above downward; and as its consistence usually increases with its age, it is customary to find it thinner below than above. Neither one nor the other condition, however, is absolute.

Bretonneau,¹ in examining the morbid lesions of the fifty-five cases (at all ages) which formed the basis of his first memoir, mentions that in one instance the false membrane existed in the trachea without any exudations being found either upon the tonsils or upon any other portion of the pharynx. Guersant² has related a case in which he saw the membrane mount the epiglottis from the upper portion of the larynx; and at the autopsy the pellicular membranes were found occupying the principal bronchi, the trachea, and the larynx as far as the convex surface of the epiglottis, where they ceased.

Jenner³ exhibited to his class a specimen in which, while the larynx, trachea, and bronchi were coated with lymph, there was but a small patch in the pharyngeal mucous membrane, limited to the posterior wall, and not in the least degree continuous with the lymph in the larynx. In this case there were two separate centres of exudation, and the laryngeal exudation occurred for some time before the pharyngeal. The exudative inflammation did not spread from the larynx to the pharynx. The laryngeal symptoms were urgent before the pharynx was in any way affected.

Prof. Chapman,⁴ in the examination of a fatal case in an infant, eighteen months of age, found that the air-vesicles were filled, and the bronchial tubes and trachea lined with a false membrane. From this membrane not affecting the larynx, and from its being thicker in the smallest tubes, and thinner in the larger ones, so much that it became a mere film in the upper part of the trachea, it was evident that the disease began in the mucous tissue of the lungs, if not in the air-vessels themselves.

Dr. Alexander Robertson⁵ exhibited to the Glasgow Path. and Clin. Soc. a specimen from an infant, aged nineteen months, of a complete cast of larynx and trachea prolonged into both bronchi, but not extending higher than the rima glottidis. The connection with the mucous membrane was nowhere inti-

¹ *Op. cit.*, p. 16.

² *Memoirs on Diphtheria*: Sydenham Soc., London, 1859, p. 216.

³ *Op. cit.*, p. 11.

⁴ *Boston Med. and Surg. Journal*, Feb. 5, 1863.

⁵ *Brit. Med. Jour.*, Feb. 27, 1875, p. 293.

mate, and in some parts there was a separation. There was no morbid structure above the vocal cords, and no diphtheritic exudation on the tonsils, pharynx, or parts in the neighborhood.

The deposit remains upon the mucous membrane for several days—from three to six in moderate cases—and then gradually disappears or exfoliates from periphery to centre, leaving the mucous membrane intact, or more or less hyperæmic; and this disappearance is sometimes followed by a second and third, and even a fourth reproduction of fresh membrane in the same place.

In a case which recovered without surgical interference, attended by myself, a few years ago, in consultation with Dr. James Collins, of Philadelphia, as many as eight distinct casts of the trachea, most of them extending a short distance down both primitive bronchi, and with bloody streaks upon the surface, were expectorated within forty-eight hours by the patient, a girl eight years of age.

According to the views of special pathologists, and those who believe with them, the pseudo-membranous patches in question may be regarded as deposits, exudations, sloughs, or epithelial exfoliations. This is an open question as yet, concerning which there is a want of uniformity among pathologists.

The pseudo-membrane, at first thin, particularly at its edges, soon thickens, and often becomes darker in color, presenting the yellowish tinge and granular aspect of chamois-leather. By imbibition of the coloring matters of the blood, it often acquires a brownish, and in some instances even almost a blackish appearance.

The morbid conditions of the mucous membrane beneath the deposit, as first noticed by Bretonneau,¹ often consists simply in ecchymoses of very limited extent, and in slight erosions. In some cases, however, there is not even a slight erosion. In other instances, on the contrary, and they are by no means infrequent, the surface beneath the deposit is raw and hemorrhagic, whether the deposit has been removed spontaneously, artificially, or by muscular movement.

When the connective tissue surrounding a patch is infiltrated with serum, the patch appears depressed, and in this

¹ *Op. cit.*, p. 16.

way bears a resemblance to a foul ulcer ; these parts sometimes becoming very vascular, so as to bleed readily on contact. This was noticed by Bretonneau, and has frequently been confirmed since his observations were made. In fact, this delusive appearance led, up to the period of Bretonneau's observations, to the opinion that the disease was a gangrenous sore-throat.

Bretonneau, in examining, during an epidemic of a fatal form of sore-throat, the body of a child who had died from what was then supposed to be gangrenous angina, and in whom some of the later symptoms were strongly analogous to those of croup, discovered a membranous tube, extending from the orifice of the larynx to the last divisions of the bronchi, and which was continuous with the supposed eschars of the isthmus of the throat, which represented the expanded portion of a funnel, of which the tracheal tube formed the stem. On raising the gray or blackish membrane in the pharynx, its under surface was found to have the whiteness, consistency, and inorganic aspect of the exudation drawn from the trachea and the bronchi ; and the wall of the pharynx was seen not to present the least trace of gangrenous alteration.¹

In some instances the pseudo-membrane interferes mechanically with the nutritive circulation of blood in the mucous membrane, and thus causes portions of the mucous membrane to suffer gangrene, and slough out ; sometimes leaving ulcers of considerable extent. This is the form of the disease termed gangrenous diphtheria.

The local deposit, though almost universal in diphtheria, is not a constant manifestation. Cases occasionally occur, and terminate fatally, too, for that matter, in which no exudative manifestation can be detected from first to last. Whether the disease can exist independently of any local manifestation is not positively ascertained. It may have become developed and have disappeared before the case has been seen by the physician ; and then he can only judge that the membrane has existed, from the character of the remaining symptoms or from concurrent circumstances.

In some cases there may be profuse hemorrhage on separation of the morbid deposit, from ulceration beneath or around it ; or simply from deterioration of the blood itself, in consequence of which it exudes in sufficient quantity to produce exhaustion.

The symptoms of laryngeal implication are hoarseness, cough, and dyspnœa, due to a certain extent to inflammatory

¹ Op. cit., p. 13, Case 3.

swelling of the parts affected, as well as to the extension of the exudation within them. These symptoms are more marked in the child than in the adult, in consequence of the larger relative size of the larynx in the adult. Laryngoscopic examination usually reveals intense congestion and tumefaction of the larynx, more or less of the borders and interior of which are covered with the exudation; so that the passage for air is considerably encroached upon, especially when the glottis is involved. In addition to this, clumps of mucus and partly detached portions of membrane may adhere to the lips of the glottis, or be driven to and fro between them in the movements of respiration, thus adding to the difficulty of breathing incident to the extension of the disease. The fever, too, reappears, or becomes more severe if it had not subsided. Respiration is accelerated in frequency, the inspiration becoming prolonged, laborious, and sibilant, the nostrils dilating, and more or less of the auxiliary muscles of respiration coming into play. The face becomes pallid, the lips and nails blue, the extremities cool, and, if the dyspnœa increases, the sub-sternal, supra-sternal, and intercostal soft tissues become deeply depressed at each inspiration. The child struggles for breath, is restless, alarmed, sometimes clutches at its throat, and exhibits all the evidences of commencing asphyxia. The cough and voice are muffled, and sometimes completely deprived of resonance. These symptoms increase with more or less rapidity, unless relief is afforded by discharge of some of the exudative products. After a while the excess of carbonic acid in the blood obtunds sensibility, and the symptoms are no longer accompanied by such evidences of distress.

In adults these symptoms of dyspnœa rarely reach the intensity that they do in children, because the larger calibre of the air-passages renders them less liable to become obstructed.

In this way the disease steadily progresses to a fatal termination, unless arrested by treatment. In favorable cases the symptoms show evidence of amelioration from the eighth to the fourteenth day, all characteristic manifestations of the affection gradually subsiding, and convalescence becoming established during the second or third week, as the case may be.

In septic cases the adynamic symptoms of blood-poisoning

are superadded, and the case usually progresses from bad to worse, death from asthenia ensuing in from two to four days if the manifestations of septicæmia attend the onset of the disease, or in from one to two weeks if apparently caused by absorption of deleterious products from the deposits and the diseased structures beneath them. Spots of ecchymoses, purpura, and irregular cutaneous eruptions are sometimes manifested. When the latter are pustular and exist upon the face, other points of the surface may become inoculated by the hands of the patient conveying matter from the ruptured pustule. Should the case terminate favorably, convalescence is usually very slow.

Gangrenous cases usually progress steadily to a fatal termination, under symptoms of rapid exhaustion and collapse. Recovery is rare, and the patient is sometimes permanently deformed from losses of tissue, morbid adhesions, and the like, which interfere with deglutition, nasal respiration or phonation.

Diagnosis.—The main points of diagnosis are the adynamic character of the febrile phenomena and the evidence of deposit on the surfaces enumerated. In sporadic cases the diagnosis is often difficult. In epidemic cases it is easy. Discrimination is necessary between common membranous sore-throat on the one hand, and croup on the other.

The Apparent Identity of Diphtheria with Croup.—The majority of practitioners, at the present day, believe in the identity of croup and diphtheria; but a very respectable and equally intelligent minority are unable to support this opinion. A consideration of the main points urged upon both sides of this interesting question cannot fail to be instructive.

A lively correspondence on the subject occupied no inconsiderable portion of the columns of the London *Lancet*, and of the *British Medical Journal*, during 1875; and elicited special attention, from the fact, among other things, that a prominent London teacher, Sir William Jenner, who contended for the non-identity of the two affections a few years previous,¹ had become an advocate of the theory of identity, in which, by the way, he has the unqualified support of some of the ablest and most prominent authorities in Great Britain.

¹ Diphtheria: Its Symptoms and Treatment. London, 1861.

For the fair discussion of the subject, as definite ideas as possible should be conceived of the terms diphtheria and croup. The former term has been sufficiently dilated upon, and may be regarded as indicating positive deterioration of the blood, in addition to the local manifestations described. The latter term has unfortunately become applied to several conditions which bear no pathological analogy save in a single result, which may follow causes very different in their nature—inflammatory, septic, toxic, and mechanic—and this one manifestation is laryngeal stridor with mechanical impediment to respiration. Now, discarding, once for all, such varieties of suffocative affections as may be included under the terms “false” croup, “spasmodic” croup, “stridulous” laryngitis, “thymic” asthma, and the like, we are to ascertain whether there is an acute idiopathic inflammatory affection of the larynx, or larynx and parts contiguous, of an exudative or pseudomembranous type, propagable along the bronchial respiratory tract, and occasionally along the respirato-alimentary tract, non-contagious in its nature, unassociated with constitutional disturbance as an essential element in its phenomena, and in which the sole danger to life is mechanical obstruction to respiration from swelling, or from the presence or accumulation of the products of the exudation; an affection the inherent tendency of which is to recovery, apart from the mechanical obstruction mentioned. (See CROUP.) Cases of this kind are not frequent, at the present day, I am willing to admit. Many practitioners practise a long while without encountering them; still they are by no means rare, and have been observed and recognized by many practitioners. Some persons who have not encountered cases of the kind, deny the existence of a true non-systemic croup, instead of simply stating that they have never seen the disease. These cases represent the true croup of those who believe in the disease independent of diphtheritic intoxication, and are classed as sporadic diphtheria by those who contend for identity. There is no doubt that many advocates of the existence of a true croup include undoubted cases of diphtheria in their categories; while cases of supposed croup, on the other hand, are included in the categories of those of the contrary opinion. Hence much of the existing confusion as to what is a case of diphtheria, and what a case of croup. If we are willing to admit, as I think we safely can, that a patient with diphtheria

may contract croup, and a patient with croup may contract diphtheria, this obscurity disappears in part. This is not mere begging the question. Typical cases differ as much as ever, but cases of coexisting disease partake of the nature of the two extremes, and the anatomical phenomena of both gradually merge into each other, while their clinical manifestations become blended. The existence of the one does not afford immunity, at the time or for the future, against the contraction of the other; and they may appear together, or in rapid sequence,¹ or they may follow at long intervals.

If the term croup is applicable to any inflammatory affection of the larynx, trachea, and parts contiguous, which is accompanied by the development of a product, which when completed represents an adventitious membrane, then it appears to me that we have several varieties of croup:

1. *Idiopathic or sthenic croup, true croup*; a purely inflammatory local affection, non-specific in its origin as far as we know, sporadic in its appearance, rarely implicating the tissues above the larynx, rarely occurring more than once in the same individual, confined almost exclusively to childhood, non-contagious, and unattended with any essential systemic complication; death occurring mechanically from asphyxia, or from slow apnœa, or from asthenia consequent on the impairment of vital force produced by prolonged impediment to respiration.

2. *Systemic croup, or the croup of diphtheria*; a systemic disease, specific in its origin to the best of our knowledge, accompanied and in part preceded by pseudomembranous manifestations in the pharynx, nares, and portions of the alimentary tract, often followed by certain characteristic disturbances in the nervous, circulatory, and glandular systems, frequently occurring more than once in the same individual, endemic or epidemic in its appearance although sometimes sporadic, contagious in its nature, and attacking people of all ages, though more frequent in children; the tendency being to death by asthenia, though it is likewise liable to prove fatal mechanically from obstruction of the air-passages.

¹ I have seen a child at the breast pass through a severe typical attack of diphtheria from exposure to emanations from excretory matters adhering to the garments of a physician, contracted during immediate convalescence from true croup, no other case of diphtheria being in the immediate neighborhood.

3. *Deuteropathic croup*; such as becomes developed in connection with certain of the exanthemata, typhoid fever, and the latter stages of phthisis and other diseases of malnutrition, in which it is often associated with similar deposits in other portions of the body; therefore bearing a closer physical resemblance to the local manifestations of diphtheria; and

4. *Traumatic croup*; such as follows the local action of steam, acids, vesicants and mechanical injuries, the membrane, as remarked by Bretonneau,¹ remaining circumscribed about the injured parts.

Certainly a special diathesis or a special infection is not necessary for the mere production of false membrane. In all these instances, the membrane is diphtheritic in the sense of being adventitious, but, as we know, adventitious membranes may become developed under still other conditions, as from the local influence of irritant gases, local injuries, and the like. To add one more to the examples that have been reported from time to time, I have in my possession a number of fragments of membranes coughed up during two years, following a tracheotomy which I had performed for the extraction of a foreign body (beef-bone) which had remained in the trachea for more than two years; and the patient informed me that she had coughed up "such fragments of flesh" from time to time before the operation. There were no general symptoms indicative of the process of membranous formation or exfoliation.

The problem offered for solution is whether the first form is an independent disease, or simply a sporadic variety of diphtheria—the second form. That instances of the first form were known to the ancients under different appellations there is abundant proof.²

It is also evident that this form of disease is not identical with the so-called *gangrenous angina* which Bretonneau first discriminated as a special affection, and to which he gave the name *diphthérite*.

Bretonneau contended for the identity of croup and diph-

¹ In the case of the prolonged sojourn of foreign bodies a permanent adventitious membrane envelops them and renders their retention harmless.

² See especially, Observations tending to ascertain whether the ancients were acquainted with the disease known to us familiarly by the name of croup, by John Redman Coxe, M.D., Prof. of Materia Medica and Pharmacy in the University of Pennsylvania. Am. Jour. Med. Sci., Nov. 1828, p. 56.

theria, and believed¹ that "Francis Home persuaded himself that he had just met with an affection which had hitherto escaped the attention of his predecessors," and that his new name "so fascinated all persons that it prevented them from recognizing a disease observed from the most remote antiquity." At the same time Bretonneau states distinctly that "no inflammation with exudation is *diphthérite* when it does not spread by contagion;" the membranous exudation being considered by him as the poison itself.

The development of diphtheritic patches upon abraded cutaneous integument is universally known, whether due to a local deposit or to an exudation from the tissues. It is not improbable, at least in many instances, that the diphtheritic patches in the throat are first developed on abraded surfaces. There is usually some history of catarrh preceding the development of diphtheria. Now, this catarrhal inflammation of the pharyngo-laryngeal mucous membrane may produce an elevation or separation of the epithelium, and thus represent the condition of abraded integument. It is difficult, and sometimes impossible, to recognize slight losses of epithelium with the unaided eye, in the usual method of examining the throat, and the pharynx and parts contiguous to it may be in this abraded condition previous to the attack. Granting this, the two processes in the skin and in the mucous membranes are analogous.

Attempts at discrimination in the nature of the exudation have failed, although characteristic differences, chemical, microscopical, and physiological, are still contended for by some pathologists. The discriminating condition pointed out by Virchow some years ago, and so extensively supported, that the pseudomembrane of diphtheria is adherent to the mucous membrane, or infiltrated into it, while that of croup simply lies upon the mucous membrane, is now acknowledged by him² as lost in particular cases; true croup of the larynx and trachea invading the pharynx and often actually coexisting with diphtheria, and not presenting as a free exudation until we reach the deeper bronchi or the pulmonary vesicles.

The difference in the nature of the epithelium of the pharynx and vocal cords (squamous) and that of the nasal passages and larynx generally (ciliated), is deemed sufficient to account

¹ Op. cit., p. 4.

² Pathologie und Therapie, I., p. 292.

for the adherence of the adventitious material in the one case, and its mere apposition in the other.

We cannot establish any essential difference on anatomical grounds, the pathological products of the two affections being identical as far as our means of examining them are to be relied upon.

There is no absolutely characteristic manifestations in the location of the pathological product, nor in the condition of the mucous membrane beneath it; even destruction of tissue being sometimes encountered in croup as well as in diphtheria.

When we investigate the clinical features and manifestations of the two diseases, we can, I think, recognize a difference as tabulated below :

CROUP.	DIPHTHERIA.
Non-specific in origin.	Specific in origin.
Never contagious.	Often contagious.
Not inoculable.	Inoculable.
Not of adynamic type.	Of adynamic type.
Usually sporadic.	Usually endemic or epidemic.
Rarely attacks adults.	Often attacks adults.
Always accompanied by exudation.	Sometimes unaccompanied by exudation.
Fatal only by physical obstruction to respiration, whether directly or indirectly.	Often fatal without any physical obstruction to respiration whatever.
No depression of heart.	Marked depression of heart.
Pulse often strong and hard.	Pulse never strong and hard, even though quick and full.
Respiration more accelerated in proportion to the pulse; ratio rarely, if ever, less than one to four.	Respiration not accelerated in proportion to the pulse; ratio usually less than one to four.
Albumen rarely in urine.	Albumen often in urine.
Not followed by paralysis.	Often followed by paralysis.
Would bear antiphlogistics.	Would not bear antiphlogistics.
Rarely attacks more than once.	Often attacks more than once.

In addition to this, it may be mentioned that diphtheria, unlike croup, has never been thought due to excessive plasticity of the blood.

With regard to contagion, it may further be remarked that I know of no recorded instance of undoubted croup (such a case as would not be classed as diphtheria by these contending for non-identity) which has been traceable to exposure to the

contagion of a case of diphtheria (such a case as would be designated diphtheria by the partizans of both views). Evidence to the contrary ought to be accepted as conclusive. With regard to the pathological product, it may be admitted that no one doubts that diphtheria may exist and even terminate fatally, without the development of any membrane in the larynx or below it. No one doubts either that the disease, to constitute croup, necessitates the production of a pseudo-membrane or its representative in the larynx or trachea, or bronchi. In diphtheria, too, the membranous affection in the larynx is usually consecutive; and, on the other hand, croup does not necessarily affect the pharynx. Diphtheritic cases may be mistaken for croup, and thus the two be regarded as identical, from there being evidences of membranous exudation in the larynx, but none in the pharynx; the fact being, as often demonstrated necroscopically, that the membrane had occupied localities out of direct sight, such as the posterior surface of the palate, the lower portions of the œsophagus, upper portion of the pharynx, and the like. Laryngoscopic and rhinoscopic inspection, when practicable, would set such doubts at rest.

In the same way as we have enteritis and typho-malarial enteritis, pneumonia and typhoid pneumonia, erysipelas, and malignant erysipelas, we may have croup and diphtheria; the disease being due to an ordinary cause in the one instance, and to a specific cause in the other; the analogy being in the organs or tissues affected, and the difference in the mode of origin and in the systemic complication.

Prognosis.—The prognosis is usually grave in diphtheria. Many cases progress to a favorable termination, but such a happy result cannot be positively predicated in any given instance, for those which are mildest at the outset may yet terminate fatally. The character of the epidemic, the hygienic conditions by which the patient is surrounded, and the opportunity that may exist for improving those hygienic conditions, all exert more or less influence on the general prognosis. We should hope for the best, and be prepared for the worst, in every instance, bearing in mind that no case, however trivial it may appear, is absolutely unimportant. Cases mild at the outset may become severe at a later period, and relapses may occur even after the first subsidence of the alarming symptoms. The age of the patient is to be taken into consideration. In

the absence of any other prominent indication, we find that the case is generally more unfavorable the younger the patient.

The general state of the constitution is of great importance. Previous general good health renders the prognosis favorable, while patients debilitated from any cause whatever are less likely to recover. Complications with other diseases, as measles, scarlatina, or pneumonia, render the prognosis unfavorable.

The deposit itself sometimes furnishes indications of the severity of the case, but by no means constantly. Simple tonsillar or pharyngeal (oro-pharyngeal) exudation alone is less grave than when complicated with naso-pharyngeal, nasal, or laryngeal exudation. When the tonsils are sheathed, as it were, in an envelope¹ of exudation, it is sometimes indicative of a condition in which laryngeal exudation is likely to occur; and the prognosis is therefore less favorable. Mild cases, however, in which there is but little deposit, may prove fatal by blood-poisoning, or by collapse before the local manifestation has become fully developed. Septic cases (so-called), and cases actually gangrenous, are exceedingly grave; the latter not only from the ulcerative processes that take place, but from increased element of poisoning carried into the system by each inspiration over the fetid detritus in the throat. Still, they sometimes recover even in the midst of the most unfavorable surroundings.

Nasal diphtheria is of such grave augury that some observers consider it of fatal significance, though without sufficient reason therefor. In children at the breast it interferes seriously with nutrition. Epistaxis, therefore, and even moderate coryza, should attract prompt attention, as indicative of nasal complication.

In his letter to Drs. Blache and Guersant,² in referring to the terror felt by the former and by Trousseau at witnessing sudden loss of life after forty-eight hours' illness, Bretonneau asserts that he had recently acquired the conviction that the disease is developed in the nostrils and extends there without any warning and without any apparent symptom. He therefore urges that visible symptoms should not be waited for, but

¹ Bretonneau, *op. cit.*, p. 24, note.

² Fifth Memoir, *op. cit.*, p. 196.

that, at the least sign of snuffling, at the slightest indication of coryza, swollen lymphatic glands should be felt for—not merely looked for—beyond the angle of the lower jaw, below the lobe of the ear, and thence down the sides of the neck. At the same time the upper lip will be found red below the nostril of the same side on which there is any glandular swelling, and unequally and proportionately upon both sides, if there is glandular swelling upon both sides.

Pain in the ear is mentioned by Bretonneau as an early symptom in one of his cases,¹ and by Dr. Beardsley, of Milford, Conn., as the first symptom in almost all the cases he saw in an endemic, occurring a day or two before any other complaint was made, and before any evidence of exudation could be detected in the throat.² I have observed the same fact in a few instances, and not only in diphtheria, but in other inflammatory processes involving the tonsils, posterior palatine folds, and epiglottis. It is characteristic, perhaps, when present, but not pathognomonic.

Epistaxis, and so likewise hemorrhage from the throat, is sometimes indicative of blood change, as well as simply direct loss from destruction of tissue; while, when copious, this direct loss of blood itself is an additional complication of unfavorable omen. Irregular cutaneous rashes and eruptions, spots of ecchymosis and purpura, are likewise of unfavorable augury. Laryngeal diphtheritis (diphtheritic croup), and with it, of course, diphtheritis of the air-tubes from larynx to ultimate bronchi, is of the gravest significance, for it indicates the approach of mechanical impediment to respiration, a condition which can but add to dangers already existing. As far as the mechanical danger alone is concerned, the constitutional condition may be almost disregarded in the prognosis; the age of the patient, the relative calibre of the larynx, and other affected air-passages, and the tenacity of the morbid product, being points of much more importance.

During the first week of the disease, in cases not directly fatal from innervation or collapse, the danger is from the deposit in the larynx, and if the larynx remain unaffected, the danger then lies in the exhaustion and deficiency of nerve force

¹ Op. cit., Fifth Memoir. p. 201.

² D. D. Slade: Diphtheria; its Nature and Treatment, Philadelphia, 1861, p. 45.

or energy; conditions which may ensue even in connection with but a trifling amount of inflammation and exudation in the throat.

The tumefaction of the submastoid, submaxillary, and cervical glands is regarded by some observers as proportionately indicative of the severity of the case—on insufficient grounds, however, according to the opinions of others.

The constitutional symptoms of the disease itself furnish indications for prognosis. High temperature may be regarded as unfavorable. A strong, full pulse is a favorable indication; a rapid and feeble pulse, on the other hand, is an unfavorable indication; while a vacillating and infrequent pulse is almost of fatal significance, unless dependent upon cardiac disease previously existing. Loss of appetite and unwillingness to take nourishment are unfavorable signs. Vomiting is an unfavorable indication, and diarrhœa still more so. The presence of albumen in the urine is regarded as an unfavorable sign, and when the albumen is very abundant the case almost always terminates fatally. Dr. Wade,¹ to whom we are chiefly indebted for the observation of this symptom, found that indications of the impairment of the renal functions were constantly precursory of an unfavorable termination. When the albumen is abundant, there is sometimes uræmic intoxication; and the supervention of delirium is almost always a fatal sign.

In cases terminating favorably, recovery usually takes place from the eighth to the fourteenth day, the symptoms gradually diminishing in severity and urgency with normal resumption of impaired function.

In cases terminating fatally, death usually occurs within a few days, sometimes not until the end of two weeks, and sometimes as late as the fifth week. The patient may succumb to asthenia, or exhaustion from the severity of the systemic disease, with or without invasion of the larynx. Death from asthenia may occur during the first week in delicate or debilitated subjects, in rare instances within thirty-six hours; but it is usually delayed until the course of the second week. The patient may die from sudden asphyxia, or from gradual apnœa, caused by the local impediment or obstacle to respiration. Asphyxia may be produced by the flapping of free or partly free exudation in the trachea, or in the larynx, which, while it

¹ Observations on Diphtheria. London, 1859.

permits inspiration, effectually prevents expiration by its valve-like action. The patient may die from the innervation following the disease, even after the establishment of convalescence, or even after apparent recovery. Bretonneau has recorded cases,¹ and so have others after him, in which, though the symptoms were mild, life was often lost, and in which the post-mortem evidences (even after tracheotomy) were insufficient to account for the death.

Prof. Jordan, of London, who has noticed more than one sudden death from laryngismus where tracheotomy had been performed and the patient apparently cured, suggests that they may be manifestations of the wonderful influence diphtheria exercises on the nervous system, shown, however, more usually by paralysis than spasm.²

The apparent laryngismus in some of the instances of this character may actually be paralysis of the dilator muscles (post-crico-arytenoids) of the glottis, which occasions inspiratory stridor; but neither spasm nor paralysis of the glottis merely could be the cause of death with an artificial opening patent below.

Bretonneau saw no case survive the sixth day of laryngeal symptoms, without tracheotomy. Jenner³ has twice seen death within twelve hours from the time the laryngeal symptoms were first noticed, and had never known it delayed more than five days after positive indications of the existence of the deposit in the larynx.

If symptoms of laryngeal implication have not become manifested within the first week, the danger from this cause, though by no means averted, diminishes with the relative prolongation of the attack.

A point to which attention is called by Prof. Flint,⁴ who had seen two cases terminate in this way unexpectedly, is a liability to sudden, fatal syncope, even in comparatively mild cases, or during convalescence, and generally due to some unusual exertion, as getting out of bed. Dr. J. F. Meigs, among others, has reported⁵ cases in which sudden or unexpected death was due to the formation of clots in the right cavities of the heart. Similar instances are not unknown to other observers likewise. I have seen it the immediate cause

¹ Op. cit., p. 47.

² Lecture on Croup, *Med. Times and Gaz.*, Sept. 21, 1872, p. 322.

³ Op. cit., pp. 36, 37.

⁴ *Principles and Practice of Medicine*, Philadelphia, 1863, p. 946.

⁵ *Am. Jour. Med. Sciences*, April, 1864, p. 305.

of death several days after a tracheotomy of continuously favorable augury.

The prognosis in diphtheria, then, should always be guarded.

Treatment.—If diphtheria is primarily or essentially a constitutional affection, its development, when once it has fairly attacked the organism, can no more be prevented than can the development of the contagious exanthemata, typhoid fever, and other specific diseases of like character. Seclusion from infection appears to be the only reliable means of prophylaxis. If removal from infected centres is impracticable, we must be content with advising avoidance of exposure to cold, inhalation of dust and other deleterious matters in the atmosphere, over-exercise of the voice, and everything whatever which may predispose to inflammation or catarrh of the nares, throat, and air-passages. At the same time care must be taken to keep the general system in its healthiest condition; and if there is occasion for the use of tonics, the tincture of the chloride of iron may be administered with great propriety.

Upon the appearance of any morbid secretions in the throat or nostrils, frequent and efficient cleansing should be instituted with washes, douches, or gargles of weak solutions of table salt or chlorate of potassium; and if there is direct exposure to infection, carbolic acid, salicylic acid, sulphurous acid, permanganate of potassium, the hyposulphites, and the like, may be judiciously substituted on account of their antagonistic action upon the development or propagation of low organisms.

The treatment to be instituted, once the pathological products have become manifest, will depend upon the views held as to the nature of the disease and its cause. Nutritive, supporting, and stimulating treatment constitutionally, is now almost universally recognized as absolutely necessary; and depleting measures, even of the mildest character, are almost universally avoided. This unanimity would indicate that diphtheria is something more than the pseudo-membranous croup, which, if we credit the records in our text-books, was formerly thought to require the use of antiphlogistic measures.

With regard to the treatment of the local manifestations, there is much less unanimity of opinion. Practitioners who consider diphtheria as chiefly a systemic disease are apt to regard local measures as useless and productive of fresh sources of injury. They will depend on systemic medication to the

exclusion of specific or special local measures, unless we look upon the exhibition of emetics, expectorants, and the like, for the expulsion of accumulations in the air-passages, as local measures. Many eminent practitioners discard all local treatment whatsoever. Practitioners who believe the disease to be chiefly local in the first instance, will direct their efforts towards removal or destruction of the morbid products, and, if too late to accomplish this result, to the exhibition of local agents that dissolve or decompose them. Those who partake of both views will pursue a mixed treatment accordingly.

Although numbers of observers denounce topical treatment on the score of its uselessness in a systemic disease, its inefficiency to prevent subsequent deposits in the same locality, its liability to induce additional deposit upon surfaces which may be accidentally or unintentionally exposed to contact with the local remedy, the difficulty of its effectual application in certain instances, and the like, evidences of the efficacy of local interference have been too numerous to justify entire reprobation of the practice. Employed by Aretæus, centuries ago, and then reintroduced into practice by Van Swieten, and again by Bretonneau, it has been abandoned and resumed again and again. Some observers resort to the local action of caustic applications, with the view of arresting the extension of the membrane over unaffected structures, or effecting its entire destruction,—and chiefly on the theory that the main danger lies in the deposit; others hope to excite a substitutive healthy inflammation of the part which shall supersede the unhealthy specific process; others, again, hope to destroy the cryptogamia which are believed to be the initial cause of the deposit; and others hope to place the mucous membrane in a condition unfavorable for the propagation of these organisms.

As diphtheria is always serious, every case demands close attention, and frequent and careful examination, with the aid of all the resources at our disposal; and the treatment, to be at all effectual in hazardous cases, must be assiduous and free from vacillation. Topical applications, when resorted to, should be made by the medical attendant himself, or by a professional assistant fully competent, no matter how frequently they need to be repeated; and other local measures should be instituted under the personal superintendence of a well-instructed attendant. Many a patient is sacrificed to inefficient

attention, a neglect that is only excusable in the country practitioner whose patients reside at distances so remote that it is impossible to secure them a proper amount of professional surveillance, and which is actually culpable when there are other physicians whose assistance can be enlisted if the regular adviser is unable by press of business to devote sufficient personal attention to his own patients.

Several objects must be kept prominently in view during the entire treatment. Chief among these is efficient sustenance of the patient, and the prompt discharge of the morbid products as they accumulate. If these two main indications can be fulfilled the patient can be carried safely through the disease. There is no specific, topical or constitutional, which can arrest the disease or prevent the evolution of the local manifestations, although there are agents which modify the process and diminish the virulence of the infection. A warm, equable temperature, an excess of humidity of the atmosphere, and free ventilation conduce to the comfort of the patient, and the facilitation of expectoration. Until the appearance of the exudation we may depend upon nutritive and tonic treatment, with thorough cleansing of mouth, throat, and nares; care being taken to disinfect the apartment and the house as far as practicable. This disinfection may be accomplished to some extent by the free use of solutions of carbolic acid exposed here and there, or sprayed about from time to time, and of sulphurous acid in spray, or in fumes from ignited sulphur; these agents being competent, in some instances, to destroy the germs which spread the infection, if they do not originate it.

It is a significant fact that chlorine compounds, whether used constitutionally or locally, are more frequently efficacious in diphtheria than any other class of remedial agents. Tincture of the chloride of iron is one of the most valued remedies for internal administration. It is usually given in decided doses frequently repeated; from five to fifteen or twenty drops, according to the age and vigor of the patient, every second hour, hour, or half-hour. It is necessary to secure its action upon the blood and system as rapidly as possible; after which the influence is maintained by less frequent administration. Its frequent deglutition likewise exerts a beneficial physical influence upon the morbid products with which it

comes in contact ; for, as will presently be stated, it is one of our most reliable agents for topical medication. I have no hesitation in commending the use of this remedy.

Quinia is much used as a tonic in diphtheria, as well as for its support to the nervous system, and as an apyretic in fever. It may be combined with the tincture of iron in the form of the hydrochlorate, or, if that is not accessible, in the usual form of sulphate. It is given in decided doses until the buzzing in the ears or some other manifestation gives token that the system is under its influence, when the doses may be lessened and the intervals between them increased. I am not much in the habit of prescribing quinia in diphtheria, unless I see some special indication for its exhibition ; but this practice is by no means to be construed into any absolute disparagement of its remedial agency. When there is difficulty in swallowing, it may be used in the form of suppository.

Alcohol, in the form of some strong wine or of brandy, is of great value as a stimulant. From half a drachm to half an ounce of brandy, or its substitute, according to the age of the patient, may be given every two or three hours, or more frequently ; and its free administration should not be delayed after the earliest symptoms of loss of vigor are apparent. Its effect on the general condition of the patient will be the criterion for its continuance. When indicated and well borne it may be used freely, especially if efficient nourishment is difficult. Made into a sort of syrup, by igniting it under a lump of sugar supported on a fork until melted, it is easily administered to children.

Carbonate of ammonium is a remedy of great value at special moments of sinking. A full dose at such periods will sometimes stimulate the patient during a short interval, which may be taken advantage of for the administration of the remedies in systematic use, or of emetics, or inhalations of lime, and the like, to facilitate the expulsion of accumulating secretions in the air-passages.

Chlorate of potassium is extensively used as an internal remedy, frequently in the form of chlorine mixture, which contains an equal number of grains of the salt and of drops of muriatic acid in simple or aromatic water, infusion of quassia, or the like, with the addition of some syrup if desirable. This salt is often employed in syrupy solution combined with the

tincture of the chloride of iron. It is better to make the admixture extemporaneously at the bedside, so as to vary the proportions of the two agents as may be required. It is also given in the form of lozenges, containing a grain or more of the salt each, administered as frequently as may be necessary to introduce the desired quantity of the chlorate, usually from thirty grains to a drachm or so in the twenty-four hours. Though rarely prescribing chlorate of potassium with confidence, the lozenge is the mode of administration that I usually prefer, because the remedy is retained longer in contact with the affected parts, and thus has a better chance to exert a beneficial influence locally. I must remark, however, that I have rarely seen, even in slight cases, the remarkable results from this remedy which have followed its exhibition in the practice of many others; and though acknowledging its occasional usefulness, I am inclined to doubt its efficacy as a reliable remedy against the disease or against its local manifestation. Furthermore, its inordinate use may irritate the kidneys, a result to be avoided in view of the significance of albuminuria as an unfavorable manifestation. It is said to be eliminated by the salivary glands and by the muciparous glands of the pharynx.

Calomel, first employed in croupous affections by the illustrious Dr. Rush, of Philadelphia, is extensively used as an internal remedy to modify the condition of the blood and to prevent further exudation; some practitioners believing that the disposition to exudation is arrested as soon as the system is under the influence of the mercurial. It is given early in the disease, before the strength of the patient has become too much impaired, in doses of from one to three grains every second hour, hour, or half-hour, until there is evidence of its constitutional effect in the characteristic stools, or upon the gums, when it is discontinued or repeated at longer intervals, as circumstances may dictate. Bretonneau and others have reported successful results from this treatment, even after the larynx and trachea had become implicated. Mercurial inunctions, a drachm of the usual ointment every hour, are sometimes employed in addition, to hasten the desired result. In infantile cases, with prominent cerebral symptoms, boring of the head into the pillow, and the like, I have seen excellent results from the internal use of calomel; but I would not recommend its employment otherwise, except at an early period, and in a

vigorous subject, and would abandon it after a few doses, if there were no decided evidence of its usefulness.

Bretonneau felt induced to believe¹ that the action of calomel in modifying the pellicular inflammation was due to its insinuation into the larynx; and Jodin attributed much of the good effects of the internal administration of both calomel and chlorate of potassium to their mechanical action in passing over the deposits.

The alkaline carbonates of potassium and sodium, and the acetate of potassium, have been recommended for their influence on the disposition to exudation, and they are often exhibited in association with calomel. Large doses are said to be necessary; from fifteen grains to a drachm in the twenty-four hours to infants, and from one to three drachms daily to adults. I have no experience in their use in diphtheria.

Copaiba and cubeb have been highly recommended by Trideau, especially in the first and second stages of the affection. To adults he administers a dessertspoonful of the syrup of copaiba every second hour, followed in the intermediate hours by fifteen grains of recently powdered cubeb in a tablespoonful of syrup, or in sugar and Malaga wine. For children the dose is about one-half of this amount. More recently he gives the cubeb every hour to the amount of one hundred and twenty to one hundred and fifty grains daily to a child one year of age, and from three hundred and seventy-five to six hundred grains to an adult; continuing at least three or four days after disappearance of the deposit, especially if glandular swelling persists. If there is no improvement within three or four days, the dose is increased, no matter what the age of the patient. Diarrhœa is combatted by syrup of poppies, in children, and by opium in adults. Should cubeb be insufficient, he gives copaiba in addition, especially to adults. He gives from twenty to thirty pills daily at regular intervals, each pill containing twenty-five centigrammes of Mi-alhe's solidified balsam and fifteen centigrammes of cubeb. He states that the scarlatiniform eruption produced by these pills always coincides with cessation of the disease, except occasionally in young children. Children are given as many pills daily as they are years of age.² These remedies are administered on

¹ Op. cit., 4th Memoir, p. 168.

² Gaz. hebdomadaire, March 28, 1877; London Medical Record, July, 15, 1877, p. 285.

the principle of their property in drying up sources of mucous secretions. Cubeb, more particularly, has received the commendation of many observers who have followed Trideau in its use. It is supposed that the elimination of these remedies by the respiratory tract enables them to exert a special topical influence on the bronchial mucous membrane. I have no experience in their use in diphtheria.

The hyposulphite of soda, recommended by Dr. Tubbs, of Upwell, is sometimes used internally, in the hope that in its decomposition the system may be favorably subjected to the influence of sulphurous acid upon low organisms. It is administered in doses of from one to three grains to children, and from eight to ten grains to adults, repeated every three or four hours. Sulphurous and sulphuric acid lemonades are prescribed by some practitioners.

On similar grounds carbolic acid and salicylic acid have been given in diphtheria with asserted benefit. I have no experience to offer in this connection, but should not anticipate much from the internal use of antiseptics from quinia, through the list, to salicylic acid, for the reason that much larger amounts would be required to disinfect the mass of the tissues than it would be convenient or safe to administer.

Bromine has been used internally with much asserted success.¹ As will be mentioned later, it is a valuable remedy by inhalation. I have no experience with its internal administration. The dose is a drop or two of a solution, one grain to the ounce, given in sweetened water, and repeated every hour or so.

Iodine and many other remedies have been extolled for their constitutional influence on the disease, but it is hardly worth while to enter into their consideration, as they are not in frequent use.

Swollen and tender glands externally have been mentioned as frequent accompaniments of the earlier symptoms. Warm applications of cotton wadding, spongio-piline, or even actual cataplasms are frequently used to relieve suffering; and some cases are treated by mild inunctions with some innocuous ointment or grease, as lard, cold cream, olive-oil, and the like.

¹ Ozanam: *Comptes rendus de l'Acad. de Sci.*, 1856, p. 102.

Care must be taken not to employ agents which may abrade the skin, on account of the danger of cutaneous infection, with its unfavorable effects. Some practitioners employ cold compresses, and even ice externally, but the practice is by no means devoid of injurious consequences, though often resorted to with impunity. If not promptly beneficial their use should be discontinued. Ice to the interior of the inflamed throat, on the contrary, is often a grateful and beneficial application, though condemned by some authors. I have always allowed my patients to take all the ice they craved, and have encouraged the frequent use of iced-water, water-ice, and ice-cream in small quantities at a time; and my impression is that the use of pellets of ice, allowed to dissolve in the mouth, is steadily gaining in favor.

Dr. A. Menzel, in a very fatal epidemic in Trieste, which resisted all ordinary treatment, and which was attended with large and rapid glandular swellings in the neck, injected four drops of an iodized solution (pot. iod. 5, iodine 1, distilled water 1,800 parts) into the tonsils, palatine folds, and soft palate. This plan proved very successful in seven cases, and in no case were any injurious consequences noticed.¹

We now come to consider the treatment in reference to the exudation itself.

The use of emetics is indicated, in children, if there be evidence of accumulation of secretions in the air-passages, in order to provoke their expectoration by the act of vomiting. The action of an emetic is to induce diaphoresis of the skin from the vascular relaxation which accompanies the act, and something of the same kind may be supposed to take place in the bronchial mucous membrane, thus facilitating the detachment of viscid or adherent secretions. The air-passages of infants are very tolerant of mucous accumulations, and therefore this point needs attention. It is an important matter to encourage cough, or to provoke it if necessary, whenever morbid products are accumulating in the air-passages. Adults are able to expectorate voluntarily, and the same indication for the emetic does not present. Alum, soon to be mentioned as one of the suitable local agents, is an excellent emetic in mild cases, and is unattended with the objectionable after-effects which some-

¹(Wien med. Woch. 1873, 45; Die prakt. Arzt. 1873, 11) The Practitioner, March, 1874, p. 211.

times follow the use of ipecacuanha, tartar-emetic, sulphate of copper, and the yellow sulphate of mercury, the four emetics most in use for the purpose. The recognition of the value of alum is due to the late Dr. Meigs, for many years Professor of Obstetrics in Jefferson Medical College. It is administered in doses of a teaspoonful in an equal quantity of honey or molasses, and repeated in ten or fifteen minutes if the first dose is ineffectual. Should three or four doses fail to produce emesis, the other articles just mentioned may be substituted in proper doses. Considerable circumspection is requisite in the use of the tartar-emetic on account of its depressing effects. The hydrochlorate of apomorphia has recently acquired great reputation as an emetic, on account of the promptness and certainty of its action and the almost entire absence of unpleasant after-effects. It is usually administered by hypodermic injection, in doses of from one-thirtieth to one-tenth of a grain, and its effects are produced in a very few minutes. I have seen very depressing results from the effect of this remedy, however, and would not resort to it in diphtheria unless it were impossible to excite emesis otherwise. Titillation of the base of the tongue is said to be sometimes effectual in inducing emesis in these instances. The emetic should be repeated at intervals of six or four hours, more or less, according to the indications. Emesis is by no means always requisite, nor should it be pushed too far.

Expectorants acting through the system are rarely of much use in diphtheria. The action of senega in rendering the exudation more fluid, and facilitating expectoration, has been insisted on by Bretonneau,¹ and he was led to associate it, in doses of a few grains, with the calomel treatment, in cases where dryness of the mucous surfaces appeared to have been the principal obstacle to the expulsion of the false membranes. In case an expectorant is indicated, I think senega the most reliable agent that can be employed. Sanguinaria is used with considerable success by a number of practitioners in Philadelphia. A little carbonate of ammonium added to the senega is sometimes of advantage. I have seen chloride of ammonium answer a good purpose in some instances.

Topical measures can only be effectual when they can be

¹ Op. cit., p. 105.

thoroughly applied to the entire exudative product ; and their use, therefore, is chiefly limited to manifestations that are accessible to vision. It is generally deemed inexpedient to resort to forcible removal of the membranes, although this is considered allowable when they are partially detached at their edges and but slightly adherent. Some practitioners, however, not wishing to limit the action of the caustic or astringent to the membranes, and doubtful of its action through them upon the mucous membrane beneath, remove the patches forcibly, and then cauterize the bleeding surfaces. The difficulty of effectual topical applications is often very great, and frequently insurmountable, especially when the deposit occupies the upper pharyngeal walls, the internal nasal outlets, the posterior surface of the palate, etc., localities requiring the artificial aid of mirrors to inspect them. Besides this there is great danger of injuring healthy tissues, and thus exciting inflammation, with perhaps effusion beneath the mucous membrane. In addition to this, in certain cases the operation causes a good deal of pain, as well as intense physical and mental suffering, and often interferes in this way with the adequate introduction of nourishment and stimulus, particularly in nervous subjects. It is questionable, therefore, whether it is justifiable to persist in making the applications by force in cases where the resistance is great, and where the outskirts of the visible deposit are out of reach.

If there are but a few circumscribed patches steadily extending in circumference, and fully within reach of instruments, there can be no valid objection to a single thorough local application, in the hope of arresting their progress by continuity. Should this fail, it is hardly likely that anything is to be gained by its repetition. In employing this method we need not forget that the first deposit is likely to be replaced by others ; and we are entitled to remember, on the other hand, that this is by no means universally the case, and that therefore there is a possibility of getting rid at once of the local source of danger by a thorough topical application. Of all the local agents that I have employed, and seen employed by others, the tincture of the chloride of iron has been by far the most efficacious. It is believed that aqueous solutions of iron are not as useful as the tincture ; and this leads to the inquiry whether its local action may be in any measure due to the

alcohol. Bacteria are said to be inevitably killed by immersion in absolute alcohol;¹ and it may be worth while to determine whether the organisms present in the diphtheritic exudation may be destroyed by its local application. Tincture of the chloride of iron, first recommended by Dr. Heslop, of Birmingham,² and by Gigot and Jodin,³ is at present the favorite topical remedy with most practitioners.

Jodin⁴ believes that it penetrates the vegetation completely, limits its action on the surface, and may be absorbed without danger; that it modifies the hemorrhagic condition which constantly surrounds the points of exudation, and provokes a desire to expectorate which facilitates the expulsion of the morbid products. He judiciously calls attention to the necessity of exerting a certain amount of pressure in its application, as a liquid simply coursing over the parts can have but an uncertain action; and to the necessity of reaching the entire exudation, as a point spared may be the source of a new deposit. He recommends gargling after the application, and repeating both processes until all is removed. For the nares syringing takes the place of gargling. The proper amount of pressure cannot be exerted in the larynx, nor the circumspection be exercised to touch every part. Here Jodin recommends tracheotomy and the application of the iron up and down through the artificial opening.

There is but little doubt that this remedy is employed with more general confidence in its efficacy than any other local agent.

The sulphate of iron (Monsel's salt) in powder has been found the most efficacious remedy by some practitioners.⁵

Hydrochloric acid, extensively employed at one time by Bretonneau, Trousseau, and others, is rarely used by the active practitioners of the present day. The same remark applies to the local use of nitrate of silver, and likewise of calomel, once highly extolled by Trousseau as a powerful modifier

¹ Bastian and others.

² *Med. Times and Gazette*, 1858, p. 552.

³ *Gaz. des hôp.*, 1858, pp. 359, 486.

⁴ *De la nature et du traitement du croup et des angines couenneuses*, Paris, 1859, p. 33.

⁵ Beardsley: *Slade on Diphtheria*, Phila., 1861, p. 70. Nelson, *N. Y. Med. Jour.*, Jan., 1874, p. 84. Ferra, *London Med. Record*, Nov. 15, 1876.

of the diphtheritic inflammation. Hydrochloric acid was employed locally by Bretonneau before he recognized the nature of the disease, and still deemed the diphtheritic aspect of parts denotive of sphacelus.¹ He applied the strong acid at intervals of twenty-four to thirty hours, and believed that it arrested the progress of the specific inflammation by substituting another. The fumes of hydrochloric acid were first employed in the disease in Bretonneau's time, but their use has been abandoned. Trousseau, likewise, also employed the fuming hydrochloric acid, applied on charpie, repeated twice a day, expecting such modification of the parts after two or three days' use as to justify the application of less active agents. He also employed the concentrated solution of chloride of iron, but abandoned it again for the muriatic acid.

Nitrate of silver is a local remedy that has been extensively employed, and was first recommended by Dr. Mackenzie, of Glasgow,² as a substitute for the sulphate of copper. Its use has been highly recommended by Bretonneau, Trousseau, and many others. Jenner states³ that the single efficient application of a solution of twenty grains to the drachm of water, frequently stays the spread of the exudative inflammation, and he has seen the same result from the solid stick carefully applied around the patch; though he believes that on the whole hydrochloric acid and water in equal parts more frequently attain that object. He reprobates, however, the repeated application of these strong local remedies at short intervals. The solid stick, in a holder so guarded that only the cauterizing point is exposed, or strong solutions of the crystals, are alike used for this purpose. Of late years this agent has lost much of its repute in these cases.

Caustic potash, oxalic acid, creasote, carbolic acid, salicylic acid, sulphurous acid, chloral, glycerine alone or containing some of the agents mentioned above in solution or combination, and various other substances, have been extolled as local applications. Care must be exercised in combining glycerine with real acids, lest explosive compounds be formed.

Powdered alum was used by insufflation as long back as in

¹ *Op. cit.*, p. 12, Case 2.

² *Edinburgh Med. and Surg. Jour.*, 1825, p. 294.

³ *Op. cit.*, p. 69.

the practice of Aretæus,¹ and successful results in the early stage of the pharyngeal exudation have been reported by Bretonneau, Trousseau, Pommier, and many others. Fifteen grains, mixed with sugar, are propelled on the parts by an insufflator, or blown upon them through a quill or other tube, every three or four hours. Daviot² speaks highly of it in the first stage as generally preventing the formation of membranes. I do not think that it is much used at present.

The local application of powdered sulphur has been highly lauded, especially by Spanish authorities, for its destructive action upon low organisms. There seems to me to be ample reason to acknowledge its efficiency in certain epidemics that have been reported, or, at least, results equaling those of other topical agents. In other epidemics, again, it is said to have been useless.

Where topical applications by the brush and probang are injudicious or impracticable, local medications by the gargle, syringe, or spray douche are often resorted to. Here solutions of alum, borax, chlorate of potassium, lactic acid, citric acid or lemon juice, carbolic acid, sulphurous acid, lime, bromine, iodine, glycerine, and the like are employed. The stronger caustic and acid solutions are not suitable for this method of employment. Simple water, hot, tepid, or cold, as best suits the patient, impregnated with Cologne water or toilet vinegar, is a grateful application in the form of douche or spray, and often as apparently efficacious as solutions more medicinal. When the exudation occupies the larynx and trachea, topical remedies are most suitably administered by inhalations. Direct cauterizations of the larynx and trachea are still occasionally practised, but the method has been almost universally abandoned as hazardous and ineffectual. Insufflations of alum, calomel, etc., are rarely employed at the present day either. That the local application to the larynx and trachea of nitrate of silver, so highly extolled by Bretonneau, Green, Gibb, and others, has been of great use in some instances, there is no reason to doubt. But it may be doubted whether any special beneficent action is to be attributed to the nitrate of silver, for many indifferent substances employed in the same manner have like-

¹ Bretonneau, *op. cit.*, p. 42.

² *Memoirs, etc.*, Sydenham Soc., p. 371.

wise proved successful in individual cases. It is likely that most of the benefit has been due to the mechanical detachment of the membrane removed, or merely loosened by the contact of the sponge in the execution of the operation. A sponge saturated with water, or with a weak solution of carbolic acid, or the like, would then be equally efficient, and be much less apt to produce intense spasm of the glottis. By placing the index finger of one hand upon the laryngeal face of the epiglottis, it is not very difficult to guide a sponge probang along it into the larynx, and by suitable movements to reach most of its interior surface, or that of the trachea, and if it come in contact with membranes they will be removed in part adherent to the sponge, and will be in part detached and expelled subsequently in the efforts of cough.

In cases where tracheotomy is out of the question, or where it will not be consented to, it may be justifiable in the face of impending suffocation from accumulated products to attempt their mechanical removal in the manner indicated, the operation being completed in as few seconds as possible. There is a moderate risk of impacting membranes in the trachea or in the primitive bronchi, a result which would accelerate the very condition for the alleviation of which the operation is attempted; but such instances would ordinarily be very infrequent. On the other hand, removal of obstructing membranes will facilitate respiration for some time, and may save life if there be no reproduction of them. The responsibility of performing the operation is great enough in any instance; and in case of impaction, immediate tracheotomy would be necessary to afford access for direct removal of the occluding products.

The agents administered by inhalation are usually such as have a solvent action upon the morbid product, or keep it diffuent so as to favor its expulsion by cough. Various alkalies have a certain solvent action upon the membrane. Lime-water is the most efficient and the promptest, and is at present the most resorted to. Iodine, chlorine, bromine, creasote, carbolic acid, salicylic acid, sulphurous acid, and lactic acid are used for the same purpose. With sulphurous acid I have had some successful results. These agents are usually administered in the form of sprays. The fumes of lime in process of slacking are much more efficient than the spray of lime-water.

Bromine vapor has been highly recommended by various

observers. Ozanam throws a large pinch of table salt or of bromide of potassium upon boiling water, and adds gradually a teaspoonful of an aqueous solution of bromine, a drop to the ounce. The vapor is inhaled slowly and deeply through a funnel of glass or paper. Leuthlen saturates a sponge in a solution of two parts each of bromine and bromide of potassium in one hundred parts of distilled water, and holds it in front of the patient's nose and mouth, much in the same way as in administering an anæsthetic.

The vapor of caustic water of ammonia, from a moistened sponge held in the throat, but kept from contact with the tissues, has been recommended to excite vomiting and expectoration.¹

Tracheotomy.—When there is such evidence of false membrane in the larynx and trachea as to threaten suffocation or asphyxia, and emetics and inhalations fail to effect its expulsion, the operation of tracheotomy is indicated to enable removal of the membrane in the first place, and respiration through an artificial opening, below the point of obstruction, in the second. If the membrane should occlude the bronchi to any extent, there is little to hope from the operation; but this condition is very difficult to determine, on account of the transmission of morbid sounds from the upper passages. The most reliable indication is continuous and increasing dyspnoea with gradual asphyxia, but unaccompanied by incurvation of the tissues above the sternum, or to any considerable extent at the base of the thorax, or in the intercostal spaces. If the tissues named are drawn in to any great extent with each inspiring effort, the indication is that the impediment is chiefly in the larynx or trachea, and much more is to be expected from the operation. Great stridor in inspiration indicates obstruction at the glottis. It is not expedient to go fully into a consideration of all the points involved in the question of tracheotomy, as that is a subject that requires attentive study of itself. In a recently published essay² I have carefully gone over the subject in all its important bearings, and presented both sides of the question as impartially as I am able to do. It will suffice to state that the operation has been successful in many

¹ Daguillon, Gaz. hebd., 1870, No. 30.

² Croup in its Relations to Tracheotomy, Philadelphia, 1874, pp. 78.

cases apparently hopeless, and promising but little success. On the other hand, it often fails even in promising cases. Much depends on the selection of cases, the proper performance of the operation, and on the after-treatment. There is no insuperable contraindication to the operation, unless it be evidence of the deposit of fibrin in the cavities of the heart. Anæsthesia is admissible, if sensation is intact, but must be employed with great caution. The operation must be deliberately performed, unless the emergency is such that the patient is sure to suffocate during the dissection. As a rule, hemorrhage should be restrained before the trachea is incised. The incision should be made into the trachea as close to the cricoid cartilage as possible, to avoid excessive hemorrhage and subsequent accidents which might occasion emphysema. The false membranes present in the larynx and trachea should be removed by extraction and suction (with syringe or with pipette), before any tube is introduced. Finally, the most assiduous attention must be paid to the after-treatment, as regards disease, wound, and tube. Indeed, a skilled professional attendant should be within a moment's call, for at least twenty-four hours after the operation, to attend immediately to any untoward accident which may occur to the tube or to the wound. Many a case is lost for want of just such attention at a critical moment. The tube should be dispensed with if practicable, and should be removed as soon as there is no further indication for its use. A silver tube is preferable to a rubber one, as affording indication, by its discoloration, of local gangrene in the track of the wound. Above all must it be kept in mind that the operation merely offers a possibility of recovery by affording a means of efficient respiration during the continuance of the disease. It will help the patient to live through the evolution and decline of the disease, but it cannot cure it. It is a chance for life which should not be denied the patient, if the conditions are such that he can be properly attended to afterwards; and the sooner the operation is performed after it is indicated, the better the hope of success. The operation is rarely successful in adults, chiefly because the size of the larynx is such that the mechanical impediment to respiration is not sufficient to call for an artificial opening below it until after the exudation has invaded the bronchi. I know of but three or four records of success after tracheotomy

in the adult, while the records of successes in children may be counted in hundreds, some of them in subjects much less than two years of age, although success is very rare at this early period of life. The main indications, after the operation, are to keep up nourishment to sustain the patient, and to encourage or to provoke cough, so as to keep the air-passages clear. All treatment should be subservient to these ends, so essential for a favorable termination to the case.¹

The main causes of death after timely and successfully performed tracheotomy are: extension of the exudation, general systemic infection, paralysis, albuminuria, pneumonia, and fibrinous deposits in the cavities of the heart.

The manner in which I have become accustomed to treat diphtheria, modified of course according to the exigencies and individualities of the case, may be stated as follows: The patient is placed in the most convenient room of the house, encumbered with as little furniture as practicable, care being taken to provide for due ventilation and an equable temperature of 75° F. Great attention is given to nourishment, and to systematic alcoholic stimulation, when the strength is becoming exhausted. The nostrils, when clogged, are assiduously cleaned by douche or syringe. Tincture of the chloride of iron is given in full and frequent doses, and applied locally to any circumscribed patches that can be reached in their entire extent. A continuous evolution of steam is kept up in the apartment so as to moisten the air; the throat and nostrils are kept as clean as possible by douches of a weak solution of carbolic acid (two grains to the ounce), and the same is occasionally administered by inhalation in spray. As soon as there is any evidence of morbid products in the larynx, or parts below it, inhalations of the fumes from lime in process of slacking² are administered for ten or fifteen minutes at a time, and repeated every second hour, hour, or half-hour, according to the freedom of respiration and the moisture of the bronchial râles.

¹ For details concerning the accidents that may occur during the operation and after it, the proper methods of procedure, the important after-treatment of the wound and its complications, the casualties which prevent recovery, and other collateral points, the author refers to his essay on Croup in its relations to tracheotomy, in which these subjects are discussed seriatim.

² Geiger: Med. and Surg. Reporter, Phila., March 24, 1866.

I give the vapor from slacking lime the preference over inhalations of the spray of lime-water, though I have seen good effects from the latter, and sometimes alternate the two methods. If the lime does not appear to suit the case, or if its good effects are not continuous, inhalations of the warm spray of bromine, a grain to the ounce of water, with a grain of the bromide of potassium, are substituted. Should these likewise prove inefficacious, the sulphurous acid spray is tried. If the laryngeal symptoms increase, and asphyxia is to be dreaded, tracheotomy is advised as soon as there is marked inspiratory incurvation of the intercostal, substernal, and suprasternal tissues, without waiting for the period of cyanosis, provided that no respite is procured by the inhalations, or by the action of emetics.

I am inclined to regard saturation of the atmosphere with steam¹ as one of the most valuable elements of the treatment of diphtheria in the presence of exudation in the air-passage; the object being to supply to the exudation an abundance of water to replace that which is lost by evaporation or coagulation in its transformation into membrane, and thus favor its detachment and expectoration. With this view I often keep up a continuous evolution of steam so great as to loosen the wall-paper in papered apartments.

Oertel,² a recent authority of some notoriety, places his main reliance in this agent in the treatment of diphtheria in the stage under consideration, with the view of promoting abundant suppuration beneath the adventitious membrane to loosen it, and preventing the propagation of the cryptogamic growth, which he states cannot penetrate into the tissues through the layers of pus.

There are a variety of expedients for obtaining a sufficient evolution of steam. If there is a stove in the room, a vessel of water containing small articles, such as handkerchiefs and napkins, may be kept boiling. If this be insufficient, wet cloths may be hung up about the room and be changed from time to time. A wash boiler may be brought into the room, already filled with boiling water, and an attendant stand by it lifting out articles of clothing on a stick, and then immersing

¹ Wanner : *Du Croup et de son traitement par la vapeur d'eau*, Paris, 1834.

² Ziemssen's *Cyclopædia*, New York, vol. i., p. 675.

them and lifting them again, keeping it up all the time. A second vessel should be ready to replace the first one as soon as its water fails to furnish sufficient steam. Buckets of water may be brought to the bedside, and hot bricks or pieces of heated iron, or fragments of lime dropped into it. Water may be poured over a hot shovel now and then to get up a sudden copious evolution of steam for the moment, and so on. A tin kettle may be altered so that a long wide spout is let into its side high up, to direct the steam towards the mouth of the patient, and this can be fed by an alcohol lamp or one of the cheap portable gas stoves in common use in cities. If a funnel-shaped tube is soldered into the cover so as to dip down into the water, the supply of steam will be more copious. This croup-kettle is inexpensive, and may replace the more perfect instrument. In the absence of a croup-kettle, a large tin pan may be placed on the portable gas stove, by the side of the bed, and kept in a state of ebullition, the vapor being directed over the patient's mouth by some extemporaneous contrivance. The air of the apartment should be kept well ventilated by an open window in an adjoining room or staircase, a screen formed by a sheet hung over a line being placed in front of the door of communication, or around the bed to protect the patient from draught. If the room is large, the bed may be brought close to the stove, and sheets may be hung round it so as to retain the steam in its vicinity. The temperature of the apartment may be maintained at 80°, 85°, or even 90° F. This steaming is kept up night and day as long as there is any occasion for it, the amount of heat and steam being then lessened gradually.

In order to assist in the early destruction of the membranes, and to afford inlets through them for the penetration of the watery vapor, I resort to the vapors of slacking lime as recommended by Dr. Geiger, repeating the process every hour or so, or whenever the character of the respiration indicates impediment due to the presence of membrane or its reproduction. Hot water is poured upon small pieces of unslacked lime in any convenient vessel. A large piece of stiff wrapping paper, folded into a funnel-shaped cone, or a stiff paper bag with one corner cut off, and inverted over the vessel, serves to direct the vapor toward the mouth of the patient. The patient must not be brought too close to the hot vapor, and his eyes may be protected by a cloth or the hand of the attendant. The ebulli-

tion of the lime in slacking forces numerous minute particles up in the steam that rises from the vessel, and these are driven with the vapor into the air-passages. It may be that the lime does not act chemically on the membranes, and merely wedges them up mechanically here and there, permitting better access of the aqueous vapor; but that it acts beneficially in forcing the expulsion of shreds of membrane, casts, and the like, there is no doubt. I know of no treatment of recent introduction which has satisfied the claims advanced in its introduction more thoroughly than that of the fumes of slacking lime in diphtheritic deposits upon the upper air-passages.

This treatment is likely to induce capillary bronchitis, or even pneumonia, but if it saves the patient from the immediate dangers of suffocation, that is a secondary matter to be attended to subsequently. I have seen numbers of children saved by this treatment, who, to the best of my judgment, would have perished without it; some of them being cases in which it was believed that tracheotomy held out no chance of a successful termination.

Sequelæ.—The paralyses that occur during convalescence, or after its establishment, or after the height of the disease has been passed, are indicative of a profound morbid impression on the nervous system. This impression is in some respects characteristic, although similar paralyses are found to occur after other severe specific systemic affections, as small-pox and typhoid fever. The amount and intensity of these paralyses of diphtheria are by no means directly proportionate to the severity of the affection. The palate is the most frequent and usually the earliest seat of the paralysis. It is seen to be relaxed, and does not contract upon contact with it of instruments or stimulus. The results are difficulty in swallowing, regurgitation of fluids through the nose, and an altered (so miscalled nasal) tone of voice. It seldom occurs before the third or fourth week of the disease, although it has been noted as early as the ninth day. Cutaneous diphtheria is sometimes followed by the same sort of paralysis of the palate, a significant fact, indicating that the impairment of nervous force is due to systemic poisoning rather than to any local effect upon the peripheral terminations of the affected nerves themselves.

The pharynx, and, to some extent, the œsophagus also, are sometimes paralytic after diphtheria; under which circum-

stances the difficulty of swallowing is still greater, so great sometimes as to necessitate feeding through a stomach-tube. Vomiting, however, may occur even after swallowing is impossible. The nerves of the larynx may be paralyzed, in which case there will be impairment of voice, constriction of the glottis, or immobility of the epiglottis, according to the nerves impaired. Laryngeal paralysis, favoring the escape of food into the air-passages, and thence its appearance at the external wound, if tracheotomy has been performed, necessitates the use of the stomach-tube. Constriction of the glottis would be an indication for tracheotomy. The nerves of respiration are sometimes impaired, and dyspnoea or apnoea occur in consequence, so that the institution of artificial respiration may be temporarily requisite from time to time. The cardiac nerves may become implicated, a manifestation, often, of fatal significance—the activity of the heart diminishing to from sixty to forty pulsations in the minute, or down to thirty, and even below that before death.

In addition to these manifestations, there may be impairment of the organs of special sense, taste, smell, hearing, and vision. In fact, the paralyses may be manifested in any of the organs and muscles in which paralysis is manifested under other conditions.

The treatment of the paralyses following diphtheria consists in the use of the ordinary methods of invigoration—fresh air, baths, and tonics—under the influence of which the nervous system gradually undergoes recuperation, and the paralyses subside. Should this not be the case, the use of strychnia and of phosphorus is indicated, while local applications of the electric current are calculated to hasten the progress of restoration to normal function. Symptoms of paralysis sometimes remain for several months after convalescence from the diphtheritic manifestations. Occasionally they are unsusceptible of amelioration, and, if important functions are interfered with, they may be the direct cause of death, as in paralysis of the respiratory organs, the heart, and the pharynx and œsophagus.

CHAPTER VI.

CHRONIC SORE THROAT.

REFERRING to the remarks preceding the discussion of acute sore throat (p. 83), the various forms of chronic sore throat will be considered under a like heading.

CHRONIC CATARRHAL SORE THROAT.

(Chronic Pharyngeal Catarrh ; Chronic Catarrhal Angina.)

In this affection the mucous membrane, and chiefly in its upper layers, is the main seat of the morbid process, which involves the pharynx, posterior surface of the palate, and pharyngo-palatine folds more prominently ; though sometimes implicating the glosso-palatine folds and the base of the tongue, and occasionally the anterior surface of the palate. The vault of the pharynx and the posterior nasal outlets become engaged, in some instances, at an advanced stage of the disease, or during temporary exacerbations ; but the larynx is very rarely invaded. There is a diffuse dull looking hyperæmia and turgescence of the parts affected, with hypersecretion from the epithelial cells. The tumid membrane bulges forward in prominent welts or folds, and its surface is doughy or pasty in appearance. The superficial veins are engorged in some instances, sometimes tortuous, and varicose in spots ; this manifestation being greater in the palatine folds than in the pharynx. A few enlarged follicles are prominent beneath the mucous membrane in some cases, but in the greater number there are no evidences of such enlargement to the unaided eye. The mucous membrane at the angles of the pharynx behind the posterior pair of palatine folds is often puffy and bulged forward in longitudinal ridges, from accumulation of submucous infiltration. In some cases enlarged follicles are very promi-

nent in the infra-tonsillar space between the palatine folds, and thence toward the sides of the base of the tongue; and the large papillæ at the base of the tongue may be enlarged also. In some instances the fungiform papillæ are very prominent and congested. There is no ulceration of the mucous membrane.

There is often no impairment of general health; but in many instances there is considerable languor, and functional inactivity, and depression. Costiveness is often complained of.

The disease is not usually a sequel of acute sore throat, but becomes gradually developed without attracting much attention. It may exist with any diathesis. Sometimes it is a mere manifestation of disorder in the intestinal tract.

Symptoms.—The earlier symptoms are simply uncomfortable local sensations, provocative of voluntary efforts of insalivation to keep the parts cleansed and comfortable. These efforts are supplemented in some instances by frequent use of drinks, which keep the discomfort in abeyance. During sleep these sensations sometimes become sufficiently irritating to awaken the patient with disagreeable sensations of dryness and constriction, rendering it necessary to moisten the throat by swallowing saliva or water. There is little or no expectoration during the greater part of the day, the accumulations being often swallowed with the saliva; but there is usually some expectoration in the morning to rid the parts of mucus which has collected over-night. An unpleasant or disagreeable taste in the mouth is a not unfrequent manifestation. Cough is not frequent. At an advanced stage the symptoms resemble those of a chronic folliculous pharyngitis of moderate severity.

Diagnosis.—The diffuse character of the inflammatory manifestations, and the absence of marked involvement of the follicles and of evidence of ulceration, are the main discriminative features in diagnosis.

Prognosis.—The prognosis is usually good. The disease may continue for years without impairing the general health, although often giving a good deal of annoyance. It is amenable to treatment, but rarely subsides spontaneously.

Treatment.—As this affection may coexist with a variety of diatheses, the systemic treatment will vary in accordance with the constitutional requirements. Alkaline laxatives are usually indicated. Local treatment is required in most instances,

and this must be of a soothing character. The local application of solid caustics and strong solutions of nitrate of silver, sulphate of copper, and the like, are often absolutely injurious. Sprays of dilute solutions of these substances, sufficiently attenuated to produce an astringent effect merely, are useful during periods of exacerbation; and the same remark applies to their topical application by the brush or wad. Chloride of zinc, from ten to twenty grains to the ounce, is often better than any other local application. Tannin, dissolved in ether, so as to leave a delicate film in the parts after the evaporation of the menstruum, is also a useful topical agent. Solutions of neutral nitrate of bismuth, and of borate of bismuth in glycerine locally applied, relieve uneasiness. The application to the pharynx is well made by means of a broad flat brush, so as to require but a single movement in washing the entire pharynx from below upwards to the elevated palate. Sprays of tar-water several times a day, weak solutions of alkaline remedies, bicarbonate of sodium, chloride of ammonium, chloride of sodium, chlorate of potassium, bromide of potassium or ammonium, five or ten grains to the ounce, are suitable remedies for home use. These applications reach the parts more effectually than gargles do. They are often preferred warm. Weak acid solutions are indicated if the secretions are too alkaline to test paper. Lozenges of demulcent ingredients, as althæa, acacia, glycyrrhiza, allowed to dissolve in the mouth frequently, often relieve a local sense of discomfort. It is necessary to persist with the treatment for a number of months to secure permanent beneficial results; but once attained, the relief is apt to be lasting, provided care is taken to avoid heedless exposure, which will readily reproduce the affection. The habit of smoking is usually injurious, and should not be indulged in by the subjects of chronic catarrhal sore throat.

CHRONIC FOLLICULOUS SORE THROAT.

(Chronic Pharyngitis, Chronic Follicular Pharyngitis, Chronic Lymphadenitis of the Pharynx, Chronic Glandulous Pharyngitis, Chronic Granular Pharyngitis, Chronic Laryngo-pharyngitis, Follicular Laryngo-pharyngitis; Granular Sore Throat, Clergyman's Sore Throat; Angina Impetiginosa (Chelius), Angina Glandulosa; Angina Clericorum, Cantatorum, Potatorum.)

The most usual form of chronic sore throat, at least in the United States, is essentially a chronic inflammation of the follicular glands of the pharyngeal mucous membrane (chronic lymphadenitis), with more or less involvement of the follicular glands of the mucous membrane of the nasal fossæ, palate, base of the tongue, epiglottis, and larynx; and frequently associated with irregular plastic fibrinous exudation into the submucous connective tissue, and plastic hypertrophy of the mucous membrane, and its contained glands. It often occurs in individuals of scrofulous, tuberculous, dartrous, arthritic, or rheumatic diathesis; but is not always a prominent feature and by no means confined to the subjects of cachexia.

It is not a frequent sequel of acute sore throat, though it sometimes succeeds repeated attacks of sub-acute sore throat. City life seems in many instances to favor a proclivity to this form of sore-throat, and this would suggest an inference that the products of ochlesis, and the mechanical and chemical emanations from various manufacturing processes contaminating the atmosphere, have at least something to do with fostering it, if it is improbable that they do not develop it in the first instance. It is prevalent in all classes of society without distinction of temperament, social position, or avocation; and occurs in both children and adults; chiefly, however, in individuals not very robust. It is probably started in passive hyperæmia of long continuance, with initial disturbances so slight, and exacerbation so gradual, that the disease may be regarded as chronic, so to speak, from the very start; and it gives so little annoyance, and is so rarely aggravated, that the patient considers it unnecessary to solicit medical advice until after it has existed for several months or several years.

At first there may have been a mere sensation of dryness, with or without an inclination to cough or to expectorate; but more or less disposition to clear the throat from time to time from foreign matters is almost always mentioned as an early manifestation. With this there may have been connected—and certainly will be, sooner or later, if the disease continue—some degree of hoarseness, inequality, or impairment of the voice, the patient being unable to depend upon it for anything beyond the ordinary requirements of conversation. In some cases more or less difficulty is experienced in swallowing. In some there is more or less impairment of hearing. Pain is not

often complained of very early in the disorder, and the discomfort is usually more that of an annoying sensation, similar to that which would accompany the presence of some foreign body, as a hair, a bristle, a pin, a lump, and so on. Sometimes there will be headache, distinctly referable to exacerbation of the affection in the retro-nasal portion of the pharynx, and due doubtless to direct disturbance of the cerebral circulation and the proximity of the brain to the nasal (olfactory) nerves. Usually there will be more or less evidence of dyspepsia and indigestion. Indeed, like chronic catarrhal sore throat, it is often only a manifestation of some general disorder of the alimentary tract. I have seen several cases in which the only cause seemed to be intestinal irritation due to the presence of tape-worm. Very often coolness of the extremities will be complained of. Despite these symptoms, the patient still feels in tolerable good health, and is able to attend to his ordinary avocations, though, perhaps, only with more or less sense of exertion. At a more advanced stage these symptoms gradually increase in severity, sometimes with constant progression, sometimes as a result of exposure to changes of temperature, followed by aggravation, and subsiding to some extent in a few days or weeks; the result remaining stationary until the next exacerbation. The impairment of vocal power will have gradually increased, and in the case of clergymen, teachers, and lecturers, have perhaps proceeded so far as to disable them from performance of their public duties. The cough will have become more frequent, accompanied by expectoration of viscid mucus, and attended with a scratching or still more unpleasant or even painful sensation in the throat, usually referred to the pharynx at the region of the base of the tongue, or else to the larynx. Respiration is impaired at times in an irregular manner, which seems to be of nervous origin altogether. Dysphagia is occasionally complained of, and it, too, is also usually nervous in character. In most instances the patient will have tried a great variety of local and systemic popular or patent remedies; and much of the intestinal disturbance that exists may be attributable to the effect of these medicines.

Although this affection, from its prominence among the clergy, has received the appellation "clergyman's sore throat," it is by no means confined to members of that profession, nor even to public speakers. Professor Horace Green, of New

York,¹ in his admirable account of this disease, says that of nearly four hundred cases that had fallen, at that date, under his observation, only about seventy-eight, or one in five, of this number, were, in any way, public speakers. It is evident, as he maintains, that when the affection occurs in persons whose vocal organs are habitually exercised, it is always attended with more aggravated symptoms than when it occurs in other subjects.

Dr. Gibb,² has seen this disease in a very exaggerated form in photographers, and in individuals exposed a good deal to the fumes of acrid chemicals in confined chambers; and has noticed that its obstinacy in them is quite remarkable. It may be inferred that the obstinacy of the affection is due to the persistence with which such individuals are constantly exposed and re-exposed to the exciting cause. A change of occupation might render the disease more manageable.

Its prevalence among clergymen is, at least in part, due to the inequalities of temperature under which they are often compelled to preach; with head, perhaps, thinly protected by hair, exposed to draughts from open windows, or the open air, at the moment that they are addressing their auditors, and thus exposing the throat and larynx to the influence of cold air not previously warmed by passage through the nostrils. Preaching in a cold church is sometimes an exciting cause.

I have known academic lecturers to contract chronic pharyngitis every autumn from the access of currents of air from open windows striking upon a bald head; and in whom the use of a skull-cap during exposure has secured immunity from the attack.

Statements have been made to the effect that Catholic clergymen are less liable to this form of disease than clergymen of other denominations, the greater liability of the latter class being in great measure attributable to their habit of leaning over the pulpit in reading their discourses, thus compressing the muscles of the thorax and abdomen during exercises in which their unimpeded action is desirable; while the immunity in the former class is due to extemporaneous preaching, with maintenance of the erect posture. It may well be admitted that there is some force in this remark, but, as far as my own experience may be a guide, it has furnished little evidence of immunity in this respect for Catholic clergymen.

¹ A Treatise on Diseases of the Air-Passages, New York, 1846.

² Diseases of the Throat and Windpipe, London, 1864.

Very often the only apparent cause is a depressed state of mind, from domestic and personal embarrassments, or the effect of prolonged sedentary and harassing professional work.

The appearances of the parts affected in this disease are characteristic, though varying greatly in individual instances.

In most cases there will be, irregularly studding the pharynx, quite a number of small projections, hemispherical in outline, elliptical or irregular, sometimes translucent colloid sacs, but usually opaque, varying in size from the bulk of a pin-head to that of a small pea, though not very often acquiring the latter dimensions, especially in cases comparatively recent. They are more deeply red in color than the surrounding tissue, which itself is congested, sometimes to a dark red, sometimes to a bluish-red, sometimes to a yellowish-red; and it is sometimes streaked irregularly with dilated blood-vessels. These prominences are sometimes isolated, and sometimes more or less irregularly clustered. They are more apt to be in clusters at the lateral angles of the pharynx, though frequently enough so on the posterior wall also. These prominences comprise enlarged or hypertrophied glands, or groups of glands, enlarged probably by an arrest of their secretion, the outlet to which has become blocked by the swollen condition of their mouths, and thickened by augmentation of connective tissue. The large glands at the base of the tongue are likewise hypertrophied in many instances. Sometimes the watery matters of the secretion being reabsorbed, there remains the albuminous portion, to which additions are constantly made. Sometimes they are distinctly acuminated and the apex bears a pustule; this appearance being more frequent at the lateral angles of the pharynx and in the vicinity of the base of the tongue. Very often their contents finally degenerate into a cheesy material, denominated "tubercular" by Green, Gibb, and others.

The contents of these glands are not usually tuberculous, though tuberculous deposits sometimes take place in the glands of the pharyngeal mucous membrane, and undergo caseation. They may even undergo metamorphosis into carbonate of lime, and I have, in a few instances, removed with the point of the knife from the pharynx and from the base of the tongue small calcareous concretions in every way similar to those concretions occasionally expectorated in cases of pulmonary tuberculosis.

The term *tubercular sore throat*, employed by the authors alluded to, as a synonym for this disease, is unfortunate, because the affection may exist for many

years without being accompanied or followed by tuberculous phthisis, a result which could hardly be averted in the prolonged persistence of a disease really tuberculous in character. It is true that tuberculous consumption is preceded in some instances by chronic folliculous disease of the mucous membrane of the pharynx and larynx; but this condition may have evoked the predisposition to tuberculous disease, evidences of which ultimately make their appearance in the follicles, or in the mucous membrane, as an expression of the general condition of system which has ensued.

Stoerck¹ denies the follicular character of these nodules and regards them as simple circumscribed masses of swollen epithelial cells deprived of their protecting external squamous layer.

There is usually a delicate areola of redness about the base of these enlargements; and sometimes the patches in which they occur are so close to each other, that the accumulated red lines, by which they are bordered, appear as though mapped out into irregular spaces for their reception. The ordinary transparent exhalation which bathes the mucous membrane in the healthy condition is superseded by discolored mucus, which is often adherent, here and there, in viscid clumps or strands. In some parts of the membrane as yet uninvaded by the diseased action, the normal exhalation will have become collected into minute drops which appear like groups of vesicles, often mistaken for herpetic vesicles, similar to those which sometimes precede ordinary membranous sore throat. The inter-

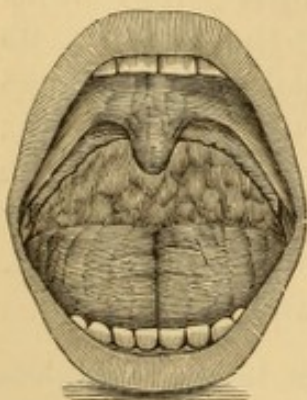


FIG. 51.—Folliculous pharyngitis.

spaced mucous membrane in the vicinity of these patches of drops of moisture, appears sunken in by contrast, and the general aspect is that "slightly raw and granulated appearance" so often quoted. In this form of the disease there is no rawness; the loss of epithelium is merely apparent, and the supposed vesicles can all be wiped off with a soft sponge, showing the uninjured mucous membrane beneath. Similar apparent vesicles are often seen upon the root of the uvula and upon the soft palate; structures which are sometimes the seat also of small groups of enlarged glands, occasionally occupying the edges of the

¹ Pitha and Billroth's *Handbuch der allgemeinen und speciellen Chirurgie*, Stuttgart, 1876, Bd. 3, Lief. 7, p. 114.

palatine folds, giving their borders an uneven appearance (Fig. 51). The tonsils are not apt to be affected in this stage of the complaint; nor the uvula to be elongated. There is as yet only a moderate sense of annoyance in the throat, a little expectoration of viscid mucus at times, but no cough. The voice is not much affected, except perhaps after long or continued use; and then its normal power is regained by rest for a day or two. The larynx will show signs of hyperæmia, with congestion of the vocal cords after the use of the voice, but not during the intervals of rest. Thus supposing the patient to be a clergyman who preached on the Sunday;—on Saturday his larynx will have appeared almost normal, on the Monday it will be hyperæmic. The active disease is confined to the pharynx.

When the disease has progressed further, the groups of follicles undergo further enlargement, and the nasal and nasopharyngeal mucous membrane becomes involved in a folliculous coryza or rhinopharyngitis. The palate and pharynx become tumid and pasty, and the orifices of the follicles give exit to a viscid secretion, sometimes protruding like the purulent contents from the ruptured apex of an acne pustule. A more viscid mucus adheres to the parts, and in greater quantity; and upon the upper portion of the posterior wall of the pharynx, behind the soft palate, irregular greenish yellow masses of concreted mucus are often adherent which have gradually glided down, or else been hawked down from enlarged follicles in the retro-nasal portion of the pharynx, the glandular tissue at its vault having become invaded by the disease, if it has not indeed been its primary seat of departure. This tissue is sometimes seen on rhinoscopic inspection to be covered with tenacious mucus. Sometimes strings of this mucus will hang from the posterior wall of the soft palate, indicating that the posterior surface of the palate, and, perhaps, the posterior nares also are implicated in the diseased action. Not unfrequently the general mucous membrane on the posterior wall of the pharynx will be attenuated, tense, and whitish; occasionally semi-transparent as if it had been thinned off by the acidity of the discharge running down over it from the retro-nasal portion of the pharynx; sometimes excoriated from the same cause. This condition does not extend, as a rule, to the lateral walls of the pharynx, or if so, it

is less apparent on account of the greater amount of connective tissue beneath. The patches of groups of enlarged follicles will have become much larger, their length almost always exceeding their breadth, but presenting great differences in this respect. Their surface is often velvety, and to the touch they are elastic. The isolated follicles sometimes undergo superficial ulceration, and small turbid whitish or grayish masses of mucus will hang from them upon the mucous membrane, and become coalesced with similar masses pendent from enlarged follicles below. Sometimes small abscesses are formed upon these follicles, presenting the appearance of inflamed pustules on the point of rupture. In the interspaces irregular spots of superficial ulceration will be seen showing a destruction of the epithelial layer of the mucous membrane. If the tongue is well depressed similar appearances will be seen to some extent in the lower portion of the pharynx. The uvula is apt to have become elongated, and its surface as well as the surface of the velum will be more thickly studded with enlarged glands, though they are not as apt to be ulcerated as are those of the pharynx. The elongated uvula sometimes draws upon the

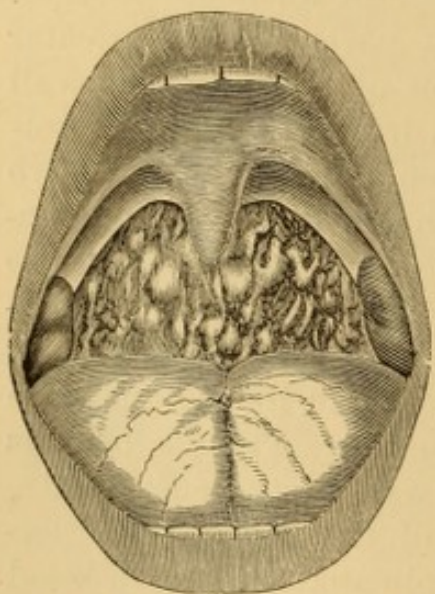


FIG. 52.—Chronic folliculous pharyngitis.

anterior arches of the palate to such an extent as to stretch the mucous membrane free from the submucous tissue in the form of a thin semitranslucent border. At other times groups of real vesicles will be observed on the soft palate and the uvula, often in more or less linear arrangement on each side of the raphé. The tonsils, too, will have become irregularly enlarged, and often bear upon their surface superficial ulcerations, covered with a grayish or whitish secretion. A common appearance presented, when the affection is of long standing, is herewith depicted (Fig. 52), from a case

ultimately cured. Extensive ulceration exists only in exceptional cases, and that, perhaps, in subjects of the scrofulous diathesis.

The hoarseness, expectoration, and dysphagia, will all be increased in severity, and cough will be present in a greater or

less degree. The larynx will be found to exhibit evidences of chronic inflammation of its mucous membrane. (See Chronic Laryngitis.)

In many instances the disease continues in this state for an indefinite time. Should it progress, the inflamed follicles ulcerate through the mucous membrane, the surfaces of the ulcers becoming coated with turbid, tenacious layers of muco-pus which trickle down the surface of the membrane. The angles of the pharynx are quite prone to be the seat of ulceration, and this sometimes extends along the walls of the pharyngo-laryngeal or pyramidal sinuses, quite to the entrance of the œsophagus. The saccular glands at the base of the tongue, which are often much hypertrophied, occasionally undergo ulceration in like manner, as does also the mucous membrane covering the glosso-pharyngeal folds and the glosso-epiglottic sinuses at the sides of the glosso-epiglottic ligament. The secretion from all these surfaces becomes purulent; sometimes sanguinolent from rupture of superficial blood-vessels. This form of the disease has been described by some authors under the special head of *scrofulous sore throat*.

In severe cases of ulcerative pharyngitis, hemorrhage of an alarming or fatal character may take place in exceptional cases. Thus Dr. Landrieux¹ records a fatal instance in a case of "scrofulous angina" in his own practice, and quotes one² of profuse hemorrhage from ulceration of the posterior palatine artery in the practice of M. Lailler.

Special Symptoms.—The voice is liable to be impaired in chronic sore throat, without any visible implication on the part of the larynx; apparently as a result from a mere extension of the nervous influence of the pneumogastric nerve.

That this may be the case is evident from what is frequently observed to occur with some public speakers, who gradually become hoarse during prolonged or energetic harangues, and relieve the hoarseness at once by swallowing a little water. Now, the water goes down the œsophagus, and not into the larynx. True, a little water, but a very little indeed, does sometimes trickle into the larynx down the inter-arytenoidal fold, but it is hardly enough to moisten the vocal cords and laryngeal mucous membrane sufficiently to account for the improvement in voice which follows the act; and so we have to fall back upon the

¹ Death from hemorrhage due to ulceration into the external carotid. Arch. gén. méd., Dec. 1874, p. 672.

² Ibid., p. 677.

theory that the impression made upon the divisions of the pneumogastric nerve distributed to the pharynx, œsophagus, and stomach, is propagated to those other branches distributed to the larynx. In like manner, a pharyngeal irritation will produce hoarseness in a larynx apparently healthy in every respect. This I have seen again and again; often after the application of nitrate of silver to the surface of but one or two groups of enlarged pharyngeal follicles; as well, also, as a result from a more extensive cauterization of the pharynx. This would seem to confirm the view of Prof. Green, that the physiological relation of the pharynx with the respiratory passages is more intimate and important than its relation with the alimentary tract; speaking in a pathological sense rather than an anatomical one, though the nervous supply of the lower constrictor muscle of the pharynx, from the superior laryngeal branch of the pneumogastric, is not to be disregarded in the connection, nor the fact that the same sort of glands that exist in the posterior wall of the pharynx exist also on the pharyngeal surface of the laryngeal mucous membrane, overlying the arytenoid muscles, and also in the aryteno-epiglottic folds, some of the glands in which open into the interior of the larynx, as well as into the pharynx.

In these cases the voice becomes veiled at times, then muffled and hoarse; these symptoms continuing, it becomes a matter of difficulty to speak in a clear, distinct tone, and the effort to do so is painful, the pain running from the region of the hyoid bone upward on both sides. The voice may be a deep bass in the morning, and gradually rise in pitch to a shrill screech in the course of the day. Sometimes continued efforts to speak result in complete aphonia, lasting for the remainder of the day. At other times the patient wakes up in the morning aphonic or dysphonic, and his voice becomes gradually stronger as he engages in conversation, until towards the middle of the day it is almost natural in timbre, with the exception of a little hoarseness.

The subjects of these cases are usually such as have outdoor employments requiring vocal effort. Impairment of voice does not occur so much in those who speak in-doors, unless there is a distinct laryngeal complication. It is met in military and naval officers, street-singers, itinerant venders, car-conductors, newsboys, shopkeepers, and the like. If the affection is allowed to progress unrestrained, the larynx is sure to become involved eventually, and may then become more seriously affected than the pharynx was in the first instance.

Deglutition is often impaired in this affection, sometimes to such an extent as to be always attended with pain or with sensations akin to spasm. At times there may even exist an inability to swallow. This dysphagia, in some instances,

appears to be altogether nervous, and in these cases particularly, although in others, also, unpleasant and even painful sensations, similar to those produced by swallowing, may exist independently of any act of deglutition.

It is said that at times the spasm will amount to that of actual stricture, and that it will sometimes be impossible to introduce an exploring sound, under such circumstances, without an amount of force which would be unjustifiable; but I have not seen any examples of it. These cases are not instances of the ordinary spasmodic stricture of the œsophagus, which is unaccompanied with chronic pharyngitis as an essential element of the disorder, and which usually yields very readily to the introduction of the sound.

Generally the dysphagia is experienced only in swallowing hard and solid food, and deglutition can be rendered much more comfortable by eating slowly and taking care that each morsel is masticated thoroughly, so that it becomes well incorporated with a sufficient amount of saliva. Some patients experience so much trouble and uneasiness in swallowing even the well-masticated bolus, that they confine themselves in great measure to spoon food or liquid diet. In other instances solids are swallowed much more readily than fluids.

In some cases where the affection has been of long standing, we observe a condition of the structures which in part accounts for dysphagia. A number of ulcerated places exist in various portions of the pharyngeal mucous membrane, irregular in outline, but more or less ovoidal in configuration, and separated by continuous divisions of unabraded membrane, so that the patches of ulceration, when numerous and not yet run into each other, present an appearance resembling the interspaces of a network. The continuous stripes of mucous membrane are usually of a pale yellowish color; the ulcerated spots have a fine red-lined margin, and, in some of the interspaces which have not as yet undergone erosion, there are prominent red patches of hypertrophied glands and connective tissue. In other cases the dysphagia seems to be due to a loss of contractile power from atrophy of the muscular tissue, or to a partial paralysis from infiltration between the muscular fibres. In these cases the posterior pharyngeal wall appears to have become arranged in more or less regular vertical folds, rendered unduly prominent by reason of the divisions dipping down between them. These ridges are due to hypertrophic swelling of the connective-tissue sheaths of the muscular fibres, over which the mucous membrane sometimes becomes so much atrophied as to admit of the detection of the muscular striæ beneath it. Moreover, there is sometimes an actual atrophy of the muscular tissue, so that the cavity of the pharynx is abnormally deep; and this excavation, as it were, is often confined to one side, most frequently the right side, judging from my own observations. In some instances the condition of things is such as to convey the idea of a lack of symmetry between the two sides of the spinal column, the outline of the con-

stituents of which is sometimes distinctly discernible through the atrophied tissues. Sometimes, indeed, the closest examination, aided by palpation with the finger, has led to the inference that there was present either a case of absorption of the connective tissue between the pharynx and cervical vertebræ, as well as of the muscular tissue itself, or else a congenital prominence of one side of the spinal column. In addition to this striated appearance of the posterior pharyngeal wall, the parts may be more or less studded with hypertrophied glands, intact or in process of ulceration, the intervening tissue being either in a sound or eroded condition.

Cough occurs in some cases of chronic folliculous pharyngitis. In others, the manifestation is a kind of high-pitched grunt, or a hem—a mere mechanical effort to dislodge some of the irritating products in the throat. The expectoration is mucous or muco-purulent, according to the grade of inflammatory action; sometimes quite fluid, sometimes in semi-solid masses, sometimes in pellets. It is sometimes streaked with blood, the sanguinolent masses being chiefly such as have been previously drawn down with effort from the posterior nares, retronasal portion of the pharynx, or the vault of the pharynx, by a sort of inspiratory nasal screatus, characteristic, but difficult to describe.

Impeded nasal respiration exists in some cases, owing to tumefaction or thickening of the nasal mucous membrane, or to accumulation of products of secretion in the nasal passages.

In many cases of chronic folliculous sore throat, as well as in chronic sore throat generally, there is a more or less plastic induration of the submucous connective tissues at the angles of the pharynx; that is to say, at the junction of the posterior and lateral walls behind the pharyngo-palatine folds, to so great an extent, sometimes, as to simulate additional adventitious post-palatine folds. They project into the cavity of the pharynx, along its posterior wall, and sometimes extend up to the pharyngeal portion of the Eustachian tube over the domain of the muscle (salpingo-pharyngis) which passes from that tube to the pharynx. This condition is independent of the follicular manifestations, and is often permanent after the latter have subsided. The mucous membrane covering these folds is often denuded of its epithelium, and presents in a high degree the so-called rawness of appearance; looking as though it might have been scraped with something rough, as a nutmeg-grater.

The presence of these indurated protrusions of mucous membrane sometimes interferes seriously with nasal respiration.

Impairment of hearing is at times attendant upon chronic follicular pharyngitis, this impairment being sometimes permanent. Disease of the pharyngeal mucous membrane is, in fact, a very frequent cause of aural disease, especially of disease of the middle ear, which very often has its origin in a catarrhal inflammation of the retronaso-pharyngeal mucous membrane.

The lower portion of the mucous membrane lining the Eustachian tube being continuous with the mucous membrane of the pharynx and palate, without any line of demarcation, is very apt to become engaged in inflammatory affections of the pharynx, especially when they occupy that portion in proximity to the orifice of the tube. Every inflammation occurring in this way is liable to be propagated along the tube, and thus to reach the structures of the middle ear. When there is chronic thickening of this part of the pharynx, or even of the soft palate, the pharyngeal orifice of the Eustachian tube may be so pressed upon as to exclude the access of air into the interior of the middle ear, and thus lead to disease as a result of simple mechanical obstruction, without any active participation whatever in the disease of the pharynx. And even when the soft palate is not affected in this manner, the posterior palatine arch may be pushed so far backward and upward by an enlarged tonsil as to produce a similar occlusion of the orifice of the tube. Then the connection of the tensor tympani muscle with the tensors of the palate is such that pressure may be exercised upon the labyrinthine structures of the middle ear, producing subjective intra-aural noises, which increase the impairment of hearing.

The Eustachian tube, as it were, bulges through the posterior portion of the lateral wall of the pharynx for the distance of a centimetre or a centimetre and a half, just in front of the posterior wall of the pharynx, leaving a sort of recess between its posterior surface and the junction of the posterior and lateral walls of the pharynx. The depth of this space, known anatomically as the recessus pharyngis lateralis, or fossa of Rosenmueller, depends therefore upon the length of tube projecting into the pharynx. This fossa of Rosenmueller is usually exceedingly distinct; but, as a result of inflammation of the mucous membrane, adhesions take place between the two sides and produce bands of tissue which stretch from one side of the walls of the fossa to the other, and in some cases the adhesions between the opposing mucous surfaces is continuous, so that the sulcus becomes obliterated, and there is no ocular evidence of its existence. A similar obliteration may also ensue as a result of hypertrophy of the glandular tissue, oftentimes profuse in this situation.

Inflammation of the pharyngeal mucous membrane covering the tube may very readily be propagated along its edges into the interior of the tube, and thus occasion deposits and accumulations of mucus or lymph, which, by their mere presence, or by producing organic obstruction, prevent the maintenance of due atmospheric pressure on both sides of the tympanic membrane, and thus lead to impairment of hearing from disease of the tube or of the middle ear itself.

Abnormal sensations in the throat exist almost invariably to a greater or less extent, and they are described by patients in various manners. Some of them complain of pricking sensations; others of a feeling as if there was a hair or a bristle that they could not get rid of; many complain of heat and burning. They are usually due to loss or absence of epithelium.

An elongated uvula, frequently coexistent with chronic folliculous pharyngitis, often gives rise to distressing symptoms; although there are many cases of considerable elongation of this structure, even when it is long enough to lie a short distance upon the base of the tongue, which are not at all attended by any of the symptoms usually considered indicative of relaxation or elongation. All the ordinary subjective symptoms of phthisis are said to have been produced in many instances by simple elongation of the uvula—not cough alone, but expectoration, and that not only mucous in character, but purulent, and even sanguinolent. These symptoms are said to be attended with acceleration of the pulse, hectic fever, and emaciation. It is likely that these latter symptoms are not entirely attributable to the elongation of the uvula, but in great measure to the depressing mental effect of a belief in the existence of pulmonary consumption on the part of the patient. The elongation of the uvula, in many instances, does not include its muscular structure, but is limited to the mucous membrane and the submucous connective tissue, which, being greatly relaxed, form a sort of pouch which becomes filled with a serous or a sero-plastic infiltration below the azygos muscles. Sometimes the mucous membrane has been drawn out into a sort of thin caudal extremity continuous with the body of the uvula. If the muscle is the seat of the infiltration, there is usually an increase in the transverse volume of the uvula, forming a condition of general hypertrophy, and not elongation merely.

Professor Green has reported a case in which an enlarged and elongated uvula was more than two inches in length, and nearly half an inch thick at its largest diameter.

Treatment.—The treatment of chronic folliculous pharyngitis is often unsatisfactory. This is due in part to the fact that the actual suffering is rarely so severe as to force strict adherence to the advice of the physician. The disease being emi-

nently chronic, requires chronic treatment, and this, again, is resisted by the patient. Furthermore, inasmuch as the general health is often apparently unimpaired, that is, so far as the patient's ability to continue at his usual avocation is concerned, avoidance of exposure to the causes of the affection cannot be secured. This is especially the case with people who gain their livelihood in great measure by the exercise of their voice. It is only when totally incapacitated for work that they submit to treatment; and then the mental depression under which they labor on account of it, still further impedes the progress towards cure.

Constitutional and local treatment are both requisite in these cases. The functions of the lungs, skin, bowels, and other emunctories must be maintained in as normal a condition as possible, by due attention to cleanliness, ventilation, clothing, diet, and temperature; and when hygienic observances are insufficient, medicinal agents are requisite in addition. Placidity of mind is an important feature in the treatment of clergymen, vocalists, and public speakers. Tonics, such as arsenic, iron, phosphorus and quinia, are often indicated. The scrofulous, syphilitic, tuberculous, arthritic, or any other diathesis, calls for suitable corresponding general treatment.

Local treatment is, in most cases, absolutely necessary to effect riddance of the local disease. In some cases its effects are quite prompt, and in some they are very tardy. Even in cases where local treatment does not appear to induce any diminution in the volume of the enlarged follicles, the benefit of local treatment in relieving subjective symptoms is often marked, reducing the lesion to one often encountered normally, in which there are large masses of enlarged follicles without giving rise to any subjective symptoms of local disease. In some cases no treatment whatever seems to have any beneficial effect on the symptoms, subjective or objective.

The favorite local treatment for chronic follicular pharyngitis consists in the topical application of the nitrate of silver for its absorbent and alterant effect upon the tissues; and although this method is much derided by some practitioners, there is little doubt that it is more efficacious, as a rule, than anything which has been suggested in substitution. The manner of application is a matter of great importance, and requires care and discrimination. Off-hand swabbing, which gags the

patient and bespatters healthy structures, does harm instead of good. The pharynx, if covered with secretions, should be cleansed by syringe, spray-douche, or mop, before the nitrate of silver is applied. This ablution washes away any adherent clumps of mucus, and secures a clean surface for the application—a very important point too seldom attended to. The nitrate of silver is usually applied in solution—a large sponge-mop or a brush being saturated with it—and then, after the superabundant liquid has been shaken off, swabbed over the parts as rapidly as possibly, the tongue being depressed by means of a tongue-depressor, the handle of a spoon, or some other contrivance. In cases of general chronic inflammation without special enlargement of the follicles, it is well, especially with children, to make a general application to the pharynx by means of a broad flat brush, carried well down to the lowest portion of the pharynx, so as to brush the posterior wall from below upward in a single motion. In cases in which there are a number of enlargements of follicles it is a much better plan to employ a small hair-pencil, or a very small piece of soft sponge, punk, or surgeon's cotton, held in a suitable pair of forceps (Figs. 53 and 54), and to press it for a few seconds

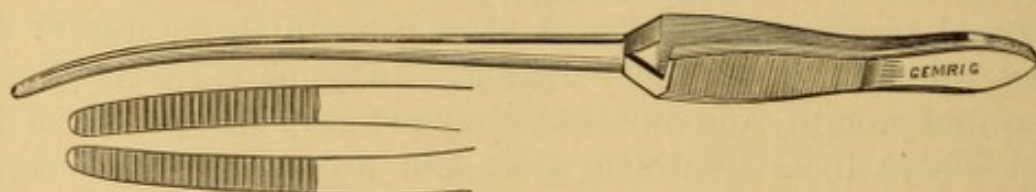


FIG. 53.—Author's forceps for local applications to pharynx.

upon the hypertrophied follicles and the ulcerated spots, one after another, gently, carefully, and effectually. Enough of the fluid will become distributed over the adjacent membrane for

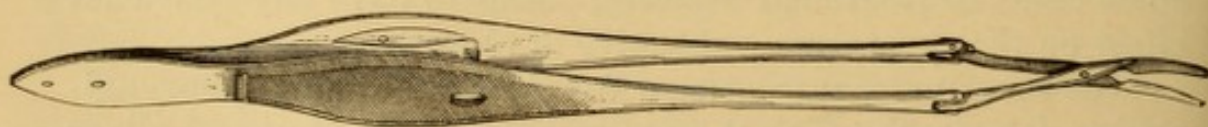


FIG. 54.—Dr. Mears' toothed forceps.

general application to the whole surface. To do this thoroughly may require several introductions of the instrument; a proceeding occupying a little time, to be sure, but one less apt to be attended by gagging or spasm, and much more apt to be beneficial in its effect. The impermeable coating which the

nitrate of silver forms with the membrane not only protects the parts from the air, and the secretions of the mouth, but condenses the subjacent connective tissue and exercises a salutary compression upon the enlarged follicle.

A solution containing from forty to sixty grains of the crystals to the ounce of water may be used in the first instance, and, if deemed advisable, its strength may be increased to one hundred and twenty, or even, in some instances, four hundred and eighty grains to the ounce, which represents saturation. Instead of using very strong solutions, it is better to melt some of the salt in a small platinum crucible, or a test-tube, and dip into it the warmed roughened end of a platinum or aluminium probe-point, so that a small quantity of the molten salt adheres to it firmly. This is safer than the use of the brittle stick-nitrate, which must be carefully guarded from fracture by enclosing it in a piece of mull or cotton cloth so that merely the point is exposed. Should a fragment break off, it will be caught in the cloth. The danger of dropping a piece of nitrate of silver into the larynx is a real one, and fatal laryngitis has ensued from such an accident. Some effectual appliance for preventing the possibility of such an accident is necessary; and the roughened probe dipped into the molten salt is the least troublesome. The caustic pencil (Fig. 48, p. 96) is an admirable method of applying the fused salt. The stronger solutions, as well as the pointed fused nitrate, are likewise used when it is desirable to produce destruction of tissue, and for this purpose must be maintained in contact with the parts for a number of seconds (20-60), and not removed immediately, as when a mere antiphlogistic or alterative effect is to be produced. Any excess of the nitrate deposited on the part is best diminished by touching it promptly with a solution of table salt or with milk. Although the applications of the nitrate of silver are in the main well borne, they sometimes provoke cough or produce a great deal of local distress, with stridor, and occasionally actual spasm of the glottis, even when carefully performed, and when not a drop of the fluid has fallen into the larynx. This remark applies also to the upper portion of the pharynx, above the level of the soft palate. For this reason it is well, when making an application to the parts for the first time, to test their sensitiveness by touching a single enlarged follicle, or group of follicles, and then to proceed further according to the indications. The

repetition of the application is made daily or at intervals of two, three, four, or more days, as the case may seem to require.¹

When, after a fair trial of two or three weeks, these applications have not been of any use, the plan may be adopted of splitting each follicle with the point of the knife, and then pressing a point of fused nitrate of silver, or the edge of a crystal of nitrate of silver, or of chromic acid, firmly secured, between the edges of the wound. In this way the remedial agent is brought in direct contact with the diseased structure, and its destruction or absorption effected more promptly than when the application is made merely upon the mucous membrane covering it.

Chloride of gold is, in some instances, a fair substitute for the nitrate of silver, and may be tried when the latter fails. It is usually used in solution of a strength varying from fifteen to sixty grains or more to the ounce of water.

Chloride of zinc, iodide of zinc, sulphate of zinc, sulphate of copper, caustic potash, iodoform, tannin, and other agents have been proposed as substitutes for nitrate of silver, and are often of much service; but they are inferior to it in the majority of cases. Dr. Mackenzie relies a good deal upon the use of the London paste,² carefully applied to the individual elevations with a sharpened wooden pen-holder, destroying a few groups of the follicles at a time, and repeating the process at intervals of a day or more, as the case may require.

Voltolini and others after him destroy these granulations with the galvanic cautery. Stoerck removes them bodily with gouge forceps; others scrape them off with a sharp spoon. Dr. Foulis substitutes the actual for the galvanic cautery, using an iron wire with a tapering bulb one-quarter inch thick, with which, at a dull red or even a black heat, he cauterizes each thickened nodule separately.³ When there is capillary engorgement, Mr. Lennox Browne divides the enlarged vessels, which supply blood to the follicles, by means of a fine galvano-

¹ A case has been reported by M. Duguet in which permanent discoloration of soft palate, pharynx, face, chest, and arms, had been apparently produced by cauterization of the pharynx with nitrate of silver, practised some years before. (Phil. Med. Times, Aug. 22, 1874, p. 751, from *le Progrès méd.*, June 13th.)

² Equal parts of caustic soda and unslacked lime in powder, made into a paste with water as required.

³ Brit. Med. Jour., Sept. 2, 1877, p. 405.

cautery point, obliterating them ; after which the follicles soon shrivel up and disappear.¹

In ulcerated cases, powdered iodoform, or a solution in ether or chloroform (one part in from twelve to twenty), will be found a serviceable remedy. As the chloroform or ether evaporate, the iodoform remains in a finely distributed coating.

In addition to this local treatment, the projection upon the parts, two or three times a day, a teaspoonful at a time, of intermittent sprays of weak (grs. i. to ij., ad f. $\frac{3}{4}$ j.) astringent solutions, such as tannin, alum, sulphate of zinc or copper, acetate of lead, iodine, carbolic acid, etc., is of great value, chiefly, perhaps, in keeping up an astringent effect upon the

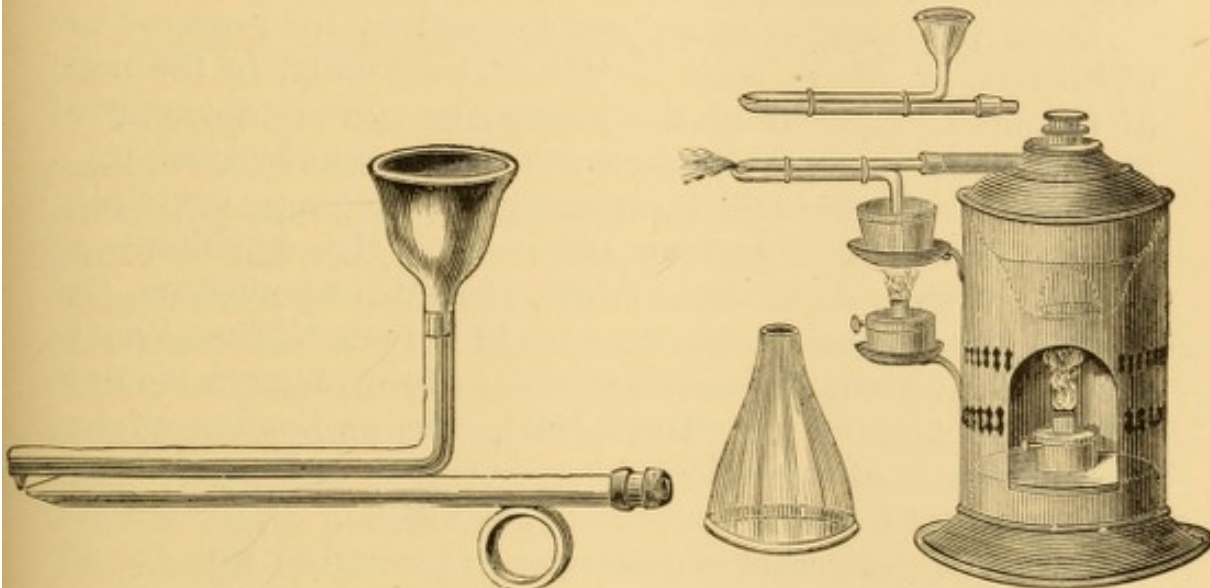


FIG. 55.

FIG. 56.

FIG. 55.—Author's arrangement of metallic spray-producer or nebulizer on Bergson's principle, with duck-bill tubes and reservoir on top; for use with compressed air from air-press or rubber bulb.

FIG. 56.—Author's arrangement of duck-bill glass tubes for sprays driven by steam, on Siegle's principle. The upper one shows reservoir blown on upper tube. The tubes are represented held in position by rubber bands, as first constructed, but it is better to have them cemented together.

tissues. I have had excellent result, even in non-specific cases, with similar use of bichloride of mercury (gr. j. ad f. $\frac{3}{4}$ iv.). A hand-ball apparatus is better for this purpose than a steam nebulizer.

As the mechanical impact of the portions of spray lends additional efficacy to this method of treatment in affections of the pharynx, it is often advantageous to use tubes so shaped that they can be inserted within the mouth (Figs. 55 and 56) or into a large cone-shaped guard or funnel held in the mouth.

¹ The Throat and its Diseases, London, 1878, p. 102.

There is sometimes advantage in connecting the reservoir with the upper tube, as in the modified apparatus exhibited by me in 1865 to the American Medical Association.¹ The terminal extremities of the tube may be arranged so as to force the spray in other directions when required for the extreme upper or lower portions of the pharynx and adjacent parts.

In obstinate cases it is often advisable to add to the constitutional treatment the administration of iodide of potassium or sodium, which will sometimes have a very satisfactory effect, and this will be heightened, in certain instances, by the tonic and alterant action of bichloride of mercury in minute (gr. $\frac{1}{120}$ to $\frac{1}{40}$) doses, even when there is no evidence of syphilitic taint, and independently, also, of any dyscrasia whatever.

Local treatment is sometimes assisted by the repeated use of blisters, or other counter-irritation, externally, to the nape of the neck, in front of the larynx, or at the supra-sternal notch. This treatment, however, is nearly out of vogue.

To alleviate pain and local annoyance, lozenges containing opium, hyoscyamus, conium, lactucarium, etc., or chlorate of potassium, chloride of ammonium, bromide of potassium, and the like, may be allowed to dissolve in the mouth from time to time. Confections of rose or chocolate form a good medium for the lozenge, but Dr. Morell-Mackenzie, of London, prefers the fruit-paste of the confectioner, in cases where the lozenges are prescribed for their immediate local effect. In the absence of a lozenge, confection of rose may be prescribed with the addition of some mineral acid, and a little oleo-resin of cubeb, or the recently prepared powder.

During the treatment of chronic folliculous pharyngitis the use of the voice should be interdicted, if possible, until the disease of the pharynx is well under control. If necessity compels the use of the voice, care must be taken to make the least use of it possible, and to avoid prolonged talking at any one time. To secure compliance with this injunction the patient should be distinctly informed that the use of the voice during the treatment will greatly retard any progress towards a cure. It is the impossibility, in many instances, of securing rest to the parts that renders their treatment protracted and

¹ Cohen: Inhalation; its Therapeutics and Practice. Phila. Ed., 1867, p. 32.

very often unsatisfactory. The habitual use of demulcent lozenges (Iceland moss, marsh mallow, gum arabic, gelatine) will often afford a good deal of relief and help to allay the irritability of the pneumogastric nerve. These lozenges can be made up by the confectioner in the form of simple gum-drops without sugar. Occasionally it may be advantageous to have a small quantity of lactucarium, conium, or other sedative incorporated into the mass, but then some restriction must be made as to the frequency of their use.

Inuring the skin to exposure by the daily cold bath should be urged upon all persons subject to exacerbation or exposure.

ATROPHIC PHARYNGITIS.

(Dry Catarrh of the Pharynx; Pharyngitis Sicca.)

This is a special variety of chronic pharyngitis attended by continuous irritation in the throat, with a sensation of dryness. It is rarely met with in young people, but often exists in middle adult life, and still more frequently in elderly subjects. It is regarded as an atrophied condition of the mucous membrane, sometimes the result of long-continued chronic sore throat. It may be confined to the infra-palatine portion of the pharynx, or involve its retro-nasal portion likewise, and occasionally the nasal passages. It is characterized by a pale, dry, and lustrous or highly polished appearance of the mucous membrane. The mucous membrane deprived of its complement of moisture is rendered an exceedingly thin, translucent layer, revealing the striæ of the constrictor muscles beneath it. Particles of dust from the street or workshop are apt to accumulate on this dry glossy membrane, and as there is little or no secretion present to assist in dislodging them, they become constant sources of irritation, leading at times to erosion of the epithelial layer, which sometimes becomes covered with desiccated grayish crusts, that excoriate the parts when detached, so that slight local hemorrhages follow.

Symptoms.—The subjective symptoms are uncomfortable sensations of dryness of the affected parts, sometimes attended with actual pain, especially in swallowing saliva; and less marked after the use of food or drink.

Diagnosis.—The pale, attenuated, and lustrous appearance of the mucous membrane, the enlarged area of the pharyngeal

cavity, and the apparent absence of secretion, are the main points of diagnosis.

Prognosis.—The affection is usually permanent, though susceptible of relief. There are no methods known of overcoming the atrophy. In young subjects the prognosis is rather favorable, the atrophy being more apparent than real.

Treatment.—Great relief is obtained in pharyngitis sicca by supplying to the parts that moisture in which they are deficient. This is to be done by the internal administration of remedies which excite the secretion from mucous membrane: such as cubeb (oleo-resin, ℥ xx., in sugar, after meals), pellitory, calamus, and other sialagogues; chloride of ammonium in small doses (grs. iij.—x.); iodide of potassium (grs. ij.—v.) when not contra-indicated. The frequent inhalation of sprays, or of the steam from hot water, will moisten the parts, and to a certain extent invite the local action of the systemic remedy; a process which is assisted still further by the frequent topical application of dilute glycerine. Dr. Fauvel, of Paris, uses locally the tincture of iodine with equal parts of glycerine, and likewise sprays of carbolic acid (1-1000 of water).

In several cases under my own care, apparently due chiefly to a habit of sleeping with the mouth open, the disease has been entirely removed in a few weeks by the use at night of an apparatus consisting of linen or leather support for the lower jaw, secured by webbing and buckles to a cap-piece adjusted to the top of the head,¹ thereby keeping the mouth forcibly closed during sleep, and encouraging normal respiration through the nasal passages only.

SCROFULOUS SORE THROAT.

As already mentioned, ulceration of the masses of enlarged and distended follicles of the pharynx in chronic sore throat has been regarded as a special manifestation due to scrofula. Drs. Travers² and Hamilton,³ and others, have directed attention to this subject. As described by Hamilton, there is a

¹ An inexpensive apparatus is supplied by Mr. Gemrig, of Philadelphia. In its absence a suspender, a bit of roller bandage, a handkerchief, or other contrivance may be substituted.

² Med. Clin. Trans., London, 1829, p. 254.

³ Cases in Hospital Practice, Strumous Sore Throat. Dub. Jour. Med. Sci., Nov., 1844, p. 282.

mild form which, when there is no ulceration, does not appear to differ from ordinary chronic sore throat with desiccated sanious mucus; and when there is ulceration over a large surface of the pharynx, or of the palate and tonsils in addition, it does not differ from what is often seen in debilitated subjects, whether scrofulous, tuberculous, syphilitic, rheumatic, or arthritic. Then he describes a severe form which includes cases with extensive ulceration of the soft palate, amounting sometimes to destruction of the uvula, and sometimes associated with perforation of the hard palate; either of which results, or both of them, may occur without engagement of the pharynx. These ulcerations he considers "lupoid" in character, having occasionally seen them preceded by superficial cutaneous lupus. When the pharynx is engaged, extensive adhesions with the palate are apt to ensue. He has seen indolent periostitis accompanying the disease, and periostitic tumors, soft nodes, in cases purely strumous. Hamilton acknowledges in many instances the existence of a syphilitic taint, though he believes that "the far greater portion of the disease depends upon a broken-down or strumous condition."

All subsequent writers admit the difficulty of distinguishing many cases of the disease from syphilitic manifestations. The test of treatment is relied on by some observers as the sole means of discrimination, and if the case is injured or unimproved by specific treatment, they place it in the category of scrofula, and resort to cod-liver oil and ferruginous tonics. Every one in extensive practice must have encountered cases of undoubted syphilis where the constitution is not benefited by anti-syphilitic remedies, and where pure tonics and fats are better. And it does not seem improbable that these so-called scrofulous sore throats are common sore throats in the subjects of latent inherited syphilitic taint of constitution, started into activity by the local irritation. An inherited syphilitic taint may remain latent an entire life, if nothing occurs to rouse it into activity, just as an acquired taint may remain dormant permanently or for an indefinite period. Thus I have attended a gentleman whose children and grandchildren were robust and free from any indication of constitutional infection. His sore throat, of several months' duration, intractable to ordinary measures of relief, yielded to specific treatment; yet the initial lesion had been contracted and cured more than fifty years before, and previous to his marriage, and there had been no other manifestation of specific taint in all that time. Should one of his grandchildren come under my care with ulcerated sore throat, I would be justifiable in attributing it to specific origin, in the absence of other direct cause; while a practitioner unacquainted with the grandfather's history might, if imbued with modern views, be disposed to regard it as a case of scrofulous sore throat difficult to differentiate from analogous manifestations of syphilis.

Hamilton's treatment consisted in the internal administration of iodide of potassium, and local applications of nitrate of silver, as well in the "purely scrofulous form of the disease," as in that in which it is mixed with an old or faint syphilitic taint.

Other authors regard the severer manifestations of scrofulous sore throat as lupus of the throat.¹ The manifestations in some of these cases involve likewise the face, nasal passages, the lips, and the tongue; the special throat lesion being located on the hard and soft palate, the palatine folds, tonsils, and pharynx. The anatomical lesions of the mucous membrane are described as erythema, circumscribed nodosities, induration, exuberant granulations, interstitial atrophy, and extensive ulcerations, with depressed stellate cicatrices and adhesions of contiguous surfaces. The manifestations are slow in progress. The symptoms are slight until the ulcerative process interferes with function, up to which period there is rather anæsthesia than hyperæsthesia, deglutition being unimpeded and the voice unaffected.

It is evident that the severity of scrofulous sore throat is often due to the existence of a syphilitic taint, inherited or acquired. I am not disposed to incline favorably toward considering it a special variety until its points of discrimination from severe catarrhal sore throat, on the one hand, and syphilitic sore throat, on the other, are more accurately determined. The treatment recommended is nourishing diet, fresh air, tonics, cod-liver oil and the iodides, and frequent local cauterization.

DARTROUS SORE THROAT.

Sore throats, due to eruptions on the mucous membrane of the palate, palatine folds, tonsils, and pharynx, have been described by authors (especially French authors) as diseases of the throat similar to the affections of the skin, with which they are usually associated. In some instances these eruptions are described with physical characters like those of the skin; in others, with such differences as the anatomical construction of analogous constituents of skin and mucous membrane would naturally account for. The mucous membranes

¹ Georges Homolle: *Des scrofulides graves de la muqueuse bucco-pharyngienne (Angines scrofulieuses graves. Lupus de la gorge)*. Paris, 1875.

being warm and moist, the appearances are often such as are produced in the analogous disease of the skin under the use of cataplasms.

Examples of some of these varieties have occasionally come under my observation, but have been hitherto regarded as accidental manifestations in the course of ordinary sore throat. Thus I have seen papules, vesicles, and pustules in the palate, palatine folds, and pharynx, but sometimes without similar manifestations in the skin, and not sufficiently often to justify, in my own mind, a separate classification on the score of special diathesis. Skin diseases are as frequent in America as on the continent of Europe, in all the varieties, perhaps, mentioned by dermatologists; and certainly if there were strong disposition to similar manifestations in the throat, it is rather singular that they have so rarely come under my observation. It may be that they are rare in America; it may be that I am unable to recognize them when I do see them. Nor am I aware that they have prominently attracted the attention of dermatologists in this country. On the other hand, many subjects of skin disease suffer with ordinary sore throat without any characteristic manifestations in the mucous membrane. The eruptions alluded to include acne, urticaria, eczema, pemphigus, psoriasis, and pityriasis.

Some of these manifestations are due to the medicinal use of certain drugs, as antimony, belladonna, and bromine.

CHAPTER VII.

SPECIAL AFFECTIONS OF THE SOFT PALATE AND UVULA.

THE soft palate is implicated in various affections of the throat by reason of its intimate connections with pharynx, tonsils, nares, larynx, and œsophagus. Recent researches have developed some points in connection with its musculature, which are important in reference to the physiology of deglutition, and occlusion of the upper or retro-nasal portion of the pharynx, and consequently on the pathology of dysphagia. Brief allusion is made to these observations, as they have not yet been generally described in English works on anatomy.

THE PHARYNGO-PALATINE MUSCLES.

Merkel¹ describes both of the pharyngo-palatine muscles as crossing in the middle line of the posterior wall of the pharynx, and then coursing further on opposite sides to unite with the upper fibres of the inferior constrictor muscle of the pharynx. They are thus enabled to participate in the function of the constrictor muscle, and a sort of sphincter is thereby formed, capable of shutting off the nasal portion of the pharynx. He considers that these two pharyngo-palatine muscles form a circular muscle, similar to the orbicularis oris, and other circular muscles of the body which have no firm points of insertion.

Luschka,² who carefully studied the whole subject anew, while referring to the opinions of Merkel and others, considers the pharyngo-palatine muscles of each side to form a whole, which, in addition to the function of assisting in shutting off the naso-pharyngeal portion of the pharynx from its lower portion, also possesses the function of shortening the pharynx, and raising the larynx in a considerable degree. Luschka

¹ Anatomie und Physiologie des menschlichen Stimm- und Sprachorganes. Leipzig, 1863, pp. 217-224.

² Virchow's Archiv, March 18, 1868, pp. 480-489, with illustrations.

recognizes a thyroidal portion and a pharyngo-palatinal portion of the muscle, which he designates as the *musculus thyro-pharyngo-palatinus*, indicative of its points of attachment with the palate, pharynx, and thyroid cartilage.

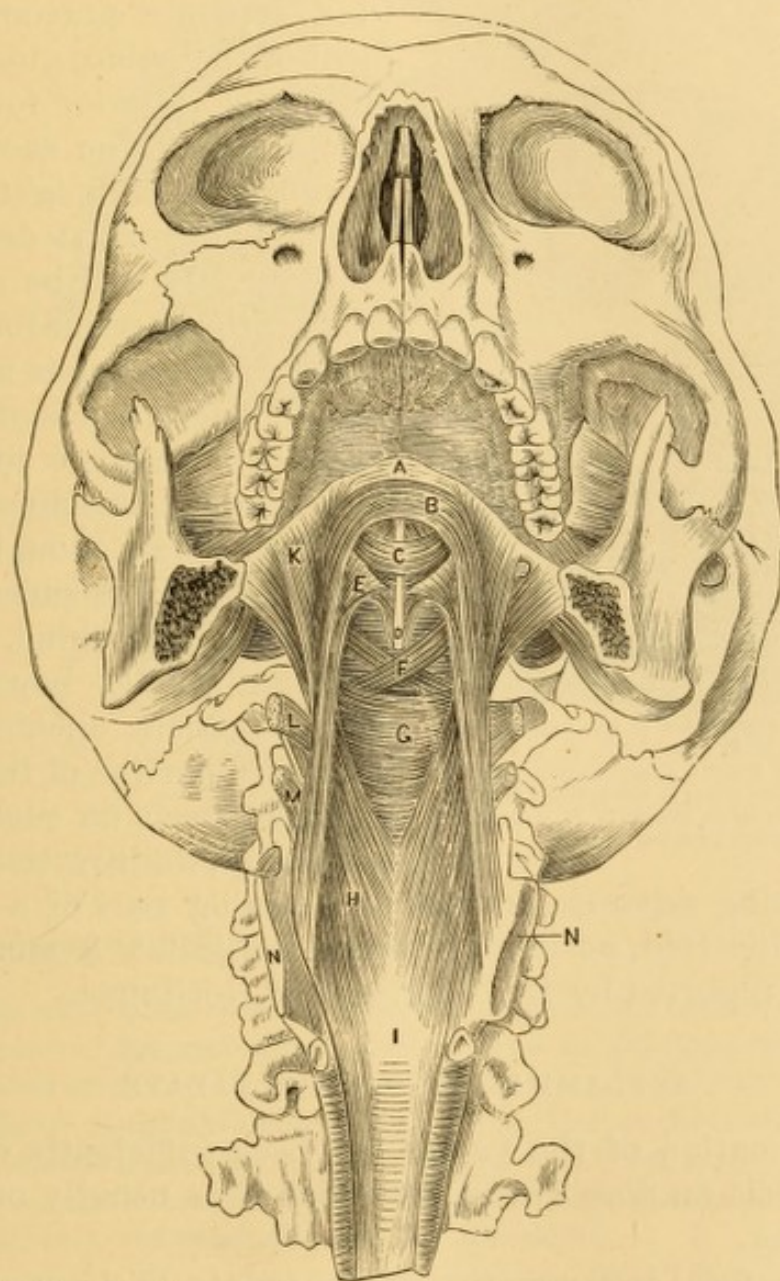


FIG. 57.—Anterior view of the musculature of the pharynx and palate after removal of tongue, hyoid bone, and larynx as far as the posterior segment of its thyroid cartilage. (Luschka.)

- A, Aponeurosis of the soft palate.
 B, The thyroidal portion of the palato-pharyngeus.
 C, The archlike connection of the levator palati.
 D, Azygos uvulae muscle.
 E, G, Bundle of constrictors in posterior wall of pharynx.
 H, Pharyngeal portion, and
 K, Palatine portion of palato-pharyngeus.

- L, Glosso-pharyngeus.
 M, Hyo-pharyngeus.
 N, Posterior segment of thyroid cartilage.
 I, Aponeurosis of thyro-pharyngo-palatine muscle, below which are the longitudinal fibres of the oesophagus springing from it.

The anterior aspect of the course of its fibres is shown in the accompanying illustration (Fig. 57).

The posterior aspect of the pharyngo-palatine and contiguous muscles is shown in another illustration (Fig. 58).

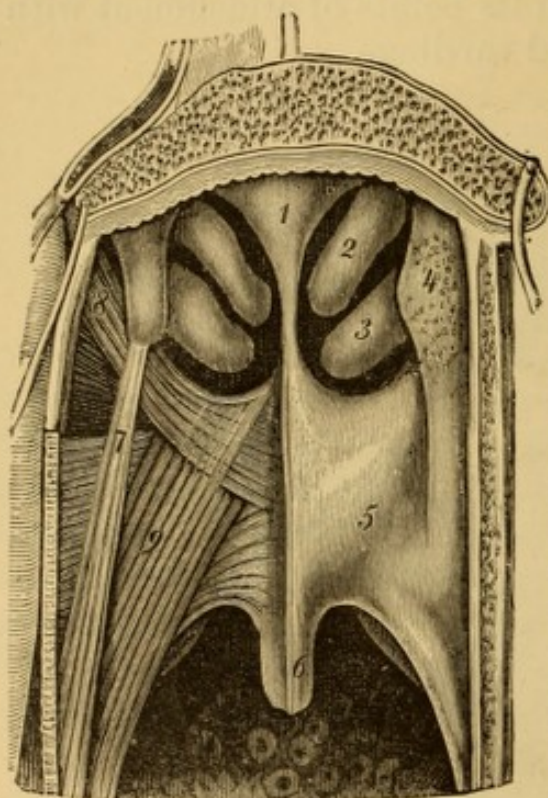


FIG. 58.—Posterior view of the palatine muscles. (Luschka.) 1, septum; 2, 3, middle and lower turbinated bones; 4, pharyngeal protuberance of Eustachian tube; 5, soft palate; 6, uvula; 7, salpingo-pharyngeus muscle; 8, levator veli muscle; 9, pharyngo-palatine muscle.

An occasional anomalous condition of the palate consists in a separate mucous investment of the palato-glossus muscle in the anterior fold of the palate, leaving on each side an opening, which might be mistaken for ulcerative destruction of tissue. It will be seen (Fig. 59) that the anterior folds of the palate are incomplete upon each side, in consequence of an elongated oval aperture just above their lingual attachments, and which is large enough to disclose the anterior surface of the posterior fold behind. The inner and slender boundary of each abnormal opening is the main free portion of the palato-glossus muscle on each side respectively, the investment of the

muscle being separate, instead of forming part of a continuous palatine fold, as in the normal subject. A similar case has been reported by Dr. Wolters,¹ of Göttingen.

INFLAMMATION OF THE PALATE.

Inflammation of the palate has been sufficiently described in the article on Sore Throat, of which it is usually one of the phenomena.

A superficial inflammation of the palate, without any other manifestation of disease, sometimes gives rise to a more or less harassing cough, especially upon eating or drinking. It seems as though a hyperæsthesia of the parts rendered them exquisitely sensitive to the contact even of food. In some cases the use of the tooth-brush provokes the cough.

¹ Henle and Pfeufer's *Zeitschrift für rationelle Medecin*, 1859, 3d series, 7th vol., p. 156, illustrated on Plate IV.

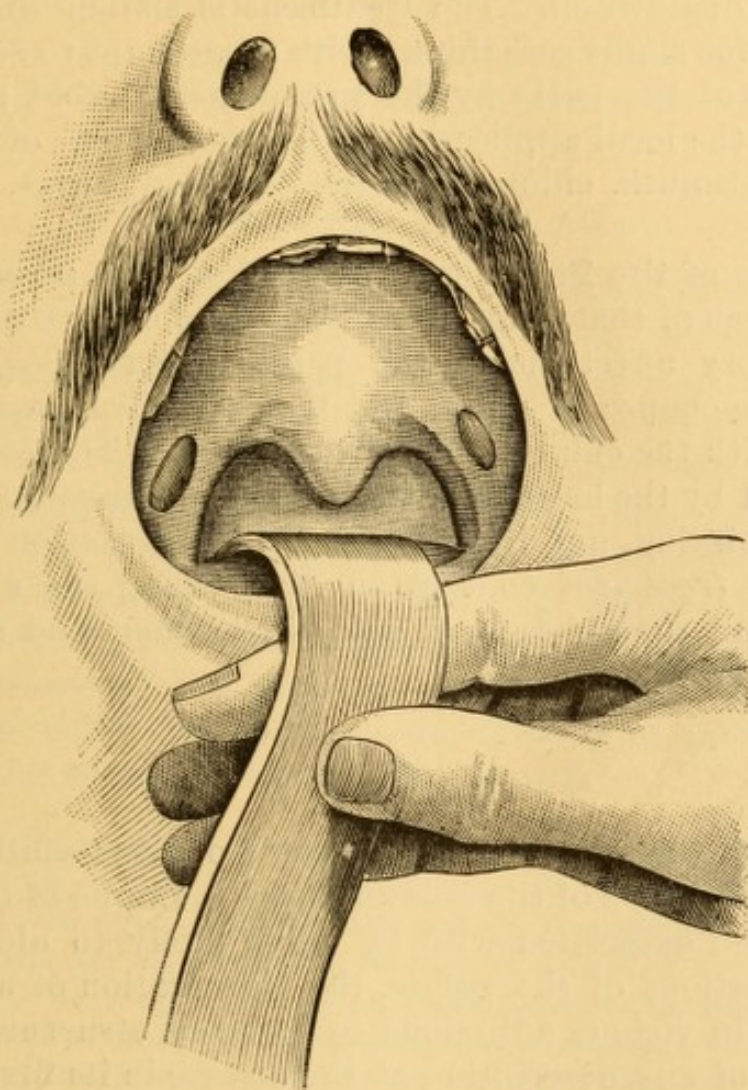


FIG. 59.—Separate investment of the palato-glossi muscles.¹ (From a drawing by Dr. Packard.)

In a case which came under my observation in 1870, the patient, a robust man, fifty-four years of age, had always suffered from an annoying tickling cough, every morning on rinsing his mouth, and at no other period of the day. Time of year and change of climate had no effect upon it. The cough recurred invariably, no matter in what part of the world he happened to be sojourning. He told me that an uncle, who had been similarly affected, finally became unable to swallow (from paralysis?), and eventually died in consequence.

Superficial inflammation of the palate is sometimes an epiphenomenon in non-specific parenchymatous inflammation of the larynx, under which circumstance the discrimination of the combined disease from syphilitic inflammation is not always easy. It also occurs in some cases of tuberculous disease of the lungs, and of the larynx, and compromises the integrity of

¹ The author: *The Medical Record*, New York, July 20, 1878, p. 45.

the act of deglutition. The treatment is similar to the local treatment for slight sore throat, with an attempt to subdue the irritability of the parts by the propulsion of cold astringent sprays, or the local application of neutral nitrate of bismuth, borate of bismuth, chloral, and the like in glycerine.

Abscess of the Palate may result from any severe form of inflammation of that structure. The *symptoms* are those of all inflammatory affections of the palate generally—pain, dysphagia, dissonance of voice, and flow of saliva, increasing in severity with the enlargement of the abscess. The *diagnosis* is determined by the localized tumefaction and discoloration, perhaps by pointing, and by the evidence of fluctuation on palpation. The *treatment* consists in discharging the abscess by incision and the subsequent use of emollient and astringent gargles or mouth washes.

LUPUS.

Lupus of the soft palate is rare, and occurs usually in connection with lupus of the face and neck. Lupus of the larynx may be also associated with it. It is likely to ulcerate and destroy portions of the palate, the cicatrization of which may terminate in vicious adhesions to adjacent structures. I am not aware of any description of the disease in its first invasion of the palate. At an advanced stage it is described as presenting small, irregular nodules, some of them minute and some as large as small peas, symmetrically arranged, and causing considerable distortion of configuration. At a later stage ulceration occurs in some instances, and then the parts present much the same physical appearance as the ulcerations in syphilitic subjects. The cicatrization of the ulcers increases the distortion of parts.

Symptoms.—There are no special symptoms, the subjective manifestations being similar to other forms of chronic sore throat.

Diagnosis.—This rests upon its association with external manifestations of lupus. In the ulcerative stages, the aspect of the parts is similar to that in syphilitic subjects.

Prognosis.—This is unfavorable. Ulcerations are apt to recur even after cicatrization.

Treatment.—This is usually limited to meeting the various indications, with the internal administration of cod-liver oil, iodide of iron, and the like, and cauterization of ulcerated surfaces.

MORBID GROWTHS OF THE PALATE.

Tumors of various kinds become developed in the soft palate. They are of comparatively infrequent occurrence. Inspection and palpation reveal their existence and consistence.

The symptoms to which they give rise are dysphagia, cough, difficulty in articulation, and alteration in the resonance of the voice, which often acquires the nasal twang from imperfect occlusion of the pharynx in the enunciation of certain sounds, or a flat dissonance from occlusion of the nasal passages. Small tumors do not give occasion to any symptoms whatever in some instances; and in others occasion intense paroxysmal cough, this being dependent on the locality of the tumor and the patient's susceptibility to reflex action.

A young lady, twenty years of age, applied to me for relief from an habitual, spasmodic cough, excited by laughing or energetic conversation, and which seemed to me to be due to reflex irritation from the presence of a papilloma, the size of her normal uvula, attached to the angle of contact of the left palatine folds. After removal of the growth the disposition to cough ceased. Another lady was relieved of similar cough by removal of a small cyst, with cheesy contents, from the same locality. A public speaker, thirty-eight years of age, who had been much annoyed for months by intermittent cough and hoarseness, so frequent and so certain to follow any attempt at addressing an audience as to interfere with the exercise of his vocation, had a small, pointed papilloma, not larger than the bulk of a small pea, located in this same angle, which was removed, and the stump cauterized as in the other cases; and he, too, became rid of his cough. In these three cases, which comprise all of the kind in my case-books, the lesion was on the left side, and the relief on removal, so to speak, immediate.

*Adenomas*¹ of the palate usually occupy the posterior surface of the palate. They are of slow growth, so that a number of years elapse before the slight symptoms to which they give rise are sufficiently prominent to attract close attention. These are at first a nasal twang to the voice, and gradually increasing

¹ For examples see Leteuneur: Arch. gén. de méd., April, May, June, 1871, p. 529; from Journ. de méd. de l'ouest, Avril 30, 1870. Dr. Clinton Wagner: N. Y. Med. Jour., March, 1874, p. 272.

mechanical dysphagia, first for liquids only, and without pain. On examining the throat, a more or less voluminous tumor, regular in contour or nodulated, is seen on one or other side of the palate beneath the mucous membrane, encroaching on the cavities of mouth and pharynx, firm and non-elastic to the touch. These tumors are usually non-adherent, or but slightly adherent to the mucous membrane. Of three cases, records of which are before me, all occurred in females; but adenomas are not confined to the sex. The prognosis of operation is good, as they can be removed entire.

The treatment of these tumors consists in removal by excision and evulsion; or by constriction, as may be most convenient. The mouth being distended, and the tongue kept out of the way, a single or double incision is made through the overlying mucous membrane, any adhesions are torn or dissected away as may be necessary, and the mass removed by enucleation with the finger. Hemorrhage is to be arrested by the tampon, with ice, hemostatics, or the incandescent caутery when required.

Cystomas are usually developed as retention cysts from obstruction of the orifices of the muciparous glands. They vary in size from the bulk of small shot to that of small eggs. They are recognized by their globular or oval form, and sometimes by the sense of fluctuation on palpation.

Fibromas are usually small and pedunculated. They occur most frequently upon the posterior surface of the palate, are slow in growth, and eventually project below the free edge of the palate.

Papillomas are quite small, rarely exceeding the size of peas, and are often dendritic. They are sometimes sessile, sometimes pedunculated.

Sarcomas of the palate¹ give rise to symptoms and general manifestations similar to those of other formations. They may attain a large size, and encroach so much on the pharynx as to compromise integrity of respiration, and necessitate tracheotomy in consequence. They require removal.

*Myxomas*² are usually small and pedunculated, and easily

¹ For examples see Christopher Heath: Diseases of the Jaw. The Lancet, Nov. 18, 1876, p. 712, illustrated. Ibid., April 15, 1876.

² For examples see Méplain (Bull. gén. de thérap., t. lxxxv., p. 547). The Practitioner, April, 1874, p. 290. Alfred Baker, Brit. Med. Jour., Aug. 4, 1877, p. 138.

removed by torsion. They may attain a large size, so that, in some instances,¹ partial excision of the jaw is requisite for their removal. Recurrence sometimes takes place after excision and evulsion. In one instance a recurrent growth of this kind was eventually destroyed by the injection of a drop of acetic acid.²

Lipomas are stated to occupy indiscriminately all points of the mouth, lips, tongue, gums, cheeks, roof of mouth, soft palate, and palatine folds.³

Myoma has been seen, the size of a small pea, in the submucosa of the posterior surface of the soft palate.⁴

Carcinoma of the soft palate is rare as a primitive affection, being usually encountered as an extension from cancer of the tonsil. It occurs in the epithelial form most frequently, but also in the medullary form; the discriminating characteristics being similar to those of the respective varieties of carcinoma elsewhere. It is liable to be confounded with syphilitic disease at an early stage. Subsequently it gives rise to ulceration and hemorrhage. The treatment is palliative.

Treatment.—Benign tumors of the palate are usually removed by incising the overlying mucous membrane, and then peeling the growth out with the fingers. Early operation is demanded, because the growths are liable to enlarge with more or less rapidity, and occasion very serious symptoms, interfering with deglutition and respiration, and necessitating very severe operations on account of the extent of tissue involved. Pedunculated tumors are usually removed by excision with curved scissors; or by the constricting wire or chain loop.

Cysts with fluid contents are emptied by puncture or incision, are afterward cauterized with nitrate of silver or strong acid, or if large are injected with irritating fluid (tincture of iodine, carbolic acid), to excite inflammatory adhesions of their walls. Small cysts are removed bodily by excision.

Malignant tumors are rarely subjected to operative inter-

¹ Baker. loc. cit.

² Méplain, loc. cit.

³ Labat (Thèse de Paris, 1874, based on thirty-two collected cases): London Medical Record, April 14, 1875, p. 277.

⁴ Wagner: Ziemssen's Cyclopædia, N. Y. ed., vol. vi., p. 985.

ference on account of the difficulty of removing all the diseased tissue, and the liability to subsequent hemorrhage from direct implication of the large blood-vessels.

DEFORMATIVE ADHESIONS OF THE SOFT PALATE.

Adhesions of the soft palate to the tonsils, to the pharynx, or to the tongue, or to all these structures more or less extensively, occasionally amounting to complete occlusion of the supra-palatine portion of the pharynx, sometimes occur as the result of inflammation, ulceration, and cicatrization, most frequently in connection with syphilis, but also in so-called scrofulous ulceration, in lupus, and in the ulcerous or malignant sore throats of diphtheria. Adhesions likewise occur as the result of traumatic injuries. The adherence may be partial and unilateral, or so complete as to cut off all communication between the upper and lower portions of the pharynx. To remedy this condition, the parts must be separated with the knife, or incandescent cautery, and the cut edges thoroughly cauterized to prevent immediate readhesion. Bits of lint may be interposed to assist this purpose, the tents being attached to a string confined by adhesive strips outside of the mouth, or tied around the ear—without which precaution they might, when detached, fall into the larynx, or upon it, and produce serious consequences.

Tubes may be introduced through nostrils and pharynx to prevent complete cicatrization; or ligatures be passed through sound portions of the palate, and then drawn forward and attached to the ear. The tendency to reunion of the cicatrices is very great. I have seen a number of these operations performed with very little benefit, and some without any. Systematic dilatation does not hold out much prospect of success, and must usually be kept up more or less continuously at intervals of one or two days. This can be done by the patient. It has been proposed to divide the healthy soft palate on each side by long incisions, in the hope that the flaps will remain separate and furnish communication between the mouth and upper portion of the pharynx.

An instructive case of extensive adhesion of the inferior margin of the soft palate to the posterior wall of the pharynx, with a description of the parts seen

on dissection, has been narrated by Dr. Wm. Turner,¹ who refers to two similar cases, one related by Rudtorffer,² and the other by Otto.³

CLEFT PALATE.

This affection is usually congenital, but may also result from disease or accident. It is remedied by means of a surgical operation, or by the employment of an obturator supplied by a skilful dentist.

In operating upon a case where the cleft concerns the soft palate alone, the edges are pared, silk or wire sutures are inserted into the flaps, and the parts carefully adjusted. Undue tension is relieved by division of the levator palati muscles on either side, and, if need be, by division of the posterior palatine fold. The latter operation is best performed below the tonsil; and the former by the method of Pollock, which is to insert a double-edged knife through the anterior mucous membrane just within the hamular process, and then to divide the muscle, or rather saw it through, by raising and lowering the handle, producing in this way an entire division of the muscle without a large wound anteriorly.

Cleft of the hard and soft palate may often be permanently closed at one operation. Sometimes the parts give way in more or less of their extent, necessitating a second operation for the closure of the gap. It is necessary to keep the mouth open by a distender during the operation.

One of the best operations is that of Langenbeck, which, with a slight modification, I have completed expeditiously in a single sitting as follows:—

The mouth having been distended by Elsberg's modification of the gag devised by Mussey, the edges of the entire cleft were split instead of being pared. This was done in a case of enormous cleft (Figs. 68 and 69), to avoid any loss of tissue. An incision was then made, according to the indications laid down by Langenbeck, on each side of the alveolar ridge, extending from a line on a level with the second incisor tooth, as far back as the last molar, the incision penetrating into the bone. A blunt, flat blade of steel, bent at its extremity to an angle of about forty-five degrees, was insinuated beneath the periosteum, and

¹ Edinb. Med. Jour., Jan., 1860, p. 612, illustrated.

² Abhandlung über die einfachste und sicherste Operationsmethode eingesperrten Leisten und Schenkelbrüche, vol. i., p. 192, Wien, 1805.

³ Handbuch der Pathol. Anat., p. 210, note, Breslau, 1813. See, also, Mauriac: Gaz. méd., Paris, March 14, 1876; Verneuil: Soc. de chir. de Paris, 1876.

gently urged forward with a sawing motion until it appeared in the slit at the cleft, the instrument being kept all the time in close contact with bone, so as to raise periosteum and mucous membrane together. This motion was then continued upward and downward until the entire flap was raised free from the bone. The elevator muscles of the palate were then divided by the method of Pollock, the incision for this purpose being on a line with, and close to, the posterior portion of the incision through the hard structures. The parts, in the instance referred to, came together without any necessity for section of the posterior palatine fold, which was therefore left intact. Wire sutures were passed through the edges of the flap by Langenbeck's needle, except as the uvula was approached, when a needle in the form of a semicircle, and held in Schwerdt's forceps, was found to suit better for these very movable parts. Several points of suture were placed in the hard and soft palate, and two in the uvula. The former were secured by a shot on each side of the cleft, the latter by a single shot. The central suture cut its way out in four or five days; the others all held, and in eight days the entire wound had united, except a small oval opening, comprising the place which had been secured by the suture which cut out. This opening steadily contracted to the size of a small pin-head, and gradually closed entirely without interference.

The subject of cleft palate, though belonging to the surgery of the mouth rather than that of the throat, is mentioned here to draw attention to the success attained in splitting the edges of the flap instead of paring them, the operation being believed to be unique in that particular. A detailed account of the operation has been published elsewhere.¹

An excellent account of operations of this kind, based on an analysis of fifty-five cases, has been written by Dr. Whitehead.²

The late Sir William Fergusson, of London, suggested the closing of clefts in the hard palate by segments of bone detached by chiselling them from the sides, and then drawn together and secured by suture. It has been stated that necrosis of the bone sometimes takes place at the point of division, and that severe hemorrhage has caused failure in the operation.³ Dr. J. Ewing Mears, of Philadelphia, has recently used the saw instead of the chisel for detaching the segments of bone, with complete success in avoiding both of these accidents. He uses the saw devised by Mr. Adams for subcutaneous section of the femur. A small incision is made in the soft palate at the line of attachment to the hard palate, the saw introduced, and the bone divided from behind forward, following the line

¹ Trans. Am. Med. Assn., 1872, p. 479.

² Am. Jour. Med. Sci., Oct., 1868, p. 383.

³ Smith: The Lancet, Sept. 22, 1877.

of incision previously made through the soft structures covering the hard palate.¹ Since publishing the record of his first operation, he has performed several similar ones with similar success.²

The skilful adaptation of an artificial velum, however, is much more successful in improving the voice, and is gradually superseding resort to severe and uncertain operative procedures.

WOUNDS OF THE SOFT PALATE.

Wounds of the soft palate occur as the result of accident, but are frequently made by the knife of the surgeon. In some instances—gun-shot wounds, for example—they are associated with wounds of the hard palate. Occasionally they are due to foreign bodies in the upper portion of the pharynx, which lacerate the posterior surface of the soft palate during extraction. The nature and extent of the wound is determined by direct inspection and inspection by reflecting mirrors, and by palpation with the fingers and with probes. A wound through the palate occasions the usual dissonance of voice and impairment of articulation. Simple incised wounds heal readily on careful approximation of the raw surfaces with wire sutures, secured by shot or plate, as in the operation of staphyloraphy. Lacerated wounds are brought together as well as may be by similar suture; and cicatrization of the gaping portions is facilitated by touching the approximated angles of the wound with nitric acid or nitrate of silver, so as to excite inflammatory swelling and adhesion at these points; and the process is repeated along the adjoining angles of the contracting gap until it is closed. A large wound requires the operation for cleft palate, or the adaptation of an artificial plate or obturator.

Wounds of the palate sometimes implicate the internal carotid artery, in which case ligation of the common carotid is indicated. Severe or recurrent hemorrhage from minor branches sometimes requires ligation of the external carotid.

NEUROSES OF THE PALATE.

Anæsthesia of the palate sometimes exists in insane patients. It likewise results, to a slight extent, from the inter-

¹ The Lancet, Dec. 15, 1877, p. 901.

² Verbal communication.

nal use of bromide of potassium. It sometimes accompanies paralysis of the palate.

Treatment.—The local action of pungent or sapid substances in lozenges, such as pepper, cubeb, and guaiacum; systematic strokings with the electric brush; and the use of acid gargles are the means most frequently resorted to in anæsthesia.

Hyperæsthesia occurs in many inflammations, and sometimes exists as a morbid sensibility, independent of apparent disease. The symptoms of the affection are pain, dysphagia, morbid sensations of dryness and of the presence of a foreign body, and irritability to contact of food and other substances.

Treatment.—The internal use of bromide of potassium; superficial cauterization with nitrate of silver; the local action of the galvanic current—the positive electrode to the palate, the negative to the nape of the neck; sprays of ice-water, tannin, or of bromide of potassium; the local use of fragments of ice, and topical applications of aconite, morphia, chloral, and bismuth, in glycerine or mucilage, are the means usually employed to overcome hyperæsthesia of the palate.

Neuralgia of the palate is treated by the internal use of quinia, iron, arsenic, and bromide of potassium.

Spasm is combated by bromide of potassium internally, and the local use of electricity as in hyperæsthesia.

Paralysis.—Paralysis of the palate occurs as a characteristic sequel of diphtheria, and sometimes follows ordinary forms of catarrhal sore throat.¹

In a case under my care, in 1870, the paralysis appeared subsequent to the termination of a successful treatment for chronic nasal catarrh. The mucous membrane of the turbinated bones had been very much thickened, and had been freely removed with forceps; this, and the local use of salt-water, having constituted the essential portion of the treatment. Some months afterward, the patient, a nintelligent gentleman, some thirty-five years of age, came to me to see what could be done to remedy a difficulty of swallowing that had been gradually coming on. There was an impossibility to swallow liquids; in the attempt to do so nearly every drop returned by the nose, and none passed into the œsoph-

¹ For examples, see *Med. Times and Gaz.*, March 4, 1871, pp. 262-3.

agus. The patient could not swallow soup; could not quench his thirst. There was no trouble in swallowing solids. Examination revealed paralysis of the elevator muscles of the palate. Treatment by electricity was adopted, the negative electrode from the second coil of an induction apparatus being moved over the muscular structure of the palate anteriorly and posteriorly, the positive electrode being placed at some indifferent portion of the body. A rather protracted treatment gradually restored the lost powers of deglutition, but the demands of public duties at home from time to time rendered the treatment more protracted than if it could have been employed continuously.

A moderate or incomplete degree of bilateral paralysis is known as *relaxed palate*.

Paralysis of the palate may be of central origin. It is then usually unilateral, and may be unassociated with paralysis of the facial muscles of the same side. It occurs in all forms of general paralysis. I have seen it the first indication of general paralysis.

Bilateral paralysis usually affects all the muscles of the palate, but some of them to a greater degree than others. When the elevator muscles are paralyzed, the palate hangs low down in the pharyngeal cavity, and may almost touch the tongue. The muscles do not react to contact of foreign bodies.

The *symptoms* are, nasal resonance of speech from want of occlusion of pharynx in articulation of nasal and naso-dental sounds; dysphagia or aphagia, food being forced in deglutition into the supra-palatine portion of the pharynx and escaping thence by the nostrils anteriorly.

Treatment.—Treatment is required suitable to the general or local lesion to which the paralysis is due. Locally, sialagogues, such as pellitory root and mezereum, or pepper and cubeb, are used to rouse the activity of the capillary circulation.

Electricity is of great service—the negative electrode being moved over the paralyzed muscles, and the positive electrode at the nape of the neck, in the hand, or at any convenient point externally. Just force enough should be employed to excite contraction, and that current should be used to which the muscles best respond. A slowly intermitted battery current is usually requisite at first.

The remedies employed internally are, phosphide of zinc (one-twelfth to one-sixth of a grain), and ignatia amara (one-half grain of the extract; ten drops of the compound tincture), three times a day; or strychnia (one grain to the ounce of

water, commencing with ten or twenty drops three times a day, and increasing the dose one drop each day until some constitutional symptoms are produced, or, if they are not developed, until the patient is taking from three-eighths to three-quarters of a grain of the strychnia daily). Strychnia may be administered hypodermically (one-sixtieth to one-twentieth of a grain of the nitrate or sulphate) every third or fourth day.

SPECIAL AFFECTIONS OF THE UVULA.

Chronic Elongation of the Uvula.—The uvula is liable to elongation with and without concomitant hypertrophy. It occurs most frequently in connection with chronic sore throat. In some instances the mucous membrane alone is elongated, but in others the muscular tissue is involved also. When hypertrophied, the excess of size is chiefly due to interstitial deposit beneath the mucous membrane. When the mucous membrane alone is involved, the elongation presents as a thin strip of tissue tapering to a point. In many cases the contact of the uvula with the tongue produces a tickling sensation, with a disposition to hem so as to get rid of it. Sometimes the uvula dips down behind the epiglottis, exciting frequent cough, and not unfrequently hoarseness, from the congestion produced in the larynx. Sometimes suffocative paroxysms are induced in this way. These symptoms are most frequent on lying down, which favors the mechanical condition giving rise to them. Occasionally the elongation is so great that half an inch of the organ rests upon the tongue; and one or two cases have been recorded in which the enlarged uvula could be brought between the incisor teeth. Many instances of elongated uvula exist, however, without producing any of the symptoms narrated.

The disturbances occasioned by an elongated uvula, when not amenable to ordinary measures (astringents), are best relieved by removal of the exuberant portion—an operation readily performed by seizing the tip of the organ with a pair of delicate forceps, drawing it forward into the mouth, and then dividing it above the forceps by the knife or a pair of curved or straight scissors. A pair of straight scissors, with a guard on one blade, to prevent the organ from slipping, insures a level excision. If carelessly performed, the stump will be longer on one side than another, and present forward instead of backward. A special

uvulatome, devised by Mr. Gemrig, of Philadelphia (Fig. 60), consists of a pair of scissors with crossing crescentic blades, to each of which a toothed branch is attached inferiorly to re-

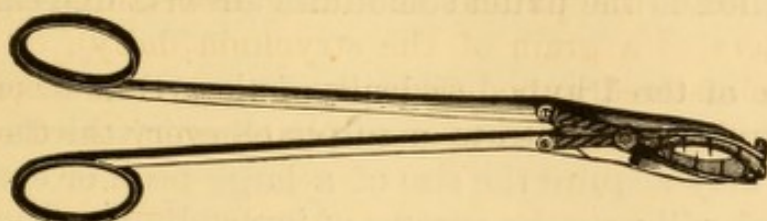


FIG. 60.—Gemrig's uvula scissors, the inferior surface presenting, to show the toothed forceps.

move the excised end of the uvula with the instrument. Elsberg's uvula sector (Fig. 61), similar in construction to Physick's amygdalatome, but with scissor-blades, and with a pair of for-




FIG. 61.—Elsberg's uvula-sector.

ceps attached below, to seize the uvula as it is divided, renders the operation very easy of performance.

The bleeding after excision of the uvula is usually insignificant, but occasionally it is quite profuse. Under these circumstances it may be controlled by compressing the stump between the blades of a pair of forceps, as in a case recorded by Lisfranc. The parts heal readily in a few days. Sometimes a membranous exudation appears on the divided surface; but this is rarely of any moment. Swallowing is sometimes difficult for a few days, and may necessitate the employment of liquid or semi-solid food. No after-treatment is required, as a rule; but it is as well to encourage the use of a mild gargle of borax, alum, or chlorate of potassium.

In some instances, where the uvula is very broad, a piece may be advantageously removed shaped like an inverted V, and the flaps brought together by silken or metallic suture.

Cases of elongated uvula which do not provoke any of the usual phenomena of titillation and cough, do not call for excision of the organ, unless it is evident that its elongation is a factor in keeping up a chronic sore throat.

Where the elongation is moderate and of recent date, retraction can sometimes be effected by repeated mechanical irritation, linear cauterization of its base with nitrate of silver, or

the use of an astringent lozenge or powder. A piece of catechu, frequently placed on the base of the tongue and allowed to dissolve there, will sometimes accomplish the purpose. Capsicum applied to the uvula sometimes answers extremely well.

Œdema of the Uvula.—Œdema of the uvula sometimes occurs during the progress of acute or chronic sore throat; and the organ may acquire the size of a large bean or even that of a plum, and will provoke spasms of impending asphyxia. The same condition may occur from the incautious use of caustics.

An accident of this kind occurred under my own hands some years ago. I had cauterized the soft palate of a syphilitic patient, in the morning, with a moderately strong solution of the acid nitrate of mercury. I was sent for in the night with the information that my patient was much worse, and apparently choking to death. On arriving at the bedside and looking into the mouth, the uvula was seen to be swollen by œdema to the size of the terminal phalanx of a man's thumb. Passing the tongue-depressor beneath it, it was raised up, and all suffocative symptoms vanished. By cutting off the end of the uvula with a pair of ordinary scissors, vent was given to the effused serum, and the danger of suffocation overcome.

The *treatment* of the œdematous uvula consists in giving vent to the fluid by incision, or excision of its end. Sometimes the œdema is accompanied by hemorrhage beneath the mucous tissue, under which circumstance the color of the swollen organ will be a blackish blue, instead of the whitish pink of ordinary œdema. Sometimes a constriction divides this portion from the upper part of the uvula. A puncture and the use of astringent washes will usually suffice for the treatment.

Morbid Growths of the Uvula.—Papillomas are the most frequent forms of morbid growth on the uvula. They occur in syphilis and in tuberculosis, and also independently of dyscrasia. They are usually sessile, sometimes pedunculated, rarely larger than the bulk of a pea. If of large size, they may give rise to unpleasant symptoms, like those occasioned by elongation of the uvula. If they give occasion to unpleasant symptoms, they may be snipped off with scissors, and the cut surface of the uvula be cauterized by the nitrate of silver.

Myxoma of the uvula is occasionally observed.

Carcinoma of the uvula occasionally occurs in connection with carcinoma of the soft palate.

Bifid Uvula.—A bifid uvula is occasionally met with as a congenital condition, and one limb may be much longer than the other. I have seen one nearly an inch long, which had never given rise to unpleasant symptoms, in a gentleman whose throat I had occasion to examine during an epidemic of diphtheria. Sometimes inflammation affecting the uvula will be confined to one-half of the organ, and thus give rise to the appearance of bifid uvula with one limb longer than the other.

Paralysis of the uvula occurs with paralysis of the palate, and independently. If unilateral, the uvula is drawn to the sound side; if bilateral, it is elongated, and does not retract on titillation. These conditions occur after acute, chronic, and specific sore throat.

Symptoms.—In bilateral paralysis there are tickling cough, hawking, and voluntary or involuntary deglutition.

Treatment.—Local use of the electric current, the source of electricity being unimportant. Excision of portion of the uvula.

Other neuroses are usually associated with the same affections in the palate.

CHAPTER VIII.

SPECIAL AFFECTIONS OF THE TONSILS.

Acute Inflammation of the Tonsils (amygdalitis, tonsillitis), is described in the articles on Sore Throat and Diphtheria.

CHRONIC INFLAMMATION OF THE TONSILS.

(Chronic Tonsillitis, Chronic Amygdalitis, Chronic Follicular Tonsillitis.)

Chronic inflammation of the tonsils is usually due to irritation of the mucous membrane of permanently enlarged or hypertrophied glands, itself often the result of frequent attacks of acute or subacute tonsillitis. It occurs chiefly in children, adolescents, and young adults. The causes are remotely constitutional weakness of some kind or diathesis, and proximately those of sore throat in general. There is usually also chronic follicular sore throat, and, not unfrequently, chronic coryza or nasal catarrh likewise. Sometimes there is chronic inflammation of the retro-nasal portion of the pharynx, with hypertrophy of the glandular tissue at its vault. Sometimes there is bronchitis. The inflammation is not always a constant phenomenon, but is liable to occur from slight causes. Attacks of acute catarrhal sore throat are apt to supervene, and as the tonsils are already enlarged, all the special symptoms of acute catarrhal tonsillitis are present in an aggravated form. There is hypersecretion from the inflamed tissues, sometimes accumulated in viscid, turbid masses adherent to the surface.

In some instances there is no hypertrophy of the glands, but a special vulnerability which renders them liable to acute, and, more frequently, subacute catarrhal inflammation, during which they become enlarged and project beyond the palatine folds.

In other cases there is a permanent catarrhal folliculitis, the lacunæ being prominent and often choked with caseous masses

of retained and desiccated secretions and epithelium which plug their orifices. The irritation from these masses, again, keeps up the inflammation. These products are sometimes discharged spontaneously, at intervals, in coughing and hawking, and can almost always be lifted out of their beds by a probe, bent wire, or something of that kind. When crushed they emit a very peculiar fetid odor, and when in place they are one of the causes of foul breath. This retained secretion often reaches the ducts of the follicular glands that empty into the lacunæ, and are beyond reach. Similar masses are often found in the enlarged supra-tonsillar glands, in the infra-tonsillar glands, and in the saccular glands in the base of the tongue. They accumulate also in the follicles of the palatine folds; below the tonsil, and running to the base of the tongue. Sometimes such accumulations are hidden behind the palatine folds which require to be pulled to one side to reveal them. The tonsils themselves are irregular in outline, and more or less intensely congested. They are often adherent to the palatoglossal fold, which sometimes is stretched out over them in a thin layer, which appears continuous with the external mucous membrane of the tonsil without any line of demarcation. Sometimes salivary concretions occupy the interior of the tonsil and keep up the chronic inflammation. Ulceration is not common in this affection except in syphilitic, scrofulous, or tuberculous subjects. It may cicatrize and recur again and again. It is chiefly met with in scrofulous individuals, but it occurs in other diatheses also. It rarely takes place unless there is some constitutional malady.

Symptoms.—The symptoms are more or less sore throat of moderate severity, dryness of throat from diminished secretion, very often cough, unpleasant odor of the breath, and more or less alteration in voice, due to mechanical change of the form of the resonant cavities of mouth, pharynx, and nose, produced by the tumefaction of the glands and mucous membrane, the deviation of the palate from its normal position, the enlargement of the glands at the top of the pharynx, and the occlusion of the nostrils by the thickened condition of its mucous membrane, the presence of polyps, and the accumulation of desiccated secretion. There is often more or less impairment of general health, with gastro-enteric catarrh, or slight chronic bronchitis, from deglutition of the morbid secre-

tions, and inspiration of the products of their decomposition respectively.

Diagnosis.—This is based on the appearances described and the symptoms enumerated.

Prognosis.—This is favorable provided the underlying cachexia is susceptible of modification, and that due care is exercised in avoiding all sources of exacerbation, and in maintaining a healthy condition of skin and digestive organs.

Treatment.—Attention to the diathesis is the first point of importance. Associated with this should be measures instituted for the removal of any local conditions which keep up the inflammation. This includes removal of nasal polypi, if they exist, and keeping the nasal passages cleansed of accumulated products. The caseous matters projecting from the lacunæ should be pried out by means of bent probes or other blunt instruments, so as to cleanse those passages and keep them patent. When this is impracticable, the offending part may be seized with a tenaculum, and a small wedge-shaped portion of the gland removed containing the diseased follicles. If they are hidden behind the anterior palatine fold, there is no objection to nicking this fold so as to get access to them. After the lacunæ are cleared out as well as may be, a bent platinum or aluminium wire, with a roughened or screw end, should be coated with molten nitrate of silver and passed into the recess so as to bring the caustic as much in contact with as great an extent of surface as possible. When the lacunæ are small, the caustic probe can be insinuated into them and carried as far as practicable without forcing it through the substance of the gland. Indeed, it is well at times to force it just a line or two, so as to get beyond the limit of the diseased process. This treatment is not to be applied to all the diseased lacunæ at once, as it would set up an acute inflammation; but two or three may be selected for the purpose and be treated in the manner indicated every three or four days, two or three new points being selected in addition, and others subsequently as some of those treated earlier are healed. When the palatine fold is adherent to the tonsil it is good practice to endeavor to release it by breaking up the adhesions with blunt probes and running the probe between tonsil and fold every day or two, to prevent readhesion. Release of the gland is sometimes promptly followed by good results. Irritation of the parts can

be soothed by means of some of the sedative or astringent sprays recommended in the treatment of sore throat; and something may be gained by using iodine in the same manner.

Should the treatment advised be inapplicable, fail after fair trial, or do positive harm, the only local resource is to get rid of a portion of the diseased structure by excising the gland. If the cut surface reveals the accumulation of secretion, it may be subjected to local treatment with better hopes of success. If the tonsils are not hypertrophied, and the treatment fails, advantage may be taken of a moderate increase of volume during an intercurrent attack of sore throat to remove a portion of them, which will be quite likely to include all the diseased follicles. Surgeons in possession of a galvano-cautery can use the small, pointed cautery instead of the caustic probe; and if this treatment fails, they can burn away by degrees the offending portion of the gland, and mould the remainder to the form of the normal organ. There are some Continental surgeons who resort to this means exclusively for all purposes of cauterization of mucous surfaces.

HYPERTROPHY OF THE TONSILS.

Hypertrophy of the tonsils usually occurs in children and young adults. It is usually a pure hypertrophy of all the constituent structures. In some instances the affection is apparently congenital; at least its existence has been noticed soon after birth. It is very rarely encountered for the first time in individuals more than thirty years of age. The subjects of hypertrophy are usually persons whose constitutions are imperfect from hereditary taint, or impaired from acute or severe disease followed by anæmia. Most cases occur in individuals of strumous diathesis, and often, but not always, in connection with other manifestations of scrofula. Some authors are of the opinion that hypertrophy of the tonsils has no connection with scrofula whatever.

As a usual thing, there is a history of successive attacks of sore throat, during which the tonsils have been swollen, each attack leaving them more and more enlarged; but sometimes there is no history of this kind, so that the affection appears to have been chronic from the start.

The enlargement may vary from a mere projection of the

glands beyond the folds of the palate, to an hypertrophy so great as to hide most of the pharynx, the tonsils being of the size of large walnuts, and touching each other anteriorly. In some instances they have been known to become adherent. Mere inspection does not always reveal the whole of the enlargement, and when the entire circumference cannot be seen, the finger should be employed in exploration, when the gland will often be found enlarged above and below, in the former instance sometimes pressing the pharyngo-palatine fold, or the palate itself, against the pharyngeal orifice of the Eustachian tube, and thus, perhaps, adding impairment of hearing to the usual symptoms of difficulty in deglutition, respiration, and articulation.

Inferiorly they may be so enlarged, in rare instances, as to press upon the larynx, and even prevent phonation.¹ I have known a tonsil to press the epiglottis down and to one side, preventing deglutition of solids, and giving rise at night to attacks of suffocation. This condition of epiglottis was seen laryngoscopically, and confirmed by palpation with the finger.

The enlarged tonsil is often adherent to the anterior palatine fold in a greater or less extent. Sometimes it is wholly detached from the tonsillar fossa, and hangs from its original bed by a mere shred of stretched tissue. The enlargement of the tonsil is less frequently hyperplasia of glandular structure than deposits of fibrinous material which have undergone organization, and thus augmented the size of the organ.

More or less engorgement of the cervical glands at the angle of the jaw accompanies aggravated cases of hypertrophied tonsils. In some instances the swelling thus produced is erroneously attributed to the enlarged tonsil itself.

Both glands are usually hypertrophied, but not always to an equal degree. Sometimes but one gland is affected, and cases of this kind are not infrequently connected with pneumonic phthisis, as pointed out by Dr. Green and others, the affection in the lung first showing itself on the same side as that on which the enlarged tonsil exists. Sometimes the enlarged gland is ulcerated, and an enlarged and ulcerated tonsil is frequently observed in cases of tuberculosis, and almost invariably on the same side as that in which disorganization is

¹ Dub. Jour. Med. Sci., April, 1878, p. 376.

greatest in the lung. These ulcerated tonsils sometimes give rise to hemorrhage.

Viscid inspissated mucus often adheres in shreds to the dilated lacunæ of the glands. The hypertrophied gland is often in a state of chronic inflammation, and this may be accompanied by chronic pharyngitis, coryza, and bronchitis. These phenomena subside usually after excision.

Symptoms.—The symptoms are those of chronic inflammation of the tonsils, added to the mechanical effects on voice, respiration, and deglutition. A moderate degree of hypertrophy produces no unpleasant symptoms, except during occasional attacks of sore throat, at which times the swollen glands impair deglutition, and sometimes interfere with respiration also.

Great hypertrophy will present an obstacle to free nasal respiration, and necessitate more or less coarse breathing through the mouth. Dryness of the throat, a peculiar clang in the voice, and snoring during sleep result from this more or less continuous disposition to keep the mouth open. It also gives occasion to a peculiar leaning of the head forward or to the side least affected, for both glands are usually involved, intuitively maintained to favor facility of respiration; and this, with the partly open mouth, and often swollen nose from the concomitant coryza, gives the patient, in marked cases, a peculiar silly aspect that is almost pathognomonic. In addition to this, prolonged interference with free respiration leads mechanically to characteristic deformity in the walls of the thorax, and consequent incomplete oxygenation of the blood, chronic emphysema, and eventual impairment of the general health.

Diagnosis.—Hypertrophy is recognized at a glance by inspecting the throat. The tonsil is seen to be enlarged, congested, and of a more or less irregularly globular configuration. The surface is smooth, if there is no intercurrent chronic catarrh, and the orifices of the crypts or lacunæ obliterated or plugged with products of retained epithelioma and secretion.

Treatment.—The treatment of hypertrophied tonsils is both constitutional and local. Constitutional treatment includes the use of nutritious diet with avoidance of certain kinds of food which are known to be deleterious and which vary in different individuals, careful attention to the functional integrity of the skin, bowels, and kidneys, and the administration

of cod-liver oil and vegetable and mineral tonics. Iron, indeed, is often prominently indicated. If the general health is good, remedies may be employed with a view to promote absorption, such being chloride of ammonium, chloride of calcium, sulphide of calcium, sulphate of potassium, iodide of potassium, and the like, in small and repeated doses to keep up continuous effect. They may be administered, when suitable, in combination with vegetable alterants, as *phytolacca*, *stillingia*, or *sarsaparilla*, which are all useful in chronic glandular enlargements.

Where the enlargement is of comparatively recent standing, the hypertrophy moderate, and the tumor of soft or elastic consistence, constitutional treatment will often eventuate in partial resorption, especially in young children. In addition to constitutional measures, local treatment can be employed, such as the use, two or three times a week, of solutions of nitrate of silver, sulphate of copper, chloride of iron, tincture of iodine, iodide of zinc, glycerole of tannin, recent ox-gall, and so on; the milder remedies being applied night and morning by the parent or nurse. The fused nitrate of silver carried into the lacunæ on an aluminium wire or platinum probe is often a valuable measure in many instances.

At the same time frequent compression of the gland between the fingers of each hand—one upon the tonsil, and the other outside of the throat—assists the process of absorption.

Where the tonsils are very much enlarged and very hard, local treatment will not often be of avail, and excision must be practised; or, rather, the removal of as much of each tumor as projects beyond the anterior palatine fold. When the organ is not very large, it may be resected by means of a guillotine instrument—the amygdalatome (tonsillotome)—the method in general use, though it possesses the disadvantage that the slicing cannot be performed exactly in the desired line, so that very often a misshapen stump remains. Excision is facilitated by pressing the tonsil inward with the finger applied externally just behind the angle of the lower jaw.

A much more satisfactory plan, in many instances, is to draw the enlarged gland out from its niche by means of a double vulsellum applied at its base, and then, as it is drawn obliquely into the cavity of the mouth, to saw it off with a large, sharp, probe-pointed bistoury, cutting from above down-

ward and from behind forward. If the blade should strike a calcareous concretion in the body of the tonsil, it should be carried to the outside of it.

There is little or no danger of wounding the normal internal carotid artery, as is often referred to in describing this operation, inasmuch as the tonsil is pulled away from the side of the throat, and a number of structures intervene between that vessel and the gland. It can only occur when an awkward attempt is made to excise the entire gland, a sacrifice which is hardly ever requisite. It is sometimes necessary to remove the whole tonsil, in cases where it hangs loosely in the throat by elongated attachments, and danger is then avoided by keeping the knife as close as may be to the diseased gland.

When the patient co-operates with the surgeon the excision is very readily accomplished, but when he struggles it is often rendered exceedingly embarrassing, from the difficulty of watching the course of the knife by the eye. Anæsthesia is therefore allowable in cases of nervous and excitable individuals; but only, I think, under protest. Chloroform may be used with children. As the operation is a quick one, nitrous oxide gas may be used. If the operation is done under anæsthesia, some safe method must be employed to keep the mouth open, and appliances be at hand (See Fig. 16, p. 29) to draw the tongue forward in case of impending suffocation from blood in the air-passages. The use of a mechanical contrivance to keep the mouth open facilitates the operation in some instances. A mouth-distender (Fig. 62) made for me in 1872, by Mr. Kolbé, on the principle of the thumb-screw in the Antiquarian Museum, Edinburgh, with an adjustable tongue-piece, which can be removed altogether when not required, is admirably adapted to maintain forcible distention of the mouth during various operations in the throat. It is retained in position, like Mussey's gag, by bent wires which pass behind the incisor teeth, but the separation

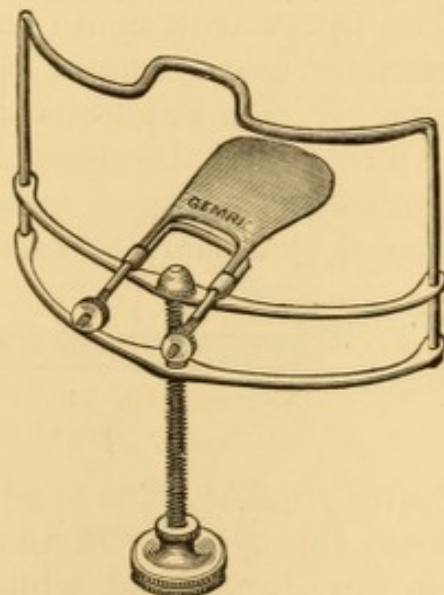


FIG. 62.—Mouth-distender, represented with the lower plate removed from the upper one by action of the screw, and in the position required during operation.

of the jaws is produced by the action of a screw attached to the movable lower plate in the middle line and below.

To avoid the difficulty encountered in excising an hypertrophied tonsil, especially in cases of children, a special tonsil guillotine or amygdalatome was invented by the late Dr. Physick,¹ of Philadelphia, consisting (Fig. 63) of a broad double

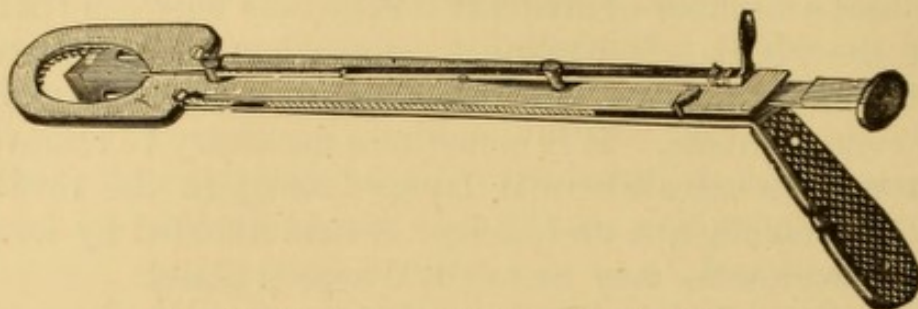


FIG. 63.—Physick's amygdalatome, or tonsil guillotine.

bevelled blade, which is pushed forward through a split ring in which the tonsil is first engaged; and it cuts from before backward, a method less likely to drag the tonsil from its bed than many of its modifications. It can be used with one hand. An excellent modification of the handle of this instrument has been devised by Dr. Morell Mackenzie, of London, which enables the operator to use the same hand with either tonsil. This instrument, in its various modifications, has had a more extended use, perhaps, than any other special instrument in surgery. Dr. Fahnestock's² amygdalatome (Fig. 64) consists of a circular knife concealed within a split ring. It is placed around the enlarged tonsil, which is then transfixed by being pierced by a sharp pointed prong which slides on the shank of




FIG. 64.—Fahnestock's amygdalatome.

the instrument. The handle attached to the blade is then drawn home through the canula supporting the ring, slicing off a portion of the gland, which comes away with the instrument. If not well made, or if allowed to become rusty, it will not cut smoothly, and the blade may break. It sometimes happens that the knife fails to cut through the gland, and the opera-

¹ Am. Jour. Med. Sci., Vol. I., p. 262.

² Ibid., 1832, p. 248.

tion has to be completed with scissors or bistoury. The same necessity may occur if the blade happens to encounter a concretion. The amygdalatome should be introduced flat, and the lower portion of the tonsil be engaged first; and it should be kept in a straight line during the incision. In this manner a sufficient amount of tonsil is removed, the palatine folds and tongue avoided, and the stump is more sightly.

A modification of Chassaignac's amygdalatome (Fig. 65), much used in Philadelphia, is provided with a mechanism by which the tonsil is lifted from its bed to the desired extent before the knife is drawn home; the entire operation being performed with one hand and in one movement, the fork having been set to the desired height beforehand. Chassaignac recommends attaching an instrument to each gland when both are to be removed, and then to practise the excisions simultaneously.¹

In my own practice, excision by the knife is preferred in operating on adults. It is only in children that I find it sometimes necessary to use the amygdalatome. The operation is facilitated, in certain cases, by first detaching the gland from the palatine folds to which it has contracted adhesions. These bands of tissue can sometimes be ruptured with the probe, or some other blunt instrument. This releases the gland so that it can be drawn out from between the palatine folds before excision. In cases of moderate enlargement with adhesions, the simple release of the gland, if properly maintained, will occasionally assist its reduction by other measures without resort to the knife.

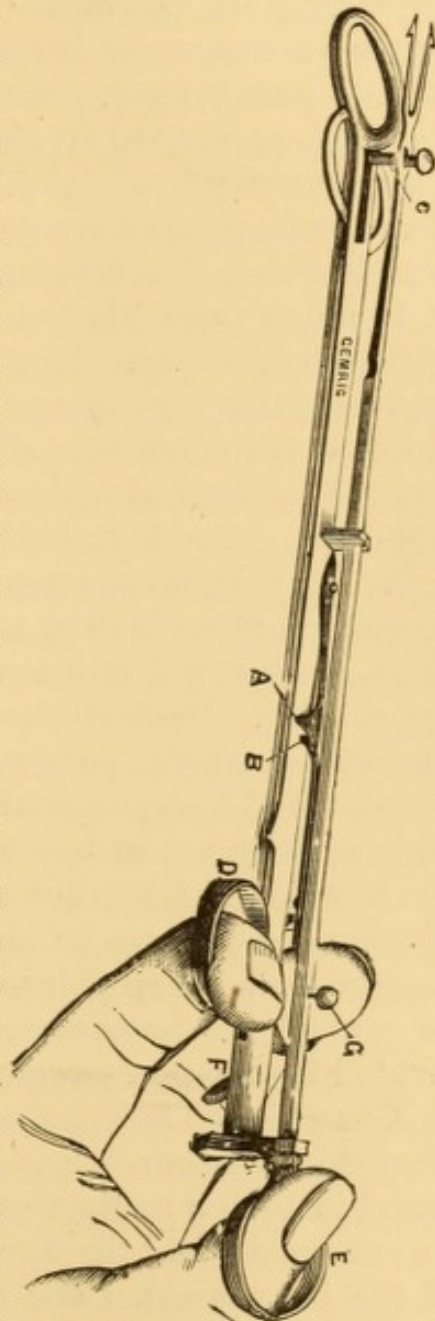


FIG. 65.—Charrière's amygdalatome.

¹ Leçons sur l'hypertrophie des Amygdales. Paris, 1854.

Although the tonsil is richly supplied with blood, and from several vessels of tolerable size, the hemorrhage following excision is usually inconsiderable, and soon ceases spontaneously, or upon the application of ice, or of a saline or acid solution. Sometimes the operation is comparatively bloodless. There are several records of more than a thousand operations at the hands of the same surgeon, without the occurrence of any serious hemorrhage. On the other hand, hemorrhage sometimes takes place to an alarming extent, and cases are on record where it has proved fatal, sometimes suddenly and inevitably. Many hemorrhages are due to injury to the palatine folds, the vessels being cut longitudinally and thus unable to retract. It is much more likely to occur with the amygdalatome than with the bistoury. Hemorrhage in young children is a very serious matter, on account of the difficulty of controlling the child so as to facilitate efforts for its arrest. In cases of anticipated hemorrhage (bleeders) it is well to administer ergot in full doses a few days before the operation.

When both tonsils require operation, it is best, if practicable, to operate upon both at one sitting. If the first one bleeds but little, the second one may be removed before the patient is aware of it. Hemorrhage may be controlled by the local contact of ice, tannin, or persulphate of iron, or by placing an absorbent wad upon each blade of a large pair of forceps, one of which, saturated with a hæmostatic, is applied as a tampon to the tonsil, and the other outside as a counter-support. If the bleeding is profuse or alarming, the carotid artery should be compressed. In some instances this artery has required ligature to control the hemorrhage. Secondary hemorrhage is to be treated by tampon or compression.

Chassaignac has proposed to remove the gland by means of the chain *écraseur*, but it has been found difficult to secure the gland in such a manner as to insure the division of sufficient of its substance, and the drawing of nothing else within the grasp of the instrument. The same objection is urged against Maisonneuve's *écraseur* of twisted wire. These *écraseurs* are therefore used only in cases of enormous hypertrophy. A device of Dr. S. W. Gross, of Philadelphia, modelled on Physick's amygdalatome, substituting a chain for the knife and tightening it by a double lever movement, has been satisfactorily employed by that surgeon.

The galvano-cautery may be employed for removing a slice of the gland by a single operation, the tumor being first encircled by a snare of platinum wire, which is gradually drawn as tightly as possible, as soon as the electric current is allowed to traverse it.

Attempts have been made, and with success, to destroy the exuberant portion of the tonsil by means of caustics. Nitrate of silver is inadequate and too slow in its action, though the fused salt well rubbed over the surface and inserted within the lacunæ so as to exert a caustic effect there, is sometimes successful. The two forms of pencils already recommended (Fig. 48, p. 96) are well adapted for these applications. The Vienna paste is very painful, and cannot be kept from cauterizing other tissues, except by means of some special contrivance. Dr. Morell Mackenzie, of London, has reported great success with the London paste, which is composed of equal parts of caustic soda and unslacked lime, a portion of which is moistened with water to the consistence of cream, at the time of use. The application may be made with an aluminium probe, a glass rod, or a bit of wood. I have sometimes found this method useful, but it requires a number of repetitions, as only a small slough is thrown off after each application. It is less painful than caustic potash, or the Vienna paste, and is not followed by as much inflammation; the latter, a matter of some importance, in view of the impossibility of protecting the uvula from the action of the caustic in the absence of a special appliance.

Prof. Donaldson, of Baltimore, has had a good deal of success by making small incisions into the tonsils, and then holding a crystal of chromic acid in the cut for some moments.

In a few instances of soft enlargements of moderate dimensions, where patients have refused to submit to operative procedure, I have reduced the size of the glands by electrolysis, employing a long platinum or gold needle, with an isolated handle, in connection with the negative pole of a battery of from ten to forty small cells, the positive pole being in connection with a sponge-electrode held externally over the region of the tonsil, or in some instances upon the surface of the gland in the mouth. A number of operations—ten to twenty—are necessary for the accomplishment of this purpose; and in

some instances, the results have not been worth the trouble of the performance.

Injections of carbolic acid and of ergotine ($\frac{1}{8}$ — $\frac{1}{2}$ gr. in a few minims of water) into the substance of the enlarged glands at intervals of a week or ten days, are said to be sometimes successful in producing absorption of the exuberant tissue.

ATROPHY OF THE TONSILS.

Atrophy of the tonsils sometimes occurs as a normal phenomenon in old age; and sometimes as a result of tonsillitis. It is seen in some cases of dry or atrophic pharyngitis, and in some cases of chronic follicular tonsillitis. In the latter disease, though the entire gland is atrophied, the lacunæ may be inflamed and present masses of dessicated mucus, as already described. In other cases the atrophy is merely apparent, there having been suppurative destruction of some of the follicles in previous inflammations, leaving a remnant or stump of tonsil.

Atrophy is usually regarded as an unimportant manifestation in itself, requiring no special attention.

MORBID GROWTHS OF THE TONSILS.

Various tumors occur in the tonsils. Their diagnosis requires care in discriminating them from mere hypertrophy, which in itself may be regarded as tumor.¹ Adenoma, lymphoma, papilloma, fibroma, lympho-sarcoma, sarcoma, and fibrous, epithelial, and medullary carcinoma, have all been described as being developed at times in the tonsil.

Lymphoma is generally regarded as clinically distinct from simple hypertrophy, though not considered histologically distinct by some pathologists. It has been reported present in general lymphadenia and leucocythemia, often as a consecutive manifestation after the neighboring glands have become enlarged. Adhesions take place to neighboring organs. Inflammation and ulceration may occur with perforation of the carotid in some instances. Suppuration of the gland rarely occurs. When necessary the gland is removed by vulsellum and bistoury.

¹ For a complete essay on the subject, consult Passaquay, *Tumeurs des amygdales*, Paris, 1873.

Fibromas may be developed from the peri-tonsillar connective tissue, and appear in the form of polyps. More frequently they grow in the connective tissue of the gland itself. They are removed by excision or constriction, or by ablation of the gland.

Lipoma.—Fatty disease, or enlargement of the tonsil, is rare.¹

Lympho-sarcoma may be regarded as a malignant form of lymphoma, growing rapidly. It is liable to implicate the palatine folds, palate, and posterior nares.

It cannot be distinguished at first from a benign growth.

Sarcoma is rare. A few cases have been described by Billroth, S. D. Gross, and others.

Treatment.—In suitable cases these tumors have been removed by incision through the anterior palatine fold to expose the mass and subject it to enucleation in the usual manner. Operative interference, however, is rarely resorted to, and to be effectual must be instituted early. Systemic medication, suitable to the general condition, is then the sole resource, with such additional measures as may be indicated by special symptoms. Arsenic is the remedy which appears most serviceable in retarding the growth of tumors. Large sarcomas have been removed by external incision by Langenbeck and Hueter, Langenbeck's patient having recovered.²

Cystomas occurring in the interior of the tonsils have usually been discovered during an operation for apparent hypertrophy; the contents of the sac being of course evacuated by the operation. In such cases an injection of iodine, or some analogous procedure, should be employed to excite adhesive inflammation of its walls. In other cases small cysts may occur on the exterior of the tonsils. They are readily removed by seizing them with a tenaculum and cutting out a wedge-shaped mass of the tonsil, including the cyst walls. A case of nervous aphonia in my practice was apparently excited by a small cyst of the tonsil, and was cured by removal of the cyst

¹ For example, see Atkinson, Edinb. Med. Jour., Aug., 1873.

² Poland: Brit. and For. Med.-Chir. Rev., Apl., 1872, p. 493.

in the manner indicated. These cysts have usually caseous contents.

A number of cases of hydatid cysts of the tonsils have been reported.

Carcinoma.—Cancer of the tonsil is rather rare. It occurs most frequently in male subjects, and after middle life. Of several cases seen by myself all were in the male subject. Medullary cancer is more frequent than epithelial and more rapid in its progress. The disease is sometimes primary, and confined to the tonsil for a considerable period, during which it is distinguishable from mere hypertrophy only by the age of the patient, its unilateral manifestation and the absence of previous history of tonsillitis. After a while there is infiltration of the surrounding tissues, and nodulated enlargement of the submaxillary and cervical lymphatic glands. Then, as the tumor enlarges, there will be earache, headache, severe pains in the throat and neck, from pressure on nerve tracts, sometimes extending along the shoulder and arm; dysphagia, indistinct articulation, emaciation, local softening, ulceration, and frequent and severe hemorrhage, the latter in itself sometimes fatal. The palatine folds, the palate, floor of the mouth, the root of the tongue and epiglottis, and the pharynx, often become implicated in varying extent. When the disease has progressed, and especially after the occurrence of ulceration and the development of fungous masses on the surface, there is little or no doubt as to the diagnosis.

Medullary carcinoma of the tonsil is often an extension of disease from the base of the tongue along the glosso-palatine fold, and may eventually involve the palate and the lymphatic glands in anatomical connection therewith. Occasionally it is secondary to carcinoma of the spleen and lymphatic glands. Epithelial carcinoma, when ulcerated, may be mistaken for syphilis.

The *prognosis* is always grave. Death may occur by asphyxia in medullary carcinoma. In the epithelial variety it is more frequently by asthenia. Sometimes it occurs by hemorrhages.

Treatment.—If the disease is confined to the tonsil, enucleation is allowable, but the whole organ must be removed. In favorable instances the operation has been performed through

the mouth. When no longer confined to the tonsil it is doubtful whether an operation be justifiable. Access to the diseased mass is sometimes made externally. To perform the operation properly, the carotid artery should first be encircled by a provisional ligature, and the pharynx be reached by the method suggested by Blandin, and executed successfully with a slight modification by Cheever, of Boston.¹ This consists in an incision passing from below the ear along the internal border of the sterno-mastoid muscle, and terminating at the level of the larynx, the cervical vessels and nerves being carefully drawn aside by an assistant, and the dissection continued until the tumor is exposed.

There is no special systemic treatment. Arsenic may be employed with slight hope of retarding the progress of the disease; and local measures, such as are discussed elsewhere, be employed to restrain hemorrhage and meet the various local indications as they are manifested.²

CALCULI.

Calculi may be formed in the crypts of the tonsils, usually in strumous subjects. They are irregular in form, and vary in size from the bulk of a small seed to that of a large bean or a small nut. They often excite cough and excessive secretion; and sometimes inflammation and abscess. When large, or when they excite inflammatory tumefaction of the gland, they may give rise to suffocative symptoms. In some instances they project beyond the surface of the organ, whence they can be removed by the forceps, aided, if need be, by one or two light strokes with the knife. Small concretions are occasionally ejected spontaneously in fits of coughing or vomiting; and some patients are subject to recurrences of this kind. These concretions are usually composed in great part of carbonate and phosphate of lime, and seem often to be the product of calcification of the caseous masses of epithelium, mucus, and salivary secretion so frequently met with in the lacunæ of the tonsils. Under these circumstances, when crushed, they emit the same offensive odor as the masses alluded to. Under

¹ Boston City Hosp. Rep., 1870; Am. Jour. Med. Sci., Apl., 1871, p. 515.

² For a more detailed account of the affection see Poland: On Cancer of the Tonsil Glands, Brit. and For. Med.-Chir. Rev., Apl., 1872, p. 477.

other circumstances they resemble the concretions sometimes expectorated from the lungs of tuberculous subjects, and have not the slightest offensive odor about them

FOREIGN BODIES.

Fish-bones, bits of toothpicks, bristles, pins, needles, and the like, occasionally get stuck or buried in the tonsils. They give rise to cough, pain, and sensations of local discomfort. They rarely interfere with deglutition. Their retention may excite inflammation and abscess. They may be readily removed by forceps. If deeply buried, an incision may be made over them, so as to render their extraction more easy.

CHAPTER IX.

SPECIAL AFFECTIONS OF THE PHARYNX.

Pharyngitis has been discussed in connection with sore throat. It rarely exists as an independent affection, without giving rise to the formation of an abscess.

ABSCESS OF THE PHARYNX.

(Pharyngeal abscess; Retro-pharyngeal abscess; Retro-œsophageal abscess.)

Catarrhal or traumatic inflammation of the mucous membrane of the wall of the pharynx occasionally gives rise to the formation of a pharyngeal abscess. Inflammation of the lymphatic glands behind the pharynx, or of the cervical vertebra, or of the intermediate connective tissue, is liable to give rise to the formation of retro-pharyngeal abscess.

Retro-pharyngeal abscess is very liable to terminate fatally within a comparatively short period, two or three days in some instances, if not recognized and properly treated; usually from pressure upon the orifice of the larynx, preventing respiration, but sometimes from starvation on account of inability to swallow,¹ or the impossibility of forcing food beyond the tumor. Death may likewise occur from œdema of the larynx.² These abscesses sometimes rupture spontaneously, but there is risk of death from mechanical asphyxia before the pus has had time to make its way through to the surface. Spontaneous discharge of the abscess may be followed by suffocation from the passage of pus into the air-passages; and a similar fatal accident occasionally attends surgical interference.

Retro-pharyngeal abscess may occur at all ages, but is most

¹ Carmichael, *Med.-Chir. Rev.*, 11, 1821, p. 518.

² For Example see Schmitz, *Jahrb. f. Kinderheilkunde*, 1873, VI., 3.

frequent in young children, often during the first few months or even weeks of life. It is not unknown in the new-born babe,¹ and is sometimes observed at a very advanced age. Male children suffer in greater proportion than females; but of the cases I have seen in the adult, the majority were in females.

The anatomical conformation of the pharynx—its lax attachment to the soft parts covering the bodies of the cervical vertebra, so necessary for its mobility in deglutition—is especially favorable for the formation of abscess. In case of suppurative inflammation of the retro-pharyngeal lymphatic glands, ample room is thus afforded for the accumulation of purulent matter, which usually forces the posterior wall of the pharynx forward over the larynx, though it may burrow in the opposite direction, and present externally in the parotid region. In some instances the fluids gravitate towards the posterior mediastinum, whence they are liable to surround the trachea, or perforate the œsophagus, trachea, or pleural sac. The abscess is usually to one side of the middle line, and discernible externally by tumefaction at the angle of the lower jaw; but in some instances it is central, or nearly so, and there is no external manifestation.

Retro-pharyngeal abscess may be idiopathic, deuteropathic, or traumatic.

The greatest predisposing cause of idiopathic retro-pharyngeal abscess in children is scrofulosis or quasi-syphilitic taint. In adults it is usually self-contracted syphilis, or a latent hereditary manifestation of it. The immediate exciting cause is usually accidental or unusual exposure to cold, or sudden change from extreme cold to undue warmth. The initial local lesion may be inflammation of the lymphatic glands behind the pharynx, or cervical spondylitis terminating in caries of the vertebra; the latter the more frequent in adults. According to Bókai,² all idiopathic retro-pharyngeal abscesses in children originate in retro-pharyngeal lymphadenitis. Sometimes, however, and especially in children, as far as I may judge from personal experience, they follow an insidious form of subacute inflammation, involving the connective tissue between pharynx and vertebræ. Furthermore, tubercle has been found in the

¹ Stromeyer, *Handbuch der Chirurgie*, Freiburg, 1865.

² Ueber retro-pharyngeal-abscesse bei Kindern. Leipzig, 1876, p. 5 (144 personal observations).

lungs, intestines, and cerebral membranes of children who have died of this disease.

Deuteropathic abscess sometimes follows erysipelas.¹ In children it sometimes follows the acute exanthemata, especially scarlatina. In some instances it follows external cervical lymphadenitis; in others, acute tonsillitis; in others, acute pharyngitis, without tonsillitis. Occasionally it seems to be a metastasis of erysipelas.² In one of my own cases, a male adult, there was, first, unaccountable malaise for three or four days; then, pharyngitis, with pharyngeal abscess so suffocating that the patient begged to have his trachea opened; the attack finally culminating in erysipelas of the nose and face, with ultimate recovery.

Traumatic abscess may follow direct wounds to the pharynx,³ usually produced by sharp foreign bodies, such as fragments of bone in swallowing,⁴ pins,⁵ and the like. In one of my own cases it was a fragment of stick with which the child was playing. Falls,⁶ likewise, have given rise to traumatic abscess. In another class of cases it is produced by stricture or stenosis of the œsophagus, from the mechanical irritation attending forced deglutition.

The greatest number of cases of retro-pharyngeal abscess occur in connection with caries of the cervical vertebræ, and often with coexisting symptoms of scrofulous degeneration or syphilitic contamination elsewhere. In some instances the caries of the vertebræ is preceded by inflammation of the pharynx.

¹ I have seen an instance in a lady past seventy years of age, in consultation with Dr. Beeken, of Philadelphia.

² For examples, see Priou, *Am. Jour. Med. Sci.*, Nov., 1830, p. 251; from *Revue Médicale*, April, 1830; Christopher Flemming, *Dub. Med. Jour.*, vol. xvii., 1840, p. 58; Froriep's *Not.* xiv., 1840, p. 157; Mondière, *Annales d'Obstetrique*, Dec., 1842. (?)

³ See case from blow of fencing-foil received through the nasal passage. Cooper, *Lectures on Surgery*, Philad., 1839, p. 68.

⁴ For eight examples, see Allin, *Retro-pharyngeal Abscess*, *N. Y. Jour. Med.*, Nov., 1851, p. 307 *et seq.* (58 cases). Two cases of fish-bone impacted in the vertebral column, and resulting in caries, followed by abscess; John Adams, *The Lancet*, June, 1847, p. 581.

⁵ Pollock, *Holmes' Surgery*, IV., p. 484. From wound of breastpin, Bókai, *Op. cit.*, p. 13.

⁶ For examples, see Smith (*Canada Med. Jour.*, Dec., 1869), *Am. Jour. Med. Sci.*, Oct., 1871; Sinkler, *Phil. Med. Times*, Apl. 3, 1875, p. 418.

Mr. H. A. Reeves reports¹ a case in which this process was in course of production at the time of death, the periosteum and common anterior ligament being gone in parts, and the bone exposed and eroded in patches—evidently the result of the pressure of the abscess, inasmuch as the bones were not carious and the joints were intact.

The articular surfaces of the vertebræ are liable to be the seat of the disease, and in this way dislocation of the vertebræ may occur, producing pressure upon the cord. Nearly all cases of abscess of the pharynx, in connection with caries of the vertebræ, prove fatal, even when the abscess has been properly treated, and the case has been judiciously managed afterwards. This is particularly the case when the abscess is at all large. Prof. Stromeyer² distinctly states that he has seen all of his cases die where caries of the vertebræ had given rise to a large retro-pharyngeal abscess. Cases are not wanting, however, in which a recovery has been effected, though in most instances attended with a permanent deformity from the altered position of the cervical portion of the spinal column.³ In Dr. Allin's table but three cases, including that of Dr. Flemming, with caries of the vertebræ, are recorded as having recovered, and in these the terms "probable" and "supposed" are prefixed, so that there is an uncertainty in this respect. Cases of recovery after exfoliation of fragments of the anterior surface of the vertebræ are not absolutely infrequent, however, at least in syphilitic subjects, in whom I have seen several examples of the kind.

Dr. Syme⁴ has narrated a case in an adult, in which a large portion of the second cervical vertebra exfoliated and was discharged into the pharynx, whence it was finally removed by the patient, who subsequently recovered.

A somewhat similar case has been recorded by Dr. Ogle.⁵

Guenther⁶ narrates one of Uhde's cases, in which the bodies of the third and fourth cervical vertebræ were removed, and the patient recovered; but, as this occurred in connection with syphilis in an individual forty years of age, it is probable that the usual course of acute abscess had been somewhat modified. In one apparently non-syphilitic case, exfoliation of a fragment of the second cervical vertebra was followed by cure in the person of a lady under my care in

¹ Brit. and For. Med.-Chir. Rev., Oct., 1873, p. 507.

² Op. cit.

³ Christopher Flemming, Dub. Quar. Jour. Med. Sci., Feb., 1850, p. 224.

⁴ Edinb. Med. and Surg. Jour., Apl., 1826, p. 311, illustrated.

⁵ Brit. Med. Jour., Jan. 20, 1872.

⁶ (Deutsche Klinik, 1856, p. 34), Lehre von den blutigen Operationen, V. p. 7.

Philadelphia. The abscess had been small and limited to the supra-palatine portion of the pharynx, a little to the right of the middle line.

These cases are all exceptional ; the result is usually different.

Symptoms.—The general symptoms suggestive of the abscess of the pharynx are : pain and soreness in the parts, referred to the palate when the abscess reaches high up, but often extending over the entire throat ; difficulty of swallowing, amounting in some instances to complete aphagia ; impeded respiration ; the dyspnœa often noisy, and so urgent as to compel maintenance of the semi-erect posture. The head is often bent backward, putting the neck on the stretch. The voice is sonorous, but produced with difficulty, and is muffled or nasal in tone. There is snoring in sleep. Cough is not frequent. External pressure and movement of the stiff neck will produce pain, or reveal tenderness. There is usually some distinct history of an attack of chilliness or shivering, denotive of the formation of pus. All the usual phenomena of obstructed respiration occur, and there are the ordinary symptoms of suppurative inflammation—acceleration of the pulse, heat of skin, and actual increase of temperature. Associated with these symptoms, there are in many cases external manifestations of tumefaction about the throat, sometimes at one point, sometimes at two or three, increasing in volume as the disease progresses. The principal point of swelling is behind the external angle of the jaw, in the depression in front of the border of the sternocleido-mastoid muscle ; and upon this point Mondière lays great stress, having observed it in all his cases of chronic retro-pharyngeal abscess. In some instances the engorged submaxillary glands undergo suppuration, and then there will be fluctuation. Sometimes the purulent matter extends forward along the pharyngo-epiglottic fold into the lingual surface of the epiglottis, simulating cyst of that structure. Sometimes the larynx is pushed forward so as to be rendered unusually prominent. In cases in which the matter gravitates, the swelling will extend lower down, and in one fatal case has been described as simulating disease of the thyroid gland.¹

Sometimes the abscess is formed between the membranous wall of the pharynx and the sheaths of the muscles, in which

¹ J. Henry Clark, N. Y. Jour. Med., July, 1849, p. 34.

instances there will be but little interference with deglutition, and the cases may have time for full progression, so as to rupture spontaneously.

In occasional instances the abscess may exist so high up as not to interfere with respiration or deglutition. The position of the abscess, though often more or less central, is sometimes at one side, and the danger is modified in consequence.¹

Diagnosis.—In view of the direct responsibility of the medical attendant in reference to a fatal issue from this disease, it is incumbent on the practitioner to bear its likelihood in mind in all cases of disease of the throat impeding respiration or obstructing deglutition, in order that due ocular inspection and digital exploration of the parts should be instituted; simple measures which, as a rule, promptly determine the diagnosis. In some instances the patient cannot open the mouth sufficiently for proper inspection of the parts, in which cases dependance rests upon the touch alone. In most instances, however, the mouth can be opened far enough to permit a good view of the pharynx by depressing the tongue with a tongue-depressor, or with the finger, or some other suitable object. There is sometimes a good deal of trouble in forcing open the mouth of an obstinate or frightened child, but the forefinger can usually be insinuated behind the last tooth and be carried behind the tongue into the pharynx. Before the abscess is formed, the swollen lymphatics can be felt, in idiopathic cases, according to Bókai, as a firm tumor beneath the wall of the pharynx, and usually behind one or the other tonsil, often discernible, likewise, by palpation externally. An abscess in the pharynx, if within direct vision, is seen to project forward in some portion of its extent, forming a tumid swelling which encroaches on the free cavity. If high up, the soft palate lies upon it, but sometimes the entire abscess is infra-palatine. Occasionally it will be so much to one side as to be liable, in a careless examination, to be taken for an enlarged, inflamed, or misplaced tonsil. It may be out of the line of direct vision, and require the aid of laryngoscopy or rhinoscopy for its detection. There are usually additional

¹ Of Bókai's 143 non-traumatic cases of it in children, 63 were on the right side, 51 on the left, 27 were central, and 2 had not been recorded; and, of 43 cases of retro-pharyngeal lymphadenitis, 23 were on the right side, 13 on the left, 3 in the middle, and 4 were not recorded. Op. cit., p. 6.

evidences of inflammation of the mucous membrane of the pharynx and adjacent parts, over which congested blood-vessels are seen coursing, and on which, in some cases, spots of ecchymosis are irregularly distributed; but in a great many cases there is no evidence whatever of inflammation beyond that of the swelling itself.

Palpation with the finger reveals the fluctuating character of the swelling in the absence of discoloration, and even with discoloration for that matter, and stamps the diagnosis of abscess; for a similar appearance of the parts may exist in cases of tumor or glandular enlargement of the pharynx, and mere inspection, therefore, may be misleading.

A few remarks are appended in relation to the differential diagnosis. As the affection occurs most frequently in children, it is apt, from the similarity of some of the symptoms, to be confounded with croup and with laryngeal abscess. In the adult it may be mistaken for œdema of the larynx. A case has been mentioned in which this laryngeal œdema was the immediate cause of death; and this, too, in an infant.

The existence of an abscess of the pharynx may be suspected in a child when attacked by frequent suffocative paroxysms, similar in many respects to those encountered in croup, but not exhibiting the same distinctness of remission. Schmitz, who reports sixteen cases, with thirteen recoveries,¹ states that the respiratory phenomena resemble those produced by enlarged tonsils rather than those of croup; and my own experience coincides with this observation. Although the restlessness of the patient and the actual obstruction to respiration may even be greater than that witnessed in croup, the relief to respiration afforded by the sitting posture may be taken as an indication of the nature of the disease. The voice is not affected as it is sometimes in croup, there being no impediment to the free vibration of the vocal cords. Pressure upon the parts always produces pain, which is not the case in croup. If there be any external swelling in croup, it will be below the angle of the jaw; while it is farther forward in retro-pharyngeal abscess, and more deeply situated beneath the sternocleido-mastoid muscle.

¹ Loc. cit.

Œdema of the larynx is more sudden in its onset, and the obstruction to breathing occurs principally in inspiration, from the valve-like action of the fluctuating folds of œdematous tissue. The dyspnœa from abscess of the pharynx will sometimes be relieved by raising the epiglottis up with the finger; but in any form of œdema of the larynx, similar relief could rarely result from the same manœuvre.

Due digital exploration and ocular inspection, direct or in the laryngoscopic mirror, will set all doubts at rest.

Prognosis.—Retro-pharyngeal abscess from caries of the vertebræ is usually fatal. In retro-pharyngeal abscess from other causes, the prognosis is favorable if the disease is early recognized and properly treated. If undetected, and therefore not attended to, death from asphyxia will in all probability result before the abscess has matured sufficiently to rupture spontaneously. Many an instance is on record, even at comparatively recent dates, in which the disease was not recognized until an examination *post-mortem*; and others are recorded in which the existence of the disease was likewise unsuspected, and the patient's life saved only by the fortunate rupture of the abscess, explaining the nature of the difficulty.

Dr. Allen records in his tables a case which occurred in the New York Hospital, August, 1849, in which the patient was being treated for syphilitic ulceration of the throat, and the abscess was accidentally ruptured during the introduction of a probang, employed for the purpose of applying a solution of nitrate of silver to the parts, the true nature of the disease having been neither recognized nor suspected. This fortuitous accident probably saved the life of that patient.

Those cases due to the presence of a foreign body, it is perhaps impossible to cure immediately by removal of the offending substance, inasmuch as it must be completely hidden by the swelling. The abscess must be treated, therefore, in just the same manner as abscesses from other causes. Sometimes the foreign body remains imbedded in the soft parts covering the vertebræ to which it has penetrated. Sometimes it is loose in the fluids of the abscess. These points have been verified by *post-mortem* examinations. In some instances the foreign body has been discharged with the contents of the abscess. More frequently the foreign body, usually a piece of bone, passes onward into the stomach after having produced the

injury. In one of the cases collected by Dr. Allin¹ the bone passed through the alimentary tract and escaped per anum; though not extracted thence without a good deal of pain.

Retro-pharyngeal abscess, by extending behind the tonsil, may eventuate in death by hemorrhage, from perforation of the internal carotid artery.²

Retro-Œsophageal Abscess.—In one form of this disease the abscess forms behind both pharynx and œsophagus. Mondière³ reported eleven such instances in adults, and seven in children varying in age from a few weeks to four years. Most of these cases arose from caries of the vertebræ, but the cause of the affection was not always apparent. Three cases followed inflammation of the throat; one case appeared to have been a metastasis of erysipelas; two cases were of rheumatic origin; and one, in a case of stricture of the œsophagus, originated apparently from overstraining in attempts to swallow large morsels of food.

It has been mentioned that the contents of the pharyngeal abscess sometimes gravitates behind the œsophagus, but there are also cases in which the abscess commences in this region, forming a variety which has been named retro-œsophageal abscess. Like the ordinary form, this variety is also due principally to inflammation and caries of the vertebræ. Guenther describes, after Duparcque,⁴ a number of symptoms which serve to distinguish this variety, the principal of which are the following:

The swelling in the lateral region of the neck is lower down, occupies a position further forward, and especially upon the left side. The food, instead of remaining in the mouth, or being driven through the nostrils, is carried downwards, some of it being swallowed, but some of it passing into the larynx and producing severe paroxysms of cough. The walls of the entire larynx being pressed together, the voice is shrill, piping, and comparable to that of a duck:

¹ M. Filleau, quoted by Gibert: *London Lancet*, June, 1828, p. 393, from *Arch. gén. de méd.*, May, 1828.

² For example, see Hoelzle: *Schmidt's Jahrb.*, xcvi., p. 312; Leishman: *Glasgow Med. Journ.*, N. S., May, 1869, p. 405.

³ Guenther: *op. cit.*, p. 6.

⁴ Schmidt's *Jahrb.*, V. Supplement, p. 191.

The relief to respiration by the sitting posture is not as marked. Pressure upon the œsophagus produces more pain than pressure upon the larynx or the upper portion of the trachea. Pressure upon the larynx prevents respiration entirely, and produces paroxysms of asphyxia. The abscess is not felt through the mouth.

These cases terminate fatally. Sometimes they rupture into the œsophagus. Several cases are mentioned by Guenther, from the records of Duparcque, Noll, and Uhde.

Mackenzie relates a case¹ in which post-œsophageal abscess resulted in a secondary disease of the cricoid cartilage of the larynx.

Treatment.—The proper treatment for these abscesses consists in timely incision by the knife to give free egress to the pus. Perhaps the safest method is to place one forefinger upon the abscess, and then to pass a sharp bistoury protected to within half an inch of its point, and make a free opening longitudinally; the patient's head being bent forward at the moment of opening the abscess, so as to prevent its contents from passing into the larynx. Children require to be securely held in the arms, and to have the head steadied by an assistant.

Schmitz recommends simultaneous occlusion of the larynx, by depressing the epiglottis with the forefinger of the left hand while opening the abscess. Caution is necessary, as instances of fatal cases of suffocation from entrance of the discharged pus into the air-passages have been placed on record.²

Sometimes it may be better to make an oblique or transverse incision. Sir Astley Cooper, Priou, Flemming, and others, employed an ordinary trocar and canula, or one specially arranged. In one instance puncture with an exploring-needle answered the purpose. Dr. Allin objects to the use of the trocar, on account of the danger of piercing the vertebræ, thus exciting subsequent complication. When the abscess extends behind the tonsil, special care is requisite on account of the proximity of the carotid artery. An abscess of this kind has sometimes been opened by the finger-nail, and in some instances mere pressure with the finger³ has sufficed to rupture

¹ Trans. Path. So., London, 1870, p. 56.

² For example see Abelin; Nord. Med. Ark. III., 4, No. 24; Schmidt's Jahrb. Bd. 154.

³ Christopher Flemming: Dub. Quart. Jour. Med. Sci., Feb., 1850, p. 224. Froriep's Not. xiv., p. 153.

the walls of the abscess. The aspirator doubtless would offer an efficient and safe method of discharging the contents of the abscess. When the abscess presents externally it is sometimes opened from the outside. In some cases the abscess is prone to refill, and attention is requisite to press the walls of the abscess from below upwards from time to time, so as to facilitate the prompt discharge of its accumulating contents.

The contents of the abscess are usually discharged by the mouth, but not invariably so. Guenther¹ mentions a case of Petrunti, in which the pus descended along the lateral walls of the throat, pushing the larynx forward, and producing such difficulty in breathing that an external incision became necessary in order to save the life of the patient. In this case the pus was found between the pharynx and larynx.

In some instances there is such relaxation of the connective tissue between the parts involved in the disease, that, after evacuation of the abscess, pus accumulates behind the pharynx, below the line of the wound made by the incision. In these cases Guenther recommends slitting the sac longitudinally and injecting solutions of an irritating character.

In cases of retro-œsophageal abscess, the necessity for performing tracheotomy is sometimes imperative.

When retro-pharyngeal abscess has been the result of acute inflammation, the parts usually heal rapidly after discharge of their morbid contents, much in the manner of subsidence in abscess of the tonsil after incision. In some instances, however, a large ulcer will be left, and impede deglutition until granulation has been well established.

In some cases suppuration of the submaxillary gland takes place, producing auxiliary abscesses which require incision.

The after-treatment will vary of course with the peculiarities of the case itself, and the character of any existing constitutional dyscrasia; and is to be conducted on the general principles of therapeutics.

MORBID GROWTHS OF THE PHARYNX.

With the exception of two forms of morbid growth, retro-nasal adenoma at the vault of the pharynx, and fibrous polypoid tumors of the supra-palatine and retro-nasal portion of the

¹ Op. cit., p. 6.

pharynx, tumors of the pharynx are not of frequent occurrence. These two forms are of sufficient importance to be discussed under separate headings.

Of the remaining varieties, the majority are developed in the submucous connective tissue, but some take origin from the bones or periosteum, and others from the glands. Some of them are pedunculated, but most of them are sessile. These latter are so tightly compressed by the mucous membrane, that they are not very movable. They occur more frequently on the lateral walls than on the posterior wall, and when thus located, often involve the palatine folds. They may extend upwards to the region of the posterior nares and Eustachian tubes, or downwards to the root of the tongue, the epiglottis, or the walls of the larynx and œsophagus. When occupying the lateral wall of the pharynx they may be confounded with tumors of the tonsils.

The varieties of morbid growth which have been observed in the pharynx include papilloma, fibroma, fibro-sarcoma, sarcoma,¹ adenoma, lipoma,² enchondroma,³ osteoma,⁴ cystoma,⁵ and carcinoma.

Pharyngeal tumors, according to their nature, may take extensive attachments, and invade the adjacent cavities. Enchondroma have been known to penetrate into the cranium, the orbits, the antra, the nasal, zygomatic, and pterygo-maxillary fossæ. Sometimes they project down the sides of the pharynx, and getting between the wings of the thyroid cartilage, compress the larynx to such a degree as to obstruct respiration. The same thing is sometimes produced by pressing the epiglottis down upon the orifice of the larynx, or by insinuation of the growth beneath the epiglottis, blocking up the entrance into the air-passage. Pharyngeal tumors may be mistaken for enlarged tonsils or for abscess.

Taylor's case of lipoma was mistaken for abscess, and incised without benefit. The deceptive sense of fluctuation was attributed to the temperature of the body. There was great dyspnœa, which tracheotomy failed to relieve. A large lipo-

¹ For recent examples, see Chapman: *Am. Jour. Med. Sci.*, Oct., 1877, p. 433.

² For recent examples, see Taylor: *The Lancet*, Nov. 11, 1876, p. 685.

³ For recent examples, see St. George's Hospital Reports, London, Vol. ii., 1867.

⁴ *Ibid.*

⁵ For examples of dermoid cysts, see Hartley: *Med. Times and Gaz.*, 1863, i., p. 640. Goschler: *Allg. Wien Med.-Ztg.*, 1865, p. 344.

matous tumor was found behind the pharynx, springing from the connective tissue. It passed behind the gullet, and projected forward on each side of the larynx.

Aneurism of the internal carotid artery, pointing in the postero-lateral wall of the pharynx, has been recorded by Porter and Syme, and (as supposed) of the ascending pharyngeal branch of the external carotid by Barnes.¹ These might be mistaken for neoplasms.

Carcinoma of the pharynx occurs most frequently as epithelial, occasionally as medullary cancer. It is usually associated with carcinoma of the œsophagus, and often extends to adjacent parts—larynx, palate, and so on (see Carcinoma of the Œsophagus).

Symptoms.—The symptoms of pharyngeal tumor are impeded deglutition, articulation, and respiration, varying with the size of the neoplasm, its location, and mobility. In two cases in children in which the tumor arose from the cervical vertebræ, I noticed marked examples of that peculiar dyspnœa termed "cornage" by the French. There is a sense of obstruction in the parts, with more or less hypersecretion, salivation, and expectoration.

Diagnosis.—Pharyngeal tumors are not often recognized until they have attained considerable size, so as to interfere with deglutition and respiration if low down, and with distinct articulation if high up. Inspection of the parts, with the aid of palpation, usually suffices for their detection. Sometimes the laryngoscopic mirror is requisite to detect their extent and points of attachment. When low down at the œsophageal extremity of the pharynx, the cautious introduction of bougies may be necessary to determine the diagnosis.

Treatment.—The treatment of these tumors, when not malignant, consists in extirpation; and the operation may present but little difficulty, or be extremely embarrassing, in accordance with the situation of the tumor, the nature of its attachments, and its proximity to the carotid artery and its branches. Indeed, in extirpating tumors in this situation, it is found expedient to ligate the carotid artery as a preliminary measure;² for in some cases its ligation has become imperative

¹ The Lancet, Oct. 30, 1875, p. 623.

² Busch: Ueber retropharyngeale Geschwuelste, Charité Annalen, viii., 1, 1857, p. 89; viii., 2; 1858.

during the performance of the operation, or subsequent to it. In simple cases all that is necessary is to expose the growth freely by an incision through its mucous coverings, straight or crucial, as the case may demand, and to complete the extirpation by enucleation with the fingers, as far as may be, aided with the handle of the scalpel, or with some other blunt instrument. Where it has been required to cut through the soft palate, it is sometimes necessary to reunite the edges of this structure by suture. Pedunculated tumors may be twisted with the forceps, or be divided by wire or chain noose, or by galvano-cautery; the mucous membrane at the root of the pedicle being divided, in some instances, by an elliptic incision to give better access to the real point of attachment.

Most of the tumors operated on in this region have been fibroids. In some instances there have been recurrences of similar growths, necessitating further operation.

In a case of the latter kind, recorded by Wagner,¹ death occurred by suffocation during a second operation, performed five months after the first one. The cause of death, however, was found to have been due to pressure of the epiglottis upon the laryngeal orifice by a portion of the tumor which had been dragged out in the operation.

Malignant tumors are rarely interfered with, except when they are very large, and fill up the pharynx so as to prevent deglutition and interfere with respiration. Then portions are removed by forceps, snare, ecraseur, or galvano-cautery. The bleeding is often insignificant, sometimes it is excessive. When the tumor presses injuriously on the larynx or epiglottis, tracheotomy is necessary to ensure respiration.

In a case of round-celled sarcoma of the pharynx, with extensive attachments, which had been attending the surgical clinics at Jefferson Medical College for two years, and which I had frequent opportunity of examining, tracheotomy was eventually performed, and large masses removed from time to time for several months subsequently; and it is quite likely that the patient would not have survived as long had a radical operation been performed when he first presented himself.²

In cases attended by copious secretion and ulceration, there is sometimes danger of such accumulations into the larynx as

¹ Deutsche Klinik, 1861, p. 61.

² The case will be reported in detail by Dr. S. W. Gross.

to demand the constant maintenance of a semi-erect posture. Fatigue in these cases may be relieved or prevented by use of the suspension respiratory brace devised by Dr. French¹ for asthmatic subjects. Urgent dyspnœa threatening suffocation demands tracheotomy.

In some malignant cases the patients die from inanition, as a local cause of the position of the tumor, before there is any great systemic cachexia. When deglutition is impracticable, nourishment is to be given by stomach tube when possible, if not, by enema. The distressing symptoms are to be met as they arise, on general principles. There is reason for believing that malignant tumors are sometimes retarded in their growth by the internal administration of arsenic, which, in small doses (gr. $\frac{1}{20}$ arsenious acid, \mathfrak{m} iij. Fowler's solution), after meals, is usually included in the general tonic and corroborative course pursued in my own practice.

ADENOMA AT THE VAULT OF THE PHARYNX.

(Retro-nasal Adenoma; Hypertrophy of the Pharyngeal Tonsil; Glandular Hypertrophy at the Vault of the Pharynx; Adenoid Vegetations in the Naso-Pharyngeal Cavity.)

The glandular tissue at the vault of the pharynx is apt to undergo simple hyperplasia, which may take the form of pendent, elongated clusters.

The existence of follicular glands at the roof of the pharynx has long been known. The celebrated William Hunter made some admirable dissections exhibiting this structure both in the normal and in the pathological condition, several of which I have examined in the anatomical portion of the Hunterian Museum of Glasgow—beautiful preparations after the lapse of more than a hundred years. Prof. Green calls attention to it in his admirable monograph on follicular disease of the pharyngo-laryngeal membrane; and many other authors mention its existence as a mass of glandular tissue, simply described as a chain of glands extending across the pharynx from one Eustachian outlet to the other. The importance of this tissue, however, in a pathological point of view, had not been fully recognized before the rhinoscope became an instrument of diagnosis; a number of cases being recorded by Voltolini and others in which disease was unexpectedly discovered during rhinoscopic examination, either for affections of the naso-pharyngeal region, or for disease of the ear implicating the Eusta-

¹ Boston Med. and Surg. Jour., May 3, 1877.

chian tubes. Sometimes the morbid condition has been discovered while employing the rhinoscope to ascertain the position of the pharyngeal orifices of the Eustachian tubes, for the purpose of verifying or assisting the introduction of the Eustachian catheter.

A very good account by Prof. Ch. Robin will be found in the *Dictionnaire de Médecine* of Nysten, eleventh (1855) and subsequent editions, under the article *Pharynx*. The best description, however, is that of Prof. Luschka.¹

This tissue is very distinct in some subjects, less so in others, but it is constant. It usually presents in the form of irregular longitudinal prominences separated by shallower or deeper fissures (Fig. 66), and distinctly studded with minute whitish follicles, less in size than poppy-seeds. A number of round pores are likewise observed, the orifices of acinous glands, and in part also

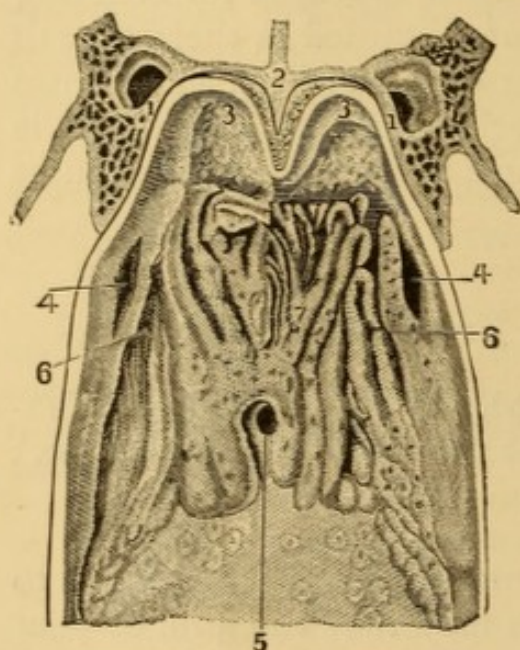


FIG. 66.—Adenoid tissue of vault of pharynx (Luschka). Posterior wall of the superior portion of the human pharynx, seen from before backward, upon a transversal section. Natural size, after Luschka.—1-1. Pterygoid process.—2. Section of the vomer.—3-3. Posterior portion of the vault of the nasal fossae.—4-4. Pharyngeal orifice of the Eustachian tube.—5. Orifice of the pharyngeal pouch (Bursa pharyngea).—6-6. Recessus pharyngens (fossa of Rosenmueller). 7. Median folds formed by the adenoid substance of the nasal portion of the pharynx.

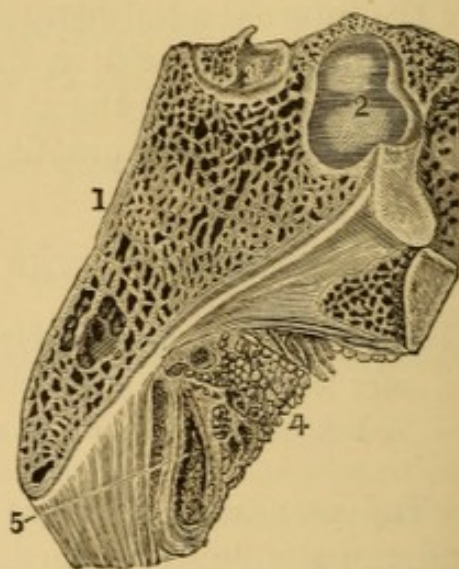


FIG. 67.—Pharyngeal bursa (Luschka). Antero-postero section of the vault of the pharynx. Natural size, after Luschka. 1. Section of the basilar process of the occipital bone. 2. Body of the sphenoid. 3. Pituitary gland. 4. Adenoid substance of the vault of the pharynx, behind which is seen, 5. The pharyngeal bursa.

N.B.—The line of reference from 5 is carried beyond the bursa in the cut.

depressed follicles. At the lower portion of the middle of the mass there is a large oblong pore the size of a large pin-head, well-defined superiorly, which is the orifice of a pouch-like appendix of the vault of the pharynx (bursa pharyngea) (Fig. 67), a foetal relic, confirmative, in Luschka's opinion, of an hypothesis of

¹ *Der Schlundkopf der Menschen*. 4to. Tübingen, 1868, p. 4 *et seq.*, Plates I.-XII.; *Das adenoide Gewebe der Pars nasalis des menschlichen Schlundkopfes*. *Arch. für mikroskopische Anatomie*, 1868, Vol. IV., Plate I. *Sur le tissu adénoïde de la partie nasale du pharynx de l'homme*: *Journal de l'Anat. et de la Physiol.*, 1869, No. 3, May and June, p. 225.

Rathke, that the glandular lobe of the pituitary body is especially produced through strangulation of the mucous membrane of the pharynx. According to Lacauchie, as confirmed by Koelliker and Luschka, the adenoid tissue at the vault of the pharynx is a conglobate glandular mass, having the same structure as the tonsils; and hence it has been termed the pharyngeal tonsil. It is soft and spongy, and so closely incorporated with the cartilaginous tissue uniting the pharynx to the base of the cranium that it is exceedingly difficult to separate them. The follicles are identical in structure with the solitary follicles of the intestine, and when in great numbers give a granular aspect to the vault of the pharynx.

This adenoid structure is important, as liable to inflammation and ulceration in chronic folliculous pharyngitis, to simple hypertrophy, and to transformation into certain varieties of naso-pharyngeal polyps. The tissue, as already intimated, is visible by pharyngeal rhinoscopy.

A case, which came under my observation while engaged in the preparation of the first edition of this volume, afforded me an admirable opportunity to inspect the external anatomy of this region at leisure in the living subject. A young girl, aged fifteen years, perfectly healthy in every other respect, was sent to me for the purpose of undergoing a periosteo-plastic operation for the closure of a large congenital cleft in the hard and soft palate. The cleft permitted a direct view of the vault of the pharynx and the adenoid or follicular tissue occupying this situation. A careful drawing was made by an artist, and kindly corrected for me afterward, with the subject before him, by Dr. Packard, of Philadelphia. The engraving (Fig. 68) gives a very accurate representation of the appearance of the parts under consideration. At the upper part of the cleft, the head of the patient being thrown well backward, the incomplete vomer is seen, and, at each side of it, the lower and middle turbinated bones. The broad bright spot indicates the angle formed between the upper part of the vomer and the roof of the pharynx, where we observe the structure in question. To either side, at the edges of the cleft, the trumpet-shaped extremity of the Eustachian tube is clearly seen, with its pharyngeal orifice. The anatomical relations of the healthy parts are perfect. Below the mass of glandular tissue is seen the outline of the upper constrictor muscle of the pharynx, the action of which in contraction was well demonstrated by titillating the parts with a probe during the examination. The wavy portion on the left side of the pharynx, seen less distinctly upon the right, is the lower portion of the salpingo-pharyngeus muscle, which, arising from the posterior and cartilaginous portion of the tube, descends to the sides of the pharynx. The action of all the pharyngeal and palatine muscles, including the posterior portion of the levator veli, the reflection of which forms the anterior and muscular portion of the Eustachian orifice, was also beautifully exhibited in this interesting case.

Another drawing (Fig. 69) exhibits the cheek of the patient pulled to one side, so as to permit a further view into the cavity of the pharynx on the opposite side, revealing the entire pharyngeal extremity of the Eustachian tube, and the whole of its orifice.

This case is the one operated upon by splitting the edges of the cleft instead of paring them, already referred to under the head of Cleft Palate (p. 213).

It will be seen in the drawings that the tissue in this instance is arranged symmetrically on either side, in the form of several elongated club-shaped

lobes on each side, with the bases upward and outward, and the narrower extensions running downward and inward toward each other; the clefts or lines of separation between these lobes being distinctly marked, and running together to form a median cleft of greater depth and width. The entire mass was of a brilliant red color, similar to that of vascular mucous membrane. The dividing spaces or clefts were occupied by a slightly opalescent fluid, secreted from the glands; and where the different streams joined in the central cleft, and ran down the posterior portion of the structure, the opalescence was marked and milky in

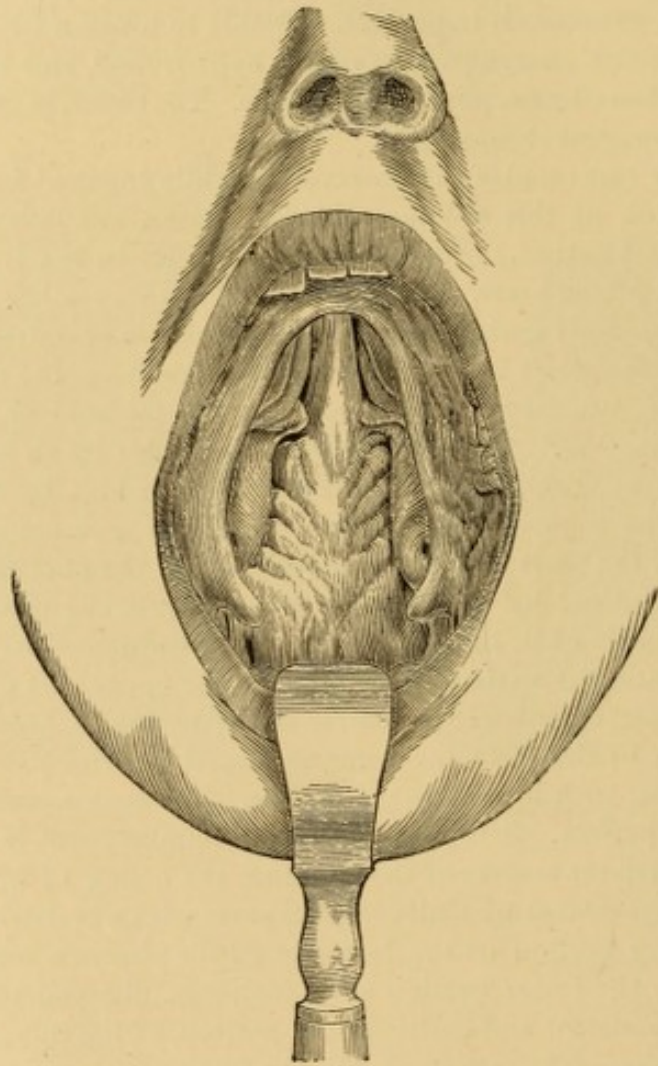


FIG. 68.—Glandular tissue at vault of pharynx, in a case of cleft palate. (From a drawing corrected by Dr. Packard.)

appearance. On removing this secretion with a sponge, the adjacent surfaces of the lobes were seen to have a slightly wrinkled aspect, as if minutely furrowed, and the bottoms of the clefts were of the same color as the lobes. The secretion reaccumulated under the eye with great rapidity. The appearance bears a striking resemblance to that described by Luschka from observations upon the dead subject; but there was no vestige to be seen, even with the aid of a magnifying lens, of any central depression or pit marking the orifice of the pharyngeal bursa. There is not the slightest doubt that this case afforded a marked exemplification, in situ, of this adenoid or glandular tissue of the nasal portion of the

pharynx; but evidently in a slight state of hypertrophy from the local irritation to which it has been subjected, during the whole life of the patient, on account of its exposed situation. Retrocession of this structure to its normal dimensions, after closure of the cleft in the palate, as had been to some extent anticipated, had not taken place some two years after the operation.

Although the presence of this structure,—this “pharyngeal tonsil,” as it has been not inaptly termed,—has been discerned frequently upon rhinoscopic examination of the healthy subject, it cannot by any means be distinguished in all

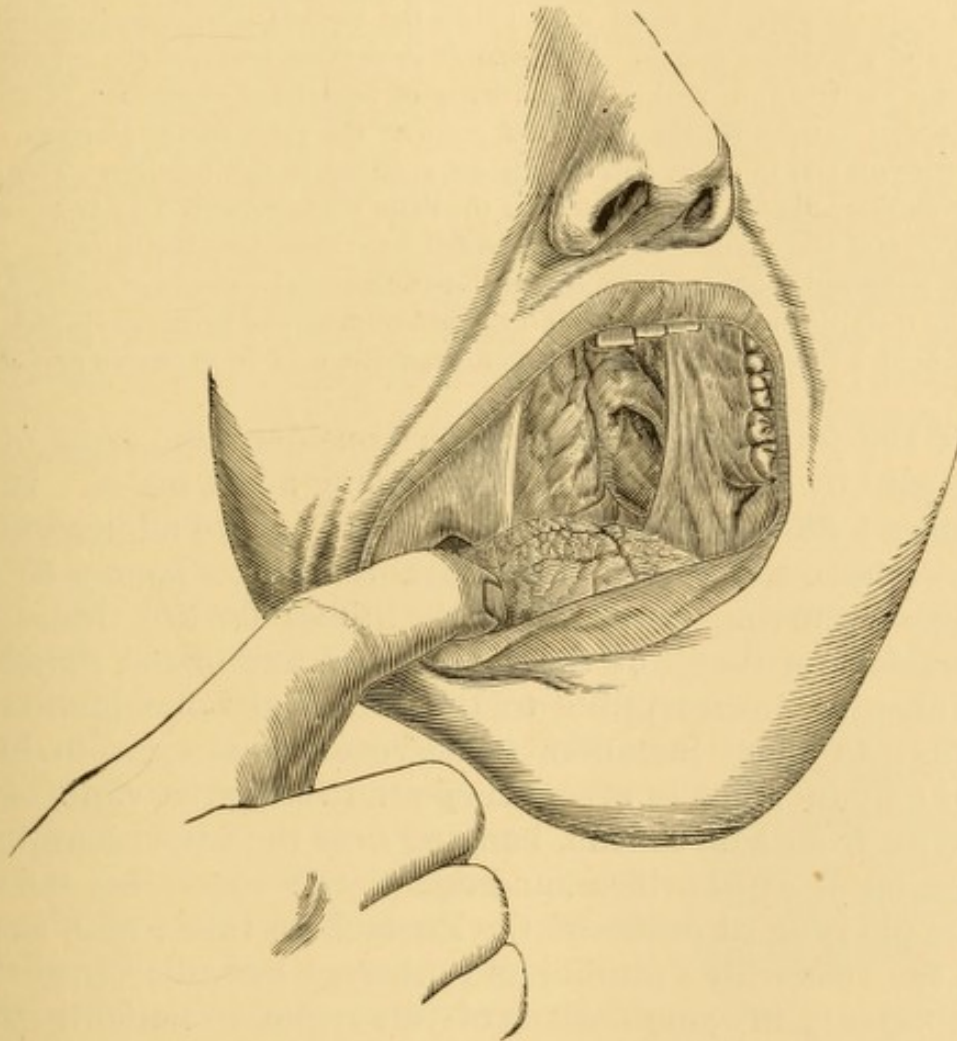


FIG. 69.—Pharyngeal extremity of left Eustachian tube, as visible in a case of cleft of hard and soft palate. (From a drawing corrected by Dr. Packard.)

cases; but experience teaches me that it can be frequently recognized, even though at first sight there may be only doubtful evidence of its presence. It is not always recognizable in cases of cleft palate. In a number of cases of this kind, in which I looked for it again and again by reflected light, I could not convince myself of any manifestation of its existence. I have frequently observed it, however, in the normal rhinoscopic image, with distinct recognition, in some instances, of the central depression of the pharyngeal bursa.

As a usual thing no distinct line of demarcation between the nasal portion of the pharynx and the vault of the pharynx can be recognized, the parts merging

into each other in a smooth uninterrupted surface; but in some instances a deep furrow is distinctly perceptible in this situation, at the junction of these two portions of the pharyngeal cavity. In one case of this kind under my treatment some years ago, this furrow was not only well-marked, but it was crossed on either side of the middle line, just above the roof of the nasal openings, by several delicate bands of tissue, similar in appearance to those bands so often observed crossing the fossa of Rosenmueller—a condition also existing in the same case. The patient had applied for relief from an annoyance of many years' duration, the principal symptom of which was a constant dropping of mucus from the posterior nasal region into the throat; sometimes entering the larynx and provoking cough. Rhinoscopic inspection revealed the condition of parts just described, as well as the existence of fimbriated elongation of some of the follicles composing the glandular mass at the vault of the pharynx. The parts were normal in color, and the disease confined to this locality. The secretion from these glands accumulated on the little bridges formed by the bands of adhesion, and when collected into drops fell from them into the throat.

The treatment consisted in rupturing these adhesions by means of a blunt, catheter-like metallic probe passed behind the palate, followed by the projection upon the parts of a tolerably strong solution of carbolic acid in glycerine and water.

Of the form of affection under consideration, most of the cases seen by myself have been in young adult males. In one instance I have had occasion to operate on two adolescent sisters. I have never seen it in advanced life. It may be that changes occurring towards middle life render this tissue, like the analagous tissue of the tonsils and agminated glands of the intestine, insusceptible to the catarrhal inflammations of youth. In some instances these vegetations exist in but a slight amount; but in others they stud the entire vault of the pharynx from side to side, hanging over the upper margins of the posterior nasal orifices, and completely concealing the view of the pharyngeal orifice of the Eustachian tube; and, as has been the case with Voltolini and others, I have discerned them unexpectedly in examinations of this region in patients suffering from chronic catarrh of the middle ear. They are said to be so numerous in some instances as to fill up the entire upper cavity of the pharynx, and to give to the finger, when passed behind the velum, the sensation of bunches of earth-worms. I have never met with them in anything like this profusion, though I have seen a few cases in which they extended along the posterior wall of the pharynx, so that they could be distinctly seen on pulling the soft palate forward, and in one or two cases they have been evident without disturbing the velum.

Dr. William Meyer, of Copenhagen, has described this affection in an elaborate article, entitled "Adenoid Vegetations in the Naso-pharyngeal Cavity;"¹ his attention having been first called to it as the cause of a peculiar defect in speech, to be mentioned subsequently as one of the symptoms of the affection. He states that he has met with 102 cases of the disease in his private practice within a period of eighteen months after his attention had been directed to the disease in his first case—a remarkable number, certainly; for before the perusal of his article I was inclined to the belief that the affection was an infrequent one, judging from my own experience, that of friends with whom I had conversed on the subject, and the small number of published cases on record. Dr. Meyer examined 2,000 children in the public schools for the poor in Copenhagen, and discovered twenty of them with the peculiar defect of enunciation which he calls "*dead*" *pronunciation*, in all of whom he met with the existence of these adenoid vegetations. Dr. Meyer states that he has met them almost completely filling up the naso-pharyngeal cavity behind the velum, and giving to his finger a sensation much like that of a bunch of earth-worms. In fact, he depends upon his finger as a means of diagnosis much more than he does upon rhinoscopy; for he states that they are sometimes so extensive as to preclude the use of the mirror, and that in some instances the velum is so thickened on its posterior surface that it encroaches too much upon the cavity to admit the mirror, even when the space itself is not so fully occupied by the vegetations.

These glandular enlargements sometimes exist as flattish cushions, similar to the prominences observed in some cases of follicular disease of the middle and lower portion of the pharynx. Sometimes they are cylindrical, and very often indeed fimbriated, hanging down like irregular tassellated fringes. (Fig. 70). Sometimes they are isolated, at others in close apposition. Their color is a deep red at the base, shading off to a lighter pink or to a yellowish cast at the apex; much like the color of the free surface of the tonsil. Their free surfaces are usually smooth, but sometimes exhibit a velvety appearance similar to that often seen in the follicular enlargements of chronic pharyngitis.

They are usually of soft consistence and bleed very freely on contact with the sponge, or even when struck with a stream of fluid projected upon them from the syringe. They usually occupy the vault of the pharynx, and the sides of the cavity,

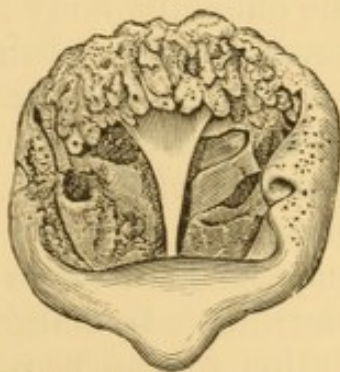


FIG. 70.—Rhinoscopic view of glandular vegetations at vault of pharynx.

¹ Hospitals Tidende, Nov. 4 and 11, 1868; extensively reviewed in Schmidt's Jahrb., 141, 1869, p. 325; communicated in English in Medico-Chirurgical Transactions, p. 191, London, 1870, illustrated.

overhanging the cartilaginous projection of the Eustachian tube, and the fossa of Rosenmueller. I have never seen them occupy the nasal septum, and Dr. Meyer states that he has never seen them there in his extensive experience; but he states that in some cases he has traced them down the posterior pillar of the palate to the level of the tonsil, and in a few instances on the upper surface of the soft palate, and he also mentions that he sometimes finds these growths hard as well as soft in texture. All those I have seen have been of soft consistence.

Symptoms.—The symptoms of the disease are similar in the main to those attending protracted coryza, or cold in the head, except that there is very little discharge of mucus from the nostrils; the mucus being expectorated through the mouth. There is more or less impediment to free nasal respiration, at times compelling the patient to keep the mouth opened slightly so as to facilitate breathing. Occasionally there will be impossibility of sleeping on one side or the other, from occlusion of one of the posterior nasal outlets, by the dropping or falling over it of these pendent vegetations. There is a sensation of fulness, or stuffiness, at the posterior nares, as from the presence of some foreign material, of which the patient endeavors to get rid by a peculiar stridulous nasal inspiration, intended to drive the offending body into the throat; this act being followed by hawking and spitting, to eject whatever may have been thus forced into the pharynx. The expectoration consists largely of clumps of mucus, more or less thickened, and sometimes streaked with blood. Sometimes there will be unmixed blood, inasmuch as these vegetations often bleed very readily and may be excited to hemorrhage by the mere movements of hawking. In marked cases there is a deficiency in the enunciation of the nasal sounds of speech, the tones of *m* and *n* sounding like those of *b* and *d*, and so on. If the disease has existed for some time, it may have produced some disfigurement in the external conformation of the nose, the upper portion of which will be compressed from side to side, and the lower portion flattened from before backward, so as to appear broader than it really is from the contrast to the upper portion. In other cases the alæ are much compressed. In some cases there is more or less impairment in hearing, from obstruction of the pharyngeal orifice of the Eustachian

tube, this deafness being sometimes associated with tinnitus aurium.

Diagnosis.—On inspecting the throat, there will usually be perceived more or less evidence of chronic follicular pharyngitis, the follicles being enlarged in elongated, puffy-looking masses; and, when the palate is elevated, thick clumps of a greenish-yellow mucus will often be seen slowly gliding down upon the posterior wall of the pharynx. Masses of this kind are often hawked into the mouth and expectorated. In some instances the palate is much thickened, especially on its posterior surface. The pharyngeal mirror will reveal the presence of the growths in the localities described, and the finger passed behind the palate will determine their consistence and mobility. When low down they can be seen on forced elevation of the palate.

Treatment.—The treatment of these vegetations consists in destroying them by cauterization, and in removing them by surgical operation. The cauterization may be performed with

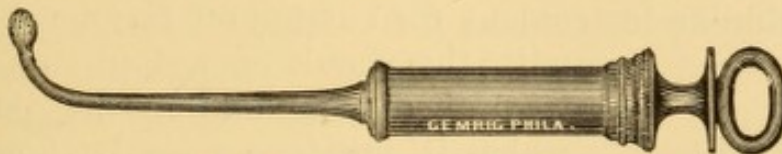

FIG. 71.—Naso-pharyngeal syringe.

the solid nitrate of silver conveyed to the parts, under guidance of rhinoscopy, by means of a curved metallic probe, which has been dipped into the melted caustic, or safely secure in a special caustic-holder. The galvano-cautery is also applicable for the purpose. Astringent powders may be propelled upon the parts in like manner, from a curved insufflator. Astringent solutions may be injected upon the parts by the naso-pharyngeal syringe (Fig. 71). I have employed, in this way, tannin, carbolic acid, sulphate of zinc and of copper, calomel, and weak solutions of nitrate of silver. Strong solutions of nitrate of silver are not always well borne by any means, and often produce an intense amount of suffering, which sometimes continues in the form of an excruciating headache for a day and more. Sneezing is very often provoked by these applications, and sometimes continues for many minutes. It is well to test the sensibilities of the parts at first with weak applications, resorting to stronger ones as tolerance is established.

Where the vegetations are large, and the parts can be educated to quietude under manipulation, these growths can sometimes be seized with properly curved forceps and be torn off or crushed off, as the case may be. Under these circumstances

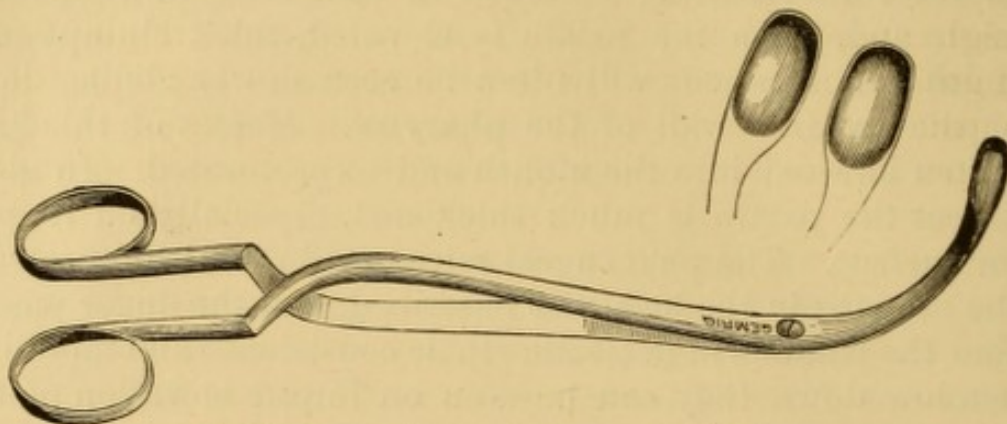


FIG. 72.—Author's (retro-nasal) pharyngeal cutting forceps.

there is usually more or less hemorrhage, but I have never seen it so extensive as to excite alarm or uneasiness. I have long used a gouge-cutting forceps (Fig. 72), modelled on Mackenzie's similar instrument for cutting off laryngeal growths,

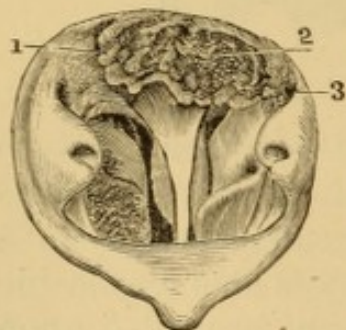


FIG. 73.—Rhinoscopic view of glandular hypertrophy at vault of pharynx. 1. Enlarged glandular mass. 2. Lobes studded with yellow spots, simulating concretions. 3. Fossa of Rosenmueller. This case shows also oedema of the membrane of the septum narium.

with the shank curved to suit the anatomical disposition of the parts over which it must be passed. Sometimes I have scraped these off with a blunt instrument resembling a vesical sound. After an operation of this kind I have usually projected powdered alum upon the parts, or syringed them with a weak solution of carbolic acid. A slight amount of hemorrhage may continue for some hours, tinging the mucus and saliva which is expectorated. A number of operations are generally necessary in order to rid the pharynx of these growths.

Fig. 73 represents a case in which the mass was torn off by short laryngeal forceps and then cauterized thoroughly with nitrate of silver, giving complete relief to an unpleasant so-called "nasal catarrh," which had existed for ten or twelve years.

When the vegetations have been long, I have been able to pass a wire loop over them, introduced through the nostril,

and then drawn the free ends through a Gooch's canula, and thus cut them through.

Dr. Meyer describes an instrument which he has devised for scraping off the larger vegetations. It consists of a little transverse oval ring, with one sharp edge, and attached to a straight stem. It is carried to the parts through the nostril and guided in its operation by the forefinger passed up behind the palate. The stem of the instrument is composed of soft steel, so that it can be bent to one side or the other, as may be desirable to facilitate manipulation. The hemorrhage in this operation is stated to be considerable, most of it flowing out of the nostrils. After the operation, the parts should be well washed with a rose syringe, or with the nasal douche; and they may then be cauterized, should this seem necessary.

There does not appear to be any disposition to repullulation of these vegetations after thorough evulsion or destruction.

NASO-PHARYNGEAL TUMORS.

Naso-pharyngeal Polyp.—This name is employed, in a general manner, to designate tumors of various characters which are developed in the superior or retro-nasal portion of the pharynx—that is, the portion above the usual level of the palate. In many instances these tumors have no more connection with the nasal organ or its accessories than if they occurred in the lower portion of the pharynx. Nor is every growth in this region, by any means, a polyp. The following varieties of morbid growth have been observed in this region: adenoma, fibroma, sarcoma, enchondroma, osteoma, carcinoma.

The naso-pharyngeal polyp proper is most frequently fibrous. Sometimes it is glandulous, apparently originating in an obstructed follicle, which has become gradually transformed into a sac containing the accumulated products of secretion, in a more or less altered state. The true fibrous polyp is usually firm in consistence, reddish or purplish in color, and arises from the base of the skull, generally to one side or the other—rarely, if ever, in the median line—a circumstance first brought to my attention by Prof. Harrison Allen, of Philadelphia. It has long been asserted by Nélaton¹ that fibrous naso-pharyn-

¹ Massé, Des polypes naso-pharyngiens, Paris, 1864, p. 13.

geal polyps never originate from the cervical vertebræ, as they were formerly supposed to do in many instances, but that their origin is always from the periosteum which covers the inferior surface of the basilar process of the occipital bone, and the body of the sphenoid bone. He states that, as the tumor develops, its prolongations may proceed along the vertebral column beneath the pharynx, but without adhering to the vertebræ. Sometimes the tumor produces erosion of the vertebræ, the existence of which is mistaken as a proof of implantation. Consecutive adhesions may take place, but they are to be differentiated from points of origin.

This form of tumor may also contract attachments with the cartilaginous portion of the Eustachian tube; or it may contract a partial adhesion to some portion of the posterior circumference of the nares, and thus literally constitute a real naso-pharyngeal polyp. The growth is usually slow in development, and manifests great tendency to extend prolongations into the sinuses of the nose and face, and the cavity of the mouth, thereby eventually producing a characteristic deformity of the countenance—"frog-face"—which augments with the increasing size and encroachment of the polyp.

As it enlarges into the free space of the pharynx, it pushes the palate forward, and can sometimes be seen extending below that structure.

These tumors occur at all ages, but are most frequent in adolescents and young adults, and chiefly in males. They are rare after middle life. They have been observed in the fœtus.

Symptoms.—The early development of these growths is not attended by prominent symptoms. As they enlarge in size, they produce augmenting or permanent obstruction to nasal respiration, anosmia, hypersecretion from nostrils or from pharynx, impaired articulation, deglutition, and respiration—as is common to obstructive disease in the retro-nasal portion of the pharynx; the severity of these manifestations varying chiefly with the size and locality of the growth, and to a certain extent with its clinical character.

Frequent epistaxis occurs in many instances, and in some cases is the earliest symptom to attract attention. It is sometimes sufficiently copious to render the patient comparatively exsanguine, and sometimes takes place in alarming quantity. Headache, vertigo, face-ache, deafness, and lachrymation occur

as the proliferations of the tumor gain deeper access to contiguous tissues.

Diagnosis.—Inspection of the pharynx, aided in some cases by rhinoscopic inspection, reveals the presence of the growth. Palpation with the finger and with probes, behind the palate and within the nasal passages, likewise detects the presence of the growth, and affords some idea of its bulk and attachments. These manipulations sometimes produce more or less hemorrhage.

Prognosis.—The prognosis is unfavorable. Spontaneous cure has sometimes occurred by sloughing. Evulsion is usually followed by recurrence. Medical treatment is practically hopeless. Death may take place by asthenia, asphyxia, or hemorrhage. Patients rarely live more than a few years with this disease.

Treatment.—Medical treatment is of no avail. The various symptoms require appropriate palliative measures. Frequent hemorrhages from the nostril require plugging of the nasal passages anteriorly, and for this purpose the patient should carry a supply of absorbent cotton, as the bleeding may occur at any inauspicious moment, on slight provocation, such as attempts to free the nose from secretions. Hemorrhage posteriorly cannot be so securely arrested, on account of the impracticability of manipulating the tampon. The systematic use of ergot (half a fluid drachm of the wine or its equivalent two or more times a day), or of turpentine, is advisable if hemorrhage is frequent. It sometimes becomes necessary to attempt extirpation of the morbid mass; but the removal of tumors from the retro-nasal portion of the pharynx is almost always embarrassing, chiefly on account of the inaccessibility of their points of attachment to operative procedure through the mouth and through the nasal passages, but also on account of the attendant hemorrhage and the difficulty in restraining it. It is good practice to accustom all the parts which will be subjected to manipulation to a preliminary contact with instruments and with the finger, so as to secure a better tolerance during the operation. The operation should always be as thorough as possible, inasmuch as subsequent operations for recurrence are rarely as satisfactory as the primary one.

Tumors favorably situated may be seized with strong, suitably curved forceps (Fig. 74) passed behind the palate, or through the nose, and forcibly torn or twisted from their

attachments. This operation is by no means safe, although often successful. Death has occurred from hemorrhage during such an operation, and from secondary hemorrhage afterward. Furthermore, as these tumors occasionally extend into the cranium, this rough procedure endangers cerebral hemorrhage and other unfortunate complications.¹

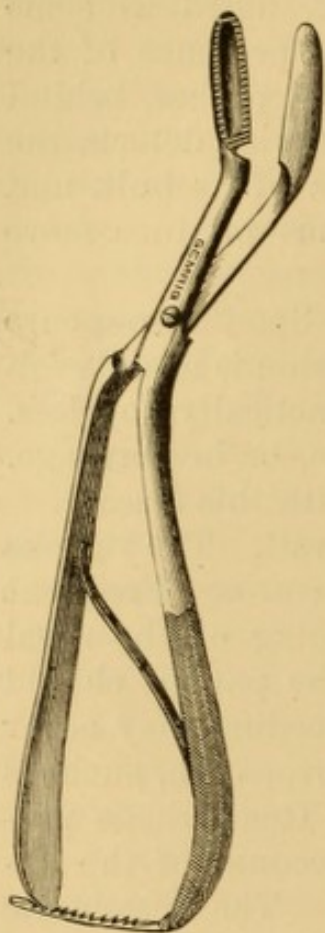


FIG. 74.—Author's pharyngeal forceps for seizing nasopharyngeal tumors.

The following report by Mr. Cooper Forster illustrates this observation: "The patient was nineteen years of age, and had a large growth filling up the left nostril, firm, fleshy, and fibrous, and covered with mucous membrane. The right nostril was not much interfered with; there was no swelling of the face or fulness of the palate, nor any projection in the throat. Chloroform was given, and a wire snare was put round the growth, which broke off, and caused it to bleed profusely. Mr. Forster then made another examination, and, having passed his finger up the nostril, found an enormous growth, which could not be circumscribed, but large portions of which he tore away with forceps. Four days after the operation the patient suddenly became unconscious. The right half of his face was numb, and, though he rallied, he was never able to speak except to say "too-too." The temperature rose to 102° F. He had three convulsive fits on the seventh day, and became totally unconscious, and died twelve

days after the operation. The post-mortem examination showed general arachnitis and sloughing of the brain about Broca's convolution. That portion of the growth which had not been removed occupied the left side of the external base of the skull, and filled the base between the greater and lesser wings of the sphenoid, the orbital plate of the frontal, and the cribriform plate of the ethmoid bone. It had extended from the nasal fossa, by way of the sphenoidal fissure, into the back of the orbit, but without damaging the optic nerve. The cribriform plate of the ethmoid was broken; and at the back part there was a small opening about a quarter of an inch in diameter, and a fracture extending forward from the opening. Microscopic examination showed the growth to consist of small fusiform cells and stellate connective tissue."

The cutting away of accessible portions by curved knives and scissors, used through mouth or nose, is still more apt to

¹ For examples see Forster: *Lancet*, May 20, 1871; *Medical Times and Gazette*, May 27, 1871; *The Medical Times*, August 15, 1871; Ratton: *The Lancet*, November 3, 1877, p. 649.

be attended by severe hemorrhage, primary or secondary, though not likely to injure the cerebral structures. The propriety of such partial operative procedure is questionable, as the chances for life are often much better if the tumor is not interfered with.

The passage of a ligature around the base of the tumor by means of a thread passed through the canule of Bellocq, or by some other method, and the subsequent excision of the growth, after securing the ligature, is attended with less risk; but even operations of this kind have been followed by death. Some ingenuity is required to complete this manœuvre.

Another operation, which has been extensively practised, consists in ligating the mass, so as to destroy its vitality, and tightening the ligature at intervals, so that the tumor shall slough off, which it will do in a period varying from four or five days to a fortnight or more. I have performed the operation readily in the following manner:

The tumor was pierced by a hempen ligature, and the ends of the thread tied and brought out of the mouth. A doubled iron wire was passed through the floor of the nasal passage, the loop drawn by the finger into the mouth, passed over the thread securing the tumor, and then guided by the finger behind the tumor, and pushed up as far as possible. The wire was drawn tight, and an assistant passed the two ends through a Gooch's canula, and, after the loop was pushed up to the base of the cranium where the polyp was attached, the wire was tightened and secured. The thread was fastened to the patient's ear. The wire was tightened each day, and on the fifth day cut through the growth, which was withdrawn by means of the thread passed through it in the first instance.

The stench which arises during mortification is sometimes unbearable to patient as well as to attendants. To prevent suffocation by the falling of the polyp upon the larynx, Graefe, in whose practice an accident of this kind occurred, has recommended the passage through the body of the growth of a thread which is secured outside of the mouth, and by means of which the extraction of the tumor is facilitated. But, even with this precaution, death by suffocation has occurred from impaction of the polyp in the pharynx, or upon the larynx, after it has become detached. The pain attending this operation is often intense, and causes swelling of the throat and of the face, in addition to which œdema of pharynx and larynx may ensue, necessitating tracheotomy. It is therefore highly important, in order that the patient may not be choked to death with it

in sleep, that a competent and well-instructed assistant should be constantly at the side of the patient, after an operation of this kind, until the mass has come away.

The polyp itself, too, sometimes increases in size, necessitating the use of incisions to give vent to some of its contents. It would appear good practice always to make incisions in the tumor after an operation of this kind, in order, in the first place, to reduce its size by loss of blood from its substance, and, in addition, to provide a vent in advance for the products of decomposition as they accumulate.

It is only in cases where there is more or less of a pedicle to the tumor that the operation of ligature is likely to be successful. In tumors with broad attachments, especially if there are prolongations into the adjoining cavities, operations of a much more serious nature are necessary for the complete removal of the growth.

In some instances the soft palate has to be divided in order to afford access to the growth. Sometimes the entire palate and uvula is slit, but, where possible, the palate alone is to be divided. By this means the tumor can be more readily seized with forceps and excised, and the hemorrhage better controlled. The usual plan has been, where the hemorrhage was excessive, to employ the hot iron. Circumstances determine the propriety of uniting the wound in the palate by suture at the time of operation, or deferring union to a subsequent period by the method of staphylorrhaphy, in order, as recommended by Nélaton, to be able to apply caustics to the stump, or parts from which the tumor has been removed. Union often takes place without suture or any other precaution to secure it.

In some instances the palate has been divided merely to afford the opportunity of ligating the polyp; in others in order to admit of its extraction by the forceps. These cases occurred chiefly in children, whose parts were too small to admit of the finger behind the palate without danger of suffocation.

Prof. Nélaton has not only divided the palate, but has dissected the mucous membrane off from the hard palate, and then cut a piece of it out in order to gain access to a tumor growing from the base of the skull, and to enable him to scrape away the periosteum from the base, and thus the better prevent a recurrence. In an operation of this kind it would

be well to remove the periosteum from the hard palate in connection with the mucous membrane, in the expectation, after reunion, of a reproduction of bone, the same as takes place after Langenbeck's operation of uranoplasty for cleft of the hard palate. The same surgeon has also removed the entire palate in cases where its structure was involved in that of the tumor.

A still more serious operation is sometimes requisite to accomplish the extirpation of these troublesome tumors. This consists in the partial or complete removal of the upper maxillary bone, as may be necessary on account of the size and situation of the growth. Access to the tumor is made from the exterior by the incisions usually practised by surgeons for partial or complete removal of the upper jaw, or for its resection in cases of growths involving the antrum. In some cases it is possible, as in a case operated upon by Larghi,¹ to reach the growth by means of an anterior opening through the superior maxillary bone, executed behind the everted upper lip.

The operation by removal of the upper maxillary bone has terminated fortunately in a number of instances; but it is often attended with a great deal of danger, not merely from the removal of the bone, itself a serious procedure, but because the nature of the growth necessitating an operation of this kind is apt to be one to present unfortunate complications.²

Prof. B. Langenbeck, of Berlin, has proposed and put into practice a method of reaching the growth, which consists in the resection of the nasal process of the upper maxillary bone and the nasal bone. This operation has been performed with more or less variation by other surgeons, and in suitable cases with successful results. It partakes of the objection to many other operations, that in too many instances it does not permit free access to the parts, so that the extirpation is sometimes incomplete.

In other instances the nose has been turned down, and the growth removed successfully by various appliances. This mode of access has been resorted to successfully in the United States.³

¹ *Gaz. Méd.*, Paris, 1867, p. 617.

² For example, *Gaz. hôp.*, Aug. 9, 1870, et seq.

³ Cabot: *Boston Med. and Surg. Jour.*, Feb. 9, 1871, p. 95.

Dr. Achille Bonnes¹ succeeded in the ablation of one of these polyps by means of a metallic nail attached to a thimble.

Dr. E. Cutter,² of Boston, has devised a very ingenious adaptation of the wire-loop to the mechanism of an *écraseur*, by which an instrument small enough for use through the nostrils, or behind the palate, can be readily employed in favorable cases; and with which he and others have operated successfully and satisfactorily.

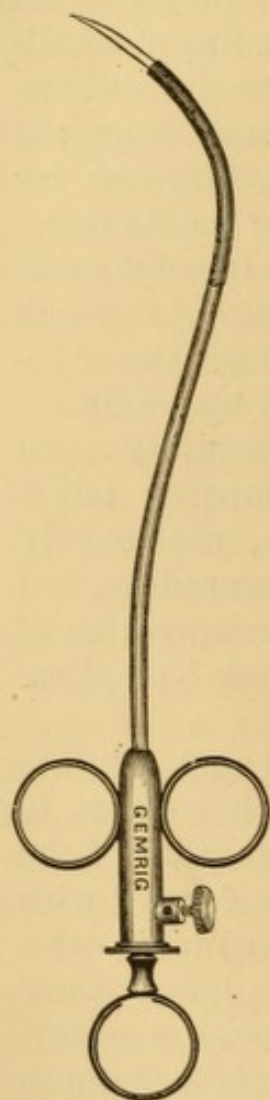


FIG. 75.—Author's nasopharyngeal electrolytic needle.

The galvano-cautery has been resorted to for the removal of these polyps; and it is preferable to the ligature or the knife, whether employed through the mouth or the nose, or after access to the parts has been obtained by means of some one or other of the surgical operations which have been mentioned. The cautery sears the vessels as it is slowly drawn through the structures, and thus greatly lessens the danger from hemorrhage. This method, first proposed and executed by Prof. Middeldorpf,³ has been employed with success by Nélaton,⁴ Dieffenbach, Voltolini, Semeleder, Neumann, von Bruns, Brenner, and others.

Electrolysis, too, has been sometimes successful in effecting riddance of these tumors, by disintegration and absorption. The non-penetrating portion of the needle should be protected by non-conducting material. It may be conveniently manipulated in a suitably curved canula (Fig. 75) properly isolated, and passed behind the palate in the usual manner, so as to avoid the necessity of dividing the velum, as has been practised in some instances. I have used a double hook constructed on the same plan to secure firm hold in a large polyp and afford two centres for exciting decomposition. I have no cures to report by this method of treatment, and my limited experience has not been satisfactory.

¹ Bull. gén. de thérap., Oct. 30, 1869, p. 364.

² Boston Med. and Surg. Jour., Nov. 24, 1870, p. 339, illustrated.

³ Galvanokaustie, Breslau, 1854, p. 148.

⁴ Legros and Onimus, translated by myself, Philada., 1870.

Prof. Nélaton has reported several cases treated by electrolysis.¹ One was cured, two were very nearly cured, one recurred, and in one case death ensued from typhoid fever during the diminution of the tumor. Fischer reports a case entirely cured within two months, after six applications of the electric current. Prof. von Brun² reports a case of success in a man, twenty-three years of age, with a large fibrous tumor of the pharynx, who had been operated upon by the constrictor of Maisonneuve three years previously, after splitting the soft palate. A recurrence had taken place, and the growth not only filled the entire pharynx, so that it projected into the mouth through the artificial cleft, reaching as far as the lower border of the palate, but sent a prolongation through the left nostril to its very external opening, and had pushed the left eyeball outward, downward, and forward to the distance of several lines. One needle from the battery was passed into the pharyngeal portion of the polyp, and another into the nasal portion. From May, 1869, until March, 1870, one hundred and thirty such applications were made, and the polyp had become so far destroyed and contracted that it could no longer be seen from the mouth or from the nose, though its remains could be felt by the finger from the mouth and from the nostril—in the latter instance only by burying the finger within the nostril to a depth of two inches. The improvement began with the institution of the electrolytic treatment.

Although the naso-pharyngeal polyp is such a serious affection that its removal may be accompanied by death, or be followed by a fatal result from hemorrhage, asphyxia, surgical fever, or pyæmia, it is well to remember that cases occasionally undergo spontaneous cures; sometimes by absorption, sometimes by necrosis and sloughing. It may, therefore, in cases where it is practicable, be a judicious endeavor to set up suppurative action in the tumor by irritant injections with tincture of iodine and the like; or to try to promote absorption by injections of ergotine and carbolic acid, as is done for similar purposes in fibrous and other morbid growths elsewhere.

Dr. Kömm³ narrates the case of a man twenty-eight years of age, who had suffered for a long time from a polyp which pressed the palate strongly forward into the mouth. It filled the entire posterior portion of the pharynx, and was so intimately connected with the surrounding tissues that ligation was not available. An attempt was made to excise it, but the patient would not suffer the completion of the operation. The patient was placed in a state of rest as to mind and body, ice was applied upon the head and around the throat, and nutrition maintained by enemata. The polyp underwent spontaneous absorption.

Occasionally, too, spontaneous sloughing of these tumors occurs. In a case

¹ Loc. cit.

² Die Galvano-Chirurgie, Tübingen, 1870, p. 85.

³ Schmidt's Jahrb. XXX. p. 61.

under the care of Mr. H. C. Johnson,¹ recurrence took place after the original tumor had been extracted by curved forceps passed around the palate. While the propriety of dividing the palate, so as to gain access to the base of the growth, was under discussion, rapid sloughing took place spontaneously, and removed every trace of the tumor.

In a case under the care of Mr. Birkett,² the hemorrhage from the polyp was so great as to necessitate ligation of the common carotid artery. The whole tumor sloughed away through a sinus which formed in the cheek, and seven years afterward the patient was reported as perfectly well, with no evidence of the tumor, and with the sinus in the cheek healed.

I am strongly inclined to believe that extensive naso-pharyngeal tumors, the attachments and prolongations of which cannot accurately be determined, should not be attacked by any radical surgical procedure until it is impossible otherwise to avert impending death. Even if the mass should be got rid of without untoward accident, which is uncertain, the recurrent growth almost sure to follow will grow much faster than the original one did, because there will be more room for growth in the absence of normal structures, which required a certain amount of time to become absorbed by the progress of the original tumor; and after it has reached the size of the growth removed, the impulse continuing, it will soon acquire a bulk absolutely greater than that which the first tumor would have acquired in its slower enlargement by the same time if let alone. Several individuals with extensive naso-pharyngeal tumor, induced by me to postpone attempts at radical operation to the latest possible moment, are living longer than I have reason to believe they would have done, had attempts been made at extirpation.

Hygroma.—An occasional form of cystic tumor in the pharynx is due to the development of hygroma of a hyoid bursa. In a case examined laryngoscopically by Dr. Clinton Wagner, of New York,³ a large tumor was revealed at the base of the tongue, resting upon the superior and posterior surfaces of the hyoid bone, and extending from the lateral wall of the pharynx to beyond the middle line; pressing the epiglottis backward

¹ Brit. Med. Jour., Jan. 1858, p. 61; Guy's Hosp'l Rep., 1867, p. 157.

² Brit. Med. Jour., 1868, p. 119; Guy's Hosp'l Rep., 1867, p. 167.

³ A Case of Synovial Bursa of the Hyoid Bone, Columbus, 1877, reprinted from the Ohio Med. and Surg. Jour.

and to one side, pushing the left ventricular band beyond the middle line, and intercepting a view of the left vocal cord.

WOUNDS OF THE PHARYNX.

Incised, punctured, lacerated, and gunshot wounds of the pharynx, are sometimes encountered. They may be due to falls sustained while sharp or brittle bodies, such as tools, sticks, and pipe-stems, are in the mouth. They are sometimes made by incautious use of the probang, by the deglutition of sharp fragments of bone, or by the impaction of a foreign body.

External wounds may pass through the tissues of the neck and thus implicate the pharynx.¹

Wounds of the pharynx, communicating externally, sometimes occur in attempts at suicide. In these instances the wound in the throat is made above the hyoid bone or below it. In the former instance the root of the tongue is wounded; in the latter the epiglottis is often implicated, and it has sometimes even been pushed down into the larynx, or been drawn into it during treatment—in either case producing suffocation. It is therefore recommended to remove any fragment of the epiglottis that is already nearly divided. After hemorrhage has been arrested, the parts are to be brought together by suture, room being left for the discharge of sputa and the inflammatory products which will present at the wound. Swallowing being difficult or impracticable, nourishment is to be maintained by the use of the stomach tube, or by allowing liquid aliment to trickle down into the œsophagus, as it were. If this be impracticable, the nourishment should be administered by enema. Medicine may be administered hypodermically or by the rectum.

The pharynx is occasionally wounded during the performance of a surgical operation.

A singular surgical wound of the vault of the pharynx is recorded as having occurred under the following unusual circumstances. In a case of obstinate suborbital neuralgia, Prof. Linhart, of Wurzburg, after the failure of many efforts at relief, including section of the affected nerve, determined to cut off the inferior maxillary nerve behind the malar branch, as well as the posterior dental nerves, to prevent recurrence in those branches. In order to avoid the disfigure-

¹ For example see White : Brit. Med. Jour., July 29, 1876, p. 146.

ment left by the method of Dr. Carnochan, of New York, he made an incision which enabled him to raise the lower eyelid, and divide the tarso-orbital membrane in scraping the border of the orbit. The myrtiform pavilion of a cannulated sound was passed between the lower floor of the orbit and the globe of the eye, as far as the summit of the orbit. The eye being held up, the curved extremity of the galvano-caustic apparatus of Middeldorpf, used in the cauterization of strictures, was introduced to the most internal angle of the suborbital fissure, and applied firmly from before backward; the current was passed, and the point occupied by the cautery was instantaneously destroyed, when the instrument penetrated from before backward without any resistance. On sounding the wound it was found it had penetrated to the bones at the base of the skull. The current was again passed, and the beak of the instrument was turned inward and glided along the base of the skull. The cautery penetrated to the cephalic portion of the pharynx, immediately behind the posterior orifice of the nasal fossa, and after the operation air issued by the orbit when the patient used the handkerchief and when he coughed. The operation was tedious and bloody, but successful.¹

Wounds of the pharynx may implicate the large cervical vessels, and thus prove immediately fatal. Mr. Marrant Baker² has recorded a case of fatal wound of the ascending pharyngeal artery by a tobacco-pipe. The foreign body producing the wound may break off in the parts, and, remaining for some time, set up ulcerative inflammatory action, which may prove fatal afterward from perforation of the vessels.³

Occasionally wounds of the pharynx give rise to abscess beneath the mucous membrane. Prompt evacuation of the contents of the abscess is called for. A case of this kind, under my own care, was produced by a stick of wood in the mouth, the patient falling prone and striking upon the stick. It is quite likely that a splinter was broken off in the pharynx, but as the stick had not been preserved, this point could not be determined.

A wound of the pharynx sometimes gives rise to emphysema in swallowing. The emphysema may extend externally and reach from the face to the chest. Though usually of slight moment, it may eventuate fatally.⁴

¹ Vierteljahrschrift für die praktische Heilkunde, t. 11, 1860. Arch. gén. de méd., Nov., 1860.

² St. Bartholomew's Hosp. Rep., 1876.

³ For example see Fingerhuth: Preussische Med. Ztg., 1864, p. 183; Archiv, 8, p. 477.

⁴ Med. Press and Circular, Oct. 18, 1876; Phil. Med. Times, Dec. 23, 1876, p. 143.

A specimen from a case of the kind in my own practice, in which emphysema, with diffuse purulent inflammation of the connective tissue, was produced in swallowing shortly after the passage of an elastic bougie which the patient was in the habit of insinuating through a stricture of the œsophagus before meals, is preserved in the Museum of the College of Physicians of Philadelphia. The bougie had passed into a small ulcerated diverticulum of the pharynx, and penetrated the mediastinum.

Treatment.—Accidental wounds of the pharynx present some difficulty in their management, on account of the embarrassment experienced in supplying nourishment. In cases of this kind, food and medicine should be administered by the rectum as far as possible, on account of the danger of the passage of food, when swallowed, into the areolar tissue of the neck. In most cases, however, the patient will manifest but little desire to swallow, on account of the pain attending the act of deglutition. In suitable cases of extensive injury, the edges of the wound are to be carefully approximated and secured by interrupted suture, the external wound being enlarged for the purpose of better access to the parts when requisite. I have never seen the operation performed. Prof. Gross recommends that the suture of the pharyngeal wound itself be cut off close to the knot, so that the loops may fall into its cavity and thus descend into the stomach. After the wound is closed, the head is to be secured by bandages in such position that the chin shall rest upon the breast so as to keep the parts in apposition until union has taken place. The subsequent treatment is conducted on general principles, every possible effort being made to secure as much rest to the parts as practicable.

FOREIGN BODIES IN THE PHARYNX.

Foreign bodies in the pharynx may be articles swallowed in food, plates of false teeth, toys and the like introduced into the mouth by children and insane patients, tacks, pins, and the like, escaping from the lips and mouth, parasites ejected from the stomach or œsophagus, foreign bodies and parasites from the nose, portions of instruments broken off in surgical manipulations. When partially swallowed, these bodies lodge in the lower portion of the pharynx; but sometimes, in the paroxysm of spasm excited by their presence, they get forced

above the palate and become lodged in the supra-palatine portion of the pharynx. The symptoms are local pain, spasm, cough, dyspnœa, dysphagia, dysphonia, and asphyxia, according to the location, size, and character of the foreign body.

They may often be removed by the finger or probe. At other times straight or curved forceps are required, as the case may be. The finger is to be placed on the foreign body, and the forceps guided along it. If too large to be extracted in mass, flexible objects (metallic plates) may be first bent with strong forceps, and brittle ones be crushed if necessary. Small objects may be seized with forceps under guidance of laryngoscopy or rhinoscopy. In extreme cases the operation of pharyngotomy is required.

LUXATION OF THE HYOID BONE.

A luxation of the horn of the hyoid bone, due to violent distension of the middle constrictor muscles of the pharynx in the act of deglutition while attempting to swallow a large and imperfectly masticated bolus, has been described by Valsalva (*dysphagia Valsalviana*). In this case there was complete aphagia, the patient having been unable to swallow fluids or solids for three days, when Valsalva's assistance was solicited. Recognizing the anatomical nature of the luxation, he rectified it by digital manipulation, and the relief was immediate.

DEFORMITIES OF THE PHARYNX.

Deformities of the posterior wall of the pharynx, due to congenital defect or disease of the cervical vertebræ, or resulting from accident or disease in after-life, sometimes occasion symptoms of disease of the throat, such as obstruction, dyspnœa, and dysphagia, which can be relieved in some instances by affording mechanical support exteriorly to the defective parts.¹

FISTULE OF THE PHARYNX.

A fistule of the pharynx is sometimes a congenital defect, sometimes the result of abscess opening externally, some-

¹ For example see Heymann (Berlin. klin. Woch., Dec. 24, 1877): London Medical Record, Feb. 15, 1878, p. 66.

times the result of an external wound penetrating the pharynx. The opening is usually in front of the larynx, to one side of the middle line. The orifice of the fistule often exudes a few drops of pus. A delicate, flexible probe insinuated along the tract will often be found to enter the pharynx.

The cure of these fistules is sometimes very difficult. Cauterization with nitric acid, nitrate of silver, and the galvanic cautery are resorted to.

Dr. Ricardo Guijo has recorded¹ a case opening in front of the thyroid cartilage, cured by two applications of the actual cautery, in the following ingenious manner: a probe was passed along the track of the fistule into the pharynx, and a canula run in over it; the probe was withdrawn, and a close-fitting, red-hot copper wire was passed through the canula, and both were withdrawn together, thus cauterizing the parts without running the risk of forcing the red-hot wire into other tissues.

STENOSIS OF THE PHARYNX.

Stenosis of the pharynx sometimes occurs as a result of vicious cicatrization after abscess and ulceration of the pharynx, palate and tongue, as already described in the section on Sore Throat. The stenosis is sometimes so great that only very thin fluid nourishment can be taken. The symptoms are dysphagia, dyspnœa on exertion, and imperfect articulation. The disease is recognized on inspection. Treatment is usually unavailing. Operative procedures, whether with cutting instruments, wire loops or ecraseurs, or with the incandescent cautery, are rarely of more than very temporary service, recicatrization being almost unpreventable. The best chance for the patient is the institution of systematic dilatation with hollow rigid bougies inserted every few days, and retained for a few minutes at a time, the practice being kept up during life. In this manner the orifice may be prevented from undergoing further contraction, and may even be somewhat enlarged, when very minute, to his greater comfort in swallowing. I have seen two instances, one after syphilis, and one after so-called scrofulous sore throat, in which the orifice would not permit the passage of a laryngoscopic mirror half an inch in diameter.

¹ *La Andalusia médica*, Aug., 1877, p. 169; *Phila. Med. Times*, Dec. 22, 1877, p. 131; *London Medical Record*, March 15, 1878, p. 122.

PHARYNGOCELE.

A diverticulum or sac is sometimes formed in the lower portion of the pharynx, and still more rarely in the œsophagus (see *Œsophagocele*). It is occasionally congenital, but is more frequently the result of external injury sustained in swallowing foreign substances. Sometimes it is produced by the repeated catching of food in the excavation of an ulcer, the walls of which become eventually converted into a sac. In other cases it seems to become formed by the mere habitual retention of food, which gradually distends the tissues and forms the sac; these cases occurring principally in the persons of hysterical females.

The symptoms excited by pharyngocele are those of mechanical impediment to effectual deglutition, very often accompanied with regurgitation of food. When the sac is empty its existence can often be detected by cautious exploration with the sound; when filled with food it presents the gross appearances of a tumor in the neck, and can often be detected by palpation externally.

The thinness of the muscular walls of the pharynx in this situation is supposed to favor the formation of these sacs, by the protrusion of the mucous membrane.

The size of the tumor varies from a minute sac to the size of a man's fist.¹

Pharyngocele is rarely amenable to treatment. When high enough up to be reached, the treatment would be excision of the sac. It has been recommended to cauterize the interior of the sac, and to feed the patient by means of the stomach-tube, so as to avoid any retention of food during the treatment.

NEUROSES OF THE PHARYNX.

Anæsthesia sometimes attends paralysis of the pharynx. Sometimes it occurs independently. In the anæsthesia of paralysis, portions of food are liable to remain in the pharynx without the knowledge of the patient, and endanger suffocation by occlusion of the larynx.

The non-paralytic form is most frequent in women, and usually a manifestation of hysteria, though sometimes un-

For example see Kühne, in Albers: *Path. Anat.*, 1839, p. 272.

attended with any other evidence of that condition. The inability to feel the contact of a solid bolus with the pharynx leads the patient to dread swallowing anything but fluid and semi-fluid nourishment.

The treatment is similar to that for anæsthesia of the palate (p. 216).

Hyperæsthesia attends various acute and chronic forms of sore throat. Sometimes it is the only morbid manifestation. The contact of solid articles of food is so disagreeable in some instances that liquid nourishment alone is taken.

The treatment is similar to that for hyperæsthesia of the palate (p. 216). In marked cases, local applications are rarely practicable in any other form than that of sprays, on account of the insurmountable provocation to reflex muscular action.

Neuralgia is rare, and its causes obscure. General anti-neuralgic measures internally and sedative lozenges are indicated in the treatment.

Spasm is a more serious neurosis, sometimes necessitating the administration of nourishment by the bowel. The treatment is similar to that for spasm of the palate (p. 216) and spasm of the œsophagus (which see), according to its grade.

Paralysis of the Pharynx.—Paralysis of the pharyngeal muscles may be due to peripheral or central disease, or to section, compression, or other injury of nerve by tumor or foreign body. Peripheral paralysis results from various forms of sore throat, especially that of diphtheria and of syphilis. Sometimes it occurs during convalescence. Central paralysis may occur in various injuries and diseases of the brain, medulla oblongata, and root of the pneumogastric nerve. I have seen it follow from cerebro-spinal meningitis and from sun-stroke. The constrictor muscles may be affected individually or together, according as the paralysis is in the domain of the glosso-pharyngeal or spinal accessory divisions of the pneumogastric nerve. It may be associated with paralysis of the palate, tongue, epiglottis, larynx, and œsophagus—progressive general paralysis originating in the domain of the medulla oblongata. Sometimes it is associated with hemiplegia, when

it is usually unilateral. Sometimes it is irregularly bilateral—partial on one side, and complete on the other. I have seen it this way after cerebro-spinal meningitis. It may depend on muscular atrophy, or upon thickening or plastic infiltrations between the muscular fibres, and is partial or more or less pronounced according to the extent of morbid lesion in the muscle or in the connective tissue. Sometimes it is apparently idiopathic. It sometimes occurs in the course of acute febrile disease, frequently as one of the precursors of death. Liquids are sometimes swallowed with great difficulty, and the attempt at deglutition is accompanied by contortions of the head and neck to assist their passage. Not unfrequently the liquid passes into the air-passages. In chronic diseases, in which the brain and spinal cord become implicated, the power of swallowing is sometimes lost a long time before death, the approach of which may be retarded by the use of the stomach-tube for the injection of nutriment.

Symptoms.—These are more or less dysphagia and accumulation of saliva. If the epiglottis is paralyzed, the effort of swallowing will drive portions of the bolus into the larynx, and if the palate is paralyzed, into the nostrils—accidents indicated by the usual symptoms. In cases of complete paralysis the saliva will stream from the mouth.

Prognosis.—This is usually favorable, unless the paralysis is due to disease or injury beyond the reach of remedies.

Diagnosis.—The diagnosis will rest on the dysphagia and attendant symptoms. Impossibility of deglutition will distinguish it from paralysis of the œsophagus, in which the bolus can be forced into the œsophagus by the muscles of the tongue, palate, and pharynx, but is arrested after the act of swallowing. Titillation of the parts is not followed by visible contraction of the muscles, as in health. In central paralysis from disease there will be some contractile response to a slowly interrupted battery current of electricity, though there is none to the induced current.

Treatment.—The local employment of electricity, and the internal or hypodermic administration of a salt of strychnia or its equivalent, with the use of tonics and nourishing broths, appear to be the most appropriate treatment for cases of this nature. In applying electricity, that form of current should be used to which the muscles best respond. If there is no

response, the current of the battery is indicated at first. The negative electrode should be applied to the pharynx, and the positive externally. In faradization both electrodes may be placed upon the paralyzed muscles. By either method the interruptions should be slow. The application may be repeated at intervals of two or three days.

In cases of complete inability to swallow, a stomach-tube is to be passed a short distance into the œsophagus, for the introduction of nourishment. One of my patients made himself a tin cup with a long spout, which he passed into the œsophagus, and then poured the liquid food through it.

CHAPTER X.

SPECIAL AFFECTIONS OF THE ŒSOPHAGUS.

ŒSOPHAGITIS.

INFLAMMATION of the Œsophagus, acute or chronic, is of rare occurrence. It is more often traumatic than idiopathic.

Acute Œsophagitis is idiopathic, deuteropathic, or traumatic. It may be circumscribed or diffuse. It may be catarrhal, phlegmonous, ulcerous, diphtheritic, or pustular. Idiopathic catarrhal Œsophagitis may result from change of temperature, "catching cold," under which circumstances it may, like catarrhal sore throat, be a premonitory manifestation of acute or subacute rheumatism. It may result from the habitual use of very hot food, and, according to some authors, of very cold food likewise; or from swallowing irritating medicines or moderately caustic substances. Deuteropathic catarrhal Œsophagitis may be an extension of pharyngeal or gastric catarrh. It may occur in scarlet fever, measles, and typhoid fever. Deuteropathic membranous Œsophagitis occurs in some cases of diphtheria and in some cases of croupous pneumonia. It occasionally occurs, likewise, in scarlatina, small-pox, dysentery, cholera, tuberculosis, carcinoma, and pyæmia. Deuteropathic pustular Œsophagitis occurs in some cases of small-pox, and in systemic poisoning by preparations of antimony. Ulcerous Œsophagitis may follow any of the forms of acute Œsophagitis. Abscess may follow circumscribed or diffuse Œsophagitis. Traumatic Œsophagitis is occasioned by mechanical injury from the passage of a foreign body or a surgical instrument, or by the deglutition of hot and acrid substances.

Symptoms.—The symptoms of acute Œsophagitis are often obscure. Moderately severe inflammation is characterized only by a sense of constriction, slight dysphagia, dull pain beneath the sternum, discharge of mucus, and occasional vomiting of

accumulated mucus. Severe inflammation is indicated by acuter pain beneath a greater or less extent of the sternum, and between the shoulders to the left side. The seat of pain, however, is not positively indicative of the locality of the inflammation. The pain is increased during deglutition, especially of solids. In inflammation of the upper portion of the œsophagus, the pain is increased on pressure externally. If there is great swelling, the dysphagia is greater, or there may be actual aphagia, and attempts at deglutition are followed by spasm, regurgitation, and vomiting. The substances vomited may be mixed with glairy mucus and with blood. The dysphagia is not always due to tumefaction of the mucous membrane, but usually in part to coexisting inflammation of the muscles or infiltration between their sheaths, which paralyzes their contractile efforts. In severe cases, too, there is more or less febrile action, and in some children convulsions, from reflex irritation of the pneumogastric nerve.

In phlegmonous œsophagitis necrosed membrane may be expelled by hawking or vomiting. In diphtheritic œsophagitis shreds of false membrane are sometimes ejected by hawking or by emesis.

Diagnosis.—The diagnosis will depend upon the existence of a certain number of the symptoms mentioned. Idiopathic phlegmonous œsophagitis may be mistaken for dorsal myelitis, the more as it is occasionally attended by spasm; but there will be no pain produced by pressing on the vertebra. Circumscribed œsophagitis is usually marked by dysphagia after deglutition. Abscess can be determined only after rupture and discharge of pus by hawking or vomiting. The location of the inflammation can sometimes be determined by auscultation. The descent of the bolus is impeded. The normal sound is masked, and accompanied by regurgitation of small bubbles of air, and there is sometimes a slight friction-sound in deglutition. In cases of circumscribed œsophagitis, which is usually annular, the obstruction to the descent of the bolus is sometimes marked.

Prognosis.—The prognosis is favorable in acute catarrhal œsophagitis and in pustular œsophagitis from the use of antimony; the manifestations often subsiding within a few days. Diphtheritic œsophagitis and the pustular œsophagitis of small-pox are usually of fatal significance. Phlegmonous

œsophagitis may prove fatal within a few (two or three) days. If not fatal, it may lead to abscesses, which, discharging internally or externally, are followed by stricture or fistule. Ulcerous œsophagitis and intense catarrhal œsophagitis may terminate in chronic thickening and more or less adhesions of the walls of the tube. The prognosis, therefore, depends greatly on the cause of the affection.

Treatment.—Mild cases require no special treatment other than confinement to the house, and the use of bland and mucilaginous articles of diet, and more or less continuous deglutition of ice. Severe cases require, in addition, restrained use of the voice, the avoidance of effort in swallowing, and the addition of anodynes to the demulcent food or drinks. If swallowing is impracticable, or too painful, food and medicine are to be given by enema, and thirst to be allayed by sucking bits of ice, the juice of acid fruits, and rinsing of the mouth with simple or acidulated water. The external application of cold compresses, frequently renewed, is also indicated. Febrile phenomena are to be combatted in the usual manner; or, if this be impracticable, by the use of the cold bath or wet sheet, and the hypodermic administration of antipyretics.

Traumatic œsophagitis is met, first, by removal of the offending body, by the use of acid beverages (vinegar and water, Orfila) if alkalies have been swallowed, or of alkaline drinks, if acids have been swallowed. The subsequent treatment is instituted on general principles.

CHRONIC ŒSOPHAGITIS.

Chronic inflammation of the œsophagus may be circumscribed or diffuse, and may succeed acute inflammation. It follows the lengthened sojourn of foreign bodies in the tube. It may result from passive congestion in chronic pulmonic and cardiac disease. Chronic œsophagitis, followed by abscess and ulceration, sometimes occurs during the progress of caries of the vertebra, whether scrofulous or syphilitic, and during the progress of aneurismal and other tumors pressing upon the tube, which may produce ulceration, local hemorrhage, and hemorrhage from the diseased blood-vessel.

Symptoms.—The symptoms of chronic œsophagitis are similar to those of acute œsophagitis, but more moderate in character.

Diagnosis.—The diagnosis rests on the same principles as that of acute Œsophagitis, the symptoms being of longer duration. The auscultatory signs are sometimes more pronounced.

Prognosis.—The prognosis is unfavorable, as there is great disposition to fibrinous infiltration of the tissues, terminating in constriction and occlusion of the tube.

Treatment.—The treatment of chronic Œsophagitis is general and local. The general treatment will vary with the cause of the disease. If due to obstructed circulation from valvular disease of the heart, digitalis and like remedies, if to obstructive pulmonic disease, chloride of ammonium and alkaline remedies will be indicated. Syphilitic inflammation requires the mixed treatment with bichloride of mercury and iodide of potassium, or similar combinations. Alcohol is interdicted, and so is the use of all irritating food and drink. The iodides are often required even in non-specific cases. External counter-irritants are sometimes resorted to. The copious use of carbonic acid waters is also recommended. The local treatment consists in the systematic use, every few days, of solutions of astringents (alum, grs. x.-xxx., ad. f. $\frac{3}{4}$ j.; tannin, grs. x.-xxx., ad. f. $\frac{3}{4}$ j.) or alterants (iodine, grs. i.-ij., ad. f. $\frac{3}{4}$ j.; nitrate of silver, grs. v.-x., ad. f. $\frac{3}{4}$ j.), passed over the surface by means of a piece of soft surgical sponge securely attached to a flexible whalebone or metallic staff.

A sponge is well secured to the staff in the following manner: the terminal extremity of the staff should be notched circularly with a knife or file, as the case may be, so as to leave three or four annular projections one below the other. A cuboid wedge of strong and soft surgical sponge is to be cut with scissors, and the apex split for a distance sufficient to take in a little more of the extremity of the rod than has been notched. These ends are then tightly bound to the rod by many turns of strong hemp or silk thread, care being taken to make due use of the projecting flanges to prevent slipping. This done, the sponge is to be trimmed to the desired shape with scissors, and the thread waxed.

Severe pain, rather sudden in coming on, is thought to be indicative of circumscribed ulceration, and is best met by superficial cauterization with a dilute solution (grs. x., ad. f. $\frac{3}{4}$ j.) of nitrate of silver. It is requisite to avoid using strong solutions, as they might readily cause infiltration and obstruction. I have sometimes applied these remedies in the form of weak ointments, of the same strength as the solutions, made with petroleum (cosmoline) or other simple unguent smeared on a

rather large, flexible bougie. I have likewise used with advantage belladonna and stramonium ointment, in the same way, to relieve pain and constriction, and have sometimes administered a bolus of the same after the local application of the nitrate of silver. Auscultation of the œsophagus should be made before these agents are applied, with a view of determining the distance to which they should be carried.

It is important, after the immediate inflammatory manifestations have subsided, that a good-sized bougie be passed down the œsophagus at occasional stated intervals (two to six weeks), to detect the commencement of stenosis, which is likely to follow chronic œsophagitis.

Catheterization of the Œsophagus.—Great care is essential in the introduction of probes, sounds, and probangs into the œsophagus. The terminal extremity of the instrument being properly warmed to avoid spasm and well anointed to diminish friction, it is taken in one hand like a pen and guided by one or two fingers of the other hand beyond the tongue and epiglottis of the patient, whose head is bent backward if the rod is a rigid one, but not unnecessarily so if the instrument is very flexible. The instrument is then insinuated into the œsophagus with as little assistance from the hand as possible. If there is any difficulty in entering the œsophagus, the point of the instrument may be shifted to one side of the larynx, so as to enter by the posterior wall of the pyramidal laryngo-pharyngeal sinus, which is directly continuous with the œsophagus. A voluntary effort of deglutition on the part of the patient at the moment of reaching the œsophageal entrance will facilitate its introduction. The introduction of the instrument may be easily effected under guidance of the laryngoscopic mirror, which is the safest means of avoiding penetration into the larynx, an accident which occasionally occurs in attempts to catheterize the œsophagus. If the patient can use his voice after the instrument has been passed a couple of inches, it is evident that it is not in the air-passage.

IMPERFORATE ŒSOPHAGUS.

Congenital occlusion of the œsophagus is one of those occasional malformations irremediable by surgery. Its existence may be suspected when the child takes the breast readily, but is unable to swallow the nutriment and rejects it by the mouth. If, as is often the case, there be a communication with the trachea, the attempt to swallow will be followed by symptoms of suffocation, caused by the entrance of food in the air-passage. On inspection, the mouth and throat appear normal. A bougie passed along the track of the œsophagus

will become arrested in a sort of cul-de-sac, usually found in the upper portion of the œsophagus.

A number of cases of this malformation have been recorded. Mr. Holmes, in his treatise on the Surgical Affections of Childhood, mentions three.¹ The obliteration in the first case commenced about an inch below the commencement of the œsophagus, and continued to a point just above the origin of the bronchi. Swallowing had produced choking, which induced the diagnosis of a communication with the trachea; and an opening of this kind was discovered after death. The child was nourished by enemata, and died on the eleventh day. In the second case, the upper and lower portions of the œsophagus were in direct communication with the trachea, which was thus, as it were, doing additional duty as part of the gullet. Dr. Ogle, who reports the case, believed that some of the milk taken by the child may have reached the stomach. The child perished on the fourth day. In the third case there coexisted malformation of the heart and great vessels, with cyanosis. The trachea communicated with the lower part of the œsophagus, and, Mr. Holmes thinks, must have communicated with the upper part also, inasmuch as attempts at swallowing always produced dyspnœa. The obliteration extended from the end of the pharynx to a point opposite the bifurcation of the trachea. The child died on the twelfth day.

From the result of the examinations made in the instances recorded, Mr. Holmes justly concludes that surgery offers very little hope of remedying or overcoming such a condition by any operative procedure. In cases where a tracheal fistule exists, in connection with obliteration of the œsophagus, he questions whether life would be permanently maintained, even if the passage of food could be restored, and he does not think the attempt should be made in any such case. Where no such communication exists, he sees no objection to the operation being attempted, after due explanation to the parents of the fatal nature of the case. The object would be to cut down upon a point of a catheter passed along the pharynx, and then to attempt to trace the obliterated œsophagus down the front of the spine, until its lower dilated portion is found. A gum catheter would then be passed through an opening made in the upper portion, and so on into the stomach through the lower portion. If the two portions are near enough to be connected by silver sutures over the catheter, and if the latter can be retained until they have united, Mr. Holmes thinks that permanent success might possibly be obtained.

¹ Reported in the Pathological Transactions of London (Vol. III., p. 91; Vol. VII., p. 52; Vol. VIII., p. 173).

Mr. Ryland¹ refers to a case related by Dr. Houston,² and which occurred under his own observation, where the œsophagus communicated with the posterior part of the trachea by a large opening. The pharynx was unusually wide, and terminated some way down the neck in a cul-de-sac, without having any connection with the œsophagus. The larynx and its muscles were all perfect. This infant lived about twenty-four hours. On every attempt to suck, fits of coughing immediately supervened, threatening suffocation by their violence, and lasting till all the milk was disgorged. The only way in which food could get into the stomach was by passing through the rima glottidis first, and then reaching the œsophagus from the opening in the posterior part of the trachea.

Mr. Annandale³ illustrates the pathological appearances of the case of an infant who died in forty-eight hours after birth, in which the upper part of the œsophagus was dilated into a pouch three-tenths of an inch above the bifurcation of the trachea, into the posterior wall of which it entered at this point. Similar cases reported by others are referred to in his article.

FISTULE OF THE ŒSOPHAGUS.

As elsewhere mentioned, a fistule of the œsophagus sometimes remains after a wound of that tube, or after the discharge of an œsophageal abscess, the result of the retention of a foreign body.

A number of cases of congenital fistule are on record, and the deficiency of development is not infrequent.⁴ The fistulous opening is seen at some part of the neck, giving discharge every day to several drops of pus or muco-pus, a drop or two of which can almost always be pressed out of the little opening. There may be but one external opening, or there may be two or three, over the thyroid cartilage, just above it, or some distance below, and usually to one side of the middle line. The external orifice of the fistule is often closed by a plug of the desiccated discharge. The track of the fistule, varying in length from half an inch to two inches, is often so minute that a delicate probe cannot be passed along it without perforating its walls. The fistule is supposed not to be connected with the air-passages, in consequence of the failure of every attempt to pass air out of it from the lungs.

If the opening have been congenital, it will probably be found on inquiry, as in a case reported by Dr. J. M. Duncan⁵,

¹ A Treatise on the Diseases and Injuries of the Larynx and Trachea.

² Dublin Hospital Reports, Vol. V., p. 310.

³ Edinb. Med. Jour., Jan., 1869, p. 598.

⁴ For recent examples see Paget: The Lancet, Dec. 1, 1877, p. 804.

⁵ Edinb. Med. Jour., Nov., 1855.

that drops of milk exuded from it at some time when the child was suckling.

The position of the fistulous opening, the direction taken by an exploring probe, and some history of the escape of nutriment, can alone distinguish it from other fistules of the neck which open externally in front of the thyroid cartilage, or to one side of it, and which originate in one of the three mucous bursæ in this situation, most frequently, according to the researches of Guerlt, in the infra-hyoid bursa.

I have seen a few cases of fistulous openings in the neck, either congenital, or of life-long standing to the best recollections of the patient.

In one of these it was impossible, even by cutting down upon the track and following its apparent entire course, to find whether it really communicated with the pharynx or œsophagus, or not. In that case no cyst was found connected with the thyro-hyoid bursa, though the track led directly to the hyoid bone, which was in part denuded of periosteum. This was scraped, the fistulous track cut out, and the parts brought together, with some benefit as far as a reduction of the amount of discharge was concerned, but failure in reference to any obliteration of the fistule, which was congenital, and existed in a healthy lad some twenty years of age.

The treatment for fistule consists in attempts to obliterate its tract by exciting adhesive inflammation; for which purpose nitric acid on a silver probe, the hot wire (see p. 277), or the galvanic cautery, may be used.

STRICTURE (STENOSIS) OF THE ŒSOPHAGUS.

Strictures of the œsophagus are occasionally congenital, and these are naturally considered inimical to life. That they are not invariably fatal is attested by a case narrated by Dr. Wilks,¹ and referred to by Mr. Holmes,² as follows:

“The patient was a very healthy man, and well nourished. He died at the age of seventy-four, of pneumonia, having never previously had a serious illness during the whole of Dr. Roote’s professional knowledge of him, which extended over upwards of thirty years. He took his food, however, like a ruminating animal, and had never been free from this ruminating tendency, as far as he could remember, so that it was believed to be congenital, especially as post-

¹ Pathological Transactions, XVII., 138.

² The Surgical Treatment of the Diseases of Infancy and Childhood, 2d Edit., p. 137.

mortem examination showed no trace of any diseased action. He always brought up a portion of every meal he took, and could not swallow solid food without washing down each mouthful with fluid. At the same time, he always persisted in saying that he did not vomit his food, but coughed it up, and that he had never been sick in his life. A bougie could be passed, but it was always followed by his coughing up more or less of the solid or liquid food taken within the last few hours. On examination, the upper part of the œsophagus was found enormously dilated, measuring six and a half inches in circumference in its undistended state, and was of nearly uniform size throughout. Towards the stomach, however, it suddenly contracted, and here the tube was as much below the natural size as in other parts it was above it. The little finger could just be squeezed through into the stomach. But there was no thickening, and no trace of cicatrization as the result of disease."

A similar condition of things is sometimes attendant upon simple stricture of the œsophagus, the result of the inflammatory process, without the production of pseudoplastic deposit. The inflammation giving rise to this condition may have implicated the submucous connective tissue only, or it may have affected all the coats of the œsophagus.

Sometimes the immediate cause of the stricture is unknown, and is therefore referred to spontaneous origin. It may be due to impacted foreign body; purulent accumulations in the walls of the tube; polypi, fibroid and other tumors; carcinoma. Most frequently the stricture is traumatic, the result of destructive inflammation, and vicious cicatrization following mechanical injury, or scalds received in swallowing hot fluids or caustic substances. The most common seat of stricture of this nature is high up in the œsophagus, at its narrowest portion; and the next, perhaps, at the lowest portion of the pharynx, just behind the cricoid cartilage. These are the portions most exposed to mechanical injury, burns, and scalds. Stricture from these causes is often incurable. Occasionally the stricture is the result of acute or chronic inflammation of spontaneous origin. It is also produced by syphilitic inflammation,¹ by malignant disease (carcinoma), and tuberculosis.

Œsophageal stricture is usually due to disease involving the mucous membrane and submucous connective tissue, though sometimes involving the muscular portion of the tube also. It may, however, be due to abnormal laxity of the mucous

¹ For examples see West: *Dub. Jour. Med. Sci.*, Feb., 1860; Virchow: *Syphilis Constitutionelle*, p. 88; Maury: *Gastrotomy for*, *Am. Jour. Med. Sci.*, April, 1870.

membrane, permitting a fold to be formed in such a manner as to impede the passage of the bolus, though there would be little or no impediment to regurgitation and vomiting. In cases which are not cancerous, the diminution of the calibre of the tube is usually due to submucous fibrinous deposit, and to thickening of the mucous membrane. This diminution may be very slight, or so great as to amount to almost complete occlusion. The seat of the stricture is usually just behind the lower portion of the larynx, or just below it; but it may occur lower down, sometimes within three or four inches of the cardiac orifice of the stomach, and sometimes just above it.¹ The stricture rarely involves more than a few inches of the tube, this being largely dependent on the cause. Most frequently the stricture is single, but sometimes there are two or more of them. In one case under my own care, there were two strictures, one just behind the lower portion of the larynx, which could be readily passed with a moderately large bougie, and another, apparently two inches below it, which could be passed only by means of a rat-tailed bougie. In another there were four. Most of the cases met with occur in early adult life, but they may be encountered at any age. Males appear to suffer more frequently than females.

The detention of food above the stricture usually dilates the œsophagus at that portion exciting hypertrophy at first, and fatty degeneration subsequently. Atrophy is apt to take place below the stricture if it is at all tight; and the mucous membrane becomes plicated longitudinally. Collapse of the tube below the stricture usually follows.

Symptoms.—Except in cases of traumatic origin, the earliest symptoms are occasional impediment to deglutition of large and firm mouthfuls, or rather a mechanical obstacle to completion of the deglutory act, with intermissions for a few meals or a few days. After awhile it becomes impossible to swallow a large solid bolus, and sometimes repeated efforts are necessary to swallow small ones, perhaps aided by external manipulation, or the pressure of liquids swallowed immediately afterward. This is sometimes attended by spasm, regurgitation, pain in the parts, oppression in the lungs, and more

¹ For examples see Maury (loc. cit.); Rawdon: Liverpool Med. and Surg. Rep., 1869, p. 117; Reid: N. Y. Med. Jour., Oct., 1877, p. 405.


or less nervous distress. Subsequently, as the disease progresses, it becomes impossible to swallow solid food, and eventually, even fluids in extreme cases. The bolus is then often regurgitated immediately after deglutition, and may be covered with mucus, pus, blood, and debris of ulcerated malignant growth, according to the nature of the cause. If the tube is much dilated above the stricture, the food may be detained in the sac for some hours, and then be regurgitated in a softened, partially decomposed condition. In stricture due to organic disease, there may be dysphonia from pressure or injury to the recurrent laryngeal nerve, producing paralysis of the vocal cord. The anatomical course of the nerve renders the left recurrent much more liable to implication than its fellow. Moderate dyspnœa may result from this paralysis of the glottis.

Diagnosis.—The diagnosis of stricture of the œsophagus is rarely difficult. First there is the dysphagia, spasm, and regurgitation of food. When high up, the vomiting or regurgitation of food may closely follow its deglutition; when low down, it may be retarded for some (15–20) minutes. There will be more or less general ill-health from insufficient nourishment; and sometimes pain, more or less severe, will be complained of in the region of the sternum, stomach, or cervical vertebræ. Cancerous disease is inferred in patients advanced in life, and substantiated by examination of debris, or evidence of pronounced cachexia. The fact being determined that the impaired deglutition is not due to paralysis, to foreign body, burn, or scald, to abscess of the pharynx or œsophagus, or to tumors in the pharynx, larynx, trachea, or thorax, laryngoscopy being employed in determination of some of these points, the suspicion of stricture arises. Auscultation will indicate the seat of stricture by the ascent of consecutive bubbles of air in swallowing water, even when it eludes detection by palpation with bougies; and in advanced cases, the diagnosis is confirmed by an attempt to pass into the stomach some rubber or other flexible bougies or œsophageal probes, terminating in olive-shaped masses of ivory of different sizes, and affixed to stout whalebone rods, which are arrested at the seat of the stricture. These instruments are to be carried through the stricture if possible, and the length of the constriction is judged of by the distance along which resistance to the passage of the instru-

ment is felt; the diameter of the stricture, by the size of the largest instrument which can be employed; and its consistence, by the amount of resistance offered to the passage of the exploring instrument. The instrument, after passing the stricture, should always be carried down into the stomach, in order to ascertain whether there be any more strictures farther down the œsophagus. Great care is necessary in the passage of these instruments, on account of the probable existence of a pouched condition of the tube immediately above the seat of stricture, into which the instrument may glide, and through which it may be thrust, to the fatal detriment of the patient, by the employment of an undue amount of muscular force. The best instruments of the kind are graduated œsophageal dilators of flexible catheter material (Fig. 76), or of whalebone, as may be most suitable, the entire instrument, rod, and graduated bulbous enlargements being of one piece. Several series are required to meet all the requirements of dilatation.

In cases where the stricture is quite small, and pouched at its side, Dr. J. Mason Warren recommends the use of a conical wax bougie with the tip bent forward, as more likely to pass the stricture than a straight bougie, which would be apt to become caught in the sac.

Prognosis.—The prognosis is usually unfavorable. It is comparatively favorable in cases of moderate stricture, ostensibly due to a curable cause. The extent and volume of the stricture progresses more or less slowly according to the nature of the cause, and in non-malignant cases it may last for years before the patient succumbs, as he does, if not relieved, from gradual inanition. In the earlier stages before the hypertrophied muscles above the stricture undergo fatty metamorphosis, the increased muscular power is sufficient to force more or less nourishment through the stricture; but when this is no longer possible, progressive marasmus must ensue. Meantime, abscess of the œsophagus may become developed in consequence of the pressure of the food retained above the stricture; and tuberculous degeneration of the lung or gangrene may take place in consequence of the reduced condition of the system. Dysphonia and moderate


 FIG. 76.—Graduated œsophageal dilator

dyspnœa from paralysis of the recurrent laryngeal nerve is recognized laryngoscopically by unilateral paralysis of the vocal cord.

Treatment.—The treatment of stricture of the œsophagus resolves itself into attention to the general health, the administration of the iodides in stricture from organized effusions into the connective tissue or muscles, and mechanical or operative measures for the removal of the causes of constriction. Foreign bodies must be extracted, or, if their nature permit, be forced into the stomach; abscesses discharged; removable tumors extirpated.

In cases of cancerous disease, the employment of local measures for relief of the constriction is, in the main, unjustifiable, because they usually produce injury which may be serious in character. Arsenic internally is thought to retard its progress if administered early and persistently; and morphia is used hypodermically to assuage pain.

The local treatment consists in the mechanical dilatation of the stricture by the repeated passage of bougies, or œsophageal probangs of larger and larger size, or of metallic tubes which, by mechanical arrangements externally, can be gradually dilated after their introduction. The ordinary dilators (Fig. 77) are not always safe instruments. If this form of instrument is employed, care should be taken that the upper portion of the bulb be much more tapering than is represented in the illustration, so that there shall be but little difficulty in disengaging the shoulder from beneath the stricture in its withdrawal. The security of the olive extremity to the shank should always be tested before it is introduced into the œsophagus.

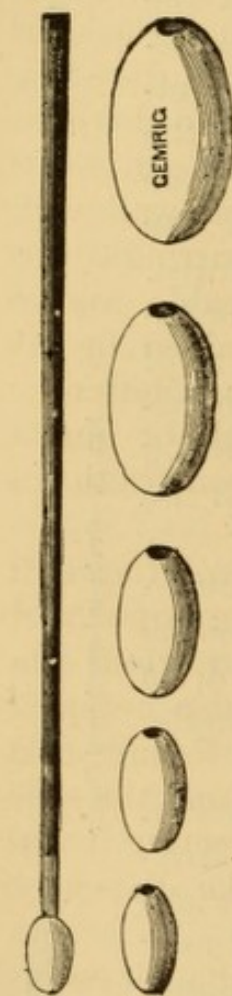


FIG. 77.—Œsophageal dilators.

In one case in which I passed such an instrument through four strictures I was unable to withdraw it without exerting force enough to detach the ivory bulb from the shank of the instrument. Fortunately the bulb had entered the stomach and was eventually digested; but the accident caused me a great deal of anxiety for many weeks, and has deterred me from using a similar instrument since.

The bougie or dilator is employed every day, every other day, or at more lengthened intervals, according to the tolerance of the parts and the progressive improvement ; being retained several minutes at each introduction, and followed by the mere passage, in and out, of a larger instrument shortly after the withdrawal of the first one. It is sometimes advisable that the final dilatation at each operation be performed with as large-sized a stomach-tube as can be passed through the stricture, that advantage may be taken of its presence in the stomach or below the stricture to pour in some liquid food from a small-lipped vessel or a syphon, in order that the parts and the patient shall be relieved from the necessity of swallowing for some hours, and thus avoid a frequently recurring source of irritation. This method is continued, if applicable, until it is pretty certain that nothing further is to be gained in this way, when the patient may be dismissed, with instructions to repeat the passage of the instrument once a week or once a fortnight, to prevent or retard recurrence of the constriction, a condition very likely to take place.

Forcible dilatation, by mechanical separation of the sides of a double metallic sound, has sometimes been employed with success ; but it is an operation which may prove injurious, and is to be undertaken with great care. Resort is also occasionally made to a combined method of gradual and forcible dilatation, consisting in passing a thin rubber tube along the stricture by means of a firm conductor, and then injecting it with compressed air, water, or quicksilver, to dilate the distensible portion within the grasp of the stricture.

Attempts are sometimes made to destroy the cicatricial tissue by means of caustics carried to the parts in a protected tube, so as to avoid contact with the sound tissues. This method is sometimes successful, but requires great caution in selecting cases suitable for it.

Division of the stricture has been performed by means of a concealed lance at the extremity of a metallic tube, the knife being projected when the stricture is felt, and then carried through it and retracted as soon as the want of resistance shows the stricture to have been passed. Dilatation is then kept up by means of œsophageal tubes and bougies frequently introduced.

Electrolysis by means of œsophageal electrodes has been

employed with asserted success; but electrization of the œsophagus of any kind is risky on account of the danger of fatal syncope from irritation of the pneumogastric nerve.

Œsophagotomy and gastrostomy have occasionally been practised in stricture of the œsophagus not malignant or due to aneurism; but the results have rarely been successful.

Dr. Jonathan Hutchinson¹ has reported a case of stricture from swallowing caustic potash, in which gastrotomy was proposed but not performed, and which was subsequently cured by dilatation with bougies.

Gastrotomy (gastrostomy), performed by Sédillot in 1849, has been occasionally performed by other surgeons in Europe and America, to establish a permanent gastric fistula in cases of stenosis of the œsophagus. The first successful case on record was an operation by Verneuil,² July 25, 1876, on a lad seventeen years of age, whose stricture was the result of swallowing a solution of potash the February preceding. It was performed under careful antiseptic precautions. "An incision was made five centimetres in length at the left border of the epigastrium, parallel to the cartilage of the eighth rib, and two centimetres from it. The several tissues were successively incised until the peritoneum was open and the stomach exposed. The stomach was then drawn by forceps to the orifice of the wound, and then secured by acupuncture and firmly sutured to the edges of the wound before the viscus was opened. This was done to prevent any flow of blood into the peritoneal cavity. A buttonhole opening was then made into the stomach, and a soft red caoutchouc tube introduced to keep it patent and provide for the introduction of nourishment; a plug being inserted into its free extremity to prevent the access of air to the interior of the stomach. Antiseptic dressings were applied."

Trendelenburg, who reports a successful case,³ notices a tendency in the attached wall of the stomach to retract from the margins of the abdominal wound. He therefore attaches it by twelve or fourteen close sutures. He makes two small crossed incisions into the stomach, preferring a small opening as doing away with any necessity for a special occlusion apparatus, all that is required being a small drainage-tube readily kept closed with a cork. In feeding, he recommends that the patient masticate his food to mingle it with saliva, and that he then blow it through flexible tubing directly into the stomach, facilitating its passage by external assistance.

The cure of a stricture by dilatation usually requires very protracted treatment, varying from six to eighteen months on the average. Many cases are altogether unsusceptible of relief, and terminate fatally in a few months or a few years.

¹ London Hospl. Reports, Brit. and For. Med.-Chir. Rev., July, 1869, p. 28.

² Gaz. Méd., Paris, 1876, No. 44, p. 176; London Medical Record, Dec., 1876; The Lancet, Jan. 13, 1877, p. 51; N. Y. Med. Jour., March, 1877, p. 325.

³ Arch. klin. Chir., XXII., 1; London Medical Record, March 15, 1878, p. 100.

In this slow way the celebrated English physiologist, Marshall Hall, fell a victim to a stricture of the œsophagus, with ulceration of a dilated sac of the pharynx and œsophagus above the seat of stricture. Post-mortem examination revealed the fact that the stricture was not very great, but that a fold of mucous membrane at its upper portion, and pointing upward, formed a sort of valve which prevented the passage of food, though there was space enough, as found after death, to pass the finger through the stricture from below upward.

When nourishment cannot be taken into the stomach, even with the aid of the stomach-tube, it is necessary to resort to nutritive enemata, a practice which should be commenced to supplement nutrition long before it becomes the ultimate resource.

Professor Billroth, of Vienna, has suggested¹ the excision of a portion of the œsophagus in cases of carcinomatous disease, being disposed to consider favorably of the operation in consequence of the success which so frequently attends the operation of œsophagotomy for foreign body, and from the fact that, as a rule, cancer of the œsophagus remains confined to its original locality, and does not extend to the lymphatic glands. From some experiments made by him upon the dog, he is inclined to regard the operation as holding out a reasonable hope of success. Nourishment could be maintained through the wound at first, and afterwards, as cicatrization took place, through the mouth, the stomach-tube being employed until its use becomes no longer necessary—this being the plan employed in the experiments alluded to.

COMPRESSION OF THE ŒSOPHAGUS.

A constriction of the œsophagus (extraneous stenosis) is sometimes due to pressure of a mediastinal, carcinomatous, aneurismal, or other tumor on the exterior of the tube, dislocation of the hyoid bone, cancer of the lung or pleura, abscess in the trachea, or between it and the œsophagus, abscess from caries of the vertebra, and so on. Similar cases sometimes occur in connection with tumors of the thyroid gland which have extended downward and backward. These cases must be carefully differentiated from stricture of the œsophagus the result of disease in the tube itself, for they are not amenable to local treatment. A few instances have been recorded in which more or less temporary amelioration has followed the careful introduction of tubes for the purpose of supplying nourishment; an enlargement of the available calibre of the œsophagus having resulted.

¹ Archiv für klinische Chirurgie. Bd. XII., part 1, 1871, p. 65.

Dysphagia, as a symptom, may be due to pressure of effused fluid in the pericardial sac, as in a case of acute rheumatism reported by Dr. Chas. Kelly.¹ Dr. Helber reports² an instance of death from compression of the œsophagus in a case of mediastinal carcinoma. In cases of aneurism, ulcerative inflammation may be excited, and the aneurism discharge into the œsophagus.³

A case of occlusion of the œsophagus, by the presence of a tumor between it and the trachea, has been reported by Drs. Mascaro and Dominguez, of Pernambuco,⁴ in which an operation for the removal of the tumor was attended with success.

DILATATION OF THE ŒSOPHAGUS—ŒSOPHAGOCELE.

Dilatation of the œsophagus is either general or partial, as it takes place in the whole or greater portion of the œsophagus, or in a circumscribed portion. Partial dilatation may involve the entire circumference of the gullet, in which case it is designated as annular or saccular, or it may implicate but a portion of the wall, which is pushed out into a pouch known as a diverticulum.

General dilatation may be the mechanical result of constriction of the cardiac orifice of the stomach, of distention by drinking large quantities of fluids, and of chronic œsophagitis. Sometimes there is no apparent cause. The dilatation is often discovered only as a post-mortem curiosity. There is usually hypertrophy of the muscles, and often erosions and ulcerations accompanying other evidences of chronic inflammation. The amount of dilatation varies from a slight enlargement to the size of a man's arm⁵ or larger.

Prof. Luschka has reported⁶ a very remarkable case of this kind in a woman some fifty years of age, who, from her fifteenth year, had possessed the faculty of voluntary regurgitation of food, without effort and without pain. Towards the close of her life she suffered with rheumatism, hemorrhagic erosions of the

¹ Practitioner, London, July, 1872, p. 22.

² Memorabilien, Dec. 12, 1868, p. 192.

³ A specimen from a fatal case of this kind was presented by Dr. Loomis to the N. Y. Path. Soc. The Medical Record, New York, Vol. III., p. 235.

⁴ Arch. gén. de méd., March, 1874, p. 357.

⁵ Rokitsansky and others.

⁶ Virchow's Archiv für Anat., &c., March, 1868, p. 473.

stomach and œsophagus, leading to the vomiting of coagulated black blood, from the loss of which, with the coexistent cancerous degeneration of several lymphatic glands, a condition of debility was produced which terminated fatally by œdema of the lungs. A *post-mortem* examination revealed the existence of an enormous dilatation of the œsophagus (Fig. 78), nearly equal in bulk to the capacity of the stomach. There was no constriction of the cardiac portion below it, as in the cases reported by Rokitansky and others. The dilated œsophagus was 46 centimetres in length instead of 29 centimetres, the normal length. Hence it is evident that it must have occupied a curvilinear position during life. At the point of greatest enlargement it equalled the size of the arm of a muscular man, being 30 centimetres in circumference; the medium circumference being normally but $7\frac{1}{2}$ centimetres. A sort of spindle shape was given to the enlargement by a slight constriction at the border of the upper and middle thirds, where it occurs in the normal œsophagus. The muscular layer was hypertrophied, and the mucous membrane gave evidence of intense catarrhal inflammation, with the existence of the hemorrhagic erosions that had been suspected during life.

M. Raymond¹ reported a case in which the abnormal dilatation took place between the lobes of the lungs, from the base of the heart to the cardia. F. Arnold has described three cases in which there was rumination.

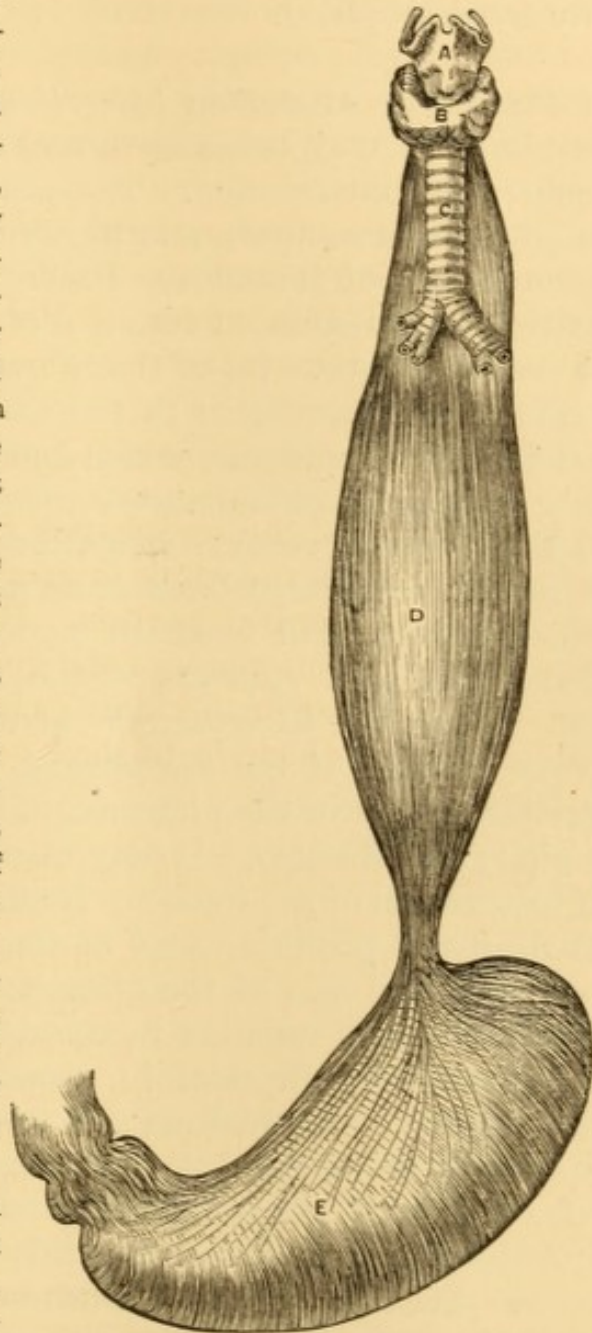


FIG. 78.—Enormous dilatation of œsophagus 1.6 natural size (Luschka). A, larynx. B, thyroid gland. C, trachea. D, œsophagus. E, stomach.

Annular dilatation is usually due to distention just above the seat of a stricture. It is sometimes due to retention of a foreign body, and is occasionally observed as a congenital anomaly. When not due to stricture, its seat is usually just

¹ Gaz. méd., Paris, 1869, No. 7, p. 91.

above the diaphragm. The upper portion of the dilatation is larger than its lower portion, and the muscular walls are usually hypertrophied.

Pouch-like dilatation (*diverticulum*) is usually due to retention of food immediately above an impacted foreign body or some other obstruction. The muscular fibres become separated and spread apart, and the efforts of deglutition gradually force the mucous membrane through them, further and further, until it is transformed into a sort of hernia or pouch external to the main tube. Rokitansky has called attention to another mode of its production in the subsidence of tumefied glands outside the œsophagus, which had contracted adhesions to the tube during the inflammatory process, and which in shrinking to their normal volume sometimes draw the tube out into a funnel-like sac, constricted at its margin by the muscular coat which has receded from the pouch. It is likewise an occasional result of rupture of the muscular coat from blows and falls. The diverticulum is usually located at the very upper portion of the œsophagus, just below the inferior constrictor muscle of the pharynx, in which case it may be in part a pharyngocele also. It may also be located behind the point of bifurcation of the trachea. Its direction is usually backward between the posterior wall of the œsophagus and the spinal column. The size of the diverticulum varies. The orifice by which the tube remains in communication is variable in size, and round or elliptical in shape. Sometimes it drags the œsophagus out of position and forms a sort of blind pouch in the direct line of the axis of the œsophagus, so that it becomes filled with food which fails to reach the stomach. Patients are sometimes starved to death in this way. Sometimes there are several dilatations. The dilatations are enlarged by retention of food, until they finally undergo inflammation, ulceration, and perforation into the lung, pleura, bronchi, or mediastinum.

Symptoms.—The symptoms are usually those of obstruction to the passage of food at first, but there may have been dilatation before this without symptoms. Deglutition is less impeded when the disease does not implicate the upper portion of the gut. Complete dilatation is sometimes indicated by addiction to habits of rumination, which are said not to be

unpleasant. One of my patients, a lady, confessed to a sensual enjoyment in the process. While the dilatation is moderate and the muscles powerful there will be little or no dysphagia, but after the muscles become paralyzed by distention, dysphagia will gradually increase and culminate in utter aphagia. Palpation with the œsophageal bougie will reveal the existence of a large sac, in which its terminal extremity can be freely moved. Auscultation indicates an alteration in the shape of the bolus of water, which trickles rapidly in a larger or smaller stream according to the degree of dilatation. Symptoms of circular dilatation are those of stricture, with retention of food above it, regurgitation of the food occurring longer after deglutition than when there is no dilatation. There is also a more or less constant foul odor from decomposing food. If high up, the dilatation may be detected externally by enlargement after taking food, and subsidence of tumefaction when the sac is emptied. If so located as to exert compression on the trachea, this will be indicated by dyspnœa. Palpation with the sound will sometimes reveal the locality and size of the dilatation, but it must be practised with a delicate hand. Auscultation is said to reveal general sprinkling of the fluid bolus, not unlike that of rain deflected by the wind. The indications of a diverticulum are similar to those just described, but regurgitation does not take place usually until several hours after a meal. As the sac enlarges there may be less and less complaint of dysphagia, because it can hold larger quantities of food. Still at the same time it may so compress the main tube as to prevent access of food to the stomach. Exploration with the sound will sometimes detect the sac (see Stricture, p. 292), and the usual precautions are requisite in using the instrument. Auscultation will reveal any deviation in the line of the œsophagus caused by pressure of the sac.

Diagnosis.—The diagnosis will depend upon the auscultatory signs, the dysphagia, regurgitation, and so on, and the results of exploration with the sound. It is to be remembered that the sound may slip by the entrance into a diverticulum without entering it, and that its passage into the stomach is not positive evidence that a circumscribed dilatation does not exist. When the dilatation is high up, the question of morbid growth or of abscess may arise. The tumefaction, as stated, is intermittent in dilatation of the œsophagus. Compression of

such a dilatation distended with food would force some of its contents into the pharynx.

Prognosis.—The prognosis is not favorable unless the cause can be removed; and not always then, unless food can be prevented from accumulating in the dilated portion of the tube.

Treatment.—If the dilatation be due to stricture or retained foreign body, the treatment would be directed to overcoming the one and removing the other. General dilatation with chronic œsophagitis requires the treatment for that affection. To prevent detention of food in a sac or diverticulum, nourishment should be introduced by the stomach tube. Stimulants are usually indicated, the general treatment being that required for stricture. If there is reason to suspect paralysis of the muscular coat of the œsophagus, preparations of phosphorus and strychnia are advisable on general principles. Stimulation of muscular contractility by the œsophageal electrode has been recommended, but the prospects of success hardly justify the risks of serious injury in the domain of the pneumogastric nerve.

MORBID GROWTHS IN THE ŒSOPHAGUS.

Morbid growths, carcinoma excepted, are not frequent in the œsophagus. They are often extensions of disease in neighboring organs. Sometimes they simply hang into the œsophagus, their point of origin being on the pharyngeal surface of the larynx or the epiglottis,¹ in the pharynx, or in the posterior nares. The latter form of growth is pedunculated or polypoid. Fibroma is the most frequent variety. Lipoma occurs also. These tumors sometimes acquire the bulk of an ordinary sausage, several inches in length.² Fibromas arising in the submucous connective tissue are usually small, but sometimes acquire the bulk of two or three inches in length and circumference. They have also been found in the muscular tissue,

¹ For example of large fibrous tumor, see Warren, *Surgical Observations*, Boston, 1866, p. 116; for example of large lipoma, see Gibb, *On the Throat and Windpipe*, London, 2d ed., p. 371.

² For examples, see Warren and Gibb, *loc. cit.*; Rokitansky, *Oestreich med. Jahrb.*, Bd. 1, p. 2; Schmidt's *Jahrb.*, Bd. 32, p. 62; Dallas, with cases of Baillie, Gräff, Schneider, Pringle, Mondière, *Arch. gén. de méd.*, Aug. and Sept., 1833. Middeldorpf, *Die polypi œsophag. atque de tumore ejus generis primo prospere extirpato*, etc., Vratislav (Warsaw), 1857.

usually just above the cardiac orifice. Papilloma has been seen on the mucous membrane, usually of the lower or upper part of the tube. Sarcoma occurs occasionally. Myxoma is infrequent. Myoma has also been found in the œsophagus.¹ These growths are usually of slow development, in many instances a number of years (four to twelve) elapsing from the earliest manifestations of their presence before they are detected.

Symptoms.—The symptoms are like those of foreign body or of stricture. Small tumors produce no special symptoms, and are detected only on *post-mortem* examination. Sometimes a large, pedunculated tumor will be ejected into the pharynx and mouth, and threaten suffocation if not promptly returned. There is no pain in benign growths as a rule.

Diagnosis.—This will rest on the symptoms of dysphagia and stricture. Tumors arising outside the œsophagus can be detected by direct inspection or by laryngoscopy. Pedunculated tumors are sometimes seen in the mouth or pharynx when they are forced out of the œsophagus. Palpation with the finger and the sound may reveal their dimensions and point of implantation. Auscultation, likewise, might suggest the presence of a tumor by alteration in the descent of the bolus and the sounds produced thereby.

Treatment.—Small tumors any distance within the œsophagus are beyond treatment unless œsophagotomy be performed. Tumors which project into the pharynx and large tumors at the entrance of the œsophagus can be transfixed with a stout ligature, and then encircled by loop, after which they may be cut off in front of the loop with knife, scissors, *écraseur* wire, or galvano-caustic snare. The loop of thread or wire should then be fastened outside of the mouth, so as to secure the remainder of the growth when it has sloughed through. The galvanic cautery may also be applied directly to destroy growths which are easy of access.

CARCINOMA OF THE ŒSOPHAGUS.

Cancer is the most frequent disease of the œsophagus that comes under treatment. It may be fibroid, medullary, or epithelial; medullary being the most frequent variety, and epithe-

¹ Eberth: Virchow's Arch., April, 1868; Gaz. hebdomadaire, 1868, p. 47.

lial next. It is usually primitive. Sometimes it is an extension of cancerous disease from the tongue, epiglottis or larynx, or from the stomach.

Primitive cancer is usually circumscribed and most frequent at the cardiac end of the Œsophagus, but it often occurs in the central portion only, and sometimes occupies the entire length of the tube. It begins in the submucous connective tissue, either nodulated or diffuse, implicates the mucous membrane, becomes further developed in the open calibre of the tube, undergoes softening and ulceration, and becomes covered with exuberant granulations. When it involves the entire circumference of the tube there is more or less constriction, real stricture, which may eventually amount to complete obstruction. When the ulcerative stage is reached, the calibre of the Œsophagus again becomes permeable to a slight degree, and the organ itself may become enlarged or hypertrophied. There is dilatation of the Œsophagus above the constricted portion, and collapse below it. As the disease progresses the adjoining tissues become involved, adhesive communication may take place with trachea, bronchi, bronchial glands, lungs, or other intrathoracic structures, and perforation may take place into the air-passages, lungs, pleura, mediastinum, pericardium, aorta, or pulmonary artery. There may be involvement of the pneumogastric nerve, with reflex influence on the spinal nerves and sympathetic, manifested by pain and paralysis in the domain of these nerves.¹ In some cases cancer of the Œsophagus has appeared to have given rise to tuberculosis;² or, as Hamburger has put it, there seems to be some disposition to cancer of the Œsophagus in tuberculous subjects. The children of tuberculous parents may have cancer of the Œsophagus, and their offspring, again, tubercle. It is most frequent in the male sex, and more so in individuals addicted to alcoholic excess than in the temperate. The immediate exciting cause is often attributed to some local injury from retention of foreign bodies, or the deglutition of hot, acrid, or foreign substances.

Symptoms.—The earliest local symptom is slight dysphagia, with impediment to completion of the act of deglutition—

¹ Surmay (Bull. méd. de l'Aisne, 1869), Gaz. méd., Paris, April, 1872.

² For example, see Nobiling (Bayer. ärztl. Intell.-Bl., Aug., 1870), Schmidt's Jahrb., Sept., 1873, p. 303.

an evidence of commencing stricture ; at a subsequent period involuntary regurgitation of food is superadded—an evidence of dilatation above the stricture, with partial retention of food ; and still later there will be vomiting, with admixture of pus and sanguinolent cancerous fragments of tissue if ulceration have taken place. It will usually be evident, however, that progressive emaciation, with more or less loss of physical power, has preceded these local symptoms. There is little pain, if any, in the earlier progress of the disease, and that rather of the nature of uneasiness in some portion of the tube. As the disease progresses there will be severe local burning or lancinating pain, particularly after meals. If the disease is high up, there may be pain between the shoulders, along the neck, and even in the head, with radiating pains toward either shoulder and along the arm ; if low down, there may be intense cardialgia and even cardiac spasm. If the trachea or larynx is displaced or compressed, there will be dyspnœa ; and if the recurrent laryngeal nerve is compressed, there will be dysphonia or aphonia. Perforation of the larynx will be indicated by cough, expectoration, hoarseness, or loss of voice ; of the trachea, by paroxysmal cough, dyspnœa, or suffocative spasm ; of the lungs, by acute pneumonitis, especially if food escape ; of the pleura, by pneumothorax ; of the mediastinum, by emphysema ; of the pericardium, by pericarditis ; of the large vessels, by hemorrhage. Perforation of the aorta or pulmonary artery is often followed by sudden death from hemorrhage ; and of the lungs, by rapid death from pneumonia.

Diagnosis.—This is based on the symptoms enumerated, and the ultimate evidence of cachexia. Auscultation and palpation with the sound will detect the locality of the disease. Laryngoscopic inspection and digital palpation is sufficient when the entrance into the œsophagus is involved. At an early stage diagnosis is difficult, and often to be based solely on negative phenomena. At a later stage it is easy, especially when cancerous fragments are regurgitated or vomited. In some instances a tumor can be felt externally. A tumor of this kind has been reported to have turned out to be the head of the pancreas pushed upward.¹ The disease is liable to be confounded with œsophagitis, stricture from vicious cicatrization,

¹ Reid : N. Y. Med. Jour., Oct., 1877, p. 404.

diverticulum, compression from thyroïdal tumors, abscess, enlarged lymphatic glands, aneurism of the aorta, cardiac and pulmonary diseases, mediastinal tumors. It may likewise be confounded with other morbid œsophageal growths, such as myxomas and fibromas.

Prognosis.—This is unfavorable. The disease is comparatively slow in progress at first, and usually exists for from one to two years, or somewhat longer. Death usually ensues from inanition or marasmus, but not infrequently from perforation into adjoining organs, and sometimes from secondary inflammation of other vital organs, as the brain or lungs.

Treatment.—Apart from the constitutional measures indicated in carcinoma generally, and in chronic diseases of the œsophagus, there is little to be done. The cautious use of the stomach-tube to convey nourishment into the stomach is allowable only during the early stage of the disease. When ulceration has ensued it is dangerous, for fear of perforating the tube and bringing on almost immediate death from injury to intrathoracic tissues. When deglutition is no longer practicable, nutritious enemata are necessary to sustain the patient, and alcoholic stimulants may be added to them. It is a good practice to accustom the patient to being fed by the bowel by administering an occasional nutritive enema long before it becomes absolutely necessary to do so. Narcotics to relieve pain are best administered hypodermically, so as not to irritate the rectum more than is unavoidable.

WOUNDS AND INJURIES OF THE ŒSOPHAGUS.

Wounds of the œsophagus sometimes occur in association with wounds and other injuries of the larynx and trachea. Wounds limited to the œsophagus are rare, and are said to be usually the result of small firearms or punctures by the point of a knife, dagger, or sword. A close investigation of this point¹ has only led to the collection of four cases of incised wounds of the œsophagus, reported by Boyer, Larrey, and Dupuytren, respectively. A case of recovery, however, after a suicidal incised wound has been recorded by Luders.² Suici-

¹ Hourteloup, *Plaies du larynx, de la trachée, et de l'œsophage*, Paris, 1869, p. 19.

² *Am. Jour. Med. Sci.*, Vol. VII., p. 248.

dal wounds are usually fatal by hemorrhage from division of the great vessels of the neck.

Attempts at exploration of the Œsophagus with the sound have been followed by laceration, as has also the incautious use of improper instruments in attempts at the extraction of foreign bodies. The Œsophagus has been wounded occasionally in making the incision for tracheotomy; and a case is on record in which the tracheotomy tube was actually passed into the Œsophagus. A case has been recorded in which an insane patient introduced the handle of a little explosive toy into the Œsophagus; it lacerated the organ a little below the pharynx, and then fractured the fourth rib at the vertebral articulation.¹ Lacerated wounds of the Œsophagus are sometimes produced during an act of vomiting. In most of these cases on record the rupture has occurred in persons of intemperate habits,² and usually in subjects of disease of the Œsophagus. Cancer, ulceration, and atrophy predispose to rupture. The injury is almost necessarily fatal, for there is no external outlet for the blood and ingesta which escape from the Œsophagus.

Rupture is not confined, however, to the diseased Œsophagus; it may take place, exceptionally, in the healthy organ.³

The rupture usually occurs just above the diaphragm, and the contents may penetrate the pleura or remain in the mediastinum. It is usually longitudinal, but sometimes transverse, and varies in size from a small perforation to the extent of as much as three inches. The mucous coat of the Œsophagus is sometimes wounded to a greater extent than the muscular and fibrous coats. In an instance recorded by Dr. C. J. B. Williams⁴ the diaphragm was also ruptured in the act of vomiting.

Symptoms.—These are sudden vomiting, first of part of contents of stomach, if during a meal or shortly after it; acute pain, with the sense of something giving way inside; vomiting

¹ Guise, see Hourteloup, *op. cit.*, p. 24.

² For examples, see Charles, *Dub. Jour. Med. Sci.*, Nov., 1870, p. 311; citing, in addition, Dryden, *Medical Commentaries*, Decade 2, 1788, Vol. II., and giving many references on the subject of rupture.

³ For examples, see Boerhaave, *Van Swieten's Commentaries*, Edinburgh, 1786, Vol. II., p. 102; Oppolzer, *Vorlesungen über specielle Pathologie und Therapie*, Erlangen, 1872, Bd. 2, Lief. 1, p. 151.

⁴ *Trans. Path. Soc., London*, Vol. I., p. 151.

of blood, great distress and anxiety, emphysema into the neck, and rapid collapse from shock. There is usually some earlier history of dyspepsia, dysphagia, or disease of the œsophagus.

Diagnosis.—This is based on the history of the case and the suddenness and general character of the symptoms.

Prognosis.—This is unfavorable in rupture. The subjects of rupture die within a few hours (three or four to twelve or eighteen), in a state of profound collapse. In cases of external wounds it is favorable in so far as the accompanying lesions are not necessarily fatal.

Treatment.—The treatment of wounds of the œsophagus must be conducted on general principles, adapted to the exigencies of the case. In traumatic cases it is sometimes requisite to keep the external opening patulous, in order to permit the injection of food into the stomach. As soon as there is evidence that cicatrization is proceeding favorably, food is to be cautiously administered by the mouth, care being taken with regard to its quantity and quality. If the food escape by the wound, nourishment must be maintained by the rectum, and thirst allayed by moistening the lips, tongue, and gums from time to time, by bits of ice in the mouth, and by periodical sponging of the body. Great precaution is necessary that the cicatrix be not ruptured in the return to an ordinary diet.

Most authors are opposed to the use of sutures in cases of wounds of the œsophagus; but, as is urged by Prof. Gross, there is probably too much temerity shown in this respect; such wounds would seem to call for treatment similar to that adopted for wounds of the intestines, and this surgeon therefore recommends that they be united by the interrupted suture, and both ends be cut close to the knot, in the expectation that the thread would find its way into the interior of the tube and be discharged with the contents of the bowel.

There is no evidence to show that wounds of the œsophagus are liable to be followed by permanent constriction of the tube. Fistulous openings sometimes remain after the healing of a wound in the œsophagus. They are treated by the local application of nitrate of silver or sulphate of copper, and are said to heal promptly. It is not generally considered advisable to make an attempt to close them by plastic operation, as is

practised in cases of fistules communicating with the larynx or trachea.

The treatment of rupture resolves itself into maintaining complete rest of the part and the body generally, the external use of ice, the hypodermic use of anodynes, and the administration of stimulus and food by enema.

PERFORATION OF THE ŒSOPHAGUS.

Perforation of the œsophagus occurs under a number of morbid conditions, alluded to elsewhere. It may take place from within or from without. From within, by retention of sharp and pointed foreign bodies, as fragments of bone, plates for false teeth, and the like ; by the corrosive action of acids and alkalies that have been swallowed ; by ulceration, abscess, carcinoma, etc. From without it may occur from peri-œsophageal abscess, degeneration of bronchial and other glands, caries of the vertebra, aneurism of the aorta, and other intra-thoracic diseases, atrophy from pressure preceding the perforation. Perforation is most frequent in the thoracic portion of the œsophagus. In a case reported by Ruehle, resulting from aortic aneurism, it was two inches below the cricoid cartilage.¹ It may be single or multiple, slit-like, circular, or irregular. The opening is usually more or less funnel-shaped, the base being in the direction from which the ulcerative action commenced. A perforation having occurred, air, blood, products of secretion, and other matters are likely to pass from the œsophagus into the surrounding connective tissue, the mediastinum, trachea, primitive bronchi, pleura, lungs, or pericardium, as the case may be. On the other hand, air, mucus, and pus may pass into the œsophagus from the air-passages, or blood from a ruptured aneurism. If the perforation is single and small, there may be no escape of contents at all.

Symptoms.—These are pain and a sudden sensation of something giving way in the region of the œsophagus ; followed by vomiting of pus, blood, or the contents of a tuberculous cavity when the perforation is from without ; cough, expectoration of contents of œsophagus or stomach, dyspnœa, suffocation, intense pain, emphysema, collapse, as the case may be when it is from within.

¹ Die Kehlkopfkrankheiten, Berlin, 1861, p. 155.

Diagnosis.—This is based on the symptoms mentioned, following a history of chronic disease of the œsophagus, or of the intra-thoracic viscera; in addition to which there may be cessation of previous dysphagia, in which case there will no longer be any impediment to the passage of the œsophageal sound if any one is rash enough to use it.

Prognosis.—This depends on the nature of the pre-existing disease, and the size and seat of the perforation, the latter points being beyond accurate determination. It is usually unfavorable, death taking place, if not instantaneous or delayed but a few hours, at a period varying from a few days to a few months. Small perforations sometimes cicatrize. In some instances where there is but one slight discharge of matters from the œsophagus, a peri-œsophageal abscess is formed which discharges externally, leaving a fistula, or internally into the œsophagus, with recovery in either instance.

Treatment.—This consists in absolute avoidance of swallowing, and the administration of food and stimulants by the rectum. The use of the stomach-tube is not to be recommended, for fear of engaging its extremity in the perforation and adding to the injury. If the patient survive the immediate effects and give evidence of general improvement, cautious attempts are to be made in resuming nutrition by the mouth.

FOREIGN BODIES IN THE PHARYNX AND ŒSOPHAGUS.

Foreign bodies may lodge in the lower portion of the pharynx and in the œsophagus, and produce sudden death from asphyxia in a few minutes, by blocking up the orifice of the larynx, depressing the epiglottis, or compressing the trachea. Death from this accident has sometimes been mistaken for death from cerebral apoplexy. Spiculated bodies are apt to catch in the mucous membrane during their descent along the œsophagus, and may be impacted at any portion of its course. The most frequent foreign body to get into the œsophagus is too large a bolus of food—as too big a morsel of meat, a piece of bone, etc.; but not infrequently is some extraneous body altogether—a coin, fish-hook, small fish,¹ pin, tack, toy, etc.

¹ For examples see *Med. Times and Gaz.*, 1863, p. 333; *Arland: Union méd.*, 1863, p. 568; *Tarneau: Gaz. hôp.*, 1863, p. 155; *Duplony: Idem.*, p. 238; *Phélippeaux: Arch. klin. Chir.*, 8, p. 481; *Lancet*, Sept. 25, 1869; *McLaren: Lancet*, July 19, 1873, p. 103.

The accident sometimes occurs in cases of stricture of the œsophagus from want of care in swallowing morsels of food ; but may also occur from putting other things into the mouth. As a matter of course such cases are the more serious on account of the stricture.¹ Animal and human parasites sometimes lodge in the œsophagus as foreign bodies. A case of acute delirium from this cause has been reported.² Since the use of false teeth has become common, the plate is sometimes swallowed during sleep and becomes wedged in the œsophagus or pharynx. A similar accident may occur if false teeth be not removed before the administration of anæsthetics, or protracted inspection of the throat. Fragments of carious nasal bone may become swallowed and impacted in the tube.³

Porter relates a case⁴ of asphyxia taking place in the street while the individual was eating, in which it was found on dissection that there was a deficiency of the palate which had been habitually kept stuffed with rags of lint. These had gotten loose and become entangled in the morsel the patient was about to swallow, which was stopped immediately over the epiglottis, and thus kept it closely shut down.

The foreign body usually lodges in the lower portion of the pharynx or the upper portion of the œsophagus, directly behind the cricoid cartilage ; but it is sometimes much lower down, opposite the bifurcation of the trachea, in the region of the diaphragm, or just above the cardiac orifice of the stomach. Dr. Harrison Allen, of Philadelphia, who attaches great importance to the pathological interest centred in the point where the tracheal curve of the œsophagus is crossed by the left primitive bronchus, believes, as the result of his researches, that this is a frequent point of obstruction by foreign bodies.⁵ A not infrequent place of lodgment is in the pyriform sinus formed by the inner wall of the wing of the thyroid cartilage and the outer wall of the quadrangular membrane of the larynx.

Symptoms.—These vary with the nature of the foreign substance and the position it occupies. A smooth and small body

¹ Menzel : Arch. klin. Chir., 1872, XIII., p. 678 ; Brit. Med. Jour., Aug. 31, 1872, p. 242.

² Laurent : Ann. Méd. Psych., Sept., 1867.

³ For example see Langenbeck : Memorabilien, 1877, H. 1 ; N. Y. Med. Jour., July, 1877, p. 97.

⁴ On the Larynx and Trachea, London, 1837, p. 224.

⁵ Phila. Med. Times, Oct. 13, 1877, p. 2.

may give rise to very slight symptoms—merely, perhaps, the consciousness of having swallowed it, and a vague sense of its presence in some defined or undefined portion of the Œsophagus. A larger body sometimes provokes to gagging and vomiting, and is often detached in the act. A pin will give rise to a sensation of pricking, and sometimes to slight hemorrhage. Large bodies prevent further swallowing by their size, and sharp ones by the pain which the effort produces. The sensations of the patient are not always reliable guides to the position of the foreign body. If the body is large or irregular, or presses upon the trachea, or sticks by a point to some portion of the larynx, there will be more or less pain in swallowing or in breathing, likely to be increased on pressure. Cough, spasm of the glottis, hoarseness, aphonia, and asphyxia may supervene; or severe inflammatory manifestations, sometimes of very serious augury. Respiration may be impeded mechanically if the foreign body press upon the air-passage, inspiration being usually affected to a greater extent than the expiratory act.

Diagnosis.—The history of the case and the occurrence of the symptoms mentioned above will usually indicate the diagnosis. Direct inspection is sometimes sufficient to detect a foreign body in the pharynx, unless very low down or hidden in a laryngo-pharyngeal sinus, in which case it may be seen on laryngoscopic inspection. Sometimes there may be laryngoscopic evidence, in mechanical injury to the posterior surface of the larynx, that a foreign body has passed into the Œsophagus. In other cases, if the foreign body has been a rough or pointed substance, as a tack for instance, its presence may be detected by the appearance of pus at the Œsophageal entrance. If the foreign body cannot be seen, the only certainty of diagnosis rests in exploration with the finger or sound. One of the best sounds for detecting a hard foreign body is Langenbeck's sound, a whalebone rod shod with a smooth, polished metallic probe-point or knob. In some cases the Œsophagus is spasmodically contracted above the foreign body, rendering access to it difficult. It is sometimes similarly contracted below the foreign body. Large foreign bodies which remain in the upper part of the Œsophagus pressing on the cricoid cartilage, or on the trachea, sometimes give external evidence of their presence by distending the soft parts of the neck. In cases in which fish-

bones, needles and pins, and the like are swallowed, and which often lodge in the pyramidal sinus, care must be taken not to be misled by the tense pharyngo-epiglottic ligament, which gives the untrained finger much the sensation of a firm and slender foreign body. This mistake has been made by myself, and doubtless by many others. Under a misapprehension of this kind the forceps may be employed to pull out normal tissues. A laryngoscopic inspection will usually set any doubt at rest; and when this cannot be made, examination of both sides will determine whether the sensation imparted to the finger is that from a foreign body, or from a normal fold of tensely stretched tissue.

Prognosis.—This depends upon the practicability of removal of the body without inflicting irreparable injury to the parts, and upon the amount of injury already sustained. If a foreign body is not removed from the œsophagus it may give rise to inflammation and abscess, and produce ulceration of the tissues in front of it. Death may ensue from the abscess produced in this way.¹ Foreign bodies sometimes make their way to the exterior in this manner, and may thus give origin to a fistule. Or the foreign body may ulcerate through the anterior part of the tube and escape into the trachea, producing death from suffocation or from inflammation of the air-passage; or it may result in the formation of a tracheo-œsophageal fistule, and thus produce irreparable mischief.

A singular case of this kind came under my notice some years since. I was called in consultation to a neighboring city to examine a man with chronic hoarseness of several months' standing. The story was, that about a year, or rather more, previously, the patient had swallowed, during his sleep, a gold plate to which a false tooth was attached, and that the physician called in attendance felt the foreign body with his finger, but, failing to extract it, pushed it forcibly into the stomach. A few months later, I was again sent for on account of a new set of symptoms. The patient was feeble and bedridden, unable to eat or drink, every attempt at drinking being followed by ejection of the fluid in a paroxysm of spasmodic cough. Laryngoscopic inspection did not reveal anything more than the general inflammatory condition recognized at the previous interview, except that there was a profuse secretion of pus. The cough and ejection did not follow immediately upon the act of swallowing, but a few moments after, as the fluid passed down the œsophagus. An opinion was therefore given that a fistulous connection existed between the œsophagus and trachea, produced by chronic inflammation following a wound made by a sharp edge of the plate, in

¹ For example see Vandewarker, N. Y. Med. Jour., April, 1871, p. 453.

the effort at pushing it into the stomach. A request to be permitted to pass the stomach-tube was not acceded to, inasmuch as it had been passed into the stomach a short time before, by the physicians in attendance, without encountering any obstruction, though pus was brought up on its extremity, the passage of the instrument being painful to the patient. The patient was nourished for nineteen days by the rectum, and was doing well, being again able to swallow with very little difficulty, when he one day ate a number of apples that had been brought into his room, was seized with cholera morbus, and died. A post-mortem examination was made, and the gold plate was found lodged in the œsophagus opposite the bifurcation of the trachea, with a communicating opening between the two tubes.

The causes of death from retention of foreign body in the œsophagus are various. Thus, it may excite inflammation and caries of the vertebræ,¹ with death from perforation of the trachea, or secondary disease of lung and other organs; or perforation of the aorta,² ulceration of the pericardium with fatal pericarditis.³

Treatment.—Prompt dislodgement is desirable in all cases of foreign body in the œsophagus. The method will vary with the nature of the body, the appliances at hand, and the emergency or peculiarity of the case. Emesis by means of the hypodermic injection of apomorphia (one-tenth grain for the adult) is sometimes employed in suitable cases, especially in children with whom the management of instruments is difficult. If the foreign body can be seen or felt, it can often be removed by the finger, or should this fail, by means of straight or slightly curved forceps, or blunt hooks. If lodged in one of the pyramidal sinuses, it can be detected with the laryngoscope and removed with the laryngeal forceps, or be dislodged by a blunt hook, and expectorated. A long forefinger will often be able to hook out a foreign body from this position, if the tongue be kept depressed by the middle finger so as not to force the forefinger up out of the pharynx. If the foreign body be within the œsophagus, its position should be as well defined as possible by means of the probe or sound, which it is well to have graduated in fractions of an inch for this purpose;

¹ For examples see Galais, *Gaz. hôp.*, 1864, No. 120; *Arch. klin. Chir.*, 8, 482; Steven, *Brit. Med. Jour.*, Dec. 10, 1870, p. 629.

² For examples see Fabrice (*Würzburger med. Ztsch.*, 1864, p. 110); *Arch. klin. Chir.*, 8, 483; *N. Y. Med. Jour.*, Dec. 10, 1869, p. 335; Aschenborn, *Berlin. klin. Woch.*, Dec. 10, 1877; *Med. Times and Gaz.*, Jan. 5, 1878.

³ For example see Conant: a case of Clark's, *Am. Med. Times*, 1864, p. 209.

and then forceps, snare, hook, or other mode of extraction be attempted, the choice of instruments depending a good deal on the known or supposed character of the foreign body. Before any instrument is introduced for this purpose, it is well to let the patient swallow a little oil if he can, or if this is impracticable, to pour some oil into the œsophagus as recommended by Langenbeck. Substances not far from the entrance may be seized with special forceps, such as the œsophageal forceps of Bond (Fig. 79) and Burge (Fig. 80), which are well bevelled at their edges, so as to prevent injury to the mucous membrane.

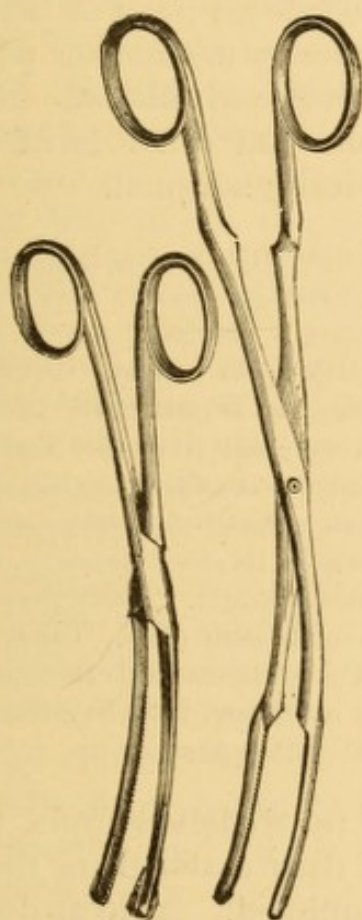


FIG. 79.—Bond's Œsophageal Forceps.




FIG. 80.—Burge's Œsophageal Forceps.

Forceps made in links are sometimes used.¹ Flexible cannulated forceps, like those of Mr. Durham (see article on Morbid Growths of the Larynx), may be available in some instances. These instruments being warmed to avoid spasm, and well oiled to glide easily, are introduced in the first instance as searchers, and when the foreign body is reached, are expanded over

¹ For illustration see *Gaz. hebdomadaire*, 1869, No. 10, p. 154.

it, the effort being made to seize it by one of its small extremities, so as to render its extraction easier and less injurious.

Blunt hooks of various patterns, some of which are exposed only when past the foreign body, are often used, but are apt to injure the mucous membrane.

One of the best of these is the coin-catcher of Graefe, a double conical hook, swiveled to the conducting rod, with the larger and projecting portions upwards. This is intended to be pushed beyond the obstructing object, and then drawn back, when one of the projecting wings will catch in the foreign body and bring it out with it. As the foreign body is usually of larger size than the swivel, the mucous membrane of the œsophagus is protected from injury in the withdrawal of the instrument. For large pieces of bone and other hard substances, this instrument is often admirably adapted.

This instrument is liable to become wedged between the foreign body and the mucous membrane, and thus become immovably fixed, an accident that will call into play the most ingenious resources of the surgeon. Adelman was compelled in one instance to leave his instrument for two days in his patient's œsophagus, whence it was removed on the third day by passing a wide gum-elastic tube over the handle of the coin-catcher so as to push the ring aside from the bone; and Langenbeck, who mentions this case, reports an instance in which the coin-catcher became impacted in an ineffectual effort to remove a shawl-pin, and in which it took him half an hour to disengage the instrument.¹ In some instances, too, it will slip back past the foreign body without withdrawing it. The device of Dr. F. A. Stanford, of Columbus, Ga.,² is a good one in such cases. Langenbeck states that when the extrication of the instrument in withdrawing a foreign body is impeded by the posterior wall of the cricoid cartilage, it can be released by pushing the instrument against the posterior wall of the pharynx.

Bags of silk and gauze, attached to whalebone rods, to be pushed beyond the foreign body and then catch it as the instrument is withdrawn, are often employed. A great deal of ingenuity has been displayed in the invention of instruments for the purpose of extracting foreign bodies from the œsophagus, a mere description of which would occupy many pages.

An impacted shoulder-blade of a rabbit, which Mr. Richard Torrance found impossible to dislodge with forceps, was removed by the following ingenious contrivance:³ A few lead pellets were firmly secured at the distal end by the

¹ London Medical Record, Feb. 15, 1878, p. 50.

² N. Y. Med. Jour., Oct., 1876, p. 368, illustrated.

³ Brit. Med. Jour., June 19, 1875, p. 810.

ordinary suture wire. The patient being unable to swallow, the pellets enabled each wire to find its way down the canal, the meshes of the whole becoming entangled with the bone, probably in different parts; and by pulling two or three of the wires at the proximal end, varying them now and again, the bone was released from its position.

One of the very simplest and best instruments for removal of foreign bodies from the œsophagus is the old French horse-hair snare and probang (Fig. 81), which is pushed into the stomach, the sponge on the end being oiled before introduction. The button at the end of the handle is then pulled out of the tube, and with it the rod to which the sponge is attached. This makes a circular snare of the horse-hair as seen in the lower drawing, in the meshes of which the body is caught and thus dragged into the mouth. When the foreign body arrives in the pharynx, its extraction can be assisted by a disengaged forefinger passed into the mouth. The horse-hairs are easily ruptured, but they can be very readily renewed wherever there is a horse, and their adjustment requires little skill.

When the body is of a nature such as the gold plate in the case narrated, the proper operation would be to bend it up with a strong pair of forceps and then to extract it. Had such a procedure been instituted in that case, the man's life would not have been sacrificed.

When the foreign substance is susceptible of digestion, and cannot be removed by instruments, it may safely be pushed down into the stomach by the œsophageal bougie or by Petit's sponge-probang—a stout whale-bone rod armed with a piece of moistened sponge. Even when not digestible, if of such a form that there is no danger of wounding the mucous membrane, or of its becoming impacted in the intestinal tract, it may be pushed down, for cases are numerous in which coins,



FIG. 81.—Horseshair snare and probang for the extraction of foreign bodies from the œsophagus.

false plates, and other substances, even a key and safety-pin,¹ and a fork² have traversed the intestinal tract and been discharged from the rectum. A copper coin, however, pushed into the stomach, may possibly excite fatal enteritis.³ A body must be pushed down with great care, especially if it have any sharp corners, otherwise serious injury may be produced. Prof. Stromeyer mentions a fatal instance in which the pleura was penetrated. A similar case is reported by Thomas Green.⁴ Even smooth bodies, such as morsels of food, must be pushed down cautiously, lest injury be done the mucous membrane, as is likely to be the result if force is exerted to push the body through and beyond a constriction just beneath it.

Great injury is sometimes unavoidably inflicted on the œsophagus in the withdrawal of foreign bodies of irregular form, such as bits of bone, plates or false teeth, and the like. These injuries may lead directly or indirectly to inflammation, ulceration, and perforation of the œsophagus. Perforation is liable to lead to emphysema of the throat and neck from accumulation of swallowed air; and this may terminate fatally by suffocation, or by putrefaction of the connective tissue. Should the trachea be penetrated, the case is additionally serious.

A number of cases have been recorded of long retention of very irregular bodies eventually extracted;⁵ and smooth bodies are sometimes similarly retained for months.⁶

Foreign bodies sometimes remain for a number of years in the pharynx and œsophagus, and cause comparatively little suffering. They are sometimes discharged spontaneously; sometimes, as in the case of needles and pins, they work their way to the surface, and to any part of the surface, in fact; and sometimes they are dislodged, and can be extracted by means of the forceps or snare. It is probable that they become encysted in some cases, and in others give rise to abscesses, with the contents of which they are discharged.

¹ Packard: Phila. Med. Times, April 15, 1872, p. 267.

² Adelmann: Congress of German Surgeons, Berlin, 1872, The Medical Record, New York, June 1, 1872, p. 236.

³ For example see Lee: St. George's Hospital Reports, 1869, p. 219.

⁴ Brit. Med. Jour., Dec. 17, 1870, p. 650.

⁵ For example see Voss: Am. Med. Times, 1864, p. 209.

⁶ For example see Borelli (Gazetta medica, Stata Sardi, 1864, No. 18): Arch. klin. Chir., 8, p. 482.

A case of transit of foreign body came under my notice some years ago, in the person of a very old man, who in his youth had swallowed two pins. The old-fashioned pins, with the twisted heads, could be distinctly felt under the skin over one of the man's shoulders, where they had remained for more than thirty years, the individual declining to have them cut down upon and removed. They went into his coffin with him.

Prof. Stromeyer mentions a case in which a needle had been swallowed, the passage of which he followed for ten days into the stomach and through the left lung, where it produced bloody expectoration. These needles pass likewise into other organs, and produce inflammation. Sometimes a bundle of needles is swallowed with suicidal intent, and produces death after a long series of years.

A curious case is narrated¹ in which an insane woman swallowed a fork with the expectation of dying under the operation which would have to be performed for its removal. An abscess formed in the abdominal walls, from which the fork was removed, and after this the patient recovered. A case is narrated, too, in which a fork made its way from the stomach to the thigh.²

When the foreign body is firmly lodged, and the symptoms of distress or danger to life are severe, the operation of pharyngotomy or of œsophagotomy is called for, and offers a fair prospect of success. Several very satisfactory cases of this kind are on record.

In instances where extraction through the mouth is impossible, and where the operation of œsophagotomy is contra-indicated, the case must be treated on general principles, or expectantly. Rest of body, nourishment by enema, tonics by enema or hypodermically, would constitute the general plan of management. Should an abscess form and point externally, it should be early cut down upon and opened.

Some individuals are subject to a recurrence of the lodgement of particles of food in the pharynx or œsophagus, from liability to spasm of the constrictor muscles of the pharynx or of the circular fibres of the œsophagus. The swallowing of a bolus on top of the arrested morsel, or of a copious draught of water, usually suffices to force the body down. If this does not answer, the services of a surgeon are required to accomplish the purpose with the probang.

A recurrence of the accident may be sometimes avoided by

¹ (Mediz. Jahrb., 1867, Vol. I.) Gaz. méd. Strasbourg. 1868. p. 20.

² Tellier (Journ. de connaissances méd.-chir.): Boston Med. and Surg. Jour., Aug. 1, 1872, p. 90.

the repeated passage of the œsophageal bougie, which obtunds the sensibilities of the parts, and thus renders them less liable to spasm. In some instances of this kind the frequent recurrence of the paroxysm indicates the formation of an organic stricture, and if there be reason to believe that such is the case, the passage of the sound is the more strongly indicated.

FANCIED BODIES IN THE PHARYNX AND ŒSOPHAGUS.

Hysterical patients often fancy that they have a foreign body in the throat. This fancy is sometimes independent of any association with hysteria. The parts are normal on inspection, but the patient cannot be dissuaded from the idea of the presence of a foreign body. Sometimes this condition is attended with an unwillingness, or, perhaps, an inability to swallow solid nutriment, but not from any paralysis of the constrictor muscles of the pharynx, for these contract readily on titillation. Sometimes, too, there is a vague dread of suffocation. Occasionally there is a history of a foreign body which has probably been expelled. The position occupied by the fancied body often changes. At one interview it will be in the œsophagus; at another, at the upper part of the pharynx, and so on. Sometimes the sensitive point will be changed by the swallowing of a glass of water, or a solid morsel, or by the passage of the œsophageal sound. These changes of position are indicative of the true nature of the case.

Occasionally a small fissure or ulcer in the pharynx will be found to be the source of trouble, especially in those instances in which the sensation of a foreign body is increased by swallowing. In other cases the affection is dependent upon some disturbance of the nervous, digestive, or genital system. Other cases must be regarded as pure neuralgias; and there is no doubt that some patients suffer a good deal under such circumstances. The affection is often associated with anæmia and debility.

These cases are sometimes of long standing, and very obdurate to treatment.

Treatment.—The internal administration of iron, quinia, strychnia, or arsenic, separately or in combination, with attention to any specially deranged functions, will form the most appropriate general treatment, while the local sensibilities of

the parts may often be materially modified, and sometimes promptly subdued by the application of solutions of nitrate of silver, or some substitute for it. A similar effect will sometimes follow the use of the electric current, with the positive pole in contact with the parts.

Cases dependent upon actual ulceration are usually promptly relieved by a few local applications of nitrate of silver or a mineral acid—sometimes by a single application.

ŒSOPHAGOTOMY.

Œsophagotomy is the general term applied to all operations for reaching the interior of the œsophagus or the pharynx from an external incision. An opening into the pharynx constitutes pharyngotomy, but it is usual to include the two operations under one head, as their line of demarcation is not very distinct, anatomically or surgically. Thirty or more of these operations are on record.

The indications for the operation occur in cases of foreign bodies in the tube resisting removal by other means ; in cases of constriction of the tube from organic stricture, or the pressure of a tumor on the outside, interfering with nourishment by the mouth. It has also been performed in dysphagia from laryngeal ulceration, and in a case of this kind performed by Dr. John Watson, of New York, the patient was nourished for three months, when he died of pneumonia. The operation has been suggested also for excision of a diverticulum or pouch of the pharynx or œsophagus, and also for gaining access to abscesses in the tube threatening to rupture into the trachea.

Guattani's method of operating as described by Langenbeck,¹ who prefers it to all others, is as follows:

The incision through the integuments begins at the middle of the thyroid cartilage and descends on the left side of the neck along the anterior edge of the sterno-mastoid muscle, and about two inches above the manubrium of the sternum. The superficial cervical fascia having been divided, and the sterno-mastoid muscle pulled outward and backward by sharp double hooks, the common carotid artery becomes visible through the middle cervical fascia covering it. This fascia is divided in the direction of the long axis of the wound, and drawn outward and backward by strong hooks, so that the carotid artery, without being touched by the instruments, disappears from the field of operation. The larynx is now

¹ (Berlin. klin. Woch., Dec. 24, 1877) ; The London Medical Record, March 15, 1878, p. 99.

drawn to the right by sharp hooks, and the deep cervical fascia is divided along the outer edge of the sterno-thyroid muscle. If this muscle be drawn toward the middle line, the œsophagus becomes visible. Langenbeck directs attention to one point he had not found noticed by others, namely, a tumefaction of the thyroid gland from stasis of venous blood, which always attends the retention for several days of a large foreign body at the level of the cricoid cartilage, and which produces difficulty of respiration from pressure in the larynx. The swollen gland lies over the œsophagus in such a way as to cover it completely. The fascia enveloping the thyroid gland must be divided in order that the gland may be raised from the œsophagus. In one of his cases the swollen gland completely covered the œsophagus on the left, and was adherent to the adjacent parts by thin layers of exudation matter; and it was found necessary to divide the deep fascia along the left border of the gland, and strip it from the œsophagus.

The œsophagus being opened, the withdrawal of a foreign body can usually be effected with forceps, and sometimes with the fingers. In some cases other instruments are necessary to detach it when firmly impacted, and unless due care be exercised the mucous membrane may be needlessly injured. In other cases the foreign body may pass down into the stomach by action of the œsophageal muscles after the constriction has been overcome by the incision.¹

After clearance of the tube and arrest of hemorrhage, Prof. Gross, of Philadelphia, recommends approximating the edges of the œsophageal wound by several points of the interrupted suture, made with very fine but strong silk, the ends being cut off close to the knot to afford the threads an opportunity of dropping ultimately into the interior of the tube.

The external wound is carefully dressed, and the patient put to rest, food being administered for the first few days by the rectum, and then by the stomach-tube for a while longer if necessary.

The operation of œsophagotomy should not be unnecessarily delayed when once determined upon, on account of the risk of permanent or irreparable injury from inflammation, suppuration, and gangrene; and on account of the propriety of affording nourishment by the natural passage as soon as possible.

When the foreign body cannot be felt from the outside, a metallic sound should be passed into the œsophagus, and pressed against the external tissues so as to act as a guide for the place of incision, and to insure penetration into the interior

¹ For example see Langenbeck, loc. cit.

of the tube. Even when the foreign body lies below the region of the neck affording access to the œsophagus, the operation is justifiable as presenting a better facility for the manipulation of the forceps. If the wound has to be dilated for this purpose, care must be taken not to injure important vessels or nerves. In one of the cases operated on by Dr. Cock¹ there was a permanent alteration of the voice, probably due to some injury inflicted upon the recurrent laryngeal nerve. Langenbeck, however,² does not fear injury of this nerve, as it is drawn to the right with the trachea, except when a large foreign body has pushed the œsophagus far to the left.

A very excellent history of the operation, with a tabular statement of all the cases that the author could find on record at the time, and including two of his own, has been published³ by Dr. David W. Cheever, of Boston. To this the reader is referred for detailed information on this special subject.

A perusal of the cases collected by various authors shows that the operation is not without danger, only nine out of the sixteen operations for removal of a foreign body collected by Guenther⁴ having been reported as successful; a result quite different from that recorded in Dr. Cheever's pamphlet, which includes most of the cases collected by Guenther, but which gives the successful cases as numbering thirteen out of seventeen. In three of the cases in Prof. Guenther's list, in which he could not ascertain the result, success may have followed, as two of them (Bégin, 1832) are so recorded by Dr. Cheever and by Prof. Koenig.⁵ Koenig reports twenty-four cases of œsophagotomy for foreign body, with four deaths and one doubtful; and Langenbeck reports two successful cases of his own, and he says that when it is considered that one of Koenig's five fatal cases is noted as doubtful, and that three of the other four were due to gangrene and perforation of the œsophagus—a result of long detention of the foreign body, the operation may be fairly regarded as attended with a comparatively small amount of danger. Koenig likewise reports six cases of œsophagotomy for stricture, all fatal.⁶

NEUROSES OF THE ŒSOPHAGUS.

Anesthesia, Hyperesthesia, and Neuralgia occur. Their symptoms and diagnosis are obscure, and resemble those of

¹ Guy's Hospl. Rep., 1858, p. 217.

² Loc. cit.

³ Two Cases of Œsophagotomy for the Removal of Foreign Bodies; with a History of the Operation. Boston, 1867.

⁴ Lehre von den blutigen Operationen, Leipzig, 1864, Vol. V., p. 269.

⁵ Pitha and Billroth's Handbuch der allg. und speciellen Chirurgie. Erlangen, 1872, Bd. 3. Abth. Lief. IV., p. 69.

⁶ Op. cit., p. 71.

similar neuroses of the pharynx, with such modifications as are dependent on the anatomical position and relations of the Œsophagus. The treatment is similar to that mentioned in connection with these analagous affections of the pharynx.

Spasm of the Œsophagus. (Cramp of the Œsophagus, Œsophagismus, Spastic or Spasmodic Stricture.)—Spasm may be limited to the Œsophagus or involve the pharynx likewise. It usually occurs in a sudden inability to swallow, or to complete the action of deglutition. This may be transient, or may continue for a number of hours, when the spasm relaxes. Relaxation is sometimes followed by discharge of flatus, and the copious secretion of pale-colored urine. It may recur at irregular intervals, or be more or less distinctly intermittent. In some instances it occurs only in attempts to swallow certain kinds of food. Cold viands sometimes produce cramp when warm and hot food is tolerated. Consciousness of a liability to spasm increases the dysphagia for the time being, or brings it on suddenly when the fact had been forgotten. It is sometimes painless and sometimes painful, and in some instances is associated with partial regurgitation of a mass of air, the *globus hystericus*. When severe there may be spasm of the air-passages, palpitation of the heart, and syncope. It occurs in diseases of the Œsophagus, but is usually a reflex or a deutero-pathic manifestation of gout and rheumatism, disease of the stomach, heart, lungs, and uterus, of the brain and spinal cord, of hysteria, and of hydrophobia. It is sometimes associated with hiccough and other manifestations of nervous origin. Sometimes it occurs without any appreciable cause. It occurs at all ages, and though most frequent in nervous females, is not confined to that sex. The liability to spasm sometimes lasts for years. Sometimes it ceases permanently as suddenly and unexpectedly as it commenced.

The seat of the spasm is referred to different regions which in their totality comprise the entire extent of the Œsophagus. In some patients the apparent locality of the constriction varies on different occasions. When it is habitually low down there is liability to distention of the Œsophagus from retention of food for a number of hours. In some instances food is regurgitated from the Œsophagus after having remained an entire

day, or even longer. When high up the regurgitation may follow the act of deglutition almost immediately.

Diagnosis.—The diagnosis is based on the sudden and intermittent character of the dysphagia, with intervals of complete relief, the symptoms of regurgitation, the existence of some of the diseases mentioned, and on physical exploration with the œsophageal sound. The sound is first arrested at the seat of constriction, and usually passed beyond it, immediately or after a few moments' rest, by sudden relaxation of the spasm. Sometimes the first operation of this kind overcomes the spasm permanently.

Prognosis.—The prognosis depends on the nature of the cause. It is usually favorable.

Treatment.—The passage of the œsophageal bougie will, as mentioned, often relax the spasm at once. If severe, and there be no contra-indication, the administration of an anesthetic may be resorted to. If contra-indicated, hypodermic injection of morphia or belladonna may be made. Relaxing and anodyne enemias are sometimes used. The warm bath may be employed, especially with children. During the intervals between the paroxysms the causal indication must be met on general principles; with the administration of tonics and antispasmodics, bromide of potassium or sodium, camphor, valerian, assa-fœtida, and so on. Counter-irritation along the left side of the spine is also indicated in persistent cases. Locally the passage of a sponge-probang, saturated with a weak solution of nitrate of silver, or iodine, may be repeated at intervals of a few days. Some cases are relieved by painting the pharynx with these solutions. In some instances these remedies may be swallowed in weak solution, or in ointment so as to smear the entire tract of the œsophagus.

Electricity is sometimes applied, the positive electrode at the seat of spasm, the source of the current being a matter of indifference. It is liable to the objections already mentioned.

Paralysis of the Œsophagus.—This may be more or less partial, or complete. It may be associated with paralysis of the muscles of the pharynx, palate, tongue, epiglottis, or larynx; with so-called bulbar paralysis; with general paralysis.

It may depend on muscular atrophy or inter-muscular infiltrations, dilatation and disease in the œsophagus itself. It

may be due to mechanical restraint from external adhesions of the œsophagus to intra-thoracic tumors,¹ to disease or wounds of the nerves distributed to the œsophagus, or of their motor roots, or to pressure from extravasation of blood, purulent accumulations, exostoses, tumors, and the like; to neurasthenia from hemorrhage, or protracted disease; to systemic poisoning in syphilis, diphtheria, and lead-poisoning. It also occurs as a result of sudden shock or fright, and furthermore, from the sudden reaction of cold upon the overheated body.

Symptoms.—Partial paralysis may give rise to no symptoms at all. The earliest symptoms are those of more or less impediment to the prompt passage of the bolus to the stomach, repeated acts of deglutition or the swallowing of additional solids or fluid being necessary. Large masses are swallowed more readily than small ones, and solids more readily than fluids; and there is often a characteristic gurgling attending the passage of fluids down the tube. Swallowing is performed best in the erect posture. These symptoms increase in severity as the paralysis progresses. There is little pain, or none at all. In some cases there is no regurgitation of food; in others it is more or less frequent. There is more or less flow of saliva from the mouth in consequence of the inability to swallow it; and in some cases the losses of material from the blood is so great as to reduce the patient very rapidly.

Diagnosis.—The diagnosis rests upon the presence of the symptoms mentioned. Paralysis of the œsophagus is differentiated from paralysis of the pharynx by the ability to swallow the bolus, which remains arrested in some portion of the tube. Auscultation will determine the locality of the arrest, and likewise an alteration in the usual form of the bolus, which assumes the configuration of an inverted cone, inasmuch as it is subjected to compression at the upper portion only. Otherwise the auscultatory indications are similar to those of dilatation. There is no impediment to the passage of the stomach-tube or œsophageal sound, which may sometimes be freely moved in the calibre of the tube.

Prognosis.—Prognosis is favorable in idiopathic paralysis if the local or special affection to which it is due is curable, and especially so if the paralysis is confined to the œsophagus;

¹ For example see Finny: Dub. Jour. Med. Sci., Oct., 1877.

but the recovery is often slow, even in curable cases. In denteropathic paralysis the prognosis depends upon the nature of the causal disease, and, as a rule, is much less favorable than the former.

Treatment.—This varies with the nature of the cause, which is to be combated accordingly. With regard to the paralysis itself, the use of *ignatia amara* and *strychnia* is indicated, and, as there is difficulty in swallowing, the remedy may be administered hypodermically. If there is only partial paralysis, it is sometimes better to give it internally, in hopes of some local astringent effect on the walls of the œsophagus. Masses that become arrested in the tube should be forced down with the œsophageal sound. In other cases nourishment must be habitually introduced through the stomach-tube, and the use of nutritive enemata be resorted to. Electricity has been employed successfully in some instances, and with the effect of increasing the paralysis in others. As announced by Duchenne, the use of an œsophageal electrode is attended by some danger of unduly exciting the pneumogastric nerve, and thereby inducing syncope.

A case of paralysis of the œsophagus coming on during pregnancy, and recurring during a second pregnancy, occurred under the care of M. Demarquay,¹ in which notable amelioration followed a treatment by electro-puncture.

(SO-CALLED) PROGRESSIVE BULBAR PARALYSIS.

(Glosso-pharyngeal Paralysis, Glosso-laryngeal Paralysis, Glosso-pharyngeal Paralysis, Labio-glosso-laryngeal Paralysis, etc.)

A certain variety of progressive general paralysis, almost inevitably fatal, makes its first appearance as a local involvement of one or more of the muscular factors concerned in the performance of the functions of mastication, deglutition, articulation, and respiration, the nerves chiefly affected being the facial, hypoglossal, spinal accessory, and pneumogastric.

To designate the main regions of the malady in one appellation would require a name as long as bucco-palato-labio-glosso-

¹ Bull. gén. thér., July 30, 1869, p. 82.

pharyngo-laryngeal paralysis. The term "progressive bulbar paralysis," suggested by Wachsmuth, and generally adopted in Germany, indicates the pathological seat of the causal lesion in the medulla oblongata.

Attention was directed to this special affection by Professor Trousseau in 1844; and marked professional notice first prominently called to it by Duchenne (of Boulogne) in 1860,¹ subsequently again (1864) by Trousseau, and by Ollivier; since which time it has formed the theme of many contributions to the medical journals of Europe and America, and has been assigned a prominent position in elaborated treatises on diseases of nervous origin. Duchenne has carefully covered the ground in an elaborate essay upon the structure and morphology of the medulla oblongata.²

The affection has been more frequently observed in males than in females, and, as a rule, in subjects of over fifty years of age. Some observers have never seen it before the age of forty. Two of my own cases, one of which was subjected to treatment, were in individuals less than thirty years of age. Some instances are on record in which the disease, or an affection simulating it to a remarkable degree, began during an access of febrile disorder. Usually, some mental trouble, such as loss of property, of means of support, of members of one's family, or the like, appears to be the exciting cause, or at least the patients make some complaint of the kind. In the case of the youngest subject in which I have seen the affection, the cause appeared to have been over-study for honors at college.

There has not as yet, I believe, been any evidence adduced of hereditary tendency to the disease. Some instances are undoubtedly of syphilitic origin. Excessive tobacco-smoking, inordinate muscular exertion, and unwonted exposure, are also said to be exciting causes. In many cases it is impossible to determine any positive assignable cause.

Pathological observations show this affection to be due to sclerosis or other structural lesion of the medulla oblongata, with atrophy and fatty or tuberculous degeneration of the roots of the nerves distributed to the parts affected by the disease. Sometimes a mere atrophy, a fatty or lardaceous degeneration of the muscular fibres of the parts affected, has been

¹ De l'électrization localisée, etc., 2. ed., Paris, 1861, p. 621.

² Recherches incono-photographiques sur la morphologie et sur la structure intime du bulbe humain, leur application à l'étude anatomo-pathologique de la paralysie glosso-labio-laryngée.—Arch. gén. de méd., May, 1870, p. 539 et seq.

found to exist, though this does not constitute an essential element of the lesion, and is rather due to their inaction.

Symptoms.—The evidence of the disease usually begins with a paralysis of the orbicularis oris, and adjacent muscles, gradually progressing, until finally the patient is unable to pronounce the consonants and vowels requiring the use of the lips, such as *o, w, m, p, b, f, v*, and in a little while is unable to blow or to kiss. As the disease progresses, the tongue becomes involved, and then the palate, the pharynx, the cheeks, and the larynx. Sometimes it begins in the tongue, with failure in the pronunciation of the dentals, etc., *t, d, n, th, ch*, etc., and more or less difficulty in controlling the alimentary bolus. There therefore occurs more or less dysphagia, gradually progressive, and finally complete; nasal speech, and escape of drinks from the nostrils; inability to retain the saliva; and aphonia. In fact, we have the combined symptoms that occur in cases of individual anæsthesia and paralysis of the organs implicated. At a further stage of the affection the respiratory muscles become affected, and the patient cannot cough or take a deep breath; and finally, in some instances, there ensues paralysis of the limbs. Sometimes cerebellar ataxia follows the affection, and this may take place even several months after satisfactory relief from the original affection.¹ The patient gradually sinks a prey to debility consequent upon inanition.

Diagnosis.—The evidence of paralysis in the regions mentioned, the history of the case, and the presence of the symptoms narrated, determine the diagnosis.

Prognosis.—This is always grave, for the disease, as a rule, is fatal. A few cases of recovery or of retrogression,² and several of amelioration, persisting for a long time,³ are on record; and in these it must be inferred that there had been merely a congestion at the roots of the nerves, a hemorrhage, or some other condition antecedent to the stage of degeneration, the tendency to which had been fortunately overcome.

Treatment.—Counter-irritation at the nape of the neck, iodide of potassium or its equivalent internally, hypodermic

¹ Schuetzenberger: Cas de paralysie labio-glosso-pharyngienne suivie d'ataxie cérébelleuse.—Gaz. méd. de Strasbourg, 1868, p. 74.

² La Tribune médicale, 1868, p. 340; Alex. Smith, Med. Times and Gaz., 1871, April 22, p. 464; the author, The Medical Record, N. Y., Vol. IV., p. 291.

³ Hérard: Gaz. Hebd., 1868, p. 182.

injections of strychnia and ergotine, and local faradization of the affected muscles, appear to be the chief remedial agents relied upon for the treatment of this affection; the chief hope being that of retarding the progress of the affection. The continuous current of the battery applied in great strength along the cervical vertebræ, or the entire spinal column, is sometimes of great temporary benefit.

CHAPTER XI.

AFFECTIONS OF THE NASAL PASSAGES.

ACUTE CORYZA.

(Acute Cold in the Head ; Acute Nasal Catarrh ; Acute Rhinitis ; Acute Rhinorrhœa.)

CORYZA is an acute inflammation of the nasal mucous membrane, sometimes confined to one passage, but more frequently affecting both, and often extending into the maxillary sinus, frontal sinus, lachrymal duct, and Eustachian tube, involving one or more of these passages separately, or several or all of them simultaneously.

It is most frequently idiopathic, but is sometimes deuteropathic. Generally sporadic, it is sometimes epidemic under special atmospheric conditions. Sometimes it is due to impetigo or to eczema. It often occurs as one of the early manifestations of measles and other exanthems, typhus fever, and facial erysipelas. Sometimes it is a direct extension of facial erysipelas ; sometimes an extension of catarrhal affections of contiguous mucous surfaces, of the conjunctivæ, pharynx, and even of the larynx. It is likewise one of the initial manifestations of congenital syphilis in the new-born babe.

It is independent of season and diathesis, and occurs at all ages, and in all classes of society.

There is no special remote cause other than ordinary vulnerability of the mucous membranes.

The chief exciting cause of ordinary coryza is sudden exposure to cold when the body is overheated, or exposure to undue heat after it has become chilled. Sometimes it is caused by the inhalation or inspiration of irritating dust, fumes, and vapors, whether by accident or in the pursuit of ordinary avocations.

It is hardly contagious, though sometimes so considered. Various experimenters have placed the secretions of coryza in contact with their own pituitary membranes without reproducing the affection.¹

Some children seem to be subject to catarrh of the nasal passages, chronic in character, from their very birth, so that it may almost be said that they are born with a chronic coryza; and this catarrh often involves the bronchiæ simultaneously, or shortly after. Accessions occur, attended with profuse secretion from the mucous membranes; the nose becomes stopped up, and the patient breathes with the mouth open. There is snoring, but no dyspnœa. The disease is sometimes fatal. Cases have occurred which have led, by their long duration, to arrest in the development of the thorax.

From a case in point reported by Dr. Herman Weber,² and from other data, Fraenkel³ inclines to the opinion that this infantile coryza is due to direct infection from the vaginal secretions during birth.

The syphilitic coryza of children has been incidentally discussed in connection with syphilitic sore throat in infants (p. 128).

The first pathological manifestation of coryza is congestion and tumefaction of the mucous membrane covering the turbinated bones and the septum narium, with arrest of secretion. This is soon followed by more or less copious hypersecretion, the products of which vary in consistence and in constituents at different stages of the affection, being at first serous, then sero-purulent or muco-purulent, and loaded with excess of salines, which sometimes excoriate the tissues. Sometimes fibrin is secreted, and collects in irregular pellets, or concretes in a membranous layer, similar in some gross physical respects to the pseudo-membrane of diphtheria, but different in remote cause and in pathology. This membranous variety is most frequent in the coryza of the new-born infant, and in the coryza accompanying the exanthemata.

Acute coryza usually lasts from four to seven days; occa-

¹ For example, see Friedreich, *Die Krankheiten der Nasenhöhlen*, Virchow's Handbuch. Erlangen, 1858. Bd. V., p. 398.

² *Med.-chir. Trans.*, XLIII., p. 177.

³ *Ziemssen's Cyclopædia*. N. Y., 1876. IV., p. 119.

sionally it is all over in two or three days ; sometimes it continues a fortnight, a month, or even longer ; a fresh attack seeming to supervene upon one which is just about subsiding. In some instances these attacks alternate with intervals of complete subsidence of two or three days' duration. Sometimes one side is attacked after the disease has subsided upon the other ; and there may be a protracted alternation of this kind. The occlusion of the nasal passages by swelling of the mucous membrane is often sudden in both onset and subsidence. Sometimes one side is blocked up for a while, and suddenly becomes permeable, while the other side becomes obstructed. If the patient be lying down, and both sides be affected, the intervascular communications are so numerous and free, that the contained fluids, blood, and serum will gravitate to the lower side, freeing the upper one. This sudden tumefaction of the nasal passage, and its prompt subsidence, as well as the copiousness of the serous discharge, is favored by extensive erectile plexuses of veins, forming a regular cavernous reticulum between the periosteum of the turbinated bones and the mucous membrane overlying them, particularly posteriorly, to which attention has been prominently directed by Koelliker, and by Kohlrausch.¹

In some cases of coryza, tumefaction of the cervical lymphatic glands occurs.

Symptoms.—The general symptoms vary from the merest consciousness of disturbance to conditions of severe local pain, with fever, loss of appetite, derangement of digestion, headache, sleeplessness, and mental and physical debility. The earliest symptoms are sensations of dryness and irritation in the nose, provocative of a disposition to sneeze, by which the uneasy sensation is relieved for the moment. In the course of a few hours undue fulness in the parts is perceptible, with some difficulty in nasal respiration, often amounting to complete obstruction, so as to necessitate the partial opening of the mouth to insure freedom of breathing. The same cause produces obtuseness of smell, and of taste so far as it is dependent on olfaction. The voice acquires the peculiar so-called nasal tone given to it when the nostrils are voluntarily closed in speaking. There is more or less pain in the parts, extending

¹ Mueller's Archiv, 1853, p. 149.

to all the localities involved in the inflammatory process. This pain is often excruciating. If the lachrymal duct is implicated, there will also be sensitiveness in the injected conjunctival mucous membrane on pressure or on exposure to light, sometimes attended with other local optic phenomena. If the inflammation has extended to the Eustachian tube, the pain may be projected to the internal ear, and be attended with abnormal auditory sensations, and more or less dulness of hearing. If it travels down the pharynx, there may be severe sore throat; and if it attacks the upper air-passages, as not unfrequently happens, there will be additional symptoms of catarrhal laryngitis, or of bronchitis, or both. The amount of fever is usually proportionate to the extent of tissue involved. Sometimes the disturbance is not confined to the respiratory tract by any means, but the whole body will feel sore and out of sorts, the joints and limbs responding as to an attack of subacute rheumatism. Cases of unusual severity are often incorrectly termed influenza.

The sensation of fulness or stuffing of the parts is very uncomfortable, and futile efforts to expel matters from the nostrils are made during the early stage of the affection, while the mucous membrane is dry. These efforts become more frequent, and of course more effective, after the establishment of the stage of secretion which follows.

The cause of the dryness of the mucous membrane in the earlier stage of coryza is not well determined. In the healthy state the mucous membrane of the nose, despite its richness in secreting glands, secretes little or no mucus, and often there is not even any exudation of serum. Many individuals have no occasion to use the handkerchief for the removal of nasal secretion, unless it be excited by the inspiration of dust, smoke, or other irritating matters in the atmosphere. The membrane is maintained in a moist condition, less by reason of any secretion, than by absorption of the vapor condensed upon it from the breath of expiration. When the membrane becomes chilled by cold, be this by direct influence, or by influence of the terminal distribution of nerve fibres, the mucous membrane can no longer absorb all this halitus of the breath, and a portion of its moisture accumulates for a while in the tissue, or just beneath it, giving rise to the familiar sense of puffiness or fulness in the parts. After a while these structures become too saturated to take up more fluid, and a process of exosmosis begins by which the watery constituents of the fluids coursing in the tissue are directed towards the surface, and drip from the nostrils, constituting the characteristic discharge of coryza. at first mere water, the exhalation of the moisture in the expired breath. When this exhalation is exhausted, exosmosis continuing, the water is derived from the contents of the blood-vessels, and

then the secretion is found to contain some of the saline constituents of the blood. The saline particles irritate the inflamed mucous membrane, and finally excoriate its surface, as well as the surface of the skin of the nostrils and upper lip in some instances, and keep up a disposition to sneeze, and a necessity for the frequent use of the handkerchief, the mechanical effect of which, as well as the irritating nature of the secretion, inflames the exterior of the nose and the cheeks, the margins of the nostrils and the surface of the lip.

At a later stage of the complaint, viscid mucus appears in the secretion, and finally, more or less pus; and the secretion is thickened, whitish, yellowish, or greenish in color, according to the intensity of the inflammatory process. It varies in quantity up to a number of ounces in the twenty-four hours, and often has a faint, unpleasant odor, which sometimes increases to absolute fetor. Sometimes small clots of coagulated fibrin appear in the secretions. The entire secretion is not always discharged. Portions dessicate into crusts, which are removed by the handkerchief, by the finger-nail, or by hawking and nasal screatus.

Diagnosis.—The diagnosis will rest upon the history of the attack, the character of the discharge, and the presence of more or less of the group of symptoms detailed; confirmed, if need be, by inspection anteriorly and posteriorly, and by palpation. The disease may be confounded with abscess, morbid growths in the nasal passages, diseases of the frontal sinus or of the antrum due to abscess or morbid growth there and discharging into the nasal passage, and to disease of the alveoli of the upper maxilla, discharging in the same manner.

Prognosis.—This is generally favorable. Acute coryza usually terminates by resolution; more rarely by suppuration. Sometimes it declines into a chronic catarrh, though that is a more frequent result of repeated attacks in more or less rapid succession. It is sometimes fatal, however, in children at the breast, on account of its interference with nutrition and respiration; and occasionally, likewise, in the very aged and infirm. It may leave permanent obstruction in the lachrymal duct, the Eustachian tube, or in the passage into the frontal or maxillary sinus, leading to chronic diseases which may eventuate in caries, dropsy, abscess, or morbid growths. Not infrequently coryza seems to be the starting-point for the development of nasal polyps.

Treatment.—Acute coryza can sometimes be promptly sub-

duced if appropriate treatment be instituted within twelve or twenty-four hours of its onset. A moderately large dose of alcohol or of opium (one to three grains), sufficient to excite the stimulant properties of the drug, inducing sleep, but falling short of narcotism, will, in some individuals, often put an end to the affection at once. Other remedies recommended in a similar manner are: carbonate of ammonium (10 grains), chloride of ammonium (20 to 30 grains), solution of acetate of ammonium (a fluid ounce), tincture of belladonna (20 minims), tincture of the chloride of iron (20 minims), tincture and ammoniated tincture of guaiacum (a fluid drachm), an emetic dose of an antimonial. These drugs are best administered on going to bed, just after the feet and legs have been immersed for a few moments in a hot bath made somewhat stimulating by means of a handful or two of ground mustard. The inhalation of chloroform to the induction of anæsthesia, administered after the patient has been put into bed, will often be found adequate to abort a cold by its relaxing influence upon the structures, which are in a state of tension.

Personal experience has proven the value of this remedy in many instances, especially such as were too advanced to promise success in the abortive treatment. The responsibility of this practice must rest upon the physician prescribing it. Chloroform is, in some respects, a dangerous remedy, to be employed in skilful and careful hands only; and therefore it is not to be generally recommended. Such happy effects have followed its use in my own hands in some cases of acute coryza, attended by intense pain and tension in the frontal and maxillary regions, with distressful obstruction to breathing, that an acknowledgment of its value is not to be withheld. These cases would have required larger doses of narcotics to control suffering than it was deemed desirable to prescribe; and the fact was remembered that the administration of chloroform for the relief of pain already existing, is by no means attended with anything like the same danger as when it is given to prevent pain. Statistics of deaths from chloroform show that a fatal result rarely happens when it is judiciously administered for the relief of pain, as in neuralgia, parturition, and operations begun without resort to anæsthesia.

When the cold has existed all day, or for twenty-four consecutive hours, it can rarely be aborted; but it is still often susceptible of being conducted to a very rapid conclusion by inducing a state of diaphoresis. This may be accomplished by the administration of diaphoretic medicines, such as Dover's powder, nitrate of potassium, tartar emetic or wine of antimony, and the like, assisted by the copious deglutition of

warm drinks, which may be slightly medicated with chamomile, sage, eupatorium, hops, or the like. An excellent plan too, is the use of the warm air bath.

This is readily prepared by burning some alcohol, either in a large lamp or in a saucer, under a chair occupied by the patient, whose naked body should be enveloped, from the neck downwards, in a blanket reaching nearly to the floor; the feet being covered with woollen stockings. The warm air, confined to the body, induces copious cutaneous perspiration, and when this has continued as long as may be desirable, ten or fifteen minutes being long enough as a rule, the patient is put to bed without removing the blanket. The action of the skin continues, exciting thirst which may be freely relieved by copious draughts of water, a full supply of which should be within reach of the patient. Before long a deep sweet sleep sets in, and the invalid feels well when he awakes in the morning. The bed should be kept till towards the middle of the day, and care be taken against further exposure to cold, and consequent recurrence of the complaint.

A portable Turkish bath, if at hand or accessible, is an excellent means of exciting diaphoresis. It consists simply in a tin box or reservoir with an open space for the alcohol lamp, and surmounted by sections of tin tubing which can be conducted under the bedclothes. When the lamp is lit, the air reaching the bed through the apparatus becomes thoroughly heated.

Another method consists in producing a localized diaphoresis by the inspiration through the nose of warm aqueous vapor, simple or medicated with volatile remedies such as chamomile, eupatorium, and the like. This treatment is advantageous in connection with general diaphoresis. All that is necessary is for the patient to lean the head over the vessel containing the warm fluids, and snuff up the vapor. If it is desired to protect the face, the steam may be directed into the nostrils by means of extemporized funnels or special inhaling apparatus. Sprays of warm water, or of tepid aqueous solutions of chloride of ammonium (5 to 10 grains to the ounce), carbonate and bicarbonate of sodium (2 to 20 grains to the ounce), carbonate of potassium (5 to 60 grains to the ounce), and the like, are also useful. During these inhalations a sense of relief sets in which continues for some time, and is then soon followed by a sensation of fulness in the parts, which, in its turn, is relieved by a more copious secretion of mucus. This process is repeated with more or less frequency, according to the urgency of the indications; the improvement gradually becoming greater and more lasting, until finally a stage of muco-purulent secretion ensues, which soon subsides without

further symptoms. The fumes of ignited opium are said to be sometimes successful in aborting or abating a severe cold in the head. Vapor of carbonate of ammonium is advantageous with some people in the early stages, exciting a copious serous secretion, attended with relief. In some instances it is absolutely abortive if promptly resorted to.

Total abstinence from liquids so as to diminish the supply for the nasal secretion is said to be highly successful,¹ the coryza beginning to dry up in about twelve hours after liquids have been left off, and ceasing between the thirtieth and thirty-sixth hours. It requires a great deal of courage to abstain from liquids for forty-eight hours or more, as is necessary to accomplish the cure by this means.

Where there is little or no general distress, but merely a stuffed feeling in the nose, the inhalation of the vapor of iodine, from the metalloid or the tincture, kept up more or less continuously for two or three hours, will, in many subjects, often suffice to cure the cold in that time. The best plan is to place two or three crystals of pure iodine in a quill or a tube of some kind, retaining the iodine in the tube by means of a light cotton or woollen wad on both sides of it. The tube is to be held in the hand, and one extremity of it is inserted within the nostril; the warmth of the hand disengages the vapor, which is snuffed up from time to time. When the vapor becomes too irritating, the tube is to be withdrawn for a few moments and then the process is repeated. In this way the inhalation is alternated between the two nostrils, if both be affected, the patient reclining in any convenient position, recumbent or semi-recumbent, and, if he likes, whiling away the time by reading or musing. The iodine provokes a flow of serum, and thus relieves the distention; and probably exerts some beneficial influence, in addition, upon the nerves of the affected membrane.

Pulverized camphor, or camphor and iodine, used in the same way, is often useful; as likewise inhalations of chloride of ammonium, either nascent from the mingling vapors of muriatic acid and strong liquor-ammonia, or from the fumes of heated sal-ammoniac. The vapor of carbolic acid, alone and in combination with the vapor of caustic ammonia is highly

¹ C. J. B. Williams: Brit. Med. Jour., Jan. 6, 1868, p. 554.

recommended in Germany, where it is known as Hager's anti-catarrhal mixture. This mixture is composed of one part of carbolic acid, three of absolute alcohol, one of caustic solution of ammonia, and two of distilled water, kept for use in a glass-stoppered dark bottle. When a catarrh is commencing, the patient pours a few drops on a few layers of blotting paper folded in a cone, which he holds to his nose, and from which he takes deep inspirations as long as any vapor is given off, the eyes being closed meanwhile; and the process is repeated at intervals of two hours.¹ Various other methods are employed more or less successfully, which it is needless to enumerate.²

A cheap and ingenious appliance devised by Dr. Pomeroy, of New York, for the inspiration or propulsion of vapors into the nasal passages (Fig. 82), consists of an egg-shaped glass reservoir, into which a sponge or a cotton wad is placed, saturated with the volatile material. The pointed extremity is inserted within the nostril, and the vapor simply inhaled by inspiratory efforts, or else propelled forward by forcing a current of air through a tube attached to the nozzle.

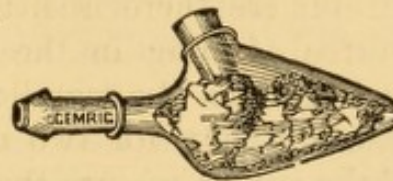


FIG. 82.—Pomeroy's nasal inhaler.

Small and repeated doses of tartar emetic ($\frac{1}{8}$ gr. every two hours), with a saline (sulphate of magnesia, one drachm), will sometimes afford relief in a few hours.

When a coryza has become fully established, warm aromatic drinks, warm foot-baths, and other methods of maintaining a gentle condition of diaphoresis, are employed until the affection is at its height, after which it gradually subsides spontaneously, and the employment of remedies is no longer indicated. Any severe general symptoms of fever, pain, and sleeplessness, are combated by antiphlogistics, sedatives, anodynes, and hypnotics, as may be required. The diet should be plain; and all exposure be avoided.

In treating the coryza of nursing infants care must be taken to keep the nasal passages pervious by frequent syringing, or withdrawal of secretions by rotary motion of a hair-pencil inserted in the passage for that purpose. Unless something of this kind is done, there will be great difficulty in nourishing

¹ Brand: Berlin klin. Woch., 1872, No. 12.

² See Cohen: Inhalation in the Treatment of Disease, Phila., 1867, 2d ed., 1876.

the child from the breast; and the spoon or even the stomach-tube may become necessary. In syringing the nasal passages of children, the head should be bent forward to avoid accidental entrance of the fluid into the larynx.

GONORRHEAL CORYZA.

This occurs in new-born infants from contact of gonorrhœal products during birth. The symptoms are those of purulent coryza. It also occurs occasionally in the adult, usually in nurses and washerwomen, from direct contact of gonorrhœal matters conveyed to the nose by cloths, handkerchiefs or fingers. The *symptoms* are those of severe purulent coryza. A careful history of the case, and examination of the suspected source of infection, are the main means of *diagnosis*. The *treatment* is similar to that for gonorrhœal inflammation elsewhere, with the free internal use of copaiba and cubeb. One of the best local applications is a solution containing one grain of carbolic acid to the ounce of lime-water, a favorite injection for urethral gonorrhœa in the Philadelphia Hospital.

IDIOSYNCRATIC CORYZA.

(Hay Fever, Hay Asthma, Rose Cold, June Cold, Autumnal Catarrh; Catarrhus Æstivus.)

A number of terms are used to designate a peculiar form of periodical coryza to which certain individuals are subject. Poor working people rarely suffer, or, if they do, rarely make complaint about it. It may, therefore, be fostered by good living and coddling. It is usually supposed to be produced by inhalation of the pollen of certain grasses or flowers, especially the hay made from early grasses,¹ the effect being due to a peculiar idiosyncrasy in the constitution of the individual sufferer. Residents of cities are as liable to it as residents in the country. It is analogous to a special cold in the head produced in some people by the proximity of powdered ipecacuanha, and seems to depend upon special susceptibility of the nasal mucous membrane, rather than to the special effect

¹ In this connection, see Blackley: *Experimental Researches on the Causes and Nature of Catarrhus æstivus*. London, 1873.

of germs. It is said to be occasionally produced by the emanation from the rose; but in some of these cases it is certainly excited by inspiration of the parasite in the flower. An old gentleman of my acquaintance is subject to an exceedingly distressing attack of coryza, with swelling of the nostrils, lips, and face, lasting for several days, from slight exposure to the powder of the chamomile flower fresh or dried. Some individuals are similarly affected by the emanations from linseed meal;¹ and an analogous affection is sometimes produced by emanations from animal matters.

Dr. H. Charlton Bastian has restated² that he has had frequent personal experience of the fact that a spasmodic and catarrhal affection, somewhat resembling hay fever, may be produced by emanations from certain nematoid worms, even after they had been preserved for two or three years in spirits of wine, and macerated for a time in calcic chloride.

Persons affected periodically almost always antedate the onset of the expected attack with wonderful accuracy, which cannot be altogether explained by reference to the ostensible cause. The autumnal variety usually occurs during the last two weeks of August, and often continues for four or six weeks. Sometimes the nostrils chiefly are affected, and sometimes the entire bronchial tract also. The conjunctiva and frontal sinuses are involved in some cases. The affection usually lasts for several weeks, but can often be arrested or avoided by a change of locality to a very high altitude or to certain spots near the sea-coast. Some years ago it occurred to Prof. Helmholz, who had long been subject to this hay fever, to examine the secretions from his nostrils, with the result of discovering vibriones. He made use of a weak solution of the hydrochlorate of quinia (1 part to 100) by injection, with relief, and was enabled to prevent the attack the year following by resorting to this local treatment before the usual date of its occurrence. Similar instances have been recorded since, but the remedy is by no means always effectual, even in those whom it may have relieved in previous seasons.

The *treatment* of idiosyncratic coryza would not differ from that of ordinary coryza, except in temporary change of locality, or the local use of some agent tending to destroy the

¹ Brit. Med. Journ., Aug. 31, 1872, p. 257.

² Introductory address: Brit. Med. Jour., Oct. 7, 1871, p. 404, note.

vegetable emanations which are supposed to give rise to the disease, such as alcohol, thymol, carbolic and salicylic acid, sulphurous acid, and quinia. A liberal regimen and vegetable tonics are often indicated. There is no specific remedy for the affection.

Some individuals lose their susceptibility to this complaint with advancing age. I have been consulted in one case where it recurred annually in a patient at that time nearly ninety years of age.

INFLUENZA.

(Epidemic Febrile Catarrh ; Contagious Cephalalgia).

This is always an epidemic disease. Its presence is liable to aggravate all diseases of the respiratory tract, increasing their mortality. It recurs at irregular intervals, most frequently during cold and moist weather, and usually prevails for about six weeks, spreading rapidly over great geographical regions, and attacking great numbers of the population, independent of position or station, often including nearly all who are much exposed to the inclemency of the weather. Horses, oxen, dogs, and other domestic animals are likewise subject to the disease. Sometimes the lower animals are attacked before the human species. One attack does not secure immunity in future epidemics. It is evidently a septic disease, probably of cryptogamic origin, as suggested by the late Prof. J. K. Mitchell, of Philadelphia. It is supposed by some authorities to be due to certain undefined electric conditions of the atmosphere. Though acute coryza is a constant manifestation, with severe frontal and supra-orbital pain, the catarrhal inflammation is by no means confined to the mucous tract of the nasal passages. Not only may it extend to contiguous mucous tracts, as in simple acute coryza, but it may involve the bronchi to their minuter ramifications. In addition to this, while a general resemblance is preserved between all epidemics, there are, at times, certain dispositions to involvement of different organs: the lungs, skin, intestines, brain, nerves, pleura, synovial and other serous membranes. It has been pointed out by a careful historian¹ that there are several predominant va-

¹ Theophilus Thompson: *Annals of Influenza; or, Epidemic Catarrhal Fever in Great Britain from 1510 to 1837.* Sydenham Soc., London, 1852.

rieties in the manifestations of influenza, one or more of which are apt to be prevalent in different epidemics. These are : 1st, Cerebral, characterized by vertigo, delirium, facial erysipelas, and sometimes parotitis ; 2d, Guttural, characterized by tonsillitis ; 3d, Bronchial, characterized by difficult and oppressed respiration ; 4th, Intestinal, characterized by diarrhœa, mucous stools, and abdominal tenderness ; 5th, Typhoid, characterized by great prostration, with depression of pulse and general symptoms of putrid or adynamic fever.

Children are less frequently attacked than adults. Pregnant women often abort during the epidemic.

Symptoms.—The attack usually commences with chilly sensations down the neck, back, and limbs, accompanied by languor, rigidity, and severe pains in the muscles. In some cases there is distinct rigor. Fever is soon manifested, and continues from two or three days to a fortnight, with evening exacerbations and sleeplessness. The pains usual to acute coryza are very intense. Thick, tenacious mucus accumulates in the posterior nares and in the pharynx, and is extricated with great difficulty. There is more or less harrassing cough, and sometimes semi-suffocative paroxysms in the attempts to dislodge and expectorate the secretions. If the lower air-passages are affected, there will be the ordinary symptoms of bronchitis. The mucous discharges soon become thick and purulent. The pulse is feeble and accelerated ; the appetite impaired ; the stomach disturbed by nausea and vomiting ; the bowels constipated ; the tongue moist and thickly coated ; the visible mucous membranes are congested and tumefied, and very sensitive to the touch ; the skin is hot and dry at first, and then moist and livid ; the face congested or flushed ; the urine, sometimes suppressed, is usually scanty and highly colored, and deposits copious sediment. The pains in and around the face and down the limbs are almost continuous, often excruciating, and sometimes exacerbated by severe and more or less prolonged muscular spasms. In elderly subjects the symptoms are much aggravated, especially those of bronchitis, in consequence of the difficulty of expectoration.

Diagnosis.—This rests on the symptoms of coryza and bronchitis, the fever, pains in the limbs, and knowledge of the presence of an epidemic.

Prognosis.—This is favorable except in the infirm, aged,

and in debilitated or very young subjects. The disease runs through its course in from one or two days to two weeks, or a little longer, a moderate average being four or five days. The bronchitis and general debility may outlast the subsidence of acute symptoms a long time, and may lead to phthisis, on the one hand, or to general nervous prostration, on the other. Even cerebral paresis¹ has been known to follow as a result of influenza.

Treatment.—This is essentially the same as that adopted for ordinary fully-formed coryza. It includes cathartics, anodynes, and febrifuges, if indicated, with the addition of tonic and supporting measures, and the direct employment of such remedies as are inimical to the organizations on the presence of which the disease is supposed to depend. The sulphites, bisulphites, or hyposulphites of sodium, calcium, or ammonium may be employed internally with this view; and inhalations through nose and bronchi of dilute sulphurous acid water act locally in the same manner. There is some evidence that the cryptogamic origin of the disease is correct, in that the maintenance of an equable temperature, kept up in the Massachusetts General Hospital during an epidemic at Boston, did not secure any immunity from the affection for the inmates in its wards; and hence it is fair to infer that the malady is due to extraneous matters in the atmosphere. On this view, the treatment above indicated is rational, and ought to be successful. The various complications should be met on general principles, care being taken, in combating evidences of inflammation, not to resort too hastily to direct depletion; and to be equally cautious about other depressing measures, inasmuch as the disease is of that adynamic tendency entitled typhoid.

Quinia, cinchonidia or cinchona, or bark in large doses would be indicated as tonics, and distilled liquors and carbonate of ammonium as stimulants. In threatening bronchial complications, especially, carbonate of ammonium in ten or fifteen grain doses, protected by some bland mucilage, may be judiciously repeated every two or three hours, or oftener, with advantage.

Mild cases do not require any special treatment other than that adopted for coryza of equal severity; but the inhalation

¹ C. Hanfield Jones: Studies on Nervous Functional Disorders. London, 1870.

of sulphurous acid water and its injection into the nostrils would be no more amiss than in the management of the severer cases.

Prophylaxis is of importance in epidemic influenza. For this purpose I would recommend the use of medicated respirators,¹ or of delicate wads of Angora wool inserted into the nostrils. The spiral fibres of wool prevent their being compressed to such an extent as to become packed when moist, as cotton wool does, and thus interfere with respiration.

The Indians of North America are in the habit of warding off influenza, catarrhs, and acute sore throats of all kinds by sleeping enveloped in blankets, and breathing through the partially closed fist.

In an article entitled "Infusorial Catarrh and Asthma,"² Dr. J. N. Salisbury, of Cleveland, Ohio, states that in 1868 he discovered an infusorium, which he has termed *asthmatos ciliaris*, in the nasal excretions of persons suffering from

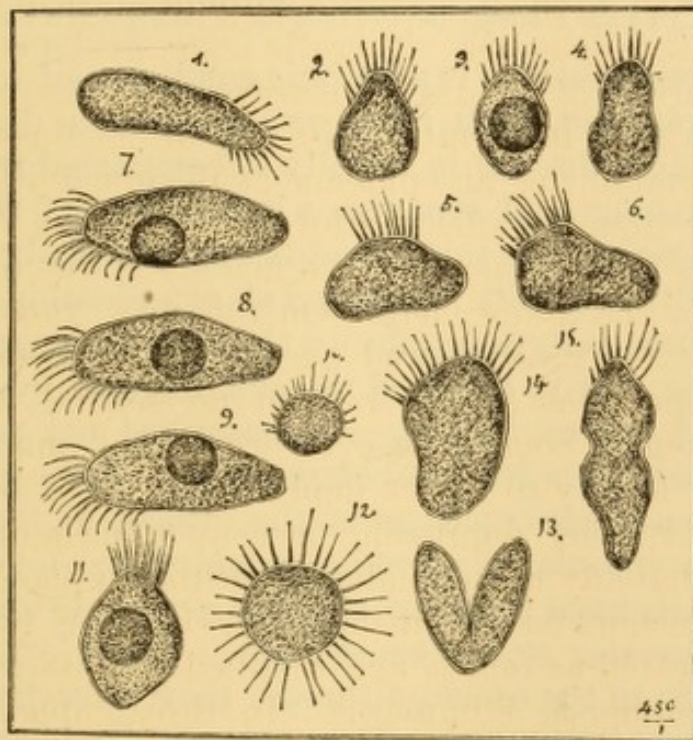


FIG. 83.—Living parasites from nasal excreta (from a drawing by Prof. P. F. Reinsch). 1-6, Common forms; 2-4, young specimens; 5, 6, 11, 14, 15, more mature specimens (15 probably dividing); 7, young cell inside; 8, 9, further positions of young cell; 10, escaped individual; 12, a rare form, resembling the actinophrys Sol.; 13, division. (Cutter.)

epidemic influenza and asthma, to which he attributes the origin of the disease, inasmuch as its destruction cures the complaint; and that he publishes the account after studying some seventy cases. The young and most active parasites

¹ Cohen: Inhalation in the Treatment of Disease, 2d ed., p. 375. Phila., 1876.

² Hallier's Zeitschrift für Parasitenkunde, Jena, 1873, illustrated.

are about the size of a mucous corpuscle, and the older ones from four to six times larger, and of an elongated oval form. They are described as protoplasmic, and possessing a body and processes or legs, and as exhibiting very active movements. They are killed by local applications of sprays of carbolic and salicylic acid, and by nascent chloride of ammonium. Dr. Ephraim Cutter, of Boston, confirms the observations of Dr. Salisbury, and has informed me, in a private communication, that he has detected the same infusorium (Fig. 83), which he terms a *rhizopod*, in the nasal excreta from cases of epidemic influenza occurring in Massachusetts in 1877-8.¹ He believes it to be morphologically identical with the *plagiophrys* found in drinking-water derived from lakes and ponds, and has seen some specimens resembling the *actinophrys Sol.*

The resemblance to the infusoria found in stagnant water is certainly very strong. Other observers have failed to recognize any abnormal elements in the nasal excreta of influenza or of hay-fever, and consider these bodies to be deformed epithelial cells.

CHRONIC CORYZA.

(Chronic Nasal Catarrh, Chronic Rhinorrhœa ; Coryza Chronica, Coryza Phlegmatorrhagia, Fluxus Nasalis.)

Chronic nasal catarrh is a chronic condition of impediment to nasal respiration, with more or less mucous discharge by pharynx or nostrils. It is usually accompanied with hypertrophic thickening, and sometimes induration, of the mucous membrane covering the turbinated bones, especially the lower ones—a condition readily recognized on examination anteriorly. Sometimes there is hypertrophy of the mucous membrane and submucous connective tissue of the alæ, in some instances to a more marked degree, forming circumscribed red protrusions, liable to be mistaken for morbid growths. These protrusions are often due to obstructions of the orifices of the secreting glands, the accumulated secretion pushing the mucous membrane before it, until a sort of exterior pocket is formed, with contents of greater or less consistence. These formations are usually elastic to the touch, although they sometimes become quite hard from induration. The parts usually bleed freely on injury, but the hemorrhage is easily arrested. Polypous or warty excrescences occasionally exist here and there, not infrequently upon the posterior portion of the floor of the nasal passage. Chronic coryza is sometimes associated with chronic pharyngitis, hypertrophied tonsils, and chronic laryngitis and

¹ See, also, Cutter : *Rhizopods (asthmatos ciliaris) a Cause of Disease*, Virginia Medical Monthly, Nov., 1878, p. 605.

bronchitis. Cases of some standing are apt to be characterized by a prominent, puffed, and glazed appearance of the pharyngeal mucous membrane (pharyngitis sicca, p. 199), in consequence of the irritation produced by the acrid mucus that trickles over it. In cases of long standing the inflammatory changes eventuate in atrophy of the mucous membrane, which is then pale rather than red, while there is no swelling or nasal obstruction, and the nasal passages are abnormally roomy.

The affection is sometimes a result of repeated attacks of acute coryza, but is more frequently manifested so gradually as to be chronic, as it were, from the outset. When first seen by the practitioner, it has often existed a number of months, or a number of years, sometimes comprising almost the entire life of the patient.

Chronic coryza is often simply an idiopathic catarrhal inflammation; but, as a rule, the subjects of the affection are pre-eminently of scrofulous diathesis, or else tainted with hereditary syphilis.

Chronic coryza is most frequent in cool, damp climates, where people are subjected to frequent change from warm, dry rooms to the cold, humid atmosphere outside. It sometimes presents varieties of manifestation in patients the subjects of the various diatheses; otherwise, the manifestations are characteristic and constant.

The inflammation of simple catarrhal chronic coryza rarely leads to ulceration, or even to abrasion of the mucous membrane; but that of scrofula and syphilis is quite prone to ulcerate. Specific inflammation, in addition, frequently destroys more or less of the cartilaginous and bony framework of the nose and nasal passages, giving rise to an offensive discharge, often leading the disease to be characterized as ozæna. The products of secretion in chronic coryza are not discharged freely, portions of them remaining pent up in the sinuosities of the passages, where they undergo decomposition, and more or less desiccation. They are discharged at irregular intervals, in crusts, lumps, or pellets.

Fetid Coryza (Ozæna).—The term fetid coryza, or ozæna, if it be preferred, merely indicates a combination of characteristic manifestations—fetid odor and discharge—attending disease involving the nasal passages, without defining its nature.

Fetid coryza is produced by various affections. It may be due to ulceration of the mucous membrane of the nasal passages or of the sinuses communicating with them, whether erythematous, catarrhal, glandulous, scrofulous, syphilitic, lupoid, or carcinomatous. It may be due to destructive disease of the bones or cartilages of the nasal organs, or of their periosteum or perichondrium; whether the disease be idiopathic, traumatic, or specific. It may be due to the development of adventitious growths in the nasal structures themselves, or in others contiguous to them. It may be due to caries of an upper tooth, with inflammation of the antrum. It may be due to the deposition of calcareous matters from the secretions, and their aggregation into rhinoliths or nasal calculi. It may be due to the retention of some external foreign body, introduced by design or accident, and to the inflammatory processes resulting therefrom. It may be due to some unfortunate individual or family idiosyncrasy, without any ulceration whatever, and even with little inflammation, or none at all. It may be due simply to retention of nasal excreta and their decomposition in the nasal passages.

It is therefore necessary to interrogate the part and the system in order to make a satisfactory diagnosis as to the cause of the discharge in any given case, and to institute the proper method of treatment.

In some cases of fetid catarrh, the bones and cartilages of the nose, as far as their condition can be examined, appear healthy; and no ulceration of the mucous membrane can be detected on inspection anteriorly or posteriorly. There seems to be some constitutional idiosyncrasy in these cases, in consequence of which, retained portions of the nasal secretions undergo desiccation, and remain impacted in some portion of the sinuosities of the nasal passages; there undergoing decomposition. This condition of system has been compared to that which is attended by the peculiar, offensive smell of the cutaneous perspiration from the feet and arm-pits of certain individuals who cannot rid themselves of their unpleasant odor even by the most scrupulous ablution. In these idiosyncratic cases the discharge is by no means profuse, unless in exceptional instances. Sometimes, indeed, it is quite scanty; but it manifests a disposition to become desiccated into thin scales or crusts, removable only with more or less difficulty: some-

times by way of the nostrils anteriorly, and sometimes by a sort of inspiratory nasal screatus, which, after repeated efforts, forces them through the posterior nasal outlets into the pharynx, whence they are expectorated. These crusts usually emit a horrible stench, perceptible at a distance of several feet, and capable of impregnating a large room with their fœtor.

Another form of fetid coryza, attended with certain local manifestations, to be yet described, is engrafted upon the strumous diathesis; and this variety, from its persistence, and from its ultimate destructive results—which, when very extensive and insufficiently attended to, resemble very much the effects of analogous conditions in constitutional syphilis—seems to contribute some force to the doctrine that scrofula is but an inheritance of syphilis—modified, it is true, but bearing a relation to that virus similar to that which some authors trace between varicella and variola.

These cases usually originate in an acute coryza or catarrh, the result of exposure to cold. This catarrh gradually becomes chronic, the attendant discharge more or less profuse, varying in color and consistence, being at one time muco-purulent, at another purulent, sometimes sanguinolent, and so on. The odor of the discharge is exceedingly offensive, and there is a permanently unpleasant odor of the patient's breath, rendering propinquity to the individual very disagreeable.

In these cases crusts of inspissated mucus accumulate at the outlets of the posterior nares from detention there of the secretions, and they often become moulded in more or less thick masses to the form of the opening, presenting, when discharged, a peculiar, honeycomb-like configuration. These moulds are usually several days concreting, and become discharged perhaps once or twice a week, sometimes oftener, sometimes less frequently. They are detached by a serous or sero-purulent exudation from the surfaces to which they are adhering. Sometimes they never exceed thin scales, and are discharged daily or more frequently, as may be. When discharged at long intervals, small, dense clumps of irregular conformation, and of similar constituents, will be occasionally drawn into the throat by forced nasal inspiration, and be then expectorated. These will possess the characteristic odor. Sometimes small caseous-like concretions will be hawked down from the glandular tissue at the nasal portion of the roof of

the pharynx, similar in appearance to the analogous matters sometimes discharged from the tonsils, and, like them, of an intolerable stench when crushed. In some instances, desiccated crusts are seen on pharyngo-rhinoscopic inspection, adhering to the glandular masses at the roof of the pharynx. When inspected immediately after spontaneous or artificial removal of the crusts, this glandular tissue is seen to be spongy, and, if the removal has been forcible, is most likely to bear decided evidence of hemorrhage. Pain will be complained of in the parts, and will be referred especially to the region of the frontal sinuses.

This form of disease of the nasal passages is met with in all classes of society : in the robust individual no less than in the delicate one ; in those who have been tenderly reared, and in those who have been brought up in the roughest manner. It may make its appearance at any age, but seems to be most frequently noticed for the first time about the period of the second dentition. Most of the patients I have seen have been girls from six or eight years of age upward to confirmed puberty or early adult life.

If, after thorough cleansing with the douche, syringe, brush, wad, and forceps, the parts are carefully examined—anteriorly by the aid of hook, probe, dilator, or speculum, and posteriorly by the rhinoscopic mirror—some points of ulceration, superficial or deep-seated, will usually be detected upon the mucous membrane. These ulcerated spots may occupy the free surface of the turbinated bones, or the lower region of the septum ; and even when ulceration cannot be discovered in these situations it is often fair to infer that it is likely to exist upon some portions of the turbinated bones altogether out of the field of direct or indirect vision. The nasal mucous membrane will be swollen, often to such a degree as to occlude the passage at one or more points ; in some instances the result of sero-fibrinous or fibrinous infiltration into the submucous connective tissue ; in others, the result, in addition, of actual hypertrophy of this tissue. In some cases little bags of thickened tissue or exuberant folds project from the walls, and are sometimes mistaken for neoplasms. The parts are usually very much congested, though they do not bleed, as a rule, except upon rough manipulation ; and they are very sensitive to contact with the probe in some instances, and not at all so in others. The

mucous membrane of the posterior portion of the septum is often seen in the rhinoscopic image, pushed off from its sides by submucous infiltration, bulging into the free space of the nasal outlets, so as to present much the appearance of turbid morbid growths.

As a matter of course, in this condition the patient will experience more or less difficulty of nasal respiration; one nostril or the other, in many instances, being impervious to air nearly all the time. This induces a habit of keeping the teeth slightly apart to facilitate breathing, and favors the formation of chronic pharyngitis; a condition which is often coincident to all forms of chronic coryza.

If the disease has existed for a number of years—and it is essentially chronic—the ulcerations will have extended beyond the limits of the tissue proper of the mucous membrane, and will have involved the cartilages and the bones, portions of which will sometimes have been destroyed, and have been discharged spontaneously; so that the cartilaginous septum is in many instances found to have been pierced through, sometimes in one or two small perforations, but more frequently in a single large, irregular hole, perhaps admitting the end of the little finger, or the end of a larger one, and looking as if it had been gouged out with some rude tool. In some instances one or more of the turbinated bones, usually the middle one, will be necrosed and bare in its entire extent, or the greater portion of it, awaiting its extraction—an operation readily accomplished with polyp-forceps. Sometimes it has been removed spontaneously, or has been pulled out by the patient, leaving a large, free space in the nostril, through which the posterior wall of the pharynx can be seen, or a portion of the upper surface of the velum. In some instances the destructive inflammation will have progressed to a farther extent, and have involved portions of the superior maxillary bone, from which copious accumulations of fetid pus and necrotic particles will have been discharged at intervals. Cases of this kind will have produced some alteration in the external configuration of the parts, the nose being sunken in or flattened out, and the nostrils distended. In some instances the orifices of one or more sinuses will be recognized, the tracks of which cannot be readily traced, perhaps because they course around the scroll of the turbinated bone. From these openings, on pressure behind

them with a probe, a few drops of creamy pus can often be discharged. In other cases, on the contrary, it is impossible to detect any traces of ulcerative action. There will be atrophy of the mucous membrane rather than hypertrophy, no evidence of induration, and consequently no obstruction to nasal respiration.

Some additional evidence of the strumous diathesis is usually apparent.

In cases of undoubted syphilitic origin—and the distinction between scrofulous and syphilitic coryza is not always well marked—the involvement of bony structures will progress to a much greater extent than that already described, the earlier manifestations having been similar to those of catarrhal and scrofulous inflammation, but more active. The turbinated bones, the vomer, the nasal bones, the palate bones, the lachrymal bones, the sphenoid, and the ethmoid, will often undergo more or less destruction. In some instances pharyngeal rhinoscopy and the use of the probe will early reveal necrosis of the vomer, the sphenoid, and the basilar process of the occipital bone. The discharge in these cases is not, as a rule, so offensive in odor as in the scrofulous cases; but it is equally persistent, and will continue as long as any dead bone remains undischarged. The tortuous contour of the nasal passages and the sinuses leading to them is such as to render it impossible in many instances to remove all of this dead bone by surgical interference through the nostrils anteriorly or posteriorly; so that its discharge must be awaited bit by bit. The amount of destruction that the parts may undergo under such circumstances is enormous. In some instances the cranial vault has been pierced, and the resulting meningitis has put an end to the complaint and to the patient.

The amount of the discharge, its consistence, and the intensity of its disagreeable odor, will vary during the course of a fetid coryza, whatever may have been its origin. An inflammation of the parts, such as follows a cold, a determination of blood to the head, over-work, the approach of the menstrual flux, all seem to increase the offensiveness of the discharge. This will become moderated after thorough cleansing and the application of suitable remedies, but will wax just as bad as ever in a few hours or a few days. When there is an involvement of bone, or a fresh involvement of bone, the fetor will be

increased until the necrosed portion has become exfoliated and discharged.

The patient is usually cognizant of his extremely unpleasant condition to a certain extent, but is unaware of the full amount of stench emitted from his body, because the sense of smell is obtunded, and in some instances entirely destroyed. With the loss of smell there is, in consequence, more or less loss of the sense of taste—so much of it as is dependent on the sense of smell. In those cases in which the frontal and maxillary sinuses are affected to a greater extent than the nasal passages, the patient is better able to appreciate his infirmity, for the sense of smell is still conserved to a considerable degree. The offensiveness of the odor in extreme cases is beyond description, and must be endured to be comprehended. It will impregnate a room for hours, and deter the practitioner from persisting in proper efforts to relieve the local condition.

Symptoms.—The symptoms of chronic coryza are those of frequent or more or less continuous obstruction of the nasal passages, with a more or less copious secretion, mucous or muco-purulent in character, discharged from the passages posteriorly as well as anteriorly. This obstruction is usually greater in damp than in dry weather; and not infrequently either one passage or the other is alternately nearly wholly impervious to the air; there being no regularity with respect to the frequency with which either nasal passage is affected. The relaxed and thickened mucous membrane absorbs the moisture from the atmosphere, undergoes expansion or distention, and in this way tends to occlude the passage. If the adjacent passages leading into the nasal fossa are implicated in the disease, there will be frontal or malar pains, earache, and more or less of the entire train of symptoms of acute coryza under similar conditions; and these will be aggravated by exacerbations which not unfrequently follow imprudent or accidental exposure to changes of temperature or external sources of local irritation. The exhalations from the parts will be more or less offensive according to circumstances, especially so if not subjected to frequent and efficient ablution.

Diagnosis.—This will rest on the presence of more or less of the group of symptoms mentioned, and upon the pathological condition of the parts and the secretions, as determined upon inspection, direct and with mirrors, palpation, and auscultation.

In order to examine the parts, they must be washed out as thoroughly as possible by means of the nasal douche, and by syringes introduced anteriorly and posteriorly into the nasal passages; the best substance in general being tepid water impregnated with table-salt—a drachm to the pint. If this fails to detach the secretions, the phosphates of ammonium and sodium, or the carbonates of sodium and potassium, may prove more efficient in like proportion. Sometimes the forceps, hair-pencil, cotton wad, or the sponge-mop may be used to detach matters within their reach. Forceps are very often required. In order to make a satisfactory examination of the parts, it is necessary that they be thoroughly cleansed. After the parts have been cleansed, they can be examined before a strong light—anteriorly by drawing the *alæ* aside so as to distend the passage, or by introducing a speculum; and posteriorly with the rhinoscope. In this way the appearance and condition of the mucous membrane is observed, and swelling, ulceration, retained secretions, foreign bodies, and morbid growths, exposed cartilage or bone, etc., detected. The tortuous contour of the turbinated bones and nasal meatuses renders it impossible to examine these structures in their entire extent; but still, under a good light, they can be explored pretty thoroughly, especially with the aid of probes bent so as to admit of application to the surfaces of the various parts, on the same principle employed by the dentist in exploring the tortuous recesses in a carious tooth. Rhinoscopic inspection discloses, in addition, the condition of the glandular tissue at the roof of the pharynx, a structure very frequently implicated in diseases giving rise to fetid discharge.

Cleansing of the nasal passages and retronasal portion of the pharynx is frequently required as a preliminary step to accurate examination and effectual local therapeutic procedures. It is impossible to determine the state of the mucous membrane of these passages, or of the morbid tissues that may be in them, unless they are cleansed of mucous secretion and dust, for which the ordinary use of the pocket handkerchief rarely suffices in chronic coryza. Where the view of the parts is prevented by only a slight amount of mucus, pus, blood, or the like, this may be removed by absorbent cotton, paper, punk, or the like, carried to the part by properly bent forceps or probes. If this is insufficient, it may answer simply to let the patient place his nose in a tumblerful of tepid water, made saline by a pinch of salt, and draw the water through the nostrils into his mouth, expectorating the matters that reach the mouth, and repeating the process several times, until the passages are cleansed. This is much more effectual than

snuffing the liquid from the palm of the hand.¹ Should this not suffice, there are a number of plans which may be adopted, according to the resources of the practitioner. He may use a syringe, spray-douche, or syphon douche—the so-called nasal douche—and he may wash the parts out from the anterior or the posterior nares, or in both directions alternately. A great deal of time and labor is sometimes requisite to effect thorough clearance of the nasal and naso-pharyngeal cavities in some cases of chronic catarrh. The ordinary barrel or rubber-bulb house syringe, discharged first by one nostril and then by another, the terminal extremity being turned towards the different surfaces of the passage during the manœuvre, sometimes answers very well. A long nozzle, with a number of perforations along its sides towards the terminal extremity, is still better. I have long used a female catheter, closed at its terminal extremity and perforated on its convex portion with three rows of half a dozen small holes, presenting upward and to both sides, so that the fluid injected through it should be propelled obliquely in several directions. The catheter is introduced, convex portion upward, along the floor of the nasal passage, until it reaches the posterior wall of the pharynx, when it is slightly withdrawn so as to clear the posterior wall. It is then attached, by a section of rubber tubing, to a syringe, or syphon, or a hydrant, as may be preferred, and thus injected. It washes the nasal passage and the pharynx very effectually. A syringe, the nozzle of which gives a return stream by means of perforations presenting backward, is likewise used by some surgeons. Dr. Yearsley, of London, employed a flexible tube, which was charged by a rubber bottle or ball syringe. With all these instruments the fluid injected returns partly by the nostril, partly by the mouth. If the nostril occupied by the instrument is compressed by the finger, so as to exclude any side passage of air, or the nozzle of the instrument be passed through a rubber washer, large enough to occlude the nostril, and the patient breathes with his mouth open, so that the palate shall become closely applied to the pharynx, the supra-palatine portion of the pharynx is shut off from the mouth, and the whole of the fluid will return by the other nostril if it is pervious.² The result is favored if the patient bend the head forward during the injection. Instead of the syringe, the nozzle of a nebulizer or spray-producer may be used, so that the finely divided spray may reach a greater extent of surface; but it has not the cleansing force of the full stream. Dr. Lefferts, of New York, has arranged a tolerably efficient spray-producer for this purpose, which occludes the nostril and drives the spray in the most favorable direction.

The method of washing the nasal passages most frequently employed at the present day is by means of the so-called nasal douche, a syphon tube, through which the fluid passes by gravity, without compressing force. This is known as Weber's or Thudichum's douche. The ordinary household syringe, with rubber-bulb compressor, answers the purpose, by simply raising the reservoir of fluid to a higher level than the nozzle, as soon as the instrument is in action. The

¹ Dr. Rumbold, of St. Louis, recommends snuffing the fluid from the palm of the hand, first with the forehead horizontal, then oblique, and finally vertical, so as to favor thorough contact of the fluid with the various surfaces of the nasal passages. See *Chicago Med. Jour. and Exam.*, May, 1877, illustrated.

² Bretonneau: *Fifth Memoir on Diphtheria*. Sydenham So. Ed., London, p. 197.

liquid will then flow in a continuous stream without further pumping. Various forms of Thudichum's nasal douche are employed, each one having some special advantage of convenience, cleanliness, or economy. The original apparatus (Fig. 84) is a flexible tube, attached to a perforated metal weight, by means of

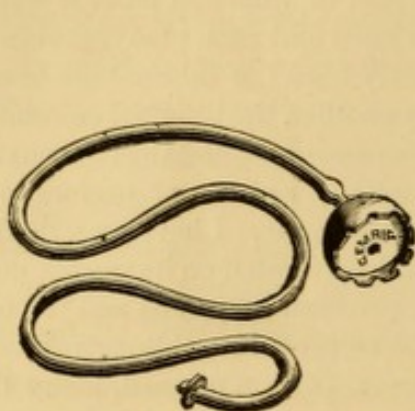


FIG. 84.—Syphon nasal douche.

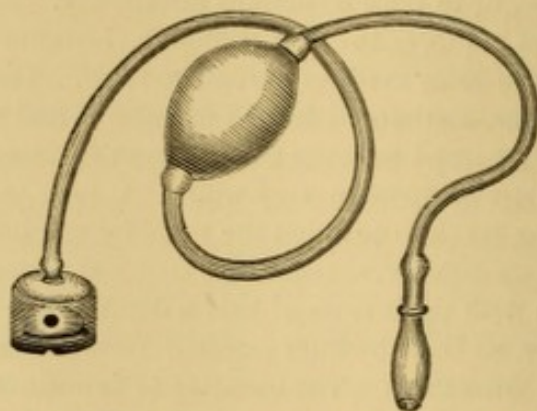


FIG. 85.—Syphon douche with compression-bulb.

which it is retained at the bottom of a jug or other vessel containing the fluid. By dipping the entire tube in the fluid, filling it with fluid before immersing it, or by suction with the mouth after immersion, or by compressing the tube in the

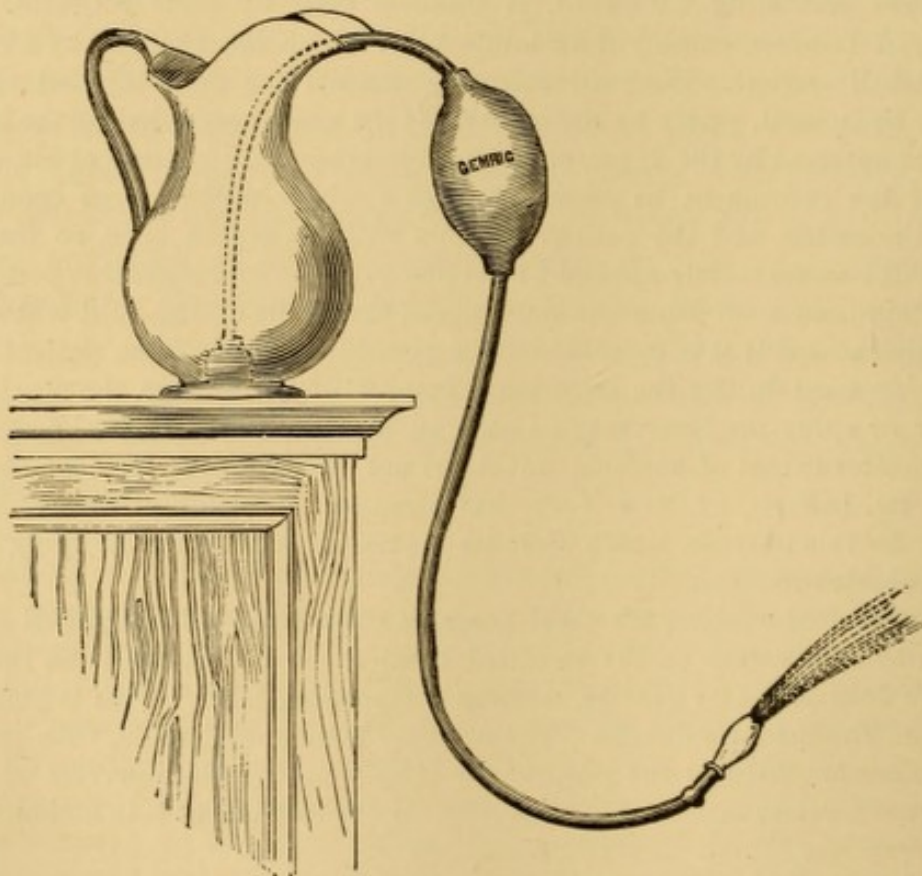


FIG. 86.—Manner of arranging syphon nasal douche (adapted from Thudichum).

direction from the vessel towards the nozzle, so as to drive out the air, the instrument is readily converted into a syphon, and the liquid runs from it on raising the reservoir. This is an admirable and compact apparatus for patients when

travelling. A glass weight is preferable to a metal one, as not liable to corrosion.

As I found difficulty in teaching some patients how to use this syphon, I modified it a number of years ago by placing a compression-bulb of rubber in the course of the tube (Fig. 85), the connections being made by small glass tubing without valves. If the bulb of this douche be compressed with one hand, and the nozzle be occluded by the other, and the weight be then placed in the vessel of water, the syphon is set in action on dropping the bulb by the side of the jug (Fig. 86) and releasing the nozzle; the fluid flowing readily and continuously. In this apparatus, weight, nozzle and connections are all of glass, rendering the apparatus very cleanly.




FIG. 87.—Bottle nasal douche.

A cheap and common form of douche consists of a bottle with a tubular offset at the bottom, to which the tubing and nose-piece are attached (Fig. 87). The bottle being filled and corked to prevent the premature flow of liquid, the nose-piece is inserted in the nostril, the bottle is uncorked, and then held up by one hand, or placed upon a support a foot or so above the patient's head. The flow is controlled by digital compression of the tube or by lowering the reservoir below the level of the nose. A rubber reservoir or bag which can be suspended from a nail or hook is more convenient than the bottle. It constitutes the so-called fountain-syringe, and is usually supplied with a mechanical appliance for compressing the tube. A spring clothes-pin or paper-clip answers the purpose, and a spring clamp can readily be made from a flexible wire or hair-pin.

The most complete apparatus is a special glass reservoir of the capacity of a quart, attached to a stand, in which it can be secured at any desired elevation so as to vary the pressure of its contents, and connected by stop-cock to three or more feet of flexible tubing, at the other terminal of which is another stop-cock and the nozzle (Fig. 88). In all these instruments the nozzle or nose-piece should be of wide aperture and large enough to occlude the nostril thoroughly, or should be provided with a pad or washer for that purpose (Figs. 87, 88); otherwise the occlusion must be accomplished by digital compression.

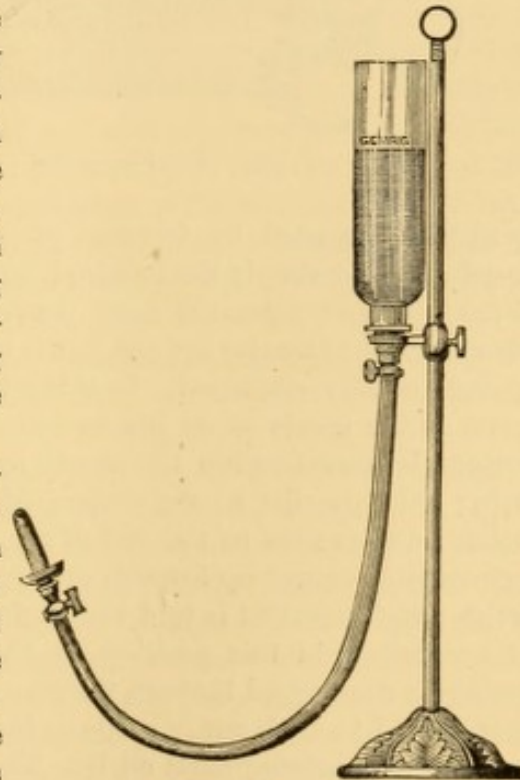


FIG. 88.—Thudichum's nasal douche (Thudichum).

In using the nasal douche, the nozzle is inserted into the nostril most obstructed, and pressed firmly so as to exclude the air and prevent the fluid from flowing backward. The head is then bent well forward, the mouth opened, and the stream allowed to flow; when it will all pass out through the opposite nostril, provided there is no occlusion. In this way masses of accumulated mucus, inspissated secretions, coagulated blood, and the like, will be discharged. The process is then repeated on the opposite side. At least a quart should be used at each ablution. The process is not painful, the sensation at first being like that of bleeding from the nose.

Cleansing the parts posteriorly by way of the pharynx and posterior nares is also of great utility and often indispensable. For this purpose the ordinary post-nasal or catarrhal syringe (Fig. 71, p. 261) is usually employed. I prefer a much larger syringe, like an aural syringe of the capacity of two or more ounces, so as to wash the parts thoroughly without too many repetitions of the manipulation, which is unpleasant; and I use a nozzle with a special curve (Fig. 89), which facilitates its passage around the palate, the terminal extremity being pierced with a great many perforations presenting forward when the instrument is in place, or with a slit sawn transversely to give a fan-like stream¹ when it is desired to wash the roof of the pharynx. This special curve of the nozzle was

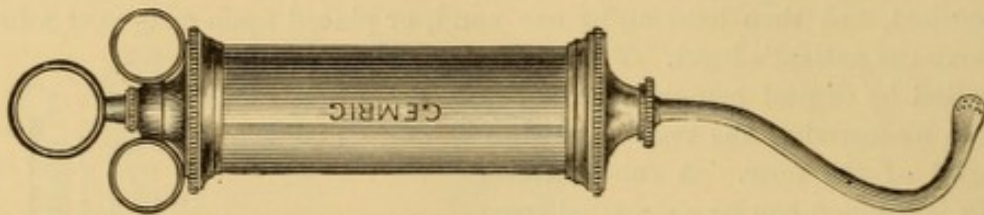


FIG. 89.—Author's posterior nasal syringe.

gradually imparted by frequent use to a number of flexible britannia-metal nozzles having simply the terminal curve, with which my syringe was originally fitted to avoid using the same nozzle with every patient. The instrument is rather heavy to handle lightly, but it is much more effectual than the half-ounce syringe usually employed. In using it the patient stands or sits erect with a basin in his hands or on his knees. The pharynx being well illuminated, the syringe is passed within the mouth by one hand, the curved part of the nozzle being held parallel to the surface of the tongue so as to avoid touching the palate; and as soon as the end of the nozzle is behind the palate, the terminal extremity is turned up towards the top of the pharynx by a movement of the wrist, and the patient is told to lean forward over the basin, and while his head is maintained in this position by the unoccupied hand of the operator, the syringe is discharged through the pharynx and nasal passages into the basin. If it is desired to wash out one side or the other, the nozzle is directed against one or the other posterior nasal outlet. The operation is repeated two or three times, if necessary, the condition of the parts being inspected meanwhile anteriorly

¹ This hint was suggested by the admirable action of a curved glass tube with flattened fan-like extremity, for douching the pharynx—a device of Dr. Sass, of New York.

and posteriorly as at the commencement. The nozzle of the syringe may be used attached to a hand-ball family syringe, or to a syphon douche, or, as is done by Dr. Sass, of New York, with his simple curved glass tubes, to a reservoir driven by compressed air, or attached to the delivery pipe of a stationary washstand. Dr. Sass' glass tube terminates in a flattened fan-shaped extremity, through which the water is driven from side to side of the pharynx, escaping through both nasal passages. This glass tube is the most cleanly instrument that can be employed, and, if carefully used, there need be little danger of breaking it. I have had one of them in use for eight years. A good non-fragile substitute for glass is found in hard rubber as utilized in the perforated nozzle suggested by Dr. Fullgraf (Fig. 90), which is provided with a little handle indicator for its more convenient manipulation.

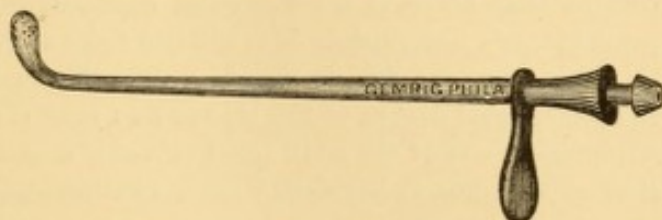


FIG. 90.—Fullgraf's retro-nasal douche.

The cleansing liquid in use in these douches is tepid water at about blood-heat, with about one drachm of table-salt or other saline to the quart. Cold water, and water of too low specific gravity, is apt to produce cold in the head; water too hot or too saline is apt to sting the parts and produce considerable local irritation. If the discharges are offensive, a little chlorine water, thymol, carbolic acid, or permanganate of potassium, may be added as a disinfectant.

Whatever method is used for cleansing the nasal passages by liquids, whether simply snuffed up from the hand, sprayed or syringed anteriorly or posteriorly, douched anteriorly or posteriorly, there is a likelihood, in certain individuals, of driving the liquid into the Eustachian tube, and even into the cavity of the middle ear; and, whenever this occurs, continuance of the practice is imprudent, unless the occurrence is a mere accident, favored by some voluntary action of the patient susceptible of control. The main cause of this accident is an involuntary movement of deglutition during the passage of the fluid, by which it is forced along with the air compressed in the pharynx, part of it taking the normal course of the air into the Eustachian tube. In a similar manner, mucus is sometimes driven into the Eustachian tube during acute coryza. The water is often innocuous—sometimes, indeed, salutary, for, in many instances of chronic coryza and of chronic catarrh of the middle ear, the Eustachian tube is implicated, and a slight washing is advantageous; but in some instances the entrance of any liquid into the middle ear will be followed by acute inflammation. Any premonitory symptoms of otitis media should be promptly met by external application of hot and anodyne poultices, and the internal administration of a saline and antimonial mixture, with the addition of a narcotic, if necessary. The attention of the profession was prominently directed to the danger of exciting inflammation of the middle ear in the use of Thudichum's nasal douche, by Prof. Moos of Heidelberg, and Dr. Knapp and Prof. Roosa of New York;¹

¹ Archives of Ophthalmology and Otology, N. Y. and Heidelberg, Vols. I., II., III.

but the accident is occasionally liable to occur in all methods of cleansing the nasal passages—even the simplest of all, snuffing liquid from the hand. The accident usually occurs while the patient is using the douche for therapeutic purposes at his own home, and generally from using too cold a liquid in cases of abnormally presenting, or unusually large pharyngeal orifice of the Eustachian tube. Accidents from these causes can usually be avoided by using warm solutions, and by due preliminary inspection of the parts rhinoscopically, to be certain that there is no abnormal conformation. When occurring under the practitioner's supervision, it is usually from movements of swallowing while the liquid is flowing; for, as shown by Dr. Weber-Liel, of Berlin, the occlusion of the pharyngeal orifice of the Eustachian tube is simply maintained by the apposition against it of the contracted elevator muscle of the palate; and the relaxation of this muscle—whether from swallowing, intermittence of the flow from the douche, over-tiring, or any cause whatever—exposes the orifice to the entrance of the current of liquid. To avoid this cause, therefore, the patient should be cautioned not to swallow until the nozzle has been removed from the nostril, or the flow checked by lowering the vessel or cutting off the supply.

Dr. Weber-Liel urges that weak solutions of carbonate of sodium be used instead of salt, as much less liable, if at all liable, to produce serious results in case of penetration of the fluid into the cavity of the tympanum; and he bases his opinion upon the results of personal observations in the human subject and experiments upon animals.¹

Fraenkel judiciously recommends² that the patient be instructed to continue uttering the sound *oo* during the operation, so as to keep the elevator muscle of the palate contracted against the posterior wall of the pharynx and the pharyngeal orifice of the Eustachian tubes.

I have been rather lengthy in discussing the subject of cleansing the nasal passages, because it is an important one. Furthermore, Thudichum's douche is too good an instrument of local therapeutics to be laid aside unnecessarily, and I am satisfied, from personal inquiries of numbers of patients who have been injured by its use, that it is often from neglect of some precaution—most frequently the use of cold water when they are too lazy to go for warm water, or in too great a hurry to wait for it. I can only recall two or three of my own patients who have been subjects of this accident, and the substitution of cold for warm water was the cause in these instances. The experience of Dr. Elsberg, of New York—the greatest, in all probability, of any practitioner on the western side of the Atlantic Ocean—has been substantially the same as my own; and a recent writer³ on the subject states, as the result of the personal use of the nasal douche in more than fifteen hundred clinical cases, in addition to those treated in his private practice, that he has neither seen nor heard of an untoward result, or even a complaint.

In some instances, too, the liquid from the anterior douche enters the frontal sinuses, and produces intense pain there—so great in some instances that the method must be abandoned.

¹ London Med. Rec., June 15, 1878, p. 242.

² Deutsch. Ztschrift. prakt. Med., 1877, No. 30.

³ Cassels: Dub. Jour. Med. Sci., June, 1877, p. 547.

It is, therefore, desirable in all instances that the first use of the nasal douche, whether for purposes of ablution or therapeutics, should be carefully made under the direct supervision of the medical attendant or a competent assistant; and that its effects be closely watched. With due care on the part of the practitioner, and due obedience on the part of the patient, otitis media should be a very unfrequent result of efforts at cleansing the nasal passages.

Prognosis.—This is good in simple catarrhal cases, provided proper measures are employed to keep the parts cleansed of accumulating secretions and other matters, and proper prophylactic precautions be taken to avoid the causes that favor exacerbations. The disease is one of long standing, and may persist a number of years, or even the entire life of the individual, without compromising his tenure of existence. In other cases the continuous impregnation of the inspired air with the decomposing products of secretion, seriously impairs the general health, and even occasions slow septic poisoning. The disease, if unchecked, may also eventuate in permanent hypertrophy of the affected tissues with more or less stenosis, in the development of various morbid growths, in adhesions of the mucous membrane, in abscess and ulceration. Ulceration, once set up in scrofulous, tuberculous, and syphilitic subjects, may proceed to extensive, and even uncontrollable destruction of the cartilaginous and osseous structures of the nasal passages and adjacent sinuses.

In idiosyncratic fetid coryza the immediate prognosis is rarely favorable, and, in spite of all that can be done in palliation of the symptoms, the affection will continue until towards middle adult life, when it usually subsides spontaneously. In other forms of fetid coryza the prognosis will depend on the practicability of getting rid of any exciting cause that maintains the morbid processes. In scrofulous coryza the prognosis is fairly good, if the system responds to the remedies usually employed with benefit in scrofula—cod-liver oil, salts of lime, iron, and the iodides. In syphilitic coryza the prognosis is dependent upon the amount of destruction of tissue which has taken place, and the susceptibility to arrest of the systemic disease by anti-syphilitic measures; but there is always a certain degree of deformity left if there has been destruction of hard tissues.

Treatment.—An important element in treatment is the maintenance of good hygienic regulations regarding diet, ven-

tilation, clothing, cleanliness, and exposure. Constitutional treatment is required, adapted to the exigencies of the case. Assiduous local ablutions by syringe or nasal douche, or by insufflation if effective, are to be performed by the patient or an assistant, night and morning, to cleanse the parts. Similar ablutions should precede local medications, otherwise little progress towards cure is to be anticipated. Without preparatory cleansing, local remedies are of questionable avail; they become entangled to a certain extent with the retained secretions, act to a certain extent as foreign bodies, and are unable to exert that beneficial influence upon the diseased tissues which often follows their application upon cleansed surfaces. The daily ablutions are on no account to be neglected, and should be attended to as punctually and as scrupulously as other wants of nature. The forcible compression exercised in the hand-ball syringe renders it a much more powerful means of cleansing the parts than any form of syphon or spray douche. At least a quart of tepid water, containing a drachm of table or coarse salt in solution, should be used at each ablution, part started through one passage, and the remainder through the other. When the secretions are very adherent, carbonate of sodium, in like proportion, is sometimes more efficient. Chlorate of potassium and chloride of ammonium are used for the same purpose. In many instances these cleansings are all that will be required to effect a cure in otherwise healthy subjects; the parts recovering spontaneously, if relieved from the continued and repeated irritation of dessicated and decomposing products accumulated in the passages. Rain water, or river water that has been boiled, is often preferable to ordinary drinking waters, which sometimes contain ingredients that are absolutely injurious to the mucous membrane. If the secretion is very copious, astringent solutions of alum (1 to 3 drachms to the quart), tannin, sulphate of zinc or of copper (20 to 60 grains to the quart), acetate of lead (30 to 60 grains to the quart), nitrate of lead (10 to 30 grains to the quart), may be used instead of the salines for their local effects upon the mucous membrane. There is said to be danger of loss of smell in the protracted use of preparations of alum, zinc, and lead. The local use of astringents and alterants by the sponge or wad, passed by throat and nostril alternately, is sometimes of great service after the douche. As an astringent, tannin may

be dissolved in ether¹ or alcohol, so as to leave a viscid deposit of tannin on the parts after evaporation of the menstruum. As an alterant, iodoform may be used dissolved in ether² or chloroform³ in the same manner. Simple steam from boiling water, directed upon the parts by rubber tubing attached to the delivery pipe of a special boiler (as that of the steam spray-producer), or simply to the nozzle of a funnel inverted over the vessel of steaming water, is of great use in detaching adherent viscid and dessicated crusts. It can only be used intermittingly. It is not prudent to face the cold air of the streets for half an hour after using steam in this manner.

In many cases of chronic coryza, sedative measures are required locally instead of corrigents or astringents, for the parts, long subject to irritation, require soothing. These may be applied in vapor, spray, solution, powder, or ointment. As already indicated, a cleansing process should precede their use. The substances employed in the liquid form are glycerole of borate of bismuth or of the neutral nitrate, lime-water, compound tincture of benzoin, tar-water, various mucilaginous liquids, milk, etc. The vapors of conium, stramonium, opium, myrrh, benzoin, pine, and tar, are used. Powders of bismuth, calomel, morphia, or iodoform, are useful if they do not accumulate and dessicate the secretions. Ointments of stramonium, belladonna, morphia, and iodoform are sometimes used with benefit, and are especially suited for children.

In case of mere thickening or induration of the mucous membrane, much benefit often follows local applications of mild solutions of sulphate of copper, nitrate of silver, chloride of zinc, carbolic acid, or iodine: or even the superficial use of the incandescent cautery of the electric current. If the mucous membrane is much relaxed, or protrudes into the passages, the most effectual plan is to twist it off with forceps—a very painful proceeding; or to encircle it with a wire snare, similar to that used for removal of aural polyps, and to cut it off by drawing the loop tight, a proceeding much less painful. To secure the action of the wire, the membrane may be drawn through it with a hook or a pair of delicate forceps. The caustic point

¹ Tannin is soluble in sulphuric ether to the proportion of one part by weight in one by measure.

² Soluble, one part by weight to fifteen by measure.

³ Soluble, one part by weight in twelve by measure.

of the galvano-cautery, or the galvano-caustic loop, may be employed for the same purpose. Voltolini and others give the galvano-cautery precedence over all other measures. The resulting sores may be touched with nitrate of silver. As the edges of these wounds contract in cicatrization, the respiratory calibre of the nasal passages is enlarged. A number of operations are usually required to free the nasal cavities from these exuberant duplicatures of mucous membrane. If the passages be occupied by polyp or other morbid growths, their preliminary extraction is an essential prerequisite.

In cases of obstruction to respiration from tumefaction, the systematic use of tubes of laminaria, introduced into the passage and allowed to swell until they begin to be tight, when they should be removed, sometimes enlarges the passages permanently. In cases of exceeding obstinacy, and which cannot be cured in this way, freedom of nasal respiration may often be gradually secured by the introduction of silver tubes through the nostrils, connected in front so as to prevent their falling into the pharynx. These may be worn every night, to keep the nostrils patulous, and to promote absorption of tissue by the compression they exercise.

All that can be effectually accomplished, in the way of treatment in the idiosyncratic variety of fetid coryza, seems to be the promotion and maintenance of an active condition of the secretory functions of the skin and kidneys by frequent bathing, night and morning, with tepid water slightly impregnated with salt, mustard, or other irritant, and by copious water-drinking—keeping up a sort of sewerage, as it were—and the thorough and efficient cleansing of the parts several times a day, especially at night and morning; making this act a constituent and essential part of the daily toilet, as much so as the use of the tooth-brush or wash-basin. For this purpose the nasal douche, or some modification of it, is the best contrivance in most instances; but if the crusts are tenacious or impacted, the pharyngeal nasal syringe and the continuous rubber hand-bellows syringe will afford better results; the latter especially in those cases in which crusts moulded to the contour of the posterior nasal outlet are apt to accumulate, and to dislodge which readily, a stream of fluid entering with some force from the front is requisite. The ordinary solution of table-salt—a

drachm or two to the quart of tepid water—fulfils the requirements of the douche for cleansing purposes; and detachment of the crusts is facilitated by the substitution or addition, as may prove most appropriate, of equal quantities of alkalines (carbonate or bicarbonate of sodium, phosphate of sodium, and the like). After the parts have been cleansed, the douche should again be used, containing a disinfectant in tepid solution. Permanganate of potassium, chlorine water, chlorinated soda, carbolic acid, thymol, and so on, employed in this manner, will in a great measure control the fetid odor of the secretions. Chlorine water (one drachm to the pint) has been oftener efficacious in my own practice than any other disinfectant. A mercurial purge, with the addition of ipecac or a saline, two or three times a week, is sometimes beneficial.

Various local applications are made at times for the purpose of altering the nutrition of the mucous membrane, in the secretion of the glands of which the diseased action is supposed to reside. For this purpose preparations of mercury and of iodine, the terebinthines, chloride of ammonium, etc., have been employed in the forms of ointment, powder, solution, spray, and vapor; but, in my own hands they have proved of only questionable benefit. Local cleansing, with disinfectant detergent douches immediately afterwards, and the maintenance of the cutaneous and urinary secretions by appropriate remedies, have rendered good service; but, to be efficient, resort to these measures must be constant.

Fortunately, this variety of fetid coryza, whatever its real nature, moderates in severity as the patient becomes older, so that by middle adult life it has subsided entirely, or in great measure. It is a long while to await permanent relief, to be sure, but it is better than no prospect of cure.

The treatment of other varieties of fetid coryza will depend upon their nature. When due to the presence of a foreign body, a rhinolith, a morbid growth, or a carious tooth irritating the antrum, the removal of the exciting cause will usually cure the discharge. In cases with constitutional taint, systemic treatment is required. The treatment of this condition, in fact, is simpler in principle than in practice; but it is always tedious, and often unsatisfactory. Palliation of the severer symptoms and diminution of the fetor can almost always be effected, but a thorough cure often requires months of persistent treatment;

in some instances seeming almost unattainable, and in others quite so. When the larger bones are diseased, and it is impossible to get access to them, the condition will continue for years, dead bone being exfoliated splinter by splinter, and fresh involvements becoming new sources of evil as older ones are undergoing amelioration.

In scrofulous cases we can endeavor to improve the tone of the constitution by resort to systemic remedies, such as cod-liver oil, lime, quinia, and iron, the preparations of chlorine, iodine, arsenic, and so on; and we may thus repress increase in the malady, even if we fail in restraining it. The administration of cubeb, preferably, in my own practice, in doses of fifteen to twenty drops, or more, of the oleoresin on sugar, after meals, will sometimes diminish the copiousness of the secretions to a certain extent, and modify their character by the local influence of the drug in its elimination through the mucous membrane of the nasal tract; and the relaxation of the bowels sometimes attending the administration of this drug, if kept within reasonable limits, acts beneficially, in a measure, as a derivative. Some practitioners prefer the recently powdered cubeb (ten to twenty grains). Capsicum, oil of turpentine (three to ten minims in emulsion or in capsule), creasote (one-half to one minim with pulverized extract of liquorice in capsule), oil of juniper (five to fifteen minims), tar-water (two to four fluidounces), three times a day, are also administered with benefit in some of these cases.

The decidedly syphilitic cases, when not so far advanced as to be irremediable, are much more manageable under systemic medication than are the idiopathic and scrofulous cases. Here small doses of the bichloride of mercury (one-sixteenth to one-quarter grain daily in two or three doses), with the free use of the iodide of potassium (ten to thirty, or even sixty grains at a dose in an emergency), are just as efficacious as in other forms of constitutional syphilis, especially if the general vigor of the patient has not been greatly impaired. If the general health is poor, a generous allowance of nutritious food, assisted by a tonic course of treatment, will be necessary before beneficial results can be expected from specific remedies.

All forms of fetid coryza require local treatment. The parts should be frequently cleansed, and topical remedies assiduously applied.

The local applications for remedial purposes consist of solutions, powders, vapors, and unguents, brought in contact with the parts by suitable appliances. When ulcerated surfaces can be reached by instruments introduced within the nostrils or behind the palate, they should be regularly touched by the sponge, cotton wad, or hair pencil, loaded with a solution of nitrate of silver, sulphate of copper or of zinc, carbolic acid, chromic, nitric, or muriatic acid, or the acid nitrate of mercury, as the case may seem to demand. Dead bone, where accessible, should be removed with forceps, assisted, if need be, by the knife or scissors. Too much force should not be exerted in the endeavor to remove dead bone. It is better practice often to use frequent traction from side to side with forceps, in a sort of dislodging motion, so as to loosen the pieces of dead bone, and thus gradually render them sufficiently movable to be extracted without much physical effort. If the bone is too large for removal through the nostril in mass, it may be crushed between the blades of strong forceps, or divided by cutting-pliers, and be extracted piecemeal. In many instances the dead bone may be removed through the mouth by means of curved forceps passed up behind the palate.

The contact of the opposing surfaces of mucous membrane can often be overcome by the daily interposition, for an hour or more at a time, of strips of compressed sponge, or of tubes of laminaria; mechanical appliances which compress the parts as they imbibe moisture from the secretions, thereby favoring absorption of the products of submucous infiltration. Where hypertrophied or exuberant mucous membrane exists, and where internal compression is insufficient to enlarge the passage for the free ingress and egress of air and the free discharge of the secretions, it is good practice, as already mentioned, to twist off portions of the membrane with delicate forceps, so that cicatrization of the irregular edges of the wound may enlarge the passage. The free bleeding accompanying this procedure exerts a salutary influence upon the parts; and though the operation is very painful, it is so efficient in its relief that the patient will readily submit to it again and again, for the sake of the ease it affords in respiration afterward.

The solutions used by douche or injection may contain chlorate of potassium, alum, thymol, creasote, the essential oils, or carbolic acid, permanganate of potassium, chloride of

lime, chlorine water, or similar substances, which, in addition to their local action on the parts, tend to control fœtor. Or we may use special injections or sprays of nitrate of silver, sulphate of zinc and of copper, the sulpho-carbolates of zinc or lime, bichloride or iodide of mercury, chloride of zinc, chloride of lime, and the like. These injections should be employed at least twice a day, night and morning, and, where practicable, three and even four times a day; and they should always be preceded by the use of the douche for cleansing purposes. They should be used in weak dilution at first—say two or three grains to the ounce—and be gradually increased in strength as tolerance of them is manifested; care being taken that none of the solution is swallowed by the patient, on the one hand, and that too free use of remedies which act promptly on the system be not made, on the other; for the nasal mucous membrane readily absorbs certain remedies, and the proximity of the olfactory filaments to the nervous centre favors the systemic effect of others. This latter fact is often utilized to subdue the pain in the frontal region, by the local application of an ointment containing three or four grains of morphia, or one or two of the extract of stramonium, to the ounce; not more than the volume of a pea being used at a time. This should be rubbed into a little wad of cotton, which may be stuck by sealing-wax upon the end of a knitting-needle, and passed along the passages as far as the patient can reach, the ointment being gently wiped off upon the parts as thoroughly as possible, and over as great an extent of surface as may be. A long-haired pencil may be used instead of the wad.

A solution of the chloride of lime was used in Philadelphia, with great success, by the late Prof. Horner,¹ who injected each nostril twice a day with a solution containing a teaspoonful of the chloride in a wineglassful of water. This practice is not much in use to-day, but it deserves to be. A somewhat similar formula,² from which I have sometimes obtained very satisfactory results, contains from five to six grains of the chloride of lime to the ounce of the decoction of krameria; of which two or three drachms, or more, strained and diluted with

¹ Amer. Jour. Med. Science, Vol. VI., 1830, p. 265.

² Dr. Detmold, of Hanover (Holscher's Annalen, B. 1804). Brit. and For. Med. Rev., Oct., 1841. Am. Jour. Med. Science, Jan., 1842, p. 232.

an equal quantity of water, are injected into the nostrils night and morning, immediately after the use of the douche, and sometimes once or twice during the course of the day. Sometimes the parts will not bear a solution of this strength, and it must be diluted accordingly. When the remedy excoriates the external tissues, as it will do sometimes, its use must be suspended or its strength reduced, as may seem most judicious. A preliminary coating with grease or collodion will prevent this excoriation.

Glycerine is sometimes of great service as an injection, particularly in scrofulous cases. It is bland, unirritating, and its affinity for moisture of all kinds facilitates the separation and removal of the secretions, inspissated crusts, and detached fragments of dead bone. I have not noticed the local irritation from glycerine reported by some writers. The addition of iodine, in the proportion of a grain or two to the ounce of glycerine, is sometimes advantageous.

Prof. Trousseau relied greatly upon certain medicated powders to be snuffed up by the patient twice or thrice a day, after the passages had been cleansed as thoroughly as possible. His principal formulæ contained calomel (a drachm to the ounce of sugar), or red precipitate (forty grains to the ounce of sugar); their use being regulated in accordance with the irritation produced. Another favorite powder, with which he was very successful, was composed of bismuth rubbed up with equal parts of Venetian talc, and this, on account of its innocuousness, was used as freely as was desired.

Camphor, tannin, cubeb, and other substances, separately or in combination, have been used in a similar manner; some practitioners mixing them with two or three times their bulk of Scotch or Welsh snuff. They are often very irritating, and are by no means cleanly. Often, indeed, they but favor the coagulation and dessication of the secretions. In mild cases benefit sometimes follows the use of a snuff, composed of one part of bismuth in four or more of acacia and some indifferent material, as starch or lycopodium, a pinch being taken after each cleaning of the passages whether by douche or handkerchief. In fetid cases a quantity of salicylic acid may be added to the powder.

The best method of applying these powders is by means of a few inches of rubber tubing, one end of which is charged

with the powder and compressed by the fingers, while the other end is placed in the mouth; the charged end is then placed within the nostril, the compression relaxed, and the powder blown into the passage.

Citrine and other ointments, more or less diluted, are sometimes used locally after thorough cleansing; being applied to the parts by the little finger, a hair pencil, or a cotton wad on the end of a wire. External compression, during withdrawal, facilitates contact.

Medicated oils are sometimes used in a similar manner. Soluble bougies have been advised for local medication by Cotti, of Vienna, containing from two to four grains of tannin, krameria, sulphate of copper or of zinc, or a suitable quantity of any other remedy. They are retained in contact with the parts for from one to four hours daily. They are very uncomfortable companions, but are of undoubted efficacy in some cases. To prevent them from slipping into the pharynx, and then perhaps into the larynx, they should be secured by a thread run longitudinally through them, and projecting for attachment externally.

The principal remedies used in the form of vapor are preparations of mercury in syphilitic or quasi-syphilitic cases. Calomel, bisulphide or binoxide of mercury are evaporated by means of a spirit-lamp, and the fumes drawn by inspiratory effort through the nasal passages.

In scrofulous and other cases, vapors of iodine, benzoin, carbolic acid, or camphor, separately or in combination, turpentine, and essential oils of various kinds, may be inspired from open vessels, tubes, and special inhalers, or, what is much better, be forced into the passages by compressed air from a rubber-ball compressor, or some other contrivance according to the resources of the patient.¹

Advantage sometimes accrues, in all forms of chronic coryza and ozæna, from the copious use of the vapor of chloride of ammonium, after the parts have been cleansed by the douche and syringe. For this purpose the powder of sal-ammoniac may be heated over a flame, in an iron spoon, and the fumes snuffed up. A much better method is to use the apparatus devised by Dr. Lewin, of Berlin, for generating the vapor and

¹ Details on these points may be consulted in the recent edition of my treatise on Inhalation in the Practice, etc., Phila., 1876.

applying it in a nascent state. The bottoms of two bottles, through the corks of which a tube passes all the way down, are covered with an ounce or so of strong muriatic acid and caustic water of ammonia, respectively; a second tube, passing from just below the corks of each of these bottles, is carried down to the bottom of a third, or wash-bottle, half filled with water. A third tube from just below the cork of this bottle communicates with a nozzle to be placed in the nostril. As the vapors from the generating bottles are driven together into the wash-bottle, they unite to form vapor of chloride of ammonium, which becomes washed before it escapes from the apparatus.

In Lewin's apparatus it was intended that the patient should inhale the vapor by the mouth and pass it out by expiration through the nose; or else inspire, for a short period, through each nostril alternately. I have found it much better to arrange the apparatus as represented in the illustration, (Fig. 91), so as to propel the vapor by means of a current of compressed air from a hand-ball compressor such as is used with the spray-producer, or from a special reservoir or air-press, which is most convenient for office work. The inspiratory method is tiresome, less efficient, and sometimes injurious to the tongue, from the constant suction forcibly striking the same spot, which it soon denudes of epithelium. The small, so-called portable and pocket apparatuses, sold in the shops to supersede the apparatus of Lewin, cannot replace it efficiently, and evolve too strong a vapor. It is necessary that the wash-bottle should be sufficiently large to contain enough water to remove all pungency from the nascent vapor.

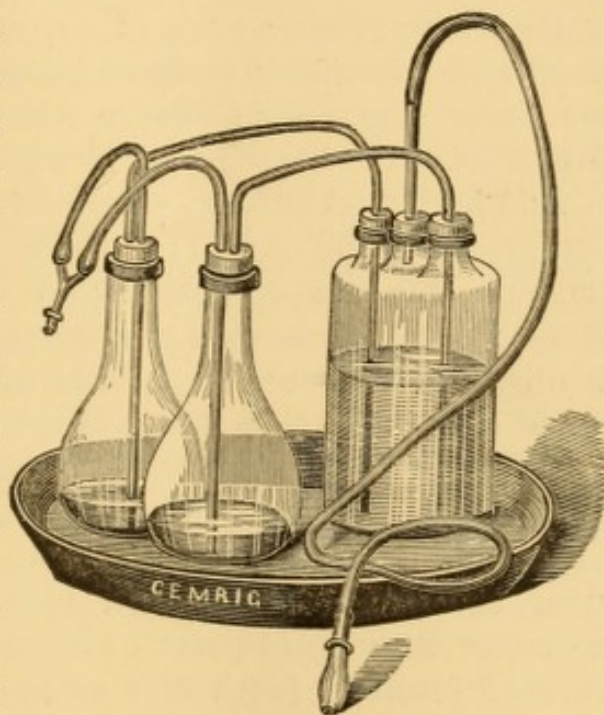


FIG. 91.—Lewin's apparatus for generating nascent chloride of ammonium, as modified by the author, for forcing the nascent vapor forward by compressed air.

The following remedial agents are recommended by various observers for local use in chronic fetid coryza:

In vapor:—Carbonic acid; creasote (3–15 minims on boiling water, or undiluted at ordinary temperatures, or rubbed up with a little carbonate of magnesium in six parts of water, a teaspoonful in a pint of warm water, at 150°, from any inhaler); carbolic acid (1–5 grains, with 2–10 drops of alcohol, in a drachm of water, thrown in a pint of warm water; or a few drops of the concentrated acid on cotton, in the bottom of an inhaler, at ordinary temperatures); camphor (a quill, or other tube, filled with coarse powder, secured by light cotton or woollen wads); mercury (cigarettes made of blotting-paper soaked in a solution of 15 grains nitrate of mercury, dissolved by a gentle heat in 6 or more drachms of water, with 15 drops of fuming nitric acid); iodine (one or two crystals, confined in a tube by permeable wads of cotton or wool, sometimes combined with camphor; or 20 or more minims of the tincture in hot water); ammonia (dilute water); chloride of ammonium (fumes from the heated salt, or nascent vapor).

In spray:—Aqueous solutions of chloride of ammonium (1–60 grains to the ounce); chlorine water (5–20 minims to the ounce); solution of chlorinated soda (5–60 minims to the ounce); permanganate of potassium (1–10 grains to 2 ounces); sulphate of zinc and sulphate of copper (1–20 grains to 2 ounces); carbolic acid (1–2 grains to the ounce).

In powder:—Insufflations of alum (alone, or mixed with one or more parts of sugar of milk or other indifferent material); tannin (alone, or rubbed up with one or more parts of sugar of milk, alum, borax, bismuth, or camphor); borax (alone, or with equal parts of sugar, alum, or tannin); subnitrate of bismuth (with one or more parts of sugar of milk, acacia, lycopodium, etc.); nitrate of silver (with 10–60 parts of sugar of milk, burnt alum, talc); calomel (with 1–5 parts of sugar of milk); camphor (with tannin, snuff); chloride of sodium; carbonate and bicarbonate of sodium; chloride of ammonium; acetate of lead (with 5 or more parts of sugar); sulphate of iron (with 20 or more parts of some innocuous material); salicylic acid (with 1 or more parts of lycopodium, or starch, or nitrate of bismuth, *Ludlow*).

With all these resources at command, it is quite possible to improve the condition of patients affected with chronic

fetid coryza, and place them under the most favorable conditions for the cure of whatever affection has given origin to the loathsome catarrh.

In cases due to ulceration of the osseous tissues, Dr. Rouge, of Lausanne,¹ and others after him, have practised a surgical operation consisting in detaching the upper lip from the upper jaw by intra-oral incisions, and turning the nose up over the face so as to expose the nasal passages and their contents to direct attack; removing all diseased bone; and then replacing the nose and lip, and retaining them in position until reunion takes place. This method leaves no external scar, and is said to be effectual. I am unaware that it has been practised in America, but it has been performed by British surgeons.²

Rouge's description of his operation is essentially as follows:

The patient lying with the head inclined to the right, to favor the escape of blood, the surgeon takes his position on the right, seizes the upper lip near the commissure between the thumb and index-finger of the left hand, and lifts it up a little, while an assistant does the same on the other side. The mucous membrane is then incised from the gingivo-labial margin of the first molar of the right side to that on the left, the centre of the incision corresponding to the frenum of the lip, which is divided near its root. The tissues are divided rapidly, until the anterior nasal spine is reached, and the cartilaginous septum of the nose is detached at its base with a stroke of the bistoury. This often suffices, on elevating the nose, to afford space sufficient for introducing the finger into the nasal fossæ and readily exploring them by sight after the bleeding ceases. If insufficient for the purpose, the cartilages of the alæ are divided by two cuts with the scissors at their insertion on the maxilla, and then the nose, completely liberated, is reflected toward the forehead, fairly exposing the anterior orifices of the nasal cavities. If the septum interferes with the free play of instruments, it is separated with the scissors, and there is no longer any obstacle. Necrosed fragments are removed by evulsion or dressing forceps, and carious bone is scraped away with the gouge. The operation being completed, the mucous membrane is touched with nitrate of silver, the parts carefully washed to remove clots and detritus, and the lip is replaced. Reunion takes place without suture. In all Rouge's operations union was complete the morning following. The frenum resumes its normal position, and the only trace of operation is a delicate rosy line at the bottom of the gingivo-labial groove. There is no local reaction, not even a swollen lip, as shown by two photographs taken twenty-four hours after the operation, the patients having walked to the photographer's, twenty minutes' distance from the hospital. There was no general reaction, and no deviation

¹ Nouvelle méthode chirurgicale pour le traitement chirurgicale de l'ozène, Lausanne, 1873.

² For examples, see Haward, St. George's Hospital Reports, Vol. VIII., 1874-6, p. 123; Cripps, The Lancet, May 5, 1877, p. 643, illustrated.

from normal temperature; the only symptom thus far observed, after eight operations, having been a little cephalalgia in a very impressionable young girl, whose ethmoid bone had been scraped, and in whom there had been for two days slight swelling at the root of the nose. In a second operation on one of these cases, undertaken for the removal of a carious portion of the ethmoid bone which had escaped detection at the first operation, the patient succumbed on the sixth day to suppurative meningitis.

NASAL ABSCESS.

Abscess of the nasal mucous membrane is met with in the inflammation resulting from traumatic injury, in that of common chronic coryza, in that of syphilis, and occasionally in idiopathic inflammation the result of sudden exposure to change of temperature. It also occurs in that condition of system which gives rise to ordinary furuncle. These abscesses are developed in the submucous connective tissue, usually not far from the exterior orifice, and they may occupy the septum or the alæ. They may be small, like a little boil, or large enough to occlude the affected nasal passage and press the septum to one side.

The abscess is usually acute, the inflammation sometimes affecting the submucous areolar tissue primarily, and sometimes secondarily, as a result of inflammation of the cartilage of the septum. There is redness with turgescence of the adjacent mucous membrane, swelling, increased secretion, and intense pain. Sometimes the exterior of the nose is swollen, red, and painful, and more or less of the face also, even in some instances to the production of œdema.

Phenomena of fever are present in severe cases, and are proportionate to the violence of the local action.

Treatment.—Left to itself, the abscess ruptures spontaneously in a few days; but the duration of the affection can be lessened by timely incision. If the inflammation is severe, a leech may be applied within the nostril, the animal being secured in a tapering tube to prevent its body from escaping through the orifice. Warm water applications are very beneficial, impregnated with sedatives or astringents.

Syphilitic Abscess is usually a tertiary manifestation, originating by a gummosus deposit, which undergoes softening and ulceration. Its progress is slower than that of acute abscess; it is less painful, and is attended by a less viscid discharge. After rupture of the abscess, the discharge is thicker,

purulent, samous, and offensive. Perforation of the septum is not an infrequent result.

Treatment.—This is the same locally as for ordinary abscess, in the first instance; but the resulting ulcer may require the local application of nitrate of mercury, iodoform, or the like. The patient should be brought under the systemic influence of iodide of potassium.

EPISTAXIS.

(Hemorrhagia Narium ; Rhinorrhagia.)

Bleeding from the nasal passages may be idiopathic, deuteropathic, or traumatic. Sometimes it occurs as a vicarious substitute for suspended menstruation. Frequent epistaxis without apparent cause, and especially if the blood be thin, copious in quantity, and difficult to restrain, is usually evidence of the hemorrhagic diathesis, and under these circumstances may lead directly or indirectly to a fatal result.¹ This form appears most frequently in boys, anterior to or just about the period of puberty. Epistaxis, especially in aged individuals, sometimes seems to occur physiologically in relief to vascular turgescence within the cranium or in the face; and this often affords spontaneous cessation to a determination of blood to the head, and to violent cephalalgia, noises in the ears, vertigo, and sleeplessness, with dryness, heat, or irritation of the nasal passages, and so on. This form of epistaxis is usually from one nostril only, but occasionally from both. The blood may flow in a continuous stream, but more frequently it falls drop by drop.

In some instances bleeding from the nose attends certain diseases at their commencement, such as relapsing, remittent, and typhoid fevers; and indeed, in combination with other symptoms, it is regarded in some measure as pathognomonic of enteric fever; though it is well known to attend other affections, such as the exanthemata, scurvy, purpura, and certain diseases of the spleen. Sometimes it occurs at the so-called critical periods of pneumonia and of various fevers.

¹ Prof. Gross has witnessed loss of life under circumstances of this kind in not less than three instances. *System of Surgery*, 2d ed., Philadelphia, 1872. Vol. I., p. 365.

It may occur in the course of several local diseases, as a result of ulceration, in chronic rhinorrhœa—especially the fetid variety, and it may attend disease of the cartilage or bone, or be connected with the disturbance occasioned by the presence of a foreign body,¹ a polyp, or other growth, or a calcareous concretion, either in the nasal passage itself or in one of the sinuses communicating with it. In some instances it is an early indication of the development of a naso-pharyngeal tumor, or of an intra-nasal osteoma.

Epistaxis may be occasioned by violent sneezing, whether spontaneous, or the result of snuffing up irritating substances. It also follows external injuries, such as a fall upon the part, or a direct blow from the fist, whether there be fracture produced or not. Sometimes it is started by picking at the mucous membrane.

Spontaneous epistaxis sometimes follows exposure to cold, or exposure to immoderate heat after previous exposure to cold.

Impediment to the free return of blood to the heart may give rise to a passive form of epistaxis. This form is witnessed in organic diseases of the heart, hypertrophy of the left ventricle, extensive exudation into the pleural sac, emphysema of the lungs, pressure of goitrous and other cervical tumors. It sometimes occurs in severe paroxysmal cough or dyspnœa. It is also occasionally produced in various affections of the abdominal viscera, such as ascites, ovarian dropsy, and the like, as a result of the pressure exerted upon the diaphragm, impeding free respiration, and thus favoring stasis of the venous circulation.

Hemorrhage from the nose, as from other outlets, has been occasioned by diminution of atmospheric pressure in ascending lofty mountains. Cases of this kind have been narrated by Humboldt as occurring at Chimborazo, by Saussure at Mont Blanc, by Bouguer at the peaks of the Cordilleras, etc. It may also be occasioned by the immoderate use of inhalations of compressed and rarefied air.

Epistaxis has been known to occur among infantry soldiers fatigued by long marches in hot weather.

¹ It has been known to have been occasioned by a leech accidentally detained in the nasal passage.

The bleeding from the nose is usually confined to one passage, simultaneous hemorrhage from both being rather uncommon. When profuse, it may accumulate in the supra-palatine portion of the pharynx, and be in part discharged through the unaffected passage, simulating an apparent bilateral hemorrhage. The blood is usually bright red in color, and coagulates readily; sometimes, indeed, in the nostril from which it is flowing, during the very continuance of the hemorrhage, so that clotted blood is discharged as well as flowing blood. As a usual thing the bleeding is not very profuse, amounting to but few drachms, and soon ceases spontaneously; but sometimes it continues for hours, in exceptional cases for days; and it may at once from its copiousness, or gradually from its continuance, induce syncope, or even terminate fatally.¹ Cases have been narrated in which epistaxis appeared periodically, returning at the same hour every day, like the paroxysm of an intermittent, and, like it, amenable to the influence of quinia. Spontaneous cessation is due to the formation of a coagulum, just as when excessive bleeding is stopped by the tampon; and if the coagulum is dislodged too early by sneezing, coughing, or using the handkerchief, the epistaxis is very likely to become renewed.

Symptoms.—These are evident, after the hemorrhage has begun. The bleeding may be preceded for a variable period by uncomfortable sensations of fulness in the head or face.

Diagnosis.—Care is requisite in certain instances to distinguish epistaxis escaping posteriorly from hæmoptysis; and also from hæmatemesis, which it may simulate from the blood having been swallowed in sleep, and then subsequently ejected by vomiting. In analogous manner the blood of epistaxis, if swallowed and not vomited, may simulate hemorrhage from the bowel.

Treatment.—When epistaxis occurs as a physiological or salutary process, it usually subsides spontaneously. When so profuse as to threaten serious injury, it is necessary to employ mechanical measures of restraint. In cases where it occurs frequently, or recurs several times a day, additional resort is made to the internal administration of astringents and other remedies which tend to contract the blood-vessels.

¹ Gross: *op. cit.*, p. 366.

The local action of cold applied to the parts affected, or to the neighboring parts, constricts the blood-vessels and favors clotting, for which purpose use may be made of cold water, or ice-compresses, or ice-bags, which are still better, placed upon the nose, the forehead, or the nape of the neck. The familiar remedy of placing a street-door key upon the skin of the back acts somewhat on the same principle, although part of the influence of this and similar measures is attributable to the reflex action of cold upon the vaso-motor system of nerves.

The bleeding can often be arrested mechanically by simple pressure upon the nostril maintained during several minutes; especially if the bleeding is from the artery of the septum, which can be readily compressed in this manner. Valsalva recommended the introduction of the patient's finger into the bleeding nostril, which gives a better chance to reach the bleeding vessel and compress it. Dr. Marin, of Geneva, states¹ that as the blood in epistaxis generally flows from one nostril only, and most frequently from the anterior third of one of the nasal fossæ, he was led to believe that by compressing the corresponding facial artery on the superior maxillary bone near the ala of the nose, the afflux of blood would be diminished, and the hemorrhage be arrested at once. He had tested this plan in very many serious hemorrhages from the nose, and the expedient had proved promptly and thoroughly successful. The amount of blood passing to the bleeding vessels can sometimes be diminished by raising both arms above the head, and thus favoring the formation of a clot, forcing the blood reaching these parts to mount against gravity, and thus lessen the pressure upon the bleeding vessels. An excellent method, acting upon a combination of the latter plan and digital compression of the nostril, was proposed by Dr. Négrier.² It consists in compressing the bleeding nostril by the finger of the opposite hand, and raising the arm of the affected side high above the head.

Dr. Chapman recommends his water-bag between the shoulders, the water being at a temperature of 105° F. This acts upon the derivation principle of encouraging an increased cir-

¹ Jour. de méd. et de chir. prat., May, 1872; Union méd., May 25, 1872; Am. Jour. Med. Sci., July, 1872, p. 266.

² Arch. gén. de méd., June, 1842, p. 168.

culation of blood at a distant surface. For a similar purpose the mustard-plaster has been applied over the stomach, or upon the ankles. Junod resorted to his famous boot, which produces an extensive dry cupping of the leg. Others produce a distant hyperæmia by confining the blood in one of the extremities, compressing the limb with a ligature above the knee or above the elbow.

Simple mechanical measures or the local application of cold failing to restrain the hemorrhage, resort must be made to the local application of mineral or vegetable astringents. These may be injected into the parts in solution, or be propelled upon them in powder; or they may be applied by means of pledgets of oakum, lint, raw cotton, or bits of sponge soaked in the solution, or sprinkled over with the powder; or, as recommended by Dr. W. W. Leeper,¹ in the form of soluble bougies similar to suppositories, so that, as the soluble bougie melts, the styptic gradually comes in contact with the bleeding surfaces. The hæmostatics usually employed are ice and the ordinary astringents, such as alum, sulphate of zinc, acetate of lead, sulphate of iron, chlorate of iron, or solutions of tannic or gallic acid, and decoctions of krameria and other astringents.

An obstinate case of epistaxis recurring almost daily, and often several times a day, for more than a year, occurring in a young scrofulous adult male, sent to me for treatment in 1873, yielded promptly and apparently permanently, for there had been no recurrence up to 1878, to the injection night and morning, for several weeks, of a drachm of a solution containing one scruple of tannin dissolved in two ounces of ice-water, with an ounce of the compound tincture of benzoin; the amendment commencing with the very first injection. The only pathological condition detected was an immense hypertrophy of the lower turbinated bone of the side from which the hemorrhages came, so that it projected out of the posterior nasal outlet and a few lines beyond the septum; looking, in fact, very much like a morbid growth.

A method of applying the styptic proposed by Créquy² consists in fitting a canula two and a half inches in length, and with a rounded extremity, to an ordinary syringe, the canula being perforated its entire length by a series of small holes arranged in spiral succession, and directed backward so as to emit small retrograde jets. When the canula is introduced

¹ Dub. Jour. Med. Sci., Nov., 1873, p. 364.

² (Union méd.), Dub. Jour. Med. Sci., Oct., 1877, p. 366.

horizontally into the nasal passage, and the syringe filled with a solution, say of the perchloride of iron, the injected fluid is thrown upon the mucous surfaces of the passage and does not fall upon the pharynx.

When internal remedies are requisite to prevent recurrence of bleeding, we select the direct hæmostatics and other articles of the *materia medica* which produce contraction of the small arteries. Thus, we administer tincture of the chloride of iron, ergot in tincture or in fluid extract, turpentine, bromide of potassium, belladonna, hamamelis virginica, and so on. These remedies are given at frequent intervals, and in small doses. Ergot is sometimes administered hypodermically. If the epistaxis is decidedly periodic, quinia is indicated internally.

During this treatment, rest of body and mind must be enjoined, with the maintenance of the recumbent or sitting posture, and the avoidance of such movements as bring the head forward. All constrictions of the clothing about the neck, chest, and abdomen should be removed. The patient should refrain as much as possible from loud talking, coughing, sneezing, snuffing, and the use of the pocket-handkerchief. The food taken, while nutritious, should not be stimulating, nor too warm; and when all disposition to epistaxis has ceased for the time, a somewhat similar, though less rigid regimen, should be kept up for some days, care being taken to promote the due action of the skin, kidneys, and bowels.

Any local disease or injury causing epistaxis should meet with prompt attention.

When the epistaxis cannot be restrained by ordinary means, or where it is very copious, resort must be had to the tampon for the purpose of plugging up the passages, and thus favoring the formation of a clot. Plugging the nostrils anteriorly is done easily enough, but occluding the nares posteriorly is much more difficult. When no special instrument for this purpose is at hand, a doubled wire, a flexible eyed-catheter or probe, or a substitute made of whalebone, after having been warmed and greased, is passed along the floor of the nose into the pharynx, whence it is drawn into the mouth by the finger. A stout thread, which has been previously secured to a small roll of lint or a piece of sponge, is now attached to the eye of the probe, catheter, or the loop of the wire, and the latter is withdrawn from the nostril, carrying the thread of the tampon with

it, and, as the thread is drawn upon, the passage of the tampon behind the palate and against the posterior outlet of the nares is assisted by the forefinger of the operator.

I have adapted Dr. Steele's elastic probe, a wire covered with elastic material to give it bulk without impairing its flexibility, as a guide to the tampon by having the eye made of flexible silver, or of a loop of the wire, instead of leaving it rigid. The probe being bent in the arc of a circle and a thread passed through its eye, the blunt portion is carried along the floor of the nasal passage and pushed onward until it appears in the pharynx, whence it is drawn out through the mouth and detached from the thread which has followed it, and to which the tampon is then to be affixed. The advantage of this flexible instrument is that there is no necessity to withdraw it along the floor of the nose, as is requisite with other contrivances; thus avoiding local irritation, and saving time, which is sometimes of greater importance. The delicate calibre of the probe permits its easy use in small children and in very contracted passages. It may be readily passed through the middle meatus, securing more effectual occlusion by the tampon.

A special instrument, much used for tamponing the nasal passage, is the canula of Bellocq (Fig. 92); but it is a superfluous instrument in most instances. It consists of a metallic tube, which is to be passed through the nostril into the phar-

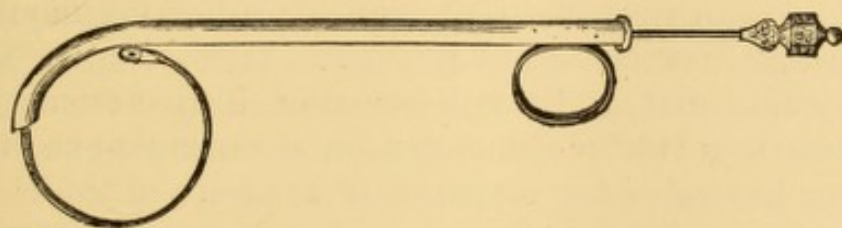


FIG. 92.—Canula of Bellocq, for tamponing the posterior nares.

ynx; a rod on the exterior, when pressed upon, forces a steel spring into the mouth; to this steel spring a perforated knob is soldered, affording a means of attachment for the thread which is to carry the tampon against the posterior nares. After the thread is secured, the instrument is withdrawn, carrying the tampon with it.

Prof. Fano ties several pledgets to the string of his posterior tampon, in order to have one or more reserves in case the first one should fail to effect thorough occlusion of the passage.

After the tampon is drawn home, an anterior nasal plug is inserted, and the ends of the double thread attached to the tampon are tied over it. If both passages need occlusion, the guide should be passed on both sides before either plug is drawn home.

The tampons should be carefully removed with the forceps and probe, after the lapse of forty-eight hours, and the nostrils well cleansed by means of the syringe; and if there is any return of hemorrhage, fresh tampons are to be applied. Prof. Gross mentions¹ that he has seen several cases terminate fatally, with low fever and delirium, from systemic poisoning produced by too long a retention of the plugs; and he refers, in the same connection, to a case met with by Prof. Colles, of Dublin, in which the retention of a tampon induced tetanus.

Dr. Kuchenmeister has devised a rhineuryntor, consisting of a rubber tube terminating in a rubber ball. The ball being forced through the nasal passage into the pharynx, is distended with water injected through the tube, and retained by a stop-cock, and then pulled forward. It does not occlude the passages accurately. A correspondent of the *London Lancet*² suggests the use of a rubber tampon distended with air, similar in construction to the air-pessary. Dr. Englisch has devised one of these contrivances, consisting of two balls united by tubing, the additional ball to remain at the external orifice, and occlude the passage anteriorly.³ The connecting tube being short, the posterior ball cannot project far beyond the posterior orifice of the nasal passage. These rubber balloons are easily ruptured, and soon become defective from age. In the absence of a rubber rhineuryntor, the œsophagus of one of the lower animals—for instance, of a sheep—may be passed through the nasal passage, and then be forcibly distended by an injection of cold water, as successfully practised by Dr. D'Arcy, of Jerseyville, Illinois, and Dr. J. W. Thompson, of Lovelaceville, Ky.⁴

In cases of excessive loss of blood by epistaxis, transfusion is sometimes requisite.⁵

¹ Op. cit., 5th ed., Vol. ii., p. 366.

² Dec. 21, 1872, p. 910.

³ Allg. Wien med. Ztg., 1875, p. 191; *London Med. Record*, June 30, 1875, p. 406.

⁴ *Med. and Surg. Rep., Phil.*, June 23, 1860, p. 250.

⁵ For example see Mortol: *Am. Jour. Med. Sci.*, July, 1874.

SYPHILITIC AFFECTIONS OF THE NASAL PASSAGES.

These are often manifestations of secondary syphilis, the disease being usually confined to the mucous membrane. They are generally attributed to mucous patches. There is chronic coryza, the matters of the discharge being viscid, yellowish or greenish in color, sometimes sanguinolent, and, as a rule, more copious in the daytime than at night, perhaps on account of unconscious deglutition of portions of the discharge during sleep. There is no ulceration of the mucous membrane at first, but it is almost certain to occur if the progress of the affection is not arrested; and when ulceration has taken place the discharge acquires an offensive odor. There is thickening of the mucous membrane from inflammatory swelling and infiltration, producing pain and a sense of obstruction to nasal respiration. Much of the discharge passes anteriorly, but some of it is apt to be hawked into the pharynx, and may often be seen clinging upon its posterior wall, behind the palate, in thick yellowish or greenish clumps. These decomposing masses irritate the mucous membrane of the pharynx, which eventually becomes involved in the inflammation, and undergoes ulceration; and in this way the disease may be propagated to the Eustachian tubes in the one direction, and to the larynx in the other.

In the tertiary form of the disease, ulceration of the mucous membrane takes place, sometimes starting from gummata, and gradually extends into the cartilaginous and osseous structures, eventuating in necrosis and discharge; permanent deformity of the nose following from loss of its bony support.

The abscesses formed during the inflammatory results of the efforts of nature in the exfoliation of the necrosed nasal bones sometimes rupture externally. Sometimes the syphilitic disease of the bones infects the overlying tissues, producing inflammation and abscess without any process of exfoliation. The external soft tissues often undergo great destruction, producing that condition known as syphilitic lupus. In a case of this kind reported by Dr. Durkee, of Boston, the cryptogamic parasite, *sarcina ventriculi*, was found in abundance in the discharge from the nostrils.¹

¹ Am. Jour. Med. Sci., Jan., 1854, p. 96.

Necrosed bones may be swallowed in sleep, and obstruct the œsophagus.

Langenbeck records the case of a woman, with syphilitic caries of the nasal bones, who thus swallowed, during sleep, both inferior turbinated bones, the vomer, and the left side of the nasal bone, all adherent to each other.¹

Symptoms.—These are much the same as those of chronic fetid coryza.

Diagnosis.—This is based on anterior and posterior inspection after cleansing, and on the history of the case.

Treatment.—The secondary manifestations of the disease are managed by local ablutions with the douche or syringe, and, if necessary, the internal or cutaneous use of mercury. The tertiary form of the disease requires the local application of mercurials and detergents in addition to ablutions, and the internal administration of the iodide of potassium and the bichloride of mercury; while dead bone must be removed where possible. (See Fetid Coryza.)

STENOSIS OF THE NASAL PASSAGES.

Occlusion of one nasal passage is sometimes due to great deflection of the septum, the left side being the affected one in most instances. In some instances the nostrils are more or less completely closed by membrane,² in others by firm fibrous tissue, or by simple continuity of integument, while in other cases, one ala or both may be adherent to the septum or to the upper lip.³ In the treatment of this class of cases no more is usually required than to make a suitable incision, and to keep the surfaces apart, by pledgets of lint or the insertion of a canula, until the parts are healed. Constriction and occlusion of the nostrils may be the result of inflammation, of accident, or disease. I have seen it follow fracture sustained in pugilistic encounter, and also contraction following ulceration. The mucous membrane is thickened in these cases from interstitial deposit, and where this is the case the difficulty can often be overcome by pulling off patches of mucous membrane so as to leave raw wounds of some size. As the edges of these sores

¹ Memorabilien, Jahrg., xxii., H. 1; N. Y. Med. Jour., July, 1877, p. 97.

² Richerand: Nosographie Chirurgicale, 4th Edit., tome II., p. 156.

³ Durham: in Holmes' System of Surgery, Vol. 4.

cicatrise, a contraction of the sides of the nostril takes place, thereby permanently increasing the calibre of the tube. The operation is painful and bloody. The repeated employment of compressed sponge, or tubes of laminaria, increase the dilatation and maintain it; but their use must sometimes be persisted in for months together, with occasional resort to them afterwards. In some instances it is necessary to remove more or less of the middle turbinated bone in order to secure a free passage for the air through the nostrils.

Occlusion of the nostril may occur as a result of small-pox, as in the case of Brown, mentioned in connection with the subject of concretions in the nasal passages.

Fracture of the nasal bones and fracture of the nasal cartilage sometimes produce more or less occlusion of the nostrils, either as an immediate result of the accident, or as an effect of the inflammation following. When such a result is to be apprehended, the nostrils may be kept sufficiently pervious for respiratory purposes, during treatment, by the use of metallic tubes inserted into them.

CONGENITAL OCCLUSION OF THE POSTERIOR NARES.

Congenital occlusion of the posterior nares is occasionally met with.

In one instance of this affection, in an infant under my own observation, there was great difficulty in suckling and breathing, and frequent suffocative paroxysms. An opening was made from the nostrils into the pharynx by boring through the occluding structures with a knife and a steel probe; and this passage was kept open, and enlarged from time to time by the insertion of a sound, and subsequently of small bits of sponge securely fastened to a holder. In this way passages were made representing the lower and middle meatuses. The operation was always attended with considerable hemorrhage, and was a frightful one in appearance, from the struggles of the child, the spattering of the blood, and the suffocative spasms that it produced. As soon as a permanent passage was secured, the child's nutrition improved at once, and markedly.

Dr. Carl Emmert has narrated¹ a case upon which he operated successfully. It was a seven-year-old boy, who from birth had been unable to breathe through the nose, and who had been nourished only with great difficulty when an infant. He was subject to attacks of suffocative paroxysms in his sleep. The nose was well formed, but the choanæ were entirely closed. Not the slightest stream of

¹ (Lehrbuch der Chirurgie, Stuttgart, 1853, Bd. II., p. 355.) Luschka: Der Schlundkopf der Menschen, 1868, p. 27.

air was perceptible at the nostrils. Mucus was continually running from them, and on weeping, the discharge was accompanied by a stream of tears. The closure of the choanæ was due in this case, as shown by a preliminary examination with the sound and as confirmed during the operation, to the presence of a bony wall or partition, covered on both sides with mucous membrane; but it was impossible to ascertain in what manner or from which bones this complete anterior wall of the naso-pharyngeal space took its origin.

Luschka, in continuation of the subject, narrates the following case which occurred under his own observation: It was a female infant who died shortly after birth. The bony framework was formed, on both sides, from the palatine bone. The free sloping border of the normally sized horizontal portion was continued in the form of a thin compact plate which inclined somewhat outward and backward, and rose up as high as the inferior face of the sphenoid bone, with which it was connected by a dentated border. The plate of bone rested with sharp border upon the median side of the internal laminae of the wings of the sphenoid. In the middle line, where, in the normal condition, the nasal spine arises, the lamella joined with that of the opposite side; while both, in their further course upward, were separated by a very narrow fissure, in which the posterior border of the rudimentary vomer had its attachment.

Voltolini mentions a case of total occlusion of the right posterior outlet,¹ apparently due to congenital adhesions, and long mistaken for nasal tumor. The true condition was revealed on rhinoscopic inspection, and was submitted to operation by the galvano-cautery.

Betts² reports a case in a fœtus of seven months, in which the posterior nares were imperforate in consequence of the presence of two triangular bones articulating above with the sphenoid, below with the horizontal plate of the palatine bone, exteriorly with the lesser wings of the pterygoid apophyses, and impinging on each other interiorly, so as to leave a median fissure.

FOREIGN BODIES IN THE NASAL PASSAGES.

Children very often insert foreign bodies, such as peas, beans, small stones, hair-pins, etc., into the nasal passages, which, if discovered, or acknowledged by the child, are very readily removed. Sometimes they are forgotten, and remain impacted for years, keeping up, well into adult life, an irritating and often offensive discharge, which is supposed to be due to nasal catarrh of scrofulous origin. The foreign body usually becomes incrustated with calcareous matter, and sometimes forms the nucleus for a veritable calculus; and it may eventually produce necrosis of one or more of the turbinated bones, necessitating their removal, at which time the cause of

¹ Die Anwendung d. Galvanocaustik, etc., 2d ed., Wien, 1870, pp. 240, 262.

² Arch. de Toxicologie, Sept., 1876; N. Y. Med. Jour., July, 1877, p. 97.

the life-long discharge is discovered to have been the presence of an impacted foreign body, unsuspected or long forgotten.

A foreign body is rarely introduced into the nostrils of the adult except by accident, the exceptions being confined to patients with hysteria or insanity. Detached fragments of necrosed or broken bone are often foreign bodies to all intents.

Occasionally the foreign body is an insect which has crawled into the nostrils from without; a leech; or a human parasitic worm which has crawled into the posterior nares from the stomach. In cases of the latter kind, the parasites, usually ascarides, may crawl into the frontal sinus, producing intense headache, and leading to delirium, which may end fatally. They have also been known to produce epilepsy. The older physicians used to attribute bad cases of ozæna, attended with severe pain in the frontal region, to the presence of insects or their larvæ in that situation.

Symptoms.—There is more or less obstruction to respiration or olfaction; more or less discharge, fetor, pain, and external deformity.

Diagnosis.—Strict inquiry as to the presence of a foreign body should always be instituted in every case of offensive discharge from the nostrils. It is the duty of the medical attendant to wash the parts thoroughly, and then examine them carefully with a good light, both by inspection anteriorly, and, where practicable, posteriorly also.

Usually, the presence of a foreign body in the nostril produces inflammatory action, the amount of which will be dependent a good deal upon the shape of the body and the character of its edges. If it be sharp, spiculated, or irregular, the irritation provoked will be much greater than when it is smooth in contour. This inflammation will result in a catarrh likely to simulate ordinary chronic coryza, with copious secretion of pus. If the foreign body be of a large size comparatively, or be of such a character as to imbibe moisture at the place of impaction, the nose will become distended out of shape, and the pain and other local symptoms will increase in severity. Sometimes ulceration will be set up in the parts against which the foreign body is lodged, and this will complicate the existing condition of things.

When foreign bodies remain in the nasal cavities for a long time, they are apt to become incrustated with the saline portions

of the serum which is secreted in consequence of the irritation they produce, and in this way they form the rhinoliths or nasal calculi sometimes found in this region. These formations may remain very small, or increase by accretion to the size of a hazel-nut, or even larger.¹ Sometimes they are discharged spontaneously, but it is generally necessary to extract them with the forceps or by other surgical procedure. The probe is usually required to detect their presence, though sometimes they are exposed to inspection on distending the nostril.

Treatment.—A foreign body in the nasal passage should be removed at the earliest moment. In some instances it can be dislodged in the act of sneezing, excited by snuff, by tickling the mucous membrane with a feather, or by some other means. The injection of a strong stream of water through the nares, from behind forward, by means of the posterior nasal syringe, or the douche of Thudichum passed from the opposite nostril, will sometimes succeed in driving the foreign body out the same road by which it entered. If the nasal douche be employed for this purpose, the reservoir should be placed quite high above the head, so as to lend sufficient propelling force to the current. A stream of water from the hydrant may be employed, conveyed through a rubber hose and a properly curved rigid tube. Curved bougies or catheters may be passed from behind forward, in the hope of getting in the rear of the obstacle and pushing it toward the exterior. Where the foreign body is impacted, and there is danger of pushing it farther on by the use of instruments inserted anteriorly, attempts should be made in the manner indicated to push it out forward from behind. This is a much better plan than the opposite one sometimes employed—an endeavor to push the body on into the pharynx, and then extract it through the mouth.

Unless the foreign body be favorably situated and of suitable shape, the forceps should not be used to extract it, on account of the danger of pushing it farther on, and thus impacting it more firmly in the very attempt to grasp it. This is particularly apt to be the case with bodies of rounded or smooth contour, such as beans, peas, beads, and the like. A much better method of extraction is to attempt to pass a slen-

¹ For unusually large examples, see Verneuil: *Gaz. des Hôp.*, 1859, p. 152. Brown: *Edinb. Med. Jour.*, 1859, p. 501.

der hook or wire loop behind the body, and draw it forward. The little rectangular hook, and the screw, devised by Prof. Gross for the removal of foreign bodies (Fig. 93), are both most admirable instruments for this purpose, being sufficiently delicate to be insinuated between almost any obstacle and the wall of the passage. The method adopted for removal of bodies impacted in the external auditory meatus, by placing a brush loaded with glue or other adhesive fluid in contact with it, and allowing it to remain until firmly adherent, so that the brush can be used as a tractor, is also applicable to the removal of certain classes of foreign bodies from the nasal passages, the hairs in the nostril being previously protected by the insertion of a tubular speculum.

The mechanical ingenuity of the surgeon will often be put to the test in devices for the removal of foreign bodies of diverse character from the nasal passages. The rule should always be to avoid unnecessary injury to the parts. If the foreign body be composed of parasites, it is advised to kill them first by the injection of vapors of alcohol, chloroform, or turpentine; or by the injection of the vermifuges employed to kill worms in the intestines. These parasites have been known to penetrate into the frontal sinuses; and in one instance,¹ to have necessitated trepanning the sinus, in order to be able to extract them.

Dr. C. Coquerel reported² five cases in which the larvæ of diptera in the nasal passages and frontal sinuses produced violent symptoms, followed by death in three of the cases. In most of the cases, several hundred larvæ were evacuated by ulceration and necrosis of parts investing the cavities. These cases occurred at the convict hospital at Cayenne; and it is supposed that the larvæ were the issue of eggs deposited in the nasal fossæ by a peculiar fly, and not parasites. In the original article Dr. Coquerel quotes several analogous cases from authors who had observed similar occurrences in Europe.

A somewhat similar case was communicated many years ago to the Philomathic Society, by M. Jules Cloquet.³



FIG. 93.—Gross's instruments for removal of foreign bodies from the nasal passages.

¹ Trélat: *Gazette Hebd.*, 1867, No. 51, p. 814.

² (*Arch. gén. de méd.*, May, 1858; *Brit. and For. Med.-Chir. Rev.*, Oct., 1858.)
Am. Jour. Med. Sci., Jan., 1859, p. 255.

³ *Am. Jour. Med. Sci.*, May, 1828, p. 228.

To remove foreign bodies of long standing, when the usual means of extraction have proved unsuccessful or are unavailable, it is sometimes necessary to gain direct access to the point of impaction by means of an external incision—either by Vidal's division of the wing of the nose, Dieffenbach's division in the middle line, or Rouge's inversion by an incision practised at the gingival margin of the upper lip.

To extract foreign bodies impacted in the frontal sinuses, it has been proposed to divide the nose at its root, and turn it over upon the face, or to practise the incision devised by Rouge.

CALCAREOUS ACCRETIONS IN THE NASAL FOSSÆ (RHINOLITHS).

Nasal calculi, or rhinoliths, are usually due to some hard foreign body forced into the passage in childhood, eventually becoming a nucleus for calcareous deposits. Some of them originate in deposits of inspissated mucus, or detained sanguinolent secretions from the inflamed mucous membrane. They are generally movable, and readily broken into fragments, being usually composed of phosphates of lime and magnesium, chloride of sodium, and carbonates of lime, magnesium, and sodium.¹

Sometimes there is no apparent cause for them whatever, unless it be the gouty diathesis, their development being analogous to that of gouty concretions in the membrana tympani.

These rhinoliths vary in size, from the bulk of small shot to that of hazel-nuts, and they may obstruct the nasal passage completely, pressing the septum before them so as to encroach upon the calibre of the other passage.

Symptoms.—They give rise to the ordinary symptoms of obstruction and irritation, with frontal or nasal pain, constant or intermittent; and may induce severe inflammation, with a copious muco-purulent discharge. Sometimes small concretions are discharged into the handkerchief. Sometimes these concretions keep up local suffering for years. Even periodical hemicrania, terminating by the evacuation of a nasal calculus, has been recorded.²

¹ Demarquay : Mémoires sur les calculs nasaux. Archives générales de médecine, 4 Ser., Vol. VIII., p. 174, June, 1845.

² Axmann : (Heidelberg klin. Annalen ; Arch. gén., May, 1829) ; Am. Jour. Med. Sci., Vol. V., p. 204.

Diagnosis.—Due visual examination anteriorly and posteriorly sometimes reveals these concretions. They are recognized, too, by palpation on careful probing of the walls of the cavity and the surface of the turbinated bones. Care must be taken against mistaking them for exposed bone or osseous tumor. The exploration should be preceded by due syringing, to wash away the secretions of the parts as thoroughly as may be; and, with a view to possible detachment, it is well to begin the cleansing process with the posterior nasal syringe.

Treatment.—This consists in removal of the concretions, often a matter of considerable difficulty. When quite accessible, delicate polyp or dressing forceps suffice. Mr. Durham, of London, has suggested forceps constructed with detachable blades, similar to midwifery forceps. When the calculus is large and likely to injure the soft parts in its removal, it may be crushed or drilled, in order to facilitate extraction, and the débris washed out from behind by a stream of water from the posterior nasal syringe, or from a nasal douche entering by the opposite nostril. In some instances the point of a knife may be passed under the edge of the calculus a short distance into the soft parts, and the calculus be then pried out in part by a blunt instrument.

Occasionally the concretion may be pent up, in consequence of adhesion of the nostrils.

Wm. H. Brown¹ has reported the case of a patient whose nostrils were closed by cicatricial tissue, the result of small-pox in childhood. An incision through the occluding membrane enabled him, without difficulty, to extract the stone, which weighed three drachms and thirty-three grains.

Voltolini relates a case² in which a pent-up concretion, in the nasal passage of a child four years of age, simulated congenital occlusion of the posterior naris, and had long been treated as a nasal tumor.

TUMORS OF THE NASAL PASSAGES.

Tumors are frequently developed in the nasal passages and in their communicating cavities and sinuses. * The majority originate from the mucous membrane, and others from the perichondrium or periosteum.

¹ Edin. Med. Jour., Vol. V., p. 50.

² Die Anwendung der Galvanokaustik, etc., 2d Ed., 1872, p. 240.

Myxoma.—This is the most frequent variety of tumor developed in the nasal passages. It constitutes the gelatinoid polyp. It originates in an enlargement of the acinous glands, the mucous membrane itself becoming hypertrophied and drawn out so that a narrow pedicle is formed, the tumor acquiring somewhat the configuration of an oyster or a fresh-water polyp. It is of a dull, dingy white color, is soft in consistence, smooth in surface and glistening, and it hangs downward into the nasal passage, or, and less frequently, backward into the pharynx. It is usually attached to the upper turbinated bone, less frequently to the middle one, and rarely to the lower one; occasionally, too, to the septum.¹ It varies in size from the bulk of a small bean to a magnitude sufficient to obstruct respiration completely, or to distend the nose out of shape. It is occasionally solitary, but much more frequently multiple. Occasionally great masses of smaller growths come into view after the extraction of one large polyp—masses which, after evulsion, are much more voluminous than the capacity of the cavities in which they accumulated; their soft consistence having admitted of close packing in the recesses of the nasal cavities.

These polyps swell in damp weather, the hygrometric nature of their contents favoring absorption of moisture. They sometimes become encrusted with calcareous deposits, and may be mistaken for osseous tumors. The immediate cause of these developments is unknown. They are usually the sequence of chronic inflammation of the mucous membrane terminating in hyperplasia, with newly organized material developed in the submucous connective tissue. They are more frequent in adults than in children, and in males than in females. Though essentially benign clinically, they sometimes become the seat of malignant degeneration.

Fibroma.—This variety of tumor is less frequent. It is red in color, denser in consistence than the myxoma, more irregular in contour, larger in bulk, and usually attached by a broad base, though sometimes by a pedicle. It is generally single, and takes its origin in the submucous connective tissue, or in the perichondrium or periosteum, as the case may be.

¹ For recent example see Mr. Davies-Colley: Guy's Hospital Reports, Brit. Med. Jour., June 30, 1877, p. 810.

It is uncertain how long this tumor may exist before it attracts attention, but its increase in bulk is rapid after it has once reached a size sufficient to excite notice. It is liable to expand in every direction, protruding into the pharynx, and sending out prolongations into the neighboring sinuses, where its subsequent development produces a characteristic deformity of visage denominated "frog face." In its gradual enlargement it pushes aside the septum of the nose, and even separates the connecting sutures of the adjacent bones; sometimes, indeed, producing absorption of the osseous base of the skull, and breaking through into the orbit or even into the cranial cavity. It is apt to degenerate into sarcoma; and when removed, is apt to be followed by it.

Adenoma.—This variety of growth is still less frequent. It is developed from the glands of the mucous membrane, may attain great size, and extend to the smallest anfractuositities of the nasal passages and adjacent sinuses.

Papilloma.—This is infrequent, and usually developed near the orifice of the nostril.

Neuroma.—A nerve-tumor is occasionally developed in the nasal passages, and is liable to be mistaken for mucous polyp.

A tumor of this kind, in a patient who died of arachnitis ten days after a third ineffectual attempt to remove it,¹ was found to be located in the neurilemma of the second branch of the fifth nerve, which, immediately after its passage through the foramen rotundum, was converted into a fibrous mass divided into five lobes, two of which were the size of a peach-stone, the others being smaller, and one of them reaching the orbit through the spheno-maxillary fissure. The fibrous tumor was situated in the temporal fossa, and had entered the nasal passages through the spheno-palatine foramen, which had become sufficiently enlarged to admit the passage of the little finger. The substance of the nerve was unaltered except from pressure.

Ecchondroma is occasionally developed in connection with the nasal septum.

Osteoma is occasionally developed in the nasal passages and in the sinuses communicating with them.² These neoplasms

¹ Greco (Ann. di med. fasc., Feb., 1830): Am. Jour. Med. Sci., 1831, p. 227.

² For an elaborate account of these tumors, see Olivier: Sur le tumeurs osseuses des fosses nasales et des sinus de la face, Paris, 1869.

are not mere exostoses or osseous sarcomata, but are true bony tumors formed either of cancellated or compact tissue, wholly unconnected with the normal bone, and developed primarily in the submucous or fibrous tissues. The surface may be uniform or nodulated, nodulation being a special characteristic of the eburnated variety. The pressure of the tumor on the normal bony structure may lead to its absorption, but the tumor remains essentially a distinct growth. These tumors increase slowly in size, producing great deformity; dislocating the eyeball if in proximity to the orbit. Their pressure upon the nerve-tracts eventually excites intense pain, which may involve all the branches of the fifth pair. When they have acquired considerable bulk the tumors may be detected by the finger in the nasal passage, or may even become visible exteriorly. At first they are covered by mucous membrane, but this gradually gives way and the osseous nature of the morbid growth can be detected by the touch. Sometimes they remain quiescent for years and then take on fresh development. They usually occur early in life, generally between the ages of twelve and twenty. When extirpated there is little likelihood of recurrence.

Epithelial and Medullary Carcinoma sometimes implicate the nasal passages, but usually originate outside of them. These tumors eventually involve all the adjacent tissues and cavities.

Symptoms.—The symptoms of a tumor in the nasal passages are those of chronic coryza, eventually followed by more or less obstruction to nasal respiration, sometimes hemorrhage, sometimes deformity; and these symptoms become pronounced so gradually that professional attention is not often solicited until the growth has gained considerable size. Tumors are rarely attended with pain, but there is an annoying sensation of stuffing-up of the nostrils, or obstruction at the posterior nares, more marked at irregular intervals, most frequently during change of moisture in temperature. These sensations induce sneezing, hawking, nasal secretion, and a frequent desire to use the handkerchief. Sometimes these symptoms resemble those of asthma so closely as to mislead an unobservant attendant to an incorrect diagnosis. The sense of smell becomes impaired,

and diminishes in acuteness with the growth of the tumor, with loss of as much of the sense of taste as is dependent on integrity of smell. The voice acquires the peculiar, so miscalled, nasal twang. Respiration is often carried on through the mouth exclusively, especially during sleep. If the tumor encroaches upon the outlet of the nasal duct, epiphora may be produced, and even lachrymal abscess. If it encroaches upon the pharyngeal orifice of the Eustachian tube, there may be more or less impairment of hearing. If it encroaches upon the soft palate or the middle portion of the pharynx, there will be more or less impediment to deglutition. If it obstructs the outlet of the maxillary sinus, the development there of a cystic or other morbid growth may be induced.

Tumors are apt to be attended by chronic catarrh, and there is a more or less constant discharge of mucus, or of mucus and pus, not infrequently sanguineous, if the tumor is vascular and its vessels delicate. Osseous, carcinomatous, and fibroid tumors are often accompanied by the more familiar myxoma or gelatinoid polyp, and, in some instances, the existence of the more serious growth is not detected until the removal of unimportant ones. Pedunculated tumors are often felt to move backward and forward with forced efforts of nasal inspiration and expiration. When the tumor is large and of soft consistence, portions become detached and are expelled by sneezing or, by blowing the nose.

Diagnosis.—Inspection anteriorly and posteriorly is usually sufficient. A pedunculated tumor, so deeply situated as to be inaccessible to illumination anteriorly, can sometimes be thrust forward by the finger or a curved sound passed through the pharynx into the posterior nares. Other tumors are immobile, or but slightly movable. Digital and mechanical palpation, with probes and the exploring needle, will give indications concerning the consistence, seat, and point of implantation of the tumor. Osseous tumors are immovable, and hard in their entire extent. Fibromas and osteomas are apt to bleed freely on digital manipulation.

Treatment.—The operative removal of nasal tumors is indicated in most instances. As a rule, they are not amenable to any other treatment, though numbers of instances are recorded of their destruction by astringents, cauterization, and electrolysis. Cures have been reported from repeated applications

daily of the saffronized tincture of opium¹ (Pr. Pharm.); gallic acid; tannin,² alone or in combination with burnt alum, borax, sugar, or camphor; alcohol; lime-water; sulphate and chloride of zinc; tincture of iodine, etc. Astringents, though incompetent for the destruction of the tumors, are capable of modifying the catarrhal condition of mucous membrane which attends

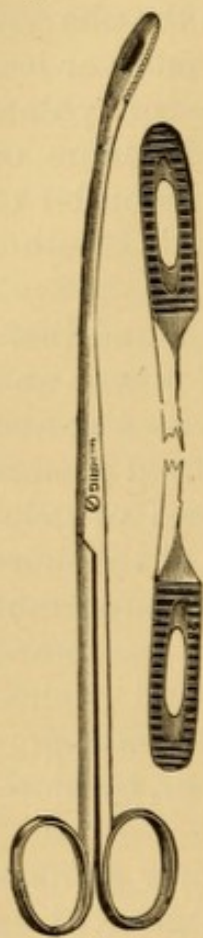

FIG. 94.—Gross's polypus-forceps.

them, and are therefore efficient local applications after radical operation. The myxoma and the pedunculated fibroma are usually removed by torsion with slender but strong forceps (Fig. 94), passed well over the pedicle of the growth, so as to tear it from its attachments. This should be done under good illumination, and not under mere guidance of the sense of touch. If several tumors are present, it is considered best to remove them all at one sitting, if this be possible. The blood lost in these operations is usually washed out by syringing. If the hemorrhage is at all profuse, astringents and ice are applied locally; and, if these fail, the nostrils are plugged back and front. This process of twisting is painful, and, though not so apt to injure the mucous membrane, or detach a portion of a turbinated bone, as when the tumor is forcibly pulled from its attachments, the latter accident occasionally occurs. The liability to this accident may be avoided by passing a wire snare over the growth, and cutting through the pedicle by drawing the loop home into the canula, or perforated rod,

through which it has been passed. The galvano-caustic loop is also used for the same purpose, and has the advantage of being less productive of hemorrhage. Care is requisite to carry the loop close to the point of attachment, which is best done by pulling the tumor into the grasp of the loop by means of nasal forceps.

When the tumor is deeply situated, or hangs into the pharynx, it may be encircled by a loop of wire passed through the nose into the mouth. It should previously be secured by

¹ Primus (Med.-chir. Ztg.; London Med. and Phys. Jour., Jan., 1828): Am. Jour. Med. Sci., Vol. II., p. 219.

² Bryant: The Lancet, Feb. 23, Aug. 24, 1867; Gaz. hebdomadaire, Oct. 11, 1867, p. 653.

a strong thread passed through its substance, if possible, to maintain control of it during manipulation. The ends of the nasal wire being held by an assistant, or by the patient himself if the operator is unassisted, the finger is then carried behind the palate, and the loop drawn out in front of the growth, after which it is pushed under the mass, and then behind, so as to encircle it, and then pushed up behind the tumor as far as possible, as the wire is drawn out of the nostrils again. As soon as it is firmly in contact with the pedicle, the outer ends of the wire are passed through the rings or perforations of a suitable canula, and attached to a rod sliding upon its handle. This is then drawn home, and the pedicle severed by gradual traction. Care must be taken, by keeping the finger upon the polyp, to prevent it from falling down upon the larynx, or into it. Some operators pass a thread through the polyp, by which to draw it out through the mouth.

Another method employed is to pass the ends of the wire through a double canula, and merely to strangulate the tumor, without attempting to cut it off. The ends of the wire are fastened around little rings at the end of the canula, and tightened from day to day until the tumor drops off. In these cases it would be best to pass a thread, if possible, through the body of the growth, and to secure it to the ear, to prevent its falling into the pharynx or larynx. Cases are on record in which tumors thus removed by the wire have fallen into the pharynx and been swallowed. In the absence of a wire, a stout ligature may be passed around the growth in like manner, and then knotted upon it, and allowed to cut its way out by strangulation. Knives and scissors are rarely used at the present day to excise nasal growths, unless they are situated near the external orifice, so that their points of implantation can be readily cauterized after the operation.

The use of the hot iron is attended with many difficulties, principally because it burns the sound tissues. This danger is avoided, to a great extent, in the more modern use of the galvanic cautery, as suggested and successfully accomplished by Middeldorpf, of Breslau.¹ A platinum wire is passed around the growth and drawn home into a double tube, the extremities of which are in contact with a powerful galvanic battery.

¹ Die Galvanokaustic. Ein Beitrag zur operativ. Medicin, p. 138.

As soon as the mass has been constricted, the connection is closed and the tumor burned through. The difficulty in the operation lies in the adjustment of the snare. Dr. Thudichum,¹ of London, has devised a special apparatus for this purpose, and commends the treatment very highly. It is not accompanied with a great deal of pain or a great deal of bleeding; but it presents the objection that it divides the growth at the point encircled by the wire, and does not draw away the pedicle, as often occurs in the use of the forceps.

The tendency to repullulation of tumors removed from the nasal passage is restrained by the topical use of astringents and caustics. Nasal myxomata manifest great tendency to repullulation—not so much, perhaps, from any predisposition of the parts to the formation of the growths, as because the shape of the cavity often renders it impossible to remove all their attachments, and the remaining portions develop new polyps after the extraction of the first one. In this way an individual the subject of nasal polyp is often compelled to undergo a series of operations for the removal of these tumors. A case is cited, in Riolan's Anatomy, of an individual who was obliged to submit to an operation of this kind every month, for forty consecutive years.

Prof. Gross recommends, in cases where there is great tendency to regeneration of polyps, or where they exist in great numbers, the removal by forceps of half, or even more, of the implicated turbinated bone—a procedure which he has sometimes adopted, and which he believes preferable to the frequent repetition of the ordinary operation.

Tumors with extensive attachments sometimes require access to be made to them by external incision through the nose or upper jaw, various operations for which are performed with such modifications as are suggested by the individuality of the case. Unless imperatively demanded to save life, an operation of this kind should not be undertaken without a good prospect of successful extirpation of the entire mass, for any portion left behind, having ample space to grow, will increase with fresh vigor and perhaps undergo malignant degeneration, becoming larger in bulk than the original tumor would have been, by the same time, had it been left alone.

¹ On Polypus of the Nose and Ozaena, London, 1869.

Osteomas being comparatively free in the cavities in which they are located, may be enucleated, and early operation is advisable. Direct access to the tumor being had by external incision if necessary, friable tumors of cancellated tissue, as previously determined by the exploring needle, may be crushed with strong forceps and removed in fragments. Eburnated tumors resist all the cutting force that can be brought to bear upon them with the strongest pliers, and even the edge of the gouge, chisel, and trephine. It is necessary to expose them fully by an external opening large enough to admit of their withdrawal in mass, as they can be dislodged by a rocking motion with forceps without much effort. This is the only kind of operation, as far as I am aware, that has hitherto been practised with success. It is quite probable that they could be drilled or ground down with a drill or burr attached to the mandril of the treadle-engine used by dentists, and thus broken up into fragments removable through a small external opening. I have avoided an otherwise necessary external operation in operating upon an exostosis in the nasal passage ground down in this way, the mucous membrane and periosteum being first turned off, and then replaced after the destruction of the growth.¹ During the operation a stream of water must be kept playing upon the parts to keep down the temperature produced by the friction, and to wash away the detritus which obstructs the view and the touch. After extraction of the tumor, the cavity from which it has been removed is to be carefully examined by inspection and palpation, and any rough débris of attachment to be scraped off, or any attendant mucous polyps removed. A large external wound requires to be partially united by suture, but with a small one mere apposition of the edges with adhesive strips is sufficient; a free opening being maintained for drainage of the products of the almost inevitable suppuration that will follow.

Recovery from operations for the removal of nasal tumors is usually rapid and unattended with untoward phenomena. Fever, erysipelas, and meningitis sometimes occur, however, and occasionally terminate fatally.

Exostoses of the nasal passages are comparatively infre-

¹ See case, *Med. and Surg. Reporter*, July 13, 1878, p. 30.

quent. They may originate in some portion of the osseous framework of the nasal passage, even the vomer;¹ sometimes they begin in the orbit, but they are most frequently extensions from the antrum. Great bulk may be acquired in the latter variety especially, producing marked deformity of the nose and face. The *symptoms* are impediment to nasal respiration, pain, muco-purulent discharge, and tendency to hemorrhage. The *diagnosis* is determined by inspection and palpation. The *treatment* consists in removal or destruction by forceps, saw, chisel, drill, or burr, access to the tumor being made through the nostril or by more or less extensive external incision, as the case may require.² In a case of exostosis developed from the palatine ridge of the superior maxilla and in the vomer, under my own care, it was found comparatively easy to grind the offending mass away through the natural passage, with the burr of the dental engine, the parts being exposed by detaching the overlying mucous membrane and periosteum, which were replaced after the exposed surfaces had been carefully polished by the corundum wheel.³

Tamponing the Post-nasal Fossæ.—In operating on diseases of the nasal passages, the posterior tampon should be applied before the patient is anæsthetized. If the anæsthetic is administered first, there may be, as reported in one of Prof. Verneuil's cases, great difficulty in adjusting the tampon; the jaws may be hard to separate; the tongue is apt to be contracted by the irritation of the canula, and force itself upward and backward so as seriously to embarrass the manipulation. A wire attached to the tampon is preferable to thread, as not liable to be divided by the knife.

When the occlusion is perfect, so that no blood can escape into the throat, the patient remains perfectly quiet during the operation, without any acceleration of pulse or irregularity of expiration. If the occlusion is imperfect, or becomes so during the operation, the escape of even a small amount of blood into the throat will provoke reflex action, which will at once accel-

¹ See Case of Removal, Michel: Gaz. hebdomadaire, 1873, Nos. 24, 25.

² For example see Mott: Am. Jour. Med. Sci., Jan., 1857, p. 35, illustrated; Duka: Trans. Path. Soc., London, Vol. XVIII., p. 256.

³ Med. and Surg. Rep., Phila., July 13, 1878, p. 30.

erate the pulse, thereby increasing the flow of blood, which may interfere with respiration, or even suspend it.

Anæsthesia is recommended in the performance of these operations, because the agitation of the patient, his ejaculations and movements, produce vascular turgescence of the parts, increasing the hemorrhage; and therefore there is much less blood lost under anæsthesia.

After bleeding has ceased, the tampon should be removed, lest its presence excite irritative inflammation.

If the septum narium is perforated, it will be necessary to tampon both the nasal fossæ, though the operation to be performed concern but one of them

NEUROSES OF THE NASAL PASSAGES.

There are neuroses of olfaction, of sensation, and of motion.

Anosmia.—Loss of smell occurs from direct pathological lesion, involving the terminal distribution of the olfactory nerves secondarily, in various idiopathic, symptomatic, traumatic, and specific affections of the nasal passages; and, likewise, from injury or disease of the olfactory bulbs or of their nerve-filaments. It may be due to mechanical conditions preventing forced inspirations towards these filaments in the upper part of the passages. If the causal disease is relieved, the sense of smell is usually restored or improved, though sometimes remaining permanently in abeyance.

The epithelium in the upper portion of the nasal passages has a special arrangement differing from the lower portion, and hence it is supposed to have some special relation with the function of olfaction.

An apparent pathological evidence of the plausibility of this opinion occurred in my own practice, in the person of a lady from whom I had occasion to remove the nasal bones, vomer, unguis, middle and lower turbinates, and pterygoid processes of the superior maxilla (the specimens are deposited in the museum of the College of Physicians, Philadelphia). The sense of smell had become completely abolished during the progress of the (specific) disease of these bones and their superjacent structures. After the removal of the parts enumerated, and the discharge of adjacent spiculæ, the sense of smell returned. Rhinoscopic inspection revealed the superior turbinated bones intact.

The subject of anosmia has been especially studied by Serres,¹ Ogle,² Notta,³ and Knight.⁴

Loss of smell is sometimes dependent upon tumor in the brain, syphilitic or other cerebral disease. When this is the case, its restoration is contingent upon recovery from the central lesion. These cases are sometimes associated with subjective derangements of olfaction, the subjective odor being usually offensive.

Taken in conjunction with severe and continuous pain, vomiting, and similar phenomena of cerebral origin, the inference would be strongly in favor of local cerebral disease; this, of course, would be the more probable if there were additional symptoms of visual or auditory disturbance. The disease does not of necessity exist in the olfactory bulbs themselves, though they must be influenced by it.

A case has been recorded in which the continual inspiration of the fumes of ether, accidentally, in the course of some experiments on animals, caused a gradual failure of the sense of smell, and at last its total aberration, the effect being attributed to the continuous contact of sulphuric ether with the minute branches of the olfactory nerve.⁵

The most frequent cause of anosmia, however, is due to blows received upon the head, whether on the forehead, parietal region, vertex, or occiput.

Mr. Hilton, in describing this traumatic lesion, attributes it to rupture of the olfactory bulbs, or separation from their beds, due to the fact that they lie directly on the floor of the cranium, unprotected by a cushion of cerebro-spinal fluid, as the parts of the base of the brain are, behind the bulbs.

Dr. William Ogle reports three cases from blows in which the sense of smell, and of that sense alone, was completely lost, one of which was of twenty-seven years' standing. He attributes the loss of the sense of smell in these cases to rupture of the olfactory nerves, as they pass from the bulb through the perforations in the ethmoid bone. He maintains that anosmia of the affected side is present in every well-marked case of facial palsy. He presents several cases of partial loss of smell, and enters into the physiological points of interest concern-

¹ Anat. comp. du cerveau.

² Anosmia, or Cases Illustrating the Physiology and Pathology of the Sense of Smell. Med. Chir. Trans., London, 1870, LIII., pp. 263-290.

³ Recherches sur la perte de l'odorat. Arch. gén. de méd., Apl., 1870, pp. 385-407.

⁴ Case, with synopsis of twenty-two cases in all. Boston Med. and Surg. Jour., Sept. 13, 1877.

⁵ (Virchow's Archiv, IV., 41, 1867), Syd. So. Bienn. Retrospect., 1867-8, p. 84.

ing olfaction. His opinion is that the external root of the olfactory nerve is the only one directly concerned in olfaction; and that it depends upon the degree in which this root or its central termination has been disorganized, whether the loss of smell be complete or partial. In support of this view, he cites an observation of M. Serres, founded on the results of nineteen post-mortem examinations of the bodies of paralytic patients, that lesion of the external root is much more efficacious in determining anosmia than is lesion of the internal root.

Sometimes the anosmia is not manifested until some months after the injury,¹ implication of the olfactory bulbs taking place as a sequence of inflammatory or other processes.

In most of these cases there is considerable impairment of taste; but sometimes, as particularly exemplified in one of Notta's cases, taste is unimpaired, though smell is entirely abolished.

Treatment.—These cases are not usually amenable to treatment, though, on the other hand, some recover spontaneously.

In addition to treatment of the exciting cause, if this be not followed by restoration of the sense, electric excitation of the upper part of the Schneiderian membrane by the interrupted galvanic current, is indicated and not unfrequently successful in rousing the dormant function. I have found, under certain circumstances the pathology of which I am unable to explain, that the only way in which I could arouse the sensation of smell was by using the covered negative electrode in the nasal passage, and the positive electrode over the course of the sympathetic nerve behind the angle of the lower jaw.

The deprivation of smell is very annoying, interfering, among other things, with the full enjoyment of food; so much of the sense of taste, or rather the appreciation of flavors, being abolished as is dependent upon the integrity of olfaction. When this is due to occlusion of the retro-nasal portion of the pharynx by adherent palate, it may be relieved by making an artificial opening in the palate.²

Dr. Moller states that strychnia applied with a brush to the nasal passages increases the acuteness of the smell, and restores it in anosmia.³

¹ J. Wickham Legg: The Lancet, Nov. 8, 1873, p. 659; Hybord: Arch. gén. de méd., March, 1874, p. 347.

² Ogle: loc. cit., p. 272.

³ (Rév. des sciences méd., Oct., 1876, from Ugeste for Läger, R. 3, Bd. 19.) Am. Jour. Med. Sci., Jan., 1877, p. 235.

Hyperosmia.—Acuteness of smell is often serviceable, especially in heralding the proximity of unpleasant or unhealthy contaminations of the atmosphere. It assists detection of certain diseases by the odor of their emanations, and thus enters into the field of differential diagnosis. The smells of small-pox, typhus fever, and other diseases are sufficiently characteristic; but it is maintained that the sense of smell is adequate to the recognition of syphilis; and it is recorded¹ that Dr. Stokes, of Dublin, more than thirty years ago, expressed the opinion that the nose might be able to detect the difference between pneumonia and bronchitis. Indeed, one author professes to be able to distinguish recent participants in coitus from the odor of their bodies. Too great an acuteness of smell, however, may become a great source of annoyance.

Some curious cases of this kind are on record. Anne of Austria is said to have fainted upon inhaling the odor of roses, although she was very fond of flowers. One of the most remarkable cases occurred in the person of Caspar Hauser, all of whose senses were exquisitely developed, so much so as to be extremely annoying to him at times; but the sense of smell was most troublesome to him, and rendered his life miserable. He perceived odors where others could detect nothing of the kind. He was overpowered by the fragrance of a rose, and could distinguish fruit-trees from each other, at a considerable distance, by the odor of their leaves. The smell of old cheese produced nausea and vomiting; and that from a churchyard occasioned a paroxysm of fever. The so-called perfumes, employed for cosmetic purposes, were more disagreeable to him than many of the decidedly unpleasant smells. In fact, every odor, excepting those of bread, fennel, anise, and caraway, was more or less disagreeable to him, so much so that the only food he would partake of was bread and water.²

Subjective abnormal sensations of smell are sometimes indications of local disease of the olfactory organs, or in the structures of the nasal passages. Occasionally they are precursors of epileptic convulsions.

Hyperæsthesia.—**Neuralgia.**—**Sternutatio.**—Hyperæsthesia occasions sneezing on very slight provocation. Sometimes it keeps up a constant snuffling. Abnormal sneezing is a result of direct or reflex irritation of the trifacial and other nerves, and is sometimes manifested in neuralgias of the facial nerves.

¹ Brit. Med. Jour., March 4, 1871. See also Isham: On Smell in the Diagnosis of Disease, Cincinnati Clinic, Oct. 9, 1875; London Med. Rec., Nov. 15, 1875.

² Feuerbach's Account of Caspar Hauser, Boston, 1832.

Sudden exposure to a strong light, whether natural or artificial, always produces sneezing in some individuals; but remoter excitation sometimes produces this result by reflex action, as in the curious cases cited by Stalpal von der Wiel¹ and Elsberg, in which violent paroxysms were excited by the coitus. The paroxysms of sneezing are sometimes prolonged and very violent. They have been known to occur almost without cessation for hours in succession.² In some cases epistaxis, hæmoptysis, menorrhagia, and cerebral hemorrhage result. In others, amaurosis from retinal hemorrhage, cerebral apoplexy, epilepsy, abortion, and sudden death from rupture of aneurisms, have ensued.³

There has long been a popular notion that severe sneezing may be followed by serious consequences. Hence the custom of ejaculating "God bless you," or some equivalent congratulatory phrase, to one sneezing. It is also said that this custom is due to the circumstance that the involuntary ejection of wind from the two extremities of the alimentary tract is liable to call forth ejaculations the reverse of compliment and congratulation.

Treatment.—If due to hyperæsthesia of the Schneiderian membrane, the local use of sedative unguents is indicated, such as camphor, stramonium, and aconite. If due to hysteria, preparations of assafœtida, valerian, with the use of tonics, are employed. If part and parcel of a neuralgia, sedatives and tonics are required. The causal indication requires appropriate treatment as a matter of course.

Paralysis of the Nostrils.—Paralysis of the nostrils may be a partial manifestation of paralysis of the facial nerve. Sometimes it is a local paralysis.

A gentleman came under my care, in 1870, affected for some years with a difficulty of breathing through his nostrils, which produced snoring in sleep, and necessitated his keeping his mouth open. He had acquired pharyngitis sicca, and was rendered otherwise uncomfortable. Bidding him make a nasal inspiration, I saw that the nostril closed externally in the act. Holding the nostril away from the septum with a pair of forceps, I found that breathing went on tranquilly and without effort. Careful exploration showing that there was no disease in the tissues of the nasal passages, the diagnosis was paralysis of the

¹ Watson: Diseases of the Nose, London, 1875, p. 343, note.

² Dr. Mosler, of Giessen, has related a case in a girl with an affection of the ear, as a sequel of typhoid fever, who was suddenly attacked with continued sneezing, which lasted for twenty-four hours. Med. and Surg. Rep., Phila., 1860.

³ Watson: Op. cit., p. 345.

dilator muscle of the nostril; and local applications of electricity were recommended. As the patient could not remain for treatment at that time, I had two silver plates made the size of the nostril, separated by a weak spring; the plates were pressed together and inserted into the nostril, and on relieving the pressure the blades expanded and kept the nostril dilated. This instrument relieved the entire trouble. It was not visible externally, and could be very readily removed for purposes of cleansing. As the patient did not return for further treatment, I presume he felt satisfied with the relief afforded by the dilator.

Symptoms.—The symptoms are: difficulty of respiration by means of the nostril, compelling respiration by the mouth if bilateral.

Diagnosis.—The nostril is flaccid, and becomes pressed towards the septum on attempts at inspiration through it.

Treatment.—The usual treatment for paralysis is indicated, with local applications of the electric current to the affected muscles, or over some portion of the nerve-distribution. To this may be added the mechanical use of appliances to keep the alæ distended.

CHAPTER XII.

AFFECTIONS OF THE SEPTUM NARIUM.

INFLAMMATION AND ABSCESS OF THE SEPTUM NARIUM.

ACUTE inflammation of the septum narium sometimes occurs as the result of injury or external violence, and may lead to the formation of abscess. Inflammation and abscess also occur independently of local injury.

Guersant¹ speaks of having frequently encountered abscess of the nasal septum in infants supposed to be affected with nasal polyps. These abscesses he attributes most frequently to blows and falls upon the nose; though they are sometimes occasioned by disease of the vomer itself, caries, necrosis, or scrofulous inflammation.

Symptoms.—There are pain, heat, dryness, and swelling of the parts, the tumefaction being sometimes sufficient to occlude the nostrils completely. The pain often extends into the frontal sinuses. The abscess may form on either side of the septum, or on both sides.

Diagnosis.—This is easy. The appearance of a tumor, the sense of fluctuation, and the history of the case, with more or less manifestation of fever, indicate the nature of the affection.

Treatment.—Such medication is required as is indicated by the condition of system.

The local treatment consists in early incision of the abscess and evacuation of its contents. If the parts do not return promptly to their natural condition, the local use of the mineral astringents may be called for.

If dead bone be present, the cure will not be accomplished until it has been thrown off necrosed, or been removed by surgical interference.

¹ La chirurgie des enfants, Paris, 1864-7, p. 383.

Chronic inflammation of the nose, especially in syphilitic and scrofulous subjects, not unfrequently terminates in abscess, producing ulcerative destruction of more or less of the cartilaginous septum. Syphilitic abscess is sometimes the result of the breaking down of gummata. There may be several perforations, or one large orifice; more frequently, perhaps, the latter. Very often the result of the examination by the surgeon will be the first intimation to the patient of the existence of a perforation. It is met with independently of any history of local disease within the patient's memory. Some authors believe it to be congenital. The probability, however, is, in at least a fair proportion of instances, that the perforation has resulted during the course of a syphilitic coryza which has occurred in early infancy.

Treatment.—If the edges of the perforation show any disposition to ulceration, they should be pencilled with nitrate of silver or sulphate of copper. Careful washing with warm water or soap-suds, conveyed on the end of a soft rag, will remove the inspissated mucus which sometimes adheres to the edges; and thus the parts will be kept clean and comfortable.

Plastic operations have been performed occasionally for closure of perforation; but in the majority of cases there is no other inconvenience than the detention of mucus at the edges, and there is no occasion for operative interference.

SUBMUCOUS INFILTRATION AT THE SIDES OF THE VOMER.

My attention had not long been directed to rhinoscopy before I met with frequent examples of a peculiar condition of parts in nasal affections which, as far as I am aware, had not been described. It consists in a peculiar puffiness of the mucous membrane on the sides of the posterior nasal septum. From personal experience, and as the result of conversations with Dr. Elsberg, of New York, and others, I soon inclined to the belief that this condition is very common.

The affection is an obstinate one, and apt to recur again and again.

I regard the condition as similar, in many respects, to the protrusions of the mucous membrane met with in the anterior nares and simulating polyp. In the latter cases the tumors are red, and in the former cases they are white or whitish.

Figs. 95 and 96, from two of my earlier cases, will serve to illustrate the nature of this affection. The tumid swellings are easily recognized each side of the septum, where they cut off the views of the turbinated bones.

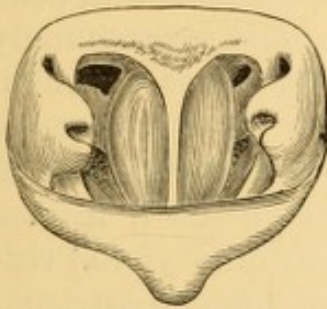


FIG. 95.—Rhinoscopic image of œdema of nasal septum.

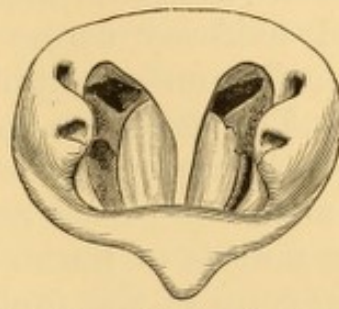


FIG. 96.—Rhinoscopic image of œdema of nasal septum.

Fig. 97 represents a more marked example. The illustration exhibits a prominent view of the left side of the pharyngo-nasal region, representing the pharyngeal end of the Eustachian tube of that side and its orifice, and a deep indentation or groove marking the boundary line between the vault of the pharynx and the nasal portions. This space and the fossa of Rosenmüller below it was bridged by numerous bands of adhesions. A portion of the œdematous membrane of the left side was pulled off with angular forceps passed behind the soft palate, and the mass of jelly-like consistence was examined microscopically by Dr. J. Gibbons Hunt, of Philadelphia, who discovered in it abundant evidence of mycelium, probably an accidental product.

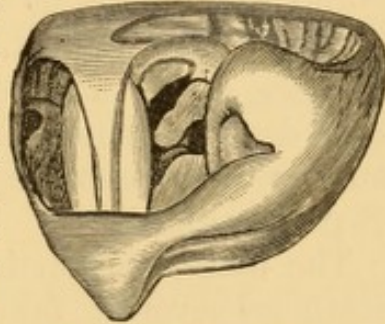


FIG. 97.—Submucous infiltration of posterior nasal septum, supposed to be due to mycelium.

This condition exists sometimes, to a very limited extent, in cases of ordinary chronic coryza, but the œdematous protrusion is slight, and apt to be constricted at one or two points of its extent; a similar moderated degree of the affection occasionally attends cases of glandular enlargement at the vault of the pharynx.

Symptoms.—The symptoms to which this condition gives rise are those of obstruction at the posterior nares, such as are often referred to the presence of polyps.

Diagnosis.—On examination with the rhinoscope, we observe at each side of the septum, and confined to the posterior portion, a tumid mass, of a whitish color, markedly distinct from the red color of the adjacent mucous membrane. The mass almost always, as I have seen it, occupies the lower portion of the septum, extending upward to a greater or less extent, and sometimes occupying the entire length of the septum.

I have rarely seen it at the upper part, with a line of demarcation below. The affection is usually symmetrical, but often exists to a greater extent upon one side than the other. The masses are roundish, with very convex outlines, and sometimes extend half-way across the choanæ, and occasionally very close to the outer margins of the nares, if not in contact with them. The general appearance of the mass is suggestive of polyp. It appears to be an œdematous projection of the mucous membrane from an accumulation beneath it of serum, serous mucus, or fibrin. The tumor usually yields readily to the pressure of the probe or other instrument, carried up behind the palate, or introduced through the nostril, being soft and elastic to the touch.

Treatment.—The best treatment of this affection consists in tearing away portions of the masses by forceps carried up behind the palate, or introduced through the nostril, as the case may best permit, the operation being performed under guidance of the rhinoscopic mirror. There is not usually a great deal of hemorrhage. After the operation the parts are cauterized. Sometimes puncturing them with the curved lancet probe suffices.

The manipulation is an exceedingly difficult one in many instances, severely taxing the patience and ingenuity of the operator, as well as the endurance and amiability of the patient. Mere puncture with the concealed lancet has not afforded good results in my hands, though it will unload the part for the time. The cicatrization of the edges of the wound made by tearing away the mucous membrane enlarges the passage for air, and is in this way beneficial. The galvano-cautery affords an appropriate means of destroying these protrusions, from the promptness with which it acts, as it is hard for patients to bear contact with these parts for more than a second or two at a time.

DEFLECTION OF SEPTUM FROM MIDDLE LINE.

The unpleasant symptoms of impeded respiration due to this affection are sometimes relieved by cutting out a piece of the septum, and thus establishing a communication between the two passages.

A portion of the septum may be removed with a sharp

punch, the blades of which are passed on either side of the septum.¹

Sub-periosteal resection of the nasal septum for the remedy of deflection has been resorted to by M. Chassaignac.² A curvilinear incision is made in the antero-posterior direction low down into the mucous membrane, and this flap is separated from the cartilage by means of a spatula, and then turned over. Several slices are then cut from the cartilage until a point has been reached which admits of its being readily pushed over to the middle line. The flap of mucous membrane is now replaced, and the parts are retained in their new position by a bit of sponge inserted into the nostril.

Some surgeons have divided the nose in the middle line, and resected the septum.

I have seen Prof. Pancoast relieve a case of this kind, attended by deformity of the organ to one side, in which the deviation had been acquired by blowing the nose by the aid of the finger and thumb. The nostrils were tamponed anteriorly and posteriorly; and the cartilaginous portion of the septum separated from the bony portion by subcutaneous division with a tenotome. The organ was then forcibly pulled to the opposite side, and maintained in position by adhesive strips.

Much can be done in some instances by inserting metallic tubes into the passages and exercising dilatation and gentle compression in this way. The use of the compressed sponge, or of the tubes of laminaria will often succeed eventually in overcoming a deviation of the septum, without any necessity for resort to the knife.

FRACTURES OF NASAL SEPTUM.

Fractures of the nasal septum occasionally occur, and, when comminuted, may obstruct the nasal passage to a considerable degree. The *treatment* has to be conducted on general principles, broken fragments being removed, and endeavors made to maintain proper position of the remnants by mechanical supports within the nasal passages.

¹ Rupperecht: Wien. med. Woch., 1868, p. 1157; Ziemssen's Cyclopædia, N. Y., Vol. IV., p. 114.

² Gaz. hebdomadaire, June 11, 1869, p. 380.

Prof. Gross¹ mentions a case brought to him four months after the septum had been broken into several pieces, in which there was encroachment upon the left nostril to such an extent as to cause almost complete occlusion to respiration on that side. In order to afford relief, he was compelled to cut away the whole of the offending part.

TUMORS OF THE SEPTUM.

Tumors of various kinds are formed occasionally in the septum. These may be mere ecchymoses, the result of blows, appearing as tumid swellings, sometimes on one side, sometimes on both. Their prompt appearance and the history of violence will serve to intimate their true nature. They usually subside spontaneously by absorption of the effused blood. If this does not take place, their contents should be evacuated by incision, otherwise they may eventuate in inflammation and abscess.

Myxomata occasionally occur on the septum. They are usually removed by excision with knife or scissors close to the wall of the septum, the raw surface being cauterized with nitrate of silver, or other caustic, to prevent repullulation.

Cystomata occur occasionally in this situation likewise. The treatment consists in evacuation of the colloid contents of the sac by excision, and local medication of its walls, so as to excite adhesive inflammation.

Ecchondromata occasionally grow on the septum, and usually require external division of the nose for their removal. The cartilaginous hypertrophy of the septum sometimes encountered is discussed in connection with the subject of deflections of the septum.

Sarcoma.—Von Vадja² reports a case of sarcoma of the septum as large as a pigeon's egg in a syphilitic male subject.

Other tumors, liable to be mistaken for malignant growths, occur in the septum, due to disease of the perichondrium, usu-

¹ Op. cit.

² (Wien. med. Presse, Mar. 18, 1877) N. Y. Med. Jour., July, 1877, p. 97.

ally the result of syphilitic infection, but sometimes manifested in scrofulous subjects. They subside under constitutional treatment and the application to their surface, or into their substance, of solutions of iodine and iodide of potassium, ergot, and carbolic acid.

CHAPTER XIII.

DISEASES OF THE FRONTAL SINUS.

SOME diseases of the frontal sinus are continuous with affections of the nasal cavities, or dependent upon them. Others appear to originate in the sinus. These latter may eventually implicate the nasal passages likewise.

INFLAMMATION AND ABSCESS.

Inflammation of the mucous membrane of the sinus is sometimes a result of external injury, and more frequently an extension of disease from the nasal cavities, principally in the subjects of tertiary syphilis.

A moderate degree of inflammation of the frontal sinus accompanies severe cases of coryza.

Forcible injections, by means of a long syringe passed high up the nasal passages, sometimes drive fluids into the sinuses, usually indicated by intense pain in the frontal region, sometimes lasting for hours. The use of the nasal douche also, at times, admits the passage of the fluid into the frontal sinuses, and thus provokes severe pain, necessitating an abandonment of the procedure. The larvæ of insects sometimes reach the frontal sinus, from the development of eggs which have been deposited in the nasal passages.

Frequent attacks of this kind sometimes result in permanent distention of the frontal sinuses, which become markedly prominent; and chronic inflammation ensues, accompanied by purulent or muco-purulent discharge from the nose, which, when offensive, constitutes one of the most obstinate varieties of fetid catarrh, on account of the profuse secretion of the purulent matter and the difficulty of subjecting it to the action of local remedies.

An occlusion of the passage between the sinus and the nasal cavity, by tumefaction or otherwise, causes accumulation of mucus, pus, and blood, as the case may be. This may even-tuate in marked distention of the parts, sometimes producing deformity of the eyeball and great swelling of the upper eyelid. Under such circumstances, should the accumulation continue, there may be danger of pressure on the brain or of perforation into the cavity of the cranium, unless there is prompt evacuation of the sinus through the nasal passage or by an external opening.

Inflammatory disease of the mucous membrane lining the frontal sinus may give rise to the deposition of calcareous concretions, similar to those met with in the nasal cavities.

Symptoms.—The symptoms are pain, sensations of distention in the parts, tumefaction externally—involving more or less of the orbital region, and perhaps the face—and serous, mucous, purulent, or sanious discharges from the nasal passages.

Diagnosis.—This is based on the symptoms, and on the absence of disease of the nasal passages and orbit.

Treatment.—The ordinary treatment for inflammation is required, means being taken to promote the discharge from the nasal passages.

The local effects of sedative ointments, applied freely to the nasal mucous membrane, is sometimes propagated by continuity to the lining membrane of the sinuses, and thus enables us to control the pain in the part. An ointment of stramonium, simple cerate, lard, or petroleum, in which a few grains of a salt of morphia to the ounce has been well incorporated, is well adapted for the purpose, as much being insinuated into the passages with a long camel's-hair pencil, or a swab on a wire, as will represent a sufficient dose (say a fourth of a grain) of the drug. External pressure during withdrawal will secure better contact. The systemic effect of anodynes applied to the nasal passages in this way is often marked and prompt.

An abscess sometimes forms in the frontal sinus, as a result of inflammatory occlusion of its outlet into the nasal passage, and discharges either by way of the nostril, or, more rarely, by perforation of the anterior wall of the sinus.

When the abscess is of syphilitic origin, there is a liability

of caries of the bone, perforation, and penetration into the cavity of the cranium. A case of perforation from syphilitic abscess has been reported,¹ in which there was a distinct hernia of the Schneiderian membrane through the aperture, a condition similar to that of tracheocele or pneumatocele.

Symptoms.—These are at first similar to those of inflammation; but they soon increase in severity, and may terminate in delirium, coma, and paralysis, if the pus has discharged into the cavity of the cranium. Erysipelatous inflammation of the soft parts overlying the sinus, with great local and general disturbance, would usually be indicative of the formation of an abscess. Sometimes there is great and even sudden swelling of the upper eyelid, and sometimes displacement of the eyeball.

Diagnosis.—This is based upon the locality of the swelling and the character of the symptoms, and on exploratory puncture or incision. The erysipelatous inflammation externally is apt to be misleading in the early stage.

Treatment.—The abscess should be evacuated as promptly as possible, either by perforating it through the nostril, or cutting down upon it externally, and entering the sinus by means of a small trephine.

In some instances a drainage-tube is left in the parts; in other instances a perforation is made into the nasal cavity, and the drainage-tube passed on through it, in order to favor the passage of the secretions by that channel. At other times the interior of the cavity is washed out by warm astringent anodyne or detergent lotions.

TUMORS OF THE FRONTAL SINUS.

Various forms of tumor are liable to development in the frontal sinus. These include myxoma, fibroma, cystoma, osteoma, sarcoma, and carcinoma. Their development causes characteristic distortion in the external configuration of the sinus and adjacent structures. They produce absorption of the bony walls by pressure, and force the eyeball outward and downward (exophthalmos), as well as the nose and face, according to the location in which they extend. They may compress

¹ Bizet: Gaz. méd., Paris, 1863, p. 663.

the bony structures of the base of the cranium and produce absorption with disturbance of the position of the anterior lobe of the cerebrum, or eventually penetrate the cavity. They give rise to serious cerebral disturbance.

Cystoma.—Cystic tumors are more frequent in the frontal sinus than any other variety of morbid growth. They occur at all ages, and may be congenital. The cyst is usually a serous cyst, but may be hydatid, or even steatomatous. In some instances the walls of the cyst undergo calcareous or osseous degeneration.

Myxoma.—Myxomatous or gelatinoid polyps are usually developed in connection with myxoma of the nasal passages. Sometimes they hang down into the nasal passages by a narrow pedicle. They are rather rare. They are frequently single, and sometimes multiple.

Fibroma.—Fibroma is still more rare. It is usually single, and may be accompanied by myxomatous polyps. It may extend into the nose and thence into the antrum and pharynx, like the veritable intra-nasal fibroma, or upward and backward into the cranium.

Osteoma.—Osseous tumors of the frontal sinus are rare. They are sometimes composed of cancellated tissue and sometimes of compact tissue. Growths composed entirely of compact tissue are very hard, ivory-like, or eburnated. They may be developed from the diploë of the frontal bone, or from the epithelium of the mucous membrane lining the sinus.

Symptoms.—The symptoms of tumor in the frontal sinus are more or less severe headache, painful neuralgic paroxysms, supra-orbital tumefaction, displacement of the eyeball downward and outward, œdema of the upper eyelid, impaired vision, epistaxis, and serous, mucous, purulent, and sanious fetid discharges from the nasal passages. The headaches are sometimes so violent as to prevent sleep.

Diagnosis.—This is difficult until the development of the tumor has begun to produce the characteristic deformity. It would then be based on the symptoms narrated, the exophthalmos, and the results of external palpation and exploratory

puncture. The headaches are often noticed to be relieved by the epistaxis, gradually returning to be relieved spontaneously only in the same manner. The tumor externally can often be indented by pressure on account of the attenuation it has undergone by absorption from compression.

Palpation beneath the frontal bone between the floor of the orbit and the eyeball will sometimes detect the presence of the tumor itself, or of fluctuating contents from serous or fibrinous infiltration in its neighborhood. Myxoma and small fibroma often escape detection during life. Cysts are liable to be confounded with chronic abscess. Osteoma are hard to the touch. An osseous cyst may be confounded with an osteoma, but the exploring needle would detect its cystic character at once and reveal the nature of its contents. In their early stages the symptoms of tumors of the frontal sinus are readily mistaken for manifestations of cachectic or specific cephalalgia.

Prognosis.—This is not favorable.

Treatment.—Removal of solid tumors by direct access, by incision of trephine, or drill-saw, through the anterior wall of the orbit, is justifiable if there are no symptoms indicating extension internally. Tumors of the latter class must be approached very cautiously, as it is impossible to determine to what extent the cranial bones or membranes may be involved.

Cystic growths may be punctured by external incision and injected with an iodine or other stimulating fluid, or be pierced through into the nasal passages for the maintenance of a drainage-tube there as in ordinary abscess.

FOREIGN BODIES IN THE FRONTAL SINUSES.

Foreign bodies occasionally gain access to the frontal sinus, sometimes from being forced up into the nasal passage, sometimes as the result of gunshot or other injury, or of fracture. Living insects sometimes crawl up from the nasal passages, or are developed from ova deposited there; or are even, it is said, drawn up in inhaling the odors of flowers and fruits. In certain parts of India and other countries fatal disease from the entrance of insects is said not to be rare.

Symptoms.—These are more or less continuous or intermittent frontal headache; cerebral excitement and even delirium;

discharge from the nasal passages, and sensations of unpleasant odors.

Diagnosis.—This is usually obscure, unless there is some positive history of access of a foreign body, or occasional evidence of insect or infusorial life in the discharges from the nose.

Prognosis.—This is favorable if the foreign bodies can be dislodged. In some instances of living insects in the sinuses it has been found impossible to dislodge them, and the cases have terminated fatally. In traumatic cases it will depend upon the amount and nature of the local lesions.

Treatment.—Vapors of carbolic acid, iodine, and sulphur, forced into one nasal passage by compressed air, the other nasal passage being closed, may be made to enter the frontal sinus for the purpose of suffocating living organisms. Saline solutions forced up by syringe or nasal douche, the head being bent forward to favor penetration, may be used to wash the parts out. Insufflation of irritant snuffs may be resorted to, to excite sneezing and thus facilitate dislodgement from the sinuses. Inorganic foreign bodies may be removed by external access, as for tumors.

CHAPTER XIV.

AFFECTIONS OF THE LARYNX AND TRACHEA.

ACUTE LARYNGITIS.

(Catarrhal Laryngitis, Erythematous Laryngitis; Laryngite Muqueuse (Cruveilhier), Laryngitis Simplex.)

Acute Laryngitis in Adults.—Acute laryngitis is an inflammation of the mucous membrane of the larynx, often confined to its internal surfaces. It may be associated with an extension of the inflammation into the trachea, or be itself an extension of inflammation commencing in the pharynx and nasal passages, in which case the pharyngeal surface of the larynx is affected also. It may be idiopathic, deuteropathic, or traumatic.

Idiopathic laryngitis is usually due to sudden or unaccustomed exposure to cold, in an individual subject to attacks of acute sore throat; or in one recently convalescent from disease in which the throat had been implicated—as scarlatina, measles, small-pox, diphtheria, and typhoid fever. It is much more frequent, however, in the course of the chronic laryngitis supervening upon tuberculosis and syphilis, an acute exacerbation from some exciting cause becoming superimposed upon the chronic laryngitis already existing.

It may be the direct result of overstraining the vocal cords in screaming and shouting, or by prolonged and excited talking in public or in private. It may be directly excited by local irritation from the inhalation of noxious gases, vapors, and dusts. Sometimes it is due to local irritation in the immediate neighborhood of the larynx, as from a sore mouth or an inflamed gum;¹ or even to local irritation at a distance. It is

¹ Prof. Stromeyer has known the eruption of the wisdom-tooth to give primary origin to a severe laryngitis.

sometimes the result of excessive mercurial salivation,¹ and sometimes the effect of idiosyncratic susceptibility to certain drugs, as calomel² antimony, and iodine. It is occasionally manifested as a distinct acute rheumatic inflammation of the articulating surfaces of the cartilages of the larynx.

Deuteropathic laryngitis is either a consecutive manifestation of existing disease, or an epiphenomenon. It occurs in small-pox, measles, diphtheria, typhoid and typhus fever, erysipelas, and pyæmia.

Traumatic laryngitis may be secondarily due to retention of a foreign body in the pharynx or larynx. It may be immediately due to incautious use of instruments within the cavity of the throat, whether for purposes of diagnosis, extraction of foreign body, or evulsion of morbid growth; to the use of sharp-toothed forceps to draw the epiglottis forward; and to imprudent severe cauterization of the larynx,³ or even the pharynx.⁴ It also occurs as a result of wounds and external injuries. These causes, however, are comparatively infrequent. The most frequent direct causes of acute traumatic laryngitis are the involuntary partial deglutition of boiling water, or caustic solutions, and the inspiration of flame, hot vapors, or acrid substances; the inflammation of the larynx following immediately.

The voluntary deglutition of hot or caustic substances with suicidal intent is not apt to be followed by acute laryngitis, because, in voluntary deglutition, the epiglottis is not taken unawares, as it were, but comes down upon the entrance into the larynx, permitting the normal completion of the act of swallowing. Hence there is no gagging, strangling, or consequent regurgitation, retaining the caustic matter in contact with the throat, or spattering it about the pharynx and the posterior nares. Under these circumstances it is the œsophagus and stomach which suffer, although the larynx is sometimes affected secondarily by extension of the inflammatory process set up in the adjacent organs.

Although the inflammatory action may not be very great in acute laryngitis, the conformation of the parts involved is such that a moderate amount of tumefaction, inseparable from

¹ Gray: Holmes's Surgery. See a preparation, with its history, in the museum of St. George's Hospital, London, Series XV., Subseries 1, No. 6.

² Locking: The Lancet, Oct. 24, 1868.

³ This has occurred once under my own hands. See case in chapter on Morbid Growths.

⁴ A marked case of this kind came under my direct observation in the person of a brother practitioner, operated on by a mutual friend.

inflammatory action anywhere, will interfere seriously with the integrity of the respiratory function; and this mechanical impediment to respiration often constitutes a grave and serious lesion. As a usual thing the inflammation involves the interior surface of the entire larynx, which then presents a uniform diffuse congestion; but it is very often limited to the supraglottic portion, the horizontal surface of the vocal cords inclusive. Sometimes it is restricted to some special locality, as the epiglottis (epiglottitis), one or both ventricular bands, one or both vocal cords (corditis vocalis), one or both supra-arytenoid cartilages (arytenoiditis), the inter-arytenoid fold (meso-arytenoiditis); in some instances affecting two or more contiguous structures. These structures exhibit diffuse congestion, with little or no involvement of adjacent parts. In some instances there are small patches of erosion or loss of epithelium along the crest of the epiglottis, or even upon its laryngeal face, or upon one or both of the supra-arytenoid eminences, or the inter-arytenoid fold, or even the edges or surfaces of the vocal cords; but these manifestations are uncommon. The secretion of mucus is generally slight in quantity, serous in quality, viscid, but thin. In some cases it is quite glutinous and adherent, and is expectorated with difficulty in small pellets, occasionally sanguinolent; while in others there is no evidence of abnormal secretion. In some cases the inflammatory process extends along the mucous membrane of the trachea and bronchi, and evidences of tracheitis and bronchitis become superadded to the special phenomena of laryngitis. In other cases there is more or less pharyngitis, or nasopharyngitis with coryza. Sometimes these affections precede the laryngitis.

Two forms of acute laryngitis may be distinguished: one superficial, in which the inflammatory action is limited more or less to the mucous membrane, and the other, deep-seated or parenchymatous (Mandl), in which it extends to the submucous connective tissue, and perhaps to the muscles. This latter form is to be discriminated from actual phlegmonous inflammation of the same tissue occurring in the course of erysipelas and other affections, and which may terminate in abscess and ulceration. Both of these forms are attended with acute phenomena of fever.

In the one form of laryngitis, the entire laryngeal mucous membrane is very red and very much swollen. The epiglottis is usually erect, and swollen to two or three times its normal thickness, while the mucous membrane of the aryteno-epiglottic folds, supra-arytenoid and arytenoid cartilages, ventricular bands, and sometimes even that of the vocal cords, is similarly swollen, the tumefaction being symmetric in some instances, and limited to one side in others.

Superficial laryngitis is sometimes limited to the mucous membrane covering the vocal cords. There is more or less vivid injection of the capillaries, linear or diffuse, as indicated by a pink, red, livid, or mottled appearance; and the edges of the cords are thick or rounded. The points of insertion of the posterior vocal processes often appear quite white through the overlying membrane, though all the rest of the surface is deeply injected. When covered by mucus, these points simulate ulceration. Occasionally some portion of the inflamed structures is coated with a layer of mucus, or probably of coagulated lymph. It is likely that the tumefaction, especially when uneven in contour, is in part due to coincident tumefaction of the glandular structure also. This swelling is sometimes so extensive as to leave only a very narrow passage for the air; it greatly impedes the motion of the parts, so that the glottis can no longer be fully dilated, and a speedy termination of life by suffocation is threatened, before there has been time for the regular course of inflammation toward resolution on the one hand, or suppuration on the other.

Acute laryngitis, when not fatal, usually continues from seven to ten days. It occasionally runs its entire course in from twenty-four to forty-eight hours; and instances are recorded in which it continued for from twelve to twenty-four hours only.

In mild cases—which occur more frequently than most practitioners are aware of—there is very little swelling of the parts. The entire mucous membrane of the larynx will be hyperæmic to fiery redness, the pain severe, the cough metallic, the voice rough, hoarse, or piping, but the acute phenomena of fever will be absent, and there will be no impediment to respiration, and but little to deglutition, and that more from the pain exercised upon the inflamed structures than from actual obstacle on the part of the inflamed epiglottis and arytenoid cartilages.

A subacute laryngitis accompanies many cases of bronchitis, and not unfrequently attends pneumonic phthisis and other pulmonary affections; under which circumstances the trachea will most likely be involved likewise, as indicated by pain beneath the sternum, pressure upon which will sometimes excite cough.

Another variety of this form of acute laryngitis involves the trachea to a greater or less extent,—properly a laryngo-tracheitis. This may be simply catarrhal; or it may be pseudo-membranous, in which case it is usually known as croup.

In the second or deep-seated form of acute laryngitis, where the submucous connective tissue is involved in the inflammatory process, in part or in great measure, there is greater swelling than has been already described, from serous effusion or sero-fibrinous, or even hemorrhagic infiltration into the areolar tissue; and this gives rise to the subjective symptoms of œdema of the larynx. On laryngoscopic inspection, however, it will be seen that the swellings are opaque, and not translucent as in simple serous œdema; and that they are more rigid, so that they do not yield to the inspiratory current of air. The aryteno-epiglottic folds, epiglottis, and ventricular bands, and progressively in the order named, are swollen from infiltration into their loose connective tissue, impeding the passage of air into the glottis. The mucous membrane is tense and congested. This form of affection is not due to mere violence of inflammation, for in some instances the severity of the local phenomena bears no relation to the acceleration of pulse, heat of skin, nervous disturbance, and other manifestations of the accompanying febrile derangement, which is much less than in laryngitis confined to the mucous membrane. The tendency is to effusion, mechanically obstructing respiration, so that the local symptoms are much more severe than in superficial laryngitis, and more imperatively require immediate relief. In addition to the physical impediment to respiration, there is a tendency to reflex spasm, always to be dreaded in the presence of mechanical interference with respiration.

Evidence of inflammatory action is sometimes observed in the palate, tonsils, or pharynx; but almost solely in cases in which the laryngitis is limited to the upper portion of the larynx, or manifested there chiefly; and conversely, there is

rarely any evidence of active inflammation in the upper part of the throat, when the lower portion of the larynx is the sole or main seat of the laryngitis.

A peculiar form of acute laryngitis has been described as *chorditis vocales hemorrhagica*. In a case reported by Navratil,¹ the surfaces of the vocal cords were covered with a dark brown layer apparently the result of hemorrhage. Upon wiping the cords, the layer became detached, and the membrane beneath was red and swollen. In a few days another dark brown deposit was formed, and frequent local applications were required before its entire disappearance.

Symptoms.—When not of traumatic origin, acute laryngitis, if at all severe, is usually ushered in by chilliness, which is quickly followed by fever; sore throat being complained of very early. Severe pain is felt in the region of the larynx, very often described as scratching or burning, and usually exacerbated for the time by cough, expectoration, protracted use of the voice, or even the access of cold air to the parts. Tenderness is felt on pressure externally, and there is a decided sense of constriction within the larynx, as though from the presence of a foreign body or from compression outside. There is reason to believe that this sensation of constriction is occasionally due to spasmodic contraction of the constrictor muscles of the glottis on the one hand, or to a paralyzed condition of its dilator muscles on the other. Indeed, there is probably more or less of a spasmodic element, present or latent, in all severe affections of the larynx.² This condition is speedily followed by dyspnœa and dysphagia. The dyspnœa in the adult is by no means excessive, unless the patient becomes highly agitated and very restless. The voice, though not invariably affected, usually becomes hoarse, dull, and hollow in timbre, though occasionally shrill and piping; varying in character according to the position and amount of tumefaction and accumulated secretions; and it is emitted with some difficulty, and often only with actual pain, the enunciation of a sentence, or sometimes even a word, being interrupted by wheezing and prolonged efforts of inspiration, phenomena which are very characteristic of constriction, whether from spasm or from

¹ Laryngologische Beiträge, Leipzig, 1871, p. 18.

² A remarkable case of sudden death, from spasm of the glottis in moderate acute laryngitis supervening upon pharyngitis, is narrated by Gray in Holmes's Surgery, London, 1862, Vol. III., p. 226.

mechanical impediment above the glottis. Sometimes there is more or less dysphonia or actual aphonia from paresis of the vocal cords, usually with complete patency of the entire glottis (Fig. 98), and sometimes confined to its posterior portion (Fig. 99), due to interstitial deposit among the fibre-sheaths of some

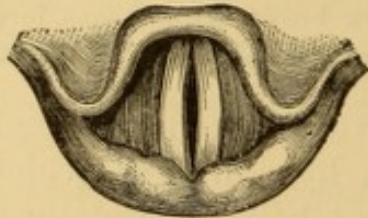


FIG. 98.—Gaping of glottis from incomplete tension of vocal cords (Ziemssen).

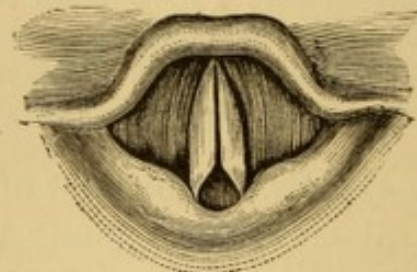


FIG. 99.—Gaping of arytenoidal portion of glottis (Ziemssen).

of its constrictor muscles. In other instances the ventricular bands are so swollen as to cover a large portion of the surface of the vocal cords in respiration, and to hide the greater portion of their surface anteriorly in phonation. The respiration becomes sonorous, sometimes with a metallic clang. The cough is painful, frequent and convulsive; sounding hoarse, deep, hollow, or brazen in tone, like the cough of croup; and it is usually accompanied by expectoration of viscid mucus, often in small pellets. It is sometimes spasmodic, and followed by inspiratory stridor. As the inflammation progresses, the fever increases, the local phenomena become aggravated, the patient exhibits anxiety as to the result, suffocative paroxysms of dyspnoea and of spasm of the glottis ensue, the countenance becomes cyanotic, and, unless relief is procured, or the morbid process subsides, death soon occurs by gradual suffocation and coma, or by veritable asphyxia; sometimes in a spasmodic closure of the glottis. Inflammation of the epiglottis and of the arytenoid cartilages is, as a matter of course, attended with a proportionate amount of dysphagia.

Diagnosis.—The presence of the subjective symptoms described, and the evidences in the laryngoscopic image of congestion and tumefaction of the aryteno-epiglottic folds, lateral walls of the larynx, ventricular bands, vocal cords, or epiglottis, as the case may be, with more or less encroachment on the normal calibre of the cavity of the larynx, of inaction or paresis of the muscles, as seen on voluntary efforts of respiration and phonation, are sufficient to establish the diagnosis. Laryn-

goscopic inspection suffices to distinguish the disease from croup; direct inspection of the throat affords evidence that the symptoms are not due to disease in that locality; and the history of the case will be different from that of traumatic laryngitis, foreign body in the larynx, or the laryngitis of tuberculosis and syphilis. Local inflammatory processes are recognized by their circumscribed aspect.

Prognosis.—In mild cases of idiopathic origin, the prognosis is good; and in severe cases it is likewise good, provided the physical condition of the parts is carefully supervised by laryngoscopic inspection, so that valuable time shall not be lost in inefficient and trifling measures after the case has become serious; and care be taken during convalescence lest undue exposure or other discretion lead to recurrence. In cases of deuteropathic origin the prognosis depends upon the nature of the primal malady, and is rarely as favorable as in idiopathic cases. In cases of traumatic origin, the prognosis is usually unfavorable, unless the local injury has been quite slight. Subacute catarrhal laryngitis may continue for a long time after subsidence of acute phenomena.

Acute laryngitis usually subsides without leaving any traces. Sometimes, however, especially if not properly managed, it declines into a chronic laryngitis, which, if neglected, is apt to terminate in ulceration; an opinion not in accord with views generally entertained. Even necrosis of the laryngeal cartilages sometimes follows acute idiopathic laryngitis. Occasionally it is the direct precursor of the development of morbid growths within the larynx. At times, too, it is followed by paralysis of the vocal cords.

In individuals of impaired constitution acute laryngitis may be followed by abscesses intra-laryngeal and peri-laryngeal; and these even by abscesses externally. Local inflammatory processes may be indicative of serious cachexia, and the prognosis is therefore to be more guarded.

Treatment.—In the treatment of acute laryngitis it is essential to arrive at a proper diagnosis at an early date, and to act promptly and efficiently, remembering that it is an acute malady, rendered more dangerous on account of the locality invaded than from the violence of its action, and that, for this reason, local treatment must take precedence of constitutional measures. The laryngoscope is here of the greatest service,

both for accurate appreciation of the condition and for accurate manipulation of local procedures.

General and local depletory measures, and the internal administration of remedies stimulating the various emunctories, are not available here as in inflammations elsewhere, because it is sometimes imprudent to wait for their action.

In the milder cases, the external application of leeches to the supra-sternal notch, and followed by emollient cataplasms, the administration of salines, and the inhalation of the steam of warm water, or of sprays of astringent solutions, such as alum or sulphate of zinc (two to five grains to the ounce), will be of great benefit, and be thoroughly efficient, with perfect rest of the larynx, silence, quiet, and the maintenance of an equable temperature. Medicinal treatment is not always indicated in these cases, and intra-laryngeal interference is sometimes pernicious. The use of warm drinks, or of other methods of inducing moderate diaphoresis, is advisable, and may sometimes be advantageously seconded by the frequent administration of small doses of aconite (fractional doses of a drop of the officinal tincture, U. S. P., every fourth of an hour for an hour or two, and then doses of one or two drops at intervals of an hour or longer, according to effects). If the local pain is severe, the watery extract of opium ($\frac{1}{4}$ –1 grain), or a small quantity of morphia ($\frac{1}{32}$ – $\frac{1}{8}$ grain), or the like, should be added to the solution inhaled by spray; and if there is considerable disturbance of the nervous system, anodynes in efficient doses should be administered by enema or subcutaneous injection. The German surgeons extol the internal use of mercury, with opium or hyoscyamus. Gibb and others recommend the local application of strong solutions of nitrate of silver or sulphate of zinc by probang or douche. Other observers extol preparations of iodine and carbolic acid in preference. I cannot recognize any indication for severe local measures, and although many patients recover in spite of them, not a few do much better without them. Bland fluids and semi-solid nourishment should be used to avoid local irritation of the parts in deglutition.

In severe cases with great tumefaction, especially when there is œdema, early scarification of the parts, or sometimes mere puncture, will be of very great service, disgorging the parts of their blood, and draining the serum from the tumid

swellings, promptly relieving the local symptoms, and rendering respiration efficient for the purposes of the economy in her own efforts at cure; for it is rarely that a second scarification becomes requisite.

Where scarification cannot be resorted to, tracheotomy should be promptly performed in the presence of urgent dyspnoea, that the lungs may receive a due supply of air to enable the system to pass through the normal stages of the inflammatory process. The air-passage should be opened as soon as practicable after the impediment to respiration becomes serious. If postponed too long, the blood will have become so thoroughly carbonized that freedom of respiration will not be followed by efficient oxygenation, and the patient will succumb a few hours after the local distress has been relieved. Furthermore, he may linger on for a few days, rid of dyspnoea, and perish ultimately from the effects of congestion of the lungs or brain, which has ensued from the prolonged inefficient aeration of the blood.

In acute traumatic laryngitis there is often an element of complication from direct destruction of tissue, and from the simultaneous lesions in the mouth and pharynx at the same time. In idiopathic acute laryngitis ulceration is rare, and usually confined to individuals seriously impaired in health by previous disease. Another complication in traumatic laryngitis is the formation of abscesses which require opening. These abscesses usually form in some part of the larynx near the point of injury; but they may occur in the structures adjacent to the larynx, and may dip down the sides of the throat, and even penetrate the tissues of the neck so as to present externally.

Inflammatory disease of the cartilages is not frequent in acute laryngitis. Local inflammatory processes are treated in the same manner as acute laryngitis of a mild type affecting the entire organ; but if great swelling or œdema take place, scarification is required.

Although the severe symptoms of acute laryngitis rarely continue longer than a few days, convalescence is occasionally very tardy, a protracted subacute catarrhal laryngitis sometimes lingering for some weeks after the severe symptoms of the acute malady have subsided. This often requires persistent treatment by repeated applications of moderately strong

(grs. xx., ad f. $\frac{5}{j}$.) solutions of nitrate of silver or sulphate of copper, aided, if need be, by the constitutional influence of iodine, mercury, or chloride of ammonium.

Acute Laryngitis in Children.—Acute laryngitis in young children, even when limited to the mucous membrane, is apt to be more severe than in adults. This is partly due to the greater delicacy and sensitiveness of the tissues, but also, in great measure, to the greater sensitiveness and excitability of the nervous system. Thus, phenomena of spasm, whether direct or reflex, will be more severe in themselves, and, on account of the small size of the glottis, more dangerous in their results. In like manner, paralysis of the glottis, preventing full inspirations, is more quickly followed by pulmonary and cerebral congestion.

The physical condition of the parts is similar to that in adults—hyperæmia, tumefaction, and hypersecretion, or even exudation into the tissues. This exudation may cause paresis of the muscles which dilate the glottis, and thus produce difficulty of inspiration. Sometimes a similar condition of paresis is due to direct irritation of the terminal nerve-fibres, or to reflex action.

A mild form of acute laryngitis sometimes attends difficult or painful dentition.

The cause is usually neglect, in permitting a child convalescing from some other affection, or suffering with a slight catarrh of the upper respiratory tract, to go about the house, the garden, or the street, instead of keeping him in his room, in an equable temperature. Taking a child out of bed to see a parade from a window has produced acute laryngitis in several instances under my own observation.

Symptoms.—The disease is sometimes ushered in, more or less suddenly, with hoarseness and cough, impairment of voice being rarely absent. There is reason to believe that it is always due, however, to some general or special cause, which is either concealed or has failed to attract attention. Sometimes it is preceded by coryza, pharyngitis, or bronchitis, the symptoms of which may have been too mild to occasion anxiety.

Like stridulous laryngismus, and like croup, it is usually at night that the special phenomena of paroxysmal cough,

with impeded, noisy, or stridulous respiration, first excite alarm, frequently rousing the patient rather abruptly from sleep. During the paroxysm the face becomes flushed, the pulse accelerated, and the general manner often exhibits great restlessness and apprehension. After a period variable in its duration from a few seconds to a number of minutes, these phenomena subside and sleep is resumed. A recurrence of the attack may take place during the night, or not come on until the following day or the next night. In the interval there are symptoms of moderate febrile reaction. The larynx is congested, as also, not unfrequently, the palate and pharynx, and sometimes the nostrils; the larynx is more or less tender to external pressure; the respiration is free, but somewhat quickened, and more or less sonorous, though there is no dyspnoea; the voice is more or less hoarse, often more especially so in the morning; the cough more or less hoarse and dry, occurring sometimes in paroxysms, sometimes in individual expiratory efforts only. Cough is often so painful, that some children will cry and clasp the neck after each paroxysm. It is usually worse at night than in daytime. In young children it is not accompanied or followed by expectoration. Sometimes there is disturbance of the digestive organs; but usually the general health does not appear to suffer. In a few days the phenomena gradually decline, and finally subside; respiration becoming quieter, the cough less frequent, less harsh, and now moist; the sputa, if expectorated, translucent; the voice, little by little, regains its ordinary quality of tone; the pain steadily decreases, and all direct evidence of the affection fades in from seven to fourteen days from the date of attack. In some instances the phenomena of spasm are slight, or entirely wanting, and the febrile reaction may be so insignificant as to give no evidence of its existence. At other times the spasmodic phenomena are excessive, and may threaten asphyxia, or even terminate in suffocation; and the febrile reaction is very great.

In some cases the local nervous phenomena are those of paralysis, instead of spasm. There is great difficulty of inspiration, as indicated by stridor, violent action of the auxiliary muscles of respiration, orthopnoea, rigidity of spine, retraction of head, and recession of the soft parts above the sternum, below the thorax, between the ribs, and even implicating the

ribs themselves in severe cases; expiration being performed with comparative freedom, or even without effort.

Diagnosis.—The suddenness of the attack, the character of the respiration, the hoarseness, pain on external pressure, and, where practicable, laryngoscopic inspection, will establish the diagnosis as differentiated from croup, œdema, foreign body, abscess of the pharynx, laryngismus stridulus, and other affections compromising respiration. Laryngoscopic examination in severe cases is practicable only in exceptional instances.

Prognosis.—This, in the absence of special complications, is favorable. Children who have suffered with acute laryngitis are more liable than adults to recurrence on exposure to cold. Children, too, are more liable to subsidence into semi-chronic catarrh, with prolonged hoarseness.

Treatment.—Moderate general antiphlogistic treatment is usually sufficient to subdue the acute laryngitis of children, care being taken, by due administration of nutriment, and, if necessary, mineral or other tonics, or even alcoholic preparations, to keep the strength as near the maximum as possible. The relaxing influence of the warm bath, and the inhalation of the steam of hot water, may often be resorted to with advantage. Mucilaginous drinks should be frequently pressed upon the patient. Belladonna in small doses is indicated, to repress the tendency to spasm. A prompt, non-depressant emetic of ipecac or alum is of use as a relaxant, especially if spasmodic paroxysms are of frequent occurrence. Difficult dentition requires attention to the gums; indigestion, an emetic or laxative, according to the indications. The local use of ice externally is often indicated. Sometimes benefit is derived from warm turpentine stupes. As there is no disposition to the exudation of pseudo-membrane, permanent impediment to respiration is not to be dreaded. Should œdematous effusion take place, the existence of which could almost always be detected by the finger, or should the element of spasm be so pronounced as to threaten suffocation, the operation of tracheotomy becomes necessary, as in the adult; though, in the case of serous œdema, the effusion could sometimes be discharged by rupturing the distended membrane with the finger-nail—a manœuvre which can be accomplished while making the digital exploration.

In cases where the difficulty in respiration seems to be

directly due to paralysis of the posterior crico-arytenoid muscles which dilate the glottis, the local use of iced cloths to the neck, repeated at intervals of one minute or thereabouts, will sometimes produce deep inspiration by reflex action at every renewal, and thus keep up a sort of artificial respiration until the condition gradually subsides. In a case attended by Dr. O'Hara and myself, these applications were continued at this interval for more than eight hours, with the result of saving a two-year-old child just convalescing from scarlatina anginosa, and in whom it was thought that tracheotomy was strongly indicated by the physical symptoms.

PHLEGMONOUS LARYNGITIS.

(Submucous Laryngitis; Diffuse Abscess of the Larynx; Laryngitis Phlegmonosa (Bouillaud); Laryngitis Submucosa Purulenta, seu Sero-purulenta (Cruveilhier); Angina Laryngea Infiltrata (Sestier); including Serous, Purulent, and Plastic Infiltration.)

This is an infrequent form of laryngitis. The inflammatory processes affect the submucous tissues especially, sometimes terminating eventually in diffuse abscess, sometimes in circumscribed abscesses. It is much rarer in children than in adults, and in females than in males. Though it occurs sometimes as an idiopathic inflammation,¹ and occasionally as an extension of acute catarrhal laryngitis, it is seldom encountered as a primary affection, but rather as a secondary one, following in the wake of erysipelas, measles, small-pox, scarlatina, diphtheria, typhus fever, and pyæmia; the various forms of perichondritis of the larynx; the inflammatory processes set up by foreign bodies; traumatic injuries, and the like. It is to be discriminated, on the one hand, from serous œdema of the larynx, though phenomena of œdema often attend it, and on the other from the sero-purulent infiltration of the submucous tissues occurring in some cases of catarrhal inflammation of the laryngeal mucous membrane. It is also to be discriminated from true erysipelatous laryngitis, with which it is not unfrequently

¹ For example see Cruveilhier: *Anat. Path.*, 1829-35, Liv. V., illustrated; and *Dict. de méd. et chir. prat.*, Paris, 1834, Vol. XI., p. 45.

confounded. These points have been mainly determined by the researches of Bouillaud, Cruveilhier, Valleix, and Sestier.

It is a very serious affection, terminating in suppuration, with destruction of the connective tissue, and sloughing of the superjacent mucous membrane; and in some instances leads to perichondritis, followed by necrosis of the cartilages, principally the arytenoids, occasionally the thyroid, which it nearly surrounds. Chronic or permanent thickening of the submucous connective tissue is apt to ensue, and this may result in stenosis of the larynx; and there is a tendency, likewise, to the formation of irregular aggregations of indurated tissue, which, pushing into the interior of the larynx, are not unfrequently mistaken for morbid growths. The mucous membrane is very apt to participate in the inflammation, sometimes in a great degree, perhaps always to some extent. Occasionally the inflammatory process extends to the submucous layers of the base of the tongue, pharynx, and soft palate; in addition to which the morbid action may involve the intermuscular connective tissues of these structures, under which circumstances it is apt to set up acute inflammation of the cervical and submaxillary glands, and even involve the connective tissue of the external structures of the throat. In other cases it surmounts the larynx, involves its external coverings, and then proceeds along the subcutaneous tissues of the neck, the purulent accumulations in these localities being continuous with those within and around the larynx.

Its most frequent seat is the upper portion of the larynx, the base of the epiglottis, and the aryteno-epiglottic folds, but it may also involve the ventricular bands, ventricles, vocal cords, and other constituents of the larynx. There is tumefaction of the supra-glottic structures especially, but to a less extent, as a rule, than occurs in œdema of the larynx. Much of this tumefaction, at least toward the last, is due to purulent infiltration. Occasionally it is found below the glottis; but here it seldom gives rise to much mechanical difficulty in respiration.

A case of subglottic œdema related by Gibb, in which he found the infiltration simulating a morbid growth, might have been of this nature.

Symptoms.—The subjective symptoms, often preceded by several days of general malaise and disquietude, are similar to

those of œdema of the larynx, but they are less in degree, slower and more gradual in their progress, and are attended with the phenomena of fever. They may be summed up in pain, dysphagia, hoarseness, cough, expectoration, dyspnœa, and, toward the last, delirium. Their progress is slow, because a certain amount of time is required for the inflammatory processes to terminate in suppuration; and it is the purulent accumulation in the submucous tissues that occasions the local symptoms. As the external tissues become implicated, the dyspnœa and dysphagia increase, saliva runs from the mouth, and the febrile condition becomes more and more adynamic. When there is fluctuation externally, the influence of palpation will sometimes be evident laryngoscopically, showing direct communication between the peri-laryngeal and intra-laryngeal purulent accumulations.

Diagnosis.—This would rest on the group of subjective symptoms, and the laryngoscopic recognition of the tumefaction already described on the interior of the throat. Later on there are external evidences of swelling in the subcutaneous areolar tissues of the neck and chin, which may be so great as to prevent opening the mouth. There will be fluctuation on palpation, and visible evidence of intercommunication between the several fluctuating tumors, should there be more than one.

Prognosis.—In severe cases, with extensive diffuse suppuration, the prognosis is unfavorable, death being almost inevitable at a period varying from a few days to three weeks. In cases involving the planes of fascia in the pharynx and external tissues it is still more unfavorable. The sloughs are very extensive, septic poisoning usually ensues, and death soon follows. Sometimes death occurs from asphyxia. Recovery takes place in more favorable cases, sometimes with permanent induration of the submucous tissues, and more or less stenosis in consequence.

Treatment.—In the early stages the external application of leeches, followed by warm fomentations and the inhalation of sedative vapors, may be resorted to with hope of benefit, according to some observers. The internal administration of large doses of quinia and the free use of stimulants are indicated. The food should be nourishing and easy of digestion. In case of great difficulty in swallowing, food and stimulus should be given by enema, and quinia by hypodermic injec-

tion. Intra-laryngeal scarification is not usually adequate to discharge the infiltration, but it is quite possible that it may occasionally furnish points for subsequent escape of pus. When the external portions of the larynx are engaged, and still more so when the overlying subcutaneous layers are involved, free and large incisions should be made externally and followed down to the suppurating tissues. These incisions often fail of accomplishing their object. If there is great dyspnoea, laryngotomy or tracheotomy affords the only means of relief, although it is rarely successful in averting a fatal result.

An unpromising case operated upon by Dr. Pollock,¹ in which an hour was occupied in performing laryngotomy, eventually recovered, although the operation had been undertaken with but little hope of saving life.

ERYSIPELATOUS LARYNGITIS.

As already noted (Erysipelatous Sore Throat, p. 113), erysipelatous laryngitis was not infrequent formerly in hospital practice during the prevalence of epidemic erysipelas.² It is usually associated with erysipelas of the tongue, palate, and pharynx, by which it is sometimes preceded. It sometimes occurs as a metastasis of external erysipelas, which subsides as the internal structures are engaged.³ It may occasion fatal œdema of the larynx.

The inflammatory process soon terminates in extensive supuration, diffuse abscess, and sloughing, involving intra-laryngeal and peri-laryngeal structures, as well as the epiglottis and other cartilages, and the trachea.

Symptoms.—The symptoms are those of adynamia, with local pain, dyspnoea, dysphonia, and dysphagia, followed by nausea, vomiting, and delirium.

Diagnosis.—Evidence of external erysipelas, or of erysipelas of the mouth and pharynx, are usually necessary to establish the diagnosis. But few laryngoscopic examinations have been made in the disease. The interior of the larynx is de-

¹ The Lancet, Sept. 5, 1863.

² For a graphic description, as it occurred in an epidemic of "black-tongue" in the United States, during 1844, '45, and '46, see Gross: System of Surgery, Phila., Vol. II. Consult also Gibb: Op. cit., p. 232. Porter: On the Larynx and Trachea, Dublin, 1837. Ryland: Op. cit.

³ Porter: Op. cit., p. 95.

scribed as red, lustrous, and tumefied, with more or less manifestation of submucous infiltration. The image, then, is simply that of laryngitis, and presents nothing characteristic, like the demarcating line of cutaneous erysipelas. In a laryngoscopic examination reported by Tuerck¹ (Fig. 100) the mucous membrane covering the left supra-arytenoid and cuneiform cartilages was much swollen, obstructing a view into the interior, and the visible portion of the ventricular band of the same side was moderately reddened and swollen, and covered the vocal cord almost completely. The arytenoid cartilage and the vocal cord were immovable. The posterior surface of the epiglottis, as well as the greater portion of the upper laryngeal mucous membrane, was only moderately congested. The laryngitis, in this instance, attended erysipelas of the face.

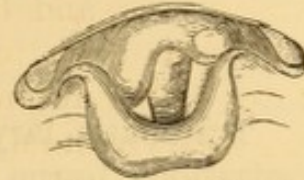

FIG. 100.—Erysipelatous laryngitis (Tuerck).

Prognosis.—This is unfavorable. But few cases of recovery have been reported. In some epidemics, in hospital, the disease has been uniformly fatal, death often occurring within two or three days. In cases of recovery convalescence has always been tardy, occupying several weeks.

Treatment.—The treatment recommended is nutritive, tonic (tincture of chloride of iron, and quinia), and stimulant, from the very outset, with the use of anodynes to allay pain and repress cough. Ryland and Gross admit the use of leeches externally in young and robust subjects, and the subsequent application of blisters. Inhalation of steam from hot water is esteemed by Ryland as a valuable local measure, often capable of enabling the vessels of the dry and inflamed mucous membrane to relieve themselves by secretion. Prof. Gross states that emetics are often serviceable, especially when the throat and air-tube are clogged with mucus, and that the bowels should be gently evacuated with a mild mercurial purgative. The case of Tuerck referred to recovered under the use of pellets of ice and an oleaginous mixture. In a case examined laryngoscopically by Gibb,² the local application of a solution of nitrate of silver (four scruples to the ounce of water), every six hours, repressed a commencing supra-glottic œdema, the patient being out of danger within forty-eight hours.

¹ Op. cit., p. 161.

² Op. cit., p. 232.

In presence of asphyxia or excessive dyspnœa, tracheotomy is recommended by Ryland, Gross, and Gibb ; but it is unhesitatingly condemned by Porter ; and my own researches into literature have not discovered a single record of life rescued by its agency.

TRAUMATIC LARYNGITIS.

Traumatic laryngitis is most frequently the result of cauterizations, burns, and scalds (laryngitis combustionis) of the mucous membrane, occurring under circumstances already narrated (see Traumatic Sore Throat, p. 98). It also results from wounds and injuries, as discussed under a separate heading. It may be the result of accident or of suicidal effort. In the former case the inflammation is usually confined to the mouth, pharynx, larynx, and nares ; in the latter the œsophagus and stomach may be implicated also, the act of deglutition being completed in the one instance, and arrested with regurgitation in the other.

Boiling water, not being taken designedly, is rarely, if ever, swallowed, spasmodic regurgitation taking place before the act of deglutition is completed.

I have consulted the records of a large number of cases in which boiling water had been accidentally taken into the mouth, and in which death ensued as a consequence of the resulting laryngitis, and in none of them had there been any evidence of the fluid having reached the stomach, and in most of them it had not even penetrated into the upper portion of the œsophagus. I am not aware of the record of the voluntary deglutition of boiling water for suicidal purposes, but presume that, in a case of the kind, the fluid would reach the stomach, just as acid and other caustic substances do under similar circumstances.

The development of the laryngitis is usually exceedingly rapid, often immediate, and generally attended with extensive œdema of the larynx. The inflammation is usually confined to the supra-glottic portion of the larynx, but sometimes it extends secondarily to the trachea and bronchi, and even to the lungs. In some instances it is confined to the pharyngeal surface of the larynx ; in others a plastic exudation, resembling the plastic exudation of croup, has been found in the larynx, trachea, and bronchi, after death. The inflammatory

action is rarely confined to the mucous membrane, but rapidly implicates the submucous tissues.

The manifestations of the injury are not always immediately apparent.

Porter¹ states that he knew a young girl, after swallowing a dose of sulphuric acid, to sit quietly and drink tea with some females, who were afterward suspected of having poisoned her, although the dose had been so powerful that she died in a few hours; and that he was aware of a man who took a second draught of the same acid, because he thought the first was not sufficiently quick in despatching him.

Symptoms.—The symptoms are those of acute laryngitis, with pain, soreness on swallowing, dyspnœa, hoarseness, etc.

Diagnosis.—The diagnosis of acute laryngitis from scalds and burns is usually easy, especially in the adult, except when the nature of the accident is purposely concealed by the determined suicide. There is severe local pain, rapid pulse, and other evidence of vascular excitement; dysphagia, dyspnœa, with its usually attendant stridulous inspiration; dysphonia; pallor of the countenance; coldness of the extremities; and considerable nervous excitement.

If the case is seen early, and the parts can be subjected to inspection, the mouth, base of the tongue, the palate and the pharynx, altogether or in part, are swollen, and of a white color, often from detachment of the epithelial layer in a membranous form, or from prompt plastic exudation. Patches of destruction of the mucous membrane are visible in greater or less profusion and extent, and there is abundant evidence of inflammatory tumefaction of the mucous membrane and submucous tissues.

Prognosis.—This is unfavorable. Severe cases are almost inevitably fatal; and, if the patient recovers, it is often with permanent stenosis of the larynx, requiring the continuous retention of a tracheotomy-tube for purposes of respiration.

Treatment.—The treatment consists in the administration of anodynes hypodermically and by inhalation; nourishment and stimulation by enema; and the local application of small pieces of ice in the mouth, with cold compresses or ice-bags about the neck; to which is to be added the performance of tracheotomy on the supervention of symptoms of suffocation.

¹ Op. cit., p. 178.

Inhalations of the spray of a solution of acetate of lead, or its frequent projection on the parts, are applicable by virtue of the beneficial effects of lead in scalds and burns of the cutaneous surface. Saturated solutions of carbonate of sodium may prove useful in like manner. Mucilaginous drinks are very soothing if they can be swallowed; and similar relief occasionally attends their mere retention in the mouth when swallowing is impracticable.

Calomel, in doses of two or three grains every hour, increasing the interval if its beneficial effects are prominent, as is sometimes the case, is highly recommended by most surgeons. The external application of leeches to the neck, and in some cases the use of blisters following, has also proved efficacious in the hands of Porter and Ryland; the former of whom states that he "can scarcely recollect a case, even where bronchotomy afterward became necessary, in which the application of leeches to the throat in the early stages was not followed by a marked, although it might be only temporary relief; and many cases have occurred in which a perseverance in such a line of practice has been attended with success as decided as it was unexpected."

The operation of tracheotomy, or of laryngotomy, is usually indicated, however, and should not be too long postponed. Inasmuch as the inflammation rarely extends below the vocal cords, owing to the spasmodic closure of the glottis at the moment of injury, there is no objection, as a rule, in performing laryngotomy through the crico-thyroid membrane, especially in the adult, in whom the parts will admit the insertion of a tube large enough for respiratory purposes.

The operation, though by no means always competent to save life in the adult, offers more hope of success than it does in children. Children are more likely to suffer from pulmonary complication after the operation, and from profuse hemorrhage, proportionally, during its performance, which is sometimes tedious from various complications; and, as loss of blood is illy borne where there has been much impediment to respiration, they are the more debilitated in consequence.

Suppuration is very great, should the patient survive; and chronic laryngitis usually remains, sometimes with stenosis of larynx or trachea, and stricture of œsophagus. Sometimes sloughing of the arytenoid cartilages (Ryland) has been observed.

ABSCESS OF THE LARYNX.

Primary circumscribed abscess of the larynx is very infrequent.¹ It is often fatal mechanically by asphyxia, sometimes within a few hours.

Stromeyer relates a case in which a cavalryman was suddenly suffocated at five P. M., having been well enough to be on parade at noon of the same day. He had complained for a few days of discomfort in the throat, but had not reported himself sick. An abscess the size of an acorn was found at the base of the epiglottis, and this had led to fatal œdema glottidis.

Secondary abscess is not infrequent, and is generally occasioned by laryngeal perichondritis or chondritis. It may occur in tuberculosis, syphilis, typhoid fever, pyæmia, glanders, and other systemic diseases; or follow retention of foreign body and various other local injuries.

In typhoid fever cases, small abscesses usually form beneath the mucous membrane, and larger ones beneath the perichondrium. They generally occur during the second and third weeks, and sometimes not until convalescence has commenced. In some instances they are associated with abscesses in the nasal passages, palate, and pharynx. They sometimes give rise to œdema of the larynx.

Abscess of the larynx, as reflected in the laryngoscopic mirror, appears as a glistening circumscribed swelling, red at its base, sometimes red, sometimes yellowish, at its apex. Abscesses have been most frequently observed upon the lower laryngeal surface of the epiglottis, the inner surfaces of the arytenoids, the supra-arytenoid eminences, the inner surfaces of the aryteno-epiglottic folds, and upon the inner surface of the inter-arytenoid fold. They are due to circumscribed inflammatory processes involving the submucous tissue or some of the laryngeal mucous follicles. An abscess of the larynx will in time open spontaneously into the larynx. The pus discharged therefrom is sometimes sanious. Whenever the abscess is opened, the pus is discharged by cough, usually with immediate relief to the symptoms of pain, tension, and hoarseness.

¹ For examples, see Schmidt's Jahrb., 1863, Bd. 118; Marcet and Hillman, The Lancet, 1868, p. 757.

Occasionally a second abscess will follow closely on the first, and sometimes be succeeded by a third or even a fourth some months later.

Symptoms.—The local symptoms are pain, cough, dyspnoea, and dysphagia.

Diagnosis.—Laryngoscopic inspection is often the only certain method of diagnosis of intra-laryngeal abscess. In children it may be confounded with croup, tonsillitis, and retropharyngeal abscess.

Prognosis.—The ultimate prognosis depends on the character of the primal disease and its susceptibility to cure. The immediate prognosis is good, provided the abscess can be discharged. Stenosis sometimes results after cicatrization.

Treatment.—In favorable cases the abscess can be punctured or incised with properly curved instruments under guidance of laryngoscopy. When this is impracticable, and asphyxia is imminent from the location of the abscess, or from intercurrent œdema, the propriety of tracheotomy comes under consideration, especially if there be any tendency to spasm of the glottis.

ŒDEMA OF THE LARYNX.

(Œdematous Laryngitis, Submucous Laryngitis, Supra-glottic and Infra-glottic (Cruveilhier), Dropsy of the Larynx; Œdema Laryngis [incorrectly Œdema Glottidis (Bayle)], Œdema Submucosum Laryngis, Angina Laryngea Infiltrata (Sestier), Angina Laryngea Œdematosa (Thullier).)

Under certain conditions, a serous, sero-sanguineous, or sero-purulent infiltration takes place with more or less rapidity beneath the mucous membrane or into the submucous connective tissue of the upper portions of the larynx, and chiefly upon the inner surfaces; the serous effusion occurring in cases that run their course with great rapidity, and the sero-purulent, or, in some instances, purulent infiltration occurring in cases in which the morbid action is slower and less violent. In some instances a fibrinous exudation takes place, and in others a hemorrhagic infiltration. The term œdema of the larynx is employed to denote any fluid or semi-fluid effusion into the submucous connective tissue of the interior of the larynx, or of either surface of the epiglottis.

The mechanical result of œdema of the larynx is first to impede respiration, and subsequently to obstruct it; and if subsidence does not soon occur spontaneously, which is rarely the case, or if the condition is not promptly relieved by surgical interference, the patient perishes by suffocation, or by congestion of the lungs and brain, the result of obstructed respiration; death occurring at a period varying from a few hours to a few days.

Although the morbid action is prominently located in the submucous connective tissue, it has been found, not unfrequently, that the mucous membrane itself has also been the subject of inflammation.

In addition to the mechanical impediment to breathing presented by the infiltration into the submucous connective tissue, there is reason to believe that there sometimes exists a condition of spasm, and sometimes a condition of paralysis of the muscles controlling the opening and closure of the glottis, inasmuch as it has been found, in the post-mortem examinations of some fatal cases, that the amount of tumefaction was insufficient wholly to account for the impediment to respiration during life. Prof. Stromeyer¹ has called attention to the circumstance that this observation has not yet had a very great influence therapeutically, at least as far as concerns the employment of direct remedies against spasm and paralysis.

My own observations of cases of œdema of the larynx, as viewed under laryngoscopic inspection, has shown me that the encroachment upon the normal breathing orifice is sometimes much less than could have been anticipated before the examination. Although the elements of spasm or of paralysis may be in some instances regarded as portions of the direct pathological sequence of the affection, there is reason to believe that the extreme nervousness induced by that dreadful fear of a fatal result which attends many cases of impeded respiration, whatever their cause, has much to do with these phenomena of spasm and paralysis.

I can recall one instance in which I counselled tracheotomy on these grounds; but the idea of the operation was only tolerated by the physician in charge of the case, and not entertained as requisite at all by the surgeon called in consulta-

¹ Verletzungen und chirurgische Krankheiten der Halsgegend, Freiburg, 1865, p. 348.

tion, for the reason that the size of the aperture of the glottis still remaining patent was much larger than the calibre of the ordinary tracheotomy-tube. My own services having been employed merely as an expert in laryngoscopy, to demonstrate the amount and nature of the disease in the larynx, my suggestion was not appreciated, and the patient perished miserably afterward by suffocation, verifying the value of the opinion offered as to the probable result in case the operation should be neglected.

Acute Œdema of the Larynx.—The most frequent seat of acute œdema of the larynx is in the aryteno-epiglottidean folds, usually both of them. In some instances an effusion occupies the lax tissues of the epiglottis at the same time; in others it is confined to the epiglottis. Occasionally it implicates the lips of the glottis,¹ converting them into thick, obstructing pads; but the infiltration, under these circumstances, occurs in the tissue of the thyro-arytenoid muscles, rather than in the space between the vocal cords and their enveloping mucous membrane. To such cases alone should the term œdema of the glottis be restricted—a term too generally employed to denote every other form of laryngeal œdema likewise. In some cases the œdema involves only the tissues immediately below the vocal cords, constituting sub-glottic œdema of the larynx, a form of this affection to which Dr. Gibb² has prominently directed attention, and which had previously been described by Cruveilhier as *laryngitis sous-muquese, sous-glottique*.

Occasionally, also, there will be œdema in the submucous tissue of the trachea, six instances of which were collated by Sestier as occurring among a total of 132 cases of œdema of the larynx. Simultaneous infiltration at the base of the tongue and in the pharynx is more frequent.

Before the present century the pathology of this malady was misunderstood. The symptoms to which it gives rise were usually inferred to be denotive of croup in the adult;³ for, although the affection has been known to occur in the infant at the breast (even, in at least one reported instance, a new-born babe),

¹ See report of immediate post-mortem appearances in a rapidly fatal case. Risch: Berlin. klin. Woch., 1866, No. 33; Ziemssen's Cyclop., N. Y., VII., p. 798.

² Op. cit., p. 211, et seq.

³ The illustrious Washington is supposed to have perished as a victim of œdema of the larynx, after an illness of less than twenty-four hours. Dr. Pitcairn, who lost his life by it in 1808, declared, according to Porter and the author of "The Gold-Headed Cane," that his disease was to be considered as croup.

and, on the other hand, in extreme old age (a case being reported at eighty-one), it is rare before the fifth year and after the sixtieth, the greatest proclivity occurring between the twentieth and fortieth year—men being affected much more frequently than women. Post-mortem evidences of the disease had been described by Morgagni in his letter on serous apoplexy, as quoted by Bayle; and later by Bichat, in his descriptive anatomy; and symptoms strongly suggestive of the disease had been described long previously; but its accurate recognition dates from a since famous paper on œdematous laryngeal angina, communicated by M. G. L. Bayle to the Society of the Parisian School of Medicine, in the early part of the present century.¹ Since this period the literature of this disease has been quite full, and many lives are now saved by a due appreciation of its nature and the rapidity of its course.

Impediment to free venous circulation in the laryngeal tissues, from inflammatory processes, from mechanical obstruction, or from paralysis of the walls of the vessels, is the immediate physical cause of the transudation, as in many serous accumulations elsewhere. The remoter cause may be idiopathic or deuteropathic disease, or mechanical or surgical injury. Œdema of the larynx sometimes occurs in the progress of acute catarrhal laryngitis, and constitutes the chief source of immediate danger in that affection. It has ensued upon deglutition of very cold water, and upon prolonged vocal effort. It often occurs in the traumatic laryngitis caused by accidental deglutition of hot liquids and caustic solutions, or by the presence of foreign bodies.² It sometimes occurs in the course of pharyngitis, whatever may have been its origin, even in simple sore throat. It has been occasionally encountered in the stridulous catarrhal laryngitis of children.

It sometimes occurs suddenly during the course of various diseases, and is not confined to maladies ordinarily accompanied by affections of the throat.³ It is most apt to occur in

¹ *Memoire sur l'œdème de la glotte ou angine laryngée œdémateuse*, Paris, 1808.

² Ziemssen mentions a case in which a patient died of inflammatory œdema of the larynx within a few minutes of entering the clinic at Greifswald, from penetration of the wall of the right ventricle of Morgagni by a sharp piece of the rib of a tobacco-leaf. The patient, who had come there on account of Bright's disease, was sitting in a wagon smoking a cigar when he arrived. Ziemssen's *Cyclopædia*, N. Y. Ed., VII., p. 794.

³ Dr. Farre records a case suddenly supervening in a case of jaundice from obstruction of the hepatic duct. *Lancet*, April 21, 1860, p. 393. Dr. W. Moore records the case of a medical gentleman suffering under abdominal aneurism, in whom temporary and recurrent aphonia was found by Dr. Smyley to be due to œdema of the vocal cords. *Dub. Quart. Jour.*, Aug., 1869, p. 13.

the waning stages of disease, in the stage of convalescence, or defervescence rather, probably from want of due protection from exposure to currents of air. Thus it has been encountered in scarlatina, measles,¹ small-pox, erysipelas, typhus and typhoid fever,² glanders, nephritis,³ Bright's disease of the kidney, whooping-cough,⁴ pulmonary catarrh, pneumonia, croup,⁵ diphtheria, and in organic diseases productive of anasarca.

It is sometimes produced in the course of chronic laryngitis of tuberculous and syphilitic origin; in laryngeal chondritis and perichondritis; in the irritative laryngitis due to the presence of morbid growths; in the pharyngitis accompanying malignant disease of the tongue, pharynx, and œsophagus, whether directly implicating the larynx or not; in glandular and other tumors in the cervical and mediastinal regions; in thoracic and abdominal aneurism of the aorta; in cases of abscesses and ulcerations of the larynx, whatever their character; in cases of abscesses and morbid growths in the vicinity of the larynx; in cases of injuries, wounds, and fractures of the larynx; in cases of wounds or other injuries to the soft parts of the throat and the parts adjacent, or to the large blood-vessels in their neighborhood. It occurs traumatically from attempts at removal of morbid growths from the larynx, in which the epiglottis, aryteno-epiglottic fold, or supra-arytenoid cartilage is seized and compressed in the blades of the forceps, or from severe cauterizations or other severe local therapeutic measures.

There is reason to believe that it may occur as part of the phenomena of acute iodism⁶ and mercurialization, even though there has been no direct exposure to cold.

¹ For examples, see Ryland: *Op. cit.*, Case IV.; Pilcher (*An Epidemic of Measles*, 1876, p. 5) mentions a case requiring tracheotomy twice within a fortnight.

² Consult Emmet: *Am. Jour. Med. Sci.*, July, 1856.

³ For fatal examples, see Thompson: *St. Geo. Hospl. Rep.*, London, 1868, III., p. 302; Hayden, *Brit. Med. Jour.*, April 11, 1874, p. 489.

⁴ See Barthez: *Gaz. des Hôp.*, 1869, 32.

⁵ *Gaz. des Hôp.*, 1869, p. 25.

⁶ For examples, see Nélaton: *Abeille méd.*, X., p. 317; Laurie, quoted in Stille's *Therapeutics*, II., p. 763; *The Lancet*, Nov. 13, 1875, p. 698. In addition, I may mention two instances from my own practice: one under my own care, fatal suddenly while the patient was at his toilet in his bath-room; the other, seen in consultation, fatal from refusal to undergo tracheotomy.

When idiopathic, it is more frequent in men than in women, and in free-livers than in more temperate persons.

Although occurring in individuals in good general health, it is more apt to take place in those of impaired constitution, or recently convalescent from acute diseases; and in some instances there would appear to be some peculiar predisposition toward its occurrence, the nature of which is not understood; for examples are on record of more than one attack in the same individual.

Under all circumstances, the immediate exciting cause, when apparent, seems to be exposure to cold and moisture.

Symptoms.—The occurrence of acute œdema of the larynx is sometimes so insidious or so sudden that there are no appreciable *ante-mortem* symptoms at all.

Van Swieten relates that Boerhave knew a man who, while dining, suddenly spoke with a change of voice, which his companions took as a joke; but he fell dead, and an examination revealed œdema of the glottis.¹

Dr. Porter² mentions two instances, within his own recollection, of young men who had retired for the night without complaining, and who were found dead from this affection on the following morning. Albers relates the case of a servant-girl who had been suffering some days from hoarseness, and who died suddenly from suffocation upon drinking some cold beverage after being overheated in the dance. Ruehle³ mentions two: a young man with swollen tonsils came home late one night, overheated from the dance, and was found dead in bed next morning from serous infiltration of the ary-epiglottic folds, which had suffocated him without awakening him. A servant-girl, a trifle hoarse, went out lightly clad in the morning, and suffocated while going upstairs on her return.

Sometimes, again, the symptoms are so sudden and overwhelming that the patient is suffocated, even in hospital practice, before aid can be procured.

When accompanying other affections, or following them, œdema of the larynx may be preceded by the usual prodromes of inflammatory fever; but, as a rule, its symptoms are marked, in most cases coming on more or less suddenly, and increasing in severity with great rapidity. These symptoms are usually more or less local tenderness, which, only in some cases, amounts to actual pain; dryness, and heat in the throat, with a sense of constriction, as from the presence of a foreign body there; difficulty of inspiration, sometimes accompanied by a

¹ Ruehle: *Op. cit.*, p. 158.

² *Op. cit.*, p. 82.

³ *Op. cit.*, pp. 50, 51.

harsh whistling or stridulous sound, and increasing, as the disease progresses, to all the phenomena of impending suffocation; cough to a greater or less degree, which is often ineffective, because the impediment to respiration, or to patency of the entrance to the respiratory organs is of a permanent character, and not due to accumulations of matters that can be expectorated; feebleness, hoarseness, or extinction of voice; more or less dysphagia, which sometimes amounts to complete inability to swallow, forcible attempts at which have occasionally been immediately productive of a fatal issue.

The patient soon becomes restless, then anxious lest he suffocate; perhaps he tries to sleep, and may actually slumber for a few moments, but he awakens after a very short interval, again a victim to his wretched sensations of choking. The face is flushed, the eyes prominent, the respiration hurried, and sometimes spasmodic, and the pulse small, quick, and tremulous, and accelerated to 100 beats and more in the minute.

Usually, however, the earlier suffocative paroxysms subside spontaneously, leaving intervals of impeded respiration. The obstruction in breathing is at first limited to inspiration, and is due to the valve-like occluding inward pressure of the tumid folds of membrane by the atmospheric current; but, as the disease progresses, expiration becomes mechanically impeded also.

When the œdema is dependent on acute disease, the suffocative paroxysms will be abrupt, violent, and occur irregularly at intervals of a few hours. When the result of chronic disease, the dyspnœa gradually increases until it culminates in a paroxysm of suffocation, which passes off with more or less relief to the general respiration, to recur, as the disease progresses, in the course of a few days, or perhaps a few weeks. Finally, however, these irregular intervals become shorter, until several paroxysms occur within the twenty-four hours, being, as a rule, more violent at night than in the daytime.

Diagnosis.—Simple inspection of the throat usually reveals more or less inflammation of the structures within sight, and sometimes infiltration of the palate, uvula, tonsils, and occasionally even of the pharynx; but very often no evidence of the disease is apparent in those organs. The infiltration of these parts is most apt to occur in œdema, the result of acute inflammation. It is chiefly only in cases involving the upper

structures of the larynx that inflammatory manifestations are found in those parts of the throat exposed to ordinary inspection.

Laryngoscopic inspection reveals the nature of the lesion at once. Exploration with the finger is almost always practicable, and permits the detection of the swollen structures, as far as regards the implication of the epiglottis and the aryteno-epiglottic folds. Care is requisite in prosecuting this digital manipulation, on account of the liability to suffocation. Prof. Trousseau mentions¹ a case in which he induced in this way a suffocative paroxysm which he had feared would prove fatal. Manipulation of the larynx externally, lifting it forward and upward, gives no relief to the dyspnœa as it does in cases of retro-pharyngeal abscess, and is thus one mode of differential diagnosis, especially in children.

When the epiglottis is involved, the œdema can very often be recognized on pressing down the tongue, appearing usually as a bladder-like eminence projecting above the base of that organ, varying in size from that of a peanut, which it not unfrequently resembles in configuration, to that of the bulk of a walnut; and it is occasionally, as in several cases seen by myself, constricted in its central portion by the glosso-epiglottic ligament, giving the appearance of two bladders rather than one. Occasionally the swollen aryteno-epiglottic folds can be brought into sight by inducing an effort of retching, which raises the entire larynx; but when the epiglottis is swollen they are less readily revealed. Sometimes the lingual surface of the epiglottis is not involved, and in such a case a casual exploration of the structures might fail to determine the diagnosis.

Viewed by its image in the laryngoscopic mirror, the aspect of œdema of the larynx (Fig. 101) is very characteristic. A pale reddish, or sometimes yellowish swelling, translucent, irregularly globular or oval in outline, in general appearance not unlike an œdematous prepuce or

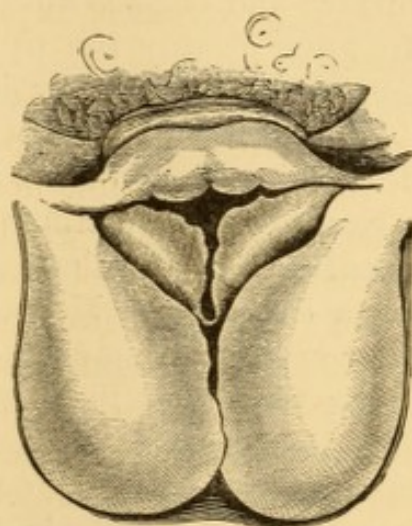


FIG. 101.—Œdema of the larynx.

¹ Clinical Medicine, Trans., Vol. III., p. 98.

eyelid, is seen to occupy the aryteno-epiglottic folds, usually both of them, though not always in equal extent, but sometimes on one side only. These swellings project toward each other, and narrow the upper orifice of the larynx into a mere slit, which becomes still narrower during inspiration from the downward pressure of the air, slightly forcing the swellings together, so that sometimes their surfaces adhere; while during the passage of the expiratory current they are more or less separated, and sometimes sufficiently so to permit a view of the parts below. Usually all distinct delineation of the so-

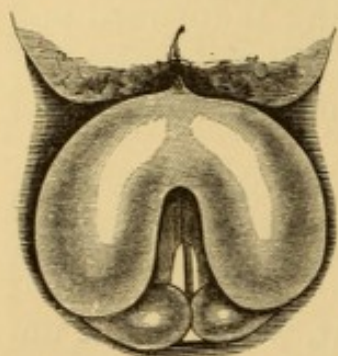


FIG. 102.—Œdema of the epiglottis.

called false vocal cord is obliterated, the entire mass, ary-epiglottic fold and ventricular band, presenting as one and the same structure. The parts are rarely vascular, and are sometimes more or less coated with masses or layers of mucus. When the epiglottis is involved, it is seen as a huge mucous sac, distended with a limpid fluid, overhanging the laryngeal entrance, and often preventing a view of the interior of the larynx (Fig. 102). The

laryngeal face is only exceptionally implicated, but the lingual surface and crest is almost always affected. When the œdema does not occupy the upper portions of the larynx, the lower portions are seen to project laterally in dropsical protrusion.

Prognosis.—Œdema of the larynx is a very serious affection, on account of its liability to produce suffocation. Such a result has been known to occur at the very first evidence of the attack, before there had been any opportunity of establishing a diagnosis. Hence it is essential to be able to recognize the condition promptly, and to treat it efficiently, lest temporizing treatment may sacrifice a patient whose life ought to have been saved. In serous œdema in idiopathic cases, and in cases occurring in the course of acute affections in robust subjects, the prognosis is favorable, provided prompt measures are taken to relieve the venous congestion, and to evacuate the effused fluids. In sero-purulent and purulent œdema it is much less favorable, and in the œdema occurring in the course of diseases in themselves fatal—as aortic aneurisms, malignant tumors, and tuberculosis—it is unfavorable. The deuteropathic œdema of acute systemic affections proffers but a doubt-

ful prognosis, and depends upon the progress of the disease after the institution of measures adapted to relief of the dyspnoea.

Treatment.—The best treatment for œdema of the larynx consists in making efficient incisions into the tumid swelling. This affords egress to the pent-up fluids, and usually arrests the threatening symptoms at once. The operation may be readily performed with a long, well-curved bistoury, protected to within a short distance of its point, and directed to the parts by the guidance of the finger upon the swelling, or upon the epiglottis. In an emergency I have used the ordinary gum-lancet with success. Under laryngoscopy, the laryngeal knife of Gibb or of Tobold affords much greater security in operating, and in great measure obviates the danger of wounding parts that should not be cut into. The spasm produced by the operation is usually insignificant. But little blood is lost, as a rule—a drachm or two perhaps, and sometimes much less; but occasionally the bleeding is profuse, requiring the most assiduous coughing to expectorate it; so that, despite the relief to the general dyspnoea, the patient has to cough for his life.

In one instance under my own hands, where œdema of the aryteno-epiglottic folds had ensued suddenly during a laryngitis of syphilitic origin, the external and internal application of ice for many minutes was requisite to restrain a bleeding of really alarming character; so that tracheotomy had been determined upon in case of a recurrence of the œdematous condition, which fortunately did not take place.

When the bleeding is but slight, it should be encouraged by a warm water gargle, or the inhalation of steam. Scarification of the external portion of the folds, or their external edges, is less liable to excessive hemorrhage, and floods the pharynx instead of the larynx. I have resorted to it on several occasions with satisfactory results. After the scarification, the parts are seen to be wrinkled, and present bloody marks of the incisions. In some instances, where the tumid swellings are acuminate and the tension very great, a few punctures rapidly made with a lance-bladed laryngeal knife will give sufficient egress to the serous effusion. This operation is less serious than scarification, and cannot replace it in severe cases.

In acute œdema a second scarification is rarely requisite, especially when the progress of the affection can be watched

with the laryngoscope, so as to be combated by less serious measures; but in the œdema of chronic disease of the larynx the operation may have to be repeated frequently. In some cases prompt, efficient, and repeated scarifications are inadequate to avert a fatal termination.

If the infiltration has progressed toward solidification, scarification will be ineffective, as it is only when the effused products are fluid that they can escape through the incisions. Under these circumstances, should the condition persist, unmodified by the local results of the scarification—such as the hemorrhage attendant upon it, and the relief to the tension, etc.—the operation of tracheotomy should be performed. When the symptoms are so urgent that death appears imminent at the moment, it is proper to open the trachea without delay. This will save the patient for the time being, and often insure recovery, if there has been no fatal congestion of lungs or brain, for the operation does not always succeed in rescuing the patient. Two instructive cases of this kind, followed by fatal results, are recorded by Drs. Pitman and Page.¹ If the operation be delayed, the impeded respiration will have prevented due arterialization of the blood, and have thus induced congestion of the brain; a condition from the effects of which the patient may be unable to rally, even though he survive for a few hours or a few days with unimpeded respiration.

The trachea is to be opened in preference to the larynx, as being at a greater distance from the seat of the disease, and less liable to involvement, as well as for the reason that the disease occasioning the œdema may be extending low down in the larynx, and therefore exist at the very point usually selected for laryngotomy. Life being thus saved by tracheotomy, scarification of the œdematous structure may be pursued with more deliberation. This will be especially necessary if the tumefaction interferes with deglutition. Under circumstances of great urgency there ought to be no hesitation in opening the trachea with the pocket-knife, if no surgical instrument is at hand, and without any dissection, the delay for which may result fatally. The case is so desperate as to be rescued by desperate means only.

Prof. Stromeyer recommends bursting the bladder-like

¹ The Lancet, April 21, 1860, p. 392.

swelling by a smart stroke of the finger at the moment of examination. The epiglottis, when involved, may thus be firmly compressed against the root of the tongue, and would be very apt to suffer rupture of its attenuated mucous membrane under a vigorous stroke from the finger. When this can be done effectually, it would appear to be more desirable than scarification, at least in the first instance. A successful manœuvre of this kind has occurred under my own hand.

Where pressure or scarification fails to afford immediate relief, tracheotomy should be resorted to at once, for the affection threatens death by suffocation before any impression can be made by ordinary antiphlogistic remedies; although cases have recovered under general antiphlogistic treatment;¹ and one of these is particularly interesting from the fact that the patient died in a subsequent attack fourteen years afterward.² Indeed cases are not infrequent in which the œdema has subsided spontaneously in the course of a few hours, even in threatening cases; but it is not safe to trust to the unaided efforts of nature, which are apt to be too slow to avert suffocation. Frequent pressure of the parts with a view to absorption, recommended by Thullier in his inaugural thesis on œdematous laryngeal angina, is hardly worthy of mention as a method of treatment, and catheterism of the larynx, which has been proposed for the purpose, generally fails to afford any relief whatever. Professor Trousseau³ has recorded a severe case of œdema of the epiglottis and ary-epiglottic folds, which was promptly relieved by inhalations of tannin; and a couple of instances in which narcotic inhalations had a very happy effect have been related by myself.⁴ But treatment by inhalation must be very rarely applicable, and not at all so where the symptoms are urgent. In one of my own cases it was not employed with the hope of a favorable result, but as a means of temporary alleviation while in quest of an instrument for scarification.

In cases of moderate severity, where the progress of the morbid process can be cautiously watched by the aid of the

¹ For examples, see Wilson: *Med.-Chir. Trans.*, Vol. V., p. 156; Arnold, *Ibid.*, Vol. IX., p. 31; Anderson: *Edinb. Med. and Surg. Jour.*, Vol. X., p. 284.

² Roberts: *Med.-Chir. Trans.*, Vol. VI., p. 135.

³ *Clin. Méd.*, Paris, 1861, p. 475.

⁴ *Inhalation: Its Therapeutics and Practice.* Phila., 1867, p. 138.

laryngoscope, the application of ice and ice-bags externally, and the continuous use of ice in the mouth, will sometimes effect an absorption of the effused products, and thus avoid any necessity for the use of the knife. Similar results may follow the judicious use of astringent inhalations in spray.

Chronic Œdema of the Larynx.—The œdema which takes place during the progress of chronic laryngeal disease usually sets in gradually, rarely insidiously, and may continue for several weeks or even months without producing any suffocative paroxysms; and this even when the entrance into the larynx is very much obstructed. It seems as if the system accustomed itself to a gradual narrowing of the air-passages, on the one hand, while, on the other, the general ill health of the patient and the lack of active exercise appear to lessen the demand for a large supply of atmospheric air. Certain it is that an amount of œdema is tolerated in chronic affections of the larynx which would produce symptoms of intense dyspnœa, or at least terminate rapidly in congestion of the lungs, if it occurred suddenly in a healthy subject.

Chronic œdema is more apt to be confined to one side than acute œdema, because the laryngeal affection which produces it is so often unilateral. In some cases the condition is due to carious disease of the laryngeal cartilages. Necrosed portions of cartilage are productive of laryngeal abscesses on their way to the exterior—here the interior of the tube—and sero-purulent accumulation will take place in the adjacent submucous connective tissue. The cricoid cartilage and the arytenoids are more prone to disease than the other cartilages

Ryland mentions a case¹ which ensued subsequent to an attack of glanders, contracted nearly a year previously, and in which dissection after death showed that the inner surface of the cricoid cartilage had undergone conversion into a ring of bone, which was carious and loose.

Sometimes the detached portions of dead cartilage are expectorated in coughing, and there is rapid abatement in the severity of the dyspnœa, but without any real progress toward recovery. It is only occasionally that the sequester can be detected laryngoscopically and detached with forceps; and if

¹ Op. cit., p. 42.

there is any difficulty in its detachment, tracheotomy may be necessary for its removal.

Opening the trachea for the mere purpose of setting the larynx at rest in chronic affections is rarely justifiable; for these diseases almost inevitably terminate in death, and the respite is hardly worth its cost; besides which, the trachea is often entirely free from any other manifestation of disease than congestion, and the condition of the lungs is usually itself productive of all the phenomena of dyspnœa and cough. Under these circumstances the operation can hardly do more than actually add to the existing evils already endangering the remnant of the patient's life; though Dr. Porter¹ states that several cases have been published strongly exemplifying the value of this practice with the view of placing the larynx in that state of quiescence so necessary to the healing of a sore anywhere.

Scarification, followed by the local application of astringent solutions, including, as such, solutions of nitrate of silver, chloride of gold, chloride of zinc, sulphate of copper, and the like, with emollient and narcotic inhalations, constitutes perhaps the best treatment. Blisters and other external counter-irritants are rarely of service, and are often productive of injury.

Infra-glottic Œdema of the Larynx.—The opinion had long been held by pathologists that œdema of the larynx could not occur below the glottis, on account of the close adherence of the mucous membrane to the perichondrium of the cartilages. On the sides of the cricoid cartilage, however, a certain amount of distinct areolar tissue is sometimes sufficiently relaxed to permit accumulation of exudative products, which in this situation are oftener fibrinous than serous. The effusion is not an extension of the œdema already present above the glottis, though occasionally coexisting with it; and it usually occurs independently. In the cases seen by myself, and in many recorded by others, there was no evidence of coexistent œdema in the upper portion of the larynx. A specimen in St. George's Museum,² from a case of erysipelas extending from the head and face to the larynx, shows bilateral sub-glottic

¹ Op. cit., p. 118.

² Gibb: Op. cit., p. 218.

œdema, and œdema of the glottis, epiglottis, and neighboring parts likewise.

Sub-glottic œdema is exceedingly rare, and has been duly recognized only since the employment of the laryngoscope in medical practice; and the use of this instrument affords the only certain means of diagnosis. This form of œdema is sometimes produced by acute laryngitis and the laryngitis of erysipelas, but occurs also in the chronic laryngitis of tubercle and syphilis, and in the laryngitis of small-pox, typhus,¹ and typhoid fever; resembling in these respects the circumstances under which the supra-glottic œdema is encountered.

Dr. Gibb, who collected evidence of eighteen instances of this affection, chiefly from material at hand in London, states that "it may be taken as a rule that the swelling never extends further than the commencement of the first ring of the trachea." In some of the cases recorded by him, the contents of the œdematous tumors were essentially fibrinous, simulating new-growths.

Symptoms.—The subjective symptoms are similar to those of acute laryngitis, with the addition of those of the ordinary forms of œdema; but the breathing is more stridulous and wheezing, and has a croupy hoarseness. There is great dyspnoea, cough, and an abundant secretion of mucus, usually more copious than in supra-glottic œdema, and likewise more fibrinous, rings of fibrinous sputa being sometimes expectorated. Dysphagia is not present unless supra-glottic œdema coexists; and the stridor is not greater in inspiration than in expiration.

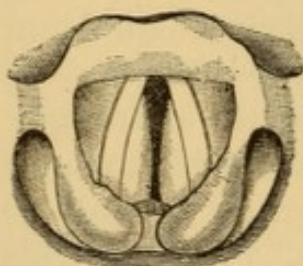


FIG. 103.—Sub-glottic œdema of the larynx.

Diagnosis.—Laryngoscopic inspection reveals projecting pads of turgid mucous membrane bulging forward from the right and left, below the vocal cords, and encroaching upon the transverse calibre of the larynx (Fig. 103).

Treatment.—Sub-glottic œdema is much more menacing to life than supra-glottic œdema, and is not as amenable to scarification and other topical measures, not only because the position of the effusion is much more difficult to reach with instru-

¹ Russel: Sub-glottic Œdema and Permanent Stricture of the Larynx, following Typhus. Glasgow Med. Jour., Feb., 1871, p. 209.

ments, but also because the effusion is apt to be more fibrinous than serous, and less likely to be discharged through incisions. The discharge of a serous effusion in the upper portion of the larynx, moreover, is assisted by the pressure exercised in the spasmodic contraction of the muscles which follows the operation, while effusion below the glottis is out of the range of muscular compression. Tracheotomy, therefore, is the only resource in serious cases. In cases of moderate extent and severity, the same remedial agents may be employed as in supra-glottic œdema; and, from the fibrinous nature of the effusion, a more salutary influence can reasonably be expected from mercurial remedies. Sub-glottic œdema demands the performance of tracheotomy, if the effusion cannot be promptly subdued by constitutional measures, and the inhalation of steam and of astringent and absorbent sprays; scarification being almost always impracticable, on account of the situation of the infiltration. If delayed too long, even tracheotomy may be impotent to save the patient, as in an unfortunate case which occurred in the earlier years of my own practice.

The deposit of sub-glottic œdema is not always absorbed, even if the patient should be saved by a timely tracheotomy; and hence it has been necessary in some instances to maintain the opening patulous, with the constant presence of the tracheotomy-tube.

Hemorrhagic Œdema of the Larynx.—Hemorrhagic infiltration of the submucous tissues of the larynx, frequently termed hemorrhagic œdema, is generally the result of traumatic injury to the parts. The effusion is usually sudden, and the resulting stenosis often fatal.

Sestier¹ relates a case in which hemorrhagic effusion into the right ary-epiglottic fold ensued upon a suicidal cut into the thyro-hyoid membrane, terminating fatally, by suffocation, upon the fifth day after the injury.

In my own hands, an aryteno-epiglottic fold was caught in a spasm produced by an awkward attempt to seize a supra-glottic neoplasm with antero-posterior forceps. Within a minute the effusion on both sides the fold was as large as a hazel-nut, and seriously impaired the breathing for several hours. Under the continuous local influence of ice in the mouth, the tumefaction subsided, and the effused blood underwent absorption in the course of a few days.

¹ *Traité de l'angine laryngée œdémateuse*, Paris, 1865, p. 137.

Hemorrhagic œdema is not always a result of traumatic injury. Sestier¹ mentions a fatal case of hemorrhagic œdema of the aryteno-epiglottic folds occurring in the course of hemorrhagic small-pox; and Ruehle,² a case of Pfeuffer's in which the hemorrhagic infiltration below the right ventricle, and causing death within four hours of the commencement of the stridulous symptoms, ensued upon salivation from inunction with mercurial ointment.

Symptoms.—These are dysphonia, dyspnœa, and dysphagia, as in similar manifestations of ordinary intra-laryngeal œdema; and their severity is dependent in great part on the locality of the lesion and the amount of blood effused.

Diagnosis.—Laryngoscopic inspection reveals the nature of the infiltration, in a more or less circumscribed swelling, reddish blue or livid in color.

Treatment.—Puncture or incision into the overlying mucous membrane, to give vent to the effused blood, is required if the case is at all threatening—if, indeed, prudential reasons would not render it desirable in any instance. The local use of pellets of ice, and the internal administration of turpentine or ergot, or the hypodermic use of the fluid extract of ergot, or of a solution of ergotine, are likewise indicated. If these measures fail, tracheotomy is the only resource in case of impending asphyxia.

CROUP.

(Exudative Laryngo-tracheitis, Pseudo-membranous Laryngitis, Hives; Angina Trachealis, Cynanche Trachealis, Cynanche Trachealis Humida, Laryngo-trachealis Membranacea Idiopathica.)

Croup consists in a peculiar idiopathic exudative inflammation of the mucous membrane of the upper air-passages or of its muciparous glands, attended in some instances by paroxysmal spasm of the constricting muscles of the glottis, and, perhaps, also of paralysis of the dilating muscles of the glottis, and of the nervous fibrillæ distributed to the minuter bronchi; these nervous phenomena being usually reflex, and sometimes direct. Though occasionally limited to the larynx, the inflam-

¹ Op. cit., pp. 63, 114.

² Kehlkopfkrankheiten, 1861, p. 177.

matory process is more frequently continuous along the trachea for half of its extent or more, sometimes as far as the bifurcation, and exceptionally more or less deeply into the bronchi, in rare instances even to their minuter ramifications. Severe cases are always attended with bronchitis, and sometimes with pneumonitis also. In some instances the inflammatory process involves the pharynx, tonsils, or palate likewise. Adults are attacked occasionally only, the greatest predisposition being comprised in the period extending from the first or second to the tenth or twelfth year of life; although it sometimes affects even the unweaned child. Inasmuch as the predisposition to croup is most marked during the period of the first dentition, it is inferred that the indiscreet use of food unsuited to the masticatory and digestive capacities of children has more or less influence in its development. From an undetermined cause, male children are attacked more frequently than females. My personal experience, however, has happened to have shown the excess in females. Many families escape altogether; others are especially liable to the malady.

Croup occasionally attacks the same individual more than once, sometimes at intervals of several years; but this is not frequent.¹

The exciting cause of croup is not always well determined. In the majority of instances it follows more or less exposure to cold; sometimes very little exposure indeed. The vicious method of dressing—or rather half undressing—children, so much in vogue by vain and silly parents, which leaves neck and shoulders, legs and knees exposed, rather invites attacks of croup, by keeping up unequal temperature of the surface.

Croup is usually dependent upon causes of incidental origin, but there appears some reason to believe that occasionally the causes are epidemic or widespread. Certain diseases implicating the mucous membranes, secondarily or primarily, such as influenza and measles, and, to a certain extent, scarlatina, seem to favor the prevalence of croup.

Croup, in its fully developed form, is notoriously fatal, and is always serious—not from the amount of inflammatory action alone, for that is comparatively insignificant as an element of

¹ Guersant relates a case in which he performed tracheotomy for croup twice in the same child.

danger, but from the location of the exudative products, and, in a less degree, from the tendency to spasm of the glottis, or paralysis of its dilator muscles, either of which may threaten suffocation.

There seem to be three distinct manifestations of croup. One is catarrhal, with an exudation of excess of mucus merely; another, croup proper, is fibrinous, in the fully developed form of which pseudo-membrane becomes deposited upon the mucous membrane, either from coagulation of the exuded products, or from evaporation of their aqueous constituents; and the third, and less frequent variety, is suppurative, an actual production of pus taking place from inflammatory action, beneath the exudation.

There is more or less spasm of the glottis in many instances, though varying greatly in frequency and in violence. Many cases are wholly without spasm. There is great difference, too, in the amount of dyspnoea, which usually presents temporary paroxysms of increase. The amount of exudation is sometimes wholly inadequate for satisfactory explanation of this dyspnoea. Sometimes, indeed, even in cases in which tracheotomy had been performed unavailingly, no mechanical cause for dyspnoea has been evident *post-mortem*; and this seems to indicate the presence of an element of paralysis affecting the nervous distribution at the ultimate bronchi, as well as that controlling the dilatation of the glottis.

In addition to the immediate local effects of croup, others become superadded as results of the dyspnoea, and lack of due interchange of carbonic acid and oxygen. These are venous congestion of the cerebral, thoracic, and abdominal viscera; and likewise vesicular or interlobular emphysema, or even rupture of air-vesicles and collapse in consequence of the unwonted muscular efforts at respiration. In some instances pneumonia is excited.

Catarrhal croup is by far most frequent; and both the membranous and suppurative varieties usually begin in the catarrhal form.

Symptoms.—A little febrile movement occurs at the commencement of an attack of croup, without being necessarily preceded by great chilliness, though it is often difficult to obtain precise information in this respect. In children the indisposition generally attracts attention for the first time

toward evening, the voice being slightly hoarse, as from a common cold. There is a little cough, but as yet without the peculiarity usually described as characteristic. Some observers assert their ability to detect the peculiar muffled resonance of the cough from its very commencement. Sometimes, for two or three days, the symptoms are merely those of moderate catarrh. After a day or two—it may be four or five days—toward night, a slight flush gradually spreads over the countenance; the eye acquires an abnormal brilliancy; the heat of skin is increased; and the pulse, which is often strong and hard, gains in quickness and fulness. At a period varying within an hour or two before midnight, or thereabouts, the child is likely to be awakened by an attack of dyspnœa, which is often the first symptom to excite alarm; but sometimes this dyspnœa does not occur until early in the morning; and it is at the same period usually that the peculiar character of the cough is detected, the sound of which is so characteristic that it is recognized as peculiar, though a verbal description conveys no adequate idea of its peculiarity. It has a specific ring or metallic resonance, which has been compared to various harsh and shrill sounds, as a cock's crow and the resonance of a brass tube. It is supposed to be due to tonic stiffening or tension of the air-tube.

The cough, at first sonorous, gradually merges into huskiness, and in some instances finally becomes muffled or almost toneless, the child being seen to cough, without making noise enough to attract attention. The voice, nearly natural at first, becomes hoarse and dissonant, acquiring a peculiar quality suggestive of the characteristics of the cough-sound; and, as the disease progresses, it declines into a dull, husky, laryngeal whisper, which often gradually becomes extinct. The dyspnœa increases during the same time, respiration being impeded in both phases, until finally all the phenomena of struggling for breath are presented—supra- and sub-sternal recession of the soft tissues, distention of the nostrils, protrusion of the eyeballs, clutching at the throat, and grasping at the arms of the attendants, as though to find a fulcrum to aid the action of the auxiliary muscles of respiration. Finally, the flush fades from the face, the cheeks become pale, and then more or less purplish, and covered with perspiration; while, at the same time, lividity of the lips comes on, and an anxious expression

of countenance, indicative of extreme distress. If not relieved, asphyxia ends the scene.

The dyspnœa is usually attributed to the presence of membrane upon the vocal cords, encroaching upon the chink of the glottis, or occluding it. There is reason, however, for believing that it is often due to paresis of the dilating muscles of the glottis, so that the chink remains partially closed. Niemeyer has actually observed the contracted glottis immobile in the child, as revealed in the laryngoscopic image. It has likewise been observed in the adult.

Severe symptoms are not always manifested on the first day, but are developed gradually in the course of two or three days, and with increasing significance.

Diagnosis.—In the absence of direct or laryngoscopic evidence of deposit, the only positive diagnostic sign is afforded by expulsion of some of the products of exudation. These may appear in the form of irregular flakes, or in that of thickened mucus. In some instances large flakes are coughed out, which bear the impress of portions of the interior of the larynx, or of the cartilages and interspaces of the trachea, the fragments presenting sometimes in shreds, sometimes in rings, sometimes in tubes, sometimes in balls. In some cases complete casts of the trachea and of portions of the bronchi are expectorated; and similar casts of still greater extent are sometimes removed from the air-passages on post-mortem examination.¹ The appearance of fibrinous deposits upon the tonsils, palate, palatine folds, or pharynx, is also indicative of the nature of the laryngeal disease, but is by no means to be relied on as a diagnostic feature; it is more apt to be indicative of the croup of diphtheria. Laryngoscopic inspection has revealed the presence of the membrane even in very young children; and this examination offers no great difficulty in subjects of four or five years of age and upward. When there are no positive evidences of membrane or exudation, the case is inferred to be croup from the general symptoms, coupled with the history of the attack.

Croup in the adult is liable to be mistaken for acute laryngitis, catarrhal or phlegmonous, according to the manifestations. The expectoration of membrane, and laryngoscopic

¹ For examples, see J. F. Meigs: Cases of Pseudo-membranous Laryngitis, Am. Jour. Med. Sci., Apl., 1849, p. 307, Cases II., III.

evidence of its presence, are the principal means of differential diagnosis. When paroxysmal spasm occurs in these cases, the impediment to respiration is less during the intervals than in phlegmonous laryngitis.

The points of differential diagnosis from diphtheria¹ are discussed in a former part of the volume (pp. 145-150).

Prognosis.—Catarrhal croup offers a tolerably favorable prognosis. Suppurative croup, too, is likely to terminate favorably. In membranous croup the prognosis is doubtful, and very grave in pronounced instances, although cases of the severest character sometimes terminate in recovery. Mild cases sometimes become worse suddenly, and terminate fatally. Croup seldom terminates favorably without treatment. The older a child, the better the prognosis, concomitant circumstances being equal. The immediate vigor of the patient is not as valuable an indication as in many other diseases, for delicate children often survive attacks apparently more severe than those to which stronger individuals succumb.

In the early stage of the disease the only immediate menace to life exists in the paroxysmal spasm of the glottis; but at a later date, when the exudative process has become fully developed, danger of suffocation from obstruction in the air-tube becomes superadded. At a later date, if the patient survives, suppuration takes place beneath the pseudo-membrane, detaching it from the mucous surface, and rendering it susceptible of being expectorated, so that the danger of suffocation is diminished.

Croup may run its course to a fatal termination in forty-eight or even twenty-four hours; but this is unusual. Its general duration is from five to eight days, though in occasional cases the attack continues for two or three weeks, or even longer, according to some observers; while in some instances a continuous liability to recurrence seems to be kept up for several months.

In the adult the prognosis is usually favorable.

Other circumstances being equal, the prognosis is good after tracheotomy, in proportion to the manifestation of appetite and the disposition to cough and expel the accumulating prod-

¹ The subject of diphtheria (croup inclusive) is extensively presented in all its phases in a large monograph by Dr. A. Sanné, entitled *Traité de la diphthérie*, Paris, 1877, pp. 654.

ucts of secretion through the artificial opening or the mouth, as may be. The capabilities of the immediate attendant in nursing charge, and the accessibility of competent professional aid in case of untoward manifestations attributable to the artificial opening or to the tube, have much to do with the prognosis after tracheotomy.

Treatment.—The treatment of croup is not a matter of uniformity in medical practice. Many pages would be required merely to designate the various methods recommended. All that will be attempted here is to describe the plan which seems to me most rational, and which, with such modifications as each individual case has required, has served me best in the actual test of practice.

The main principle held in view is to sustain strength while assisting the patient through the normal or abnormal phases of the disease. The treatment of the catarrhal form differs little from that for ordinary catarrh, save that the patient is confined to bed, in a well-ventilated room, warmed to a temperature approaching 80° F., and the air of the apartment is kept very moist by continuous evolution of steam. If the child is too young to make voluntary efforts at expectoration, an emetic of alum, as employed by the late Professor Meigs, of Philadelphia, is given twice, or oftener, in the twenty-four hours, to provoke expectoration during the act of vomiting; and this only for the reason that the air-passages of children are too tolerant of mucous accumulations to risk such increase as to offer an untoward mechanical complication during the management of the case. The use of the yellow sulphate of mercury for the same purpose, suggested by Dr. Ware, of Boston,¹ has recently re-acquired great reputation in New York² and elsewhere. The bowels are to be kept relaxed, if need be, by some gentle alkaline laxative. The diet consists of milk if the child be quite young, or of eggs, beef-tea, and other animal broths or soups, with a moderate allowance of farinaceous food, if the child be older. If there is general debility, quinia and iron, both preferably in the form of hydrochlorate, are administered. Finally, if there is much local inflammatory action, the neck is enveloped externally in a wet cotton or spongio-piline poultice,

¹ Boston Med. and Surg. Jour., April, 1830.

² Fordyce Barker, Am. Jour. Obstet.

covered lightly with oiled silk, oiled paper, or thin rubber sheeting to promote moisture.

In cases where there is reason to believe that the exudation is undergoing transformation into pseudo-membrane, the treatment is more active. The temperature of the apartment is maintained at from 85° to 90° F., and the atmosphere is more copiously loaded with steam, as in the croup of diphtheria (see pp. 173, 174), in hope of supplying, to the exudation, water to replace that lost by evaporation or coagulation in its transformation into membrane.

To favor the early destruction of the membranes, and to afford inlets through them for the watery vapor to get beneath them so as to facilitate their removal without waiting for the period of suppuration, resort is made every two hours, hour, or half-hour, as the case may seem to require, to the inhalation of the vapor from slackening lime, as recommended by Dr. Geiger (see pp. 174-5)—a method more reliable than inhalation of lime-water nebulized into spray.

This method is founded upon the power of lime-water to dissolve the membranous exudation out of the body. It does not act with anything like equal power on the membrane in the body, probably in some measure on account of its conversion by carbonic acid in the air-passages into the inert carbonate, but possibly for want of prolonged contact with the exudation.

Where vapor charged with lime does not do efficient service, good results are often obtained from the use of bromine inhalations as recommended by Ozanam, a useful formula being one grain of bromine, five grains to one drachm of bromide of potassium, and an ounce of water, which quantity is nebulized into spray by the steam apparatus, and diluted only so far as the case may seem to require. Alternation back to the lime after the use of the bromine, seems sometimes to be indicated and to be of real service. These inhalations are continued from ten to twenty minutes at a time at suitable intervals night and day, irrespective of sleep, and very often succeed in forcing the detachment and expulsion of shreds of membrane, sometimes in copious masses. They are intermitted from time to time, if the respiration has remained much improved for a number of hours continuously, and are resorted to again upon the least indication of fresh embarrassment in breathing. Care must be taken in some instances to remove the secretions from the

mouth mechanically, as they sometimes accumulate there in dangerous quantity.

Inhalations of lactic acid, sulphurous acid, sulphuret of mercury, and other agents said to be able to disintegrate the membrane, have not, in my own hands, produced results at all comparable to those from lime and bromine; and though resorted to occasionally, I have always felt disposed to place much greater dependence upon the lime and the bromine.

There is great risk, in this treatment, of exciting catarrhal bronchitis or pneumonia, sequelæ which often occur without it, but the risk of such a result is hardly greater than the risk of death under inefficient management; besides which, if the child is saved from death by the croup, a fair opportunity is presented to carry him through his pneumonia by being on the alert to repel its earliest manifestations. I have never seen death from this cause after a successful management of croup by the method narrated, although sometimes apparently inevitable. In this form of the disease, in young infants, the emetic is usually administered at intervals of not longer than six hours, as long as any evidences remain of continued formation of membrane, unless, indeed, as sometimes happens, vomiting takes place spontaneously; and if alum prove insufficient, as it sometimes will, my own practice is to resort to a strong decoction of senega, or to ipecacuanha, never to tartar-emetic, and rarely to sulphate of copper or the turpeth mineral. Prof. Niemeyer's description of an infant bathed in the bluish excretions from its rectum, when the emetic has ceased to operate upon the stomach, is too horrible to justify persistence in the use of sulphate of copper once it has proved inactive.

The same indication exists as in catarrhal croup to keep the contents of the bowels soluble; and calomel forms a most judicious ingredient in the laxative, for if it ptyalize the child, suspension of the exudative process is apt to follow.

Compound spirit of ether, camphorated tincture, or some other preparation of opium, extract of belladonna, gelseminum, or some similar drug, is sometimes required to repress the tendency to spasm. The warm-water dressing is kept applied to the exterior of the neck, and sometimes replaced by a flaxseed poultice.

In addition to nourishing diet and tonic medicines, systematic stimulation with alcohol and with carbonate of ammo-

nium is employed at frequent intervals (two or three hours). Time and again I have seen a full dose of carbonate of ammonium (two and a half to five grains) rouse a child from excessive exhaustion, and tide its fleeting life over the ten or fifteen minutes necessary to administer the inhalation of the vapor of lime, or the spray of bromine, to afford another chance for the detachment of recently-formed membrane. When cerebral symptoms supervene, calomel in small and frequent doses ($\frac{1}{12}$ – $\frac{1}{3}$ gr.) is often adequate to their control. In my own practice there has never been occasion to resort to tracheotomy to save the life of a child with inflammatory croup, though I have seen it performed, and that successfully, in the practice of others.

Should, however, the method of treatment narrated fail to afford relief, and there be no positive evidence that the exudation occupied the bronchial tubes, I would counsel tracheotomy, or resort to it myself as soon as continued and augmenting dyspnoea threatened suffocation; and without waiting for actual manifestations of asphyxia, in the conviction that an early performance of the operation offers its best chance to save life. It is due, however, to the treatment above narrated to say that I have seen the life of several patients preserved through it, if not by means of it, for whom the performance of tracheotomy had been previously declined by more than one surgeon as offering no hope of a successful result.

The local application of solutions of nitrate of silver (one drachm and more to the ounce) highly extolled by Prof. Horace Green,¹ Dr. Gibb, and others, has been very beneficial in many instances; in some of them, doubtless, by the mere mechanical detachment of the membrane removed or merely loosened by the contact of the sponge in the performance of the operation, and thus, perhaps, exciting the muciparous glands to hypersecretion with the effect of further detachment. It is only upon this view that we can explain like benefit attributed to very indifferent substances employed in the same manner; although Dr. Green's belief was that the nitrate of silver arrested or changed the character of the secretion from the muciparous glands, to which he attributed the exudation of the membrane. The salts of iron are sometimes employed in the same manner as the nitrate of silver. I have never felt any

¹ Observations on the Pathology of Croup, N. Y., 1849.

inclination to employ local remedies in this way, though as bold as most practitioners with regard to manipulation within the larynx.

Inhalations of oxygen, as a means of counteracting the baneful effects of the carbonic acid producing the asphyxia, has proved occasionally successful in the hands of Beigel, Michel, and others. It has even been proposed as a substitute for tracheotomy, but it cannot replace the operation as long as the orifice of the glottis is diminished by swelling or false membrane. Atmospheric air is wanted rather than oxygen, and if the natural passage is too occluded to admit a proper supply, a larger aperture should be made artificially. If the operation is not indicated, it is more rational to employ an agent capable, under favorable conditions, of disintegrating the membrane or detaching it. Still, it must not be ignored that some experiments instituted by Dr. B. W. Richardson¹ led him to the belief that the retention of carbonic acid favors the fibrination of the exudation, so that oxygen may possibly counteract this effect of the carbonic acid, and keep the exudation diffuent.

Ice applied externally has long been employed with great success by Dr. Hiram Corson, of Norristown, Pa., who is a strong advocate for its use in all inflammatory affections of the throat. Dr. F. Betz² has recently recommended the early, continuous, and energetic application to the front of the neck of a bottle or bladder filled with finely powdered ice, retained by a light bandage. The vessel is renewed before the ice is completely melted. Salt is added when the temperature is high. This treatment, it is claimed, lowers the temperature of the anterior part of the larynx and trachea, so that the process of exudation is arrested; and if too late to subdue the formation of false membrane, the ice is of value during the operation of tracheotomy and in the after-treatment.

Tubage of the larynx has been recommended to insure the access of air to the lower air-passage and supersede tracheotomy;³ but its results have not been promising, tracheotomy having become absolutely necessary in a number of cases thus

¹ The Lancet, Sept. 24, 1870, p. 438.

² Memorabilien, Sept. 10, 1876; London Med. Record, Feb. 15, 1877, p. 71.

³ Du traitement du croup par le tubage du larynx. E. Bouchut: Comptes rendus de l'Académie des Sciences, 1858; Gaz. des Hôp., 1858.

treated. The theoretical indication is not verified in practice.

The indications for tracheotomy are similar to those discussed in connection with the croup of diphtheria (p. 170). If the dyspnœa indicating the operation be due to paresis of the dilator muscles (posterior crico-arytenoids) of the glottis, the value of tracheotomy will be incontestable and its prospective success almost assured.

Tracheotomy accomplishes a single object only, though an all-important one—it permits a greater access of atmospheric air. The medical treatment is by no means to be interrupted. Tonics and stimulants are sometimes more strongly indicated from the fact that the child often experiences such difficulty in swallowing that adequate nourishment cannot be introduced by the mouth; and, in addition, he has to overcome the nervous shock incident to the operation, especially if performed without anæsthesia. Great care is required in maintaining cleanliness of the inner tube, for a double tube should always be employed if accessible. In its absence a section of rubber tubing, carefully secured, may be substituted temporarily. In some instances irritation from the tube is so great as to necessitate its withdrawal, and the excision of portions of the edges of the tracheal wound, so as to secure an oval opening, at least the size of the normal glottis, for the access of air. The opening in the trachea affords an avenue for the direct introduction of local remedies, and this use of it is sometimes utilized. Lime-water, solutions of chlorate of potassium, chlorate of sodium, and other remedies are reported to have been injected in this way with success. These substances, too, have been injected directly into the undivided larynx and trachea¹ by means of a curved, sharp-pointed syringe, rather larger than the hypodermic syringe, plunged from the outside through the crico-thyroid ligament, or between the cartilaginous rings of the trachea. The plan does not appear to possess any advantage over inhalation, while it might possibly prove directly injurious by unexpectedly wounding an artery of anomalous distribution.

As has been intimated, much of the success after tracheotomy in croup depends upon the assiduity and judiciousness of the after-treatment; and the

¹ Albu : Deutsche Klinik, 1869, No. 39, p. 290.

observations following apply to diphtheria as well. The patient should be kept in bed well covered up, the temperature of the apartment being maintained at from 70° to 72° or thereabout, and a moderate evolution of steam be kept up, with facilities at hand for promptly increasing it, if demanded. The external opening should be covered by a bit of woollen gauze to keep the inspired air warm and moist, so as to lessen any tendency to desiccation of the secretions into coriaceous crusts and plugs which occlude the tube, excite paroxysms of cough, and sometimes suffocate the patient. In exceptional instances this tendency does not exist. If reaction is not prompt, warm aromatic drinks are indicated, with flying sinapisms to the surface. Hemorrhage is restrained by compresses applied around the tube, which should not be removed unnecessarily, as it is the only support for compression. Traumatic fever should be kept within due bounds. Nutrition is important. Every possible effort should be made to coax or induce the patient to take a proper amount of nourishment; and great laxity with regard to its character is permissible, if the temptation to eat succeeds. The inner canula should be carefully removed every two or three hours, cleansed, dipped in warm water, and replaced, so as to be kept patulous. Should it become occluded by secretions in the interval, they should be gently removed by curved forceps, sponge, mop, or feather, as may be. When the inner tube is occluded and fastened by magma to the outer one, the whole appliance should be removed. The life of the patient may depend on the presence of a person competent to perform this service and replace the tubes when cleansed, or keep the wound open by some other means if reintroduction is impracticable. Should there be no voluntary disposition to cough out the products of secretion, the disposition should be excited by dropping a little warm water into the trachea, or by titillating it with a feather. Cough and appetite are the two main favorable indications. Granulations presenting at the external wound require local applications of iodoform, sulphate of copper, or nitrate of silver. The canula should be removed as soon as it is evident that respiration through the natural passage can be relied upon; the period varying from four to nine days on the average, being sometimes as early as the first day, and at others not until several weeks or even months. The artificial opening should be allowed to contract naturally without interference. These and other important collateral points have been discussed in detail in a special essay.¹

A child who has passed through an attack of membranous croup, especially if it has been actively treated by steaming and inhalation, should be confined to the house for a number of weeks; and the greatest circumspection should be exercised with regard to its diet and clothing. The reduction of the temperature of the bed-room to that of adjoining apartments should be accomplished gradually, and not occupy less than forty-eight hours. The voice does not always return promptly;

¹ Croup in its Relations to Tracheotomy, Phila., 1874. See also Sanné, *op. cit.*; and *Étude sur le croup après la trachéotomie*, Paris, 1869.

sometimes weeks or months elapse before it has become natural. This is sometimes due to infiltration or thickening of the vocal cords, occasionally to paralysis, and sometimes to the development of little papillomas, results of the catarrhal inflammation that has existed. These conditions usually subside gradually without special treatment. Iodide of potassium or chloride of ammonium are perhaps the most suitable internal remedies; and their effects would be accelerated by the daily inhalation of sprays of weak solutions of tannin or some other astringent.

TRACHEITIS.

Inflammation of the trachea is frequently associated with laryngitis. Occasionally, however, inflammation is confined to the windpipe.

Acute tracheitis occurs sometimes as an idiopathic affection, sometimes as a deuteropathic result of small-pox, measles, typhoid fever, syphilis, carcinoma, pulmonary tuberculosis, diphtheria, and croup, and occasionally from traumatic causes.

I have seen a case of traumatic ulceration of the posterior wall of the trachea in the body of a young man who died suddenly, suffocated by an accumulation of blood in the trachea, and the post-mortem examination of whose body I was invited to perform by Dr. Shapleigh. There was no evidence of phthisis; and the larynx was normal. There had been hoarseness during life, and occasional hemorrhage, the earliest indications having commenced three years before death, and subsequent to a garotting by highwaymen. The ulceration was apparently the result of simple inflammation, non-specific and non-tuberculous.

Symptoms and Diagnosis.—Pain referred to the windpipe and to the top of the sternum, expectoration of mucus, sometimes in rings, and the accompaniment of a peculiar, brazen-like cough, are the main features of differential diagnosis from laryngitis, bronchitis, or general catarrhal inflammation of the air-passages. If the disease is confined to the trachea, there will be no hoarseness. In favorable cases, laryngoscopy reveals the inflamed condition. The mucous membrane covering the rings and inter-cartilaginous spaces is more or less red or dark-red in color; but this appearance is not to be depended on as a certainty in diagnosis. There is sometimes considerable swelling, but not sufficient to embarrass respiration.

Chronic tracheitis occurs in cases of folliculous pharyngolaryngitis, pulmonary tuberculosis, and syphilis. Laryngoscopy reveals a dark-red aspect of the mucous membrane, and clumps of mucus are usually seen adherent, here and there, to the cartilages or to the interspaces. Though usually associated with chronic laryngitis, chronic tracheitis is sometimes a local affection. The chronic tracheitis of tuberculosis and syphilis is apt to become extended into the submucous tissues, in some instances to invade the cartilaginous structures, producing extensive and irremediable destruction of tissue, of which, as a rule, no adequate conception can be obtained, despite laryngoscopic inspection, until an examination of the parts after death. Papillomas and fungous vegetations, similar to those developed in the analogous ulcerations of the larynx, are occasionally met with.

The cicatrization of syphilitic ulcerations, and sometimes of tuberculous ones, is apt to produce great contraction, sometimes amounting to stenosis or stricture, a condition usually irremediable if below the point at which a judicious tracheotomy can be performed. A constriction sometimes results from submucous infiltration of the lining membrane of the trachea, a very remarkable case of which has been recorded by Dr. Gibb.¹

Treatment.—The treatment of acute tracheitis is, in the main, similar to that for acute laryngitis, only much less active. This includes rest, warm water poultices externally; inhalation of steam, impregnated, if desired, with balsamic or anodyne ingredients, and a mild relaxant or antiphlogistic course (sulphate of magnesia, with tartar emetic) internally. An acute attack might, in its earliest state, be aborted by means of a large dose of opium, or the local application of a strong solution of nitrate of silver.

Chronic tracheitis requires treatment similar to chronic laryngitis. The local applications may be made with the sponge probang or with the douche. The latter instrument can always be used to propel solutions down the trachea; the passage of the sponge requires special skill in manipulation. Rigid forceps cannot be used, except for the upper part of the trachea. Sulphate of zinc or nitrate of silver are most univer-

¹ Op. cit., p. 397.

sally considered applicable for the local treatment of chronic tracheitis. I have derived great benefit from both of them. The treatment for the chronic tracheitis of tuberculosis and syphilis is that for the chronic laryngitis of these diatheses.

The following somewhat remarkable case is worthy of record in this connection:

Chronic Inflammation of the Trachea, of Forty Years' Standing, cured by Nitrate of Silver.—Hannah L——, æt. 45, called upon me (April 1, 1867), at the recommendation of Dr. Atkinson, with a chronic sore throat, which had existed as long as she could remember, a period estimated at forty years. There was evidence of congestion, on laryngoscopic inspection, clear down the trachea.

A sponge saturated in a solution of nitrate of silver, sixty grains to the ounce, was passed down the entire length of the trachea, thoroughly swabbing the parts, every other day. Within a week the relief to all the tracheal symptoms was marked. The frequency of the application was diminished, and in little more than two months she was discharged from treatment, the cure apparently complete. Several years afterward I learned from Dr. Atkinson that the relief had been permanent.

CHRONIC LARYNGITIS.

Chronic laryngitis occurs idiopathically, deuteropathically, and traumatically. The inflammatory process may be limited to the mucous membrane, or to the mucous membrane and its glandular structure, or it may extend into the submucous connective tissue and into the muscular tissue, or still more deeply into the perichondrium and the very substance of the cartilages.

Chronic laryngitis is most apt to occur as one of the constituent associates of chronic pneumonic phthisis. It occurs likewise as one of the constitutional manifestations of syphilis; as an accompaniment of carcinoma and of lupus; as a complication in the latter stages of typhoid fever; as the result of long-continued irritation from minute particles of extraneous matter inhaled by habit, accident, or in the course of special avocations; as an extension of bronchitis and tracheitis; as the result of frequent attacks of ordinary catarrhal laryngitis; as a result of glandular inflammation of the pharynx, tonsils, palate, and parts adjacent, whether acute or chronic; as a consequence of protracted or frequent use or abuse of the voice in singing, declaiming, or shouting. It likewise attends certain local affections to which the larynx is occasionally subject,

such as distention of the veins (phlebectasia), which some authors attribute to the catarrhal inflammation.

Adults are affected more frequently than children; men more than women; and individuals predisposed to phthisis, or tainted with syphilis, more than the subjects of any other diathesis.

Catarrhal Chronic Laryngitis.—Chronic inflammation of the mucous membrane of the larynx is sometimes a sequel of acute laryngitis. More frequently it occurs without having been preceded by the acute disease in any of its forms, or being referable to any special cause of initial disturbance. The story will run, if the patient was, or remains, otherwise in comparative good health, that, without exposure to cold, or any other assignable cause, there gradually arose a sense of something wrong in the throat—say, an occasional and often momentary huskiness of voice in speaking, an occasional expectoration of a little pellet of glairy or viscid mucus, with local dryness, leading to frequent insalivation, and now and then a slight, or more or less distressing, sense of impediment to respiration at night, the patient being awakened by a suffocative sensation, as if the epiglottis had become wedged across the pharynx, readily relieved by swallowing saliva or water. These inconveniences might occur so seldom that they would hardly attract consideration when not actually present. Then, after a while, soreness supervenes, or occasional pains with increased expectoration, perhaps with entire subsidence of the strangulating spasm, and partial subsidence of the state of dryness, or, in some cases, increased dryness.

In this state the patient may remain for years, his general health apparently unimpaired, and suffering but little locally, except when the manifestations of the disease are exasperated by over-exposure, over-work, or over-indulgence.

It is not improbable, in these protracted cases, that calcification of the cartilages of the larynx and upper portion of the trachea has ensued as a result of prolonged chronic inflammation and interference with nutrition of the cartilages, together with general hypertrophy or increase of the connective tissue, so that their complete return to the normal condition is not to be expected.

A somewhat special form of chronic laryngitis, most frequent in young adults between twenty and thirty years of age,

although attributed to a severe cold, or sore throat, as the initial disturbance, seems rather to be due in great part to over-feeding, accompanied usually with the abuse of condiments, a habit by which it appears to be kept up at any rate. The free use of alcohol is not an essential factor in exciting the complaint, for it is encountered in a marked degree in individuals altogether unaccustomed to the habitual use of stimulants. I have noticed it more frequently in individuals with dusky skin, and perhaps troubled with enlarged sebaceous follicles or acne of the forehead and face. The general health is good, except a tendency to costiveness, occasioning resort, now and then, to laxatives. The skin is moist and the extremities warm. The pulse is usually full and slow. The tongue is red, or reddish brown, thick, puffy, with prominent papillæ, and is covered at its base with a creamy fur, projecting more or less irregularly in streaks toward the tip. In some cases mere casual inspection discloses a clean tongue, but careful examination reveals the coating at its base. The mucous membrane of the pharynx, palate, and palatine folds is relaxed, and pastily puffy, the tonsils often a little enlarged, usually unequally, and the uvula is generally slightly relaxed. The follicles of the throat are not prominent, but the mucous membrane looks as if underlaid by a layer of effused lymph bulging it forward. The posterior portion of the uvula and palate, and the upper portion of the pharynx, as well as the naso-pharyngeal surfaces generally, will be found in a similar puffy condition. Usually these parts are more deeply colored than normal, but very often the color is unchanged. The entire larynx, however, is always congested, and the vocal cords are pink or red instead of being white or whitish. This redness of the cords is greatest at their arytenoidal insertions, converting the maculæ flavæ into maculæ rubræ. The mucous membrane covering the supra-arytenoid cartilages is quite red and puffy, and a similar condition extends more or less along the whole ary-epiglottic fold. The epiglottis is often flaccid, so much so at times that its edges are rolled together laterally during movements of retching and the like. A streak or pellet of mucus often occupies the interarytenoidal commissure, and mucus is often also adherent along the lateral walls of the larynx, representing accumulations coughed up from time to time, but not yet coughed out. This coughing keeps up the congestion of the larynx. The

trachea often participates in the hyperæmia. The mucus in the trachea is very adherent, and seems to require a good deal of effort to dislodge it. I have watched its progress up the trachea, from ring to ring almost, gaining a little at each cough, until finally it reaches the larynx. The hoarseness is marked and constant; less evident in singing than in ordinary conversation; greatest early in the morning, and after meals. There is a sense of fulness in the throat, a consciousness of the presence of a layer of phlegm to be hawked up or coughed out. There is no pain, but constant and annoying local discomfort. Sleep is usually good, and the matters are expectorated freely in the morning, after which the expectoration is light, and sometimes almost unnoticed for the rest of the day. It usually comes up in little yellowish clumps which have become formed by the accumulations coughed from time to time into the larynx. Sometimes the morning clumps are brownish, and occasionally they are almost black from admixture of the constituents of the blood.

In other cases the expectoration is more profuse, so as to interfere with sound sleep; and there may be dyspepsia, vertigo, headache, and more or less manifestation of general nervous disturbance.

Fetid Chronic Laryngitis.—In some cases of chronic laryngitis, happily rare, the secretions, or excretions as they might be termed, are exceedingly fetid, viscid, and adhesive, clinging for days to the walls of the larynx, where they undergo desiccation into annular crusts of dark yellowish or greenish tinge, discharged spontaneously with difficulty, and only at long intervals, perhaps by a process of suppuration beneath them. Sometimes they are dark brown from admixture with blood. They are easily recognized in the laryngoscopic image; and may encircle the entire surface of the cricoid cartilage, or even of the rings of the trachea; for a tracheitis is often associated with this plastic form of laryngitis. The decomposition of these crusts in the body gives rise to a fetid exhalation not unlike that from fetid coryza (nasal ozæna). They excoriate the mucous membrane beneath them, which is often eroded, and prone to bleed. The crusts themselves are composed of deformed, degenerated, and fatty epithelium, mucus, and pus. The term fetid laryngitis is applicable to this form of the

affection. Its pathology has not been explained. The few instances I have seen have all, I believe, been in natives of Germany. Fraenkel¹ cites a case in connection with the analogous nasal affection.

Dr. Baginsky reported a case in which there were several sets of these masses, the intervening mucous membrane being denuded of epithelium, eroded, and bleeding readily. He considered it similar to the pharyngitis impetiginoides of Waldenburg, and believes the prognosis to be unfavorable, as perichondritis is to be feared.²

Ulcerative Chronic Laryngitis.—Chronic laryngitis, of whatever origin, is liable to eventuate in ulceration of the mucous membrane, especially in debilitated or cachectic individuals. In some particulars the cachectic varieties of the disease differ, but in many they are alike, both as to the seat of the ulcerations and their aspect. Chronic idiopathic laryngitis is the least liable to the ulcerative process. Many observers deny the possibility of ulceration in chronic catarrhal laryngitis. I have seen it often, and know no reason why an abundant proliferation of cells, excited by catarrhal inflammation, cannot compress the nutrient vessels of the mucous membrane and cause ulceration, the same as in cachectic inflammations.

Ulceration may vary from slight excoriation of the mucous membrane, or mere fissure, to necrotic destruction of all the tissues; and between these extremes there may be every possible stage of gradation. The origin of the ulceration is not always attributable to the mere inflammation of the mucous membrane, which is often to be regarded as consecutive to inflammation of the mucous glands, which eventually undergo disintegration, and ulcerate through it. The pressure of swollen surfaces in the acts of phonation and cough, and sometimes in mere respiration, is often the apparent cause of ulcerative action in the mucous membrane.

In some cases the chronic inflammation eventuates in hypertrophy of the muscles, connective tissue, or mucous membrane, or in fibrinous infiltration into these tissues, narrowing the calibre of the larynx, and producing a condition of permanent stenosis. This plastic laryngitis is most apt to occur in syphi-

¹ Ziemssen's Cyclopædia, N. Y. Ed., IV., p. 140.

² (Med. So., Berlin, May 17, 1876) London Medical Record, Dec. 15, 1876, p. 561.

litic individuals. In other cases there is atrophy of the muscles with consequent paresis.

In many cases of chronic laryngitis, the trachea participates in the inflammation more or less extensively (chronic laryngo-tracheitis); and in many others there is also an inactive, or a subacute inflammatory condition of the pharyngeal and nasal mucous membrane (chronic pharyngo-laryngitis), which is sometimes antecedent to the laryngeal affection, and sometimes subsequent to it. The glands at the base of the tongue are sometimes inflamed and hypertrophied (Fig. 104).

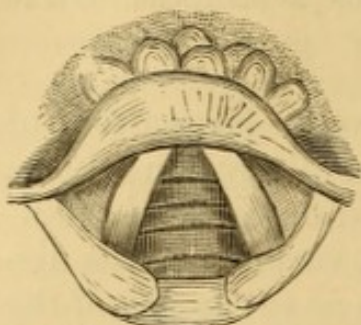


FIG. 104. — Enlarged glands at base of the tongue.

The inflammatory manifestations in chronic catarrhal laryngitis are usually diffuse. Sometimes they do not extend below the vocal cords. In some instances they are limited to special structures, as the epiglottis, or one or both ventricular bands or vocal cords; but less frequently, in consecutive laryngitis, attending a diathesis or following acute systemic disease, than in the idiopathic form. In others there are exudative infiltrations into some of the tissues, and if these implicate the vocal cords directly or indirectly, or the inter-arytenoid fold, or internal faces of the arytenoid cartilages, due vibration of the cords, or closure of the glottis in phonation may be impossible, and the voice be hoarse or muffled in consequence.

The muscular tissues sometimes suffer severely in chronic laryngitis.

Moura¹ has recorded a case in which microscopic examination revealed transformation into fibrous tissue of the striated muscular fibres of the entire posterior crico-arytenoid muscle of the left side, and of part of the corresponding muscle of the other side. Tuerck² has recorded a case of pulmonary tuberculosis, in which microscopic examination revealed chronic inflammation of the muscular substance of the vocal cords, with disappearance of the striped muscular fibres.

In some instances there is hyperplastic induration of the muscular portion of the vocal cords, manifested chiefly on their inferior or tracheal surface (hypertrophic chorditis voca-

¹ *Traité pratique de laryngoscopie et de rhinoscopie*, Paris, 1865, p. 187.

² *Op. cit.*, p. 203, illustrated.

lis). This is sometimes preceded by hypertrophy of the mucous membrane and submucous connective tissue. The inferior portions of the vocal cords project far into the interior of the larynx, in irregular longitudinal tumid welts or folds, just beneath the glottis (Figs. 105, 106), red or reddish brown in color,

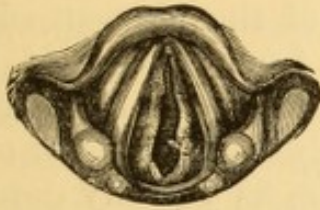

FIG. 105.

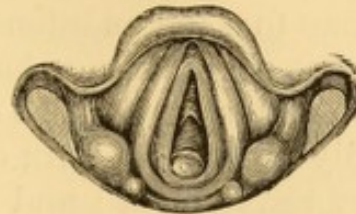

FIG. 106.

FIG. 105. —Chronic tumefaction of the lower surface of the vocal cords, and of the posterior wall of the larynx (Tuerck).

FIG. 106. —Same case as Fig. 105, eight months after tracheotomy; showing the tracheotomy-tube in position, projecting just beneath the posterior portion of the image of the glottis (Tuerck).

and occasion stenosis sometimes to such an extent as to demand tracheotomy, usually with the prospect of permanent retention of the tube, as absorption of these products is rare.

As first described by Tuerck,¹ there is a special chronic inflammation of the vocal cords in singers, characterized by minute, whitish, tumor-like elevations on the horizontal surface of the cords, to indicate which he has proposed the name *chorditis tuberosa*. The pathological significance of these elevations has not been determined. In several cases in my own practice—chiefly in females—these prominences have been on the left cord only.

Chronic catarrhal laryngitis is usually limited, at first, to the intralaryngeal mucous membrane, whence it ultimately involves the upper boundary of the larynx, and thence the perilaryngeal mucous membrane. The parts, on inspection laryngoscopically, are always more or less diffusely hyperæmic and slightly tumefied, their color varying with the case from a mere deepening of the normal tint to a deep red, brownish red, or even a deep purplish red. The injection and tumefaction is less than that of acute catarrhal laryngitis. Enlarged superficial veins are sometimes visible upon the surface, in many instances only on the epiglottis, sometimes upon the ary-epiglottic folds, occasionally on the vocal cords, and in some instances on the infraglottic walls. Very often the membrane

¹ Op. cit., pp. 164-166, illustrated.

appears thickened and indurated, or rendered more prominent by thickening of the submucous connective tissue or by deposits within it, and with a villous aspect. The vocal cords are not always participants in the general inflammatory condition, and their color often appears whiter than normal by contrast. When involved, their discoloration will vary from a pink tinge to a red as intense as that of the adjacent surfaces. Sometimes slight hemorrhage occurs from rupture of the engorged blood-vessels. The supra-arytenoid cartilages are often unusually prominent, with enlarged, clubbed, globular outline, and very red in color; and if there be as yet any deposit of mucus it is apt to be located upon the inter-arytenoid fold at their base. Clumps of more or less viscid mucus sometimes adhere upon the ventricular bands or the vocal cords, stretching often in strands from one side to the other. The free edges of the vocal cords are very apt to be thickened, even when not much changed in color. This thickening gives them somewhat the physical aspect of cords instead of bands. The secretion is increased, and there are slight accumulations of translucent or semi-translucent mucus at various parts of the surface. In some instances the entire interior surface of the larynx is covered with glairy mucus. The free rim of epiglottis is prone to become eroded, even when there is no similar manifestation elsewhere. When the trachea is involved, the membrane covering the rings is reddened by congestion, and the color of the intermediate portions is of a still darker red.

In cases of greater severity, and in scrofulous subjects most frequently, the glandular structures become actively participant in the inflammatory process. They swell and become prominent, and sometimes undergo destruction, so that the mucous membrane becomes ulcerated, and usually in several places; most frequently upon the posterior laryngeal wall, the ary-epiglottic folds, and the posterior portions of the vocal cords, upon which localities small irregular papillary excrescences are sometimes seen—usually proliferations of pavement epithelium, sometimes of connective-tissue elements. Care must be taken not to mistake as ulcers little clumps of adhering mucus. The application of a moistened sponge or of a shower of warm-water spray will often detach the mucus, and show whether the membrane beneath is unabraded. Sometimes a mere cough will suffice. The ulcers, unless in process

of repair, are almost usually covered with grayish or ash-colored pus, of variable aspect; and upon its forcible removal by compression with sponge, the ulcers almost invariably bleed, but not freely. If in process of repair, the ulcers are covered with healthy pus, and their borders exhibit evidence of reparative process.

The epiglottis is thickened, in many instances to several times its normal dimension; in others it appears to be softened and flaccid, and not unfrequently undergoes some alteration in shape, with loss of symmetry. In other cases it is nodulated and spongy in appearance. Very often it has become much less mobile than normal. After a certain length of time, but chiefly in tuberculous and syphilitic cases, more or less ulceration occurs in various parts of its mucous membrane, generally on the laryngeal surface of its free portion, or upon its very border. If not arrested, this ulceration gradually extends in the direction of the glands imbedded in its substance.

There are no specifically characteristic appearances distinguishing ulceration in syphilitic laryngitis from that occurring in tuberculosis. The edges of the ulcer, in syphilis, are perhaps more frequently sharp and gnawed-like in outline, its superficies more depressed in extent, less regular in appearance, and the surrounding tissue redder in color. All the developments of each case must be duly considered to determine its differential diagnosis.

The evidence of ulceration in the trachea recognized laryngoscopically, and seen as it is in perspective, affords but a comparatively vague idea of the extent to which this ulceration may have progressed. Post-mortem appearances often exhibit far greater evidences of destruction than laryngoscopic inspection had revealed during life. Laryngeal ulcers are sometimes of very great extent, and when near the articulating surfaces of the cartilages or the vocal processes are usually associated with necrosis of the underlying cartilage from preceding ulcerative perichondritis. In tuberculous cases the ulcerations heal slowly, and often recur in the same locality, or are followed by fresh ulceration in other localities. The syphilitic ulcer is much more likely to remain healed when once cicatrized. Ulceration without apparent constitutional origin heals readily and permanently, as a rule, under judicious management.

In addition to the accumulations of mucus in the interior

of the larynx proper, collections of mucus, or mucus and saliva are almost always to be observed in the pyramidal, and in the glosso-epiglottic sinuses. Sometimes the mucous membrane forming the walls of these sinuses is inflamed and even ulcerated. These ulcers are rather more amenable to treatment than the intra-laryngeal ulcers.

If the disease progresses, it is almost certain to involve the tongue, pharynx, palate, and adjacent structures not already affected, and may lead to ulceration of the same character.

If the morbid process extends in depth so as to involve the muscular tissue, as is most frequent in the chronic laryngitis of pulmonary tuberculosis, the transverse fibres may become atrophied, destroyed, transformed into fibrous tissue, or in part into fat, or otherwise degenerated. Sometimes the chief seat of the inflammatory action is the vocal cords, the involvement of the adjacent structures being evidently consecutive. The vocal cords become thick, irregular, dark colored, and restrict the orifice of the glottis very much, the voice becoming hoarse in tone and inconstant. Organizable deposits of the products of inflammation accumulate in the submucous tissue to such an extent sometimes as to amount to stenosis. They are most frequent below the glottis, but may involve the lips of the glottis (*chorditis vocalis inferior hypertrophica*¹), and also portions of the larynx above it. In some instances there is partial or complete immobility of one or both vocal cords from paresis or impaired innervation of the muscles to which their movements are due, or as a result of fibrinous deposit or thickening of connective tissue. Hypertrophy of the various tissues—mucous, connective, and muscular—occur sometimes in such quantity and position as to threaten fatal stenosis, and necessitate tracheotomy. When the locality is such as to present impediment to due approximation of the vocal cords, persistent dysphonia, or even aphonia, is entailed in consequence.

Symptoms.—The subjective symptoms of chronic laryngitis are usually inadequate, at first, to indicate the amount of disease existing. In ordinary cases there is not often much more than a disagreeable sense of uneasiness or soreness, with moderate hoarseness and a sense of tickling or titillation inducing a strong and sometimes irresistible desire to cough. There is

¹ Catti: *Allg. Wien med. Ztg.*, Nr. 25, 26, 30, 1878; *Leffert's Reports*, N. Y. *Med. Jour.*, Oct., 1878.

usually a copious discharge of mucus or muco-pus, varying in consistence with the locality, duration, and character of the morbid process; and in the early stages a glairy mucus, which at a later period becomes glutinous, turbid, and stained with dark points of pigmentation. Sometimes it is streaked with blood. This blood is occasionally due to actual hemorrhage without ulceration, but occurs as a result of ulceration much more frequently. The expectoration is usually most copious in the mornings, from accumulation during night. The hoarseness, too, is often more marked in the mornings.

If the disease progresses unrestrained, the symptoms gradually become more and more distressing; the general system evinces phenomena of irritative fever, which often assumes a periodic character, and is attended with diaphoresis; the heart-beats increase from ninety to as many as one hundred and twenty in the minute, and keep accelerated. Gastric and intestinal disorder supervene. The cough becomes more troublesome, painful, and of longer continuance; the paroxysms, toward the last, bathing the patient with sweat, and producing great debility, so that finally effective coughing is often impossible. The dysphagia becomes intense as the ulceration of the epiglottis and the superior portion of the larynx increases in extent, so that, in many cases, deglutition finally becomes impossible, usually first for fluids, and subsequently for solids as well. Everything attempted to be swallowed is painfully regurgitated; thirst cannot be allayed by ordinary means; and the patient often perishes from actual starvation.

The pain, especially when the epiglottis is deeply ulcerated at the side, runs into the ears, so much so at times that much more complaint is made of the pain in the ears than of that in the larynx. This pain is augmented by swallowing or by local applications. It is dependent on direct or reflex irritation of the auricular branch of the pneumogastric nerve, probably from undermining of the tissues in its neighborhood by extension of the ulcerative process outward toward the pharynx. In some cases there is very little pain, even when there is considerable ulceration. In others there is comparatively little or no pain except on swallowing, or perhaps on talking, or when the larynx is manipulated externally for the purpose of eliciting the symptom. In others again, though not in a large proportion, there is constant and excessive pain.

The voice, which at first is perhaps but slightly altered, becoming husky only on exertion, gradually becomes habitually hoarse, and may eventually become extinct. The character of the voice is by no means actually dependent upon the actual amount of disease in the vocal cords. It is sometimes perfectly normal when the cords are quite congested; and often remains tolerably good even when they are in a state of ulceration. Thickening of the vocal cords from interstitial deposit, and not from mere vascular turgescence, always produces hoarseness; and their destruction by ulcerative action entails aphonia, unless the ventricular bands take on the vicarious duty of phonal reeds. The mere character of voice, therefore, does not afford a reliable indication of the condition of the vocal cords. This can be learned only from laryngoscopic inspection. Aphonia may be simply due to impaired innervation of the vocal muscles. Sometimes partial paresis of some of these muscles prevents proper approximation of the cords, and sometimes, although the approximation is perfect, there will still be want of power to throw them into phonal vibration. On the other hand, marked hoarseness sometimes exists with very little evidence of disease in the cords themselves. Here there is probably a paralysis from deposition of inflammatory products between the fibres of the laryngeal muscles, and sometimes from local irritation of the terminal nerve filaments. It is thus evident why a diminution in the grade of the dysphonia, or a return of voice, as it is called, so often occurring in chronic diseases of the larynx, is by no means indicative of actual improvement; an important element as to prognosis, without a knowledge of which too favorable an opinion might be hazarded.

Diagnosis.—This will be based on the history of the case, laryngoscopic evidence of the morbid conditions detailed, and manifestations of the symptoms enumerated.

Prognosis.—In the simple catarrhal form the prognosis is good, provided there is due avoidance of the local causes which give origin to the malady or keep it up. In the fetid variety the prognosis is not good, as chondritis may be present. In the ulcerous form the prognosis varies with the extent and depth of the lesion and the nature of the underlying diathesis, or original cause. It is favorable in the absence of cachexia,

less favorable if associated with perichondritis and chondritis, and least favorable in tuberculosis.

In cases of permanent thickening with ultimate stenosis of the calibre of the larynx the prognosis is unfavorable as to restoration of the normal size of the air-passage by constitutional and local treatment, or by artificial dilatation of the passage, tracheotomy being usually required. The prognosis as to life is often good, provided the artificial opening is made.

Treatment.—The general condition of system and the local manifestations demand equal consideration. Cases uncomplicated with ulceration often yield readily to simple topical astringent and saline treatment, with due attention to diet, clothing, exposure, and maintenance of the functions of the skin and other emunctories. Alkalines, mineral and vegetable tonics, cod-liver oil, and alterants are often indicated by the general symptoms. Local remedies may be inhaled in weak sprays, or, what is better, may be topically applied in strong solution by douche, brush, or sponge. Water is the best menstruum, though glycerine is often preferred for direct application. Ether and chloroform may be used with iodoform and tannin. For inhalation an ounce is the usual amount at a dose. The remedies in most frequent use are alum (five to ten grains), tannin (two to ten grains), sulphate of zinc or copper (two grains or more), acetate of lead (two grains or more), sulphate or sesquichloride of iron (one or two grains), carbolic acid (one or two grains), the nitrate of silver (half a grain to two grains), nitrate of aluminium (one to five grains). This class of agents are applicable to cases of hypersecretion. If secretion is diminished, the indication is for solutions of chloride of ammonium (five grains and upward), iodide of potassium (five grains), compound solution of iodine and iodide of potassium (two or three minims), chloride of sodium, or chlorate of potassium (five grains and upward). Or we may use vegetable promoters of secretion, as tincture of pyrethrum (ten minims and upward), fluid extract of jaborandi (one to five minims), and the like. The addition of a few drops of cologne-water often renders the local effect of the inhalation much more agreeable. If the parts are painful, small proportions of the watery extracts of opium, hyoscyamus, belladonna, stramonium, or conium may be added. Paregoric is often very soothing.

These inhalations should be taken in the patient's own apartment, three or more times a day. Individuals compelled to go out to business can take an inhalation morning and evening, the proportion of the remedial agent being correspondingly increased. The only precautions necessary are, to avoid irritation of the bronchial tubes by too powerful inspirations, when strong astringents are used ; to ascertain that the sprays gain access into the larynx ; to protect the face and teeth from strains of nitrate of silver, ferruginous preparations, etc., by directing the spray through a funnel-shaped tube held in the mouth ; and to avoid exposure to the outside air for at least twenty minutes after a warm inhalation.¹

If local treatment by inhalation is inefficient, resort is made to systematic topical medication with more potent agents. In cases of long standing, or of much severity, it is best to adopt this plan at once. During the intervals appropriate inhalations may be kept up at home, as serving a better local purpose than gargles.

Among local remedies, nitrate of silver, sulphate of copper, and sulphate of zinc will be found the most frequently beneficial, though mild cases often yield to alum ; but in the laryngitis of tuberculosis, tannin is often more serviceable ; and in that of syphilis, the acid nitrate of mercury in due dilution (one part to ten or more). Iodine, carbolic acid, nitrate of aluminium, nitrate of lead, chloride of gold, chloride of zinc, iodide of zinc, the salts of iron, the various mineral acids, and, in fact, the entire list of destructive chemicals have been extolled as topical agents in chronic laryngitis. In individual cases resort to an unusual remedy is compulsory in the hope of producing effects which cannot be obtained by ordinary means. The remedies employed by myself are, almost exclusively, nitrate of silver and sulphate of zinc in ordinary cases, tannin in cases associated with phthisis, and the acid nitrate of mercury in syphilitic cases. The laryngitis attending carcinoma is, perhaps, best let alone, as far as severe topical applications are concerned, unless interference becomes necessary for restraint of hemorrhage ; and even then the bleeding may often be controlled by inhalations of weak solutions of iron, ergot, tannin, or turpentine.

¹ See further details in: *Inhalation ; Its Therapeutics and Practice*. Philadelphia, 1867, second ed., 1876.

The solution of nitrate of silver most frequently used, varies from forty or sixty grains to the ounce, to one hundred and twenty grains, and in some cases a saturated solution is employed, usually produced, at the moment of use, by rubbing a small bit of moistened sponge, for some seconds, upon a large crystal of the salt. The tolerance of the parts is tested in the first instance by a weak solution, which is diminished in strength, or increased, according to the indications. It is undoubtedly better when the application can be borne—and it almost always can—to make a decided impression by a severe application, and wait three or four days for its effects to cumulate and subside before renewal, than to torment the inflamed structures by daily applications of mild, and too often, on that account, inefficient solutions. In some cases the fused nitrate of silver is used ; but this is rarely requisite, except to touch isolated spots and to prevent the nitrate from spreading around the tissues and over them to as great an extent as when applied in solution.

The sulphate of zinc is used in the proportion of from thirty to sixty grains to the ounce. It has been found principally efficient in cases of diffuse congestion of the entire laryngeal mucous membrane, and more or less, usually, of that of the trachea also. Here, by the use of the syringe, or the vertical douche, the parts can be washed at once with a stream or dense spray of the solution.

Some remarks are necessary as to the means of applying local remedies. Sprays may be propelled by hand or by steam. The former method is preferable for momentary applications; the latter for prolonged inhalations. Any contrivance will answer which furnishes a uniform fine spray, and is simple enough in construction to be adjusted by the patient when out of order. Glass or vulcanite tubes are required with substances that would corrode metallic tubes




FIG. 107.—Laryngeal douche.

or be altered in passing through them. Glass tubes are more cleanly and better supervised in every way. Dr. Sass' style of tube and reservoir is preferable to all others I have seen for office use.

Douches may be given by spray-producers properly curved at their terminal

extremities; or by means of catheter-like tubes with bulbous extremities perforated with a series of small holes, through which the solution is propelled by compressing a rubber bulb at the other end (Fig. 107), as first recommended by Gibb, or by forcing the piston of a syringe down upon a few drops of the solution in the nozzle; or by means of a curved syringe with multiple perforations at the extremity of the nozzle (Fig. 108).

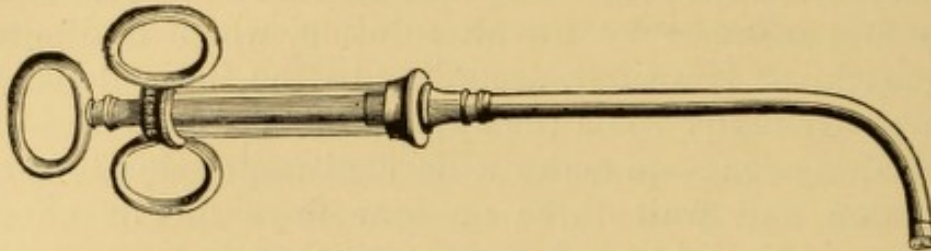


FIG. 108.—Tobold's laryngeal syringe.

Direct topical applications to limited surfaces are made, under laryngoscopic inspection, by means of brushes, sponges, or cotton wads securely attached to a bent rod or other appliance. The manipulation in their use—and the one description will suffice for all laryngoscopic manipulations—is as follows: The part to be operated upon being clearly illuminated by the mirror, the instrument is taken in the disengaged hand and its laryngeal extremity passed into the pharynx close to the mirror, until its point is so nearly in contact that its image is distinctly visible; when, without losing sight of either diseased tissue or point of instrument, it is carefully passed by the aid of the reflection in the desired direction. A little preliminary practice upon an excised larynx, or a model, or a rough substitute for it, is requisite to learn how to manipulate by reflection, for the oblique position of the mirror renders the image rather deceptive as to the actual distance and position of its component parts. It is merely an extension of the manipulation required in shaving by reflection, but in an unfamiliar direction, and it requires practice to become expert, especially when important and delicate operations are to be attempted. It is not always, even after long practice, that the actual contact of the instrument with the diseased spot can be recognized in the mirror, for usually, and nearly always at a first application, spasmodic action ensues at the moment of contact; and sometimes the instrument, if not withdrawn, will be caught upon the epiglottis or upon the base of the tongue; an occurrence which it is desirable to be able to avoid; although under certain circumstances, as when a general application is being made by means of a moistened sponge, the action may be advantageous by compressing the sponge and thus forcing its contents out upon the parts. Under these circumstances the character of the contact is determined by the impression conveyed to the finger by the end of the instrument. As soon as practicable after the operation, which means as soon as the spasmodic action ceases, the parts are to be re-examined, in order to determine the success of the application or judge of the necessity for its repetition.

Patients soon become accustomed to the momentary contact of a foreign body with the laryngeal mucous membrane; although the distress at first is often very great. There is spasm with choking sensations, and expectoration, at times associated with stridulous inspirations and cough; while the sense of con-

striction and dread of suffocation sometimes endure for several minutes. There may also be nausea and vomiting from reflex action. The same sensitive effect occurs as when a foreign body has been removed from the conjunctival mucous membrane, in the continuance of the sensation its presence produced. From a similar cause patients will continue to feel as if the sponge were in the throat after it has been withdrawn, and this will sometimes keep up the feeling of impending suffocation. When the spasm excites the usual distressing symptoms of strangulation, a few forced expirations, or the inhalation of a few whiffs of chloroform or of nitrite of amyl, will soon control it if it does not subside promptly spontaneously. With each repetition of the operation, the sensibility of the parts diminishes, until, after a while, it is merely followed by hawking or clearing of the throat. The earlier applications induce active congestion of the parts, sometimes followed by extravasation of blood beneath the mucous membrane, with increased secretion, followed by a sense of rawness, dryness, or burning, in greater or less degree, and continuing for a period varying from fifteen minutes to several hours. As the applications are repeated these effects, too, gradually diminish in intensity. The swallowing of cold water will materially alleviate its distress when it is severe; and the inhalation of an anodyne solution or vapor will overcome the irritation if it continues for some time.

Very often a successful application or operation can be made at the first attempt; but in cases of extreme irritability of structures a certain amount of preparatory educatory manipulation is requisite. Repeated contact of an extraneous body is the best method of inducing tolerance.

In some instances the epiglottis is more irritable than the interior of the larynx. The best plan to overcome this is to pass the finger behind it, and pull it forward several times, and then to teach the patient to perform the manœuvre himself, directing its repetition two or three times a day. An extension thimble, with a good, broad, blunt end, may be inserted several times a day. When the epiglottis is very much depressed, the patient must pull it forward frequently, so as to develop a tendency to a more erect position. A patient can be taught to raise the epiglottis with one forefinger, and then to pass a sponge probang along the back of the finger down into the larynx. By this, or some similar method, the sensibility of the part will be gradually subdued; and it is surprising sometimes how soon the irritability is overcome. It is an important practical observation that a patient who has been suffering a long time with severe disease will learn, even when of nervous temperament, to control his sensations promptly, while one whose trouble is trivial or imaginary will require longer tuition and preliminary manipulation. Again, it will be noticed that a patient who may be exceedingly docile, and may co-operate well during the earlier interviews, will sometimes become less tolerant of manipulation as relief is being obtained.

When the convenient introduction of an instrument is precluded by obstinate depression of the epiglottis, that structure will have to be forcibly raised by means of properly curved forceps, hooks, or pincettes, of which Bruns' (Fig. 17, p. 33) is one of the best.

Certain precautions are necessary to success in limiting a local application to certain portions of structures, and in order to gain access to others. For this purpose avail is made of the physiological effects of certain voluntary move-

ments. Thus, to medicate the floor of the glottis, or prevent any of the material used from reaching the trachea and lower laryngeal cavity, the patient is directed to emit a vocal sound during the operation. This closes the glottis. If, on the contrary, the instrument is required to reach the lower laryngeal cavity, or penetrate into the trachea, a deep inspiration is to be taken, which opens the glottis and permits the passage of the instrument between its lips. If an application is to be made to the laryngeal surface of the epiglottis, or to the anterior portion of the vocal cords, ventricular bands, etc., the tongue is forcibly extended, and a note of high pitch uttered, to expose these structures more fully. To touch a spot upon the lingual face of the epiglottis, or in the glosso-epiglottic sinuses, or upon the base of the tongue, the base of the tongue is allowed to remain in a more natural position, or is protruded in such a way that the epiglottis will not be raised to its erect position. Then, again, the preliminary movements of retching, swallowing, coughing, etc., voluntarily executed, will elevate the entire larynx, and bring the structures within nearer reach of an instrument.




FIG. 109.—Mackenzie's brush-holder.

The rod or other instrument for intra-laryngeal use should be bent so that the vertical or laryngeal portion is nearly at a right angle with the horizontal portion or handle, as suggested by Dr. Morell Mackenzie, because the curve is then less liable to come in contact with the edge of the epiglottis and excite spasmodic contraction of its muscles. The safest holder for a sponge is a stiff wire, with two or three bulbous expansions at the end, or with a screw-thread, around which the sponge can be securely tied. Brushes are now furnished by the instrument-makers mounted in sockets which can be screwed on such a wire so that the one holder answers for either brush or sponge (Fig. 109). The sponge should be of the very best quality. To secure it firmly it should be moistened and then rounded off with the scissors, one end being cut tapering with a wedge-shaped piece cut out (see Fig. 109), so as to present two firm supports for tying it securely to the thread-screw of the staff, or between bulbous projections, to keep




FIG. 110.—Sponge-holder with bayonet-catch.

it from slipping. When secured, the projecting portion of sponge can be trimmed to suit the special indication.

A steel rod, split at the end to form roughened jaws provided with sharp

teeth, and secured by a bayonet-catch (Fig. 110), forms a handy and efficient sponge-holder for small pieces of sponge or amadou, which can then be trimmed as closely to the instrument as desired, so that only a mere point projects with which to touch limited surfaces, as small follicular ulcers.

I was long in the habit of employing curved spring forceps for holding the sponge, on account of the ease with which it could be detached, and thus be cast aside immediately after use; but I found that, no matter how carefully the instrument had been constructed, the time would come, sooner or later, when it would be no longer safe; and thus I have returned to the primitive and tedious method of tying the sponge on the rod with well-waxed surgical thread. No application should be made to the interior of the larynx without testing the sponge, mop, or brush, to ascertain that it is thoroughly secure. No brush or sponge should be used on more than one patient. In many instances the sponge should not be used a second time even on the same patient. Brushes should be soft and capable of being drawn to a fine point. Full-bellied brushes may be used for diffuse work. The majority of practitioners prefer brushes to sponges for topical applications to the interior of the larynx. For general applications to the pharyngeal surfaces of the larynx, to the free borders of the epiglottis and ary-epiglottic folds, and to the lingual face and upper portion of the laryngeal face of the epiglottis, they answer very well; but for applications to the interior surfaces of the laryngeal membrane I find them much inferior to sponge, for the action of the epiglottis is such, very often, that it bends the brush in such a manner that its free extremity is forced outside and beyond the supra-arytenoid cartilages, and does not reach the interior of the larynx at all. Sponge, being simply elastic and not flexible in small fragments, is not forced out of the larynx by the contraction of the epiglottis and constrictor muscles of the uppermost portion of the larynx, but is rather compressed by them so that the contained fluid is pressed out over all the surfaces with which the sponge is in contact. Soft surgical sponge of good quality is nearly if not quite as unirritating as the camel-hair pencil. When it is desired to confine the application to very limited surfaces, as those of small ulcers, a minute bit of sponge is much more certain in its action than the point of a brush in the deeper portions of the larynx, and at least equally so in the more accessible portions. Some

practitioners use a cotton wad, but there is a possibility of little fragments becoming detached within the larynx, and its employment is imprudent. In reaching the exterior surfaces of the larynx and its free borders, it is sufficiently safe, and may be preferred for its softness.

It is often necessary to make a strong caustic application to a very small point—a minute follicular ulceration, for example. This cannot be done with cotton wad, sponge probang, or full-bellied brush, because the healthy tissues will be cauterized to their detriment. A delicate, fine-pointed hair-pencil may answer for superficial surfaces, but it does not admit of firm pressure being made upon the part, as is often desirable. For this purpose a pair of curved forceps are necessary, the jaws of which taper to a fine point (Fig. 111). A small longitudinal bit of sponge or amadou is inserted between the blades, and then




FIG. 111.—Author's lateral spring laryngeal forceps for securing minute fragments of sponge or amadou.

trimmed closely on the sides and as closely at the point as may be required. The exposed portion may thus be limited to a surface no larger than a pin-head, and as a comparatively large portion is hidden in the grasp of the instrument it is not likely to become detached. The compressing spring of the forceps should be lateral, so that the pressure of the forefinger would not disengage the catch, as might occur with instruments curved on the flat.

In the absence of a laryngoscopic mirror, intra-laryngeal applications are best made by carrying the instrument along the forefinger, previously passed behind the epiglottis, which is to be pressed forward against the base of the extruded tongue. The handle of the instrument is raised to direct the distal extremity forward as soon as it passes the point of the finger. This is sometimes the only method practicable with children. As the epiglottis may be normally or abnormally depressed, its position should always be determined by inspection or palpation before any attempt is made to introduce an instrument into the larynx.

Local applications of powders are sometimes made advantageously to the general surface of the supra-glottic portion of the larynx. The powder may be deposited upon a localized surface from a brush or sponge, or may be blown into the general cavity of the larynx in the form of a dry shower, propelled from the end of a curved tube, into some convenient portion of which it has

been introduced. It may be projected by a puff of the breath, or, as is much more seemly, by a puff of compressed air from a reservoir, or from a rubber bulb at the end of the tube or along its surface. In Rauchfuss' insufflator (Fig. 112), which is the most convenient one I have used, the powder is inserted into a slot, which is then covered by a slide. The instrument is discharged by compressing

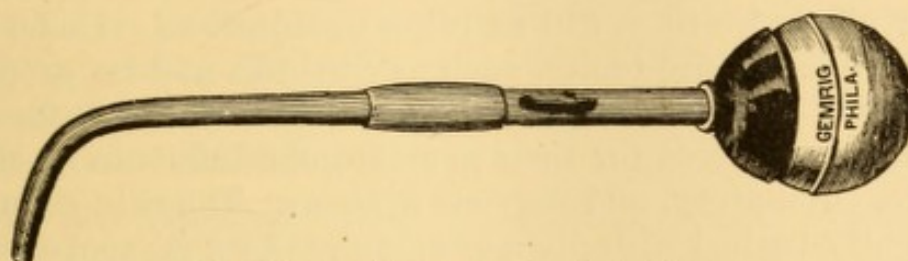


FIG. 112.—Rauchfuss' laryngeal powder-insufflator.

the bulb with the thumb. The terminal extremity of the tube should be large, else it will become too easily clogged up, for it is almost always withdrawn moistened with mucus from the larynx or with saliva from the mouth. In the absence of a special instrument, the powder distributor sold by grocers and others to propel insect-powder may be used, the terminal extremity being bent to suit. Accurate propulsion is rarely practicable, because of the difficulty of controlling the distal extremity of the tube, which is almost certain to undergo slight displacement in the manipulation.

Powders are sometimes much less irritating than solutions for purposes of general medication of the larynx. When too pungent or active, they must be properly triturated with some innocuous attenuating material, as lycopodium, althæa, glycyrrhiza, acacia, magnesia, starch.

The chief substances used in powder are alum (pure or 1:1 to 1:5), tannin (pure or 1:1 to 1:10), acetate of lead (1:5 or more), sulphate of zinc (1:5 to 1:30), nitrate of silver (1:20 to 1:80), as astringents; calomel (pure or 1:1 to 1:5 or more), bismuth (1:5 or more), iodoform (1:20 or more), hyoscyamus (1:20 or more), belladonna (1:10 or more), as sedatives; oxysulphuret of antimony (1:1 to 1:5 or more), chloride of ammonium (1:5 or more), as relaxants; a little morphia (one-sixteenth of a grain or more) being added when indicated for relief of pain or irritability. Sometimes two or more of these powders are combined. The quantity used at a time is about as much as would fill the nib of an ordinary steel pen, and the insufflation is practised daily or oftener, according to indications. Patients are readily taught to manipulate upon themselves. If it is intended to limit the shower of powder to the supra-glottic portion of the larynx, the insufflation is made during phonation; if it is intended to reach the lower portion of the larynx and the trachea, it is propelled during inspiration or just after it.

In obstinate cases of chronic laryngitis, persistent counter-irritation externally, at the sides of the larynx, at the supra-sternal notch, behind or below the ears, or at the nape of the neck, is often of advantage. In addition, the internal use of

alterative or tonic doses of iodide of potassium, arseniate of potassium, chloride of ammonium, bichloride of mercury, or such other constitutional remedies as may be indicated by the cachexia or the individualities of the case, are often efficacious, provided due strength can be maintained by efficient nourishment; otherwise they will as often be injurious. Under such circumstances, pure tonics, such as cinchona and its products, ignatia and its products, chloride of iron, or other ferrous salts, should be employed for their general good influence on the digestive, circulatory, and nervous systems. The skin should be frequently bathed with plain or acidulated water, cool or tepid, as may be most comfortable and pleasant. Excesses at table should be avoided, exposures to atmospheric changes prevented, and the voice used as little as may be. If the patient is necessarily exposed to the inspiration of irritant substances, he should wear a metallic respirator¹ at the time, or cover the nostrils and mouth with a veil; or keep the mouth closed, and protect the nostrils by a tiny wad of angora or other wool, delicate enough not to interfere with respiration. In severe cases, attended with frequent cough, the respirator or its substitute should be in constant requisition to moderate the local stimulant effect of the oxygen in the air, which is sometimes too irritating for the hyper-sensitive mucous membrane. The value of the respirator in these cases can hardly be appreciated by those who have not witnessed its beneficial effects. Should these measures fail after a fair trial, treatment is reduced to adherence to a hygienic regimen, and resort to palliative measures as occasion may suggest. Change of climate is sometimes desirable, permanent or temporary, as results may determine. Heroic measures will not be likely to do good, and may transform an endurable condition of simple chronic inflammation into an ulcerative one, still more difficult of management.

In cases of ulcerative laryngitis, more active local treatment is demanded, especially when there is intense inflammation of the submucous tissues, associated with tumefaction of the epiglottis or the upper margin of the larynx (chronic œdema). These occur chiefly in phthisis, sometimes in syphilis, occasionally in chronic laryngitis without cachexia. Here local

¹ For females, the respirator-veil devised by Mr. Lenox Browne, of London (Brit. Med. Jour., Nov. 18, 1876; London Medical Record, Dec. 15, 1876), seems a most desirable appliance.

treatment is required, not so much as a curative procedure, but rather as the best means of relieving the attendant dysphagia, which, if not allayed, will gradually lead to death by starvation. Often the best agent is a solution of nitrate of silver ($\mathfrak{D}\text{j.} - \mathfrak{D}\text{ij. ad f. } \mathfrak{z}\text{j.}$), carefully applied every other day, every day, or even twice a day, as may be required. These applications, by coating the parts with a protective covering, sometimes form the only means of affording temporary opportunities to swallow nourishment.

Dr. S. Scott Allison has advised the local use of sweet-oil, to alleviate the pain of deglutition, in this condition. Dr. Gibb recommends the internal and local use of bromide of ammonium. Dr. Schroetter extols the local use of powdered morphia in some innocuous powder, as gum arabic or sugar (one to four grains to the ounce), propelled directly upon the parts from an insufflator. Sugar, however, sometimes increases the immediate suffering, though it also seems at times to exert a beneficial influence on the ulcerative action, facilitating the discharge of slough. I have tried all these methods, at times, with benefit. The nourishing qualities of cod-liver oil render it a desirable substitute for sweet-oil in this connection. The patient may attempt to swallow it, and, though he may fail, the lubrication of the surfaces will facilitate the passage of the next bolus, and a few more subsequently, so that a certain amount of nutriment can be taken into the stomach. A large-bellied brush on a curved shank may be loaded with the oil, or with a glutinous solution of bromide of ammonium, or morphia, and be passed by the patient to his gullet, and be partially swallowed as it were, so as to wipe the contents from the brush upon the epiglottis and upper portion of the posterior part of the larynx. Sometimes it is necessary for the physician to make the application. In many cases it may be entrusted to a skilled attendant. It should be repeated several times during the twenty-four hours, according to results, care being taken that an application be made within an hour of each meal-time, so that advantage may be taken of its soothing effect for the swallowing of food.

As soon as there are unmistakable signs of amelioration, these applications may be suspended, as the improvement is apt to continue once a better local nutrition has commenced; but, should the condition become worse, or should it, at the onset, be of such a character as to threaten suffocative manifestations, free scarification is indicated; after which the nitrate of silver may be employed, if required. After the tumefaction is under subjection, and even previously, dilute glycerine, swallowed if possible, or applied by the brush, or allowed to trickle along the back of the throat, will often be of service, though it rarely absorbs moisture from the œdematous swelling, as has been asserted. In many cases, unfortunately,

chronic œdema is associated with progressive disease of the cartilage, and is reproduced again and again.

The detachment of mucus by expectoration is sometimes difficult, and may be favored by bending the head toward the floor, so as to invoke the aid of gravity. I have seen a patient get upon his knees and bend his head to the ground, to detach masses promptly that he was otherwise unable to expel without prolonged and violent effort.

Severe dyspnœa occurs at intervals in many cases, sometimes continuously for the time being, sometimes spasmodically. When dependent on physical causes, such as tumefaction, œdema, excessive granulation, etc., special local treatment directed to these conditions is requisite. When the cause seems to reside in excessive irritability of the parts, or in reflex influence from disturbance of other parts, or disturbance of nervous origin, the local application externally of cloths wrung out of heated camphor-water, and placed over the larynx, trachea, and sternum, with cold applications to the head and face, will often be serviceable. The internal administration of volatile pungent medicines, as valerian, ether, ammonia, and the like, is also indicated, if the condition of the throat will permit of their deglutition.

Occasionally chronic laryngitis is confined to a single structure, as the epiglottis. Under these circumstances, the complaint is often rapidly cured by local treatment alone, as exemplified in the following record of a case of epiglottitis :

A lady, æt. 32, applied February 9, 1867, with a sore throat, attended, for nearly five months, with painful dysphagia as the most prominent symptom. The difficulty of swallowing had been so great at times that she had been forced to assist deglutition with her hands. Inspection revealed chronic folliculous pharyngitis; but the most marked morbid appearance was a thickened and inflamed epiglottis, relaxed and bent backward toward the right side. This point was quite painful to the touch. The parts were thoroughly washed with a solution of nitrate of silver, sixty grains to the ounce, after which swallowing was accomplished much more easily and without pain. Two or three subsequent applications, at intervals of two or three days, relieved these symptoms entirely.

Permanent stenosis resulting from chronic laryngitis can sometimes be overcome by dilatation, but often requires tracheotomy.

TUBERCULOUS LARYNGITIS.

(The Chronic Laryngitis of Phthisis ; Laryngeal Phthisis ; Chronic Tuberculous Laryngo-tracheitis ; Throat Consumption.)

The fact that various diseases of the larynx, some remediable, and others incurable, present similar subjective phenomena of impaired voice, enfeebled respiration, cough, purulent or sanguineo-purulent expectoration, and, when protracted, diarrhœa and hectic fever, led at one time to great confusion in the interpretation of these symptoms ; several conditions of different origin being included under the head of phthisis laryngea, which was even regarded to some extent as a special malady in which tuberculization, if not tubercle, is limited to the larynx.

Tuberculous laryngitis is an ulcerative laryngitis or laryngo-tracheitis accompanying pulmonary tuberculosis, and liable to involve the mucous membrane, glands, muscles, cartilages, and all intervening and contained tissues. It is usually a secondary manifestation, though asserted to be primary also. The precise dependence of the ulcerative processes upon direct tuberculosis is a matter of doubt and dispute. Primary deposits of tubercle in the larynx and trachea are so rarely demonstrable that the very tendency is denied by some observers, and doubted by many.

They have been recognized by Rokitansky, Virchow, and other pathologists. Rindfleisch¹ admits the possibility of eruption of real miliary tubercle in the lining membrane of the larynx, but intimates that the tubercles are so few and so rarely to be detected, that they must be regarded as a very insignificant factor in the ulcerative process of laryngeal phthisis. Certainly, the enlarged mucous glands of the laryngo-tracheal mucous membrane, hyperplastically distended with retained secretion of long-continued catarrhal inflammation, must be regarded as a non-tuberculous element. The presence of these inflammatory products in the glands leads to their ulcerative destruction, and the confluence of several of these ulcers produces the racemose configuration, generally considered characteristic of a tuberculous ulcer. In contrast with these views, recent observers, accustomed to use the laryngoscope, have claimed to detect tubercles in the mucous membrane of the larynx early in the disease, and some of them² have depicted laryngoscopic images of the deposits. If the preceding

¹ Pathologische Gewebelehre, 2d Ed., p. 330.

² Gibb : *Op. cit.* ; Marcet : *On Diseases of the Larynx*, London, 1869.

explanation be plausible, it can hardly be doubted that these nodules, so large as to be plainly visible, must have been enlarged mucous follicles. I cannot recall a case that presented this distinct studding of the larynx even in part. I have occasionally seen from one to four isolated white spots, as large as ordinary pin-heads, upon the walls of the lining membrane of the larynx, which retained their position and aspect for months continuously in cases of slowly progressive pulmonary tuberculosis; and I have thought these might possibly have been degenerated tubercles. Early softening of laryngeal tubercles and their removal by ulceration are given as the reasons why they are so rarely detected; and Virchow mentions that, when superficially seated, the softening and ulceration occur without previous caseation or sufficient enlargement to render them visible to the unaided eye. They are hardly recognizable, then, in a reflected image. I have frequently observed, however, in tuberculous subjects, groups of enlarged glands over the arytenoid cartilages, the supra-arytenoid cartilages, the lateral walls of the interior of the larynx, and, in occasional instances, upon the laryngeal face of the free border of the epiglottis, which presented somewhat these appearances; but I have not regarded them otherwise than prominent glands, to the external coloration of which a yellowish tinge had been given by the tension of the mucous membrane over them. Even the examination of similar conditions in the excised larynx has failed to afford reason for a different opinion. Similar appearances are not unusual in some of the simpler inflammations of the mucous membrane of the lips, the cheeks, etc., occurring under the depressing influence of excess of temperature, indigestion, overwork, or even mental anxiety. The same thing is seen, occasionally, along the borders of the glosso- or the pharyngo-palatine folds in cases of chronic pharyngitis, both idiopathic and associated with tuberculosis. Miliary tubercles have been detected in the larynx in some primary cases of acute tuberculosis; and in some cases of secondary acute tuberculosis supervening upon chronic phthisis. In an instance under my own care, in which the patient perished in less than three weeks from acute tuberculosis, the primary manifestation of which was a sub-acute laryngitis, the specimen, now in the Museum of the College of Physicians of Philadelphia, was carefully examined by Dr. Longstreth, pathologist to the Pennsylvania Hospital, without revealing any evidence of the presence of tubercle.

There is no histological inference why tuberculous deposits should not take place in the larynx. They are occasionally detected in the tongue, where they give rise to ulcers of various sizes, with floors covered by small and defective granulations, but distinct from another class of ulcers occurring in similar situations in cases of tuberculosis, and which are the result of the systemic condition of cachexia, rather than of a local deposit of tubercle. The latter class are similar to many tuberculous ulcerations in the larynx and trachea. I have seen acute tuberculosis commence in at least two instances in parenchymatous pharyngo-laryngitis, not distinguishable from the similar process resulting from exposure, and sometimes termed rheumatic, and in one of these instances there was not even ulceration of the larynx.

Some individuals with pulmonary tuberculosis are subject to intercurrent attacks of ordinary catarrhal laryngitis, wholly

disconnected with the tuberculization; and this laryngitis is amenable to treatment just as the idiopathic variety, and is to be carefully discriminated from tuberculous laryngitis, on the score of efficient prognosis, and the liability of indiscreetly crediting therapeutic measures with remedial powers that they do not possess.

I cannot but ignore the assumption of special disease to be called *laryngeal phthisis*, whether it be the tuberculous ulceration of portions of the laryngeal mucous membrane observed in some cases of general or pneumonic phthisis early in the period of softening, or whether it be the extensive suppurative perichondritis and chondritis occurring in syphilis, typhoid fever, and other diseases, as well as in certain cases of general tuberculosis;—sometimes phthisical only in the sense of consuming the patient by exhaustion and hectic, without tuberculosis. Tuberculous disease confined to the larynx is so rare as to be of doubtful occurrence.

In common with many other practitioners, the instances of tuberculous laryngitis observed by myself have usually exhibited simultaneous evidence of at least presumptive tuberculous disease of the lungs. On the other hand, pulmonary tuberculosis is often unassociated with any evidence of tuberculous laryngitis during any portion of its progress. Tuberculous disease may possibly become manifested in the larynx previous to any manifestation in the lungs; but in the absence of positive evidence to the contrary, which is hardly probable without fortuitous post-mortem examination accidentally offered, it is fair to consider absolute freedom from pulmonary involvement as unproved. The denial of ulcerative processes as occurring in chronic catarrhal laryngitis,—with which my own observations from the very first have not been in accord, seems to me one reason why the existence of tuberculous laryngitis is so strongly maintained as not unfrequently anterior to the pulmonary involvement. The suspected laryngeal tuberculosis occasionally cured without impairment of the lung supervening, is, I am inclined to believe, often a simple catarrhal laryngitis with follicular ulceration. Waldenburg¹ and Buhl, and others with them, believe that a primary laryngeal affection often precedes pneumonic phthisis, which is then secondary to the disease in the throat. The primary affection observed by Buhl is described as a perichondritis considered analogous to peribronchitis. Hering,² in common with Waldenburg, believes that the so-called tuberculous ulcers in the larynx and bowel do not originate in softened tubercles, but in inflammatory affections of the mucous membrane and its follicles, with which a secondary miliary tuberculosis in contiguous parts may become associated. Primitive

¹ The London Medical Record, July 29, 1874, p. 462

² Ibid.

laryngeal tuberculosis is likewise recognized by French¹ and British,² and other observers, several of whom have described the laryngoscopic manifestations with great minuteness.

In the earliest stages of the disease the affection is usually unilateral, and on the same side in which disorganization is taking place in the lungs. Subsequently the other side is attacked likewise, the involvements of the larynx following the course taken in the lungs. Though the stages of the laryngeal disease previous to ulceration may coincide with any period of the pulmonary disease, ulceration is presumptive evidence of the advanced stage characterized by excavation in the lung. In some instances there is involvement of the submaxillary or cervical glands, usually but not invariably confined to that side of the larynx which is affected to the greater extent. Sometimes the tumefaction occurs suddenly, and in a very few days the affected gland acquires the bulk of an almond or more, and is exquisitely tender to the touch. At other times the swelling is gradual, and has progressed for some time before it attracts attention. One or a few glands may be affected, or a whole chain or more.

Tuberculous laryngitis is rarely manifested before puberty. Indeed, I cannot recall an instance in my own practice. It is usually seen in young adults between twenty and thirty years of age, and then, with decreasing frequency, to about the fortieth year. It is infrequent again in advanced life. Males suffer more frequently than females.

It is very rarely that distinct evidences of presumptive tuberculous deposit are apparent, upon laryngoscopic inspection, in the incipient stage of pneumonic phthisis. There is reason to suspect that such deposition may have been in progress when, later in the disease, the surface of the anæmic mucous membrane is here and there raised in small, whitish prominences, the size of pin-heads or mustard-seeds, irregularly oval or round in outline, and looking as though they could be popped out from beneath the membrane by the point of a bistoury. Sometimes there are groups of such elevations. They occur on

¹ Notably Mandl: *Traité pratique des maladies du larynx et du pharynx*, Paris, 1872, p. 678; Isambert: *Conférence cliniques sur les maladies du larynx et des premières voies*, Paris, 1877, p. 184.

² Browne: *The Throat and its Diseases*, London, 1878, p. 222; James: *Sore Throat*, London, 1878, p. 247.

the epiglottis, but more frequently on the intra-laryngeal surface of the ary-epiglottic folds, on the ventricular bands, and on the inner surface of the supra-arytenoid cartilages; but they occupy any portion of the larynx, and are sometimes observed in the pharynx likewise. These have been supposed to be miliary tubercles. Occasionally they remain for months without a change in appearance, as though they might be calcareous degenerations of former tubercles. It is likely that they are occasionally discharged and expectorated, but no direct evidence of the kind has come under my own observation. Isambert, however, has recently observed some instances of such enucleation and discharge of caseous tubercle from the epiglottis in acute miliary tuberculosis of the throat.¹

In very many instances the first objective manifestation of the disease is a well-marked pallor of the entire mucous membrane of the larynx, the mucous membrane of the mouth, palate, and pharynx being in a similar condition; though sometimes the margins of the anterior palatine folds are quite red from congestion, and limited streaks or patches of congestion are observable upon the palatine folds, and upon the pharynx. This anæmia is but an expression of general impairment of nutrition, and is sometimes evident in advance of similar manifestations in other localities. Accompanying this condition, there is an irregular vascularity of portions of the mucous membrane, which is here and there elevated in irregular ridges or welts, red in color, of a distinctly villous aspect, indicative of denuded epithelium. In some instances spots of ecchymosis are irregularly distributed beneath the mucous membrane of the epiglottis, or in the interior of the larynx, and little irregular varices also; and, in some of these cases, a similar condition is observable at the angles of the palatine folds, and in other portions of the mucous membrane of the palate and pharynx. There is often a general swollen condition of the mucous membrane, but it is by no means constant. Circumscribed tumefaction is more frequent, and its most frequent locality is upon the exterior surfaces of the supra-arytenoid cartilages (Fig. 113), which are often

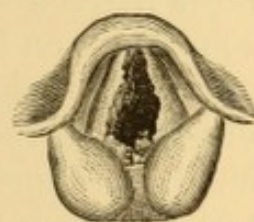


FIG. 113. — Pyramidal tumefaction of supra-arytenoid structures in tuberculous laryngitis; showing also linear ulceration of vocal cords, and ulceration of inter-arytenoid fold.

¹ Op. cit., p. 387.

transformed into tumid pyriform, or irregularly rounded cushions, sometimes pale, sometimes very red, sometimes fiery red; and not unfrequently actually livid at the points where they become pressed together in phonation and in deglutition. Sometimes they prevent closure of the larynx in deglutition, and render swallowing uncertain and painful. In some cases the epiglottis is quite flaccid, in marked contrast to its ordinary rigidity. The fold of tissue between the arytenoid cartilages is almost invariably and even characteristically affected, and is usually red, often with irregular projections on its laryngeal surface, which gradually acquire the appearance of submucous tumors or vegetations, condylomatous or acuminate, the growth of which is sometimes accelerated, and again retarded during the course of the disease. This laryngeal face of the meso-arytenoidal fold, when the seat of disease, is almost constantly covered with a thin layer of mucus, or muco-pus, or pus, which gradually trickles over the bridge of tissue into the pharynx, and occasionally, when wiped clean with a sponge, discloses an irregular ulceration of the membrane, whose œdematous notched margins constitute the vegetations alluded to. There is usually a thinner layer of mucus or of muco-pus bathing the interior of the larynx to a greater or less extent, with often small clumps of thicker and more opaque mucus clinging in strands to the edges of the vocal cords. Irregular papillary excrescences of variable size, but usually comparatively small, are developed very early in some instances. They may occupy any portion of the mucous membrane, a frequent locality being the inner surfaces of the upper part of the arytenoid cartilages, most frequently of one only, usually that on the left side, but sometimes on both. In some instances they become developed on the hitherto unaffected side, months after having been observed on the other side. In other instances the ventricular bands, or supra-ventricular surfaces, will be invaded first. The vocal cords are usually congested, sometimes so intensely as to have the same color as the general laryngeal mucous membrane, and, if the latter be at all anæmic, even a deeper red. They are often thickened from induration.¹ Sometimes they are irregularly studded with points or patches of ecchymoses,

¹ In a case reported by myself (Trans. Path. Soc., Phila., Vol. VI., 1877, p. 83), they had become much larger in volume than the ventricular bands.

and sometimes they are overlaid by enlarged vessels. Occasionally similar evidences of extravasation of blood exist on the epiglottis, the lateral walls of the larynx, and sometimes along the anterior wall of the trachea, even to its bifurcation. Erosions takes place at times at these points, giving rise to local hemorrhages.

At a more advanced stage, the velvety projections of the mucous membrane undergo abrasion, and ulcers are left, varying in shape and position. Sometimes the ulceration is limited to the posterior wall of the larynx (Fig. 114), one or both ventricular bands, one or both ary-epiglottic folds, the base of the epiglottis anteriorly, or some other special structure; but, as a rule, they occur at several localities, especially at points of contact (Fig. 115), either simultaneously or in more or less rapid succession. These localities are those which are most copiously provided with mucous glands. The entire glandular structure becomes

involved. The secretions accumulate in the glands or in their ducts, destructive inflammatory action is set up around them, and finally the glands suppurate and leave irregularly racemose and contiguous unhealthily granulating sores, which evince little or no disposition toward repair, but remain covered with an aplastic lymph irregularly distributed over their surfaces. In some instances the mucous membrane upon the vocal cords gives way likewise, and ulcers are left upon these structures. Sometimes, the fibrous structure of the cord undergoes ulceration likewise. Sometimes, when the membrane gives way at the very edges of the cords, an irregularly jagged or toothed outline is left, resembling a narrow shred of scoloped muslin, deprived of some of the transverse threads. The posterior portion of the cord is the site by far the most frequently affected. Sometimes the denuded vocal processes project into the laryngeal cavity (Fig. 115), even at times without involvement of the bodies of the arytenoid cartilages.

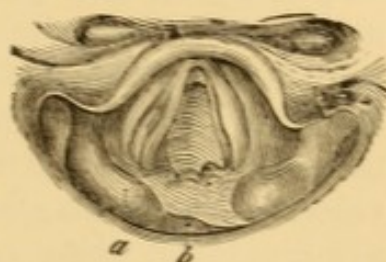


FIG. 114.—Ulceration on posterior wall of larynx (Tuerck). *a*, Right cuneiform cartilage; *b*, right supra-arytenoid cartilage.

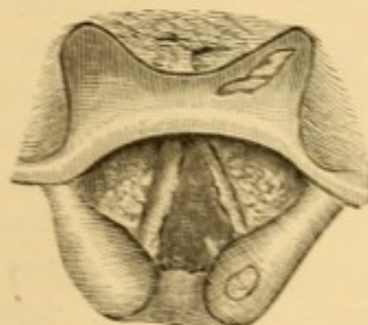


FIG. 115.—Ulceration of epiglottis, ventricular bands, vocal cords, and external face of one supra-arytenoid eminence, with denudation of vocal process of same side.

The unhealthy viscid secretions of the larynx and bronchi, and the pulmonary sputa, readily adhere to these projections, and accumulate there, irritating the membrane and the glands, and perhaps become in part absorbed and actually lead to the follicular ulceration, as originally suggested by Louis. Their presence excites frequent occasion to clear the glottis and interarytenoid fold from clumps of adherent mucus which produce irritation and irrepressible cough. The lateral walls of the larynx soon undergo augmented tumefaction, and the ventricular bands project, sometimes on both sides, but more frequently on one side only, so as to overlap the vocal cords more or less completely; their borders approximate in closure of the glottis before those of the vocal cords themselves, sometimes, indeed, vibrating sufficiently, in attempts at phonation, to produce a husky, muffled substitute for the normal voice. Very often all ocular evidence of demarcation between ary-epiglottic folds and ventricular bands is entirely obliterated. The latter structures not unfrequently exhibit a dull grayish aspect, and are sometimes covered with an ash-colored membranous deposit. The general signs of disintegrative inflammation increase, the destructive processes often proceeding from below upward. Thus the epiglottis becomes invaded, its edges being indurated or ulcerated, as well as its laryngeal face, which is the more frequent seat of attack. The pharyngeal surface of the larynx becomes implicated, the purulent or muco-purulent secretion accumulating in the pyramidal sinuses, which are sometimes filled with it, and in

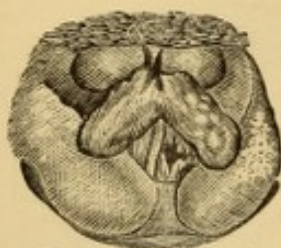


FIG. 116. — Ulceration of epiglottis, ventricular bands, and interior of larynx.

the glosso-epiglottic sinuses. The swollen structures become more and more irregular and deformed in outline, so that it is extremely difficult to describe or depict the altered appearances of the parts (Fig. 116). Sometimes the ventricular band is adherent to the vocal cord below it, obliterating the ventricle; coincidently with which, and also sometimes independently of it, one vocal

cord is elevated higher than its fellow, or depressed, in either case preventing proper approximation, and entailing persistent dysphonia. This condition may prevail at quite an early stage of the disease, when the only subjective symptom will be the hoarseness. In addition to this there may be paralysis

of the vocal cords from degenerative changes in the muscular tissue, or from interstitial deposits, in the latter instance attended by a certain degree of stenosis, varying with the amount of swelling and the fixed position of one or both cords. This presents a serious obstacle to the expectoration of the products effused or secreted below the glottis, and in some instances produces painful dyspnœa and inspiratory stridor. Irregular exuberant granulations are not unfrequently developed by the heat and moisture of the parts. They spring up about the bases of the tuberculous ulcerations or around their edges, sometimes augmenting into veritable neoplasms, usually containing epithelial elements, as shown under microscopic examination, and retaining a marked disposition to repullulation from their base whenever they are torn off by forceps or destroyed by caustics, procedures which become necessary at times for the relief of dyspnœa, and of annoying titillations that excite irrepressible cough. These granulations occur perhaps most frequently upon the inter-arytenoid fold, but also on the inner surfaces of the arytenoid cartilages, on the posterior edges and inferior faces of the vocal cords, sometimes at the anterior angle of the vocal cords, or in the angle of the thyroid cartilage below them, at the base of the epiglottis, sometimes near the edge of the epiglottis on its laryngeal face, and upon the surface of the ventricular bands. Again and again they may be seen to sprout, fungus-like, from the bed of the ulcer, and increase in size from week to week. These ulcerations are often the mouths of undermining sinuses leading to diseased or dead cartilage. Sometimes the vegetations appear without any evidence of ulceration, present or past, and, when pulled off, become the starting-point of the process; so that some prudence is advisable in interfering surgically with them. It is only when of such size as to interfere with important functions that they are to be removed; for they may slowly disappear under judicious general and topical treatment.

These vegetations readily undergo erosion and ulceration. When occupying both vocal cords, the attrition of the ulcerated surfaces may excite adhesive inflammation, culminating in the formation of an organized web between them, as occurs also in syphilitic and even in catarrhal laryngitis under similar circumstances. In one case of tuberculous laryngitis I had an

opportunity to watch the formation of this membrane almost from its first outgrowth.

A lad, nineteen years of age, in advanced pneumonic phthisis, of hereditary nature, had irregular excrescences on the inter-arytenoid fold and both vocal cords (Fig. 117). Ulceration of the growths on the vocal cords ensued, followed by the development of a few membranous bands from side to side (Fig. 118). Despite all efforts to prevent it by dividing these bands with the knife, and subsequently by rupturing them with blunt instruments, a firm web formed (Fig. 119) within less than a fortnight. Tracheotomy was then proposed, but declined,

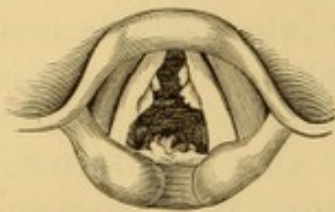

FIG. 117.—Growths on vocal cords and inter-arytenoid fold in a case of phthisis.

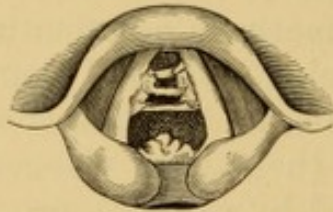


FIG. 118.—Membranous adhesions between ulcerated growths on vocal cords, same case.

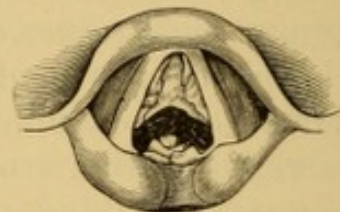


FIG. 119.—Ultimate formation of web of membrane between vocal cords in same case.

and the patient passed in other hands. Three months subsequently the patient again solicited my services, much emaciated, and with extensive catarrhal laryngitis, with copious secretion of muco-pus, the membrane remaining intact; and with such dyspnœa that I performed laryngotomy, without anæsthesia, dissecting the crico-thyroid membrane from the thyroid cartilage, and inserted a tube, through which he breathed with comparative comfort during the remaining six weeks of his life. Extensive ulceration of the supra-glottic portion of the larynx, including the web, with obliteration of the ventricles and discharge of both arytenoid cartilages, took place; but there were no evidences of inflammatory or ulcerative action below the glottis. The cricoid cartilage and all the cartilaginous rings of the trachea were of a deep modena-red color, from absolute deposit of pigment, as determined by Dr. Shakespeare, of Philadelphia, under microscopic inspection.

Ulcerative action, once well advanced in the laryngitis of phthisis, is exceedingly intolerant of attempts at control. It is soon accompanied by infiltration into the tissues, and is apt to surmount the laryngeal wall, posteriorly or laterally. It then interferes with freedom of respiration, presents an impediment to deglutition, and a provocation to vomiting; conditions of affairs which grow steadily from bad to worse, until finally it becomes impossible to nourish the patient by the stomach, or even to quench his thirst. Almost every particle attempted to be swallowed is regurgitated with violence, sometimes passing into the larynx, sometimes into the nostrils, sometimes in both directions at once, producing intense spasmodic parox-

ysms of cough, dyspnœa, and painful stridor, so that the pangs of hunger and of thirst will be endured as long as possible before temporary alleviation is again purchased at the expense of a repetition of the dreaded paroxysms. The distress is so intense that the often too tardy approach of inevitable death is awaited with bitter satisfaction, and, if consciousness remains to the last, it is with a sigh of relief that the patient expires.

After the larynx is in this ulcerated and swollen condition, but little can be seen of its interior in many instances (Figs. 120, 121); and the enlarged area of the arytenoid and supra-arytenoid regions, the cartilages of which are probably undergoing caries, necrosis, or exfoliation, the swollen folds forming

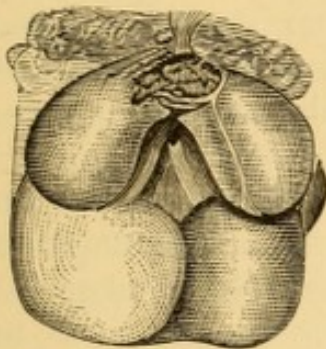


FIG. 120.—Edema of larynx in tuberculous phthisis, with central ulceration of lingual face of epiglottis and linear cicatrix, marking previous ulceration of its free edge.

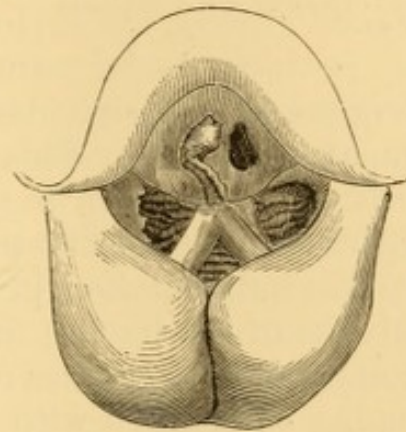


FIG. 121.—Edema of larynx with ulceration, in the latter stage of phthisis. (The patient perished suddenly from suffocation, because tracheotomy had been declined.)

the lateral walls, and other œdematous structures are so overlaid with mucus, pus, and detritus that no definite idea can be obtained of their condition, other than of the general nature of the impediment which they present to respiration and deglutition. The ulcerative action may destroy the vocal cords and other free structures, finally reaching the laryngeal skeleton; and necrosis and discharge of the laryngeal cartilages are apt to follow, if the patient survives long enough for the necessary changes to take place.

Ulceration of the posterior wall of the pharynx, the mucous membrane of the lips, cheek, palate, and tongue also occurs in some cases at a comparatively advanced stage of the affection. Sometimes cicatrizations are seen marking the seat of previous ulceration upon the soft and hard palate and on the pharynx.

I have likewise seen these ulcerations of mouth and pharynx in pneumonic phthisis, unassociated with involvement of the larynx.

The structures undergoing destructive ulceration are not the same in all cases. There is marked and contrasting immunity, sometimes, of some special structure, as the epiglottis or the vocal cords, while there is general destruction of others. The epiglottis may become destroyed to a mere irregular stump in some cases (Fig. 122). It undergoes irregular perforation, or extensive ulceration at its base, in others. In some it is not attacked. Though usually attacked from below, where there is an accumulation of glandular structure, it sometimes

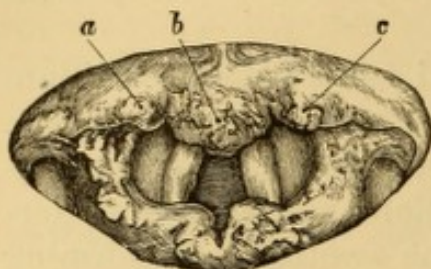


FIG. 122.—Extensive destruction of epiglottis (Tuerck). *a, b, c*, Remnants of epiglottis.

undergoes progressive destruction from its tip, as is more frequent in syphilis. This is quite apt to occur if the tuberculosis takes place in a syphilitic subject, but occurs also independently of specific taint.

As the inflammation progresses in the larynx, the mucous membrane of the trachea undergoes chronic inflammation, the mucous glands sometimes remaining unaffected, and sometimes becoming surcharged with retained secretion that has undergone fatty degeneration. Many of these masses are eventually discharged by ulcerative process, leaving numerous follicular ulcers, some of which coalesce into larger ones of irregular outline, with sharp edges and foul bottoms. These progressively involve the submucous connective tissue and perichondrium, denuding the cartilages to a variable extent, so that they are destroyed in detritus, or in smaller or larger fragments, which are exfoliated and sometimes expectorated.

In some cases there is a marked tendency to suppurative chondritis or perichondritis of the cartilages, rarely set up as a primary process, but usually resulting from extension of disease in the soft tissues. This is the laryngeal phthisis of the earlier authorities. These cases are particularized by the great extent to which the cartilages are involved, denuded, destroyed, and discharged. In exceptional cases the perichondritis is not suppurative. In some it proceeds to the formation of abscess, upon the spontaneous or surgical evacuation

of which the morbid action subsides promptly, as in phlegmonous abscess of the tonsil or pharynx. The abscess formed during these processes may point inward to the interior of the larynx, externally into the pharynx, or outwardly to the cutaneous surface, according to the position of the part chiefly implicated. The larger cartilages usually undergo disintegration, and are discharged in *débris* or in fragments. The arytenoids are sometimes discharged in mass, and even the necrosed cricoid has been expectorated in one piece. All the cartilages are liable to this perichondritis, the arytenoid cartilages especially, and the cricoid, and thyroid also, less frequently. As the arytenoid cartilages are the levers by which the vocal cords are moved, the free outward and inward motion of these structures is impeded by tumefaction, thus impairing the voice; and complete aphonia usually ensues on their destruction. Aphonia is not a necessary result of loss of the arytenoid cartilages, as inflammatory adhesions may weld the vocal cords, as it were, to the mucous membrane, which then, with an intervening deposit of organized products of infiltration, answers the purpose of an imperfect cartilage. Involvement of the arytenoid cartilage is recognized laryngoscopically by the œdematous swelling of the parts (Fig. 123), usually associated with some point of ulceration in the inter-

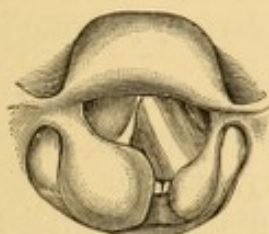


FIG. 123.—Perichondritis of arytenoid cartilage in tuberculosis. Ulceration in inter-arytenoid fold.

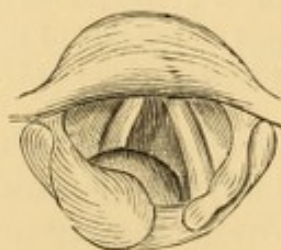


FIG. 124.—Abscess from perichondritis of arytenoid, projecting above the glottis.

arytenoid fold or in the parts beneath the glottis. The perichondritis of the arytenoid frequently leads to abscess at its base (Fig. 124), which is recognized by its supra-glottic position, and which frequently discharges at the junction of the vocal process with the vocal cord.

The cricoid cartilage suffers sometimes primarily and sometimes as an extension from the disease in the arytenoids. The condition is recognized laryngoscopically by a swollen or ulcerated appearance of the part, as the case may be, within the

larynx, either posteriorly and beneath the glottis, or else bulging between the vocal cords and underneath them, from one side or the other (Fig. 125).

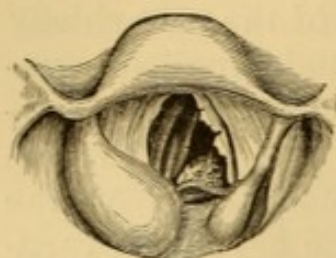


FIG. 125. — Perichondritis of right arytenoid and right side of cricoid cartilage, with necrosis of latter, and protrusion beneath the displaced vocal cord; ulceration of left vocal cord, and fungus vegetation in the interarytenoid fold.

The posterior segment is more frequently the seat of disease than the anterior portion. The abscess in this instance may discharge internally into the larynx, or externally into the pharynx. The necrosed cartilage may be broken into smaller or larger fragments, or be crumbled into detritus. It is grayish or brownish black in color; often quite ossified. It may be discharged in part, or even in whole, during life. Sometimes there is ankylosis of the crico-arytenoid articulation; but this

is generally believed to be rare.

The thyroid cartilage is most usually affected anteriorly, just below the vocal cords. Sometimes the disease extends from the cartilage or the internal perichondrium to the anterior perichondrium, and thence into the subcutaneous tissue, forming an abscess which may give rise to a fistule.

Rokitansky and others have recorded cases of cutaneous emphysema originating in this manner. Schroetter¹ has narrated a case of perichondritis, without ulceration, in a tuberculous child ten years of age, soon followed by subcutaneous emphysema of the side of the neck, and, at a later date, by pleuritic exudation on the same side of the body.

The epiglottis, when the seat of perichondritis, becomes irregularly swollen into a thick, ungainly pad, or fungus-like mass, often spongy on either side of a distinct whitish ridge, indicating the cartilaginous skeleton of the organ. It is usually bent upon itself, larger on one side than the other, and very often prevents a satisfactory view into the interior of the larynx; though usually some portion of the glottis can be exposed by some device or other, sufficient, at all events, to suggest an estimate of its condition. Sometimes the epiglottis is the only cartilage attacked; but more frequently the arytenoid, or at least the supra-arytenoid cartilages, are diseased likewise.

Perichondritis is usually attended with more or less chronic œdema or fibrinous infiltration into the tissues, liable to all

¹ Op. cit.; Wien, 1871, p. 60.

the changes and dangers of that condition. The inflammatory process may result in calcification or in ossification of portions of the cartilage, followed by necrosis and dislocation of fragments, which, becoming foreign bodies to all intents, attempt to make their way to the surface in the usual manner of dead bone. Fungus excrescences are developed at the orifices of the sinuses leading to the necrosed cartilages, similar to those which occur in connection with analogous sinuses leading from dead bone.

The disease progresses, if the patient lives long enough, until the diseased or dead cartilage is expelled; and then there is risk of suffocation during its expulsion. Sometimes the necrosed cartilage can be recognized laryngoscopically, its progress toward detachment watched, and even occasionally assisted by traction with forceps.

The cartilaginous rings of the trachea undergo similar processes in many cases, and are laid bare in fragments or in mass, which are sometimes expectorated.

In an instance under my own care¹ multiple minute and aggregated ecchondromata had become developed upon the central portions of the cartilaginous rings of the trachea, looking to the unaided eye much like caseous degeneration of miliary tubercles or mucous glands. The specimen has been deposited in the museum of the College of Physicians of Philadelphia. Osteomata have been discovered under similar circumstances.

Symptoms.—The subjective symptoms are those generally of chronic laryngitis (p. 482), associated sooner or later with the usual constitutional manifestations of phthisis. Pain in the larynx is not usually very great, nor is it severe upon external or internal manipulation of the organ, except when the posterior wall is prominently involved, when motion laterally will often be quite painful. Internal manipulation often provokes paroxysmal cough. In some cases there is severe pain, less apparently from the amount of ulcerative action going on, than from exposure of nerve filaments. When the epiglottis is ulcerated, pain running to the ears is often complained of, and is sometimes much more severe than that in the epiglottis itself, which is sometimes not at all painful even to the contact of the finger or instruments. Progressive ulceration of the epiglottis and posterior wall of the larynx entail dysphagia, and

¹ Trans. Path. So., Phila., Vol. IV., 1874, p. 144.

eventually aphagia, with escape of food into the air-passages, provocative of violent and exhausting paroxysms of cough. Œdema, submucous infiltration, and hypertrophies entail dyspnœa, which may become extreme.

Diagnosis.—The earliest diagnostic indication is marked pallor of the mucous membrane. Subsequently the peculiar semi-circumscribed pyriform tumefaction of the supra-arytenoidal extremity of the ary-epiglottic fold, often unilateral on the same side in which disorganization is progressing in the lung, is characteristic; as also are ruginous tumefaction and subsequent ulceration of the inter-arytenoid fold of tissue. Finally there is irregular ulceration in various portions of the larynx with chronic œdema of the free margin of the larynx or of the epiglottis, or of both, local accumulations of mucus and pus at projecting points, and fungous proliferations about the edges or beds of the ulcers. The aspect of these ulcerations is hardly sufficiently characteristic for differential diagnosis without reference to the cachexia; and in cases of tuberculosis in syphilitic subjects discrimination is often impossible, even by the test of treatment. Seen as the parts are in perspective and in profile, an adequate idea of the extent of ulceration in the posterior wall of the larynx in its infra-glottic portion, and in the trachea, is only approximative. In many tuberculous cases the progression of ulceration is from below upward; but this is far from being universal. Even the lingual surface of the epiglottis is sometimes the first structure to undergo ulceration. In syphilitic cases the progression is usually from above downward. If ulceration has taken place, corroborative evidences of the cachexia are usually manifest in auscultatory indications of disorganization in the lungs, and in the character of the sputa, while there are the usual subjective phenomena of constitutional phthisis. Perichondritis and chondritis are indicated by local tumefactions. In cases of doubt as to the involvement of arytenoid or cricoid cartilages, the location of the main swelling and of the resultant abscess, above the glottis or below it, indicate the discrimination respectively. The diagnosis of perichondritis is usually confirmed by pain and tenderness produced by external pressure upon the various portions of the larynx, and by gently moving it in mass from side to side.

Prognosis.—The prognosis is unfavorable as to life. It is

often favorable as to amelioration in the earlier stages, and even when there is moderate ulceration.

Phthisis, with laryngeal complications, is apt to be chronic, lasting from two or three to seven or eight years. It is almost invariably attended finally with extensive ulceration of the trachea, in parts often beyond the limits of laryngoscopic inspection—ulceration that may lead to perforation into the œsophagus. Ulceration of the bronchi leading from the pulmonary disorganizations is also frequent.

Whether tuberculous laryngitis be an independent disease, or dependent upon tuberculous disease in the lungs, the essential malady is the same; and pulmonary symptoms become developed sooner or later, either before the manifestation of the laryngeal ulcerations, or during their progress. There is strong reason for believing that tuberculization of the lung has already begun in all cases, and that in doubtful ones its progress is simply insufficient for physical demonstration. Many cases of pulmonary tuberculosis proceed to their fatal issue without any involvement of the larynx; but in many others, if their stages are completed, the larynx becomes implicated toward the close, if not earlier. When the larynx is seriously involved, the disease is rarely, if ever, curable, and is sometimes insusceptible of amelioration or relief. At times the laryngeal symptoms recede or subside for a while, local remedies seeming to repress the local manifestations or modify them; and when this is the case, it is usually evident, at the same time, that the pulmonary complications are progressing anew. Sometimes the pulmonary affection diminishes while that in the throat increases. At other times they advance together, in spite of the best-directed efforts. Occasionally the throat becomes healed without any advance in the disease of the lungs; and in rare instances the disease seems to be arrested in both localities. I have even known this improvement to be steadily maintained for a number of years, varying from between three and four to more than six, without any intercurrent manifestation of an advance in the affection.¹ Under my

¹ One young lady, from whom I removed the entire free portion of the epiglottis in 1872, after two years' ineffectual efforts to induce cicatrization of eroding ulcerations, and who had marked flattening of one infra-clavicular region, as well exhibited in a photograph in my possession, was still alive in 1878, and able to superintend her household.

own care, some very unpromising cases, of decidedly unfavorable prognosis, have improved steadily, much to my gratified surprise and almost against hope, under the use of cod-liver oil internally, inhalations of carbolic acid, and local applications of nitrate of silver. On the other hand, and what is more to the point, I have often signally failed in restraining the onward progress of destruction, in spite of all the aid that love or money could command, in cases apparently favorable for improvement, and where there was every reason to hope for it, from family history, physical condition, integrity of digestive powers, and ability and willingness to second in every way the efforts of the physician.

Treatment.—Constitutional treatment is of paramount importance. The hygienic surroundings of the patient, as to temperature, clothing, diet, occupation, facilities for judicious exercise, ample rest of part and body, and freedom from anxiety of all kinds, should be of the most favorable character attainable. The healthy functions of the skin should be promoted by frequent ablutions or baths, as may be most suitable. A full amount of healthful sleep should be secured at regular hours. The integrity of the digestive functions should be maintained, to the exclusion of all other treatment, if necessary. The most nutritious food that can be digested should be eaten, including, as additional food, the daily use of cod-liver oil. It will be found that oftentimes cod-liver oil is best borne about three hours or so after a meal, or just about the close of stomachic digestion. Emulsions with acacia and with extract of malt are often tolerated better than the oil alone. Infusion of wild cherry, solutions of bromide of potassium, salts of lime and so on, may be combined with the oil in emulsion when indicated. If necessary, the oil may be alcoholized, etherized, or otherwise made palatable. Sometimes it will be found to be taken better by warming the tablespoon. A tablespoonful morning and evening is usually sufficient. If it provokes nausea or loss of appetite, it must be abandoned. Under these circumstances the pancreatic emulsion may be employed, care being taken to secure a reliable preparation. When there is difficulty in digesting animal food, pepsin is indicated at meals, and this is sometimes advantageously combined with pancreatin, hydrochloric and lactic acid. When there is difficulty in digesting farinaceous food, diastase

is indicated in like manner, and this may be administered in the form of malted barley or fluid extract of malt, care being taken to secure a reliable preparation, as recently manufactured as possible, because the diastase is a very unstable product. The extract of malt may be eaten from a spoon, be spread upon bread or cracker, or be stirred into water, milk, or wine. From one to four ounces may be taken daily with advantage. The desirability of incorporating various medicinal ingredients with the malt is of questionable utility. It should be used rather as an article of diet than a remedial drug. Artificial koumiss is useful in some instances where fresh milk disturbs the digestion.

Quinia is often administered as a tonic, the usual practice being to associate iron with it; but it is often preferable to administer the quinia or some other product of cinchona alone, and to depend upon suitable food for the introduction of iron.

The constitutional treatment, therefore, is exactly that most suitable for pulmonary tuberculosis.

Local treatment is also requisite; and although not curative by any means, it is almost always indispensable as a means of relief, especially if there is ulceration.

Nitrate of silver is a good local remedy, but tannin is better in some instances. A saturated solution of tannin in glycerine or ether may be applied by sponge, cotton wad, or hair pencil. Solutions of it in water, too, are often used. Powdered tannin may be propelled upon the parts from an insufflator, or be directly applied by the sponge.

Iodine in compound solution is useful as a topical application in many instances. So, too, is iodoform, in powder, or mingled with tannin, or in solution in ether (one drachm to fifteen or more), or in chloroform. Morphia and other preparations of opium are judiciously combined with the other remedies in local applications to relieve pain or suppress irritability.

The spray of tepid water, impregnated with good cologne-water or toilet vinegar, a few drops to the ounce, will often prove grateful to the parts, while facilitating dislodgment of the products of secretion. When secretion is abundant and tenacious, excellent results often follow inhalations of solutions of the carbonates of sodium or potassium (one to ten or more grains to the ounce); when it is excessive or unpleasant

in odor, much benefit follows the use of carbolic acid (a grain or two to the ounce), to which a few drops of the compound solution of iodine may often be added with advantage. In a few instances I have seen this combination apparently arrest the progressive course of confirmed phthisis with ulcerative laryngitis, and permit the resumption of the patient's ordinary employments, where no such result had been anticipated. In other respects the local treatment is that for chronic laryngitis in general. The harassing cough due to accessible points of ulceration is sometimes markedly relieved by insufflations of morphia (one-eighth to one-half grain), once or twice a day. In some cases a tuberculous condition of the entire trachea often coexists, which cannot be reached otherwise than in general medication of the upper air-passages by injection, insufflation, or inhalation.

Due supplies of fresh air are very desirable, and an equable temperature likewise. The patient should be encouraged to go out into the open air every day for two or three hours, whenever strength and weather permit, and when at home should occupy an apartment kept at a temperature approaching 70° F., as determined by the thermometer, care being taken that the air does not become too dry, and that efficient ventilation is maintained without exposure to direct draught.

Too often, alas, the march of the disease to its fatal termination cannot be restrained, and all that can be done is to meet the progressive needs of the case as best may be, and soothe the path to the grave by every available means.

Tracheotomy has been recommended in certain cases of tuberculous laryngitis, simply as a means of securing rest to the inflamed larynx; and the operation has sometimes been followed by such a result. It cannot be curative, however, directly or indirectly, and is therefore only justifiable to ward off asphyxia from œdema, tumefaction, or impaction of necrosed cartilage. This being done, a renewed tenure of existence is sometimes secured for a few weeks or a few months, occasionally for a few years. Six months has been the longest prolongation of life in my own practice. Dr. Serkowski¹ has performed tracheotomy for tuberculosis of the larynx with unusual success in two instances. One of the patients, a female,

¹ (Przegląd Lekarski, No. 13, 1877; Allg. med.-chir. Ztg., Aug. 15.) London Med. Recd., Feb. 15, 1878, p. 73.

wore the canula for two years, and was still living at the end of seven years. The other one died at the end of three years, and post-mortem examination showed far-advanced phthisis. In cases of considerable infiltration into the tissues, whether serous or fibrinous, death may become imminent from asphyxia, and tracheotomy is then indicated to avert it. Some cases undergo marked improvement as soon as access of atmospheric air to the lungs is secured by the artificial opening. The tube is to be worn until there is ample laryngoscopic evidence that it has become superfluous. In cases of serous œdema threatening suffocation, absorption takes place more or less promptly, but there is great risk to life in awaiting it, and therefore tracheotomy appears justifiable even in serous œdema, if scarification has proved inefficient.

The process of exfoliation of necrosed cartilage is usually very painful, on account of the pressure of the sharp and irregular edges of the cartilage upon the inflamed superposed mucous membrane, provoking frequent spasms of cough from the well-nigh constant titillation of the parts, and often producing great pain in swallowing. Nourishment must be administered by enema, and anodynes be inserted hypodermically. Ice and fruit-juice (oranges, lemons, etc.) may be retained in the mouth from time to time to allay thirst; and, for a similar purpose, frequent sponging of the entire cutaneous surface may be resorted to; while anodyne inhalations and insufflations soothe the inflamed tissues by their topical influence.

Should symptoms of dyspnœa be seen to be due to impaction of cartilage, unfavorably disposed for extraction by forceps, tracheotomy is demanded to insure the safety of the patient. After discharge of the offending cartilage, the local and general condition of the patient improve at once, especially if no necrosis be going on elsewhere; so that he seems for a time to have gained a fresh lease of life. With exceptions so rare that their existence may almost be doubted, the disease is inevitably and progressively fatal; and after death, evidences exist of extensive involvement of the rings of the trachea, portions of which have not unfrequently been detached and expectorated during life.

Recovery, however, occasionally occurs in undoubted cases of perichondritis, even when there has been discharge of dead cartilage.

SYPHILITIC LARYNGITIS.

Syphilitic laryngitis (see also Syphilitic Sore Throat, p. 119) may be simply catarrhal, or it may be ulcerative. The ulceration may be superficial or deep-seated. Deep-seated ulceration may be associated with perichondritis from extension of the process commencing in the perichondrium, or, as is more likely, with secondary perichondritis from extension of the process commencing in the mucous membrane. It may be associated with gummata, which have undergone disintegration beneath the mucous membrane.

The distinctive characteristics of secondary and tertiary syphilis cannot be accurately recognized in the larynx. Laryngitis occurring within a few weeks or a few months of infection is presumably secondary. Specific manifestations appearing for the first time a number of years after infection, must be regarded as tertiary. Mucous patches are sometimes seen in the larynx in secondary syphilis, and some observers hold the opinion that superficial ulceration is always due to them; but many laryngoscopists have never recognized them in this locality. They are described with the usual characteristics of mucous patches in the mouth. The primary laryngitis of constitutional syphilis, if excited by exposure to change of temperature, presents the same erythematous appearance as ordinary catarrhal laryngitis. More frequently it commences slowly, in a manner similar to ordinary chronic laryngitis. Superficial ulceration is much more liable to occur than in simple chronic laryngitis; and it is in this stage that most of the cases are presented for laryngoscopic examination. These ulcerations are irregularly covered, in some instances, with granulations varying in size from a pin-head to a pea; and these are liable to increase of growth even after cicatrization of the ulcer. There is nothing specific in their formation or in their appearance. They may enlarge to such an extent as to demand operative interference.

Deep ulceration is almost always evidence of tertiary stages, and is rarely met with until a number of years, five or more usually, after the primary infection. Sometimes it is still more tardy, not occurring until after ten, twenty, or even thirty years.¹

¹ Tuerck : Op. cit.

The parts most liable to ulceration in syphilitic laryngitis are the epiglottis, its anterior surface and free border most frequently, the supra-arytenoid eminences, the ventricular bands, and the vocal cords. The infra-glottic portion of the larynx is usually attacked subsequently, and finally the trachea. Ulceration of the interior of the larynx may precede ulceration of the epiglottis, or occur independently.

There are often several ulcers at different portions of the larynx, and not at all confined to one side; indeed symmetric arrangement is much more frequent than in tuberculosis, and is even regarded to some extent as characteristic. There is even a symmetric outline to the individual patches in many instances. The specific ulceration extends deeply and widely; in the one instance producing destruction of the cartilages, and, in the other, denudations of such large extent of surface that in the cicatrization of the soft tissues the calibre of the laryngeal cavity is considerably diminished, to such an extent, in some instances, as seriously to compromise respiration. The epiglottis undergoes progressive destruction. The other cartilages are eaten out of their investments, as it were; that is to say, ulceration extends into the cartilage, and, if a small one, surrounds it, or, if it be a large one, circumscribes a portion of it, which perishes by necrosis, is laid bare, and becomes detached from its connections, remaining, in some instances, entangled in a sort of pocket scooped out of the soft tissues. The necrosed cartilage finally breaks through to the interior, and is discharged by cough, but, if it be situated below the glottis, it may induce paroxysms of suffocation, or actual asphyxia from its presence as a foreign body. The arytenoid cartilages and the cricoid are most apt to produce this complication, though occasionally it is effected by exfoliation of part of the thyroid. Sometimes the inflammatory process begins in the external perichondrium, and the resulting abscess ruptures externally, so that the necrosed cartilage is removed in that way. Occasionally it is discharged in crumbling masses or detritus. The epiglottis, though sometimes attacked on its laryngeal face, more frequently undergoes progressive destruction from the side; the diseased process being directed that way, perhaps, in consequence of the direct lateral connections of the epiglottis with the pharynx, which has most likely been involved in the first instance. In many instances the entire epiglottis is de-

stroyed, so that a mere stump remains to represent the organ. This, however, does not prevent deglutition, and sometimes does not even interfere with it.

Gummata are formed in the larynx in tertiary syphilis. They appear as grayish or yellowish globular projections, with broad bases, and covered by unbroken mucous membrane, more or less coated with mucus or pus, and vary in volume from a millet-seed to that of a hazel-nut. They are often single, but sometimes multiple (Fig. 126). They occur on the epiglottis or in any portion of the larynx, not unfrequently in the inter-arytenoid fold (Fig. 127), and have been seen even in the

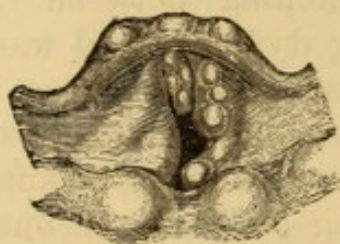


FIG. 126.—Multiple gummata (Mandl).

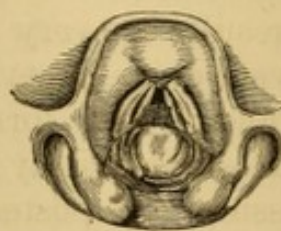


FIG. 127.—Gumma on inter-arytenoid fold; necessitating tracheotomy on supervention of acute catarrhal laryngitis from exposure.

trachea. They usually undergo disintegration, and ulcerate through the mucous membrane, though this may not occur for a long time. When interfering with the glottis, they may occasion dyspnœa, and this may be so great at times as to require tracheotomy, especially during intercurrent acute, or sub-acute catarrhal inflammation.

The result of the chondritis or perichondritis, whether preceding or following syphilitic ulceration of the mucous membrane, is to produce more or less fibrinous infiltration in the adjacent submucous tissue, giving rise to a condition which may be regarded as a sort of chronic œdema. This, if extensive, occasions suffocative symptoms, and may threaten asphyxia. Sometimes blood-vessels are opened by the ulcerative process, and hemorrhage follows, which may terminate fatally.¹ The trachea becomes involved in the ulcerative action; portions of its cartilages undergo necrosis and are expectorated; while extensive ulcers are formed, the cicatrization of which produces constriction or stenosis of the windpipe, which, when low down, is often beyond relief, even from tracheotomy; the

¹ For example see Tuerck: *Op. cit.*, p. 413, illustrated.

parts not being adapted for improvement from artificial dilatation.

Sometimes the submucous infiltrations become organized and transformed into dense fibrous tissues incapable of undergoing absorption, thus eventuating in permanent deformity and constriction of the larynx. This contraction of the calibre of the tube—technically termed stenosis—even when attended to early, does not often yield to systematic dilatation, but rather necessitates resort to tracheotomy to secure artificial respiration below the seat of obstruction. The vocal cords may become adherent to one another, or may become united by a broad, fibrinous membrane stretching between them. These results are very serious, entailing dyspnœa and more or less dysphonia, or even aphonia, if at all extensive. The membranous web formed between the vocal cords usually unites them anteriorly for a variable distance from the anterior commissure, the posterior portion being crescentic in outline. In a case reported by Navratil the entire lengths of the cords were involved, the opening being central. It originates in the approximation of the raw surfaces of ulcerations, or even erosions, and the organization of the plasma thrown out from side to side. In one reported case,¹ the cords became united by membrane within six days; and in another² the anterior third united in fourteen days, and in six weeks the union of the cords was complete.³

As a result of ulceration and the development of granulation upon adjacent surfaces, adhesions of various parts take place not unfrequently, sometimes interfering seriously with the functions of deglutition, phonation, and sometimes even of respiration. Without detailing the various examples of this kind which may present themselves, mention may be made of depression of the epiglottis to one side or the other, preventing proper closure or complete erection of the valve; adhesions of the epiglottis to the lateral wall of the pharynx; adhesions of the ventricular band to the vocal cord below, preventing proper vibration of the cord, and thus producing often a shrill, weak, piping voice, and sometimes preventing closure of the glottis;

¹ Rossbach : *Langenbeck's Archives*, Vol. XIV.

² Sommerbrodt : *Berlin klin. Woch.*, Apl. 1, 1878; *London Med. Record*, May 15, 1878, p. 204.

³ Compare author's case in tuberculous laryngitis, p. 506.

adhesions anteriorly of the two vocal cords, of the two ventricular bands, of the inner mucous surfaces of the arytenoid cartilages, etc. Other results of chronic laryngitis are hypertrophy of mucous membrane, connective tissue, or muscular substance, varying in extent, locality, and interference with function. Then there may be muscular atrophy, and the development of morbid growths.

Symptoms.—These are the same as in chronic laryngitis, catarrhal or ulcerous, of the same grade. There is sometimes a peculiar odor from the secretions, which is suggestive of their specific character. The pain and dysphagia are less marked than in tuberculous laryngitis.

Diagnosis.—This is by no means easy in many instances. Even the ulcerative stage cannot be distinguished with certainty from other cachectic (tuberculous, carcinomatous) forms of chronic laryngitis by ocular inspection only, especially so in instances in which syphilis and tuberculosis coexist. The suspicious character of the history of the case, and the evidence of analogous disease elsewhere, will aid the diagnosis; and if this be correct, anti-syphilitic treatment will almost always prove it, unless the case has progressed beyond the susceptibility to cure. The general appearances of chronic laryngitis having been already discussed, some special points only require consideration. Syphilitic laryngitis is very often preceded by syphilitic inflammation of the palate, pharynx, tongue, mouth, or nasal passages, sometimes existing in a continuous manifestation, sometimes confined to one or more localities. In the extensive ulcerations that accompany tertiary syphilis, and which may attack any and every portion of the larynx, we sometimes notice deep, gnawed-like excavations, with undermined edges, more or less rounded in their visible outline, surrounded by an inflammatory areola, and covered with a grayish or grayish yellow lardaceous deposit; features which are almost always to be regarded as characteristic. The presence, too, of cicatrizations, marking the locality of earlier ulcers, is often presumptive evidence of syphilis, inasmuch as ulcerations of the larynx rarely heal during the active progress of tuberculosis or carcinoma. The tumefaction of the tissues in the immediate neighborhood of these ulcerations is apt to be of firmer consistence, or more indurated than the analogous swellings of tuberculosis; and there is not apt to be as abun-

dant secretion of mucus and pus. Syphilitic laryngitis is usually accompanied, in its earlier or later manifestations, with syphilitic inflammation of the hard and soft tissues of the mouth, palate, and pharynx, sometimes resulting in actual necrosis and discharge of the anterior portions of the underlying bony structure. In some instances, however, the syphilitic manifestations are limited to the larynx, even without involvement of the epiglottis or of the aryteno-epiglottic folds. Indeed, it may be confined to the interior, or even to one vocal cord.¹ Syphilitic laryngitis, too, is sometimes the only manifestation of secondary syphilis.

Prognosis.—This is much more favorable than in analogous conditions in tuberculosis, and depends chiefly upon the susceptibility of the case to the remedial influence of specific remedies. If there is extensive ulceration, especially when associated with infiltrations, hypertrophies, and involvement of cartilages, permanent constriction of the calibre of the tube may be apprehended in cicatrization, in some instances to such an extent as to require the permanent retention of a tracheotomy-tube below the point of constriction. In similar involvements of the trachea too low down for tracheotomy, the extensive stenosis is beyond relief, and necessarily fatal. Stenosis from extensive hyperchondrosis of the thyroid cartilage has been overcome by Prof. Heine, of Prague, by sub-perichondrial dissection of the anterior halves of the two sides respectively, and their extraction by forceps.

Treatment.—In its catarrhal or secondary ulcerative manifestations, the treatment of syphilitic laryngitis differs little from that of ordinary laryngitis, except that secondary ulcerations, if evincing no signs of retrogression, indicate the propriety of mercurialization. In tertiary forms, however, before the ravages of the disease have entailed irreparable destruction, its progress can be promptly arrested, in many instances, by the internal use of the iodide of potassium and the bichloride of mercury, and the local application of acid nitrate of mercury, diluted in from four to ten parts of water. The cauterization need not be repeated oftener than every third or second day. Strong solutions of nitrate of silver and of the

¹ Post-mortem evidence. J. Wm. White; Phila. Med. Times, June 28, 1873, p. 61.

mineral acids are also efficient; but not more so than the acid nitrate of mercury, and often much less so. Some surgeons rely on local applications of tincture of iodine, or of iodoform.

The general treatment, systemic or local, is that for chronic laryngitis in general. Alum, sulphates of zinc and of copper, though useful in catarrhal inflammations, are much less so in ulcerative conditions. Local relief in cases of extensive ulcerative œdema and the like is the same as in analogous conditions in tuberculosis. Isambert extols the local use of chromic acid (one part in from five to eight of water). Other surgeons prefer chloride of zinc and sulphate of copper; and some destroy the unhealthy surfaces with the point of the galvano-cautery, to excite healthy and reparative inflammation below.

Membranous webs, occluding the glottis from side to side, are divided by incision or by galvano-cautery, the edges cauterized, and readherence prevented, if possible, by frequent introduction of dilating sounds. These laryngoscopic operations are often rendered futile by insurmountable tendency to recicatrization, whereby the morbid condition is reproduced. Success in cases of this kind would seem to require exposure of the interior of the larynx by external division of the thyroid cartilage, and excision of the whole of the cicatricial tissue.¹

When syphilitic laryngitis has existed for a long time, such an amount of destruction may have taken place, and such a degree of systemic poisoning, as to render recovery impossible. The constrictions produced by the cicatrices of extensive ulcers, and the adhesions between adjoining surfaces, in cases that recover, are often such as to render tracheotomy necessary, with the permanent use of the tube; for the constrictions following syphilis are not, as a rule, amenable to dilatation.

Threatened asphyxia or unconquerable dyspnœa, from gummy tumor, loose cartilage, morbid growth, abscess, or œdema, may necessitate tracheotomy. Tracheotomy for the purpose of conquering dyspnœa due to tumefactions in the larynx is perfectly justifiable, and usually successful. It is likewise justifiable for the mere purpose of securing rest to the organ—much more so, indeed, than in analogous conditions attending tuberculosis.

¹ For an interesting case in which external section of the thyroid cartilage was performed in order to divide the web, see Mackenzie: *Med. Times and Gaz.* Aug. 19, 1871, p. 218.

The treatment for local adhesions consists in relieving the tension as far as possible by laryngoscopic division of the constricting bands of tissue, and then cauterizing and re-cauterizing the adjacent surfaces, to prevent fresh adhesions. These cases require careful watching and prompt attention to overcome the disposition to recurrence, which is very apt to take place in spite of all efforts. When the epiglottis is implicated, much good can be done by teaching the patient to move the organ frequently by means of his forefinger.

In a case of stenosis due to "concentric hyperchondrosis" as a result of the hyperplastic chondro-perichondritis, Prof. Heine¹ performed a successful resection of the anterior portion of the thyroid cartilage, splitting that structure in the middle line, separating the perichondrium and superjacent soft tissues, to the distance of one-half its surface on the two sides, with the elevator, and then removing the denuded portions by longitudinal section with bone forceps. The patient rallied so well from the operation that an artificial vocal apparatus could be substituted for the ordinary canula on the fifth day. He became able to resume work after a while; but the disease made new inroads, and he died, eleven months later, in an advanced stage of tuberculosis.

PRIMARY CHONDRITIS AND PERICHONDRITIS.

This is a chronic inflammatory process, commencing in the cartilage itself, or, as is more frequent, in its investing perichondrium. It occurs most frequently in tuberculosis, but also in syphilis, carcinoma, typhoid fever, small-pox, and other systemic diseases. It likewise follows traumatic injuries.² Sometimes, too, it occurs idiopathically, independently of any diathesis or local injury,³ apparently from exposure to cold and wet, or from over-straining of the voice (idiopathic laryngeal chondritis or perichondritis).

Primary chondritis commences in the cartilage by hyperæmia and tumefaction, accompanied by œdematous infiltration

¹ Arch. klin. Chir., Bd. XIX., 1876, p. 514

² Ziemssen has seen it produced in the ossified cricoid cartilage of an aged subject, from frequent introduction of the œsophageal sound. Cyclopædia, N. Y. Ed., VII., p. 816.

³ Tuerck, Gibb, Schroetter, Ziemssen.

of the superjacent soft tissues; and it is usually followed by supuration beneath the perichondrium, which becomes detached from the cartilage while the latter undergoes necrosis. An abscess is formed, which projects within the larynx or outside of it, in some instances remaining unbroken, in others destroying the perichondrium and superjacent tissues, and discharging into the larynx or the pharynx, as the case may be. The larger cartilages may be destroyed and discharged in fragments; the smaller ones in detritus, fragments, or in mass. The arytenoid cartilages are often discharged in one piece; and this may even take place with the cricoid.¹ In a case of chondritis of the cricoid cartilage in which I performed tracheotomy, and subsequently opened intra-laryngeal abscesses laryngoscopically, there was apparently a reproduction of this cartilage, the original one remaining necrosed in the cricoidal portion of the interior of the larynx, as a foreign body.²

I had performed tracheotomy for a friend in a case of extensive laryngeal œdema attendant upon phthisis, and attributed by me at the time to chondritis or perichondritis of the two arytenoid cartilages; and subsequently I incised an abscess at the base of each arytenoid cartilage. The larynx healed, but dilatation of the glottis remained impracticable. Death occurred from pyæmia, just six months after the tracheotomy. On the post-mortem examination the mucous membrane was intact, save at the points where the abscesses had been discharged. Below the glottis, and encircled by the cricoid cartilage, there was found a foreign body, which the most careful examination by anatomical experts failed to distinguish as resembling anything else than a portion of the ossified cricoid cartilage; but, as there was a cricoid cartilage in the natural position, and apparently unchanged by any loss of tissue, I was led to the supposition that there had been suppurative chondritis, with exfoliation of the original cricoid cartilage, and subsequent reproduction of a second one from the perichondrium. The specimen was deposited in the museum of the College of Physicians of Philadelphia.

The discharge of these abscesses may be followed by the establishment of fistulæ. Extensive emphysema may take place through a fistula of this kind.³

The disease is usually fatal. Recovery may take place both in cases in which there has been no necrosis of cartilage,

¹ Ruehle: *Op. cit.*, p. 175.

² *Trans. Path. Soc., Phila.*, 1874, p. 148. Specimen deposited in museum of College of Physicians, Philadelphia.

³ Wilks: *Trans. Path. Soc., London*, 1858, p. 34; Tuerck: *Op. cit.*, p. 209; Ziemssen: *Loc. cit.*, p. 827.

and those in which portions of dead cartilage have been discharged.

Primary perichondritis commences in the perichondrium, which undergoes suppurative and destructive inflammation, exposing the cartilage, which, in its turn, is subjected to degenerative inflammation and necrosis. The cricoid cartilage is attacked more frequently than the arytenoids, and these more frequently than the thyroid. The process may go on simultaneously in two or more cartilages.

External chondritis or perichondritis of the larynx, terminating in suppuration externally, occasionally occurs independently of any disease of the mucous membrane. Dr. Gibb¹ has related a remarkable instance affecting one wing of the thyroid cartilage, in which an abscess formed externally, yielding blue pus on incision. There was no evidence of disease in the interior of the larynx. The patient recovered promptly.

The chondritis and perichondritis of tuberculosis and syphilis having been discussed (pp. 508, 520), it remains to refer to the affection as it occurs in typhoid fever at a period varying from the second week to the establishment of convalescence. The cricoid and the arytenoid cartilages are most frequently involved; the latter occasionally primarily, it is maintained, but usually as an extension of ulcerative processes from the intralaryngeal surface of the posterior wall of the larynx, beginning in the glands of the meso-arytenoid fold or in those at the base of the cartilage. It may commence in suppurative inflammation and abscess of the submucous connective tissue. The posterior vocal process is a frequent point for discharge of the abscess. The posterior surface of the cricoid cartilage is often the earliest point of attack, both as a result of gravitation in the recumbent position, it is alleged, and its frequent subjection to compression during deglutition, the process being similar to that occasioning bed-sores from pressure over osseous prominences.

Symptoms.—The earlier symptoms are not characteristic. There is usually some hoarseness with local pain, especially on movement or pressure externally, and sometimes in deglutition or in phonation. Hoarseness, cough, and dysphagia are manifested later; then dyspnoea, perhaps with stridor or with

¹ Brit. Med. Jour., Dec. 13, 1873, p. 684.

paroxysmal suffocative spasms; and finally stenosis. When the abscess is discharged, there is expectoration of pus, usually with more or less subsidence of the local distress. In the later stages the symptoms are the same as in the chondritis and perichondritis of tuberculosis.

Diagnosis.—In the laryngoscopic mirror the abscess in perichondritis of the cricoid is seen to project from one side of the larynx as a tumid fold (Fig. 128) below the glottis. If the arytenoid cartilage is involved, the abscess will point above the

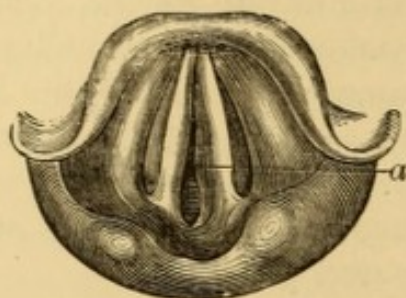

FIG. 128.—Primary perichondritis of cricoid cartilage, abscess unopened. Anchylosis of left arytenoid (Tuerck). *a*, Inner wall of abscess. Appearance day before death from pneumonia, in a case of less than three months' duration, and in which the initial cause for the perichondritis could not be made out in the post-mortem examination.

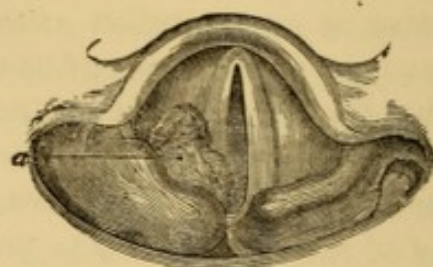


FIG. 129.—Perichondritis of cricoid, with loss of right arytenoid, in a case of typhoid fever (Tuerck). *a*, Wall of abscess.

glottis, as it often does also when cricoid and arytenoid are both involved (Fig. 129). There are indications of chronic inflammation, with more or less tumefaction and infiltration of tissues; and in disease of the arytenoids there is lack of movement of the vocal cords, from local infiltration or from partial or complete anchylosis of the crico-arytenoid articulation. It is often difficult to estimate the actual amount of destruction, even when inspection of the larynx is not much impeded by swelling; post-mortem examination often showing much more than had been surmised from laryngoscopic inspection.¹

In perichondritis of the thyroid cartilage, the abscess could only be seen beneath the vocal cords. If affecting the exterior of the larynx there is more or less tumefaction, eventually affording evidence of fluctuation.

Incisions into the abscesses, whether external to the laryngeal tube or in its interior, will afford vent to pus. The locality of pain, spontaneous or excited by pressure, will also indicate the cartilage affected.

¹ For examples with illustrations, see Tuerck: *Op. cit.*, p. 217.

Prognosis.—This is unfavorable in the majority of instances.

Treatment.—This is the same as for perichondritis in tuberculosis—due sustenance of the patient, with the use of tonics and stimulants, early discharge of the abscess by incision, and tracheotomy to avert suffocation from stenosis or from impaction of fragments of necrosed cartilage; tracheotomy being always preferable to any form of laryngotomy as being at a distance from the seat of active disease and its products, such as peri-laryngeal and intra-laryngeal accumulations of pus and disintegrated cartilage, the presence of which may embarrass the operation at the same level, or even interfere with its completion.

LUPUS.

Lupus of the larynx has been occasionally detected, chiefly confined to the supra-glottic structures. A few cases have been reported by Tuerck,¹ Tobold,² Ziemssen,³ Grossman,⁴ Leferts⁵ and Beringier,⁶ respectively; and it is probable that other examples have escaped recognition. Nearly all the cases recorded were in females, and in all save one there were cutaneous manifestations of lupus, suggestive or corroborative of the nature of the disease in the larynx. Tuerck's male patient, forty-five years of age, presented the physical evidences of lupus of the larynx (Fig. 130) sixteen years after he had had primary chancre, and three years after the total disappearance of recurrent lupus of the nose and lip, which first appeared eleven years after the syphilitic infection. Ziemssen's case⁷ (Fig. 131) is the only one in which there

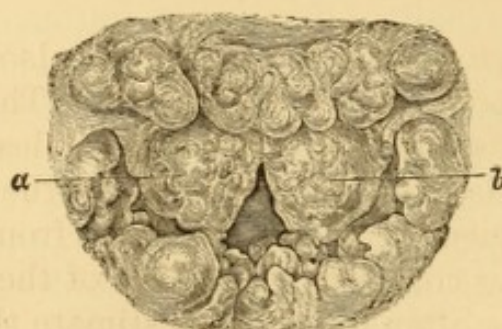


FIG. 130.—Lupus of the larynx (Tuerck).
a, b, Epiglottis.

¹ Op. cit., p. 425.

² Laryngoskopie und Kehlkopfkrankheiten, Berlin, 1874, p. 307.

³ Cyclopædia, N. Y. Ed., VII., p. 854.

⁴ Allg. Wien. med. Ztg., 1877, XX., p. 182.

⁵ Am. Jour. Med. Sci., Apl., 1878, p. 370.

⁶ Annales des maladies de l'oreille et du larynx, July, 1878.

⁷ Op. cit., p. 853.

were no cutaneous or other manifestations of the disease; the diagnosis having been based upon failure of protracted treatment by iodide of potassium, and arrest of progress under six months' use of cod-liver oil and strong cauterizations with fused

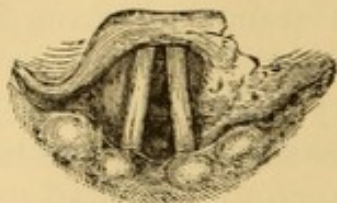


FIG. 131.—Lupus of larynx (Ziemssen).

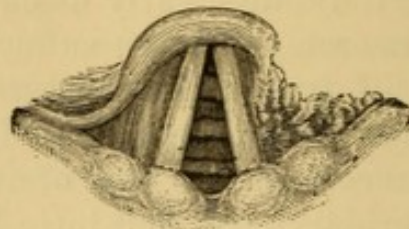


FIG. 132.—Syphilis of larynx (Ziemssen).

nitrate of silver. The similarity of the laryngoscopic image in this case to one of syphilitic ulceration, illustrated by the same observer¹ (Fig. 132), is very marked. Lefferts' case, a typical one, occurring in a female with extensive lupus of face and throat, of thirty-one years' standing, and commencing in the nose, is described as having borne greater resemblance to the physical appearances of tuberculous laryngitis than to those of either syphilis or carcinoma.

It is quite probable that the involvement of the larynx is usually a late manifestation of lupus, which has commenced in the nose or upper lip, and then extended along the mucous membrane of the nasal passages to the palate, pharynx, base of tongue, and epiglottis. The palate and pharynx undergo destructive ulceration and vicious cicatrization. The epiglottis becomes thick, indurated, and rigid, and undergoes destructive ulceration, similar, according to Tuerck, to that observed in cases of laryngeal syphilis and carcinoma. Hard nodules of hyperplastic tissue occur on the base of the tongue, epiglottis, or some portion of the interior of the larynx, as the case may be, analogous in aspect to the lupus nodules of the buccal and pharyngeal mucous membrane, and cutaneous surface.

Symptoms.—The symptoms are various degrees of dysphagia, dysphonia, and cough, according to the location of the disease and the amount of secretion. Pain appears to be exceptional.

Diagnosis.—This rests on the coexistence of external lupus. The disease may be mistaken for manifestations of syphilis, carcinoma, or tuberculosis.

¹ Ibid., p. 871.

Prognosis.—This is unfavorable.

Treatment.—The internal use of cod-liver oil has been of more benefit than any other treatment recorded. Local applications of nitrate of silver have produced apparent arrest of the progressive ulceration in a small proportion of instances, but are not well borne in all cases. The treatment, therefore, is to be instituted on general principles.

LEPRA.

The larynx is peculiarly affected in some cases of elephantiasis, with more or less catarrhal inflammation, deformity, and hypertrophy of some portions of the laryngeal structures, and destruction of tissue in others. These changes are accompanied in some instances by papillary nodules from a very minute size to that of peas. I have never had an opportunity of seeing the leprous larynx in the living subject. Gibb¹ mentions a peculiar shrillness of the voice, the production of which hardly appears to be accounted for in his description of the affection. Wolff,² who examined a number of cases in the island of Madeira, does not mention this peculiarity of voice. He speaks of a fatal constriction of the larynx, and also of œdema rapidly fatal; a condition which Norwegian physicians³ have often encountered. This affection is usually connected with a similar condition of tongue, mouth, and pharynx, and, according to the belief of Mackenzie,⁴ never attacks the mucous membrane until after it has manifested itself upon the cutaneous surface. It is often associated with extensive disease of the pharynx and nasal passages.

Lamblin⁵ describes the earlier laryngoscopic evidences as patches, followed by tubercles with interstitial thickenings, adhesions of parts, ulcerations, and necroses. Schroetter,⁶ who examined a number of lepers in Sweden and Norway, describes the laryngeal manifestations as small connective-tissue nodules

¹ Op. cit., p. 273.

² De lepra Arabum (Elephantiasis Græcorum), Virchow's Archiv, 1868, Bd. XXVI., p. 44.

³ Tuerck: Op. cit., p. 429.

⁴ Essay on Growths in the Larynx, London, 1871, p. 36.

⁵ Étude sur la lèpre tuberculeuse ou éléphantiasis des Grecs, Paris, 1871.

⁶ Laryngologische Mittheilungen, Wien, 1875, p. 85.

on the epiglottis, ary-epiglottic folds, or posterior wall of the larynx; or uniform thickenings at these points or over the entire larynx; the parts being simply thicker than normal in mild cases; while in severe cases, approximation of the sides of the epiglottis, and tumefaction of the ary-epiglottic folds diminish the free space of the vestibule of the larynx, or, when the disease extends further down, produce moderate stenosis of the larynx, the calibre in extreme cases being constricted to the bulk of a lead-pencil; and, in some instances, destruction of the morbid connective tissue ensues, with extensive ulceration.

A couple of illustrated laryngoscopic observations in lepra, recently reported from a clinical lecture by Dr. Elsberg, of New York,¹ one (Fig. 133) in the person of a young Cuban, and the other (Fig. 134) in a native of New York, for three years a

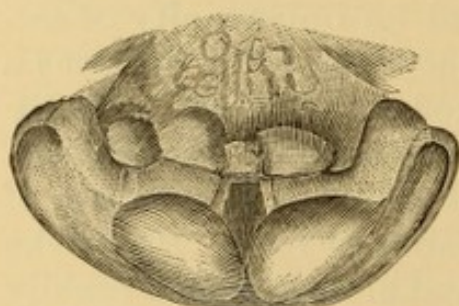


FIG. 133.—Appearance of larynx in leprosy (Elsberg).

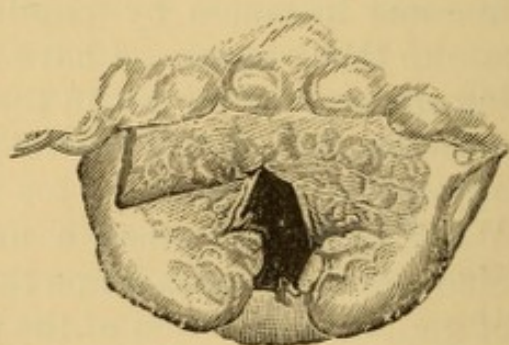


FIG. 134.—Appearance of larynx in leprosy (Elsberg).

resident of Cuba, show the characteristic deformities and irregular nodulation of the epiglottis and other laryngeal structures, which are certainly unlike the appearances presented in affections which come more frequently under notice.

Symptoms.—These are dysphonia, sometimes of a peculiar character, and liable to eventuate in aphonia; cough and expectoration of translucent sputa, finally sanguinolent; more or less anæsthesia of the parts, sometimes to a marked degree; then dyspnoea subsequently, perhaps permanent, and suffocative paroxysms. Pain is infrequent, and often there is no pain. Lamblin describes pain on pressure of the thyroid cartilage, and very fetid breath.

Diagnosis.—This depends chiefly on the external manifestations of lepra, and upon the characteristic thickenings and nodulations of the laryngeal structures.

¹ The Medical Record, N. Y., Jan. 4, 1879, p. 10, illustrated.

Prognosis.—This is unfavorable. Voice is usually permanently impaired.

Treatment.—Astringents and iodoform locally are said to be of service. Bromine and vegetable tonics internally, with astringents locally, strengthened the voice and improved the health of Gibb's patient, without influencing the general anæsthesia. Elsberg speaks of grateful effects from iodoform in ether; and mentions the use of gurjun-oil as highly praised in leprosy for both local and internal use. Stenoses often require tracheotomy, the beneficial effects of which, however, have no influence on the fatality of the disease.

HYPERTROPHY OF THE LARYNX.

I have seen one case of which I could make nothing but a condition of general hypertrophy. The symptoms were intense dyspnœa and stridor, which had gradually increased for some two years, and finally attended with aphagia a few days before my attendance was solicited. On laryngoscopic examination all the visible portions of the laryngeal structures were immensely thickened, so that a very small slit remained for breathing; but they were normal in color. The voice was muffled and weak. I performed tracheotomy on the day following, and inserted a tube, which the patient, a gentleman about seventy years of age, wore until his death, which occurred about one year later. After relief of dyspnœa by tracheotomy, considerable collateral tumefaction of the exterior of the larynx and of the surrounding connective tissue subsided, so that deglutition became practicable, and the patient gained greatly in strength, while his voice became clearer and stronger. The stenosis was not improved. The patient was dissuaded by his family from submitting to attempts for dilating the calibre of his larynx, being satisfied to wear his tube permanently. As he was under homœopathic treatment, except during the brief interval in which he was in charge to undergo tracheotomy and receive the necessary services arising in consequence, I am unable to describe the subsequent history of the case. After my attendance ceased, he resumed his homœopathic medication, and I had no opportunity of determining the nature of his malady, or of instituting a post-mortem examination.

MORBID GROWTHS OF THE LARYNX.

Laryngoscopy has revealed the unexpected fact that morbid growths are frequently developed in the larynx. Seventy cases, probably, would represent the entire ante-laryngoscopic record, while thousands have been recorded within the past twenty years of laryngoscopic investigation. The cause of this discrepancy seems to have been that the subjective symptoms excited by growths in the larynx are not such as to indicate the presence of a neoplasm, except in marked instances; while, in the customary laryngoscopic examinations in diseases of the throat, many tumors, or at least excrescences, are discovered whose existence would not have been inferred otherwise. The use of the laryngoscope, too, has led to better interpretation of these subjective symptoms, and it is not uncommon for the accomplished laryngoscopist to suspect the existence of a laryngeal neoplasm, by the voice and manner of the patient, before detecting it by laryngoscopic inspection. The far greater proportion of laryngeal neoplasms are benign, and remain benign. Some growths are malignant from their commencement, others become malignant, though benign originally.

It is sometimes difficult to trace the origin of these formations. Patients usually attribute them to "colds." They appear to take their departure, whatever be the predisposing cause, from catarrhs, syphilitic and tuberculous sore throat, erysipelas, the exanthemata—particularly measles, exudative inflammation of the larynx, whether croupous or diphtheritic, whooping-cough, and the inhalation of irritating substances, whether in solid or gaseous form. The tumors produced in syphilitic and tuberculous subjects, however, have rarely any characteristic features belonging to the special dyscrasia, save gummata, which some pathologists term syphiloma, and include among tumors.

Mackenzie refers laryngeal neoplasms to hyperæmia, and to catarrh as the most frequent cause of the hyperæmia.¹ His opinion is that neither syphilis nor phthisis, nor any other constitutional condition, appears to favor their growth; but that both these diathetic conditions apparently exercise a decidedly antagonistic influence to the development of new-formations. My own experience

¹ Essay on Growths in the Larynx, London, 1871. An elegant and classical work, worthy of close study.

favors a different conclusion. Apart from certain imperfect papillary growths which are developed on the intra-laryngeal mucous membrane in the latter stages of certain forms of phthisis, I have seen a great proportion of cases in which distinctly formed neoplasms, of circumscribed outline, and often of tolerably large size, existed in cases of phthisis at a comparatively early stage, as well as when the pulmonary ravages were evident on auscultation; and in some of these cases the danger of impending suffocation has been averted, and the voice improved or restored by intra-laryngeal interference. Tuerck has described a case of mucous polyp¹ of the left side (ventricular), the subject of which was found six years afterward far gone in pulmonary tuberculosis. From the illustration given of the post-mortem appearances, there could hardly be any suspicion as to the character of the case. It is not introduced by Tuerck in connection with the subject of tuberculosis; and tuberculization may have been merely coincidental. Prof. Gross² figures a marked case of fibrous pedunculated growth found in a man thirty-eight years of age, who finally died of tuberculous phthisis in a state of profound marasmus. The laryngoscopic picture of a pedunculated neoplasm upon a vocal cord, in a case of advanced phthisis, is presented farther on from one of my own cases.

With regard to syphilis, it is undoubtedly true that but few cases of syphilitic congestion of the larynx give rise to the formation of growths; but I cannot endorse the opinion that few laryngeal growths can be attributed to syphilis. In sixty-six cases occurring consecutively in my private practice, during a period of five years (1866-1871), eight cases were distinctly traced to syphilitic congestion of the laryngeal structures, and twenty-two cases occurred in patients with phthisis. It is but justice to Dr. Mackenzie to quote that he admits that "of course laryngeal growths may occur in syphilitic persons as they do in the healthy, but syphilis does not appear to be a factor in their production." Syphilis is a disease of such great influence upon physiological and pathological conditions generally, that it is not improper to refer all cases of growth in syphilitic individuals to that cause wherever there is anything like a clear history, or whenever there is other evidence of syphilitic disease; and to suspect a syphilitic origin whenever there is no other assignable cause, in a patient who has already suffered from syphilitic poisoning, especially if the remoter symptoms have been manifested in the throat.

Growths in the larynx appear at all ages. Some are congenital, others are developed in advanced life. My own experience includes cases apparently congenital, and one occurring at upward of eighty years. They are more frequent in males. Children acquire them at all ages. They have been oftenest observed in the adult between the twenty-fifth and forty-fifth year. They appear to be much more frequent in Europe than in America. Intra-laryngeal growths are occasionally associ-

¹ *Op. cit.*,

² *System of Surgery*, Philadelphia, 5th Ed., 1872, Vol. II., p. 293.

ated with neoplasms on the exterior surface of the larynx, and the latter sometimes occur independently of any intra-laryngeal tumors.

Nearly all the varieties of morbid growths known to pathology, benign and malignant, have been observed in the larynx, papilloma being the most frequent variety, and fibroma next. In Dr. Mackenzie's tabulated list of one hundred cases of benign laryngeal growths subjected to treatment,¹ sixty-seven were judged to be papillomata. Of the sixty-six consecutive cases of growth of all kinds, benign and malignant, noted by myself in 1871, forty-eight were known or inferred to be of that nature. The results of the observations of other laryngoscopists² in extensive practice do not differ materially from those of Dr Mackenzie.

Papillomatous growths are usually sessile and frequently multiple. Other formations are usually single. Exceptions, however, are not infrequent.³ Fibroma, simple and compound, myxoma, adenoma, cystoma, sarcoma, angioma, lipoma, epithelioma, and carcinoma have been found in the larynx by different observers. Laryngeal epithelioma is sometimes peculiar in developing papillary outgrowths rather than penetration into the interior of the structures. Many growths are composed of more than a single form of tissue. These neoplasms are liable to the usual degenerations. Cysts are rare, usually occupying the epiglottis. Another morbid growth is sometimes encountered in the shape of a web or membrane stretching from one vocal cord to the other, as already described as occurring in ulcerative laryngitis (p. 506). It is, however, occasionally congenital.⁴

The papillomatous growths, occurring in cases of phthisis, are apt to recur spontaneously. This does not appear to be the case in the absence of constitutional dyscrasia, though recurrence takes place in some instances. Malignant growths, as a matter of course, are exceedingly apt to recur.

Laryngeal neoplasms vary in size from the bulk of a small

¹ Op. cit.

² Fauvel reports 206 papillomas out of a total of 300.

³ See author's case of multiple myxoma, *Trans. Path. Soc., Phila., IV., 1873*, p. 151.

⁴ For examples, see Elsberg: *Trans. Am. Med. Assn., Phila., 1870*; Scheff (*Allg. Wien. med. Ztg.*, Nov. 28, 29, 1878); Leffert's Reports, *N. Y. Med. Jour.*, Oct., 1878.

seed to that of a mass sufficient almost to fill the laryngeal cavity, and project outside.

Morbid growths may occupy any portion of the larynx. Their most frequent seat is upon the vocal cords. Coyne's discovery of vascular papillæ on the edge of the vocal cords, and his detection of glands on their superior and inferior surfaces,¹ account, in part, for this proclivity. The constant motion of these structures might be supposed, on the one hand, to be antagonistic to the development of a growth, or, on the other, to keep up by this very activity a vascular supply of pabulum for its development, once the morbid action has become established. That the activity of the vocal cords is not antagonistic to the formation of morbid growths, is very evident. The anterior portions of the vocal cords, and, in fact, the anterior portions of the larynx generally, are much more frequent seats of morbid growths than the posterior portions.

The subjoined table, from the first edition of this volume, gives the nature and seat of the sixty-six consecutive cases of morbid growths in the larynx referred to :

Thirty-one Cases without apparent Constitutional Disturbance.

9 cases of papillomata (3 multiple)	on one vocal cord.
6 " " (2 ")	on both " cords.
3 " "	beneath " "
1 case "	on both " " and both ventricular bands.
1 " "	" " " " and posterior wall of larynx.
1 " "	" " " " and one arytenoid cartilage.
1 " "	in left ventricle.
2 cases "	on left aryteno-epiglottic fold.
3 " "	" epiglottis.
1 case "	" " and left aryteno-epiglottic fold.
1 " of fibroid polyp (pedunculated)	beneath one vocal cord.
2 cases of epithelioma	upon both vocal cords.

Twenty-two Cases associated with Phthisis.

4 cases of papilloma (3 multiple)	on one vocal cord.
3 " " (2 ")	" both " cords.
1 case "	" both ventricular bands, and posterior wall.
1 " "	" posterior wall of larynx.
1 " "	" " " " and both ventricles.
1 " "	" one ventricular band (left).
2 cases "	" epiglottis.
1 case fibroma	" one cord.
1 " epithelioma	" " "

¹ Recherches sur l'anatomie normale de la muqueuse larynge, Paris, 1874.

- 1 case of epithelioma on both cords and both ventricles.
- 1 " " " epiglottis, one vent. band, one vocal cord.
- 1 " trachoma " both vocal cords.
- 2 cases of cystoma (refilling in a few months) on both arytenoids.
- 2 " membranous bands on both cords, stretching from one to the other anteriorly.

Eight Cases associated with Syphilis.

- 4 cases of papilloma (1 multiple) on both vocal cords.
- 1 case " " one " cord.
- 1 " " " epiglottis, and both ventricular bands.
- 1 " " " " " " " " and both vocal cords.
- 1 " sarcoma (spindle-celled) " both ventricles, both arytenoid cartilages, and posterior wall of cricoid.

Five Cases of Malignant Growths.

- 1 case of fibro-sarcoma on one vocal cord.
- 1 " medullary carcinoma of epiglottis, and right ventricular band.
- 2 cases epithelial " of epiglottis.
- 1 case " " filling entire larynx.

Symptoms.—The general symptoms of a morbid growth in the larynx are much the same, whatever the nature of the neoplasm, varying with its location, size, character of attachment, and its interference with phonation, respiration, and deglutition. Some growths do not give rise to any special symptoms at all, and are accidentally, or rather unsuspectingly, discovered upon laryngoscopic examination to determine the cause of some apparently trifling obstinate affection.

The usual symptoms of laryngeal neoplasm, when large enough to interfere with function, or when situated upon an important part of the structures, are cough, dysphonia or aphonia, dyspnoea, dysphagia, and pain.

Cough is not a frequent symptom, unless the growth is contiguous to the glottis or encroaches upon it, or is of large size and movable, or vascular and apt to bleed. The cough may be dry and hacking, or moist and accompanied by expectoration of mucus, or mucus and blood, according to the nature of the growth and the inflammatory condition of the larynx. When the morbid growth is of very soft consistence, portions of it sometimes appear in the expectoration. When vibration of the lips of the glottis is interfered with, the cough will be rough, hoarse, muffled, or aphonic, as the case may be. When

the growth is large, the cough is often brazen in tone, recalling the sound of the cough of croup.

Dysphonia occurs only when the growth, by its seat or its size, interferes with the due vibration of the vocal cords; and thus a tumor of considerable size, if at a distance from the glottis, may not give rise to marked dysphonia at all. A growth upon the vocal cords, between them or beneath them, will produce hoarseness even when the morbid product is very small; but a growth upon other portions of the larynx will not affect the voice seriously unless it extends permanently or at times within the chink of the glottis, or presses upon one or both vocal cords so as to impede their free vibration. Where a growth is so situated as to encroach on the glottis and interfere with the functions of the vocal cords at intervals only, the hoarseness or dysphonia will be irregularly intermittent, so that the voice will fail and return, as it were, several times during the utterance of a single sentence. A small growth upon the vocal cords may entangle a clump of mucus now and then, and thus give rise to sudden hoarseness or even aphonia, which ceases as suddenly, upon detachment of the mucus. According to the position of a small growth upon the vocal cords, especially in cases of symmetrical excrescences upon both cords, the alteration of the voice will concern a certain portion of the musical scale, its pitch varying with the length of cord in vibration. In this way a double vocal sound, an octave apart, is produced by a growth situated at the juncture of the middle and anterior third of the cords, and thus dividing them into two sets of vibrating reeds. Unless the growth is quite large, or protrudes within the chink of the glottis, actually preventing its closure, there will hardly be complete aphonia. Sometimes the voice is uneven, that is to say, hoarse, aphonic, and shrill, at irregular intervals during speech. Usually there is a characteristic dull timbre to the aphonic or dysphonic intonation, suggestive of mechanical obstruction, and differentiating it at once from hoarseness and loss of voice from other causes. When the growth is large, or when it incommodes the glottis a good deal by its position, it produces a peculiar staccato mode of utterance, owing to frequent inspiratory breaks in enunciation, and at once suggestive, to the practised ear, of the presence of a tumor in the larynx.

Dyspnœa exists only when the growth is comparatively

large, so as to offer obstruction to the respiratory current, or when there is intercurrent tumefaction of adjacent parts from catarrhal inflammation. It will be irregularly intermittent unless the growth be very large; and will vary, with the case, from mere embarrassment of breathing to distress of the severest character, threatening asphyxia. In many instances the dyspnœa can be relieved by change of position of the head; and this is indicative of a movable tumor. Sometimes laryngeal growths produce asphyxia by impaction of the neoplasm so as to occlude the glottis. Several such cases, in which I forewarned patients of this result, occurred in individuals, with tumors within the larynx, who declined surgical interference, postponed it, or were dissuaded from it.

The tumors were not very large in any of these instances, as will be seen by reference to the accompanying illustrations of two of them (Figs. 135 and 136), and did not even produce serious dyspnœa; but they were in dangerous locations, and seriously compromised the integrity of the glottis.

As these cases are particularly instructive, the two referred to are placed on record as examples of the series.

A. S—, a brewer, aged forty, was brought to me November 9, 1868, by Dr. Bloom, of Philadelphia, to be examined as to the cause of a chronic hoarseness which had existed for upward of twenty-five years. The patient had chronic folliculous pharyngitis, with congestion of the larynx. The vocal cords were thickened and very red in color, and upon each of them was an irregular flabby

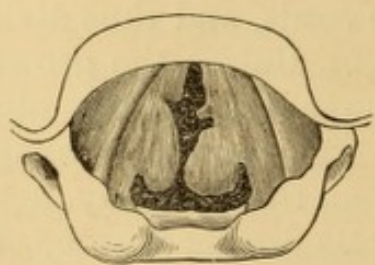

FIG. 135.—Tumors on both vocal cords, producing sudden death.

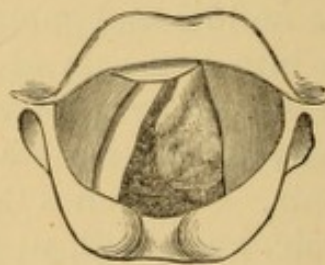


FIG. 136.—Tumor on left vocal cord, producing sudden death.

growth, also very red in color (Fig. 135). As the patient was suffering from a little sore throat at the time, it was impossible to determine whether the color of the growths was simply due to temporary injection of their mucous covering, or whether this was their ordinary aspect. An operation for removal of these growths was urged upon the patient, to which he consented; and making an appointment for a subsequent interview, he left my house. I never saw him again. Some months afterward, Dr. Bloom informed me that the patient had been dissuaded by his wife from undergoing the operation, and that he had died sud-

denly. The patient attributed his disease to syphilis, contracted when very young.

Wm. McN——, æt. 56, a shoemaker, was sent to me March 1, 1869, by Dr. Shapleigh, of Philadelphia, who examined him with me at a second interview on the following day. A red, irregular tumor was found upon the left vocal cord (Fig. 136). Dysphonia, with paroxysms of distressing dyspnœa, had existed for about a year. The patient had contracted syphilis years before, but was otherwise in general good health. An operation was urged upon this patient also, and an appointment made for tentative procedure, which was never kept. A few weeks later I was informed by Dr. Shapleigh that he had been told by the friends of this patient that he had sought relief elsewhere, and was placed under treatment for syphilitic laryngitis, part of which consisted in cauterizing the larynx with the ordinary sponge-probang; and that having died suddenly, a post-mortem examination had been made, revealing the presence of the tumor, to the existence of which the death had been attributed.

These were cases of sudden death, and, in the absence of a laryngoscopic examination, would in all probability have been pronounced by a coroner's jury as due to a "visitation of God." Doubtless other instances of sudden death attributed to a visitation of Providence have been due to suffocation by a laryngeal tumor, the existence of which has not been suspected. Examinations of the larynx in cases of sudden death would throw light on this point.

Voltolini¹ records a case in which a patient with a syphilitic gummous tumor, compromising the integrity of the orifice of the glottis, died at the very moment that an incision was being made into his trachea for relief to his respiration.

In contrast to these cases, many others are on record of much larger growths, implicating the glottis to a much more serious extent in appearance, and also in reality, and in which there were no severe symptoms of dyspnœa threatening suffocation.

Dysphagia is not apt to be produced unless the tumor is so large as to encroach upon the cavity of the pharynx, or unless it occupies the epiglottis, or the region of the arytenoid or supra-arytenoid cartilages, or the pharyngeal surface of the larynx.

Pain of an acute character is unusual in growths in the larynx, and when present is usually due to some associate cause. More or less of an aching sense of annoyance, however, is not infrequent, with sometimes a sensation as of the presence of a foreign object, and a consequent disposition to eject it by expectoration. In occasional instances, however, there are severe paroxysms of pain.

¹ Op. cit., 2d Ed., p. 133.

Sympathetic epileptic seizures may supervene in susceptible subjects.¹ In a small proportion of cases, if the growth has acquired comparatively enormous dimensions, some evidence may be present externally in an altered configuration of the larynx. When the tumor is large and of soft consistence, portions are sometimes spontaneously detached or broken off during paroxysms of cough, and expectorated. Once in a while a growth is spontaneously detached; once in a while it undergoes spontaneous absorption.

Diagnosis.—The diagnosis of growths in the larynx may, under certain favorable circumstances, be assisted by physical exploration with the end of the finger; but merely a vague notion can be thus obtained, even when the growths are high up and quite large. Satisfactory diagnosis as to the existence of a tumor, its seat, mode of attachment, size, etc., cannot be complete without laryngoscopic examination. The entire surface of the growth cannot always be inspected in this way; but much valuable information on this point, as well as with reference to its consistence, its movability, and the feasibility of its removal through the mouth, may be obtained by palpation with a bent probe or laryngeal sound, introduced and manipulated under laryngoscopic inspection. This exploration is not usually very difficult, inasmuch as the very presence of the tumor has already rendered the parts somewhat tolerant of mechanical manipulation.

It is impossible to pronounce absolutely as to the nature of a laryngeal neoplasm before some portion of it has been removed; and even then there is no certainty that the remaining portion is of the same structure. Certain physical appearances, however, together with the locality occupied by the growth, often furnish sufficient evidence for an approximately accurate diagnosis. Thus papillomas are often multiple, usually sessile, and more or less cauliflower-like or dendritic, sometimes distinctly racemose, in one or more little bunches of seed-like masses. They vary in color from a quite pale to a very intense red, and in some instances are so pale as to be quite white. They vary in size from the bulk of small seeds—which is infrequent—to that of large berries, or grape-like

¹ Case related by Sommerbrodt: Berlin. klin. Woch., Sept. 25, 1876; London Med. Record, Aug. 15, 1877, p. 327.

bunches of minute berries. They usually occupy the anterior portions of the larynx, and their most frequent seat is the vocal cord. They are sometimes sufficiently bulky to almost occlude the entire calibre of the larynx. Fibromas are usually single,¹ smooth in contour, and generally pedunculated either by a thin pedicle at one extremity, or by a broad one longitudinally. They are usually red in color, though some of them are white or gray. They vary less in size than papillomas, their bulk varying from that of a small pea to that of a lima-bean or even a large nut; and they are usually of much slower development. Their most frequent intra-laryngeal seat is the vocal cord, but they are not infrequent on the pharyngeal and subcutaneous surfaces of the larynx likewise. Myxomatous fibromas are usually single and pedunculated, and are smooth in contour. They are frequently pyriform in shape, sometimes globular, and vary from the size of small seeds to that of large beans. Their color varies from pale to deep red. Their usual seats are the vocal cord and laryngeal surface of the epiglottis. Myxomas, which are quite rare,² are usually single,³ smooth, or slightly irregular in configuration, and generally pedunculated. They are pink or red in color, and vary from the size of small seeds to that of large beans, which they occasionally exceed in bulk. Their most frequent seat is the commissure or anterior portion of the vocal cords. Angiomas (of which I have not seen any example) are more or less reddish or bluish black in color, and vary from the size of peas to that of blackberries. Fauvel's two cases occupied the vocal cord.⁴ Mackenzie's case⁵ was in the pyriform sinus, therefore outside of the respiratory canal. Lipoma (of which I have not seen an example), in the case described by Bruns,⁶ was so large as nearly to fill the larynx, sessile, lobulated, elastic to the

¹ In an instance of multiple (six) fibromas reported by myself (The Medical Record, N. Y., 1869, p. 265), internal growths occupied the two ventricles, two external ones grew from the anterior portion of the cricoid cartilage, and one growth covered each lateral posterior surface of the cricoid. The specimen is in the museum of the College of Physicians of Philadelphia.

² Mackenzie reports but one case out of his first hundred, while Fauvel reports fifty-three out of his three hundred, making them next in frequency to papillomas.

³ There were three in one of my cases. See note, p. 536.

⁴ Op. cit., p. 190.

⁵ Op. cit., Case 89, Pl. II., Fig. 12.

⁶ Polypen des Kehlkopfes, Tübingen, 1868, p. 84.

probe, bright red in color, and located upon the left arytenoid cartilage. Cystomas are usually sessile, globular, translucent, and white or red in color. They vary in size from the bulk of small seeds to that of small cherries. They usually occupy the epiglottis or the ventricle, but are occasionally located on the vocal cord. On the epiglottis they resemble the appearance of cystoma of the eyelid. Other benign growths do not present any gross characteristic appearances available in diagnosis. Sarcomas present no distinctive characteristics to the unaided eye. They are smooth or irregular in outline, red or whitish in color, sessile, of comparatively large size, and occupy the anterior portion of the larynx most frequently.

Carcinomas are described under a special heading.

Care must be taken to differentiate these various morbid growths from fungous excrescences or exuberant granulations about the edges of certain ulcers, tuberculous and syphilitic, and from gummata. An everted ventricle may simulate a morbid growth from the ventricle. The occurrence is very rare. But few instances are on record,¹ and only one² in which the condition was recognized during life.

In a case under my own care, a very villous, red, elongated mass overlapped the left vocal cord as far as the posterior margin of the ventricle, the line of entrance into which was undefined. The posterior portion of the vocal cord was normal, and the suspicion of everted ventricle was entertained, though not verified by attempts at replacement. As the patient withdrew from treatment on my refusal to operate before duly ascertaining the nature of the case, the diagnosis has been incomplete. The patient's general health was good, and great disposition to cough had been the only symptom anterior to the hoarseness for which he sought relief.

Prognosis.—The prognosis of intra-laryngeal neoplasm is good as regards life, voice, and riddance of the tumor, in the great majority of instances of benign growths. It is bad, as a matter of course, in cases of clinical malignancy. Tumors which cannot be removed by intra-laryngeal procedure are menacing to life, according to their size, rapidity of growth, and proximity to the glottis; or their encroachment upon it if external or in the epiglottis. Growths upon the vocal cords too small to be seized or excised, or beyond reach on their inferior surface,

¹ Moxon: Trans. Path. So., London, XIX., 1868, p. 65; Mackenzie: Op. cit., p. 34, illustrated; Lefferts: The Medical Record, N. Y., June 3, 1876, illustrated.

² Lefferts: Loc. cit.

entail permanent impairment of voice unless they undergo absorption. The methods of operation, too, have considerable influence on the prognosis. Removal through the mouth is much less liable to terminate fatally than removal through external openings, and recurrences are much less apt to follow.¹ Permanent impairment of voice is almost unavoidable if the thyroid cartilage is divided between the vocal cords, which become united directly or by commissural tissue anteriorly, and thus shorten the vibrating reeds, rendering the voice more or less shrill and dissonant.

Mr. Lennox Browne states² that he has knowledge of at least five instances in which perichondritis, or other equally fatal result, has followed as a direct consequence of intra-laryngeal instrumental operations for removal of benign growths from the larynx. He also states that it every now and then occurs that spasm of the larynx after an operation on a growth is so severe as to require tracheotomy; he himself having been called upon to perform it for such a reason.

Recurrences of benign morbid growths are almost entirely confined to sessile papillomas, chiefly from incomplete extirpation or inefficient cauterization of the tissues from which they have been torn. Some so-called recurrences are simply subsequent developments in new situations, and by no means attributable to previous imperfect operation. It occasionally occurs that papillomas become transformed into epithelial carcinoma,³ sometimes from mere local irritation from cough and pressure, and sometimes from irritation set up by repeated unsuccessful attempts at removal by evulsion.⁴ Adenomas are likewise liable to become malignant.

Treatment.—Some growths in the larynx undergo spontaneous cure by absorption or by constriction, separation, and expectoration;⁵ but such a fortunate result seldom occurs, and

¹ See Mackenzie: *Op. cit.*, p. 97; Paul Bruns: *Die Laryngotomie zur Entfernung intra-laryngeal. Neubildungen*, Berlin, 1878, p. 148; for a contrary opinion, see Browne: *The Throat and its Diseases*, London, 1878, p. 251.

² *Brit. Med. Jour.*, May 8, 1875, p. 603, and *op. cit.*

³ For examples see Gibb: *Brit. Med. Jour.*, Sept. 30, 1865, p. 328; Bruns: *Neue Beobachtungen von Polypen des Kehlkopfes*, Tübingen, 1868, p. 44; Mackenzie: *Op. cit.*, p. 183.

⁴ Browne: *Op. cit.*, p. 254.

⁵ A recent example has been reported by Mr. Arthur William Robson, of Leeds (*Brit. Med. Jour.*, May 29, 1875, p. 708), in which a female patient with aphonia,

cannot be predicted. It would therefore be imprudent to await it.

A morbid growth of the larynx is a very serious affection, even if clinically benign in structure; and, if of such size as to interfere seriously with the function of respiration, demands removal by surgical procedure.

Certain growths of syphilitic origin, arising, in part, if not in whole, from the cicatrizing surface of ulcers, even when quite fleshy or sarcomatous in appearance, and of comparatively large bulk, are amenable to systemic medication by iodide of potassium and bichloride of mercury; and in cases of this nature, in which the growths are small and do not interfere with the respiratory functions, it is proper to give specific treatment a fair trial before resorting to operative procedures. Even in cases of comparatively large growths, compromising the function of respiration, it is not inadvisable, if concomitant indications are favorable, to perform tracheotomy in order to banish the dyspnoea, and to await the result of internal treatment before instituting local interference. The progression or retrogression of the growths in such cases should be watched most assiduously by frequent laryngoscopic inspection. In two marked instances under my own care, absorption took place after tracheotomy, without any intra-laryngeal interference whatever.

In most instances of laryngeal growths, however, an operative procedure is requisite, either for their removal by forceps or cutting instruments, or for their destruction by caustics or crushing instruments.

If the growth is small, and does not interfere with the function of respiration, there is no necessity for surgical intervention, except in cases of impairment of the voice in individuals who gain their livelihood by singing or speaking. In an individual to whom a moderate degree of hoarseness is of little account, a small benign growth need not be subjected to treatment unless repeated laryngoscopic examinations reveal that it is increasing in size. Under these circumstances there can be no doubt as to the propriety of its prompt removal. Cases are on record where small growths have remained stationary for long numbers of years.

dyspnoea, and other symptoms, due to a pedunculated polyp (myeloid sarcoma under the microscope), eventually coughed the morbid growth out.

I had the opportunity to examine, from time to time, the larynx of a lady, in whom a small growth on one of the vocal cords had remained unchanged for more than ten years, presenting the same appearance as first seen when originally detected by Dr. Elsberg, of New York, as to the cause of a hoarseness of voice which had then existed for some sixteen years. It is the case depicted in Fig. 26, in his Prize Essay.¹ On one occasion this patient requested me to examine her larynx on account of increased hoarseness following exposure to cold, and I saw that the little nodule on the right of the vocal cord had acquired a tapering end, which, in phonation, struck the opposite cord, and produced increased hoarseness and a troublesome sensation in the parts; but shortly afterward the parts resumed their ordinary appearance. Repeated recurrence of hoarseness from similar attacks, and evidence of augmentation in size, eventually led Dr. Elsberg to remove the growth.

A case will be narrated subsequently in which an elderly gentleman had probably carried a laryngeal growth since his childhood, and which, becoming enlarged so as to produce distressing hoarseness, was destroyed by a single application of the acid nitrate of mercury.

A growth of the larynx may be removed by intra-laryngeal operation carried on through the mouth, or after previous incision of lateral pharyngotomy, or the incision of laryngotomy, partial or complete, anterior or lateral. Removal of more or less of the entire larynx, and even of the whole of it, has been occasionally practised in malignant cases.

Removal through the mouth is now usually effected under laryngoscopic circumspection. There are, at least, two cases on record of removal through the mouth in ante-laryngoscopic days: those of Koderick, of Brussels, in 1750, and of Green, of New York, in 1845.

The operations performed for the removal of growths within the larynx are: cauterization; scarification, followed by cauterization; crushing or cutting with forceps; evulsion with forceps, wire loop, or small chain *écraseur*; excision with knife, scissors, wire loop, or galvano-cautery—all of which are practicable through the mouth; and removal after section of the crico-thyroid membrane, thyroid cartilage, thyro-hyoid membrane, or by excision of a portion of the larynx, or the whole of it.

In some instances, especially with neoplasms threatening recurrence, thorough removal is requisite, sometimes entailing sacrifice of vocal cord or other structure; and in these cases

¹ Laryngoscopic Surgery illustrated in the Treatment of Morbid Growths within the Larynx. Prize Essay of the American Medical Association for 1865.

direct access is necessary, by splitting the larynx externally.

Removal after sub-hyoidean laryngotomy has been performed by Dr. Pratt,¹ in 1859, and subsequently, in 1863, by Dr. Follin;² but it is not likely that this operation will ever become legitimized in surgery, because, as judiciously remarked by Dr. Mackenzie, the cases most suitable for it are just those which can be most readily reached through the mouth by laryngoscopic manipulation.

Voltolini has called attention to the fact that soft growths can sometimes be detached or rubbed off, as it were, with a sponge, which is twirled round and round in the larynx for the purpose. In a recent communication³ he states that the method is likewise applicable to harder growths, the manipulation being repeated at intervals (four to eight days), until the polyp becomes livid, mortifies, and falls off. I have occasionally been able to scrape off soft growths from the upper portion of the larynx with the finger-nail, a method particularly applicable in children of from five or six to ten or twelve years of age.

Small, soft papillomata, which are frequently multiple, may often be destroyed by repeated applications of caustics (nitrate of silver, chloride of zinc, chromic acid, nitric acid, acid nitrate of mercury, Vienna or London paste, galvano-cautery). Even growths of considerable size are sometimes amenable to this treatment, though it is better, as a rule, to remove as much of the morbid tissue as possible with the forceps, and then to cauterize the remnant of the neoplasm.

Various instruments have been devised to convey the caustic material to the parts, most of them so shielded as to prevent unnecessary contact of the caustic with the sound tissues.

To describe all the instruments constructed for this and other purposes of laryngoscopic surgery, and discuss their merits, would be a task as thankless as unnecessary. All that will be attempted will be to describe those really valuable instruments which have withstood the test of experience; and this remark refers to the entire subject of laryngeal surgery. The illustrated catalogues of the instrument-makers furnish a very accessible source of supplying any deficiency.

¹ Gazette des Hôpitaux, 1859, No. 103, p. 409; Elsberg's Prize Essay, p. 15.

² Mackenzie on Laryngeal Growths, p. 99, from Arch. Gén. de Méd., Feb., 1867.

³ (Monatschr. für Ohrenheilkunde, Nov. 3, 1878); The London Med. Rec., Nov. 15, 1878, p. 478.

To be effective, the caustic must be used in concentrated solution or in substance, and must be retained in contact with the morbid structure for a number of seconds. Mere momentary touching will not prove efficacious. It may even be detrimental, by augmenting the disposition to hyperplasia. The cauterization is repeated daily, or every other day, or less frequently, according to circumstances; and this frequency must be regulated according to individual results. The first contact of a caustic solution with any portion of the larynx usually induces a distressing spasm. The severity of spasm becomes less and less as the parts become accustomed to the manipulation. It is well, therefore, to test the sensibility of the tissues by the preliminary employment of moderate measures before resorting to severe ones. Prof. Stromeyer mentions that several patients have lost their lives in the surgeon's office by incautious cauterization of the larynx.

Operations of this kind, therefore, and in fact all intralaryngeal operations, should not be undertaken until the surgeon has, by repeated practice in minor cases, acquired sufficient skill to carry his instrument safely to the desired point. Fortunately, sound tissues bear the momentary contact of the ordinary caustics very well, and but little injury ensues if they are cauterized instead of the growth. This, however, does not destroy the growth which has not been reached.

The morbid growth itself is much less sensitive, as a rule, than the normal laryngeal surface, and therefore, if the patient is steady and the operator skilled, there is much less danger of inducing suffocative paroxysms than might otherwise be anticipated.

In my own practice this treatment is reserved for destroying very small growths which cannot be grasped with forceps or snare. It is also employed to excite destructive action in the remnants of larger growths, as much of which as possible has previously been removed by instrumental procedure.

Concentrated caustic solutions are best applied by small pieces of sponge securely fastened to slender but strong and rigid wires (Fig. 109, p. 490), or firmly held between the teeth of delicate forceps (Fig. 111, p. 492).

The fused nitrate of silver in stick may be applied by means of special caustic-holders, of which different forms—some rigid and some flexible—have been contrived by Lewin, Elsberg,

Tobold, Bruns, Fauvel, and others. All instruments of this kind are clumsy, and conceal the essential point of the instrument from view. A much better method is that of dipping a roughened platinum bulb, or the screw end of Mackenzie's aluminium brush-holder, into melted caustic, after first heating the metal to enable it to take up sufficient of the material and to hold on to it for several hours. Prof. Stromeyer recommends a metallic sound with a glass bulb soldered on it, the bulb to be immersed in a concentrated solution of nitrate of silver, which is then allowed to dry upon it.

Prof. Tobold has also devised a concealed socket, movable in any direction, in which the molten nitrate of silver, or chromic acid crystals, if preferred, can be inserted, and which is

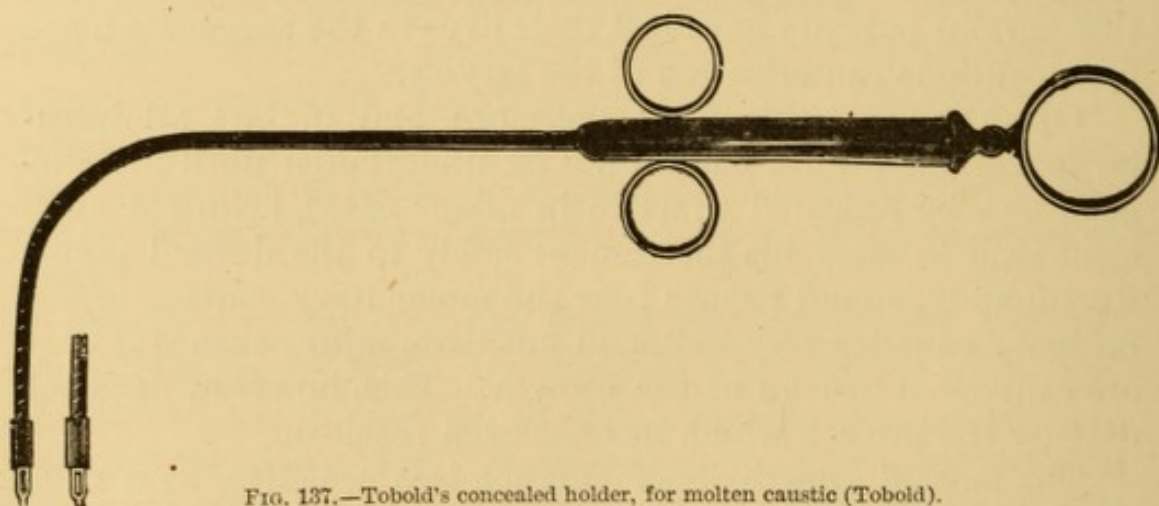


FIG. 137.—Tobold's concealed holder, for molten caustic (Tobold).

pushed forward at the desired moment to expose the caustic (Fig. 137). The London paste (p. 196) is the escharotic preferred by Dr. Mackenzie, of London.

The accompanying illustrations (Figs. 138 and 139) will represent the sort of growths suitable for treatment with caustics.

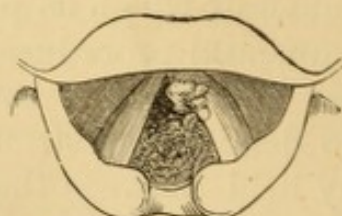


FIG. 138.—Excrescence on left vocal cord (destroyed by caustic).

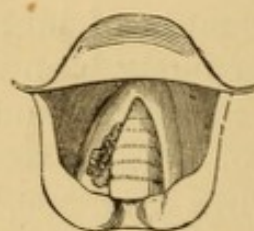


FIG. 139.—Excrescence on right vocal cord (destroyed by caustic).

A gentleman, aged about sixty years, had been hoarse from childhood, but the hoarseness had increased very much during four or five months previous to

soliciting my services. A small warty excrescence occupied the anterior portion of the left vocal cord (Fig. 138), in such a position as to interfere seriously with vocalization. The voice would become suddenly aphonic during the enunciation of a sentence, and then, after a cough, revert to its former hoarseness. The annoyance of this inconvenience, a harassing cough, and a dread of some fearful result, rendered the patient anxious for relief. An attempt was made to remove the growth with forceps; repeated efforts only failed to detach more than insignificant portions. Nitrate of silver failed utterly. Being unwilling to open the larynx for the removal of a growth which was not interfering with respiration, I decided, by the advice of a professional friend, to attempt its destruction with the strong acid nitrate of mercury, which was introduced without hesitation, inasmuch as the patient had borne repeated applications of the molten nitrate of silver with little inconvenience. No difficulty was experienced in touching the spot; but the most violent spasm of suffocation ensued that it had been my lot to witness from the intra-laryngeal application of caustics. For a moment I thought I had before me one of those unfortunate cases alluded to by Prof. Stromeyer, and actually had my hand upon my penknife with a view of plunging it into the trachea, in case the spasm continued a few moments longer, when the paroxysm ceased, to my unutterable relief. After one or two less violent paroxysms the immediate danger was over, and I mentally resolved that I would not use the acid nitrate of mercury again under similar circumstances. The patient had a violent inflammation of the larynx for several days, with aphonia, paroxysms of asthmatic dyspnoea, and more or less painful deglutition. Rest, purging, liquid diet, and the frequent inhalation of steam impregnated with narcotics, constituted the treatment for this condition. The tumor sloughed off, and the patient's voice became better than it had been for years. After his recovery the patient told me that I should not make another such application, even if it should be the only method of saving his life. Several years have elapsed, and he has had no return of his former trouble.

A lady, thirty-two years of age, was referred to me by Prof. Flagg, on account of persistent hoarseness of some five or six months' duration. There was no cough, expectoration, pain, or dyspnoea; but there was an occasional sensation of something in the throat which she would like to get rid of. A small

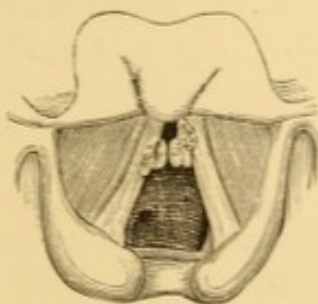


FIG 140.—Epithelial growths on both vocal cords, in a case of phthisis.

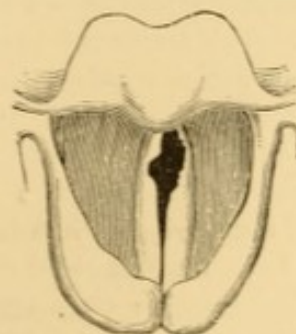


FIG. 141.—Appearance of cord after destruction of growths with chromic acid.

gelatinous-looking mass was seen upon the right vocal cord, which, on probing, proved to be a morbid growth (Fig. 139). It was repeatedly cauterized with

fused nitrate of silver, two or three times a week, and in less than a month was completely removed by the treatment, the voice having recovered its original clearness.

These two cases have been selected, the one to show that the element of danger in severe applications is not always removed by tolerance to measures less severe; and the other to show how readily a soft growth of recent occurrence sometimes yields to the nitrate of silver. The appearances of the larynx before treatment in a case of epithelial growths, and after their destruction by chromic acid, is also illustrated (Figs. 140, 141). These occurred in a case of phthisis.

Treatment by nitrate of silver is very protracted, as a rule.

A lady was placed under my care in 1866, by Dr. A. Douglass Hall, of Philadelphia, with complete aphonia of more than a year's duration. Several minute growths occupied both vocal cords. I found it impossible to grasp them in the forceps, and resorted to nitrate of silver. Applications were made every two or three days for several months, with occasional intervals of a week or two to see if the growths would recede without further treatment; and, at the end of some five or six months, the cords were clear, and the voice, which had improved from the very first, sufficiently sonorous for all practical purposes, but not clear enough for purposes of singing. The voice continued good for several years—in fact, until the patient's death from phthisis in 1872.

A prominent female vocalist applied to me, in the winter of 1867, on account of a difficulty in singing and occasional hoarseness, and in whom I was able to watch the formation of the growth as well as its gradual retrocession. Laryngoscopic examination showed deficient power in the muscles of the left vocal cord. As soon as the lady would exert her voice, the cord became bent in the middle so as to destroy the elliptic figure of the opening of the glottis in phonation. I told her she must give up singing, to rest the parts. This she could not do, being under engagement, but she promised to follow my advice in other matters, and to obey me in all as soon as her engagement was concluded. She visited me every day, and I employed local electrization by the induced current, with the negative pole directed to the cord by Mackenzie's laryngeal electrode, the positive pole attached to a sponge being placed in front of the crico-thyroid membrane. This treatment improved the voice for the time. In a few weeks the patient's duties required her presence elsewhere, and local treatment was intermitted. She continued, however, to pay great attention to her general secretions, and to take, three times a day, ten drops of the compound tincture of *ignatia amara*, which had been previously prescribed. Toward the close of the winter she returned to Philadelphia, the voice much worse than it had been before she left. I now noticed that the bend of the cord had become permanent, and that the knuckle thus formed struck the opposite cord every time she attempted to run the scale, and that at this point it was eroded or scratched. The treatment by electricity was renewed without essential benefit, though there seemed to be some improvement; but the eroded appearance upon the distorted cord became gradually converted into that of a knob, which finally developed itself into a nodule the size of the head of a large pin. With this I should not

have felt inclined to interfere at the time, had it not been that the patient was a professional vocalist dependent upon her voice for a livelihood, and anxious to have her vocal powers restored at any personal sacrifice. To seize so small a growth with a pair of forceps was out of the question. Several unsuccessful attempts were made to pierce its base with Tobold's lancet knife, and so detach it from the cord. Finally it was determined to persist in the local contact of the molten nitrate of silver conveyed upon a very delicate roughened bulb of platinum. The treatment was extremely protracted. Many times the tumor was missed and the cord cauterized; but these persistent efforts were crowned with success, and finally—but not until the patient had been under my care for two years, with summer intermissions—all trace of disease was removed, and after a few months' practice, to regain lost ground, the lady was able to sing with much finer effect than she had ever been able to accomplish before. Her voice has remained perfect ever since (1878).

Soft growths in the upper portion or vestibule of the larynx can sometimes be dug out, as it were, with the nail of the forefinger, especially in children; and this method should always be tried before resorting to severer procedure. When too low to be reached by the finger, they may sometimes be brushed off their points of implantation by means of a firm piece of moistened sponge first passed beyond them, as especially announced by Voltolini. The majority of laryngeal growths are suitable for removal by evulsion with forceps. Instruments for this purpose must be slender and strong, and well curved.

To meet the various indications presenting themselves, forceps are required of different lengths, and with jaws opening in different directions. The jaws should be provided with teeth (Fig. 142), or with serrations, or both, to hold on

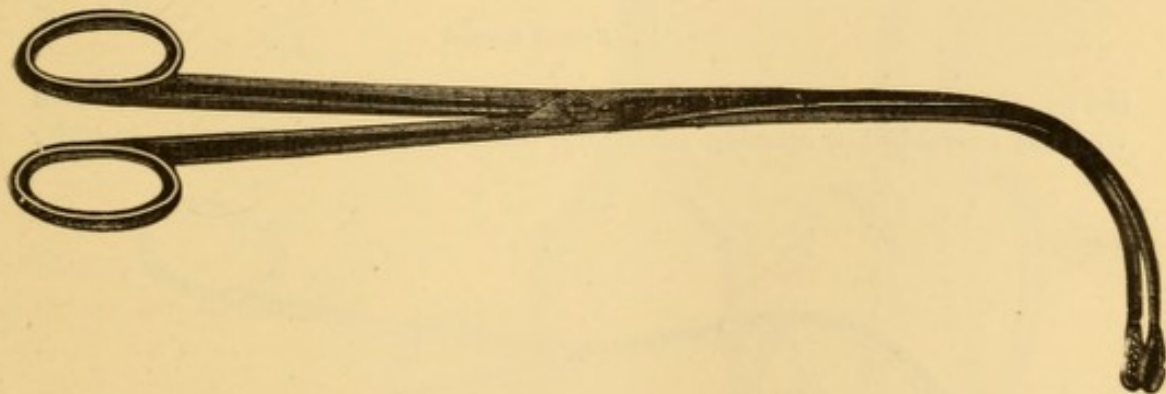


FIG. 142.—Tobold's forceps (Tobold).

to the growth when it is once grasped, so that it is either removed in mass, or in little bits, such as are gouged out by the jaws of the forceps. Fauvel's forceps (Fig. 143) are provided with a retaining catch on the rings, which prevents the closed jaws from reopening. In Cuzco's forceps the jaws open at their extremity

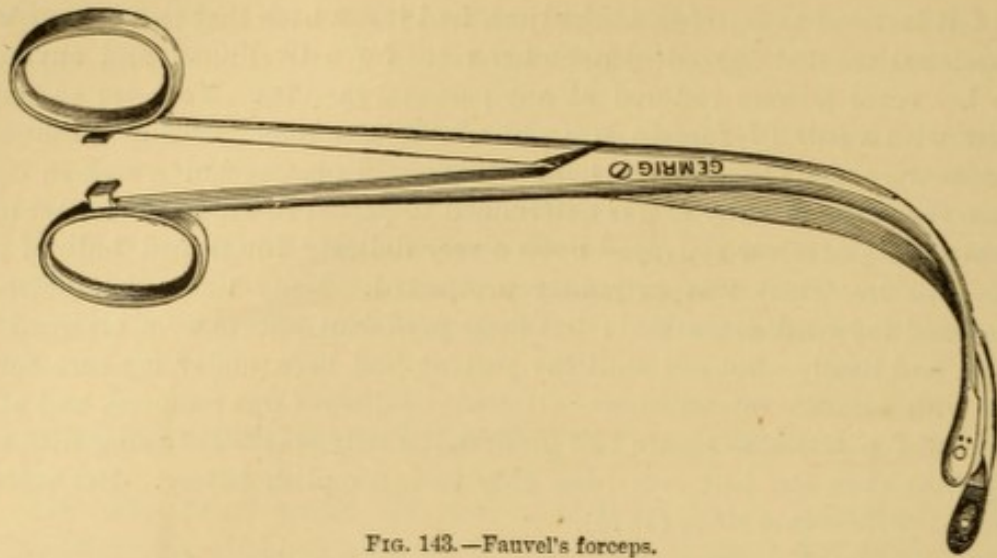


FIG. 143.—Fauvel's forceps.

only (Fig. 144), and thus do not cut off a view of themselves in the laryngoscopic mirror. They are very efficient, and quite strong. The addition of a catch to

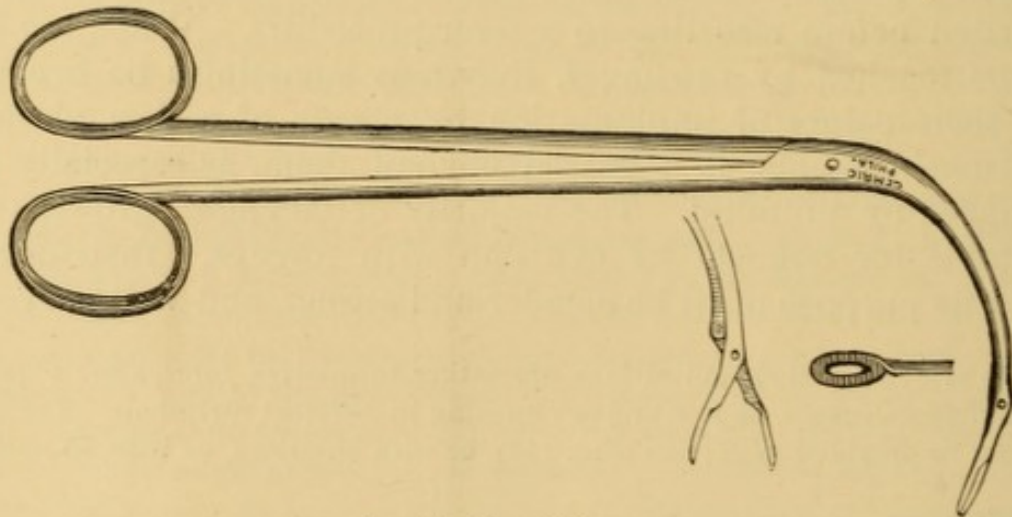
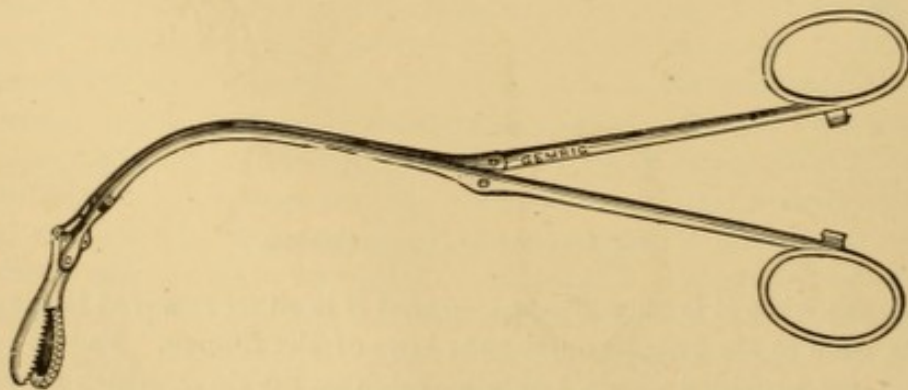


FIG. 144.—Cuzco's forceps.

the handles render them more secure. Separate instruments may be constructed with the movable jaw opening anteriorly, posteriorly, or to either side, in order



145.—Luer's forceps.

to facilitate the removal of growths situated in different localities of the larynx. Luer's forceps, on a similar principle, are more delicate in construction, and ingeniously contrived to transmit motion to the jaws in the opposite plane to that of the handles (Fig. 145).

Dr. Mackenzie's forceps have a more abrupt or rectangular curve (Fig. 146),

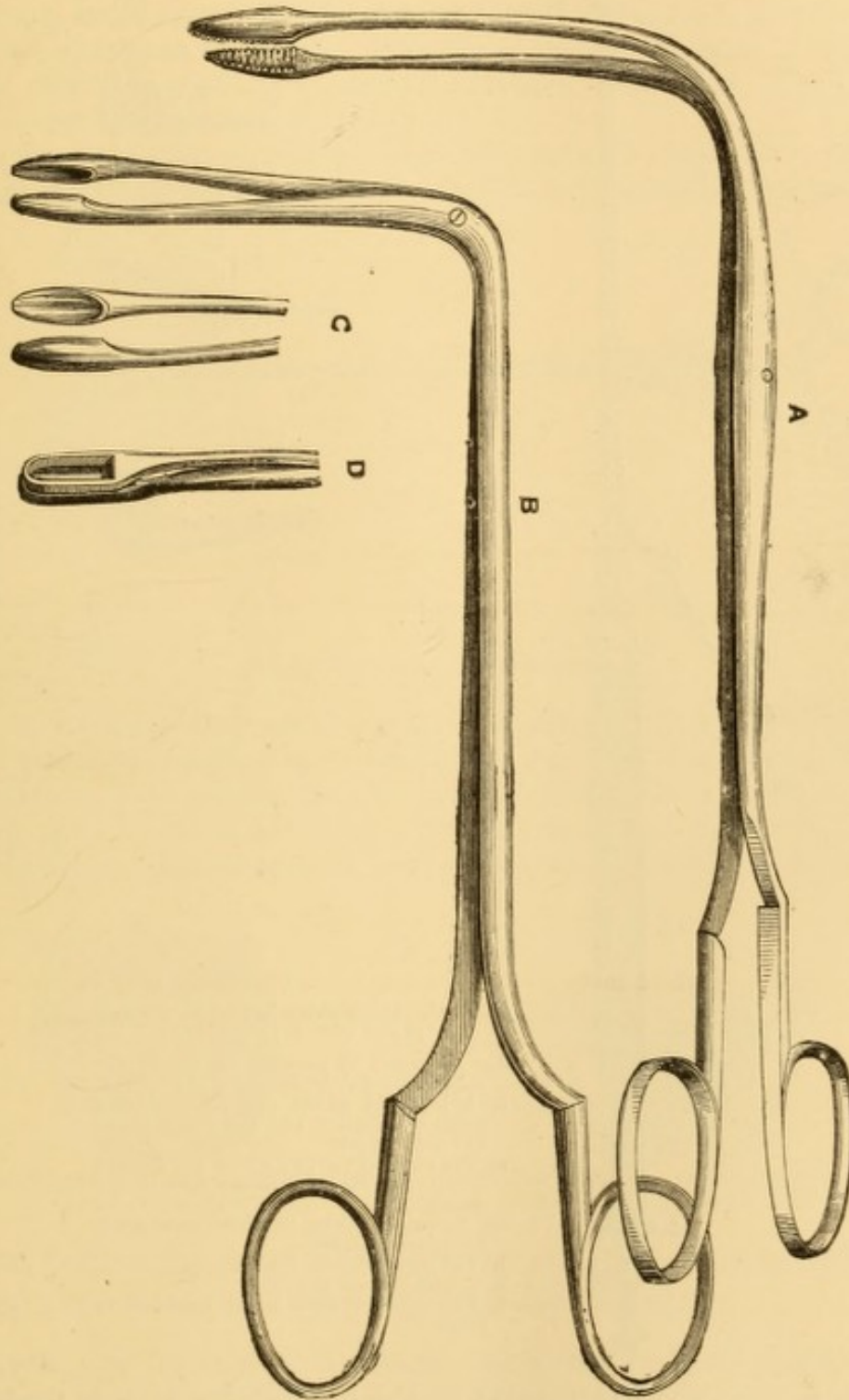


FIG. 146.—Mackenzie's laryngeal forceps (Mackenzie).

- A. Lateral forceps. B. Antero-posterior forceps. C. Cutting forceps.
D. Forceps, one blade of which cuts, while the other presents a flat surface.

so that contact with the epiglottis is, in many cases, more easily avoided than with instruments with the catheter-like curve. I use them more frequently than any other.

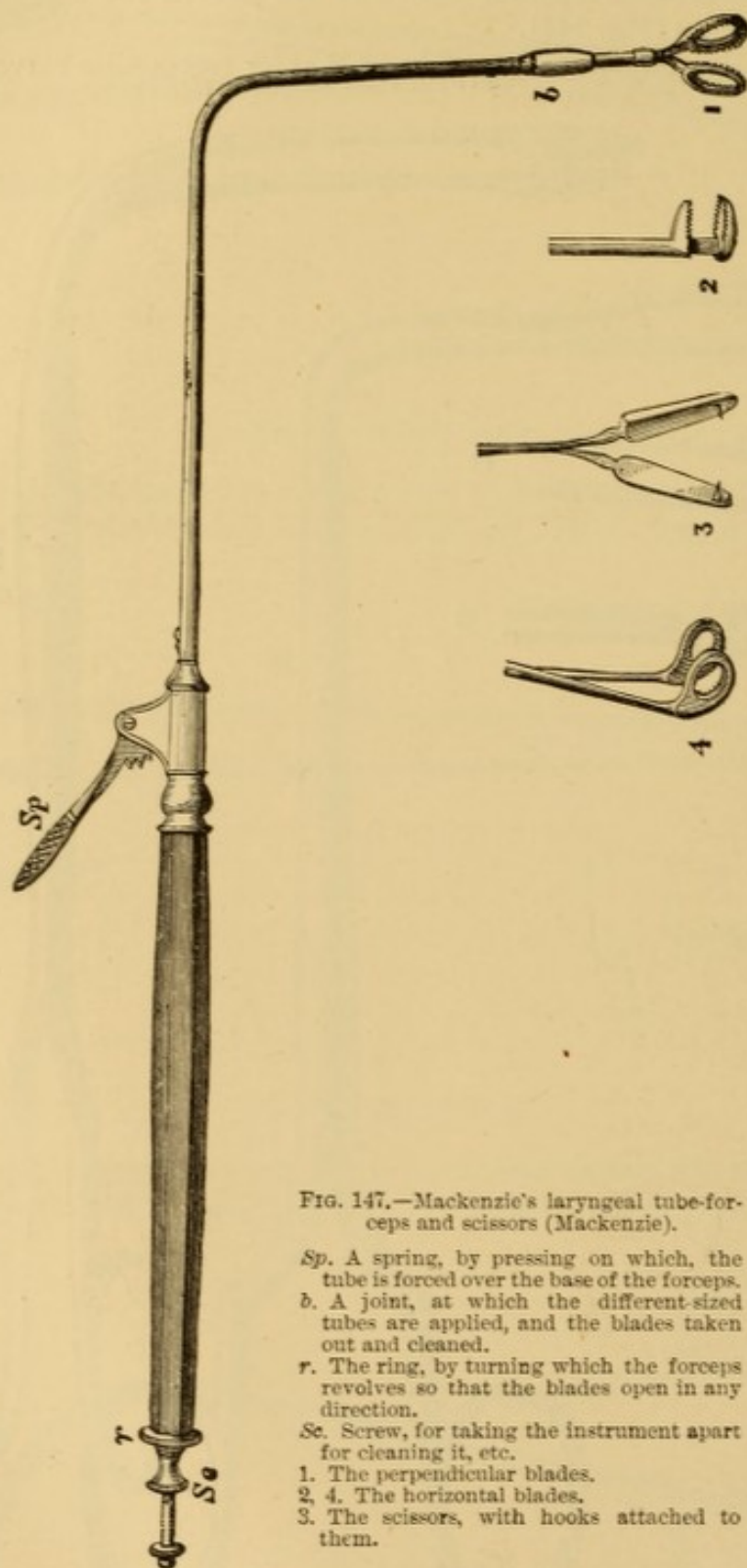


FIG. 147.—Mackenzie's laryngeal tube-forceps and scissors (Mackenzie).

Sp. A spring, by pressing on which, the tube is forced over the base of the forceps.

b. A joint, at which the different-sized tubes are applied, and the blades taken out and cleaned.

r. The ring, by turning which the forceps revolves so that the blades open in any direction.

Sc. Screw, for taking the instrument apart for cleaning it, etc.

1. The perpendicular blades.

2, 4. The horizontal blades.

3. The scissors, with hooks attached to them.

Tube-forceps were early designed by Mandl, Semeleder, Stoerck, Lewin, and other laryngoscopic operators, the object being to construct a slender instrument, the jaws of which could be closed or opened by the pressure or release of a

spring in the handle, controlled by one of the fingers of the operating hand. They are so constructed that the blades of the forceps portion can be turned in any direction. These instruments are most serviceable in removing small growths or fragments of larger ones. The delicacy of their mechanism is incompatible with a sufficient degree of strength for most purposes, and they are exceedingly liable to get out of order. In certain cases of soft growths in the immediate vicinity of the glottis, and below it, they are available by their slenderness, when the use of larger instruments is out of the question. The simplest device is that of Mackenzie (Fig. 147).

The most recent departure in tube-forceps is Durham's adaptation to the ordinary and convenient scissor handles of a flexible copper wire running through a

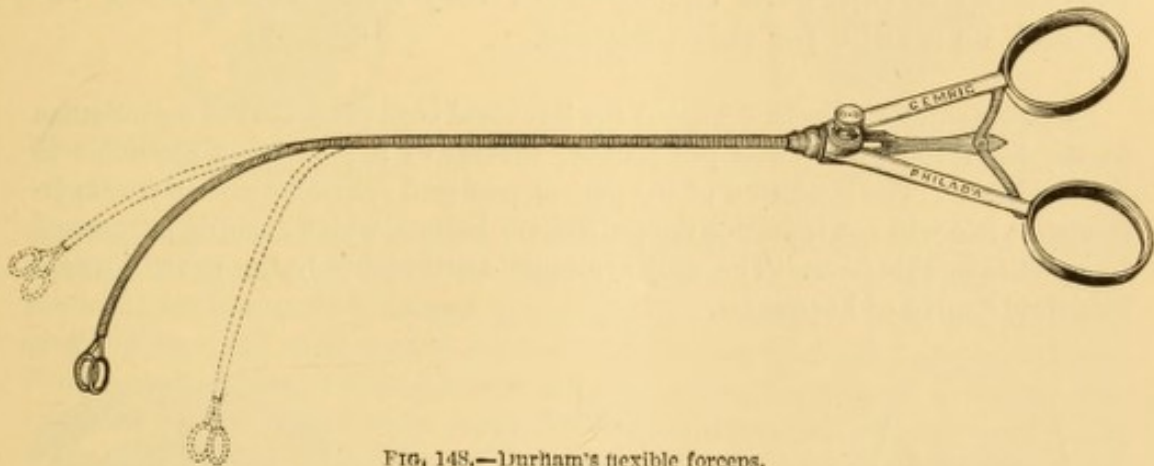


FIG. 148.—Durham's flexible forceps.

flexible spiral coil of wire,¹ which permits expansion of the blades of the forceps, or runs over them according as the handles are separated or approximated. Its flexibility permits of bending the instrument to any desired shape (Fig. 148). In reaching parts which do not offer any resistance to the introduction of the instrument it is admirably adapted for use in larynx, pharynx, or nasal passages.

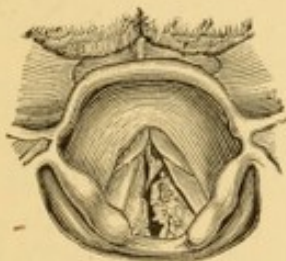

FIG. 149.—Papillary growths in phthisis. Removed with forceps.

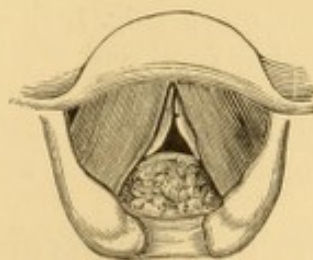


FIG. 150.—Papilloma occupying posterior laryngeal wall. Removed by evulsion.

The following notes will serve to illustrate the varieties of morbid growth suitable for evulsion with forceps:

A young man, the subject of phthisis, had several papillary growths above and below the vocal cords (Fig. 149), productive of great dyspnoea and hoarse-

¹ A similar device of spiral coil was formerly used by Elsberg to expose or conceal a caustic point. *Laryngoscopy Medication*, N. Y., 1864, Fig. 4, p. 29.

ness. The growths were in the main removed with Mackenzie's tube-forceps, with relief to the dyspnœa and improvement in the voice.

A married lady had suffered for four years with hoarseness, which gradually increased to aphonia; and, for a year or so, with dyspnœa. The ventricular bands were very thick and hypertrophied, the true cords were barely seen, and a papillomatous tumor of the size of a small cherry, or a very large pea, occupied the posterior wall of the larynx below the inter-arytenoidal fold (Fig. 150). The growth was removed by evulsion with Mackenzie's antero-posterior forceps, with prompt relief to the dyspnœa and gradual restoration of voice.

When a growth is pedunculated, it can be very readily removed by a tug with the forceps, very little force being required, as a rule, for this purpose.

A pedunculated growth occupied the left vocal cord (Fig. 151) of a gentleman in the last stage of phthisis pulmonalis, brother of a prominent physician in Philadelphia. The condition of the patient rendered operative procedure superfluous, as it could not influence the pulmonary lesions, which steadily progressed to an unfavorable issue. The only symptom attributable to the growth was a moderate degree of hoarseness.

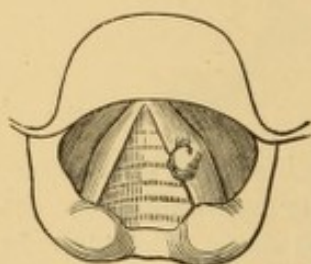


FIG. 151.—Pedunculated neoplasm on vocal cord, in a case of phthisis.

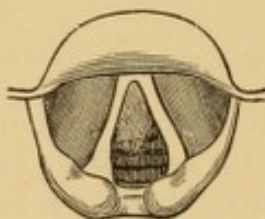


FIG. 152.—Pedunculated fibroma beneath vocal cord. Removed with Fauvel's forceps.

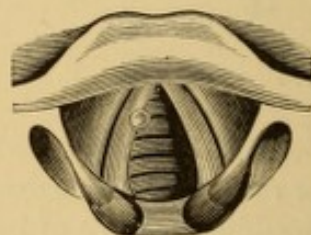


FIG. 153.—Cyst of vocal cord. Removed with forceps.

A fibroid polyp (Fig. 152) was readily removed with Fauvel's forceps from beneath the left vocal cord of a lady of Philadelphia.¹

A married lady, in Philadelphia, with prolonged hoarseness, incorrectly attributed to phthisis, had a very small cyst upon the vocal cord (Fig. 153), which I readily removed with forceps, with immediate relief to all unpleasant symptoms.²

Where the growths are large, it is seldom that they can be removed in mass. As a rule, small pieces are torn off from time to time, so that a number of operations are necessary before the larynx can be cleared.

A married lady, twenty-six years of age, referred to me June 3, 1870, by Prof. Stillé, of Philadelphia, had a large papillomatous growth, the size of a fil-

¹ Case detailed in *Am. Jour. Med. Sci.*, April and October, 1867.

² *Phila. Med. and Surg. Reporter*, Sept. 21, 1878, p. 246.

bert, upon the left side of the larynx, and a small growth of the same nature upon the right vocal cord (Fig. 154). I removed quite a large piece of the main growth with Cuzco's forceps, and sent it to Prof. Stillé, who handed it to Prof. Tyson, by whom it was pronounced a simple epithelial formation.

On the following day Dr. Stillé examined the patient with me, recognized the morbid mass, and approved of treatment by evulsion. The patient visited me from day to day with frequent intervals, and I gradually cleared the larynx by

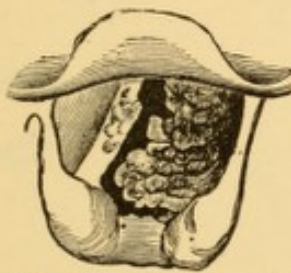


FIG. 154.—Laryngeal growths. Removed by evulsion and caustics.

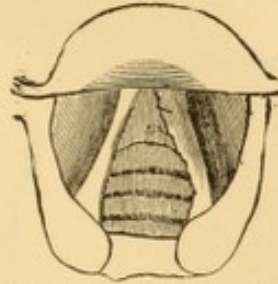


FIG. 155.—Same case as Fig. 154, after removal growths.

evulsion, until, at the end of three weeks, it presented no appearance of morbid growth, though the left vocal cord had not become smooth (Fig. 155). During the course of treatment it became apparent that the large growth was multiple, growing from the vocal cord as well as from the ventricle and ventricular band. The amount of tissue removed was much greater than the mass of a filbert. The remnants of the growth were cauterized with deliquesced carbolic acid; and, when the patient departed for her home, her voice, which was completely aphonic at the time I first saw her, and which had been very hoarse for about a year and a half, was in excellent condition. She was recommended to continue for some time daily inhalations of a weak solution of carbolic acid. A few months later I was notified by her physician that her voice had continued to improve in strength and clearness, and that it was at that time in all respects satisfactory, and could be heard at a considerable distance down the road, and that, at the time of writing, there was no evidence of growths having been in the larynx. Recurrence took place seven years afterward,¹ growths of the same character becoming developed on the left vocal cord as before, but not upon the other structures primarily affected; while new developments had occurred on the posterior surface of the vocal cord and ventricular band of the right side. Treatment by evulsion, as before, followed by cauterization with molten nitrate of silver, gradually cleared the larynx of morbid growth, and at last accounts (May, 1878) the voice was good, and there was no further evidence of recurrence.

There are some dangers attendant upon the incautious use of the forceps. Spasm of the larynx is liable to occur, and is said to be so great at times as to demand immediate tracheotomy.² A more frequent result is the accidental removal of normal tissue, leading to ulceration. Acute inflammation may result

¹ Med. and Surg. Rep., Philadelphia, Aug. 24, 1878, p. 159.

² Browne, quoted by Thornton, Brit. Med. Jour., April 13, 1878, p. 523.

from untoward compression of normal tissue, or from direct injury to the morbid mass when not extracted in bulk or in fragments. Tracheotomy has sometimes become necessary shortly after such accidents. Many operators have removed large numbers of growths from the interior of the larynx without any untoward result of the kind; but as it is liable to occur even in skilful hands, its mention is necessary.

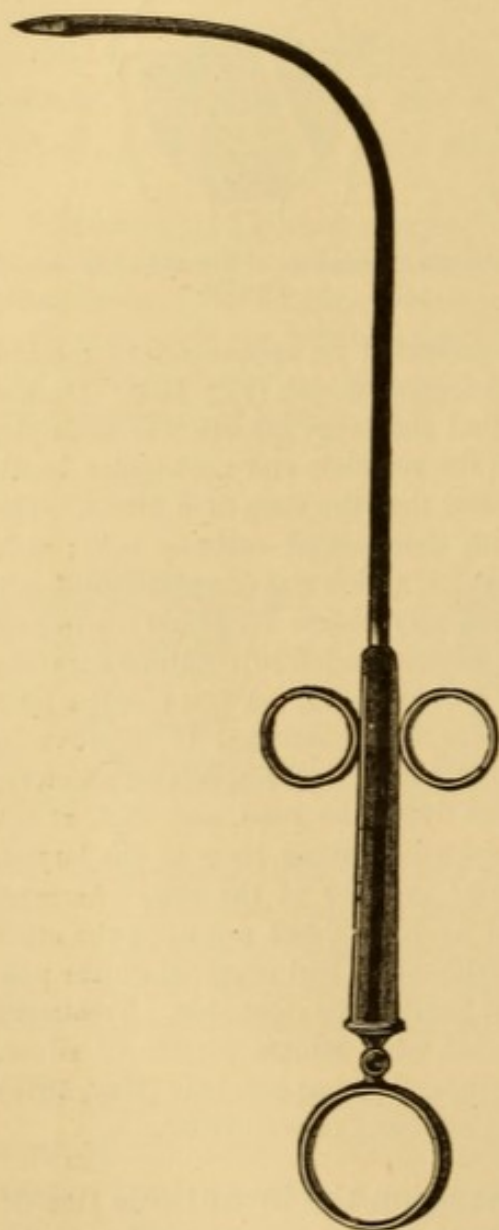


FIG. 156.—Tobold's concealed knife
(Tobold).




FIG. 157.—Tobold's lancet-pointed probe
(Tobold).

Growths that cannot be extracted by evulsion with forceps, or which have been incompletely removed, may be firmly crushed between the jaws of the instrument to excite destructive inflammation; and the suppuration thus induced some-

times disposes of the whole of the morbid tissue. The inflammatory results during the process may require treatment applicable to traumatic laryngitis of moderate severity.

Excision with knife or scissors is sometimes practised for the removal of growths from the larynx. The sheathed knife (Fig. 156), the point of which is exposed after its introduction

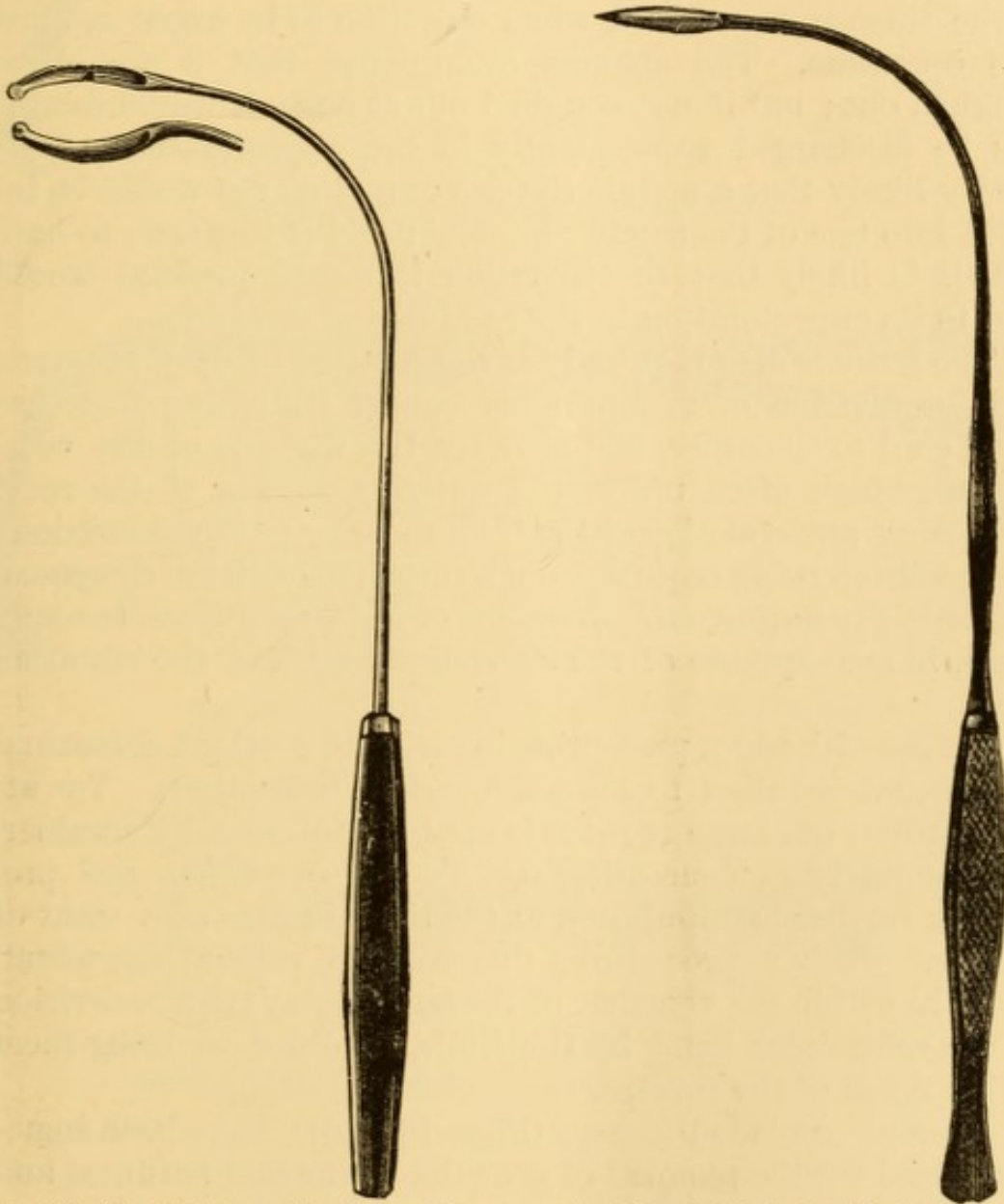


FIG. 158.—Tobold's knife, with single cutting edge (after Tobold).

FIG. 159.—Tobold's knife, with double cutting edge (after Tobold).

into the larynx, is preferred by many operators; but it sometimes hides a good view of the field of operation, in which case, if the patient is steady and the operator skilled, unconcealed knives are preferable (Figs. 157, 158, 159). The use of

the knife is also necessary, occasionally, to detach a portion of a growth at its base, in order the better to adapt it for removal with the forceps. Besides this, a minute growth on the edge of one of the vocal cords, which cannot be seized in the forceps, may sometimes be detached by piercing its base with a small lance-shaped knife, which, as it is pushed onward, severs the growth from the cord. The danger of dropping the tumor in the trachea has caused some objection to be urged against this operation. The chances are greater that it would be coughed out; but if not coughed out at once, it would doubtless be discharged subsequently in the expectoration. It is hardly likely that a nodule the size of a large pin would be inhaled into one of the smaller bronchi; and if this were to happen, it is likely that the irritation it would produce would lead to its expectoration in the products of secretion.

The knife is also required for the incision of cystic tumors, and for division of membranous bands, stretching from one vocal cord to the other, and also for the division of the commissure which often unites the anterior portion of the vocal cords after removal of growths from them by external incision; the operation being requisite, not so much for relief of dyspnoea, but rather to improve the character of the voice, which becomes shrill, in consequence of the shortened length of the vibrating reeds.

Knives with edges presenting in various directions, direct and oblique, are required to meet the various indications. The attempt to cut out large growths is apt to be followed by considerable hemorrhage, concealing the field of operation, and preventing further manipulation at the time, in case of a want of success. Such a procedure, therefore, is rather imprudent. Growths within the ventricle of the larynx may require division of the ventricular band by the knife, in order to bring them within reach of the forceps.

Scissors, or bladed forceps (Figs. 160, 161), have been sometimes used for the removal of growths of unusual hardness and favorably situated.

The use of cutting instruments entails a good deal more hemorrhage than instruments for crushing or for evulsion.

For the same purpose small guillotine knives of various forms, acting on the principle of the simple amygdalatome, have been devised by Tuerck, Stoerk, Lewin, and others; but

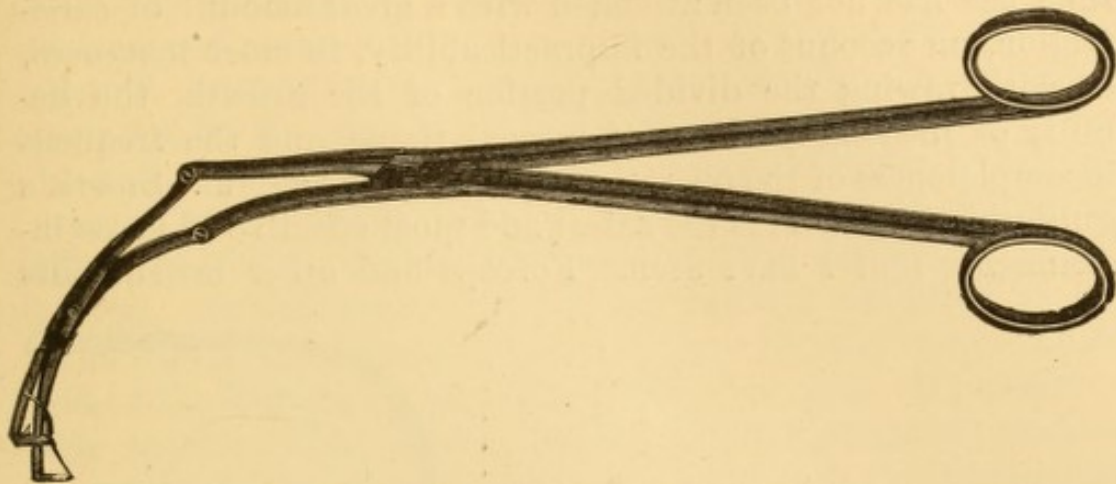


FIG. 160.—Tobold's horizontally cutting scissors (Tob

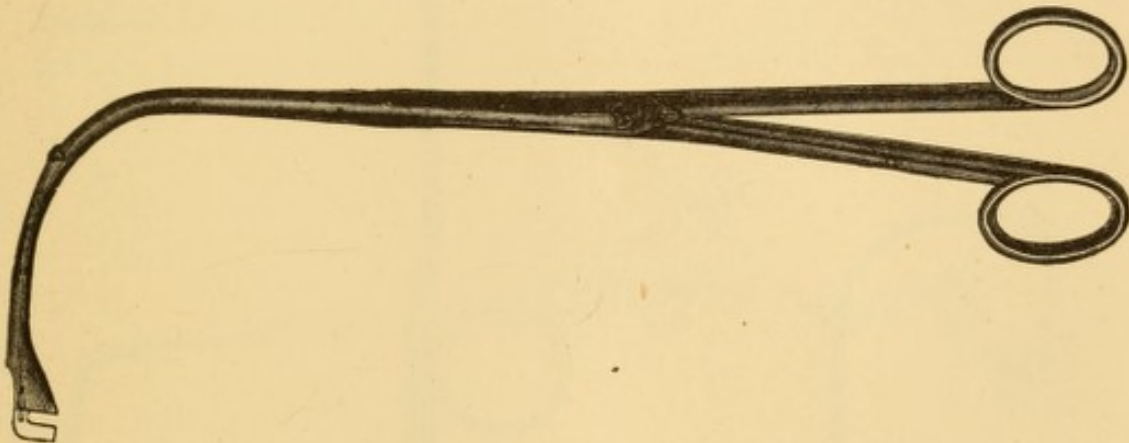


FIG. 161.—Tobold's perpendicularly cutting scissors (after Tobold).

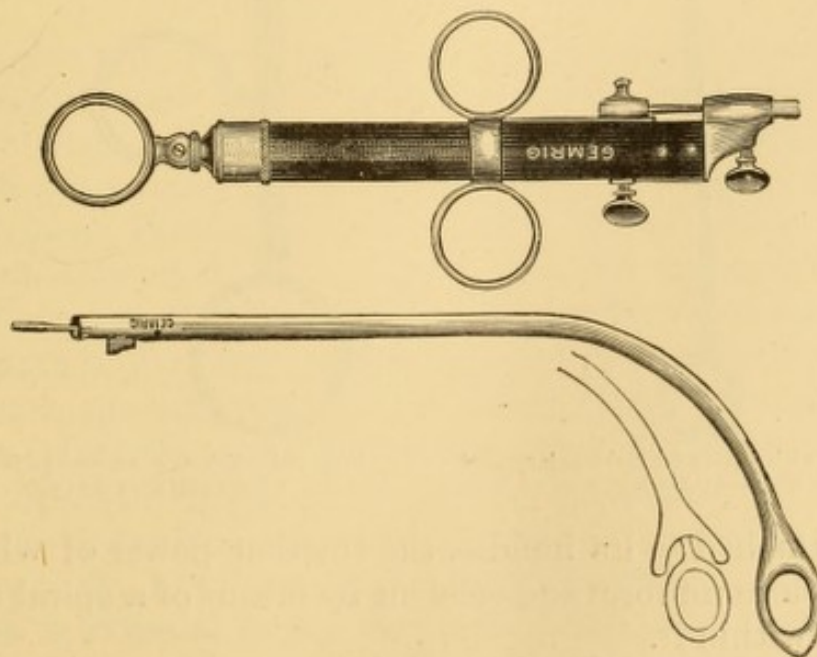


FIG. 162.—Stoerk's universal handle for guillotine, etc., with two forms of the guillotine shown below.

their use has not been attended with a great amount of satisfaction, on account of the impracticability, in most instances, of withdrawing the divided portion of the growth, the liability of incising portions of normal tissue, and the frequent incompleteness of the operation even when successful. Stoerk's guillotine (Fig. 162) is the safest and most effective of these instruments that I have seen. Forceps and other instruments

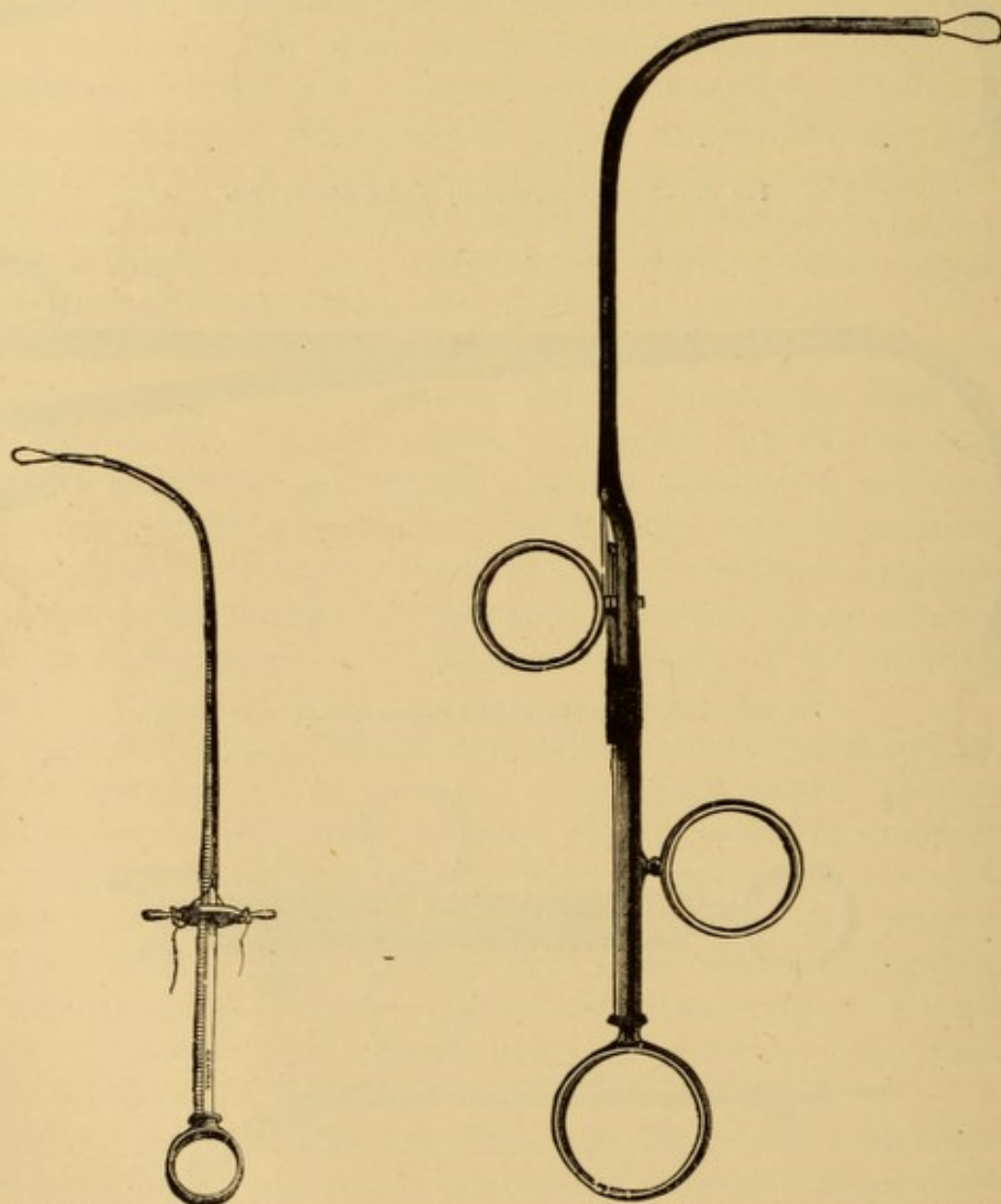


FIG. 163.—Gibb's wire-snare for dividing laryngeal growths (Gibb).

FIG. 164.—Tobold's wire-snare for dividing laryngeal growths (Tobold).

may be attached to its handle, the traction power of which is rendered more uniform and efficient by means of a spiral spring concealed within it.

In cases of small growths favorably situated, Dr. Macken-

zie prefers the use of rigid loops or rings of wire of various shapes, and presenting at various angles to the stock, the inner edge of the ring being sharpened, so that after the growth is encircled by the ring, it can be jerked or scraped off.

Another class of cutting instruments, suitable for the removal of growths with narrow pedicles, consists in wire-snare (Figs. 163, 164), similar to those for the removal of aural polyps. An instrument of this kind was first employed by Dr. Gibb for the removal of laryngeal growths, and in his hands, and in the hands of some others, has been used with considerable success. The great difficulty in its employment consists in ensnaring the growth, and in drawing the wire evenly around its base, a nicety of manipulation which I have been unable to acquire, and which I have not attempted for a number of years. In one case, in which I succeeded in encircling a polyp satisfac-

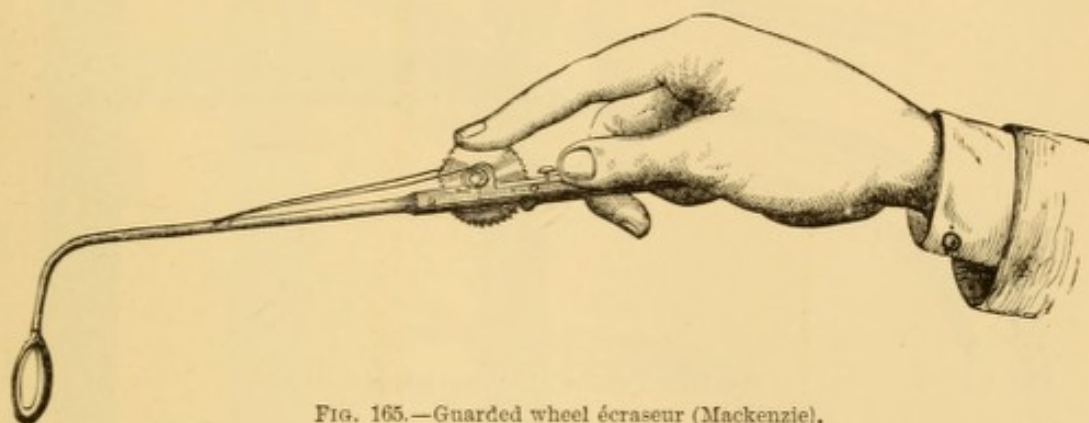


FIG. 165.—Guarded wheel *écraseur* (Mackenzie).

torily, the wire broke on drawing it home, and some difficulty was experienced in disengaging it from the growth, the wire having to be removed from the instrument for that purpose. The growth was removed subsequently with curved forceps. These instruments, though called *écraseurs*, do not act on the crushing principle of that instrument, but cut through the tumor. Dr. Mackenzie has devised a wire *écraseur*, tightened by wheel and ratchet (Fig. 165), and with which he has succeeded in removing a growth, the size of a cherry, from the under surface of the epiglottis, and another, the size of a bantam's egg, from the posterior surface of the cricoid cartilage. He states that from the slowness with which it acts it can only be used when tracheotomy has been previously performed, or where the growth is external to the laryngeal canal, and that it is only adapted to large growths. I have used it successfully without

the ring in removing intra-nasal tumors, but have never employed it in the larynx.

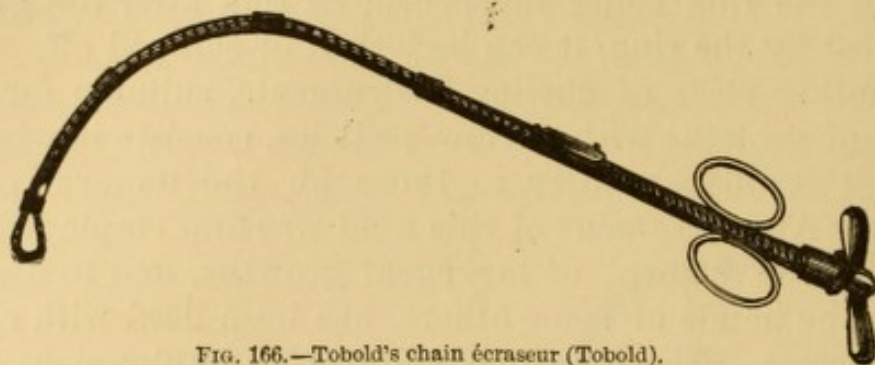


FIG. 166.—Tobold's chain écraseur (Tobold).

Tobold has constructed a real écraseur (Fig. 166), provided with a delicate chain. I have tried this instrument a few times, but failed to manipulate it with any success.

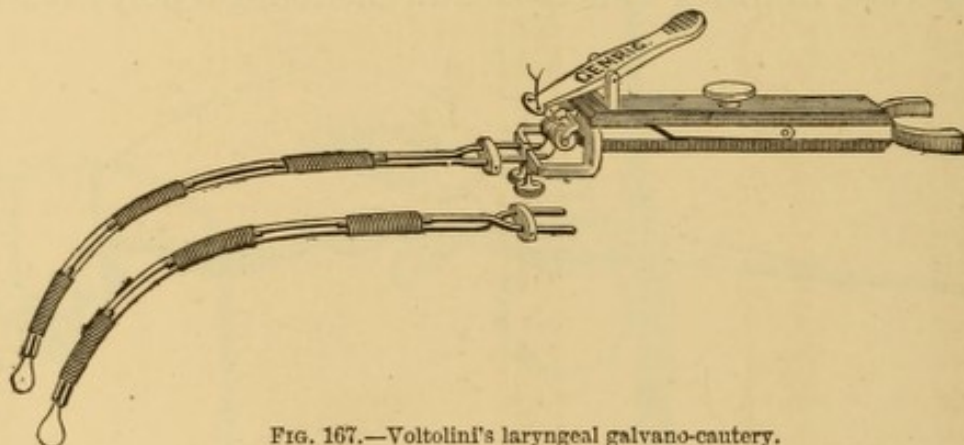


FIG. 167.—Voltolini's laryngeal galvano-cautery.

The galvano-cautery, as first suggested by Prof. Middendorpf,¹ of Breslau, is recommended for the removal or destruction of laryngeal growths, on the score of thoroughness of action

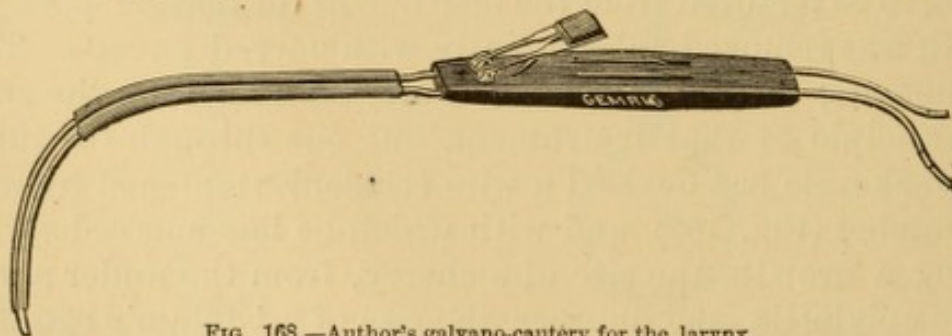
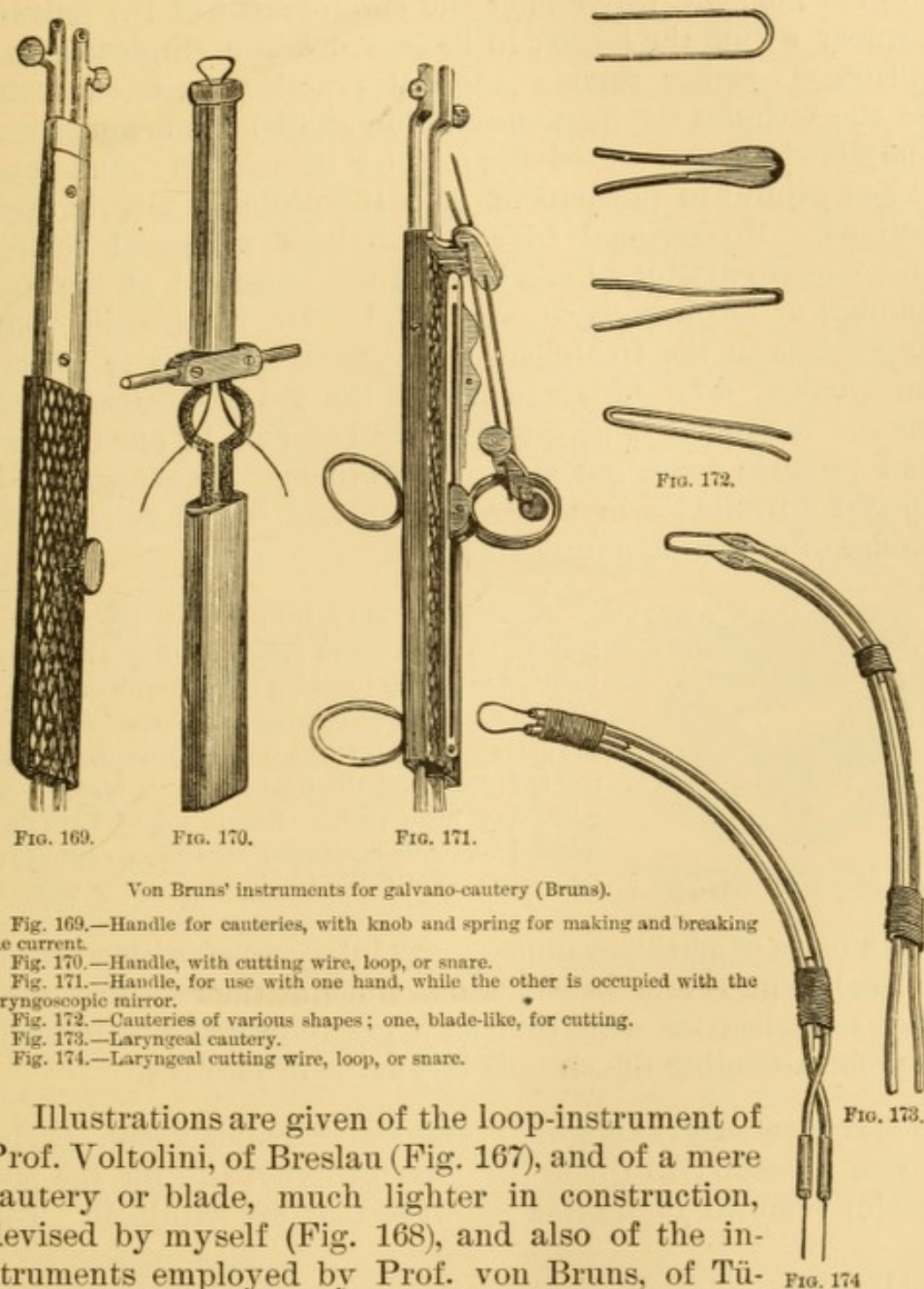


FIG. 168.—Author's galvano-cautery for the larynx.

and slight risk of hemorrhage, the tumor being cut through by means of a loop or blade of platinum or iron heated to a white heat by the electric current. The loop is passed around the

¹ Die Galvanokaustik, Breslau, 1854.

growth, and drawn tightly, the same as for removal by the wire-snare or *écraseur*, and then, the current being passed through it, the growth is gradually constricted until it is cut through, and usually comes away attached to the instrument. In using the caustic blade, it is pressed through the growth.



Von Bruns' instruments for galvano-cautery (Bruns).

Fig. 169.—Handle for cauteries, with knob and spring for making and breaking the current.

Fig. 170.—Handle, with cutting wire, loop, or snare.

Fig. 171.—Handle, for use with one hand, while the other is occupied with the laryngoscopic mirror.

Fig. 172.—Cauteries of various shapes; one, blade-like, for cutting.

Fig. 173.—Laryngeal cautery.

Fig. 174.—Laryngeal cutting wire, loop, or snare.

Illustrations are given of the loop-instrument of Prof. Voltolini, of Breslau (Fig. 167), and of a mere cautery or blade, much lighter in construction, devised by myself (Fig. 168), and also of the instruments employed by Prof. von Bruns, of Tübingen¹ (Figs. 169–174).

¹ Beard and Rockwell: Medical and Surgical Electricity, New York, 1871

This method of treatment has been highly extolled by Vololini,¹ Bruns,² and others; but, although often successful, the infrequency of cases requiring it, and the trouble attendant upon keeping a suitable voltaic apparatus in good order, added to the difficulty of obtaining skilled assistance at the desired moment, will render the employment of the galvano-cautery within the larynx to be regarded as a surgical accomplishment rather than a surgical practice, until such time as the technics for its manipulation shall become much more simplified. I have used the method occasionally, and found it less painful to the patient than the ordinary caustic applications. Professional friends who have witnessed some of these manipulations have been much surprised at the small amount of inconvenience occasioned. Dr. Mackenzie, whose experience in the treatment of laryngeal growths is perhaps unequalled, does not recommend the galvano-caustic treatment. He found it give a great deal of pain in one instance, and produce acute œdema in two others. He recognizes no special advantages in the treatment, and considers the other modes of operating amply sufficient.

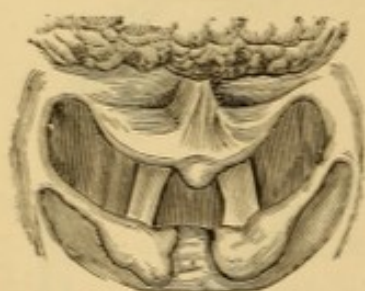

FIG. 175.—Neoplasm on epiglottis. Destroyed by galvano-cautery.

A gentleman had a little growth, probably congenital, on a depressed epiglottis (Fig. 175), which induced cough by touching the pharynx in deglutition; and, as I was making some experiments with the galvano-cautery at the time he came under treatment, I destroyed the tumor with it readily, and with very little pain. But it might have been snipped off with horizontal scissors or cutting forceps just as readily.

In cases of phthisis, unnecessary interference with a growth in the larynx is reprehensible, inasmuch as the resulting ulcer may not cicatrize, and this may precipitate the unpleasant sequelæ attending the chronic laryngitis of phthisis.

Laryngotomy.—Under exceptional circumstances, it becomes necessary to divide the larynx externally for the successful removal of morbid growths that are within it. This

¹ Die Anwendung der Galvanokaustik im Innern des Kehlkopfes und Schlundkopfes, Wien, 1867.

² Neue Beobachtungen von Polypen des Kehlkopfes, Tübingen, 1868; Die Galvano-Chirurgie, Tübingen, 1870.

necessity may be due to the position of the growth, rendering it inaccessible to intra-laryngeal manipulation; to the great size of the growth and the danger of hemorrhage in its extraction; and to malignancy. A malignant growth, no matter where situated, if at all submitted to operative procedure, should have such direct access to instruments, that, in the language of Prof. Gross, "the very atmosphere of the morbid mass may be removed," and this requires dissection, which cannot be practised with instruments adapted to laryngoscopic surgery.

The division of the larynx may, or may not, be preceded by tracheotomy.¹ When the growth is small, or even when it is large, and the probabilities are that, after splitting the larynx, the operation for removal of the growth would be a simple one, such as strangulating or cutting out a tumor without ramifying adhesions, so that a comparatively slight amount of injury would be inflicted upon the intra-laryngeal structures, the larynx may be safely opened at once, without previous tracheotomy. When, on the other hand, a great amount of injury of this kind is anticipated—injury which would lead to a good deal of inflammation—it is better to perform tracheotomy a few days in advance, in order to facilitate respiration, and secure rest to the injured parts subsequently.

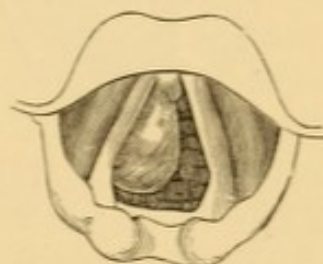


FIG. 176.—Fibroma on right vocal cord. Removed after thyrotomy, without tracheotomy.

A man, aged twenty-six years, and a subject of phthisis, had a fibroma attached to the right vocal cord (Fig. 176), for the removal of which I divided the larynx without having performed tracheotomy. Dyspnœa, on account of which the operation was performed, was relieved; but, although the growth was favorably situated, and the vocal cords were uninjured in the operation, the aphonia existing prior to the operation persisted after it. A detailed account of this case has been published elsewhere.²

I removed a large epithelioma from the left vocal cord and ventricle, as well as two much smaller growths from the right vocal cord, of the larynx of a young gentleman after the previous performance of tracheotomy. The appearance of the growth at the time of the operation (Fig. 177), the appearance of the larynx

¹ Dr. Ephraim Cutter, of Boston, was, I believe, the first surgeon to perform this operation without recourse to tracheotomy. He has published an account of nine cases of the kind, in a pamphlet entitled "Thyrotomy, for the Removal of Laryngeal Growths, Modified," Boston, 1871.

² The Medical Record, 1867, Vol. IV., p. 218.

a few months after the operation (Fig. 178), and the appearance of the parts nearly four years after the operation (Fig. 179), are well shown in the accompanying illustrations, in the last two of which the line of the tracheal incision is distinctly seen. An important feature in connection with this case, which is reported in detail elsewhere,¹ consists in the fact that there was a reproduction of tissue in the left vocal cord, the anterior portion of which had been purposely sacrificed in the removal of the growth, and from which an expansion took place to the other cord anteriorly, as well depicted in the drawings. This case was eminently successful as to the restoration of the voice, the patient declaring that, although a little rough, his voice is as good as it ever was. This shows us that the vocal cords, or a substitute for them, can be reproduced, and seems to confirm the view that they are mere duplicatures of elastic membrane, and not special structures. Eleven years after the operation (1878) the patient's larynx did not

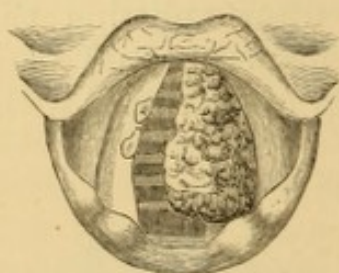


FIG. 177.—Laryngeal growths, for the removal of which thyrotomy was performed after tracheotomy.

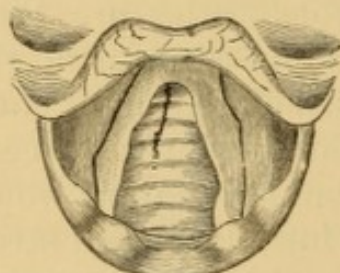


FIG. 178.—Appearance of the parts some months after the operation.

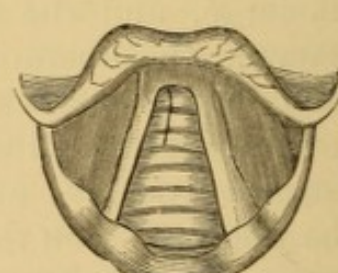


FIG. 179.—Appearance of the parts some years after the operation.

vary much from the sketch (Fig. 179); the voice was good, and his health excellent. I am now inclined to believe that the diagnosis of epithelioma was incorrect, though based on the opinion of skilled microscopists. The growths were probably papillomas. I have never had occasion to divide the thyroid cartilage since this operation, and should not have done so in this instance had the tumor not been considered an epithelioma.

In a case of epithelioma of the larynx, removed by direct attack after laryngothyrotomy, Dr. S. H. Chapman, of New Haven, removed the right vocal cord, which was the seat of the neoplasm.²

I have seen some of these operations accomplished without any difficulty, and accompanied by very little hemorrhage. Others have been attended with serious difficulties.

Section of the thyroid cartilage for removal of laryngeal growth was performed by Brauers, of Louvain, in 1833,³ by Ehrmann, of Strassburg, in 1843,⁴ by Buck, of New York, in

¹ The Medical Record, N. Y., 1867, p. 244.

² Am. Jour. Med. Sci., Jan., 1878, p. 137, illustrated.

³ Mackenzie: Op. cit., p. 3.

⁴ Laryngotomie pratiquée dans un cas de polyp du larynx, Strassburg, 1844.

1851¹ and 1861,² and quite frequently since; the recorded cases now (1878) numbering more than one hundred. The same operation had been performed, however, at a much earlier date by Dessault³ for the removal of a foreign body; and attention was called by him to the fact that a similar operation might be performed for the removal of laryngeal polyp.

In performing this operation, the patient is placed in the usual recumbent position for laryngotomy or tracheotomy, or is seated upon a chair thrown back and steadily supported, the neck being rendered prominent by being bent over some firm support. The anterior portion of the larynx being freely exposed by section of the skin and subcutaneous connective tissue, a vertical opening is made into the crico-thyroid ligament by a sharp-pointed knife, the blade presenting upward; and this may then be carried upward, separating the anterior wall of the larynx into halves, care being taken to keep the knife in the middle line, so as to avoid wounding the vocal cords. If preferred, the section of the cartilage may be made with a probe-pointed knife. The knife should be very strong; and a stout pair of angular scissors should be at hand to divide the cartilage, should it be ossified or offer much resistance to the knife. If the growth present in the line of incision, it will be very apt to be wounded and to bleed. The severed halves of the thyroid cartilage are to be held apart by strong blunt hooks.⁴ The morbid growth is then removed by forceps, knife, scissors, *écraseur*, or galvano-cautery, as may be most expedient, and the raw places cauterized with fused nitrate of silver, a comparatively strong solution of acid nitrate of mercury, or the incandescent cautery, to destroy remnants and repress tendency to repullulation. When this has been done, the wound is allowed to come together naturally, and the parts are held in position by adhesive strips externally. There is no necessity for a suture in the cartilage, or even in the skin. Some disturbance of the parts must ensue during the paroxysms of cough that usually continue for a few days after an oper-

¹ Trans. Am. Med. Assn., Phila., 1853, p. 523.

² Am. Jour. Med. Sci., Jan., 1867.

³ *Œuvres chirurgicales*, Paris, 1801, T. II., p. 279.

⁴ Dr. Cutter, of Boston, has devised a pair of double-pronged hooks, resembling a blunt pair of old-fashioned table-forks, with the terminal ends turned downward, the intention being to place one prong above a vocal cord and one below it.

ation of this kind. A simple dressing is all that is required. After the wound has been dressed, a full opiate should be administered. Liquid nourishment can usually be taken from the very first, though swallowing is sometimes difficult for a few days. Recovery is usually prompt, unless the general state of the constitution has become much impaired beforehand.

During the operation it is very essential that the blood should be promptly sopped up by small bits of sponges, securely attached to forceps, or, what is preferable, to rods of whalebone; and several of these should be at hand.

In one of my operations an assistant, excited by the spattering of the blood accompanying the spasmodic heaving of the respiration, induced in these operations by the presence of blood and the direct access of cool air, dropped a piece of sponge from the forceps, and it was absolutely on its way down the trachea in the inspiratory current, when I seized it with the forceps and extracted it. The possibility of such an untoward accident may be avoided by securing the sponge firmly and permanently to its holder.

The mere opening of the larynx is not a matter of great difficulty, but the extirpation of a tumor with safety to the integrity of the vocal cords involves a good deal of care, labor, and responsibility in cases of tumors with extensive attachments:—on the one hand on account of the spasmodic heaving of the parts at the contact of instruments, and on the other hand on account of the passage of blood into the trachea. To avoid this descent of blood into the air-passages in this and other operations where it might occur, Roser has suggested operating with the head pendent from the operating-table. Trendelenburg has devised a rubber bag which encircles the tracheotomy-tube, and into which air is forced externally, so as to convert it into an elastic tampon. Foulis uses a curved syphon-tube, the exterior extremity of which is beyond the field of operation. I have never seen any of these devices put into practice.

It is doubtful whether anæsthetics should be employed in the performance of these operations. All in which I have been interested as operator or assistant were performed under anæsthesia, the effect of which, as a rule, was very satisfactory. In one case, however, in which I was assisting Dr. Elsberg, of New York, the patient, an elderly man, nearly died from the chloroform, and after he was revived the operation had to be finished without further resort to anæsthesia. In another, occurring in Philadelphia,¹ death actually occurred from the adminis-

¹ The Medical Record, 1869, Vol. IV., p. 265.

tration of the anæsthetic. It must not be forgotten, in this connection, that if the integrity of the glottis is already compromised by the presence of a large neoplasm, there is danger of death by suffocation during the administration of an anæsthetic, despite the usual relaxing influence of such an agent. It would be well, therefore, in cases where there is any doubt as to the propriety of employing anæsthesia, to make the initial incision beforehand, inasmuch as statistics show that death is much less likely to occur when anæsthetics are administered for relief of pain, than when given for its prevention.

In all cases of intense dyspnœa threatening suffocation, connected with a growth in the larynx, laryngotomy or tracheotomy should be performed as an initial procedure, to avert death by asphyxia, even when it is practicable to extract the growth through the mouth subsequently. The danger of provoking spasm by tentative efforts is not to be underrated. In addition to this, the laryngeal or tracheal wound can be utilized for gaining access to the neoplasm. These operations of tracheotomy should be performed without resort to anæsthesia whenever the patient can be induced to submit to it. Local anæsthesia of the line of incision by ether or rhigolene spray, by ice, or by previous cauterization with carbolic acid, is sometimes practised. I have performed several tracheotomies without any anæsthesia, local or general, and the report has universally been that the pain was much less than had been anticipated.

If tracheotomy have been performed previous to the removal of recurrent or malignant growths, it would be prudent, unless strongly contraindicated, not to dispense with the use of the canula for a few months at least; and the use of the pea-valved inner tube (see under Tracheotomy) will reduce the inconvenience to a minimum. This would secure two avenues of access to the new growth, and insure freedom of respiration should the neoplasm enlarge rapidly.

Patients at a distance from medical supervision should be taught auto-laryngoscopy, to enable them to detect the first evidences of any recurrence of growth.

The comparative advantages and risks of intra-laryngeal operations, and operation by external division of the thyroid cartilage, has been carefully discussed by Dr. Paul Bruns,¹ from collated statistic records of more than one

¹ Die Laryngotomie zur Entfernung endo-laryngealer Neubildungen, Berlin, 1878, pp. 166-183.

thousand intra-laryngeal operations and ninety-seven external ones. This observer concludes substantially as follows:

Thyreotomy is not a difficult operation, nor menacing to life, but greatly endangers the integrity of the voice. It should not be performed until after failure by a skilled laryngoscopist to remove the neoplasm through the mouth. Incision of the thyroid cartilage between the vocal cords should always be avoided if possible, on account of the resultant injury to voice, and the attempt be made to get along with simple incision of the crico-thyroid membrane, or with the further division of the cricoid cartilage, and, if requisite, the upper ring of the trachea. In urgent cases threatening asphyxia, tracheotomy should be performed, and attempts be made subsequently to operate through the mouth, or if these fail, through the wound, extending the incision to the lower border of the larynx if necessary. In cases of malignant growth, carcinoma especially, either operation is injudicious.

Lateral Laryngotomy.—Luschka has described¹ a lateral thyroïdal laryngotomy for access to morbid growths situated in the ventricle of the larynx, by which injury to the vocal cord or its muscle may be avoided. I do not know that it has ever been performed on the living subject.

“The long axis of the laryngeal sac is situated at about a vertical line drawn from the junction between the first and second fourth of the horizontal interval between the superior incisure of the thyroid cartilage and its posterior border. This vertical line furnishes the direction to be given to the incision for lateral thyroid laryngotomy, which requires division of the skin, subcutaneous colli, and sterno-hyoid muscles, exposing the thyroid cartilage, which is to be split from top to bottom; or, if ossified, to be sawn through with a small, flat saw, advantageously introduced upon a grooved director which has been shoved behind the cartilage from its lower border. When the edges of the divided cartilage are held asunder with blunt hooks, the upper end of the laryngeal sac comes into view, so that no difficulty is presented in dividing its lateral wall as far as the level of the upper surface of the vocal cord.”

Supra-thyroid Laryngotomy.—The operation of supra-thyroid laryngotomy, or sub-hyoidean pharyngotomy, as it is called, is a method of gaining access to the pharynx and to the larynx by drawing the epiglottis through a wound made in the external tissues. It was first practised by Bichat² on animals, for the purpose of observing the part taken by the epiglottis in the production of voice. Its performance on the human subject was proposed by Malgaigne³ and by Vidal de

¹ Der Kehlkopf des Menschen, Tübingen, 1871, p. 18.

² Traité d'anatomie descriptive, Paris, 1819, II., p. 402.

³ Manuel de méd. opératoire, Paris, 1835.

Cassis, and was first practised on the person of an American gentleman, by Dr. Prat,¹ a French naval surgeon, stationed at the time at Papiete, the capital of Otaheite.

A fibroid tumor existed on the epiglottis, which could be felt with the finger, but it could not be extracted through the mouth. The patient, who was the subject of advanced pulmonary phthisis, suffered also from extreme dysphagia, which finally increased to veritable aphagia. There was also difficulty of breathing. The patient, who could neither eat nor drink, insisted on being relieved, and Dr. Prat operated in accordance with the directions of Malgaigne. The transverse incision, 2-3 millimetres in length, through the thyro-hyoid membrane, brought him down to the epiglottis, upon the left side of the laryngeal face of which the tumor was found. It was seized with forceps, and excised with scissors. No vessels required ligature. The edges of the wound were united by suture, and a dressing was applied rather tightly. The wound healed rapidly, and the troubles of respiration and deglutition subsided. The patient died shortly afterward from phthisis, and at the autopsy no trace of the growth was to be found.

This operation has been performed a number of times since, for removal of tumors from the larynx, by Follin,² Debron, and Langenbeck;³ by the latter on several occasions.⁴

Of six cases, the records of which are before me, three terminated fatally within a few days of the operation, and three were successful. This limited success hardly justifies its repetition for the removal of laryngeal neoplasms, especially when, as has been judiciously intimated by Mackenzie,⁵ the cases favorable for the operation are those which, as a rule, can be most easily treated through the mouth.

In performing this operation, a transverse incision, from five to six centimetres in length, is made, parallel with the lower border of the hyoid bone, dividing skin, fascia, sternohyoid muscles, hyo-thyroid membrane, and the tissues anterior to the epiglottis. The epiglottis is then seized and drawn out of the external wound, exposing the interior of the larynx. The advantages of the operation over splitting the larynx are the avoidance of injury to the cartilaginous framework of the

¹ (Gazette des hôpitaux, 1859, No. 103, p. 809) Elsberg's Prize Essay on the Treatment of Morbid Growths within the Larynx, Phila., 1866, p. 15; Mackenzie: On Growths in the Larynx, p. 98.

² Arch. gén. de méd., Feb., 1867.

³ Allg. med. Cent.-Ztg., 1870, Nos. 8, 9, 10, pp. 93, 103, 105, 115.

⁴ Idem. For more recent example, see Brit. Med. Jour., Feb. 2, 1878, p. 154.

⁵ Op. cit., p. 100.

larynx, which might eventuate in necrosis, and the avoidance of separating the vocal cords, which would eventuate in more or less vicious adhesion anteriorly, with permanent impairment of voice.

EVERSION OF THE VENTRICLE OF THE LARYNX.

Eversion or prolapse of the ventricle of the larynx has been occasionally observed,¹ the lesion having been discovered after death in two instances, with reason for believing that the prolapse had occurred in the death agony. In a case reported by Lefferts, of New York,² the lesion was detected during life, and was bilateral. There was aphonia of two years' duration, the onset of which had been sudden, followed by dyspnœa, with stridulous respiration in both phases. Two characteristic tumors protruded from the ventricles, one of which receded during the efforts of phonation. The larynx was opened by external incision of the thyroid cartilage, and the prolapsed ventricles removed with scissors. The result was satisfactory.

MORBID GROWTHS OF THE TRACHEA.

Tumors are occasionally developed in the trachea, and are sometimes diagnosed by laryngoscopy. Their existence has occasionally been determined during the operation of tracheotomy.³

Tumors in the lower portion of the larynx are liable to be mistaken for growths in the trachea. A tumor located by myself in the sub-glottic portion of the larynx, and certainly not below the cricoid cartilage, if my vision was not deceptive, was subsequently reported as occupying a position corresponding to the fourth or fifth tracheal ring.

No special symptoms of tracheal tumor could be recognized, as a rule, until the size of the growth became sufficient to produce stridor, or impede respiration. Early in its development, its existence might possibly be recognized or suspected by dry, sonorous râles otherwise unaccounted for. Tumors in

¹ See notes, p. 544.

² The Medical Record, June 3, 1876, illustrated.

³ For example, see And. H. Smith: Am. Jour. Med. Sci., July, 1876.

connection with the œsophagus would be accompanied with symptoms of dysphagia or stricture, in addition to whatever special tracheal symptoms might be present. The removal of an intra-tracheal tumor usually necessitates laying the tube open from the outside. Occasionally, however, a tumor may be removed from the trachea through the mouth, as exemplified in the following case of extirpation of a sarcoma from the trachea, successfully performed by Dr. Schroetter, in 1867.¹

The patient was a journeyman house-painter, æt. thirty-four, who had been under treatment for a long time for chronic laryngeal catarrh, with a slight cicatricial contraction of the anterior portion of the left vocal cord. Finally the laryngoscopic examination revealed the existence of a tumor (Fig. 180) upon the anterior wall of the trachea, in the region of the fourth tracheal cartilage; and in its posterior portion it seemed as broad as the dilated glottis. It was of a pale red color, covered here and there with yellowish mucus. The tumor was observed to move with forced respiration, showing that it had a pedicular attachment to the posterior wall of the trachea.

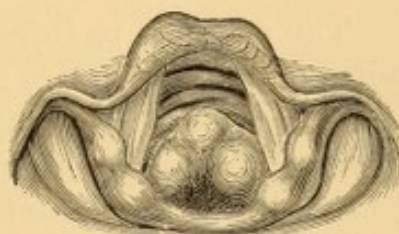

FIG. 180.—Tumor of the trachea (Schroetter).

Local anæsthesia was produced by pencilling the larynx, first with chloroform, and then subsequently, at intervals of about an hour, with a solution of the acetate of morphia—10 grains to the drachm of water.² Portions of the tumor were removed with forceps on several occasions, and finally the portion remaining was injected with a solution of the sesquichloride of iron, two parts to one of water, which produced cauterization, and shrinking of the tumor to a mere immovable stump.

It would have been a better and safer practice to have opened the trachea externally, and have removed the entire tumor at once, cauterizing the points of attachment to prevent repullulation. As a sample of pluck and patience on the part of the operator, and endurance on the part of the patient, the case is unique, and its report worth perusal by those interested. That the opinion above enunciated in the first edition of this volume was well founded, is shown by the sub-

¹ Wien. med. Jahrb., 1868, H. 1., pp. 64-72; Jahresbericht der Klinik für Laryngoskopie, Wien, 1871, p. 80; *ibid.*, 1875, p. 602; London Medical Examiner, April 4, 1878, p. 296.

² This method of inducing tolerance of the parts preparatory to operating within the larynx, though much resorted to in Germany, is not in favor elsewhere. Dangerous narcotism is sometimes produced, requiring vigorous measures to overcome it; and in some instances it has proved fatal. The elder Prof. Pancoast informed me that a result of this kind had occurred during one of his visits to Vienna, and I have been informed of others by reliable gentlemen engaged in studying the art of laryngoscopy abroad at the time. Schroetter lays down the rule: to avoid deglutition of any of the solution, and to wash out the mouth and pharynx thoroughly afterward with a gargle of a drachm each of tannic acid and alcohol to six ounces of water.

sequent history of the case. Repullulation ensued, and in December, 1869, it appeared as a new growth on the right side of the trachea. The patient avoided operative interference until December, 1870, at which time it had nearly the same circumference as at first, its attachment being visible on the posterior portion of the right side of the trachea, and on its posterior wall. Various efforts were made under local anesthesia to destroy the tumor by galvanocautery, evulsion with forceps, and injection of iron as before, but only with incomplete success, and the operations were suspended without thorough eradication of the growth.

In December, 1873, repullulation had taken place to the bulk of a hazel-nut, the tumor being immovable, and situated upon the right half of the posterior wall of the trachea. Subsequently it was again successfully removed with forceps. Recurrence is again recorded in March, 1878, the growth having been so gradual during the past four years as not to have necessitated operative procedures.

The attempt to inject iron into a growth of this kind is not without danger, for in a case of tracheal tumor occurring in a girl nineteen years of age, and similar to the case narrated,¹ an attempt by an inexperienced hand to imitate Schroetter's injection of iron terminated in the death of the patient.²

Sudden death may be produced by a tumor of the trachea, which may become detached spontaneously, or by cough, and thus occlude the glottis.³

A case of polyp of the trachea is recorded⁴ by Dr. Fifield. The patient, a female, was subject to attacks of dyspnoea, and for four days before death sat with her forehead on the back of a chair. The left bronchus was perfectly covered by a firm rosy polyp, the size of a small grape; the pedicle was attached to the trachea at the mouth of the bronchus, where it had acted as a ball-valve, permitting expiration, but preventing inspiration. The case was unconnected with any disease of the lungs.

Dr. Gibb mentions⁵ a case of cystic tumor (cyst or abscess?) on the anterior wall of the trachea, which burst spontaneously.

Prof. Tuerck⁶ has observed several cases of tumor of the trachea, some of which he discovered on the laryngoscopic inspection. One of these was associated with growths in the upper portion of the left bronchus.

¹ Schroetter : *Op. cit.*, 1871, p. 85.

² *Op. cit.*, 1875, p. 102.

³ For example see *Gaz. méd.*, 1844, p. 385, from *London Medical Gazette*; Green : *Op. cit.*, p. 30.

⁴ (*Boston Med. and Surg. Jour.*, Nov. 14, 1861.) Gibb : *Op. cit.*, p. 392.

⁵ *Op. cit.*, p. 392.

⁶ *Klinik der Krankheiten des Kehlkopfes und der Luftröhre*, Wien, 1866, p. 502, et seq.

Some cases of so-called tumors of the trachea, however, are involutions of the tube produced by the compression of tumors external to the wind-pipe (Fig. 181); others are extensions inwards of tumors from the œsophagus, the latter class of affections being usually malignant. In some instances the growth commences in the cervical glands, and thence extends into the trachea and œsophagus.

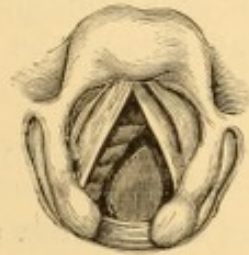


FIG. 181. — Involution of trachea by an aneurism of arch of aorta.

In a marked case illustrated in the work of Dr. Gibb,¹ the calibre of the tube was almost entirely filled by an oval tumor, an inch and a quarter in length, growing from the posterior wall and blended with œsophageal disease.

Tuerck² has recorded a marked case of involution of the trachea, with illustrations of the laryngoscopic appearances during life, and the post-mortem appearance of the parts themselves, the tumor being an involution from external pressure of a substernal cystic goitre, compressing the calibre of the trachea to a narrow slit.

In a case of aneurism in my own practice, the laryngoscopic picture (Fig. 181) looks very much like that of a tracheal tumor. The dyspnœa was intense, and the patient died asphyxiated, just after a hopeless tracheotomy had been performed to satisfy the urgent demands of the patient and his relatives. The aneurism could easily be felt through the wound.

In a case of tuberculosis already alluded to,³ I found a number of small ecchondromata attached to the cartilages of the trachea. Chiari has reported⁴ a case of osteoma in the trachea of a woman dead of acute tuberculosis, and mentions the record of one other case of tracheal osteoma.

TRACHEOCELE.

Tracheocele is a hernial protrusion of the mucous membrane between the rings of the trachea, forming a tumor externally. It is of very rare occurrence. Several instances have been related by Larrey under the title of *Aërial Goitre*. In a case re-

¹ Op. cit., p. 391.

² Ibid., p. 521.

³ Page 511.

⁴ London Med. Record, July 15, 1878.

ported by M. Devaltz,¹ of Bordeaux, the tumor was composed of two principal lobes, one passing to the right side under the muscles of the neck, and the other to the left under the clavicle.

CARCINOMA OF THE LARYNX AND TRACHEA.

Carcinoma of the Larynx occurs as a primitive product, or as an extension of degeneration of contiguous organs—œsophagus, pharynx, palate, and tongue. It is rarely consecutive, and rarely excites consecutive disease in other organs.² Cancer from extension was formerly considered more frequent in the larynx than the primitive disease, possibly as an incorrect conclusion from *post-mortem* evidences of involvement of contiguous structures; but laryngoscopic evidence *ante-mortem* has revealed primitive cancer as the more frequent manifestation, an additional verification of an observation by Virchow, that primitive cancers are especially apt to become developed at the narrowest parts of canals. The disease may be first developed in the interior of the larynx, or in its exterior wall. Sometimes it remains circumscribed, and sometimes it invades adjacent organs. It is most frequently epithelial, sometimes medullary,³ and rarely fibroid. It is more frequent in males, the statistical record being three to one in some compilations, and is most frequent between the ages of forty and sixty-five, though it has been detected at all ages, even during the first year of life⁴ and in extreme old age.

Laryngeal carcinoma is most frequently unilateral, and the left side of the body is the more frequently engaged, though both sides often become involved in advanced stages. The upper portion of the interior of the larynx is most prone to attack, the ventricular band being a favorite locality. The ary-epiglottic fold, ventricle, vocal cord, and epiglottis are likewise frequent seats of departure, circumscription to the epiglottis being occasionally encountered.

Cancer rarely remains circumscribed, and its ravages will

¹ Gaz. Hebd., June 24, 1873.

² For example see Sands: N. Y. Med. Jour., 1865.

³ Fauvel: Traité pratique des maladies du larynx, Paris, 1876, p. 689, saw sixteen cases of epithelioma and nineteen of encephaloid out of thirty-seven cases, two of which were doubtful.

⁴ For example see Dufour: Bull. de la Soc. Anat., Paris, 1865, p. 53.

destroy all the tissues of the larynx as well as those of adjacent structures. The medullary variety exhibits the greater tendency to ulceration extending into the adjoining tissues, while the tendency is greater in the epithelial form to ulcerative destruction of portions of its own mass. Exhausting and even fatal hemorrhage may ensue from the ulcerative process. Lymphatic involvements are not constant, and are more frequent in the epithelial variety.

Primary epithelial carcinoma begins in the epithelium of any portion of the mucous membrane, and penetrates the mucous membrane, submucous connective tissue, and other soft structures, down to the cartilages; destroying everything before it in its gradual extension. The dimensions attained by the tumor are not limited by the laryngeal skeleton; it may project interiorly into the pharynx, or externally beyond the neck. The cartilages undergo destruction and disintegration, and are sometimes discharged in the abscesses which form externally. When ulceration takes place, the tumor is usually covered with sanguinolent mucus and pus; and small portions become detached and are expectorated or swallowed. Though circumscribed more often than the medullary variety, it is usually diffuse, presenting first as a slight globose tumefaction of normal coloration, and subsequently as a pale, wrinkled, or more or less nodulated mass. In some instances it is apt to become overlaid with small papillomatous excrescences, which give it a characteristic appearance. Epithelial carcinoma is occasionally developed from benign growths—papilloma and adenoma, from irritation to which they are subjected in cough, or from ineffective efforts at intralaryngeal extraction; sometimes it is developed at or near the site of such growths, which have been thoroughly removed by intralaryngeal procedure or by direct access from the exterior.

Primitive medullary carcinoma is developed¹ in the submucous connective tissue, or in degeneration of the thyroid cartilage, or one of the arytenoids, and subsequently projects into the interior of the larynx, becoming exposed on degeneration of the overlying mucous membrane. When large enough to interfere with function, it presents first as a pale, sessile, globular mass, slightly irregular in outline, undergoes nodula-

¹ Rokitansky: *Path. Anat.*, III., p. 25.

tion on its exterior into a few lobes or into a number of lobules, and finally may become cauliflower-like. It is then usually soft in consistence, caseous in aspect, and grayish-red in color. Sometimes it is circumscribed in outline, and even pedunculated. It soon ulcerates, and then bleeds readily on slight provocation. As it increases in bulk, it encroaches on the respiratory calibre of the tube, and may produce the most dangerous stenosis, even when entirely outside the aërial canal.¹ On the other hand, it may displace the tongue and hyoid bone.

In both varieties, the perilaryngeal and adjacent surrounding tissues undergo tumefaction, infiltration, and discoloration, and this is followed by more or less assymetric enlargement, evident externally. Normal structures become displaced, to the serious embarrassment of deglutition and respiration, and eventually the adjoining structures—tongue, pharynx, œsophagus, and lymphatic glands, become involved. Cancerous degeneration from extension of the disease from contiguous organs is more apt to be attended with collateral local œdema, though this occurs likewise in the advanced stages of primary carcinoma.

Symptoms.—There are no characteristic symptoms in the early stage of primitive cancer of the larynx. More or less vague symptoms of catarrhal inflammation, with dysphonia, become manifested, sometimes without attributable cause, sometimes after undoubted exposure to cold, or to unusual exercise of the voice, and occasionally, as in one case in the practice of Demarquay² and in one of my own,³ after traumatic injury. Hoarseness is often the first objective symptom, and the dysphonia usually augments gradually during a series of months, sometimes amounting to two years, and sometimes terminates in aphonia. The other early symptoms are, in the main, those of mechanical obstruction within the larynx. According to the location of the disease and its increase in volume, symptoms of dyspnœa, dysphagia, and cough will gradually supervene, with more or less extensive salivation, and expectoration which becomes purulent, sanguinolent, and fetid after ulceration has

¹ Robertson : Trans. Path. Soc., London, Vol. XII. ; Gibb : Op. cit., p. 267, illustrated; the patient dropped dead in the street, on his way to the hospital.

² Blanc : Étude sur le cancer primitif du larynx, Paris, 1872, p. 57.

³ Trans. Path. Soc., Phila. Vol. VIII.

begun. The dysphagia may augment to complete aphagia, and the dyspnœa to apnœa.

It is only after hoarseness has been very persistent, and often then not until it has been followed by more or less dysphagia, or a certain amount of dyspnœa, that the patient, as a rule, is subjected to laryngoscopic examination. The dyspnœa is usually greater in inspiration, though affecting both phases. In addition to the physical production of dyspnœa, paroxysms of increased dyspnœa, and sometimes of spasm of the larynx, supervene in some instances, these seizures being more prevalent at night or during sleep. When the tumor has attained considerable size, the dyspnœa augments to approaching asphyxia, with the usual indications of insufficient oxygenation and hypercarbonization, progressive apnœa, and cyanosis; or, if there is much ulcerative destruction of tissue, the dyspnœa may diminish with the increase in the calibre of the air-passage. Emaciation, fever, and progressive marasmus soon ensue. If, as often happens, deglutition becomes impracticable, the exhaustion is still more rapid. The symptoms in the advanced stages are similar to those in severe cases of tuberculosis. Pain is sometimes severe, but rarely of the lancinating character usually indicative of carcinoma. Death may take place by asphyxia, hemorrhage, exhaustion, collapse, or pyæmia.

Diagnosis.—The diagnosis is obscure at first, though the age of the patient, in some instances, and the absence of direct evidence of other diseased conditions of part or system might excite suspicion as to the true nature of the malady. The earlier appearances are those of moderate catarrhal inflammation, with subsequent circumscribed hypertrophy of the mucous membrane. After a while a more or less regular and uncircumscribed tumor (Fig. 182) will be seen occupying some portion of the structures beneath the mucous membrane, without material alteration in the color of the overlying membrane, and with little, if any, evidence of inflammatory action around it. After a while the overlying membrane becomes nodulated, dark, sometimes irregularly vascular, and finally ulcerated at one or more points. When the larynx has become involved from extension of cancer already existing in its neighborhood,

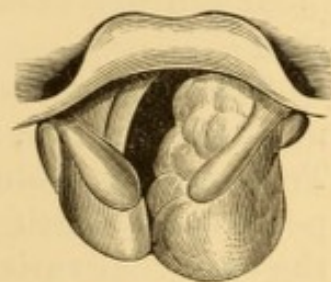


FIG. 182.—Medullary carcinoma in early stage. From a patient æt. 70.

there will be little difficulty in diagnosis. There is little difficulty, either, in diagnosing primitive laryngeal cancer in its advanced stages when the characteristic irregular, nodulated, variegated, vascular, and sometimes ragged, aspect of its surface, the tumefaction or actual cancerous involvement of neighboring lymphatic glands, the occasional hemorrhages, the cachectic expression of countenance, perhaps the existence of the characteristic shuttle-like pains of carcinoma, and the history of the case could hardly leave any doubt as to its nature. Even this doubt could be cleared away by microscopic examination of fragments of the growth detached and coughed up, or pulled off for the purpose. The laryngoscopic appearances vary from time to time with the extension of disease, the expectoration of fragments, etc., so that the case cannot always be recognized at long intervals from the laryngeal image alone.

Discrimination between medullary and epithelial cancer is impossible in the earlier stages. After the development of vegetations on the surface of an epithelial cancer this differential diagnosis is practicable.

In the ulcerative stages of intra-laryngeal cancer of small dimensions, or cancer of the epiglottis, the disease is liable to be mistaken for syphilis, and, to a less degree, for tuberculosis.

Prognosis.—This is unfavorable. Excision or destruction of the mass is almost inevitably followed by recurrence; even total excision of the larynx offering little prospect of immunity therefrom.

Death may take place by asthenia, asphyxia, or hemorrhage.

The average tenure of life is greater in epithelial than in medullary cancer, the period varying from two to four years. Tracheotomy prolongs life for a few months by averting or postponing death by suffocation, the period being longer in the epithelial variety than in medullary carcinoma.

Treatment.—Treatment can only be palliative as regards the local manifestations, the systemic treatment being similar to that for cancer in general. In the earlier stages cautious use of the voice and abstinence from all measures calculated to react injuriously on the larynx are indicated. The local and general treatment is that applicable to the grade of inflammatory action apparent. The internal use of small doses of arsenic (one-twenty-fourth of a grain of the acid, or its equivalent in

some other preparation) is advisable, as there is presumable evidence that this remedy exerts some restraining influence on the extension of cancer. Ergot may be used likewise for its effect in contracting the blood-vessels; and it becomes prominently indicated, at a later stage, when hemorrhages supervene. Pain may be alleviated by anodyne inhalations. Ulcerations are sometimes rendered less painful and irritable by the local application of weak solutions of nitrate of silver (ten to fifteen grains to the ounce). Hemorrhages may be restrained by inhalations of sprays of solutions of iron (a few drops of the tincture of the chloride to the ounce of water) or of ergot (one to ten minims of fluid extract to the ounce of water). Aromatized sprays are good likewise to cleanse the parts of mucus and pus, and may be used for this purpose several times a day; and if the exhalations are fetid, a little tannin, carbolic acid, thymol, or permanganate of potassium may be added.

Dyspnœa is treated by rest, and such local measures as are applicable to similar physical conditions occasioning it in other diseases. When semi-detached portions of tumor impede respiration, they may be removed with forceps, and the parts cauterized. Under other circumstances mechanical interference of this kind is to be avoided. When threatening asphyxia, tracheotomy is indicated; and this operation should be performed low down, so that the wound shall be at a distance from the disease, on account of its likelihood to direct involvement by extension of the morbid process.

Dysphagia is treated by the use of semi-fluid or fluid food. When deglutition is impracticable, alimentation per rectum is required; and it is good practice to resort to this occasionally before it is absolutely necessary, in order to accustom the system to that mode of nourishment, as well as to give the diseased structures consecutive rest from efforts at deglutition, for hours together. If the dysphagia is due to an enlarged and ulcerating mass of epiglottis, the offending portion may be removed with cutting-forceps, an operation which in one of my cases was followed by great amelioration of this symptom, and consequent temporary invigoration of the system; and without any subsequent unpleasant results. Exsection of large portions of the larynx, and even its entire ablation, have been successfully practised for temporary relief; but the propriety of these two measures is still undetermined.

Carcinoma of the trachea is very rare. Primitive cancer has been observed.¹ It is sometimes associated with primitive cancer of the bronchi.² It usually commences in the soft tissues in the interior of the tube, beginning near the cricoid cartilage or near the bifurcation, and eventually involves the cartilaginous framework. As examined post-mortem, the appearances are similar to those described in connection with cancer of the larynx.

Symptoms.—There would be few symptoms until the cancerous mass became large enough to obstruct respiration, when the symptoms would be those of tracheal stenosis. Previous to this, cough, expectoration, and occasional dyspnoea occur, according to the location, condition, and size of the mass. If the cancer invades the larynx or œsophagus, the symptoms referable to involvement of these structures become super-added.

Diagnosis.—Symptoms of stenosis, in connection with manifestations of cachexia, might lead to correct surmise as to the existence of cancer of the trachea, but unless so located as to be accessible to laryngoscopic inspection, only the microscopic examination of expectorated fragments could establish the diagnosis with certainty.

Prognosis.—The disease is necessarily fatal. Death may occur by hemorrhage, perforation, asthenia, or asphyxia.

Treatment.—Palliative measures, by inhalation and otherwise, are all that can be attempted, the usual efforts being made to keep the general system in as good a condition as possible. Surgical relief is out of the question.

STENOSIS OF THE LARYNX AND TRACHEA.

(Stricture of the Larynx and Trachea ; Constriction or Compression of the Larynx and Trachea.)

Stenosis of the larynx or trachea implies more or less occlusion of the calibre of the tube, productive of dyspnoea, sometimes to so great an extent as to threaten death by apnoea or asphyxia. It may be confined to either larynx or trachea, or

¹ For examples see Schroetter : Op. cit., p. 86.

² For examples see Langhans : Virchow's Arch., 1871, p. 470.

involve both structures. The cause of the occlusion may be within the air-tube, in its walls, or outside of it. Obstruction within the tube may be the direct or remote result of inflammatory processes, of whatever origin, or may be due to hypertrophy of tissue, morbid growth, or foreign body. Obstruction from without may be due to external compression from abscess, aneurism, morbid growth, or foreign body. Many of these causes are discussed under individual headings.

Stricture of the Larynx and Trachea.—Stricture of the larynx may follow chondritis or perichondritis, whether hyperplastic or necrotic. It may be due to organization of effused products of inflammation, cicatricial constriction of ulcers, or losses of tissue from wound or injury. It may likewise be due to vicious adhesions of adjacent intra-laryngeal structures (vocal cords, ventricular bands, etc.), whether the result of disease or injury, or even to vicious adhesions of peri-laryngeal structures, the result of injury.¹ It is most frequent as a result of syphilitic inflammatory processes, but occurs in tuberculosis, also, and is sometimes due to the local lesions sustained in diphtheria, typhoid fever, small-pox, and measles. Stricture of the trachea is most frequently the result of vicious cicatrization of syphilitic ulcers. It is not infrequent near the bifurcation, and thereby beyond the reach of remedy,² but occurs likewise, high up, even just below the larynx.³

Symptoms.—These may be summed up in mechanical impediment to respiration, varying in degree, urgency, and noisiness with the extent, firmness, and location of the stricture. Inspiration is usually prolonged and stridulous. Phonation is not necessarily affected, but may be impaired even when the stricture is in the trachea. Deglutition is sometimes impeded

¹ For examples see case of complete stenosis of larynx beneath the vocal cords, from cutaneo-pharyngeal membranous partition formed during cicatrization of a suicidal wound. Reynaud : Journ. univ. et hebdom. de méd. et de chir. prat. etc. Vol. III., 1831, p. 201. Bourget : Thèse de Montpellier, 1844; Arch. gén. de méd., Dec., 1845.

² For examples see Chaissaignac : Schmidt's Jahrb., Bd. 102, p. 98; Vigla : Idem, p. 100; Dittrich : Quoted by Virchow, Arch. XV., p. 308; Mackenzie : Med. Times and Gaz., Mch. 11, 1871, p. 293; and others referred to in Merkel's excellent report on laryngoscopy; and by Trendelenburg : Arch. klin. Chir., 1872.

³ For examples see Virchow : Loc. cit.; Wilks : Schmidt's Jahrb., Bd. 123, p. 178; Semeleder : Ibid., Bd. 134, p. 118.

when the uppermost portion of the larynx is involved. The dyspnœa is eventually followed by insufficient aëration of the blood and its usual manifestations.

Diagnosis.—The previous history of the case and the manifestations of dyspnœa indicate the character of the affection, which is confirmed by auscultation and inspection. Laryngoscopy usually reveals alterations and adhesions encroaching upon the calibre of the tube. There is manifold variation in the character of the stenosis. Sometimes the vocal cords are more or less adherent; sometimes the ventricular bands, or the inner surfaces of the arytenoid or supra-arytenoid cartilages; sometimes the epiglottis is adherent to the aryteno-epiglottic folds, and so on. Sometimes the stricture is due to submucous infiltrations, sometimes to hyperchondrosis, and sometimes to two or more of these conditions.

Tracheal stenosis cannot always be detected laryngoscopically, but its existence is inferable from previous history, absence of laryngeal stenosis, and lack of evidence of external compression on auscultation, percussion, and palpation. Exploration with sounds and bougies assists in determining the extent of stenosis, and is sometimes the sole means of detecting tracheal stenoses.

Prognosis.—Stenosis of the larynx—constitutional condition being favorable—presents a good prognosis as to life, provided that an artificial opening is made below the seat of obstruction. In very favorable cases the stenosis may be overcome by systematic dilatation and other local treatment; but the permanent retention of the tracheal canula is necessary in most instances, as the tendency to reproduction of the stenosis is sometimes insurmountable. Tracheal stenosis offers an unfavorable prognosis in all instances when situated below a point at which tracheotomy can be made available, inasmuch as tracheal stricture is hardly ever susceptible of dilatation. When high up, respiration can be secured through an artificial opening.

Treatment.—Stenosis so great as to cause intense dyspnœa usually requires an artificial opening into the air-passage, below the seat of stricture, with permanent retention of the canula. Attempts at systematic dilatation, previous to the introduction of laryngoscopy, and even for some considerable time afterward, were practised from below upward, through

the tracheotomy-wound—a procedure occasionally crowned with success.

In a remarkable case under the care of Mr. Liston,¹ the dilatation was commenced with bougies no larger than darning-needles, and was eventually concluded by the retention for fifteen days of a tube equal in diameter to that of the largest œsophageal tubes; and success followed, despite a second temporary tracheotomy, which became requisite the day after closure of the original artificial opening.

In some cases a second canula was passed into the larynx, through a fenestrum in the first one, and allowed to remain for a variable period. This, of course, prevented use of the voice for a time; but the ingenious artificial vocal apparatus has recently been adapted to cases of stenosis, and might supplement the normal voice during the treatment.

Dr. Wegner, of Berlin,² has successfully adapted an artificial vocal apparatus to the larynx of a female child, eleven years of age, in whom cicatricial closure of the trachea, with complete destruction of the vocal cords, had followed an attack of diphtheria four years previously. When admitted to hospital, she was wearing a tracheal tube, and was quite voiceless. The laryngeal passage was made pervious by laryngotomy and the use of bougies. The apparatus, with which she could speak easily and distinctly, differed from Gussenbauer's in the absence of the tongue-shaped epiglottis, and in being so constructed that the voice-tube was introduced first, and the tracheal tube afterward.

Since the introduction of laryngoscopy, various intra-laryngeal operations have been performed previous to the dilatation, for the purpose of relieving adhesions or removing redundant tissue, by knife or galvano-cautery, as most available. After such operations, dilating forceps are introduced through the mouth, and the parts kept asunder for a few moments, and then stretched. I have used a bivalve-forceps, separating posteriorly with scissor-like movement, each blade the length of the normal glottis; and have even used large-sized polyp-forceps for the purpose. Then hollow dilators are introduced for short periods (a few minutes to half an hour) two or three times a day. In some instances the dilating tubes have been allowed to remain for several hours or for several days; but there is great difficulty in their use, on account of the trickling of saliva down their sides into the larynx. Trendelen-

¹ Edinb. Med. and Surg. Jour., 1828, Vol. XXIX., p. 118.

² London Medical Record, June 15, 1878, p. 269.

burg has in great measure obviated this difficulty by substituting small segments of dilators, secured by a strong thread, which is allowed to protrude from the mouth, and which is less liable to excite salivation, in the first instance, or conduct as great a quantity of fluid into the larynx, in the second.

When the dilatation is well advanced, a valved tracheotomy-tube is substituted for the plain canula, so as to encourage expiration through the natural passage, instead of the artificial one. If this goes on well, the tube is occluded after a while, and both phases of respiration carried on through the natural passage. If this, too, goes on well, the tube is withdrawn for a few minutes every few hours, and after a while for a few hours every day, until it is evident that respiration can be effectually carried on in the normal manner; and then the tube is permanently withdrawn, and the artificial opening allowed to contract without aid or interference. It often happens that respiration becomes impeded in a few days after withdrawal of the tube, so that the old incisions have to be reopened and the tube reinserted; but in a few days it may be withdrawn again, and perhaps permanently. Meanwhile dilatation by bougies or tubes is continued daily by the patient, who should be taught the manœuvre, which requires prolonged continuance to prevent reconstriction of the passage. It is generally useless to employ dilatation if the constrictions or adhesions have not been previously relieved by the knife or cauter; for the parts are elastic, and, though they may be stretched by the introduction of a bougie, they contract again immediately on its withdrawal, or soon after.

Of late, however,¹ and chiefly through the labors of Prof. Schroetter, of Vienna, systematic dilatation of the strictured larynx has been sufficiently successful in some instances to justify abandonment of the canula, and closure of the artificial opening;² and even to overcome some cases of stenosis without necessity for resort to an artificial opening at all. Schroetter's method of dilatation is as follows: He begins by accustoming

¹ Schroetter: *Laryngologische Mittheilungen*, Wien, 1875, p. 32; and *Beitrag zur Behandlung der Larynx-Stenosen*, Wien, 1876, illustrated. Trendelenburg: *Arch. klin. Chir.*, Bd. 13, 1872, p. 334. Labus: *Il cateterismo e la dilatazione meccanica nelle stenosi della laringe*, Milano, 1876.

² Some of Schroetter's recent cases were exhibited before the Imperial Society of Vienna: *London Med. Record*, June 15, July 15, 1878.

the parts to the presence of a catheter or sound, to which efforts the first few days (3-8) are devoted. He then removes the canula, and inserts a catheter through the constriction, within which it is allowed to remain until it becomes necessary to replace the tracheal canula (5-30 minutes). As soon as a No. 15 catheter can be introduced, he begins with special graduated dilators of rubber or pure tin, of the triangular shape of the normal orifice of the open glottis, and with rounded corners. A series of twenty-four tin bougies are used, four

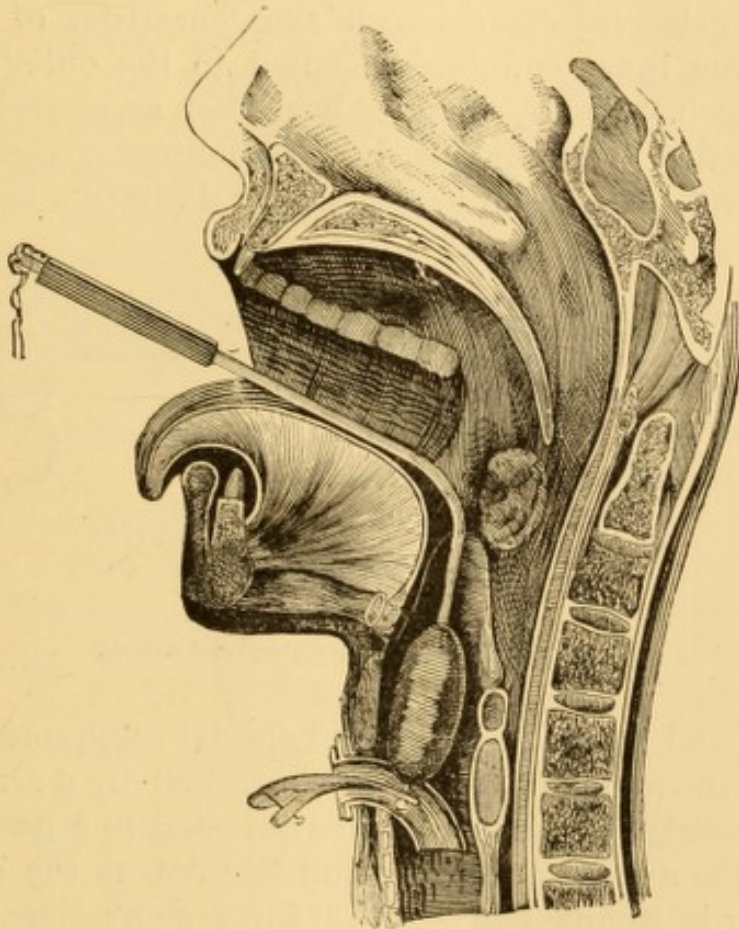


FIG. 183.—Schroetter's method of dilating stenosis of the larynx (Labus).

centimetres in length, and graduated in bulk from six to sixteen millimetres. A brass rod passes through the centre of each bougie, with an eye above for affixing a thread, and a small knob below for securing it in position, by means of a perforated spring forceps inserted within the tracheal canula, through a fenestrum in which the knob projects for the purpose (Fig. 183). The bougie is placed in position by means of a special canulated laryngeal director, through which the

string is passed, and which is removed as soon as the bougie has been secured in the grasp of the forceps. These bougies are allowed to remain night and day until removal is necessary to cleanse them, or it becomes advisable to replace them with larger ones. The forceps is withdrawn when the bougie is to be removed, and it is then extracted by means of the string, which has been secured externally. More recently the bougie has been secured in place by means of a special inner canula, which is short, and provided superiorly with a rod or staff, which passes through a perforation in the lower portion of the bougie, which projects through the fenestrum of the outer canula. The inner canula is secured to the outer one by a bayonet-catch. Hollow bougies have been suggested, to facilitate respiration in the direction of the normal channel, during the treatment. In order to render the dilatation more rapid,

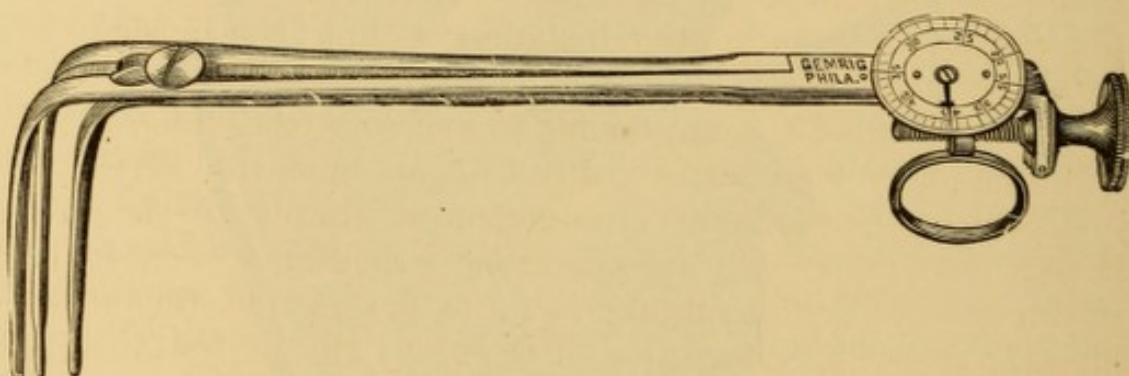


FIG. 184.—Mackenzie's dilator for laryngeal stenosis.

Schroetter and others have devised special mechanical dilators (Fig. 184), the action of which is controlled by a screw movement externally, which is likewise adjusted to a gauge, which indicates the amount of dilatation secured at the other end. The dilator is retained in position for a short time, and then replaced by a bougie of corresponding calibre, which is secured in the canula. These dilators are by no means well borne, and it is still uncertain whether they really hasten the cure.

When the dilatation is complete, the external wound is closed, and retraction prevented by the retention daily, for from fifteen to thirty minutes, of curved tubes of hard-rubber, the laryngeal portion of which has the same shape as the tin bougies, and the horizontal portion protruding from the mouth is furnished with a curved offset presenting downward, so that mucus and the like shall not be coughed into the face of the

manipulator. Patients are said to soon learn to introduce these for themselves.

It takes a very long time—from six to eighteen months, or longer—to overcome laryngeal stenosis by this method of dilatation. I have never been able to induce a patient to place himself under my care with such an uncertain prospect before him, and therefore lack personal experience in the procedure. A number of cures have been reported by Schroetter and a few others, and a larger proportion of cases rendered much more comfortable, though unable to dispense with the canula altogether, despite ability to breathe with its orifice occluded.

In cases due to adhesions of parts, or to membranous extensions between them, the dilatation, as already intimated, is preceded by division of the occluding tissues with knife or incandescent cautery. Sometimes this is not done until after preliminary tracheotomy; but the treatment may be conducted to a successful issue in some instances without the presence of an artificial opening.¹

In cases where it is impossible to overcome the stenosis, and in which the voice is irrevocably lost, an operation might be justifiable, under suitable circumstances, simply to clear the larynx for respiratory purposes alone—dividing it externally, raising the mucous membrane as far as practicable, then stripping the offending structures off clear to the perichondrium, and replacing the mucous membrane. Even an artificial vocal apparatus might be introduced, so that the loss of voice, though irrevocable, might not be irretrievable.

Constriction of the larynx and trachea from external compression, when not accidentally due to a foreign body in the pharynx or œsophagus, is usually produced by cervical or mediastinal tumor, goitre being a not infrequent, and in some countries by far the most frequent, cause. A special form of constriction of the glottis is due to paralysis of its dilator muscles (see Neuroses of the Larynx). The pressure of a cervical tumor occasionally produces serious occlusion of the calibre of the larynx, sufficiently at times to produce death by asphyxia.

¹ For examples, see Schnitzler: *Wien. med. Presse*, 1867, No. 5; Stoerck: *Wien. med. Woch.*, 1867, No. 48.

A married female applied at my clinic with intense dyspnœa, augmented at intervals to impending suffocation, as narrated by herself and relatives. A nodulated tumor of the bulk of a child's fist existed high up on the right side of the neck. Laryngoscopic inspection revealed the right side of the larynx pressed so much upon the left as to leave but a very limited space for respiration, the whole larynx being pushed very much to one side. The interior was normal, save for slight hyperæmia. Tracheotomy was advised and entertained, but was postponed on account of insufficiency of light, as the dyspnœa was not excessive at the moment, and the patient was put to bed for a few days, during which the dyspnœa moderated to such a degree that she was dissuaded from undergoing the operation. Death from suffocation was reported not long afterward.

Constriction of the trachea, produced by pressure of aneurismal or other tumors on its exterior, is to be carefully discriminated from stricture of the tube, the result of disease of the trachea itself.

The main sources of constriction are aneurisms of the aorta, cervical abscess, enlarged lymphatic glands, and other cervical tumors, benign and malignant, goitrous and other tumors of the thyroid gland, and intra-thoracic growths.

Symptoms.—The symptoms of compression thus exercised are those of impeded respiration, in marked cases amounting to dyspnœa, with prolonged inspiratory stridor, and in severe cases proceeding to asphyxia. In some cases paroxysms of suffocation are frequent and prolonged.

Diagnosis.—The existence of a tumor in the vicinity would lead to the suspicion of compression of the trachea, if dyspnœa were present. Still, this symptom might exist as the result of compression of the nervous trunk, independently of any mechanical interference with the trachea. Compression of the main nerve, or of the inferior laryngeal fibres, would in like manner entail aphonia, a condition which may therefore coexist as a symptom of compression upon the trachea from the outside. External tumors are detected by inspection and palpation; intra-thoracic tumors by auscultation and percussion of the chest. The blocking of the calibre of the trachea by the encroachment of the tumor can often be distinctly observed in the laryngoscopic mirror, and this is the most accurate guide in the diagnosis. Tuerck¹ mentions several cases of this kind, and depicts the images seen in the laryngoscopic mirror. In a case of acute bronchocele examined laryngoscopically by

¹ Op. cit., p. 507 et seq.

myself,¹ the inward bulging of the tracheal wall, principally on the left side, was distinctly visible, although the tumor was larger externally on the opposite side; and this observation was confirmed by the post-mortem examination. The action of the glottis during the paroxysms of excessive dyspnœa, as I have seen it in several instances, is spasmodic. It does not close, but remains more or less widely open, and an additional spasmodic dilatation takes place with each inspiration; and if this is forcible, the vocal cords vibrate in the effort. The whole interior of the larynx seems stretched to its uttermost, as by some encircling external force, the epiglottis thrown stiffly up, the ventricular bands retracted, the ventricles prominent, the vocal cords tense, and the opening of the glottis sufficiently dilated to expose the tracheal rings (Fig. 181 *bis*). In instances where there is infiltration into the connective tissue, as is sometimes the case, this extreme dilatation cannot occur. Still, the effort made by the parts to give as much room as possible for the inspiratory current, is very marked.

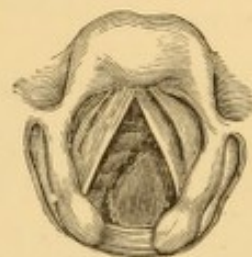


FIG. 181 *bis*.—Involution of trachea by aneurism of the arch of the aorta. Extreme dyspnœa.

In the case illustrated I was called in an emergency to a male patient in the pangs of a suffocative paroxysm, concerning the previous history of which I could get no information. It was impossible to determine the nature of the obstruction, which, from its position on the left side and low down, was presumed to be aneurism of the arch of the aorta; but in order to give the patient the chance of relief in case of its being something else, and located sufficiently high to insert a canula below it, tracheotomy was performed low down, and without an anæsthetic. The dyspnœa was not relieved. The obstruction could be felt by inserting the finger through the wound, but there was no way of overcoming it. The patient died asphyxiated on the table, shortly after the operation. A subsequent history from the attending physician revealed the diagnosis of aortic aneurism. A post-mortem examination was not allowed, but permission was given to enlarge the opening in the tissues sufficiently to insert the forefinger with ease, and the obstruction was distinctly felt a little below the supra-sternal notch. The sketch was made from memory a few hours after.

Prognosis.—This depends on the nature of the cause, and its susceptibility to arrest, retrogression, or cure. Constrictions high enough to admit of the insertion of a canula beneath them, hold out a prospect of prolonging life until further

¹ John B. Roberts: Am. Jour. Med. Sci., Oct., 1876.

threatened by the progress of the disease. In constrictions low down and beyond the reach of an artificial opening, death by apnœa or asphyxia is often inevitable.

Treatment.—The treatment must be directed to the cause as almost the sole means of remedy. It is only when the constriction is situated comparatively high up in the trachea that any prospect of relief is offered in the operation of tracheotomy.

Constriction of the trachea, of an entirely different nature, sometimes exists, and may be mistaken for constriction from a tumor whose presence cannot be determined. For a knowledge of this affection we are indebted to Dr. S. Scott Allison,¹ who has pointed out a condition of the trachea giving rise to suspicion of tubercle of the lung, and involving the form and calibre of the trachea, and which has received little notice from pathologists. This condition he describes as one of constriction of the tube immediately above its bifurcation. The extent of narrowing varies, but is very manifest to the eye in many cases. It affects the whole circumference of the tube, and does not proceed from projections at particular spots. The cartilages remain of normal length, the soft parts of the posterior wall only being reduced in breadth. This is very obvious, and depends usually on undue muscular contraction. No morbid lesions are found, saving narrowing and over-vascularity, and some thickening of the mucous membrane; the calibre of the narrowed part being unduly less than that of the trachea in its upper part. A similar condition of the trachea is mentioned as occurring in the latter stages of pulmonary tuberculosis.

Symptoms.—These are described as difficulty in both inspiration and respiration, with auscultatory constrictive phenomena at the sternum, great sense of oppression in the region of the sternum and adjacent parts of the chest, liable to exacerbation on exposure to cold, and on occasions of increase of vascular congestion, or of spasmodic action. It may give rise to emphysema.

Prognosis.—This affection is regarded by Dr. Allison as comparatively safe and generally local, despite its occasional accompaniments of general derangement of health, loss of flesh, cough, and occasional streaky hœmoptysis.

¹ On Morbid Throat in Relation to Consumption, London, 1869, p. 12.

Dr. Johann Schnitzler¹ has recorded an instance of constriction of the trachea associated with paresis and spasm of the larynx, from pressure of hypertrophied thyroid gland upon the pneumogastric nerve, and in which he attributed the stenosis to spasm of the tracheal muscles.

FISTULÆ OF THE LARYNX AND TRACHEA.

A fistula of the larynx or trachea is either congenital, or the result of abscess or of traumatic injury. When congenital, it is inferred to be due to incomplete closure of the branchial arches of early fœtal existence.

There is little annoyance attending this affection, other than that arising from the more or less constant presence of a slight amount (a few drops daily) of discharge at the external or cutaneous orifice, and the necessity of having the opening covered with cloth to absorb it as accumulated. Sometimes the pus is forced out by the patient at regular intervals, and wiped away; the parts remaining comfortable in the interim. The existence of an internal opening communicating with the air-tube can occasionally be observed with the laryngoscope, or be detected by the injection of colored fluid, or by the passage of a delicate probe along the fistulous tract. The egress of air from the exterior at once denotes that the fistula is complete, that is to say, has both an external and internal opening. These manipulations will serve to differentiate it from fistula of the pharynx or œsophagus, or from fistula merely leading to the thyro-hyoid bursa.

The site of the cutaneous opening in congenital cases is usually constant in the region of the sterno-clavicular articulation at the inner or outer margin of the sterno-mastoid muscle. In some instances it is at or near the middle line of the neck. Congenital fistula is sometimes double-sided. Ten such instances, out of a total of forty-six, have been reported by Heusinger.²

When the result of abscess, there is perforation of the air-tube by inflammatory action, either from disease of the trachea itself, the retention of a foreign body in the trachea or in the

¹ Wiener Klinik, Jan., 1877, illustrated on p. 26.

² Virchow's Archiv, Bd. 33, S. 177.

oesophagus, or pressure sustained externally from a morbid growth or an enlarged gland.

Behier¹ reports a case from abscess, in which the air passed behind the posterior wall of the pharynx, forming a tumor which pressed against the uvula, and extended to between both lower heads of the sterno-mastoid muscle.

When traumatic, the lesion is usually the result of direct violence, in most instances suicidal wounds by knife.

The external appearances and the subjective symptoms vary with the character of the case. There is frequently marked alteration in the voice. If the orifice is large, the voice cannot be produced without occluding the opening with the finger. There is excessive secretion, with exhausting cough, expectoration, and discharge of saliva, mucus, and pus through the wound. Sometimes there is considerable dysphagia. These drains produce emaciation.

Subcutaneous or incomplete fistulæ of the larynx or trachea are sometimes present, of which I have seen two examples in young adults of both sexes. The symptoms in these cases were very similar. A sudden emphysematous swelling would appear in front of the neck and under the jaw; in one instance pushing the tissues forward beyond the chin, and of course producing great deformity. Sometimes the entire occurrence would take place within a few minutes, and sometimes the tumor would not attain its greatest size under several hours. It would gradually subside spontaneously in the course of a day or two, or under the influence of friction externally, but sometimes remained for three or four days. Though making its appearance often under the influence of emotion or exertion, it would occur sometimes without any apparent cause.

There being no reason to believe in the spontaneous evolution of gaseous products in the necks of these individuals, it was presumed that a fistula existed beneath the skin, communicating with the larynx or trachea. No internal evidence of fistulous opening could be discovered with the laryngoscope. There was no history of sudden emphysema from cough or straining as demonstrative of traumatic rent of the trachea. One instance was associated with enlarged cervical glands. The condition is technically known as pneumatocele.

¹ Gaz. des hôp., 1854, p. 142.

Treatment.—The deformity in the neck, the constant presence of the discharge, and the frequent imperfections of the voice, often render the patient desirous of undergoing an operation for obliteration of the fistula, or at least of its cutaneous opening. As a rule, however, the operation is less successful than similar operations undertaken for obliteration of fistulæ of inflammatory or traumatic origin in other parts of the body.

A number of procedures are in vogue for obliteration of these fistulæ, varying with their size, position, and the nature of the tissue involved. Small fistulæ are sometimes obliterated by inflammatory adhesion excited by the local use of dilute nitric acid, or acid nitrate of mercury insinuated along the tract by probes, or carefully injected. The pointed galvano-cautery may be used for the same purpose. An ingenious device mentioned elsewhere (p. 277) consists in passing a probe through the tract, sliding a canula over it, withdrawing the probe, and substituting a red-hot copper wire. Larger fistulæ are obliterated externally by suture or transplantation of integument.

In cases of small fistulæ, with the borders of the opening covered by integument, Dieffenbach¹ sets up inflammatory action in the edges by touching them with tincture of cantharides, and then draws them together by suture, removing the threads in from six to eight days. When the opening is large enough to expose the interior of the trachea, he freshens the edges by cutting out a small wedge above and below, draws the borders forward with a hook, and detaches them with a flat-bladed knife so far that they can be brought together from either side without tension, and secures them with four to six points of twisted suture. If the edges are callous, he makes a long vertical incision on each side of the opening and detaches the borders from the subjacent parts. Sometimes a circular piece may be removed from the circumference of the opening, and the wound be united with twisted suture.² Larger openings are occluded by transplanting skin flaps from adjacent tissues, the method and choice of flap varying with the nature of the case. A rather unique operation, the suggestion of a surgeon whose name has unfortunately escaped both my note-

¹ Die operative Chirurgie, Bd. I., S. 508.

² Watson : Edinb. Med. Jour., April, 1844.

book and my memory, consists in adjusting a flap, cutaneous side inwards, and, after adhesion has taken place, cutting the exuberant portion loose and replacing it upon the proximal portion of the cutaneous gap, its distal portion having been united by twisted suture at the initial operation. A friend, who employed this method at my suggestion, informed me that it had answered admirably.

WOUNDS OF THE LARYNX AND TRACHEA.

Wounds of the larynx and trachea may be external or internal, the latter variety being much more rare, usually due to foreign body, and sometimes promptly fatal.¹

External wounds of the larynx and trachea, gun-shot, contused, lacerated, punctured, and incised, are liable to occur in military encounter; and also as the result of accident, murderous attack, or suicidal effort.² Accidental wounds of the trachea are often punctured. A large proportion of suicidal wounds of this region occur among the insane. Razors, knives, and the like are usually employed by the sane suicide; but insane subjects and incarcerated criminals resort to many ingenious and curious devices to construct a cutting implement, bits of glass and sharpened spoon-handles being the most frequent. Suicidal attempts of this kind fail more frequently than they succeed, from ignorance of the location of the great vessels, and the popularity of the notion that any sort of extensive wound of the air-passage is necessarily fatal.

As the suicide makes the stroke he usually throws the head backward to render the larynx and trachea more prominent, and this draws the large vessels back beyond the range of the knife, so that the air-passage alone is wounded. Malgaigne states that the larynx is found severed in young suicides only, old ones wounding the trachea more frequently; and he intimates that this may be due to an inability on the part of an old person to throw his head as far back as a young one. When the suicide is familiar with the anatomy of the parts, or

¹ For examples see a case of sudden death from oedema of the larynx from a wound produced by a pointed piece of bone; and another from spearing of the walls of the ventricle by the rib of a tobacco-leaf, related by Ziemssen in his *Cyclopædia*, N. Y. Ed., Vol. VII., p. 80.

² Brierre de Boismont found that of 4,595 suicides, 121 had cut their throats.

when he makes a sweeping cut in his excitement, the great vessels of the neck are severed in the incision, and death ensues rapidly from hemorrhage—and not from the injury to the air-passage.

The larynx is generally believed to be the usual seat of suicidal wounds, but, in reality, the trachea seems to be wounded just as often.

Thus, Sabatier's list¹ gives the larynx as the seat of injury in twenty-three instances,² and the trachea in twenty-two. The thyroid cartilage was wounded in ten cases, and the crico-thyroid membrane in thirteen. Of the additional cases collected by Hourteloup, the hyo-thyroid membrane was found wounded in twelve, and the crico-tracheal membrane in one. The list is an imperfect one, however, as it contains no example of wounds of the epiglottis, which are not infrequent in this class of injuries.

Incised wounds above the hyoid bone, though they open into the mouth and pharynx, and wound the root of the tongue to such an extent sometimes as to give rise to serious hemorrhage, do not implicate the larynx.

If the wound into the larynx is made below the hyoid bone, then the pharynx is entered, and the upper portion of the cavity of the larynx opened or exposed, sometimes wounding or severing the epiglottis, and even severing the arytenoid cartilages. The epiglottis is usually visible through the wound, together with the posterior portion of the pharynx, and more or less of adjacent structure. The pharynx is sometimes so severely implicated that but a minute portion, half an inch or so, of its posterior wall remains intact. In a great many instances³ the hyoid bone and the tongue are severed from the larynx. When the epiglottis or an arytenoid cartilage has been partially severed in this way, there is a liability to suffocation by impaction of the fragment in the glottis, and this may occur shortly after the receipt of the injury, or not until some hours or even some days. Cases are on record of fatal result from both of these complications. It is, therefore, generally deemed advisable to remove with knife or scissors any movable fragment of epiglottis, arytenoid cartilage, or other structure, the retention of which may favor such an accident.

When the knife has been applied several times to the

¹ Hourteloup : *Plaies du larynx, de la trachée et de l'œsophage*, Paris, 1869, p. 16.

² *Op. cit.*

³ Liston, p. 265.

throat, as happens in some instances, and as is shown by the jagged condition of the integument, the cartilages are sometimes divided into several fragments, and under such circumstances great care must be taken to see that no loose fragment of cartilage is allowed to remain, lest it become detached and thus obstruct the glottis. In these cases of multiple wounds, the immediate danger from entrance of blood into the air-passages is much greater than where there has been but a single cut. The danger from hemorrhage into the air-passages is much greater in wounds of the trachea than in wounds of the larynx, because the thyroid gland is almost always wounded also, and the hemorrhage, therefore, much greater than in wounds implicating the larynx.

Symptoms.—These are pain, cough, spasm, bloody expectoration, dyspnoea, and dysphonia or aphonia.

Diagnosis.—The diagnosis of an external wound into the larynx or trachea is usually easy, even before a thorough examination into the extent of the injury. The special diagnostic signs are the presence of frothy blood at the external wound, and escape of air through it, or evidence of emphysema of the neck from escape of air into the connective tissue. If the patient is not suffocated by the blood which has flown into the air-passages, it is expectorated, partly through the wound and partly through the mouth. There is usually syncope as a result of the hemorrhage, and most of the cases when seen immediately after the injury are found in this condition.

Prognosis.—The prognosis is always doubtful, though many cases eventuate in recovery. Slight wounds occasionally terminate fatally; while severe ones, sometimes complicated with injury to the pharynx and œsophagus—get well, though usually only after a protracted course.

In some instances, after recovery takes place, considerable stenosis of the larynx or trachea occurs, which often requires the permanent use of a tracheotomy tube. Attempts have been made to remove the offending tissue bodily, after fully exposing it to access of the knife, but the results have not been promising.

In other instances, especially where there have been several wounds, perichondritis and necrosis occur with all their attendant evils.

Though gunshot wounds of the larynx and trachea occur in the same locality as incised wounds, there is not as much primary hemorrhage; but the secondary hemorrhage may be profuse, and suffocate the patient by running down the air-passage. This is particularly the case in wounds of the trachea, on account of the injury to the thyroid gland and vessels. In gunshot wounds of the larynx, the main source of danger is from the inflammatory swelling of the superjacent soft parts.

These cases require to be carefully watched until all dangers from hemorrhage and inflammation are over. The sequelæ of an injury of this kind are usually severe, and may terminate in hectic from the profuse expectoration of mucus and pus.

Severe gunshot wounds are also liable to be complicated by serious contusion or laceration of the important nerves on the side affected, and therefore there may be paralysis or spasm of the muscles of the glottis, interfering with respiration, independently of œdema or other results of inflammation; and this condition may require the operation of tracheotomy in order to render respiration independent of the larynx. Punctured, lacerated, and gunshot wounds are more complicated than simple incised or contused wounds, and more likely to require preliminary tracheotomy¹ and the insertion of a tube. Recovery from the injury, too, is more protracted.

Treatment.—Liston, Rust, and other surgeons, caution the practitioner against being deceived by the arrest of hemorrhage which follows the syncope, for, if ignorant, he will close the wound by suture, and thus prevent the outward escape of the blood from the second hemorrhage, which is almost sure to occur as soon as reaction comes on; and as this will run down the trachea, he may drown his patient instead of saving him; or a clot may form in the air-passages, and thus produce sudden asphyxia.

Cases made fatal in this way by too assiduous attention are on record; and Liston² records a case in which his own house-surgeon, despite the principles he had repeatedly inculcated, came near losing a patient in this way, whom Liston saved by instantly cutting the sutures loose and removing a clot which impeded respiration.

¹ Consult Witte, on wounds of the larynx and their treatment, especially the value of a prophylactic tracheotomy (Arch. klin. Chir., 1877, Bd. XXI., H. 1, 2, 3, pp. 217, 391), Leffert's Rept., N. Y. Med. Jour., Feb., 1878, p. 200.

² Op. cit., p. 267.

It is, therefore, an important point, in the management of these cut-throat cases, that the parts should not be united by suture until it is certain that all danger from reactionary hemorrhage is over. Even ligation of the bleeding vessels does not secure immunity from the later hemorrhage, for this may come from parts whose bleeding is not controlled by the ligated vessel. If the hemorrhage is excessive, and irrestrainable by styptics and ligatures of the bleeding vessels that can be reached, perhaps the best plan is to tie the carotid, a measure which has been carried out by Le Gros Clark with the happiest result. If the wound be a very extensive one, it is allowable to unite its outer portions; but the central portion should be left open, and if there is any danger of bagging of the horizontal wound, the pockets formed by its lower edge should be divided vertically (Stromeyer), so as to prevent the burrowing of pus; for these wounds never unite by first intention, and more or less extensive suppuration is to be awaited. When all danger from hemorrhage is at an end, the parts on either side of the opening communicating with the air-tube can be brought together with adhesive strips, assisted by sutures in the soft tissues, ample room being left for drainage; but no suture should be taken through the cartilage, its perichondrium, or even its connective tissue, inasmuch as sutures are not well borne in these situations, and either cut their own way out, or produce so much local irritation as to necessitate their removal by the surgeon.

Prof. Gross and some other surgeons have no fear of this kind; but in perusing carefully the records of a considerable number of cases of wounds of the larynx and trachea, gathered from the most varied sources abroad and at home, I find that those cases have done best in which sutures were avoided, and that in most of the cases where they were resorted to, it became necessary during the treatment to remove them, even when the wound was not a very extensive one, while in others, where not removed by the surgeon, they tore their own way out.

Severe injury to the larynx and trachea, such as fracture, laceration, contusion, inflammation—anything in fact that compromises the integrity of the calibre of the parts for respiration—demands precautionary tracheotomy, the choice of locality for which will vary with the peculiarities of the case.

After the parts are in apposition, the head is to be gently flexed forward and retained in position by a light bandage, so as

the better to favor approximation of the horizontal edges of the wound, cicatrization of which may be expected in from two to three weeks. The head should not be confined too much, or too far forward, as this may cause the edges to overlap.

Stromeyer attaches a small tuft of hair sidewise over the brow to a bandage fastened to a girdle or jacket—more as a reminder to the patient that he shall not make any incautious movement of the head, than to hold it fast; and he finds this generally sufficient to fulfil the object. He mentions a case in which a man had cut entirely through the sterno-cleido-mastoid, in spite of which the head stood straight when he did not move it. As soon as he attempted the slightest movement, the head flapped toward the opposite side as quick as the snapping-to of the blade of a pocket-knife. This discontinued as soon as the head was bound by the tuft of hair to the opposite side.

The parts should be lightly covered by gauze, or a woollen scarf, to modify the temperature of the inspired air; and the room should be kept at a warm temperature and the atmosphere moist, the same as after operations of tracheotomy, etc. There is always a great deal of difficulty in the after-management of these cases, and this is increased if the pharynx or œsophagus have been wounded in the injury. The unavoidable movements of head and neck, tongue, and larynx, keep up more or less agitation of the parts, to which is to be added the escape of the secretions, mucous and purulent, through the wound, and sometimes the passage of aliment or drinks also. If, in addition, the patient be insane, or intent on sacrificing his life, he will tear open the dressing, put his fingers into the wound to stop respiration, and so on. Such patients had better be conveyed to hospitals, where they can be watched and managed by competent nurses and skilled attendants.

At other times, a feeling of shame, mortification, fear, or even of repentance, will act unfavorably on the progress toward union.

The inflammatory reaction that follows is to be treated on general principles; but if œdema should ensue from this or any other cause, or asphyxia be threatened, a longitudinal incision should be made into the trachea below the seat of injury, and a tracheotomy tube be introduced.

Dr. Eugene Beach has related¹ a case of perforation of the trachea by the tine of a pitchfork, followed by general emphysema, which had assumed alarming

¹ N. Y. Med. Jour., March, 1877, p. 302.

proportions within three hours, threatening asphyxia. After incising the skin at several points, the tissues of the neck were divided down to the perforation in the same manner as for tracheotomy. The patient recovered.

Dr. Walter F. Atlee has reported¹ a case of punctured wound of the trachea, with bloody expectoration and emphysema following, in which the patient recovered without tracheotomy.

Nourishment should be given by the mouth, and can usually be well taken, even in cases where the epiglottis has been divided, if there is no wound of the pharynx or œsophagus. If these structures are wounded, it becomes necessary, until the power of deglutition has been regained, that fluid nourishment be administered by means of a small stomach-tube, a syphon-tube, or a feeding-cup with a long nozzle to reach into the œsophagus. Nourishment may also be administered by enema, and medicine, if necessary, by enema or by hypodermic injection.

Despite the institution of rest and the most careful management, more or less bronchitis will usually occur, attended with a copious secretion of mucus, due perhaps to the entrance into the air-passage of some of the secretions from the wound. Under these circumstances, care must be taken to catch the secretions upon a sponge or soft mop as they are expelled from the wound, as well as to cleanse the parts frequently. Preparations of opium, which tend to restrain the secretion and quiet the cough, are applicable in the first instance, and their use may be continued if no contra-indications present. Care must be taken lest the combined influence of the catarrhal inflammation of the air-passages, impeding respiration, and the use of the opium induce a partially asphyxial condition which will obtund the normal sensibility of the larynx, permitting the passage of fluids into the larynx, and thus through the wound and down the trachea.

These wounds heal slowly and by suppuration. Sometimes they do not unite in their entire extent, and a fistulous opening remains which requires to be closed by cauterization with nitric acid or the acid nitrate of mercury, or, if such applications fail, by means of a plastic operation.

During the healing of these wounds, contraction is very apt to occur, necessitating the permanent use of the tracheotomy

¹ Am. Jour. Med. Sci., April, 1878, p. 439.

tube. These constrictions have been overcome in a few instances by Professor Liston and others; the method employed being that of gradual dilatation. In one instance of this kind I was enabled to relieve the patient from the necessity of wearing a tube, dilatation being produced in the contracted glottis (the wound having been directly below the vocal cords) by the frequent passage of large perforated catheters through the wound up into the mouth, and the seesawing of these instruments, up and down, by means of the two hands.

FRACTURES OF THE LARYNX AND TRACHEA.

Fracture of the Larynx.—Fractures of the larynx occasionally take place as the result of mechanical injury, sometimes in connection with simultaneous fracture of the hyoid bone, but oftener without this complication. These fractures are sometimes single and sometimes multiple.

Usually only the thyroid and cricoid cartilages suffer fracture. The arytenoid cartilages, on account of their mobility upon the cricoid, are more apt to suffer dislocation. In many cases both thyroid and cricoid cartilages are broken; but when the accident is confined to one cartilage, it is the thyroid which is most frequently fractured.

In 46 cases of fractures of the larynx and trachea collected by Guerlt,¹ 16 cases occurred in persons from nine years of age to thirty, 12 in males and 4 in females; which may not represent the proper proportion, inasmuch as in a number of these cases the age of the patient is not mentioned in the original report. It will thus be seen that ossification of the cartilages is not as important an element in this form of injury as it is usually supposed to be. Of these 16 cases, the thyroid cartilage alone was affected in 6; the "larynx" in 2, without designating what portion; the cricoid alone in 1; the trachea alone in 1.

The most frequent cause of fracture is a murderous attempt at choking with the hand, whether premeditated or performed during the excitement of a scuffle. A blow upon the anterior portion of the throat with the fist, or with some

¹ Handbuch der Lehre von den Knochenbrüchen: Dr. Guerlt. Hamm, 1864, Theil 11, Lief 1.

hard weapon, as a billet of wood, is also a source of fracture. Sometimes the cause is purely accidental, as a fall in which the neck strikes upon a hard substance. Occasionally, it is said, it is produced in awkward hanging.

Symptoms.—The symptoms attending a fracture of the larynx, varying of course with the nature and extent of the lesion, will be as follows: At first a spasmodic cough, sometimes preceded by spitting of frothy blood, and almost always attended with bloody expectoration; and very soon severe dyspnœa, with all its accompaniments of cyanosis, coldness of skin, smallness of pulse, frequent and labored respiration, with large mucous laryngeal râles, hoarseness of voice, or even aphonia; and sometimes an inability to speak at all, a few inarticulate tones being forced out in the attempt; more or less painful swallowing; and in all severe cases attended with rupture of the mucous membrane, there will ensue an emphysema of the throat and neck, extending steadily over the face, the cervical vertebræ, down into the mediastinum, and sometimes over the entire body. This emphysema is said to be more apt to take place in the intermuscular than in the subcutaneous connective tissue. Cases occur, but exceptionally, in which the symptoms will not be at all of a serious character; perhaps merely soreness and some hoarseness of voice; but it is likely, in these instances, that the internal mucous membrane has not suffered laceration.

Diagnosis.—The history of wound or injury, and the appearance of the symptoms described, establish the diagnosis. Manipulation of the parts, however, affords the evidence of fracture. In severe cases there will be more or less deformity from over-riding of the fragments. Cartilaginous crepitation will also be elicited on moving the fragments one upon the other; but care must be taken not to mistake for this the crepitation which can be produced in the normal larynx by lateral movements, or by slight pressure against the vertebræ.

It is also to be remembered, in this connection, that the upper horn of the thyroid cartilage is occasionally found disconnected from the body of the cartilage, and enclosed in the lateral thyro-hyoid ligament. Luschka¹ found this condition in three instances, the anomaly existing on the left side only

¹ Virchow's Archiv, March 18, 1868, p. 478.

in each case. It would therefore appear that this process is a sort of epiphysis; and the anomaly in question is well to be remembered, as it might be mistaken under certain circumstances for a fracture, the result of mechanical injury.

In one instance, in making a post-mortem examination on the body of a man upon whom, several months before, I had performed tracheotomy for syphilitic ulcerative laryngitis, I not only found that there was no upper horn of the left side of the thyroid cartilage, but that there was no evidence of it in the thyrohyoid ligament. The specimen, which was handed around for inspection at my Muetter Lectures on this subject in 1872, is preserved in the Muetter Museum of the College of Physicians of Philadelphia.

Prognosis.—The prognosis is always grave, and especially so when the cricoid cartilage has suffered fracture; for, as pointed out in an article by Dr. Hunt,¹ of Philadelphia, perusal of the records of published cases shows that fracture of the cricoid cartilage has always terminated fatally. This must be due to the contusion and laceration of the soft parts, blood-vessels and nerves inclusive, which must result from an injury sufficient to break this very strong circular cartilage.

Severe cases of fracture of the larynx often terminate fatally at once, or within a short period after the receipt of the injury, usually from effusion of blood beneath the intra-laryngeal mucous membrane, from displacement of fragments, or accumulation of blood in the respiratory canal of the larynx or trachea.

Treatment.—Should the patient survive the immediate injury, and symptoms of dyspnoea present themselves, an opening should be promptly made into the air-passage below the seat of injury, without waiting for the effects of antiphlogistic treatment. Even in cases that do not present any great severity of symptoms at first, an operation of this kind may soon become necessary on account of the production of œdema or submucous hemorrhage; and it is questionable whether it is not sounder practice to perform tracheotomy in all cases, and thus avoid even the chance of danger from sudden asphyxia. This operation should certainly be performed if the surgeon does not remain by the side of his patient, or leave a competent representative in his place, as it may present the only escape from sudden death during an emergency in the

¹ Am. Jour. Med. Sci., Apl., 1866, p. 378.

absence of a medical attendant. While a few cases have recovered without the preliminary operation, a greater number have terminated fatally for want of it.¹

The displaced fragments should be replaced with the greatest care; and in some instances the performance of laryngotomy, which can add but little, if anything, to the danger of the case, will afford greater facility in reposing the fragments by the aid of probes or catheters passed within the larynx, through the artificial opening. The fragments should be merely replaced, without any attempt to retain them in position by suture, inasmuch as the results of experience teach that the cartilage is very intolerant of the presence of sutures, which soon cut their way out, if the symptoms they produce do not render their early removal necessary. The wounds in the soft parts may be approximated by adhesive strips and sutures, care being taken to leave sufficient opening below for drainage, keeping it patulous, if need be, by a shred of lint, inasmuch as these wounds heal by suppuration, and rarely by first intention.

This done, the patient should be placed at perfect rest, and the case be treated on general principles.

The insertion of a canule in the artificial opening is usually required; and in many instances its permanent use cannot be dispensed with even after recovery from an operation, on account of vicious adhesions and contractions. Sometimes a fistula remains; and this can be covered up by a plastic operation externally.

The after-treatment will depend upon the peculiarities of the case, and be conducted on general principles with maintenance of rest of parts and of system.

Fracture of the Tracheal Cartilages.—Fracture of the cartilages of the trachea occurs under the same circumstance as fracture of the larynx, sometimes without simultaneous fracture of the larynx or hyoid bone, but oftener in connection with a similar injury to these organs. Guerlt² gives nine cases of fracture of the tracheal cartilage, in four of which the fracture involved the trachea alone, while in the other five it was

¹ For a striking example in point, see Fredet: *Quelques considérations sur les fractures traumatiques du larynx*, Paris, 1868, p. 5.

² *Op. cit.*

combined with fracture of the hyoid bone and larynx. His principal remarks are :

“The causes of the isolated fracture of the trachea were : direct violence to the throat by pressure of a solid body, such as a wagon, the buffer of a railroad-car, blows upon the throat with the fist or with a foreign body.

“The general *symptoms* are very similar to those of fracture of the larynx, with which it is so often associated—severe dyspnœa and rapidly extending emphysema; but the local symptoms are much more difficult to distinguish, for there is no elevation of the dislocated fragments, no abnormal mobility or crepitation ; and the latter symptom is easily simulated in the presence of extravasation of blood or emphysema.

“The *diagnosis*, therefore, is difficult as far as regards the nature and seat of the injury, though it can generally be made out from the general symptoms, and by exclusion.

“The *prognosis* of the injury is unfavorable, as it is in severe injuries of the larynx ; and the accident leads without abatement to rapid death, although, in a few cases, life may be saved by prompt operative interference. Of seven collected cases, in five of them death followed in one and a half, three, twelve hours, and on the day following that of the accident. In one only, in a patient apparently dead at the time, was life saved by tracheotomy, followed by the removal of masses of blood and mucus that had accumulated in the air-passages, and then by the institution of artificial respiration.

“The *treatment* must be similar to that adopted in fracture of the larynx, and consists principally in promptly laying the wounded part freely open, when its anatomical position permits it, and especially in extensive transversal laceration of the trachea, and the consequently possible dislocation of both fragments, which may interrupt or compromise the access of the atmosphere to the lungs, a circumstance under which life can continue for a very short time only.

“Although no observations of the kind have been made, it is likely that the free laying open of the torn trachea will secure the passage of the air to the lungs, and avoid the most imminent danger of life. Recovery would then take place in the same manner as it would after a horizontal section of the trachea made in an attempt at suicide. Union of the wound by suture is to be avoided, and union by suppurative inflam-

mation to be awaited, union being promoted by a proper position given to the head."

CONTUSIONS OF THE LARYNX AND TRACHEA.

Contusions of the larynx or trachea are sometimes produced as the result of accident or external violence. They are not usually very serious in their nature. Their treatment would consist in rest of the parts, soothing applications externally, and careful watching. Dr. Le Gros Clark¹ records a case of contusion from a blow, which produced pain on motion of the parts and pain on swallowing. There was also complete aphonia. There was no blood in the sputa. The voice began to return in ten days, and the patient was well in three weeks.

A contusion of the larynx may produce spasm of the glottis, threatening suffocation, and thus rendering the operation of laryngotomy or tracheotomy necessary. Contusions in this region are sometimes attended with severe injury to the soft parts. Dr. Louis Stromeyer² states that he has seen, after an accident of this kind, a spasmodic retraction of the muscles of the neck lasting for several days, so that the head was bent backward as in opisthotonos, and could hardly be moved. Rest and suitable outward applications quieted the condition, and the patient recovered without any untoward symptoms.

RUPTURE OF THE TRACHEA.

Rupture of the trachea occasionally occurs in connection with fracture of its cartilages. Sometimes it is associated with similar injury of the larynx.³ Rupture or laceration is liable also as a result of accident or injury, the rupture taking place between two of its rings, or between the upper ring and the cricoid cartilage.⁴ It may also be ruptured by the discharge of a mediastinal abscess.

¹ Lectures on Surgery, 1870, p. 229.

² Handbuch der Chirurgie, Freiburg, 1865, Vol. II., p. 309.

³ O'Brien: Eighteenth Vol. Edinb. Med. and Surg. Jour., quoted by Ryland: Op. cit. In this case, resulting from a kick under the jaw, a rupture was found extending from a similar injury of the thyroid and cricoid cartilages through the first ring of the trachea.

⁴ Long (Brit. Med. Times, July 26, 1856) relates a case from the patient's neck being caught by the coupling-irons of two railway carriages, in which, during tracheotomy, which saved the patient's life, it became evident that the trachea had become separated from the larynx for the distance of about two inches.

A boy was admitted into Dr. Johnson's ward at King's College Hospital,¹ cyanotic, almost pulseless, and gasping for breath, having been suddenly seized at play with urgent dyspnœa. There was a history of cough and sore throat of a fortnight's duration. Tracheotomy was performed without relief, and the child died shortly after the operation. A mass of caseous bronchial glands was found to have softened down into an abscess, which, bursting into the trachea, had obstructed it completely. A rounded opening, the size of a threepenny-piece, was found in the trachea just above its bifurcation. The bronchi were loaded with pus.

The accidents which may occasion this injury are cough in croup,² bronchitis,³ chiefly in children; and violent inspiratory efforts in dyspnœa from obstruction or compression.⁴ There is reason to believe that the accident has occasionally occurred during violent expiratory efforts in labor, and even in defecation. Various local injuries may have produced rupture or laceration of the trachea, such as the kick of a horse,⁵ crushing between hard substances,⁶ as the buffers of railway cars, jamming against a post,⁷ a fall,⁸ etc. Counter-pressure may also produce rupture of the trachea, as reported by Mr. Godlee,⁹ in which a child was run over by the wheel of a cart, which passed over his chest, fracturing the third, fourth, and fifth ribs, at their point of greatest convexity, on the right side. The trachea was split, front and back, immediately above the bifurcation. In another case of severe dyspnœa and collapse, after injury to the chest of a child, the left bronchus was found completely torn across.¹⁰

Symptoms.—The special symptoms are dyspnœa, usually attended with emphysema of the neck.

Diagnosis.—This rests on the history of strain in coughing,

¹ Brit. Med. Jour., Oct. 27, 1877, p. 592.

² For two examples see Latour: *Manuel sur le croup*, Orleans, 1808; Voss: N. Y. Med. Jour., Jan., 1860, p. 37.

³ Bredschneider (Casper's Woch., 1842, p. 261): Guerlt, op. cit., p. 336.

⁴ Thomas Marshall: *Gross' Pathological Anatomy*.

⁵ Lauenstein: Berlin. klin. Woch., 1870, No. 42. Robertson, of Wiesbaden: The Lancet, Sept. 6, 1856; here there was complete rupture of the trachea from the larynx, the laryngeal cartilages remaining uninjured.

⁶ Long: *Supra*.

⁷ Beck: *Med. Jurisprudence*, 1st ed., p. 718. In this case the trachea was totally divided.

⁸ John L. Atlee: *Am. Jour. Med. Sci.*, Jan., 1858, p. 120.

⁹ *M. d. Times and Gaz.*, Dec. 12, 1874, p. 675.

¹⁰ Howard Marsh: *Ibid*.

or of accidents of such character as have been described, and on the presence of dyspnoea and emphysema.

Prognosis.—This is unfavorable. If the rupture occur at a point too low for tracheotomy, it is almost necessarily fatal.

Treatment.—This consists in provisional tracheotomy at the seat of rupture, or below it if practicable, and such general measures as are requisite to secure rest, and quiet excited respiration.

FOREIGN BODIES IN THE LARYNX AND TRACHEA.

Foreign bodies are frequently drawn into the air-passages, and when not promptly expelled by coughing, usually become impacted in some portion of the larynx or trachea, though they occasionally lodge in the bronchi. Foreign bodies, too, may gain access from the outside, as in the oft-reported case of La Martinière, who, detecting a small wound in the neck of a boy who had been suddenly seized with a paroxysm of suffocation while playing with a whip, cut down upon the wound, and extracted from it a pin. The pin had been attached to the whip-cord, and had penetrated into the trachea.

Purulent bronchial glands have become detached, and thus produced sudden death by suffocation. They also rupture into the air-passages by ulceration, and thus produce sudden suffocation.¹

Matters vomited from the stomach during a state of insensibility or paralysis have inundated the air-passages, and thus produced death.² An accident of this kind sometimes occurs in the new-born babe, the matters usually consisting of mucus and meconium. It has been known to occur during the performance of a surgical operation under anæsthesia, and even without it; and instances have been reported³ where even tracheotomy was of no avail. Parasitic worms sometimes find their way into the air-passage from the alimentary canal; and insects and other animals from the nose. Leeches, too, are said to gain access from careless application within the mouth.⁴

¹ For recent examples see Kjerner (Hygiea, Nordiskt med. Ark., VI., No. 1): N. Y. Med. Jour., Aug., 1875, p. 206.

² For recent examples see Brit. Med. Jour., Sept. 16, 1876, p. 381.

³ For recent examples see Smyth: The Lancet, Oct. 3, 1874; Phila. Med. Times, Nov. 7, 1874; House: Brit. Med. Jour., Sept. 16, 1876, p. 16.

⁴ Éléments de chirurgie clinique, F. Guyon, Paris, 1873.

Necrosis of the laryngeal (notably the cricoid) or tracheal cartilages, and their complete or partial exfoliation, may be followed by their confinement in the interior of the tube, thus rendering the dead structure a foreign body.

Illy-made tracheotomy tubes sometimes become detached from their collars and fall into the trachea. A similar accident occurs from corrosion of the solder in instances where they are retained for long periods without removal. Even the body of a metallic tube, long retained in position without cleansing, will become corroded and liable to breakage in the trachea.

The most frequent cause of the entrance of foreign bodies into the air-passages is due to sudden inspiration while the body is in the mouth. Many accidents of this kind occur in children who are very apt to put toys and other things into their mouths while at play; and many of them take place during drinking. Hence the variety of objects which gain access to the air-passage is very numerous, and of the most diverse character.¹ Sudden suffocation is sometimes produced by the accident. Most of the foreign bodies which gain entrance into the air-passages are of hard consistence, and not likely to undergo alteration of size. Vegetable and animal matters, on the other hand, are liable to become increased in size from imbibition of moisture, and therefore add gravity to the prognosis.

Sometimes the epiglottis becomes impacted in the larynx as a foreign body, and may even produce asphyxia. It usually occurs during eating, from pressure of the bolus, but I have known it to occur during the swallowing of saliva, and threaten asphyxia, according to the account of the patient, himself a physician, and subject to this accident.

A case of sudden asphyxia from impaction of the epiglottis while eating, and which occurred under the direct observation of Middeldorpf, has been related by Ruehle.² They were suddenly called to a nurse who had passed them, a few moments before, eating a piece of bread. Thinking a piece of the bread occluded the larynx, Middeldorpf inserted his finger to remove it, but, instead of a foreign body, he found the epiglottis firmly held backward, with its upper edge bent between the arytenoid cartilages; and on disengaging the epiglottis with his finger, all dyspnoea ceased.

¹ See Samuel Johnston's case of removal of a toy-locomotive from sub-glottic cavity, by tracheotomy and thyrotomy, with recovery, illustrated: *Arch. Clin. Surgery*, N. Y., Dec., 1876. In a case seen in consultation by myself, a number of years ago, the foreign body was the bladder of a mechanical rubber trumpet.

² *Die Kehlkopfkrankheiten*, Berlin, 1861, p. 13.

It is not improbable that some cases of otherwise unaccountable sudden death at a meal may be due to this cause.

Reliable articles on the subject of foreign bodies in the air-passages are contained in all treatises on surgery, and, therefore, no more is necessary here than a general description of the nature of the accident, the symptoms it gives rise to, and the treatment indicated. The classical monograph of Prof. Gross,¹ contains all the essential information that can be desired on the subject, with the single exception that these bodies, when lodged in the larynx, or in certain portions of the trachea, can sometimes be recognized with the laryngoscopic mirror—an instrument introduced into the practice of medicine and surgery subsequently to the publication of Dr. Gross's volume.

The foreign body may lodge in different portions of the larynx or trachea, or may remain loose in the windpipe, and move up and down it with the efforts of respiration. When not arrested in the larynx or trachea, it usually falls into one of the bronchial tubes, more frequently into the right tube; the reason being, as shown by Prof. Gross, the anatomical direction of the septum at the bifurcation of the trachea, to the left of the middle line, so that a foreign body striking it is apt to be deflected to the right, its passage in that direction being additionally favored by the greater calibre of the right bronchus. Sometimes a foreign body falls into each bronchus; and sometimes it passes through the bronchus into one of its subdivisions.

When a foreign body is retained in the air-passages for a long time it occasionally becomes encysted. At other times it is expelled through the mouth, or by ulceration through the walls of the chest.

Symptoms.—The immediate effect of the entrance of a foreign body is usually a severe paroxysm of pain and coughing, with more or less dyspnœa, due to mechanical occlusion, or to spasmodic action excited in the laryngeal muscles. Sometimes suffocation takes place on the instant. The symptoms of the accident are thus graphically described by Prof. Gross: "The patient is seized with a feeling of annihilation; he gasps for breath, looks wildly around him, coughs violently, and almost loses his consciousness. His countenance immediately becomes livid, the eyes protrude from their sockets, the body is contorted in every possible manner, and froth, and sometimes even blood, issue from the mouth and nose. Sometimes he grasps

¹ A Practical Treatise on Foreign Bodies in the Air-Passages, Phila., 1854.

his throat, and utters the most distressing cries. The heart's action is greatly disturbed, and not unfrequently the individual falls down in a state of insensibility, unable to execute a single voluntary function. In short, he is like one who has been choked by the hand, or by the rope of the executioner. Sometimes a disposition to vomit, or actual vomiting, occurs immediately after the accident, especially if it take place soon after a hearty meal. The relief occasionally experienced from this source is very great. In some instances, again, there is an involuntary discharge of fæces, and even of urine."

"The duration of the first paroxysms varies from a few seconds to several minutes, or, in severe cases, as when the foreign body is arrested in the larynx, even to several hours. With the restoration of the respiration, the features resume their natural appearance, and the patient recovers his consciousness and power of speech. The voice, however, frequently remains somewhat altered, the breathing is more or less embarrassed, and the individual is harassed with frequent paroxysms of coughing, attended often with a recurrence of all, or nearly all, the original symptoms. Thus the case may progress for an indefinite period, until the foreign body is expelled, or until it produces death by functional or organic disease of the air-passages."

Sometimes the symptoms are very slight, and under these circumstances the foreign body, when hard and of smooth contour, may remain for long periods without producing injury. I have met with two instances of such sojourn of foreign body for upwards of ten years, the body, in one instance a pebble, being ejected spontaneously in a fit of coughing, long after the occurrence of the accident had been forgotten.

Even when impacted deeply into the larynx, there may be no special subjective symptoms after the subsidence of the stormy manifestations immediately following the accident; so that the presence of the foreign body may long remain undetected.¹

The effects of a sojourn of a foreign body, as enumerated, and discussed in detail by Prof. Gross, are: inflammation of the mucous membrane of the larynx, trachea, and bronchi; sometimes inflammation of the lungs, an inflammation which

¹ Whistler: Impaction of a Bone in the Larynx for Five Weeks; removed by the aid of the laryngoscope. The Lancet, Dec. 2, 1873, p. 779, illustrated.

may be followed by ulceration; the formation of abscesses; a deposit of tuberculous matter; œdema of the larynx; pulmonary emphysema; enlargement and softening of the bronchial lymphatic ganglions; effusion of serum and lymph, and occasionally of pus in the pleura; extensive adhesions, and sometimes inflammation of the heart, pericardium, and liver. To this list may be added caries and necrosis of the cartilages of the larynx, trachea, and bronchi.

Diagnosis.—The diagnosis of a foreign body in the air-passages, in the absence of direct history, is mainly based upon the suddenness of the onset of the symptoms. Auscultation of the trachea and lungs also aid in diagnosis; in the first instance when the body is loose, and in the latter instance when it is impacted in one of the bronchial tubes. All the symptoms of a foreign body in the air-passages may be produced by impaction of a foreign body in the pharynx or œsophagus, pressing the epiglottis down on the laryngeal orifice or exciting pressure, laterally or posteriorly, or by mechanical occlusion by the foreign body itself. The finger and the œsophageal sound will determine this point in most instances. Care should be observed in these examinations, as they are not always unaccompanied with danger. The laryngoscope will sometimes reveal the presence of a foreign body in the trachea or in the infra-glottic portion of the larynx; and almost always its presence in the supra-glottic portion of the air-tube, or in the lower portion of the pharynx. When the foreign body is visible in this manner,—and an examination of the kind should not be neglected when time and opportunity permit,—valuable information is obtained as to its position, and the selection of the proper instrument, or surgical operation, for its extraction. In presence of great emergency tracheotomy may be performed to avert suffocation, and the laryngoscopic inspection be made subsequently.

In a case of choking, where life had been saved by tracheotomy, the presence of a large piece of fat bacon just under the epiglottis was revealed by laryngoscopic examination, and was removed accordingly.¹

Prognosis.—The prognosis is always grave as long as the foreign body remains in the air-passage, and therefore measures

¹ Macnamara: Brit. Med. Jour., May 30, 1874, p. 714.

should be instituted for its prompt removal or extraction as soon as the diagnosis has been made. A patient with a foreign body in the air-passage is not safe, notwithstanding the number of cases on record in which foreign bodies have sojourned for prolonged periods without untoward results.

A married lady expelled in a paroxysm of cough a smooth pebble, which was said to have been inhaled during childhood more than twelve years before; and though the accident occasioned a good deal of anxiety at the time, the unpleasant symptoms had gradually ceased, and the circumstance become practically forgotten. The physician in attendance at the time of the accident remembered the case distinctly when I called his attention to it. In another case, a plum-stone, coughed up in a similar manner by a patient with chronic bronchitis, was said to have been inhaled several years before; but there was no corroborative medical evidence.

Although instances are not rare in which foreign bodies have remained for years without being productive of serious injury, there are others in which fatal inflammations have resulted, despite the spontaneous expulsion of the foreign body in some cases. It cannot be considered safe to let the foreign body alone, if there is any reasonable opportunity for effecting its riddance.

Treatment.—Spontaneous expulsion of the foreign body often takes place, usually followed by recovery, but sometimes followed by death. Expulsion is often produced under the action of emetics and errhines, but the danger of producing impaction of the body within the larynx presents a serious objection to their use.

Inversion of the body and succussion of the chest and back is liable to the same danger of producing impaction. Still, these methods have proved successful in many instances.

In cases of smooth or rounded bodies, such as coins and pebbles, whose weight and shape favor their response to gravity, the plan employed successfully in one case by Mr. Geo. Padley¹ is well worth remembering and repeating.

“A strong bench having been fixed, with the legs of one end on a couch and the others on the floor, the patient was made to sit upon the upper part of it, with his knees flexed over the end. He was then directed to lie back upon the inclined plane thus formed, and, having done so, instantly raised himself up with the sixpence in his mouth. The supine position probably favored the exit of the

¹ Brit. Med. Jour., Nov. 6, 1878, p. 721.

coin, and the readiness with which, by his own effort—the knees acting as a fulcrum—he regained the upright position would have saved him from the danger of spasm in the event of its non-expulsion.”

In a case under the care of Krishaber he turned the boy over to avail himself of that position, inserted his finger, and then removed the foreign body with forceps.

In certain favorable cases the foreign body, when situated in the upper portion of the larynx, can be seized with a pair of laryngeal forceps under guidance of the laryngoscopic mirror, and be safely extracted through the mouth.

Leeches are among the strange objects which have been removed in this manner. In the report of an interesting case of the kind removed by Dr. Clementi, of Sicily, attention is called to several other instances, in two of which the animals were recognized by laryngoscopy and successfully removed.¹

In suitable cases a properly bent probe may be insinuated under one extremity of the foreign body to pry it loose, so that it may be ejected by cough.

When the foreign body is situated within the glottis, or beneath it, attempts at removal in this manner are rarely advisable, on account of the danger of producing asphyxia by spasm of the glottis, or by impaction of the foreign body between the lips of the glottis in the effort at extraction. Only when the body is small or slender, and favorably situated for seizure and withdrawal, should this operation be attempted.

An instructive case of this nature has occurred in my own practice, in the case of a lady sent to me from Easton by Dr. Mixsell. The foreign body, a piece of beef-bone, had been inhaled into the larynx while eating soup, two years and a half previously. On examination, the bone was seen below the vocal cords, impacted between the anterior and posterior walls of the cricoid cartilage, which had undergone caries at these points. I made an attempt to seize the body with a pair of laryngeal forceps, and readily succeeded, but a good deal of force was necessary to dislodge it, and the instrument was withdrawn without the foreign body within its grasp. A moderate amount of hemorrhage followed, accompanied by violent paroxysms of spasm of the glottis, which continued for about half an hour, and were eventually allayed by the inhalation of ether. A subsequent laryngoscopic examination showed that the foreign body had been detached from its connections posteriorly, and that it was hanging by its anterior attachment. It had caught against the under surface of the vocal cords in their

¹ Trolard : *Algérie méd.*, 1870, 29 ; Massei ; *Morgagni*, Oct., 1874, p. 750. See *Gaz. med. italiana*, 1874, No. 48 ; *Arch. klin. Chir.*, 1875, p. 194 ; or *Med. Times and Gaz.*, Jan. 16, 1875.

spasmodic approximation during the operation, and had thus been dragged out of the grasp of the forceps. I declined to interfere further through the mouth, and subsequently performed tracheotomy, with the assistance of Drs. Packard and Sinkler. The bone, which was distinctly seen in the larynx just before the operation, could not be found after it, and it was concluded that it had become detached, coughed up, and swallowed during the spasms of coughing with which the operation was attended; and the case has done well ever since. The ulceration of the cricoid cartilages healed kindly, their progress being watched with the laryngoscope. A day or two after the operation a small piece of bone was found plastered by a clot of blood to the wall in front of the position occupied by the operating-table, but it represented only a small portion of the bone seen with the laryngoscope. Subsequent examinations, however, proved that no portion of the foreign body had remained in the air-passage.

Dr. Moritz Schmidt has related¹ an instance in which, after several ineffectual trials, he caught a bone in the trachea, but was unable to draw it through the glottis, and the forceps slipped. Fortunately the bone had become broken in two pieces, both of which were coughed out.

I have extracted fish-bones and pins without difficulty, under guidance of laryngoscopy, but they were favorably situated above the glottis.

A perusal of the reports of even successful removals of infra-glottic foreign bodies shows that a certain amount of danger is often inseparable from attempts at removal in this manner.

The proper treatment for a foreign body in the air-passage, inaccessible from the mouth, consists in making an artificial opening below the glottis, in order to afford the best chance for the expulsion or extraction of the body, and to avoid the danger of suffocation by spasm of the glottis. An operation of this kind may become a serious matter if in the presence of any considerable pulmonary complication. Laryngotomy, confined to the crico-thyroid membrane, is preferred in the adult when it is evident that the foreign body is in the larynx. Sometimes, though rarely, more or less complete division of the thyroid cartilage is required, as, for instance, when the body is impacted in one of the ventricles of the larynx, and cannot be dislodged through the wound in the crico-thyroid membrane. In cases of foreign body in the trachea, and also in most cases occurring in small children, the operation of tracheotomy is to be preferred, as admitting of a larger opening, and the freer play of dislodging instruments. The opening

¹ Arch. klin. Chir., 1875, H. 1, p. 186.

should be sufficiently large to permit the ready escape of the foreign body, and should in all cases exceed the length of the glottis. At least one inch and a quarter in the adult, and not less than one inch in the child, is the rule adopted by Prof. Gross.

In most instances of sudden asphyxia impending from impaction of food or other foreign body in the pharynx, and pressing the epiglottis down, the inspiratory current taken through the artificial opening rushes upward, elevates the epiglottis, and drives the morsel into the mouth, whence it is readily extracted. If the foreign body be in the air-passage itself, it is very often ejected, as soon as the air-passage is open, in a fit of coughing, from the wound or from the glottis, and under the latter circumstances it may lodge in the mouth or pass down the œsophagus. At other times it presents at the lips of the wound, whence it is readily extracted with forceps. If the foreign body does not move toward the exterior, it is customary to turn the patient upon the face and to strike the chest or back with the hand. It has also been recommended to blow strongly into the wound, so as to compress the air within the trachea, that it may gather expulsive force in the coughing which follows.

If these manœuvres do not effect expulsion of the body, instruments must be passed into the air-tube for that purpose. Great care is requisite in manipulations of this kind, as they usually provoke violent paroxysms of cough, during which the mucous membrane of the parts may be endangered. If breathing is improved after incision into the trachea, it is presumptive evidence that the foreign body is above the seat of the wound, and therefore the larynx should be explored first. The foreign body, if felt in the larynx, can often be pushed through the glottis into the mouth by the instrument used in exploration. Sometimes the location of the foreign body is such as to impede the introduction of a canula, if it is necessary to keep the wound open.

All instruments ought to be warmed before being passed into the trachea, as they are much less likely to cause severe spasm than if cold. The instrument employed will vary with the nature of the case and the resources of the surgeon. A long, bent probe with a blunt, hooked extremity will often be of service. So also a pair of delicate curved forceps, such as

are used for torsion of nasal polyps. The curved portion of the laryngeal forceps may be used with success. Whatever instrument is employed, it should first be manipulated as a sound or searcher until the location of the foreign body is discovered; and then suitable efforts may be made at extraction. When the body lies at the commencement of one of the bronchi, care must be taken that it is not pushed farther on in the manipulation. Under these circumstances a stout copper or other flexible wire, terminating in a small, blunt hook, may be insinuated past the body and then drawn upon to dislodge it, when it will be likely to be coughed out or coughed within grasp of the forceps at the seat of the wound. Dr. Sands, of New York, discovered that the bifurcation of the trachea can be reached by the forefinger from the ordinary tracheal wound, and may be taken advantage of to detect the position of the foreign body, and thus facilitate the intelligent use of instruments for its extraction.¹ Efforts at extraction should not be prolonged for many minutes. It is much better practice to keep the wound open by hooks, or by ligatures passed through its edges and fastened round the neck, and to repeat the efforts at removal in a few hours or upon the following day. Meanwhile the wound should be covered by a fold of thin muslin to modify the temperature of the inspired air. Very often the foreign body is expelled through the wound thus left open, during the absence of the surgeon.

The wound should be kept patulous until the foreign body has been expelled; and if this does not take place for a long time, a canula may be worn to keep it patulous; but under ordinary circumstances the canula will be in the way and prevent the expulsion of a foreign body situated below it. Under these circumstances, should there arise any evidence of the dislodgment of the body, the canula should be promptly withdrawn to give it chance to escape. Sometimes the foreign body is forced by cough along the side of the canula and escapes by the mouth.

As long as the wound is kept open, the air of the apartment in which the patient resides should be kept warm and moist by the evaporation of steam. When the foreign body has been expelled, or when from other reasons it is deemed desirable to

¹ Buck: Trans. N. Y. Acad. Med., N. Y., 1870.

close the aperture, the edges of the cutaneous wound are brought together by adhesive strips, and sutures if necessary. A simple dry dressing is usually all that is requisite. The wound usually heals kindly in a few days, unless kept patulous in part by convulsive or catarrhal cough and the escape of air; under which circumstance a permanent tracheal fistula sometimes results.

Another operation for removal of a foreign body in the larynx, and consisting in entering the pharynx by an incision practised below the hyoid bone—a pharyngotomy to which the term sub-hyoidean laryngotomy is sometimes employed—was resorted to by Dr. Lefferts, of New York,¹ to remove a brass watch-ring which had become imbedded in the tissues of the larynx, encircling the aryteno-epiglottic fold and ventricular band of one side; and thus interesting both the external and internal wall of the respiratory canal at that point. The character of the case, and the resort to this operation for its removal, are both unique in the records of surgery.

NEUROSES OF THE LARYNX.²

NEUROSES OF SENSATION.

Anæsthesia of the larynx occurs in diphtheritic paralysis, in so-called bulbar paralysis, and in hysteria. It may be partial or complete. It is sometimes associated with anæsthesia of the pharynx and of the palate. The asserted anæsthesia of the epiglottis, described as pathognomonic of hysteria, is but an occasional manifestation. Laryngeal anæsthesia is one of the phenomena of approaching dissolution in various affections. The *symptoms* are usually only such as are due to the coexisting paralysis, and are not of a character to indicate anæsthesia, unless it is evident that particles of food escape into the larynx without producing the uncomfortable sensations usually produced by that accident. The *diagnosis* is determined by the absence of reflex action on testing the excitability of the intralaryngeal mucous membrane with the laryngeal probe or other instrument. In some instances the anæsthesia has been found

¹ A brass ring lodged in the larynx for four years. The Medical Record, N. Y., Dec. 15, 1874, illustrated.

² For an elaborate discussion of this subject, see Ziemssen's Cyclopædia, N. Y. Ed., Vol. VII.

to exist as far as the upper surface of the vocal cords only ; in others to include the infra-glottic portion of the larynx and more or less of the trachea. In one instance, observed at my clinic, there was anæsthesia of the entire trachea, so that I could pass a sponge probang clear to the bifurcation, without exciting spasm or painful sensation. The *prognosis* is good, unless the coexisting paralysis is sufficient in itself to threaten life.

Treatment.—General treatment is required, varying with the cause of the condition. In case the accompanying paralysis is so great as to prevent deglutition, and nourishment by the stomach-tube is indicated, caution is requisite lest the tube be inserted into the anæsthetic larynx, which will not resist its introduction as under ordinary circumstances. Phosphorus and strychnia are usually indicated as medicinal agents, and the latter is often administered advantageously hypodermically (one-thirty-sixth to one-twenty-fourth grain, gradually augmented), at intervals of two days, or more frequently. Local stroking with the electric brush, with a moderately strong current from the secondary coil of an induction apparatus, applied to the interior and exterior of the respiratory walls of the larynx, will sometimes rouse the obtunded or dormant sensibility ; the negative electrode being applied to the larynx, and the positive electrode, by means of a large sponge, to the exterior of the throat and the nape of the neck.

Hyperæsthesia of the larynx is frequently observed in inflammatory affections of the larynx. It sometimes occurs in nervous and hysterical subjects. It is often associated with a similar condition of the pharynx and palate. The *symptoms* are morbid sensations of very diverse character, usually described as extremely distressing, and more or less continuous. The *diagnosis* is established by laryngoscopic inspection and intra-laryngeal manipulation. The *prognosis* depends upon the removal of the cause.

Treatment.—General treatment of the systemic condition is required, as well as treatment for any local disease which may cause the hyperæsthesia, or keep it up. The use, several times a day, of sprays of ice-water or of sedative solutions, such as are mentioned in the earlier pages of this volume, is indicated. Local applications of solutions of bromide of potassium or ammonium, iodoform, chloral, camphor, aconite, morphia,

neutral nitrate of bismuth, at frequent intervals (a day, or less), or the occasional (once a week) effectual application of a strong solution of tannin or nitrate of silver thoroughly applied on a large sponge, upon which the parts are allowed to contract, are useful in overcoming the morbid sensitiveness of the parts. The very sensitiveness of the parts usually unfits them for tolerating the presence of an electrode, but the prolonged use of the constant current percutaneously, or the positive pole of an induction current to the exterior of the larynx, and the negative to the nape of the neck or in the hand, is sometimes useful.

Neuralgia.—Neuralgia of the larynx sometimes occurs. It may be associated with neuralgia of adjacent structures, and of the face. It is not infrequent in carcinoma and other clinically malignant affections. It is occasionally excruciating in syphilis (see p. 125).

The *symptoms* are those of peculiar intermittent, darting, lancinating, or shuttle-like pains, as in other neuralgias. The *diagnosis* rests on the peculiarity of the pain. The *prognosis* depends upon the character of any existing local lesion. In malignant disease, there is no relief except from anodynes. In idiopathic neuralgia, the prognosis is usually favorable, and to a lesser degree when accompanying external neuralgias.

Treatment.—Laryngeal neuralgia must be treated constitutionally on general principles by iron, phosphorus, strychnia, arsenic, or anodynes, according to the systemic indications. I know of no local treatment calculated to relieve the pains.

SPASM OF THE LARYNX.

(Laryngismus Stridulus, Spasmus Glottidis, Phreno-glottismus ; Suffocatio Stridula, Angina Stridulosa ; Suffocative Laryngismus, Spasm of the Glottis, Spasmodic Croup ; Pseudo-Croup ; Cerebral Croup.)

The characteristic manifestation of this affection is a sudden spasmodic closure of the glottis, or of the vestibule of the larynx, preventing the free inspiration of air ; the attempt at inspiration being usually accompanied by a peculiar vocal stridor, almost identical with that which occurs in croup and whooping-cough, or when any local irritant has excited a

spasm of the glottis. There is danger of suffocation during the spasm.

It is purely a nervous affection, unaccompanied by local inflammation. Though occurring occasionally in the adult, it is particularly a disease of childhood, usually confined to the period of the first dentition; and, to a certain extent, chiefly among those who have been weaned early.

It has been known to occur in the new-born child, proving fatal in a few hours.¹ In some cases a predisposition to the spasm seems to be hereditary. It may be due to occlusion of the orifice of the larynx by an abnormally pendent epiglottis, or by impaction of the epiglottis from spasmodic contraction of the aryteno-epiglottic muscles, and subsequent incarceration of the free edge of the epiglottis, when long and pointed, between the larynx and the pharynx.

In the summer of 1867 I had under professional care a scrofulous male infant, between two and three years of age, with protracted laryngismus stridulus; the suffocative paroxysms, as described by the mother, being unusually intense. On one occasion an intense paroxysm occurred in my presence, and as it failed to yield to cold water dashed upon the face and neck, or to ammonia held in front of the nostrils, I plunged my forefinger deep into the child's throat and felt the epiglottis so forcibly drawn down by the spasmodic action of the aryteno-epiglottic muscles that its free edge had become wedged between the posterior face of the larynx and the wall of the pharynx, occluding the larynx completely. Carrying the finger to the left side of the larynx I found it comparatively easy to free the epiglottis from its incarcerated position; and with the ensuing deep inspiration of air, the impending asphyxia was averted. The nature of the difficulty was explained to the mother, who was instructed in the manipulation necessary to overcome it. The constitutional remedies and other measures instituted in the hope of subduing the disposition to spasm were unavailing; and the child finally died, some weeks later, in a paroxysm similar to the one described.

A second case occurred during the spring of 1877, in a scrofulous male infant, nineteen months of age. I had the opportunity of verifying the same sort of incarceration of the epiglottis from spasmodic action, on several occasions, one of which was in the presence of an esteemed colleague during a consultation held as to the propriety of performing tracheotomy, in view of the frequent recurrence of the paroxysms. Unfortunately it was determined to defer the decision for twenty-four hours, in order to test the efficacy of large doses of bromide of potassium; and shortly before the early hour fixed for the visit on the following morning, the child died in a paroxysm which the mother was

¹ Hugh Miller : Brit. Med. Journ., Nov. 17, 1877, p. 689.

unable to overcome by manipulation, although she had previously succeeded in elevating the epiglottis in several paroxysms.

I am inclined to believe, therefore, that the spasm of laryngismus affects the aryteno-epiglottic muscles, in some instances at least, as well as those muscles which close the glottis; and that the incarceration of the epiglottis, continuing after relaxation of the spasm, may be an immediate cause of death. In undoubted cases of this kind, tracheotomy may be absolutely indicated as necessary to avert asphyxia in a recurring paroxysm of spasm.

All laryngeal inflammations in children are prone to excite direct spasm of the laryngeal muscles, which is then an epiphenomenon of importance.

The pathology of this affection seems to have been misinterpreted, until it was shown by Dr. Marshall Hall to be frequently due to the reflex action in the motor system of nerves excited by the irritation of the trifacial in dentition, the pneumogastric in nutrition, or the spinal nerves in disorders of the intestines. It occurs frequently in children of scrofulous diathesis, especially those who are the subjects of rickets. Caries of the cervical vertebræ has in some instances been discovered after death. The pressure of an enlarged thymus gland (thymic asthma), of an abscess, or of an enlarged bronchial gland upon some part of the course of the pneumogastric or of the spinal accessory nerve is also, at times, the cause of spasm of the larynx.

Spasm is not the sole element of insufficiency of the rima glottidis, as there is often coincident paralysis of the posterior crico-arytenoid muscles; sometimes bilateral, sometimes unilateral. In some cases of supposed spasm the tongue is swallowed, as it were, occluding the larynx; and this is occasionally fatal.¹

Spasm of the larynx is generally manifested suddenly, usually during sleep; the child waking in fright, with temporarily suspended respiration from closure of the glottis, or with excessive dyspnœa attended by a peculiar phonal inspiration produced by the forced passage of the air through the vibrating lips of a spasmodically contracted glottis. Indications of impending suffocation are present during a severe paroxysm, and death may take place in the spasm, even at the very first paroxysm; but usually, just as asphyxia seems im-

¹ For recent examples see Hennig (*Jahrb. für Kinderheilk.*, XL, 2 and 3.): *Am. Jour. Obstet.*, Jan., 1878, p. 208.

minent, the spasm relaxes, probably from the anæsthetic effects of the retained carbonic acid gas, and the air rushes into the windpipe with a characteristic stridor; sometimes with the intervention of a paroxysm of coughing or of crying, or of both together, the entire phenomena occupying but a few moments. In some cases but a single paroxysm occurs; but in most of them others follow at intervals of a few days or a few hours, sometimes with increasing frequency. The first paroxysm may be the most serious one of the series, but is oftener less serious than those that follow. In some instances the paroxysms are accompanied by spasmodic contractions of the extremities, and in occasional ones they are followed by general convulsions. Sometimes sudden fright, or sudden excitement in play, such as is produced by tossing the child into the air, excites the first paroxysm of the affection.

The paroxysms may cease for a time, to recur at intervals of a few days, a few weeks, or a few months, the susceptibility continuing for a protracted period. Recurrences after comparatively long periods are often coincident with fresh eruption of teeth.

Some cases are attended by an inconstant laryngo-tracheal, or even broncho-tracheal, mucous râle, due to accumulations of secretions in the air-tube—for the air-passages of children are very tolerant of such accumulation; but this is usually a complication from some intercurrent and perhaps altogether independent cause. Symptoms of cerebral irritation sometimes co-exist with this affection, and become manifested during its paroxysms; and they are usually due to coexistent causes of independent origin.

Symptoms.—These are sudden inspiratory stridor, which may be followed by apnœa or asphyxia, with the other phenomena already detailed.

Diagnosis.—The absence of fever, cough, and alteration of voice, distinguishes this affection from croup, with which it is sometimes confounded. The ingestion of unusual food, the existence of inflamed gums, or other sources of irritation, constitutional or local, indicate the nature of the affection.

Prognosis.—The danger of asphyxia in a paroxysm renders the prognosis doubtful in any individual instance; but by far the greater number of cases recover. The probable ultimate prognosis will depend upon the nature of existing complica-

tions, the possibility of overcoming the apparent disposing causes, and the diathesis, general health, and hygienic surroundings of the patient.

Treatment.—The indication during the paroxysm is to relax the spasm and ward off asphyxia. This is accomplished by dashing cold water upon the child's face, and other exposed parts of its body; cold sponging; exposing the surface to a current of cool air; slapping the breast, back, buttock, etc.; the patient being placed in a warm hip-bath, if the facilities for so doing are at hand. If the spasm does not relax, the forefinger should be placed deeply into the throat to discover whether the epiglottis is impacted, and if so, the finger is to be insinuated beneath it so as to release it. Dr. Gibb¹ recommends holding the child on its stomach, which he thinks allows the tongue and epiglottis to fall forward, and permits the lips of the glottis to become relaxed. This is usually all that can be done at the first paroxysm. For use in subsequent paroxysms, warm water should be at hand for purposes of the bath, or for the administration of an enema; morphia for hypodermic injection, or an anæsthetic, for use by inhalation.

After subsidence of the paroxysm, efforts must be made to overcome the immediate source of reflex irritation, which may reside in the mouth, stomach, intestines, prepuce, spinal column, or brain. In addition to this, antispasmodic remedies should be employed externally and internally, with cautious resort to narcotics, chloral, and the bromides, if not contraindicated.

If the child is deficient in vigor, the use of vegetable or mineral tonics is indicated; if scrofulous, cod-liver oil, extract of malt, iodide of iron, sulphate of potassium, chloride of calcium, phosphate of lime, may be most suitable.

The gums should be looked after, too, the bowels kept relaxed and great care be paid to diet, proper clothing, and the maintenance of equable temperature.

Laryngismus stridulus sometimes occurs in the adult, usually in connection with a paralytic condition of the posterior crico-arytenoid muscles. The rigid approximation of the vocal cords is markedly apparent in the laryngoscopic image. The cause

¹ Op. cit., p. 334.

in the adult, may be reflex action from disease of the alimentary canal or other portions of the body; or it may be of cerebral origin, or be due to pressure upon the nervous trunks; or it may be one of the manifestations of hysteria. The spasm is usually temporary and recurrent. I have seen it permanent. The condition is sometimes attendant upon the laryngitis of phthisis, several instances of which have occurred in my own practice. When this paralytic condition exists, any slight exertion, or even mental emotion, will excite spasm of the glottis. Rest, then, physical and mental, is an important element in the treatment of the affection. Systemic remedies suited to the diathesis, to the condition of the organs of digestion and secretion, are required, together with the use of antispasmodics, and of relaxing inhalations. Topical treatment of the larynx is imprudent, as liable to excite spasm of the glottis. If the affection appears permanent or persistent, especially if there be laryngoscopic evidence of the paralytic condition of the muscles which dilate the glottis, tracheotomy is indicated;¹ and it becomes imperatively demanded in the presence of marked evidences of inflammatory action, inasmuch as a moderate swelling, of no moment under ordinary circumstances, would here render respiration impossible.

After the performance of tracheotomy, the local application of the electric current to the affected muscles would not be dangerous to life, and theoretically would hold out reasonable prospects of cure. Practically, it has failed, in my hands, to be of any benefit whatever. Should this fail, the opening in the trachea would have to be kept patulous until the condition subsided spontaneously, or through the influence of a general tonic treatment.

Spasm of the glottis sometimes occurs in connection with the ulcerative laryngitis of phthisis, independently of any direct element of paresis; and under these circumstances fatal suffocation may suddenly supervene.

In a case apparently of this nature,² examined two hours and one-half after death, the rima glottidis was found completely and rather firmly closed, the

¹ In four non-inflammatory cases of this nature in which I counselled tracheotomy as a precautionary measure, death in a paroxysm of spasm of the glottis has been the penalty paid for disregarding the advice.

² Porter: *Op. cit.*, p. 231.

upper part of the larynx being the seat of extensive ulceration. About twenty-four hours after the death, the opening of the glottis had become nearly as large as it should have been normally.

Spasm of the larynx may be excited by the presence of foreign bodies in the air-tube or pressing upon it, by the presence of tumors in the tube or pressing upon it, or by pressure upon the laryngeal fibres of the pneumogastric nerve, or by pressure upon their points of origin within the cranium. Discrimination in these cases requires careful consideration of the history of the case, accurate laryngoscopic inspection, and minute physical exploration of the neck and thorax.

SPASM OF THE TRACHEA.

Spasm of the trachea occurs occasionally. Porter¹ reports a case, the dissection of which showed a contraction of the trachea to more than two-thirds of its diameter, and one inch and a half in length, situated midway between the larynx and the bifurcation of the trachea. The contraction relaxed gradually after the tube was slit, so that, the day following, the part did not appear contracted, or in a state of disease of any kind.

Dr. Beverley Robinson² performed tracheotomy in an adult for spasm of the air-tube, and, as attacks of dyspnoea recurred subsequently, it was evident that the difficulty existed below the orifice in the trachea. He had failed to detect any aneurism, and attributed the paroxysms to spasmodic asthma.

Spasm of the trachea is probably due to contraction of the muscular fibres in the posterior or so-called membranous wall of the trachea, described by Portal, Sir Charles Bell, Meckel, Koelliker, and others.

IRRITATIVE COUGH.

There is an irritative cough, usually referred to the trachea, occasionally to the larynx, apparently nervous in origin, sometimes reflex, sometimes attendant upon local irritation or congestion, which simulates to some extent the dry, short, hack-

¹ Op. cit., p. 18.

² N. Y. Med. Jour., 1878, March, p. 299.

ing cough in the early stage of pulmonic phthisis. The cough is more or less frequent, sometimes paroxysmal, occasionally periodically so, and usually most frequent in the morning. As a rule, it does not occur at night, and sleep is good. It is usually encountered in connection with disorders of the mouth, teeth, stomach, liver, or uterus. It is sometimes very violent during dentition.

Treatment.—A few drops (ten to thirty) of spirit of chloroform with wild cherry, in infusion, fluid-extract, or syrup, will often relieve the disposition to cough. Meanwhile, constitutional or local treatment, directed to the source of irritation, is requisite.

SPASMODIC COUGH.

A peculiar spasmodic cough occurs independently of any appreciable lesion. It is most frequent in females, and is usually attributable to hysteria. Sometimes it is associated with some degree of dementia. Sometimes it is accompanied with choreic movements of the head or trunk. It occurs in married as well as in unmarried women, and in males as well as females. There is usually some characteristic tone to the cough, such as that of the cry of one of the lower animals, the yelping as of a little cur being the sound most frequently met with. Paroxysms of cough come on more or less frequently, at irregular intervals of about five or ten minutes, half an hour or longer, and continue for two, three, five, or more minutes at a time, the characteristic sound of the cough being repeated fifty or sixty times a minute.

In a peculiar case under my care, some years ago, the sound of the cough might be represented by the syllables "ha, hich," the latter syllable having the Greek or Teutonic sound, and being given at a pitch a fourth higher than that of the first one. The subject of this affection was the daughter of a clergyman. In another subject, also the daughter of a clergyman, the sound was so much like that of a little poodle, that patients in the reception-room during the time of her visit would ask, "Why that lady hadn't sense enough to leave her dog in her carriage?" This character of cough is often met with. Some twenty years ago, a girl's boarding-school in Philadelphia was broken up in consequence of an hysterical spasmodic cough of this kind spreading among the scholars. The people in the neighborhood were wont to collect in front of the school house to hear the girls bark, which made matters worse, so that finally the school had to be temporarily dismissed, and the pupils distributed to their various residences.

I have had under my care three cases of spasmodic cough occurring in three brothers more than forty years of age, a fourth and older brother being similarly affected; the cough having continued in each case from fifteen to twenty-five or more years. The father of these four brothers was subject to similar cough from his boyhood until he had become over seventy years of age, since which time, a period then of more than ten years, he had not suffered from this cough. The sisters of these gentlemen have never been affected with the cough. The father and three of the sons are regular physicians in good standing. The three cases referred to I examined laryngoscopically. The larynx was very much congested in each instance, but I could detect no other cause for the trouble than the very large size of the epiglottis. The gentleman with the largest epiglottis informed me that he was subject to suffocative spasms at the dinner-table, in one or two of which he had become unconscious, but had been brought-to by his wife, who places her fingers back in his throat. Two of his brothers have had several similar spells also, though they recovered without the interference of a second person. I feel inclined to the opinion that the epiglottis of these gentlemen sometimes becomes impacted into the larynx in deglutition, thus producing the spasm of suffocation—a condition which I have known to occur repeatedly in young children subject to suffocative paroxysms, in whom I have detected a large epiglottis as the cause of the paroxysms, and whose parents I have taught the method of relief by running the finger down beneath the epiglottis and pulling it up. Two of these children were also subject to spasmodic cough.

A Philadelphia lady, married for twenty-eight years, and who had been a subject of spasmodic cough for more than twenty years, had an epiglottis quite deeply indented in the centre of its free edge, its lateral portions projecting so much beyond the depressed portion as to give it somewhat the appearance of a fissure. The laryngeal face of the epiglottis was red and very velvety in appearance.

The laryngoscopic appearance of the glottis in the production of spasmodic cough is very peculiar. The cords come together as though driven with great force from the exterior, and then suddenly separate as the peculiar sound of the cough is made. I have watched the action over and over again during the entire paroxysm of a barking cough, without in the slightest way embarrassing the patient, or the cough either. In cases where the cough has a deep, rough sound, the vocal cords do not approximate, but are succussed into comparatively slow vibrations by the shock of the expiratory current of air, and thus produce a peculiar, low-pitched, muffled tone. When phonation is attempted the cords approximate normally. Occasionally I have found that a forced expiration or a forced inspiration would break the spasm for a moment; and under these circumstances the patient is enabled to control the paroxysm—a matter of moment in resuming social intercourse, itself

of therapeutic benefit as a mental or emotional tonic. There is rarely much evidence of local disorder in the larynx other than intense injection of the mucous membrane covering the supra-arytenoid cartilages, sometimes of the laryngeal face of the epiglottis, and sometimes, again, of the entire larynx; these congestions being in all probability the result of the constant cough, and not its cause.

Treatment.—Proper treatment of these cases is often perplexing. Anti-spasmodic remedies avail at one time and are useless at others. The general health, when impaired, as is frequently the case, requires due attention; and in females any sexual irregularity or infirmity is to be corrected. Anodyne inhalations often moderate the intensity and frequency of the cough. The same result also follows, at times, the internal use of belladonna, gelseminum, bromide of potassium, arsenite of potassium, or chloral. Sometimes the internal use of strychnia controls the cough. In one of the cases of the brothers referred to good results attended the local application of tincture of aconite root to the epiglottis, followed immediately by a saturated solution of tannin in glycerine. This relieved the cough from the first, and controlled the frequency and intensity of the paroxysm for a long time. The cough eventually lost its peculiar shrill, unpleasant sound, and became more like the cough of chronic bronchitis in elderly people.

I have seen good results follow the local employment of electricity in a few instances, but I am not prepared to deny that the emotional influence of the manipulations was not without a calming effect. In these applications I employed the positive pole of the secondary coil of an apparatus of induction, within the larynx, and the negative pole by large electrodes to the naked feet, and after a few moments the positive pole was shifted to the exterior of the larynx, the operator's hand being employed as electrode. During the applications of the current the cough ceased, and would often remain controlled for hours at a time, recurring less and less frequently, and in shorter paroxysms, with perhaps but one or two characteristic barks at a time instead of fifty to sixty in rapid succession, and so on, gradually diminishing in frequency and intensity, until the attacks ceased altogether.

At other times I have resorted effectually to the continuous galvanic current from ten to fifteen or twenty elements, an

elongated electrode connected with the positive pole being placed over the cervical region of the sympathetic nerve, on each side alternately, a few minutes at a time, and the other electrode being held in the hand of the same side. In one instance, occurring in a lad of eleven years of age, the son of a medical gentleman, a single application of this kind controlled the spasmodic cough at once and permanently, though it had existed for several months, and was very severe in character. Seven years later a similar cough was controlled in this patient in the same manner. Applications of this kind require great care, and should be discontinued immediately upon the occurrence of any unpleasant sensations in the part, in the chest, or in the head. Each application should continue for thirty seconds to three or four minutes only, according to the susceptibilities and tolerance of the patient.

A spasmodic cough, of less intensity, sometimes occurs in affections of the ear, the influence being conveyed, probably, through the chorda tympani nerve. Cases of obstinate cough, without sufficient cause in the throat, require careful examination into the condition of the auditory apparatus. Inasmuch as affections of the epiglottis, such as œdema, ulceration, etc., are sometimes accompanied by severe pain in the ears, pain to which the local suffering at the seat of disease is as nothing in comparison, it is likely that a reverse influence produces an irritability of the epiglottis or of the glottis itself, in cases of affections of the ear or of the Eustachian tube, to the pharyngeal portion of which the larynx is in direct communication by one of the divisions of the pharyngo-palatine muscle. The cause of the ear-cough being recognized, the treatment will of course be directed to that cause.

MOTOR PARALYSES OF THE LARYNX.

Paralyses of the muscles of the larynx may be due to infiltration of the muscular fibres, muscular atrophy, tumefaction of adjacent tissues, direct compression from infiltrations, morbid growths, or foreign body, compression, wound, or injury of nerve-tracts, inclusion of nerve in a ligature, cerebral disease, constitutional dyscrasia, general or local anæmia, or hysteria. Paralyses of long standing may lead to atrophy or

fatty degeneration of the muscles as a result of their inaction, or even to atrophy of the vocal cords. Sometimes it leads to atrophy or degeneration of the nerve.

Motor paralyses from direct nerve lesion may exist alone or associated with paralyses of sensation. They may be confined to a single muscle, or may implicate several muscles, or one or more groups of muscles. The paralysis may be in the domain of either superior or inferior laryngeal nerve, or may involve both. It may be bilateral or unilateral, and either form may be partial or complete. It may be limited to the larynx, or be associated with paralysis of the pharynx or palate, or with regional or general paralysis.

Bilateral paralysis is usually due to cerebral disease, systemic intoxication, bilateral injury, or functional disturbance. Unilateral paralysis is usually due to local disease or injury, whether cerebral or peripheral. Special causes will be enumerated under the head of the individual forms of paralysis.

The innervation of the muscles of the larynx, with the exception of a single pair, the crico-thyroids, is derived from the inferior or recurrent laryngeal nerves, and that pair is supplied by the superior laryngeal nerves.¹ Both sets of nerves are derived from the pneumogastric, their motor filaments,—for the superior laryngeal is chiefly a nerve of sensation, being offshoots from its spinal accessory fibres. They are, of course, liable to compression from disease in the cervical region. In addition to this, it is to be borne in mind that the recurrent laryngeal nerve of the left side, which is much the more frequently affected, winds around the arch of the aorta from before backward, whence, from a point between the origins of the innominate and carotid arteries, it courses upward in front of the œsophagus in the furrow between that organ and the trachea, and is thus accessible to intrathoracic compression of various kinds; while the recurrent nerve of the right side winds around the subclavian artery, which it crosses, and then runs up behind the trachea in the tracheo-œsophageal furrow of that side, and is therefore chiefly liable to compression from disease at the apex of the right lung, as it lies between the pleural sac and the artery. Muscles of antagonistic function, dilatation and contraction, are thus supplied by filaments from the same nerve, disease of which may produce paralysis in some of the muscles, and spasm in others. (Concerning the action of the muscles supplied by these nerves, see p. 62.)

¹ Some observers maintain the opinion that this nerve also supplies the thyro-epiglottic and aryteno-epiglottic muscles, at least in part; not from anatomical demonstration, which fails to prove it, but as a clinical inference from observing that paralysis of these epiglottic muscles is sometimes associated with paralysis of the crico-thyroids, and not unfrequently with paralysis of sensation in the domain of the same nerve. Some, too, claim that it serves in part to innervate the arytenoid muscle likewise.

In compliance with the happy suggestion of Dr. Morell Mackenzie,¹ laryngoscopists generally term the posterior crico-arytenoid muscles the abductors of the vocal cords, because these muscles separate the cords, and the lateral crico-arytenoids and the arytenoid proper the adductors, because they bring them toward each other; while the thyro-arytenoids have been designated as laxors, and the crico-thyroids as tensors of the vocal cords, respectively, in virtue of their action on these structures.

Paralysis of the Thyro-Epiglottic [and Aryteno-Epiglottic?] Muscles.—The thyro-epiglottic muscles are the depressors of the epiglottis, which aid in its occlusion of the orifice of the larynx to prevent the ingress of food and drink in deglutition. Diphtheria is the most frequent cause of this paralysis, the manifestation occurring sometimes during the disease, and sometimes after it. It is likewise part and parcel of the completed phenomena of progressive bulbar paralysis, and perhaps of some cases of general paralysis. It may be associated with paralysis of the contractors of the glottis, under which circumstance it may become difficult to nourish a child tracheotomized in diphtheria, nutriment escaping into the larynx, and thence, in part, externally through the wound or the tube. It is a matter of uncertainty whether this paralysis is in the domain of the superior or the inferior laryngeal nerve.

Symptoms.—There is escape of food and drink into the air-passages, with the usual manifestations of the accident, as detailed under the heading of foreign bodies in the air-passages (p. 616).

Diagnosis.—The epiglottis is seen, in the laryngoscopic image, to remain erect, and not to become depressed in imitated movements of deglutition, which, with the mouth open, are of course incomplete. When proceeding from diphtheria the paralysis is usually associated with paralysis of the palate or pharynx, and impairment of sensation or anæsthesia in the interior of the larynx.

Prognosis.—This depends upon the possibility of nourishing the patient, and preventing food from entering the air-passages, and on the response of the paralyzed muscles to nerve tonics, and to electric excitation. Prognosis as to life is influenced by the nature of coexisting paralyses, and the character of the initial lesions.

¹ Hoarseness, Loss of Voice, and Stridulous Breathing, London, 1868, p. 2.

Treatment.—Strychnia hypodermically (one-sixty-fourth grain daily, or less frequently) with phosphorus (one-one-hundredth to one-thirtieth grain two or three times a day) and cod-liver oil, if they can be introduced by the œsophagus, or even by the rectum, in larger proportions, are indicated constitutionally. Local electrization of the paralyzed muscles (one electrode at the lateral border of the lower portion of the epiglottis) may be resorted to daily. Food may require introduction by enema or stomach-tube.

Paralysis of the Crico-Thyroid Muscles (tensors of the vocal cords).—This is the only paralysis positively in the domain of the superior laryngeal nerve. It is most frequently bilateral, but may be unilateral. It may be associated with paralysis of the antagonizing group of muscles (thyro-arytenoids), and with paralysis of the lateral crico-arytenoids, or with both, as is not infrequent. The most frequent cause is overstraining the vocal cords in shouting, screaming, and singing in too high a pitch, or during an attack of sore throat.

This form of paralysis has occasionally been directly produced in ligating the primitive carotid artery, from inclusion of a little twig which leaves the superior laryngeal nerve just before its division into the two branches, passing to the external and internal faces of the wing of the thyroid cartilage respectively. If, therefore, the voice is rough and deep, or otherwise altered after an operation upon the primitive carotid, it may be inferred that this twig has been included in the ligature.

Symptoms.—There is a lack of precision in tone, with a loss of control of the voice, and frequently an inability to command the higher notes, a peculiar dissonant sliding rise in pitch being occasionally manifested involuntarily in conversation. Prolonged vocal effort is often fatiguing, and sometimes painful.

Diagnosis.—In marked cases laryngoscopy reveals a lack of longitudinal tension in phonation, sometimes associated with a more or less slight undulatory outline of the horizontal surface of the vocal cords, which are usually slightly congested, sometimes with a pearlish translucence. In other cases the abnormal appearances are so slight as to elude detection, and the localization of the paralysis is an inference from the character of the phonal symptoms, and the lack of any other positive means of accounting for them.

Prognosis.—Recovery of the normal voice may be anticipated, but may require protracted treatment; but it is not to be expected when the paralysis is due to surgical injury, or to disease of the nerve.

Treatment.—Rest from vocal effort, and the local use of the induced current percutaneously, both the electrodes over the region of each muscle alternately (to the outer sides of the crico-thyroid ligament), are the indications. If this be insufficient, one electrode may be inserted into the larynx on either surface of the latero-posterior wall of the cricoid cartilage. Mechanical manipulation externally, so as to bring the cricoid cartilage upward and forward upon the thyroid, is sometimes useful as a local gymnastic exercise, especially in those cases in which the paralysis is associated with paralysis of the lateral crico-arytenoids in a frequent form of aphonia.

Paralysis of the Thyro-Arytenoid Muscles (relaxors of the vocal cords).—This form of paralysis is quite frequent, and may be bilateral or unilateral. It is sometimes associated with paralysis of the antagonizing muscles (crico-thyroids), or with paralysis of the arytenoid, and lateral crico-arytenoids. Its most frequent cause is forced use of the voice during catarrhal inflammation, and during the change of voice; but it is likewise produced by straining the vocal cords in shouting, singing, screaming, and prolonged speaking, even when there is no inflammation.

Symptoms.—The impairment of voice is chiefly manifested in a rise of pitch, but a deep tone can sometimes be obtained by effort. The quality of the tone is unpleasant in either case,

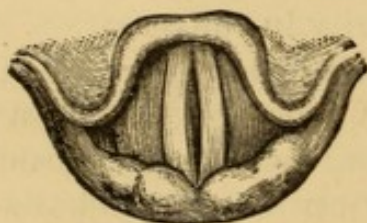


FIG. 185.—Bilateral paralysis of thyro-arytenoids in acute laryngitis (Ziemssen).

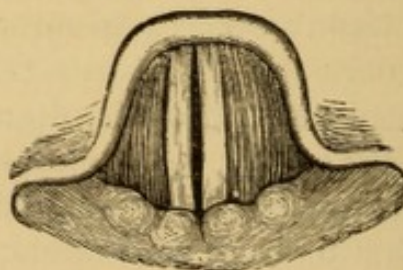


FIG. 186.—Unilateral paralysis of (right) thyro-arytenoid (Ziemssen).

and vocal effort is fatiguing or even painful. If associated with paralysis of other muscles in the domain of the inferior laryngeal nerve, there is dysphonia or aphonia, as the case may be.

Diagnosis.—The vocal cords approximate posteriorly, but not without a decided bulging outward at the central portion of the glottis, the orifice of which during phonation is elliptic (Fig. 185). In unilateral paralysis, the ellipse is incomplete (Fig. 186). When associated with paralysis of the arytenoid muscle, the ellipse is incomplete posteriorly at the vocal processes of the arytenoid cartilages, and the intercartilaginous portion of the rima glottidis bulges outward (Fig. 187), from failure of contact of the cartilages and their processes.

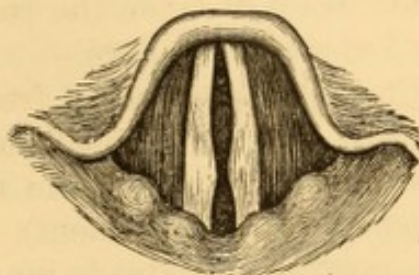


FIG. 187.—Bilateral paralysis of thyroarytenoids with paresis of arytenoid (Ziemssen).

Prognosis.—Satisfactory restoration of voice may be expected in cases resulting from simple over-exertion of the voice, and in those occurring in acute laryngitis. In cases due to over-use of the voice, during the period of normal change, it is more doubtful. The singing voice is sometimes impaired permanently.

Treatment.—This consists in resting the voice, and in systematic vocal exercises, declamatory and rhythmic, in that portion of the scale in which the voice is defective. Young men with shrill voices, who are able to speak in a base tone with effort, should be encouraged to use that tone deliberately when required to speak, and to avoid the shrill tone at all times, using the voice as little as possible. Direct electric excitation of the muscles may be employed for a few minutes each day, either with the laryngeal electrode in contact with the vocal cords, or exteriorly, according to Ziemssen's plan, with the electrode in the pyramidal sinus, and therefore outside the respiratory canal.

Bilateral Paralysis of the Lateral Crico-Arytenoid Muscles (lateral adductors of the vocal cords).—This form of paralysis may be complete or incomplete. It rarely exists as an isolated paralysis. It may be functional, or be due to organic or structural lesion. In its functional form it is by far the most frequent of all the laryngeal paralyses. It is very often associated with paralysis of the arytenoid muscle (central adductor of the cord), and sometimes with partial, or even complete paresis of the posterior crico-arytenoids (abductors), and may likewise be as-

sociated with paralysis of the thyro-arytenoid muscles (laxors), or the crico-thyroids (tensors), or both. It is often a manifestation of hysteria in males, as well as females, and the loss of voice which it entails is in such cases denominated hysterical or nervous aphonia (functional paralysis). Nervous aphonia from this paralysis may exist, however, independently of any evidence of hysteria, and occurs in anæmic and chlorotic subjects, and in phthisis. It also occurs at the menopause. It sometimes results from shock, fright, or other mental emotion.

A case under my care occurred in a married lady, intelligent, and apparently sound in mind and body, who lost her voice several years previously under the following circumstances: She was residing in the country, and received an urgent message to visit her parents' home, as her father, to whom she was much attached, lay very ill. On her arrival she was met by the physician, who explained to her that her father was dying. On entering her father's room, and realizing his condition, she was unable to speak to him, though her voice had been as good as ever the moment before, and had survived the shock of the mournful intelligence. This condition had persisted for three or four years in spite of treatment. It was permanently cured by electricity.

Aphonia from hysteroid paralysis of the vocal cords is manifested in conversation only in some cases, the voice being reliable in singing.

One of my patients actually performed duty in a church choir in Philadelphia for more than two years, during the whole of which time, according to her assertion, she had been unable to utter a vocal sound in conversation. I cannot recall any case before puberty, and the greater number occurred at or about the menopause. In some cases there has been marked anæsthesia of the laryngeal mucous membrane, but this manifestation has not been constant or characteristic. In others there has been hyperæsthesia. In some there has been no power at all to decrease the size of the patent glottis. In others there has been more or less, in some almost amounting to normal closure for phonation. A few of them have exhibited more power on one side than the other.

The cause of these paralyses is sometimes involved in obscurity. A certain number of cases occur as one of the manifestations of hysteria; and can sometimes be recognized, when doubtful, by more or less complaint of headache. Others occur as reflex influences in nasal, pharyngeal, laryngeal, tracheal, or bronchial catarrh; the catarrh of tonsillitis, diphtheria, scar-

latina, measles, and small-pox; irritation excited by morbid growths in nares, pharynx, or larynx; rheumatism; syphilis; scorbutis; scrofulosis; dyspepsia; constipation; worms in the alimentary canal; retained fæces in the rectum; displacements and diseases of the uterus; pregnancy. Not unfrequently the paralysis results from over-work, or too continuous professional use of the voice. Many public speakers and opera-singers have been deprived of their voices at some time or other from this cause. Madame Talma was known to have been compelled to quit the scenes on this account; though it is rare that the aphonia occurs during the excitement of public singing. All these varieties of functional paralysis may be intermittent, the voice going and returning suddenly; or the paralysis may continue for many months or a number of years.

Bilateral paralysis is not unfrequently the direct result of exposure of the cervical region to cold and wet. Quite a number of my clinical patients have been servants, who have lost their voices hanging out the clothes, or scrubbing the door-step in inclement weather. It also occurs in some cases of superficial acute laryngitis, and in confirmed catarrhal laryngitis. It is often independent of appreciable structural or organic lesion, being simply due to a want of voluntary power to direct the cerebral current, as it were, along the affected nerve-tracts. Bilateral paralysis from structural lesion is usually due to systemic poisoning, metallic, diphtheritic, or syphilitic, to disease of the brain or medulla oblongata implicating the main nerve-roots, or to pressure upon both recurrent laryngeal nerves, or even only one of them, or pressure on the main pneumogastric trunk. A case has been reported from compression by an effusion in the pericardium.¹

Symptoms.—These are aphonia, or loss of voice, if the paralysis is complete or nearly so; dysphonia with intermittent aphonia, if the paralysis is incomplete or partial. In complete paralysis cough is aphonic and weak, and there is no power to make the explosive "hem." The laryngeal whisper in which the patient speaks is fatiguing and indicative of the escape of air in a large current, aptly designated by Ziemssen as a phonative waste of breath. When the patient speaks in a labial whisper this characteristic waste of breath is avoided. In

¹ Bäumlér: Arch. f. klin. Med., Feb. 22, 1867; Mackenzie: Op. cit., p. 15.

functional paralysis there is sufficient force exercised to move the vocal cords a little way toward the middle line, but not enough to bring them into close apposition. When the paralysis is associated with paresis of the antagonist muscles there is inability to dilate the glottis to its full extent on forced inspiration, and under these circumstances there is sometimes moderate dyspnoea on exertion. The strain on the abdominal muscles in efforts at phonation gives rise to fatigue and local pain.

Diagnosis.—In this form of paralysis, as most frequently presented, the vocal cords remain in the respiratory position,

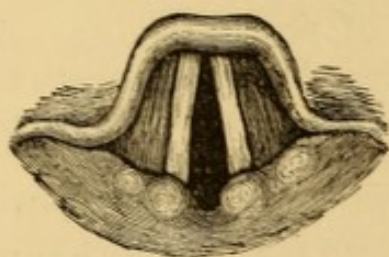


FIG. 188.—Bilateral paralysis of recurrent nerve, caused by cancer of the œsophagus (Ziemssen).

or nearly so, and cannot be approximated by voluntary effort, so that aphonia is entailed in consequence; although in cases not dependent on disease of nerve-centres, or on direct pressure, approximation of the

cords with resultant phonation may take place in movements of coughing, laughing, and sneezing. The

position of the vocal cords, when the paralysis is associated with paralysis of the antagonist muscles, is stationary (Fig.

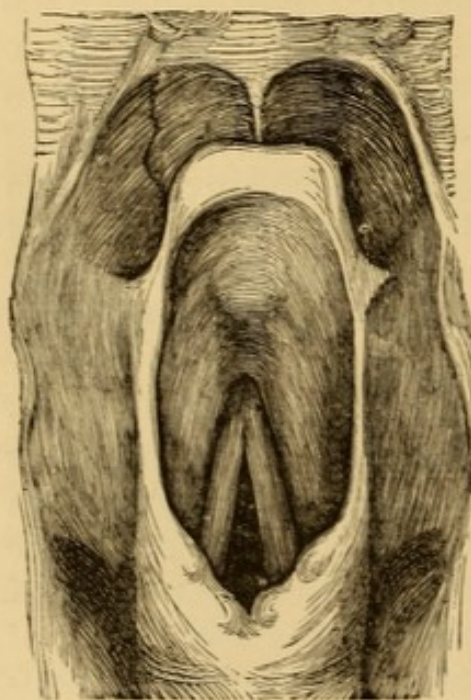


FIG. 189.—Cadaveric position of the vocal cords, drawn from a larynx removed from a recent cadaver (Ziemssen).

188), midway between that of phonation and deep inspiration, and has been aptly designated by Ziemssen as the cadaveric position, on account of its close resemblance to the position of these structures in the recent subject (Fig. 189); so that, when associated with this paralysis of the posterior crico-arytenoids, there is no dilatation of the glottis on forcible inspiration. Complete paralysis of the lateral crico-arytenoids with unrestrained action of the antagonizing posterior crico-arytenoids is recognized by immobility of the vocal cords in extreme dilatation.

So-called functional paralysis is occasionally associated with a similar paralysis of the voluntary control of the diaphragm on

forced expiration, rendering the patient unable to utilize the current of air even for a labial whisper, and a condition which may be termed *apsithyria*,¹ or loss of whisper, becomes super-added to the aphonia or loss of voice.

Prognosis.—The prognosis as to voice is unfavorable in cases proceeding from disease or injury of the nerve-centres, and is dependent on the susceptibility of these affections to retrocession or cure; the aphonia, as a rule, being irremediable by local measures. In cases due to defective innervation at the points of ultimate distribution, which is much more frequent, the prognosis as to return of voice is good, as they are almost always amenable to local and tonic treatment. Paralysis attendant upon laryngitis usually subsides with cessation of the inflammatory process. In cases due to local pressure of morbid growths, or other product, the prognosis depends upon the susceptibility of these products to remedial measures. Cases due to destruction of the nerve are irremediable. In cases of long standing, in which there has been atrophy of the muscles, the voice, if restored, often remains weak for a long time, and sometimes permanently. Hysterical paralysis is subject to irregular relapse.

Treatment.—Treatment of the disease to which the paralysis may be due is required in the first instance. In cases of functional disturbance, arsenic, cinchona, and strychnia are indicated as nerve tonics, and systematic local applications of the electric current to the vocal cords, or to the paralyzed muscles, or the trunk of the nerve, to rouse the dormant motor power. The paralysis, when not due to lesion of the nerve-centres, or to local pressure upon the nerve in some part of its course, is almost always susceptible of prompt cure, even when the aphonia has existed for a number of years. Particularly true of hysterical paralysis, it is also true of paralyzes unassociated with hysteria. In many instances of hysterical paralysis, control of the voice is lost suddenly, and as suddenly regained, it may be in a few hours, in a few days or weeks, or after several months or even years.

In many of these cases the voice may be readily restored by any excitation directly applied to the glottis; usually as a result of the spasmodic action of the vocal cords thus pro-

¹ See author's examples: *Medical and Surgical Reporter*, Phila., May 1, 1875.

duced, but in some instances as a result of the mental emotion following. The methods employed for this purpose have been various, often indifferent, and sometimes selected at random for the purpose of testing the point. They have consisted in inhalation of the vapors of chlorine, iodine, turpentine, and ammonia; direct applications of cold water, tincture of iodine, nitrate of silver by sponge-probang to the glottis; the injection of sprays of ice-water, sulphuric ether, sulphate of zinc, etc., by the laryngeal syringe. In quite a large number of instances, even when complete aphonia had existed continuously for a number of years, I have seen the voice restored by the simple introduction of the laryngoscopic mirror, the patient being purposely impressed with the idea that this manipulation constituted the operative procedure. In fact, this is the method I adopt in cases of habitual loss of voice, often with

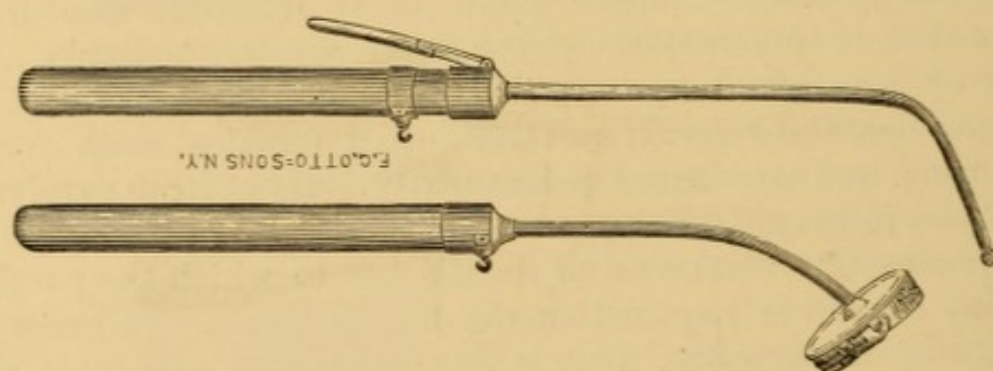


FIG. 190.—Mackenzie's laryngeal electrodes.

instantaneous effect. Where simple introduction of the mirror does not suffice, recourse is had to one of the other methods indicated; and if these are not promptly successful, resort is made to the passage of an electric current through the parts, the negative pole being brought in contact with the vocal cords, or over the muscles at fault, and the positive pole being placed at an indifferent place upon the cutaneous surface, usually in the hand of the patient, or upon the neck just over the crico-thyroid membrane.

Local electrization in the treatment of laryngeal paralysis was introduced by Dr. Mackenzie, who devised special electrodes for the purpose (Fig. 190).

The upper figure represents an isolated electrode to be placed within the larynx, a bit of sponge or kid being fastened upon the exposed bulb to prevent the stinging or burning sensation that accompanies the uncovered instrument. The conducting wire from the battery is attached to a metallic ring, which en-

circles a glass handle; this metallic ring is brought in contact with the laryngeal portion of the instrument by pressing a metallic spring-interrupter upon it. In this manner the passage of the current is controlled, and, when the spring is not depressed, the instrument is a simple probe or sound. The lower figure represents a sponge electrode, which is to be placed on the outside of the neck and held by the patient or an assistant. Dr. Mackenzie prefers for this purpose a sponge electrode more recently devised by him, attached to a collar which is secured around the neck of the patient, who in this way is attached to the battery by the conducting wire; but I still prefer the original device, as the electrode is under the entire control of the patient, who can interrupt the passage of the current the moment it becomes too unpleasant.

The laryngeal electrode has been modified by Mackenzie, Tobold, Ziemssen, and others, so as to branch into two divisions (Fig. 191), one of which can be placed on each vocal cord, or one outside of the laryngeal wall and the other within. In similar manner, the electrode has been made of two isolated

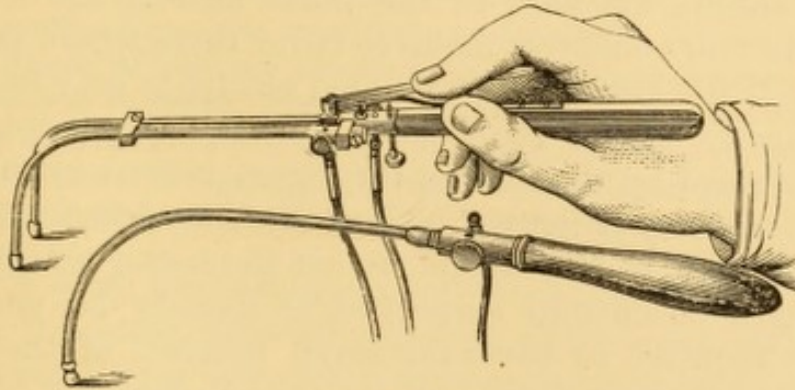


FIG. 191.—Ziemssen's double and single electrodes (Ziemssen).

rods, one of which is placed in connection with each pole of the battery.

To avoid exciting the muscles of the pharynx into contraction when employing Mackenzie's laryngeal electrode upon the pharyngeal surface of the larynx, as, for example, when placing it over the arytenoid muscle, it is well to unscrew the metallic bulb, and replace it by a thin, curved plate, the convex portion of which is insulated by a layer of hard rubber. The plate being perforated, a thin strip of sponge is sewed on with silk.

Any galvanic battery, induction-coil, electric or magneto-electric machine, may, as a rule, be used as the generator of electricity, this being usually in these cases a matter of indifference—a fact which indicates that it is not the special electric influence to which the result is to be attributed, but the stimu-

lus conveyed by electric shocks. In this way, too, the success of intra-laryngeal applications of electricity can be explained, in cases where external applications have failed. In cases where the electric treatment is prominently indicated, it sometimes occurs that the few seconds at a time during which the current can be borne within the larynx is insufficient for making a sufficient amount of electricity-shocks through the paralyzed parts, and success follows protracted electrization practised externally, even after failure with the intra-laryngeal method. In the external method one pole may be placed in front of the crico-thyroid ligament, and the other upon the nape of the neck; or the current may be transmitted through the thyroid cartilage from side to side; or one pole may be placed over the crico-thyroid membrane, or at the side of the neck, and the other in the hand. Physiologically, the negative electrode should be used at the point nearest the laryngeal muscles, and an endeavor made to cover them where possible; and if this is not successful, a pointed electrode may be pressed down along the side of the trachea, as near as possible to the course traversed by the inferior laryngeal nerve; or the laryngeal electrode may be passed a short distance down the œsophagus, by the side of the larynx, to act the better on this nerve. The strength of current employed is usually no more than would be required to move the small muscles of the thumb. Ziemssen localized excitation of the muscle from the bottom of the pyriform sinus posteriorly, and near the external margin of the plate of the cricoid cartilage.

The local electrization is continued every day, or every other day, until there is return of voice. This result sometimes follows the very first application. After return of voice it is prudent to continue the treatment, at gradually lengthened intervals, for two, three, or four weeks, or until the voice has regained its original strength and volume. Four or five applications, of a few seconds' duration each, are made at each interview. But, even without any further treatment, the voice often remains good after it has once been restored in this way.

When the current of the battery or the induced current fail, shocks from the electric machine are sometimes effective, the spark being obtained from the skin over the crico-thyroid membrane.

Relapses take place with more or less irregularity in some

instances, and require repetition of the same treatment. Meanwhile, attention should be paid to the general health, and suitable constitutional treatment be instituted as occasion may require. Strychnia is particularly indicated. In some cases, indeed, it is adequate to recovery without any topical measure. Injected hypodermically, as recommended by Waldenburg,¹ in doses commencing at one-sixty-fourth of a grain, and increased, the sulphate or the nitrate of strychnia will often act most happily after a few injections, repeated at intervals of three or four days. It cannot always be relied upon. I have employed it in this manner in much larger doses; and internally in doses gradually augmented to one-fourth of a grain, three times a day, producing the characteristic constitutional effects of the drug, but without any effect upon the voice.

In the case of a young lady, seventeen years of age, of scrofulous diathesis, otherwise healthy, I gave this drug, first hypodermically, then internally in the doses mentioned, without any beneficial results, having previously failed with faithful resort to electricity, applied locally and externally. Finally, when the patient had been under care for about a year, the voice returned gradually under the direct influence of a galvanic current from forty small Smee cells, applied externally, with interruptions of about three hundred in the minute.

I have seen the reflex action of an emetic successful in restoring the voice, even after failure of the methods narrated.

Hysterical cases sometimes undergo spontaneous cure after failure of remedies, local and constitutional, material or emotional. Sudden fright is sometimes followed by recovery of voice, and this influence is sometimes excited for therapeutic purposes.

Dr. Henry K. Oliver,² of Boston, has called attention to a method of treating aphonia from paralysis of intrinsic muscles of the larynx by external manipulation of the organ, with restoration of voice at a single sitting. The manipulation consists essentially in compressing the wings of the thyroid cartilage, in their posterior and upper part, between the thumb and forefinger, so as to aid the muscles in a natural endeavor to produce the necessary approximation for phonation. Accidental choking has sometimes cured paralytic aphonia.

In a number of cases artificial stretching of the cords, by

¹ Allg. med. cent. Ztg., 1864, No. 21.

² Am. Jour. Med. Sci., April, 1870, p. 305.

drawing the cricoid cartilage up on the thyroid, gives tension enough at once to throw the cords into vibration on phonal effort, and a weak voice results, the precursor of full power later. A position is taken behind the patient, the thyroid cartilage steadied by the two thumbs and forefingers, and the cricoid cartilage manipulated from below by leverage with the ends of the two middle fingers.

Unilateral Paralysis of the Lateral Crico-Arytenoid Muscle (lateral adductor of the vocal cords).—This is most frequent on the left side, the course of the recurrent laryngeal nerve on that side exposing it to compression and implication in disease much more than its fellow on the right. The principal causes of the paralysis are pressure of some sort upon some portion of the nerve, or its atrophy or destruction by tumor or malignant disease. External injury to the nerve is an occasional cause of paralysis. Tumors pressing on the nerve may press likewise upon the trunk of the pneumogastric, and thus occasion reflex paralysis upon the opposite side, as suggested by Dr. Geo. Johnston,¹ in explanation of bilateral paralysis of the vocal cords with pressure upon one side only.² It occurs likewise in organic cerebral disease, in phthisis, in metallic poisoning, and as a result of direct wound or injury, whether accidental or surgical.³ Certain operations in the cervical region necessitate removal of sections of important nerves, thereby entailing unilateral paralysis with dysphonia.⁴

Unilateral paralysis sometimes occurs in the domain of the spinal accessory nerve alone, from direct exposure to cold, and is usually an epiphenomenon attending paralysis of the same side of the palate, as well as of the muscles of the trunk and upper extremity supplied by other ramifications of the same nerve. Sometimes it is distinctly rheumatic, attended with localized pain and tumefaction of the crico-arytenoid articulation.

¹ Brit. Med. Jour., June 27, 1874, p. 827.

² See Bæumler's case of aneurism of the innominate artery: Path. Trans. London, XXIII., p. 66; and Johnston's case of aneurism of the aorta: Ibid., XXIV., p. 42.

³ For examples see Horner: Loss of Voice from Inclusion of Par Vagus in a Ligature of the Carotid Artery, etc., Am. Jour. Med. Sci., Vol. X., p. 403; Cock: Case of Impairment of Voice after Oesophagotomy, Guy's Hospl. Rep., 1858, p. 1217.

⁴ For example see Billroth: Arch. d. Heilk., 1864, p. 271.

Symptoms.—The symptom of this condition is dysphonia or impairment of voice, rarely aphonia. Sometimes the hoarseness is very slight, and, if the patient is robust, the voice may be almost normal in quality and tone, though impaired in volume and susceptibility to modulation. This is due to the fact that the unaffected vocal cord is sometimes pulled by the arytenoid muscle, aided perhaps by the rotatory motion of the lateral crico-arytenoid, beyond the middle line, so as to approximate the paralyzed and stationary cord, and thus fulfil the physical requirements of the production of voice, the supra-

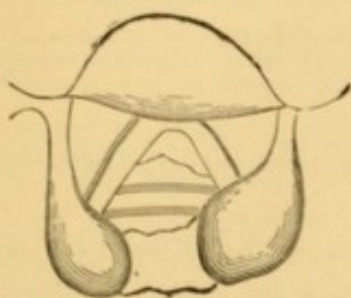


FIG. 192.—Paralysis of left vocal cord in a case of aneurism of the aorta. Appearance during respiration.

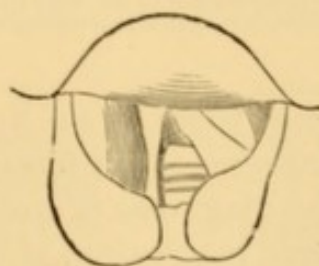


FIG. 193.—Paralysis of left vocal cord in a case of aneurism of the aorta. Appearance during attempted phonation.

arytenoid cartilage of the unimpaired side passing to the inside of the corresponding structure of the impaired side, so as to reach the cord. The phonation in some of these cases is due entirely to the vibration of the sound cord; sometimes the tension of the crico-thyroids is sufficient to permit limited vibration of the cord of the paralyzed side. In some cases, as in the two illustrated above, the loss or impairment of voice is the first intimation of the existence of serious disease.

Diagnosis.—The unaffected cord is seen to occupy the normal position in respiration, while the paralyzed cord, under the abducting influence of the posterior crico-arytenoid, remains more or less widely separated, and does not participate in the to-and-fro movement of the unaffected cord in the two phases of the respiratory movement (Fig. 192). In attempted phonation the unaffected cord reaches the middle line, but the paralyzed cord fails to meet it (Fig. 193). In some instances the mobile cord crosses the middle line sufficiently to meet the opposite cord, the supra-arytenoid cartilage passing to the in-

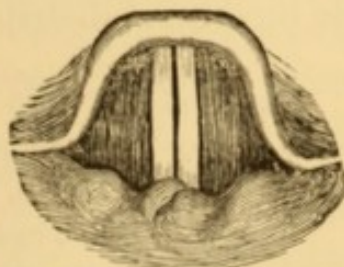


FIG. 194.—Crossing of the supra-arytenoid cartilages (Ziemssen).

side (Fig. 194), and phonation is thus effected. In cases associated with great tumefaction of the supra-arytenoid tissues, as in tuberculosis, the appearances are similar (Figs. 195 and

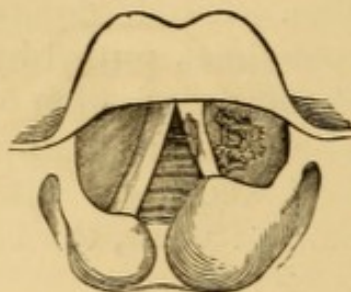


FIG. 195.—Paralysis of left vocal cord in a case of phthisis. Appearance during respiration.

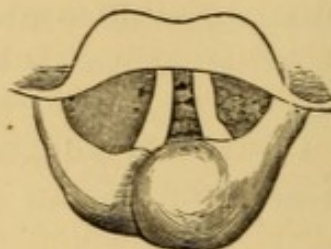


FIG. 196.—Paralysis of left vocal cord in a case of phthisis. Appearance during attempt at phonation.

196), but there is no approximation of the cords even though the crossing takes place.

The diagnosis of unilateral paralysis being made by laryngoscopic inspection, it becomes necessary to make a thorough examination of the neck and chest, and interrogate other evidences of disease, to arrive at the actual or probable nature of the lesion.

Prognosis.—This is usually unfavorable, both as regards voice and life, as the lesion occasioning the paralysis is often in itself fatal.

Treatment.—This form of paralysis being usually deuteropathic, it is necessary that treatment be directed to the causal lesion. If there is any evidence of partial normal motion on effort, an attempt may be judiciously made to increase it by direct excitation with that form of electric current to which it gives most response, continuance being contingent upon the results. In cases of cerebral lesion, excitation of the nerve in its peripheral distributions may react injuriously on the brain.

Paralysis of the Arytenoid Muscle (central adductor).—This is most frequent in acute catarrhal laryngitis, but occurs in hysteria likewise.

Symptoms.—These are impairment of voice, usually attended by a perceptible expiratory current of air which has not been utilized in phonation, and which causes fatigue in talking.

Diagnosis.—The lateral adductors are competent to turn the vocal processes together, by which the inter-ligamentous

portion of the rima glottidis can be closed, but the cartilaginous portion remains patent (Fig. 197).

Prognosis.—This is favorable. If due to catarrhal inflammation, the paralytic condition subsides with the inflammatory process. If hysterical, it can usually be cured by local applications of the electric current to the arytenoid muscle, which is easily reached. Nerve tonics, valerian, and assafœtida, are often indicated. Any special uterine or other lesion which may retard recovery requires appropriate attention.

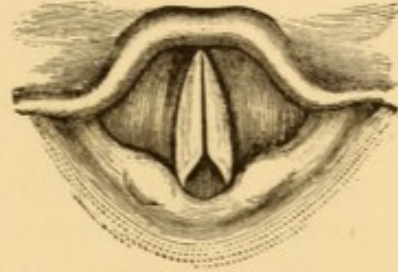


FIG. 197.—Paralysis of the arytenoid in acute laryngitis (Ziemssen).

Treatment.—This is similar to the treatment of functional paralysis of the lateral crico-arytenoids. In applying electricity, the electrode with a broad face, so as to cover a considerable portion of the arytenoid muscle, is preferable to a pointed electrode. The manipulation is so exceedingly easy that it is almost impossible to make a mistake.

Bilateral Paralysis of the Posterior Crico-Arytenoids (dilators of the glottis, abductors of the vocal cords).—This form of paralysis, unlike those already discussed, is directly menacing to life, inasmuch as there is inability to dilate the glottis, while the unrestrained action of the antagonizing muscles tends still further to diminish its patency, so that inspiration is labored, noisy, and difficult, and urgent dyspnoea is frequent. If, as is sometimes the case, there is spasm or tendency to spasm of the antagonistic muscles, suffocation is imminent, and sometimes inevitable if precautionary tracheotomy has not been performed. The affection fortunately is not frequent; it appears to occur more frequently in males than in females, and has been noticed at various ages from five years upward. Quite a number of isolated cases are on record. Ziemssen¹ narrates nine instances from various sources, including one of his own; Semon has reported a series of six in his own practice; I have had five under my own more or less immediate care, and have seen a few in the practice of others.

The cause is often obscure, even on post-mortem examina-

¹ Cyclopædia, Vol. VII., p. 959.

tion. Compression of both recurrent nerves, or atrophy and disorganization has been detected in some instances,¹ degeneration of the roots of the pneumogastrics and spinal accessory nerves in at least one,² and perichondritis in another.³ In several cases there were atrophy and degeneration of the muscles, though not always associated with discoverable nerve lesion. The initial lesion has been attributed to catarrhal and specific inflammation, pulmonary tuberculosis, constitutional syphilis, cerebral lesion, disease of tissues in the course of the nerves, and to hysteria. In one of my cases, the patient attributed his disease to excessive tobacco-smoking. This case, too, afforded an opportunity of observing that the disease may begin unilaterally, although it is generally bilateral by the time it comes under the notice of the laryngoscopist, and it is worthy of record for several other reasons which will be apparent.

A gentleman, forty-six years of age, of good physique and in apparent health, had suffered for two years or more with cough, dyspnoea, and occasional obstruction and alarming spasm of the larynx, which had eventuated in loss of consciousness in the street on two occasions. His respiration was labored, inefficient, and attended with such inspiratory stridor in sleep that it could be heard all over his residence. Early in life he had had a suppurative inflammation of his left ear, which had eventually subsided. He had been addicted to excessive smoking (fifteen or sixteen segars a day, and an occasional pipe or two in addition) for many years. Hearing was somewhat impaired. Laryngoscopic inspection revealed paralysis of the posterior crico-arytenoid muscle of the left side, with a tendency to spasm of the glottis, as provoked by the examination. Interrogation revealed the fact that irritation of the left external auditory meatus always induced cough, followed by spasm of the larynx, so that the patient dared not cleanse the ear for fear of exciting a paroxysm. A tentative treatment was instituted, with the addition of a constant supply of nitrite of amyl at hand for inhalation upon the occurrence of a spasm. All went well for a few days, when an inadvertent manipulation of the ear brought on a terrific spasm that was reported as well-nigh fatal. Recounting this to me next day while awaiting his attending physician, Dr. Hinkle, in my reception-room, he placed his finger in his ear to illustrate the occurrence, when a severe paroxysm of spasm was provoked just as Dr. Hinkle entered the room, in time to assist me in controlling it by the prompt administration of vapor of chloroform. On the following day I performed tracheotomy, and the patient has been wearing a tube for more than two years. After the operation, the patient's hearing improved and remained improved. Color-blindness,

¹ See Riegel: Berlin klin. Woch., Nos. 20 and 21, 1872, No. 7, 1873; Ziemssen's Cyclopædia, N. Y., Vol. VII., p. 960; Semon: Brit. Med. Jour., May 4, 1878, p. 662.

² Pentzold: Ziemssen's Cyclopædia, Vol. VII., p. 962.

³ Semon: Loc. cit.

however (chiefly interchange of red and green), soon supervened, and ophthalmic inspection revealed progressive atrophy of the optic nerves, which has since increased to very indistinct vision. The tendency to cough and spasm on titillation of the ear continues, but no lesion is apparent on inspection. Within a few weeks after the operation the right vocal cord became paralyzed likewise (Fig. 198, p. 656), and at the end of about three months the paralysis became so complete, and the tension of the vocal cords and ary-epiglottic folds so marked, that it is difficult to believe that there is not, in addition, permanent spasm of the arytenoid and lateral crico-arytenoid muscles (Fig. 199), for from that time to the present, now more than two years, I have never seen the glottis in any other condition, although there is sometimes just enough separation of the arytenoid cartilages on forcible inspiration to see that they are not welded together; otherwise the condition simulates adhesion of the arytenoid cartilages as I have seen it in stenosis after syphilis. The general health of this patient has gradually become impaired. No treatment, local or constitutional, has had the slightest influence on the paralysis.

In some instances there is paralytic contraction of the antagonizing muscles after a while, simulating constant spasm. In moderate cases of this kind the vocal cords are not in close approximation posteriorly, and there is a narrow slit along the entire length of the glottis. In these cases there is inspiratory stridor only. When the arytenoids remain in contact, there is expiratory stridor also. The mucous membrane strips back, as it were, from the edges of the vocal cord during inspiration, the cords being forced downward by the force of the inspiratory current of air, so as to resemble somewhat the bowed portion of the blades of a pair of scissors curved on the flat, the edges of the fibrous structure becoming very distinct; and there is a manifest dilatation in expiration. The voice is always good, except when concomitant hyperæmia produces hoarseness.

Semon, in reporting a case with concomitant paralysis of face and legs,¹ mentioned that in one instance there was post-mortem evidence of compression of both recurrenents by firm connective tissue, one from perichondritis. Dr. Beverley Robinson reports a case which was associated with locomotor ataxia.²

Symptoms.—The diagnostic symptom is dyspnœa with inspiratory stridor, which is often very loud, especially during sleep, so loud, at times, as to be heard all over the house. It is sometimes impossible to breathe except in the erect, semi-erect, or even a constrained, position of the head. Expiration

¹ Lancet, April 20, 1878, p. 568.

² Am. Jour. Med. Sci., April, 1878, p. 378.

is easy, and usually noiseless. The dyspnœa is increased on exertion. There may be occasional or frequent spasm of the glottis. There is no impairment of voice except there is accompanying catarrh; but there is a peculiarity in utterance, as in inflammatory stenosis, the flow of speech being frequently interrupted by prolonged stridulous inspiration. The general health may be apparently unimpaired, or may give evidence of other affections associated with the paralysis.

Diagnosis.—Continuous inspiratory stridor in the adult is suggestive of the nature of the affection. Laryngoscopic inspection reveals a characteristic appearance of the glottis. The vocal cords cannot be abducted to any distance by the most powerful effort (Fig. 198). In marked cases, or during spasm of the antagonists, the cords cannot be abducted at all,

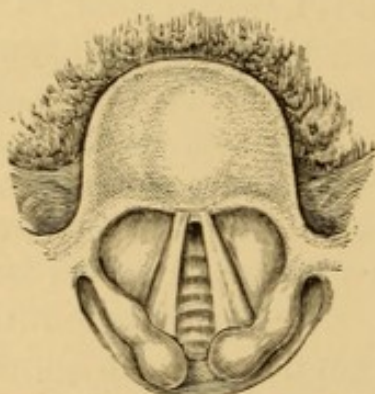


FIG. 198.—Bilateral paralysis of the posterior crico-arytenoids. Patient wearing the canula. (From a drawing by Dr. Packard.)

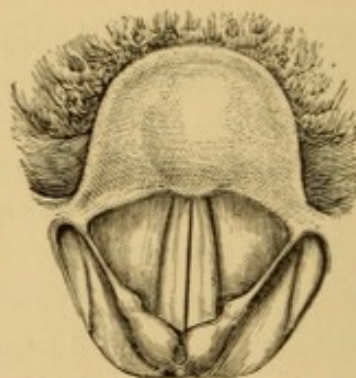


FIG. 199.—Bilateral paralysis of the posterior crico-arytenoids: in same case as Fig. 198, at a later stage of the affection.

and an exceedingly narrow slit remains between the vocal cords (Fig. 199), which are pressed further toward each other and downward during inspiration, so that sometimes the overlying mucous membrane is drawn down beneath the level of the fibrous edges of the cords, which are rendered very prominent beneath it, and which vibrate during the stridor. In expiration the cords are blown upward into a vaulted form with enlargement of the elliptic or triangular orifice, as may be, and the air passes freely out of the larynx. There is not necessarily any alteration in the color and configuration of the parts, which may be pale or slightly congested; and the phonal vibrations are normal, or abnormally conspicuous. In the presence of acute laryngitis, as I have seen it in one instance, there is diffuse redness with slight tumefaction.

The resemblance to adhesion of the opposing surfaces of the

arytenoid cartilages may be so great as to render the diagnosis difficult in the absence of previous history ; and the latter condition may in its turn be mistaken for the one under consideration.¹

Prognosis.—The prognosis is unfavorable, unless a provisional tracheotomy is performed ; the tendency being to death by suffocation. A few cases of cure are on record—one as the result of treatment by electricity.² After tracheotomy, the prognosis is good as far as regards liability to sudden death from asphyxia. A case has been reported³ in which the canula was removed with safety at the end of fifteen weeks ; but its permanent retention is usually requisite. Several of the cases reported had been wearing the tube for a number of years, and in one case of which I have cognizance, the tube has been worn for more than twelve years, with ability to continue the arduous duties of a judge upon the bench.⁴

Treatment.—If the dyspnœa is at all urgent, or if there is any tendency to spasm, tracheotomy is indicated without delay as the only means of relieving the dyspnœa and averting suffocation. Three cases, one under my own immediate care, and two others that I had been attending in consultation, perished by suffocation because the operation would not be submitted to.

In cases that are not urgent, but attended with spasm, and which can be closely watched, nitrite of amyl should be constantly at hand for inhalation in a paroxysm ; ether, or even chloroform, is applicable in its absence. If the paralysis is constant, the safest procedure in my estimation is to perform the tracheotomy and let the patient breathe with the tube plugged with a rubber stopper or a cork, when the dyspnœa is not urgent ; removing the plug, in order that access of air to the lungs can be insured, at any moment that respiration may become embarrassed. Otherwise the case is to be treated on general principles. Electrization, without previous tracheotomy, can hardly be regarded as prudent, even though it has been successful in the instance referred to, for local manipu-

¹ For example see Sidlo : Ziemssen, op. cit., p. 969.

² Ziemssen : Op. cit., p. 964.

³ Rehn : Ziemssen, op. cit., p. 965.

⁴ Mackenzie's case, recorded in his essay on Hoarseness, Loss of Voice, and Stridulous Breathing, p. 34.

lation to the larynx is apt to provoke spasm—the very condition that should be avoided in this affection; besides which, it is impossible to localize the influence of the current on those fibres of the recurrent which supply the paralyzed muscles, while there is greater probability of stimulating the antagonistic muscles supplied by other fibres of the same nerve. After tracheotomy, electrization may be employed with impunity, as far as danger from spasm is concerned. The muscles are reached from the posterior surface of the larynx, below the position of the arytenoid muscle. The manipulation is somewhat embarrassing because the instrument is apt to slip, and require readjustment.

Unilateral Paralysis of the Posterior Crico-arytenoid Muscle (abductor of one vocal cord).—In this affection one vocal cord remains immobile on inspiration, while the action of the other one is normal. The causes may be similar to those productive of bilateral paralysis, but are confined to one side. Compression of one inferior laryngeal nerve, or upon one of the pneumogastriks, is the most frequent cause, the nature of the compression varying, and the left nerve, as a matter of course, being affected most frequently. It is sometimes due to hemiplegia. Sometimes it precedes the bilateral form of the paralysis. In a case in a sailor recently under my care, in Jefferson Medical College Hospital, the paralysis was due to having been caught around the neck by the sheet of a sail, during a storm; the dysphonia having been noticed within four hours after the injury, and having been permanent, with frequent interurrences of aphonia from cold or moderate exposure.

Symptoms.—There is moderate dyspnœa, increased on exertion, and moderate inspiratory stridor, paroxysmally or on exertion. The voice is usually hoarse and muffled, or shrill and dissonant, especially when forced.

Diagnosis.—The impaired cord remains at or near the middle line, the movement of the unimpaired cord being normal on respiration, and even slightly excessive on phonation, to approximate its paralyzed mate. The vibrations of the two cords in phonation are unequal.

Prognosis.—This is usually unfavorable, on account of the organic lesion which has caused the paralysis.

Treatment.—The treatment is confined to management of

the cervical or intra-thoracic disease, whatever it may be, and such constitutional measures as are otherwise indicated. Special treatment of the paralysis is rarely indicated. Undue exertion should be avoided, so as to keep the respiratory requirements at a minimum. Tracheotomy may become necessary if the dyspnœa become extreme from increase of paralytic stenosis, or stenosis from tumefaction in intercurrent catarrhal inflammation.

CHAPTER XV.

SURGICAL OPERATIONS UPON THE LARYNX AND TRACHEA.

ARTIFICIAL OPENINGS INTO THE LARYNX AND TRACHEA.

(Laryngotomy; Laryngo-tracheotomy; Tracheotomy; Bronchotomy.)

INCISIONS into the air-tube become necessary to remove certain foreign bodies or morbid growths; or to secure direct access of air below obstructions occluding the normal channel, whether in the air-passage, above it, or outside of it. The following-named diseases, injuries, and accidents may necessitate the artificial opening: acute laryngitis, whether idiopathic, specific, deuteropathic, or traumatic; œdema of the larynx; pseudo-membranous laryngitis or laryngo-tracheitis; chronic laryngitis, with ulceration; glossitis; tonsillitis; pharyngeal and œsophageal abscess; chondrial necrosis in syphilis, tuberculosis, and typhosis; interstitial or cicatricial stenosis from inflammatory disease or traumatic injury; neoplasms in the air-tube, or in the pharynx or œsophagus; fractures and other wounds of the larynx or trachea; foreign bodies in the air-passage, or impacted in the pharynx or œsophagus; external compression by goitre and other tumors; spasm of the glottis or of the larynx in laryngismus, epilepsy, tetanus, and hydrophobia; paralysis of the posterior crico-arytenoid muscles; certain cases of asphyxia from various causes, requiring prompt institution of artificial inspiration by direct inflation; operations on the mouth and jaw in which asphyxia may result from occluding accumulation of blood in the air-passages. Foreign bodies, croup and diphtheria, interstitial stenosis, and œdema of the larynx, present the most frequent occasions for the operation.

According to the requirements of the case, choice is made of one of three operations—partial or entire laryngotomy,

laryngo-tracheotomy, and tracheotomy. So-called sub-hyoid laryngotomy,—a pharyngotomy by external incision practised below the hyoid bone, is occasionally performed for gaining access into the larynx from above, to extirpate a morbid growth or remove a foreign body.

Laryngotomy may be partial or complete. Partial laryngotomy is usually limited to division of the crico-thyroid ligament, and is chiefly applicable to acute affections in which an artificial opening is required for a short time ; as in acute laryngitis, œdema of the larynx, fracture of the larynx, division of adherent vocal cords, extraction of favorably located foreign bodies, safety in evulsion or destruction of large neoplasms under laryngoscopic manipulation, or partial or entire removal of certain forms of subglottic growths. It is thought that the prolonged or permanent retention of a canula at this point is productive of necrosis of the adjacent cartilage, and impairment in the motion of the vocal cords ; for which reasons tracheotomy is generally preferred in cases where a tube is to be worn for a long period. The operation is usually performed on adults only, the opening in children being too small, as a rule, for utilization. It is sometimes associated with division of the cricoid cartilage, and even of a small portion of the thyroid ; occasionally in adults, and quite frequently in children. Complete laryngotomy includes division of both cricoid and thyroid cartilages with the intervening membrane. It is sometimes necessary for removal of large foreign bodies, large neoplasms, segments or fragments of cartilage, or cicatricial tissues. Thyroidotomy (thyreotomy, thyrotomy) implies division of the thyroid cartilage, usually associated with the division of the crico-thyroid membrane, but without implication of the cricoid cartilage. It is chiefly practised for the extirpation of morbid growths, but occasionally for removal of foreign bodies. Division of the cricoid cartilage is usually avoided, unless compulsory, because it impairs the solidity of the laryngeal skeleton.

Laryngo-tracheotomy implies division of one or more of the cartilaginous rings of the trachea, continuously with division of the cricoid cartilage or additional portions of the larynx. It is practised for removal of foreign body, and in some cases of croup.

Tracheotomy is a division of the trachea, alone, in some

portion of its extent, and is most frequently practised for removal of foreign body, for croup and diphtheria, for chronic laryngitis and its consequences, and for compression in the larynx or upper portion of the trachea.

It is important that every practitioner should acquire some familiarity with these operations, if with no others, for the safety of a life may depend on promptitude, incompatible with any delay in sending for surgeons, assistants, or instruments.

In many cases in which the operation is performed it is necessary to maintain the artificial opening patulous for a certain or uncertain period. This may be provided for by removing an oval or circular section of the trachea, as practised by Mr. Lawrence, of London, a diamond-shaped piece as practised by Mr. Carmichael of Dublin,¹ or a rectangular piece as is done by others; by excision of the anterior wall of the cricoid cartilage with or without preservation of its perichondrium; by making a valvular or flap incision, as practised by Prof. Brainard, of Chicago;² by keeping the edges of the incision asunder by blunt hooks or stitches secured behind the neck; or by the most usual plan of inserting a special rigid canula or tracheotomy-tube. Some surgeons excise a portion of the air-tube, and endeavor to make assurance doubly sure by inserting a tracheotomy-tube in addition. It is generally supposed that stitches into the sides of the tracheal incision cut out very soon; but Prof. Roser, of Marburg, reports having kept them in position for three or four days, in forty instances, without any injurious effect,³ and Dr. H. A. Martin, of Boston, finds that they will not cut through for two or three weeks, if the traction is moderate. The ligatures are simply twisted or tied into loops and secured by adhesive strips to the side of the neck or crossed at the back, as practised by Martin, so as to exert slight traction.

The canula most in use at the present day is the modified double tracheotomy-tube of Trousseau (Fig. 200), suggested by Geo. Martin, to overcome the pernicious effect of occlusion by coagulating mucus, pus, blood, etc.⁴ The inner canula, alone, becomes clogged, and can be removed for cleansing without

¹ Trans. King's and Queen's Coll. Phys., Ireland, 1820, p. 170.

² Chicago Med. Jour., March, 1857; Am. Jour. Med. Sci., July, 1857, p. 291.

³ Sydenham Soc. Year-Book, 1863, from Arch. d. Heilk., II.

⁴ Philosoph. Trans., London, 1736.

depriving the patient of his safety-tube. It is made a little longer than the outer tube, so as to protect the latter and make sure of cleansing it on reintroduction. The outer tube should be movable in its shield or collar, if the latter is tied to the neck, or should be supplied with movable rings for attachment of the tapes, if of one piece with the shield, so that the position of the tube may not be much disturbed in the movements of the neck.

Silver is the best material for these tubes, as tarnishing of the surface gives an indication of the condition of the track of the wound, which is not furnished by the hard-rubber tubes so much in use. Soft-rubber tubes have been introduced into use lately.¹ In certain cases of constriction of the trachea, low down, it is necessary to have an unusually long tube, for which a suitable sized catheter, or a section of india-rubber tubing, may be substituted in an emergency. I have found rubber tubing form an admirable temporary inner tube for long canulæ whose curves would not admit a rigid tube. The outer portion should be turned on itself and secured, by stitching, to tapes or to an extemporized shield. If allowed to turn downward, the escape of mucus, etc., is rendered much less offensive and unseemly.

Whatever character of tube be used, care must be taken that it is well made, a point not properly attended to by instrument-makers. Even solid silver undergoes corrosion from long use, and soldered tubes often become corroded, and, even after moderate prolonged usage, part at the junction of flange and canula, from the corroding effects of galvanic action. The only tube absolutely safe, for protracted use, is one with flange and canula beaten out of the solid metal. Cases are not infrequent in which serious accidents have followed the use of illy-made tubes, and even too prolonged use of well-made ones; and similar accidents are liable with the hard-rubber tubes screwed to the collar or shield.² Some patients are so reckless,

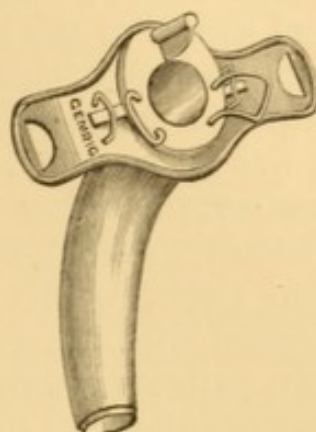


FIG. 200.—Trousseau's double tracheotomy-tube.

¹ Paley: *The Lancet*, Dec. 11, 1875, p. 834; Baker: *Ibid.*, Dec. 2, 1876, p. 784.

² For examples of escape of tubes or portions of tubes into the trachea and bronchi, see Porter: *On the Larynx and Trachea*, London, 1837, p. 144; Albers: *Arch. klin. Chir.*, H. 8, 1867, p. 177; Waters: *Brit. Med. Jour.*, Feb. 15, 1868, p.

or ignorant, or uncleanly, that they will wear a tube for months together without removal. Hence corrosion of the solder at the junction of shield and canula, and detachment and escape of the latter into the air-passage. I have seen the tube so firmly impacted in the wound, after long usage, as to require considerable force in its removal; and on one occasion it was so corroded after eight or ten months' retention, that I am certain a few weeks longer would have added another instance to the dozen indicated in the foot-note. It is important that patients wearing these appliances should be impressed with the necessity of their frequent examination. My own patients are instructed to become provided with duplicate sets of tubes and to change them daily, as part of the toilet.

Necessity for making an artificial opening on the instant sometimes occurs when proper instruments are not at hand, or a tube for insertion after the operation. In imperative cases, threatening death by delay, the operation must be performed promptly, and at all hazard. Occasions for this sudden interference sometimes occur in the regular course of practice, but sometimes at the dining-table or upon the street, or upon some other occasion when a physician is fortuitously present as a guest or spectator. If he sees suffocation imminent, and is unable to set the cause aside, it is his imperative duty to open the trachea or divide the crico-thyroid membrane by one bold incision with pocket-knife or scissors, if no other instrument is at hand. The knife may be plunged into the crico-thyroid space, and then turned around in the cut to enlarge the opening for the access of air. There is no time for dissection; and failure to rescue the patient, in such an emergency, will be due to unfavorable circumstances, and not to professional negligence. A quill, a tooth-pick, a tube from the barrel of a pencil-case, answers the purpose of a temporary canula until a suitable one can be procured, if such an appliance be required, or the edges of the incision may be separated by bent hooks improvised from hair-pins or wire; and until this substitute is

141; Masing: *St. Petersburg med. Ztschr.*, H. 7, 1869; *Boston Med. and Surg. Jour.*, Feb. 23, 1871, p. 128; Buck: *Trans. N. Y. Acad. Med.*, 1870; Pick: *Trans. Path. Soc., London*, 1870, p. 416; Ogle: *Med. Times and Gaz.*, Nov. 5, 1870, p. 531; Holt-house: *The Lancet*, Jan. 27, 1872, p. 113; Ogle and Lee: *Med. Times and Gaz.*, Sept. 21, 1872, p. 324; Davy: *Brit. Med. Jour.*, July 8, 1876, p. 45; Thornton: *On Tracheotomy*, p. 36; House: *The Lancet*, Apl. 7, 1877.

in readiness for insertion, the wound may be kept patulous by retaining the knife crosswise in it.

Somewhat similar emergency occasionally occurs during administration of an anæsthetic, in consequence of spasmodic, paralytic, or mechanical occlusion of the glottis, in which the prompt opening of the trachea is necessary to save life.¹

An admirable tracheotomy-tube, which can be made in a few moments, was extemporized by Dr. Benjamin Howard, of New York,² during an emergency which happened while on a shooting excursion. It is made of lead, which is almost always accessible in some form or other; a Minié bullet having been used on the occasion referred to. The directions of Dr. Howard are as follows:

"Take a piece of lead, whether in the form of sheet, pipe, or bullet, and, if necessary, hammer it out as thin as it can be used without breaking. Of this, cut a piece the shape of a parallelogram about two and a half by one and a quarter inches, or enough larger to allow a margin; roll it around a trimmed stick, ramrod, or pencil, thus making a tube, as in Fig. 201, and level both edges so that, by trimming and dressing, the seam may be smooth and firm. Cut the upper end so as to form four slips of equal size, *bb*;

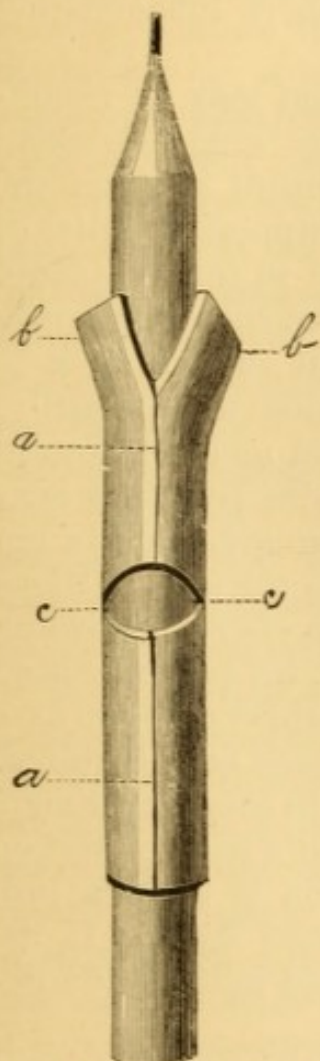


FIG. 201.—Howard's extemporaneous tracheotomy tube. The sheet of lead rolled around a pencil.—*aa*, Seam down centre bevelled and dressed smooth.—*bb*, Slips cut at upper end of tube, to be turned down as at *bb*, Fig. 202, two of them being there pierced with eyelet-holes.—*cc*, Section cut out transversely from two-thirds the circumference of the tube, which at *c*, Fig. 202, is bent upon itself.

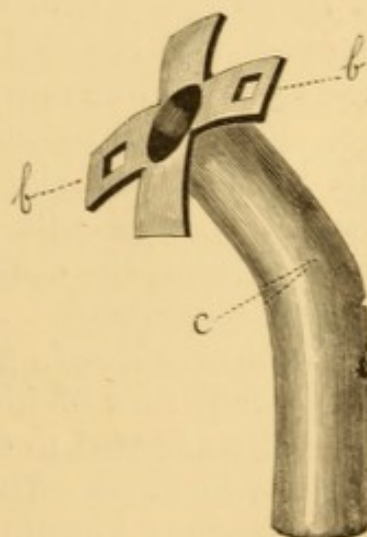


FIG. 202.—Howard's extemporaneous tracheotomy tube. Lead canula.—*bb*, Flange and eyelet-holes.—*c*, Joint where tube is bent on itself.

¹ For recent example under the care of Mr. House, see Brit. Med. Jour., Oct. 26, 1878, p. 642.

² The Medical Record, Nov., 1871, p. 391.

and at about the middle of the tube cut out a transverse elliptical section from about two-thirds of its circumference (Fig. 202, *c*). Withdraw the pencil and bend the tube upon itself. Turn down the slips, and in two of them cut eyelet-holes through which a string or tape may be passed around the neck, to retain the canula in its position in the wound."

A similar device, resorted to by Professor Trousseau in 1828, is mentioned in his Lectures.¹

Leaden tubes are useful, too, in cases where inflammation occurs in the track of the wound.

In performing these operations, the patient may be recumbent or semi-recumbent. In the adult the semi-recumbent position is often preferable. In the recumbent position the shoulders are to be elevated, and a firm support (a billet of wood or a rolling-pin, or a bottle, enveloped in towels) placed beneath the neck to render the larynx and trachea sufficiently prominent, but without forcing the head far enough back to flatten the trachea and embarrass respiration unnecessarily. Some operators stand at the patient's head and cut toward them, from below upward; the advantage being that they have a better view of the inferior portion of the wound, and are not liable to have blood and mucus coughed into the face. Others stand at the side of the patient, and cut from above downward. In operating in the semi-recumbent position, the patient's head is thrown back over the top of the chair, which answers as a support, and the chair itself is tilted as far back as is required, and secured from movement by chocking, or in some other manner. The operator may stand at the patient's head or rest on his knees at the side, when, if the operation is to be a prolonged one, he will need a cushion to kneel upon. If the patient faint, the chair can at once be lowered until he is sufficiently recumbent.

Professor Rose's plan of operating, with the head pendant² to prevent flow of blood into the air-passages, has been successfully adapted to tracheotomy and other operations interesting the air-tube. The head is supported in the two hands of an attendant kneeling on a cushion in front of the operating-table, and a speculum is placed within the angles of the jaws, and the tongue held up with blunt forceps so as not to cover the palate and occlude respiration. The operator is seated

¹ Lectures on Clinical Medicine, Sydenham Soc. Edition, Vol. II., p. 489.

² Arch. klin. Chir., Bd. 17, 1874, p. 454.

opposite the head of the patient, and makes the usual reversed incisions.

The knife is employed by most surgeons in all these operations, but dread of hemorrhage has led to resort to the various forms of incandescent cautery. Some prefer the galvano-caustic knife;¹ others the galvano-caustic loop, introduced through the entire tissues by needle before adjustment to the battery;² others the thermo-cautery of Paquelin;³ and others the actual or potential cautery.⁴ Dujardin⁵ used a caustic paste; Chaissaignac has proposed the *écraseur*;⁶ and Guerin a subcutaneous tracheotomy.⁷ In using the incandescent cautery, the parts are to be divided by light touches of the blade, the molten fat being absorbed by sponge, and removed, until the trachea is exposed, which is then incised by the knife in the usual manner. Krishaber, who has employed the thermo-cautery in a number of instances, has found it better to divide the tissues by a series of light touches of not more than a second in duration each, instead of making a linear division, which requires several seconds of contact. In this manner he avoids ebullition and fusion of the fat, to which the subsequent eschars are attributable, the separation of which may be followed by secondary hemorrhage.

It is sometimes necessary to perform these operations under general anæsthesia, especially in children. If an anæsthetic is not used in children, the limbs and trunk must be carefully wrapped so as to prevent struggling. When far gone in blood-poisoning, from retained carbonic acid, there is anæsthesia enough to render this precaution unnecessary. Adults can often be induced to submit to the operation without anæsthesia, and usually state that the pain has been much less in reality than in anticipation. It is often important to have the patient cough, take a deep breath, expectorate, and the like, to facili-

¹ Verneuil: Bull. d. l'Acad. Méd., 1872, p. 299; Bull. de therap., 1872, p. 472; Voltolini: Berlin klin. Woch., IX., 1872, p. 11; The Lancet, May 18, 1872, p. 688.

² Amussat: Idem, Arch. gén. de méd., Jan., 1873.

³ Krishaber: Annales des maladies de l'oreille, du larynx, etc., Paris, 1876, 1877, 1878; Poincot: The Lancet, 1878, Feb. 16, p. 247, March 23, p. 418.

⁴ (Le Clerc: Revue méd., 1851.) Kuehn: In Guenther's Lehre von den blutigen Operationen, Leipzig and Heidelberg, 1864, Vol. V.; de Rause and Muron: Gaz. méd. Paris, 1873, No. 48; Phila. Med. Times, Oct. 25, 1873, p. 54.

⁵ Kuehn: Loc. cit.

⁶ Med. Times and Gaz., May 25, 1872, p. 604.

⁷ Idem.

tate the operation, and hence it is desirable to do without anæsthesia. Local anæsthesia with ice, ether or rhigolene spray, or carbolic acid paint, is sometimes resorted to, to subdue the sensibility of the skin, the incision of which is much more painful than that of the subcutaneous tissues. Chloroform is preferable to ether as an anæsthetic in these operations, if not contraindicated, especially in children, and is to be preferred as a matter of course in operating by artificial light, especially if it be close to the work. A pendant directly over the bed or table is the best artificial light, if accessible. Reflectors are useful when the direct light is poor or unfavorably located.

Laryngotomy.—This is usually confined to division of the crico-thyroid membrane. The position of the crico-thyroid ligament being determined by the touch, an incision, from an inch to an inch and a half in length, is made in the middle line, so that its central third shall expose the ligament, the incision dividing the skin and cervical fascia. The parts may be made tense between the thumb and fingers of the disengaged hand, or they may be pinched up into a transverse fold and be divided after transfixion of its base. The ligament is then freed of any superimposed tissue not divided by the first incision, care being taken to avoid wounding the communicating branch of the two thyroid arteries, which, if in the way, is to be shoved to one side, twisted, or divided between a double ligature, as the needs of the case may determine. The ligament is then divided by a horizontal or vertical section, according to the nature of the case; and, if the opening thus made is insufficient, it is to be split crosswise. Some surgeons detach it from the cricoid cartilage, others from the thyroid. In the latter case the two superior thyroid arteries had better be secured before the section of the membrane is made. In making this section, care must be taken that the knife divides the mucous membrane of the air-tube as well as the ligament itself. The ligament retracts immediately that it is severed from the cartilage, and, if the mucous membrane has not been included in the incision, the interior of the tube will be still uncovered, and a second incision be necessary. Care must be taken not to injure the posterior wall of the larynx with the point of the knife, and also not merely to push before it the

anterior laryngeal mucous membrane, which is sometimes detached from the ligament. The sound of escape of air is a guide to penetration of the tube, and complete entrance into the cavity of the larynx is denoted by a peculiar whizzing sound, and the expulsion of air, mucus, and blood from the opening. When an opening into the ligament is not large enough for the purpose required, the cricoid cartilage is to be divided, and, if need be, even a portion of the thyroid cartilage, due precaution being taken to avoid wounding the vocal cords. Ossification of these cartilages may require the use of strong scissors, bone-forceps, or the saw. The sudden entrance of air into the occluded air-passage is not unfrequently followed by momentary apnœa, which is very apt to be mistaken for cessation of respiration by those who have not had much familiarity with these operations, and thus to frighten the novice unnecessarily. A few seconds will place the matter beyond doubt.

Tracheotomy.—This operation may be expeditiously performed in the following manner, which, in its essential points, is that recommended by Prof. Langenbeck :

The operator standing at the right side of the recumbent patient, and a skilled assistant at the left, an incision is made into the skin and subjacent fascia, either by rendering the integument tense or by pinching it up in a transverse fold. This incision extends from the cricoid cartilage to about a third or fourth of an inch from the top of the sternum, being from an inch and a half to two inches in length. The incision must be made in the middle line, and its direction maintained throughout the subsequent dissection. A good plan to avoid losing the middle line is to keep a tenaculum hooked at the lower part of the cricoid during the whole operation. In certain cases of tumor externally, it is necessary to make the incision more or less to one side. Any wounded arteries being secured, the operator seizes the subcutaneous connective tissue with a pair of sharp-toothed forceps on one side of the middle line and parallel to it ; the assistant seizes it in like manner at a corresponding point on the opposite side, and the two raise the fold of fascia, which is then divided by the operator. In this way fold after fold is divided, the large veins being pressed aside as well as may be, or, if they cannot be avoided, divided between double ligatures. All ligatures should be cut close,

lest they become detached in subsequent steps of the operation, or in introducing the canula. Any necessary retraction of soft tissues is made by means of bent hair-pins or blunt hooks. Some surgeons divide the fascia on the grooved director with knife or blunt-pointed scissors. The sterno-hyoid and sterno-thyroid muscles are then carefully separated by the handle of the knife, with as little use of the blade as possible, exposing the upper portion of the trachea, which is usually covered by the isthmus of the thyroid gland. This structure is avoided, when practicable, by pushing it upward, or by endeavoring to reach the trachea from below it; but, if this cannot be done with safety, two ligatures are thrown around it, between which it is then to be divided. Some surgeons have no fear of hemorrhage, and cut boldly through the isthmus; others lacerate it by tearing it. During all this time an assistant at the head of the patient keeps the field of operation clear from blood with small pieces of sponge firmly secured to a stick or held in forceps. In very short-necked individuals almost the entire trachea may lie within the thorax, and in persons with disease of the cervical vertebræ the whole of it may lie below the sternal notch, in either case rendering the operation more difficult and embarrassing. As soon as the trachea has been fully exposed, and cleared, by scraping, of superjacent fascia—an important point in avoiding subsequent emphysema—a sharp tenaculum is thrust into it, beneath the cricoid cartilage or one of its rings, and it is raised somewhat forward and steadied, when it is divided from below upward, in three or four of its upper rings, by a sharp-pointed bistoury, inserted into one of the interspaces. Care must be taken to penetrate the anterior mucous membrane of the trachea on the one hand, and to avoid striking the posterior wall on the other. The fact of penetration is confirmed by the peculiar hissing sound with which the air rushes out of the wound, and by the convulsive cough which shoots the blood and mucus out to a great distance. The operator now seizes the edge of the tracheal wound upon the left side, with a pair of toothed slide-forceps, closes the slide, and hands the instrument to his assistant, when with a similar pair of forceps he secures the other border. Slight traction being now made, the edges of the wound are separated, and air enters without impediment. If the canula is to be employed, it is then introduced. If the

trachea has not been opened sufficiently, it is again raised up from the bottom of the wound, and the opening is enlarged with a probe-pointed bistoury, care being taken that no vessels are left in the path of the knife. It sometimes happens that ossification of the cartilages requires the use of strong scissors, or even the saw.

Hemorrhage is restrained by small pieces of ice enclosed in a fold of towel or napkin, and held in contact with the bleeding surfaces. Should this not suffice, the bleeding vessels should be sought for and secured by ligature. As a rule, the hemorrhage should be controlled before the incision is made into the trachea, unless the latter is imperatively requisite; but, if the bleeding is venous and due to the existing impediment in respiration, the trachea may be opened at once and the tube introduced, when, with the free access of air, the ordinary course of the circulation will be resumed, and the hemorrhage will usually cease spontaneously; indeed, some authors state that it will always be arrested at once.

Trousseau has made the statement¹ that he has never been obliged to tie a single vessel,—vein or artery. In 111 cases out of 113, he had found the hemorrhage arrested the very moment the canula had been introduced; twice it had continued after the insertion of the tube, but compression of the tissues upon it sufficed to arrest the bleeding. He therefore concludes that the veins should be avoided in performing tracheotomy; and, when that is impossible, they should be freely divided, and need not be ligated; but that the trachea should be opened, and the canula inserted and secured in position.

Cases are recorded, however, in which patients have been suffocated by sudden flux of blood into the trachea, before there had been time for re-establishment of the circulation.

The hemorrhage is sometimes very great, even when there are no anomalous vessels to embarrass the operation; at other times the action of the circulatory system has become so much enfeebled by the want of air, that the hemorrhage is insignificant.

A so-called bloodless method of tracheotomy is pursued in Germany, by Bose² and others. The cricoid cartilage being exposed by vertical incision, it is steadied with the finger, and

¹ *Traité de phthisie laryngée.*

² *Arch. klin. Chir.*, Bd. 14, 1871, p. 137; *Henry: Brit. Med. Jour.*, May 25, 1878, 752.

a transverse incision, rather less than half an inch in length, is made, as near its upper margin as possible, to divide the duplicature of fascia which envelops the thyroid gland and connects it with the trachea. The lower border of this incision is seized with forceps, and the fascia is stripped off from the trachea with a blunt hook or director. As the operator gradually descends with the director, he loosens the isthmus of the thyroid gland from the trachea, pushing the gland outward and downward, and lays the upper tracheal rings quite bare, so that they can be seized and divided in the usual manner.

Another method of operating consists in transfixion of the parts, and cutting through coverings and windpipe in a single stroke—puncture and incision—with a knife, or puncture with a blade-like trochar, the tracheotome, of which many varieties have been devised.¹ This is hap-hazardous. Some surgeons dissect down to the trachea, and then employ a double-bladed tracheotome to penetrate the windpipe and dilate the wound by separating the blades. Here, it is superfluous. Chaisagnac, Isambert, and others have operated by fixing the trachea with a grooved tenaculum passed directly beneath the cricoid cartilage, and then penetrating the tube by a direct puncture along the groove, through the skin and subjacent tissues. Though successful at times, this procedure is very dangerous, and sometimes fatal. In these instantaneous operations there is not space enough in the wound to secure a bleeding vessel, if necessary.

Considerable spasmodic disturbance often attends the introduction of the tube, which renders it sometimes difficult to retain it in position while being secured to the neck; but this spasm usually passes off in a few seconds or minutes.

Sometimes considerable difficulty is encountered in introducing the tracheotomy-tube. This may be due to insufficiency of the artificial opening, or to resiliency of the cartilages. I have never had any difficulty of this kind, and have usually placed a tenaculum or a bent hair-pin in the wound upon one side, while an assistant placed another opposite, so that the edges of the wound were separated by gentle traction, and the tube slid down between the posterior faces of the two instruments, which guided the canula safely and speedily into the

¹ See Kuehn: *Op. cit.*

trachea. Some surgeons secure the trachea on each side by a ligature, divide it between the two ligatures, and separate the lips of the wound by drawing on the ligature. Roser inserts the ligatures, on either side, after the incision is made. I have seen the edges of the wound drawn so far apart in this way as to flatten the calibre of the trachea, and prevent insertion of the tube for mere want of room.

Prof. Trousseau devised a special dilator (Fig. 203) for the tracheal wound and the guidance of the canula, which has been considered by some surgeons as almost an indispensable requisite in the operation. The instrument is introduced into the wound closed, its branches are then separated, and the tracheotomy-tube slid down between them. The ends of the blades are turned in opposite directions, and thus facilitate the movement of the canula. It is more difficult of manipulation than hooks or hair-pins. Elsborg's nasal dilator (Fig. 7, p. 15) is often a more useful instrument. Quite a variety of appliances have been devised for this purpose. They are sometimes very useful when there is difficulty in introducing the tube after it has been taken out to be changed or cleaned, in the after-treatment; and likewise in maintaining patency of the orifice during temporary removal of the tube, or while searching for false membranes or foreign bodies, at the time of operation or afterward.

The introduction of the tube will be facilitated by the insertion of a close-fitting bougie or catheter as a guide or conductor. The tubes used by myself are each provided with a well-fitting metallic conductor (Fig. 204), similar to that used with the cylindrical anal or vaginal speculum, composed of a rigid wire, with handle, and a protruding beaked extremity, flattened from side to side, and fitting closely at each orifice, so as to be perfectly steady, and constitute a single instrument

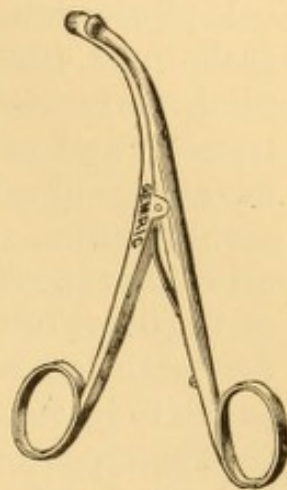


FIG. 203.—Trousseau's dilator

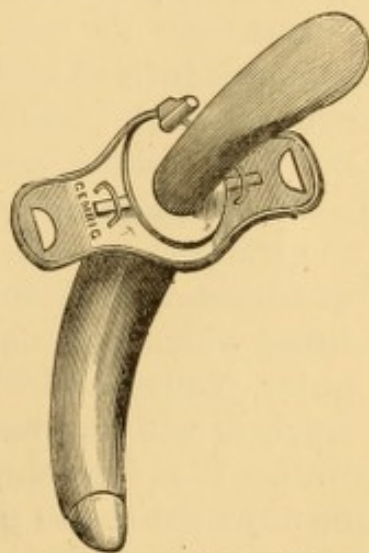


FIG. 204.—Author's rigid conductor, for facilitating introduction of tracheotomy-tube.

as it were. As soon as the canula is in place, the conductor is immediately removed. The whole manipulation is so quickly done that there is practically no suspension to respiration. The rectangular tube of Mr. Durham is furnished with a conical pilot-conductor, with a vertebrated or flexible body of scale-links, like the inner tube. Dr. Krishaber¹ uses a hollow pilot, perforated, catheter-like, at the sides of its beaked extremity, and otherwise an ordinary inner tube, which has the advantage of not interfering at all with respiration during its manipulation, and which appears to be the most desirable of all contrivances of its class. The sides of the terminal portion of the outer tube used by him are truncated, so as to give room for large lateral orifices in the piloting tube. This I should judge to be the most suitable device yet produced.

The tapes are usually sewed on the rings of the outer tube. It is much better to have them made with button and button-hole, as I have done for a number of years, which is equally secure, and much more convenient for changing them, especially as this can be done without removing the tube. A section of rubber webbing interposed in the course of the tape, as suggested by Thornton, is of some avail in the movements of the head, by virtue of its elasticity. One tape should be much longer than the other, so that they can be tied at the side of the neck instead of behind it. Dr. Thornton uses hooks and eyelets; but I have found them less secure than the button and button-hole, and no more easily manipulated.

To avoid pressure upon either anterior or posterior wall of the trachea, as sometimes occurs by the tilting of the ordinary quadrant-shaped canula, Mr. Durham, of London, devised a tube² which is so curved that the two orifices present in rectangular planes, and which therefore occupies the centre of the trachea, without reaching far enough either way to strike its wall. It is furnished with a movable collar, by which it can be adjusted to the proper depth from the surface. As a rigid inner tube of the same shape cannot be introduced, he has had it made of links, so as to be flexible. This inner tube requires much more careful attention than a tube in one piece,

¹ *Annales des maladies de l'oreille, du larynx, etc.*, July 1, 1878, p. 142, illustrated.

² *The Practitioner*, London, April, 1869, p. 212.

as it presents numerous points for the detention of mucus and other products, which clog it more quickly, and sometimes prevent its removal.

After the tube has been inserted, and respiration is quiet, the edges of the external wound above and below the tube are brought together by adhesive strips, the lower end of the wound being left patulous for drainage. A piece of oiled silk or rubber sheeting is usually slit and slipped under the shoulders of the tracheotomy-tube, to prevent it from rubbing the skin—but I find that it often excites a cutaneous eruption, and that it may be dispensed with. The wound is dressed with cold water or with a greased rag, at the fancy of the operator. In most instances no dressing whatever is required.

A piece of gauze or muslin is then straddled upon a strip of adhesive plaster, and secured at the upper portion of the neck, in such a manner as to overhang the orifice of the canula. This protects the tube from dust, and modifies the temperature of the inspired air by retaining some of the warmth of the breath of expiration. The dressing may be attached to the neck in the same manner. It saves the discomfort of tying bands around the patient's neck, and admits of ready inspection of the parts. This mode of dressing was brought to my notice by Dr. Packard.

As long as the patient is confined to his room, which ought always to be for four or five days at least, the apartment should be kept warm, at a temperature of not less than 80° F., and even upward, 85° to 90° at times with advantage, the heat being determined by a thermometer; and more or less of an atmosphere loaded with steam should be secured by some of the means already narrated (see Diphtheria, p. 173). This lessens in great measure any risk of bronchitis or pneumonitis, a risk which is, perhaps, always present in a greater or less degree.

For the first twenty-four hours the inner canula should be removed every two or three hours and be immersed in warm water, for the solution of the tenacious, gummy mucous deposits, almost always presenting, which adhere to it; and it should not be reintroduced until after the outer tube has been cleansed in position, by means of a feather, or a linen or sponge mop, securely fastened to a whalebone or other stem. A special form of forceps (Fig. 205) was devised by Trousseau for removing false membranes, which is exceedingly useful in

operations for diphtheria and croup. Mr. Karop has devised a single tube of coiled silver wire, with an ingenious collar, admitting of ready changing of the tube, and which is said to facilitate the passage of mucus without requiring the use of

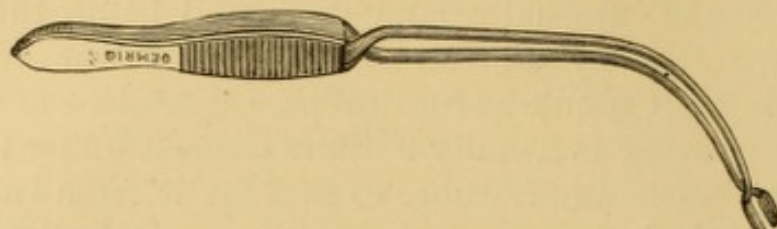


FIG. 205.—Trousseau's forceps for the tracheal canula.

feathers, sponge, or mop.¹ At first, the removal and insertion of the inner canula very often provoke spasmodic cough; this can be lessened, in the latter instance, by warming the tube before introducing it. After the first twenty-four or forty-eight hours there is rarely occasion to remove the inner tube more than three or four times a day, unless it become occluded, a condition which will become evident by the sensations of the patient, or his movements, if too young to express them. When it is proposed to remove the canula permanently, a finger is placed upon its orifice, to ascertain whether the patient can breathe comfortably through the larynx with the air that passes by the side of it; and, if respiration can be maintained for a number of hours with the orifice occluded with a cork, the tube is withdrawn, but kept within easy reach for reintroduction if necessary. The external wound usually closes promptly without any interference. If it should contract in a few hours to such an extent as to interfere with reintroduction of the tube, should that become necessary, it can be dilated with the appliances figured on pages 15 and 592, if at hand, or with some similar contrivance, such as a strong pair of small forceps. When the wound has contracted a great deal, a fresh incision may be necessary to reintroduce the tube.

Fungous granulations presenting at the wound at any time, are to be repressed by local applications of iodoform, tannin, gallic acid, sulphate of copper, nitrate of silver, or the incandescent cautery; or, if extensive, they are to be snipped off and the surface of the wound cauterized.

The irritation of a tube, especially if fenestrated, will some-

¹ Brit. Med. Jour., Aug. 19, 1876, p. 237.

times give rise to exuberant granulations in the track of the wound, usually at the upper angle of the tracheal orifice. They occasionally develop into actual polypi. They require evulsion or excision, with cauterization of the stump; and subsequent readjustment or alteration in the shape of the tube. The valvular action of such a flap explains the possibility of unimpeded respiration with the tube occluded, with impossibility of respiration when it is removed.

In cases where a tracheotomy-tube is worn for a long time, I have noticed, in several instances, that it is gradually forced upward, so as eventually to occupy a position higher in the neck than that at which it had been originally inserted. In one of my patients the tube was actually forced up out of the trachea in this way, and a longer one had to be substituted. This appears to be the result of muscular action, and seems confined to the tissues exterior to the trachea. It is quite probable that too low an operation is often made in cases where it is deemed desirable that the artificial opening shall be as far as practicable from the seat of disease, and that nature's efforts rectifies the error.

Permanent tubes are sometimes perforated with a fenestrum on their exterior surface to permit access of air to the vocal cords. I have never found this necessary, sufficient volume of air passing by the sides of the tube for purposes of phonation or expectoration. The fenestrum should be entirely in the intra-tracheal portion of the tube—therefore much lower than it is usually made. If it encroach on the track of the wound, it is very likely to excite irritation, and develop fungous granulations, as I have seen in several instances not in my own immediate practice.

A patient upon whom I operated in 1867, and who went abroad shortly after, was cautioned by me against allowing any foreign surgeon to persuade him to put a fenestrum in his tube, as I knew he would be urged to do. He was overpersuaded in Paris, however, and the consequence was that his tube became impacted by granulations through the fenestrum, which resisted the surgeon's efforts to repress them with caustic, and which required forcible withdrawal of the tube and its replacement by another without an opening, putting the sufferer to unnecessary detention, expense, pain, and anxiety.

Patients compelled to respire permanently through an artificial opening should be provided with a number of tubes, and taught the necessity of their frequent (daily is best) removal

for purposes of cleaning. It should be also remembered that metallic tubes are liable to undergo slow corrosion by long use, and that the retention of a tube in this condition may lead to serious accident. Porter states¹ that in one of his cases the instrument, having been used for three years, became so corroded that it broke across in the middle, and a portion of it dropped down the windpipe, so that another operation became necessary for its extraction. Similar accidents have been recorded by others. In one instance² the second tracheotomy for the removal of the fragments of the tube was not made until fourteen months after the detachment of the tube from its shield. In a case³ in which a tracheotomy-tube had been retained in the trachea upward of five and a half years, the whole outer tube had become oxidized and eaten away, so that nothing remained but the shield, which lay external to the windpipe. The inner tube was also partially destroyed, at least half of it having disappeared; and the remaining portion was much thinned, and had an eroded margin where the part had been eaten away. It had not been withdrawn for two years. A tracheotomy-tube, worn for six years,⁴ wore out, separated from the shield, and dropped down the trachea.

Breathing through a tracheotomy-tube may be maintained for indefinite periods.

Stromeyer mentions a patient, operated upon by his father, who wore a tube for forty years. A female patient operated upon by Dr. Purdon⁵ wore a tube for forty-six years. After death "the interior of the larynx was healthy, all trace of inflammation having disappeared except the contraction, which had probably followed cicatrization, leaving the lower aperture of the larynx so narrow as only to admit an ordinary probe." The specimen showed a healthy air-tube in every respect, save the little aperture into the trachea where the skin and mucous membrane became continuous. All the muscles attached to the hyoid bone were normal in every way, except the omo-hyoid, which was reduced to the size of a mere thread.

It sometimes happens that tracheotomized individuals are compelled to wear a tube permanently, or for an indefinite

¹ Op. cit., p. 144.

² Ogle and Lee: *Med. Times and Gaz.*, Sept. 21, 1872, p. 324; see likewise Houlhouse *The Lancet*, Jan. 27, 1872, p. 113.

³ Thos. P. Pick: *Trans. Path. Soc. London*, 1870, p. 416.

⁴ Ogle: *Med. Times and Gaz.*, Nov. 5, 1870, p. 531.

⁵ *Dub. Jour. Med. Sci.*, Nov., 1877, p. 446. Report of case, *ibid.*, 1st series, No. 24.

period. Cases are on record in which it has been worn for more than forty years, with little or no inconvenience. The fistulous track becomes covered with a membrane analogous to mucous membrane with squamous epithelium.¹ As most of these subjects are compelled to occlude the tube² externally whenever they want to speak, they should wear an inner tube arranged with a valve, which admits the air of the inspiratory current, but occludes the expiratory current, forcing it to pass by the sides of the tube through the larynx, so that it can produce vibration of the vocal cords if they are intact or nearly normal. The best form of speaking-tube that I have seen is that of Luer (Fig. 206), to which my notice was drawn by Dr. Roe, of Rochester. It has a curved adjustable chamber in which a light, hollow silver-ball valve falls forward by gravity during expiration, and is rolled backward against a pair of wires during inspiration. It is easily hidden behind collar or cravat.

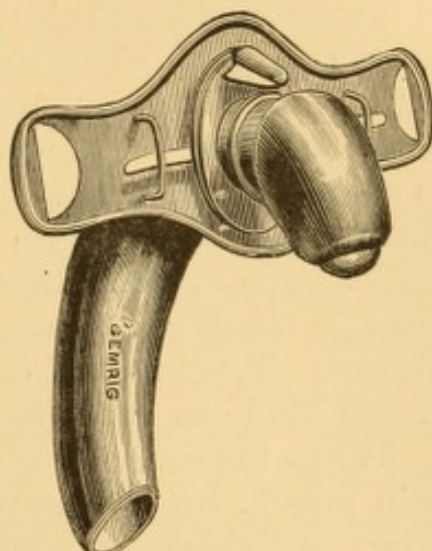


FIG. 206.—Luer's pea-valved tracheotomy-tube.

When skilfully made the valve is practically noiseless, and attracts no attention. Its use, too, diminishes excessive secretion, the expectoration of which is often annoying to the sufferer. When not required for purposes of conversation, as at night, and in the privacy of home, the valve is removed to facilitate respiration, which it slightly impedes in most instances.

CATHETERIZATION OF THE LARYNX AND TRACHEA.

Catheterism of the upper air-passage is occasionally resorted to in cases of mechanical obstruction to the entrance of air,

¹ In a case of croup following measles, in which death occurred on the forty-sixth day from some undetermined cause, the canula having remained in use on account of a stenosis of the larynx, Henle found the fistulous opening clothed with smooth plicated membrane resembling a mucous membrane, and covered with flat nucleated epithelium-cells, 0.008''' in diameter. *Am. Jour. Med. Sci.*, Oct., 1853, p. 491.

² For recent examples of ability to speak without occlusion of the tube, see *Med. and Surg. Rep.*, Phila., 1878, pp. 184, 218.

other than that produced by the presence of a foreign body. This may occur from enlargement, thickening, or malposition of the epiglottis ; from stenosis within the larynx or trachea ; from external pressure upon the trachea ; from paralysis of the muscles opening the glottis ; or from spasmodic closure of the glottis. It is also resorted to for the purpose of practising injections into the trachea or bronchi. A simple elastic catheter of large size and sufficiently long (about twelve inches) answers for the purpose. This method was much employed for injecting the bronchi or pulmonary cavities by the late Prof. Horace Green, of New York, who recommended bending the catheter to a suitable curve and then dipping it in cold water, to give it sufficient stiffness to do away with the use of the metallic guide. The French surgeons prefer a silver instrument. Care must be taken that the instrument is not passed into the œsophagus. With the aid of the laryngoscopic mirror a mistake of this kind can be avoided.

When the catheter has entered the trachea, there is usually pain, cough, spasm, loss of voice, and egress of air through the tube. All these symptoms may be produced with the catheter in the œsophagus. If there is voice, it is proof that the instrument has not been introduced within the larynx.

In cases where the catheter is to be retained for any length of time, its presence in the mouth is very uncomfortable. On this account it has been recommended to allow the upper end of the catheter to protrude through one of the nostrils, which is accomplished by fastening it to the staff of a Bellocq's canula passed through the naris. Sometimes the catheter cannot be directed into the trachea through the mouth, and it is then recommended to pass it through the nose in the first instance, a procedure usually more embarrassing, but sometimes not difficult of accomplishment. I have had no experience with prolonged retention of the catheter through the nasal passage.

EXSECTION (EXTIRPATION) OF THE LARYNX.

Partial or total removal of the larynx in mass has been performed a number of times recently for malignant disease. The feasibility of the operation is said to have been entertained

in 1856 by Koeberle,¹ but it was first executed in 1873 by Professor Billroth, of Vienna,² who had been emboldened to the undertaking by the successful results of some experiments on dogs made by Czerny in 1870.³ The larynx has been extirpated with part of the epiglottis, the whole of it, or without it; has been removed in part; and has been removed with more or less of adjacent structures, in one instance including the hyoid bone and portions of the tongue, pharynx, pharyngo-palatine folds, œsophagus, and the submaxillary glands of both sides.⁴ In a number of these cases, probably half, death has ensued within from three to fourteen days, from pneumonia, as is not unusual in extensive operations in the cervical region, whether opening into the air-passage or not; but death has resulted from collapse in one case only.⁵ But one case out of the first ten of total extirpation was known to have survived the operation six months.⁶ Death from recurrence of the malignant growth took place in three months in Billroth's first case, in four months in Langenbeck's case, and in six months in Heine's case.⁷ A case of complete extirpation in a female, fifty-two years of age, performed by Dr. George Wegner, of Berlin, in September, 1877, had survived nine months at last reports,⁸ and I have seen no record of the death of this patient, or of one operated on by Dr. Foulis, of Glasgow,⁹ at about the same time. Whether more encouraging results will follow recourse to the operation at a less advanced stage of the disease, remains to be seen. It is only by estimating the probabilities of life without resort to extirpation, that a conclusion can be drawn of the propriety of the operation, aside from inseparable immediate risks.

Hæmorrhage has been reported as considerable in the

¹ Berger: *Revue des sciences méd.*, IX., 1, p. 298; *Am. Jour. Med. Sci.*, Jan., 1878, p. 268.

² Gussenbauer: *Arch. klin. Chir.*, Bd. 17, 1874, p. 343, illustrated.

³ *Wien. med. Woch.*, 1871, p. 559; *Brit. Med. Jour.*, June 18, 1870, p. 637.

⁴ Langenbeck: *Berlin klin. Woch.*, Aug. 16, 1875; *Med. Times and Gaz.*, Aug. 28, 1875; *Am. Jour. Med. Sci.*, Oct., 1875; *Arch. klin. Chir.*, supplement to Bd. 21, 1877, p. 136, illustrated.

⁵ On the sixth day; Schmidt: *Arch. klin. Chir.*, Bd. 18, 1875, p. 189.

⁶ Bottini's first case, reported by Martelli (*Gaz. del Cliniche*, March 9, 1875), *London Med. Record*, April 28, 1875, p. 261.

⁷ Reported in *Böhm. Correspond.-Blatt.*, 1874, No. 17.

⁸ *London Med. Record*, July 15, 1878, p. 269.

⁹ *The Lancet*, 1877, p. 532; Jan. 26, 1878, p. 118.

majority of the operations, as slight in one or two, and as absolutely prevented in one performed by the galvano-cautery. The following selections will illustrate the method of performing the operations, for further details of which reference is made to the original reports. In most of these cases the patients had been wearing the tracheal canula.

Billroth's first case, a man, thirty-six years of age, had been previously subjected to division of the larynx for the removal of malignant growth, and the same operation was being repeated when it became evident that extirpation would be necessary to remove the mass. The consent of the patient being obtained, on recovering from the anæsthetic, he was immediately replaced under its influence, and the operation was performed in the following manner: The incision in the soft parts was continued up to the hyoid bone, and the tissues were separated from the larynx on both sides. The trachea was divided transversely below the cricoid cartilage, and a canula inserted into it. The larynx was then drawn forward with sharp double hooks, and the cricoid cartilage separated from its attachments to the œsophagus from below upward; then the larynx was detached from behind forward, and the operation completed by transverse division of the thyro-hyoid ligament. Compresses of sponge were employed to prevent the blood from flowing into the trachea. Inspection showing that the epiglottis was involved in the disease, about one-third of that structure was removed on one side from the base upward, as well as portions of the upper two rings of the trachea. The trachea, which had been held in position by sharp hooks, was now stitched to each side of the external wound, and the pharynx stitched so as to bring the raw surfaces of the œsophagus in contact and give it a form which would impede the escape of food by the wound. The patient was much exhausted from pain and loss of blood during the operation, which occupied an hour and three-quarters. Some wine was administered by the stomach-tube; and frequent paroxysms of cough were stilled by injection of morphia. There was some secondary hemorrhage which gave trouble, but the patient rallied well, and on the eighth day was able to swallow liquids without much escape from the wound, and on the eighteenth day could swallow solids, so that artificial means of introducing nourishment were discontinued. On the twenty-first day a Gussenbauer's artificial vocal apparatus was introduced, enabling the patient to speak in a loud, monotonous and artificial voice. After doing well for a time, recurrence ensued, with death about three months after the operation.

Professor Mass, of Breslau, extirpated an entire larynx in 1874¹ for carcinomatous adeno-fibroma in a man fifty-seven years of age. To prevent the flow of blood into the trachea, he shoved a footstool under the middle portion of the vertebral column, so as to bring the entire field of operation below the level of a tracheotomy-tube which the patient was wearing. A longitudinal incision was made from the hyoid bone to the tracheal wound. The larynx was freed from the soft parts, the thyro-hyoid and thyro-epiglottic ligaments were divided first, on account of the greater development of the tumor above; the larynx was then

¹ Arch. klin. Chir., 19, 1876, p. 507.

rapidly separated from the œsophagus, bent forward, and then the trachea was divided from the cricoid cartilage from behind forward. The patient did well until the thirteenth day, when pneumonia supervened, with death the day following. In a second and successful¹ case, Mass employed the same manœuvre satisfactorily to prevent the flow of blood into the air-passages, again divided the upper portions first, but retained the epiglottis, and a small annular portion of the cricoid cartilage, likewise, to facilitate retention of the canula and secure a free opening from the trachea to the mouth without any artificial appliance. The epiglottis was found so much in the way of artificial vocal apparatus that that structure would be removed by Mass in repeating the operation on another subject.

Bottini, in his second case, used the galvano-cautery instead of the knife,² and reports the operation as almost absolutely free from hemorrhage. The patient, a man, forty-eight years of age, having declined preliminary tracheotomy, was placed under anæsthesia, and a T incision was made with the galvanic knife. The flaps were then dissected off right and left, and everted. The sterno-hyoid and sterno-thyroid muscles were then divided at their superior attachments, as well as the two crico-hyoids,—and the larynx exposed. An attempt to isolate the larynx with forceps and probe had to be intermitted on account of hemorrhage, so that the galvanic knife was resumed to arrest the bleeding, which it did immediately, and then to isolate the structures to be removed. The crico-thyroid membrane was incised, and a large canula of hard-rubber introduced. In attempting to isolate the larynx from the œsophagus, it was seen that the anterior wall of the œsophagus was involved in the disease, and it was decided to sacrifice it. The larynx and the œsophagus were then encircled in a loop, and, although this included a large portion of the cricoid cartilage ossified at several points, the incandescent wire cut through the osseous portion without difficulty. A second loop, already in readiness, was then employed to cut the adherent base of the larynx above and behind. The extirpation was accomplished as an exsanguinous operation in the absolute sense of the word, and the only bleeding occurred when the galvanic loop was abandoned to make use of the director. The wound was dressed by the open method, and the void parts filled with carbolated charpie after the introduction of the stomach-pump to administer stimulants. Death occurred from pneumonia on the third day.

Langenbeck made a partial excision of the larynx in a man, sixty-four years of age, for the purpose of removing a carcinomatous growth with its attachments, including half of the cricoid cartilage of the right side, the arytenoid cartilage of the same side, and nearly all that half of the thyroid cartilage. Numerous ligatures were required during the operation. Pneumonia occurred in two days, and the patient sank rapidly.³

Artificial Vocal Apparatus.—To remedy the loss of voice to which patients are subjected by extirpation of the larynx,

¹ Arch. klin. Chir., XX., 1877, p. 535.

² Annales des Maladies de l'oreille, du larynx, etc., July 1, 1878, p. 182; Leffert's Reports, N. Y. Med. Jour., Oct., 1878.

³ Brit. Med. Jour., Feb. 2, 1878, p. 154

an ingenious artificial substitute for the vocal apparatus has been devised by Gussenbauer,¹ which is likewise applicable for introduction into the larynx in loss of voice from destruction of the vocal cords. In its approved form it consists essentially of a canula containing a vibrating reed, and intended to be inserted at will through the external orifice of a double laryngo-tracheal canula. The entire appliance consists of three canulæ: a tracheal canula, with a large aperture on its convex surface; a somewhat similar tube, with a similar aperture, which is passed within the first one in the reversed direction, so as to ascend the air-passage—thus far representing an appliance long in use, at times, to maintain respiration through the mouth in cases of moderate stenosis of the larynx, with an artificial opening in the trachea; a third and short tube which fits into the second one, and is supplied with a plate bearing a vibrating reed, which is set into vibration by a powerful voluntary expiratory effort, producing a monotonous sound, which, broken into articulate speech in the usual manner, serves as an artificial substitute for the normal voice. This apparatus is supplied with an artificial epiglottis for cases in which the epiglottis has been removed; the artificial valve being maintained erect by the force of a spring, and being depressed in deglutition by the descent of the base of the tongue. The reed-case is easily detached, to be cleansed from time to time of accumulated mucus. Retention of the epiglottis sometimes interferes² with the use of the apparatus, and its removal interferes sometimes also,³ so that the question of its influence is still a matter of inquiry. Gussenbauer's tube has been subjected to various modifications, of which the most important one seems to have been suggested by Dr. Irvine⁴ for Dr. Foulis's case. The laryngeal tube, which is the more difficult of insertion, is adjusted first, and the tracheal tube passed through it, the latter carrying the reed, which is simply pushed into a groove in its sides, and thus readily adjusted or withdrawn. Heine⁵ modified the original apparatus by flattening the laryngeal tube and making it more rectangular, so as to present forward more than

¹ Arch. klin. Chir., Bd. 17, 1874, p. 349, illustrated.

² Mass: Loc. cit.

³ Wegner: Loc. cit.

⁴ The Lancet, Jan. 1878, p. 119, illustrated.

⁵ Loc. cit.

backward, and he likewise adjusted a turn-key to the reed, by which it could be moved aside when not in use, so as to permit an unimpeded current of air for free inspiration.

These voice-tubes are inserted as soon as the parts will bear them—which occurred on the ninth day in Heine's first case—and they require special adjustment and alteration to meet individual indications. The reeds are made of thin plates of metal, hard-rubber, or ivory. I have no personal knowledge of these tubes, or of the operations which led to their suggestion.

CHAPTER XVI.

AFFECTIONS OF THE LARYNGO-PHARYNGEAL AND OF THE GLOSSO-EPIGLOTTIC SINUSES.

The Laryngo-Pharyngeal Sinuses may undergo ulcerative inflammation from disease of the glands, or from irritation excited by the retention of particles of food. Fish-bones and the like sometimes tear the mucous membrane in their passage to the œsophagus. The sensations of this lesion are a more or less continuous pricking as by the presence of a sharp or pointed body, more particularly felt on swallowing, but also on coughing, sneezing, or any other movement of the parts, such as extending the tongue. The abraded or divided surfaces are put upon the stretch, giving rise to the pain. There is usually a more or less copious secretion of mucus in the sinus, sometimes filling it, and hiding the affected spot from view. A sponge plunged into the sinus will absorb this fluid, and the parts can then be examined.

Topical applications by means of a sponge dipped into a solution of nitrate of silver, will soon eradicate the entire trouble.

Foreign bodies, such as bits of thread broken off in sewing, sometimes remain in these sinuses for a long time, keeping up constant irritation. They are recognized laryngoscopically and removed with forceps.

The glands at the bottoms of these sinuses are sometimes liable to take on inflammation and ulceration. This condition attends phthisis not unfrequently, but may exist independently of that or any other apparent systemic affection.

An ulceration in one or both of these sinuses may be mistaken for laryngitis, as it may give rise to irritation, pain, hoarseness, cough, and purulent expectoration.

A case of supposed chronic laryngitis, which had gone the rounds of several large hospitals in Great Britain and the United States during eighteen years, and had been ineffectually treated, though occasionally relieved, by the passage into

the larynx of a sponge probang loaded with a solution of nitrate of silver, was found by the author, on laryngoscopic inspection, to be due to ulceration in one of these sinuses, and was effectually cured by a few local applications of the nitrate of silver, made under guidance of the laryngoscope. This case, on account of the view it afforded of the entire trachea, and several rings of the right bronchus, was exhibited by me, in 1867, to the members of the Medical Society of the State of Pennsylvania. The relief has been permanent (December, 1878).

The Glosso-Epiglottic Sinuses may be affected in a similar manner. Sometimes they are the seat of cystoma. They likewise afford lodgement for foreign bodies. Ulceration may give rise to great annoyance. Laryngoscopic examination is usually requisite to reveal the condition of these sinuses effectually.

Mrs. B., æt. thirty, mother of three children, applied to me Nov. 19, 1866, with a sense of pain across the throat, as of a sharp, foreign body. The pain was constant, and increased on swallowing, especially with acid substances. There was slight expectoration of mucus. After failing to get relief in private practice during eight months, she entered one of our hospitals, where her neck was blistered to no purpose. Her general health being good, the physicians made fun of her at first, then treated her for bronchitis, after that for neuralgia, and finally determined that her disease was a waywardness of pregnancy. She had become much emaciated from mental anxiety. Examination revealed ulceration of both glosso-epiglottic sinuses, especially of the left side. A few applications of sulphate of copper (sixty grains to the ounce) cured her complaint.

CHAPTER XVII.

EXTERNAL AFFECTIONS OF THE THROAT AND NECK.

DIFFUSE INFLAMMATION OF THE CONNECTIVE TISSUE OF THE NECK.

(Diffuse Cervical Phlegmon, Diffuse Cervical Abscess, Ludwig's or Louis's Angina; Cynanche Cellularis Maligna, Cynanche Sublingualis Rheumatico-Typhodes.)

DIFFUSE inflammation of the connective tissues of the neck—sometimes traumatic—is sometimes idiopathic, and sometimes an extension from adjacent inflammations. Sometimes it commences at a distance on the base of the skull.¹ Sometimes it cannot be referred to any special organ, although the submaxillary and cervical glands are often implicated. The cervical muscles, too, give way to the inflammatory process in some instances. The disease is much more frequent in adults than in children.

Idiopathic cases are usually attributed to the influence of cold, but the peculiar influence attracting the inflammatory action to the cervical region is uncertain. It has been thought to be more apt to prevail during epidemics of diphtheria, but hardly on sufficient evidence. Secondary cases follow various inflammatory diseases of the lower jaw, hyoid bone, and larynx. Deuteropathic cases have been occasionally encountered in the acute exanthems and in typhoid and puerperal fevers. Traumatic cases occur chiefly as a result of military encounter, and occasionally as a result of suicidal attempts.²

The tendency to gangrenous destruction of the connective tissue is very great, and the parts, when opened surgically, or examined after death, are saturated with a discolored, fetid, and sanious pus, in which there are more or less numerous shreds of dead tissue. Septic poisoning and pyæmia may be produced.

¹ Porter: Op. cit., p. 94.

Porter: Loc. cit.

Whether secondary or consecutive, or whether originating in the connective tissue, this inflammatory process is apt to become menacing to life by rapid extension to the surrounding, and to the deeper structures. It may extend clear around the neck, and from the region of the parotid gland down to that of the clavicle. The various planes of connective tissue become destroyed and gangrenous, with the formation of irregular, diffuse abscesses, which burrow extensively or point externally as may be. The abscess may point subcutaneously, gravitate into the mediastinum, or rupture into the trachea or œsophagus, or even into the mouth; sometimes pursuing a very circuitous route to reach the exterior.

In one of my cases the affection began, after the extraction of a tooth, in an inflammatory swelling of the submaxillary glands, principally upon the opposite side, closing the jaws immovably, and deforming the visage to a marked degree. The lower tissues of the neck were not affected at first. In a few days the abscess burst into the mouth, at a point opposite the second molar of the lower jaw on the side of the greatest enlargement, and for several days discharged large quantities of fetid ichorous pus. The abscess then extended beneath the digastric and omo-hyoid muscles, and presented externally over the thyroid cartilage, at which point it was opened by incision, giving egress to several ounces of horribly offensive pus, in which were clots of blood and detritus of dead connective tissue. As soon as this counter-opening was made, the discharge by the mouth ceased. The parts gradually resumed their natural appearance; but although the submaxillary swellings subsided as soon as the abscess commenced to discharge in the mouth, the rigidity of the jaws did not abate until several days after the external incision. During all this time the teeth were slightly separated so that the tip of the tongue could be passed between them, and this enabled sufficient concentrated liquid nourishment to be taken to keep up the patient's strength during the progress of the abscess.

Symptoms.—These are first slight fever, with headache, loss of appetite, and dysphagia. Soon there is tumefaction of one side of the neck or of both, without cutaneous congestion. Evidence of the swelling is frequently evident on inspection and palpation of the floor of the mouth, with congestion of the overlying mucous membrane. The tumor enlarges rapidly, and in a few days may be level with the chin or even extend beyond it. The cutaneous surface has then become tense and brawny, and there is more or less collateral œdema, especially of the face. The patient lies with the head thrown back in a constrained position. The dysphagia increases almost to aphagia, the jaws cannot be separated to receive the food or chew it; a

viscid, unpleasant saliva accumulates in the mouth or dribbles from it; the breath is offensive. Speech and articulation are impaired. Respiration becomes impeded by the pressure of the tumor on the upper air-passages, the pharynx, and the tongue. This may increase to urgent dyspnœa, or even to asphyxia. If resolution takes place, the symptoms gradually abate. If suppuration ensues, the skin undergoes congestion, fluctuation becomes evident, and palpation will often elicit crepitus, at points, if gangrene is taking place. The general symptoms are those of adynamia, in some instances associated with those of pyæmia.

Diagnosis.—This will depend on the evidence of swelling, otherwise not to be accounted for, externally and within the mouth, the existence of the symptoms enumerated, and, later on, evidence of fluctuation and crepitus as may be.

Prognosis.—This depends on the nature of the existing cause, should there be any. If resolution takes place, which is not very frequent, recovery is to be expected. Suppuration, too, is sometimes followed by recovery, even when extensive and gangrenous; and when not extensive, and of a healthy character, recovery is the rule. In many cases, however, the prognosis is unfavorable. Gangrenous destruction of tissue is apt to be followed by septicæmia and pyæmia; and penetration of the pus into the air-passages, by asphyxia. The usual course of an idiopathic case which recovers, occupies from ten to twenty days. In consecutive cases the course may be much more chronic.

Fortunately cases of diffuse cervical abscess are comparatively unfrequent. They are often fatal, and usually by pyæmia and not by suffocation. The bones in the neighborhood are sometimes affected. I saw one case, after recovery, in which the abscess broke just over the sternum, the adjacent ends of the clavicles having apparently undergone inflammation and slight loss of substance. The inferior maxilla, the hyoid bone, the larynx, and the thyroid gland have been found to have undergone degenerative disease from these abscesses.

Cases of sphacelus and sloughing of the thyroid gland from diffuse inflammation of the connective tissue of the neck have been recorded by Lebert and others, in which recovery ensued without any apparent inconvenience from the loss of the gland.¹

¹ Brit. Med. Jour., Feb. 2, 1876, p. 192.

Treatment.—In addition to general constitutional treatment required to meet febrile and other indications, nourishing food by the mouth, as long as it can be so taken, and then by enema, is prominently indicated, with a liberal use of quinia or cinchonidia (twenty to sixty grains daily in divided doses) and the free use of alcoholic stimulants. In the earlier stages cold applications (ice-bags) may be employed externally to favor resolution, with pellets of ice in the mouth. When the parts are very painful, the use of leeches externally is admissible. Œdema of the larynx, and compression of the larynx and trachea, may require tracheotomy, but there is not always sufficient space to perform the operation successfully. Incision into the tissues may relieve the tension. An unusually long tube, or a section of rubber tubing may be necessary to reach the interior of the opened windpipe. When symptoms of suppuration become manifested, warm applications are indicated to assist the process; and the case should be carefully watched and the parts frequently inspected and palpated, so that due advantage can be taken of any indication of the approach of the purulent contents to the surface, as indicated by an erysipelatous blush, and an œdematous condition of the external parts, with sometimes a glazed appearance of the integument. Previous to this manifestation it cannot be known at what point the pus may make its appearance, and it would therefore be injudicious to dissect the tissues of the neck in order to hunt for it. Pirogoff¹ recommends the division of the tissues of the neck in the middle line, or at point of greatest tension, for antiphlogistic purposes in traumatic cases, even when the position of the abscess cannot be ascertained.

As soon as the abscess can be detected externally, it should be opened by incision, to prevent the burrowing of the pus by the sides of the trachea, or into the chest behind the sternum, a circumstance which would be almost inevitably followed by penetration of the pleura and the discharge into that cavity of a highly offensive and irritative material.

Porter states² that in all cases where the distress produced by abscess pressing on the larynx or trachea was intolerable, he made a deep incision down to the trachea, and although it often happened that he did not cut upon the matter in the first

¹ Kriegchirurgie, 1864, p. 113.

² Op. cit., p. 125.

instance, yet it always made its appearance on the following day, the abscess never failing to burst into the wound.

Discrimination is necessary in opening abscesses of the neck, especially if they are circumscribed. They are sometimes situated over large arteries, which impart to them their pulsation, so that it is rendered difficult to distinguish an abscess from an aneurism. On the other hand, an aneurism may be mistaken for an abscess. A mistake of this kind may be followed by fatal results from surgical interference. Wardrop's investigations show that aneurisms of the neck are most likely to appear in certain situations. Thus, an aneurism at the root of the carotid artery will show itself first in the small triangle between the sternal and clavicular portion of the sterno-cleido-mastoid muscle; an aneurism of the innominate artery on the tracheal side of that muscle; and an aneurism of the subclavian at the outer side. These points may be referred to in case of doubt.

TUMORS OF THE NECK.

Tumors of the neck, which occur in nearly all the varieties known to pathology, are often directly injurious, independently of their clinical malignancy, producing serious secondary affections of lungs and brain by their pressure on important vessels and nerves, and displacing or compressing the larynx, trachea, pharynx, and œsophagus mechanically by their position. They are not usually directly dangerous to life until they acquire a great bulk.

The displacement of the upper air-passage, which may occasionally take place from cervical tumor, without producing marked dyspnœa, is very great.

In a marked case of cervical tumor, ten inches in its transverse, and eleven in its longitudinal, diameter, in a young man under the care of my colleague, Dr. S. W. Gross, in Jefferson Medical College Hospital, the thyroid cartilage was displaced nearly two inches to the right of the middle line, and was four inches from the symphysis of the chin, stretching the thyro-hyoid ligament to the length of two inches, and was laterally six inches from the lower portion of the external auditory meatus. The larynx was thus thrown almost into a horizontal position, extending to the sterno-cleido muscle, whence the trachea descended in a vertical line behind the clavicle (Fig. 207). Internally the tumor occupied fully two-thirds of the pharynx, and pushed the velum so far over that the uvula was

almost in contact with the posterior fold of the palate. It reached over to the displaced epiglottis, on the extreme right, and prevented laryngoscopic inspection.

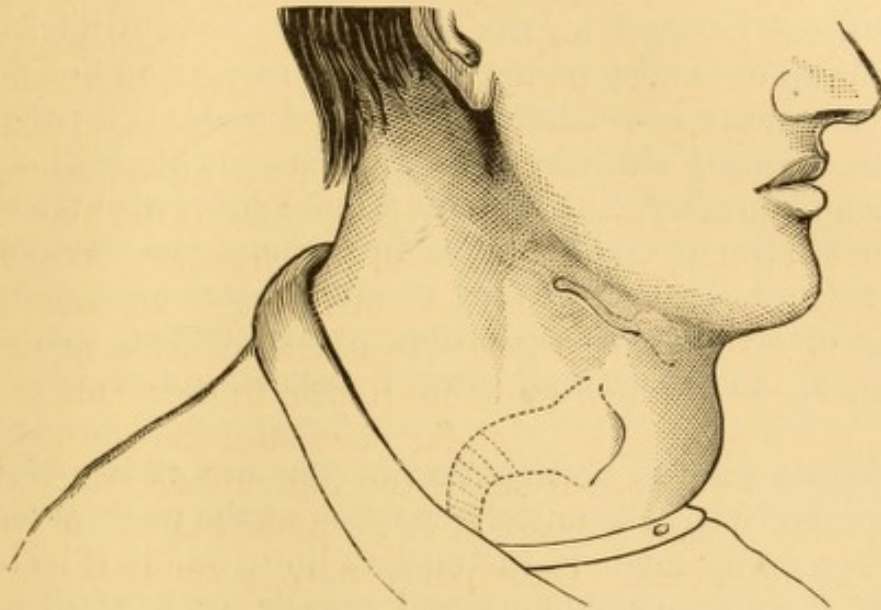


FIG. 207.—Great displacement of larynx and trachea by cervical tumor. (From a drawing by Dr. Praeger.) The solid lines represent the portions of hyoid bone and larynx visible externally; the dotted lines represent the outline of larynx and trachea, as readily detected on palpation.

tion of the interior of the larynx (Fig. 208). Otherwise than an occasional disposition to rest with his head leaning on the arm of his chair to relieve respiration, there was no evidence of dyspnoea; and there was no dysphagia.

Treatment.—In many cases it is impossible to ascertain the nature of the tumor before it has been removed, as is sometimes necessary to avert immediate danger to life. As a rule, however, tumors are not subjected to operation for the mere purpose of correcting the deformity; for it is impossible to know beforehand the nature of the attachments which may have been made, and which may implicate the carotid artery, the jugular vein, or the pneumogastric nerve.

Remedial measures are, therefore, limited to appropriate constitutional treatment, with leeching, blistering, and inunction over these tumors. Lymphomas of recent formation sometimes subside under the influence of this kind of treatment; but those of long standing, and other varieties of tumor, are not very amenable to treatment.

Electrolysis has been suggested to excite recession or absorp-

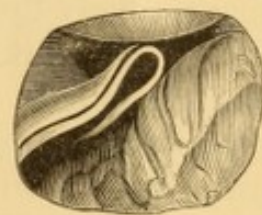

FIG. 208.—Laryngoscopic view of horizontal displacement of larynx to the extreme right, by cervical tumor.

tion of these tumors; and some cases of success are reported¹ by Mauduyt, Duchenne, Demarquay, and Meyer. In three cases of atheromatous tumor, apparently of similar nature to some of those referred to, the process was faithfully tried by myself for an extended period without success; and one case, after failure in my own hands, was placed under the care of a physician specially skilled in the applications of electricity to medicine and surgery, but without a more successful result.

Tumors in the mediastinum produce symptoms affecting the larynx, trachea, etc. Thus they produce hoarseness, aphonia, whistling or stridulous inspiration, expectoration, sometimes sanguinolent, vomiting, and, toward the last, epistaxis.

Operations for the Extirpation of Tumors of the Neck.—

If the tumor occupy the anterior portion of the neck, a vertical incision is usually made in the median line; but if it be in the region of the sterno-cleido-mastoid muscle, or beneath it, the incision is made in a line with the anterior or posterior border of that muscle, or a double incision is practised, including a space equal to the breadth of the muscle, as the case may be. It is only under unavoidable circumstances that this muscle is to be cut, and therefore the external incisions are made so as to admit of working beneath it, to facilitate which, the muscle is relaxed by bending the head to that side. If its division cannot be avoided, it should not be cut to any extent greater than is absolutely necessary. As a rule, bleeding vessels are scrupulously ligated, and careful dissection made to the sheath of tissue in which the tumor is imbedded, when an attempt is made to detach it by the fingers alone, without the aid of any cutting instrument. When closely adherent, its connections are broken down as far as may be deemed safe, and the root of the mass is encircled by a very stout double or triple ligature, so as to compress any vessels which it may contain; and the division is made in front of the ligature. If the operation present complications of hemorrhage, and the tumor is to be removed at all hazard, it should be detached from its cardiac surface first, in order to avoid the frequent ligation of vessels from the same trunk. Care must be taken to see whether the tumors

¹ Moritz Meyer: *Electricity in Practical Medicine*. Hammond's Translation. New York, 1869, p. 480.

have formed attachments with the sheath of the great vessels, lest they be incautiously wounded; and in examinations to determine this point the natural relation of parts must not be disturbed too much, else, as I have witnessed in an operation for the removal of a cystic tumor from the neck of an infant, unnecessary dangers may be encountered; in this instance the internal jugular vein was drawn out and lengthened, so as to look like the wall of the cyst, and had it not been for the prompt attention of a skilled assistant, the vein might possibly have been wounded.

It not unfrequently happens that the external carotid artery and internal jugular vein require ligation during the operation. In some of these operations it is a matter of prudence to exercise compression on the jugular vein to prevent access of air to the circulatory current, in case the vessel is wounded accidentally.

After removal of the tumor the upper portion of the external wound is united by suture, and a pledget of linen inserted in the lower portion to prevent union and permit drainage. A cold-water compress, or an oiled rag, as may be preferred, with lint to absorb the secretions, secured by bandage, completes the dressing.

Severe inflammation is liable to occur after extensive operations in the region of the great vessels of the neck; and this is to be met by the usual antiphlogistic treatment.

Death from pneumonia is not infrequent.

MUMPS.

(Parotitis Rheumatica, Polymorpha, Metastica, Epidemica; Cynanche Parotidæa.)

Mumps is the name given to a peculiar contagious or quasi-contagious inflammatory affection of the parotid gland and the surrounding connective tissue, and usually occurring but once in the same individual. It is sometimes idiopathic, sometimes deuteropathic, and sometimes epidemic. It occurs chiefly in young male adults, especially when crowded together in colleges, barracks, jails, etc., but it may affect women and children also. It seldom attacks persons over thirty years of age, yet elderly persons are sometimes subject to it. It occurs princi-

pally in spring and fall, and is supposed to be excited by cold and damp weather. The disease, whatever its nature, may be, is liable to be continued, as it were, in the testicles or the mammæ; its extension to these organs, when occurring, being part of the real progress of the disease rather than a mere metastasis. It is also occasionally propagated to the membranes of the brain, in which case the meningitis may terminate fatally.¹

Parotitis sometimes attends systemic diseases, as typhoid fever, scarlatina, variola, rubeola, cholera, and pyæmia; under which circumstance it is known as metastatic parotitis.

It sometimes attends ulcerative affections of the epiglottis and other laryngeal structures, proceeding to the formation of abscess, which requires prompt evacuation to prevent burrowing of its contents among the lax tissues of the neck. An idiopathic abscess of the parotid sometimes occurs, exceedingly painful, and exciting the nervous system. It requires prompt evacuation.

Deuteropathic parotitis occurs in severe forms of stomatitis and sore throat, facial erysipelas, cranial osteitis, and other inflammatory affections of the throat, neck, and face. It likewise occurs in the convalescence from severe continued fevers and the exanthemata. Sometimes it is produced by salivary calculi.

Symptoms.—The first symptom of the affection is usually pain and stiffness at the angle of the jaws, followed by marked tumefaction behind and below the ears, sometimes on one side only, more frequently upon both. It may extend forward on the cheek, and downward below the ramus of the lower jaw. Deglutition becomes painful, and there is difficulty or inability to open the mouth. The saliva may be increased or diminished. Dryness of the throat, with soreness, is often complained of, and earache also not unfrequently. There is more or less fever, anorexia, and so on, for two or three days, when they gradually decline. If the affection has been unilateral, the parotid on the other side often becomes involved in turn. Very often, as the fever declines, the swelling over the parotid region subsides, and is followed by swelling of the testicles in the male, or of the mammæ in the female, one or both glands being affected. There are sometimes symptoms of a similar

¹ London Med. Gaz., 1851, p. 651.

transference of the morbid influence to internal organs. Sometimes it takes place to the brain, threatening collapse, meningitis, or even mania; and this cerebral disturbance sometimes terminates fatally. The parotid gland rarely suppurates; but the affection is said to terminate in this manner occasionally.

Treatment.—The treatment of mumps is mildly or actively antiphlogistic, according to the vigor of the patient and the character of the case. Good results follow the hot-air or sweat bath, given in the patient's room by means of burning alcohol beneath a chair upon which the patient sits enveloped in a blanket. Warm applications are kept to the inflamed part, such as wads of soft cotton, wrung out of boiling water, and then placed in a bag of oiled silk. Cold applications are to be avoided, lest they repel the disease to the testicle. A gentle saline cathartic is sometimes indicated, but active treatment is not often required. Involvement of the testicle is treated by warm fomentations, with confinement in bed, if the patient has been permitted to sit up.

If the brain becomes involved, stimulants will be called for in a state of collapse; the lancet, cold to the head, purgatives, and counter-irritants at a distance, in mania.

Permanent injury to the gland, or to the constitution, sometimes follows this affection. Blistering, and inunctions of mercurial and iodized ointments, are recommended for the enlarged gland, and tonic and alterant remedies for the constitution.

A swelling of the lymphatic glands in the region of the parotid, and sometimes, perhaps, of the parotid itself, occurs not unfrequently in connection with abscess of the pharynx, as already mentioned; and pharyngeal abscess may therefore be mistaken for mumps. A similar condition sometimes occurs in connection with adynamic pneumonitis.

BURSAL TUMORS OF THE THYRO-HYOID REGION.

(Thyroid Cysts; Hygromata.)

There are three bursæ in the thyro-hyoid region, which occasionally undergo transformation into cystic tumors. One of these, the ante-thyroid bursa, exists in front of the thyroid car-

tilage. It is subcutaneous. Another, the infra-hyoid bursa, occurs below the hyoid bone. It is occasionally multiple. The third one, the supra-hyoid bursa, which appears to be an abnormal bursa, only occasionally present,¹ is found in the structure of the root of the tongue. It is situated on the upper border of the hyoid bone, between the posterior insertions of the genio-hyoid and genio-glossal muscles. These bursæ are liable to inflammation, serous and viscid accumulations, and the diseases of bursæ generally; the infra-hyoid bursa being affected the most frequently, and the supra-hyoid bursa the least frequently.

Cysts of these bursæ, technically known as hygromata, are developed not unfrequently, and may attain sufficient size to interfere with deglutition, articulation, and respiration, according to their position in the mouth or pharynx. Spontaneous absorption occasionally takes place, but this is too infrequent to depend on. When large enough to interfere with function, a surgical operation is required. The affection is of slow progression; and is supposed to originate from mechanical irritation of the bursa. The *diagnosis* of such cysts rests on their seat, and the result of puncture with the exploring needle. Their contents do not differ from those of other cysts, save that they do not contain any epithelial elements, the presence of which is indicative of glandular origin, and, therefore, when present, referable to the thyroid gland. The *prognosis* is favorable, if submitted to early operation. If not, the cyst may attain considerable bulk, rendering operative procedures much more serious.

Treatment.—Incision, excision, and extirpation of these cysts have been practised; the first two operations are not often successful; and extirpation, complete or partial, seems to be almost inevitably followed by a fistule, which is hard of cure. Puncture, and the injection of iodine after discharge of the cyst, seems to offer the best chance of success. Troublesome fistules are apt to remain after the discharge of one of these cysts. For further details, and the records of a number of interesting cases, the reader is referred to the classical work of Guerlt.²

¹ For interesting case involving this bursa see Wagner: Ohio Med. and Surg. Jour., 1877.

² Ueber die Cystengeschwülste des Halses, Berlin, 1855.

AFFECTIONS OF THE THYROID GLAND.

INFLAMMATION OF THE THYROID GLAND.

(Acute Bronchocele ; Thyroiditis ; Thyro-adenitis.)

Acute inflammation of the thyroid gland is rare, and may be idiopathic, deuteropathic, or traumatic. It sometimes takes place in the normal gland, but is more frequent in the hypertrophied or diseased gland.¹ It occurs in both sexes, and in the female perhaps oftener during pregnancy. The entire gland may be involved, or one lobe only. The development may be confined to the anterior mediastinum.² Idiopathic thyroiditis is sometimes the result of direct exposure, as in a male subject under my own care, in whom it followed prolonged exposure to inclement weather during a number of hours with insufficiency of clothing and nourishment; but in some cases the exciting cause is not apparent. It may be associated with pharyngitis, laryngitis, and œdema of the larynx. Deuteropathic thyroiditis has been observed in chronic interstitial nephritis, typhoid fever, pyæmia, and in puerperal conditions. Traumatic thyroiditis may follow injury to the gland from wounds, or violent blows, or compression. Thyroiditis may terminate in resolution, or in suppuration and abscess, with partial or complete destruction of glandular tissue,³ and of the surrounding planes of connective tissue; and the purulent products may become discharged externally with recovery, or descend into the mediastinum or into the sac of the pleura. The tumefaction may be so great as to suffocate the patient by direct pressure upon the trachea, or by irremediable dyspnoea from compression or irritation of the pneumogastric nerves. When it extends posteriorly, deglutition may be rendered impossible, and starvation ensue. The purulent products may escape by rupture anteriorly, or by perforation into the œsophagus, trachea, or larynx, suffocation being sometimes rapid in the latter instances; or

¹ For recent example see Verneuil: *La France méd.*, 1876, No. 66; *London Med. Record*, Nov. 15, 1876, p. 496.

² For example see Bennet: *On Intra-thoracic Growths*, London, 1872, p. 167.

³ Gascoyen: *Brit. Med. Times; Lancet*, Feb. 12, 1876, mentions a case of sphacelus of the gland, with rapid recovery, in a case of acute idiopathic inflammation of the neck, in which there was no discomfort from loss of the gland. Lebert is referred to as instancing seven cases.

the system may become simply exhausted by suppuration, and necrotic destruction of the tissues.

Symptoms.—Idiopathic thyroiditis usually begins with more or less intense fever, and prompt swelling of the gland, which becomes painful to manipulation. According to the amount of tumefaction, and its position, there will be dyspnœa, often intense, and sometimes spasmodic and paroxysmal, dysphagia, cyanosis, headache, tinnitus, vertigo, and delirium; these symptoms varying in constancy with the diminution and augmentation of the tumefaction. Sore throat, pharyngitis and laryngitis are indicated by their special symptoms. Hæmoptysis, from congestion of the larynx and trachea, may be the earliest symptom.¹ Suppuration may be indicated by the usual chill, and abscess by increased pain and febrile manifestations, with fluctuation, if near the surface. The various accidents from great swelling, suppuration, or perforation, are indicated by the usual phenomena.

Diagnosis.—This rests on the presence of a tumor moving with the larynx on deglutition, or with immobility of the larynx if bound down by inflammatory products; the group of symptoms described; and the history of the case. The overlying integument is often inflamed. The formation of abscess, when anterior, is recognized by fluctuation, with injection of the integument, or subcutaneous œdema. The disease may be difficult to discriminate from diffuse phlegmonous inflammation of the connective tissue of the neck.

Prognosis.—In cases of moderate enlargement, and in inflammation of the normal gland, the prognosis may be regarded as fairly favorable, and termination by resolution be anticipated. It is less favorable if the gland be enlarged or diseased; though resolution takes place in the hypertrophied gland also. In excessive enlargement it is unfavorable in view of the probability of suffocation, which cannot be relieved by tracheotomy. After suppuration has taken place it depends upon the direction taken by the pus; and when abscess has formed, upon its position and the possibility of its evacuation.

Treatment.—Antiphlogistics, febrifuges, and mercurials internally, leeches, and iced cloths, and mercurial inunctions externally, constitute the sum of treatment in the earlier stages,

¹ Verneuil's case, *supra*.

with such general indications as each case may suggest. Threatened asphyxia may be prevented, in some instances, by laryngotomy or tracheotomy, and the introduction of a long, flexible tube beyond the point of obstruction. Some cases of recovery through tracheotomy are on record,¹ but in most cases it is unavailing.²

GOITRE.

(Ordinary Bronchocele, Hypertrophy of the Thyroid Gland, Struma, Chronic Enlargement of the Thyroid Body.)

The most frequent affections of the thyroid gland are hypertrophy, and the development of cystomata in its interior or externally. They occur much more frequently in females than in males, possibly on account of a sympathetic relation between the gland and the uterus. In some women the thyroid gland often swells during menstruation to a perceptible degree, though it may be slight, and a similar effect sometimes follows impregnation; and in olden times the size of the neck was even regarded as one of the tests of virginity. Certain forms of hypertrophy increase during each successive pregnancy or lactation (the goitre of pregnancy), and retain the acquired enlargement. Sometimes the enlargement is so immense as to prove fatal.³

Chronic enlargement of the thyroid gland frequently exists endemically, especially in the valleys of mountainous districts, being so universal in some localities that immunity is regarded by natives as a species of deformity, or an arrest of development. Strangers remaining for any length of time in these regions sometimes acquire goitre, which usually disappears spontaneously on removal from the locality, though occasionally permanent. This has been noticed not unfrequently in the troops of Continental armies when sent into regions where goitre prevails;⁴ the infantry, whose respiratory organs are impeded in action by the weight of their knapsacks, suffering

¹ For recent example, see Cairn : *The Lancet*, Jan. 29, 1876, p. 171.

² See table in article by Roberts : *Acute Bronchocele with Cardiac Hypertrophy*, etc. *Am. Jour. Med. Sci.*, Oct., 1876.

³ For examples, see Guillot : *Arch. gén. méd.*, Nov., 1860 ; Roberts : *Loc. cit.*

⁴ For recent examples, see Michaud : 280 Cases in the Garrison of St. Etienne ; *Gaz. méd.*, Paris, Jan. 10, Feb. 7, 1874 ; *Med. Times and Gaz.*, Feb. 21, 1874.

more than other branches of service, in which the respiratory organs are less taxed. According to H. Larrey it is due to the constriction of the collar and stock, to which recruits are unaccustomed. Indeed, it is not improbable that the custom of carrying loads upon the back, as practised by the peasantry in the mountainous districts of Switzerland and Bohemia, and other parts of Europe, impeding the circulation in the great vessels of the neck, especially during the tedious ascent of elevations, has some influence in developing the prevalence of goitre in those regions. Increase of the proportionate number of white cells in the blood has been noticed in cases of goitre. Exertion of various kinds, chilling of the exposed throat, and similar causes, seem to favor the development of goitre; but the real cause is not well understood, even where it exists endemically.

In certain valleys of the Alps goitre is associated with a condition approaching to idiocy, and known as cretinism. Some comparatively recent observations have led to detection of a great difference in the temperature of the two sides of the valleys in which the cretins reside, this temperature being subject to certain considerable fluctuations; and it is believed that its influence on the circulatory system may have a great deal to do with the development of goitre.

Goitre may be present as a congenital affection, but more frequently makes its appearance about the period of puberty or early adolescence. Sometimes it occurs in several members of the same family, in consequence, at times, of hereditary proclivity. The size of the tumor may vary from but slight enlargement to the bulk of an adult head. When very large it usually drags the skin of the neck down, and may project a great distance over the chest and abdomen.¹ The enlargement may be altogether in front, or it may extend beneath the sternocleido-mastoid muscles, or behind the sternum. In the latter cases there is a good deal of pressure exercised upon the tra-

¹ Dr. Perassi, of Turin, operated, in 1864, upon an enormous goitre, of fifteen years' growth, which hung down nearly as far as the umbilicus, in a man forty-six years of age. The mass being exposed close to the neck, it was included in a series of partial ligatures and cut off in front of them, the portion removed weighing 5,550 grammes (about 12 lbs. 4 oz.). The patient left the hospital cured at the end of a month. (*Giorn. della R. Acad.*, May, 1878.) *London Med. Record*, Oct. 15, 1878, p. 439. It has been stated that these tumors have been known to acquire the weight of fifty pounds.

chea, giving rise to distressing dyspnœa, resembling that of asthma, and productive, ultimately, of pulmonary emphysema. Sudden death by asphyxia sometimes occurs,¹ not unfrequently due, according to Rose,² to sudden bending of the flaccid trachea, the cartilages of which have undergone softening and fatty degeneration from pressure. In post-sternal goitre the trachea is compressed into the form of a prismatic cylinder, or an elongated oval, the larger diameter of which may be in the lateral or in the antero-posterior direction. The enlargement is usually very slow, consuming many months or years in its progress. Sometimes it is fatal within a few months. Sometimes the affection remains stationary for a number of years, and then undergoes gradual or rapid increase in size. As a rule, there is no pain in the tumor, the suffering being due to pressure upon the windpipe and the large vessels and nerves, finally culminating in attacks of suffocation, spasmodic cough, inability to maintain the recumbent posture, and assumption of peculiar positions to facilitate breathing. The exhausting efforts at respiration and the impeded state of the venous system are liable to produce œdema of the larynx, lungs, trunk, and limbs.

The goitre may affect both lobes or one only; it may be confined to the isthmus, or to a third or occasional supplementary lobe; or it may involve one lateral lobe, and either the isthmus or the supplementary lobe.

The contents of the tumor may remain constant or vary at different stages. At first, when soft and elastic to the touch, and without extensive attachments, it is probably a mere hypertrophy or hyperplasia (simple or glandular goitre), often amenable to treatment. Irregularities or nodosities presenting upon its surface after a while, are usually indicative of some metamorphosis, rendering the prognosis much more doubtful. The changes noticed are inflammation, transformation of cells into cysts (cystic goitre), and colloid, fibrous, sarcomatous, and carcinomatous degeneration, the latter chiefly medullary. Fibroid and cystic degenerations often coexist. Inflammation is indicated by increased heat and greater firmness to the touch.

¹ For recent case of cystic goitre, with autopsy, see Johnson: Brit. Med. Jour., Oct. 27, 1877, p. 591.

² Der Kropftod und die Radicalcur der Kröpfe. Berlin, 1878.

This inflammation is sometimes salutary, and leads to a spontaneous dissolution of the tumor, as is sometimes seen in cutaneous erysipelas.¹ Knowledge of this fact has suggested treatment by artificial induction of inflammation. When resolution does not occur, the inflammatory process may terminate in abscess, or in the formation of permanent fibrinous deposits (fibrous goitre); or it may extend to the larynx and trachea, and endanger a fatal result by suffocation from direct compression, perforation and discharge of abscess, or by pyæmia. The fibrinous deposits of the inflammatory process may subsequently undergo fatty, amyloid, calcareous, or osseous degeneration.

The formation of cysts is favored by the anatomical construction of the gland, the cells of which become distended by an accumulation of their natural contents, the cell originally affected enlarging at the expense of its neighbors, and the remaining glandular structure undergoing atrophy from pressure. Usually one or a few cysts enlarge in this way to a great size, but sometimes numerous cysts enlarge to sizes varying from that of peas to that of plums. In this way the encysted variety of goitre is produced, a form recognized usually by fluctuation, or by inspection of its contents upon the groove of the exploring needle.

When the cysts are small their contents are viscid, but when large they contain serum, or serum and blood, or coagulated blood, or the detritus of fibrous tissue. The cysts are usually complete, but sometimes portions of their walls are composed of the gland tissue itself. Cystic goitres may attain great size, and have been known to contain more than a pint of fluid. In one case, subsequently successfully excised for me by Dr. Packard, of Philadelphia, I withdrew much more than a pint of brown, grumous fluid. Large cysts are not apt to undergo degeneration, but the walls of the smaller ones sometimes become calcified.

A peculiar form of cystic goitre in which new glandular tissue, exactly analogous to the embryonic tissue of the thyroid gland, becomes developed in the cavity of the cyst, has been

¹ Spontaneous cure by abscess and rupture externally, following an attack of typhoid fever, has been recently recorded by Dr. Starr. *Phil. Med. Times*, April 27, 1878, p. 345.

described by Prof. Stromeyer as parenchymatous cystic goitre. This tissue is very vascular and very gelatinous, so that it can be scooped out with the finger. It presents a deceptive sense of fluctuation when examined externally, and in this way may be readily mistaken for the ordinary cystic goitre with fluid contents. Its diagnosis, it is said, cannot be always ascertained with certainty, except during the course of an operation.

Hydatid cysts are an occasional occurrence. They have been known to empty into the larynx by perforation, and be discharged by cough.

Exophthalmic Goitre.—A peculiar variety of goitre, termed exophthalmic, is attended by abnormal prominence of the eyeballs, sometimes amounting to protrusion, and sometimes due to an accumulation of fatty products behind the eyeball, or to serous infiltration of the connective tissue of the orbit. It is also accompanied with dilatation and palpitation of the heart, the impulses of which are more than one hundred in a minute; and sometimes exceed this by twenty beats, and even more (forty), under the influence of emotion and physical exercise. There is often a systolic bellows murmur from functional valvular derangement of the left side. It is sometimes an accompaniment of anæmia, but exists with plethora also, and, though occurring occasionally in males and in children, is encountered almost exclusively in young adult females. Though recognized as a special affection by Flajani, of Rome, it was first properly described by Professor Graves, of Dublin, after whom it is known as Graves' disease; and likewise by Basedow, in compliment to whom it is known also as Basedow's disease. The entire thyroid gland swells into an easily compressible tumor, of large size usually, and there is a systolic thrill of the superior thyroid artery, very sensible on delicate manipulation of the tumor. The pulsation is often perceptible to the patient, and is attended with throbbing of the carotids and with a hammering or singing noise in the ears. These symptoms are less manifest in the recumbent position. The eyes are usually in constant motion; and their protrusion, in marked cases, is so great as to prevent closure of the lids, even in sleep. Inflammation of the cornea sometimes supervenes in consequence of its constant exposure. Sometimes there is paresis of the upper lid. Sometimes there is strabismus. The sight suffers.

Diarrhœa and profuse diaphoresis are not uncommon phenomena. There is often great nervous irritability, sometimes mania. Falling of the hair of the eyebrows and eyelashes and of other portions of the body has been observed. The nutrition of the system is impaired, and the patient sometimes dies, after the lapse of several years, from marasmus.

Though most frequently bilateral, exophthalmic goitre is sometimes unilateral, and has even been observed, with the enlargement of the gland and of the eyeball, on the opposite sides of the body.¹

The cause is obscure. It is often attributed to mental emotion, nervous shock, phthisis, exhausting disease, and tardy convalescence, as is the general opinion, or to a central neurosis propagated along the sympathetic. Dr. Graves regarded it as a neurosis of the sympathetic. The sweating is due to the neurotic paresis of the cutaneous vessels; and the falling of the hair may be similarly accounted for. Professor Stromeyer² considers the exophthalmus an additional evidence of nervous origin, from having observed a similar condition, independent of disease of the thyroid gland, in the habitual spasm of the sterno-cleido-mastoid muscle; in which, however, the protrusion of the eyeball is confined to the side of the muscle affected, occurring only when its contractions are excited by an erect position of the head, or under the influence of emotion. This habitual spasm of the sterno-cleido-mastoid muscle, as Stromeyer says, is considered by every one as a neurosis; and the fleeting exophthalmus, which exists in connection with it, appears to him to be dependent upon spasm of the oblique muscle of the eyeball and of the levator palpebræ.

Symptoms.—These are various grades of dyspnœa, dysphagia, dysphonia, palpitation of the heart, cough, œdema of the larynx, neck, face, and upper limbs, cyanosis, headache, tinnitus, nausea, vertigo, syncope, delirium, mania. The dyspnœa may be paralytic, asthmatic, spasmodic, paroxysmal, or suffocative, according to the character of the pressure on the air-tube, vessels, or nerves. The cerebral symptoms occur at a later date, and augment with the increasing size and pressure of the tumor. Should it get so large as to hang over by its weight,

¹ Yeo: Brit. Med. Jour., March 17, 1877, p. 321.

² Op. cit., p. 389.

and thus release the contiguous structures from direct pressure, the severity of many of these symptoms abate. There is no pain in the tumor, as a rule, though pressure on nerve-tracts may produce thoracic, cervical, facial, and frontal neuralgia as the tumor enlarges. There is also more or less mechanical impediment to the movements of the neck, and finally inability to sleep or breathe in the recumbent position, or with the head in any position that favors pressure on the trachea.

Diagnosis.—This will depend on the labored respiration and other attendant symptoms, and on the presence of a tumor externally, and moving with the larynx. Lateral and sub-sternal or post-sternal enlargements may be detected laryngoscopically by the inversion of the walls of the trachea. Paralysis of the vocal cord from pressure on the nerve-trunk can also be recognized. Paroxysmal dyspnœa is often seen to be altogether independent of direct compression of the air-tube. The glottis is abnormally dilated, and yields but slightly to the usual movements of approximation in the expiratory phase of respiration. Cysts are detected by the sense of fluctuation, and sometimes by globular protrusion. Echinococci cannot be distinguished from other cysts. Carcinoma of the thyroid gland is distinguished from goitre by its rapid development and the involvement of the neighboring lymphatic glands.

Prognosis.—The prognosis is favorable in recent enlargement of soft consistence, tolerably favorable in fibroid and cystic degenerations of moderate size, and unfavorable in those sub-sternal and other forms which exert compression upon important structures, in those which have contracted extensive adhesions, and in those which have produced degenerative atrophy and disappearance of the cartilaginous rings of the trachea. Danger from the latter sources may be dependent on shrinkage of the tumor and consequent loss of support for the thinned tracheal rings. It is rarely that the size of the gland recedes to its normal volume, even in favorable cases. In the unfavorable cases, death may take place by asphyxia from compression, or from sudden flexure of the flaccid trachea, or by gradual apnœa from external stenosis, or by exhaustion.

Treatment.—This is both constitutional and local. It is only in recent cases, and in those of comparatively small size, that purely medical treatment offers a fair prospect of success.

Various operations are in vogue for the destruction or re-

moval of a goitrous tumor. Although often successful, they are not to be undertaken without careful consideration. Attendant risks of some moment are imminent from the vascular condition of the gland itself, the nature and extent of its attachments, which may involve the large vessels and nerves of the neck, and from pneumonic and cerebral complications during the after-treatment. Cases of death are sometimes directly produced by operations upon the thyroid gland, and may occur on the operating-table. Sudden death during operation, before operation, or during preliminary administration of an anæsthetic, has been shown to be sometimes due¹ to sudden flexion of the flaccid trachea from change of position of the tumor, or loss of control of the proper relative position of head, neck, and chest for respiration. The majority of surgeons, therefore, approach these operations unwillingly, and some, in high estimation, condemn them unhesitatingly.

When goitre is due to locality of residence, removal is indicated as the first step toward relief.

The liberal use of iodide of potassium, internally and externally, is often effective in uncomplicated cases of soft consistence, even when of considerable size. Its internal administration may require temporary suspension, should it impair the general health. This disturbance of the general health is not entirely due to the remedy, but in great measure to the rapid absorption of the constituents of the tumor diminishing under its influence. Coexisting catarrhal inflammation of the larynx and trachea require appropriate management before resorting to specific treatment for the goitre itself, inasmuch as the constant movement of the gland in the acts of coughing is unfavorable to its retrogression. The chloride of ammonium is indicated here, both for its favorable influence upon inflammatory conditions of the air-passages, and for its value in promoting absorption of hypertrophied tissue. Various other remedies have been recommended in the treatment of goitre, most of them selected empirically; but they do not appear to have given as much general satisfaction as iodide of potassium, or chloride of ammonium. Locally, tincture of iodine or compound tincture may be painted once or twice a day, of officinal strength, or diluted with ether, glycerine, or alcohol. Inunc-

¹ Rose : *Op. cit.*

tion of ointments of iodine, or of iodide of mercury in dilution, are sometimes preferable to the paints or lotions.

When medicinal treatment fails, electricity sometimes offers a fair prospect of success. Numbers of cases are on record of successful electric and electrolytic treatment.

In a case of several years' standing, and of large size, involving both lobes to an unequal degree, in a young man who had undergone the iodic and other medicinal treatment, under competent care for three or four years, electrolytic treatment with the negative pole inserted by a needle electrode into the substance of the tumor, with the positive pole applied outside by means of a large sponge, caused the absorption of this tumor in a few weeks; but five applications being necessary for the purpose. Four Bunsen cells, containing a gallon of very weak solution each, were used in this case, and the current was passed from five to ten minutes at a time. More than six years subsequently this patient applied to me for another ailment, and the cure had been permanent.

A young lady, some seventeen years of age, had a goitre of very moderate size and of soft consistence, which began to appear some two or three years before, while visiting in Switzerland. In this instance, fifteen small Smee cells were used; ten applications being required for the complete disappearance of the tumor, the applications being made twice a week and for about ten minutes at a time. In neither instance was the pain great; so that anæsthesia was not requisite.

In a case of immense cystic goitre, some little favorable result followed a protracted treatment of some twenty applications from a Smee's battery of from ten to twenty, and, on one or two occasions, thirty small cells; the number being increased during the application according to the effects upon the patient. Circumstances over which I had no control prevented the continuance of the treatment, and the patient ultimately perished.

In another instance, a patient with a goitre the size of a large orange was being treated locally with the induced current for paralysis of one vocal cord, possibly due to pressure on the recurrent nerve. During this treatment, the goitre diminished considerably in size, and finally disappeared, though the lady had been encumbered with it for ten or twelve years.

There was always a gaseous swelling produced at the seat of the puncture, from the development of hydrogen gas; the tissues around for a considerable distance became very red, and presented a bruised or black and blue appearance, as from a blow of the fist, for a day or two after; and a little eschar was formed at the point of the puncture. Occasionally a drop or two of blood followed the withdrawal of the needle; but this was exceptional. On several occasions vertigo, and on one occasion syncope, was produced by the application. No internal treatment whatever was employed during the treatment of these cases. The young girl wore a bag of small shot upon the tumor for several hours every day, to favor absorption by equable compression.

Dr. Althaus¹ expresses the belief that all cases of broncho-

¹ Medical Electricity, London and Philadelphia, 1870, p. 643.

cele, however large, may be cured by electrolysis, if the treatment be persevered in for a sufficient time ; the cystic variety being much more rapidly curable with it than the solid.

Percutaneous applications of the electric current over the cervical portion of the sympathetic, first employed by Dusch, have often been resorted to in exophthalmic goitre. Drs. Eulenberg and Guttman¹ have seen this treatment ameliorate the cardiac symptoms without diminishing the goitre or the exophthalmos, under the influence of a constant ascending current from six or eight elements. They report that Chvostek nearly effected a cure in this way in thirteen cases. Dr. Moritz Meyer reports four in which the tumor was almost entirely reduced.

When a goitrous tumor is not amenable to remedial influence, all that can be done is to maintain as good general health as possible, avoiding all exertion which, by inviting blood to the part, would facilitate its further enlargement or favor compression of the vessels of the neck. If the tumor enlarges beneath the sterno-cleido-mastoid or other muscles, and is thereby pressed injuriously upon the trachea and œsophagus, the tension may sometimes be relieved by subcutaneous division of these muscles, or by incisions into the cervical fascia.

In post-sternal goitre, pressing upon the windpipe, it has been recommended that efforts be made to raise the tumor from its bed and attach it to the integuments above, so as to relieve the pressure upon the parts. This has been done by means of a ligature passed through the tumor, by which it is kept directly under the skin at the upper portion of the neck, and then adhesive inflammation is induced, by the formation of an eschar in the integument by means of the Vienna paste or some other caustic.

When the dyspnœa is very great, relief can sometimes be afforded by tracheotomy, provided the compression exist at the upper portion of the trachea, a point which can be determined in some cases by laryngoscopic inspection, as well as by external manipulation of the growth. The insertion of a long tube is necessary in these cases, in order to pass beyond the point of obstruction. In the absence of a long tracheotomy-tube, a perforated catheter or a section of rubber tubing may

¹ Die Pathologie des Sympatheticus, 1873.

be substituted.¹ Pressure upon the nervous trunks will give rise to dyspnœa, giddiness, and other symptoms produced by direct pressure upon the windpipe and blood-vessels; and under such circumstances tracheotomy would be useless.

Hypodermic injections of ergotine have been practised successfully, and although the injection may be inserted at the larger side, the smaller side may be the first to diminish.² Injections have been made into the tumor with success. They are not invariably harmless. In one instance which came to my knowledge death ensued suddenly shortly after such an injection, although a number of previous injections had not been followed by any untoward symptom.

Cystic goitres are evacuated by puncture with trocar, and then injected with alcohol, carbolic acid, tincture of iodine, or tincture of choride of iron, retained by plugging the canula for a number of minutes or hours to excite inflammation. Mackenzie retains from two to eight fluid drachms of the solution of iron in the cyst for seventy-two hours. Evacuation by slow drainage is also practised. These procedures have been occasionally followed by fatal septicemia.

Blisters and other methods of exciting cutaneous inflammation over the goitre, or injections to excite inflammation in its substance, may be employed to imitate nature in some of her demonstrations of spontaneous cure.

Fibrous goitres are sometimes treated by direct injections of ergotine, carbolic acid, tincture of iodine, and tincture of chloride of iron, into their substance. Caustic darts are recommended by Mackenzie.

I have heard of fatal results following these injections so shortly as to be attributable to the operation. In one instance the tumor had been injected several times with impunity, yet the patient died in the carriage in which she was being transported as usual to her residence.

The surgical operations resorted to for the cure or removal of a goitrous tumor have usually been performed more for relief of the dangerous symptoms than on account of the deformity. Cases in which no immediate danger threatens life usually offer the best prospect of success in operating. It is

¹ See Bennet: *On Intrathoracic Growths*, London, 1872, p. 167; *The Lancet*, Jan. 29, 1876, p. 171.

² Coghill: *The Lancet*, Aug. 14, 1877, p. 158.

doubtful whether a severe operation be justifiable for mere relief of a deformity. Halting between these two opinions, surgeons are apt to let the goitre alone.

Radical operations are adapted to the cystic form of goitre rather than the fibrous.

Ligation of the base of the gland is sometimes practised, usually after due exposure of the tumor by incision through the integument and careful dissection; but occasionally the subcutaneous ligature has been employed. The ligature is tightened from day to day until there is evidence of the death of the tumor, when it is removed in front of the ligature, or cut off by tightening the ligature still further.

Incision is practised by dividing two inches or more of the integument in the middle line, if the tumor is in front; or in front of the sterno-cleido-mastoid or behind it, if the tumor is lateral. The parts being freely exposed by careful dissection, every vessel being tied as soon as wounded, before the cyst is opened, a puncture is made into the cyst, and its contents allowed to drain off slowly. Then the opening in the cyst is enlarged to the extent of an inch or more, or to that of the external wound, and the edges are kept separated by a strip of oiled lint. Suppuration occurs as a result of the inflammation excited, and its products escape readily by the external opening.

Excision consists in making the incision through the integuments, as above, and incising the cyst to get rid of its contents; after which its edges are excised to greater or less extent. This operation is more serious than incision, and much more liable to hemorrhage at the time, and to serious consequences subsequently.

The introduction of a seton, either through skin and tumor, or through the tumor only, after division of the skin, has been practised with success; but the treatment is very protracted, and not devoid of the unpleasant results that follow the other operations. Where the seton is thrust through the skin, it is recommended that it be a silken thread passed by means of a large needle instead of a regular seton lancet, as presenting less danger of hemorrhage. Additional threads may be introduced as the case progresses.

Dr. Llewelyn Thomas has several times seen extreme dyspnoea relieved within a few hours of the introduction of a large

seton of two or more threads. He recommends that the seton should be a very large one, introduced very far back, and very deeply.¹

Ligation of the thyroid arteries has been resorted to. These arteries sometimes acquire a bulk equal to that of the carotids, and it has been thought that starvation of the tumor, by their ligation, would deprive it of nutriment and thus induce absorption. This method has been successful in some instances, but in others a good result has been thwarted by the prompt establishment of the collateral circulation.

Extirpation of the tumor by the knife is sometimes employed, and has often been practised with success, though the operation is condemned as a rule. Small tumors with but few attachments are removed readily enough, but large ones with extensive attachments present many difficulties. Operations of this kind should be performed slowly and cautiously, with due use of the fingers and knife-handle, and nothing important should be cut until after it has been secured by ligature. After the exposure of the growth its detachment should be approached from behind forward. In this way large tumors have been successfully removed with comparatively little hemorrhage, as I have witnessed under the hands of Prof. Pancoast, and Drs. Maury² and Packard, of Philadelphia. The names of several American surgeons, especially those of the two Warrens, of Boston, are favorably known in connection with this operation.

Rose³ cautions against allowing any change of position during anæsthesia from that assumed by the patient as most comfortable for respiration, for fear of sudden death from flexion of the air-tube. He then counsels tracheotomy at the softest and narrowest point of the trachea, always to be found above. This done, he proceeds to the extirpation, splitting the gland from below upward, between the two lobes, whether in the middle line of the body or not, and then extirpates the whole gland. A long canula is then inserted into the trachea, and retained until the soft portions of the anterior wall of the trachea have become firm.

¹ The Lancet, Dec. 22, 1877, p. 926.

² For notes of this case, see Photographical Review of Medicine and Surgery, Phila., Dec., 1871.

³ Op. cit.

AFFECTIONS OF THE THYMUS GLAND.

Affections of the thymus gland are not frequent. The number of lobes of the gland is sometimes greater than usual, and there has occasionally been noticed marked diminution in the size of the gland, atrophy, or even its entire absence. Occasionally it persists into adult life.¹ Tumors, too, are sometimes developed in its substance.

Thymitis.—Inflammation of the thymus gland has been occasionally met with and recognized. There is reason to believe that it sometimes occurs unrecognized, for cases of unaccounted-for death have been found, on dissection, to have been due to purulent inflammation of this gland. Acute purulent inflammation has been attributed to suppuration of masses of tubercles in chronic tuberculosis. That acute thymitis does occur there is sufficient evidence, though few cases have been recorded.

Dr. Allan Burns² mentions a case of abscess of the thymus gland, with discharge of its contents externally. An ulcer formed externally, from which the patient drew out from between the laminae of the mediastinum a portion of lymphatic substance about three inches in length. A very curious physico-physiological fact is mentioned in connection with this case, and which has some bearing upon the mechanism of the respiration. When cicatrization of the wound was completed, it was found that the trachea, the innominate artery, and the thyroid branch of the lower thyroid artery, were covered merely by a thin pellicle of skin, a covering insufficient to prevent the external pressure of the air upon the trachea, and producing a permanent difficulty in breathing, from sinking in of the trachea above the sternum at each deep inspiration.

A case of distinct thymitis is mentioned by Dr. Chas. A. Lee³ as having occurred in his own practice, and in which the gland suppurated and discharged externally; and a case of acute inflammation, without characteristic manifestation, is reported by von Wittich.⁴

¹ For recent example, see Brigidi (Comm. clin. Pisa; Jour. méd. et chir. prat., April, 1877): London Medical Record, July 15, 1877, p. 273.

² On the Surgical Anatomy of the Head and Neck, Second Edit., Glasgow, 1824, p. 26.

³ On the Thymus Gland; its Morbid Affections, and the Diseases which arise from its Abnormal Enlargement. Amer. Jour. Med. Sci., Jan., 1842, p. 140.

⁴ Hypertrophie und theilweise Vereiterung der Thymusdrüse, Virchow's Arch., 1855, VIII., 4.

Syphilitic thymitis, or something very like it, has been described by Dubois, Depaul, and Wedl, with semi-solid or fluid collections of diffuent matters scattered through the interior of the gland.¹

Hypertrophy of the Thymus Gland.—The thymus gland occasionally undergoes hypertrophy ; but its normal size varies between such limits that the diagnosis of enlargement is sometimes erroneous. Fatal results sometimes ensue from these enlargements. The condition is usually indicated by hoarseness and stridulous respiration, with occasional or paroxysmal augmentation in severity. The treatment usually adopted includes the use of alterants and absorbents, as in hypertrophied gland-tissues generally. The subject of hypertrophy of the thymus gland strongly attracted the attention of the profession in the earlier part of the present century. It was believed by many to be the chief cause of the laryngismus stridulus of infants, from pressure of the enlarged gland upon the pneumogastric nerve, or on the recurrent laryngeal, or from pressure upon the trachea, or on the great vessels. The affection was termed thymic asthma, and was also known as Kopp's asthma, in compliment to the man who most enthusiastically developed the idea then prevalent of the pathology of the affection. Subsequent experience proved that the premises were false on which these conclusions were based. It was found that many children perished of thymic asthma, without any post-mortem evidence of enlargement of the gland ; that in some of the fatal cases the gland was actually atrophied, or at least smaller than is usual ; and that a few rare but undoubted cases of enlargement were not productive of the asthmatic phenomena. These demonstrations, and the fact that the pressure from a tumor ought to induce constant disturbances of respiration rather than intermittent and spasmodic manifestations, gradually led to the rejection of the theory of Kopp.

On one occasion, while operating on a child, some six or seven years of age, for removal of foreign body from the wind-pipe, I was somewhat embarrassed by this gland, which projected upward into the wound to a greater extent than is usual in tracheotomy low down.

¹ Berkeley Hill : Syphilis and Local Contagious Disorders, London, 1868, p. 226.

Degenerations of the Thymus Gland.—Cases have been reported of fatty, calcareous, tuberculous, and carcinomatous degeneration.

Sir Astley Cooper¹ has related the case of a young woman, nineteen years of age, who suffered from severe dyspnoea consequent upon the sudden increase of a swelling of several years' duration at the inferior portion of the neck, and supposed to be composed of enlarged lymphatic glands. The patient died at the end of a fortnight, worn out by the irritation excited by the difficulty in respiration. On examination of the body it was found that the disease was situated in the thymus gland; the swelling extending from the arch of the aorta to the lower part of the thyroid gland, which was also considerably enlarged. The thymus appeared of a yellowish white color, and was divided into several large lobes. It projected into the innominate vein, and its reticular structure, on incision, was found to be filled with a white pulpy material. The trachea was involved in the tumor, and its sides were compressed by it, so that its transverse diameter was somewhat diminished.


But little is known concerning diseases of the thymus gland, and their pathology is obscure, except, perhaps, in instances where tuberculous degeneration occurs as an expression of the general state of system in certain subjects of phthisis.

No special treatment can be laid down for these affections. They must be managed upon general principles, and the employment of such measures as tend to improve and maintain the general well-being of the entire system. As most of these affections necessarily occur at an early age, the resort to remedies usually employed for the reduction of enlarged glands can rarely be advisable.

The question of an operation for removal of the gland may sometimes come up, but the judiciousness of the course must rest on the general principles of legitimate surgery. The extirpation of the gland, under certain circumstances, was suggested by Dr. Allan Burns, but there are obvious reasons why such a procedure should not be determined on hastily, or undertaken except as an extreme measure.

¹ The Anatomy of the Thymus Gland, Phila. Edit., 1845, p. 35.

INDEX.



INDEX.

- Abdomen, removal of foreign body (fork) from walls of, 319.
- ABELIN, on suffocation from contents of pharyngeal abscess, 248.
- Ablation of larynx, 585 [see Exsection]; of naso-pharyngeal polyps by metallic finger-nail, 270.
- Ablutions, in coryza (chronic), 362; sore throat (chronic), 194.
- Abortions, prevalence of, during epidemic influenza, 343.
- Abrasion of mucous membrane as differentiated from ulceration, 3.
- Abscess, abdominal, from passage of foreign body from alimentary tract, 319; cervical (diffuse), 688; chondrial and perichondrial, 508, 518, 525; follicular, in chronic sore throat, 185; laryngeal, 109, 441, (diffuse) 433; nasal, 374, 383, (syphilitic) 374; œsophageal, 239, 264, 313, 441, 508, 510, 660, (diffuse) 433; palatine, 122, 208, (syphilitic) 122; peri-œsophageal, 310; retro-pharyngeal, 239; retro-tonsillar, 93; sub-tonsillar, 93; thymic, 714; thyroidal, 704; tonsillar, 93, 97, 122, (traumatic) 241; A. of frontal sinus, 414, 415, (syphilitic) 415; of septum narium, 407, (syphilitic) 408.
- Absorption, spontaneous, of morbid growths of the larynx, 545; of naso-pharyngeal tumors, 271.
- Acacia, in sore throat (chronic), 179, 198.
- Accretions, calcareous, in nasal fossæ [see Rhinoliths].
- Acid [see also Carbolic Acid and Salicylic Acid]: *carbonic*, in coryza (chronic), 372; its influence in promoting fibrination of exudation in croup, etc., 468; *citric*, in diphtheria, 168; *chromic*, in laryngitis (syphilitic), 524, morbid growths of larynx, 550, sore throat (chronic), 196; *hydrochloric*, in diphtheria, 166, sore throat, 103; *lactic*, in croup, 466, diphtheria, 168; *mineral*, 130, in coryza (chronic), 367, laryngitis (syphilitic), 524, sore throat (chronic), 198; *muriatic*, [see *hydrochloric* above]; *nitric*, in fistule of larynx, 599, morbid growths of larynx, 548, sore throat, 103; *oxalic*, in diphtheria, 167; *sulphuric*, in diphtheria, 162; *sulphurous*, in diphtheria, 156, 158, 162, 167, 169, in hay-fever, 342, weak solution of, in sore throat (chronic), 179.
- Acid nitrate of mercury, in fistule of larynx, 599; laryngitis (syphilitic), 523; morbid growths of larynx, 548, 551; sore throat (chronic folliculous), 197, 198, (phagedenic) 103, (syphilitic) 127.
- Acidulated gargles, in anaesthesia of the palate, 216.
- Acne of the throat, 203.
- Aconite, in hyperæsthesia of the larynx, 625, palate, 216; laryngitis (acute), 428; sore throat, 88, 94; spasmodic cough, 635.
- Acuteness of smell [see Hyperosmia].
- ADAMS, on retro-pharyngeal abscess, 241.
- ADELMAN, on impaction of coin-catcher in the œsophagus, 316; passage of foreign body (fork) per rectum, 318.
- Adenoid tissue at vault of pharynx, 76, 254.
- Adeno-fibroma of larynx, 682.
- Adenoma, of larynx, 536; nasal passages, 393, (retro-nasal) 253; palate, 209; pharynx, 250, (vault of) 253, 259, (rhinoscopic image of) 262; tonsils, 234.
- Adhesions, deformative, of arytenoid cartilages, simulating paralysis of posterior crico-arytenoid muscles, 657; palatine, 102, 122, 212; pharyngeal, 102, 122; pharyngo-cutaneous, in stenosis of larynx after incised wound, 587; laryngeal (syphilitic) 520, (tuberculous) 504; rupture of palato-tonsillar, 224.
- Adult, spasm of larynx in the, 630; tracheotomy for diphtheritic croup rarely successful in the, 171.
- Air, fresh, in laryngitis (tuberculous), 516.
- Air-bath, hot, in coryza, 337; mumps, 697.
- Air-passages, diphtheritic croup of, 153; foreign bodies in, 614, 678; sudden inundation of during anaesthesia, 614. [See also under Larynx and Trachea.]
- ALBERS, on escape of tracheotomy-tube into air-passages, 663; œdema of larynx, 447.
- ALBU, on percutaneous injections into the larynx and trachea, 469.
- Albuminuria, in diphtheria, 138, 154, 172.
- Alcohol, in coryza (acute), 336, 339; croup, 466; diphtheria, 159; goitre (cystic), 711; hay-fever, 342; influenza, 344; sore throat (acute), 103, 114; A. inimical to bacteria, 166.
- ALLEN, on accidental rupture of pharyngeal abscess, 246; foreign bodies in the œsophagus, 311; naso-pharyngeal tumors, 263.
- ALLIN, on retro-pharyngeal abscess, 241, 242, 247.
- ALLISON, on constriction of trachea, 596; local use of sweet oil in chronic laryngitis, 495.
- Althæa, in sore throat (chronic), 179.
- ALTHAUS, on electrolysis in goitre, 709.

- Alum, in coryza (chronic), 362; croup, 464, 466; diphtheria, 163, 167, 168; laryngitis (chronic), 485, 486, 493; œsophagitis, 284; sore throat (acute), 88, 96, 105, 129 (chronic), 197.
- Aluminium buibs, holders, and points, for molten caustics, 96, 550; *nitrate of A.*, in laryngitis (chronic), 485, 486.
- Amadou, for local applications, 194, 492.
- Ammonia, caustic water of, in diphtheria, 170; paralysis of the larynx, 645.
- Ammonium: *acetate of*, in coryza (acute), 336; *bromide of*, in coryza (acute), 338, hyperesthesia of the larynx, 625, laryngitis (chronic), 495, sore throat (chronic), 179; *carbonate of*, in coryza (chronic), 336, 338, croup, 467, diphtheria, 159, 164, influenza, 344, laryngitis (chronic), 496; *chloride of*, in coryza, 326, 337, 338, (chronic) 370, diphtheria, 164, goitre, 708, laryngitis (chronic), 485, 493, pharyngitis (atrophic), 200, sore throat (chronic), 179, 198, tonsils (enlarged), 228; *sulphites of*, etc., in influenza, 344.
- AMUSSAT, on tracheotomy by galvano-cautery, 667.
- Amygdalotomes, 230.
- Amygdalitis, acute, 89, 222; chronic, 222.
- Amyl, nitrite of, in spasm of the larynx, 489, 657.
- Anchylolysis of crico-arytenoid articulation, 510.
- ANDERSON, on œdema of the larynx, 453.
- Anæmia, the, of tuberculous laryngitis, 501.
- Anæsthesia, danger from retention of plates of false teeth during, 311; inundation of air-passages during, 614; occlusion of larynx during, 665; A. in coryza (acute), 336; excision of tonsils, 229; laryngoscopy, etc., 34; spasm of the larynx, 630, 657; tracheotomy, 171, 668; cutaneous A. for tracheotomy, etc., 573, 683; local A. of the larynx for toleration of intra-laryngeal operations, 577; A. of the larynx, 624, 642; œsophagus, 323; palate, 210; pharynx, 278; trachea, 625.
- Aneurisms, of aorta, a cause of involution of the trachea, 579, of laryngeal paralyses, 652; of internal carotid artery in the pharynx, 251; the locations of cervical, 692.
- Angioma, of the larynx, 526, 543.
- Angina [see also Sore Throat], aphthous, 103; catarrhal, 84, 177; chronic, 177; clerical, 179; erythematous, 84; follicular, 179; gangrenous, 100, 147; glandulous, 179; herpetic, 103; impetiginous, 179; laryngeal, 433, (infiltrating) 433, 442, (œdematous) 442; Louis', 688; Ludwig's, 688; malignant, 100; membranous, 103; pharyngeal (œdematous), 89; phlegmonous, 89; simple, 84; stridulous, 626; tonsillar, 89; tracheal, 458; ulcerous, 100.
- Anginose scarlatina, 110.
- Animals, influenza of domestic, 342.
- ANNANDALE, on imperforate œsophagus, 288.
- Anodynes, in carcinoma of the larynx, 585; coryza (acute), 339; influenza, 344; laryngitis, 428; neuralgia of the larynx, 626.
- Anomaly, of horn of thyroid cartilage, 608.
- Anosmia, 401; in chronic coryza, 353.
- Antimony, in coryza (acute), 336, 339; diphtheria, 164; laryngitis (chronic), 493; sore throat (acute), 94.
- Antiphlogistics, in coryza, 339.
- Aorta, perforation of, by foreign body in the œsophagus, 314. [See Aneurisms.]
- Aphagia, from retro-pharyngeal abscess, 239.
- Aphonia, in paralyses of larynx, 640, (hysterical) 642, (nervous) 642; tuberculous laryngitis, 509.
- Aphthous sore throat, 103.
- Apnoea, from paralysis of larynx in diphtheria, 176; artificial entrance into air-passages, 669.
- Apomorphia, in diphtheria, 164; foreign body in the œsophagus, 314.
- Apsithyria, 345.
- Arachnitis from tumor of nasal passage, 393.
- ARÉTÆUS, on topical applications in diphtheria, 157, 168.
- ARNOLD, on dilatation of œsophagus, 298; œdema of larynx, 453.
- Arsenic, in carcinoma of the larynx, 584; of the tonsil, 237; coryza (chronic), 366; malignant growths of the pharynx, 253; malignant stricture of the œsophagus, 294; neuralgia of the larynx, 626, of the palate, 216, paralyses of the larynx, 635; sore throat, 88; spasmodic cough, 635.
- Artery, compression of carotid, in hemorrhage after amygdalotomy, 232; hemorrhage from internal carotid, in pharyngeal abscess, 247, from ascending pharyngeal, in wound of pharynx, 274, from posterior palatine, in ulcerative pharyngitis, 187; ligation of carotid, in ulcerous sore throat, 103, external carotid, in wounds of the palate, 215, as a traumatic cause of laryngeal paralysis, 640, 650, of the thyroid, in goitre, 713.
- Articulation (speech), defective, 209, 223, 251, 260.
- Artificial light, examinations by, 37; openings into larynx and trachea, 660; vocal apparatus, 682, 683, 684.
- Aryteno-epiglottic folds, 73, 79; muscle, 59, 64.
- Arytenoid cartilages, 79; perichondritis of, 509; commissure, 65; fissure, 58, 65; muscle, 63.
- Arytenoiditis, 425.
- ASCHENBORN, on perforation of the aorta by foreign body in the œsophagus, 314.
- Asphyxia, in anesthesia, 614; diphtheria, 154; goitre, 703, 708; laryngeal abscess, 441; morbid growths in larynx, 540, in trachea, 578; retro-pharyngeal abscess, 239, 248; sore throat of small-pox, 108; spasm of larynx, 628.
- Aspiration in pharyngeal abscess, 249.
- Assafœtida in paralysis of larynx, 653.
- Asthenia, death by, in diphtheria, 132, 154.
- Asthma, hay, 340; infusorial, 345; Kopp's, 715; thymic, 628, 715.
- Asthmatos ciliaris, 346.
- Astringents, in lepra, 533; nasal polyps, 396.
- Ataxia, cerebellar, after bulbar paralysis, 329; locomotor, 655.
- ATKINSON, on lipoma of tonsil, 235.
- ATLEE, on punctured wound of trachea, 606; rupture of trachea, 613.
- Atmosphere, deleterious substances in the, as a cause

- of sore throat, 6; warm and moist, in croup, 464, 465, in diphtheria, 173, 174, in tracheotomy (after treatment of), 675.
- Atresia of larynx, œsophagus, pharynx, trachea. [See Stenosis.]
- Atrophic pharyngitis, 199.
- Atrophy, of laryngeal muscles in paralyses, 637, of nerves in do., 637, 654; of œsophagus, 291, 325; pharynx, 347; tonsils, 234.
- Auscultation, 80; of œsophagus, 292.
- Auto-laryngoscopy, 43; method of Czermak, 45, of García, 18, 44, of Johnson, 45.
- Auto-rhinascopy, 78.
- Autumnal catarrh, 340.
- AXMANN, on rhinoliths, 389.
- Bacteria, inimical action of alcohol on, 166; presence of, in diphtheria, 135.
- BAGINSKY, on fetid laryngitis (chronic), 477.
- BAKER, on fatal hemorrhage from wound of ascending pharyngeal artery, 274; myxoma of the soft palate, 210; soft-rubber tracheotomy-tubes, 663.
- Bark, preparations of, in influenza, 344. [See Quinia.]
- BARTHEZ, on œdema of the larynx in whooping-cough, 446.
- BASEDOW, on exophthalmic goitre, 705.
- BASTIAN, on bacteria, action of alcohol on, 166; on hay-fever, 341.
- BATAILLE, on the triceps-laryngea muscle, 64.
- Bath, cold, 7; in sore throat (chronic), 199; foot, in coryza, 339; hot-air, in coryza, 337, in mumps, 697; Turkish (portable), 337; warm, in spasm of the larynx, 630.
- BAÜMLER, on compression of recurrent laryngeal nerve by effusion into pericardium, 643; paralysis of larynx, 650.
- BAYLE, on œdema of the larynx, 445.
- BEACH, on perforation of the trachea, 605.
- BEARDSLEY, on diphtheria, 153.
- BECK, on rupture of the trachea, 613.
- BEHIER, on fistule of the larynx, 598.
- Belladonna, in coryza (acute), 336; croup, 466; cough (spasmodic), 645; epistaxis, 379; laryngitis (chronic), 485, 493; sore throat, 95.
- BELLOCQ, his canule for tamponing posterior nares, etc., 381, 680.
- BENNET, on thyroiditis, 699; tracheotomy in goitre, 711.
- Benzoin in coryza (chronic), 363; sore throat, 95.
- BERINGIER, on lupus of the larynx, 529.
- BERNUTZ, on perforation of larynx in small-pox, 107.
- BETTS, on croup, ice in, 468; nasal passages, congenital occlusion of, 286.
- BEVAN, on œsophagocopy, 68.
- BICHAT, on laryngotomy (supra-thyroid), 574; œdema of the larynx, 445.
- Bifid uvula, 221.
- Bifurcation of trachea, inspection of, 68; influence of, in cases of foreign body in the air-passages, 616.
- BILLROTH, on excision of portion of the œsophagus, 297; exsection of the larynx, 681, 682; paralysis of the larynx after certain operations in the neck, 650; sarcoma of tonsil, 235.
- BIRKETT, on spontaneous sloughing of naso-pharyngeal tumor, 272.
- Bismuth, *borate*, *neutral nitrate*, and *subnitrat*: of, in coryza (chronic), 363; hyperesthesia of larynx, 626, palate, 216; laryngitis (chronic), 493; sore throat (chronic), 179.
- BIZET, on perforation of cranium from syphilitic abscess of frontal sinus, 416.
- BLACKLEY, on autumnal catarrh, 340.
- Black-tongue, epidemic, 436.
- BLANC, on primitive carcinoma of larynx, 582.
- BLANDIN, on extirpation of carcinomatous tonsils, 237.
- Blisters in sore throat (chronic), 198.
- Blows on the head, a cause of anosmia, 402.
- Blue-pus in abscess of thyroid cartilage, 527; -tinted chimneys, to whiten artificial light, 38.
- BOERHAAVE, on œdema of the larynx, 447; rupture of the œsophagus, 307.
- BOISMONT, on suicidal wounds, 600.
- BOKAI, on retro-pharyngeal abscess, 240, 241.
- BONNER, on ablation of naso-pharyngeal polyps with a metallic finger-nail, 270.
- Borax, in diphtheria, 168; sore throat, 105, 129.
- BORELLI, on retention of foreign body in œsophagus, 318.
- BOSE, his method of bloodless tracheotomy, 671.
- BOTTINI, on exsection of the larynx, 681, 683.
- BOUCHUT, on tubage of the larynx in croup, 468.
- Bougies, in dilatation of stenoses of larynx, 591, œsophagus, 293, pharynx, 277. Soluble B. in coryza (chronic), 370; epistaxis, 379.
- BOUGUIER, on epistaxis, 378.
- BOUILLAUD, on phlegmonous laryngitis, 494.
- Brain, the, in epidemic influenza, 342. [See Cerebrum.]
- BRAINERD, on tracheotomy, 662.
- BRAUERS, on thyrotomy (for laryngeal growth), 570.
- BREDSCHNEIDER, on rupture of the trachea in bronchitis, 613.
- BRENNER, on the galvano-cautery in naso-pharyngeal tumors, 270.
- BRETONEAU, on diphtheria, 135, 139, 140, 141, 142, 143, 148, 149, 152, 153, 155, 160, 164, 167.
- BRIGIDI, on persistence of the thymus gland into adult life, 715.
- Bright's disease, œdema of larynx in, 446.
- BRODIE, his method of mercurial inunction in infants, 129.
- Bromine [see also under Ammonium and Potassium], in croup, 464; diphtheria, 162, 168, 169; sore throat, 103.
- Bronchi, carcinoma of the, 586; casts of the, in croup, 462; diphtheritic deposits in the, 140; injections into the, 680; inspection of the primitive, 67; tumor of the, 578.
- Bronchitis, chronic, 227; in diphtheria, from inhalations, etc., 175; hay-fever, 341; influenza, 342, 343; wounds of larynx and trachea, 606; rupture of trachea in, 613; subacute laryngitis in, 424.

- Bronchocele, 701, (acute) 595, 679.
 Bronchotomy, 660.
 BROWN, on occlusion of nasal passages, 385; rhinoliths, 388.
 BROWNE, his nasal speculum, 16; respirator veil, 494; on dangers in intra-laryngeal manipulations for removal of laryngeal growths, 545; the galvano-cautery in chronic sore throat, 196; tracheotomy after intra-laryngeal manipulations, 545; tuberculous laryngitis, 500.
 BRUNS, VON, his epiglottis-pincette, 33, 489; galvano-cautery appliances, 568; on galvano-cautery in treatment of laryngeal neoplasms, 567, 568; lipoma of the larynx, 543; naso-pharyngeal tumors, electrolysis in, 271; galvano-cautery in, 270; removal of endo-laryngeal neoplasms, 573.
 Brushes and brush-holders, 179, 194, 490.
 BRYANT, on nasal polyps, 396.
 BUCK, on foreign bodies in the trachea (tracheotomy-tube), 664; thyrotomy for laryngeal growths, 570.
 BUHL, on tuberculosis of the larynx, 499.
 Bulbar paralysis, progressive, 327, 638.
 Burns of the throat, 98.
 BURNS, on abscess of the thymus gland, 719; extirpation of the thymus gland, 716.
 Bursa, ante-thyroid, 698; hyoid, 272; infra-hyoid, 698, fistule of the, 289; pharyngeal, the, 254; supra-hyoid, 698, cysts of the, 698; synovial, of hyoid bone, 272; tumors of the bursæ in the thyro-hyoid region, 697. [See Hygroma.]
 CABOT, on depressing the nose to gain direct access to naso-pharyngeal tumors, 269.
 CAIRN, on tracheotomy in acute bronchocele, 701.
 Calamus, in atrophic pharyngitis, 200.
 Calcification of cartilages in chronic laryngitis, 474.
 Calcium, *chloride of*, in enlarged tonsils, 228; and spasm of the larynx, 630; *sulphide of*, in enlarged tonsils, 228; *sulphites, etc., of*, in influenza, 344.
 Calculi, of frontal sinuses, 415; nasal passages, 386, 388; tonsils, 237.
 Calomel, in croup, 466, 467; diphtheria, 160, 166; laryngitis (chronic), 493.
 Camphor in coryza (acute), 338, (chronic) 372; hyperesthesia of larynx, 625; sore throat, 95.
 Canula, for carrying nasal tampon, 381; œsophageal tube, 680; tracheotomy, 469, 672, 674, 675, 677, 679.
 Capsicum, in coryza (chronic), 366; elongated uvula, 220.
 Carbolic acid, in carcinoma of larynx, 585; coryza, 338, 340, 359, 363; diphtheria, 158, 162, 167, 169; enlarged tonsils, 234; goitre, 711; hay fever, 342; laryngitis (chronic), 485, 486, (tuberculous) 516; pharyngitis (atrophic), 200; sore throat (acute) 88, (chronic) 197.
 Carcinoma, of bronchi, 586; epiglottis, 580, 585; frontal sinuses, 417, larynx, 536, 545, 580, 581, 583, 626; mediastinum, 298; nasal passages, 394; œsophagus, 303; palate, 211; pharynx, 250; thyroid gland, 707; tonsils, 234, 236; trachea, 580; uvula, 220.
 Caries of cervical vertebræ, 123, 241, 628.
 CARMICHAEL, on starvation in retro-pharyngeal abscess, 239; tracheotomy, 662.
 Carotid artery. [See Artery.]
 Cartilage, *cricoid*, as a foreign body in the air-passage, 615; regeneration of, 525; *nasal*, fracture of, 385.
 Cartilages, *laryngeal and tracheal*, calcification of, in chronic laryngitis, 474, 511; disintegration of, in tuberculous laryngitis, 506, 511; necrosis of, in syphilitic laryngitis, 519; ossification of, 511, 669; pigmentation of, in tuberculous laryngitis, 506.
 Caseous products in glands, infra-tonsillar, 223; sacular, at base of tongue, 223; infra-tonsillar, 223; tonsillar, 223, removal of, 224.
 CASSELS, on the nasal douche, 359.
 CASSIS, VIDAL DE, on supra-thyroid laryngotomy, 574.
 Casts, fibrinous, in croup, 462; diphtheria, 131, 141, 142.
 Cataplasms, in diphtheria, 149; laryngitis, 428.
 Catarrh, autumnal, 340; diphtheritic, 149; dry, of pharynx, 199; epidemic febrile, 342; fetid, 414; folliculous (chronic), 179; granular (chronic), 179; infusorial, 345; laryngeal, 422, 474; nasal, 262, (acute) 331, (chronic), 346; œsophageal, 282; pharyngeal (chronic) 177, (dry) 197; pulmonary, œdema of larynx in, 446.
 Catechu, in elongation of the uvula, 220.
 Cathartics, in acute coryza, 339; influenza, 344.
 Catheterization of the bronchi, 680; larynx, 549, 679; œsophagus, 286, 293; trachea, 679.
 CATTI, on hypertrophic chondritis vocalis, 482.
 Caustic, molten, 96; -paste, in tracheotomy, 667; -pencil, 96, 195.
 Caustics, in chronic catarrhal sore throat, 179; enlarged tonsils, 233; fistule of pharynx, 277.
 Cauterization, incautious, a cause of œdema of uvula, 220; spasm of larynx, 549, 551.
 Cautery, actual or incandescent [see also Galvano-cautery], in coryza, 363; sore throat, 103, (folliculous) 196; readhesions of soft palate, 212; tracheotomy, 677; thermo-, in tracheotomy, 667.
 Cephalalgia, contagious or epidemic, 342.
 Cerebrum, the, in diphtheria, 137; influenza, 343; scarlatina, 111; syphilis, 123.
 Cervical glands, engorgement of, in hypertrophied tonsils, 226; tumors, 692.
 Chamomile, as a cause of idiosyncratic coryza, 341; in sore throat, 95.
 Chancres, primary, in throat, etc., 119.
 CHAPMAN, on diphtheria, 141; epistaxis, 378; epithelioma of larynx, 570; sarcoma of pharynx, 250.
 CHARLES, on rupture of the œsophagus, 307.
 CHARRIÈRE, his amygdalatome, 231; tonsil écraseur, 232.
 CHASSAIGNAC, his amygdalatome, 231; on amygdalatotomy, 231; resection (subperiosteal) of nasal septum, 411; stricture of trachea, 587; tracheo-

- tomy by *écraseur*, 667; by instantaneous incision, 672.
- Cheeks, chancre of, 120.
- CHEEVER, on excision of carcinomatous tonsils, 237; œsophagotomy, 323.
- Cherry, wild, in irritative cough, 633.
- Chest-tones, mechanism of the production of, 62.
- CHEYNE, on ulceration of the larynx in measles, 110.
- CHIARI, on osteoma of trachea, 579.
- Children, laryngitis (acute) in, 430; pharyngeal abscess in, 240; syphilitic sore throat in, 127. [See Infants.]
- Chloral, in cough (spasmodic), 635; diphtheria, 167; hyperesthesia of larynx, 625; of palate, 216; spasm of larynx, 630.
- Chlorine, and its compounds, in coryza, 329, (chronic) 366; diphtheria, 158, 169; enlarged tonsils, 228; paralysis of larynx, 646; -mixture, 158. [See also under Ammonium, Calcium, Potassium, Sodium.]
- Chloroform, in coryza (acute), 336; cough (irritative), 633; local anesthesia of larynx, 577.
- Chocolate, for lozenges, 198.
- Cholera, mumps attendant on, 696.
- Chondritis, in laryngitis (syphilitic), 520, (tuberculous) 508.
- Chorditis tuberosa, 479; vocalis, 422, (hemorrhagic) 425, hypertrophic, 478, 482.
- CHVOSTEK, on exophthalmic goitre, 710.
- Cicatrices, of ulcerative tuberculous laryngitis, 507; stellate, of syphilis, 123.
- Cinchona in influenza, 344; laryngitis (chronic), 494, (tuberculous) 575; paralysis of larynx, 645; sore throat, 105. [See Quinia.]
- Cinchonidia, in influenza, 344.
- CLARK, on contusions of larynx and trachea, 612; hemorrhage in wounds of larynx and trachea, 603; pericarditis from foreign body in the œsophagus, 314; pharyngeal abscess, 243.
- Cleansing the throat, importance of, 194; nasal and naso-pharyngeal cavities, 350, 354, 359.
- Cleft palate, 215, 256; adhesion of edges by splitting instead of paring them, 213.
- CLEMENTI, on leeches as foreign bodies in the larynx, 620.
- Clerical (clergyman's) sore throat, 182.
- Climate, change of, in chronic laryngitis, 494.
- CLOQUET, on parasites in the nasal passages, 389.
- COCK, on impairment of voice after œsophagotomy, 650.
- Coddling, a cause of hay-fever, 340.
- Cod-liver oil, in coryza (chronic), 364; enlarged tonsils, 228; laryngitis (chronic), 495, (tuberculous) 514; paralysis of larynx, 639; spasm of larynx, 630.
- COGHILL, on ergotine in goitre, 711.
- Coin-catcher, œsophageal, 316.
- Cold bath, 7; in epistaxis, 378; compresses, in croup, 468, diphtheria, 163, laryngitis, 432, 439; direct action of, as a cause of disease of the throat, 5, of development of morbid growths in the larynx, 534; in the head (acute), 331; June-, 340; rose-, 340; water, in paralysis of larynx, 645.
- Collapse of the œsophagus, 291.
- COLLES, on tamponing the posterior nares, 382.
- Compresses, cold, in croup, 468, diphtheria, 163, laryngitis, 432, 439; warm, in croup, 466, laryngitis, 428, 432, 435, sore throat, 89.
- Compression, of the carotid artery in hemorrhage after amygdalotomy, 232; of the œsophagus, 297; of the tonsil (local), in hypertrophy of the organ, 228.
- CONANT, on pericarditis from foreign body in the œsophagus, 314.
- Concentric hyperchondrosis of syphilitic laryngitis, 525.
- Conductors, for facilitating introduction of tracheotomy-tubes, 673, 674.
- Confection of rose, for lozenges, 198.
- Conium, in coryza, 363; laryngitis (chronic), 485; sore throat, 95, (chronic) 198.
- Constriction of the larynx and trachea, 586, 593; of the œsophagus, 297.
- Consumption, throat-, 497.
- Contusions of the larynx and trachea, 612.
- COOPER, on degenerations of the thymus gland, 716; traumatic pharyngeal abscess, 241.
- Copaiba, in coryza, 340; diphtheria, 161.
- Copper, sulphate of, in coryza, 363; diphtheria, 164; enlarged tonsils, 228; laryngitis (chronic), 486, (syphilitic) 524; sore throat (acute), 99, 127, (chronic) 179, 196, 197.
- COQUEREL, on parasites in the nasal passages, 389.
- Cords, vocal. [See Vocal Cords.]
- CORSON, on ice in croup, etc., 468.
- Coryza, acute, 260, 331, 422, 430; chronic, 227, 346; diphtheritic, 152; fetid, 347; folliculous, 185; glandered, 117; gonorrhœal, 340; idiosyncratic, 340; infantile, 332; membranous, 332; periodic, 340; phlegmatorrhagic, 346; rubeolar, 109; scrofulous, 352; syphilitic, 352, (infantile) 128, 332.
- COTTI, on soluble bougies in chronic coryza, 370.
- Cotton, for making local applications in sore throat, 194.
- Cough, advantages of position in favoring expectoration by, 496; aural or ear-, 636; importance of, in diphtheria, 163; in chronic folliculous sore throat, 190; in croup, 461; in hyperesthesia of palate, 206; in morbid growths of palate, 209; irritative, 632; spasmodic, 633.
- Counter-irritation, in bulbar paralysis, 329; laryngitis (chronic), 493; sore throat (chronic), 198.
- COXE, on croup, 148.
- COYNE, on vascular papillæ at edges of vocal cords, and on glands on their superior and inferior surfaces, 537; ulceration of the larynx in measles, 110.
- Cramp, of the œsophagus, 324.
- Cranium, bones of the, destruction of in coryza (specific), 352; mumps attendant on osteitis of, 696; perforation of, by syphilitic abscess of frontal sinus, 416.
- Creasote, in chronic coryza, 372; diphtheria, 167, 169.
- Crepitation, in diffuse inflammation of the tissues of

- the neck, 690; fractures of the larynx, 608; normal, of larynx on palpation, 80.
- Cretinism, with goitre, 702.
- CRÉQUY, on epistaxis, 379.
- Crico-arytenoid muscles, paralysis of lateral, 641, 650; of posterior, 628, 630, 658, 660.
- Cricoid cartilage, 66; discharge of, in chondritis, 525; diseased, from post-oesophageal abscess, 248; division of, in laryngotomy, 669; perichondritis of, 510; reproduction of, after chondritis, 525.
- Crico-thyroid ligament or membrane, 60, 66; muscle, 63; paralysis of, 339.
- CRIPPS, on Rouge's operation for removal of dead bone in fetid coryza, 373.
- Croup, 424, 458; apparent identity of, with diphtheria, 145; catarrhal, 460; cerebral, 626; clinical differentiation of, from diphtheria, 150; deuteropathic, 148; diphtheritic, 147; fibrinous, 460; idiopathic, 147; pseudo-, 626; spasmodic, 626; sthenic, 147; suppurative, 460; systemic, 147; traumatic, 147; treatment of, after tracheotomy, 470.
- CRUVEILHIER, on laryngitis (phlegmonous), 423, (ulcerous of rubeola) 110; oedema (subglottic) of larynx, 444.
- Cryptogamia, presence of, as a cause of diphtheria, 133.
- Cubeb, in atrophic pharyngitis, 200; coryza, 340, (chronic) 366; diphtheria, 133; paralysis of palate, 217; sore throat, 198; oleo-resin of, 198; powder of, 198.
- CUTTER, his early efforts at laryngoscopy, 18; écraseur (wire), for excision of naso-pharyngeal tumors, 270; hair-pin retractors, 16; retractors for the divided thyroid cartilage, 571; on catarrh (infusorial), 346; rhizopods a cause of disease, 346; thyrotomy without preliminary tracheotomy, 569.
- CUZCO, his laryngeal forceps, 554.
- Cynanche cellularis maligna, 688; parotidæa, 695; sublingualis rheumatico-typhoides, 688; trachealis, 458, (humida) 458.
- Cystoma, of epiglottis, 544, simulated by pharyngeal abscess, 243; of frontal sinus, 417; larynx, 536, 544; lingual sinuses, 54, 687; nasal septum, 412; pharynx, 250, (dermoid) 250; thyroid gland, 579, 701, 703, 704, 711, (parenchymatous) 705; thyro-hyoid bursa, 697; tonsils, 225; trachea, 578; vocal cord, 558.
- CZERMAK, his early observations in laryngoscopy, 18; multiple mirrors, 35; reflectors, 38; on auto-laryngoscopy, 45; infra-glottic laryngoscopy, 48; rhinoscopy, 69.
- CZERNY, on exsection of the larynx in dogs, 681.
- DAGUILLON, on vapor of ammonia in diphtheria, 170.
- DALLAS, on tumors of the œsophagus, 303.
- D'ARCY, on tamponing the posterior nares, 382.
- Dartreus sore throat, 202.
- DAVIES-COLLEY, on myxoma of the nasal passage, 392.
- DAVIOT, on insufflations of alum in diphtheria, 168.
- DAVY, on escape of tracheotomy-canule into air-passage, 664.
- Daylight, reflection by diffuse, 37.
- DEBROU, on supra-thyroid laryngotomy, 574.
- Deformities of the pharynx, 276.
- Degeneration of muscle, in chronic laryngitis, 478; in paralyses of the larynx, 637; of nerves in paralyses of the larynx, 654.
- Delirium, acute, from foreign body in nasal passages, 387; from parasites in frontal sinuses, 418, in œsophagus, 311; from retention of nasal tampon, 382; in influenza, 343.
- DEMARQUAY, on carcinoma of the larynx, 582; electrolysis in cervical tumors, 694; electro-puncture in paralysis of œsophagus, 329; rhinoliths, 389.
- Demonstro-laryngoscopy, 46; -rhinoscopy, 78.
- Demulcent drinks in laryngitis, 428, 432, 440, sore throat, 87.
- Dental engine, in destroying and removing nasal osteoma, etc., 399.
- Dentist's extension-thimble, 79, 489.
- Dentition, a cause of irritative cough, 633; of spasm of the larynx, 628; laryngitis, etc., in, 420, 430.
- DEPAUL, on syphilitic thymitis, 715.
- Depletion in acute laryngitis, 428.
- Deposit, the, in diphtheria, 139, (multiple) 142.
- DESSAULT, on division of the larynx for extraction of foreign body, 571.
- DETMOLD, on chloride of lime and krameria in chronic coryza, 368.
- DEVALTZ, on tracheocele, 580.
- Diaphoresis, general, in coryza, 336, 339; local, in do., 337.
- Diaphragm, paralysis of the, 644; rupture of the, 307.
- Diastase in tuberculous laryngitis, 514.
- DICKSON, on membranous sore throat, 105.
- DIDAY, on syphilitic coryza, 128.
- DIEFFENBACH, his operation for direct access to naso-pharyngeal tumors, 390; on fistules of larynx, 599; galvano-cautery in naso-pharyngeal growths, 270.
- Dilatation of the œsophagus, 298; on, of stenosis of the larynx, 588; nasal passages, 364; œsophagus, 224; pharynx, 277; trachea, 521.
- Dilators, laryngeal, 589; œsophageal, 224, 293; tracheal, 673.
- Diphtheria, 131; as a cause of membranous sore throat, 104, of ulcerous sore throat, 101; croup of, 147; gangrenous, 145, 152; its apparent identity with croup, 145; its differentiation from croup, 150; nasal, 152; oedema of larynx in, 446; septic, 152; sporadic, 146; tracheotomy in, causes of death after, 172; rarity of success from, in adults, 171.
- Discoloration of the skin from topical use of the nitrate of silver in chronic sore throat, 196.
- Disinfection, in diphtheria, 158.
- Displacement of larynx and trachea by cervical tumor, 33, 692, 693.
- DITTRICH, on stricture of the trachea, 587.

- Diverticulum, œsophageal, 300; pharyngeal, 279.
- DOBELL, his tongue-holder, 29.
- DOMINGUEZ, on occlusion of œsophagus by tumor, 298.
- DONALDSON, on cauterization of enlarged tonsils, 233.
- Dover's powder in acute coryza, 336.
- Douche, in chronic laryngitis, 487; laryngeal, 487; nasal, 335; in removal of foreign bodies, 388.
- Drinks, warm, in acute coryza, 337, 339.
- DROU, on syphilitic infection from breast-milk, 119.
- Drugs, abuse of, a cause of sore throat, 84.
- DRYDEN, on rupture of œsophagus, 307.
- Dryness of mucous membrane in coryza, 334.
- DUBOIS, on syphilitic thymitis, 715.
- DUCHENNE, on applications of electricity to œsophagus, 327; electrolysis in cervical tumors, 694; progressive bulbar paralysis, 328.
- DUFOUT, on carcinoma of the larynx, 580.
- DUGUET, on permanent discoloration of skin from local use of nitrate of silver, 196.
- DUJARDIN, on tracheotomy by caustic paste, 667.
- DUNCAN, on congenital fistule of the œsophagus, 289.
- DUPARCQUE, on retro-pharyngeal abscess, 247.
- DUPLAY, his nasal speculum, 14; tongue-depressor, with mirror attached, 73.
- DURHAM, his adjustable forceps for extraction of rhinoliths, 391; flexible forceps for larynx, pharynx, etc., 315, 557; tracheotomy-tube, linked inner tube and piloting conductor, 674; on occlusion of nasal passages, 384.
- DURKEE, on sarcini ventriculi in the nasal passages, 383.
- DUSCH, on electrolysis in exophthalmic goitre, 710.
- Dysentery, as a cause of ulcerous sore throat, 101.
- Dyspepsia, a cause of chronic folliculous sore throat, 181.
- Dysphagia, from abscess of larynx, 442, pharynx, 243; carcinoma of larynx, 582; compression of œsophagus, 298; laryngitis, 425, 435, (tuberculous) 511; morbid growths of larynx, 541; œdema of larynx, 448; stricture of œsophagus, 292; ulceration in sore throat, 189; Valsalviana, 276.
- Dysphonia. [See Hoarseness.]
- Dyspnoea in carcinoma of larynx, 582, croup, 461, diphtheria, 144, laryngitis, 425, 431, 435, (chronic) 483, morbid growths of larynx, 539, œdema of larynx, 448, paralysis of larynx, 176; respiratory brace for, 253.
- Ear, pains in, in diphtheria, 152, laryngitis (chronic), 483.
- EBERTH, on myoma of the œsophagus, 303.
- Ecchinococci, in cystic goitre, 707.
- Echondroma, of nasal passages, 393; nasal septum, 412; trachea, 511; 578.
- Ecchymoses, in diphtheria, 142.
- Écraseurs, for excision of tonsils, 232; laryngeal tumors, 565; naso-pharyngeal tumors, 270; tracheotomy, 667.
- Eczema of the throat, 203.
- Effusion, pericardial, a cause of compression of œsophagus, 298; paralysis of larynx, 643.
- EHRMANN, on thyrotomy for extirpation of laryngeal tumors, 570.
- Electric current, the, in anosmia, 403; bulbar paralysis, 330; coryza (chronic), 363; dilatation of the œsophagus, 302; diphtheritic paralysis, 176; goitre, 709; hyperesthesia of the palate, 216; neuralgia of the palate, 216; paralysis of the larynx, 625, 626, 638, 640, 645, 652, 653, 657; of the œsophagus, 327; of the palate, 216, 217; of the pharynx, 280; of the uvula, 221; spasm of the larynx, 631; spasmodic cough, 635. [See Galvano-Cautery.]
- Electrolysis, in cervical tumors, 694; enlarged tonsils, 233; goitre, 709; naso-pharyngeal tumors, 270; stricture of the œsophagus, 295.
- Electro-puncture in paralysis of the œsophagus, 327.
- ELSBURG, his combination of laryngoscopic mirror and reflector, 42; flexible staff to laryngeal instruments, 557; method of warming mouth mirrors, 26; mouth-gag, 213; nasal dilator or speculum, 15; support for laryngoscopic reflector, 41; uvula sector, 219; on auscultation of the œsophagus, 82; congenital web between vocal cords, 536; lepra, 532; penetration of fluids from nasal douche into Eustachian tubes, 359; submucous infiltration at sides of vomer, 408; sternutation, 405; tubercles in the posterior wall of the larynx, 58.
- Emetics, in croup, 464; diphtheria, 163; sore throat (acute), 87; paralytic aphonia (hysterical or nervous), 649.
- EMMERT, on congenital occlusion of nasal passages, 385.
- EMMET, on œdema of larynx in typhoid fever, 446.
- Emphysema, cutaneous, in tuberculous laryngitis, 510; from chondritis (suppurative), 526; perforation of œsophagus by foreign body, 318, of trachea, 605; wounds of larynx and trachea, 602; of pharynx, 274.
- Enchondroma, of the pharynx, 249.
- Endermic use of morphia in sore throat, 85.
- Enema, nutrition by, in carcinoma of larynx, 585; paralysis of larynx, 639; sore throat, 97; tuberculous laryngitis, 517.
- ENGLISH, on tamponing the posterior nares, 382.
- Enteritis, fatal, from a copper coin in alimentary tract, 318.
- Epiglottitis, 53; artificial, 684; carcinoma of, 580, 585; chancre of, 120; cystoma of, 536, 544, simulated by pharyngeal abscess, 243; depressed, 32, 56; elongated, 56; excision of, in tuberculous laryngitis, 513; impaction of, 273; 615; incarceration of, 628; influence of, on adaptability of artificial vocal apparatus after excisions of larynx, etc., 684; instruments for elevating, 32, 33; in syphilis, 123; irritability of, 489; manipulations of, in adhesions from laryngitis, 525; muscles of, 56; œdema of, 111, 450; palpation of, 79; paralysis of, in diphtheria, 176; pendent, 56, 628; -pincette, 33, 489; ulceration of, in laryngitis (syphilitic), 520, (tuber-

- culous) 504, 508; unfavorable position of, for laryngoscopic inspection, 32; varieties in form of, 55; wounds of, 273, 601.
- Epiglottitis, 422, 496.
- Epistaxis, 375; in diphtheria, 152, 153; naso-pharyngeal tumors, 264.
- Epithelioma, of larynx, 536, 545, 570; simulation of, in syphilis, 124.
- Epithelium, character of, as favoring adherence of adventitious materials, 159; desquamation of, in scarlatina, 111; squamous, fungus of thrush confined to, 118.
- Erectile venous plexuses of turbinated bones, 333.
- Ergot, in carcinoma of larynx, 585; epistaxis, 265, 380; hemorrhagic oedema of larynx, 458; laryngitis (chronic) of carcinoma, 486.
- Ergotin, in bulbar paralysis, 330; enlarged tonsils, 234; goitre, 711; hemorrhagic oedema of larynx, 458.
- Erosions of mucous membrane in sore throat (acute), 86.
- Erysipelas, as a cause of mumps, 696, of pharyngeal abscess, 241, of ulcerous sore throat, 105; facial, in goitre, 704, in influenza, 343; laryngitis of epidemic, 436; oedema of larynx in, 436.
- Ether, as a cause of anosmia, 402; as a solvent for tannin, 179; in croup, 466; laryngitis (chronic), 496; paralysis of larynx, 646.
- Ethmoid bone, caries, etc., of, in chronic coryza, 352.
- EULENBERG, on electrolysis in exophthalmic goitre, 710.
- Eustachian catheter, syphilitic infection conveyed by, 119; *tube*, direct view of pharyngeal extremity of, 257; in diphtheria, 140, measles, 109, scarlatina, 112, syphilis, 123; penetration of fluid into, from nasal douche, 359; rhinoscopic view of pharyngeal extremity of, 75.
- Eversion of the ventricle of the larynx, 576.
- Evulsion, of laryngeal growths, 546, 553; nasal polyps, 396; naso-pharyngeal tumors, 265; pharyngeal tumors, 251.
- Exanthemata, the, a cause of pharyngeal abscess, 241; sore throats of, 107.
- Excision, of the oesophagus, 297; tonsils, 225, 228; uvula, 218, 220.
- Excrescences, papillomatous, in measles, 110; in the fistulous tract of the wound of tracheotomy, 676. [See Morbid Growths.]
- Exercises, vocal gymnastic, in paralyses of larynx, 641.
- Exophthalmic goitre, 705.
- Exophthalmos, 416.
- Exostoses of nasal fossæ, 399.
- Expectorants in diphtheria, 164.
- Expectoration, facility of, favored by position, 496.
- Exsection of larynx, 680; tonsils, 237.
- Extension thimble, 79, 489.
- Extirpation of larynx, 680; pharyngeal tumors, 251; thymus gland, 716; thyroid gland, 713.
- Exudation, the, a cause of death after tracheotomy in diphtheria, 172; of common membranous sore throat, 105; croup, 460; diphtheria, 139.
- Exudative laryngo-tracheitis, 458.
- FABRICE, on perforation of aorta from foreign body in oesophagus, 314.
- FAHNESTOCK, his amygdalatome, 230.
- Falsetto tones, mechanism of production of, 62.
- Fancied bodies in the pharynx and oesophagus, 320.
- FANO, on tamponing the posterior nares, 381.
- FARRE, on oedema of the larynx, 444.
- FAUVEL, his laryngeal forceps, 554; on angioma of the larynx, 543; carcinoma of the larynx, 580; iodine, glycerine, and carbolic acid in atrophic pharyngitis, 200.
- FERGUSON, on cleft of hard and soft palate, 213.
- Fetid coryza (chronic), 347; laryngitis (chronic), 476.
- Fever. [See Typhoid and Typhus Fever.]
- Fibroma, of frontal sinuses, 417; larynx, 536, 569, 588, 682; nasal passages, 392; oesophagus, 302; palate, 210; pharynx, 249; tonsil, 235.
- Fibro-sarcoma of pharynx, 249.
- FIFIELD, on polyp of trachea, 578.
- Finger, the fore-, as a tongue-depressor, 9; pressure of, in rupturing abscess of the pharynx, 248, oedema of larynx, 453.
- FINGERHUTH, on fatal hemorrhage from foreign body in pharynx, 274.
- Finger-nail, in incising pharyngeal abscess, 248; scraping away laryngeal growths, 548, 553.
- FINNY, on paralysis of oesophagus, 326.
- Fissure in the larynx, 477; pharynx, 320.
- Fistule, congenital, of the neck, 288; of the infra-hyoid bursa, 289; larynx, 510, 536, 597; oesophagus, 288, 308; pharynx, 276; thyro-hyoid bursa, 289, 698; trachea, 597.
- FLAJANI, on exophthalmic goitre, 705.
- FLEMMING, on pharyngeal abscess, 241, 242.
- FLINT, on syncope in diphtheria, 155.
- Flux, nasal, fluxus nasalis, 346.
- Follicles. [See Glands.]
- Folliculous sore throat (chronic), 179.
- FOLLIN, on sub-hyoid or supra-thyroid laryngotomy for extirpation of morbid growths, 548, 575.
- Food, promiscuous use of hot and cold, a cause of sore throat, 6.
- Forceps, compression of tonsil with, in hemorrhage after amygdalotomy, 232; dilating, 589; flexible, 315; link, 315; laryngeal, etc., 492, 549, 553, 556, 562; naso-pharyngeal, 266; oesophageal, 315; polyp, 396; pharyngeal, 194; retro-nasal (cutting), 262; tracheotomy-tube, 646.
- Foreign bodies, a cause of epistaxis, 376; in frontal sinuses, 389, 418; glosso-epiglottic sinuses, 687; laryngo-pharyngeal sinuses, 686; larynx, 571, 614; pharynx and oesophagus, 310; nasal passages, 348, 386; tonsils, 238; trachea, 614, 678.
- Forks, passage of, from stomach to exterior of body, 319.
- FOSTER, on cerebral hemorrhage following evulsion of naso-pharyngeal tumor, 266.
- FOULIS, on actual cautery in chronic folliculous sore throat, 196; exsection of larynx, 681; syphon

- tracheal tube during operations threatening suffocation, 572.
- Fovea centrale, 65.
- Fracture, of larynx and trachea, 604, 606; nasal septum, 412; tracheal cartilages, 610.
- FRAENKEL, his nasal speculum, 15; tongue-depressor, 10; on acute tuberculous sore throat, 115; fetid chronic laryngitis, 477; infantile coryza, 332; nasal douche, 359.
- FREDET, on fracture of the larynx, 610.
- FRENCH, his respiratory brace for dyspnoea, 253.
- FRIEDREICH, on non-contagiousness of coryza, 332.
- Frog-face, 264, 333.
- Frontal sinuses, abscess of, 414, 415, (syphilitic) 415; foreign bodies in, 389, 418; inflammation of, 414; insects in, 418; occlusion of, 415; parasites in, 414, 418; perforation of cranium from syphilitic abscess of, 416; tumors of, 416.
- Fruit-juice, to allay thirst in tuberculous laryngitis, 517; -paste for lozenges, 198.
- FULLGRAFF, his naso-pharyngeal douche, 359.
- Fumes of lime in croup, 464; diphtheria, 169.
- Fungous vegetations in laryngitis (tuberculous), 502, 505, 511, (ulcerous) 544; tracheal fistule, 677.
- Fungus, the, of thrush, 118. [See Cryptogamia.]
- GALAIS, on perforation of trachea from foreign body in œsophagus, 314.
- GALLARD, on pharyngeal erysipelas, 113.
- Galvano-cautery, in chronic folliculous sore throat, 196; excision of tonsils, 233; exsection of larynx, 683; fistule of pharynx, 277; laryngeal growths, 566; naso-pharyngeal tumors, 270; tonsillitis (chronic), 228; tracheotomy, 667.
- GARCIA, his device of laryngoscopy, 18; method of auto-laryngoscopy, 44.
- Gargles in anesthesia of the palate, 216; diphtheria, 168.
- Gargling, 95.
- GASCOYEN, on sphacelus of thyroid gland, 699.
- Gastrostomy and gastrotomy, 296.
- GEIGER, on inhalations of fumes of lime in croup, 464; in diphtheria, 172.
- Gelsemium, (gelsmium) in croup, 466; spasmodic cough, 635.
- GEMRIG, his uvula-scissors, 219.
- GIBB, his laryngeal douche, 487; snare, 564; on carcinoma (epithelial), 545, of larynx, 582; chondritis (external), 527; chronic folliculous sore throat, 182, 183; croup, nitrate of silver locally, in, 467; cystoma of trachea, 578; involution of the trachea, 579; laryngitis (acute), nitrate of silver in, 428, (chronic) bromide of ammonium in, 495, (erysipelatos) 436, 437, 438, (tuberculous) 497; lepra of larynx, 531; lipoma of œsophagus, 303; œdema of the larynx (sub-glottic), 444, 456, in small-pox, 107; spasm of the larynx, 630; vocal cord, destruction of, in small-pox, 109.
- GIGOT, on tincture of chloride of iron in diphtheria, 166.
- Glanders, a cause of ulcerous sore throat, 101; coryza of, 117; œdema of larynx in, 466, chronic, following, 454; sore throat of, 116, 117.
- Glands, bronchial (enlarged), a cause of spasm of the larynx, 628; cervical, engorgement of, in hypertrophied tonsils, 226; enlarged simulating tubercle, 498; hypertrophied, in chronic folliculous sore throat, 183, 185; infra-tonsillar, 13; lingual (enlarged), in chronic laryngitis, 478; lymphatic, involvement of, in diphtheria, 132, 138; palatine, 12; pharyngeal, 239; supra-tonsillar, 13; thymus, affections of the, 714, enlarged, a cause of spasm of the larynx, 628; thyroid, affections of the, 699, hypertrophy of, 701, sphacelus of, 690, 699; tonsillar, 13.
- Glass bulbs for applying nitrate of silver, 550.
- Glossitis, tracheotomy in, 660.
- Glosso-epiglottic fold, 54; sinuses, 54, affections of the, 687.
- Glosso-laryngeal and glosso-pharyngeal paralysis, 327.
- Glottis, 60; cleft, chink, or fissure of the, 60; constriction of the, from paralysis after diphtheria, 176; diagrammatic representation of reflected image of the, 26; lips of the, 60; œdema of the, 442, (sub-glottic) 455; paralysis of the, 425, 443, 460, 462; spasm of the, 195, 660, (in croup) 460.
- Glycerin in coryza (chronic), 369; diphtheria, 167, 168; laryngitis (chronic), 495; pharyngitis (atrophic), 200.
- GODLEE, on rupture of the trachea, 613.
- Goitre, 660, 701; aerial, 579; cystic, 579, 703, 704, 711, (hydatid) 705, (parenchymatous) 705; exophthalmic, 705; fibro-cystic, 703; fibrous, 704, 711; glandular, 703; post-sternal, 703, 710; of pregnancy, 701.
- Gold, chloride of, in laryngitis (chronic), 486; sore throat (chronic), 196.
- GOSCHLER, on cystoma of pharynx, 250.
- Gouge, the, in chronic folliculous sore throat, 196; -forceps, laryngeal, 555; naso-pharyngeal, 262.
- GRAEFE, his coin-catcher, 316; on securing pharyngeal tumors before evulsion, etc., 267.
- GRAHAME, on phagedenic sore throat in phthisis, 101.
- GRAVES, on exophthalmic goitre, 705, 706.
- GRAY, on mercurial salivation as a cause of acute laryngitis, 421; sudden death from spasm in acute laryngitis, 425.
- GRECO, on neuroma of nasal passage, 393.
- GREEN, on chronic follicular (tubercular?) sore throat, 182, 183; croup, nitrate of silver locally in, 467; elongated uvula, 192; follicular glands at vault of pharynx, 253; injections into bronchi, 680; laryngeal neoplasm, removal of, through the mouth, 547; phthisis, connection of enlargement of the tonsils with, 226; pleura, penetration of, in foreign body in œsophagus, 318.
- GROSS, his appliances for removal of foreign bodies from nasal passages, etc., 389; nasal polyp forceps, 396; tonsil écraseur, 232; on epistaxis, fatal hemorrhage from, 375, 377; epithelioma, simulation of, by inherited syphilis of nose, 125; erysipelatos laryngitis, 436, 437, 438; foreign bodies in the air-passages, 616; fracture of nasal

- septum, 412; œsophagotomy, 322; sarcoma of tonsil, 235; sutures in wounds of œsophagus, 308; tamponing posterior nares, 382; turbinated bone, removal of, in certain cases of nasal myxoma, 398; wounds of pharynx, 275; of larynx and trachea, 604.
- GROSSMAN, on lupus of the larynx, 529.
- Growths, morbid, of larynx (in measles), 110, (phthisis) 568, (syphilis) 124. [See Morbid Growths.]
- Gualacum, in anesthesia of the palate, 216; phlegmonous sore throat, 94.
- GUENTHER, on œsophagotomy, 323.
- GUÉRIN, on subcutaneous tracheotomy, 667.
- GUERLT, on cystic tumors of the neck, 698; fistule of the infra-hyoid bursa, 289; fracture of the larynx and trachea, 606, 610.
- GUERSANT, on abscess of the septum narium, 407.
- GUIJO, on fistule of the pharynx, 277.
- GUILLOT, on goitre of pregnancy, 701.
- Guillotines, laryngeal, 563; tonsil-, 230.
- GUISE, on laceration of the œsophagus, 307.
- Gummata, 122; in larynx, 520; palate, 122; septum narium, 408.
- Gunshot wounds, of larynx and trachea, 603.
- Gurjun oil, in lepra, 533.
- GUSSENBAUER, his artificial vocal apparatus, 682, 684; on excision of the larynx, 681.
- GUTTANI, his method of œsophagotomy, 321.
- GUTTMAN, on exophthalmic goitre, 710.
- GUYON, on access of leeches to air-passages, 614.
- Hæmoptysis, in acute thyroiditis, 700.
- Hæmostatics, in epistaxis, 379.
- HAGER, his anti-catarrhal mixture for coryza, 339.
- Hair-pencils for local applications, 491.
- Hair-pins for extemporaneous blunt hooks or retractors, 14, 672.
- HALL, on spasm of the larynx, 628.
- Hamamelis, in epistaxis, 390.
- HAMBURGER, on auscultation of the pharynx and œsophagus, 81.
- HAMILTON, on scrofulous sore throat, 200.
- HARTLEY, on cystoma of pharynx, 250.
- Hay-fever, 340.
- HAYDEN, on fatal œdema of larynx in nephritis, 446.
- HAYWARD, on Rouge's operation for direct access to nasal passages, 373.
- Headache, of hysterical paralysis (laryngeal) 642; sore throat (chronic folliculous), 181.
- Head-tones, mechanism of the production of, 61.
- Hearing, impairment of, in adenoid hypertrophy at vault of pharynx, 260; hypertrophy of tonsils, 226; sore throat, 91, (chronic folliculous) 191.
- Heart, death by clots in, in diphtheria, 155; fibrinous deposits in, 172.
- Heat, use of, in warming mouth-mirrors, 27.
- HEATH, on sarcoma of palate, 210.
- HEINE, on exsection of larynx, 681; resection of thyroid cartilage, 525.
- HEITZMANN, on the cryptogamia of diphtheria, 134.
- HELBER, on compression of œsophagus from mediastinal carcinoma, 298.
- HELMHOLTZ, on quinia in hay-fever, 341.
- Hemicrania, periodic, from rhinoliths, 389.
- Hemorrhage, after excision of tonsils, 232, uvula, 219; from internal carotid artery, in pharyngeal abscess, 247; in laryngitis (syphilitic), 520; nasal tumors, 375; naso-pharyngeal tumors, 265; pharyngitis (ulcerous), 187; sore throat, 187; tracheitis (ulcerative), 471; tracheotomy, 671; wounds of pharynx, 274, of larynx and trachea, 602, 603.
- Hemorrhagic œdema of the larynx, 457; stasis in the uvula, 89.
- HENLE, on the fistulous tract of tracheotomy, 679.
- HENNIG, on swallowing of the tongue, 628.
- HERING, on tuberculosis of the larynx, 499.
- Herpes, facial, in sore throat, 105; pharyngeal, etc., 103.
- Herpetic sore throat, 103.
- HESLOP, on tincture of chloride of iron in diphtheria, 166.
- HEUSINGER, on congenital fistules of the neck, 597.
- HEUTER, on sarcoma of tonsil, 235.
- HEYMANN, on deformities of the pharynx, 276.
- HILLMAN, on abscess of the larynx, 441.
- HILTON, on anosmia, 402.
- History, brief, of laryngoscopy, 18.
- Hives, 458.
- Hoarseness, in carcinoma of larynx, 582; croup, 461; laryngitis, 425, 430, 435, (chronic) 483; morbid growths of larynx, 539; œdema of larynx, 448; its relief by deglutition of water, 187.
- HODGINSON, on noosing the uvula, 72.
- HOLMES, on imperforate œsophagus, 287.
- HOLTHOUSE, on escape of tracheotomy-tube into air-passages, 664, 678.
- HOME, on croup, 149.
- HOMOLLE, on scrofulous sore throat, or lupus of the throat, 202.
- Hooks, blunt, for extracting foreign bodies from the œsophagus, 316; extemporaneous, from hair-pins, 14, 672.
- Hops, in phlegmonous sore throat, 95.
- HORNER, on chloride of lime in chronic coryza, 368; loss of voice from inclusion of pneumogastric nerve in ligature of carotid artery, 650.
- HOURELOUP, on wounds of larynx and trachea, 601; œsophagus, 306.
- HOUSE, on escape of tracheotomy-tube into air-passage, 664; sudden inundation of air-passages during anæsthesia, 614; tracheotomy in emergency, 665.
- HOUSTON, on imperforate œsophagus, 288.
- HOWARD, on extemporaneous tracheotomy-tube in emergency, 665.
- HUMBOLDT, on epistaxis, 376.
- HUNT, on fracture of larynx, 609; mycelium in œdema of nasal septum, 409.
- HUNTER, on follicular glands at vault of pharynx, 253.
- Hydatid cyst, of thyroid gland, 705; tonsil, 235.
- Hydrophobia, tracheotomy in, 660.
- Hygienic precautions against contracting diseases of the throat, etc., 7, 88, 156, 345.

- Hygroma, of pharynx, 272; thyro-hyoid bursa, 697.
 Hyoid bone, fracture of, 606; luxation of, 276; synovial bursa of, 272; wounds of, 601.
 Hyoscyamus, in laryngitis (chronic), 485, 493; sore throat, etc. (chronic), 198.
 Hyperchondrosis, concentric, of thyroid cartilage, 525.
 Hyperesthesia, of larynx, 625, 643; nasal passages, 405; œsophagus, 323; palate, 216; pharynx, 279.
 Hyperosmia, 404.
 Hyperplasia, of retro-nasal gland-tissue, 253.
 Hypertrophic chondritis vocales, 478, 482.
 Hypertrophy, of larynx, 543; œsophagus, 291; pharyngeal tonsil, 253; tonsils, 225; uvula, 218; vocal cords, 478, 482.
 Hypnotics, in coryza, 339; sore throat, 97.
 Hypodermic injections (local) in enlarged tonsils, 234; of morphia in sore throat (phlegmonous), 95; strychnia in paralysis of the larynx, 639, 649, palate, 218.
 Hyposulphites, the, in diphtheria, 156, 162; influenza, 344.
 Hysteria, aphonia of, 642; from elongated epiglottis, 56; spasmodic cough of, 633; vagaries of, 320.
 Ice, in croup, 468; diphtheria, 163; hemorrhagic œdema of larynx, 458; laryngitis (acute), 433, (traumatic) 439; sore throat (acute), 87.
 Iceland moss, in chronic sore throat, 198.
 Idiosyncratic coryza, 340.
 Ignatia in laryngitis (chronic), 494; paralysis of œsophagus, 327, palate, 217.
 Illumination, artificial, 37; direct, 38; accessory apparatus for augmenting, 35-43; natural, 36.
 Image, normal laryngoscopic, 24, 52, 58, 60, 61, (magnified) 34; reflected, of nasal passages, 16; rhinoscopic, 74.
 Impediments, to laryngoscopic examinations, etc., 27.
 Imperforate œsophagus, 286.
 Incandescent cautery, in arresting hemorrhage, 210; fistule of larynx, 599; tracheotomy, 667. [See Cautery, and Galvano-cautery.]
 Incarceration of the epiglottis, 628.
 Indians, their method of warding off colds, influenza, sore throat, etc., 345.
 Infants, syringing nasal passages of, 339; syphilitic sore throat, etc., in, 127; tolerance of, to accumulations in the air-passages, 163, 464.
 Infection, of diphtheria, 135; seclusion from, 156.
 Inflammatory affections of the throat, causes of, 5.
 Influenza, 342; bronchial, 313; cerebral, 343; guttural, 343; intestinal, 343; typhoid, 343.
 Infra-glottic laryngoscopy, 48; œdema, 455.
 Inhaler, nasal, 339. [See Spray-producers.]
 Inhalation or inspiration of irritants, a cause of disease of the throat, 6; in croup, 466, 468; diphtheria, 168; laryngitis (chronic), 485.
 Injections, into bronchi, 680; larynx and trachea, 680, (percutaneous) 469.
 Injuries, external, a cause of epistaxis, 378; of the œsophagus, 306.
 Innervation, death by, in diphtheria, 155.
 Insects, in air-passages, 614; frontal sinuses, 418; nasal passages, 389; œsophagus, 311.
 Inspection, direct, of nasal passages, 13, 17, throat, 9; indirect (by reflection), 16, 17; infra-glottic, 49; laryngoscopic, 50; rhinoscopic, 73; tracheal, 67, 68.
 Inspiration, the larynx in, 58. [See Inhalation.]
 Insufflation, of alum in diphtheria, 168; of powders in general, 96, 493.
 Inter-arytenoid commissure and fold, 65, 502.
 Internal carotid artery, aneurism of, in pharynx, 251.
 Intestines, disorders of, a cause of sore throat, 181; of spasm of larynx, 628; in influenza, 342, 343.
 Inunction, mercurial, 129, 160; in diphtheria, 162.
 Involution of the trachea, 579.
 Iodine and its preparations, in coryza (acute), 338, (chronic), 363, 366, 372; diphtheria, 162, 163, 168, 169; enlarged tonsils, 228; goitre, 708, 711; laryngitis (chronic), 485, 486, 494, (syphilitic), 523, 524, (tuberculous) 515, 516; œsophagitis, 284; paralysis (bulbar), 329, of larynx, 645; pharyngitis (atrophic), 200; sore throat (chronic), 197, 198, (scrofulous) 202, (syphilitic) 126, 130.
 Iodism, œdema of larynx from, 126, 446.
 Iodoform, in coryza (chronic), 363; hyperesthesia of larynx, 625; laryngitis (chronic), 493, (syphilitic) 524, (tuberculous) 515; lepra, 533; sore throat (chronic), 196, 197, (syphilitic) 130.
 Ipecacuanha, in croup, 466; diphtheria, 164; powder of, a cause of idiosyncratic coryza, 340.
 Iron, preparations of, in carcinoma of larynx, 585; coryza (acute), 336, (chronic) 364; croup, 464, 467; diphtheria, 158, 165, 166; enlarged tonsils, 228; goitre, 711; laryngitis (chronic), 485, 486, 494, (tuberculous) 515; neuralgia of larynx, 625, palate, 216; sore throat (erysipelatous), 114, (phagedenic) 103; spasm of larynx, 630; tumor of trachea, 578.
 IRWINE, his artificial vocal apparatus, 684.
 ISAMBERT, on laryngitis (syphilitic), chronic acid in, 524, (tuberculous) 500; sore throat (acute tuberculous), 115, (syphilitic), 120; tracheotomy (instantaneous), 672.
 ISHAM, on olfaction, 404.
 JACOBI, on diphtheria in the new-born, 133.
 JAMES, on tuberculous laryngitis, 500.
 Jaw, mechanical support for lower, in atrophic pharyngitis, etc., 200.
 JENNER, on diphtheria, extensive deposit in, 140; extension of pseudomembrane of, 141; identity of croup with, 145; laryngeal, 155; nitrate of silver in, 167; swollen glands in, 138; vegetable organisms in, 134.
 JODIN, on diphtheria, calomel in, 161; tincture of chloride of iron in, 166; vegetable organisms in, 134.
 JOHNSON, his method of laryngoscopy, 45; on cystic goitre, 703; paralysis of larynx, 650; rupture of trachea, 613; spontaneous sloughing of naso-pharyngeal tumor, 272.

- JOHNSTON, on foreign bodies in the air-passages, 615.
- JONES, on cerebral paralysis from influenza, 344.
- JORDAN, on death by innervation in diphtheria, 155.
- Juniper, in chronic coryza, 366.
- JUNOD, his boot in epistaxis, 379.
- KAROP, his tracheotomy tube, 676.
- KELLY, on compression of œsophagus from effusion into pericardium in acute rheumatism, 298.
- KJERNER, on suffocation from rupture of abscess in air-passages, 614.
- KNAPP, on the nasal douche, 359.
- KNIGHT, on anosmia, 402.
- Knives, laryngeal, 560, 561, 565, (guillotine) 563.
- KODERICK, on removal of laryngeal neoplasm through the mouth, 547.
- KOEBERLE, on exsection of the larynx, 681.
- KOELLIKER, on the erectile venous plexuses of the turbinated bones, 333.
- KOENIG, on œsophagotomy, 323.
- KOHLRAUSCH, on the erectile venous plexuses of the turbinated bones, 333.
- KOMM, on spontaneous absorption of naso-pharyngeal tumors, 270.
- KOPP's asthma, 715.
- KRAMER, his elastic head-band for supporting reflector, 36.
- Krameria, in chronic coryza, 368.
- KRISHABER, his illuminating apparatus, 39; piloting inner tracheotomy-tube, 674; on chancre of the epiglottis, 119; extraction of foreign body from air-passages, 620; tracheotomy by the thermocautery, 667.
- KUECHENMEISTER, his rhineuryntor for tamponing the posterior nares, 382.
- KUEHNE, on pharyngocele, 278.
- LABAT, on lipoma of palate, 211.
- Labio-glossopharyngeal or laryngeal paralysis, 328.
- LABUS, on dilatation of stenoses of larynx, 590.
- LACAUCHIE, on adenoid tissue at vault of pharynx, 285.
- Laceration of the œsophagus, 307.
- Lachrymal bone, caries, etc., of, in chronic coryza, 352.
- Lactic acid, in croup, 466.
- Lactucarium, in chronic sore throat, 198.
- LAILLER, on hemorrhage from posterior palatine artery in ulcerative pharyngitis, 187.
- LAMBLIN, on lepra of the larynx, 531.
- Laminaria, tubes of, for maintaining patency of nasal passages, 364, 411.
- LANDRIEUX, on fatal hemorrhage in scrofulous angina, 187.
- LANGENBECK, his method of closure of cleft of hard and soft palate, 213; of tracheotomy, 669; sound for detecting position of foreign bodies in œsophagus, 312; on exsection of the larynx, 681, 686; deglutition of necrosed nasal bones, 384; impaction of coin-catcher in the œsophagus, 311; nasal bones as foreign bodies in the œsophagus, 311; laryngotomy (supra-thyroid), 575; œsophagotomy, 322; resections for access to naso-pharyngeal tumors, 269; sarcoma of the tonsils, 235, œsophagotomy in, 321.
- Lancet, laryngeal, 560.
- LANGHANS, on carcinoma of trachea, 586.
- LARGHI, on excision of upper maxillary bone behind the everted upper lip, 269.
- LARREY, on acquired goitre, 702; aerial goitre, 579.
- Laryngeal phthisis, 497, 508.
- Laryngismus, 626, 660, 715.
- Laryngitis, acute, 420, 660; catarrhal, 420, 474, 660, of pulmonary tuberculosis, 498; chronic, 446, 473, of phthisis, 497, 631; erythematous, 420; erysipelatos, 113, 436; fetid (chronic), 476; mucous, 420; œdematous, 442; parenchymatous, 433; phlegmonous, 433; plastic, 433; pharyngo- (parenchymatous), 498, of acute tuberculosis, 498; pseudo-membranous, 458, 660; purulent, 433; rubeolar, 109, 446; scarlatinous, 446; sero-purulent, 433; serous, 433; submucous, 433, 442; syphilitic, 446, 518; traumatic, 98, 195, 421, 429, 438, 445; tuberculous, 446, 497, 501; ulcerous, 477; variolous, 107, 446.
- Laryngo-pharyngeal sinuses, 57; affections of the, 686.
- Laryngo-pharyngitis, chronic, 179, 478; -tracheitis, chronic, 424, 478; exudative, 458; membranous, 458; tuberculous (chronic), 497.
- Laryngoscopes, hand-, 38. [See Laryngoscopy.]
- Laryngoscopy, 17; auto-, 43; demonstro-, 46; history of, 18; infra-glottic, 48, 49; recipro-, 46; tracheal, 48.
- Laryngostroboscopy, 62.
- Laryngotomy, 660, 661, 668; lateral, 574; sub-hyoid or supra-thyroid [see also Pharyngotomy], 544, 575; for removal of foreign body, 621, of morbid growths, 548, 568, 573; inspection through wound of, 48.
- Laryngo-tracheotomy, 660, 661.
- Laryngo-tracheitis (pseudomembranous), 660.
- Larynx, ablation of, 585; abscess of, 598, (diffuse) 433; adenoma of, 536; anesthesia of, 577, 624; carcinoma of, 536; catheterization of, 679; chondritis of, 525; compression of by pharyngeal tumors, 250; contusions of, 612; croup of, 458; cystoma of, 536; dilatation of stenoses of, 588; diphtheria of, 136, 144; displacements of, 692, 693; dropsy of, 442; epithelioma of, 536; eversion of ventricle of, 576; exsection of, 585, 680; fibroma of, 536, 543; foreign bodies in, 660; hyperesthesia of, 625; hypertrophy of, 533; injections into, 469, 680; lepra of, 531; lipoma of, 536; lupus of, 529; morbid growths of, 534, 660; myxoma of, 536, 543; muscles of, 62; neuralgia of, 626; œdema of, 107, 111, 424, 442, 507, 660, (chronic) 510, (hemorrhagic) 424; occlusion of [see Stenoses], 628; papilloma of, 536, 542; paralysis of, 176, 636, (functional) 641, 644; perforation of, in small-pox, 107; perichondritis of, 525; rupture of, 612; sarcoma of, 536; sore throat (chronic folliculous) of, 185; spasm of, 489, 626, 660, 715; stenosis and stricture of, 586, 660; syphilis of, 123, (mucous patches) 121, 518;

- tubage of, in croup, 468; tuberculosis of, 497; wounds of, 598.
- LATOUR, on rupture of trachea in croup, 613.
- LAUENSTEIN, on rupture of trachea, 613.
- LAURENT, on parasites in the œsophagus, 311.
- LAVERAU, on œdema of the larynx, 86.
- LAWRENCE, on tracheotomy, 662.
- LAWRIE, on œdema of larynx from iodism, 446.
- Laxatives, in chronic sore throat, 178.
- Lead, *acetate of*, in chronic sore throat, 197; chronic coryza, 362; chronic laryngitis, 485; *nitrate of*, in chronic coryza, 362; chronic laryngitis, 486.
- LEBERT, on diffuse cervical abscess, 690.
- LE CLERC, on tracheotomy by actual cautery, 667.
- LEE, on escape of tracheotomy-tube in air-passages, 664, 678; fatal enteritis from copper coin in intestine, 318; thymitis, 714.
- Leeches, as foreign bodies in the air-passages, 620.
- LEEPER, on epistaxis, 379.
- LEEUWENHOEK, on vegetable organisms in the throat, 135.
- LEFFERTS, on cleansing nasal passages, 355; eversion of the ventricle of the larynx, 544; pharyngotomy (sub-hyoid) for removal of straddling foreign body impacted in the walls of the larynx, 576, 624; lupus of the larynx, 529.
- LEGG, on anosmia, 403.
- Lemon-juice, in diphtheria, 168.
- Lenses, condensing, for increasing illumination, 38; magnifying objects in examinations of throat, etc., 12, 34.
- Lepra, of the larynx, 531.
- LETENNEUR, on adenoma of palate, 209.
- LEUTHLEN, on bromine vapor in diphtheria, 170.
- LEVRET, his efforts at laryngoscopy, 18.
- LEWIN, on chloride of ammonium in chronic coryza, 370; molten caustic, 96; œsophagoscopy, 68.
- LIEL, WEBER, on the nasal douche, 379.
- Ligature, the, in removal of goitre, 712; naso-pharyngeal tumors, 267.
- Lime, expedients for evolving fumes of, 174; -fumes, and lime-water, in coryza (acute), 340, (chronic) 363, 368; croup, 464; diphtheria, 168, 169, 172, 174; *phosphate of*, in spasm of larynx, 630.
- Lingual glands, enlarged in chronic laryngitis, 478; sinuses, 54, affections of the, 687.
- LINHART, on surgical wound of pharynx, 273.
- Linseed meal, provocative of idiosyncratic coryza, 341.
- Lipoma, of larynx, 536, 543; œsophagus, 302; palate, 211; pharynx, 249, 250; tonsil, 235.
- Lips, chancre of the, 120.
- Liquids, total abstinence from, in acute coryza, 338.
- LISTON, on arrest of hemorrhage after excision of uvula, 219; dilatation of stenosis of the larynx, 589, 606; wounds of the larynx, 601, 603.
- LOCKING, on acute laryngitis, 421.
- Locomotor ataxia, 655.
- London paste, in enlarged tonsils, 233; laryngeal neoplasms, 550; sore throat (chronic follicular), 196.
- LONG, on rupture of the trachea, 612, 613.
- LORI, his multiple mirrors, 35.
- LOUIS, on follicular ulcerations in tuberculous laryngitis, 504.
- LOUIS' angina, 688.
- Lozenges, astringent, in sore throat, 88, (chronic) 179, 198.
- LUDERS, on wounds of the œsophagus, 306.
- LUDLOW, on salicylic acid in chronic coryza, 572.
- LUDWIG'S angina, 688.
- LUER, his laryngeal forceps, 554; pea-valved tracheotomy-tube for phonation, 679.
- Lungs, the, in influenza, 342; tuberculous laryngitis, 500.
- Lupoid sore throat, 201.
- Lupus of the larynx, 529; nasal passages, 383; palate, 208; throat, 202.
- LUSCHKA, on anomaly of horn of thyroid cartilage, 608; congenital occlusion of nasal passages, 386; dilatation of the œsophagus, 298; follicular glands at roof of pharynx, 254; lateral glosso-epiglottic folds, 54; lateral laryngotomy, 574; pharyngeal bursa, 254; pharyngeal tonsil, 257; pharyngo-palatine muscles, 204.
- Luxation of hyoid bone, 276.
- Lymphadenitis, external cervical, a cause of pharyngeal abscess, 241; pharyngeal (chronic), 179, 180; retro-pharyngeal, 240; tonsillar, 91.
- Lymphoma of tonsils, 234.
- Lympho-sarcoma of tonsils, 235.
- MACKENZIE, his amygdalatome, 230; bracket for supporting illuminating apparatus, 39; brush-holders, 490; dilator for stenosis of larynx, 592; écraseur, 565; electrodes (laryngeal), 646; forceps, 555, 556; knife-loops or rings, 565; on angioma of larynx, 543; auscultation of pharynx and œsophagus, 82; causes of development of morbid growths in the larynx, 534; cauterization of enlarged tonsils, 233, of laryngeal neoplasms, 550; division of thyroid cartilage for excision of cicatricial tissue, 524; electricity in paralysis of the larynx, 646; eversion of the ventricle of the larynx, 544; epithelial carcinoma of the larynx, 545; fruit-paste for lozenges, 198; injections in cystic goitre, 711; galvanocautery (laryngeal) 568; lepra of the larynx, 531; London paste in enlarged tonsils, 233; nitrate of silver in diphtheria, 167; paralysis of the larynx, 638, 657; post-œsophageal abscess, 248; recipro-laryngoscopy, 46; sore throat (chronic follicular), 196; stricture of the trachea, 587; sub-hyoid laryngotomy, 548, 575.
- MACNAMARA, on foreign bodies in larynx, 617.
- Macule flavæ, 65.
- Magnesia, sulphate of, in coryza, 339; sore throat, 94.
- Magnifying lens, in examinations of the throat, etc., 12, 34.
- MALGAIGNE, on suicidal wounds, 600; supra-thyroid laryngotomy, 574.
- Malignant pustule, a cause of ulcerous sore throat, 101, scarlatina, 110.
- Malt, extract of, in spasm of larynx, 630; tuberculous laryngitis, 515.

- MANDL, on endermic use of morphia in sore throat, 95; multiple gummata in larynx, 520; laryngitis (parenchymatous), 422, (tuberculous) 500.
- Manipulation, external, of the larynx, 23, mechanical, in paralyses of the larynx, 640, 649, 650; of laryngoscopic mirror and other appliances, 22, 169, 488.
- MARCEY, on abscess of larynx, 441; tuberculous laryngitis, 497.
- MARIN, on epistaxis, 378.
- MARSH, on rupture of the trachea, 613.
- MARSHALL, on diphtheria in the new-born, 133; rupture of the trachea, 613.
- Marsh-mallow, in chronic sore throat, 198.
- MARTIN, his tracheotomy-tube, 662; on tracheotomy, 662.
- MARTINIÈRE, LA, his unique case of foreign body in the larynx, 614.
- MASCARO, on occlusion of œsophagus by tumor, 298.
- MASING, on escape of tracheotomy-tube into air-passage, 664.
- MASS, on exsection of larynx, 682; influence of epiglottis in application of artificial vocal apparatus, 684.
- Massachusetts General Hospital, records of, in an epidemic of influenza, 344.
- MASSEI, on leeches as foreign bodies in larynx, 620.
- MAUDUYT, on electrolysis in cervical tumors, 694.
- MAURY, on extirpation of thyroid gland, 713; syphilitic stricture of œsophagus, 290, 291.
- Maxillary bone, superior, caries of, 351; partial or complete removal of, for access to nasal tumors, 298, naso-pharyngeal tumors, 269; resection of, behind upper lip, 269.
- MAXWELL, his early efforts in laryngoscopy, 18.
- MEARS, his toothed forceps, 194; on cleft palate, 213.
- Measles, as a cause of ulcerous sore throat, 101; laryngitis of, 109; mumps in, 696; œdema of larynx in, 446; pseudo-membrane in, 109; sore throat of, 109; ulceration of larynx in, 110, 446.
- Mechanical action of topical agents in diphtheria, 169.
- Mediastinum, carcinoma of, 298; tumors of, 694.
- MEIGS, on alum in croup, 464, diphtheria, 164; bronchial casts in croup, 462; fatal syncope in diphtheria, 155.
- Membrane, false or pseudo, of croup, 460, diphtheria, 139; necessity for mechanical removal of, after the incision into the air-passage, 171; web of, 536, cutaneo-pharyngeal, in stenosis after suicidal wound of larynx, 587, in laryngitis (syphilitic), 521, (traumatic) 587, (tuberculous) 506.
- Membranes, serous and synovial, affected in influenza, 342.
- Membranous sore throat, simple or common, 103.
- Meningitis, from chronic coryza, 352, mumps, 696; spinal (syphilitic), 123.
- MENZEL, on percutaneous injections of iodine in diphtheria, 123; foreign bodies in œsophagus in cases of stricture of œsophagus, 311.
- MÉPLAIN, on myxoma of palate, 210.
- Mercurialization, œdema of larynx from hyper-, 446.
- Mercury, a cause of stomatitis, 118, œdema of larynx, 446; *acid nitrate of*, in laryngitis (chronic), 486, (syphilitic) 523; morbid growths of the larynx, 548, 551; sore throat (phagedenic), 103, (syphilitic) 127; *bichloride of*, in coryza (chronic), 366, 372; laryngitis (syphilitic), 523; sore throat (chronic folliculous), 197, 198, (syphilitic) 126; *sulphate of*, in croup, 464, 466; in diphtheria, 164.
- MERKEL, on lateral glosso-epiglottic folds, 54; pharyngo-palatine muscles, 204.
- Meso-arytenoiditis, 422.
- MEYER, on adenoid vegetations in the naso-pharyngeal cavity, 259; electrolysis in cervical tumor, 694; goitre, 710.
- Mezereum, in paralysis of the palate, 217.
- MICHAUD, on acquired goitre, 701.
- MICHEL, on exostoses of nasal fossæ, 400.
- MIDDELDORFF, on galvano-cautery for removal of laryngeal growths, 566, nasal tumors, 397, naso-pharyngeal tumors, 270; impaction of epiglottis in larynx, 615; tumor in œsophagus, 303.
- Miliary tuberculosis of the larynx, 497, 498; throat, 501.
- Milk, local use of, to moderate effects of nitrate of silver, 195; syphilitic infection from breast, 119.
- MILLER, on spasm of larynx in the new-born, 627.
- Mirrors, laryngoscopic, 20, 31, (multiple) 35; introduction of, as an emotional means of cure in paralyses of the larynx, 646; rhinoscopic, 71.
- MITCHELL, on influenza, 342.
- MOLLER, on strychnia in anosmia, 403.
- MONDIÈRE, on pharyngeal abscess, 241; retro-pharyngeal abscess, 247.
- MOORE, on œdema of larynx, 444.
- Moos, on the nasal douche, 359.
- Morbid growths, of frontal sinus, 416; larynx, 534, 660; palate, 209; pharynx, 249; nasal passages, 393; nasal septum, 412; œsophagus, 302; thyroid gland, 579; tonsils, 234; trachea, 576, 660; uvula, 220.
- MORGAGNI, on œdema of the larynx, 534.
- Morphia, in coryza (chronic), 363; hyperæsthesia of larynx, 625, palate, 216; laryngitis (tuberculous), 516; sore throat (acute), 87, (chronic) 495, (phlegmonous) 94; local anesthesia of larynx by, 577.
- MORTON, on transfusion of blood in epistaxis, 382.
- MOSLER, on sternutation, 405.
- MOTT, on exostoses of nasal fossæ, 400.
- MOURA, his method of examination by reflected solar rays, 36; on degeneration of muscle in chronic laryngitis, 478.
- MOXON, on eversion of the ventricle of the larynx, 544.
- Motor paralyses of the larynx, 636.
- Mouth-distenders, 29, 229; -gags, 213.
- MOYNIER, on swollen glands in diphtheria, 138.
- Mucous membrane, color of inflamed, 4, erosion or abrasion of, 3; normal secretion of, 2; gangrene of, 132; hypertrophy of, in chronic coryza, 346;

- retrenchment of exuberant folds of, 363; retro-nasal, in chronic folliculous sore throat, 191; sphacelus of, 132; ulceration of, 132; *patches* (syphilitic), 121; in larynx, 518; nasal passages, 383.
- Mucus, secretion or development of, 3.
- Mumps, 695.
- MURON, on tracheotomy by actual cautery, 667.
- Muscles, arytenoid, 63, (paralysis of) 652; aryteno-epiglottic, 64; constrictors, of the pharynx, 204; crico-arytenoid (lateral), 63, (posterior) 63; crico-thyroid, 63; laryngeal, 62; degeneration of, in chronic laryngitis, 478, in paralyzes of larynx, 654; palato-glossi, separate investment of, 206; pharyngo-palatine, 204; thyreo-pharyngo-palatine, 205; thyro-arytenoid, 64; thyro-epiglottic, 64; triceps laryngea, 64.
- MUSSEY, his mouth-gag, 213.
- Mycelium, in nasal fossae, 409.
- Myelitis, syphilitic, 123.
- Myoma of œsophagus, 303, palate, 211.
- Myrrh, in coryza (chronic), 363; sore throat, 95.
- Myxoma, of frontal sinus, 414; larynx, 536; nasal passages, 392, 398; nasal septum, 412; œsophagus, 303; palate, 210.
- Nail, the finger, in incising pharyngeal abscess, 248; tearing away laryngeal growths, 548, 553; metallic do., for ablation of naso-pharyngeal growths, 270.
- Nares, posterior, rhinoscopic view of, 74; tamponing, 381, 382, 400.
- Nasal bones, fracture of, 385; necrosis of, 352, with escape into œsophagus, 311, 384; calculi, 386, 388, 389; *donche*, 355, 356, 358; excreta, in influenza, 345; *passages*, abscess in, 374; adenoma of, 393; carcinoma of, 374; cleansing of, in coryza (chronic), 359, (fetid) 350, (infantile) 339, diphtheria, 172, influenza, 345; dilatation of stenosed, by tubes of laminaria, 385, silver, 364, 385; direct inspection of, 13; ecchondroma of, 393; examination of the throat and, 19; exostoses of, 399; fibroma of, 393; foreign bodies in, 386; image (reflected) of the, 16; in diphtheria, 140; sore throat (chronic folliculous), 190; myxoma of, 393, 398; neuroma of, 393; occlusion of, 384, 385, 391; osteoma of, 393; palpation of, 80; papilloma of, 393; parasites in, 389; stenosis of, 384; *polyps*, 393, 398; *septum* [see Vomer], abscess of, 407; cystoma of, 412; deflections of, 384, 410; ecchondroma of, 412; fracture of, 411; infiltration (submucous) of, 408; inflammation of, 407; myxoma of, 412; œdema of, 408; perforation of, 351, 408, 409; posterior, 74; resection (superiosteal) of, 411; sarcoma of, 412; ulcerations of, 348, 350; *tumors* [see detailed under Nasal Passages].
- Naso-pharyngeal cavity, adenoid vegetations in the, 259; *donche*, 359; forceps, 262; syringe, 261; tumors, 263, a cause of epistaxis, 375, spontaneous absorption of, 270, sloughing of, 270; pharyngitis, 422.
- NAVRAIL, on chondritis vocalis hemorrhagica, 425; membranous web between vocal cords, 521.
- Nebulizers, 197.
- Neck, congenital fistule of the, 288, 597; diffuse inflammation of the connective tissues of the, 688; tumors of the, 692.
- Necrosis, of larynx, after wounds, 602; chondrial, necessitating tracheotomy, etc., 660.
- Needles, progress of, from œsophagus to exterior, 319.
- NÉGRIER, on epistaxis, 378.
- NÉLATON, on naso-pharyngeal tumors, 264, division of soft palate for access to, 268, galvano-cautery in, 270; œdema of larynx from iodism, 446.
- Nematoid worms, a source of idiosyncratic coryza, 241.
- Nephritis, œdema of larynx in, 446.
- Nerves, compression of pneumogastric and spinal accessory a cause of spasm of the larynx, 628, 631; involvement of spinal and sympathetic in œsophageal carcinoma, 303; laryngeal, 637.
- NEUMANN, on the galvano-cautery in naso-pharyngeal tumor, 270.
- Neuralgia, of the larynx, 626; palate, 216; pharynx, 279.
- Neuroma, of nasal passage, 393.
- Neuroses, of the larynx, 624; œsophagus, 323; palate, 215; pharynx, 221; uvula, 221.
- NIEMEYER, on the sulphate of copper emetic in croup, 466.
- Nitrate of silver [see Silver].
- NOBILING, on tuberculosis and carcinoma of the œsophagus, 303.
- Noose, palate-, 72.
- Nose, depression of, for access to naso-pharyngeal tumors, 269; flattening of, in syphilis, 126.
- Nostril, paralysis of, 405.
- NOTTA, on anosmia, 402.
- Nourishment, by enema in paralyzes of larynx, 639; by œsophageal tube in paralyzes of pharynx, 281.
- Nurses, gonorrhœal coryza of, 340; wet-, admissibility of syphilitic, 129.
- Nutrition, disorders of, a cause of spasm of larynx, 628.
- O'BRIEN, on rupture of larynx and trachea, 612.
- Occlusion, of larynx, 628 [see Stenosis]; nasal passages, 384, 385; œsophagus, 298; pharynx, 123.
- œdema, of epiglottis, 92; glottis, 442; larynx, (acute), 331, 442, (chronic) 454, 510, 520, (hemorrhagic) 457, (infantile) 245, (infra- or sub-glottic) 107, 455, from iodide of potassium, 126; palate, 91, 111; pharynx, 91; uvula, 91, 111, 220; retropharyngeal abscess, 239; sore throat (acute), 87, (phlegmonous) 93, (syphilitic) 124; wounds of larynx, 603.
- OERTEL, on diphtheria, protracted pharyngeal involvements in, 136, steam in, 173, swollen glands in, 138, vegetable organisms in, 134; on laryngostroboscopy, 62.
- œsophageal, forceps, 315; nets, 316; probang, 317; snares, 316, 317; sounds, 312; tube, 281.

- Œsophagismus**, 324.
- Œsophagitis** (acute), 282, (chronic) 281, (traumatic) 284.
- Œsophagoccele**, 298.
- Œsophagoscopy**, 68; anatomical obstacles to, 69.
- Œsophagotomy**, 296, 319, 321.
- Œsophagus**, abscess of, 247; anesthesia of, 323; auscultation of, 81, 292; carcinoma of, 303; catheterization of, 293; compression of, 297; constriction of, 297; cramp of, 324; dilatation of, 298; diphtheritic deposit in, 140; diverticulum of, 300; excision of part of, 297; fibroma of, 302; fistule of, 288; foreign bodies in, 310; hyperesthesia of, 323; imperforate, 286; injuries of, 306; laceration of, 307; lipoma of, 302; myoma of, 302; myxoma of, 302; neuralgia of, 323; neuroses of, 323; occlusion of, 298; papilloma of, 302; paralysis of, 175, 325; parasites in, 311; perforation of, 309, 318; rupture of, 307; rupture of retro-œsophageal abscess into, 248; sarcoma of, 318; spasm of, 319, 324; stenosis of, 289, (extraneous) 297; stricture of, 289, 290, 324, (spasmodic or spastic) 324, dilatation of, (forcible) 295, (mechanical) 294, division of, 295, gastrotomy for, 290; ulceration of, 285; wounds of, 306.
- OGLE**, on anosmia, 402; escape of tracheotomy-tube into air-passage, 664, 678; imperforate œsophagus, 287; pharyngeal abscess, 242.
- Oil**, sweet, in chronic laryngitis, 495.
- Ointments**, mercurial, in coryza (chronic), 363; syphilitic sore throat of infants, 130.
- Oleo-resin of cubeb** in sore throat (chronic), 198.
- Olfaction**, 404.
- OLIVER**, on external manipulation in certain forms of aphonia from paralysis of vocal cords, 649.
- OLIVIER**, on osseous tumors of nasal passages and the sinuses of the face, 393.
- OLLIVIER**, on progressive bulbar paralysis, 328.
- Opium**, and its preparations [see also *Morphia*], in coryza (acute), 336, 338, (chronic), 363; croup, 466; laryngitis (chronic), 485, 495; nasal polyps, 396; sore throat (chronic), 198, (membranous) 106, (phlegmonous) 95.
- OPFOLZER**, on rupture of the œsophagus, 307.
- ORFILA**, on traumatic œsophagitis, 284.
- Organisms**, vegetable, in diphtheria, 133; sore throat, 92.
- Ossification**, of laryngeal cartilages, 511, 669.
- Osteitis**, cranial, 697.
- Osteoma**, intercranial, a cause of epistaxis, 376; of frontal sinus, 417; nasal passage, 393, 399; pharynx, 249; trachea, 579.
- Otitis**, external, in scarlatina, 111, media, in do., 111.
- Ox-gall**, in enlarged tonsils, 228.
- Oxygen**, in croup, 468.
- OZANAM**, on bromine in croup, 464; diphtheria, 162, 170.
- Ozena**, laryngo-tracheal, 476; nasal, 347.
- PACKARD**, on dressing wound of tracheotomy, 675; extirpation of cystic thyroid gland, 713; foreign body (key and safety-pin, passed per rectum), 318.
- PADLEY**, on expulsion of foreign bodies from the air-passage, 619.
- PAGE**, on tracheotomy in œdema of the larynx, 452.
- PAGET**, on congenital fistule of the œsophagus, 288.
- Palate**, abscess of, 208; adenoma of, 209; adhesions of, to adjacent strictures, 212; anesthesia of, 215; carcinoma of, 211, chancre of hard, 120; cystoma of, 210; division of, for access to nasopharyngeal tumors, 268; fibroma of, 210; hyperesthesia of, 30, 206; in diphtheria, 138, sore throat (chronic), 185, (membranous) 104, syphilitic) 122, 123; lupus of, 208; morbid growths of, 209; myoma of, 211; myxoma of, 210; neuroses of, 215; œdema of, 111; papilloma of, 210; paralysis of, 175, 216, 217; wounds of, 215; cleft-, 213; -elevator, 12, 70, 72; -noose, 72.
- Palatine folds**, chancre of, 120; normal appearance of, 12.
- Palatitis**, 206.
- Palato-pharyngitis**, 84.
- PALEY**, on soft rubber tracheotomy-tubes, 663.
- Palpation**, 78, 80, 245, 312; of nasal passages, 80; tonsils, 78; trachea, 623.
- PANCOAST**, on deflection of nasal septum, 411; extirpation of thyroid gland, 713; local anesthesia of the larynx, 577.
- Pancreas**, head of, simulating œsophageal carcinoma, 305.
- Pancreatin**, in tuberculous laryngitis, 514.
- Papilloma**, of nasal passages, 373; larynx, 536, 542, 548, 557, 559; œsophagus, 303; palate, 210; pharynx, 249; tonsils, 234; transformation of laryngeal, into epithelial carcinoma, 545.
- Papules**, guttural, 203.
- PAQUELIN**, tracheotomy by thermo-cautery of, 667.
- Paralyses and pareses**, bulbar (progressive), 327; bronchial, 458, 460; catarrhal, 216; cerebral, of influenza, 344; diaphragmatic, 644; diphtheritic, 132, 172, 175; glosso-pharyngeal, 327; glottic, 460, 462; labio-glosso-laryngeal, 327; laryngeal, 603, of aryteno-epiglottic muscles, 638, arytenoid muscle, 652, crico-thyroid muscles, 639, lateral crico-arytenoid muscles, 641, 650; posterior crico-arytenoid muscles, 460, 628, 630, 653, 658, 660, thyro-arytenoid muscles, 640, thyro-epiglottic muscles, 639; nasal, 405; œsophageal, 325; palatal, 216; pharyngeal, 279, 280; syphilitic, 123; uvular, 221; vocal, 505.
- Parasites**, in air-passages, 614; frontal sinus, 418; nasal passages, 389; œsophagus, 311.
- Parotitis**, 695.
- Pellitory**, in paralysis of palate, 217; pharyngitis (atrophic), 200.
- Pemphigus**, guttural, 203.
- Pencil**, caustic, 96.
- PENTZOLD**, on degeneration of nerves in paralyses of larynx, 654.
- Pepper**, in anæsthesia of palate, 216; paralysis of palate, 217.
- Pepsin**, in tuberculous laryngitis, 514.
- PERASSI**, on excision of enormous goitre, 702.

- Percussion, 82.
 Perforated reflectors, 37, 41.
 Perforation, of the aorta, 314; larynx, 107; nasal septum, 351; œsophagus, 309.
 Pericardium, effusion into, causing compression of œsophagus, 298; of recurrent laryngeal nerve with paralysis of larynx, 643; ulceration of, by foreign body in œsophagus, 314.
 Perichondritis, laryngeal, 508, 520, 654, (primary idiopathic) 525, 527, (traumatic) 602; vertebral (syphilitic), 123.
 PETIT, his œsophageal sponge-probang, 249.
 PFEUFFER, on hemorrhagic œdema of larynx, 458.
 Pharyngeal bursa, the, 254; tonsil, the, 76, 255.
 Pharyngitis, atrophic, 199, 234; catarrhal, 84, 430; chronic, 179, 227, 346, 351; erysipelatous, 113; follicular (chronic), 184; glandular, 179; granular, 179; impetiginous, 477; œdematous, 89; phlegmonous, 89, 90; simple, 84; suppurative, 89, 90; laryngo-, chronic, 179; naso-, 422; sicca, 199, 347.
 Pharyngo-epiglottic fold, 53; -laryngeal sinuses, 57, 79, affections of the, 686; foreign bodies in the, 312; -laryngitis, 478.
 Pharyngocele, 278.
 Pharyngotomy, 276, 319, 321, (sub-hyoid) 624.
 Pharynx, abscess of, 239, accidental rupture of abscess of, by probang supposed to be passed into larynx, 246, differential diagnosis of abscess of, from croup and from abscess and œdema of the larynx, 246, hemorrhage in abscess of, 247; adenoid tissue at vault of, 76, 254; adenoma at vault of, 253; adenoma of, 249; adhesions of adjacent structures to, 212; anaesthesia of, 278; asymmetric appearance of, 13; auscultation of, 81; carcinoma of, 250; chancre of, 120; constrictor muscles of, 204; cystoma of, 250; deformities of, 276; diverticulum of, 278; dry catarrh of, 199; enchondroma of, 249; examination of, 10; fibroma of, 10, 249; fibro-sarcoma of, 249; fistule of, 276; foreign bodies in, 274, 275, herpes of, 103; hygroma of, 272; hyperæsthesia of, 30, 279; hypertrophy (glandular, of), 253; in diphtheria, 138, 140; sore throat (chronic follicular), 185; inspection of the, best method for, 11; lipoma of, 249; lymphadenitis (chronic) of, 179; neuralgia of, 279, 320; neuroses of, 278; occlusion of, 123; osteoma of, 249; papilloma of, 249; paralysis of, 175, 279, 280; posterior wall of, 57; sarcoma of, 249; sensitiveness of, 24; spasm of, 279, 319; sphincter of, 204; stellate cicatrices of (syphilitic), 123; stenoses of, 124, 277; ulceration of the, 320; vault of the, 76; wounds of, 273, 601.
 Phlegmon, diffuse cervical, 688.
 Phonation [see Voice], larynx in, 60, 61; prevented by enlarged tonsils, 226; with Luer's pea-valved tracheotomy-tube, 679; artificial vocal apparatus for, 589, 593.
 Phosphorus, in anaesthesia of larynx, 625; dilatation of œsophagus, 302; diphtheritic paralysis, 176; neuralgia of larynx, 626; paralyzes of larynx, 638.
 Phthisis, chronic laryngitis of, 497; influence of, in development of morbid growths of the larynx, 535; from influenza, 344; laryngeal, 497, 508; membranous sore throat in, 105.
 PHYSICK, his tonsil-guillotine, 200.
 Phytolacca, in enlarged tonsils, 228.
 PICK, on escape of tracheotomy-tube into air-passage, 663, 678.
 Pigmented cartilages in tuberculosis, 506.
 PILCHER, on œdema of larynx in measles, 442.
 Pilots, for tracheotomy-tubes, 673, 674.
 Pine, oil of, in coryza (chronic), 363.
 PIROGOFF, on diffuse cervical abscess, 691.
 PITMAN, on tracheotomy in œdema of larynx, 452.
 Pityriasis, guttural, 203.
 Plastic, operations for fistule of larynx, 599.
 Platinum, bulbs and points, for molten caustic, 96, 550.
 Pleura, in influenza, 342; penetration of, in pushing foreign body down the œsophagus, 318.
 Pneumatocele, 598.
 Pneumonia, adynamic, 697; after croup, 466; diphtheria, 172, 175; œdema of larynx in, 466.
 Pocket illuminators, 41.
 POLAND, on carcinoma of tonsils, 237.
 Pollen, a cause of periodic coryza, 340.
 POLLOCK, on laryngotomy in phlegmonous laryngitis, 436.
 Polyps-forceps, 396.
 Polyps, nasal, 340; naso-pharyngeal, 263. [See also under Morbid growths.]
 POMEROY, his nasal inhaler, 339.
 PORTER, on asphyxia from foreign body in pharynx, 311; burrowing tonsillar abscess, 93; diffuse cervical abscess, 688, 691; epiglottic muscles, action of, 56; escape of tracheotomy-tube into air-passage, 663, 678; laryngitis (erysipelatous), 436, 437, (traumatic) 439, 440; œdema of larynx, 444, 455, sudden onset of, 447; spasm of trachea, 632; suffocation from spasm of larynx in ulcerous laryngitis, 631.
 Position, advantage of certain, in cough, 496.
 Potassa, caustic, in diphtheria, 167; sore throat (chronic), 196, (phagedenic) 103.
 Potassium, bromide of, in epistaxis, 379; hyperæsthesia of larynx, 625, palate, 30, 216, pharynx, 30; neuralgia of palate, 216; sore throat (chronic), 196; spasm of palate, 216; spasmodic cough, 635; carbonate of, in coryza (acute), 337; laryngitis (tuberculous), 515; chlorate of, in diphtheria, 159; laryngitis (chronic), 485; sore throat (phagedenic), 103; iodide of [see Iodine and its preparations]. œdema of larynx from use of, 126; nitrate of, in coryza (acute), 336; permanganate of, in carcinoma of larynx, 585; coryza (chronic), 359; diphtheria, 156; sulphate of, in enlarged tonsils, 228; spasm of the larynx, 630.
 Poultices, in croup, 464; diphtheria, 162.
 Powders, in coryza (chronic), 363, 369; laryngitis (chronic), 492, 493; sore throat (phlegmonous), 96.

- PRAT, on supra-thyroid laryngotomy for access to laryngeal neoplasm, 548, 575.
- Pregnancy, effect of influenza during, 343; goitre of, 701.
- PRIMUS, on opium in nasal polyps, 396.
- PRIOR, on pharyngeal abscess, 341.
- Probang, accidental rupture of pharyngeal abscess by, 246; laryngeal, 548; cesophageal, 317.
- Probe, flexible, for tamponing posterior nares, 381; lancet pointed, 560.
- Processes, the vocal, 65.
- Prophylaxis, against diphtheria, 156; sore throat, 88.
- Pseudo-croup, 626.
- Psoriasis, guttural, 203.
- Puncture and incision in hemorrhagic oedema of larynx, 458.
- PURDON, on prolonged life with respiration through the tracheotomy-tube, 678.
- Purpura, a cause of epistaxis, 375.
- Pustules, guttural, 203.
- Pyramidal sinus, 57.
- Pyriform sinus, 57; foreign bodies in, 312.
- Quadrangular membrane of the larynx, 53.
- Quinia, in coryza (chronic), 364; croup, 464; diphtheria, 159; epistaxis, 380; hay-fever, 341, 342; laryngitis (tuberculous), 515; neuralgia of the palate, 216; sore throat (acute), 88, (erysipelatos) 114, (phagedenic) 103.
- Quinsy, 89.
- RATTON, on evulsion of naso-pharyngeal tumors, 266.
- RAUCHFUSS, his powder insufflator, 493.
- RAUSE, on tracheotomy by actual cautery, 667.
- RAWDON, on stricture of the cesophagus, 291.
- RAYMOND, on dilatation of the cesophagus, 298.
- Recipro-laryngoscopy, 46.
- REEVES, on pharyngeal abscess, 242.
- Reflection, by diffuse daylight, 37; solar rays, 36.
- Reflectors, 16, 35, 36, 37, (extemporaneous) 43; perforated, 37, 41.
- REHN, on paralysis of larynx, 657.
- REID, on stricture of cesophagus, 291; tumor of head of pancreas, 305.
- REMAK, on vegetable organisms in diphtheria, 134.
- Resections, for access to naso-pharyngeal tumors, 269; of thyroid cartilage for syphilitic concentric hyperchondrosis, 525.
- Respiration, during laryngoscopy, 34, posterior rhinoscopy, 70; impeded nasal, in chronic follicular sore throat, 190; the larynx in, 61.
- Respirators, 8, 345, 494.
- Respiratory-brace, in dyspnoea, 253.
- Retention of foreign bodies in cesophagus, 318.
- Retractors, hair-pin, 14.
- Retro-cesophageal abscess, 239, 247; pharyngeal abscess, 239; lymphadenitis, 240.
- REUBOLD, on the sore throat of thrush, 118.
- REYNAUD, on stenosis of larynx by cutaneo-pharyngeal partition, after suicidal wound, 587.
- Rheumatic sore throat, 86.
- Rheumatism, acute, compression of cesophagus from pericardial effusion in, 298.
- Rhineuryntor, 382.
- Rhinitis, 331.
- Rhinoliths, 348, 389.
- Rhinopharyngitis, 185.
- Rhinorrhagia, 374.
- Rhinorrhoea, acute, 331; chronic, 346.
- Rhinoscopic, image, 74; inspection, structures exposed to, 73.
- Rhinotomy, anterior, 13; by mirrors, 77; pharyngeal, posterior or retro-nasal, 69, by mirrors passed through nasal passage, 77.
- RICHARDSON, on clinical thermometry in diphtheria, 137; retention of carbonic acid in fibrination of exudation in croup, 468.
- RICHERAND, on occlusion of nasal passages, 384.
- RIEGEL, on atrophy and disorganization of recurrent nerves in paralyzes of larynx, 654.
- Rima glottidis, 60.
- RINDFLEISCH, on tuberculous laryngitis, 497.
- RIOLAN, on recurrent nasal myxoma, 398.
- RISCH, on oedema of lips of glottis, 444.
- ROBERTS, on acute bronchocele, 595, 701; oedema of larynx, 453; rupture of trachea, 613.
- ROBERTSON, on carcinoma of larynx, 582; extension of pseudo-membrane in diphtheria, 141.
- ROBIN, on follicular glands at vault of pharynx, 284.
- ROBINSON, on paralysis of posterior crico-arytenoid muscles, 655; spasm of the trachea, 632.
- ROBSON, on spontaneous extrusion of laryngeal growth by expectoration, 545.
- ROKITANSKY, on carcinoma of larynx, 581; dilatation of cesophagus, 300; tuberculous laryngitis, 497; tumor of the cesophagus, 303.
- ROOSA, on the nasal douche, 359.
- ROSE, on cause of sudden death in goitre, 703, 708; extirpation of hypertrophied thyroid gland, 713.
- ROSENUELLER, the fossa of, 75.
- ROSER, his method of operating on the pendent head, 572, 666; on tracheotomy, 662.
- ROSSBACH, on membranous web between vocal cords, 521.
- ROUGE, his operation for gaining deep access to nasal passages, etc., 390.
- Rubeola. [See Measles.]
- RUEHLE, on discharge of cricoid cartilage in one piece, 525; impaction of epiglottis in larynx, 615; oedema of larynx, 447, (hemorrhagic) 458; perforation of the cesophagus, 309.
- RUMBOLD, on cleansing nasal passages, 355; posterior rhinoscopy by mirror passed through nasal passages, 77.
- RUPPRECHT, on deflection of septum narium, 411.
- Rupture, of larynx and trachea, 612; cesophagus, 307.
- RUSH, on calomel in diphtheria, 160, 161.
- RUSSEL, on oedema of larynx, 456.
- RUST, on hemorrhage after wounds of larynx, 603.
- RYLAND, on laryngitis (erysipelatos), 437; oedema of larynx in measles, 446, (chronic) after glanders, 454; ulceration of larynx in measles, 110.

- SABATIER, on wounds of larynx, 601.
 Sage, in sore throat, 95.
 Salicylic acid, in coryza (chronic), 372; diphtheria, 162, 167; hay-fever, 342.
 SALISBURY, on infusorial catarrh and asthma, 345.
 Salivation, a cause of acute laryngitis, 421; excessive, in small-pox, 107.
 Salt, in cleansing nasal passages, 359; local use of, 7; after applications of nitrate of silver, 195.
 SANDS, on consecutive disease from carcinoma of larynx, 580; digital exploration of trachea through wound of tracheotomy, 623.
 Sanguinaria, in diphtheria, 164.
 SANNÉ, on croup and diphtheria, 463.
 Santal, in phlegmonous sore throat, 95.
 SANTORINI, cartilages of, 51, 53, 58.
 Sarcoma, of frontal sinus, 417; larynx, 536, 544, (myeloid) 546; œsophagus, 303; palate, 210; pharynx, 210, 249; tonsil, 235; trachea, 577.
 Sarcini ventriculi, in nasal passages, 383.
 Sarsaparilla, in enlarged tonsils, 228.
 SASS, his naso-pharyngeal douche, 359; spray-producers, 487.
 SAUSSURE, DE, on epistaxis, 376.
 Scalds of the throat, 98.
 Scarification, in laryngitis (acute), 428; sore throat (phlegmonous), 96.
 Scarlatina, mumps in, 696; œdema of larynx in, 446; sore throat of, 110.
 SCHEFF, on congenital web between vocal cords, 536.
 SCHELL, his nasal speculum, 15.
 SCHMIDT, on exsection of larynx, 621; foreign bodies in the larynx, 621.
 SCHMITZ, on œdema of larynx in retro-pharyngeal abscess, 239; pharyngeal abscess, 245.
 SCHNITZLER, on constriction of trachea, 597; dilatation of stenosis of larynx, 593.
 SCHUETZENBERGER, on bulbar paralysis, 328.
 SCHROETTER, on carcinoma of trachea, 586; dilatation of stenosis of larynx, 590, 591; local use of morphia in chronic laryngitis, 495; lepra of larynx, 531; tumor of trachea, 577.
 Scissors, laryngeal, 556, 561, 563; uvular, 219.
 Scrofula, membranous sore throat in, 106; pharyngeal abscess in, 240; sore throat of, 187, 200.
 Scrofulous sore throat, 187, 200.
 Scurvy, a cause of epistaxis, 375.
 Secretions, nasal, in influenza, 345.
 Sedatives, in chronic coryza, 362; hyperesthesia of the larynx, 625.
 SÉDILLOT, on gastrotomy, 296.
 SEMELEDER, his reflector, 36; spectacle-frame for supporting, 36; on galvano-cautery in naso-pharyngeal tumors, 270; œsophagoscopy, 68; stricture of trachea, 587.
 SEMON, on paralyzes of posterior crico-arytenoid muscles, 653, 654, 655.
 Senega, in croup, 466; diphtheria, 168.
 Senses, impairment of special, after diphtheria, 176.
 Septicemia, in diphtheria, 145.
 Septum, bronchial, in deflecting foreign bodies in the trachea, 616; nasal [see Nasal septum], posterior, 74, deflection of, 384, fracture of, 411, perforation of, 351, (syphilitic) 128, resection of, 411, tumors of, 412; tracheal, 616.
 SERKOWSKI, on tracheotomy in tuberculous laryngitis, 516.
 SERRES, on anosmia, 402.
 SESTIER, on œdema of larynx, 444, (hemorrhagic) 457; phlegmonous laryngitis, 434.
 Seton, the, in goitre, 712.
 SHAPLEIGH, his case of asphyxiating hemorrhage in traumatic tracheitis, 471.
 Sheet, the wet, 7.
 Sialagogues, in paralysis of the palate, 217.
 SIDLO, on adhesion of arytenoid cartilages simulating paralysis of posterior crico-arytenoid muscles, 657.
 Silver, nitrate of, accident from local use of stick of, 195; discoloration of external tissues from local use of, 196; in carcinoma of larynx, 585; coryza (chronic) 365; croup, 467; diphtheria, 166; elongation of uvula, 219; fistule of pharynx, 277; hyperesthesia of the larynx, 626, palate, 216; laryngeal growths, 548, 550, 552; laryngitis (chronic), 486, 493, 495, (syphilitic) 523, (tuberculous) 515; œsophagitis, 284; paralysis of larynx, 640; sore throat (chronic), 179, (erysipelatos) 115, (folliculous) 193, 195, (phlegmonous) 96, (syphilitic) 130; tonsillitis (chronic), 224, 228, 233.
 Singers, sore throat of, 179.
 SINKLER, on pharyngeal abscess, 241.
 Sinuses, facial, osseous tumors of the, 393; frontal diseases of the, 389, 414; glosso-epiglottic, 54, affections of, 687; lingual, 54; pharyngo-laryngeal, 57, 79, affections of the, 312, 686; pyramidal or pyriform, 57, 79.
 Skin, diphtheritic deposit on abraded, 140; discoloration of, from topical use of nitrate of silver in chronic sore throat, 196; eruptions of, in diphtheria, 153, sore throat, 202, 203, influenza, 342.
 Sloughing, spontaneous, of naso-pharyngeal tumors, 272; thyroid gland, 690, 699.
 Small-pox, a cause of ulcerous sore throat, 101; occlusion of nasal passages from, 385, 391; sore throat of, 107.
 SMITH, on bulbar paralysis, 329; pharyngeal abscess, 241; morbid growths of trachea revealed by tracheotomy, 576; vegetable organisms in diphtheria, 135.
 Smoke, traumatic sore throat from inhalation of, 99.
 Smoking, injurious effect of, in chronic catarrhal sore throat, 179.
 SMYLY, his method of demonstro-laryngoscopy, 48.
 SMYTH, on inundation of air-passages during anesthesia, 614.
 Snakes, laryngeal, 564; œsophageal, 317.
 Sneezing, 404; a cause of epistaxis, 376.
 Snuff, in chronic coryza, 369.
 Sodium, bicarbonate and carbonate of, in coryza, 337; laryngitis (tuberculous), 515; sore throat (chronic), 179; chloride of, in laryngitis (chronic), 485; sore throat (chronic), 179; sulphites, etc., of, in influenza, 344.

- SOMMERBRODT**, on membranous web between vocal cords, 521.
- Sore throat**, 83, 425; acute, catarrhal, common, erythematous, simple inflammatory, or superficial, 84; aphthous, 103; chronic (catarrhal), 177, (folliculous, granular) 179, clerical or clergyman's, 180; dactylos, 202; diphtherial, 138; erysipelatous, 113; exanthematous, 107; gangrenous, 100, 117; glandular, 116; herpetic, 103; lupoid, 201; malignant, 100; membranous (common or simple), 103; mercurial, 118; phagedenic, 106, 117; phlegmonous, 89; rheumatic, 86; scrofulous, 87, 200; syphilitic, 119, (infantile) 127; tuberculous (acute), 115; traumatic, 98; ulcerous, 100.
- Spasm**, of larynx, 425, 559, 603, 620, 626, 627, 630, (from local applications to larynx) 489; oesophagus, 319; palate, 216; pharynx, 195, 279, 319; trachea, 632.
- Spasmodic cough**, 633.
- Specific action of deleterious substances in the atmosphere**, as a cause of sore throat, 6.
- Spectacle-frame**, for supporting reflector, 36.
- Speculum**, mouth, 29, 229; nasal, 14.
- Sphenoid bone**, caries of, 352.
- Sphincter**, of pharynx, 204.
- Spinal meningitis** (syphilitic), 123.
- Spleen**, disease of, a cause of epistaxis, 375.
- Sponge**, 194; compressed, in coryza (chronic), 367, deflection of nasal septum, 411, evulsion of morbid growths of larynx, 548, 553; methods of securing, to staff, 285, 490; -holders, laryngeal, 490, 548; -probang, oesophageal, 285, 317.
- Sponging**, hygienic use of, 7; in chronic laryngitis, 494.
- Spray producers**, 197.
- Sprays**, in anesthesia of the larynx, 625; carcinoma of larynx, 585; coryza, 337, (chronic) 355, 362; diphtheria, 168; hyperesthesia of the palate, 216; laryngitis (acute), 428, (chronic) 487, (tuberculous) 525; paralysis of larynx, 645; pharyngitis (atrophic), 200; sore throat (acute), 88, (chronic), 179, 197, (phlegmonous) 96, (syphilitic) 127, 130; mechanical impact of, 198.
- Staff**, bent, for elevating depressed epiglottis, 32.
- STANFORD**, on extraction of foreign bodies from oesophagus, 316.
- STARR**, on spontaneous cure of goitre, 704.
- Steam**, in coryza (chronic), 362; croup, 464, 465; diphtheria, 172, 173; laryngitis (acute), 428; pharyngitis (atrophic), 200; sore throat (phlegmonous), 95.
- STEELE**, adaptation of his flexible probe, for application of posterior nasal tampon, 381.
- Stenosis**, of larynx, 124, 479, 482, 496, 505, 519, 533, 586, 602; nasal passages, 384; oesophagus, 289, (extraneous) 297; pharynx, 277, a cause of pharyngeal abscess, 241; trachea, 520, 602.
- Sternutation**, 404.
- STEVEN**, on perforation of aorta by foreign body in oesophagus, 314.
- Stilllingia**, in enlarged tonsils, 228.
- STOERCK**, his gouge for evulsion of exuberant tissue in chronic folliculous sore throat, 196; guillotine (laryngeal), 563; method of managing tongue during laryngoscopic inspection, 23, of testing warmth of mirror, 26; tongue-depressor with mirror attached, 73; on chronic folliculous sore throat, 184; dilatation of stenoses of the larynx, 593.
- STOKES**, on extensive diphtheritic deposit, 140; olfaction, 404; suffocation from rupture of tonsillar abscess, 93.
- Stomach**, diphtheritic deposit extending into, 140.
- Stomatitis**, mumps in, 696; sore throat of, 118.
- Stramonium**, in chronic coryza, 363.
- Stricture** [see Stenosis], of the larynx, 456, 586; oesophagus, 289, 290, (spasmodic, spastic), 324; trachea, 586.
- STROMETER**, on abscess of the larynx, 411; acute laryngitis from eruption of wisdom-tooth, 420; applications of fused nitrate of silver to larynx, etc., 550; goitre (exophthalmic), 706, (parenchymatous cystic) 705; incautious cauterization of the larynx, 549; oedema of larynx, 452; paralysis of the glottis in oedema of the larynx, 443; perforation of pleura by foreign body in oesophagus, 318; pharyngeal abscess, 242, in the new-born, 240; progression of needles from oesophagus to exterior of the body, 319; prolonged life with respiration through tracheotomy-tube, 678; wounds of larynx and trachea, 604, 605, 612.
- Structures**, of nasal passages exposed to direct inspection, 16; throat, do., 12; exposed to inspection by reflection of image (laryngoscopic), 50, (rhinoscopic) 73; involved in sore throat, 83; pyriform tumefaction of supra-arytenoid, in tuberculous laryngitis, 501.
- Struma**, 701.
- Strychnia**, in anesthesia of larynx, 625; anosmia, 403; dilatation of oesophagus, 302; neuralgia of larynx, 626; paralysis (bulbar), 330, (diphtheritic) 176, laryngeal, 639, 645, 649, oesophageal, 327, palatal, 217, pharyngeal, 280.
- Subcutaneous tracheotomy**, 667.
- Suicidal wounds**, 273.
- Sulphur and its compounds**, in croup, 466; diphtheria, 158, 168; influenza, 344.
- Sunlight**, examination of throat, etc., by, 36.
- Supra-arytenoid**, cartilages, 51, 53, 58; structures, pyriform tumefaction of, in tuberculous laryngitis, 501.
- SURMAY**, on involvement of spinal and sympathetic nerves in oesophageal carcinoma, 303.
- SWIETEN, VAN**, on topical applications in diphtheria, 157.
- SYME**, on pharyngeal abscess, 242.
- Syncope**, fatal, in diphtheria, 155.
- Syphilis**, as a cause of development of morbid growths in larynx, etc., 535, of ulcerous sore throat, 101; infection of, from milk of nurse, 119; of larynx, 518, 628; nasal passages, 383; palate and palatine folds, 120, 121; laryngeal growths in, 535, 546; membranous sore throat in, 108; pharyngeal abscess in, 240; sore throat

- of, 119, (infantile) 127, (secondary) 120, (tertiary) 122; stellate cicatrices of, 123, 128; stricture of œsophagus in, 290.
- Syphiloma [see Gummata].
- Syringe, an extemporaneous substitute for a Spray-machine, 88, 96; laryngeal, 488; nasal (posterior), 358; naso-pharyngeal, 261; uses of the, 130, 168, 358.
- Tampon, in epistaxis, 380; hemorrhage after excision of tonsils, 232.
- Tamponing, posterior nasal outlets, 400.
- Tannin, in carcinoma of larynx, 585; coryza (chronic), 362; enlarged tonsils, 228; hyperesthesia of larynx, 626, palate, 216; laryngitis (chronic), 485, 486, (tuberculous) 515; nasal polyps, 396; œsophagitis, 254; spasmodic cough, 635; sore throat (acute), 88, (phlegmonous) 96, (chronic catarrhal) 179, (folliculous) 196, 197.
- Tape-worm, a cause of chronic folliculous sore throat, 181.
- Tar-water, in chronic coryza, 363.
- Tartar-emetic [see Antimony].
- TAYLOR, on lipoma of pharynx, 250.
- Teeth, caries of, a cause of fetid coryza, 348.
- TELLIER, on removal from thigh, of a fork which had been swallowed, 319.
- Test-paper, in determining chemical reaction of mucous membrane, 179.
- Tetanus, from retention of nasal tampon, 382; tracheotomy in, 660.
- Thigh, removal from, of fork which had been swallowed, 319.
- Thimble, dentist's extension, 32.
- Thirst, fruit-juice to allay, 517.
- THOMAS, on the use of the seton in goitre, 712.
- THOMPSON, on influenza, 342; œdema of larynx in nephritis, 446; tamponing posterior nares, 382.
- THORNTON, on escape of tracheotomy-tube into air-passages, 664; securing tapes to tracheotomy-tube, 674.
- Throat, anatomical regions of, often diseased together, 5, 83; causes of inflammations of, 5, 6, 84; consumption of, 478; diseases of the, in general, 1; eruptions of the, 202; examination of the, 9; granular, 2; herpes of the, 103; inspection (direct) of, 9; normal appearance of, 497 [see Sore Throat]; -consumption, 497.
- Thrush, sore throat of, 118.
- THUDICHUM, his nasal douche, 355, 357; nasal speculum, 15; on galvano-cautery for removal of nasal tumors, 397.
- THULLIER, on œdema of the larynx, 453.
- Thymic asthma, 628.
- Thymitis, 714, (syphilitic) 715, (tuberculous) 716.
- Thymol, in carcinoma of larynx, 585; idiosyncratic coryza, 342.
- Thymus gland, affections of the, 714; degenerations of the, 716; enlargement of the, 628, 715.
- Thyreo-pharyngo-palatine muscle, 205.
- Thyreotomy, 660.
- Thyro-adenitis, 679.
- Thyro-arytenoid ligaments (inferior), 60, (superior) 59; muscles, 64, paralysis of, 640.
- Thyro-epiglottic muscles, 63.
- Thyro-hyoid bursæ, tumors of, 697.
- Thyroid arteries, ligation of, in goitre, 713; cartilage, 66, abscess of, 527, anomaly of, simulating fracture, 608; division of, for excision of cicatricial tissue, 524, evulsion, etc., of morbid growths, 570, in laryngotomy, 669, perichondritis of, 510; gland, affections of the, 699, cystoma of, 697, disease of, simulated by pharyngeal abscess, 243; wounds of the, 602.
- Thyroiditis, 679.
- Thyreoidotomy, 660.
- Thyrotomy [see Laryngotomy], 660; for removal of foreign bodies, 621.
- Tobacco-smoke, a cause of disease of the throat, 6; -smoking, a cause of bulbar paralysis, 328; laryngeal paralysis, 654.
- TODD, his concealed holder for molten nitrate of silver, etc., 550; electrodes (laryngeal), 647; écraseur, 566; forceps (laryngeal), 553; illuminator and support for reflector, 40, (as arranged by author) 41, (portable or pocket) 41; knives, concealed and exposed (laryngeal), 560, 561; lancet-probe, 560; method of infra-glottic laryngoscopy, 49; scissors (laryngeal), 563; snare, 564; syringe (laryngeal), 488; on direct inspection of the larynx and pharynx, 11; lupus of the larynx, 529.
- TODD, on pharyngeal erysipelas, 114.
- Tongue, adhesions of, to soft-palate, etc., 212; chancre of, 120; chronic catarrh at base of, 177; glands at base of, in chronic folliculous sore-throat, 183, 187; management of the, in laryngoscopy, etc., 28; swallowing of the, 628; titillation of base of, to provoke emesis in diphtheria, 164; wounds of the, 273, 601.
- Tongue-depressors, 9, 29, 72, (folding) 9; -holders, 29.
- Tonsil, hypertrophy of the pharyngeal, 253; pharyngeal, 76.
- Tonsil-écraseur, 232; -guillotine, 228.
- Tonsils, abscess of, 97; adenoma of, 234; adhesions of, to soft palate, etc., 212; atrophy of, 234; calculi of, 237; carcinoma of, 234, 236; chancre of, 120; cystoma of, 235; enlargement of, 226; excision of, 225, 228; exudation of, in diphtheria, 138, 152, membranous sore throat, 107; fibroma of, 235; follicular catarrh of, 91, 222; foreign bodies in, 238; hemorrhage from excision of, 232; hyperesthesia of, 85; hyperplasia of, 98, 226; hypertrophy of, 225, 346; induration of, 98; interference of enlarged, with laryngoscopic manipulations, 20, 31; lipoma of, 235; lymphadenitis of, 91; lymphoma of, 234; lympho-sarcoma of, 235; normal appearance of, 13; palpation of, 78; papilloma of, 234; resection of, 228; sarcoma of, 235; scarification of, 97; sheathing of, in diphtheria, of grave import, 140, 152; syphilitic disease of, 121.
- Topical applications, in diphtheria, 157, 165; laryngitis (chronic), 486; sore throat (chronic), 179, 194.

- TORRANCE**, his device for removing foreign bodies from the œsophagus, 316.
- Trachea**, anesthesia of, 625; carcinoma of, 586; ecchondroma of, 578; foreign bodies in, 614, 678; in diphtheria, 140, laryngitis (chronic), 478, syphilitic sore throat, 124; inspection through artificial opening in the, 48; involution of the, 579, 595; laryngoscopic inspection of, 67; morbid growths of, 576; osteoma of, 579; perforation of, by foreign body in the œsophagus, 313; sarcoma of, 577; ulceration of, in tuberculous laryngitis, 508; wounds of, 602.
- Tracheitis**, acute, 471; chronic, 472; traumatic, 471; ulcerative, 471.
- Tracheocele**, 579.
- Tracheoscopy**, 48, 66.
- Tracheotomes**, 672.
- Tracheotomy**, 660, 662, 666, 667, 669; bloodless, 671; instantaneous, 671; in bronchocele (acute), 701; carcinoma of larynx, 584; croup, 459, 467, 469; diphtheria, 170, treatment after, 171, rarely successful in adults, 171; foreign body in air-passages, 617, 621; goitre, 710; laryngitis (acute), 429, (chronic) 479, (erysipelatos) 437, (phlegmonous) 436, (traumatic) 560, (tuberculous) 516; lepra of larynx, 533; morbid growths of larynx, 569, 573, 576, of trachea, 576; paralysis of larynx, 657; retro-œsophageal abscess, 249; spasm of larynx, 631; stenosis of larynx, 588; traumatic sore throat, 98.
- Tracheotomy-tube or canule**, 662, 663, 672, 674, 675, 677, 678; as a foreign body in the air-passage, 615, 663; choice of a, 171; extemporaneous substitutes for ordinary, 664; introduction of the, 672; pea-valved, for phonation, 679.
- Transfusion**, in epistaxis, 382.
- TRAVERS**, on scrofulous sore throat, 200.
- Traumatic**, carcinoma of larynx, 582; laryngitis, 99; pharyngeal abscess, 241; sore throat, 98; stricture of larynx and trachea, 587, œsophagus, 290; tracheitis, 471.
- TRELAT**, on parasites in nasal passages, 389.
- TRENDELENBERG**, his rubber tracheal tampon, 572; on dilatation of stenosis of larynx, 590, stricture of trachea, 587; gastrotomy, 296.
- TRIDEAU**, on copaiba and cubeb in diphtheria, 161.
- Trocar**, in evacuating pharyngeal abscess, 248.
- TROLAND**, on leeches in the larynx, 620.
- TROUSSEAU**, his dilator of tracheotomy wound, 673; tracheotomy-tube, 662, forceps for cleaning, 676; on bulbar paralysis, 328; extemporaneous tracheotomy tube, 666; hydrochloric acid in diphtheria, 167; infection of diphtheria, 135; medicated powders in chronic coryza, 369; œdema of larynx, 449, 453; suppuration of glands in diphtheria, 139; syphilitic cicatrices, 128; syphilitic coryza (infantile), 128; tracheotomy, 671.
- Tubage of larynx in croup**, 468.
- TUBBS**, on hyposulphate of sodium in diphtheria, 162.
- Tubes**, to dilate nasal passages, 364, 385; to prevent readhesion of divided tissues, 212.
- Tubercle**, laryngeal, simulated by enlarged glands, 498; miliary, in the larynx, 497, 498; œsophageal, 303.
- Tuberculosis**, a cause of morbid growths in the larynx, 535, of ulcerous sore throat, 101; acute miliary, of the throat, 501; acute sore throat of, 115; carcinoma of œsophagus in, 303; ecchondroma of trachea in, 579; membranous sore throat in, 106.
- Tuberculous laryngitis**, 497; laryngo-tracheitis (chronic), 497; sore throat, 183; thymitis, 716.
- TUERCK**, his labors in laryngoscopy, 18; magnifying apparatus, 35; mirror, 20; method of infraglottic laryngoscopy, 49; tongue-depressor, 10; on chondritis tuberosa, 479; constriction of trachea, 594; emphysema after suppurative chondritis, 526; involutions of the trachea, 579; laryngitis (circumscribed traumatic), 99, (chronic) degeneration of muscle in, 478, (erysipelatos) 437, (syphilitic), very late manifestation of, 518, fatal hemorrhage in ulcerative, 520; lupus of the larynx, 529; sore throat of small-pox, 108; tumor of trachea, 578.
- Tumors** [see Morbid Growths].
- Turbinated bones**, the, in chronic coryza, 346; removal of, with nasal myxoma, 397.
- TURNER**, on vicious adhesions of palate to adjacent structures, 213.
- Turpentine**, in coryza (chronic), 366; epistaxis, 379; hemorrhage from naso-pharyngeal tumors, 265; hemorrhagic œdema of larynx, 458; laryngitis (chronic), 486; paralysis of larynx, 646.
- Tympanum**, the, in syphilitic sore throat, 123.
- Typhoid fever**, a cause of ulcerous sore throat, 101; chondritis and perichondritis in, 527; mumps in, 696; œdema of larynx in, 446.
- Typhus fever**, œdema of larynx in, 446; subglottic œdema, and permanent stricture of larynx after, 456.
- UHDE**, on pharyngeal abscess, 242.
- Underclothing**, hygienic selection of, 7.
- Urine**, albuminous, in diphtheria, 138.
- Urticaria**, guttural, 203.
- Uvula**, bifid, 221; carcinoma of, 221; elongated, 31, 89, 185, 192, (chronic) 218; excision of, 127, 218, 221; hemorrhage after excision of, 219; hemorrhagic stasis of, 89; hypertrophy of, 220; morbid growths of, 220; myxoma of, 220; neuroses of, 221; noosing the, 72; normal appearance of, 12; œdema of, 111, 220; paralysis of, 221; syphilitic disease of, 121, 122; -sector, 219; -scissors, 219.
- VADJA**, on sarcoma of nasal septum, 412.
- Vagina**, secretions of, a cause of infantile coryza, 332.
- Valerian**, in chronic laryngitis, 496; paralyses of larynx, 653.
- Valleculæ**, the lingual, 54.
- VALLEIX**, on phlegmonous laryngitis, 434.
- VALSALVA**, on epistaxis, 378; luxation of the hyoid bone, 276.


- VANDERWARKER, on abscess of the œsophagus, 313.
 Vapors in chronic coryza, 362.
 Variola [see Small-pox].
 Vegetable organisms, in diphtheria, 134.
 Vegetations, adenoid, in naso-pharyngeal cavity, 253; inter-arytenoid, of tuberculous laryngitis, 502, 505; syphilitic, in sore throat, 121.
 Ventricle, of the larynx, 59; eversion of, 544; incision of, for access to growths, 562.
 Ventricular bands, 57.
 VERNEUIL, on gastrotomy, 296; rhinoliths, 388, 391; tamponing posterior nasal outlets, 400; thyroiditis, 699, 700.
 Vertebrae, cervical, caries of, 241; inflammation of, a cause of pharyngeal abscess, 239; perichondritis of, 123; syphilitic disease of, 123.
 Vertigo, in influenza, 343.
 Vesicles, 203; herpetic, 105.
 VIDAL, his operation for deep access to nasal passages, 390.
 Vienna paste, in laryngeal growths, 548.
 VIGLA, on stricture of trachea, 587.
 Vinegar, in phlegmonous sore throat, 95.
 VIRCHOW, on carcinoma of larynx, 580; exudation of diphtheria, 134, 149; stricture (syphilitic), of œsophagus, 290; stricture of trachea, 587; tuberculous laryngitis, 497.
 Vocal apparatus, artificial, 589, 593, 683.
 Vocal cords, adhesions between, 521; destruction of, in small-pox, 109; glands of mucous membrane of, 537; hypertrophy of, in chronic laryngitis, 478, 482; induration of in tuberculous laryngitis, 502; overstraining the, a cause of sore throat, 6; paralysis of, 505; ulceration of, in tuberculous laryngitis, 501; vascular papillæ at edges of, 537; visible occasionally to direct inspection, 10; gymnastic exercises in paralyzes of larynx, 641; membranes, 60; processes, 61, 65, denudation of, in tuberculous laryngitis, 503.
 VOGEL, on vegetable organisms in diphtheria, 134.
 Voice, artificial, apparatus for, 589, 593; in chronic follicular sore throat, 188; chronic enlargement of tonsils, 227; convalescents from laryngitis of small-pox, 108; croup, 461; fistule of larynx, 598; œsophageal abscess, 247; vicious adhesions, 102; loss of, from inclusion of pneumogastric nerve, in ligature of carotid artery, 650; mechanism of the, 61; without occlusion of orifice of tracheotomy-tube, 679; [see Phonation].
 VOLTOLINI, his laryngeal galvano-cauterics, 566; magnifying apparatus, 35; multiple mirrors, 35; staff for elevating depressed epiglottis, 32; on congenital occlusion of nasal passages, 386; follicular glands at vault of pharynx, 253; galvano-cautery in chronic follicular sore throat, 196; inspection of the pharynx, 11; mechanical detachment of morbid growths of larynx, 548; œsophagoscopy, 68; rhinoliths, 389; rhinoscopy with two mirrors, 72.
 Vomer [see Nasal septum], caries, etc., of, in chronic fetid coryza, 352; submucous infiltration at sides of, 408.
 Vomiting, laceration of œsophagus in, 307.
 VOSS, on retention of foreign body in œsophagus, 318; rupture of trachea, 613.
 WACHSMUTH, on progressive bulbar paralysis, 328.
 WADE, on albuminuria in diphtheria, 154.
 WAGNER, on adenoma of palate, 209; cyst of suprahyoid bursa, 698; hygroma of pharynx, 272; myoma of palate, 211.
 WALDENBUG, on œsophagoscopy, 68; strychnia in paralysis of larynx, 649; tuberculosis of the larynx, 499.
 WANNER, on vapor of water in croup and diphtheria, 173.
 WARE, on yellow sulphate of mercury in croup, 464.
 Washerwomen, gonorrhœal coryza of, 340.
 Water, aromatic, 95; hygienic use of, 7; in croup, 466, diphtheria, 168, laryngitis (tuberculous), 515; warm, in coryza, 337, sore throat (phlegmonous), 95.
 WATERS, on escape of tracheotomy-tube into air-passage, 663.
 WATSON, on fistule of larynx, 599; œsophagotomy, 321; sternutation, 405.
 Web, membranous, between vocal cords, 536.
 WEBER, his nasal douche, 355; on infantile coryza, 332.
 WEDL, on syphilitic thymitis, 715.
 WEGNER, on artificial vocal apparatus, 684; dilatation of stenosis of larynx, 589; exsection of larynx, 681.
 WERTHEIM, his magnifying apparatus, 35; multiple mirrors, 35.
 WEST, on syphilitic stricture of œsophagus, 290, 291.
 Wet-nurse, admissibility of syphilitic, 129.
 Whisper, abolition or loss of, 645.
 WHITE, on external wound of pharynx, 273.
 WHITEHEAD, on cleft of hard and soft palate, 213.
 Whooping-cough, œdema of larynx in, 446.
 WIEL, on sternutation, 405.
 WILKS, on emphysema after suppurative chondritis, 526; stricture of œsophagus, 289, trachea, 587; vegetable organisms in diphtheria, 135.
 WILLIAMS, on rupture of œsophagus, 307; total abstinence from liquids in coryza, 338.
 WILSON, on œdema of larynx, 453.
 WINTRICH, on percussion of the larynx, 82.
 WITTE, on wounds of larynx and trachea, 603.
 WITTRICH, on thymitis, 714.
 WOLFF, on lepra of the larynx, 531.
 WOLTERS, on congenital deficiency in anterior palatine fold, 206.
 Wool, hygienic use of wads of, in influenza, 345.
 Wounds, of the larynx, 600, palate, 215; œsophagus, 306; throat, 98; thyroid gland, 602; tongue, 273, 601; trachea, 600, 602.
 WRISBERG, cartilages of, 51.
 Xanthoxylum, in phlegmonous sore throat, 95.
 YEARSLEY, on cleansing nasal passages, 355.
 YEO, on exophthalmic goitre, 706.


ZAUFAL, his nasal speculum, 14.


ZIEMSEN, his laryngeal electrodes, 647; on chondritis (traumatic primary), 525; electricity in paralyses of larynx, 647, 648, 657; emphysema after suppurative chondritis, 526; lupus of the larynx, 529; neuroses of larynx, 624; œdema of larynx, 444; paralyses of larynx, 641, 643, 644, posterior crico-arytenoid muscles, 653; wounds of larynx, 600.

Zinc, *chloride of*, in coryza (chronic), 363 morbid

growths of larynx, 548; laryngitis (chronic), 486, (syphilitic) 524; sore throat (chronic catarrhal), 179, (folliculous) 196; *iodide of*, in enlarged tonsils, 228; sore throat (chronic folliculous), 196; *phosphide of*, in paralysis of palate, 217; *sulphate of*, in coryza (chronic), 362; laryngitis (chronic), 485; paralyses of larynx, 646; sore throat (chronic folliculous), 197, (phlegmonous), 96.







Date Due

Denco 293-5			

RF 40
879C

