

**Lessons in practical anatomy, for the use of dissectors / by W. E. Horner, M.D.**

**Contributors**

Horner, William E. 1793-1853.  
Harvey Cushing/John Hay Whitney Medical Library

**Publication/Creation**

Philadelphia : J. G. Auner, 1836.

**Persistent URL**

<https://wellcomecollection.org/works/rzdphtrq>

**License and attribution**

This material has been provided by This material has been provided by the Harvey Cushing/John Hay Whitney Medical Library at Yale University, through the Medical Heritage Library. The original may be consulted at the Harvey Cushing/John Hay Whitney Medical Library at Yale University. where the originals may be consulted.

This work has been identified as being free of known restrictions under copyright law, including all related and neighbouring rights and is being made available under the Creative Commons, Public Domain Mark.

You can copy, modify, distribute and perform the work, even for commercial purposes, without asking permission.

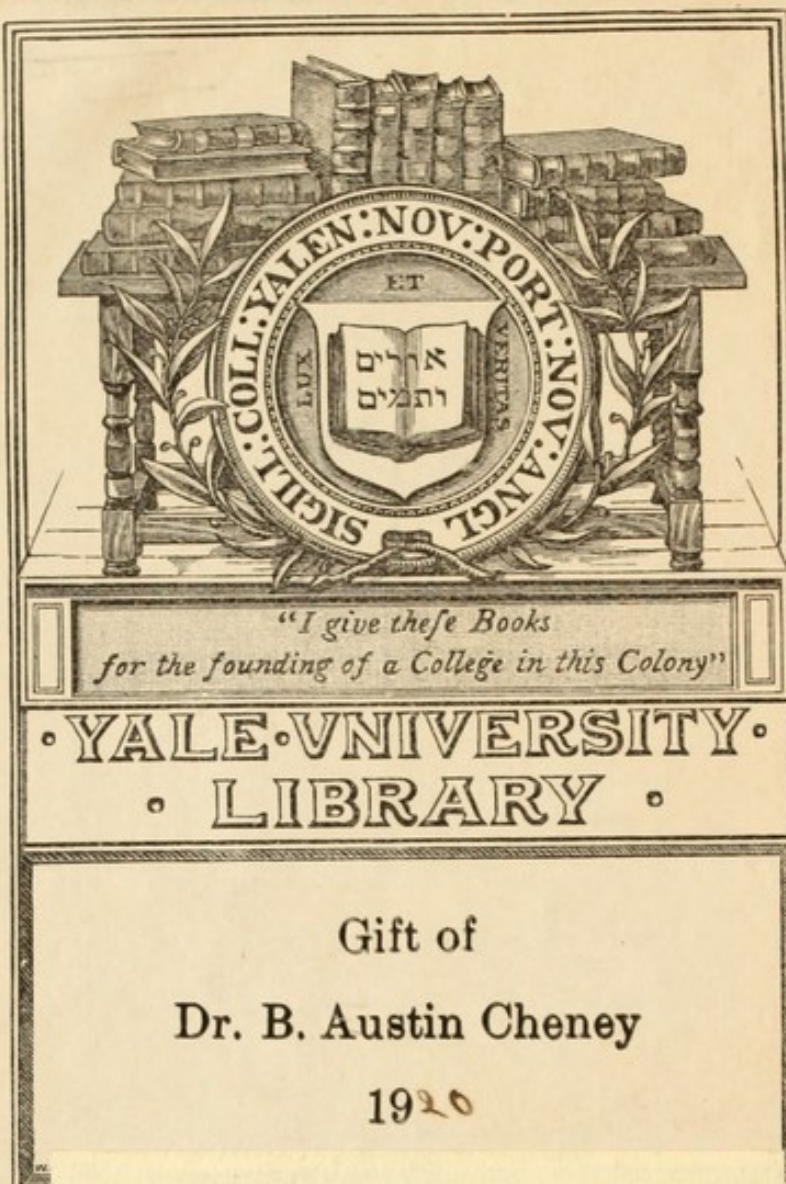


Wellcome Collection  
183 Euston Road  
London NW1 2BE UK  
T +44 (0)20 7611 8722  
E [library@wellcomecollection.org](mailto:library@wellcomecollection.org)  
<https://wellcomecollection.org>









Gift of  
Dr. B. Austin Cheney  
1920

YALE  
MEDICAL LIBRARY




HISTORICAL  
LIBRARY



















LESSONS  
IN  
PRACTICAL ANATOMY,  
FOR THE  
USE OF DISSECTORS.

By W. E. HORNER, M. D.,

PROFESSOR OF ANATOMY IN THE UNIVERSITY OF PENNSYLVANIA; SURGEON  
AT THE PHILADELPHIA HOSPITAL, *Blockley, &c.*

---

THIRD AND IMPROVED EDITION.

---

PHILADELPHIA:  
PUBLISHED BY J. G. AUNER,  
NO. 331 MARKET STREET.  
1836.



Entered, according to the Act of Congress, in the year 1823, by WILLIAM E.  
HORNER, M.D., in the Clerk's Office of the District Court of the United States  
for the Eastern District of Pennsylvania.



TO

PHILIP S. PHYSICK, M. D.,

PROFESSOR OF ANATOMY IN THE UNIVERSITY OF PENNSYLVANIA.

DEAR SIR :

PERMIT me to dedicate to you this little work, proceeding from a course of Anatomical Studies, in which your patronage has been incessantly active; and which, without your disinterested protection and encouragement, might probably have long since been relinquished. I consider it a feeble and insufficient testimony of the large debt of gratitude that I owe you; and wish that it was more worthy of your notice; however, as it is the best at present in my power, I hope that it will be accepted in the sense in which it is offered. That a life so usefully employed as yours in mitigating the ills of human existence, and in enlarging the boundaries of the science of medicine, may be protracted through a long series of years with undiminished physical and mental vigour, is the sincere prayer of,

Dear Sir,

Your obedient servant,

W. E. HORNER.

Philadelphia, July 1st, 1823.



Digitized by the Internet Archive  
in 2012 with funding from  
Open Knowledge Commons and Yale University, Cushing/Whitney Medical Library

# CONTENTS.

PREFACE, - - - - -	Page vii
INTRODUCTION.—On Dissecting, and on the method of making Anatomical Preparations, - - - - -	xiii
PART I.	
OF THE HEAD AND NECK, - - - - -	1
CHAP. I. External Parts of the Head and Neck, - - -	1
Sect. I. Of the Muscles and Fasciæ of the Head and Neck, - - - - -	2
II. Of the Glands of the Head and Neck, -	23
III. Of the Blood vessels of the Neck and Head, -	29
IV. Of the Nerves of the Head and Neck, -	38
CHAP. II. Of the Internal Parts of the Head and Neck, -	50
Sect. I. Of the Brain and Spinal Marrow, - - -	50
II. Of the Brain and Spinal Marrow, according to GALL and SPURZHEIM, - - - - -	76
III. Of the Eye, - - - - -	110
IV. Of the Ear, - - - - -	126
V. Of the Nose, - - - - -	139
VI. Of the Mouth, - - - - -	143
VII. Of the Pharynx and Œsophagus, - - -	148
VIII. Of the Larynx, - - - - -	152
PART II.	
OF THE TRUNK, - - - - -	159
CHAP. I. Of the Thorax, - - - - -	159
Sect. I. Of the Muscles in front, and on the sides of the Thorax, - - - - -	159
II. Of the Viscera of the Thorax, - - -	162
CHAP. II. Of the Abdomen, - - - - -	186
Sect. I. Of the Muscles of the Abdomen, - - -	187
II. Of the Parts concerned in Inguinal Hernia, -	198
III. Of the Parts concerned in Femoral Hernia, -	207
IV. Of the Contents of the Abdomen, - - -	216
V. Of the Diaphragm, &c. - - - - -	250



	Page
CHAP. III. Of the Male Pelvis, - - - - -	258
Sect. I. Of the Viscera of the Male Pelvis, - - -	258
II. Of the Perineum and the Fasciæ of the Male Pelvis, - - - - -	278
CHAP. IV. Of the Organs in the Female, for the Generation and Nourishment of the Infant, - - - - -	292
Sect. I. Of the Female Pelvis, - - - - -	292
II. Of the Female Mammæ, - - - - -	306
CHAP. V. Of the Nerves and Vessels of the Trunk, - - -	311
Sect. I. Of the Nerves, - - - - -	311
II. Of the Blood vessels, - - - - -	320
III. Of the Thoracic Duct, - - - - -	334
CHAP. VI. Of the Muscles of the Back, - - - - -	336
PART III.	
OF THE EXTREMITIES, - - - - -	351
CHAP. I. Of the Upper Extremities, - - - - -	351
Sect. I. Of the Fascia, - - - - -	351
II. III. Of the Muscles, - - - - -	352
IV. Of the Blood vessels, - - - - -	380
V. Of the Nerves, - - - - -	395
CHAP. II. Of the Lower Extremities, - - - - -	404
Sect. I. Of the Fascia, - - - - -	404
II. Of the Muscles, - - - - -	407
III. Of the Blood vessels, - - - - -	437
IV. Of the Nerves, - - - - -	451
PART IV.	
OF THE LIGAMENTS, - - - - -	463
CHAP. I. Ligaments of the Head and Trunk, - - - - -	463
Sect. I. Ligaments of Head and Spine, - - - - -	463
II. Ligaments of Thorax, - - - - -	467
III. Ligaments of Pelvis, - - - - -	469
CHAP. II. Ligaments of the Upper Extremities, - - -	472
III. Ligaments of the Inferior Extremities, - - -	480
PART V.	
OF THE INTEGUMENTS, - - - - -	489
CHAP. I. Skin, - - - - -	489
II. Hair, - - - - -	493
III. Nails, - - - - -	493
IV. Sebaceous Organs, - - - - -	494
INDEX, - - - - -	495

## PREFACE TO THE THIRD EDITION.

THE following sheets were put together originally, with a hope of their contributing to facilitate the most difficult and important part of a medical education, the study of Practical Anatomy, or of Anatomy by personal dissections; and are the result of many observations made in the course of twenty-four years by myself, or by the young men who have confided in me by submitting to my instructions. The arrangement is in some respects unusual, as regards a work on this branch of science; but has arisen from much reflection on the subject, and from a careful observation of that course which students are most disposed to adopt when left to themselves. There are but few men possessed of moderate activity of mind, who do not, in the prosecution of a study even new to them, adopt some labour-saving means, overlooked and sometimes unknown, to such as are much further advanced. It has happened to me frequently, while superintending the studies of others, to observe this fact; and also that none of the books in common use answered continually for reference, either



in consequence of their actual plan not being suitable to the course of dissections, or from the partition of the subject among several students, causing the dissection of one person to interfere with that of another. The idea of forming a text-book to obviate the latter was thus suggested; and I trust, therefore, that the present treatise will, in most cases, be found to answer either where several students dissect together on the same subject, or where the student dissects alone upon a portion of the body.

In the original conception of the work it appeared to me that I might introduce advantageously remarks on Morbid Anatomy, &c; but in computing the number of pages that the descriptive anatomy alone would occupy, I found that such a mass of materials would become a system, and interfere much with the simplicity and conciseness that I wished to predominate in the character of the performance. I have therefore intentionally indulged very seldom in such remarks. But as their introduction is common in manuals of Anatomy, I will state why it has not been imitated in the present. In my own progress as a student, I had a hand-book of that kind, but it very frequently happened that the subject I was engaged in dissecting, had none of the diseases or morbid appearances, that the page I was reading referred to. The author indeed



seemed to labour under the presumption that the young anatomist was working on just such a subject as he had in view; and therefore blended his morbid and descriptive anatomy so much by alternate sentences for each, and sometimes in the same sentence, that the eye could not without much trouble, distinguish what was appropriate. A positive inconvenience was thus sustained.

I have been concise on another subject: Directions how to proceed; to which some Anatomists give the highest importance, so high indeed that in many instances the subject matter is lost in the directions how it is to be found out. In the opinions of some, I may here have committed a fault: my general intention has been, in all cases, to assist by directions where the novelty and obscurity of the operation left no clew for the student; but where the dissection or mode of examination was a plain appeal to common sense, connected with common powers of vision, I have thought it superfluous, and even ridiculous to write down what was to be done. In the common operation of walking, it would be quite philosophical to tell a being of another world, who knew nothing of this, and was differently constituted, that it was accomplished by putting one leg before the other; but perhaps there is no human being, in the rational exercise of his faculties, who



would thank any one for such information. On this ground I have omitted many directions; but it is not improbable that things which seem perfectly plain and appreciable to one in the daily exercise of Anatomy, may be more obscure to another less occupied with it.

It will be seen that the work consists of three Parts;\* the Head and Neck, with the contained organs, form one part, the Trunk a second, and the Extremities a third. The division is obviously artificial, as probably every other plan must be; for in following the details of Anatomy, it is impossible to avoid chasms in the description. The human body is a whole, but made up of such a multitude of parts that no mind can comprehend or receive at once all of them. In this dilemma each writer will probably have an arrangement, which, to him, appears better than all others. It may be asked, why I have put the most difficult part of Anatomy first? I answer, that it is only first to him who chooses to study it first. The plan of the book enables the student to commence with either of the parts, with nearly equal advantage. In adopting it, the most prominent objection to my mind was the necessity of repeating the same observations in differ-

\* This arrangement has been slightly altered in the present edition but not in such a way as to affect the general plan of the work.

ent places. In writing I have had this continually in view, and though it could not always be avoided, I have nevertheless endeavoured to curtail so much its frequency, that I trust it will not be considered a blemish of much magnitude.

As the objects of this book are limited to what its title page proposes, any deficiency in it must be made up by consulting my *Treatise on Special and General Anatomy*, 4th Ed. 1836.



THE  
In writing a paper, it is essential to  
avoid the use of words which are not  
clearly understood, and to avoid the  
use of words which are not in common  
use. The words which are used in this  
paper are chosen to be understood by  
the general reader, and to be in  
common use. The words which are  
used in this paper are chosen to be  
understood by the general reader, and  
to be in common use.

## INTRODUCTION.



### *On Dissecting, and on Anatomical Preparations.*

THE dress of a student of anatomy should consist of an apron, extending from the neck to half-way down the legs; and a pair of sleeves, attached to the apron or not, according to the fancy of the wearer. It should be so loose as to give him perfect freedom in all his motions. The instruments are contained in a box, called a Dissecting Case. They should consist of four knives, one single hook, one double hook, one pair of forceps, one pair of scissors, one blow pipe, and two crooked needles.

Cleanliness is of the first importance; the dissector should, therefore, never suffer his table to become foul from blood or pieces of flesh standing on it, neither should he suffer blood to remain in the different depressions about the subject, when it can be conveniently got out. He should keep a sponge for himself, for where a sponge is used by several it becomes nobody's business to clean it; the consequence is that



it is seldom fit for use. When the integuments of a subject are laid open, the parts exposed either dry or putrefy rapidly. A constant rule is hence established not to turn down more skin than the freedom of dissection requires, and to save it as much as possible to cover the parts again, when the dissection is suspended for an interval. When there is not enough of it for this purpose, a damp cloth, several folds thick, should be at hand to assist in covering.

The knife should be held like a writing pen in the right hand; when muscles are dissected it should be exclusively used for cutting, as the scissors do not answer. The integuments of the parts covering the muscles, should be held perfectly tense with the other hand, or with the forceps. The knife should be passed with a steady and light stroke in the direction of the muscular fibres, and in such a way as just to graze them. This latter rule is indispensable; no one can dissect a muscle well without observing it, and it should be continually present to the mind of the student.

#### OF INJECTIONS.\*

There are three kinds of injections in use among anatomists, the Coarse, the Fine, and the Minute; which

\* Swammerdam first used wax injections and that about the year 1672. Corroded preparations were first made by Francis Nicolls,



are applied to the filling of the arteries and of the veins, in order to demonstrate their course more satisfactorily.

No. I.

For coarse injections, take the following ingredients:

Yellow Bees-Wax, pure, sixteen ounces,  
Bleached Rosin, eight ounces,  
Turpentine Varnish, by measure, six ounces.\*

Or, No. II.

Yellow Resin, two pounds.  
Yellow Wax, one do.  
Turpentine Varnish, a sufficient quantity to make the mixture flexible when cold.†

Or, No. III.

Tallow, two pounds,  
White Wax, ten ounces,  
Common Oil, six ounces,  
Venice turpentine, four ounces.‡

Mix and liquefy them over a slow fire, or, what is still better, in boiling water.

Professor of Anatomy at Oxford, about the beginning of the last century. Rouhaut, a surgeon of the King of Sardinia, first dissolved glue to inject small vessels with. Homberg of Paris, proposed a mixture of equal parts of tin, bismuth and brass, wherewith to inject blood-vessels by means of a pneumatic apparatus for forcing it in.

\* Fyfe,....Pole.    † Nicholls.    ‡ Munro.



For making either mixture red; add Vermilion  $\text{℥ij}$ .

do.	do.	yellow;	King's Yellow, $\text{℥ijss}$ .
do.	do.	white;	Best Flake White, $\text{℥vss}$ .
do.	do.	pale blue;	$\left\{ \begin{array}{l} \text{Best Flake White, } \text{℥ijss}. \\ \text{Fine Blue Smalt, } \text{℥ijss}. \end{array} \right.$
do.	do.	dark blue;	Blue Verditer, $\text{℥xss}$ .
do.	do.	black;	Lamp-Black, $\text{℥i}$ .
do.	do.	green;	$\left\{ \begin{array}{l} \text{Powdered Verdigris, } \text{℥ivss}. \\ \text{Best Flake White, } \text{℥iss}. \\ \text{Gamboge, powdered, } \text{℥i}. \end{array} \right.$

#### No. IV.

For Fine injection take the following:

Brown Spirit Varnish,  $\text{℥iv}$ .

White Spirit Varnish,  $\text{℥iv}$ .

Turpentine Varnish,  $\text{℥i}$ .

Mix and heat.

To make this mixture red; add Vermilion,  $\text{℥i}$ .

do.	do.	yellow;	King's Yellow, $\text{℥i}\frac{1}{4}$ .
do.	do.	white;	Best Flake White, $\text{℥ij}$ .
do.	do.	light blue;	$\left\{ \begin{array}{l} \text{Fine Blue Smalt, } \text{℥iss}. \\ \text{Best Flake White, } \text{℥i}\frac{1}{4}. \end{array} \right.$
do.	do.	dark blue;	Blue Verditer, $\text{℥iv}$ .
do.	do.	black;	Lamp Black, $\text{℥ss}$ .

#### Or, No. V.

According to Dr. Munro, a fine injection may be obtained, by pouring oil of turpentine on any finely powdered colouring matter, till it reaches a proper consistence.

## No VI.

For Minute injection take the following:

Most Transparent Glue, broken to pieces, or isinglass,*	℥viij.
Water,	℔iiss.
	Mix.

Let it stand till the glue is soft, which will take from one to two days. Then heat it gently till the consistence is uniform, or a perfect size is made.

To make this mixture red; add Vermilion, ℥v.

do.	do.	yellow; King's Yellow, ℥iv.
-----	-----	-----------------------------

do.	do.	white; Best Flake White, ℥v.
-----	-----	------------------------------

do.	do.	blue; Fine Blue Smalt, ℥viij.
-----	-----	-------------------------------

do.	do.	green;	{ Powdered Verdigris, ℥iij. Best Flake White, ℥ij. Gamboge powdered, ℥ij.
-----	-----	--------	---

do.	do.	black; Lamp-Black, ℥i.
-----	-----	------------------------

In all of these formulæ for Injections, it is of the utmost importance to success in throwing them in, to have the colours in the purest condition and reduced to the finest powder by levigation or trituration. In Philadelphia they are found, for the most part, in a state fit for use in the Druggist's, and Painter's and Glazier's shops. But to render injection still more certain it is better to strain the mixtures, after the

\* The Isinglass is much more expensive, but more minute.



colours are added, through a fine flannel cloth, which will arrest the impurities both in the original mixture and in the colouring ingredients.

### No. VII.

A commodious preparation, and, for the most part, a very successful one, has been in use amongst us for many years. It is also much approved, I have understood, in other parts of the United States, and is commonly called the Cold Injection. To make it, take

White Lead and Red Lead, of each  $\text{℥iv}$ .

Linseed Oil enough to form a thick paste by rubbing them well together. Liquefy this paste with Turpentine Varnish,  $\text{℥viiij}$ .

Just before injecting sprinkle this mixture with cold water. The advantage of it is, that it does not require the subject to be previously heated. The colour may be improved with vermilion.\*

These ingredients are used in various proportions

\* As making a mixture for each time one has to inject is rather troublesome, a larger quantity of the ingredients with the exception of the varnish may be blended, and then kept fluid for a long period by pouring water in the vessel. After the varnish is once added the mixture must be used immediately, as it then begins to thicken. This is a very common injection, and several persons have supposed themselves to be the inventors of it. I have lately been informed by the Right Rev. Bishop Onderdonk of Pennsylvania that it originated with Mr. Allan Ramsay a Scotch Anatomist.

by different anatomists, and it may be found advantageous to increase or diminish their relative quantity according to circumstances. The Red Lead is more drying than the White, and is sometimes used without the other as follows:

### No. VIII.

Red Lead.

Linseed Oil sufficient to bring it to the consistence of putty.

Then equal parts of Spirits of Turpentine and Turpentine Varnish, until it is reduced to a semifluid state.

Just before injecting sprinkle it with a little water and stir it.\*

White Lead, treated in the same way with linseed oil and turpentine varnish, may have its colour changed to fancy by any of the colouring matters mentioned. It is not necessary to strain these lead mixtures.

### No. IX.

When the student wishes only to prosecute the dissection of the vessels without making a preparation of them, the following injection will answer.

Tallow, ℥ij.

Turpentine Varnish, ℥x.

Red Lead, ℥viij.

Mix.

\* Charles Bell's system of Dissections, London, 1809.



This mixture retains its fluidity, when melted, for a long time, and may be thrown from the arch of the aorta through the primitive and many of the secondary arterial trunks, without heating the subject. Its cheapness makes it very advantageous.

The success of this injection will be increased by throwing in first, a syringe full of Nos. IV. or V. properly heated, with a view of warming somewhat the vessels and removing their rigidity.

In the use of these formulæ, excepting Nos. VII. VIII. and IX., it is indispensable to warm the subject thoroughly by previous immersion in water hot enough to excite the sensation of scalding in the finger. If the water be warmer, it will cause the parts to contract and become rigid instead of softening them. The injections must be of a proportionate temperature.

The more limited the range of an injection is, the more likely it will be to succeed well, as the force of the syringe is thereby concentrated. Hence a rule is established to put the pipe as near as possible to the part intended to be injected.

No. I. is used for corroded and dried preparations. Nos. II. and III. for the latter alone. Nos. IV. and V. are sometimes used as the precursor to the three first. No. VI. is adopted in wet preparations and such as are



intended to demonstrate minute vascularity. Nos. VII. and VIII. answer remarkably well for dried preparations; it takes about twenty-four hours to harden; the part injected should, therefore, not be disturbed till the expiration of that period.

The student acquainted with the circulation of the blood will always know where to fix his pipes when an injection is to be accomplished, whether arterial or venous, or both. It is therefore unnecessary to extend this paper by describing the method of proceeding in each individual preparation, general rules being sufficient, and to the intellectual mind much more acceptable.

#### DRIED PREPARATIONS.

Whenever a section of the body, as the head, the arm, leg, or any other part, is to be injected, the arterial pipe must be fixed into its principal trunk or trunks: and the venous pipe into one of the extreme branches. A very common, and, indeed, the most frequent source of misfortune to the young anatomist, is the neglecting to take up such vessels as were cut in the separation of the part. It may be avoided by blowing into the pipes when fixed, whereby all the ramifications being inflated, such as are cut can be thus easily found out and secured.



Male subjects, from birth till the age of twenty-five or thirty, answer best for dried preparations of the greater part of the arterial system. After thirty, few subjects answer well in consequence of a profusion of adeps blending itself with the muscles, and not unfrequently of a diseased state of the arterial system.

In dried preparations the arteries should be fairly traced in all their ramifications, and the muscles separated from each other. Every thing not essential to the object of the preparation must be cut away. When the part is fully dissected, care should be taken to put every portion of it in a proper posture, and to fix it so till it becomes stiff by exposure to the air. The muscles are to be kept asunder by strips of wood.

When the preparation is thoroughly dried, and not before, it should be varnished. But previously to the latter process, it should be washed twice with a solution of caustic potash, in order to remove a greasy coat which it is apt to form on its surface. It should afterwards be washed with water to remove the soap that results from the application of the potash. Soap-boiler's ley answers perfectly, in the place of the caustic potash of the shops. Dried preparations suffer much from insects, and the best security for them is obtained by immersion in a solution of corrosive sublimate, till



they become impregnated with it; they may afterwards be put in position and dried. If they are too large to subject to this process, even after they are dried, they may be washed four times advantageously with this mixture:

Corrosive Sublimate    ʒi.

Muriate of Ammonia, ʒiss.

Water,                    lbi.

At the two last washings add to the foregoing.

Common Glue, dissolved, ʒi.

The glue makes the mixture adhere to the preparation, and also furnishes for the varnish a basis or ground, which makes it stick and dry well. Two thin coats of copal varnish must afterwards be laid on with a soft brush.

#### CORRODED PREPARATIONS.

The heart, lungs, liver, spleen, pancreas, kidneys, and penis, are most commonly chosen in making corroded preparations. Their vessels, excretory ducts, and cavities, as the case may be, should be distended moderately with No. I. observing to give to each system in the structure of the viscus, a colour different from the rest. The successful injection of these requires good management, because, if too much force



be used, extravasation will occur and the preparation will be materially disfigured.

After injecting it, the preparation is to be laid in a mixture of three parts of muriatic acid, with one of water, which corrodes the fleshy part and leaves the injection exposed. The process of corrosion occupies from three weeks to two months, according to the bulk of the viscus. The acid becomes weakened during the time, and we should, therefore, every week, add enough of the fresh, to bring it to its original strength.

When the fleshy part is converted into a soft pulp, the preparation must be taken out of the mixture with the greatest care and subjected to a small gentle stream of water, which washes off the pulp and leaves the vessels bare. If the corroding process be unfinished the part must be replaced in the acid mixture and kept there till it is completed. On the pulp being removed, let the preparation remain floating in water for twenty four hours in order to remove any acid which may adhere to it; then dry it by suspension in the air or by laying it on a heap of soft carded cotton, covered with a thin cambric cloth, in order to prevent the cotton from sticking to its vessels.

As corroded preparations break from the slightest violence, I have latterly used with great improvement to their strength, a size of isinglass, into which they



were dipped; by repeated applications of this they become well coated with it, and thereby too strong to be injured by slight jars.

The preparation should be fixed on a pedestal of plaster of Paris, and varnished by dipping it into copal varnish diluted with one-half its quantity of spirits of turpentine. It should, after drying, be varnished in the same way once more. Such preparations, when kept under glass bells or cases, are among the most beautiful that can be made.

#### WET PREPARATIONS.

Minute injections generally, and all morbid derangements, are proper subjects for wet preparations. The natural structure of many parts is also very advantageously displayed in this way. The article previously to being put up, should be steeped in water changed daily, till all the blood is out.

Spirits of wine, spirits of turpentine, and a solution of corrosive sublimate, are each excellent for suspending such preparations in. The latter answers particularly well for eyes and for thin membranous parts, as an intestine, &c. Two grains of corrosive sublimate, with an equal quantity of muriate of ammonia, to an ounce of water, make a solution sufficiently antipu-



trescent for an eye, and which contracts the preparation much less than spirits of wine. When larger bodies are preserved the quantity of corrosive sublimate must be increased proportionately.

Bottles for wet preparations should have wide mouths, short necks, and broad heavy bottoms. The preparation being properly displayed and suspended, the mouth of the bottle must be secured with a bladder; over this must be placed sheet lead, about the thickness of a quarter of a dollar, and trimmed so as to correspond in size with the top of the bottle; over this lead another piece of bladder is to be stretched and secured. The outside bladder, being properly trimmed, should be varnished twice with copal varnish coloured with lampblack.

#### QUICKSILVER INJECTIONS.

These constitute a beautiful and interesting department in the occupations of the practical anatomist. The parts most frequently subjected to this process are the lymphatics and lacteals. In the extremities we introduce the pipe at the point farthest from the heart, and having injected one trunk, the pipe must be withdrawn and introduced into another, and so on till all the trunks are filled. In injecting for the lacteals we must introduce the pipe into a lacteal trunk



in the mesentery and inject backwards; as the lacteals on the intestine itself are, for the most part, too small to admit of its introduction into them.

The Liver has a great many lymphatics in its peritoneal coat; they may be injected from one of the trunks on the broad ligament. It is unnecessary to preserve the whole liver; a section of it half an inch thick dried and hung in spirits of turpentine answers very well.

The Parotid Gland injected with quicksilver, from its duct, affords a fine preparation. The injection must be made before the gland is removed from the body; the blood should afterwards be soaked out, and the gland dried and hung in spirits of turpentine.

The Vesiculæ Seminales and the Testicles of the adult, are also excellent subjects for this kind of preparation. The lactiferous ducts of the mammæ are very favourably displayed in the same manner; they are injected separately from the nipple.\* A woman who has died during lactation is the best subject for it.

\* Bristles should be previously introduced into each duct, and withdrawn successively as the injection advances, otherwise we may commit the mistake of injecting a duct twice. As each duct is injected, it should be secured with a ligature.



The hand of a thin, aged female may be readily injected, both arteries and veins, by a pipe fixed into the radial artery. After it is filled it should be macerated in water frequently changed till all the blood is removed and the cuticle comes off; it should then be dried and varnished.

The Veins of the kidney of a cat are said to afford a beautiful preparation with quicksilver.

#### PREPARING BONES.

Bones are best prepared by maceration in warm weather; and a dropsical subject is much better than any other, from the marrow being less abundant and mixed with serum. The skeleton should be roughly cleaned and put into a macerating vessel, the brain being removed. The water should be changed daily as long as it is discoloured by the blood. Afterwards it should be left till putrefaction has softened and dissolved all the ligaments and soft parts. The skeleton should then be taken out and washed well in clean water with a little ley added to it. It is then to be dried and is fit for use. If the maceration be properly conducted no bleaching is necessary; if otherwise, the process adopted in whitening linen and cotton clothing answers well, that is, exposure to the sun, frequent wetting with water, and chlorine.



A cranium from four to ten years old treated in this way affords a fine preparation for studying its bones in a state of separation. To accomplish the latter it is only necessary to fill its cavity with peas or beans after the maceration is over, and to immerse it in warm water. The beans in a short time begin to swell and open the sutures completely. The bones of the face must be taken asunder with the fingers.

In order to show the animal part only of bone, take a section of it and immerse it in an acid mixture composed of muriatic acid one ounce, and water one quart. In from one to four months, according to the size and solidity of the bone, the calcareous part will be taken away by the acid.\* On such a preparation one may demonstrate the pliability and the lamellated and fibrous texture of the hardest bone.

A bone, by being thrown into a strong fire, will have all its animal part destroyed and nothing but the calcareous left. This preparation is the reverse of the last.

To demonstrate the vascularity of bone, cut off the limb of a fœtus, or of a young child, and fix a pipe into the principal artery. By filling the part with the size injection, the vessels of the bone will also be injected.

\* The acid is to be renewed from time to time.



Remove the flesh when it becomes cold, and macerate in water till the blood is washed out. Place the bone in the acid mixture just mentioned till the calcareous part is removed; soak it in pure water again for a day; then dry it, and finally immerse it in spirits of turpentine to make it transparent.\*

#### ON FUMIGATION.

The air of rooms where dead bodies are kept, as well as the walls and furniture, become exceedingly offensive; to correct which we resort to the following mixture with great advantage. It is called the Guytonian from its inventor.

Take Manganese or peroxyd of 1 part	
Common salt	7 parts
Water	4 parts
Sulphuric acid at 66°	4 do each by weight.

The water and the acid should be previously mixed and allowed to cool. Then stir all the ingredients well together in a stone vessel.

When the room is abandoned for the night, close its doors and windows and commence this fumigation.

\* For a very valuable and instructive exposition in detail, of the art of making anatomical preparations; I would recommend the treatise on this subject by Usher Parsons, M. D., Professor, &c.



The next morning it will be found much sweetened, and on ventilating freely, its atmosphere will lose still more of its offensiveness and be in a great measure renovated.

The fumes of this mixture are very penetrating; they give their peculiar smell to clothing for several days, and rust metallic surfaces intensely. All articles, therefore, which are not intended for such depuration should be removed.

A milder fumigation which may be used beneficially in sick chambers is obtained by pouring in successive portions, five parts of hydrochloric acid upon one of peroxyd of manganese.

---

Students of Anatomy have their fears much excited on the score of the constitutional symptoms, arising from small wounds inflicted during their dissections; under an erroneous impression, that a specific virus is, thereby, introduced into the system. Inconveniences of this kind, though they do occasionally occur, are by no means frequent; and are just as apt to be produced from the prick of a needle, of a brier, or of an oyster-shell. The first intimation of such mischief, is the part becoming painful, red, and swollen, and the arm getting somewhat stiff; if in the early stage of these symptoms, a blister be applied according to the recommendation of Dr. Physick, the person live lightly, and take a saline cathartic, the treatment is almost invariably sufficient for the cure. Such accidents are much more liable to occur from the prick of a spicula of bone, than from any other cause to which the Anatomist is exposed, furnishing thereby, a useful hint for him, never to break a bone, but always to saw it off smoothly.





LESSONS  
IN  
PRACTICAL ANATOMY.

---

PART I.  
OF THE HEAD AND NECK.

---

CHAPTER I.  
OF THE EXTERNAL PARTS OF THE HEAD AND NECK.

THE integuments of the cranium are remarkably thick and hard, but give the sensation, when felt externally, of being a very thin layer spread over the bones. The latter is particularly the case as far as the hair extends. They consist of skin, and below it of small, compact, granulated masses of fat enclosed in the cells of a cellular substance; which has very much of a ligamentous character, and adheres closely to the muscle and tendinous matter beneath.

The muscles of the face should always be dissected as early as possible after death; under the most



favourable circumstances they are difficult for the student to make out, and are rendered unintelligible to him in a few days by the changes which their diminution of volume, infiltration, and confusion of colour with contiguous parts, produce.

I would also advise that one side of the face and neck be appropriated exclusively to the dissection of the fasciæ, muscles, and glands; every thing, therefore, should be removed which interferes with a thorough examination of them. The student having accomplished this, may afterwards work on the other side of the subject for the blood-vessels and nerves. To trace the arteries properly, they ought to be filled previously with common injection; tallow, coloured with red-lead, answers very well; it is of less importance to inject the veins. It is unnecessary to heat the subject for such injection.



## SECTION I.

### *Of the Muscles and Fasciæ.*

THE OCCIPITO-FRONTALIS muscle consists of two symmetrical parts, and coming from the back of the head is inserted into the front of it; it has four bellies of muscular fibres, two behind and two before, connected by a thin tendon which covers all the top of the head. The dissection of this muscle is difficult,



from the close adhesion of its tendon to the pericranium below, and to the integuments of the head above. It is best, therefore, to commence by making one incision, through the integuments only, from the root of the nose to the fore end of the sagittal suture, and another from the commencement of the first along the upper margin of each eyebrow to the external angular process of the os frontis; by raising up this flap and enlarging it in an appropriate manner on each side, it leads to the dissection of the whole muscle.

It arises from the superior semicircular ridges of the os occipitis by tendinous and fleshy fibres which form two distinct bellies about an inch and a half long, one on each side of the bone. Its tendon, when carefully traced, will be found terminating a little in front of the coronal suture in the two anterior fleshy bellies which cover the whole front part of the os frontis. The internal edges of these latter are in conjunction below.

It is inserted fleshy, on each side, into the superior margin of the orbicularis oculi and corrugator supercilii, and by its nasal slip into the internal angular process of the os frontis and into the root of the os nasi.

It pulls the skin covering it backwards and forwards, and throws the forehead into horizontal wrinkles. It also elevates the supercilia.

The COMPRESSOR NARIS arises by a pointed begin-



ning from the root of the ala nasi; it spreads like a fan over the lateral parts of the nose below, is inserted into its fellow of the opposite side, on the dorsum of the nose; and into the lower part of the os nasi, where it is connected with the nasal slip of the occipito frontalis.

This muscle consists of thin and pale fibres immediately under the skin. If it act from both extremities by its curved fibres being made straight, it will compress the nostril; but if it act from its dorsal margin assisted by the nasal slip of the occipito frontalis, it will dilate the ala nasi, and has, therefore, been called dilatans nasum by Columbus.

The ORBICULARIS PALPEBRARUM is a broad circular muscle lying immediately under the skin of the eyelids, and over the tarsi cartilages. It covers the whole front of the bony orbit and extends from four to eight lines beyond its margin, being connected to subjacent parts by cellular tissue; its temporal section is fastened to the temporal fascia beneath.

It arises fleshy from the internal angular process of the frontal bone, from the upper end of the nasal process of the os maxillare superius and the os unguis, and from the upper edge of the round horizontal tendon called internal palpebral ligament that fixes the internal commissure of the eyelids to the nasal process of the superior maxilla. These fibres perform the circuit of the eyelids, and, coming around to the internal canthus



again, are inserted into the orbital margin of the nasal process, and of the orbitar process of the upper maxilla, and into the lower edge of the same horizontal tendon.

The Ciliaris muscle is the internal margin of the orbicularis planted on the edges of the tarsi cartilages.

As the Orbicularis muscle is fixed at its nasal and temporal portions more than elsewhere, it is obvious that the contraction of its circular or curved fibres by making them straight, will close the eyelids and wrinkle the skin on them. This muscle frequently has a slip from its lower border to the upper lip, anterior to the zygomaticus minor.

The CORRUGATOR SUPERCILII is placed at the internal end of the superciliary ridge. It arises from the internal angular process of the os frontis, and passing obliquely upwards and outwards between the lower edge of the occipito frontalis and the upper edge of the orbicularis, is concealed by them. It is inserted into the former principally, but its fibres also blend with the latter.

It draws the forehead into vertical wrinkles.

The LEVATOR LABII SUPERIORIS ALÆQUE NASI is fixed just at the side of the nose. It arises by a pointed production from the nasal process of the os maxillare superius near the internal canthus of the eye, and by a broad origin from the anterior margin of the orbitar process of the same bone. Passing



downwards it is inserted into the side of the ala nasi, and into the upper lip, being narrower below than above.

It draws the upper lip and the ala nasi upwards.

The **LEVATOR ANGULI ORIS** is a small muscle concealed very much by the last; it arises from the anterior part of the superior maxillary bone, between the foramen infra-orbitarium and the first small grinder, and is inserted into the corner of the mouth.

It raises up the angle of the mouth.

The **ZYGOMATICUS MINOR** is a small muscle sometimes deficient, arising from the fore part of the os malæ; it descends obliquely and is inserted into the upper lip just above the corner of the mouth.

The **ZYGOMATICUS MAJOR**, being on the outside of the last and much larger, arises from the malar bone externally, at its posterior inferior part just above the lower edge, where this bone contributes to form the zygoma, and passing obliquely downwards is inserted into the corner of the mouth, by running into the depressor anguli oris.

These two last muscles draw the corner of the mouth towards the cheek bone, or obliquely upwards and outwards as in smiling.

The **DEPRESSOR LABII SUPERIORIS ALÆQUE NASI** is



concealed by the orbicularis oris and by the levator labii superioris alæque nasi. To get a view of it the upper lip must be inverted and the lining membrane of the mouth removed on the side of the frænum of the lip. This muscle arises from the inferior part of the upper maxilla in front of the alveolar processes for the dens caninus and the incisores, and is inserted into the side of the ala nasi and into the contiguous part of the upper lip.

It depresses the upper lip and the ala nasi.

The **DEPRESSOR ANGULI ORIS** arises broad and fleshy from the base of the lower jaw on the side of the chin; being somewhat triangular, its apex is inserted into the corner of the mouth.

This muscle draws the corner of the mouth downwards. It lies immediately under the skin, and blends above with the zygomaticus major and with the levator anguli oris.

The **DEPRESSOR LABII INFERIORIS** is in part beneath the last muscle, and, like it, arises broad and fleshy from the basis of the lower jaw on the side of the chin; its fibres pass obliquely upwards and inwards and are inserted into the whole side of the lower lip.

It draws the lip downwards.

These two last muscles are much obscured by being mixed with a quantity of adipose matter; the skin, also,



is closely blended with them, and the roots of the beard penetrate between the intervals of their fibres.

The **LEVATOR LABII INFERIORIS**, being placed beneath the depressor labii inferioris, is demonstrated by turning downwards the lower lip and dissecting away its lining membrane on the side of the frænum; It will then be seen to arise in front of the alveolar process of the external incisor and the canine tooth of the lower jaw, and passing obliquely downwards to be inserted into the lower lip.

It elevates the lower lip.

The **BUCCINATOR** muscle arises from the root of the coronoid process of the lower jaw bone, from the back part of the upper maxilla near the pterygoid process and from the roots of the alveolar processes of both bones as far forwards as the dentes bicuspidés. It is inserted into the corner of the mouth and into the contiguous parts of the upper and lower lip.

It draws the corners of the mouth directly backwards.

The **ORBICULARIS ORIS** is a circular muscle just beneath the skin, much blended with adipose matter externally, but more plain on the surface contiguous to the lining membrane of the mouth. It constitutes considerable part of the thickness of the lips, and



surrounds the mouth entirely. It has no bony origin, but arises from the fibres of the several muscles which join each other at the corner of the mouth, and, therefore, consists of two semicircular planes, one for the upper, and the other for the lower lip.

It is the antagonist to most of the other muscles of the mouth. From its superior part a pyramidal slip goes to the tip of the nose, called by Albinus, *Nasalis Labii Superioris*.

The *MASSETER* is placed immediately under the skin, and forms the fleshy protuberance on the back of the face before the ear. It arises tendinous and fleshy from the malar process of the upper maxilla, and from the inferior edge of the malar bone between the maxillary and zygomatic sutures; it arises also from the temporal bone between the zygomatic suture and the tubercle. The masseter covers all the exterior surface of the ramus of the lower jaw, as low down as its base. It is divided into two portions, which lie one beneath the other; the internal is the smaller, and is inserted tendinous into the outer part of the root of the coronoid process. The external extends from the malar bone to the angle of the inferior maxilla, where it is inserted tendinous and fleshy. A part of the internal portion may be seen at the zygomatic suture behind the external, without the latter being raised up.

It closes the jaws.



The *TEMPORALIS* lies on the side of the head occupying its middle inferior region; it is covered externally by a thick dense tendinous membrane, the fascia temporalis, which arises from the semicircular ridge on the side of the cranium, and is inserted into the upper margin of the zygoma. By removing this fascia, the temporal muscle is seen to arise fleshy from its inner surface, from the semicircular ridge on the side of the os frontis and parietale its whole length, also from the surfaces of bone, between this ridge and the zygoma including a part of the frontal bone, the lower part of the parietal, and the squamous portion of the temporal. From this extensive origin, the fibres converge towards the zygoma and are inserted tendinous into the coronoid process of the lower jaw, surrounding it on every side; some of these tendinous fibres in front go down nearly as low as the last dens molaris.

The temporalis receives a small accession of fleshy fibres from the internal face of the zygoma. It pulls the lower jaw directly upwards.

This is a proper place also for looking at the Pterygoid muscles; they are, however, but imperfectly seen. The only way to get a very good view of them is to make the dissection on a vertical section of the head, or on a head detached from the cervical vertebræ, which can be done very conveniently when we are engaged in the study of the nose, or of the pharynx.



The **PTERYGOIDEUS EXTERNUS** arises fleshy from the outer side of the external pterygoid process of the sphenoid bone, from the tuber of the upper maxillary, and from the under surface of the temporal and spinous process of the sphenoid bone. It passes outwards and backwards horizontally, and is inserted into the inner side of the neck of the inferior maxilla and into the capsular ligament of the articulation.

The **PTERYGOIDEUS INTERNUS** arises by tendinous and fleshy fibres from the internal plate of the pterygoid process of the sphenoid bone, at the outer side of the Eustachian tube. It fills up the most of the pterygoid fossa, and passing downwards and backwards, is inserted tendinous and fleshy into the interior face of the angle of the lower jaw.

Both of these muscles are important in mastication; they close the jaws, throw the lower one forward, and produce the grinding motion by acting alternately.

*Of the Muscles of the Neck.* The dissection of this part can now be advantageously pursued; with which view, make one incision through the skin, along the clavicle and upper edge of the sternum, another from the chin, over the thyroid cartilage to the sternum, and a third from the chin to the upper part of the ear. The flap thus marked out is to be raised carefully without cutting up a superficial membrane that lies below the skin called *Fascia Superficialis*.



The *Fascia Superficialis Cervicis* or *Colli* is a continuation of the one placed in front of the abdominal muscles, and which passes from them to the thorax and afterwards to the neck. Its connexion with the clavicle and sternum is not very strong, and it goes from them along the neck to the face, being slightly fastened to the base of the lower jaw in advance of the *masseter* muscle. It is spread over the *parotid* gland, is fixed to the *mastoid* process, to the *meatus auditorius*, and to the *zygoma*; in the latter place it is continuous in some measure with the *fascia temporalis*. The existence of this membrane is thought, by Mr. Colles of Dublin, to obscure the affections of the neck and of the *parotid* gland, by checking the development of tumours, rendering their fluctuation and particular feel very equivocal, and giving a wrong course to the pus when they suppurate. The *fascia superficialis* is better marked over the *parotid* gland, and about the base of the jaw, than lower down.

The *PLATYSMA MYODES* muscle, or the *MUSCULUS CUTANEUS*, is immediately beneath the *fascia superficialis*, or rather is between two laminæ of it, the thicker one being the innermost. It covers a very considerable portion of the side of the neck, and extends from the thorax obliquely to the face.

It arises from the condensed cellular membrane on the upper part of the *pectoralis major* muscle and the *deltoid*, just below the clavicle and nearly the whole



length of this bone. Its fibres are much more pale than those of other muscles, are collected into longitudinal fasciculi, constituting a plane of scarcely a line in thickness, and terminate in the integuments of the lower jaw and cheek. It is slightly attached to the lower jaw, and sometimes runs into the muscles of the lower part of the face.

When the whole muscle is in action, it elevates the skin of the neck. The external jugular vein is seen nearly in the centre of it, in the same direction with the fibres of this muscle, between it and the sternomastoid.

The STERNO-CLEIDO-MASTOIDEUS is beneath and decussates the last muscle. It forms always a prominent feature in the outline of the neck, by passing obliquely from the upper front part of the thorax to the base of the cranium.

It arises tendinous and fleshy from the edge of the upper part of the sternum, and fleshy from the sternal end of the clavicle. These origins are separated by a considerable fissure; they soon unite and are inserted tendinous into the mastoid process and into that part of the superior transverse ridge of the head next to it.

It draws the head towards the sternum. This muscle is to be detached from its origin, and allowed to hang aside by its insertion, in order to get at the parts beneath. We shall then see two narrow, hand-



some ribbon-like muscles on each side of the middle line of the trachea; they are the sterno-hyoideus and sterno thyroideus. But before we go to the dissection of them, it is necessary to look at another fascia of the neck; the

*Fascia Profunda Colli* or *Cervicis*. When the origin of the sterno-cleido mastoideus is turned to one side, the Fascia Profunda of the neck is brought into view. This membrane arises from the larynx, forms a thin capsule to the thyroid gland, and being closely attached to its inferior margin, it descends by investing the sterno-hyoid and thyroid muscles, being well marked on their anterior surfaces. It is firmly fastened to the upper edge of the sternum, the sternal end of the clavicles, and to the cartilages of the first ribs, forming an elastic and resisting membrane from the larynx to the thorax. By turning off the sterno-hyoid and thyroid muscles from their attachment to the sternum, the fascia profunda will be seen still more distinctly passing behind them from the inferior margin of the thyroid gland to the upper bone of the sternum, this lamina of it being inserted into the sternum twelve or fifteen lines below its upper edge. It encloses or surrounds the transverse vein and the arteria innominata.

Beneath the fascia profunda, are the trachea, the roots of the arteries of the head and upper extremities, and the trunks of their veins. There is much loose cellular and adipose matter placed at the lower part of



the neck beneath this fascia, between it and the trachea, and through which the thyroid veins with their ramifications pass. This last circumstance must always render suppurations and operations in the part highly dangerous, as the pus may form fistulæ under the sternum; moreover, the continual motion of the part in respiration prevents adhesion from occurring, and, therefore, disposes to ulceration. An ingenious idea on the uses of this fascia and of the sterno-hyoid and thyroid muscles as connected with it, was suggested by the late ALLAN BURNS; he conceived that they were a defence to the upper part of the thorax, and sustained the atmospheric pressure, which, without them, would fall upon the trachea, and produce difficulty of breathing, from the air not passing through the larynx sufficiently rapidly to keep pace with the dilatation of the thorax. He illustrates the opinion by a case very much in point, of a gentleman who had lost this fascia and the muscles by suppuration, and who was afterwards incommoded by atmospheric pressure upon the trachea at this place.\*

The external borders of the fascia profunda are

\* The late Dr. Jason O. B. Lawrence, who, to the great regret of all who knew him, died prematurely, in 1823, in the midst of his labours and usefulness in anatomy, informed me that this fascia profunda is well developed in the neck of a cat; and that having occasion to remove it in an experiment, the respiration of the animal was conducted with great difficulty, amounting almost to suffocation. This is a good confirmation of Mr. Burns's hypothesis.



continued into the sheaths of the great vessels of the neck. It and the fascia superficialis are also continuous with each other along the anterior edge of the sterno-cleido-mastoideus.

Within the inferior maxilla, at its angle, is a ligamentous expansion connected with the pterygoideus externus muscle, and spread out between the styloid process and the ramus of the lower jaw. This membrane called the stylo-maxillary ligament, is joined with the fascia superficialis at its inferior edge just before the upper part of the sterno-mastoideus, whereby its breadth is increased downwards in the neck, giving it somewhat the condition of a vertical septum of that region; and at its lower edge it runs into the cellular sheath of the great vessels of the neck. Through its lower part, penetrate the stylo-hyoideus and the digastricus muscle, and the upper part separates the parotid from the submaxillary gland. It is felt like a cord extending downwards and backwards below the angle of the maxilla inferior. It is connected at its internal edge with the compages of the nerves and vessels of the part in such a manner as to forbid description, but the practical anatomist will find no difficulty in discovering and understanding it.

Below this septum a round ligament like a nerve passes from the extremity of the styloid process to the appendix of the os hyoides.

The STERNO-HYOIDEUS arises thin and fleshy on the



interior of the thorax from the approximated surfaces of the cartilage of the first rib, the clavicle, and the first bone of the sternum; it passes upwards, somewhat obliquely, and is inserted into the inferior edge of the base of the os hyoides.

It draws the os hyoides towards the sternum.

The STERNO-THYROIDEUS is beneath the last and concealed in a considerable degree by it. It arises fleshy from the interior surface of the sternum, about an inch below its upper margin, and from the cartilage of the first rib; diminishing in breadth somewhat as it ascends, it is inserted obliquely into the side of the thyroid cartilage.

It draws this cartilage towards the sternum.

The THYREO-HYOIDEUS arises obliquely from the side of the thyroid cartilage externally, and is inserted into a part of the base and nearly all the cornu of the os hyoides. It looks like a continuation of the last.

Use; To draw up the thyroid cartilage.

The OMO-HYOIDEUS passes obliquely across the neck from the superior edge of the scapula to the os hyoides. It is a thin narrow muscle divided into two bellies, one at each end, by an intermediate tendon; its inferior part is concealed by the trapezius muscle, its middle, where the tendon exists, crosses the great vessels of the neck and is covered by the sterno-cleido-



mastoid muscle, and its upper extremity is over-lapped by the platysma myodes.

It arises from the scapula just behind the notch in its superior costa, and curving somewhat downwards in its course is inserted into the lower edge of the base of the os hyoides next to its cornu.

It draws the os hyoides downwards.

The DIGASTRICUS is a double-bellied muscle at the upper side of the neck, passing from the back part of the base of the head to the chin. It arises, principally fleshy, from the fossa of the temporal bone at the inside of the mastoid process; as the muscle descends towards the os hyoides, its middle part is formed by a round tendon which passes through the stylo-hyoideus muscle, and is fixed, by a ligamentous loop, to the cornu of the os hyoides. After this the muscle becomes again fleshy, and is inserted into the inside of the base of the maxilla inferior at the side of the chin. It receives an accession from the base of the os hyoides.

It draws the os hyoides upwards. By raising the posterior belly of this muscle we get a better view of the styloids, which are three in number, and placed within it.

The STYLO-HYOIDEUS, being the <sup>most</sup> ~~more~~ superficial of the three, arises tendinous from the middle and inferior part of the styloid process of the temporal bone, and being perforated, as mentioned, by the tendon of the



digastricus, is inserted tendinous into the cartilaginous juncture of the base and cornu of the os hyoides.

It draws the os hyoides upwards and backwards.

The **STYLO-GLOSSUS** is within and above the other; it arises from the upper internal part of the styloid process, tendinous and fleshy, and is inserted into the side of the root of the tongue, forming thereby a part of its structure.

It draws the tongue backwards.

The **STYLO-PHARYNGEUS** is more deeply situated than either of the other two muscles. It arises from the inner side of the styloid process near its root, and is inserted into the inside of the pharynx between the middle and upper constrictors, opposite the tonsil gland. It afterwards continues between the lining membrane of the pharynx and the middle and lower constrictors, to the posterior margin of the thyroid cartilage.

It draws the larynx and pharynx upwards.

The **MYLO-HYOIDEUS** forms the floor of the mouth, and suspends the tongue; it arises from a ridge at the root of the alveolar processes of the lower jaw, extending from the last dens molaris to the chin. Its fibres converge inwards, and are inserted into the corresponding fibres of the opposite side by a white tendinous line placed between it and its fellow, and extending from the base of the os hyoides to the chin. This



muscle lies above, so as to be concealed by the anterior belly of the digastricus, and when it contracts it draws the os hyoides upwards, and projects the tongue.

The GENIO-HYOIDEUS is immediately above the last, by turning down the anterior edge of which, it is seen. It arises tendinous from the tubercle on the posterior side of the symphysis of the lower jaw, and increasing somewhat in breadth, is inserted into the anterior part of the base of the os hyoides.

It draws the os hyoides upwards and forwards. By removing this muscle we bring into view

The GENIO-HYO-GLOSSUS, which arises also tendinous from the tubercle on the inside of the maxilla inferior, near the symphysis, and is inserted into the base of the os hyoides, and into the tongue its whole length, constituting a part of its substance. The muscles of the opposite sides are in contact, and throw the tongue into a great variety of positions, according to the fibres which are brought into action.

The HYO-GLOSSUS is just on the exterior of the last. It arises from the base and part of the cornu of the os hyoides broad and fleshy, and is inserted into the side of the tongue. It draws the tongue inwards and downwards.

The LINGUALIS may also be seen in part in this dis-



section. It is one of the intrinsic muscles of the tongue, and lies on the inner side of the last. For a further account of the muscles of the tongue, see the article MOUTH.

There are four pairs of muscles situated behind the pharynx and œsophagus, close to the cervical vertebræ, which can only be seen imperfectly in this dissection.

1. The LONGUS COLLI is next to the middle line of the vertebræ, and arises from the sides of the bodies of the three superior vertebræ of the back, and from the anterior edges of the transverse processes of the five lower cervical vertebræ. Its fibres pass somewhat obliquely upwards and inwards, to be inserted into the front of the bodies of all the cervical vertebræ.

It bends the neck forwards, and to one side.

2. The RECTUS CAPITIS ANTICUS MAJOR arises tendinous and fleshy from the fronts of the transverse processes of the third, fourth, fifth and sixth cervical vertebræ, forms a considerable fleshy belly, and is inserted into the cuneiform process of the os occipitis just before the condyle. It is placed on the outside of the longus colli, and bends the head forwards.

3. The RECTUS CAPITIS ANTICUS MINOR arises fleshy from the front of the first cervical vertebræ near its transverse process, and is inserted under the rectus



major before the root of the condyloid process of the occipital bone.

It bends the head forwards.

4. The **RECTUS CAPITIS LATERALIS** arises fleshy from the front of the transverse process of the atlas, and is inserted tendinous and fleshy into the ridge on the outside of the condyle of the occiput, leading from it to the mastoid process. It pulls the head a little to one side.

On the outside of these muscles, passing from the exterior edges of the cervical vertebræ to the upper parts of the thorax, are the **Scaleni** muscles, three in number, and named from their situation.

1. The **SCALENUS ANTICUS** arises by three distinct tendinous heads from the transverse processes of the fourth, fifth and sixth cervical vertebræ, and is inserted tendinous and fleshy into the upper edge of the first rib, just anteriorly to its middle.

2. The **SCALENUS MEDIUS** arises by distinct tendons from the transverse processes of all the cervical vertebræ, and is inserted tendinous and fleshy into the upper part of the first rib, in all the space from its middle to its tubercle.

3. The **SCALENUS POSTICUS** arises from the transverse



processes of the fifth and sixth cervical vertebræ, and is inserted into the upper face of the second rib just anterior to its tubercle.

These muscles are concealed by the sterno-cleido-mastoideus and the anterior edge of the trapezius; to be well seen, the clavicle should be loosened from the sternum and thrown off to one side. The third Scale-nus is best seen in dissecting the muscles of the spine, and resembles very much one of that class to which Albinus gives the name of Levatores Costarum. All the Scaleri elevate the ribs and bend the neck to one side. They are particularly interesting as connected with the course of the large blood-vessels and nerves of the upper extremity, which will be more particularly alluded to in the dissection of the axilla.



## SECTION II.

### *Of the Glands of the Head and Neck.*

THE THYROID GLAND, (*Gland. Thyroidea*,) consisting of two lobes united by an isthmus, is placed on each side of the upper part of the trachea, and extends upwards laterally by the cricoid cartilage to the thyroid. It resembles a pair of saddle-bags in its general outline; the upper edge, however, being very much ex-



cavated or crescentic, with the horns pointing upwards. The isthmus passes over the second ring of the trachea, and is firmly fixed to it by a short cellular substance. Duverney and Sæmmering in their plates represent a muscle, passing on the left side of the larynx, from the base of the os hyoides to the upper edge of the thyroid gland, to which they give the name of *Musculus Glandulæ Thyroideæ*. Its occurrence in this country is, I presume, exceedingly rare, as out of several hundred subjects which I have superintended the dissection of, but few examples of it have been noticed.

It may be observed, however, that a process of the isthmus looking like a muscular slip is frequently formed on the left side, and goes up to the base of the os hyoides, and that sometimes a few filaments are detached to the gland from the thyreo-hyoid or crico-thyroid muscle.

This gland is covered by the sterno-hyoid and thyroïd muscles. It is of a dark brown colour, has a capsule from the contiguous cellular membrane or fascia, besides its own proper coat. The structure of it is very imperfectly understood; the most that we know is, that it is extremely vascular; when cut into or inflated it exhibits a great number of cells communicating with each other, of different sizes, and containing an unctuous and somewhat transparent fluid, and that it has no excretory duct.



On each side of the neck are three large salivary glands, the Parotid—the Submaxillary—and the Sublingual.

The PAROTID GLAND (*Glandula Parotis*) is the most considerable of the three, and its form is very irregular, depending on the space into which it is crowded. It reaches from the zygoma downwards to the angle of the jaw, occupying the space from the mastoid process and meatus auditorius to the ramus of the jaw, and extending from the skin externally to the styloid process, styloid muscles, and the tendon of the digastricus internally; it is there only separated from the internal carotid artery by these parts internally; its connexions are numerous and exceedingly intricate. It is removed in the dead subject from the contiguous parts with great difficulty, and in the living subject its complete and safe extirpation is nearly impracticable. The portio dura nerve and the external carotid have to penetrate directly through its substance in order to arrive at their destinations.

It has been observed that this gland is covered externally by an extension of the fascia superficialis of the neck; from the interior face of this fascia many prolongations are sent off, which penetrate the gland in every direction, separating its lobules from each other and conducting the blood-vessels and nerves through its substance. The substance of the gland is formed of small rounded granulations of a light pink colour,



united into lobules of various forms; an arteriole may be injected, going to each of them.

The parotid gland is elongated at its anterior margin into a point, lying on the posterior part of the masseter muscle. From the upper part of this point proceeds the parotid duct across the masseter muscle, about eight lines below the zygoma; and according to the observations of Dr. Physick, in a line from the under part of the lobe of the ear to the tip of the nose. The parotid duct, (*Ductus Stenonianus*), is about the size of a crow quill; it arises from the granulations of the gland, by ramuscles which, unite successively, to form it. The gland is sometimes divided into two lobes, in which case each has an excretory duct that joins the other, half an inch in front of the anterior edge of the gland. The common duct lies close to the masseter muscle, and may easily be overlooked by the young anatomist; forwards it dips over the edge of this muscle into a fatty mass between it and the buccinator, and, perforating the latter, has its orifice in the mouth, opposite the second large molar tooth of the upper jaw.

Sometimes at the posterior part of this duct, between it and the zygoma, a small gland is situated, varying in its size and form, and called by Haller the accessory of the parotid.

The SUBMAXILLARY GLAND (*Gland. Sub-Maxillaris*) is irregularly ovoid. It is situated below the Platysma



myodes in the space bounded by the digastric muscle below, the mylo-hyoid towards the mouth, and the body of the lower jaw externally—and is in contact with the facial artery. It almost touches the parotid gland behind, being separated from it only by the septum sent in from the fascia superficialis; and at the posterior edge of the mylo-hyoideus it touches the sublingual gland.

Its structure is the same with that of the parotid gland, except the capsule of cellular membrane with its internal prolongations, being much looser. It has an excretory duct, (*Ductus Whartonianus*), arising in the same way by ramuscles, but much thinner and more extensible than the parotid duct; it penetrates between the back edge of the mylo-hyoid and the hyoglossus muscle, and continues between the genio-hyoglossus and the sublingual gland; from the latter it receives occasionally several branches; it terminates by an orifice on the side of the frænum linguæ near its anterior edge.

The SUBLINGUAL GLAND (*Glandula Sublingualis*) is placed under the lining membrane of the mouth between the side of the tongue and the mylo-hyoid muscle, and being oblong it is parallel with the genio-hyoglossus where the latter is about to join the tongue.

This gland is not uniform in the arrangement of its excretory ducts. Sometimes it has fifteen or twenty excretory orifices in the lining membrane of the mouth;



on other occasions several of these short ducts are collected into one or two principal trunks (*Ductus Riviniani*) which open either directly into the mouth or into the duct of Wharton. By turning up the tip of the tongue, the projection of this gland is readily seen, as well as several salivary granulations, or little glands, which border on it.

*Lymphatic Glands.* Medical men are often consulted on the subject of indurated and not very painful swellings in the neck, which most frequently are enlarged lymphatic glands. In a course of dissections these should by no means be overlooked, as they are very numerous. They vary much in size and number; being for the most part flattened ovals, some are not more than two lines in their long diameters; others are nine or ten lines long. They are both superficial and deep-seated.

Between the skin and the insertion of the sterno-mastoid muscle there are from four to six; in the interstice just above the clavicle between the posterior edge of the sterno-mastoid muscle and the anterior edge of the trapezius, bordering on the external jugular vein, there are half a dozen. Between the skin and the parotid gland there are two, one above and the other below. On the submaxillary gland, and at its anterior and posterior extremities, there are eight or nine. It is supposed, by respectable surgeons, that several asserted cases of extirpation of the parotid and



of the submaxillary gland, have amounted actually only to the removal of some of these lymphatic glands in a state of enlargement.

The deep-seated lymphatic glands are also very abundant; along the course of the great cervical vessels, but principally between them and the anterior edge of the trapezius muscle, there are about twenty. Between the lower edge of the thyroid gland and the sternum on the trachea, there are four, and this chain is continued downwards towards the heart by the existence of several on the side of the œsophagus, trachea, and great blood-vessels.



### SECTION III.

#### *Of the Blood-Vessels of the Neck and Head.*

THE RIGHT CAROTID ARTERY is a branch of the arteria innominata, and the left a branch of the aorta; their course differs somewhat at first, the right being more oblique, afterwards the course and distribution are uniform in both. A regular ascent is performed in front of the cervical vertebræ at the side of the œsophagus and pharynx, no branch being sent off till the carotid is near the os hyoides and just below its cornu. Here it divides into two branches of nearly equal size, the internal and the external carotid; the



first is intended for the brain, and the last for the external parts of the neck and head. In the lower part of the neck the carotid is covered by the sterno-hyoideus and thyroideus and the anterior edge of the sterno-cleido-mastoideus, and at an inch and a half below its bifurcation it is crossed obliquely by the omo-hyoideus muscle. This point may be ascertained before the skin is opened by a horizontal line drawn across the neck over the first ring of the trachea, and consequently below the larynx. In its whole course it is joined with the par vagum, sympathetic and descendens noni nerves.

Parallel with the larynx the carotid may be felt pulsating very distinctly, being there covered only by the platysma myodes. It is contained in a sheath of condensed cellular membrane common to it, the internal jugular vein and the par vagum nerve.

The EXTERNAL CAROTID, (*Carotis Externa*) at the place of bifurcation, is interior and anterior to the internal carotid, and it immediately begins to send off branches in the following order:

1. The ARTERIA THYROIDEA SUPERIOR passes in a meandering direction to its principal destination the thyroid gland, through which it is minutely distributed anastomosing freely with the other arteries of the same body. In its course it sends off the laryngeal branch, which penetrates to the muscles of the larynx, between



the os hyoides and thyroid cartilage and also some twigs to the same between the thyroid and cricoid. It sends off some smaller branches to contiguous parts.

2. The ARTERIA LINGUALIS arises just above the last; it goes very near the cornu of the os hyoides, by penetrating the hyo-glossus muscle. At the root of the tongue it sends off a transverse branch (the Dorsalis Linguae), and a little further forwards it divides into two branches, one going to the Sublingual Gland (the Ramus Sublingualis), the other distributed through the tongue (the Arteria Ranina.)

3. The ARTERIA FACIALIS arises near and above the other; it is tortuous, passing under the stylo-hyoid and the tendon of the digastric muscle. It is much involved with the submaxillary gland, to which it sends branches. The submental branch arises from it here, which passes forwards to the symphysis of the jaw, near the exterior margin of the mylo-hyoid muscle.

The Arteria Facialis mounts over the lower jaw just before the masseter muscle; to the latter it sends a branch; forwards it sends another towards the front of the chin called Inferior Labial. On a line with the corner of the mouth, it sends to the lips the Inferior and the Superior Coronary Arteries, which are very tortuous and surround the mouth, anastomosing freely with those of the other side.

After this the facial artery ascends to the internal



canthus of the eye, sending off intermediately a branch to the ala nasi, and another which anastomoses with the inferior orbital artery; at the internal canthus it anastomoses with branches from the ophthalmic and then terminates.

4. The ARTERIA PHARYNGEA INFERIOR arises from the carotid opposite to the lingual; it is small, being distributed on the pharynx and sending a branch upwards through the foramen lacerum to the dura mater.

5. The ARTERIA OCCIPITALIS is large, and arises opposite to the facial and sometimes higher up. It crosses over the internal jugular vein and the eighth pair of nerves, passes the base of the cranium under the insertion of the muscles going to the mastoid process, and is distributed to the parts lying on the occipital bone; its upper branches anastomose with those of the temporal artery.

Its collateral branches are, one to the dura mater through the posterior foramen lacerum, or the mastoid foramen, another to the interior parts of the ear, and a considerable one to the complexus and adjacent muscles of the neck.

6. The POSTERIOR AURIS, or ARTERIA STYLO-MASTOIDEA, arises from the carotid at the lower edge of the parotid gland, and passes backwards and upwards between the meatus externus and the mastoid process,



to terminate behind the ear. It is distributed principally to the contiguous superficial parts but, one branch goes up the stylo-mastoid foramen, to the tympanum and to the labyrinth.

The EXTERNAL CAROTID, while detaching these branches, becomes very deeply situated under the digastric and stylo-hyoid muscles, and the inferior end of the parotid gland, afterwards it penetrates the substance of the gland, becoming much involved in it, and sending off several small twigs. It ascends through the gland and exhibits itself superficially just before the meatus externus, in mounting over the root of the zygoma. When on a line with the neck of the jaw bone it sends off a very large branch, the internal maxillary, to the parts underneath the ramus of the bone. The origin of this branch is to be considered as the termination of the name external carotid, and the trunk is afterwards called temporal.

The ARTERIA TEMPORALIS goes to the side of the head; while it is still bedded in the parotid, it sends off the Transversalis Faciei, which crosses the masseter muscle below the Parotid Duct, and is distributed to the contiguous parts. The temporal artery then rises over the zygoma, where a branch leaves it which penetrates the temporal fascia, and is distributed to the muscle beneath; this is the Middle temporal artery.

The temporal artery having got an inch or so above



the zygoma, divides into an anterior and a posterior branch. The first is distributed forwards on the temple, inosculating with its fellow of the other side, and with the facial and the ophthalmic artery. The second is distributed laterally on the parietal region, also anastomosing with its fellow of the opposite side and with the occipital artery.

The ARTERIA MAXILLARIS INTERNA can be got at only by removing the ramus of the jaw; it winds around the neck of the inferior maxilla, and proceeds in a very tortuous manner to the bottom of the zygomatic fossa, touching in its course, the inferior surface of the temporal bone. It passes between the internal and external pterygoid muscles immediately after leaving the carotid artery; and sends off several branches, generally in the following order:

1. To the cavity of the tympanum through the glenoid fissure.
2. The lesser meningeal, to the dura mater through the foramen ovale.
3. The greater meningeal, to the dura mater through the foramen spinale. From this trunk sometimes proceeds the lesser meningeal to the dura mater through the foramen ovale.
4. The inferior maxillary, to the teeth of the lower jaw through the posterior mental foramen.
5. Two branches to the temporal muscle, the first is the posterior deep, the second the anterior deep temporal artery.



6. Branches to the pterygoid muscles and to the masseter.

7. A branch to the buccinator and zygomaticus major.

8. The alveolar artery to the great and small molar teeth of the upper jaw.

9. The infra orbital, through the infra-orbital canal, to the canine and incisor teeth, and to the cheek.

10. The palatine artery through the posterior palatine canal to the soft palate.

11. The superior pharyngeal artery to the upper part of the pharynx.

12. The spheno-palatine, which is the terminating branch of the internal maxillary artery, and is very minutely distributed to the Schneiderian membrane by two trunks, one on the septum of the nose, and the other on its external side.

**THE INTERNAL CAROTID ARTERY, (Carotis Interna)** at its commencement, is generally dilated like an incipient aneurism; it curves much in getting to the foramen caroticum and is in contact with the par vagum and sympathetic nerves; it sends off no intermediate branches. In the canal, it gives a branch to the tympanum, and as it lies on the side of the sella turcica, it gives the anterior and posterior arteries of the cavernous sinus. Its subsequent history is merged in that of the ophthalmic and cerebral arteries.



The following arteries belonging to the neck, are derived from the subclavian, as it is about to get between the *scaleni* muscles.

1. The *ARTERIA VERTEBRALIS* which goes into the canal of the transverse processes of the *vertebræ* of the neck at the sixth, and, following its course, enters the *foramen magnum occipitis* to be distributed to the brain. It is very tortuous at the first and second *vertebræ*.

2. The *ARTERIA THYROIDEA INFERIOR*, which passes up obliquely to the thyroid gland between the great vessels of the neck and the *vertebræ*; in its distribution it anastomoses very freely with the other thyroid arteries. This artery generally sends off

The *CERVICALIS ANTERIOR*, a small artery, which is distributed along the course of the *scaleni* muscles, and which comes frequently from some other branch of the subclavian.

3. The *CERVICALIS POSTERIOR*; it is very tortuous, and runs horizontally across the root of the neck, to the *trapezius* muscle and the subjacent ones. It arises most frequently, either from the subclavian or the inferior thyroid.

The veins of the face and external parts of the Head correspond so much with the distribution of the arte-



ries, that they may be considered as having nearly the same course; to undertake the description of them, therefore, would be almost a repetition of what has been said.

Towards the angle of the jaw they are collected into a common trunk, the external jugular (*Jugularis Externa*), which crosses obliquely the sterno-cleido-mastoid muscle under the platysma myodes in the direction of the fibres of the latter, and runs into the subclavian vein just behind the clavicle, at the posterior edge of the sterno-cleido-mastoid muscle. Sometimes the external jugular, almost immediately after its formation, joins the internal jugular. On other occasions the facial vein joins the external jugular; and the temporal vein, with slight accessions from the side of the face, forms a trunk which descends almost vertically under the platysma myodes and outside of the sterno-cleido-mastoideus to join the subclavian vein in front of the scaleni muscles. The varieties are, in short, too numerous to be recounted in this work.

The INTERNAL JUGULAR VEIN (*Jugularis Interna*) may, with propriety, be considered as the great venous trunk of the brain, being a continuation of the lateral sinus. It lies on the outside of the internal and of the common carotid artery, enclosed in the same sheath, descends into the upper mediastinum in contact with the pleura, and is joined at the internal edge



of the scalenus anticus muscle by the subclavian vein. This jugular vein is occasionally much dilated, and in the contractions of the right auricle, spreads over the carotid artery. One vein is sometimes much larger than the other.

The UPPER THYROIDAL VEINS discharge into the internal or external jugulars; the Lower Thyroidal Veins into the transverse or subclavian veins; sometimes a trunk is formed across the upper edge of the sternum from one subclavian to the other, and above the great transverse vein; into this the inferior thyroidal veins discharge in whole or in part. The variety of arrangement is here also too great to admit of a standard description.



#### SECTION IV.

##### *Of the Nerves of the Head and Neck.*

A MINUTE dissection of these will scarcely be undertaken by the young student; to perform it successfully requires much time, patience, and address; when, by advanced study, the two latter are obtained, the labour will be fully compensated, by the pleasure and information it affords. For a very minute dissection a



lean subject is indispensable; for a common one, it is less important, and much of this dissection may be performed on the subject appropriated to the arteries.

The *PORTIO DURA* comes out at the stylo-mastoid foramen, is almost immediately afterwards deeply involved in the parotid gland, and divides into fasciculi in its substance. Emerging at different points it is distributed very minutely on the side of the face, sending branches to the temple which join those of the supra-orbital nerve, branches to the cheek which join those of the infra orbital nerve, branches to the chin which join those of the inferior maxillary nerve, and branches to the upper part of the neck, which join those of the superior cervical nerves.

The distribution of this nerve is too minute to admit of more than a general reference to it. Its branches join each other frequently, forming the net-work called *pes anserinus*. The dissection of it should be commenced at the stylo-mastoid foramen, or in the parotid gland, and the skin should be raised only as its branches are exposed; without this precaution the dissection will fail.

The *TRIGEMINUS*, or Fifth Pair of nerves, comes next. Its branches are brought into view by sawing off the ramus of the lower jaw and detaching it entirely, observing to leave the pterygoid muscles by cutting close to the bone through their insertions; when the



adipose and cellular membrane is then cleared away, the second and third branches of this nerve are seen deep in the bottom of the zygomatic fossa. For the distribution of the first or ophthalmic trunk, see the "Auxiliary parts of the eye."

The Second, or SUPERIOR MAXILLARY branch of the Fifth, comes out of the cranium through the foramen rotundum, and is first seen in the upper part of the pterygoid fossa. It immediately sends forwards a branch into the infra-orbital canal of the upper jaw bone, which passes through it, comes out at the infra-orbital foramen, and terminates by branches on the face. This is the infra-orbital nerve, which, just before entering the canal, sends off the Posterior Dental Nerve to supply the three last molares, and afterwards sends off the Anterior Dental Nerve to supply the canine, and incisor teeth. The Bicusgate teeth are supplied by an union of filaments from the anterior and posterior dental nerves.

Afterwards, the Superior Maxillary Nerve passes downwards in two divisions, sometimes to a level with the spheno-palatine foramen, and forms the spheno-palatine ganglion, or the ganglion of Meckel, from which proceed the Pterygoid, the Lateral Nasal, and the Palatine Nerves.

The PTERYGOID NERVE, retrograding through the foramen of the same name, gets into the cavity of the



cranium through the anterior foramen lacerum at the point of the petrous portion of the temporal bone and there divides; one branch joins the carotid artery, (see Sympathetic Nerve,) and the other passing into the vidian foramen has a singular course through the ear. (See Chorda Tympani.)

The LATERAL NASAL NERVE consists of several filaments from the spheno-palatine ganglion; getting into the nose they are distributed to the pituitary membrane of the outside of the nose, and also to the same membrane which covers the septum. One of the branches of the latter makes a long sweep, dips into the foramen incisivum, and, according to M. J. Cloquet, forms a ganglion with its fellow near the bottom of the canal. With this ganglion communicate branches of the palatine nerve.

The PALATINE NERVE passes through the posterior palatine canal to the roof of the mouth; it there divides into filaments supplying the lining membrane, the soft palate, the uvula, and the tonsils. In its way downwards, it sends several small twigs to that portion of the pituitary membrane which covers the inferior turbinated bone.

The INFERIOR MAXILLARY NERVE, or the Third Branch of the Fifth Pair, comes through the foramen ovale into the zygomatic fossa, and divides imme-



diately into two branches, one of which is distributed in minute ramifications to the muscles of mastication, as the pterygoid, masseter, and temporal; it also sends a branch the Superficial Temporal, the size of a knitting-needle, which joins the portio dura, and in order to get to it, adheres closely to the neck of the inferior maxilla. This last branch, from being blended with the portio dura, must of course, as long as it remains undivided, render nugatory the section of the portio dura for tic douloureux.

The Second Branch of the Inferior Maxillary Nerve passes between the pterygoid muscles and divides into two trunks; one of which proceeding to the tongue is the Lingual or Gustatory nerve, and the other going to the lower jaw bone, is the proper Inferior Maxillary Nerve. The first in its progress between the pterygoid muscles is joined by the chorda tympani; it then passes above the mylo-hyoid muscle near the duct of Wharton; and advancing to near the end of the tongue is divided very minutely among the papillæ. The inferior maxillary nerve enters the posterior maxillary foramen; but while doing so despatches a branch, the Mylo-hyoid, to the submaxillary gland and the muscles under the jaw; it then goes in a canal in the spongy part of the bone. Very frequently it divides into two branches, the upper of which is literally the dental nerve, and is spent by dismissing ramifications to all the teeth successively. The nerve below, however, remains to come out, at the anterior maxillary foramen, and is spent on the chin.



In order to proceed properly in the dissection of the Nerves of the Neck, the skin must be carefully raised from the sterno-cleido-mastoid muscle; by which means we shall see the spinal accessory nerve emerging from the muscle, and after having given a few branches to it, passing backwards to be distributed on the anterior edge of the trapezius muscle.

By detaching next the sterno-mastoid muscle from its origin and turning it aside, the spinal accessory nerve will be seen, coming from the posterior foramen lacerum where it adheres to the Par Vagum, Glosso-Pharyngeal and Ninth Nerve; and passing obliquely behind the internal jugular vein downwards and backwards, in order to reach the sterno-mastoid muscle.

At this stage of the dissection a multitude of nervous filaments is seen upon the neck going to its muscles, integuments and other parts, and interwoven with its blood-vessels. They form an intricate plexus derived from various combinations of the eighth and ninth pairs, the sympathetic and the proper cervical nerves, the detailed description of which is too elaborate for a dissector's manual. It is best, therefore, for the attention to be confined to leading trunks.

The GLOSSO-PHARYNGEUS is a small nerve coming from under the internal jugular vein, adhering to it, and to the other branches of the eighth pair, by condensed cellular membrane; it passes to the tongue between the stylo-glossus and stylo-pharyngeus muscle, and



on the outside of the internal carotid artery. Following the course of the stylo-glossus muscle at its internal edge, it gets to the root of the tongue, where it is distributed on its side and middle, and to the papillæ maximæ. In its course, it sends several branches to the muscles of the pharynx, and to its internal membrane.

The Ninth Pair, or the NERVUS HYPOGLOSSUS, is also very deeply seated, where it emerges from the cranium at the anterior condyloid foramen. Adhering for some distance to the par vagum, by condensed cellular membrane, it abandons the par vagum by getting between the internal carotid artery and the internal jugular vein, and crossing them obliquely about half an inch below the glosso-pharyngeus muscle. It descends much lower in the neck than the glosso-pharyngeal, forming a large curve with the convexity downwards. It is the nearest large nerve below the glosso-pharyngeal, the order of descent being first the lingual branch of the fifth pair, the glosso-pharyngeal second, and the ninth nerve third.

In its descent the Ninth nerve winds externally around the external carotid artery, just below the origin of the occipital artery. Here it is below the posterior belly of the digastricus, and the stylo-hyoideus. It then passes forwards somewhat horizontally under the external jugular vein towards the root of the tongue, where it is at the side of the hyo-glossus muscle a



little above the os hyoides, and crossed externally by the stylo-hyoideus and the tendon of the digastricus. It now ascends on the inside of the mylo-hyoideus, and divides abruptly into many ramifications distributed to all the muscles of the tongue, from the space between the genio-hyo-glossus and the lingualis muscle.

Where the Ninth nerve winds externally around the external carotid, it dismisses the Descendens Noni. The latter descends externally along the common carotid, connected with its theca as far as midway between the sternum and os hyoides; and unites with ramifications from the first, second, and third cervical nerves, to form a bow under the sterno-mastoid muscle. Above this bow the descendens noni detaches branches to the upper parts of the sterno-hyoid and thyroid muscles, and from the bow branches proceed to the lower parts of these muscles.

The PAR VAGUM, an important nerve, is immediately seen on separating the common carotid, and the internal jugular from each other. It lies in the sheath of these vessels at their back part and between them. Emerging from the cranium at the posterior foramen lacerum it is somewhat swollen, adheres to the ninth nerve and to the superior cervical ganglion of the sympathetic. It then leaves them after a short distance, assumes the position, just expressed, and maintains it down the neck till it reaches the upper margin of the thorax.



Shortly after quitting the cranium, it sends to the middle constrictor of the pharynx, the Nervus Pharyngeus.

Just below the pharyngeal nerve, the Laryngeus Superior is sent off, which descends obliquely under the Internal Carotid, and divides at the posterior edge of the thyreo-hyoid membrane into an internal and external branch. The former being the largest and above, proceeds between the os hyoides and the thyroid cartilage under the thyreo-hyoideus muscle, to the internal parts of the larynx where it is distributed by minute ramifications to the arytenoid muscles, epiglottis and lining membrane. The external branch descending, is disposed of by ramifications to the pharynx, to the lower part of the larynx, and to the thyroid gland.

In the upper part of the thorax, or the lower part of the neck, the par vagum abandons the common carotid, and passes before the subclavian artery on the right side, and before the aorta on the left. Immediately after passing these vessels it divides into an anterior and a posterior trunk; the first is the continued par vagum, the second the recurrent or the inferior laryngeal.

The Laryngeus Inferior has the same distribution on both sides, but it is to be observed that on the right, it winds around the subclavian artery, and on the left it winds around the arch of the aorta. The nerve is then deeply situated on the side of the trachea, and ascends to the larynx, sending branches to the trachea;



the œsophagus and the thyroid gland. It is minutely distributed by terminating ramifications to the small muscles of the larynx, and to its lining membrane. One of its branches at the inferior part of the larynx, communicates with filaments from the laryngeus superior.

The Laryngeus Inferior has branches connecting it with the inferior cervical ganglion of the sympathetic; the cardiac plexus; and the pulmonary plexus of nerves.

The NERVUS SYMPATHETICUS is also on the back part of the great vessels of the neck close to the vertebræ; it is commonly said to be in their sheath; this, however, is a loose, if not an inaccurate style of speech, as by passing a knife handle below the sheath and raising it up, it will be seen that the sympathetic is not one of its contents; but, on the contrary, that it is fastened somewhat tightly to the longus colli, and the contiguous muscles, by cellular membrane.

The sympathetic nerve arises by filaments of the pterygoid and of the sixth nerve, which form a network in the carotid canal around the artery; a little above or below the termination of the canal, they unite by two principal trunks to form one nerve. This chord is close to the eighth and ninth nerves and opposite to the second cervical vertebra, it swells out into the Superior Cervical ganglion; it then descends, and, opposite to the space between the fifth and the sixth cervical vertebræ, it forms the Middle Cervical Gan-



gion, which is much smaller and more irregular than the first. The sympathetic is traced with some difficulty from this, in consequence of numerous branches coming from it; a trunk, however, may be found, as the continuation of it, which passes to the interval between the head of the first rib and the transverse process of the last cervical vertebra, where another enlargement occurs, denominated Inferior Cervical, or First Thoracic Ganglion.

The first Ganglion is increased by filaments from the sub-occipital, the first, second and third cervical nerves. The second Ganglion receives filaments from the fourth, fifth and sixth cervical nerves. The Third Ganglion receives filaments from the sixth and seventh cervical, and the first dorsal nerves. From these ganglions proceed the cardiac nerves.

The NERVUS PHRENICUS is a small, straight, insulated nerve coming principally from the third cervical, but also derived, in part, by filaments from the second and fourth. It is found on the humeral side of the great vessels of the neck, removed a considerable distance from them and lying upon the anterior face of the scalenus anticus muscle. It descends into the thorax between the subclavian artery and vein, and within the anterior end of the first rib.

Each of the Cervical Nerves, including the sub-occipital, after its ganglion is formed by the posterior



fasciculus of the spinal marrow, exists as a trunk which is joined by the anterior fasciculus of the same. This common trunk gets out between the transverse processes of the cervical vertebræ, and is immediately divided into an anterior and a posterior branch. The posterior branches are distributed to the muscles and to the integuments which lie on the posterior part of the cervical vertebræ, but the anterior branches are variously disposed of. The sub-occipital and the three first cervical nerves have their anterior branches going principally to the muscles which arise from the transverse processes of the vertebræ, and to the skin of the neck. Each of these anterior branches is united by filaments to the nerve above and below it, and a sort of plexus is formed which lies over the levator scapulæ muscle. Filaments are also sent from the anterior branches of the cervical nerves which join with the spinal accessory nerve, the hypo-glossal, the portio dura, the sympathetic, and the phrenic in various ways, which are too numerous to be mentioned here.

The AXILLARY PLEXUS, from which the nerves of the upper extremity are principally derived, arises from the anterior branch of the four inferior cervical nerves and of the first dorsal. These branches are much larger than the posterior, and emerge between the anterior and the middle scalenus muscle. They send some very small filaments to the lower and middle cervical ganglions of the sympathetic.



## PART I.

### CHAPTER II.



#### SECTION I.

##### *Of the Encephalon or Brain, and Spinal Marrow.*

THE best way to get at the brain, both in public and private dissection, is to make a cut through the scalp across the top of the head from ear to ear, then to turn down the scalp over the face, and behind the back of the neck. The skull cap may be separated by a saw carried only through the external table just above the tips of the ears, and about an inch above the superciliary ridges. With the aid of an iron chisel, and a mallet, the bone is afterwards easily broken through and separated from the dura mater. Should the adhesion of the latter be great a common spatula is very well adapted to destroy it. Bichat breaks the skull-cap to pieces with a hammer and then removes it, which is a



much inferior mode to the other, and objectionable from the spiculæ of bone made by it.

The medullary mass placed within the cavity of the cranium is termed in common language Brain. It affords the following parts for separate examination. 1. The Membranes. 2. The Cerebrum. 3. The Cerebellum. 4. The Pons Varolii and the Medulla Oblongata.

1. The membranes are three: The Dura Mater, Tunica Arachnoidea, and Pia Mater.

The DURA MATER lies immediately in contact with the bones of the cavity of the cranium, being closely connected to them by blood-vessels and filaments of fibres. It is a white, shining, semitransparent membrane consisting of two layers, the internal of which forms several processes. The most conspicuous is the Falx Major, which arises from the centre of the anterior part of the sphenoid bone, from the crista galli of the æthmoid, from under the whole of the middle line of the frontal bone, the sagittal suture, and superior part of the occipital bone, as far as the junction of the limbs of its cross at the internal occipital protuberance. It is narrow before and broader behind, where it joins with the tentorium.

The next process is the Tentorium, which forms an arch slightly convex above, and crescentic in its gene-



ral figure. It is connected to the horizontal limbs of the occipital cross, to the superior ridge of the petrous bones, and to the posterior clinoid apophysis on each side. Immediately under the centre of the tentorium and running towards the occipital foramen, is the Falx Minor. On each side of the sella turcica is a process of dura mater forming its lateral boundaries. At the anterior edge of the tentorium is the Foramen Ovale through which the crura of the cerebrum pass to the Pons Varolii.

In the angle formed by the reflection of the internal lamina of the dura mater from the external, are some large cavities called Sinuses. The first is the superior Longitudinal Sinus, and is triangular; it commences by a small beginning near the crista galli having according to some a small vein from the nose joining it through the foramen cæcum. It enlarges by a continual accession of veins from the pia mater and terminates at the occipital cross. On cutting into it, we see it lined by a delicate smooth membrane;—its sides retained together by many little tendinous strings called the Chordæ Willisii;—and the veins of the pia mater running into it obliquely forwards, so as to produce the effect of valves. In this sinus, and also under the dura mater near the top of the brain are many small bodies of various sizes, the Glandulæ Pacchioni, from a line or less to three or four lines in diameter. One of the largest of these bodies



on each side, actually protrudes from the surface of the brain through the dura mater, and makes a deep pit into the parietal bone, near the sagittal suture.

From the posterior extremity of the longitudinal sinus proceeds on each side in the posterior margin of the tentorium, the Lateral sinus, terminating in the foramen lacerum posterius.

At the inferior edge of the falx major between its duplication, is the Inferior Longitudinal Sinus. And at the junction of the falx major and tentorium is the Fourth Sinus, formed by the inferior longitudinal sinus and a vessel from the interior of the brain called the Vena Galeni. The fourth sinus joins the superior longitudinal sinus at the internal occipital protuberance where the general meeting of the vessels is called Torcular Hierophili.

Around the pituitary gland, in the sella turcica, is the Circular sinus of Ridley; and at the side of the sella turcica, is the Cavernous Sinus. On the occiput and about the petrous bone there are several smaller sinuses which, together with the circular and cavernous, empty into the lateral.

The Dura Mater is supplied with nerves from the sympathetic which are traced with some difficulty. Its principal artery is from the internal maxillary, and passes through the foramen spinale, making the deep arborescent indentations in the parietal bones. There are some other branches derived from the internal



carotids and vertebals. The veins accompany the arteries, and do not discharge into the sinuses except very partially.

Within the Dura Mater and covering the whole exterior surface of the pia mater, is a delicate transparent membrane with no red vessels in its composition, the Tunica Arachnoidea. It forms an uniform coat, not dipping into the convolutions of the encephalon. It may be seen distinctly on the superior surface of the brain like a shining, smooth surface to the Pia Mater, but cannot readily be raised up from it. On the basis of the brain, it is a lamina naturally separating itself about the medulla oblongata and the contiguous parts, from the membranes between which it is placed. It lines the internal surface of the Dura Mater, having the same reflections as a synovial membrane, and secretes a lubricating fluid which facilitates the motions of the brain.

The PIA MATER is a tender and highly vascular membrane, lying in close contact with the brain, dipping into its convolutions and spread over the surface of its ventricles in a manner difficult to be understood without dissection. It is much thinner and more delicate in the cavities of the brain than exteriorly, and seems there more like a vascular net-work than a perfect membrane. It is highly useful in conducting ves-



sels into the substance of the brain by being so extensively spread over its surface, and by dividing them minutely before they penetrate it.

Its blood vessels are exceedingly numerous, being received from the vertebral and internal carotid arteries at the basis of the cranium in the manner which will be explained at the end of the chapter. Its veins, are all inserted into the sinuses of the dura mater, and therefore do not accompany the arteries.

2. The CEREBRUM fills by far the greater part of the cavity of the cranium, and extends from the tentorium and anterior basis of the cranium to the vault of the latter. It is partially divided above by the falx major, into two equal parts called Hemispheres, and below we see that each of these hemispheres is subdivided into three lobes. The Anterior Lobe is upon the orbital process of the frontal bone; the Middle Lobe is in the middle fossa of the basis of the cranium; and the Posterior Lobe upon the tentorium. Between the anterior and middle lobes there is a deep indentation, the Fossa or Fissura Magna Sylvii, formed by the posterior edge of the little wing of the sphenoid bone, which prescribes their boundaries. The middle and posterior lobes are not so well separated from each other.

The external surface of the cerebrum is arranged into many convolutions which, at a little distance, give it the appearance of intestines. The pia mater, dip-



ping down to the bottom of them keeps their opposite faces in contact.

If a section be made into the brain, it will be seen to consist of matter of different colours and consistence. The external matter, varies from a line to three or four in depth; is the Cineritious or Cortical; is of a yellowish red colour; somewhat less consistent than the other; and covers all the convolutions. Within the cortical is the Medullary or Fibrous Matter, which is of a white colour, with small spots or dots of red owing to the blood vessels.

By separating the hemispheres, we see that just below the edge of the falx major they adhere together by the pia mater of the opposite sides. Dissect this adhesion through, which brings into view a broad expansion of medullary matter, the Corpus Callosum, extending from the anterior to the posterior edge of the falx, and marked in its centre by two white lines running longitudinally and slightly curved with their convexities towards each other. Between these lines is a fossa called Raphe. Other lines not so distinct pass laterally and at right angles to the first two. By pulling the hemisphere still more from its fellow, we bring into view its edge, which laps over the corpus callosum and is separated from it by a fissure running the whole length of the latter.

The hemispheres above the corpus callosum must now be removed with a sharp knife, whereby a view is got of the Centrum Ovale of Vieussens, and also of



the connexion formed between the hemispheres by the Corpus Callosum. The centrum ovale is properly speaking the oval nucleus of medullary matter which is left when the cortical is scraped or cut away, but is most commonly described as the oval disk which is formed by the aforesaid section. The corpus callosum is placed in its middle, and forms the great medullary commissure between its two sides, and, also the roof of the lateral ventricles.

By removing the corpus callosum, the Lateral Ventricles, one on each side, are brought into view. They are very irregular cavities consisting each of a central portion or body and three processes or cornua, and extend from the anterior to the posterior portions of the hemispheres. In the anterior lobe is the Anterior cornu separated only by the Septum Lucidum from its fellow. In the middle lobe is the Inferior or Middle Cornu passing in a winding direction downwards and forwards, and in the posterior lobe is the Posterior Cornu, also called Digital Cavity.

In the anterior part of the lateral ventricle is the Corpus Striatum, a long convex body, broad before and coming to a point behind; it is cineritious or cortical externally and medullary within; when scraped the latter looks fibrous. At the posterior part of the corpus striatum is the Thalamus Nervi Optici, a large convex body, the surface of which is medullary and the interior cortical; it has a node or tubercle on its upper anterior face, and three on its posterior side; they



are of different sizes in different subjects. Between the thalamus and the corpus striatum is a streak of medullary matter called *Tænia Striata*.

In the posterior cornu of the lateral ventricle is a rising called *Hippocampus Minor*; and in the inferior cornu is a larger rising the *Hippocampus Major*, passing to its bottom and increasing in breadth as it descends. Its lower end puts on the appearance of a claw, being called, from that cause, *Pes Hippocampi*.

A considerable part of the *Thalami Nervorum Opticorum* is concealed by the *Fornix*. This is a triangular arched body of medullary matter narrow before and broad behind, and extending from the anterior to the posterior extremity of the thalami. It commences forwards by two crura very much curved, with their concavity backwards, and which arise deeply from the sides of the thalami near their union with the corpora striata. These crura come afterwards into contact, increase much in breadth, conceal the thalami, and form the fornix, which posteriorly is lost in the back of the corpus callosum and the hippocampi majores. The angle formed by the back and lateral margins is elongated and accompanies the hippocampus major for some distance, in the form of a thin crus which is easily demonstrated by raising it on the knife handle. This crus is the *Corpus Fimbriatum*, or *Tænia Hippocampi*. The under surface of the fornix is called *Lyra*.

The *Septum Lucidum* is fixed between the lateral ventricles, at their fore part; is connected above to the



corpus callosum, and below to the fornix. It consists of two laminae with a cavity between them at their front, called the fifth ventricle. To get a good view of the septum lucidum, it should be examined as the corpus callosum is raised up. In many subjects, particularly when there has been a small dropsical effusion into the ventricles, the septum looks like a continuation of the middle of the fornix, a lamina of it being contributed by the internal margin of each crus.

Under the fornix and lining the cavities of the lateral ventricles, as well as the other ventricles, is placed a delicate reflection of pia mater with many vessels in it, but so very thin that it can scarcely be raised up as a perfect membrane. This membrane gets into the lateral ventricles from the fossa of Sylvius and under the back of the corpus callosum. Along the hippocampus major and the exterior margin of the fornix, on each side, is placed a fold of it quite loose and floating, and consisting of a great congeries of small veins and arteries. This fold is the Plexus Choroides, which, becoming smaller anteriorly, dips under the anterior crus of the fornix, and its veins unite into a large trunk which runs under the fornix to terminate posteriorly in the vena Galeni. That portion of the pia mater lying under the fornix and bounded on each side by the plexus choroides, being a more complete membrane, is called the Velum Interpositum.

The fornix should now be raised with the velum in-



terpositum, by cutting through its anterior crura and turning it backwards, which gives a more perfect view of the thalami. From these bodies on the opposite sides being in contact, a kind of junction, the Commissura Mollis is formed by their convexities. Anterior to this junction, is a triangular space called Vulva. It is here that the lateral ventricles communicate, under the anterior crura of the fornix, with the third ventricle. The communication is the Foramen of Monro. Behind the commissura mollis is a similar triangular space, the Anus. The Third Ventricle is brought fully into view by separating the thalami, and we shall find that it is formed of the space between them. At its lower front part is an open way, the Iter ad Infundibulum, leading to the basis of the brain, and at its posterior part is the aqueduct of Sylvius, or the Iter e Tertio ad Quartum Ventriculum.

The Tubercula Quadrigemina, or Nates and Testes, are situated at the posterior part of the thalami, the nates being above. They are each about three or four lines in diameter; consist of medullary and cineritious matter; and constitute a means of communication between the cerebrum and cerebellum by being united to the valve of the cerebellum, also called the Valve of Vieussens, which is inserted into their lower part.

The Pineal Gland, a small conoidal cineritious body, is found on the top of the nates. It is commonly four lines in its longest diameter, and contains a small



quantity of calcareous matter, feeling and looking like fine sand, which, however, is occasionally collected into one or more irregular masses a line in diameter. This sandy matter is the *Acervulus Cerebri*. The pineal gland is situated between the nates and the back of the fornix, being closely connected with the under surface of, and surrounded by, the *velum interpositum*, so that, most frequently, when this membrane is raised along with the fornix, the pineal gland is torn from its place. If we are careful to avoid this accident, we shall find, passing along the upper edge of the thalami, on each side, above the *commissura mollis*, a medullary streak the *Peduncle* of the pineal gland, which goes from the latter to the anterior crus of the fornix.

At the anterior part of the third ventricle, just below the *crura fornicis*, and seen between their curvature where they diverge, is the *Commissura Anterior*, a medullary band like a nerve near the *corpus striatum*, and passing from the lower anterior part of one thalamus, to the other. At the back part of the third ventricle just under the pineal gland, is the *Commissura Posterior* passing also from one thalamus to the other, and being a semicylindrical fold of medullary matter.

The *Valve of the Cerebellum*, is seen by cutting off the posterior lobes of the cerebrum, removing the *tenitorium*, and dissecting away the *pia mater* just behind



and below the tubercula quadrigemina. It passes up as a broad lamina of medullary matter an inch wide, from the central part of the cerebellum to the inferior portion of the testes. By introducing a probe from the third ventricle through the aqueduct of Sylvius, it will be seen that this valve forms the roof of the fourth ventricle; and that it is thinner in its middle than on either side.

The further examination of the Encephalon should be prosecuted by detaching it from the basis of the cranium and turning it out, the nerves being left as long as possible, and the spinal marrow also. When inverted it has the following parts uppermost. The anterior and the middle lobes of the Cerebrum; The two hemispheres or lobes of the Cerebellum; The pons Varolii or Tuber Annulare; and the Medulla Oblongata.

The Cerebellum is remarkable for the difference between its size and that of the Cerebrum, as it occupies only the space between the tentorium and the posterior fossæ of the basis of the cranium. It is divided into two hemispheres or lobes by the falx minor. Though covered by the same membranes, its appearance differs from that of the cerebrum in consequence of its convolutions being straight and thin, and resembling horizontal laminae. The latter are separated by fissures penetrating, from four lines to twelve, and thereby increasing the surface for the entrance and exit of the vessels. The upper surface of the cere-



bellum is slightly convex corresponding with the concavity of the tentorium; The under surface has a double convexity corresponding with the double concavity in the inferior part of the occipital bone. The upper central part of it, just above the fourth ventricle is called *vermis superior*; and when the two hemispheres are separated below, a prominence like a third lobe is seen between them, and is the *vermis inferior*. This central part of the cerebellum is the fundamental portion of Gall.

When the cerebellum is cut into, the medullary matter is found principally in its centre, and sends off processes in every direction into the cortical. From this circumstance the medullary matter has an arborescent outline upon all vertical sections made into the cerebellum and has obtained the name of *Arbor Vitæ*, which is merely expressive of this arrangement without designating any particular part of it. If horizontal cuts be made the *arbor vitæ* resemblance is not manifested, and the proportion of medullary matter appears more considerable. The two *Crura* of the cerebellum one on a side pass from the medullary portion, being in fact a mere continuation of the latter. They are separated from each other by the fourth ventricle and are inserted into the posterior upper part of the *Pons Varolii*. In their centre is a denticulated oval ring of cineritious matter called *Corpus Dentatum* or *Rhomboideum*.



The crura Cerebri arise from the medulla of all the lobes, make their first appearance at the back of the anterior, and between the middle lobes; their internal margins touch; they pass backward to be connected with the anterior superior part of the pons varolii and are lost in its substance. They are formed of a mixture of medullary and cineritious matter.

The Pons Varolii, thus constituted by the blending of the substance of the four crura, two from the cerebrum and two from the cerebellum, is fixed upon the posterior part of the body of the sphenoid bone and on the cuneiform process of the os occipitis.

It is between the anterior part of the cerebellum and the posterior part of the middle lobes of the cerebrum. It is hemispherical on its inferior surface, and about sixteen lines in diameter; is divided into two halves by a superficial middle longitudinal depression with transverse ridges passing from it on each side. In its substance is much cortical matter blended with medullary, the latter is arranged into striæ running in different directions.

The MEDULLA OBLONGATA is that portion of encephalic substance between the Pons and the superior margin of the first cervical vertebra. Arising from the back of the former, it swells considerably almost immediately, and then tapers down gradually to form the commencement of the spinal marrow. There is a



circular indentation above defining its boundaries at the Pons, but below there is none. A longitudinal fissure on its fore part, divides it equally. On each side of this fissure above, is an oblong eminence called Corpus Pyramidale, coming to a point below, and disappearing gradually. On the outer side of that again, and separated from it by a fissure on the side of the medulla oblongata, is an ovoidal and still more prominent convexity, but not so long, called Eminentia Olivaris. And on the outside of this is another and smaller eminence, the Corpus Pyramidale Laterale, or Corpus Restiforme. The Medulla Oblongata consists of medullary matter externally, and has some cineritious internally. By lifting it up from the cerebellum and dissecting away the tunica arachnoidea and pia mater, a good view may be got of the Fourth Ventricle of the brain, which is closed below and separated from the spinal canal by these membranes. It will now be easy to understand that the parietes of the fourth ventricle are formed by the valve of Vieussens and by the cerebellum, above and posteriorly; by the pons Varolii anteriorly; by the medulla Oblongata below; and by the Crura Cerebelli laterally. The posterior face of the medulla is marked by an arrangement of its surface corresponding in some measure with the slit and nib of a writing pen, from which it has the name of Calamus Scriptorius.

Between the Crura Cerebri at their anterior part are two small round bodies, three lines thick, in contact



with each other; they are the Corpora Albicantia or Eminentiae Mamillares. They are placed in a cineritious substance, the Pons Tarini, or Tuber Cinereum, forming with them the floor of the third ventricle.

The INFUNDIBULUM is a flat funnel-shaped tube alluded to in the account of the third ventricle, but best seen in this period of the dissection. It is placed just before the corpora albicantia, and passes from the third ventricle to the pituitary gland, having its apex in contact with the latter, and its broad part opening into the ventricle. It is generally impervious at its apex. It is cineritious externally, which gives it a red cast, and medullary internally.

The GLANDULA PITUITARIA occupies the sella turcica, and is somewhat spherical, being about six or seven lines in diameter. Its structure is firm and resisting, formed of a tough cineritious matter externally, and of a kind of medullary internally. It is almost concealed by a close reflection of dura mater over it.

There are nine pairs of nerves going from the basis of the brain, and named numerically by beginning in front.

The 1st Pair, the OLFACTORY (NERVI OLFACTORII,) appropriated to the nose, arise by three striæ from the corpora striata, and make their appearance on the



back and inferior part of the anterior lobes. Their structure is soft and pulpy, and they are protected from the weight of the brain by being deposited in a triangular groove formed by a convolution. They swell out into bulbs at their fore part on the sides of the crista galli, and perforate the cribriform plate of the æthmoid bone by numerous filaments. They get a coat from the dura mater which gives them great strength, and are then distributed as mentioned in the account of the nose.

The 2nd Pair, the OPTIC NERVES (NERVI OPTICI,) are of considerable magnitude, and differ somewhat in their texture from the other nerves in consequence of having a general investment of pia mater before it surrounds their particular fasciculi; and also from having more medullary matter in them. They arise from the posterior end of the thalami and from the testes, and make their appearance between the middle lobes and the crura cerebri. There is a very close intertexture of the nerves of the opposite sides just before the infundibulum, so that it is a question whether they decussate each other, or simply unite. Being the nerves of vision, they pass to the ball of the eye, through the foramina optica and are expanded into the retina.

The 3rd Pair, (MOTORES OCULORUM,) arise from the inner margins of the crura cerebri near the pons varolii by several filaments. They pass outwards and



penetrate the dura mater near the posterior clinoid process and traversing the upper part of the cavernous sinus they get into the orbits through the foramen sphenoidale. They are distributed to the muscles of the eye, except the obliquus superior and rectus externus, and contribute to the ophthalmic ganglion.

The 4th Pair, (TROCHLEARES.) Each arises by two filaments which quickly unite, from the valve of Vieussens just below the testes. It is not larger than a common sewing thread, and makes its appearance at the anterior lateral margin of the pons varolii. It penetrates the edge of the tentorium not far from the entrance of the third nerve, and running in an investment of dura mater through the cavernous sinus at the outer side of this nerve, it afterwards crosses it above, and getting into the orbit through the foramen sphenoidale, is appropriated to the trochlearis muscle.

The 5th Pair, (TRIGEMINI,) are the largest of all. Each arises by three portions, the middle being largest, from the side of the tuber annulare just where it is blended with the crus cerebelli. Their fibres may be traced through the pons into the posterior column of the medulla oblongata and are collected into one cord, which passes into a canal of the dura mater, lying on the anterior part of the petrous bone. They are not connected to the canal except at its lowest part, where



they receive a coat from it. The nerve is then expanded like a fan, into seventy or eighty filaments. At the lower end of the latter is a brownish substance, the ganglion of Gasser, formed principally upon the middle root of the Trigemini. The nerve then passes off in three great divisions, named from their appropriations; the Ophthalmic nerve which goes out of the cranium at the foramen sphenoidale of the orbit; the superior Maxillary, at the foramen rotundum; and the Inferior Maxillary, at the foramen ovale.

The 6th Pair, (MOTORES EXTERNI.) Each nerve arises from the commencement of the medulla oblongata in the base of the corpus pyramidale, its root being frequently overlapped by the pons. It passes forward through the dura mater, in a canal, of the cavernous sinus, on the inside of the fifth nerve, and lying between this nerve and the carotid artery, it detaches one or more filaments to form the commencement of the sympathetic nerve, and which accompanies the carotid artery through the carotid canal to the neck. The trunk of the motor externus then gets into the orbit through the foramen sphenoidale and is appropriated to the rectus externus muscle of the eye.

The 7th Pair, is composed of two nerves the PORTIO MOLLIS and the PORTIO DURA. The first arises from the posterior face of the medulla oblongata, at the calamus scriptorius and corpus restiforme, being sepa-



rated from its fellow of the opposite side by the slit of the calamus scriptorius. The second, or portio dura, arises from the superior part of the corpus restiforme behind near the pons. A third nerve which, at a little distance, joins the portio dura, and is a mere fibril of it called portio Media, arises near the latter. The seventh nerve, thus constituted of a hard and of a pulpy portion, dips into the meatus auditorius internus. The mollis goes to the ear and is spent upon the labyrinth; the dura, passing along the aqueduct of Fallopius, gets out at the stylo-mastoid hole and goes to the face.

The 8th Pair, consists of three portions having different destinations: The Glosso-Pharyngeal; The Par Vagum or Pneumo-gastric; and the Spinal Accessory nerve of Willis. The two first arise near each other behind the Corpora Olivaria from the side of the Medulla Oblongata. The Glosso-Pharyngeal is before the other, and consists of one cord. The Par Vagum is composed of several fasciculi having a flattened appearance, which afterwards unite together. The Spinal Accessory has a remarkable origin from the posterior fasciculus of the Medulla spinalis, occasionally as low down as the seventh cervical nerve. Its fibres successively form a round trunk, which passing up the spinal canal and then into the cavity of the cranium through the foramen magnum, is associated with the nerves just mentioned; it is assisted also by contribu-



tions from the side of the Medulla Oblongata. The eighth pair passes out of the cranium at the posterior foramen lacerum, anterior to the internal jugular vein, and separated from it by a spine of bone as well as by a process of dura mater. The distinction of the nerves from each other is also kept up here, by processes of dura mater between them. They adhere on the outside of the cranium and then part for their different destinations; the Glosso-pharyngeal for the tongue and pharynx, the Par Vagum for the lungs and stomach, and the Spinal Accessory for the muscles and integuments of the neck.

The 9th Pair, (HYPOGLOSSI.) Each nerve arises from the side of the medulla oblongata in the groove between the corpus pyramidale and olivare, by three or four fasciculi. These fasciculi unite into a trunk, which gets from the cranium through the anterior condyloid foramen, and is distributed to the tongue.

### *Of the Medulla Spinalis.*

THIS is in continuation with the medulla oblongata, and is contained in the vertebral canal. It passes down as far as the first or second vertebra of the loins; and there terminates in a conical point.

It has the same number of membranes with the



Brain; to wit, the Dura Mater, Tunica Arachnoidea and Pia Mater.

The Dura Mater resembles very much the same membrane of the brain except that it has more elasticity. It does not adhere closely to the bone, but lies loosely enveloping the spinal marrow and nerves, until it touches the foramina through which the latter pass out. Between the spinal canal and the dura mater is interposed a soft, watery and vascular fat, which forms a sort of bed for the dura mater and fills up many of the inequalities of the canal. At the egress of the dura mater from the cranium just around the foramen magnum, it adheres very closely to it and also to the first cervical vertebra.

The Pia Mater is in close union with the Medulla Spinalis, and is commonly found with its veins injected after the same way, with the pia mater of the brain; it is, however, not so vascular, it ends by a conical cord below which goes to the lower end of the sacrum with the dura mater.

The Tunica Arachnoidea lies loosely between the dura and the pia mater, preserving a character of extreme tenuity and transparency; it may be elevated any where with a pair of forceps; continues downwards to the end of the spinal cavity, and connects the fasciculi of nerves together.

On each side of the spinal marrow running between the anterior and posterior fasciculi of nerves, is a nar-



row semitransparent band, called *Ligamentum Denticulatum*, fixed beneath the *tunica arachnoidea*, and connected to the *pia mater* by its internal margin. It is first observed arising at the occipital foramen; it then descends, and as it passes between the anterior and posterior fasciculi of nerves, it detaches many little round tooth-like processes, fixed to the inner surface of the *dura mater*, and carrying the *tunica arachnoidea* along with them. From these processes it derives its name.

The *Medulla Spinalis* from being a continuation of the *medulla oblongata*, like it consists of two kinds of matter, cineritious and medullary. The latter is placed externally. The *medulla spinalis* has anteriorly and posteriorly a fissure penetrating almost to its centre and extended its whole length, which divides it into two equal parts. These halves are again divided each into an anterior and posterior column, by a lateral fissure which is not so deep or long as the other, but terminates in the thoracic portion of the canal, and is nearer the posterior than the anterior fissure. The posterior column is again divided into two. These several divisions of the spinal marrow being connected by the internal cineritious matter, when a horizontal cut is made, the latter puts on the appearance of a line with a crescent at each end. At the upper end of the *medulla spinalis* near the *oblongata*, a considerable part of the anterior portions or columns crosses from the side to which they belong to the opposite one, and in doing so they are interwoven.



In the bottom of the anterior fissure there is a commissure of transverse fibres, said to be like the teeth of a saw; and at the bottom of the posterior fissure there is a commissure of longitudinal fibres.

From the anterior and posterior portions of the spinal marrow flat fasciculi of nerves proceed by double roots which penetrate the dura mater separately and derive a coat from it. This coat exists for some distance as a sheath, united to the nerve by loose cellular substance, but is closely fixed to it near the intervertebral foramen. The posterior fasciculus, at this place, forms a ganglion, which sends out a nerve at its fore part; this nerve, just at its origin, is united to the anterior fasciculus, and thus forms the commencement of the spinal nerve. As soon as the spinal nerve clears the foramen between the bones, it sends branches backwards to the muscles of the spine, others forwards to join the sympathetic, and the middle trunk goes according to the part of the body to be supplied.

There are thirty pairs of spinal nerves; seven to the neck, twelve to the back, five to the loins, five to the sacrum, and one which passes between the occiput and first vertebra called Sub-occipital. The nerves of the neck, from their origin to the intervertebral holes, are short and nearly horizontal; those of the back pass obliquely downwards, increasing in obliquity as they descend. The lumbar and sacral nerves are extremely oblique, the lowest being almost vertical; they arise very much in a cluster close to each other, and form, while still within the dura mater, the Cauda Equina.



*Of the Blood Vessels of the Brain and Spinal Marrow.*

THE brain is supplied by the Internal Carotids and the Vertebral Arteries. The former, passing in a very tortuous manner through the canal in the temporal bones, appear in the cavernous sinus at the sides of the anterior clinoid processes. They there send off, each anteriorly, the ophthalmic artery through the optic foramen, and, in a short space afterwards, the Arteria Communicans Posterior, a branch which goes backwards, to join the posterior artery of the cerebrum; the main trunk is continued into the fossa of Sylvius, and forms the Arteria Media Cerebri, and from this is sent off the Arteria Anterior which supplies the anterior lobe of the brain and the corpus callosum. The arteria anterior communicates by a short transverse branch, the Communicans Anterior, with its fellow.

The Vertebral Arteries come up through the foramen magnum and unite with each other at the posterior part of the pons varolii, to form the basilar artery.

The BASILAR artery divides anteriorly into two branches which run to the posterior lobes of the brain; they constitute the Arteriæ Posteriores Cerebri. From the basilar near the vertebrae, arises, on each side, a



trunk, the Arteria Inferior Cerebelli; and from its anterior part the Arteria Superior Cerebelli. The circle of Willis is formed by the anterior bifurcation of the basilar, with the internal carotids and the Arteriæ Communicantes.

The veins of the brain have been mentioned as all emptying into the sinuses of the dura mater.

The Arteries of the spinal marrow are derived from the vertebrales, intercostals, lumbar and sacral arteries. The veins accompany the arteries and form sinuses on the outside of the dura mater, one on each side, which empties into the occipital and lateral sinus, anastomosing, however very freely with a plexus of veins which surrounds the spinal column.



## SECTION II.

*Of the Anatomy of the Brain and Spinal Marrow, according to the system of MM. Gall and Spurzheim.*

THE brain and spinal marrow, as stated, consist of two kinds of substance, cineritious and fibrous or medullary. The cineritious is found abundantly on the surface of the brain, within its substance at particular places, and diffused through the spinal marrow; its consist-



ence is pulpy and gelatinous, varying in degree in different subjects. It is of a yellowish-red colour for the most part; and is extremely vascular, in consequence of which, some anatomists have considered it to consist entirely of blood-vessels; but Albinus and Sæmmering have both proved by injections, that there is some other substance which is probably secreted by them. This substance, according to Gall and Spurzheim, is the matrix or soil of the fibrous substance constituting the other part of the brain.

A very general error has prevailed in regard to what is called the medullary portion of the brain; some consider it to be solid, others that it consists of hollow tubes, some that it has no vessels, others that it consists entirely of them. The fact is that it is fibrous, which may be demonstrated by scraping it from the centre to the circumference in the direction of its fibres, by boiling its convolutions in oil, or macerating them in nitric or muriatic acid diluted with alcohol. For these reasons Messrs. GALL and SPURZHEIM reject the term Medullary as communicating a false idea, and call it the Nervous Mass.

The SPINAL MARROW, according to these gentlemen, in worms and caterpillars, consists of a series of ganglions united to each other by nervous branches, giving it the form of a chord with small tubercles of various shapes and sizes. For every superficial ring or seg-



ment of these animals, there is one of these knots or ganglia for the origin of nerves, and the size and number of the nerves emanating from one of these ganglia, will always be in proportion to the size of the ganglion itself. In fishes, amphibia, and birds the same arrangement prevails, only in not so distinct a shape, the ganglia being nearer to each other, and with the uniting bands forming a chord of more equal size, swollen however where large nerves go off. The same knotted condition is observed in the mammalia and in man, but not so evidently in the latter; one may, however, be convinced of it by removing the spinal marrow, detaching the tunica arachnoidea, and observing the profile between the eye and the light. The outline is every where more or less waving, corresponding with the origins of the nerves, the largest swellings being where the nerves of the extremities go off, which are the largest nerves of the medulla spinalis. The spinal marrow, for these reasons, is enlarged from the third vertebra of the neck to the first dorsal; it is then gradually diminished to the tenth dorsal; it afterwards enlarges to the first lumbar vertebra, and forms an elongated point where it terminates.

The ENCEPHALON is considered by all anatomists to consist of Cerebrum or Brain, and of Cerebellum or little Brain, each of which is formed of two symmetrical halves called Hemispheres. Besides which there



exist the Pons Varolii and the Medulla Oblongata, till lately considered as emanations from the Cerebrum and the Cerebellum.

On each side of the Medulla Oblongata there are three protuberances; the most anterior is the Corpus Pyramidale, just behind it is the Eminentia Olivaris, and behind it again is the Corpus Restiforme; these projections being named from their exterior configuration. The medulla oblongata consists of cortical and fibrous or medullary matter. The latter is composed of fasciculi which may be traced into the brain above, and into the spinal marrow below. MESSRS. GALL and SPURZHEIM consider the cerebral mass to arise from those fasciculi instead of the latter coming from the cerebral mass, as is most commonly taught and believed. The corpora pyramidalia, like the other eminences, are fibrous, and their fibres arise in a peculiar manner. This peculiarity consists in the fibres of the right corpus pyramidale arising from the left side of the medulla spinalis and the fibres of the left corpus pyramidale arising from the right side of the medulla spinalis. These fibres decussate each other an inch and a quarter below the pons Varolii, sometimes in single bands, but commonly by an intertexture of three, four, or five fasciculi from each side. This arrangement is readily seen by stripping off the pia mater and tunica arachnoidea, and then separating the two sides of the fissure in front of the medulla oblongata.



This peculiarity in the origin of the pyramids is supposed to explain the fact of blows on one side of the head paralysing the opposite side of the body, as the same fibres are continued from the origin of the pyramids to the part of the brain which is injured in these cases. In regard to the other portions of the medulla oblongata, the fibres of which they consist have no such crossing; are continued into the cerebral mass above and communicate with the medulla spinalis below. The principal facts worthy of notice being that a portion of the anterior columns retreat to form the bottom of the fourth ventricle, and that of the posterior column one part terminates in the borders of the same ventricle while the remainder is continued as corpus restiforme into the fundamental portion of the cerebellum.

### *The Cerebellum.*

THE Cerebellum consists of two lobes or hemispheres separated below in part by a groove which makes them very distinguishable from each other. By opening this groove behind we get a view of the other or third part of the cerebellum, called Vermis Inferior, or, by Gall and Spurzheim, the Fundamental Portion. They are induced to give it this name as it expresses in a measure a fact of some importance, viz. that it always exists in animals that have a cerebellum,



whereas, the lateral parts or lobes do not. Fishes and reptiles are in the latter predicament, but all warm-blooded animals, with man at their head, have the lobes.

In man the cerebellum is more complicated and perfect; nevertheless, a constant uniformity is observed in all animals in regard to the origin from the medulla oblongata. In the interior of the medulla oblongata on each side, within the corpus restiforme, an accumulation of cineritious substance is observed from which springs an elementary chord of fibrous matter. This chord increases as it ascends towards the cerebellum, and near the latter it is covered by the auditory nerve and its ganglion. These should be carefully scraped away; we then see the fasciculus of fibres entering into the interior of the hemisphere of the cerebellum. Proceeding two or three lines, the fibrous chord meets with a collection of cineritious matter of an oval shape with serrated edges, called Corpus Dentatum. The fibres become so blended with this body, that it is impossible to pursue them in any determinate course. The corpus dentatum is considered as a ganglion or accumulation of cineritious substance, for the purpose of giving origin to more fibres in the cerebellum. Accordingly several new fasciculi of medullary or fibrous matter arise in it, and ramify in different directions towards the periphery of the cerebellum. Wherever a large ramification of fibres departs from it, the quantity of cineritious substance about its root is increased,



hence results the fringed or serrated margin. That the corpus dentatum, is a matrix for the fibrous structure of the cerebellum, seems proved by the fact, that the greater number of viviparous animals have the cerebellum proportionably smaller than man, and in them the corpus is so little developed that they are said by some to be destitute of it.

The CORPUS DENTATUM detaches inwardly a large branch which contributes to form the vermis or the Fundamental Portion of the Cerebellum. In the vermis, the fibrous or medullary matter radiates by seven branches towards its circumference, their extremities and subdivisions being covered by cineritious matter.

The corpus dentatum also sends off other branches which go upwards, downwards, and outwards, towards the periphery of the hemisphere; expand into horizontal layers, and have their peripheral extremities covered with the cineritious substance. Such as are nearest to the middle of the cerebellum are longest, and the others gradually decrease in length as they are nearer the place where the original chord entered the corpus dentatum. If the cerebellum be cut vertically through the middle of the corpus dentatum; eleven principal branches are found proceeding from it; but this number diminishes if the cut be made near the circumference of the cerebellum. It is this arborescent arrangement which, resembling the *Thuya*, or tree of Life, gives occasion to the name *Arbor Vitæ*.



“ Horizontal or transverse cuts of these branches or leaves present only a white substance; therefore anatomists are wrong in maintaining that the quantity of the cineritious mass is more considerable in the cerebellum than in the brain.”

*Commissures of the Cerebellum.*

A description of fibrous matter exists in the cerebellum which cannot be traced, either to the primitive fasciculi from the corpora restiformia, or to the new fibres derived from the corpus dentatum. These fibres come from the cineritious matter on the surface of the cerebellum, pass in various directions through the diverging fibres; but always so as to converge towards the anterior external margin of the cerebellum, where they form a large and thick layer of fibrous matter. The anterior fibres cross in front of the tuber annulare, but the middle and posterior pass transversely through it, getting between the longitudinal bands of the tuber annulare which are distributed to the hemispheres of the cerebellum. These transverse fibres, from the opposite sides of the cerebellum, unite with their congeners, in the middle vertical line of the pons varolii. The pons varolii is therefore, the place of union for the fibrous structure of the two hemispheres of the cerebellum, and as such is called, by MM. GALL



and SPURZHEIM, the Great Commissure of the Cerebellum.

Considerable light is thrown upon this subject by comparative anatomy, for this great commissure has its dimensions always in strict proportion to the developement of the lateral parts or hemispheres of the cerebellum. In the mammalia generally, as the lateral parts of the hemispheres are small, the tuber annulare is small. In fishes, and reptiles, it does not exist at all, because they have no hemispheres to the cerebellum. On the contrary, in man, the hemispheres of whose cerebellum are so large, the tuber annulare is remarkably broad and prominent: so much so as to conceal the origins of several nerves which are exposed in other animals, and, therefore, to assume fallaciously the appearance of giving origin to them.

Although such animals as are destitute of hemispheres are without the great commissure of the cerebellum, yet as they all have the fundamental portion, so they have a Lesser Commissure belonging to it. This commissure is formed of the fibres which come from the upper and lower parts of the fundamental portion, and join each other in constituting the *Valvula Cerebelli*, or the Valve of Vieussens, which runs upwards and forwards to join the Inferior Tubercula Quadrigemina or the Testes. This primitive commis-



sure of the cerebellum forms, in common description, the roof of the fourth ventricle.

### *The Cerebrum.*

THE Cerebrum is derived from the corpora pyramidalia under the following circumstances. As the pyramids are about entering the pons varolii, they contract so as to give the appearance of a neck. The pons varolii has a considerable quantity of cineritious substance in it; the fibres of the corpora pyramidalia, in passing through, are divided into several fasciculi which derive an increment from the cineritious matter, some of the fibres being disposed in layers and others interwoven with transverse chords coming from the cerebellum. Besides the filaments from the corpora pyramidalia, others arise from the posterior part of the medulla oblongata and from the corpora olivaria to penetrate into the pons varolii. The several fasciculi, thus formed from the different points of the medulla oblongata by passing through the cineritious substance of the pons varolii, are so reinforced and multiplied that on issuing from the latter they form the pedunculi or crura of the cerebrum. And as in man, the inferior or pyramidal fasciculi receive the greatest accession of new fibres; they, therefore form two thirds of these crura.

In order to see the course just described of the



fibres of the medulla oblongata, remove its membranes and those of the pons, and make an incision one line deep through the front of the pons from the crus of the cerebrum to the base of the corpus pyramidale of the same side. With the handle of a scalpel introduced to the bottom of the incision, scrape or push the surface of the pons towards the crus of the cerebellum on the one hand, and towards the middle line of the pons on the other. We thus obtain a distinct sight of the transverse medullary fasciculi constituting the anterior superficial layer of the pons also called the great commissure of the cerebellum, and when all these are removed we see plainly the longitudinal fibres coming from the pyramidal bodies; by scraping still deeper, more of the fibrous structure of the tuber annulare is brought into view.

The anterior and external fibres of the crura of the cerebrum are derived from the continuation and the successive increase of the primitive pyramidal bundles or the corpora pyramidalia. The incessant reinforcement of these fibres is produced by their meeting continually in the Pons and the Crura Cerebri with cineritious substance. At the upper extremity of the crus where the optic nerve crosses it, the corpus striatum, a large mass of cineritious substance exists, and with which blend the fibres of the crus, whence an immense number of new fibres is generated and added to the course of the others. These fibres, shortly after their origin, begin to diverge, and being expanded in several



directions terminate in the convolutions of the anterior and middle lobes of the brain; not in all of the convolutions belonging to these lobes, but in the inferior, anterior and exterior. In this way the original fibres of the corpora pyramidalia may be traced through the medulla oblongata, Pons Varolii, crura cerebri, and corpora striata, to their terminations.

The fibrous fasciculi on the posterior and external part of the medulla oblongata formed by the corpora olivaria, and a few others just behind, ascend in the same manner as those of the corpora pyramidalia through the tranverse fasciculi of the pons varolii which come from the cerebellum. By meeting also with cineritious substance they are multiplied, but less considerably than the fasciculi from the corpora pyramidalia. They form the interior and posterior part of the crura cerebri and pass through the thalami nervorum optico-rum. The thalamus consisting principally of cineritious substance, through which the fasciculus of the corpus olivare has to pass, the fasciculus has an accession of many new fibres. MM. GALL and SPURZHEIM reject the opinion of the optic nerve arising from the thalamus, and rather consider the thalamus as one of the ganglions of the brain, from its being appropriated to the production of a great number of fine fibres, which ascend in a diverging direction, and which at their exit from the superior margin of this ganglion form large fasciculi. The anterior fasciculi of the thalamus penetrate the corpus striatum where it forms



a part of the lateral ventricle, and receive from it a considerable accession of new fibres. All the several fasciculi of the thalamus, by radiating very widely, are finally distributed in the convolutions of the posterior lobe of the brain, and in the superior convolutions of the anterior and the middle lobe.

From the pyramidal fasciculi passing through the corpora striata and being there multiplied, and from the olivary fasciculi passing through the thalami and being there also multiplied, the corpora striata, and the thalami are said to be ganglions, or an apparatus of increase where many new fibres arise and join others. By such arrangement new cerebral fasciculi are added to the old in the same way that many branches might be engrafted upon the stock of a tree.

#### *Commissures of the Cerebrum.*

“THE Hemispheres of the Brain offer the same phenomena as the cerebellum in regard to the two orders of nervous fibres. The fibrillæ which come from the crura cerebri in expanding in order to form the duplicatures or convolutions at the periphery of the hemispheres, stop, as has been observed, with points in the cineritious substance. But it is certain that besides these fibres there may be demonstrated in all the circumference of the hemispheres beyond



the tissue on which rests the base of the convolutions, a particular nervous substance, which appears to be at first spread in layers, and which is afterwards united into filaments, and lastly into distinct fasciculi. These fasciculi converge or incline towards the interior of the brain in order to form with their congeners of the opposite side, a commissure between the two hemispheres. In some convolutions of the lower part of the posterior lobe, this converging mass may be followed in an uninterrupted bed till it forms distinct filaments. For this reason it is that we presume, that this white and soft substance to be met with in all the convolutions, is continued every where in the same manner to the commissures, although it be not susceptible of distinct demonstration."

"As these fibres converge, and as they have in every part a different course, and indeed in some places one altogether different from the diverging fibres, or such as come from the base of the brain, particularly in the anterior and posterior parts of it: As, besides this, they are separated from them, and much softer and more white, we believed ourselves authorized to consider them as a particular nervous system."

The CORPUS CALLOSUM, or Great Commissure, is, therefore, derived from the converging or returning fibres of the hemispheres of the cerebrum; the fibres from the opposite sides uniting at the raphe. The anterior and posterior lobes are so disposed, that their



returning fibres do not cross transversely, but in a radiated manner; hence the great commissure is shorter than the hemispheres, as it occupies only their middle part. Also as these fibres are collected very much in consequence of their converging, the anterior and posterior edges of the corpus callosum are thicker than its middle, and present the appearance of a fold not unlike that of the pectoralis major at the arm-pit.

The COMMISSURA ANTERIOR is derived from the converging fibres of the front convolutions of the middle lobes. These fibres pass through the corpora striata without adhering to them, and present on both sides of the brain the form of a bow with its convexity forward.

The COMMISSURA POSTERIOR is derived from the posterior convolutions of the middle lobes of the brain, and from some of those of the posterior lobes. It also consists of converging nervous fibres, which are lost in the posterior duplicature of the Commissura Magna. It forms, at its junction with its fellow, a flat band and not a round chord, and is much smaller than the anterior commissure. The Middle Commissure of the cerebrum is a mass of very soft and delicate transverse fibres, going from one thalamus to the other, in the space between the anterior and posterior commissures. These transverse fibres are almost always torn, upon separating the hemispheres.



Several other parts of the cerebrum are considered as commissures by G. and S., or consisting of converging fibres, as the *Tænia Striata*, the *Posterior Crura* of the *Fornix*, and the *Lyra* or under surface of the *Fornix*. They do not consider the obliquity of the course of the fibres of these bodies, an objection to their being commissures, inasmuch as the returning filaments of the middle parts of each hemisphere, are the only ones which have a transverse direction.

The *SEPTUM LUCIDUM* is also a commissure arising by a fasciculus of fibres sometimes strongly marked, from the most internal convolution, at the anterior extremity of the middle lobe, on each side. It ascends, in front of the anterior commissure, above the junction of the optic nerves, and is spread into a delicate membrane forming with its fellow the septum of the lateral ventricles. Between the two laminæ composing it, is a cavity called the fifth ventricle of the Brain. These laminæ are extended through the middle of the great commissure, and assist in forming the raphe by means of perpendicular fibres, the direction of which is diverging towards the convex or superior part of the great commissure.

It is probable that all the nerves of animal life have those commissures and at any rate they are visible in many other places. For example, they exist in the transverse fibres at the bottom of the anterior fissure of the spinal marrow and of the medulla oblongata, in



the latter of which we must take care not to confound them with the decussation of the pyramids. And besides this, the longitudinal band at the bottom of the posterior fissure, extending the whole length of the spinal marrow, keeps its several nerves concatenated. The transverse band behind the commissure of the cerebellum in mammiferous animals, the junction of the tubercula quadrigemina and the transverse band at the origin of the fourth pair of nerves are similar unions or commissures.

It is not possible to say with propriety that these commissures are positive unions of the converging fibres, from the corresponding parts on each side; for a perpendicular cut through the middle line of the corpus callosum, of the tuber annulare, and the middle of the spinal marrow, demonstrates perpendicular striæ accompanied with blood vessels. Possibly the vertical laminæ on each side of the middle line may form a seam by juxtaposition; but it is more probable that the converging fibres are continued across these.

Besides the commissures, there are Transverse Bands (*Complicationes Transversæ*), which should be attended to. Messrs. G. and S. consider them as corresponding with the transverse bands at the joints of straw. They say that at every point of considerable increase there is one of them, as at the lower end of the Corpus Olivare, in the middle of the Crus Cerebri, at the external margin of the optic nerve in the Crus Cerebri, between the thalamus and Corpus Stri-



atum, at the external margin of the Corpus Striatum.

The EMINENTIÆ MAMMILLARES are separated in the human subject, but adhere so as to form only one body in other mammalia. Each eminentia contains three chords, two internal and one external. The external unites with the transverse band under the optic nerve in the crus cerebri. The foremost of the two internal chords unites with the anterior crus of the fornix of the same side, and the other sinking into the interior of the thalamus, unites with another transverse band. They are true ganglions.

The PINEAL GLAND is erroneously named, as it has nothing of a glandular structure, but is composed of cineritious and medullary substance. Four nervous threads are produced in it which go to contiguous parts, two on each side; one goes along the superior internal margin of the thalamus, and ends in one of the transverse fasciculi found in the divergent fibres. The second goes backwards and downwards, and adheres to the commissure of the Tubercula Quadrigemina.

“The PITUITARY GLAND is a collection of cineritious substance placed behind the junction of the optic nerves. It is obviously traversed by white filaments which arise in it, and is prolonged into the Infundibulum.”



The TUBERCULA QUADRIGEMINA. The anterior ones or the nates, are evidently ganglions for the origins of the optic nerves, (see the account of these nerves.) They are flattened and somewhat cineritious externally and are united to each other by a strong and broad fasciculus, considered as a commissure of the optic nerves. The testes are of a more conical and elevated form, the medullary matter in them is more external, and they have also a transverse band which unites them. The use of the testes is unknown, but they are supposed to give origin to the optic nerves.

*Of the Ventricles and Convolutions of the Brain.*

It has been stated that the brain has two orders of medullary fibres, the one called diverging, because they have their rudiments in the medulla oblongata, and are so spread as to have their extremities terminating near the periphery of the brain, in the cineritious substance forming it. The other order of fibres is called converging, because they pass from the circumference of the brain to the interior parts or middle line, and constitute the Commissures. These converging fibres cross the diverging at various angles, sometimes obliquely, sometimes in a rectangular direction. It is uncertain whence they proceed, whether they are derived from the imperceptible and curved extremities of the diverging fibres in the same way



that the veins are continuations of the arteries, or whether they are a new creation in the cortical circumference of the brain where they have their primitive radicles, in a manner corresponding with the origins of other nerves in the different ganglions. As the diverging fibres or mass is extended in every direction towards the circumference of the brain, and as the converging fibres come from all parts of the same circumference, and form large layers in the upper portion of the brain, as for instance the corpus callosum, it results that between the two orders of fibres there are vacuities; and these are called the ventricles of the brain.

The Convolution of the Brain have generally been considered by anatomists, as intended merely to increase its surface, in order that the blood-vessels of the pia mater might have more convenient access to it. This opinion is renounced by Messieurs GALL and SPURZHEIM on account of its being too mechanical, and they think, that the convolutions are the result of a more important and finished arrangement, which is as follows.

Immediately after the diverging fibres decussate the converging, which they do at the external margins of the ventricles, they separate from each other and are prolonged into the convolutions, forming a fibrous expansion. These fibres are not all of the same length, for some stop near the sides of the ventricles at the



bases of the convolutions, and others are extended to the surface of the brain. By such arrangement the convolutions are also of different depths. Each convolution consists of two layers of the diverging fibrous or medullary matter, which are symmetrical, are in juxtaposition, and adhere to each other by their contiguous surfaces. Besides this, as has been several times stated, each convolution has its covering of cineritious matter, about a line deep. The medullary fibres penetrate somewhat into the internal face of this covering, from which it is paler and more firm than the exterior surface. The fibrous matter being successively inserted into the sides of the cortical covering of the convolutions, its quantity of course is diminished at the summit of the convolution; hence each simple convolution is wider at its base than at its summit. Some of the convolutions however reverse this rule, for they are flattened or depressed at their summits, like a ridge or duplicature of cloth having its top pushed a little inwards. The convolutions do not all stand out in a radiated direction as regards the centre of the brain, for some of them are bent either to one side or the other.

Each convolution, besides being formed by the ends of the diverging fibres covered with cineritious matter, has, in its structure, nervous fibres more minute and soft than the diverging ones. These are the commencements of the converging fibres, and can be seen only in the convolutions of the posterior lobes of the



brain; the inference, however, is made that they exist in all the convolutions. It is these fibres which accumulate at their decussation with the diverging ones, or immediately after, into the large fasciculi which form the ventricles and the commissures.

If we separate a convolution from the brain and make a perpendicular cut across it, the cut surface is plain and exhibits no mark of being divisible into two laminæ. Yet it does consist of two laminæ with their opposite faces in contact, and agglutinated in all probability to each other by a loose cellular tissue. This fact is proved by the effects of hydrocephalus, for here the water, acting constantly with a distending force, separates the two laminæ of fibrous matter and sometimes effaces the appearance of convolution, converting it into a membrane. The prolongations or convolutions of the cerebellum are formed after the same manner, except that they are divided into branches and leaves, and are smaller than those of the brain.

In the case of a woman affected with hydrocephalus, Dr. GALL found the following condition of the brain. The cerebral mass was distended into a large bladder, by which the total or partial disappearance of all the convolutions had been produced. In places where they had disappeared entirely, the cineritious substance was of almost uniform thickness. All the interior surface of the enlarged ventricles was perfectly



white, and, in a majority of places not only the nervous fibres were distinctly seen, but the blood-vessels which accompany them. The ventricles contained about four pints of clear and limpid water. The fibrous structure and the blood-vessels had no where been impaired. This woman died at the age of fifty-four of an inflammation of the bowels, but from her earliest infancy she had been afflicted with hydrocephalus. She was not very thin, and was as active and intelligent as women of her class in general. This observation led to a train of reflections which terminated in Dr. GALL separating, artificially, the two laminæ of the convolutions of the brain.

His plan is, to remove the pia mater from the whole surface of the brain, and then to introduce the fingers through the inferior part of the brain by the side of pons varolii into the inferior process of the lateral ventricle, along the course of the tænia hippocampi. By this means they may be carried into the body of the lateral ventricle, and by gently extending and separating them, the convolutions are easily unfolded into a membrane without destroying their fibres. During this operation a slight resistance is felt at the circumference of the ventricles, and at the base of the convolutions, at the place where the diverging and converging fibres cross each other. But the tissue which connects them being lacerated, the remainder of the separation is effected without much difficulty. All the interior of the cerebral expansion, thus produced,



resembles a case of hydrocephalus; the fibrous structure being unimpaired, white, and smooth, and covered externally by the cineritious matter.

The crossing of the two orders of fibres is easily demonstrated, but they cannot be detached from each other without tearing their texture; this, however may likewise take place in hydrocephalus, by the slow and uniform pressure of the water continually increasing in the ventricles.

A much easier way to demonstrate the convolution as consisting of two layers, is to remove it from the rest of the cerebral mass, and to make a transverse cut through it, from its summit to its base; by a gentle pressure then with the finger and thumb, from the summit to the base, the two laminæ of fibrous matter may be readily separated from each other, leaving their faces, which were in contact, smooth and uninjured.

Take a section of the periphery of the hemisphere, which has been detached a little distance from the circumference of the ventricles, and consequently nearer the surface than the intertexture which unites the diverging and converging fibres. If the convex part of this be laid in the palm of the hand so as to allow the weight of the section to operate in drawing the convolutions asunder, a very slight additional effort will be sufficient to separate them and to show that their lam-



inæ are only agglutinated to each other. While this process is going on, a little groove or fissure is seen at the place of separation, as well as the perpendicular direction of the fibres and of the blood-vessels.

Let the sections of the brain be hardened for some time in alcohol, or in nitric or muriatic acid diluted with alcohol, or be boiled in oil for ten or twelve minutes, the laminæ of the convolutions may then be separated without difficulty, (and only in the middle line where they are joined together,) by pressing from their summit to their base with the finger and the thumb. The fibrous expansion will be demonstrated clearly, but there will be no vestige or appearance of lacerated fibres.

The following experiment is thought by the authors of this system to prove incontestably that each convolution consists of two fibrous layers, and that these layers do not grow together, but are slightly adherent the one to the other. By blowing with a small tube transversely on a convolution, the convolution is broken to pieces, and no distinct result follows; but by blowing with the same pipe in the direction in which the natural fissure of the convolution is supposed to exist, the convolution splits from top to bottom. By trying the same experiment on a convolution somewhat depressed at its summit, it opens at the base by a simple fissure, and at the superior part this fissure is extended towards each angle by being bifurcated. By injecting water in the direction of a fissure through a



finely pointed syringe, the separation of the convolutions is made with still greater facility than with air, so that the water passes for the distance of an inch or more into the convolution, and even extends itself into the convolutions communicating with this one: of which the examiner may be assured by cutting off the tops of such convolutions. This last experiment will succeed by injecting the water in a transverse direction upon a convolution; so soon as the water has washed away the lamina first opposed to it and gets to the middle, it extends itself laterally in the direction of the fissure of the convolution.\*

Under the conclusiveness of such demonstrations the authors of the system very justly complain, that instead of considering the convolutions both of the Cerebrum and Cerebellum as consisting of two laminæ of fibrous matter placed one against the other and covered by cineritious substance, anatomists still continue to talk of a substance in the convolutions, which is white, soft, and pulpy.

### *Of the Nerves of the Head.*

The most of them can be traced very satisfactorily to the medulla oblongata, and therefore they are con-

\* In all these experiments on the convolutions, it is better to have the pia mater removed previously.



sidered from below upwards. GALL breaks up the association forming the 8th pair, and describes each as a distinct nerve.

The ACCESSORY NERVE forms a natural communication between the nerves of the neck and those of the head, for some of its branches arise in the neck and others in the head. They all come from the posterior segments of the spinal marrow and medulla oblongata; but their origin varies in different individuals, and in the two sides of the same individual, sometimes beginning at the fifth, and sometimes at the seventh cervical nerves. They arise for the most part by single threads which unite successively into a common chord, but sometimes these threads are multiplied, and then form a single chord which joins with the main nerve.

This nerve is spent upon the Sterno-Mastoid and Scapular Muscles, and upon the Pharynx. Hence the sympathy of the stomach and œsophagus with these muscles. The convulsive motions of the shoulders, œsophagus and pharynx, in hydrophobia; and the stiffness of the shoulder and sterno-mastoid muscle in stomach complaints.

The HYPOGLOSSAL NERVE, arises in part between the Corpus Pyramidale and Olivare, and partly below them. Its threads issue, after the manner of the spinal nerves, separately. These threads unite and form three or four fasciculi, which join successively into a



common chord. The hypoglossal nerve is distributed to the tongue and to all the muscles attached to the os hyoides and to the salivary glands. It is connected also by anastomosis to nearly all the nerves found in the neck and throat. It does not taste, but acts in the motions of the tongue performed in mastication, deglutition, &c. GALL says its communication with the cervical nerves, explains how the voice is lost in injuries of the cervical medulla.

The PAR VAGUM, or Nerve of Voice, arises by numerous filaments from the side of the medulla oblongata between the corpus olivare and restiforme, nearer the latter. At their origin these filaments are distinct, but they afterwards unite to form a flattened cylinder, which passes out with the internal jugular vein. It is united with nearly all the nerves of the neck by anastomosis and being distributed to the larynx, lungs and stomach, it performs an extremely interesting part in the animal economy. From this we understand how its injuries impair the voice; how nausea, cough and vomiting follow the tickling of the pharynx; the connexion between the speech and the voice, &c.; and the oppression and cough from sordes in the stomach.

The GLOSSO-PHARYNGEAL NERVE, composed of several filaments, arises from the medulla oblongata near the tuber annulare, and just above the par vagum.



It is united by ramifications in the neck to the facial and sympathetic; and is spent upon the constrictors of the pharynx, and the muscles of the tongue.

All the nerves as yet described correspond very closely with those of the spinal marrow, inasmuch as they rise in the cineritious substance placed interiorly in regard to the point at which they issue, and unite into one or several fasciculi. The nerves that follow have the peculiarity of being successively produced by cineritious substance, and of uniting in the cerebral mass into a fasciculus which rises towards its surface, being more or less visible according to circumstances.

**The MOTOR EXTERNUS.** The origin of this nerve is better seen in the bullock or sheep than in the human subject. In man it sometimes appears to come from the pons or medulla oblongata, or from between the two, according to the breadth of the former. But arising, in fact, from the lower part of the medulla oblongata, it ascends the whole length of the pyramids at their side in the form of a little fasciculus, and divides commonly behind the pons into two smaller fasciculi which depart from the common mass of the medulla, one behind the other. The pons varolii being much larger in man than in the animals just mentioned, frequently some of its transverse fibres cover the motor externus at its point of departure. In this case it appears to rise from the pons, and as its fila-



ments do not all come from the same place, a different origin is assigned to them.

The FACIAL NERVE is considered to arise from the place of union between the pons, medulla oblongata and crus cerebelli, but its origin is better illustrated in the sheep than in the human subject, in the former of which it departs from the medulla below the posterior edge of the pons. It ascends as a fasciculus in the medulla oblongata between the corpus restiforme and the glosso-pharyngeal nerve, to a transverse band at the back edge of the pons in these animals. Passing below this band it pierces it at the internal edge of the auditory nerve. When in the human subject, there is an appearance of this nerve arising from the pons, it is a consequence of the pons being broad enough to conceal a part of its origin.

This nerve explains the motions of the face in laughing or in crying, and the pains in the head and ears during the toothach.

The AUDITORY NERVE. On the anterior face of the fourth ventricle, transverse white medullary striæ exist, supposed to be the origin of this nerve. These striæ vary in number and distinctness in different individuals, being arranged sometimes in rays, occasionally as pencils, at other times they are parallel. Often those of one side are higher than those of the other; sometimes they form little bands and then again are



rounded and projecting, being, in all cases, separated from each other by a fissure in the median line. GALL says he has never seen their decussation from the opposite sides, spoken of by Portal. Many of these medullary striæ go to the auditory nerve, but others go in part to the anterior lobules, or thrust themselves into the middle of the cerebellum.

Mammiferous animals want these medullary striæ; one may, therefore, assert confidently, that many of the filaments of the auditory nerve arise in the cineritious substance of the fourth ventricle. This cineritious substance is in less quantity in man, but forms an oblong elevation, the *Fasciola Cinerea*, called *Ruban Gris* by the French anatomists; in the sheep, hog, horse, ox, it is the size of a pea. This body may be considered the ganglion of the auditory nerve, and is placed precisely where this nerve winds around the corpus restiforme, its size being always proportionate to that of the auditory nerve.

In animals, immediately behind the pons a large transverse band is extended from one auditory nerve to the other, which passes above all the other ascending nervous fasciculi with the exception of the pyramids. In man it is covered by the posterior part of the pons, and is considered by GALL as a commissure of the auditory nerves.



The TRIGEMINUS, or 5th Pair. Comparative anatomy affords the surest aid in regard to the origin of this nerve, also, according to GALL. "In fish the ganglion from which this nerve proceeds is insulated, and its nervous fibres from their beginning are separated from the common mass. In mammiferous animals a large fasciculus exists at the exterior edge of the under surface of the medulla oblongata, which passes beneath the transverse band already mentioned, and projects itself between it and the pons. In the ape and in man this fasciculus is covered in part by the pons, hence the opinion prevails that it arises at the side of the pons. By removing cautiously the posterior part of the pons till the fasciculus of this nerve be reached, it will then be easy to follow its entire course to the lower part of the exterior edge of the corpus olivare. In this manner it will be seen very readily, that even in the interior of the pons it divides into three principal fasciculi, and that its fibres are increased by the cineritious substance in different places."

The TROCHLEARIS, 4th Pair, arises from the side of the valve of the brain, but much lower down than is generally supposed, sometimes by one filament, and at others by several. GALL observes, that at the place indicated generally as its origin, it only projects from the valve, which is a very different thing from its actual origin.



The MOTOR OCULI, 3d Pair, issues from the internal edge of the crura of the brain between the pons and the eminentiæ mammillares. Its origin penetrates to the third ventricle, but is separated from it by an interposed stratum of medullary matter. Many filaments compose its roots which are reinforced by additions from the cineritious substance called Pons Tarini, but it has no filament from the eminentiæ mammillares as has been asserted.

The OPTIC NERVE, in man, but more distinctly in mammiferous animals, comes as a large fasciculus of fibres from the nates, winds around the exterior edge of the optic thalamus, where it is united to a considerable mass of cineritious substance, called Corpus Geniculatum Externum, and is by it reinforced. So far the fasciculus is attached to the optic thalamus, but afterwards is only placed upon the crus of the cerebrum to which it adheres, by its anterior edge being united to the neighbouring cerebral fibres. In front of this the nerve becomes rounder and adheres to a firm bed of cineritious substance, the *tuber cinereum*, and receives from it, particularly above, several nervous filaments which unite to each of its sides. The optic nerve is so much reinforced by these filaments that the increase of its bulk is very perceptible, particularly after its junction with its fellow.

In birds the optic nerve comes very distinctly from the nates, which establishes more fully that it must



have the same origin in man and in the mammalia. In the left hemisphere of the brain of a deranged female, Dr. GALL found the thalamus almost destroyed by an ulcer, the corpus striatum and the hemisphere much diminished, but the optic nerve of the same side remained entire and like its fellow. The nates were in a natural state. When, on the contrary, he has found the optic nerve dwindled away, it has been attended with a corresponding diminution of the nates which belongs to it. In the horse, bullock, deer, &c. the optic thalami are smaller than in man, while the optic nerves themselves are larger; no proportion therefore exists between them, while it does exist as regards the nates.

Messieurs GALL and SPURZHEIM believe that the optic nerves decussate each other, and they quote the experience of Dr. Sœmmering, who had observed the fact in seven one-eyed men; and in the horse, the dog, the hog, the cat, the goat, the rat, and the rabbit.

The OLFACTORY NERVE issues from the cineritious substance, in the inferior surface of the hemispheres. Its first filaments are seen at the anterior part of the internal convolutions of the middle lobes; they are soft and delicate, and are surrounded for some distance by cineritious substance. These filaments approach each other and form commonly three principal roots, the internal of which is shorter and broader than the two external. The most exterior, which is the longest,



may be followed to the bottom of the fissura sylvii. These are the only nerves of which there is any doubt whether they take their origin in the hemispheres or not, but even if they do, they are not continuations of the medullary fibres of the hemispheres.



### SECTION III.

#### *Of the Eye.*

THE hairs on the superior edge of the orbit are called Supercilia, and on the edges of the eyelids the Cilia.

The Orbicularis Palpebrarum muscle being removed, immediately beneath it are the two Tarsi Cartilages, which form the margin and a considerable part of the breadth of the upper and of the lower eyelid. The upper cartilage is of a semi-oval figure, the broadest part being not quite half an inch; the lower cartilage is of an uniform breadth, not exceeding in any part one-fourth of an inch. Their external extremities are united with each other and kept in their places by a ligamentous expansion (*Ligamentum palpebrale externum*) connecting them with the orbital margin of the malar bone, and internally they are fixed to the nasal process of the superior maxillary bone by the



tendon (*Ligamentum palpebrale internum*) which affords origin in part to the orbicularis palpebrarum. The edge of these bodies is slanting so that a groove is formed posteriorly where they are in contact, by which the tears are conducted to the inner corner of the eye. Near the internal extremity of each, but not in the cartilage itself, is to be found in the centre of a small eminence, a foramen the Punctum Lachrymale, capable of receiving a bristle, and being the orifice of a canal, the Ductus or Canaliculus Lachrymalis, which conveys the tears into the Sacculus Lachrymalis.

On the posterior surface of the tarsi cartilages, are placed several white tortuous canals in contact with each other, and having their extremities on the edges of the eyelids; they are the glands of Meibomius, and secrete an unctuous substance. In the upper lid there are about thirty, and in the lower about twenty.

At the internal junction of the eyelids is placed the Caruncula Lachrymalis, a small granulated body inferior in size to a grain of wheat, and of a glandular structure for secreting an unctuous fluid.

The lids are connected to the ball of the eye by a delicate vascular, and highly sensible membrane, the Tunica Conjunctiva, which is spread over the anterior third of the eye, not excepting the cornea, but there it becomes perfectly transparent. At the inner surface of the eye, the conjunctiva is thrown into a fold, the



Valvula Semilunaris, corresponding with the membrana nictitans of some animals.

The LACHRYMAL DUCTS (Canaliculi Lachrymales) are under the skin of the internal canthus, are from five to six lines long, and terminate by separate foramina in the sacculus lachrymalis. There is a sort of flap of the internal membrane of the sac which falls over these orifices.

The Lachrymal Sac occupies all the concavity in the os unguis, and extends from a short distance above the tendon of the orbicularis muscle, to the cavity of the nose under the anterior part of the inferior spongy bone; it is contracted to the size of a small crow-quill at its nasal extremity, and there has the name of Ductus ad Nasum. A duplicature of the membrane of the nose resembling a valve, is frequently found at the orifice below.

The Lachrymal Gland for the secretion of tears is placed in the superior and external part of the orbit, near its margin; it is about ten twelfths of an inch long, and half an inch wide, being flattened so as to suit the parts with which it is in contact. It is placed on the outer side of the tunica conjunctiva, and sends five or six small ducts through it, whose orifices are in the tunica conjunctiva of the upper eyelid near the exter-



nal junction of the tarsi cartilages. It is divided into an anterior and posterior lobe by a small ligamentous band attaching it to the depression of the os frontis.

The muscles in the orbit are as follow:

1. **LEVATOR PALPEBRÆ SUPERIORIS** arises near the superior margin of the optic foramen, and is inserted into the upper margin of the superior cartilage of the eyelid. Use, to draw the lid upwards.

2. **LEVATOR OCULI**, or **Rectus Superior**, arises from the superior margin of the optic foramen, and is inserted into the upper part of the ball of the eye near the cornea, by a flat tendon. It turns the cornea upwards.

3. **DEPRESSOR OCULI**, or **Rectus Inferior**, arises from the inferior margin of the optic foramen, and is inserted into the lower part of the ball of the eye near the cornea. It draws the cornea downwards.

4. **ADDUCTOR OCULI**, or **Rectus Internus**, arises from the internal margin of the optic foramen, and is inserted into the internal part of the ball of the eye near the cornea. It draws the cornea inwards.

5. **ABDUCTOR OCULI**, or **Rectus Externus**, arises from the external margin of the optic foramen, and is inserted into the external part of the ball of the eye. It turns the cornea outwards.



6. **OBLIQUUS SUPERIOR**, arises from the internal margin of the optic foramen, runs along in contact with the orbital plate of the os frontis, passes through the trochlea near its internal angular process, and, being enclosed in a sheath sent off from the trochlea, its round tendon is inserted about half-way between the cornea and optic nerve in the superior part of the eyeball. It turns the eye on its axis.

7. **OBLIQUUS INFERIOR**, arises from the orbital plate of the superior maxillary bone near the os unguis, and is inserted into the outer part of the eyeball half-way between the cornea and optic nerve. It turns the eye on its axis.

8. **TENSOR TARSI**. At the internal canthus of the orbit is a small muscle belonging to the internal commissure of the eyelids.

This muscle is about three lines broad and six lines long; it arises from the posterior flat surface of the os unguis near its junction with the os æthmoides, and passes forwards and outwards, lying on the posterior face of the lachrymal ducts. As it approaches the commissure of the lids, it splits into two parts nearly equal, each of which is appropriated to a duct, and inserted along its course almost to the punctum lachrymale.

To get a distinct view of it, the eyelids must be



separated from the eye and turned over the nose, leaving the tendinous attachment of the orbicularis and ciliaris muscle. The *valvula semilunaris* being brought into sight by this process, must be dissected away, and also the fat and cellular membrane underneath it. The muscle is now seen, and by passing bristles through the lachrymal ducts its connexion with them is rendered evident, at the same time that we get a good idea of its size, origin, and insertion. While making this inspection, by turning the muscle somewhat aside, we shall be rendered sensible of another fact of some importance, that the attachment of the inner commissure of the eyelids to the internal canthus of the orbit is imperfectly described, even by anatomists of much minuteness in their accounts. It is attributed exclusively to the tendon of the orbicularis muscle, so much so that in the operation for fistula lachrymalis we are strictly enjoined not to cut through the tendon, lest a puckering of the eyelids be produced by their line of extension being destroyed. The fact, on the contrary, is, that a ligamentous matter behind this tendon passes between the internal ends of the eyelids and the posterior flat surface of the *os unguis*, so that admitting the tendon of the orbicularis to be cut through, this ligament assisted by the little muscle described, would prevent the dreaded deformity. The internal extremity of this posterior ligament is at least half an inch from the insertion of the orbicularis tendon into the nasal process, and it brings the eyelids into the



curve commonly seen at their junction. The lachrymal ducts are involved in this posterior ligament, passing along it into the sac instead of going along the edges of the commissure, as commonly described, just under the skin.

The muscle described must influence considerably the position of the puncta lachrymalia by drawing them towards the ball of the eye and keeping them in close contact with it; it is, therefore, a very efficient means for regulating so far the lachrymal passages and for securing the course of the tears. I am indebted to Dr. PHYSICK for a further suggestion in regard to its use, which appears highly probable. In cases of extreme emaciation, it is well known that the adipose matter around the ball of the eye is more or less absorbed, causing the eye to sink deeper into the orbit, and consequently to retire somewhat from the lids. The effect of this muscle is to draw the lids backwards and to keep them applied on the ball. Again, in the elevation of the upper lid, or rather the drawing of it within the orbit by the levator palpebræ, the tendency of the margin of the lid is to leave the ball; the upper part of the little muscle obviates this tendency. As such appears to be the actions of the part, I must, therefore, coincide with him in calling it *Tensor Tarsi*, a name expressive of its functions.

The puncta lachrymalia have a power noticed by Richter, of projecting themselves beyond the plane of the eyelid in which they lie, and have an equally obvi-



ous power of retracting themselves so as to do away all appearance of prominence. I do not understand the cause of the first motion, but the second depends upon the muscle just described.

The Ball of the Eye is composed of several coats and humours. As the human subject can seldom be obtained sufficiently fresh for a proper display of the structure; it is recommended to use the eyes of sheep, bullocks, or pigs, which can be got at any time. The eye is to be removed from the orbit and cleared of its fat, and muscles. Anatomists have devised various means for fixing it for dissection; for my own part I have found a common saucer sufficient, and water enough in it to float the organ; the specific gravity of this fluid approaches so nearly to that of the eye, that it affords a very good support to its delicate membranes, and sufficient stability for most purposes of examination.

The Tunica Sclerotica, the first coat of the eye, is to be examined by opening the ball very freely and turning out all of its contents. We shall then see that it has considerable thickness, being of a compact fibrous texture, possessed of little elasticity, and therefore well calculated for giving support to the interior structure. It is white and tendinous like the dura mater, and has few vessels or nerves. It is connected behind, to the optic nerve, where it is perforated by several small



holes for the passage of the nerve; and before to the Cornea.

The Cornea is a perfectly transparent membrane, consisting of many laminae united by a delicate cellular substance. It is much more convex than the sclerotica, and is united to it by a broad sloping edge, where the two membranes adhere very firmly to each other by the sclerotica overlapping the cornea. They may be separated by putrefaction. The cornea in a healthy state has no red blood circulating through it. It is covered before by the tunica conjunctiva, which there becomes assimilated in its sensible properties to it; and behind by the capsule of the aqueous humour.

An eye being floated in the manner just mentioned, a puncture is to be made with a lancet or sharp-pointed scalpel, through the sclerotica about half way from its centre; and the blunted blade of a pair of scissors being introduced through the opening, a circular cut should be made all around, taking great care not to injure the coat below. By making radiated sections to the optic nerve from this circular one, we shall be able to peel off, with but little difficulty, all the posterior part of the sclerotica; observing, however, to leave the optic nerve. What remains of the anterior part of the sclerotica may be easily drawn away along with the cornea. This stage of the dissection gives a good view of the TUNICA CHOROIDEA; of a white circle called



the Ciliary Ligament seeming to terminate it before, and of the Iris placed upon the fore part of the eye, an opening in the middle of which affords a glimpse of the internal structure.

The Tunica Choroidea lines all the interior of the sclerotica and is a much thinner and more delicate membrane than it; it appears black, and is covered on the outside with a flocculent cellular substance connecting it with the sclerotica. Its black colour depends upon a large quantity of colouring matter deposited principally on its inner surface, and called *Pigmentum Nigrum*. The tunica choroidea abounds with blood-vessels, which make it look perfectly red in living animals devoid of the black pigment. It has a singular arrangement of veins which can be made distinct only by injection. They are called *Vasa-Vorticosa*. It is well furnished with nerves, which appear like flattened pieces of white thread lying on its outside. If the Iris be torn away, the anterior edge of the membrane is seen terminating in a fringe called *Corpus Ciliare*, and this fringe, if closely observed, will be seen to consist of a great number of short and distinct processes, arising from small folds called the *Ciliary Striæ*, and covered with *pigmentum nigrum*.

The Iris is a membrane placed across the eye just behind the cornea; it is highly vascular, but having a large quantity of *pigmentum nigrum* on its posterior



surface, the vessels are not evident in a living state. Its anterior surface determines the colour of the eye. In its centre is a round hole called the Pupil, for admitting light, and which is increased or diminished by the action of circular and radiated filaments composing the body of the membrane. They are considered by many as muscular. In the foetus the pupil is closed by the Membrana Pupillaris till the seventh month.

The CILIARY LIGAMENT as stated is a circle of whitish substance which is placed around the anterior part of the eye, and serves to connect strongly the Iris with the Tunica Choroidea; and these again with the anterior edge of the Sclerotica and the margin of the cornea. In it is a canal called the Aqueduct of Fontana.

Having finished the examination of these parts; with two pair of fine forceps strip off the whole of the Tunica Choroidea. This is one of the nicest manipulations in the whole dissection, and must therefore be done with great care. If it be well executed, the most delicate membrane in the human frame, will be found lining the choroid coat; it was discovered in Dublin, by Mr. JACOBS, and may be satisfactorily demonstrated, by commencing at the optic nerve with the extremity of a knife-handle, and turning the membrane down, by scraping towards the anterior part of the eye. It extends from the optic nerve to the anterior edge of the Retina.



Beneath the *Tunica Jacobi*, is placed the *Retina*, a delicate, transparent, and pulpy membrane, extending from the optic nerve distinctly to the commencement of the *Ciliary Striæ* of the *Choroid Coat*; and some anatomists maintain that it goes on as far as the circumference of the *Crystalline Humour*, which is by no means so obvious. The optic nerve, after penetrating the cribriform part of the *Tunica Sclerotica*, forms a bulb on its inside; from this bulb the membrane called *Retina*, is expanded over the interior surface of the eye. The *Retina* consists of two layers; the internal is a very delicate and a vascular net work, consisting of fine meshes; the external is the proper nervous matter, having a consistence not much stronger than common mucus. In the centre of the optic nerve is seen the artery which supplies the *Retina*, called the *Arteria Centralis*. The branches of veins correspond with the arterial ramifications, and we commonly see them distended with blood in our dissections of animals killed by a blow on the head. In the centre of the *Retina* is the foramen of *Sœmmering*, surrounded by a yellow spot, and having a fold connecting it to the bulb of the optic nerve. Impressions made on the *Retina* are supposed, generally, to be the cause of vision, and of the contractions and dilatations of the pupil. Dr. *Physick* believes, in regard to the latter, that the *Iris* is immediately stimulated by the light, as he has seen cases where the motions of it were active and well marked, in paralysis of the *Retina*.



The Humours of the Eye are three, the Vitreous, Crystalline, and Aqueous. They are all perfectly transparent, but differ much in their consistence and structure.

The Vitreous occupies nearly all the eye posterior to the Iris; it is like melted glass, from whence its name. When minutely examined, it is found to consist of a fluid like water contained in a very delicate membrane or capsule, which is cellular; the peculiar consistence of it is therefore derived from the latter. This capsule, called *Tunica Hyaloidea*, is fixed at the bottom of the eye by a branch of the central artery of the Retina, and before, by a close adhesion to the Ciliary Striæ and Body. The Retina lies loose upon it.

The Crystalline Humour is fixed on the anterior part of the Vitreous just behind the pupil. It is a double convex lens, about three and a half or four lines in diameter, the posterior convexity of which is much the greatest. Its consistence is that of half dissolved glue, but it becomes more solid towards the centre. By putting it in boiling water for half an hour, it becomes hard and opaque, and one is enabled to unravel its structure. It consists entirely of concentric lamellæ, which, with a needle, may be separated into very fine fibres. It is enclosed in a capsule of the same shape, and between it and the capsule is found a small quantity of transparent fluid called *Liquor Morgagni*. Anatomists do not agree in regard to the



origin of the capsule, some thinking that it is entirely derived from the tunica hyaloidea, others that it is totally distinct from it, an opinion which I am disposed to consider the correct one. Admitting the opposite to be correct, the structure of the tunica hyaloidea is unquestionably much altered, especially in front, as the capsule there is possessed of more thickness, is elastic; and cuts very much like the thin shavings of a finger nail. In the tunica hyaloidea surrounding the circumference of the capsule of the lens, is placed the Canal of Petit, which, when inflated or injected is seen to be divided in a radiated manner by a number of incomplete partitions.

The Aqueous Humour is placed between the lens and the cornea, and is nearly as thin as water. The Iris floats in it, which has occasioned the division of the space occupied by the aqueous humour into Anterior and Posterior Chambers of the Eye; all the space of the aqueous humour behind the Iris is called the Posterior Chamber, and all the space before the Iris is called Anterior Chamber. Both of these chambers are said by M. J. Cloquet to be lined by the capsule of the aqueous humour; this membrane, however, is not very evident except on the posterior surface of the Cornea.

The ball of the eye and the muscles surrounding it, are imbedded in a considerable quantity of adipose



matter, the profusion of which, in health, gives prominence to the organ; and the absorption of which, in disease, produces the sunken eye.

*Of the Vessels and Nerves met with in the Orbit.*

To display these parts the roof of the orbit must be entirely removed. The internal Carotid Artery, as it lies near the anterior clinoid process of the sphenoid Bone, detaches a large branch, the Ophthalmic; which in passing through the optic foramen is first under the optic nerve, then gets to the outside of it, and finally winds over to the inside of the nerve. Near the posterior part of the eye it sends off a branch which penetrates to the centre of the optic nerve, and is distributed to the retina. It also divides into several branches which go to the Lachrymal gland;—to the muscles of the eyeball;—to the Tunica Choroides, constituting the Ciliary Arteries;—and finally, branches which pass through the anterior and posterior æthmoidal foramina and through the superciliary foramen. At the bottom of the orbit, and coming out at the infra-orbital foramen upon the face, is found a large branch of the Internal Maxillary Artery.

The Veins of the orbit have very much the same course with the arteries, some being connected with the facial vein at the internal angle of the eye, and



passing into the external jugular; and others, sending a trunk through the foramen opticum, which runs into the cavernous sinus, and consequently into the lateral sinuses.

Five trunks of Nerves are to be found in the Orbit.

1st. The Optic, which is expanded into the Retina.

2d. The Third Pair, or MOTOR OCULI, which, passing through the foramen sphenoidale into the orbit, divides into two branches. One goes to the upper part of the orbit, and is distributed to the Levator Oculi and the Levator Palpebræ Superioris; the other goes to the Adductor, the Depressor, and the Obliquus Inferior. From it is sent a filament which runs to the Lenticular or Ophthalmic ganglion; the latter is situated on the outside of the optic nerve near its entrance into the orbit.

3. The TROCHLEARIS, or Fourth pair of nerves, is exclusively appropriated to the Obliquus Superior muscle, and also gets into the orbit through the foramen sphenoidale.

4. The MOTOR EXTERNUS, or Sixth nerve, passes through the foramen sphenoidale of the orbit, and is spent on the Musculus Abductor.

5. The first branch of the Fifth nerve, or the OPH-



THALMIC, passing also through the same foramen, divides into the Frontal, Nasal, and Lachrymal. The first has but little to do with the Orbit, as it simply passes along its superior part to get out upon the forehead, through the supra-orbital foramen and at the Trochlea of the os frontis. The second passes along the inner side of the orbit, sends a filament to the Lenticular ganglion; another through the anterior æthmoidal foramen which goes ultimately to the nose, and what remains is distributed to the lachrymal sac and the contiguous parts. The third branch goes to the Lachrymal Gland, whence its name.



#### SECTION IV.

##### *Of the Ear.*

THE organ of hearing may, for the purpose of study, be divided into three parts, the boundaries of which, even by nature, are well defined; to wit, the External Ear, the Tympanum, and the Labyrinth.

THE EXTERNAL EAR consists of the structure exterior to the head; and of the passage called Meatus Auditorius Externus, leading to the interior of the petrous portion of the temporal bone.



The part, in common language called Ear, is principally cartilaginous, but to the lower edge of the cartilage is appended a softer structure consisting of delicate granulated adeps, with a kind of tendinous cellular membrane. The cartilaginous portion is called Pinna, the other Lobus. The pinna presents a very unequal surface both on the outside and on the inside. The former being the part employed in collecting rays of sound and converging them through the meatus externus, merits our principal attention. The deep concavity in the middle of it, is called Concha. In the upper part of the concha, and dividing it into two unequal fossæ, we find a ridge of cartilage commencing, which is traced in the form of a scroll along the circumference of the pinna till it terminates insensibly in the posterior part of the lobus. This fold is the Helix; within it is a ridge of cartilage which is the Antihelix, terminating above by a bifurcation. On the anterior part of the concha, and overlapping it obliquely, is the cartilaginous process called Tragus, and opposite to it at the lower end of the antihelix is the Antitragus. Under the fold of the helix is the Cavitas Innominata, and between the bifurcation of the antihelix is the Scapha.

The Meatus Auditorius Externus is about one inch in depth, calculating from the bottom of the concha; it proceeds obliquely forwards in a course corresponding to the situation of the petrous bone, and besides



that, has a curve with the convexity upwards. The internal half is bony, but the outer half is composed of cartilage and of ligamentous matter. If the skin be removed from the ear it will be seen that the concha is formed not entirely by cartilage; but at the bottom of it, and connecting it and the commencement of the helix with the tragus, is a ligamentous expansion which contributes also to the meatus externus. In the tragus cartilage, near the bone, are found two fissures filled up with elastic ligamentous substance; they are the *Incisuræ*. The whole of this arrangement of cartilaginous and membranous matter is highly favourable to the exercise of the sense, as the former, by its resistance, is well calculated for reverberating sound, and the latter affords great facility of motion as a kind of hinge is formed by the *incisuræ*. The cartilaginous is joined by ligaments to the bony meatus, the exterior edge of the petrous bone being rough and irregular for this purpose; there are also three ligaments, one sent to a point above the mastoid process, one to the zygomatic process, and a third to the temporal aponeurosis.

The External Ear is covered by a delicate skin having a great number of sebaceous follicles in it; as the skin descends into the meatus it becomes still more delicate and sensible, is beset with hairs, and under it are found, in considerable numbers, the *glandulæ ceruminosæ* which secrete the wax.



On the external ear are five muscles, which can seldom be seen distinctly enough to merit the name. On the superior and anterior part of the helix is the *Helicis Major*; on its inferior part is the *Helicis Minor*; on the anterior side of the tragus is the *Tragicus*; on the anterior part of the antitragus is the *Antitragicus*; and on the cranial side of the ear is the *Transversus Auris*.

In most persons there are also three muscles appropriated to the movement of the external ear, upon the head, and which, though sufficiently well developed, are scarcely ever employed. The *Attollens Auriculæ*, which arises by a broad membrane from the tendon of the *occipito frontalis* and the fascia of the temporal muscle, and is inserted into the prominence made by the *Scapha* or *Fossa Navicularis*. The anterior *Auriculæ*, which arises from the temporal fascia just above the posterior part of the zygoma, and is inserted into the anterior part of the helix. And the *Retrahens Auriculæ*, consisting of two or three slips, the inferior of which arises from near the root of the mastoid process, and is inserted into the prominence made by the concha below; while the second slip arises from the temporal bone higher up than the former, to be inserted also into the back of the concha above the first. The names of these muscles express their action.

2. The *Tympanum* is situated in the outer part of the *Petrous Bone*, and is separated from the *Meatus Externus* by a partition called *Membrana Tympani*.



The membrana tympani is placed very obliquely, just at the bottom of the meatus, its upper part being the outermost. It is not flat, but has its centre drawn inwards by the handle of the malleus. It consists of four layers, the cuticle, the true skin, the proper membrane, and the lining membrane of the tympanum. When successfully injected, it shows a high degree of vascularity. The two outer layers are easily separated from the others, and do not partake much of their vascularity.

The tympanum contains a great deal of curious and interesting structure; its depth is about three lines; its antero-posterior diameter, six lines; and its vertical diameter rather more. On its superior posterior part is an oval opening communicating with an extensive cellular arrangement in the Mastoid Portion of the temporal bone; and on its anterior side is seen the canal of Eustachius going to the Posterior Naris. In the bottom and central part of the tympanum, is a striking convexity, the Promontory, just above the superior edge of which is the Foramen Ovale, and below and somewhat behind it, is the Foramen Rotundum. On the posterior surface of the tympanum, in a line with the foramen ovale, is a very small bony process, the Pyramid, which is hollow, and has a hole in its apex.

Four small bones are found in the tympanum, which



form a chain between the membrana tympani and the Labyrinth; they are the Malleus, Incus, Os Orbiculare, and Stapes.

The **MALLEUS** is placed before the others, and consists of a spherical head, a neck just below the head, uniting it with a tapering handle; a long and crooked projection of the anterior part of the neck, called *Processus Gracilis*, and a short one on the outside below the other, called *Processus Brevis*, which sends out a round ligament\* to the edge of the tympanum.

The **INCUS** resembles somewhat a molar tooth, with two fangs widely separated, and one much longer than the other. The superior and anterior part of the body of the bone is excavated for articulating with the head of the Malleus. From the lower part of the body proceeds the *Processus Longus*; and from the back part looking into the orifice of the mastoid cells is the *Processus Brevis*.

The **OS ORBICULARE** is a flattened sphere about the size of a mustard-seed placed between the extremity of the long process of the Incus and the Stapes.

The Stapes resembles very much a stirrup-iron, and

\* This ligament is described by some as the *Laxator Tympani Minor Muscle*.



is placed horizontally at right angles with the malleus. It has a small head, articulating with the os orbiculare, from which proceed an anterior and a posterior crus. On the inner side of each crus is a fossa running its whole length. The crura diverging in their progress and gently bent, are united by a broad base, which corresponds in its dimensions with the foramen ovale over which it is placed.

To get a good view of the malleus and incus, we must cut away the superior margin of the tympanum; their bodies will then be seen placed vertically and in contact, a complete articulation being formed by them.

The cavity of the tympanum is lined by a delicate and vascular membrane, continued through the Eustachian tube from the pharynx, and into the Mastoid Cells. The little bones are all covered by a reflection of the same, and the foramen rotundum is closed up by it.

There are three muscles appropriated to the movement of these bones, two to the Malleus, and the other to the Stapes.

The LAXATOR TYMPANI, placed in the glenoid fissure of the temporal, and arising from the spinous process of the sphenoid bone, is inserted into the processus gracilis of the Malleus. It draws the Malleus outwards, and consequently relaxes the membrane of the tympanum.



The **TENSOR TYMPANI** arises from the cartilage of the Eustachian tube, lies in its upper bony part, and is inserted by a tendon into the neck of the malleus, a little below the processus gracilis. It draws the handle of the malleus inwards.

The **STAPEDIUS** occupies the conical cavity of the pyramidal process, and is inserted by a delicate round tendon into the head of the Stapes. It draws this bone backwards.

3. The **LABYRINTH**. To obtain a good view of this structure, a foetal bone must be procured, as the labyrinth is more accessible in it and nearly as fully developed as in the adult. The petrous bone here has a condensed but thin structure on its surface, which being removed, brings into view a soft and cellular bone easily managed with a pen-knife. By paring it away, we come in contact with the labyrinth, which is readily recognized by its hardness and brittleness, and may be got out with but little trouble. Having proceeded thus far, the labyrinth is seen to consist of three parts; above and posteriorly are the Semicircular Canals, in the centre is the Vestibule, and below is the Cochlea. The whole of this structure is hollow.

The Semicircular Canals attached to the back and upper part of the vestibule, are so situated that one is Superior, another Posterior, and the third Exterior.



The superior and posterior are united together at their upper extremities, and therefore have a common canal entering into the vestibule; their other extremities are widely divergent from each other, and enlarged, each forming an ampulla before it enters into the vestibule. The exterior canal is shorter than the others, lies nearly horizontal, and has its external extremity enlarged also into an ampulla which is placed near the ampulla of the superior canal. These three canals, from two of them uniting, have only five orifices in the vestibule.

The Vestibule has a cavity about the size of a grain of barley, and is placed just on the inner part of the bottom of the tympanum. The foramen ovale is the common orifice between them. On the superior and exterior part of the cavity contiguous to the openings of the canals is the semi-elliptical depression, and below this and somewhat more internally is the hemispherical depression, the recollection of both of which will be useful to us at a subsequent period of the description. At the lower part of the vestibule is a foramen communicating with the cavity of the cochlea.

The Cochlea, consists of a conical tube wound spirally two and a half times on itself, and is fixed at the anterior part of the vestibule. It has a broad cribriform base forming the bottom of the meatus audi-



torius internus, and an apex which occasions the promontory in the tympanum. Passing from its base towards the apex is a pillar of bone called *Modiolus*, on which the conical tube is wound. This pillar tapers almost to a point, and then is spread out into a cavity resembling a funnel, from whence the name *Infundibulum*. The apex of the cochlea from its covering over the *Infundibulum* is called the *Cupola*.

When the conical tube is cut open freely a partition is seen to divide it into two equal portions from the base to the summit. This partition, called *Lamina Spiralis*, arises by two delicate lamellæ of bone with an intermediate cellular structure from the *Modiolus*, but does not go completely across the canal, for on minute examination, the lamina spiralis is seen to consist besides of cartilage, of a cellular portion containing a fluid, and of a membrane. These portions are called zones, we therefore have *Zona Ossea*, *Coriacea*, *Vesicularis*, and *Membranacea*. The lamina spiralis terminates in the infundibulum by a process called *Hamulus*.

The divisions in the Cochlea thus made by the lamina spiralis form the scalæ. The lowest of these scalæ has the foramen rotundum looking into its base, and the upper communicates by the foramen at the bottom of the vestibule with the cavity of the vestibule. From these communications we have the names *Scala Tympani*, and *Scala Vestibuli*. The scalæ commu-



nicate also with each other just at the hamulus in the infundibulum.

The whole labyrinth is lined by a highly vascular membrane, exhibited by our preparations in the university, which seems to be very different from common periosteum.

Thus far the description has applied only to the bony labyrinth, but by removing it we shall find besides the vascular membrane just mentioned, the following parts. Three Membranous Semicircular Canals within the bony, conforming to their figure and containing a pellucid fluid; these canals all communicate by their extremities with a sac called *Alveus Communis*, situated in the semi-elliptical depression of the vestibule.—Within the vestibule, and occupying the hemispherical cavity, is another and smaller sac like a bubble filled with a transparent fluid; distinct from the former, and called the *Sacculus Sphericus*. To complete this part of the description of the labyrinth, it is to be observed that between the bony and membranous canals, in the vestibulum on the outside of the sacs, and in the *scalæ* of the cochlea, is to be found a transparent fluid, which can pass from one of these cavities into the other by the foramina already mentioned.

It is in connexion with this fluid that we find two supposed aqueducts for its removal, called after *Cotunnus*, one for the Vestibule, another for the Cochlea.



The first arises near the common orifice of the superior and posterior semicircular canals, and discharges itself just behind the meatus auditorius internus. The other comes from the cochlea near the foramen rotundum, and runs into the jugular fossa just at the root of the spine for separating the eighth pair of nerves from the internal jugular vein.\*

The Nerve of Hearing, or the *PORTIO MOLLIS*, is distributed throughout the labyrinth. The bottom of the meatus internus being divided into two unequal fossæ by a ridge; the uppermost is the smaller and perforated with several foramina, all of which, except the anterior large one are appropriated to the passage of the portio mollis to the vestibule. The larger fossa at the bottom of the meatus is also cribriform, and forms the basis of the cochlea; through it pass fibrillæ to the cochlea, vestibule, and semicircular canals. The portio mollis, descending to the bottom of the meatus, passes in several divisions, to the soft structure within the bony labyrinth. One division entering the vestibule, is spent on the alveus communis and membranous canals; another division goes to the sacculus sphericus. A third division, penetrating from the base of the modiolus, runs through it and comes out upon the lining membrane of the cochlea, between the plates of the lamina spiralis, and through the infundibulum

\* M. Ribes has ascertained that they only conduct blood-vessels.



and other parts. The fibrillæ of the portio mollis, during this distribution, continue exceedingly delicate, and are finally found in a pulpy state resembling the retina upon the internal surface of the cavities and sacs just mentioned.

The PORTIO DURA, though not concerned in the function of hearing, passes through the petrous bone in a curious manner. Entering into the large foramen in the upper fossa of the meatus internus, it goes outwards almost as far as the vidian foramen and there makes a very abrupt turn backwards, forming an acute angle called its elbow. It then runs just above the foramen ovale, making a ridge in the tympanum; continues its course so as to surround the back part of the tympanum, and emerges at the foramen stylo-mastoidium. It is afterwards distributed to the face. Its canal in the bone is called the aqueduct of Fallopius. Near the vidian foramen it sends a filament to the tensor tympani and at the base of the pyramid one to the stapedius.

The CHORDA TYMPANI, a branch of the pterygoid nerve, passes into the vidian foramen and joins the portio dura, running closely connected with it almost to the stylo-mastoid hole. It then leaves the portio dura at an acute angle and enters into the back part of the tympanum, crosses this cavity completely, by going between the long leg of the incus and the handle of the



malleus. It gets from the tympanum through a foramen in the fissure of the glenoid cavity, and joins ultimately the lingual branch of the fifth pair of nerves.

The labyrinth is principally supplied with blood from a branch of the vertebral artery which gets to it through the meatus internus. The tympanum and external ear are supplied from the stylo-mastoid and temporal arteries.



## SECTION V.

### *Of the Nose.*

IN order to understand this part of our structure it is necessary to be well acquainted with the bones constituting its cavity, both individually and collectively. Being thus prepared, we shall see that the nostrils which are incompletely separated from each other in the skeleton have a perfect septum in the recent subject, which renders them two distinct cavities. This is effected by a cartilage placed at the anterior part of the vomer and of the nasal lamella of the æthmoid bone. At the junction of this cartilage with the nasal suture, it spreads out on each side into a wing, which is attached to the lower edge of the nasal bones, and the adjoining margin of the nasal process of the upper



maxillary, and extends, by such means, the bridge of the nose.

Proceeding from the lower edge of the wing of this cartilage, and from the external bony margin of the anterior naris, is an elastic ligamentous membrane forming the side of the nostril. At the anterior part of this membrane is an oval cartilage which forms two-thirds of a ring, the exterior portion of it is the broadest; the internal portion, placed in contact with the corresponding part of the oval cartilage of the other side, runs backwards, and forms by the union, the *Columna Nasi*. In the back of the ligamentous membrane there are several detached pieces of cartilage which give firmness to the structure and produce the prominence of the *ala nasi*. It is by means of these several cartilages that the orifice of the nostril is kept open.

The posterior nares, being separated by the vomer, are oval, and do not present an outline differing much from that produced by the naked bone. At the posterior extremities of the inferior turbinated bones are the orifices of the Eustachian tubes placed obliquely, and large enough to admit the end of the little finger. It is not difficult to reach them with an instrument gently curved, introduced through the inferior meatus of the nose. They are here partly membranous and partly cartilaginous, running upwards and outwards to the bony canal leading to the cavity of the tympanum.



The SCHNEIDERIAN membrane is spread over all the bones composing the nostril, and by its thickness diminishes the foramina leading into the sinuses. Under the anterior part of the middle spongy bone is an orifice which leads through the æthmoidal cells into the frontal sinus. At the middle part of the middle meatus, or that between the lower and middle spongy bones, is the opening into the Antrum Highmorianum capable of giving entrance to a common quill. In the meatus formed posteriorly in the æthmoid bone, under the cornet of Morgagni, are the orifices of the posterior æthmoidal cells; at the back part of this cornet, and a little above it, is the orifice of the Sphenoidal Sinus. Immediately under the fore part of the inferior spongy bone is the orifice of the Ductus ad Nasum. This membrane is laid smoothly on the septum of the nose.

The Schneiderian or mucous membrane, when well injected, shows great vascularity; its reflections into the sinuses are not, however, so thick or vascular as the other parts of it. The surface which looks towards the cavity of the nose is villous like velvet, and is studded with many mucous follicles which pass obliquely into it, some of them being arranged in rows. It adheres closely to the bones, and that surface in the compactness of its texture resembles periosteum.

Its nerves are derived from three sources.

1. The OLFACTORY, or Nerves of Smelling. They pass on each side of the crista galli, in two rows, perfo-



rating the cribriform plate, and taking a coat of dura matter which renders them strong and fibrous. One row is spread on the membrane covering the upper part of the æthmoid bone, and descends as low as the inferior edge of the middle spongy bone; the other is distributed to the membrane of the nasal septum and its fibres descend somewhat lower. The fibrillæ of these nerves terminate on the mucous surface of the membrane.

2. The SPHENO-PALATINE NERVE comes from the Spheno-Palatine Ganglion through the spheno-palatine hole, and gives fibres to the septum and lateral parts of the nose. One of the former dips into the anterior palatine hole, joins with its fellow from the other side, and forms a ganglion near the roof of the mouth.

3. The NASAL NERVE of the First Branch of the Fifth Pair, passing through the anterior æthmoidal foramen into the cranium, dips down at the side of the crista galli into the nose, and may be traced along the nasal bone to the tip of the nose.

The nose is supplied principally with Blood from the internal maxillary artery and from the æthmoidal branches of the ophthalmic. Its veins accompany the arteries.



## SECTION VI.

*Mouth.*

THE cavity of the mouth is chiefly formed by the palatine process of the upper maxillary and palate bones, above; by the tongue and the muscles connected with it, below; by the cheeks laterally; by the lips before; and by the soft palate behind.

THE TONGUE has its root at the os hyoides; it is there thin, but broad; its tip and sides, owing to the lining membrane passing a considerable way under them before it is reflected to the organ, are left free. Four pairs of muscles compose its bulk. The Styloglossus, which arises from the anterior part of the styloid process, and is inserted into the side of the tongue near its root, the fibres going to the tip. The Hyoglossus, which arises broad and thin from the cornu, appendix, and body of the os hyoides, and forms a considerable part of the bulk of the tongue on its side. The lingualis, which arises indistinctly from the root of the tongue, on the inner side of the former muscle, and its fibres are to be traced as far as the tip. And lastly, the Genio-Hyoglossus muscle, the most internal of the four, lying in contact with its fellow of the opposite side. It arises from the tubercle on the posterior face of the symphysis of the lower jaw; its



fibres radiate so as to be inserted from the body of the os hyoides to the tip of the tongue. Besides these regular and well defined muscles, there are many fibres which cross the organ in various directions and facilitate much its motion. They are the *superficialis linguæ* forming a thin layer on the upper surface of the tongue; the *Transversales Linguæ* being scattered fasciculi going horizontally, and the *Verticales Linguæ* which are also scattered and go vertically.

The superior surface of the tongue on its anterior two thirds is rough from the presence of a number of eminences on it, called *Papillæ*. At the posterior part are about nine of them, arranged like the letter V, with the point backwards, much larger than the others. They are fixed in pits, and surrounded by a fold of the integuments; from their particular form, they have been called *Papillæ Capitatæ* or *Maximæ*. Distributed over the tongue, and scattered at irregular distances from each other, are the *Papillæ Mediæ*, more numerous than the others, and smaller. A third class of them occupies, by far the greater part of the surface of the tongue, and are called *Papillæ Villosæ*. And a fourth set of them, filling up the intervals left between the others, and being the smallest of any, are called *Papillæ Filiformes*. It is probable that these *Papillæ*, except the first, are essentially connected with the function of taste, as they are abundantly supplied with nerves and blood-vessels, having a peculiar arrangement.



At the posterior part of the tongue is a fold of the membrane covering it, which rises up to join the Epiglottis cartilage; and within this duplicature is a ligamentous bridle serving to keep the Epiglottis cartilage erect; muscular fibres from the base of the tongue form its commencement. On each side of it is a small pouch which occasionally produces some trouble from articles of food lodging in it. A little anterior to this fold is a small blind hole, receiving the central papilla maxima and into which some mucous glands discharge their contents, it is called the foramen Cæcum of Morgagni; and sometimes behind it is another foramen cæcum but without a papilla. Scattered about the root of the tongue we find many mucous glands.

The lining membrane of the mouth, when the cuticle is separated from it by maceration, exhibits a surface covered with fine villi. On the lips and cheeks, under it, are situated many small glandular bodies, called *Glandulæ Labiales*, and *Buccales*. It forms a *frænum* where it is reflected from the upper and lower lips to the centre of the Jaw bones. On the alveolar processes, its texture is more dense, constituting the gums, which closely surround the necks of the teeth. This membrane is also united to the lower side of the tongue by a *frænum*, on each side of which we see the orifices of the ducts of the sub-maxillary glands. Under the tongue, at its side, and projecting into the cavity of the mouth, but covered by the lining membrane, is the Sublingual Gland, opening by fifteen or



twenty distinct orifices. On the cheeks, opposite the interstice of the second and third molar teeth of the upper jaw, is found the orifice of the duct of the Parotid Gland.

The lining membrane of the roof of the mouth, is of a dense structure, having a ridge in it just under the middle palate suture, and on each side of that, transverse ridges extending towards the alveolar processes. It adheres very closely to the bone, and beneath are to be found many mucous glands of various sizes, having their excretory ducts terminating on the surface of the palate.

### *Of the Fauces.*

At the posterior part of the mouth may be seen very distinctly, by depressing the lower jaw, an incomplete partition which divides it from the pharynx. It is the Velum Pendulum Palati, formed by the lining membrane of the mouth reflected over several muscles. In the centre is a projection termed Uvula. On each side of the uvula the soft palate has its inferior margin terminating in two crescentic ridges called its lateral half arches. The anterior half arch is rather more distinct than the posterior, and arising from the side of the uvula, runs around to be inserted into the side of the basis of the tongue. The posterior half arch, arising from the side of the uvula near the anterior, runs back-



wards and outwards, and is lost insensibly about the middle of the pharynx. Between the half arches, on each side, is placed the Tonsil Gland, the surface of which is commonly so reticulated, that it might readily be mistaken for ulceration. The space between the lateral half arches is the Fauces, and the anterior opening into it, is the Isthmus of the Fauces.

By dissecting off the membrane of the soft palate which is continued from the mouth, several mucous glands are brought into view lying immediately under it, and also the muscular structure, which is as follows:

1. In the anterior half arch is the **CONSTRUCTOR ISTHMI FAUCIUM**, which arises from the middle of the soft palate near the root of the uvula, and is inserted into the side of the tongue near its root in a line with the papillæ maximæ. It tends to close the opening from the mouth into the pharynx.

2. In the posterior half arch is the **PALATO-PHARYNGEUS**. It arises from the middle of the soft palate behind, near the root of the uvula, and is inserted in the pharynx between the middle and lower constrictors and into the superior posterior margin of the Thyroid Cartilage. It draws the velum palati downwards.

3. **CIRCUMFLEXUS** or **Tensor Palati**, arises from the spinous process of the sphenoid bone behind the fora-



men ovale, and from the contiguous part of the Eustachian tube, it passes in contact with the pterygoideus internus muscle, and terminates in a broad tendon below, which winds around the hook of the internal pterygoid process, and is inserted into the soft palate near its middle, and into the posterior lunated edge of the palate bone. It spreads the palate.

4. *LEVATOR PALATI*, arises from the point of the petrous bone and contiguous part of the Eustachian tube; it is on the inner side of the former muscle, and passes downwards to be inserted into the soft palate. It draws the soft palate upwards.

5. The *AZYGOS UVULÆ* arises from the posterior termination of the palate suture, runs through the centre of the soft palate, and ends in the point of the uvula. It draws the uvula upwards and diminishes the vertical breadth of the soft palate.



## SECTION VII.

### *Of the Pharynx and Œsophagus.*

THE PHARYNX is a large membranous cavity placed at the posterior part of the nose and of the mouth for



opening an external communication with the cavities of the thorax and abdomen. It lies before the cervical vertebræ, being connected to them by cellular membrane, is closely attached to the basis of the skull before the foramen magnum, to the posterior margin of the upper and under jaws, to the back parts of the os hyoides and of the thyroid and cricoid cartilage, and below it contracts so as to be continuous with the œsophagus. In consequence of these several attachments it constantly remains a patulous unoccupied cavity, having a free communication with the nostrils and Eustachian tubes above, with the mouth just below them, with the larynx still lower down, and with the œsophagus at its bottom. The lining membrane which is expanded over it, is continuous with the lining membrane of these several cavities.

To get a good view of the pharynx, the head ought to be cut off at the root of the neck and all the cervical vertebræ be removed; the cavity being then stuffed with baked hair, we proceed to the dissection of the muscles which form it, of which there are three pairs.

1. **CONSTRUCTOR PHARYNGIS INFERIOR**, arises from the side of the cricoid and of the thyroid cartilage; it unites with its fellow in a white line in the centre of the posterior part of the pharynx. Its superior fibres are very oblique, covering the lower edge of the next



muscle, and its inferior fibres are more transverse, being connected with the œsophagus.

2. **CONSTRUCTOR PHARYNGIS MEDIUS**, arises from the appendix and cornu of the os hyoides, and from the round ligament, connecting the latter with the cornu of the thyroid cartilage. It is inserted, in the same way as the foregoing, into its fellow and into the cuneiform process of the os occipitis just before the foramen magnum.

3. **CONSTRUCTOR PHARYNGIS SUPERIOR**, arises from the pterygoid process of the sphenoid bone, and from the upper and under jaw bones behind the last molar teeth being connected with the buccinator muscle. It is inserted into its fellow by a white line in the middle of the pharynx and the upper end of which adheres to the cuneiform process of the os occipitis; it has its lower edge concealed by the preceding.

These muscles all assist in conveying the food from the mouth into the œsophagus.

The pharynx, after the dissection of these muscles, may be cut open vertically at its back part, when a very satisfactory view of all the cavities connected with it will be obtained.



*The Œsophagus.*

This is a tube leading from the pharynx to the stomach, it is placed between the trachea and cervical vertebræ above, passes into the thorax between the laminæ of the mediastinum and in contact with the dorsal vertebræ, penetrates through the left foramen of the diaphragm and terminates in the cardiac orifice of the stomach. (See posterior mediastinum).

The Œsophagus is formed of three coats, the muscular, the nervous, and the mucous. When distended it is cylindrical, but larger below than above. The muscular coat is very strong, consisting of two planes of fibres, the external being longitudinal and the internal circular. The nervous coat connects together the other two; it is formed of cellular membrane which allows them to move very freely upon each other, and conducts the blood-vessels through their structure. The mucous coat is a continuation of that of the pharynx, it is covered by a very delicate cuticle, which is continued into the stomach, and forms in some animals an abrupt and well marked termination just at the cardiac orifice. The internal coat of the œsophagus is most frequently found in longitudinal folds, which are removed by its distension; it abounds with mucous follicles, and is well furnished with blood-vessels.



## SECTION VIII.

*Of the Larynx.*

By the term Larynx is understood the irregular cartilaginous tube which forms the upper termination of the windpipe. The basis of the structure is made by five distinct cartilages; and a crooked bone the os hyoides, which is intermediate to the larynx and the tongue, serving the purposes of both.

The Os HYOIDES resembles much the letter U, divisible into its basis or curved part and its cornua, or lateral projections. It is parallel with the lower jaw and about half an inch below it. It acts as a root to the tongue; as two arms in holding out the bag-like orifice of the Pharynx; and from it, is suspended the Larynx. The base of the os hyoides is broad and convex anteriorly, above it is flattened on each side by the insertion of muscles from the lower jaw, and at its posterior part it is excavated sufficiently to receive the tip of the little finger. At the ends of the base the two cornua arise, separated from it by cartilage and therefore moveable; they are about an inch long, are somewhat flattened, and have a tuberculated termination behind. On the cartilaginous interval of each side, is placed a bony body about the size of a grain of wheat, the Appendicula, which stands up obliquely towards



the styloid process, and is connected to its tip by a round ligament resembling a nerve; this ligament in some cases has been found ossified in the greater part of its length. The five cartilages of the Larynx are the Thyroid, Cricoid, two Arytenoid, and the Epiglottis.

The **THYROID CARTILAGE**, (*Cartilago Thyroidea*,) is about an inch below the *os hyoides*, and forms a very striking prominence in the male neck. It consists of flat sides which are symmetrical, and united to each other by an angle slightly acute at its anterior part; the upper place of union forms the projection called *Pomum Adami*. The sides of this body lean over somewhat, by which its transverse diameter above is somewhat larger than that below. The upper edge is notched in front and terminates behind by a long process on each side, the *Cornu Majus*, which looks towards the end of the cornu of the *os hyoides* and is connected to it by a round cord the posterior thyrohyoid ligament. The inferior edge is somewhat incurvated, and terminates behind by a short process on each side, the inferior cornu, or *Cornu Minus*, by which it is fastened by the posterior crico-thyroid ligament to the side of the cricoid cartilage and establishes a centre of motion between the two.

The **CRICOID CARTILAGE**, (*Cart. Cricoides*;) is an oval ring of unequal breadth and thickness placed im-



mediately below the thyroid cartilage. Its lower margin is horizontal and affixed to the first ring of the trachea; the upper margin is very oblique, rising from before backwards, till the breadth behind is three times as great as that before. In front the cricoid cartilage is thin, behind it is thick. On the upper edge behind, on each side, a little head or convexity is formed for establishing a sort of ball and socket joint with the arytenoid cartilage. The interior surface is flat, the exterior is marked by the muscles which lie on it.

The ARYTENOID CARTILAGES, (Cart. Arytænoideæ, Triquetraë,) two in number, one on each side of the upper back part of the cricoid, resemble each a triangular pyramid curved backwards and having an excavated base. The internal sides of the two are flat, face each other, and by the action of their muscles may be brought together; when thus joined they resemble the spout of a pitcher. In front they are excavated somewhat irregularly. On the top of each is a little cartilaginous tubercle about the size of a grain of wheat, (Corniculum Laryngis,) which is included in the soft parts and is extremely moveable. There is a regular articular cavity between the cricoid and arytenoid cartilages.

The EPIGLOTTIS CARTILAGE, (Epiglottis,) is an oval disk with an elongated pedicle below, its upper edge being thin and rounded. It is fixed behind the base



of the os hyoides and has its pedicle connected to the entering angle on the posterior face of the thyroid cartilage. The broad surfaces of this cartilage present forwards and backwards, and are above the level of the arytenoids; from this position of the epiglottis it is said to be placed as a valve over the opening of the larynx; its valvular office, however, I have great cause to disbelieve. It is very elastic, having a fibro-cartilaginous structure, and is perforated with many foramina giving it a cribriform appearance.

The upper edge of the Thyroid Cartilage is connected to the internal edge of the Os Hyoides, by a thin and somewhat elastic membrane *the middle thyro-hyoid ligament*, which fills up the whole of this interval, and completes the front and lateral parietes of the Larynx. Between this membrane and the cavity in the base of the Os Hyoides, is a small sac, very rarely mentioned by anatomists, and considered by such as speak of it, as a Bursa Mucosa. It has no connexion with any other cavity, and is occasionally the seat of disease.

Between the Epiglottis and the Thyroid Cartilage, and on the posterior face of the Thyro-hyoid ligament, is a quantity of loose fatty matter intermixed with small mucous glands; the perforations in the Epiglottis are supposed to conduct the excretory tubes of the latter into the Larynx.

Between the Thyroid and Cricoid cartilages, in



front, there is a ligamentous membrane which fills up this interval; it is the middle Crico-thyroid ligament, and in Laryngotomy, is indicated as the proper place for the operation.

From the anterior part of the base of each Arytenoid cartilage, a ligament passes horizontally to the entering angle of the Thyroid. These ligaments are not parallel, but converge from the Arytenoid cartilages, and are very near each other in front. At the distance of three lines above these, are two other ligaments passing also horizontally from the Arytenoids to the thyroid cartilage; they are more parallel, but have not their ligamentous character so well defined.

There are several pairs of muscles belonging to the Larynx.

1. The **CRICO-THYROIDEUS**, arises tendinous and fleshy from the anterior lateral surface of the cricoid cartilage, and passes upwards and backwards, to be inserted into the inferior cornu of the thyroid cartilage, and the adjacent part of its inferior edge. Use, to draw these cartilages obliquely together.

2. The **THYREO-HYOIDEUS**, which is described in the account of the neck.

3. The **CRICO-ARYTENOIDEUS POSTICUS**, arises from



the back of the cricoid cartilage, occupying its excavation, and is inserted into the posterior part of the base of the arytenoid cartilage. Use, to draw the arytenoid backwards, and make the ligaments tense.

4. The **CRICO-ARYTENOIDEUS LATERALIS**, arises from the side of the cricoid cartilage, and is inserted into the side of the base of the arytenoid. Use, to draw this cartilage outwards, and open the chink of the glottis.

5. The **THYREO-ARYTENOIDEUS**, arises from the posterior face of the thyroid cartilage, and the ligament connecting it with the cricoid, and is inserted into the anterior edge of the arytenoid cartilage. Use, to relax the ligaments of the glottis.

6. The **ARYTENOIDEUS OBLIQUUS**, arises from the base of one arytenoid cartilage, and is inserted into the tip of the other. It is a very small fasciculus, and sometimes only one muscle exists. Use, to close the chink of the glottis.

7. The **ARYTENOIDEUS TRANSVERSUS**, arises posteriorly from the whole length of one arytenoid cartilage, excepting a little part of the tip, and is inserted in a corresponding manner, into the other. Use, to close the chink of the glottis.



8. The **THYREO-EPIGLOTTIDEUS**, arises by a few fibres, from the posterior face of the thyroid cartilage near its entering angle, and is inserted into the side of the Epiglottis. Use, to draw the Epiglottis downwards.

9. The **ARYTENO-EPIGLOTTIDEUS**, arises by a few indistinct fibres, from the superior lateral parts of the arytenoid cartilage, and is inserted into the side of the Epiglottis. Use, to draw the Epiglottis downwards.

These two last muscles are frequently so small and undefined, that they cannot be satisfactorily distinguished from the adjacent soft parts.

The cavity of the Larynx is lined by a continuation of the mucous membrane of the Pharynx. This membrane, where it establishes the upper boundary of the Laryngeal cavity, forms a fold on each side, extending from the Epiglottis to the Arytenoid Cartilage; it then sinks into the cavity beneath. In extending from the upper to the lower ligament of the glottis, on each side, it forms a pouch between them, called the ventricle of Galen or Morgagni. From the lower ligament this membrane passes to line the Cricoid Cartilage, and thence into the trachea.

The fissure between the two lower ligaments, is the Rima Glottidis; and the cavity above the upper ligaments is the Glottis.

For an account of the Trachea, see the article  
**THORAX.**



## PART II.

### OF THE TRUNK.

---

#### CHAPTER I.

##### OF THE THORAX.

THE dissection of the cavity of the Thorax should be preceded by that of the muscles which lie upon its front part and sides.



##### SECTION I.

###### *Of the Muscles.*

1. THE PECTORALIS MAJOR is the most superficial, and forms the large swelling cushion of flesh under the skin of the breast. It arises tendinous from the anterior face of the two upper bones of the sternum their



whole length, fleshy from the cartilages of the fifth and sixth ribs, and by a fleshy slip from the upper part of the tendon of the external oblique muscle. It arises also fleshy from the interior two-thirds of the clavicle. The clavicular and sternal portions of the origin are separated by an interval, giving the appearance of two muscles.

The fibres converge and terminate by a broad, thin tendon, which is inserted into a roughness on the exterior edge of the fossa of the os humeri for the biceps tendon, and into the bracial fascia. The under edge of the muscle, near its insertion, is folded inwards, which gives the rounded thick margin to the fore part of the axilla. That part of the broad tendon belonging to the clavicular portion of the muscle is inserted lower down than the sternal, which produces a decussation of the fibres of the tendon.

The Pectoralis Major moves the arm upwards and inwards.

2. The PECTORALIS MINOR is brought into view by raising the last muscle. It is comparatively small and somewhat triangular, arising by thin tendinous digitations from the upper edges of the third, fourth, and fifth ribs. It soon becomes fleshy, and is inserted, by a short flat tendon, into the inner face of the coracoid process of the scapula. Its use is to draw the scapula inwards and downwards.



3. The **SUBCLAVIUS** is a small muscle placed immediately under the clavicle. It arises from the cartilage of the first rib, and is inserted into the inferior face of the clavicle from near the sternum to the conoid ligament, which connects the coracoid process and the clavicle together. It draws the clavicle downwards.

4. The **SERRATUS MAJOR ANTICUS** is a broad muscle lying on the sides of the ribs, between them and the scapula, and arising from a line anterior to their middle. In well defined bones the precise points of origin are readily seen. It arises from the nine upper ribs by fleshy digitations, the superior one of which seems almost like a distinct muscle, the five lower are connected to the obliquus externus abdominis, the digitations of the two muscles interlocking with each other.

The fibres converge, and are inserted into the base of the scapula its whole length. Its action is to draw the scapula forwards.

5. The **INTERCOSTALS** fill up the spaces between the ribs. There are two in each space. The External arises from the spine, and from the inferior acute edge of each rib almost to its cartilage, and is inserted into the superior rounded edge of the rib below for the same distance, its fibres passing obliquely forwards. The internal Intercostal, arises from the inferior edge of the rib, beginning at the sternum, and going backwards to the angle of the rib, it is inserted into the



superior rounded edge of the rib below on its inner side, its fibres passing obliquely backwards. They draw the ribs together.

With a view to examine the cavity of the thorax, the sternum along with the cartilages of the ribs, is to be taken out. We then see, on their posterior faces, a muscle called

6. **TRIANGULARIS STERNI**, which arises from the whole length of the cartilago ensiformis at its edge, and from the inferior half of the edge of the second bone of the sternum. The fibres go obliquely upwards and outwards to be inserted into the cartilages of the third, fourth, fifth and sixth ribs by fleshy and tendinous digitations. Its use is to depress the ribs, and consequently to diminish the cavity of the thorax.



## SECTION II.

### *Viscera of the Thorax.*

THE most usual manner of getting into the cavity of the Thorax is that just mentioned; but there is a much better one introduced here, by the late Professor WISTAR, in which the five middle true ribs on each side are removed, all the rest with the sternum being left.



This plan gives an excellent view of the several viscera, and also of their relative situation and extent; and is such as I would recommend the student to adopt, in at least one dissection. The principal objection to it is, that it renders the upper parts of the trunk unfit for farther investigation, inasmuch as the superior extremities must be removed in the first place. If the muscles connecting the upper extremities to the trunk, on its fore and back parts, should have been previously dissected, this objection is no longer valid.

Approaching the cavity of the thorax, by either of the methods mentioned, we see at once its most striking contents, viz. the Heart and Lungs, each covered by an appropriate membrane. The heart is between the sternum and the dorsal vertebræ; the lungs are on each side of it and when in a healthy state, always collapse upon the thorax being opened.

### *The Pleuræ.*

Each of the two lungs has an appropriate membrane called Pleura, which covers its external surface; and giving it a glistening smooth appearance, is reflected from the internal face of the lung over the side of the pericardium to the sternum before, and to the spine behind. This membrane also lines the ribs, intercostal muscles and diaphragm, of that side of the thorax to which it belongs. Above, it passes up as high as the



head of the first rib, and below, it goes as low down as the last rib. That part of the pleura which covers the lung, is the *Pleura Pulmonalis*, and that which lines the ribs, the *Pleura Costalis*.

As the pleuræ are bags, one on each side of the thorax, it is very demonstrable that the opposing faces of them form a septum, which extends from the sternum in front to the spine behind, and from the upper part of the thorax to the diaphragm. This septum is the *Mediastinum*; and the heart is placed in its middle. The portion of the septum between the heart and sternum is the *Anterior Mediastinum*; between the heart and spine is the *Posterior Mediastinum*; and between the heart and the upper part of the thorax, is the *Superior Mediastinum*; each of which merits strict attention.

It is obvious then, that the septum consists of two laminæ, one from each pleura. These two laminæ are somewhat separated, where they are called *Anterior Mediastinum*, by the remains of the thymus gland above, and by adipose and cellular membrane below. The anterior mediastinum is attached to the middle of the sternum, except at its lower part, where it inclines somewhat to the left side. To get a good view of its contents, the sternum must be sawed through longitudinally, and the two halves separated an inch by a small block of wood. The contents of the posterior mediastinum and of the superior, are best seen and understood at a subsequent stage of the dissection.



The Pleura is a thin and transparent membrane connected to the parts on which it lies by a short cellular substance. No red vessels, in its healthy state, are to be observed. In the young subject, it is free from adeps; but in advanced life, attended with corpulency, considerable masses of fat are found in the anterior mediastinum, and between it and the pericardium. The exhalent vessels of the pleura are derived from the intercostal, internal mammary, phrenic, and some other arteries, and secrete a fluid which lubricates its surface.

### *The Pericardium.*

Between the pleuræ, and under the sternum, is the Pericardium, containing the heart. It is a white, semi-transparent membrane, of a condensed fibrous structure internally, and possessed of little or no elasticity, which renders it highly appropriate for sustaining the action of the heart in its dilatation.

It is lined by a serous lamina which forms a complete bag in being reflected over the surface of the heart, so as to give it an investing membrane. This investment commences at the back part or base of the heart, and is continued over the whole of it, being extended on the aorta to the branches which arise from the top of its curvature; on the pulmonary artery to its bifurcation; on the pulmonary veins to their first branches; on the ascending cava to the diaphragm;



and on the descending cava to the middle of the space between the entrance of the Vena Azygos and the Transverse Vein. The exterior lamina has not these reflections, it is only united to the several parts where the reflections commence.

An analogy is observable in this arrangement with the membranes of the joints; the exterior lamina of the pericardium corresponds with the capsular ligament, and the internal lamina with the synovial membrane. It is the exterior membrane which supports the heart, and the interior which furnishes the lubricating fluid, found in general in the pericardium, to the amount of a drachm. The fore part of the pericardium lies loosely on the heart. The pericardium is attached strongly, by all its inferior surface, to the tendon of the diaphragm.

### *The Heart.*

The Heart is a hollow muscle consisting of four cavities, two auricles, and two ventricles. Its shape is somewhat conical, but flattened on the under surface. The base of the cone is formed by the auricles, the body by the ventricles, and the apex by the point of the left ventricle projecting beyond that of the other. The heart being fixed as mentioned between the sternum and the dorsal vertebræ, has its base turned obliquely towards the right side, while its apex is about the junc-



tion of the fifth left rib with its cartilage. Its flat part reposes on the flat tendon in the centre of the diaphragm, also is on a horizontal line, or nearly so, with the inferior end of the second bone of the sternum. The heart, in consequence of being tied down to the diaphragm by the pericardium, is, excepting its pulsations, exposed to but little motion, and is therefore almost uniformly in the same position. It has, between the internal membrane of the pericardium and its own substance, more particularly along the course of the coronary vessels, adipose matter in great abundance in old subjects, and this adipose matter sometimes penetrates so deeply between the fasciculi of its fibres as to give them a very loose texture, and apparently to disqualify them in some measure from performing their functions.

The parietes of the heart are formed principally of muscular fibres, which are variously arranged; some pass spirally around it, others in an irregular and indeterminate manner, but all in such a direction as to concur, by contracting, in effacing its cavities. The cavities are lined by a fine membrane which is a continuation of, and resembles the internal coat of the arteries and veins. Between the auricles and ventricles, and at the orifices of the great arteries, this membrane is raised up and reflected so as to constitute valves.

The heart is divided into Right and Left sides, each consisting of an auricle and of a ventricle. The Right



Auricle receives the two great trunks of the Venous System, to wit, the ascending and the descending Vena Cava. The Left Auricle receives the pulmonary veins. The Right Ventricle sends off the Pulmonary Artery, and the Left Ventricle the Aorta.

The Right Auricle, situated at the right posterior part of the heart, is an oblong cavity about a line in thickness. To view its internal arrangement it should be slit open in front from cava to cava, we shall then see that its posterior surface is smooth and is formed by a continuation of the structure of the great veins which meet each other at an obtuse angle, and form a projection into the auricles. This last circumstance, connected with a slight thickening of the part, has given occasion to the name *Tuberculum Loweri*. Anteriorly the auricle is swelled into a pouch, (*Sinus Venosus*) in which the muscular fibres, instead of being uniformly spread into a coat, are collected into transverse fasciculi lying parallel to and near each other; they are called *Musculi Pectinati*. At the upper part of the pouch or sinus is the proper auricular portion of the cavity, whence it got its name; it is not marked by any striking peculiarity except that the *musculi pectinati* prevail in it. The auricles have a common septum, and on it, just below the *tuberculum Loweri*, is situated the *Fossa Ovalis*, which in the foetal state was an opening between the auricles, and indeed at the upper part of this depression we often find a fora-



men large enough to admit a probe into the left auricle even in subjects advanced into old age. The edges of the fossa ovalis, are elevated and thickened, being the Columnæ or Annulus Fossæ Ovalis.

Beneath the fossa ovalis is the Eustachian valve. It is formed by a duplicature of the lining membrane of the auricle and of the ascending cava, being spread somewhat obliquely across the orifice of the latter. It is of a crescentic shape, about half an inch wide, but occasionally reticulated, and commences at the left side of the annulus ovalis; it terminates anteriorly about the junction of the auricle and the vein. It is connected by its convex edge to the parietes of the auricle, and its concave or floating edge looks somewhat upwards. Just before and below the Eustachian valve is another much smaller, but also semilunated, the Valve of Thebesius, which covers the orifice of the great coronary vein.

At the left side of the right auricle is an opening of more than an inch in diameter, the Ostium Venosum, through which it communicates with the right ventricle.

In the right auricle are many small orifices of coronary veins called Foramina Thebesii; they also exist in all the other cavities, but are not so numerous there. They are said to be particularly conspicuous in cases of diseased lungs.

The next cavity to be examined is the Right Ventri-



cle; to expose it satisfactorily it should be divided extensively along the septum ventriculorum superiorly and inferiorly. It is of a triangular form, and its sides are much thicker than the sides of the auricle, as they measure, most commonly, about three lines. Its internal surface is very irregular and rough, the muscular structure of it being thrown into projecting columns the Columnæ Carneæ of very indeterminate figures, arrangement and dimensions. Some of them jut out and are connected to the valve at the ostium venosum by the Chordæ Tendineæ; others pass from one side of the ventricle to the other, and a third series presents a reticulated appearance, lying on the face of the ventricle and connected with it. Their general object is to strengthen the ventricle, to enable it to expel its contents and to agitate well and mix the blood.

The Ostium Venosum has a tendinous margin, from which is reflected the lining membrane of the ventricle, so as to form a broad fold surrounding it. This fold being eight or ten lines wide, is irregularly divided at its floating edge, into three parts, whence the name of Tricuspid Valve has been given to it. The tricuspid valve, is situated in the ventricle, has its loose margin attached to the round tendinous chords just mentioned, called the Chordæ Tendineæ, which again arise from the Columnæ Carneæ. These tendinous attachments of the tricuspid valve prevent it from being thrown into the auricle when the ventricle contracts.

At the upper part of the ventricle is the orifice of



the pulmonary artery, which conveys the blood to the lungs; provision for it is made by the upper part of the ventricle becoming smooth. The orifice of the artery is round, and about twelve lines in diameter. From the internal surface of the artery, a little beyond its orifice, three valves arise called Semilunar, which may be compared, each to a semicircular plane, connected by its circumference, to a cylindrical cavity. The diameter of the plane is loose; in the centre of it, is a small cartilaginous body, the *Corpusculum Aurantii*; and on each side of the corpusculum, the diameter of the valve, instead of being a straight line, is slightly festooned. The valve is almost diaphanous, and seems to be produced by a reflection of the lining membrane of the artery. Between the coats of this reflection is, however, to be found another substance very much like that of the artery, which also forms a festooned edge a little below the one just described. As the three valves are placed in a row surrounding the artery, in its action they are thrown down, forming thereby a complete septum against the return of the blood into the ventricle; and the *Corpuscula Aurantii* being in the middle of each form a point of support or abutment at which the edges of the valves sustain each other. Between the outer face of the valve and the internal face of the artery, a pocket attended with a dilatation of the artery is formed, called the *Sinus of Valsalva*.



The PULMONARY ARTERY is a large white fibrous tube given off in the manner mentioned; under the arch of the aorta, it divides into two branches, right and left, which go to the lungs of their respective sides. The right branch is the larger of the two, and passing under the arch, is then minutely distributed to its lung. The left is in front of the descending aorta, and is distributed to the left lung with equal minuteness.

The blood is brought from the lungs by the pulmonary veins, which are four in number, two on each side. The branches constituting the trunk of each of these veins, are generally united before the trunk penetrates the pericardium. This trunk afterwards unites to the auricle at one of its corners.

The Left Auricle has about the same cubic capacity with the right, but differs from it somewhat in its figure, by being more square. Its broad internal surface looks towards the spine. It is fixed to the posterior part of the left ventricle, and is divided like the right auricle, into the Sinus Venosus, sometimes called Sinus Pulmonalis, and into Proper Auricle. The latter is situated at the left side of the pulmonary artery, and is somewhat longer, narrower, more crooked, and more notched at its margins than the other proper auricle. When the left auricle is cut open, which should be done by a slit down its middle, it will be perceived that



its parietes are thicker than those of the right, and that both externally and internally, its surfaces are perfectly smooth, except in the proper auricular part, where the *Musculi Pectinati* prevail.

The Septum between the auricles, viewed on this side, is smooth, not presenting any remarkable appearance; when held up to the light, it is seen to be thinner and more transparent at the place corresponding with the fossa ovalis of the other side. At the anterior and inferior side of the auricle is the ostium venosum, communicating with the left ventricle; it has a tendinous margin, and is rather more than an inch in diameter.

The left Ventricle differs from the right in shape, by being more conical, but it is equally capacious. Its anterior part constitutes the apex of the heart, and strikes against the ribs. The best mode of examining its cavity is to make an incision through its parietes near the septum, and to separate it completely on that side from its fellow. Another incision should be made so as to detach it from the auricle, also, near their septum. The latter cut is to be executed with particular care, so as to avoid wounding the interior structure. That done, we see its general arrangement within, corresponding with the right ventricle. Its parietes are eight lines thick, being about three times as thick as the other. Its *columnæ carneæ*



are larger and stronger, but arranged on the same principle, some passing from side to side of the cavity, others being reticulated and easily raised up from the part of the ventricle on which they lie, and a third set aiding the valvular apparatus at the ostium venosum.

The Mitral Valve exists at the left ostium venosum, and is formed by a duplicature of the lining membrane of the ventricle. It is partially divided into two parts, which are pointed at their edges. Its columnæ carneæ are numerous and strong, and its chordæ tendineæ are of corresponding characters. The mitral valve prevents the regurgitation of blood into the auricle, and is so placed that the upper half of it, when the blood is rushing into the ventricle, conceals the orifice of the aorta.

Towards the orifice of the aorta, which is at the posterior superior part of the ventricle, the surface of this cavity is smooth to facilitate the passage of blood. The septum between the ventricles is of the same thickness with the left ventricle; it is formed partly by the right ventricle, but principally by the left.

The Mouth of the Aorta is about an inch in diameter, and is furnished with three Semilunar Valves, Corpuscula Aurantii, and Sinuses of Valsalva, after the same manner with the pulmonary artery, so that the description of one will suit the other with the addition that those parts of the aorta are stronger and more developed. The coats of the aorta are nearly



three times as thick as those of the pulmonary artery, to qualify it for bearing the increased pressure of the blood. The aorta is dilated shortly after its commencement so as to form the large Sinus of Valsalva. The aorta lies first at the back of the pulmonary artery, it then gets to its right, being between it and the superior vena cava; part of it is there to the right of the spine, it then makes its arch which brings it to the left of the spine, and in contact with it about the third dorsal vertebra. The superior part of its arch is about eight lines below the upper edge of the sternum.

The heart being a mere machine for propelling blood, requires another source for its nourishment besides the fluid circulating through its great cavities; this is furnished by the Coronary Arteries, which are two in number. The first, called Right Coronary, becomes visible between the pulmonary artery and the right auricle, and passing on the septum between the right auricle and ventricle, extends around the heart to its flat side, distributing to the contiguous parts branches which, for the most part, pass off at right angles. The second, or Left Coronary Artery appears between the pulmonary artery and the left auricle; before it has become very obvious, it divides into two branches, one passes on the septum ventriculorum to the apex of the heart; the other winds on the septum between the left auricle and the left ventricle, and



some of its branches pass on the flat surface of the heart to its apex.

The Coronary Veins receive the blood of the coronary arteries; a common trunk is formed by them, which passes for some distance on the septum, between the left auricle and ventricle, and then opens into the right auricle just anterior to the Eustachian Valve, at the spot already indicated.

### *Of the Lungs.*

The Lungs are of a bluish colour, and occupy by far the greater part of the cavity of the thorax; they are two distinct bodies placed one at either side of the heart, from which circumstance they are called right and left Lung. Their external shape and dimensions with an inconsiderable exception, are the same, as they correspond in their periphery with the symmetrical sides of the thorax. The apex of the heart, from being pushed into the lung of the left side, gives its surface towards the mediastinum, a somewhat different figure from the lung of the right side; the left lung is also the smaller.

To appreciate the extent and form of the lung, it must be recollected that the cavity of the thorax is much deeper behind than it is before. The vertical diameter before, amounts only to the length of the two upper bones of the sternum, whereas the same diame-



ter behind, is the whole length of the column formed by the dorsal vertebræ. The figure of each lung is also modified by the convexity of the Diaphragm; for this body, extending from the lower point of the dorsal vertebræ obliquely upwards to the end of the second bone of the sternum, would, if it were only a plain surface, influence the contiguous faces of the lungs so as to make them resemble, when united, the inferior part of an ox's hoof; but this resemblance is much increased by the diaphragm forming a convexity towards the thorax, which rises much above what its plane would. The similitude of the lungs to the ox's hoof, with the back part foremost, is therefore sufficiently exact for anatomical comparison, and particularly as it regards their inferior surface.

The lung lies loose every where, except at the surface corresponding to the side of the basis of the heart; here it is attached to the heart by the pulmonary veins, pulmonary artery, and by a branch of the trachea. These tubes constitute the Root of the Lung, and over the root is reflected the pleura, from the pericardium. The pleura which covers the root of the lung is extended downwards, under the name of *Ligamentum Pulmonis*, and serves to fix the posterior edge of the lung to the pericardium, as low down as the diaphragm.

The right lung is divided by an oblique and a horizontal fissure passing from it, into three lobes—the



left lung has a single oblique fissure dividing it into two lobes. Each lobe consists of a multitude of lobules adhering laterally by cellular substance: and each lobule is formed of a congeries of air vesicles, which communicate freely through their sides from the imperfection of the latter. Though the cells of different lobules do not communicate in that direct way.

The parietes of the air vesicles are of extreme tenuity and have the pulmonary artery and vein ramifying with exceeding minuteness on them for the purpose of respiration.

The lung of the bullock exhibits the structure better than that of the human lung, by a little tearing of the parts asunder. The lobuli are also well seen in the foetus, and in very young subjects.

The Trachea, the bifurcation of which forms the Bronchiæ is a tube almost cylindrical, which passes in front of the œsophagus and of the vertebræ, from the inferior part of the larynx to the third dorsal vertebra; it there divides into the Bronchiæ, and is placed between the pleuræ of the two sides of the thorax. The right Bronchia is shorter, larger, and less slanting than the left; it sinks below the pulmonary artery, and penetrates the lung opposite to the fourth dorsal vertebra; the left being long and narrow, enters the lung below the pulmonary artery, opposite to the fifth dorsal vertebra. The bronchiæ then divide and subdivide



through the structure of the lung, till the ultimate extremities terminate in the air vesicles.

The trachea preserves its cylindrical shape, and is kept open by a cartilaginous structure, which is composed of from sixteen to twenty pieces, more or less distinct from each other. Thus arranged, the cartilages form about two thirds of the circumference of a circle, occupying the front of the trachea, and giving it the appearance, anteriorly, of a cartilaginous tube. The remaining third is membranous. The cartilages of the trachea are deposited in a kind of perichondrium, possessed of extreme elasticity, which has continually a tendency to approximate the cartilages, and is resisted only by the attachments of the two extremities of the trachea. The effect of this elasticity is demonstrated in the living body by attempts at suicide, where the trachea being cut through, so great a gap is made in the throat, that it presents the appearance of a part having been removed. The deficiency at the back part of the cartilages, is filled up by a condensed cellular substance in continuation with this elastic membrane. Transverse muscular fibres are placed between the extremities of the cartilages, and by their contractions bring them towards each other; according to the opinion of Dr. PHYSICK, by diminishing the size of the trachea they assist in the expulsion of mucus. A continuation of the mucous membrane of the Pharynx and Larynx lines the trachea; it is studded with a great number of follicles which secrete mucus. Under the



membrane are many glands, from the size of a millet-seed to that of the head of a small pin and which have their excretory tubes terminating in the trachea. These glands are also abundant on the posterior face of the transverse muscular fibres.

The Bronchiæ, in dividing, still preserve, for some length, the cartilaginous structure of the trachea, but as they approach their terminations, the deficiency at their back part ceases and the cartilages form sections of circles which produce, by the apposition of several of them, complete cylinders. This arrangement holds till finally the cartilaginous structure ceases, and only membrane is left. It is probable, from the elasticity of the lung and from its collapsing when the thorax is opened, that the elastic membrane, in which the cartilages are deposited, forms the essential cellular structure of this organ on which the blood vessels are ramified.

At the lower end of the trachea, and about the root of the lungs, is found the commencement of a chain of lymphatic glands which follow, for some distance, the bronchiæ. In the adult they are black, numerous, and vary from the dimension of a large pin's head to that of a kidney bean.

The lungs are furnished from the aorta with nutritious vessels, called Bronchial Arteries; they follow the course of the bronchiæ and communicate freely with the pulmonary arteries; notwithstanding the latter they



have their proper veins, which empty on the right side, into the vena azygos, and on the left into the subclavian vein. The bronchial veins also communicate freely with the pulmonary veins.

While studying the contents of the thorax it is of the first importance to attend to the relative situation of the parts included in the description. One of the most useful and interesting points is the space between the two upper ribs, bounded laterally by the pleuræ, anteriorly by the sternum, posteriorly by the upper dorsal vertebræ, and having the top of the pericardium for its basis. This cavity is too irregular to admit of comparison with any thing else without a hazard of communicating false ideas of its shape. The course of the pleura, on each side, must be well attended to, and in order to understand it, the obliquity of the first rib must be taken into consideration. Considering the spine as a vertical column, the first rib, so far from being horizontal, is, in a majority of subjects, inclined downwards so much, that it makes an angle of about forty-five degrees with the spine; and the pleura, being reflected from the internal edge of the first rib from its head to its front part, will, of course, observe a similar obliquity. It is probably this circumstance which Sabatier, Scëmmering, and Colles allude to when they speak of the pleura rising above the level of the first rib. This arrangement should influence the considerations arising from a wound in the lower part of the neck, as a ball or sword passing through horizon-



tally just above the sternal end of the clavicle, would certainly enter the cavity of the pleura in a great number of persons.

In this upper section of the mediastinum, just at the upper edge of the sternum, are the remains of the Thymus Gland, much shrivelled, having a ligamentous feel, and of a light pink colour. In contact with the pleura on the right is the Descending Vena Cava. The common trunk of the left subclavian and internal jugular, (Vena Innominata) after crossing, by an oblique descent, the upper portion of the sternum, joins the descending cava about an inch above the place where the latter penetrates into the pericardium. Behind this transverse vein are the top of the arch of the Aorta, the origin of the Arteria Innominata, the left Carotid, and the left Subclavian Artery. The œsophagus makes a vertical descent just before the dorsal vertebræ, the trachea is placed before it, and we see the arteria innominata crossing the latter obliquely from left to right. The arteria innominata is placed much more superficially than the left subclavian, being removed from the upper end of the sternum only the thickness of the transverse vein, and is very accessible as proved by Dr. MOTT's operation;\* whereas the other, being the last branch given off from the curve of the aorta in its course backwards, is an inch deeper, and inaccessible in the living body. The arteria innominata

\* Eclectic Repertory, Vol. 9, p. 1.



varies much in length before its division into subclavian and carotid; I have examples of it from half an inch to two inches, but the general length is about sixteen lines.

In this dissection the phrenic nerve is seen to descend in contact with the internal edge of the scalenus anticus muscle, and passing between the subclavian artery and vein, to proceed vertically in contact with the pleura at first, and afterwards between it and the pericardium to the diaphragm. The par vagum is on the inner side of the internal jugular vein, and gets into the thorax between the subclavian artery and vein near the origin of the subclavian artery. The trunk of it passes along the side of the trachea, and behind the root of the lungs to the œsophagus and terminates at the stomach. On a level with the subclavian artery, the Recurrent or Inferior Laryngeal Nerve is sent off, which, to get to the larynx, winds around the subclavian of the right, and the aorta on the left side. About the root of the lungs, the Pulmonary Plexus is detached from the Par Vagus nerve. The sympathetic nerve lies closer to the vertebræ, and sends off from its two inferior cervical ganglions principally, the branches which supply the heart, by the cardiac plexus. In the thorax it continues its course by the heads of the ribs, and sending off the greater and lesser Splanchnic nerves is distributed in a manner to be described hereafter.

In making this dissection it must be observed that



from the lower part of the thyroid gland, the condensed membrane called *Fascia Profunda Cervicalis*, which seems to afford protection to the upper opening in the thorax, and is extended to the upper edge of the sternum, has beneath it, connecting the vessels and other parts together, a loose, vascular, adipose, and cellular matter, which must be removed by dissection, before the rest of the structure can be rendered distinct. The plan for opening the thorax, by the sternum being sawed in two longitudinally and kept open to the distance of an inch or so, is by far the most exact and satisfactory manner of studying these parts.

This stage of the dissection having been accomplished, the sternum must be removed, and by turning up the lungs, we see the parts contained in the posterior mediastinum and what is meant by it. To the left is the aorta, which gradually gets to the front of the dorsal vertebræ in the lower part of the thorax, as it penetrates the crura of the diaphragm. The *Œsophagus* is in the middle above, but in getting to its own opening in the diaphragm it crosses the aorta very obliquely and is then to the left of the lower dorsal vertebræ. The *Vena Azygos*, made up of the six lower intercostal veins on the left side and the ten lower of the right, occupies the right side of the mediastinum and forms an arch at its termination where it joins the descending cava, over the root of the right lung. The Thoracic duct enters the thorax between



the crura of the diaphragm, and passes nearly in the middle line between the aorta and the vena azygos, till it reaches the third dorsal vertebra; it then inclines to the left side, and rising into the root of the neck, forms an arch which terminates in the angle produced by the junction of the left internal jugular and subclavian vein. The Par Vagum is strictly within the limits of the posterior mediastinum, the Sympathetic is not.



## PART II.

### CHAPTER II.

#### OF THE ABDOMEN.

BEFORE the commencement of the dissection of the Abdomen, it is useful to acquire a knowledge of its regions, the boundaries of which are thus established by imaginary planes passing through the subject. Draw a line from the superior part of the crista of one Ilium, as it appears through the skin, to the superior part of the other; strike a perpendicular then from the anterior inferior spinous process of the Ilium on each side through the cartilages of the ribs above; then draw a fourth line parallel with the first, through the points where the latter touch the cartilages of the ribs. These four lines, two vertical and two horizontal, which represent as many planes, form with the periphery of the abdomen nine regions. The one, above, on the right, is the Right Hypochondriac, that in the middle, the Epigastric, and that to the left, the Left Hypochondriac. The region which has the navel in its centre is the Umbilical, and on its sides are the Right and the Left Lumbar Region. Below the um-



bilical is the Hypogastric Region, and on the wings of the latter are the Right and the Left Iliac Region.

Some anatomists call the pit around the ensiform cartilage the Scrobiculus Cordis, and a small space just behind, and elevating itself about an inch above the pubis, the Regio Pubis. The boundaries of the latter are rather undefined, but the terms are in use.



## SECTION I.

### *Of the Muscles of the Abdomen.*

To begin the dissection of the muscles of the abdomen, a straight cut must be made through the skin from the end of the second bone of the sternum to the symphysis pubis; another is to cross this at its commencement above, extending obliquely towards the armpit, till it reaches the side of the chest. The second terminates and a third commences there, having a sweep backwards, parallel in its direction with the margin of the cartilages of the ribs, and equidistant from it. The third cut by being extended to the spine affords an opportunity of opening the integuments still further, by a vertical cut over the spinous processes down to the small end of the sacrum. This manner of opening the integuments of the side of the belly, de-



scribes in a great measure the outline of the external oblique muscle, makes it thoroughly accessible in the progress of the dissection, and enables one to see and to display every part of it. One of the greatest obstacles (simple as the circumstance may appear,) to understanding the broad muscles of the abdomen well, is the imperfect manner in which the integuments are opened by dissectors: and there is no dissection more apt to be spoiled, than the one in which we are now engaged, owing to the want of a plan, founded on some previous knowledge of the parts, for commencing operations. Having thus marked off the section of the subject on which to work, begin by dissecting at the upper part to turn the flap downwards. But few strokes of the knife will be made, before the upper fibres of the external oblique muscle will be exposed. The flap is now to be entirely dissected off as far down as the hip and thigh, exposing, by such means, the superior margin of the pelvis, from the spine to the symphysis pubis. The beginner must cut very slowly, seeing that he detaches fully the cellular membrane from the muscular fibres; by cutting in the same direction with the latter, he will leave them clean and brilliant, and the transition to the broad tendon connected with them, will be comparatively easy.

In this dissection, as indeed in all others of the muscles I cannot attach too much importance to cutting parallel with the fibres; it is absolutely essential to the beauty of the display, and indispensable to a person



desirous of success in practical anatomy. A dissection done in any other manner is unfit for study from its obscurity, and offensive to inspect from its roughness. The sum of directions to make a good dissector of muscles, is to cut in the line of the fibres, close to them, and to keep the cellular membrane tense.

There are five pairs of muscles to the abdomen, three broad and two narrow.

1. *MUSCULUS OBLIQUUS EXTERNUS*, arises from the eight inferior ribs by muscular and tendinous digitations attached near their anterior extremities. The first head is covered by a slip from the pectoralis major, the five upper heads are interlocked with the serratus major anticus, and the three inferior with the latissimus dorsi. The fibres pass obliquely downwards, and terminate in a broad thin tendon. This tendon extends over the whole front of the abdomen from the lower end of the second bone of the sternum, to the symphysis of the pubes.

It is inserted into the whole length of the linea alba, and into the anterior half or two thirds of crista of the Ilium, by muscular fibres posteriorly, and tendinous anteriorly. And from the anterior superior spinous process, the tendon stretches to the body of the pubes, forming thereby the ligament of Poupart.

In the middle line of the body, the tendons of the three broad muscles on each side of the abdomen unite



to form the *Linea Alba*, which extends from the sternum to the pubes. From two to three inches in the adult on each side of the *linea alba*, but more distant from it above than below, is another line formed by the same tendons, which is the *Linea Semilunaris*. The navel, which originally was a hole for the passage of the umbilical vessels, and in the adult, is commonly depressed into a pit, now appears in the *linea alba* as a protuberance composed of condensed cellular membrane. Just at the navel there appears a line crossing the *linea alba*, and extending from one *linea semilunaris* to the other. At the lower end of the *Cartilago Ensiformis*, there is another, and half-way between this and the navel, a third. About half-way between the navel and the pubes is a fourth, but it is generally imperfect. These are the *Lineæ Transversæ*, and they are formed by tendinous matter in the substance of the *recti* muscles, connecting them to their tendinous sheath in front.

The most interesting insertion of the tendon of the external oblique is, the part constituting *Poupart's Ligament*. The latter, as it approaches the pubes from the *Ilium*, splits so as to leave a hole for the passage of the *Spermatic Chord* in the male, and of the *Round Ligament* of the *Uterus* in the female. This opening obtains the name of *External Abdominal Ring*. The tendon forming its upper boundary, is inserted into the *symphysis pubis*, and into the pubes of the opposite side, by fibres which are interwoven with and decussate



those of its fellow. The tendon forming the lower margin of the ring, is inserted into the spine of the pubes, and into its crest for an inch. The portion inserted into the crest of the pubes, is Gimbernat's ligament, which, it will be readily understood, means only a part of Poupart's.

The ring in the external oblique is rather triangular than round; its base is formed by the body of the pubes, and its point is at the place where the tendon separates. The latter is kept from parting still further, by a fasciculus of tendinous fibres which runs across it. The tendinous sides of this opening are called its Columns, and from their situation, internal and external, or upper and lower Columns.

There are several small round holes in the tendon of this muscle. which afford passage to nerves and to veins. When, by the cleanness of the dissection, the tendon has its characteristic gloss and polish, they are very distinct.

Use. This muscle compresses the viscera of the abdomen, and brings the pelvis and thorax towards each other.

The external oblique is now to be turned over to the other side, by dissecting up its origin from the ribs, and its insertion into the crista of the Ilium. This process will enable the student to gain a more satisfactory view of its insertion into the spine and crista of the pubes.



2. The *OBLIQUUS INTERNUS* lies beneath the last, and its fibres pass in a contrary direction to the fibres of the other. It arises tendinous, by the fascia lumborum, from the three inferior spinous processes of the loins and from all those of the sacrum, tendinous and fleshy, from the whole length of the crista of the Ilium, and fleshy from the upper half of Poupart's ligament. Though the fibres of this muscle, in general, decussate the fibres of the external oblique all of them do not, for the lower are brought gradually to pursue the same direction towards the symphysis of the pubes.

Near the *Linea Semilunaris*, the muscular fibres cease, and the tendon begins.

It is inserted into the cartilaginous margin, formed by the six inferior ribs; that is, by fibrous condensed cellular membrane, into the cartilages of the seventh, eighth, and ninth ribs, and by flesh into the tenth, eleventh, and twelfth. It is inserted also into the side of the ensiform cartilage, its whole length, and into the *linea alba*, from the sternum to the pubes.

The tendon of this muscle divides into two laminæ, in a manner which will be better explained presently, after the rectus and pyramidalis muscles have been dissected and turned down.

Its use is the same as that of the External Oblique.

The Internal Oblique is now to be dissected up from its attachments to the ribs, vertebræ, ilium, and exter-



nal half of Poupart's ligament; by beginning near the spine of the ilium, where it is separated more distinctly from the muscle below, by an artery, a vein, and cellular substance.

3. The **TRANSVERSALIS ABDOMINIS**, arises by the **Fascia Lumborum**, from the transverse processes of the last dorsal, and of the four upper lumbar vertebræ, and also by it from the posterior third of the spine of the ilium. It likewise arises fleshy from the anterior two-thirds of the spine of the ilium, and from the upper half of Poupart's ligament; tendinous and fleshy alternately, from the inferior margin of the thorax formed by the cartilages of the six or seven inferior ribs, at their inner surfaces, where they are concerned in the origin of the diaphragm.

The fleshy part of this muscle occupies about one-third of its extent. It is inserted, into the side of the ensiform cartilage, filling up the vacancy between it and the cartilages of the sixth and seventh ribs, and into the linea alba, from the extremity of the sternum to the pubes.

Use, to compress the contents of the abdomen.

4. The **RECTUS ABDOMINIS** muscle is seen beneath the tendons of the other muscles on each side of the linea alba. A longitudinal cut, its whole length, is to be made on its inner edge through these tendons, and they turned over towards the linea semilunaris. Its



origin will then be seen as a flat tendon of an inch or more in breadth, coming from the symphysis pubis and the upper posterior part of the body of the pubes. The muscle increases gradually to the breadth of three or four inches in its ascent. The tendinous intersections, confining it to the tendinous sheath in front, are established at the places mentioned as *lineæ transversæ*, but, for the most part, they do not extend through the muscle.

Inserted fleshy, into the cartilago ensiformis and into the cartilages of the fifth, sixth and seventh ribs.

It draws the thorax towards the abdomen.

5. The PYRAMIDALIS is at the lower front part of the rectus and is about three inches long. It arises somewhat thick, tendinous, and fleshy from the upper part of the pubes, from near its spine to the symphysis between the rectus behind and the insertion of the external oblique before, and is fixed in a sheath formed by the separation of the common tendon of the transversalis and internal oblique muscles. It tapers to a point above, and is

Inserted into the linea alba and internal edge of the rectus, two thirds of its own length, by beginning about an inch above the pubes.

It strengthens the lower part of the abdomen.\*

The Rectus and the Pyramidalis muscles are now

\* This muscle is often wanting.



to be detached from their origins and turned aside. By doing so we become sensible of an arrangement of the tendons of the broad muscles always difficult to describe intelligibly, and generally imperfectly understood. It is this; at the *linea semilunaris* the tendon of the internal oblique and that of the *transversalis* unite intimately, and just beyond this junction two laminae are formed, which enclose the rectus muscle. The anterior lamina is one-half of the tendon of the internal oblique which, after passing half an inch or an inch, is joined to the tendon of the external oblique, goes in front of the rectus muscle, and covers it from origin to insertion. The posterior lamina is made by the posterior half of the tendon of the internal oblique united at the *linea semilunaris* to the tendon of *transversalis*; and which in this manner passes behind the rectus muscle from the *cartilago ensiformis* to a line half-way between the umbilicus and the pubes. From this line downwards, all the tendons go in front of the rectus muscle. The *obliquus externus* tendon may, however, be dissected from the common tendon of the others, without much difficulty, almost to the *linea alba*.

The term insertion is very inadequate to express the manner in which the tendons of these broad muscles all terminate in the *linea alba* from the thorax to the pelvis, but the inspection of the part will qualify the the term so as to prevent mistakes.



The CREMASTER muscle is commonly attributed exclusively to the internal oblique; as it is said to be a detachment of fibres from it. The dissection is now in a stage to exhibit what is really the fact in regard to this muscle—that it is also formed by fibres from the lower edge of the transversalis muscle. The history of its formation is as follows: in the descent of the testicle, the testicle has to pass beneath that edge of the transversalis and of the internal oblique, which is extended from the upper part of Poupart's ligament to the pubes, and as it descends it comes in contact with a fasciculus of these fibres and takes it along. This fasciculus constitutes the Cremaster muscle, which, in adult life and in a strong muscular subject, is seen descending on the outside of the spermatic chord, and spreading over the anterior part of the tunica vaginalis in arches with their convexities downwards, then rising on the inner side of the chord and inserted into the spine of the pubes.\*

It draws up the testicle.

As one becomes acquainted with the dissection of this part by operating on a number of subjects, he will be sensible that there are differences in individuals

\* Mr. J. Cloquet, of Paris, has given this explanation of the formation of the cremaster and it sometimes is manifest in the adult; it is, however, not in accord with Mr. Hunter's account of it, neither does it correspond with what I have witnessed in the male buffalo, in a specimen given to me by Dr. R. Harlan. Mr. Hunter has seen it running up to the testis, while the latter was still in the loins.



which render the established descriptions occasionally unsuitable. One of the most usual is the deficiency of the transverse muscle in that part, the origin of which is usually attributed to the upper half of Poupart's ligament. In this case the internal oblique has increased thickness, and of course, the cremaster will be exclusively derived from it. In other instances the two muscles are so much blended that they cannot be satisfactorily separated from each other.

The Transversalis, and the Internal Oblique perform so important a part in the doctrines of Hernia, that one desirous of understanding them well, should at this time, pay attention again to the mode of their insertion into the pubes. It will thus be seen that they form below, a common tendon, which is inserted, for an inch, into the crista of the pubes behind Gimbernat's ligament, into its spine, and into that part of its body which is behind the external abdominal ring; and that just within and above their insertion the same common tendon splits into two laminæ, one going before, the other behind the pyramidalis muscle, thus forming a sheath for it as just stated.

In examining the origins of the RECTI muscles from behind, the peritoneum being stripped off, it will be seen that a protusion of intestine between them is prevented by the internal edge of the one tendon overlapping the internal edge of the other; and by a triangular ligament called, by Mr. Breschet its discoverer, the Superior Pubic Ligament.



## SECTION II.

*On the parts concerned in Inguinal Hernia.*

It is better for the student to postpone the subject of Hernia, until he has become acquainted with the abdominal muscles and the contents of the abdomen. When he has paid due attention to what is remarked concerning them, the rest of the investigation will be comparatively easy.

Make an incision through the skin and fat, from the Umbilicus to the dorsum of the Penis, and for three or four inches along the inner margin of the thigh; commence another at right angles with the beginning of this, and continue it from the umbilicus in a straight line towards either flank; make a third incision parallel with the first, beginning an inch behind the anterior superior spinous process of the ilium, and terminating in the second incision. The flap of skin thus marked out, must be turned down over the thigh by a careful dissection, which will bring into view the fascia superficialis abdominis.

THE FASCIA SUPERFICIALIS consists of condensed cellular membrane, which may be considered as taking its origin on the front of the thigh, and extending in front of the abdominal muscles, as high up as the thorax;



indeed, if we are disposed to trace it to its whole extent, there is no difficulty in following it over the front of the thorax, also to the neck, and even to the face. In ordinary cases its aponeurotic character is very equivocal, but where the parts about the groin have been pressed upon and thickened by the irritation of hernial protusion it is better developed. On the thigh it is blended with fat, and encloses between its laminæ the lymphatic glands of the groin, and the small vessels given off from the femoral artery immediately below Poupart's ligament. On the tendon of the external oblique it is more condensed; branches of the femoral artery are also seen in it there; one longer and larger than the others, the *arteria ad cutem abdominis* of Haller, winds over Poupart's ligament and runs upwards somewhat in the line of the epigastric artery, being distributed to the skin of the abdomen; the division of it will produce sufficient hemorrhage to require attention. On the symphysis pubis and about the external ring the laminæ of the fascia superficialis are multiplied, and it has more of the character of common adipose matter, as in most cases the *adepts* there, is abundant. This fascia is more loosely connected to the parts beneath it, along the anterior margin of Poupart's ligament than elsewhere, which disposes the femoral hernia to observe that course in its increase. From the pubes it may be traced as a condensed cellular membrane along the penis to its extremity, and, according to Mr. Colles of Dublin, when matter is



formed beneath it, it is apt to create fistulous sores on this organ. A thin lamina of this membrane may also be traced for some distance along the spermatic chord, to the testicle.

The FASCIA SUPERFICIALIS, under the name of Tunica Abdominalis, is well developed in animals with a large and projecting belly, particularly in the large ruminantia and the solipedia. It has a yellowish tinge, is very elastic and strong, and well calculated to support the viscera in them.

In dissecting at the Abdominal Ring, do not work too closely between the spermatic chord and the margin of the ring; by which precaution we avoid cutting the process of the fascia superficialis that unites the two. This process arises from the margin of the ring all around; it passes immediately to the spermatic chord, and is lost insensibly on the exterior surface of the cremaster muscle. A quantity of loose cellular substance, intermixed with fat, is placed between the constituent parts of the chord and the cremaster muscle. This cellular substance, the cremaster muscle, and the fascia superficialis form, in scrotal ruptures, a thick lamina over the hernial sac, called Tunica Vaginalis Communis.

Next make an incision through the fascia superficialis and the tendon of the external oblique, commencing at



the Linea Semilunaris a quarter of an inch above the upper margin of the external ring, and ending a quarter of an inch above the anterior superior spinous process of the Ilium. This incision should be regularly curved, its convexity being downwards, and almost touching the middle of Poupart's ligament. The tendon of the external oblique, bordering on the incision, should be then turned upwards and downwards, by which a good view is given of the inferior part of the internal oblique muscle where it arises from the iliac or upper half of Poupart's ligament, and is inserted into the crista of the pubes just behind the external abdominal ring. The origin of the cremaster muscle is well seen, and the constituent parts of the chord, as they are about to enter into the external ring.

Separate the inferior margin of the internal oblique from Poupart's ligament, and turn it upwards, beginning near the anterior spine of the ilium, where the distinction between the internal oblique and the transversalis is better marked. The lower part of the transversalis is thus exhibited placed behind the internal oblique, and having the same origin from Poupart's ligament and insertion into the Pubes. The raising of the internal oblique brings into view more of the spermatic chord near the external ring.

The Transversalis Muscle is then to be detached from Poupart's ligament, and raised up. This gives a



complete view of the spermatic chord, consisting here of its vessels, nerves, and excretory duct, united by cellular membrane. The upper part of the visible portion of the chord, is about half-way between the anterior spine of the ilium and the symphysis of the pubes, and penetrates the fascia transversalis. The fascia transversalis is placed immediately behind the transversus muscle, between it and the peritoneum. The opening of the fascia transversalis, which permits the chord to pass, is called the Internal Abdominal Ring, in order to distinguish it from the opening in the tendon of the external oblique, called the External Ring. The internal ring is rather nearer to the symphysis pubis than to the spine of the ilium. It will now be understood that the space between the internal ring and the external ring, is about eighteen lines in the adult, and that it is very properly called the Abdominal, Inguinal, or Spermatic Canal as giving passage to the spermatic chord. The anterior side of the canal is formed by the tendon of the external oblique; the inferior part in the erect posture, is formed by Gimbernats's ligament; the posterior parietes are formed by the fascia transversalis, and above, this canal is overhung by the internal oblique and transversalis muscles. It should be observed that the spermatic chord, after penetrating the fascia transversalis, does not cross, directly, the inferior edge of the internal oblique and transversalis at right angles; but it crosses them very obliquely, its inclination being towards the pubes, so that the spermatic



chord can only be considered as disengaged from the inferior edge of these muscles, about the middle of the abdominal canal.

The opening in the Fascia Transversalis is not abrupt and well defined; but the fascia, where it transmits the spermatic chord is reflected by a thin process to the chord, and insensibly terminates in its cellular substance. At the posterior or ventral face of the External Ring, the fascia transversalis is not in contact with the chord, but that part of the tendon of the internal oblique and transversalis which is inserted into the crista of the pubes, and forms a sheath for the pyramidalis muscle, is placed between them, and secures this opening.

The incisions which were originally made only through the skin of the abdomen are now to be carried through the parietes of the same into its cavity, and the flap thus constituted, to be turned down in order to get a view of its posterior or ventral face. This surface covered by peritoneum is divided in the iliac region near the middle of Poupart's ligament into two superficial fossæ by a narrow falciform process of the peritoneum. The process arises from the side of the bladder and extends upwards and inwards towards the umbilicus, stopping about two inches short of the umbilicus. It is broader below than it is above, and its loose edge is turned towards the abdomen. By strip-



ping down the peritoneum we shall see that this falciform process is simply a duplicature of it, occasioned by a fibrous chord, the umbilical ligament of the bladder, which once was the umbilical artery of the foetus. This chord passes near the pubic margin of the internal abdominal ring. Replacing the peritoneum we become convinced that the bottom of the superficial fossa on the outer or iliac side of the falciform process, corresponds with the internal abdominal ring, and frequently a little pouch of peritoneum enters the latter. The fossa on the inner or pubic side of the falciform process is just behind the external ring, but separated from it by the fascia transversalis, and the tendon of the lower parts of the internal oblique, and the transversalis muscles where they are inserted into the pubes, and form the sheath of the pyramidalis. The two fossæ indicate the points where inguinal herniæ commence, the proper inguinal protusion beginning generally in the external fossa, and the ventro-inguinal in the internal fossa. We should here notice the looseness of the attachment of the peritoneum by cellular substance to the parietes of the abdomen, and consequently the little resistance which it, unsupported, can afford against intestinal protusion.

The view of the FASCIA TRANSVERSALIS from behind is extremely satisfactory. For a proper knowledge of this membrane, the profession is indebted to the labours of Sir Astley Cooper, and much of the zeal with which



the anatomy of hernia has been investigated, in latter years is attributable to him. The fascia transversalis is a thin tendinous membrane most generally, occasionally it more resembles condensed cellular membrane. It arises from the internal or abdominal edge of Poupart's ligament, and from the crista of the pubes just behind the insertion of the tendon of the internal oblique and transversalis muscles, and is extended upwards on the posterior face of the transversalis muscle to the thorax. At its origin it is attached to the inferior edge of the transversalis and internal oblique, particularly the part of the edge between the internal ring and the pubes. It is also attached to the exterior margin of the rectus abdominis. The internal abdominal ring or opening in this fascia marks it out in some measure as consisting of two portions, that on the iliac side of the ring is not so thick as the other, or the one on its pubic side, and both portions are much more tendinous near the crural arch than they are higher up.\*

Removing the peritoneum from the iliacus internus muscle, we see the spermatic vessels descending from

\* Were it not for the important influence of the fascia superficialis and the fascia transversalis upon hernia, and the consequent necessity of a minute knowledge of them, the description might be much curtailed in considering them in their proper light, to wit, as the sheaths of muscles; for it is now sufficiently apparent that the first is contiguous to the external oblique and the second to the transverse muscle.



the loins to the internal ring, where they are joined by the vas deferens coming from the pelvis. As they engage under the edge of the internal oblique muscle, after penetrating the ring, the cremaster muscle is detached to spread itself over them. The spermatic chord, thus constructed, passes through the abdominal canal in the manner mentioned, obliquely downwards and inwards; emerging from the external ring it descends vertically, lying rather upon the outer column of the ring than upon its base.

On the posterior face of the fascia transversalis, between it and the peritoneum, is the Epigastric Artery. The epigastric arises from the external iliac as the latter is about to go under Poupart's Ligament; it ascends inwardly along the internal margin of the internal abdominal ring to the exterior margin of the rectus abdominis muscle, which it reaches after a course of two and a half or three inches. The spermatic chord, in getting from the abdomen to the abdominal canal, therefore, winds, in part, around the epigastric artery, in the first of its course being at the iliac edge of the artery and then in front of it. Two epigastric veins attend the artery, one on each side, which end by a common trunk in the external iliac vein.

From what has been said it will now be more fully understood that this structure admits of two places of protusion. In the first, the intestine protudes the peritoneum through the internal ring and along the abdo-



minal canal into the groin, the constituent parts of the chord being behind the sac and separated by it from the cremaster muscle, which, in this case, forms one of the envelopes of the sac. In the second, from weakness of the fascia transversalis and the pubic insertion of the internal oblique and transversalis muscles, a protusion immediately from behind the external ring may occur, in which the whole chord, including the cremaster, is at the outer margin of the sac. In the first species, or the Inguinal Hernia, the epigastric artery is at the pubic side of the neck of the sac; but in the second, or the Ventro-Inguinal, it is at the iliac side.

The anatomical arrangement of the parts concerned in inguinal hernia in the female is the same as in the male, except that the round ligament of the uterus supplies the place of spermatic chord, and there is no cremaster muscle.



### SECTION III.

#### *Of the parts concerned in Femoral Hernia.*

THE study of Femoral Hernia should be commenced with precise ideas, of the concave edge of the os innominatum, which terminates externally by the anterior



superior spinous process of the ilium, and internally by the symphysis pubis;—also of the muscles of the lower extremity which are connected with this edge;—and of the insertion of the tendon of the external oblique.

A muscular subject without much fat answers sufficiently well for this dissection; the male black is, therefore, most frequently resorted to in our school. If the subject have suffered somewhat from a previous infiltration or dropsy of the cellular membrane, the facility of separating the different layers of fascia from each other is much increased. Make an incision through the skin from the umbilicus to the root of the penis, and extend the lower end of the incision around the penis along the internal margin of the thigh for six inches. Commence a second incision at the umbilicus, and carry it out to the flank of the side on which you operate. Begin a third incision through the skin at the termination of the first and carry it to the outer side of the thigh. A flap, consisting simply of skin, being thus described, is to be carefully raised and turned out of the way. In raising this flap of skin guard against cutting up with it the fascia superficialis abdominis, which lies immediately beneath, and which is next to be dissected up.

The FASCIA FEMORIS is beneath the fascia superficialis abdominis; its general character and arrangement are



introduced into the account of the lower extremity, but there are other and minute circumstances in its disposition at the groin, indispensable to a knowledge of femoral hernia. When the fascia superficialis is cleared away, the fascia femoris is seen to arise at the groin along the anterior edge of Poupart's ligament, from the spine of the ilium to within a short distance of the spine of the Pubes. This portion of it is thin, and through it the sartorius muscle may be seen; it is therefore called the sartorial fascia. The fascia femoris arises also from the crest and spine of the pubes, and along its ilio-pectineal ridge which is a continuation of the same; this latter portion covers the pectineus muscle, and is called the pectineal fascia. The pectineal fascia is behind the femoral artery and vein, and the sartorial fascia is before them.

The SAPHENA VEIN, placed between the fascia femoris and the fascia superficialis, runs up along the inner side of the thigh, and joins the femoral vein an inch and a half below Poupart's ligament. Raise the saphena where it joins the femoral vein, and beneath this junction a rounded semicircular edge of the fascia femoris is seen, where the sartorial fascia becomes continuous with the pectineal. Apply the end of a finger to this edge and draw it downwards. Immediately on its being made tense, the sartorial fascia will show itself to terminate by a thin edge in front of the femoral vein. This edge is concave or crescentic,



and extends from the junction of the sartorial and pectineal fascia to the crista of the pubes; it is frequently reticulated. At the upper end of this crescent, the sartorial fascia terminates in a point or angle which is directed deeply towards the pubes. The upper margin of the angle is closely connected with the edge of Gimbernat's ligament and the point is inserted into the crista of the pubes in the same line with Gimbernat's ligament but exterior to it, just at the internal margin of the femoral vein. This angular production or elongation of the sartorial fascia is called Hey's or the Femoral Ligament. The free edge of it is turned towards the femoral Blood-vessels by a sort of half twist.

By introducing a finger under Hey's ligament into the abdomen, we find that the crural arch of Poupert's ligament, and the sartorial fascia exercise a mutual tension on each other like the falx major and the tentorium; by abducting the limb very much and turning the toe outwards, the greatest rigidity is given to both, but by making the limb cross the other and turning the toe inwards, both are relaxed.

A posterior view must now be taken by opening the abdomen. The peritoneum must be separated from the abdominal muscles, from the iliacus internus and psoas magnus, which brings into view the fascia iliaca.

The Fascia Iliaca is a tendinous membrane which



lies on the iliacus internus and psoas magnus muscles, and is continued into the tendon of the Psoas Parvus. Externally it is connected to the margin of the crista of the ilium; at the internal edge of the psoas magnus it is connected with the brim of the pelvis, and sinks into the cavity of the pelvis, being continuous with the Aponeurosis Pelvica; and below, it is inserted into the edge of the crural arch from the anterior superior spinous process of the ilium almost to the pubes. The external iliac vessels are upon this fascia between it and the peritoneum; by raising them with a knife-handle it will be seen that the fascia iliaca goes over that part of the pubes which gives origin to the pectineus muscle, and that it is continuous with the pectineal fascia. If the student should have a preparation in which every thing is removed from the os innominatum except the insertion of the tendon of the external oblique, it will be of essential service to him here: for by it will be seen the arched form of the edge of the tendon next to the bone, from whence the name Crural Arch; the vacancy which exists between the bone and the arch; and the insertion of Gimbernat's ligament from the spine of the pubes, an inch or more along its crista. He will then understand how this space is only partly filled by the iliacus internus and psoas magnus, and that if the fascia iliaca had not an attachment to the crural arch so as to keep it down towards these muscles, hernial protusions would be constantly occurring.



The iliac vessels pass beneath the crural arch on the inner margin of the psoas magnus muscle, the vein being nearest the pubes and the artery at the outer side of the vein. Close inspection will satisfy us that the fascia iliaca is inserted into the crural arch as far as the vein, and may indeed be traced to the crista of the pubes, and that it is so connected with the vessels that no opening for hernia exists between them, or indeed in all the space from the internal margin of the vein to the spine of the ilium. But at the inner side of the vein between it and Gimbernath's ligament an opening appears called the Crural or Femoral Ring, and is the place where femoral hernia commences. This opening is generally occupied by a lymphatic gland and a lamina of condensed but loosely attached cellular substance, called sometimes the Cribriform Fascia, continuous with the Aponeurosis Pelvica.

Make a cross cut of an inch in length, through the Fascia Iliaca; then, by introducing the finger, or a knife-handle through this cut, downwards, our conceptions of the attachment of the fascia iliaca with the crural arch, and its continuity with the fascia pectinea, will be much improved.

The femoral vessels are enveloped by a sheath. To see this distinctly, separate the fascia transversalis from the transverse muscle; cut vertically through the falciform process of the fascia lata femoris, over the



artery, and continue the cut also through Poupart's Ligament, taking care to injure the fascia transversalis as little as possible. To render this part of the examination convenient, only a narrow flap of the abdominal muscles should be left at the groin. By turning towards the symphysis pubis the falciform process, with that part of Poupart's ligament to which it adheres, we shall see that the fascia transversalis is not only attached to the edge of the crural arch, but that it continues to the thigh in front of the femoral vessels. The fascia iliaca, besides its connexion with the pectineal fascia, gives a layer to the posterior face of the femoral vessels. The sheath of the femoral vessels is by this method of examination proved to be formed from the fascia transversalis in front, and the fascia iliaca behind. Mr. Colles has adopted a very satisfactory mode of describing the formation of the crural sheath, which I think more expressive than such as are most in use. The fascia transversalis and iliaca, he considers as a continuous membrane, which may be compared to a funnel, from the manner in which it lines the lower part of the abdomen. The inner side of the funnel is deficient. From its lower part proceeds the membranous neck which surrounds the femoral vessels, and constitutes their sheath. This sheath is very separable from the sartorial fascia in front, and the pectineal fascia behind, and may be traced, easily, to the entrance of the saphena vein into the femoral. On the thigh, just below Poupart's ligament



it has a number of foramina in it occasioned by the passage of the lymphatic vessels from the surface of the thigh.

At the place where the fascia iliaca is united to the crural arch, a white line appears, formed by their union; in this is fixed the *Arteria Circumflexa Ilii*, coming from the external iliac. The epigastric artery is about half an inch distant from the Femoral or Crural Ring, at its outer side. Occasionally, the Obturator Artery comes from the Epigastric, and winds around the internal margin of the ring. As the iliac vessels enter the sheath beneath Poupart's ligament, a close fibrous connexion is formed from them to the sheath both anteriorly and posteriorly, which sends a partition between the artery and the vein, and a partition also on the inner side of the vein. By such arrangement hernial protusions are prevented at this spot; the only opening for them, being at the inner side of the vein between it and Gimbernat's ligament or at the Crural Ring, as stated.

When an intestine descends, it passes into the femoral sheath on the inner side of the iliac vein, it follows the course of this vein down the sheath, till it comes to an aperture made by one of the lymphatic vessels; it then protrudes through this aperture, and gets under the fascia superficialis. The route thus indicated constitutes the Femoral Canal of Cloquet. Afterwards,



if the hernia increase; instead of continuing to descend, it turns upwards and outwards, towards the anterior spinous process of the ilium. From this, it is obvious, that the places of stricture may be: First, the opening in the femoral sheath for the lymphatic; Secondly, Hey's Ligament; and Thirdly, the edge of Gimbernat's Ligament which looks towards the iliac vein. Mr. Colles, whose opinions are entitled to the utmost respect, thinks that surgeons err in regard to the third place, and that the stricture is formed there, by the internal margin of the commencement of the sheath of the femoral vessels instead of by Gimbernat's ligament. He says that this orifice remains with a sharp and distinct edge, even when Gimbernat's ligament is taken completely out of the way, and that the edge of Gimbernat's ligament, supposed to constitute this stricture, stops several lines short of the Crural Ring. A dissection performed in the manner that he recommends, is unquestionably in favour of his position.

The Anterior Crural Nerve has but little to do with this dissection, as it is placed beneath the fascia iliaca, and is on the outside of the artery.



## SECTION IV.

*Of the Contents of the Abdomen.*

FOR common examination, a crucial incision through the parietes of the Abdomen: from the sternum to the pubes on the left of the navel; and from one side to the other, on a line with the umbilicus, but a little below it, answers very well. The flaps, thus made, being turned aside, and kept down, the viscera of the abdomen can be easily seen.

1. The LIVER is in the Right Hypochondriac region; it occupies nearly the whole of it, the upper part of the Epigastric, and the right superior part of the left Hypochondriac. The fundus of the gall bladder projects from its right inferior surface beyond its anterior edge.

2. The STOMACH, when not distended much, is confined to the lower half of the Epigastric region and to the right inferior part of the left Hypochondriac.

3. The SPLEEN, if not large, recedes into the back part of the left Hypochondriac so much, that to be seen it must be drawn out.



4. The small Intestines lie in the Umbilical, Hypogastric, part of the Iliac regions, and also in the Pelvis, when the viscera of the latter are not distended.

5. The COLON begins in the right Iliac region, passes up into the right Lumbar and Hypochondriac and through the upper part of the Umbilical, or the lower of the Epigastric, according to the distension of the stomach; it then gets to the left Hypochondriac, being commonly higher up in it than in the right Hypochondriac; thence it passes into the left Lumbar and Iliac, forms its sigmoid flexure, and dips into the pelvis, where it is continuous with the rectum.

6. The OMENTUM MAJUS is in front of the small intestines, and most frequently found gathered up in the Umbilical region. If it be not diseased, it may be drawn downwards to the pelvis, and spread out so as to conceal all the front of the intestines.

7. The PANCREAS is at the back of the Epigastric Region, behind the stomach; it lies horizontally, and extends from the right of the spine into the left Hypochondriac region. It cannot be seen without cutting through the omentum majus, and turning the stomach upwards.

8. The Kidneys and Capsulæ Renales are in the



Lumbar Regions, at their back parts. They should not be sought for at this stage of the dissection.

It is useful to know that the position of the viscera of the abdomen is influenced much by the position of the body, and that in what is said of the occupancy of the regions, it is understood that the subject is on his back. When one stands upright, the lumbar vertebræ are more convex in front, and the abdomen more protuberant below. The pelvis is so adjusted that the acetabula are nearly in a vertical line with the spine, which gives great obliquity to the superior strait, mounts the sacrum up on high, and brings the bodies and rami of the pubes not many degrees from the horizontal line. Most of the viscera descend, but more particularly the liver, which being no longer sustained by the false ribs, and being influenced by its heavy inert mass, may, in many cases, be felt externally along the right inferior margin of the thorax. This descent of the liver will be according to the degree of vacuity of the stomach, intestines, and bladder.

It is said by Winslow, that the uneasiness, pain, and faintness we feel in a vacuity of the stomach, &c. from the want of food, arise from the liver drawing the diaphragm downwards. Portal informs us, that in order to ascertain the descent of the liver in the erect posture, he has often thrust poignards below the false ribs of dead bodies, and that he has invariably found the wounds much higher up, than when they were inflicted in the horizontal posture.



It should be well recollected that the abdominal cavity is always full, there being no unoccupied space in it; hence, whenever any viscus has an inordinate growth, or a tumour forms on it, or an effusion occurs in the peritoneal cavity, the other viscera are encroached upon. In a treatment for sickness, when the stomach and bowels have been evacuated by low diet and purging, air supplies the place of more solid matter, and keeps them distended. It is indeed exceedingly rare to find the small intestines contracted; in the large, it is more common.

Having become generally informed on the viscera of the abdomen, by repeated handling, we should, in the next place, proceed to an examination of their forms and structure.

The PERITONEUM is a thin, delicate, semitransparent membrane, very extensible, and spread out so as to line the cavity of the abdomen, and to give an external covering to the greater number of its viscera. In man, it is a complete sac, having no hole in it; but in woman, its cavity communicates externally through the Fallopian tubes. It has a double use; in consequence of covering the viscera, it is so reflected from them to the sides of the abdomen, that its processes keep the viscera in their proper places, and therefore answer as ligaments. Again, its internal surface being smooth, highly polished, and continually lubricated by a thin albuminous fluid corresponding with the synovia of the



joints, the motions which the viscera have upon each other in exercise, and in the peristaltic movements of the bowels, are much facilitated.

The manner in which a double night-cap is applied to the head, will afford the easiest conception of the reflections of the peritoneum. If there were only one viscus in the belly, and that of a somewhat regular outline, as the spleen, the comparison would be rigid, and perfectly appreciable. One part of the cap is close to the head, and compares with the peritoneal coat of the spleen; the other is loose, and is equivalent to the peritoneum, where it is in contact with the parietes of the belly. It is also evident from this, that none of the viscera can be said to be within the cavity of the peritoneum; that they are all on its outside; and that a viscus in getting a coat from the peritoneum, merely makes a protusion into its cavity. Starting with this most simple proposition, it is easy to conceive of a second, a third body, and so on, deriving an external coat from a protusion into the same sac. Admitting these bodies to be spheres, the proposition is immediately intelligible; and as a last step from it, the idea is not rendered much more complex by substituting any bodies, even the most irregular in form, for these spheres. Such, then, is the fact, in regard to the stomach, intestines, &c.; they all, with exceptions to be stated, derive an external coat from the peritoneum.

The reflections of peritoneum forming the ligaments of the liver will be best described in connexion with



that viscus. Its reflections over the viscera of the pelvis will be described with them; we will merely say for the present, that it covers the upper and back part of the urinary bladder, and is reflected from it to the rectum.

The reflections for immediate study are the Omenta, Fatty Appendages of the Colon, the Mesentery and the Mesocolon.

1. There are four OMENTUMS. Omentum Minus or Hepatico-Gastricum, Omentum Majus or Gastro-Colicum, Omentum Gastro-Splenicum, Omentum Colicum.

*a.* The OMENTUM MINUS extends in a transverse direction from the transverse fissure of the liver; from the right of the lobulus Spigelii at the posterior half of the umbilical fissure; and from the inferior face of the diaphragm; to the lesser curvature of the stomach from the end of the œsophagus to the pylorus and duodenum. It is composed of two laminæ which, near the stomach, are separated by the coronary vessels. It has always but an inconsiderable quantity of fat in it. Its right margin is commonly called the Capsule of Glisson, and contains the hepatic vessels.

*b.* The OMENTUM MAJUS, or GASTRO-COLICUM, is an irregular quadrilateral membrane having its base upwards. The latter is fixed anteriorly to the greater curvature of the stomach, and posteriorly to the trans-



verse arch of the colon. It hangs loose in its inferior part, and is sometimes found spread over the intestines as low as the pelvis; it is, therefore not improperly compared to an apron. On its right side it is continued into the omentum colicum, and on the left into the gastro-splenicum. It consists of two laminae, the anterior is fixed to the stomach, the posterior to the colon. Each of these laminae again is composed of two, so that it may be compared to two bags, one within the other, connected at their upper or open end to the stomach and colon. The internal and external bags are very separable above, but below they are closely united. In corpulent subjects a great deal of fat is found in this membrane.

By searching for the neck of the gall bladder, we shall find near it under the capsule of Glisson, the Foramen of Winslow, an opening which conducts into the bag of the omentum majus. It is large enough to admit easily two fingers. By detaching the omentum majus from the stomach, and turning it down, we shall see the nature of its cavity, its extent, and all the parts constituting its parietes. This cavity is bounded above by the omentum minus and stomach; in front by the two laminae sent from the stomach; behind and below, by these laminae being reflected upwards and joining the colon, and posteriorly and above, by the upper lamina of the mesocolon which is extended to the Lobulus Spigelii. By a little reflection it will be understood



that I have described an uninterrupted cavity, beginning at the lobulus spigelii by the omentum minus, and terminating with the lobulus spigelii by the upper lamina of the mesocolon. It is acknowledged on all sides to be one of the most obscure propositions in descriptive anatomy, even when the subject is before a young student. It is a point well worth mastering, as, when this is accomplished all other difficulties, in studying the reflections of the peritoneum, are much diminished.

*c.* The OMENTUM COLICUM is a prolongation of the omentum majus, from the internal side of the right ascending colon, and from the adjacent part of the transverse. It is filled with fat from the same causes as the preceding, but consists of only two single laminae.

*d.* The OMENTUM GASTRO-SPLENICUM is that process of peritoneum which extends from the large extremity of the stomach to the spleen; it may be considered a prolongation of the omentum majus, and encloses in its duplicature the arteries and veins called Vasa Brevia.

*e.* The APPENDICULÆ EPIPLOICÆ are little processes of peritoneum, filled with fat, appended at irregular intervals to the anterior sides of the cæcum, colon, and the upper part of the rectum.



The MESENTERIUM is extended obliquely across the spine from a line parallel with the second lumbar vertebra to the right iliac fossa. This part, called its root in the adult, is about six inches in length and flat, but the inferior edge, which is loose and pendulous having the intestines connected with it, has its circumference increased to many feet, which causes it to lie in folds. The mesentery attaches the left extremity of the duodenum, the jejunum, and ileum to the spine. It consists of two laminæ of peritoneum separated by the mesenteric arteries and veins, the lacteal glands and vessels, and the nerves derived from the solar plexus. There is also some fat between them.

The MESOCOLON fixes the large intestine to the back of the abdomen. The posterior part of the cæcum is in contact with the iliac fascia and is tied down to it. The colon in the right and left lumbar regions is also for the most part immoveably fixed, the mesocolon being there of very little length; but the transverse mesocolon is long, and forms a complete and moveable partition between the upper and the lower parts of the abdomen, which permits the colon to ascend and descend according to the distension of the small bowels and stomach. In the left iliac region the mesocolon is elongated so much as to allow very free motion to the sigmoid flexure of the gut, and continues into the mesorectum.



*Of the Ventriculus, or Stomach.*

The stomach is a conoidal sac curved considerably. As was stated, it is in the epigastric region; in contact above with the diaphragm, with the left lobe of the liver and the lobulus spigelii; on the left with the spleen; behind with the pancreas; and below with the colon and mesocolon. The stomach has a very great obliquity in its situation, the right extremity being much lower down than the left.

The exterior of the stomach presents two faces, two orifices, two curvatures, and two extremities.

When the stomach is nearly empty it becomes somewhat flattened, and then exhibits the Anterior and the Posterior face; in a state of distention, the first looks obliquely upwards, and the latter obliquely downwards. The angle, formed with the œsophagus, is increased according to the degree of distension.

The orifices are the Pyloric and the Cardiac. The pyloric viewed externally presents nothing remarkable but seems to be a continuation of the right extremity of the stomach into the duodenum. The cardiac, formed by the junction of the œsophagus with it, is at the upper edge of the stomach, and some distance from the extreme left.

The curvatures are the Great and Small. The first includes the great extremity and the inferior edge of the



stomach to the pylorus; the small is the upper margin between the orifices.

The Tuber or great extremity of the stomach is the part to the left of a vertical plane passing through the cardiac orifice; it is smaller in proportion in children than in adults.

The stomach consists of four laminæ. The external is peritoneal, and derived from the separation of the two leaves of the omentum minus. The second is muscular, its thickness is inconsiderable, and the fibres which compose it are remarkably pale; they are best seen near the cardia and at the pylorus. At the latter they are collected into a ring of considerable thickness, which, making a marked prominence internally, helps to constitute the valve of the pylorus. The muscular fibres go in three directions. The first being longitudinal, are continued from similar ones of the œsophagus and extend to the pyloric orifice. The principal part of them is collected into two bands, the thicker of which passes along the lesser curvature, and the thinner along the greater. The second set of muscular fibres surrounds the stomach by segments of circles, none of them going completely around. It is this set, in an especial manner, which assists in forming the pyloric orifice. The third and most profound set of muscular fibres is oblique, and forms two large bands. One is extended from the left side of the cardia over the anterior and posterior faces of the stomach; and the other is prolonged from the right side of the same orifice



over the great extremity also before and behind, where it supplies the scarcity of transverse or circular fibres.

The third coat of the stomach consists of a very dense compact short cellular membrane, which unites the muscular and internal coat, and conducts the vessels and nerves to the latter.

The fourth or Internal Coat of the stomach, called, also the Mucous or Villous, is of a light red. It is like velvet, and is thrown into very irregular folds, according to the degree of contraction of the stomach. At the pyloric orifice it forms a circular fold constituting the pyloric valve and having a round hole in the centre. At the base of this valve the muscular fibres make a distinct ring.

### *Of the Intestinal Canal.*

This Canal is from thirty to thirty-five feet long; in the human subject, and extends from the Pylorus to the Anus. It consists of two portions, the longer forming four-fifths of the whole, extends from the stomach to the ileo-colic valve, the other from this latter to the anus. The first is *Intestinum Tenue*, the second *Intestinum Crassum*. This canal like the stomach consists of four coats, peritoneal, muscular, nervous, and villous.



The small Intestine, or *INTESTINUM TENUE*, is divided somewhat artificially, by anatomists, into three parts, Duodenum, Jejunum, and Ileum.

The *DUODENUM* deduces its name from its length, which has been fixed at twelve fingers breadth. It is also called *Ventriculus Succenturiatus*. Beginning at the pylorus, it passes to the right, and upwards, towards the neck of the gall-bladder; it then forms a right angle, and passes downwards before the right kidney, to the third lumbar vertebra between the two laminae of the Mesocolon on the right side. Here it forms a round elbow, and crosses the spine obliquely upwards, making its appearance to the left of the second lumbar vertebra, where it is continued into the mesenteric portion of intestine.

The head of the Pancreas lies in the bend of the duodenum, and fixes it firmly just there. The first part, where it emanates from the pylorus, is moveable, and covered with peritoneum; the second and third portions are between the laminae of the mesocolon, but have no peritoneal coat; and the termination is both moveable, and has a peritoneal coat. The partial deficiency of peritoneal coat, is said to be the cause why the duodenum is susceptible of an enlargement, in some cases, but little inferior to the stomach.

The muscular coat of this intestine consists of two planes of fibres, the external one longitudinal, the other circular and much the most numerous. Beneath is the



coat of cellular membrane connecting it with the mucous or villous coat. The internal coat is reddish, tinged with bile, and occupied by a great number of rugæ or folds. They are transverse and oblique, very near each other, about three lines broad, and as prominent in the distended as the undistended gut; these constitute the *Valvulæ Conniventes*. Many mucous follicles exist in this intestine, and mucous glands, called *Glandulæ Brunneri*; the latter are particularly accumulated about the pyloric orifice. It is, in the posterior part about four inches from the stomach, that the orifices of the pancreatic and hepatic ducts are found.

The Inferior, or Mesenteric portion of the *Intestinum Tenue*, has the same coats with the preceding. In the upper two-fifths, called *Jejunum*, the *valvulæ conniventes* are numerous, and arranged transversely; but in the lower three fifths, called *Ileum*, they gradually diminish, and near its termination, cease entirely. There is a gradual diminution of the diameter of this intestine from above downwards. From the length of the mesentery, great latitude of motion is allowed to it. It presents a very irregular and confusing appearance at first, but one soon becomes accustomed to its course and convolutions; and then its commencement and termination are as readily found as those of any other organ. It is probable that in the distentions of this bowel, the peritoneal coat does not stretch much, as the *laminæ* of mesentery are



loosely applied against each other where they join the intestine, and are separated in its distentions, as far as the first row of the mesenteric arches of blood-vessels. Cases are reported, in which it has had appendiculæ epiploicæ and cul-de-sacs projecting from its sides. I have never seen the former, but of the latter, a specimen was presented to me some years ago, taken from a child by the late Dr. EDWARD BARTON; and another specimen now belongs to the Wistar Museum, obtained in the dissecting rooms.

The mucous or internal coat of the Intestinum Tenue, differs from that of the stomach, in resembling more the downy cuticle of an unripe peach. The little projections from it, are called Villi. It abounds with mucous follicles and glands; the latter consist in those of Brunner which are insulated from each other and may be seen at intervals along the whole intestine: and in those of Peyer which make about thirty patches of an elliptical shape and of various sizes towards the lower end of the Ileum.

The large Intestine or the Intestinum Crassum, has already been explained in regard to its course. It is more obviously a conical tube than the small intestine, being very large at its commencement when inflated, and diminishing much to the lower end of the sigmoid flexure. Anatomists call its commencement, or that part below the ileo-colic valve, Cæcum or Caput Coli;



and the remaining portion, which is by far the longest, the Colon, until it reaches the pelvis, when it becomes Rectum.

The Caput Coli is about two inches in length, and is fixed to the Iliac fascia by peritoneum and loose cellular membrane. At its inferior extremity, towards the left is the Appendicula Vermiformis, a blind cavity of four coats, about four inches long, and of the size of a turkey quill, enclosed in a duplicature of peritoneum. It floats loose, and occasionally becomes a cause of mischief, by getting around the ileum, and inflaming, by which it adheres and produces, in some measure, strangulation. The colon makes a large sweep around the abdomen, and in passing under the gall-bladder, touches it, and thus becomes tinged with bile after death. In its transverse course, we frequently find it passing through the umbilical region.

The coats of the Intestinum Crassum, correspond in number with those of the small intestine; but there are some differences in structure. The longitudinal muscular fibres are much more conspicuous; they are collected into three bands, which commence at the head of the colon, and extend to the upper part of the rectum; one is superior, another inferior, and a third anterior. They are equidistant from each other. These longitudinal bands produce the cells of the colon, by drawing its extremities nearer together. The cells are separated laterally, by partitions or buttresses formed of a doubling of all the coats of the intestine; whereas



in the small intestine, the valve or doubling belongs exclusively to the mucous membrane. These cells are not so numerous or well formed in the sigmoid flexure and thereabouts; the channel is therefore more open and unobstructed. By dividing the longitudinal bands, the cells are removed, and the intestine elongates considerably.

The Ileo-Colic Valve, or valve of Bauhin, or Tulpius, is a great curiosity in the anatomical structure of this gut. The ileum runs into the left side of the colon, and continues its cellular and mucous coat into the corresponding coats of the colon, the muscular coat of the latter being simply parted. To prevent the further separation of the muscular fibres, a little ligamentous arrangement, called the Retinaculum Morgagni, prevails at each end. When viewed from within the colon, the opening appears as a transverse, or very narrow elliptical slit, established by two lips, the superior broader than the inferior. They meet like the gates of the common ship-dock or hydraulic lock; and from being placed transversely, in regard to the cavity of the intestine, every distention which the latter may suffer from the accumulation of fæces, has a tendency to force this valve, and will, by stretching its extremities, make the lips tighter and more resisting.

The internal coat of the large intestine differs very materially from that of the small. It has few or no villi. Near its commencement, it preserves the fungous appearance of the stomach, but about the sigmoid flexure,



it is a plain smooth surface. A great many mucous follicles and mucous glands are in it. It has lacteals, but they are not so numerous as in the small intestines.

The Rectum will be described with the Pelvis.

*Of the Liver, (Hepar, Sive Jecur.)*

The Liver secretes the bile. Its position in the abdomen and the space it occupies have been mentioned. It is placed in the following relations: above, it is in contact with the concavity of the diaphragm; below, are the Omentum Minus, the Stomach, and the Transverse Arch of the Colon; behind, is the Vertebral Column, intercepted however by the lesser muscle of the diaphragm, and the Ascending Cava. When we lie on the right side it is sustained by the ribs in the easiest posture; when on the left it sometimes occasions uneasiness by pressing on the stomach; and when on the back it compresses the ascending cava.

Its colour is reddish brown. Its form is happily compared, by Professor Chaussier, to the section of an ovoid made in the direction of its greatest diameter, the thick end being to the right side. It is fastened in its situation by the following reflections of the peritoneum. From the centre of the diaphragm, and extending from the umbilicus backwards to near the ascending cava, is the Falciform or Suspensory Ligament, consisting of two laminae; it is thickened at its anterior



edge by what was once umbilical vein in the foetus, but is now converted into a fibrous substance called Round Ligament. This falciform ligament divides the upper surface of the liver unequally into two, the left being the smaller; it also penetrates a notch in the anterior edge of the liver. On the right of the falciform process, and extending from the diaphragm to the posterior edge of the liver, is the Right Lateral Ligament; to the left of the same process, and also extending from the diaphragm to the back edge of the liver, is the Left Lateral Ligament; and that portion of peritoneum concerned in the union of these three ligaments forms the Coronary Ligament. Within the circumference of the coronary ligament the surface of the liver is not covered by peritoneum, and it is attached to the diaphragm by loose cellular substance.

The precise shape of the liver is best seen in one removed from the body. The following parts are noticed by anatomists: its upper surface, its lower surface, its right extremity, its left extremity, its anterior edge and its posterior edge.

The upper surface is uniformly convex, and presents nothing remarkable but its unequal division by the suspensory ligament.

The lower surface is very irregularly concave, and on it are the following appearances: From the front to the back edge is a deep fissure corresponding in situation, with the suspensory ligament above, and with it, giving occasion to divide the liver into right and left



lobes. This is the Sulcus Umbilicalis, occupied in front by what was umbilical vein, and in the rear by what was ductus venosus, both vessels in the adult being in a ligamentous state. Crossing this fissure at right angles, passing from the left lobe, for some distance into the right, and occupying about the middle third or fourth of the long diameter of the liver, is the Sulcus Transversalis. In it are the Vena Portarum, Hepatic Artery, and Ducts. The Lobulus Spigelii or posterior lobe is at the back of the liver just to the right of the posterior part of the sulcus umbilicalis. It is like a ridge and terminates forwards in a papilla which is one of the portæ of the liver; to the right, the lobulus spigelii sends off a small process which unites it with the greater lobe of the liver, and is called the Lobulus Caudatus. On the front of the inferior surface between the fore part of the umbilical fissure and the gall-bladder is a flat rising, the Lobulus Anonymus or Quartus; its posterior extremity, opposite to the anterior of the lobulus spigelii, is the second pula or porta of the liver.

The right extremity of the liver is very thick and almost fills the right hypochondriac region, but the left tapers to a very thin edge. The posterior border or edge is thick, and indented by the spine, but the anterior edge is thin. The former is sometimes converted into a complete canal, marked by a short large sulcus for the ascending vena cava; the latter only has the notch for the suspensory ligament already mentioned.



Besides the peritoneal coat, the liver has a second, which covers its whole exterior surface, adhering very closely to the peritoneum on one side, and to the liver on the other ; it penetrates into the substance of the liver, and holds together its granulated structure.\* This tunic is easily seen by stripping off the peritoneum, and in parts which naturally are left uncovered by the latter.

The Blood-vessels are of three kinds. The two first bring the blood to the liver, the third takes it away. The hepatic artery, a branch of the cœliac, after having detached some smaller ramifications, gets to the transverse fissure of the liver and divides into three branches ; one to the right lobe, one to the left lobe, and another to the Lobulus Spigelii ; they, however, subdivide before they reach the substance of the liver. These branches are between the sinus portarum and the biliary ducts. The vena portarum is formed from the union of all the veins of the intestines, stomach, pancreas, and spleen, forming a single trunk about three inches long. It gets to the transverse fissure of the liver, over the duodenum and under the pancreas, and immediately sends off, at right angles, two branches which, collectively, are called the sinus of the vena portarum. The right branch, being the shortest and largest, is distributed to the great right lobe ; the left sends its branches to the lobulus spigelii, anonymus, and left lobe.

\* See Sæmmering's Anatomy. Laennec's Journal de Medecine.



At the bottom of the transverse fissure is a lamellated fibrous cellular tissue, closely adhering to the liver, which accompanies the vena portarum, the hepatic artery, and hepatic duct in their ramifications, forming sheaths for them as they go off successively. As the branches of these tubes keep together, they are united by the cellular sheaths. Glisson believed these sheaths to be muscular and they have obtained the name of his capsule ; and, indeed, the capsule is generally spoken of as lying on the aforementioned vessels, even before they reach the liver. The hepatic veins arise from the capillary extremities of the hepatic artery and vena portarum ; there are three principal trunks of them coming, two from the right and one from the left lobe of the liver, and emptying into the ascending cava, just below the diaphragm ; there are also, five or six little trunks, coming from the posterior surface of the liver, and the lobulus spigelii, which empty into the ascending cava below the other. The hepatic veins have no valves, and may, in a section of the liver, be readily distinguished from other vessels by their lonely course, by their crossing the others at right angles, and by their thinness. All of these vessels of the liver are remarkable for the number of their anastomoses and the facility of their communication with each other. A minute injection of either pervades all parts of the liver, and the injection if persevered in will fill all the other vessels. By tearing the substance of the liver a good view of its organization may be obtained;



it will then be seen to be composed of an immense number of spherical or polyhedrous grains, (*Acini*,) united to each other by the cellular tissue of the internal coat. These grains contain the essential and ultimate points of the glandular arrangement, the anastomoses of the vessels are formed in them, and also the capillaries of the hepatic duct ; but what the final organization is by which bile is formed is yet doubtful.

The nerves of the Liver will be mentioned at another place, along with the general account of such as belong to the Abdomen.

The Gall-bladder, (*Vesicula*, sive *Cistis Fellea*,) is fixed on the inferior surface of the great lobe, in a broad shallow fossa for the purpose. It is not placed in the line of the short diameter of the liver, but somewhat obliquely, its anterior end, which reaches to the edge of the liver, being turned to the right, and its posterior, which goes to the transverse fissure, being turned towards the left. Its shape is conical, the base being rounded off and the apex curved ; the body diminishes gradually to the apex. The gall-bladder has three coats ; the peritoneal is only partial, from the upper face of the gall-bladder being in contact with the liver. The second coat is cellular membrane, in which ramifies a great number of blood-vessels and lymphatics. The third may be considered a continuation of the mucous coat of the intestines, but has some peculiarities. On its internal face, it is thrown into irregular tortuous folds or wrinkles of extreme



delicacy, in the intervals of which are many round or polyhedrous cells ; some small, others a line and a half deep, particularly about the middle of the body. In the neck or apex of the gall-bladder, from three to seven or more elevated semilunar folds are formed, of the internal membrane : a spiral arrangement is sometimes adopted by them.

The gall-bladder and the contiguous parts, after death, are always tinged with bile, which does not occur in the living body. I have, however, in one case in our dissecting rooms, seen a gall-bladder in an old African woman, filled by a pint of very fluid watery greenish bile, and the tissue of which had been so lax, that a quart or more of the same secretion had percolated into the abdomen probably before death.

The HEPATIC DUCT arises, by very delicate branches, from the Acini of the Liver. These branches are united into three or four trunks, in the transverse fissure, which trunks again unite into one about the size of a writing-quill, and eighteen or twenty lines long. The Hepatic Duct joins, at a very acute angle, with the Cystic Duct, which is somewhat smaller and shorter, and the two form the Ductus Communis Choledochus. The biliary canals thus formed, are situated in the right side of the Hepatico-gastric, or lesser Omentum, in what is commonly called the Capsule of Glisson. The Ductus Communis being three inches, or three and a half long, is to the right of the Vena



Portarum and the Hepatic artery; descends behind the pancreas and the upper part of the duodenum; and passes obliquely between the coats of this intestine, for the distance of an inch, its orifice being, as mentioned, at the back of the second turn of the intestine.

The Biliary ducts have two coats. The external is a lamellated fibrous membrane, highly extensible, and having many blood-vessels. The internal is of the same character with that of the gall-bladder. In the cystic canal, and towards the lower part of the Ductus Communis, are several longitudinal folds.

*Of the Spleen, (Lien, Splen.)*

This organ, as mentioned, is situated deeply in the left hypochondriac region, in the concavity of the Diaphragm at the left extremity of the stomach, and above the Colon. Its form approaches to the longitudinal section of an oval, being commonly four and a half inches long, and two and a half wide. But there is no viscus in which more frequent varieties of magnitude occur. I have seen it extending almost to the Ilium, and but little smaller than the liver; and again, not by any means the length just mentioned as a medium size. Its transitions of magnitude are frequent and rapid in the same individual, depending on the stage of digestion, upon sickness, and probably on mental sensations. Several spleens sometimes exist in the same person.



In such cases the supernumerary ones are, for the most part, very small.

The Spleen has a partial division lengthwise, by a fossa, where the blood-vessels are connected with it. Its circumference is sometimes notched. Its colour varies from a deep blue, which it is in early life, to a very dark brown. It is fixed by three processes of peritoneum, the names of which indicate their attachments; the Gastro-splenic, the Splenico-phrenic, and the Splenico-colic ligaments.

The external coat of the spleen is obtained from the peritoneum, being a continuation of the processes just mentioned. The internal coat is a grayish, compact, extensible, elastic membrane, in close adherence with the external; it sends in processes to accompany the blood-vessels; and moreover from its internal face there proceeds a multitude of lamellæ and of fibres, dividing its cavity into cells. It seems to be intended to sustain the natural shape of the spleen, and to support its peculiar structure.

The spleen is remarkably well furnished with blood-vessels. It derives a large artery from the cœliac, distinguished by its tortuous course, and by the branches which it furnishes to the stomach and pancreas. It divides into several trunks just before it enters the spleen. The veins come out by an equal number of trunks, unite into one trunk, and attend the artery along the upper edge of the pancreas; it joins the Vena Portarum.



In the body of the spleen are found many grayish, soft, semi-transparent gelatinous corpuscles, from an almost imperceptible magnitude to a line or more in diameter. By Malpighi, they were considered glandular; and by Ruysch, as convoluted vessels. The mass of the spleen, upon a superficial examination, seems to consist in a bloody dark brown pulp, contained in the numerous cells of the internal coat. On this cellular structure, the vessels pass. M. Assolont considers that blood, besides existing in the arteries and veins, is placed in a state of particular combination, and of intimate union with the other organic elements of the viscus, and with a large quantity of albumen; that this peculiar combination of the blood forms the dark grumous fluid just mentioned, which may be easily seen by scraping the spleen with the handle of a scalpel. Of the latter, there can be no doubt; but a question arises whether it is contained in the cells I have just spoken of, or in the extremities of the vessels. Slight examination is in favour of the former, but M. Marjolin, denies it, on the following grounds. That injections, cautiously made, pass immediately from the arteries into the veins; and that when the spleen, successfully injected, is frozen, one can see no ice in the interstices of the vessels, while the capillary ramifications of the vessels distended by the injected fluid, are distinctly seen. The probability then is, that the peculiar structure of the spleen is formed essentially of arterial and venous capillary vessels, with very delicate and extensible coats, and



that they communicate with each other, without the intermedium of any cell; and that the extreme tenuity of these vessels, and their extensibility in every direction, are sufficient to explain the augmentation of volume which the spleen affords, under certain circumstances, and the promptitude with which it diminishes under others.

It has no duct.

*Of the Pancreas, (Pancreas.)*

This is an oblong conglomerate gland, extending across the spine, and fixed in the back and lower part of the epigastric region. It is connected to the spleen on the left, to the duodenum on the right, is behind the stomach and between the laminae of the transverse mesocolon.

The Pancreas is of a light gray colour. It is about six or seven inches long and two wide; and would represent tolerably a parallelogram, if at its right extremity, it were not swollen out into a head, to which Winslow gave the name of Small Pancreas. It has two faces, two edges, and two extremities. The anterior face is turned obliquely upwards and corresponds with the superior lamina of the mesocolon. The posterior face is obliquely downwards, has a long fossa in its upper part for the splenic vessels, and is in contact



with the aorta, vena cava ascendens, the superior mesenteric vessels, and several nerves.

The pancreas has no peritoneal coat, excepting the mesocolon, neither has it a proper tunic, unless one should consider as such the lamina of condensed cellular membrane which envelopes it, and which sends in processes between its lobules.

The structure of the pancreas strongly resembles that of the salivary glands and consists of granuli, united into lobules, which form lobes whose interstices are occupied with numerous vessels. The excretory duct of the gland arises from these granulations, by very fine radicles which, uniting, form larger cylinders inclining from left to right. These latter empty successively into a long tube, the Ductus Wirsungii, going the whole length of the gland and situated near the very centre of its substance; it is small at the splenic extremity, but gradually increases till it becomes as large as a crow's quill at the other end. It is there joined by the duct of the lesser pancreas, and in a short course afterwards empties into the ductus communis choledochus, or runs at its side and makes a distinct opening into the duodenum at the posterior part of its second curvature.

The arteries of the pancreas are principally derived from the splenic. The veins empty into the splenic.



*Of the Kidneys, (Renes.)*

To get a good view of the kidneys, the other abdominal viscera should be removed, or at least the intestines.

The Kidneys are two glandular bodies for the secretion of urine, fixed one on each side of the spine. They are in the back part of the lumbar regions in a space extending from the upper part of the eleventh dorsal vertebra to the lower part of the second lumbar, though the right, in consequence of the pressure of the liver from above, is lower down than the left. They are deposited in a large parcel of fat on the upper part of the great *psoæ*, the *quadrati lumborum* muscles, and on the lower part of the great diaphragm.

The shape of the kidney is a compressed ovoid excavated on one side like a bean. The broad end of the ovoid is above, and the excavation presents obliquely forwards and inwards. The latter has a deep fissure in it for the passage of the blood-vessels and excretory duct. The kidney is hard and solid; its colour is brown.

The kidney has not a peritoneal coat, but it has a proper capsule, which completely envelopes it and penetrates into its fissure. The capsule is there perforated with many foramina for transmitting the blood-vessels. This membrane is fibrous, semi-transparent, and some-



what elastic ; it is easily peeled from the surface of the kidney, and in doing so we see that it adheres by a very delicate cellular and fibrous tissue and by some small vessels. The kidney being originally formed in lobes which subsequently unite, the vestige of this union is frequently preserved.

The kidney being laid open longitudinally, we shall obtain an idea of its internal arrangement. It is seen obviously to consist of two parts of different appearance ; the external which, from its position, is called *Cortical* ; and the *Internal* or *Tubular*.

In regard to the structure of the kidney, it receives from the aorta, at right angles, a large artery, the *Emulgent*, which divides into several branches as it approaches the fissure ; these terminate by penetrating to all parts of the gland in a crowd of arterioles, so that when they are injected with wax and corroded, the figure of the gland is preserved. Some of these minute arterial branches terminate in corresponding veins, and others in the glandular structure of the organ.

The *Cortical* part is the most vascular ; it is, at an average, about two lines in depth, is made of granules called *acini*, and forms the periphery of the gland, but different portions of it project and form partial partitions between the tubular sections. It tears with facility, with a granulated edge or surface, and its colour is a dark or reddish brown. When viewed with a microscope the granulations are distinctly seen of extreme minuteness, and receiving the capillary extremi-



ties of the arteries. I have more than once injected these granulations from the arteries, and observed the fluid coming through the ureter and the emulgent vein.

The second or Tubular portion of the kidneys, to the naked eye, consists of conoidal fasciculi of fibres presenting their bases to the periphery of the organ, and their apices towards its centre. These cones are from twelve to eighteen in number, and as mentioned, are partially separated from each other by processes from the cortical part; they are dense, of a lighter brown, and tear with facility in the course of the fibres. Each cone is formed by a great number of very fine canals converging close to each other near the apex, and joining. They appear only to give passage to the urine, as cases have occurred, in which they were entirely removed by suppuration and ulceration. The technical name for these canals, is *Tubuli Uriniferi*; they begin in the cortical part of the kidney from the acini and pass through it in a serpentine course. The terminations of the cones are called *Papillæ*, and an attempt has been made to establish for them some peculiarity of organization; but that idea is now abandoned, and they are generally admitted to be the same with the other portions of the tubular part. They have many orifices in them which are the terminations of the tubes, and from which urine in most subjects can be readily squeezed.



*Of the Excretory Ducts of the Kidneys.*

The excretory duct of the kidney begins in its centre by a dilatation called Pelvis, branching into several divisions called Calices, each of which ends in three or more funnel shaped tubes named Infundibula. Each papilla has its appropriate infundibulum which adheres to and surrounds its base; but sometimes there are two of the former to but one of the latter.

The excretory duct of the kidney has two coats, the external of which is fibrous and the internal mucous. The latter is said to be continued over the papillæ, and may probably enter into the tubuli uriniferi. It enjoys a great degree of extensibility and contractility of tissue, and its sensibility not perceptible in health, is exquisite in disease.

The Pelvis of the kidney is continued into the Ureter, a canal about the size of a writing quill, and which is in contact behind with the psoas magnus muscle, and the iliac and hypogastric vessels, crosses the vas deferens at the back part of the bladder, and passes obliquely through the coats of the latter, to end in an orifice a little behind that of the Urethra.

The emulgent veins are parallel with the arteries, and terminate in the vena cava ascendens.



*Of the Renal Capsules, (Capsulæ Renales.)*

They are two little triangular pyramidal bodies, one for each kidney and placed at its superior part; they are of a yellowish brown colour, somewhat tinged with red, and being connected with some process of foetal existence, are much larger than in the adult; their structure also seems to be much changed in the latter. From being placed precisely on the upper extremity of the kidney they have the lower surface which touches it of a corresponding concavity.

On the exterior of this body is a proper coat formed of lamellated and condensed cellular tissue, which furnishes from its internal surface many prolongations dividing the gland into lobes. These lobes are divisible into lobules, which again consist of a granulated structure that seems susceptible of other divisions. These granulations are not firm and resisting.

In the centre of the Capsula Renalis, frequently there is a triangular cavity which may be demonstrated by thrusting a tube into it, and inflating, or by an incision. In the foetus this cavity contains a reddish viscid fluid coagulable by alcohol: in children it becomes yellow: in adults it is dark brown, and in old people it is either wanting or in a remarkably small quantity.

The arteries of these bodies come from the emul-



gents, the phrenics and the aorta. The veins terminate on the right side in the cava, and on the left in the emulgent.



#### SECTION V.

##### *The Diaphragm, (Diaphragma,)*

Is a complete, though moveable septum, placed between the thoracic and the abdominal cavity; it is extremely concave below and convex above, the concavity being occupied by several of the abdominal viscera. To view it properly, all the abdominal viscera should be removed, a large billet of wood placed under the loins of the subject, and the peritoneum carefully dissected off. It is particularly necessary to attend to the latter direction in order to get a good view of the varied structure of this important organ, and the dissector, while performing it, is continually liable to the accident of a puncture being made through it into the thorax; in which case the diaphragm loses its concavity, and becoming flabby and displaced, the value and beauty of the display are much impaired.

The dissection being properly achieved, exhibits a broad concave muscle connected with the inferior margin of the thorax on all sides, and having for its



centre a silvery tendon resembling in its outline the heart of a playing card. This cordiform tendon occupies a considerable part of the extent of the diaphragm, having its apex next to the sternum and its notch towards the spine; the muscular part of the diaphragm is inserted all around its circumference. The cordiform tendon is nearly horizontal in the erect posture, its elevation being on a line with the lowest end of the second bone of the sternum. On each side of this tendon the muscular fibres rise so high upwards before they join it, that they are on a horizontal level with the anterior end of the fourth rib. The fasciculi of muscular fibres are, for the most part, convergent from the circumference of the thorax, and are easily separated from each other.

In the diaphragm are three remarkable foramina. The first, (*Foramen œsophageum*) is in the back of the muscle between the spine and the notch of the cordiform tendon, a little to the left. It gives passage to the œsophagus and the par vagum nerves as connected with it, and is rather a fissure or a long elliptical foramen made by the separation and reunion of the muscular fibres; for above and below at each end of the ellipsis these fibres decussate each other in columns. To the right of this foramen and a little above its horizontal level, in the back part of the cordiform tendon, is a very large and patulous foramen, (*Foramen quadratum*) for the ascending vena cava. It is between an irregular quadrilateral figure and a circle; its edges



are composed of fasciculi of tendon rounded off, and are not susceptible of displacement, or of alteration in their relative position to each other, by which means is obviated any impediment which might arise from a different arrangement, to the course of the blood in the ascending cava. Almost in a vertical line below, but about three inches from the foramen for the œsophagus, is the third hole (*Hiatus aorticus*) in the diaphragm, which affords passage to the aorta. It is just in front of the bodies of the three upper lumbar vertebræ, and is a much longer elliptical hole than the œsophageal; its lowest extremity or pole is constituted by the tendinous crura of the diaphragm, and its upper by a decussation of muscular fasciculi arising from them. Through it, besides the aorta, pass the Thoracic Duct, and the Great Splanchnic Nerve from each side.

In the horizontal position of either the dead or the living body, the right side of the diaphragm ascends higher in the thorax than the left, but the weight of the liver makes it, in the vertical posture, descend lower than the other.

Thus circumstanced, the Diaphragm arises fleshy, from the internal face of the upper edge of the Xiphoid Cartilage, from the internal face of the cartilages of the seventh true, and of the succeeding false ribs, on each side. That is, from the cartilages of the eighth and ninth, from the osseous extremities of the tenth and eleventh, and from both the osseous and cartilagi-



nous termination of the twelfth rib. As the line described includes almost the whole of a circle, and the fibres all converge to the cordiform tendon, they, of course, will pass in different radiated directions, and be of different lengths which it is unnecessary to specify. Between the sternal and costal portions, on each side, there is a triangular fissure filled with fatty cellular tissue, which sometimes leaves an opening for Hernia. I have seen a case of this kind, in which the transverse part of the Colon was the subject of protrusion into the Thorax. It is probable that greater displacements of the abdominal viscera, into the thorax of adults or children, may have had a congenital origin in this very fissure, and are subsequently, when the parts are modified to this unnatural situation, set down as a *Lusus Naturæ*. The part described in this paragraph is called the greater muscle of the Diaphragm.

Besides these origins, the Diaphragm has several from the vertebræ of the loins, called its *crura*, there being four, on each side of the foramen for the aorta. The first pair, entirely tendinous, comes from the front of the body of the third vertebra of the loins, and is prevented from being very distinct in its origin, in consequence of running into the ligament in front of the bodies of all the vertebræ. The second pair of heads is on the outside of the first, and arises tendinous from the Intervertebral ligament, between the second and third vertebræ. The third pair of heads arises tendinous from the upper part of the lateral margins



of the second lumbar vertebra. And the fourth pair of heads comes also tendinous from the fore part of the roots of the transverse processes of the second lumbar vertebra. These tendinous heads terminate in what is called the Lesser muscle of the Diaphragm, which is inserted into the notch of the cordiform tendon. It will now be understood that the aorta passes between the heads of the lesser muscle, and that the œsophagus has a hole in the upper part of its belly.\*

The origin of the Diaphragm is completed between its greater and lesser muscles, by a tense ligament, called *Ligamentum Arcuatum*, which passes from the root of the transverse process of the first lumbar vertebra to the inferior part of the middle of the twelfth rib; with the upper edge of this ligament the Diaphragm is connected; and with the lower, the *psoas magnus* muscle. At the margin of the other ribs, the diaphragm is connected with the *transversalis abdominis*.

The action of this muscle, in assisting respiration, is very obvious; its fibres passing in a curved line with their convexity towards the thorax, from the bony margin of the thorax to the cordiform tendon, and having a tendency to become straight by contracting, will

\* This origin of the lesser muscle of the Diaphragm is given by Albinus, but it is difficult to make out fairly, and for the most part it would do much better to say that it arises tendinous, from the first, second, and third vertebræ. The heads are occasionally much smaller on one side than the other.



descend, and thereby enlarge the thorax. It is not certain that the cordiform tendon descends, its connexions being too strong and numerous to admit of much motion. In expiration, the relaxation of the Diaphragm, with the contraction of the abdominal muscles, restores the former to its first state. In vomiting, the Diaphragm and abdominal muscles concur to expel the contents of the stomach.

The PSOAS MAGNUS muscle arises, fleshy, from the side of the bodies of the last dorsal and of the four upper lumbar vertebræ, and from the transverse processes of all the lumbar vertebræ. It forms an oblong fleshy cushion on the side of the lumbar vertebræ, and, constituting the lateral boundary of the inlet to the pelvis, it passes out of the pelvis, under Poupart's ligament about its middle.

It is inserted, tendinous, into the trochanter minor of the os femoris, and fleshy for an inch below it.

It bends the body forwards, or draws the thigh upwards.

The PSOAS PARVUS, arises, fleshy, from the contiguous edges of the last dorsal and of the first lumbar vertebra at their sides, and from the intervertebral ligament. It is at the anterior and internal edge of the psoas magnus; has a short belly, and a long tendon by which it is inserted into the linea innominata, about half-way between the spine of the pubes and the junction of this



bone with the ilium. The tendon, besides, is expanded into the fascia iliaca.

Its use seems to be, to draw upwards the sheath of the femoral vessels which is derived from the fascia iliaca, and consequently to draw upwards the vessels themselves, which probably diminishes the liability to injury from their too great or sudden flexion. This muscle is sometimes wanting.

The *ILIACUS INTERNUS* occupies the concavity of the ilium, being on the outside of the *psoas magnus*. It arises, fleshy, from the transverse process of the last lumbar vertebra, from the inner margin of the crista of the ilium, and from its whole concavity; also from the anterior edge of the concavity of the ilium at and above the anterior inferior spinous process, and from that part of the capsule of the hip joint near this process.

This muscle terminates in the tendon of the *psoas magnus* just above the insertion into the *trochanter minor*.

It has the same action with the *psoas magnus*.

The *QUADRATUS LUMBORUM* is an oblong muscle passing from the superior back part of the spine of the ilium, by a tendinous and fleshy origin of two or three inches in length. It lies at the side of the lumbar vertebræ, into all the transverse processes of which it is inserted by short tendinous slips. It is also inserted



into the lower edge of the last rib near its head, and into the transverse process of the last vertebra of the back.

It bends the loins to one side, and will draw down the last rib. This muscle is covered posteriorly, by the tendinous origin of the transversalis abdominis muscle, which separates it from the sacro-lumbalis and longissimus dorsi.



## PART II.

### CHAPTER II.

#### OF THE MALE PELVIS.

THE first step of the student, after a short examination in situ of the contents of the pelvis, should be to detach the penis from its bony connexions and to remove it, with the bladder and rectum, from the pelvis. Then to make a fair and clean dissection of these organs by detaching the surrounding fat, cellular membrane and muscles. This dissection is best made with the scissors, and its utility is in proportion to its cleanliness; the latter is much assisted by inflating the bladder and by stuffing the rectum. The scrotum may be separated and laid aside for future examination.



#### SECTION I.

##### *Of the Viscera of the Male Pelvis.*

THE *Rectum*, being the termination of the colon, begins at the left sacro-iliac symphysis; from thence it



passes down obliquely towards the middle of the sacrum about one half of its length; its course afterwards is directly downwards before the sacrum and os coccygis till it terminates in the anus; its orifice there points backwards and downwards. It is round till just before its termination, it then dilates into a pouch which is spread on each side of the prostate, and is apt to be cut in lithotomy.

The inferior third of the rectum is destitute of peritoneum, its anterior face is in contact with the lower fundus of the bladder, the vesiculæ seminales and the prostate gland. Posteriorly and above, it is confined to the sacrum by the mesorectum, which conducts its nerves and blood-vessels. The dip of the peritoneum between the vesiculæ seminales so as almost to touch the base of the prostate gland should be remarked.

The muscular structure of this gut is remarkably strong, consisting externally, of vertical and parallel fasciculi of fibres close together; and internally of circular fibres which form a thick and continued plane, particularly on a level with the lower fundus of the bladder. Just below the pouch of the rectum these circular fibres form the Internal Sphincter Muscle. Many of the longitudinal fibres on getting to its inferior margin pass beneath it and are then turned upwards so as to be inserted into the mucous coat. The mucous membrane of the gut is smooth above, but at the lower part it is thrown into several longitudinal folds called



the Columns of the rectum, at the lower end of which are some small blind pouches looking upwards; its mucous lacunæ are numerous. The anus is thrown into radiated folds from the influence of the external sphincter ani.

The *Bladder*, (*Vesica Urinaria*,) is fixed just behind the symphysis of the pubes and when pressed upon by the neighbouring viscera, is somewhat flattened before and behind; but removed from the body and distended, it resembles an elongated sphere, of which the greatest diameter is vertical in regard to the linea ilio-pectinea. The technical name for each end of the sphere is *Fundus*, distinguished by the terms upper and lower, the lower being somewhat the more obtuse. From the upper end proceeds to the navel a long conical ligament, the *Urachus*. By putting the anterior parietes of the abdomen on the stretch we shall see starting out and protruding the peritoneum into a semilunar duplicature on each side of the *urachus*, the remains of the umbilical arteries of the foetus which now are called the *Round Ligaments* of the bladder, though they have but little or no influence on it. At the anterior part of the lower fundus, the bladder is somewhat elongated into a process called its *Neck*, resembling a truncated cone, and being the commencement of the *urethra*.

The bladder consists of four tunics; the *Peritoneal*, *Muscular*, *Cellular*, and *Mucous*.



The PERITONEAL is a very incomplete coat placed upon the upper and posterior parts of the bladder, and passing from it to the muscles of the abdomen before, and to the rectum behind. It is connected to the muscular coat by very loose cellular membrane, which prevents it from participating in any considerable distensions of the organ, and permits it to leave the anterior face of the bladder, so that its reflection to the recti muscles in these cases, is placed much above the pubes. Tapping the bladder is performed here, as well as the high operation for the stone.

The MUSCULAR coat consists of flattened fasciculi of white fibres passing in very varied directions, and separated to some distance from each other. Many of them arise from the neck of the bladder and pass before and behind upwards towards the urachus, where they end; others, arising laterally from the same place, pass up in a corresponding course and also terminate at the urachus. There are many transverse and oblique fibres uniting these together, but still leaving interstices through which the internal coat occasionally protrudes, and thus forms cells in the cavity of the bladder. There is an accumulation of fibres about the neck of the bladder and the urachus, which gives an increased thickness at these points.

The CELLULAR coat consists of a close, dense, lamellated, and filamentous tissue, highly extensible and dif-



ficult to tear. It is impervious to water, closely adherent to the muscular and mucous membranes, and pervaded by many vessels.

The Mucous, or internal coat of the bladder, though called villous, has less of this appearance than that of the stomach. It is white with a slight tinge of red; abounds with mucous follicles which, in a state of health, are difficult to be discerned; possesses great extensibility and but little contractility, from whence when the bladder is not very full, it is thrown into folds passing in various directions. It offers several points for observation. 1. A triangular space between the orifice of the urethra and those of the ureters, (the *Trigone Vesicale* of the French,) which is elevated into a plain smooth surface. Mr. Charles Bell thinks the lateral margins have muscular fibres beneath, intended to regulate the orifices of the ureters.\* 2. The *Uvula Vesicæ*, a small pointed production terminating the triangle in front, and formed by a projection of the third lobe of the prostate gland into the cavity of the bladder. 3. The orifices of the ureters, about an inch behind the orifice of the urethra. 4. The inferior *Fundus*, (*bas-fond* of the French,) a depression of the general concavity of the bladder making it lower than any other part, placed between the base of the trigone

\* My personal investigations on this point have not verified the assertion.



and the posterior side of the bladder. 5. The Internal Orifice of the neck of the bladder, resembling somewhat the neck of a Florence flask.

The Neck of the Bladder is thicker than any other part; it is surrounded by cellular tissue in which a great number of veins is found, and it penetrates, in front, the prostate gland, which has a continual tendency to close it. It has a sphincter muscle formed in the following way which may be seen by removing the lining membrane. A transverse fasciculus crosses its inferior semi-circumference from one lateral lobe of the prostate gland to the other; this fasciculus is half an inch wide and from one to two lines thick, and is placed over the third lobe of the prostate. The superior semi-circumference is also crossed by a thin layer of muscular fibres, which spreads itself out at the ends where it is lost in the ordinary muscular structure which it resembles exactly.

Under the mucous membrane corresponding with the vesical triangle there is a muscle of the same shape and dimensions, the posterior corners being inserted around the orifices of the ureters, and the anterior being attached to the caput gallinaginis.

*Prostate Gland, (Glandula Parastata.)*

This is a body about the size and form of a horse chestnut, fixed as stated on the neck of the bladder,



and penetrated by the urethra, which traverses it much nearer its superior than its inferior surface. The base of it is turned backwards, and the point forwards; its inferior surface rests upon the rectum, and its sides, in the distentions of this organ by fæces, are overlapped by it. The Prostate has, posteriorly, a notch in its centre, which divides it into two lateral lobes, and by raising the Vesiculæ Seminales, we shall see where their excretory ducts penetrate the gland, and separate from the body of it the little tubercle, called the Third Lobe.

The organization of this body, seems to consist in a condensed, white, extensible, though easily lacerated fibro-cellular tissue, and within it are placed a great number of mucous follicles, which form from eight to twelve ducts,\* passing obliquely forwards, and terminating in the urethra at the sides of the urethral crest or Caput Gallinaginis. The fluid secreted is thick, ropy, white, and semitransparent in a healthy state. The Prostate is surrounded by a fibrous capsule, of which more hereafter.†

The SEMINAL VESICLES, (Vesiculæ Seminales,) are two convoluted bodies of two inches in length, one on

\* Loder says there are from thirty-two to forty-four.

† An opinion prevails among the anatomists of Philadelphia, that the prostate is larger in the African than in whites. Indeed this much may be said of all the organs of generation in both sexes.



each side of the lower fundus of the bladder, approaching each other very nearly at the base of the Prostate, but diverging much as they recede. They are separated before, by the interposition of the vasa deferentia; and being fixed between the rectum and the bladder, they are matted to the latter by a close cellular texture, having many large veins pervading it.

When inflated and dried, they present the semblance of cells, but are in fact long tubes, which, by being convoluted, are reduced to the apparent dimensions mentioned: there are also several pouches on each side of this long tube which increase the number of cells. The convolutions are preserved by the intermediate cellular tissue. These bodies consist of two coats, an external, which is fibrous and cellular; and an internal, which is mucous, being a continuation of the lining membrane of the bladder. They are commonly filled by a drab-coloured thick fluid, supposed to be a mixture of the semen, and of their own proper secretion, though, of this, Mr. Hunter doubted.\* The excretory duct of each vesicle is about a line and a half long, when it joins in the substance of the prostate with the vas deferens of the same side; a common canal, (Ductus Ejaculatorius) is thus formed, which runs parallel with its fellow, below the urethra.

The DUCTUS EJACULATORIUS, is about eight or ten

\* See Observations on the Animal Economy.



lines long, and opens by an oblong orifice, at the lateral anterior face of the Caput Gallinaginis ; it is larger behind than before, which gives it a conical shape, and allows fluids injected to pass freely from the vas deferens to the vesicula, or the reverse.

*Of the Penis, (Membrum Virile, Mentula.)*

It is a membranous and cellular body affixed to the margin of the pelvis, at and below the symphysis pubis, and appropriated to the passing of urine and semen. It is formed by the common integuments, by cellular tissue, by the corpus cavernosum, and by the corpus spongiosum.

The skin covering the penis is more thin and delicate than in most other parts of the body, and is furnished with a considerable number of sebaceous follicles, more particularly about the root of the organ. It is very loosely connected by cellular membrane to the parts beneath, so that it is easily made to correspond with all states of the penis. At the anterior extremity it is arranged into a duplicature or fold, the Preputium, which is inserted just behind the glans ; the inferior part of the prepuce is connected with the extremity of the glans by a process called Frænum.

The penis, besides arising from the bones of the pelvis in a manner which will be presently explained, is fixed to the symphysis pubis by a ligament, (Liga-



mentum Suspensorium,) which is a triangular fibrous body, flattened laterally and lost insensibly on the fascia of the thigh covering the adductor muscles. The portion of it which goes to the penis arises in front of the symphysis pubis and is inserted into the dorsum of the penis near its root; from this insertion it is extended over the penis, and according to Mr. Colles constitutes one of its coverings, by going as far as the glans. Professor Marjolin says that he has seen on several occasions muscular fibres entering into its composition, and in that case it draws the organ with more force towards the anterior parietes of the abdomen.\*

The Corpus Cavernosum of the penis, forms by much the most considerable portion of the whole organ. Externally it is a white fibrous membrane of a dense structure, enjoying extensibility and an extreme degree of contractility; its fibres pass for the most part longitudinally, except about the root, where they are blended with the periosteum of the bone, and with the tendons of the muscles. This coat of the penis is occasionally called its elastic ligament. It arises by two conical crura, one from the internal face of the crus of each pubes and ischium, to within a little distance of the anterior part of the tuber ischii. At the lower part of the symphysis pubis these crura join and form a body, which, when stripped of its connexions, resembles two cylinders lying along side of each other and

\* I have seen it in one case, February 11th, 1825.



united ; anteriorly they terminate in common by a truncated cone covered obliquely by the glans. At the posterior part of the corpus cavernosum, in its centre, there is a tolerably complete septum of the same kind of substance, separating its two halves from each other, but anteriorly this septum is imperfect, having an arrangement like the teeth of a comb, whence the term *Septum Pectiniforme*.

In the middle of the corpus cavernosum above, is a longitudinal sulcus for lodging the veins of the penis, and in the same manner below, another for the corpus spongiosum urethræ. The cavity of this membrane is filled by a spongy tissue, which arises from its internal face, and is formed of filaments and little laminae ; they, by crossing each other, form a multitude of cells which have a perfectly free communication with each other, and generally are somewhat occupied by blood.

The *Corpus Spongiosum Urethræ* extends from ten or twelve lines behind the junction of the crura of the corpus cavernosum, to the anterior extremity of the penis. Externally it is covered by a coat resembling that of the corpus cavernosum, except that it is thinner. In its centre is the canal for the urine. Between this canal and the coat is a spongy structure, much finer than that of the corpus cavernosum, and though the cells communicate freely, still they have the appearance of convoluted veins. The corpus spongiosum is not of the same thickness in its whole course ; its commencement in the perineum where it is pendulous, is enlarged into



what is termed its Bulb; from this it diminishes gradually to the end of the corpus cavernosum, where it is again enlarged into the Glans Penis. The transverse diameter of the glans being larger than that of the body of the penis, it forms all around a projecting shoulder, the Corona Glandis. The surface of the glans is covered by thin skin making a very delicate epithelium, and a great number of papillæ for the termination of nerves. Numerous follicles also exist about the corona glandis, to secrete the sebaceous fluid which collects there in persons who are not cleanly. They constitute the glands of Tyson.

The Urethra is a canal whose length varies according to the degree of erection in the penis, and extends from the neck of the bladder to the extremity of the glans. It has several curvatures and receives in its course the ductus ejaculatorii, the excretory ducts of Couper's glands, and the mucous lacunæ of its internal membrane. The first part of this canal which traverses the prostate gland is about fifteen or eighteen lines in length; it is the Prostatic Portion, and is well supported by this body, although its own sides are very thin. On its inferior surface is the Verumontanum or Caput Gallinaginis, an oblong projection of the lining membrane an inch in length, broad behind where it commences a little in advance of the Uvula Vesicæ, and coming to a point very gradually before. In the posterior ridge of the caput is a long cleft, which is the orifice of a lacuna observed first by Morgagni; and



on the front surface on each side, is the orifice of the ductus ejaculatorius. On the sides of the caput gallinaginis the canal of the urethra is depressed into something like a cul-de-sac, where are to be found the orifices belonging to the lacunæ of the prostate gland as stated.

Between the Prostate and the Bulb is the Membranous Part of the urethra, about eight or ten lines long; it is unprotected except by a soft covering which seems in some measure to be a mixture of gelatinous matter and muscular fibre. The former was considered by Littre as a glandular body which secreted a viscid humour into the interior of the canal; the latter probably is the part described by Winslow as the inferior prostatic muscle, which arising on each side of the membranous canal, goes to be inserted into the corresponding branch of the pubes near the symphysis. The membranous part of the urethra does not get into the end of the bulb, but penetrates it from above, half an inch or more occasionally, from its extremity, just below the junction of the crura of the Corpus Cavernosum.

The canal varies in its dimensions; at its commencement at the bladder it is large; it then contracts at the back of the caput gallinaginis, and immediately enlarges in the fore part of the prostate at the sides of the urethral crest. The membranous part is small; the canal then enlarges in the bulb. In the body of the penis the canal is successively diminished, till it comes almost to



the glans, when it is so remarkably enlarged as to get the name of Fossa Navicularis; it terminates finally by a short vertical slit at the extremity of the glans.

In the whole length of the canal there are two whitish middle lines, one above and the other below, and in the membranous and spongy portions, excepting the fossa navicularis longitudinal folds of the lining membrane exist which are effaced by distention. In the upper part of the canal there are a great many mucous lacunæ; Loder, in his plates, has marked about sixty-five; there is one particularly large in the upper surface of the fossa navicularis, which, it is said, has stopped the point of a bougie and been mistaken for stricture.

At the posterior part of the bulb are Couper's Glands, two small bodies about the size of a garden pea. Their excretory ducts are about an inch long, and, passing very obliquely under the internal membrane of the urethra, they terminate at the anterior part of the bulb, in the lower side of the canal. Other glands, but smaller, of the same kind exist occasionally; they are placed just before Couper's and are called the glands of Littre.

Mr. Shaw of London has described a set of vessels

\* Sir Everard Home has lately communicated to the Royal Society a highly interesting paper on the structure of the lining membrane of the urethra. From his microscopical observations, he is induced to think, that there can be no doubt of its muscularity.



immediately on the outside of the internal membrane of the urethra, which, when empty, are very similar in appearance, to muscular fibres. He says he has discovered that these vessels form an internal spongy body which passes down to the membranous part of the urethra, and forms even a small bulb there. See Med. Chir. Trans. vol. x. His preparation, being a quicksilver injection of the part, is certainly a very satisfactory demonstration of their existence: yet in my own observations, I have not been able to distinguish them from the cellular membrane connecting the canal of the urethra to the corpus spongiosum.

### *Of the Testicles, (Testes.)*

These bodies, two in number, are surrounded by several coats, the most external of which, is common to both the testicles and is called Scrotum; the others are proper. The scrotum is a sac formed by a continuation of skin from the internal sides of the thighs, from the inferior part of the penis, and from the anterior part of the perineum. It is very thin, darker than the rest of the skin, sparingly covered with hairs, has many sebaceous follicles in it, and is closely united to the cellular membrane beneath. It is very extensible, and has a great power of contraction, its surface being covered with wrinkles which are more apparent when it is contracted. It consists of two symmetrical



halves marked off from each other by an elevation of skin, the Raphe, which extends from the perineum over the scrotum along the inferior surface of the penis to the end of the latter.

Beneath the scrotum is the Dartos, a fibrous membrane, which is vascular, reddish, and deprived of fat; it arises from the inferior margins of the crura of the ischia and pubes, and passing downwards, it joins the raphe; it is then reflected upwards, forms a septum between the two sides of the scrotum, and goes up to the inferior part of the urethra. This membrane has been confounded with cellular substance; but it appears from the reports of Messieurs Chaussier, Lobstein, and Breschet, that it does not exist in the scrotum till the descent of the testicle, and that it is an expansion of the gubernaculum testis.

Notwithstanding its great contractility, the question of its muscular structure is not settled, and certainly, in the greater part of its extent, there is not the appearance of muscular fibre, but at its posterior end, just at the anterior point of the sphincter ani, I have often seen a broad muscular expanse, the character of which could scarcely be misconceived. The contractility of the scrotum has been attributed to the cremaster muscle instead of this membrane, but common observation will convince most persons that the elevation of the testicles in the scrotum by the contraction of the cremasters is very distinguishable from that contraction of the scrotum by which the testicles are



squeezed against the sides of the pubes and the scrotum brought into a hard corrugated mass.

The Cremaster muscle is rather an imperfect coat; its course has been explained in the account of the abdominal muscles. Its fibres are much separated on the tunica vaginalis; they lay on its front part, and on the internal and external sides of the spermatic chord. Within the last is a coat of cellular substance the Tunica Vaginalis Communis.

The Tunica Vaginalis Testis was originally a process of peritoneum, though it appears in the adult as a complete sac. The testicle being protruded into it from behind, one half of the sac applies itself closely to the epididymis and testicle, while the other half is loose; the whole arrangement being precisely after the manner of a double night-cap when drawn over the head. It passes up some distance on the chord; its cavity is smooth, polished and moistened by a synovial halitus which allows the surfaces to move freely upon each other.

The Tunica Albuginea is the proper coat of the testicle which preserves its form, and is in immediate contact with the glandular structure. It is a dense strong, white, and fibrous membrane, corresponding very much in its general characters with the tunica sclerotica of the eye. From the internal surface of the albuginea, several membranous processes forming partial partitions pass off, and terminate at the posterior part of the cavity in the Corpus Highmorianum. These



septulæ conduct the blood-vessels through the substance of the gland, and form little apartments filled up by the seminiferous tubes. The Corpus Highmorianum is a longitudinal projection of the tunica albuginea, somewhat broader above than below; its upper part is perforated by the vasa efferentia.

The form of the Testicles as communicated by the tunica albuginea, is very much that of an oval, somewhat compressed laterally, the edges presenting forwards and backwards; they do not hang with the long diameter vertical, but the upper end is advanced a little forwards, and the lower points somewhat backwards. They are both of the same size generally, but in case of a difference the right is larger; it is also higher up than the left, a circumstance which has been marked by sculptors in all ages.

The glandular structure of the testicle consists of a congeries of convoluted tubes, stated by Monro to amount to three hundred, whose diameters do not exceed individually the one two-hundreth part of an inch, and when extended to their full length, would form in the aggregate, a tube 5208 feet long. These tubes, almost inconceivably fine as they are, can be injected in a retrograde course through the vas deferens with mercury, but the task is one of exceeding difficulty, and scarcely ever succeeds fully. Such preparations are consequently very rare in anatomical cabinets.

The Tubuli Seminiferi, it has been stated, fill up



nearly the whole of the cavity of the albuginea, being kept from each other by the processes termed *Septulæ*. These tubes send out a great number of trunks, which, from their observing a straight course, obtain the name of *Vasa Recta*. These *vasa recta* unite near the centre of the testicle, and form a net-work, the *Rete Testis*. From the *rete testis* there proceed from twelve to eighteen tubes, which pass through the upper part of the *corpus highmorianum*, and get to the outside of the *tunica albuginea*; these are the *Vasa Efferentia*. Each of these *vasa* is rolled up externally at this place, so as to give the outline of a cone, therefore, it gets the name of *Conus Vasculosus*. Each cone successively empties into a single tube on the back of the testis, which is prodigiously convoluted and forms a large body, the *Epididymis*.

The *Epididymis* is a prismatic arch enlarged at both extremities, and resting vertically on the back of the testicle, being connected with it by the *tunica vaginalis*. The enlargement above is the *Globus Major*, and is formed of the *coni vasculosi*, but what remains of this body below, consists of one tube excessively convoluted. The enlargement below is the *Globus Minor*; after this is formed, the tube becomes less convoluted and turns upwards on the inside of the *epididymis*, and a little further on it becomes nearly straight, and is called *Vas Deferens*. There is a blind duct which



commences at the top of the epididymis and terminates below, the intention of which is not known.\*

The Vas Deferens is a white tube about a half line in diameter, having a cartilaginous feel; its cavity is large enough to admit a bristle. It passes on the back of the spermatic chord, and continues with it through the abdominal canal; at the internal ring it leaves the residue of the chord, and dipping into the pelvis by the side of the bladder, goes between it and the ureter to the lower fundus, approaching its fellow on the inside of the vesiculæ seminales, and ending in the urethra, by the Ductus Ejaculatorius. About two and a half inches from its termination it becomes somewhat tortuous and enlarges.

The Spermatic Chord is formed of the Vas Deferens, the Spermatic Artery and Veins, Lymphatics, Nerves, and Cellular membrane, all covered by the Cremaster muscle. The artery arises from the aorta and retains its first size till it arrives at the testis, it then divides some of its branches being spent on the epididymis, and the remainder going into the testis, and terminating on the tubes. The veins in ascending form a remarkable plexus, the Corpus Pampiniforme, at the internal ring they unite into one trunk, which on the right joins the ascending cava, and on the left the emulgent vein.

\* It is sometimes called the Vasculum Aberrans Halleri, and is said by Mr. Cruikshank, to be an anomaly.



Having thus become acquainted with the structure of the viscera of the male pelvis, I advise the student in the next place to put a subject in the posture recommended for Lithotomy, in order that he may work on the Perineum.



## SECTION II.

### *Of the Perineum and the Fasciæ of the Male Pelvis.*

THE subject being fixed in the posture indicated, make a horizontal cut through the skin, at the junction of the raphe of the perineum with the scrotum, extending it on each side three inches, make another transverse cut of the same length over the end of the os coccygis; drop a perpendicular cut equally profound with the first from its middle to the point of the os coccygis. The skin constituting the flap on each side being raised up carefully, so as not to injure subjacent parts, when the two flaps are pinned aside the structure of the perineum is sufficiently opened for the time.

The Perineal Fascia is first exposed; it occupies nearly all the space between the anus and the posterior margin of the scrotum, (insensibly blending with the latter,) and between the rami of the pubes and of the ischia, being very firmly fixed to these bones. This



fascia, in case of rupture in the posterior part of the urethra, prevents the urine from showing itself in the perineum, and drives it into the cellular structure of the scrotum. In abscesses of the perineum, it also prevents the fluctuation from being very evident. Having studied well its connexions, structure and influence, it is to be raised up and turned to each side by a cut down its middle in order to bring into view the Perineal muscles.

The Erector penis is so situated as to cover the whole of the crus of the penis which is not in contact with the bony margin of the pelvis. It arises, therefore, from the anterior part of the tuber ischii tendinous and fleshy, its fleshy fibres, adhering to the internal and external margins of the rami of the pubes and ischium, proceed upwards, and, just before the union of the crura of the penis, end in a flat tendon which is lost on the side of the elastic membrane of the penis.\*

Its use is not well understood.

The Accelerator Urinæ lies on the bulb and back part of the corpus spongiosum urethræ; it is a thin muscle consisting of oblique fibres.

It arises by a pointed production from the side of the body of the penis; its origin is continued obliquely

\* The late Dr. Lawrence informed me that he has frequently found muscular fibres between the bone and the crus penis.



across the inferior surface of the crus where the latter begins to form the body of the penis. It arises also from the inner side of the ramus of the pubes between the crus penis and the triangular ligament of the urethra. The muscles of the opposite sides are inserted into each other by a white line which marks the middle of the bulb of the urethra, and by a point into the anterior extremity of the sphincter ani, where they are joined by the transversales perinei.

In order to see the origin of these muscles very distinctly, separate them from each other in the middle line and dissect them from the corpus spongiosum. Cut transversely through the corpus spongiosum about three inches before the triangular ligament and dissect it clearly from the corpus cavernosum, turning it downwards so that it may hang by the membranous part of the urethra. By putting the two acceleratores on the stretch it will be seen that, besides the origins mentioned, they arise also from each other by a tendinous membrane that is interposed between the corpus spongiosum and cavernosum, so that they literally surround the posterior part of the urethra constituting a complete sphincter muscle for it.

These two muscles are considered by M. Chaussier as forming but one ; in that case its origin will be reversed, and commence in the middle line of the perineum instead of terminating there. The relation of this muscle and the erector penis should be observed, in order to appreciate the difficulty of getting into the



membranous part of the urethra in lithotomy, without cutting through the muscular fibres of one or the other.

It propels the urine and semen forward.

The Transversus Perinei, as its name implies, passes directly across the perineum ; it arises from the inner side of the tuber ischii just at the origin of the erector penis, and is inserted where the sphincter ani and the accelatores join.

I have observed that, when the lower part of the accelerator was extended much below its usual line and strongly developed, the transversus was very irregular in its origin and course, consisting frequently of a few fibres which did not deserve the name of a distinct muscle, and were almost unappropriated in the adipose matter of the part.

Occasionally a fasciculus of muscular fibres exists, called, by Albinus, Transversus Perinei Alter, which arises in front of the first and is inserted into the perineal junction just behind it.

The use of these muscles seems to be, to contribute to fix the bulb of the urethra.

The Sphincter Ani muscle consists in a plane of fibres which surrounds the anus in order to keep it closed. It has two fixed points, the last bone of the os coccygis behind and the perineal union of the other muscles in front ; its lateral diameter occupies about



one-half of the space between the tuberosities of the ischia, as it is in the middle of this space. The point of it in front is continued into the dartos.

Besides closing the orifice of the rectum it will draw the bulb of the urethra backwards, or the point of the os coccygis forwards.

The Coccygeus muscle rather belongs to the interior of the pelvis, but is seen well enough here. It arises by a small, tendinous, and fleshy beginning from the spine of the ischium, and, lying on the anterior face of the anterior sacro-sciatic ligament, it is inserted into the side of the last bone of the sacrum and into all those of the os coccygis.

It draws the os coccygis forwards.

The Erectores Penis, Acceleratores Urinæ, and Transversi Perinei are now to be removed. A large quantity of adipose and cellular matter will be found on each side of the rectum between it and the parietes of the pelvis, concealing the levatores ani muscles. This fat is better left in situ for the present.

The muscles being removed, the bulb of the urethra is seen to great advantage, extending in the middle of the perineum almost to the anus. It is not loose and pendulous as described, but is connected by its superior face to the Triangular Ligament of the urethra, a membrane which fills up the space below the symphysis of the pubes. This ligament is a septum be-



tween the perineum and pelvis, and, when closely examined, is seen to connect itself to the internal edges of the rami of the pubes and ischia at the inner posterior sides of the crura penis as far down as the beginning of the latter. At its lower edge its ligamentous character is not so well defined. It extends from the top of the pubic arch downwards an inch and a half, filling up all the intermediate space between the bones. On its anterior surface is the bulb of the urethra, and just at the extremity of the latter, enclosed by the ligament and adhering to it, are Couper's Glands. A perforation exists in it through which passes the membranous part of the urethra; to get a view of which the corpus spongiosum if not already detached must be cut through an inch anterior to the symphysis pubis; dissected carefully from the corpus cavernosum; and turned down on the perineum. The opening at first is not very apparent in consequence of its edges being continued a little distance on the canal, but by detaching them the hole becomes well defined.

Here it becomes necessary to attend to the relative situation of the bulb, and of the membranous part of the urethra. The former has just been described going towards the anus, the latter passes upwards towards the neck of the bladder, they consequently form a considerable angle with each other, and the membranous part of the urethra is much the deeper; the recollection of which is all important in lithotomy, as it teaches us to avoid the one, and to cut into the other. It will



also be observed that the hole in the triangular ligament is an inch below the symphysis pubis.

By dissecting off the upper corner of the triangular ligament, we are made acquainted with another just behind it, which is totally distinct. This ligament is half an inch broad, thick and strong particularly at its lower edge, and is very firmly attached laterally to each pubes just below the symphysis. Mr. Colles calls it pubic ligament, with great propriety; I would suggest, as somewhat more expressive, the term Inter-Pubic ligament, as it serves to distinguish it from another called pubic, which is above the pubes.\* The breadth of this having been stated at half an inch, it is obvious that the hole in the triangular ligament is half an inch below the lower edge of the interpubic.

We have now seen as much as can be viewed advantageously from the perineum at this stage of the dissection, and I recommend an inspection of the parts from above on the side of their abdominal surfaces. The pelvis is therefore to be separated from the trunk at the last lumbar vertebra and the posterior part of the pelvis to be removed, sawing through the os ilium from its crista to the upper margin of the sciatic notch on each side; the os coccygis however must remain in situ, as it is very material to the description of the

\* See Abdominal Muscles.



Levatores Ani muscles. Care must be taken not to injure the rectum in these sections.

Begin by raising the peritoneum from the anterior surface of the rectum, after which by letting the rectum fall backwards and putting the raised peritoneum on the stretch, an excellent view is obtained of the line of attachment of the latter to the lower part of the bladder. It is seen that the peritoneum is reflected from the bladder at the posterior end of the vesiculæ seminales, but that a pouch or process of it is sent down between them which reaches to a short distance from the prostate gland, and that below this process of the peritoneum, a very small space of the bladder lies naked which can be punctured from the rectum, without injuring either the cavity of the peritoneum or the vesiculæ seminales. The upper margin of this pouch next to the bladder forms a strong horizontal doubling stretching across the pelvis, when the rectum is empty.

By distending the bladder moderately, the different reflections of the peritoneum from it to the abdominal parietes and to those of the pelvis will be better understood, and the possibility of puncturing the former above the pubes without getting into the cavity of the abdomen will be demonstrated fully, as well as the freedom with which its neck may be divided in the lateral operation for the stone.

Next strip the peritoneum from the sides of the pelvis, which brings into view the Aponeurosis Pelvica



connecting the bladder to the sides of the pelvis. "This fascia descends from the ilio-pectineal line to about midway in the depth of the pelvis; here it is reflected from the surface of the muscles (the Levatores Ani) and applies itself to the prostate gland and bladder, on the body of which it is ultimately lost. At the angle of its reflection this fascia appears particularly strong and white, but becomes more weak and thin as it lines the muscles and covers the bladder. In tracing this membrane it will be seen, that from the pubes just below the symphysis, a pointed production of it constituting its anterior margin is fixed into the side of the neck of the bladder. This pointed production on each side is called by most anatomists the Anterior Ligament of the bladder. Between the two just beneath the symphysis of the pubes a pouch large enough to receive the end of the finger is formed by the union of the fasciæ of the two sides; this pouch connects the middle anterior part of the neck of the bladder to the lower margin of the symphysis pubis."

A good account of this fascia is published by M. Breschet.\* He says, "that when the aponeurosis which covers the iliac fossa arrives at the internal margin of the iliacus internus and psoas magnus muscles, near the superior strait of the pelvis, it plunges

\*Thesis on Hernia, p. 130, presented to the Faculty of Medicine in Paris for the place of Chef des Travaux Anatomiques, in the year 1819.



into this cavity in order to line its sides, and to cover the muscles which are applied on its several openings. Having got very low down it embraces the rectum, is reflected upon the bas-fond of the bladder, the prostate gland, and in woman upon the vagina. From which cause these viscera may be said to be in part in the cavity of the pelvis, and partly out of it, if we consider this cavity as the space on the outside of the aponeurosis. Some practitioners have observed, that the consequences of the operation of lithotomy are different when the instrument penetrates more or less deeply behind or on the side. Inflammations, suppurations, abscesses in the cavity of the pelvis occur when the instrument is thrust in too much, while no such accidents follow an instrument introduced moderately deep. Some distinguished practitioners\* have asked the reason of these differences, and I believe that I have found them in the arrangement of the aponeurosis pelvica. If the instrument does not penetrate beyond this fascia, there is no abscess in the pelvis, or if a small quantity of pus be formed, it readily finds an issue externally. On the contrary, if the pelvic aponeurosis be injured, inflammation develops itself, suppuration takes place beyond this aponeurotic barrier, the liquid cannot get out; and it makes ravages which sometimes cause the death of the patient."

This description of the aponeurosis pelvica is true,

\* Scarpa's Memoir on Hawkins' Gorget.



but rather too general; the most common condition of it is found to be as follows. It adheres closely to the periosteum of the pubes between the upper margin of the thyroid foramen and the crista of the pubes; about the middle third of the linea innominata it is obviously a continuous membrane with the iliac fascia, but behind this again it arises from the remaining third of the linea innominata.

The portion of this fascia which Mr. Colles speaks of as particularly strong and white, forms a bow, the concavity of which looks upwards, one end of the bow being fastened to the pubes above the foramen thyroideum, and the other end to the ischium above its spine. The perineal surface of this bow is an important point of the origin of the levator ani. Above the bow this fascia is very thin, for the fibres of the obturator internus can be readily seen through it.

At the bow this fascia divides into two laminæ, one having the course to the bladder and rectum indicated, the other covers the lower part of the obturator internus muscle and constitutes the obturator fascia. The levator ani is interposed between the laminæ. The aponeurosis pelvica also forms a bow or semilunar edge in front of the sacral nerves.

The Levator Ani muscle is essentially connected with the aponeurosis pelvica. In order then to get a view of it, make a cut through the fascia, from the symphysis pubis backwards to the sciatic notch about half an



inch above the middle of the fascia. As the muscle is placed nearer to the perineum, the fascia must be turned down towards the bladder as low as possible, the upper surface of the muscle is thus exposed, and also the manner in which it may be said to arise, particularly at its posterior part from the under or perineal surface of the fascia.

The Levator Ani muscle arises fleshy from the back of the pubes near its symphysis, and from near the superior margin of the foramen thyroideum above the obturator internus muscle. It also arises from the aponeurosis pelvica, where this membrane is extended as a thickened semilunar chord from the superior margin of the thyroid foramen to the spinous process of the ischium. This second part of the origin of the levator ani is defectively described in most books on anatomy. It is then seen to cross obliquely, as far as the spine of the ischium, that portion of the obturator internus which arises from the plane of the ischium.

From this extensive origin the fibres converge, descend backwards, and have three distinct places of insertion; the posterior fibres are inserted into the two last bones of the os coccygis; the middle, and by far the greater number are inserted into the semi-circumference of the rectum between its longitudinal fibres and the circular fibres of the sphincter ani; and finally, the most anterior fibres pass obliquely downwards and backwards on the side of the vesical end of the membranous part of the urethra, and on the side of the prostate gland,



and are inserted into the common point of the perineal muscles. These insertions of the levatores ani, to be well understood, must be studied both from the perineal and abdominal surfaces.

It yet remains to speak more definitively of the Triangular Ligament ; it has been seen from the perineum, and is now to be viewed from the pelvis. Remove the anterior part of the levatores ani; the ligament is then seen occupying the interval under the symphysis and between the rami of the pubes and ischia. Its base or inferior edge is crescentic ; and half an inch above the base, is the hole for the membranous part of the urethra. This hole is, in fact, not very distinct, for the triangular ligament is reflected backwards from its edges along the membranous part of the urethra, which obscures the hole. The prostate gland also gets a ligamentous capsule from a continuation of this same reflection, and is thereby very firmly fixed in its place.

The edges of the triangular ligament, fastened to the side of the pubic arch, are continuous with the fascia covering the obturator internus muscle. The triangular ligament is a membrane consisting of two laminae ; the bulb of the urethra is fastened to the anterior lamina, and the prostate is fixed to the posterior lamina ; between these laminae above, is the interpubic ligament, and several blood-vessels derived from the vena ipsius penis.

Mr. Colles says: " if we attempt, in conformity to the



custom of anatomical writers, to describe all these continuous fasciæ which connect the bladder and urethra to the pubes, as productions of one and the same fascia, we might say that the triangular ligament, by its outer edges, is fixed into the rami of the pubes and is there continuous with the ligament lining the obturator muscles, that the edge of the opening for receiving the membranous portion of the urethra is produced backward along the prostate, and having ascended as high as the arch of the pubes, it there splits into two laminae, one continuing its course over the upper surface of the gland and bladder, the other lining the upper portion of the levator ani."

The description of the fasciæ of the pelvis is one of the most difficult and perplexing in the whole range of anatomy, and the proof of it is, that almost every writer on the subject considers the labours of his predecessors imperfect, and, with a very laudable spirit, hoping to supply the defect, invites the attention of the profession to his improved views. Not joining in this conviction, of the insufficiency of preceding descriptions, and the consequent value of such as are offered as substitutes, I feel satisfied in drawing materials from Mr. Colles's excellent work on Surgical Anatomy.



## PART II.

### CHAPTER IV.

#### OF THE ORGANS IN THE FEMALE FOR THE GENERATION AND NOURISHMENT OF THE INFANT.



#### SECTION I.

##### *Of the Female Pelvis.*

THE viscera of the female pelvis should be first studied in their natural situations ; they should then be removed and dissected neatly for more satisfactory examination. The whole study may afterwards be concluded with a side view, as in the male subject.

The Female Pelvis contains the Urinary Bladder and Rectum, besides the Organs of Generation. The two first do not demand particular description here, as enough has been said concerning them in the account of the male pelvis. The Organs of Generation are situated between them, and consist of the Vulva exter-



nally, of the Vagina in the middle, and of the Uterus with its appendages internally.

Under the term Vulva we consider the Mons Veneris, the Labia Majora or Externa, the Labia Minora or Interna, the Clitoris, the Vestibulum, the orifice of the Urethra, the Fourchette, and the Fossa Navicularis.

### *Of the Vulva.*

The MONS VENERIS is an eminence on the fore part of the pubes which is produced by the deposit of a great quantity of fat under the skin. In very corpulent women its size is occasionally enormous. The skin covering it, at the age of puberty, is studded with hair, and under it, is a considerable number of sebaceous glands.

The Labia Externa are oblong eminences, continued downwards and backwards, one on each side, from the mons veneris, and unite with each other by the fourchette at the anterior part of the perineum. They are produced in the same way with the mons veneris by a deposit of adipose matter beneath the skin or integuments; they are broader and more prominent above than below. On the side which looks to the thighs they are formed by the common skin, furnished sparingly with hairs; but on the internal face the integument is a mucous membrane, being a continuation



of that of the vagina. These bodies have many sebaceous glands externally, and mucous orifices internally on them. In their interior structure much cellular membrane, like that of the scrotum, is found possessed of great extensibility in order to favour the dilatation of the parts in parturition. Between them is a longitudinal rima about twice the length of the orifice of the vagina for favouring still more the expulsion of the foetus. It is the *Fissura Vulvæ* of authors.

The *CLITORIS* is a small body situated between the upper extremities of the labia externa on the lower part of the symphysis pubis, and corresponding with the male penis. It is furnished with a suspensory ligament, and curved towards the urethra. It consists of a body and of two crura; the body is about an inch long, and the crura being of the same length, arise from the internal faces of the crura of the pubes. It is covered by an elastic ligamentous membrane; has an internal spongy body capable of erection like the penis, divided by a septum pectiniforme, and having a similar supply of blood-vessels and of nerves. It has also an erector clitoridis muscle lying upon each crus and extended to the side of its body in the same way with the erector penis.

The extremity of the body of the clitoris projects into the upper part of the bottom of the rima, and is called its Glans, but does not resemble, in structure, the glans penis. A kind of hood is thrown over it by a



duplication of the integuments of the part, which giving some resemblance to the penis, it is therefore called the Prepuce, (Preputium.) This prepuce is occasionally much elongated and its orifice constricted, so that the secretion from its cryptæ is imperfectly discharged and produces much itching and irritation. Mr. Marjolin relates the case of a Spanish girl of four years, in whom he performed circumcision successfully, in order to free her of a very bad habit to which she was addicted in consequence of this disease.

The LABIA INTERNA, or NYMPHÆ, are two membranous productions passing downwards, one from each side of the prepuce. They arise from the internal sides of the labia majora, are seldom so broad naturally as to project beyond them, and, are wider in the middle than elsewhere; they terminate insensibly about half-way down the orifice of the vagina. They consist of a duplication of the mucous membrane of the part, between the laminæ of which is placed a vascular cellular membrane giving to them, when excited, a somewhat erected condition. In young subjects their vascularity communicates a vermilion tint, which is lost in the progress of life. They are supposed to direct in some measure, the stream of urine; but it is more probable that, as they are effaced during parturition, they are intended to facilitate the enlargement of the vulva.



The VESTIBULUM is the depression at the upper part of the rima, bounded by the clitoris above and the nymphæ laterally; in it are many mucous follicles.

At the inferior part of the vestibulum, about an inch below the glans clitoridis, is the Orifice of the Urethra, (Orificium Urethræ.) It is generally marked by a slight rising or tubercle which is easily distinguished by the sensation of touch alone; its margin is often bounded by a little caruncle on each side. The urethra itself is an inch long, larger and much more dilatable than that of the male; its course is obliquely downwards and forwards from the neck of the bladder; passing under the symphysis of the pubis, and being slightly curved from that cause. It consists of two membranes a lining and an external one. The lining membrane is a continuation of that of the bladder; is thrown into several longitudinal folds, and has many mucous follicles in it. The external coat of the urethra consists of condensed laminated cellular membrane, forming a cylindrical body of half an inch in its transverse diameter, which has given the idea of the existence of a prostate gland in the female. The lower and lateral surfaces of this cylinder are in contact with the vagina forming a protuberance into its cavity, and the upper surface is firmly connected to the triangular ligament of the pubes.

The FOURCHETTE, or FRENULUM VULVÆ, is situated



at the inferior junction of the labia externa; it is a narrow duplicature of skin extending across the vulva from one side to the other, and is, most frequently ruptured at the first parturition and disappears. That portion of the rima, betwixt it and the orifice of the urethra, is called, by many anatomists, the Fossa Navicularis.

### *Of the Vagina.*

The VAGINA is the intermediate part of the sexual organs, and extends from the Vulva to the Uterus, being placed between the Bladder and Rectum, and compressed anteriorly and posteriorly by them. In virgins its external extremity is contracted into a smaller canal than the internal, and besides this, is closed by a membrane called the Hymen.

The HYMEN, situated just within the orifice of the vagina, is a partial septum formed by a reflection or duplicature of its lining membrane; it varies very much in shape, breadth and thickness. Most commonly it is crescentic and fixed to the inferior part of the vaginal orifice by its convex edge, the horns being upwards; in other cases it is to the side. Sometimes it is a circular membrane having a hole in the centre. It is generally so weak that it is ruptured at the first act of copulation, but occasionally so resisting that it has required artificial division to make it yield even to the



expulsive efforts of the uterus in parturition. Its presence then is not invariably a proof of virginity, nor is its absence a proof of improper indulgence.

The vagina is a membranous canal of from four to six inches in length, differing according to age and pregnancy, being much shorter in women who have borne children, than in virgins. Its shape varies somewhat, near the vulva its greatest diameter is vertical, but behind near the uterus the greatest diameter is transverse. Its anterior and posterior surfaces are in contact from the circumstances just mentioned of pressure between the bladder and the rectum. It is shorter before than behind, corresponding in this respect with the pelvis by which it is influenced, and also in consequence of being attached to the uterus higher up on the sacral than on the pubic side.

The peritoneum, in descending from the uterus anteriorly, touches the top of the vagina for a little distance, and is then reflected to the bladder, but posteriorly, nearly the upper half of the vagina has a peritoneal coat, before this membrane is reflected to the rectum. The attachment of the vagina to the bladder is strong and close just about the urethra, but its connexion to the rectum is by rather loose cellular membrane.

It consists of two coats, a fibrous and elastic one externally, and a mucous one internally. The first is of a reddish colour, and seems to be formed of condensed cellular membrane, its fibres not passing in any



determinate direction. Many blood-vessels are found in its structure, and it has an abundance of large venous sinuses surrounding it.

On the anterior part of this coat externally, there is a flat spongy body, (*Corpus Spongiosum Vaginæ*), about one inch broad and a line or two thick, which is placed on its superior and lateral surfaces, covering about one half, or two-thirds of the whole circumference of the vagina. The structure of this body closely resembles that of the *corpus spongiosum urethræ*, and from being very vascular, is subject to distention in its cells during sexual excitement. This body is covered by the *sphincter vaginæ* muscle.

The *Sphincter Vaginæ* arises from the body of the clitoris and the *crus pubis*; forms an expanse of an inch and a quarter around the anterior end of the vagina; and is inserted into a dense whitish substance in the centre of the perineum, common to it, the *sphincter ani* and the *transversi perinei* muscles.

The transverse perineal muscles exist in the female, and have the same circumstances of origin and insertion, but are not so strong as in the male.

Anterior to the *corpus spongiosum* on each side of the vagina, near its middle is frequently a mucous gland, about the size of a garden pea, which is the *Couper's gland* of the female.

To bring into view satisfactorily the internal membrane of the vagina, the canal should be slit up laterally from its external orifice to the uterus; this membrane



being mucous will then be observed as continuous with the mucous membranes of the vulva and uterus. Near the vulva it is of a vermilion tinge, but near the uterus it is grayish with several dark spots giving it a marbled appearance; its thickness diminishes as it recedes from the external orifice.

In females in whom the hymen is ruptured, its remains consist in from two to six small tubercles, the *Carunculæ Myrtiformes*. On its anterior or pubic wall the internal surface of the vagina is divided longitudinally by a ridge, commencing in a sort of tubercle, at the anterior orifice of the vagina just under the meatus urinarius; this ridge proceeds backwards, but becomes indistinct in approaching the uterus; from it on each side proceed transverse ridges or folds of the mucous membrane, which are particularly numerous and prominent before, but become indistinct and irregular near the uterus. The inferior side of the vagina has the same sort of arrangement as the superior, only not so well marked.

By cleaning the vagina and suspending it in water an abundance of mucous cryptæ may be observed on its whole internal surface, which by an increased discharge produce leucorrhœa.



*The Uterus and its Appendages, the Fallopian Tubes  
and Ovaria.*

The Uterus is a compressed pyriform body with a cavity in its centre, placed between the bladder and rectum, has the small intestines above it, and the vagina below. Unimpregnated it is two inches and a half long, and an inch and a half wide at its broadest part; its anterior surface is much flatter than the posterior. It is divided into fundus, body, and neck. The fundus is the superior convex edge, the neck the narrow part below about an inch long, and the body the portion between these two.

The uterus is maintained in its situation in the centre of the pelvis by the reflections of the peritoneum, which are called ligaments. The peritoneum, after covering the uterus completely is reflected anteriorly upon the vagina, and at each side of this reflection is a fugitive duplicature of the membrane denominated the Anterior Ligament, which goes to the bladder. The peritoneum in passing from the back part of the uterus to the vagina and subsequently to the rectum, has on each side of this reflection also a duplicature, which constitutes the Posterior Ligament. The peritoneum is also reflected from the whole length of each side of the uterus to the corresponding part of the cavity of the pelvis; these reflections are termed the



**Lateral or the Broad Ligaments.** The peritoneum covers much more of the vagina posteriorly, than it does anteriorly.

These Broad Ligaments, with the uterus, form a transverse septum in the middle of the pelvis. At the superior edge of this septum, on each side, is the Fallopian Tube, and on the posterior face of the septum, below the edge, and about an inch or a little more from the uterus, on each side, is an Ovarium. The peritoneum adheres to the uterus by a cellular tissue, which is somewhat loose and can be easily dissected from it.

Besides the ligaments mentioned, the uterus has two more, one on each side, called the Round Ligaments. They arise from the side of its body, between the duplicatures of the broad ligaments, and pass under the peritoneum to the abdominal ring, through which they penetrate, and are lost upon the fat of the mons veneris and of the labia majora. They are of a fibrous structure, and have many blood-vessels in them.

The neck of the uterus is enclosed by the cavity of the vagina, in such a way that it projects into the latter. In the centre of this projection is the Orifice of the Uterus, (*Os Tincæ*,) which is not perfectly cylindrical but somewhat flattened or oval; this orifice is bounded before and behind by the lips or projections of the neck, which are transverse. The posterior lip is somewhat thinner than the anterior, but, in consequence of the insertion of the vagina on that side being



higher up, it projects more into the vagina, and is easily distinguished by the finger.

Behind the *os tinæ* is the Cavity of the Neck, which is a paraboloid cylinder, larger in the middle than at either end; its termination forwards is about the size of a small writing quill, the posterior extremity is somewhat larger. In the middle of this cavity, before and behind, longitudinally, is a line formed by an elevation of the lining membrane, and on each side of this line, transversely or obliquely, there are others presenting an arborescent arrangement. This is the *Arbor Vitæ*. In the interstices of the transverse lines there are small mucous glands called *Ovula Nabothi*, in consequence of this anatomists mistaking them for eggs.

The cavity of the body of the uterus is triangular, the sides of the triangle being curved inwards so as to present their convexities to its cavity. The cavity is nearly equilateral, and has its anterior and posterior surfaces in contact; the angle below is continued into the cavity of the neck, and the angles above are continuous with the fallopian tubes, being extended very far through the parietes of the uterus in order to meet them. This cavity is sometimes divided into two symmetrical halves by an elevated line on its anterior and posterior surface, running from above downwards. It is said, that in some cases, they have had a complete partition.

The internal membrane of the uterus is a continua-



tion of that of the vagina, and adheres so closely that its existence has been doubted. It has very little thickness, is extremely smooth, and presents villosities so fine, that they are seen with difficulty by the naked eye. It is of a light pink colour, which changes into a deeper vermilion a few days before and during menstruation. It abounds with mucous cryptæ and exhalent orifices.

The texture of the uterus is essentially fibrous and of a white colour tinged with red, from having a great number of blood-vessels in its composition. The fibres have no determinate course, but are blended and interwoven in every direction. Its muscularity is not apparent in the unimpregnated state.

The FALLOPIAN TUBES, (*Tubæ Uterinæ*), are two membranous canals fixed, as mentioned, in the upper edges of the broad ligaments. They are about four inches long, somewhat serpentine, and extend from the upper angles of the uterine cavity to the sides of the pelvis. At their uterine extremities these tubes scarcely admit a hog's bristle, but as they proceed externally, about half-way of their length, they begin to increase, and continue to do so very rapidly almost to their termination, where they become somewhat contracted, and immediately afterwards enlarge to end by an oblique trumpet shaped mouth, singularly fringed, called *Morsus Diaboli*, or *Corpus Fimbriatum*. This latter part of the tube is loose and pendulous, over-



hanging the ovarium on the back part of the broad ligament.

The Fallopian Tube seems to be a continuation of the structure of the uterus, having a fibrous membrane externally, and an internal mucous one; the latter is principally concerned in forming its large extremity, and is rendered erectile in sexual excitement, probably by its great vascularity.

The OVARIES, (*Ovaria*, *Testes Muliebres*,) are situated one on each side of the uterus, and on the posterior face of the broad ligament enclosed in a duplicature of it. They are compressed ovoids about half the size of the testicle, of a very light pink colour; are connected to the uterus by a small, vascular, and fibrous chord, called Ligament of the Ovary, which is inserted into the uterus just below the fallopian tube. The external end of the ovary has one of the processes of the corpus fimbriatum or *morsus diaboli* adhering to it.

The surface of the ovary is generally found somewhat uneven, from a number of marks resembling cicatrices. It has a complete peritoneal coat, and within this is another of a strong, compact, fibrous character, sending many processes internally, and which is the tunica albuginea.

The structure of this body is imperfectly known; a good deal of vascular fibrous matter enters into its composition, containing from fifteen to twenty vesicles



of various sizes, from the head of a small pin to a French pea. The parietes of these vesicles are very thin, transparent, and vascular, and contain an albuminous light coloured fluid.

The Bladder and Rectum, with unimportant exceptions, are the same in both sexes. The arteries of the viscera of the pelvis, in both cases, are derived from the internal iliacs.

The Levator Ani, Coccygeus, and Sphincter Ani muscles have the same arrangement as in males.

The Fasciæ connecting the bladder to the sides of the pelvis, and the triangular ligament of the urethra also exist.



## SECTION II.

### *Of the Female Mammæ.*

THE Mammæ are two glandular bodies, situated over the thorax, upon the great pectoral muscles between the arm-pits and the sternum, and intended, in the female, for the secretion of milk. They are hemispherical, and vary much in size, according to the age of the person and the state of the uterine system.

The skin which covers the mamma is very fine and thin, and through it may be seen readily the veins



which creep beneath it. It is very extensible, but does not possess much power of contraction. Beneath the skin, between it and the surface of the gland, there is an abundance of cellular substance intermixed with lobules of fat, which together make a greater volume of matter than the gland itself. The exterior surface of the gland is rendered very unequal, by being penetrated at different depths by this cellular and adipose matter, and its lobules are divided by irregular fossæ from each other. The substance of the gland is united to the pectoralis major muscle, by a loose cellular tissue, which contains very little fat.

The mamma is composed of lobes of different sizes, united together in such a way by cellular texture, that they cannot be separated without injury to them. These lobes are composed of Lobuli, which again are formed by granuli of a white colour tinged with red. These granuli are the size of a millet-seed, and according to some anatomists, consist of vesicles which are very apparent by the aid of a microscope, in a gland filled with milk.\*

The roots of the excretory vessels, or the lactiferous ducts, arise from these grains; they are extremely fine, and unite, after a short course, to contiguous ones, by successive accumulations resembling the branches of a tree; large trunks are finally formed which terminate in still larger, placed in the centre of the gland near the

\* See Marjolin, vol. ii. p. 295.



base of the nipple. All the lactiferous ducts converge from the circumference of the gland to its centre; their course, however is very tortuous; their coats are thin, semitransparent, and very capable of extension and contraction. They are numerous, from two to four of them unite into a common trunk, called sinus, which is only a few lines long, and placed near the base of the nipple. These sinuses are about fifteen in number and are of different diameters, the largest about three lines wide, but others scarcely exceed the diameter of the lactiferous tubes. From the extremity of each sinus arises a small excretory duct, which conducts the milk to the summit of the nipple. This duct is of a conical shape, sometimes dilated in its middle, and is curved and folded upon itself when the nipple is not in a state of erection, by which means the milk is prevented from flowing through it. The sinuses, and these ducts, are united together by condensed cellular membrane; they have no valves, neither have the lactiferous tubes in any part of their course.

An opinion was entertained by Haller, and by many other anatomists after him, that some of the lactiferous ducts originated in the surrounding cellular texture; this has been refuted by the researches of Cuboli. The excretory ducts of the different lobes are, for the most part, kept distinct from each other, there being no anastomoses between them; hence it happens that in the injection of the gland with mercury, it is necessary to inject each milk duct of the nipple separately.



Some anatomists have thought that there is a direct communication between the roots of the lactiferous tubes, and the arteries, veins and lymphatics. Mascagni, after a very successful injection of the gland, in which he filled its vesicles with quicksilver, not meeting with such an occurrence, was induced to think that when such communication did happen it was by rupture.

The AREOLA in virgins, is a rose coloured circle, which surrounds the base of the papilla or nipple. In women who have borne children, or in those whose age is advanced, it becomes of a dark brown. The skin of the areola is extremely delicate, and on its surface, particularly in pregnant or nursing females, there are from four to ten tubercles, which sometimes form a regular circle near its circumference, and in other subjects are irregularly distributed. Each of these tubercles has, near its summit, three or four foramina, which are the orifices of the excretory ducts of a little gland forming the tubercle. From this gland is secreted, according to some, an unctuous fluid for protecting the surface of the areola, while others consider it only as lactescent. The areola consists of a spongy tissue, beneath which there is no fat; it is susceptible of distention during lactation, or from sexual excitement.

The PAPILLA or NIPPLE is the truncated cone in the



centre of the mamma, of the same colour with the areola, and surrounded by it. The milk ducts all terminate on its upper end. It is collapsed and in a very pliable state for the most part, but when excited it swells, becomes more prominent, and of a deeper colour. Its skin is rough, and provided with numerous and very small papillæ. Its internal structure consists merely of the milk ducts, united by condensed cellular membrane.

The mamma is supplied with blood from the external thoracic, intercostal, and internal mammary arteries. Its veins attend their respective arteries. The nerves come from the brachial plexus and the intercostals. Its lymphatics run into the internal mammary and axillary trunks.



## PART II.

### CHAPTER V.

#### OF THE NERVES AND VESSELS OF THE TRUNK.

I HAVE thought it better to give a separate consideration to the nerves and vessels of the trunk, by not involving them with the viscera; because it is the easiest manner of studying them, and such as the student most frequently adopts when left to his own discretion; which alone, is in some measure a proof of its being the most natural and agreeable method. The arteries should be filled with either of the coarse injections; this is less important for the veins, and may be dispensed with.



#### SECTION I.

##### *Of the Nerves.*

THE Phrenic Nerve passes into the thorax from the neck, by the side of the descending cava on the right,



between it and the pleura; it then continues on the side of the pericardium in a direction almost straight, to the diaphragm, going before the root of the lungs. On the left side, with the exception of the descending cava, and of its being turned somewhat out of its way by the projection of the point of the heart, its course is the same.\*

The nerve getting to the diaphragm is spread out in a radiated direction in its muscular wing, both on its upper and lower surface. Anatomists of sufficient respectability report branches from the sympathetic mounting up to the diaphragm, and having their terminating ramifications united with those of the phrenic. Portions of the renal plexus of nerves, are also said to be bestowed on the diaphragm.

The *PAR VAGUM*, before it gives off the recurrent nerve, sends off one or more twigs to join the cardiac plexus, it also contributes to the same when the recurrent nerve is separating from it. From a little below this place, the *par vagum* sends off the *Anterior Pulmonary Plexus*, derived principally from two branches, a large and a small one, which subdivide and go in front of the trachea and of the root of the lungs. The ramifications of this plexus follow generally the bronchia and blood-vessels, into the substance of the lungs, but some of them are turned into the cardiac plexus.

\* For a further account of this nerve see the *NECK*.



The trunk of the par vagum proceeds then on the outside of the bronchia, and a little lower down behind it, then passes in contact with the posterior surface of the root of the lungs. Here it gives off successively five or six branches of different magnitudes, which leave the main trunk almost at right angles, divide and subdivide, and following the bronchia, are spent upon its ultimate ramifications in the lungs. These branches constitute the Posterior Pulmonary Plexus.

After the posterior pulmonary plexus is given off, the par vagum remaining still considerable, attaches itself to the œsophagus, being split into three or four fasciculi which spread out and unite again. From the crossing of the bronchia to the joining with the œsophagus, a great many small ramifications are sent to the œsophagus, forming a plexus on it; some are sent also to the aorta.

The Left Par Vagus is situated on the anterior lateral surface of the œsophagus, and the Right Par Vagus on the posterior lateral surface, each however adhering to its own side, and forming a plexus which partially surrounds the œsophagus. They pass through the foramen of the diaphragm, along with the œsophagus, and their fibres are reassembled into more considerable trunks. The left par vagum is distributed along the lesser curvature of the stomach, between the cardia and the pylorus, to the anterior side of the stomach, to the lesser omentum, and some of its branches extend to the left hepatic and the solar plexus.



The right par vagum surrounds with its branches the cardiac orifice of the stomach, supplies the under side and great curvature, sends branches along the gastric artery to unite with the hepatic and splenic plexuses, and one trunk to the solar plexus.

The SYMPATHETIC, or INTERCOSTAL NERVE, is principally employed in the thorax in supplying the heart. With this view it sends to it three nerves on the right side, and two on the left, called Cardiac.

The Right Superior Cardiac is derived by several filaments from the upper cervical ganglion, joined by some from the superior laryngeal nerve. They unite into one trunk, which accompanies the common carotid on its external surface as far as the middle cervical ganglion; here the trunk divides, one part of it and the smaller, running along the carotid and arteria innominata to the aorta, the other joining a plexus just below the middle cervical ganglion.

The Middle or Great Cardiac Nerve arises from the inferior part of the middle cervical ganglion, passes along the external surface of the carotid artery, and crosses the subclavian in front just at its root, it then goes along with the arteria innominata for a little distance, and terminates in the upper part of the cardiac plexus.

The Third or Small Cardiac Nerve comes from the lower cervical ganglion, by several filaments which unite into a smaller number to form a plexus, which



descends behind the subclavian artery, and between the innominata and trachea, to the posterior part of the arch of the aorta.

On the left side the Upper Cardiac nerve originates in the same way as on the right, from the first cervical ganglion and upper laryngeal; attending the common carotid, it is increased by fibrillæ from the sympathetic, between the first and second ganglions. In the upper part of the thorax this nerve is between the carotid and subclavian arteries, and at their roots some of its branches go in front of the aorta and others behind it. The second cardiac nerve of the left side, is derived from the middle and lower cervical ganglions of the sympathetic. Several branches being despatched by the two ganglions, they form a plexus which surrounds the subclavian at the origin of the inferior thyroid and transversalis colli arteries. From this plexus several chords proceed longitudinally behind and before the subclavian artery to the aorta, and here being joined to branches from the upper cardiac nerve, they form a plexus on the anterior and posterior faces of the aorta.

The Cardiac Plexus consists of a very considerable number of nervous filaments, formed by the combination of the cardiac nerves on both sides, with branches sent off from the recurrent nerves and the par vagum. It is placed between the aorta and the trachea and bronchiæ and is fixed in loose cellular and adipose membrane at its upper part. Below, its meshes are



much involved with the glands about the bifurcation of the trachea, and on the aorta its branches lie very close to this vessel, being bound to it by the internal lamina of the pericardium.

Several branches of the plexus wind over to the front of the aorta and pulmonary artery, where they are also confined closely to these vessels by the internal lamina of the pericardium, and are seen to enter into their structure. The cardiac plexus, penetrating from the base of the heart to the root of the aorta, is diffused through the muscular structure of the former, its trunks following the courses of the coronary arteries.

The Sympathetic Nerve, from the last cervical ganglion, proceeds over the head of the first rib, and descends through the thorax in contact with the heads of all the ribs, and exterior to the pleura. At the upper edge of the head of each rib it forms a ganglion, which unites with the intercostal nerve behind it by one or two branches. At the lower part of the thorax it penetrates into the abdomen beneath the crus of the diaphragm; it then proceeds forwards and downwards on the spine between the tendinous crus of the diaphragm and the psoas magnus muscle, and lies on the side of the bodies of the lumbar vertebræ, being near the vena cava on the right side and the aorta on the left. About the middle of the body of each lumbar vertebra, it forms a ganglion which joins by one or



two nervous filaments with the corresponding lumbar nerve, which filaments pass between the bone and the psoas muscle. From the loins, the sympathetic descends into the pelvis on the inner side of the foramina of the sacrum; here also it forms a ganglion corresponding with each sacral nerve, and detaches a filament to join it. Finally the sympathetic terminates on the os coccygis where the ultimate branches of the opposite sides unite.

From several of the upper ganglions of the sympathetic in the thorax, fibrillæ depart which join the posterior pulmonary plexus, and also are distributed in the form of a plexus on the aorta. From the sixth, seventh, eighth, ninth, and tenth thoracic ganglions, branches are sent off, which, descending obliquely on the sides of the vertebræ, unite successively so as to form a considerable trunk, the Great Splanchnic Nerve, which gets into the abdomen through the foramen in the diaphragm for the aorta, or by penetrating the crus. From the tenth, and eleventh dorsal ganglions, filaments are in like manner, successively sent off, which form one trunk that penetrates into the abdomen, through the crus of the diaphragm; this constitutes the Lesser Splanchnic Nerve, which, in part, unites to the great splanchnic nerve, and the remainder goes to the renal plexus.

The Great Splanchnic Nerve, having entered the



abdomen terminates in the Semilunar Ganglion. This ganglion is situated on the crus of the diaphragm, and on the sides of the cœliac and superior mesenteric arteries. It is frequently formed rather by a congeries of small ganglions arranged in a lunated form, than by a single one. These small ganglions are united by a reticular work of nerves, and from them proceeds a very intricate and combined net-work of nervous fibres, called the Solar Plexus.

The Solar Plexus is behind the stomach, above the pancreas, and surrounds with its branches, the cœliac, superior mesenteric, and renal arteries. It is formed from the semilunar ganglions of both sides, and to their ramifications are added some from the par vagum and phrenic nerves. That portion of the solar plexus on the cœliac artery, assumes the name of cœliac, and dismisses ramifications in the course of the gastric, hepatic, and splenic arteries to the viscera supplied by them, as the stomach, liver, pancreas, and spleen.

The Superior Mesenteric Artery has around it the Superior Mesenteric Plexus, which accompanies the arterial branches to the right side of the colon, to its transverse portion, and to all the small intestines. From the inferior part of this plexus, proceeds a detachment in front of the aorta, to the inferior mesenteric artery which supplies the left side of the colon and the rectum.



From the lower part of the solar plexus, arises the Renal Plexus, which surrounds the emulgent artery, and is distributed to the kidney and to the capsula renalis. The renal plexus detaches near the kidney a few fibres, which being joined by others from the first or second lumbar nerves, accompany the spermatic artery, and are therefore called the Spermatic Plexus. In the male they are distributed on the chord and testis, and in the female on the ovarium and fallopian tube.

From the lower part of the renal and solar plexus there preceeds a reticulated structure of nerves in front of the aorta, as low down as its bifurcation. This is joined by fibres on each side from the sympathetic of the loins. It divides, and following the course of the hypogastric artery on each side, is distributed to the bladder, rectum, and vesiculæ seminales of the male, and to the uterus, vagina, bladder, and rectum of females. This is the Hypogastric Plexus, which is further increased by filaments from the sacral parts of the sympathetic.

The other nerves of the trunk consist of the Dorsal, the Lumbar, and the Sacral. Each arises as a solitary trunk from its appropriate spinal ganglion, and very soon divides into anterior and posterior fasciculi. The posterior is distributed to the muscles of the back, but the anterior has a destination not so uniform.

The anterior branches of the dorsal nerves are all



connected to the ganglions of the sympathetic, and, running between the internal and external intercostal muscles, are distributed to the parietes of the thorax and abdomen. The first dorsal nerve joins the axillary plexus. The second sends a branch through the external intercostal muscle, to the axilla, which joins with a branch of the internal cutaneous nerve of the arm, and is supposed, as it also sends a filament to the lower cervical ganglion of the sympathetic, to establish the sympathy between the arm and the heart in angina pectoris. The third dorsal also sends a branch to the axilla.

The upper lumbar nerves are employed upon the integuments of the abdomen, and in the formation of the lumbar plexus which supplies the front of the thigh and leg. The lower lumbar nerves and the sacral, form the sciatic plexus, which supplies the posterior parts of the lower extremity.

The further consideration of the spinal nerves is referred to the Anatomy of the Limbs.



## SECTION II.

### *Of the Blood-Vessels of the Trunk.*

THE course of the aorta, from its origin to its passage through the diaphragm, has already been men-



tioned, (see Thorax;) as well as that a line to subtend the base of its curvature, must be drawn from the sternal extremity of the third rib on the right, to the dorsal extremity of the third rib on the left side. The first branches given off after the coronary arteries, are the Arteria Innominata, the Left Carotid, and the Left Subclavian. The Arteria Innominata is in advance of the others, and divides after an inch or an inch and a half of length, into right carotid and right subclavian. For an exposition of the course of the Carotids, see the article NECK.

The Subclavian Artery, before it passes between the scaleni muscles, sends off five branches: of which the Inferior Thyroid, the Vertebral, and the Transverse Artery of the neck are mentioned in the article Neck. The remaining two, to wit, the Internal Mammary and the Superior Intercostal belong to the trunk.

The Internal Mammary Artery, after its origin, descends immediately, and fixes itself between the pleura and the cartilages of the true ribs, about three fourths of an inch from the outer edge of the sternum; it gets into the abdomen and is distributed finally to the rectus muscle, anastomosing in it with the epigastric artery. It sends a branch which attends the phrenic nerve on the side of the pericardium; it supplies the intercostal muscles, anastomoses with the intercostal arteries and sends some branches to the mamma.



The Superior Intercostal Artery runs across the head of the first and second rib, and supplies the intercostal spaces corresponding to them; it also, sometimes, supplies the third intercostal space.

Below its curvature, in the thorax, the aorta gives off the Œsophageal, the Bronchial, the Posterior Mediastinal and the Intercostal Arteries.

The Bronchial Arteries are vessels intended for the nourishment of the lungs; the right comes from the superior aortic intercostal artery, and the left from the aorta; this arrangement is not uniform, for sometimes both come from the aorta.

The Œsophageal Arteries are five or six in number, and are spent upon the œsophagus, as their name implies; the lowermost descends to the stomach.

The Posterior Mediastinal, as their name indicates, supply the posterior mediastinum and its contents.

The Aortic Intercostals supply, commonly, the ten inferior intercostal spaces. The upper ones have to rise somewhat obliquely to get to their destination, whereas the lower ones pass nearly horizontally. The right are longer than the left, and the œsophagus is in front of them. Each one joins the rib near its tubercle, and keeps at its lower edge, between the internal and external intercostal muscles in the groove of the bone. The first branch is the dorsal, given off near



the spine; which passes to the muscles of the back, and despatches an arteriole through the intervertebral foramen to the medulla spinalis. When the intercostal arrives near the middle of the rib, it sends off a branch which passes near the upper edge of the lower rib. When it has got two-thirds of the length of the rib, it leaves the lower edge to be distributed to the intercostal space and contiguous parts.

The Abdominal Aorta passes almost in front of the vertebræ, being pushed but very little to the left of the median line. It gives off several large branches to the viscera, and at the intervertebral space of the fourth and fifth vertebræ of the loins it divides into the two Primitive Iliacs.

The Phrenic Arteries come from the aorta immediately on the latter emerging between the crura of the diaphragm. They are two in number, and named from their situations, Right and Left; they ramify on the concave surface of the diaphragm. Their origin is subject to variations.

The Celiac Artery, (*Arteria Cœliaca*) is immediately below the phrenic; it is a large vessel about half an inch long, standing from the aorta at right angles, and divides into the Hepatic, Gastric or Coronary, and Splenic Arteries.

The Hepatic Artery goes to the liver through the



capsule of Glisson, and is distributed through this viscus. Near the liver it sends off the Right Gastro Epiploic, which is distributed to the great curvature of the stomach and the contiguous parts.

The Gastric Artery is between the other two; it joins the stomach near the cardia, and proceeds along the lesser curvature to the pylorus, supplying contiguous parts of the stomach.

The Splenic Artery is the largest of the three. It goes tortuously along the upper edge of the pancreas to the spleen; in its course it sends to the stomach the Left Gastro Epiploic, which is spent on its greater extremity and the left side of the greater curvature. From this vessel also are derived the Vasa Brevia of the stomach, and the Arteries of the Pancreas.

The Superior Mesenteric, (*Arteria Mesenterica Superior*) is about half an inch below the cœliac, and is nearly of the same size; it passes downwards under the pancreas and above the duodenum, supplying all the small intestines, the right side of the colon, and its transverse arch. It has a great many anastomoses in it; constituted by a series of arcades, one upon the other, diminishing in size as they approach the intestine. That branch of the artery which supplies the junction of the ileum with the colon, is called *Arteria Ileo-Colica*; that which supplies the right side of the great intestine, is the *Arteria Colica Dextra*; and that which supplies the arch of the colon, is the *Colica Media*.



The Emulgent Arteries, (*Arteriæ Emulgentes*) are two in number, one from each side of the aorta, coming off at right angles from it, and not much inferior in size to the mesenteric. The right is the longest, and passes behind the ascending vena cava. They go to the kidneys and to the capsulæ renales. The arterial distribution from the aorta here is subject to variations, the arteries of the capsulæ renales coming sometimes from the aorta, and on other occasions from the emulgents. There are also several arteries going to the adipose matter in which the kidneys are placed, equally unsettled in their origin.

The Spermatic Arteries, (*Arteriæ Spermaticæ*) arise immediately below the emulgents, one on each side; they are about the size of a crow-quill, and are remarkable for their length. They pass downwards to the testicles, behind the peritoneum, and before the psoæ muscles, not far from the ureters, spermatic plexus of nerves, and spermatic veins. At the internal abdominal ring the spermatic artery meets with the vas deferens, and constituting a part of the spermatic chord is distributed on the testicle in the manner described in the account of that organ. In the female, these arteries go to the ovaria, fallopian tubes, and uterus.

The Inferior Mesenteric, (*Arteria Mesenterica Inferior*) arises below the spermatics; it is much smaller than the superior. Three branches proceed from it,



called the Left Colic Arteries, from their distribution to the left side of the colon, and are distinguished from each other by the terms Superior, Middle, and Inferior. The superior anastomoses with the colica media, forming with it the great Mesocolic Arch. The others supply the sigmoid flexure of the colon, and the part just above it. A branch is continued from the inferior mesenteric to the rectum, constituting the superior Hemorrhoidal artery.

From the centre of the fork formed by the bifurcation of the aorta, there proceeds a small arterial tube, about the size of a crow-quill, called the Middle Sacral from its running down to the os coccygis, just over the middle line of the sacrum. It sends branches on either side towards the foramina in the sacrum.

The Lumbar Arteries, (*Arteriæ Lumbares*) are from three to five in number on either side; they pass off at right angles from the aorta over the sides of the lumbar vertebræ, some of their branches penetrate the intervertebral foramina to get to the medulla spinalis, others pass to the muscles of the back. Besides which, the lower parts of the parietes of the abdomen are supplied by them. They inosculate with the circumflexa ilii, with the epigastric and with the gluteal arteries.



The Primitive Iliacs, (*Art. Iliacæ Communes*) one on each side, are formed by the termination of the abdominal aorta; they extend from the fourth lumbar vertebra to the sacro-iliac junction, opposite to which they divide into two trunks, the External Iliac Artery and the Hypogastric. In this course they give off no collateral branch of any consequence, and are crossed by the ureters.

The Hypogastric or Internal Iliac, (*Arteria Iliaca Interna, or Ramus Hypogastricus,*) gives off several branches, the origins of which differ considerably. The main trunk itself is of various lengths, and is distributed to the viscera of the pelvis and to the muscles on its external surface. Sometimes it is previously divided into two principal trunks, an anterior and a posterior. From it the following branches proceed.

1. The Ilio-Lumbar Artery, (*Arteria Ilio Lumbalis,*) is commonly the first branch of the hypogastric or of its posterior trunk. Arising from its posterior external part, it passes outwardly between the *psoas magnus* and *iliacus internus* muscles, and divides into two branches, one of which is distributed to the loins, and the other upon the *iliacus internus* muscle.

2. The Lateral Sacral Arteries, (*Arteriæ Sacræ Laterales,*) come next, arising by one or more trunks from the hypogastric or one of its large branches; they commonly equal in number the foramina of the sacrum, and passing into them are distributed upon the



inferior part of the cauda equina; they also anastomose with the middle sacral artery.

3. The Obturator Artery, (*Arteria Obturatoria*,) comes from the hypogastric, or one of its trunks, and passes along parallel with the brim of the pelvis; going through the obturator foramen it is distributed to the hip joint, and to the muscles on the upper internal part of the thigh. Its origin is occasionally from the epigastric.

4. The Middle Hemorrhoidal Artery, (*Arteria Hemorrhoidæ Media*,) comes sometimes from the gluteal. It is thus named from its relative position to the upper and lower hemorrhoidal, on the rectum. Besides going to this organ, it supplies the prostate gland and the vesiculæ seminales of the male, and the vagina and bladder in females.

5. The Uterine Artery, (*Arteria Uterina*,) is peculiar to females, and gets to the uterus between the laminæ of the broad ligaments.

6. The Vesical Arteries, (*Arteriæ Vesicales*,) are derived from what was the umbilical artery of the fœtus, and are distributed to the bladder.

What remains of the hypogastric consists in two large branches, the Gluteal and the Ischiatic.

7. The Gluteal Artery, (*Arteria Glutæa*,) passes out of the pelvis at the upper part of the ischiatic foramen above the pyriformis muscle, it is situated in contact with the edge of the bone, and its trunk is accessible from the external parts of the pelvis. Hav-



ing got to its outside, the trunk of the gluteal divides immediately into branches which are distributed upon the gluteal muscles.

8. The Ischiatic Artery, (*Arteria Ischiadica*,) coming from the inferior part of the hypogastric, is situated before the belly of the pyriformis muscle, and issues from the pelvis below its inferior edge and in front of the sciatic nerve. It pursues its course downwards on the back part of the thigh, between the trochanter major and the tuberosity of the ischium, being then at the internal edge of the sciatic nerve. It is distributed to the inferior edge of the gluteus maximus, and to the muscular structure near the sacrum and coccyx; also to the muscles, on the back and upper parts of the thigh.

The Internal Pudic Artery, (*Arteria Pudica Interna*,) arises from the Ischiatic within the pelvis, emerges from the pelvis with the ischiatic, and then returns between the two sacro-sciatic ligaments to the inner side of the tuberosity of the ischium, and continues on the inner side of the ramus of the ischium and of the pubes towards the symphysis. In this course it gives off several branches in the following order. A small branch to lower edge of pyriformis muscle. The Lower Hemorrhoidal Artery to the lower part of the rectum, and to the sphincter ani muscle. To the back part of the scrotum the perineal muscles and the skin it gives



the Perineal Artery, originating near transversus perinei muscle and passing in its direction. Upon the arrival of the internal pubic near the penis, it detaches to this body a branch which penetrates and ramifies minutely through the structure of the corpus spongiosum urethræ. At the symphysis of the pubes it sends off a branch which gets to the dorsum of the penis, and extends longitudinally as far as the glans, being distributed to the elastic ligament, to the integuments, and to the prepuce; this is the *Superficialis Dorsi Penis*. Finally, the terminating branch of the internal pudic penetrates into the corpus cavernosum, passes straight forwards on the septum, and is distributed to the cells, by very minute branches, some of which go to the other side.

The External Iliac Artery, (*Arteria Iliaca Externa*,) seems to be the continuation of the common iliac; it passes along the brim of the pelvis on the inner side of the *psoas magnus* muscle to *Poupart's Ligament*. Here it is about half-way between the symphysis of the pubes and the anterior superior spinous process of the ilium, having the anterior crural nerve on its outside and the external iliac vein on its inside. It gives off no branches till it reaches *Poupart's ligament*, when the *Epigastric* arises from it.

The *Epigastric Artery*, (*Arteria Epigastrica*,) at first passes inwards; it then rises upwards obliquely till it reaches the exterior edge of the *rectus* muscle. Con-



tinuing afterwards to ascend, it is spent upon the anterior parietes of the abdomen by many branches, some of which inosculate with the internal mammary.

The Circumflex Artery, (*Arteria Circumflexa Ilii*,) arises from the external iliac near the epigastric. It runs along the posterior edge of Poupart's ligament to the spinous process of the ilium, thence it continues its course near the internal margin of the crista, being distributed to the iliacus internus muscle. A branch of it, near the spinous process, rises upwards and is spent upon the abdominal muscles. It anastomoses with the *arteria ilio lumbalis*.

### *Veins of the Trunk.*

The Superior Cava, (*Cava Descendens*,) is sufficiently alluded to in the description of the thorax, to render a further notice of it here unnecessary. It receives the blood from the left arm and side of the head, by a trunk (the *vena innominata* formed by the union of the left subclavian and internal jugular vein) which crosses the sternum obliquely a little below its superior edge. This venous trunk, and the corresponding one belonging to the right arm and the right side of the head which descends vertically, constitute in fact by uniting the Descending Cava.

On a horizontal line with the upper edge of the root of the right lung is the point where the descending cava



is joined by the vena azygos. The latter is formed by the union, into one trunk successively, of the ten inferior intercostal veins of the right side. About the sixth dorsal vertebra this trunk is joined by one formed by the successive union of the six inferior intercostal veins of the left side. The trunk of the vena azygos, as stated, is on the right side of the posterior mediastinum, and forms a regular and beautiful arch over the root of the right lung.

The six superior Intercostal Veins of the left, discharge into the left subclavian vein by a common trunk; the two superior of the right side into the descending cava.

The Internal Mammary Vein has nothing very peculiar; it observes the course of its artery, and empties into the subclavian vein near its origin.

The Cava Ascendens is formed in the lower part of the abdomen, by the union of the external and internal iliac veins into the common iliacs, and the subsequent junction of the latter at the fourth lumbar vertebra. This vein ascends on the right of the aorta, receives the Lumbar—the Spermatic—the Emulgent—the Capsular—the Hepatic and the Phrenic Veins and in its course penetrates the right opening of the diaphragm and terminates in the right auricle.

Each artery of the pelvis has its corresponding vein; it is therefore unnecessary to describe the latter, ex-



cept in regard to peculiarities. About the neck of the bladder, vesiculæ seminales, and the base of the prostate there is a considerable accumulation of veins forming a very vascular plexus; they come originally from the vena ipsius penis and from the proper vesical veins.

The several veins of the pelvis derived from the ischiatic, gluteal, and internal pudic arteries, &c. accumulate at the sacro-iliac junction into one trunk, the Internal Iliac, which ascends by the side of the hypogastric artery and joins the external iliac vein.

The ascending cava is joined, at its fork, by the middle sacral vein and above it, by the lumbar veins on each side. The right spermatic vein discharges into the ascending cava, but the left into the emulgent of that side. The emulgent and capsular veins correspond with the arteries, the right being shorter than the left, from the position of the vena cava. The left emulgent vein is in front of the aorta.

The ascending cava is next joined by the hepatic veins which have been mentioned, and lastly, by the phrenic.

The Venous Trunks, derived from the superior and inferior mesenteric arteries and from those of the cœliac which do not go to the liver, as the splenic and gastric, form that large trunk the vena portarum, the history of which is given in the account of the Liver.



## SECTION III.

*The Thoracic Duct, (Vas Chyliferus.)*

THE common trunk of the absorbent system commences most commonly at the second or third lumbar vertebra, in front of its body, by the union of the absorbent vessels of the lower extremities, pelvis, and intestines. This vessel immediately after its formation, is sometimes subjected to a dilatation of various shapes and lengths, called the Receptaculum Chyli; after which it proceeds regularly upwards in front of the vertebra, between the vena azygos and the aorta, to the upper part of the thorax. It passes between the crura of the diaphragm, and for some part of its course, is immediately behind the œsophagus. At the fourth dorsal vertebra it begins to incline to the left, and preserving that direction, it gets into the neck as high as the upper edge of the seventh cervical vertebra and just to its left side. Here it forms an arch, which descends forwards and outwards in front of the subclavian artery, between the internal jugular vein and the scalenus anticus muscle; and then terminates by an orifice protected by two valves, in the fork formed by the junction of the left internal jugular and subclavian veins.

Several interesting varieties occur in the vas chy-



liferus; sometimes two trunks are formed originally on the lumbar vertebræ, which run parallel with each other, and then unite at the lower dorsal vertebra. The thoracic portion of the duct varies in size and continuity, being divided once or oftener into two trunks, which unite again, and being also contracted at particular points. The cervical, or terminating portion of the duct is occasionally divided into two tubes which have separate orifices. There is a very good plate in Caldani, representing the occasional terminations of the lymphatic trunks in the region of the neck; in this plate the thoracic duct empties after a considerable dilatation, into the internal jugular vein, about an inch above its junction with the subclavian; and the lymphatics of the left side of the head and neck, form two trunks, which discharge separately, into the convex side of the Thoracic duct; the lymphatics of the left upper extremity form a trunk, whose orifice is in the subclavian vein, about an inch below its junction with the internal jugular.

The lymphatics of the right arm, lung, right side of the neck and head, converge towards the junction of the right subclavian and internal jugular by four trunks, and then unite into one, which discharges itself at the posterior face of this junction. The venous orifice of this Trunk, like that of the Thoracic Duct, is secured from a regurgitation of blood by one or more valves.



## PART II.

### CHAPTER VI.

#### OF THE MUSCLES OF THE BACK.

MAKE an incision through the integuments from the lower part of the occiput to the os coccygis, directly over the spinous processes of the vertebræ. Make a second incision from the upper end of the first, to the lobe of the ear. Make a third cut through the integuments from the acromion process to the posterior fold of the arm-pit. Lastly, make a cut horizontally from the acromion process to the spine.

Begin the dissection at the last cut, and raise the upper, and then the lower flap, in the direction of the muscular fibres, as they make their appearance. In this manner is exposed the two most superficial muscles of the back, the Trapezius and the Latissimus Dorsi.

The **TRAPEZIUS** is a beautiful broad muscle, immediately under the skin, covering the back parts of the neck and thorax, and extending from the bottom of the latter to the top of the former. Its anterior edge



above, is parallel with the posterior edge of the sternocleido-mastoideus. Its posterior edge is joined with that of its fellow, and below, it overlaps the latissimus dorsi in part.

It arises from the occipital protuberance, and from eight or ten lines, sometimes more, of the upper semicircular ridge of the occiput, by a tendinous membrane. It arises also from the five superior spinous processes of the neck, through the intervention of the Ligamentum Nuchæ, and tendinous from the two lower spinous processes of the neck, and from all of the back.

It is inserted fleshy into the external third of the clavicle, tendinous and fleshy into the acromion process, and into all the spine of the scapula. Its fibres having a very extended origin must of course converge in getting to these insertions; the upper fibres descend, the lower ascend, and the middle are horizontal.

It draws the scapula towards the spine. In the cervical portion of these muscles, formed by the origins of both muscles united, is an elliptical expanse of tendon lying over the ligamentum nuchæ, and extended on each side. The ligamentum nuchæ itself, is a vertical septum of ligamentous matter, extending from the central line of the occipital bone, to the spinous processes of all the vertebræ of the neck. At its upper part, where the spinous processes of the neck are



short, this membrane is very broad, and divides completely the muscles of the two sides of the neck from each other.

The *LATISSIMUS DORSI* is situated under the skin at the lower part of the back, so as to cover its whole posterior portion. It arises by a thin, tendinous expanse, from the seven inferior spinous processes of the back, and by a thick tendinous membrane from all those of the loins and sacrum. This membrane is the fascia lumborum, is common to several of the muscles which have their origin in this region, and extends along the iliac margin of the sacrum, so as to arise also from the posterior third of the spine of the ilium.\* Besides these origins, the latissimus dorsi has three or four fleshy heads from the sides of the three or four inferior false ribs, which are interlocked with the inferior heads of the obliquus externus abdominis.

From this extended origin the fibres converge, so as to form the posterior fold of the axilla, and to terminate in a flat, thick tendon, of two inches in breadth, which is inserted into the posterior ridge of the groove of the os humeri. The upper part of this muscle passes over the inferior angle of the scapula, and derives a fasciculus of fibres from it.

\* This origin frequently is tendinous at the back part of the ilium, and fleshy in front.



It draws the os humeri downwards and backwards.

Detach now the trapezius from its origin and turn it over the shoulder. Begin also to detach the latissimus dorsi from its origin above, turning downwards the upper edge of the muscle as the separation goes on. By doing so, in a little time is brought into view the upper edge of the

**SERRATUS INFERIOR POSTICUS.** The origin of this muscle is inseparably united to that of the latissimus dorsi, therefore to view it properly, let the fleshy part of the latissimus be detached from the fascia lumborum. We shall then see that the serratus arises by a tendinous membrane from the two inferior spines of the back, and the three superior of the loins.

It is inserted by fleshy digitations into the under edge of the four inferior ribs.

It draws the ribs downwards, and is an antagonist to the diaphragm in some respects, but more particularly to the serratus superior posticus.

The removal of the trapezius above, brings into view several muscles, the most superficial of which are the rhomboid, there being two together looking very much like one.

The **RHOMBOIDEUS MINOR** is above. It is a narrow muscle which arises by a thin tendon from the three inferior spines of the neck, and passing obliquely



downwards, is inserted into the base of the scapula opposite the origin of its spine.

The **RHOMBOIDEUS MAJOR** arises also by a thin tendon from the last spine of the neck, and from the four superior of the back, and is inserted into all the base of the scapula below its spine.

These muscles draw the scapula upwards and backwards. Detach them from their origins, which shows next,

The **SERRATUS SUPERIOR POSTICUS**, arising by a thin tendon from the three inferior spines of the neck and the two superior of the back, and inserted into the second, third, fourth and fifth ribs by tendinous and fleshy slips, a little beyond their angles.

This muscle draws the ribs upwards. A good view of the serratus major anticus where it is inserted into the base of the scapula, and of its situation between the thorax and scapula, is obtained at this stage of the dissection. The muscle itself, in consequence of arising on the anterior lateral parts of the thorax, has been considered in the remarks preliminary to the study of that cavity.

The **LEVATOR SCAPULÆ** is placed between the posterior edge of the sterno-cleido-mastoideus and the ante-



rior of the trapezius; its lower end is just above the Rhomboideus Minor. It arises by rounded tendons from the three, four or five superior transverse processes of the neck, between the scaleni muscles and the splenius colli.

It is inserted fleshy into that part of the base of the scapula above the origin of its spine. As its name expresses, it draws the scapula upwards. A good view of this muscle may be obtained in the front dissection of the neck.

The SPLENIUS muscle comes next; its inferior extremity is under the serratus superior, but the principal part of it is covered by the trapezius. It arises from the spinous processes of the five inferior cervical and of the four superior dorsal vertebræ.

It is inserted into the back of the mastoid process and a small part of the adjacent portion of the os occipitis, and also into the transverse processes of the two superior cervical vertebræ. It is customary to consider the part which goes to the head as Splenius Capitis, and the part below as Splenius Colli; the latter, in that case, is said to arise from the third and fourth dorsal vertebræ. It draws the head and neck backwards.

Between the spinous processes of the vertebræ and the angles of the ribs, on either side, there is a deep fossa filled up by muscles, some of them large and



powerful; the most striking are the *Sacro Lumbalis* and the *Longissimus Dorsi*.

The *SACRO LUMBALIS* and *LONGISSIMUS DORSI* have a common origin from the back of the pelvis and of the lumbar vertebræ, and extend to the top of the thorax. They arise, tendinous externally, and fleshy internally, from the posterior surface of the sacrum by its external margin and spinous processes; they arise also, tendinous from the spinous processes, and fleshy, from the ends of the transverse processes of all the vertebræ of the loins and from the posterior part of the spine of the ilium. From the under surface of this common belly, two tendinous and fleshy heads are inserted into the inferior edge of the transverse process of each lumbar vertebra, the smaller near its root and the larger near its extremity. On a level with the lowest rib, and, indeed, somewhat below it, a fissure occurs in the muscle which divides it into the two parts.

The *Longissimus Dorsi* is nearest the spine; it is inserted, by small double tendons proceeding from its internal surface, into the ends of the transverse processes of all the vertebræ of the back, except the first. It also, from its outer edge, sends long slender tendons by which it is inserted into the under edges of all the ribs near their angles, except the two inferior.

The *Sacro Lumbalis* is inserted from its outer edge into all the ribs at their angles, by long and thin ten-



dons, which are longer, the higher they are inserted.

By turning over this muscle from the other, towards the ribs, one may see coming from the eight lower ribs, as many slips, which run into the under surface of the sacro lumbalis; they are the *Musculi Accessorii ad Sacro Lumbalem*.

These two muscles keep the spine erect, and draw down the ribs.

Between the ends of the spinous processes and the edge of the *longissimus dorsi*, is a muscle almost entirely tendinous, and scarcely to be distinguished from the latter, both in consequence of its close connexion with it and of its insignificant size. At its lower part it is absolutely a portion of the *longissimus*, and can be separated from it only by an unnatural division. It is a mere string lying along the sides of the spinous processes, and is called from its origin and insertion, the *Spinalis Dorsi*.

The *SPINALIS DORSI* arises tendinous from the spinous processes of the two superior lumbar, and of the three inferior dorsal vertebræ, and is inserted tendinous into the spinous processes of the nine superior dorsal vertebræ, except the first.

It tends to keep the spine erect. Turn now the splenius from its insertions, which exhibits several muscles under it.



The **CERVICALIS DESCENDENS** is a small muscle placed at the upper portion of the thorax, between the insertions of the *sacro lumbalis*, and of the *longissimus dorsi* into the upper ribs; it looks, at first, very much like a continuation or appendix of the first, running to the cervical vertebræ.

This muscle arises from the upper edges of the four superior ribs by long tendons; it forms a small belly, which is inserted into the transverse processes of the fourth, fifth and sixth vertebræ of the neck, between the *levator scapulæ* and *splenius colli*, by three distinct tendons.

It draws the neck backwards.

The **TRANSVERSALIS CERVICIS** is on the inner side of the last and in contact with it, being about the same size, and having very much the same course and appearance. It is considered as an appendage to the *longissimus dorsi*.

It arises from the transverse processes of the five superior dorsal vertebræ by distinct tendons, and forms a narrow fleshy belly, which is inserted by distinct tendons also, into the transverse processes of the five middle cervical vertebræ. It draws the head backwards.

The **TRACHELO MASTOIDEUS** is at the inner side of the last muscle, in contact with it.

It arises, by distinct tendinous heads, from the



transverse processes of the three superior vertebræ of the back, and of the five inferior of the neck, and is inserted by a thin tendon, into the posterior edge of the mastoid process.

The dorsal origins are frequently deficient or irregular. It draws the head backwards.

The **COMPLEXUS**, a fine, large muscle, is situated at the inner face of the trachelo-mastoideus, and is readily recognised by showing itself between the bellies of the two splenii capitis, just below the occiput. A quantity of tendinous matter exists in its middle, which gives it the complicated appearance from whence its name is derived.

It arises, by tendinous heads, from the seven superior dorsal, and the four inferior cervical vertebræ by their transverse processes; also by a fleshy slip from the spinous process of the first dorsal. It is inserted into the inferior part of the os occipitis by the surface between the upper and lower semicircular ridges, and on the outside of the vertical ridge which exists in the middle of the bone.

It draws the head backwards.

The **SEMISPINALIS COLLI** is a muscle which passes obliquely from transverse to spinous processes, and is situated between the **complexus** and the **multifidus spinæ**; the course of its fibres renders it difficult to be distinguished from the latter.



It arises from the transverse processes of the six upper vertebræ of the back, by tendons which are involved with those of the adjacent muscles, and passes up the neck, to be inserted into the sides of the spinous processes of the five middle cervical vertebræ.

It extends the neck obliquely backwards.

The *SEMISPINALIS DORSI* is lower down on the spine, and with difficulty distinguished from the multifidus. Like the other, it passes from transverse to spinous processes, and lies under the *longissimus dorsi*, between it and the multifidus.

This muscle arises by tendons connected with those of the other muscles, from the transverse processes of the seventh, eighth, ninth, and tenth dorsal vertebræ, and passes upwards obliquely, to be inserted, tendinous, into the sides of the spinous processes of the two lower cervical, and five upper dorsal vertebræ.

It draws the spine obliquely backwards.

The *MULTIFIDUS SPINÆ* lies under the muscles as yet mentioned, close to the bones of the spine; in order to see it well, they, therefore, should all be cut away.

It has its commencement, tendinous and fleshy, on the back of the sacrum, being connected to its spinous processes and posterior surface, also to the back part of the spine of the ilium. It there forms a belly of sufficient magnitude to fill up much of the cavity between the spines of the sacrum and the posterior part of the



ilium. It arises also from the roots of the oblique and transverse processes of all the vertebræ of the loins, of the back, and of the four inferior of the neck.

The multifidus is inserted, tendinous and fleshy, into the roots and sides of the spinous processes of all the vertebræ of the loins, of the back, and of the five inferior of the neck.

This muscle consists of a great number of small bellies, which are parallel to each other, each arising from a semicircular process, and going to the spinous process either of the first or second vertebra above it.

It twists the spine backwards and keeps it erect.

Between the head, and the first and second vertebræ, and between the two latter, there are, on each side, four small muscles, intended for the motion of these parts upon each other. They are brought into view by the removal of the complexus.

The **RECTUS CAPITIS POSTICUS MAJOR** arises tendinous and fleshy, from the extremity of the spinous process of the dentata, and is inserted into the inferior semicircular ridge of the os occipitis, and part of the surface below it.

Its shape is pyramidal, the apex being below. It turns the head, and also draws it backwards.

The **RECTUS CAPITIS POSTICUS MINOR** is at the internal edge of the first. It arises tendinous from the



tubercle on the back part of the first vertebra, and is inserted into the internal end of the inferior semicircular ridge of the os occipitis, and into part of the surface between it and the foramen magnum.

It is also pyramidal, with the apex downwards. It draws the head backwards.

The **OBLIQUUS CAPITIS SUPERIOR** arises from the transverse process of the first cervical vertebra, and is inserted into the inferior semicircular ridge of the os occipitis, behind the posterior part of the mastoid process and beneath the complexus muscle.

It draws the head backwards.

The **OBLIQUUS CAPITIS INFERIOR** arises from the side of the spinous process of the dentata, and is inserted into the back part of the transverse process of the first vertebra of the neck.

It rotates the first vertebra on the second.

The **INTERSPINALES** are small short muscles, placed between the spinous processes of contiguous vertebræ. In the neck they are double, in consequence of its spinous processes being bifurcated; in the back they are almost entirely tendinous; in the loins they are single and well marked.

They draw the spinous processes together, and keep the spine erect.



The *INTERTRANSVERSarii* are also short muscles placed in a similar manner, between the transverse processes of the vertebræ. In the neck they are double, in the back they are small, tendinous, and not well marked, and in the loins they are single and readily seen.

They draw the transverse processes together, and will, of course, bend the spine to one side.

The *LEVATORES COSTARUM* are small muscles concealed by the *sacro-lumbalis* and *longissimus dorsi*, and pass from the transverse processes of the last cervical and the eleven superior dorsal vertebræ, to the upper edges of all the ribs. They are twelve on either side of the spine, are tendinous in their origins, and insertions, with intermediate muscular bellies.

The upper ones are small and thin, and they increase in magnitude as they descend. From the inferior edge of nearly all these muscles a fleshy slip is detached, which passes over the rib next below its origin, to the second rib below, and occasionally to the third. These slips are called *Levatores Costarum Longiores*. The others which descend from the transverse process to the rib next below, are called *Levatores Costarum Breviores*.

These muscles are parallel in their obliquity, with the external intercostals, and are not very obviously separated from them. They perform the same service, that of elevating the ribs.








## PART III.

### OF THE EXTREMITIES.



### CHAPTER I.

#### OF THE UPPER EXTREMITIES.



#### SECTION I.

##### *Of the Fascia.*

THE Upper Extremity, consisting of shoulder, arm, fore-arm and hand, has not so regular, or so strong an investment of fascia as the thigh. On the shoulder, excepting its back part, and on the arm, this envelope has but few ligamentous fibres in it, and is principally condensed cellular membrane, but in the fore-arm its character is better developed, and is there decidedly



aponeurotic. The aponeurosis of the fore-arm forms a complete sheath for its muscles. It is connected with the bony prominences at the elbow joint, more particularly the external and internal condyle and the ridges leading to them by processes called intermuscular partitions or septa; with the ulnar side of the tendon of the biceps muscle, and the olecranon process of the ulna; it then passes down to the carpus, where it terminates both anteriorly and posteriorly in the annular ligament of the wrist. It is attached to the ulna along its internal margin, from the elbow joint to the wrist and several muscles arise from its interior surface. It is unnecessary to undertake, from the first, a regular dissection of this fascia, inasmuch as it will be gradually exposed in proceeding with the muscles.

The upper extremity is most conveniently studied by detaching it from the trunk, taking care to leave the clavicle with the former.



## SECTION II.

### *Of the Muscles of the Upper Extremities.*

THE Muscles situated on the shoulder are six in number; they extend, for the most part, from the scapula to the head and neck of the os humeri.



1. The DELTOIDES arises from the inferior edge of the whole spine of the scapula, from the outer margin of the acromion process, and from the exterior third of the clavicle. Its origin, for the most part, is tendinous and fleshy, mixed; but at its posterior part, it is entirely tendinous.

It is inserted by a tendinous point, into the triangular rough surface, on the outer side of the os humeri, near its middle. It raises the os humeri to a horizontal line with the acromion.

The deltoid is situated just beneath the skin, and forms the cushion, which protects and gives rotundity to the shoulder joint. Its general configuration is triangular, and, when spread out, its upper margin being opposed to the insertion of the trapezius, is much more extensive than one would suppose. Its fibres do not converge regularly to its insertion like the radii of a circle; but the whole muscle is divided into several parts; between which, the interposition of intermuscular tendons affects the course of the fibres, makes several portions of the deltoid look penniform, and others like smaller deltoids introduced into the larger.

The deltoid covers the insertion of the pectoralis major, latissimus dorsi, and teres major, besides that of the other muscles of the shoulder. It also conceals the origin of the biceps flexor cubiti and of the coracobrachialis. Its insertion is between the triceps extensor and the biceps flexor, and above the origin of the brachialis internus.



The deltoid should be detached from its origin and thrown down, which gives a good view of the other muscles.

2. The SUPRA SPINATUS arises fleshy from the whole fossa supra spinata which it fills up, and from its margins. Forwards it terminates in a thick robust tendon closely connected with the capsular ligament of the joint, and which passes under the jugum formed by the articulation of the acromion with the clavicle.

It is inserted tendinous into the inner face of the great tuberosity of the os humeri and will assist in raising it.

3. The INFRA SPINATUS arises fleshy from all that portion of the dorsum scapulæ below its spine, from the spine as far as the cervix, and from the several margins of the fossa infraspinata. Its fibres pass obliquely to a middle tendon, which adheres closely to the capsular ligament, and goes under the projection the acromion.

This tendon is inserted into the middle face of the greater tuberosity of the os humeri.

The infraspinatus rolls the os humeri outwards and backwards.

4 The TERES MINOR is situated at the inferior margin of the infraspinatus, in the fossa of the inferior costa scapulæ, and looks very much like a part of



the infraspinatus, to which it occasionally adheres so closely, as to be separated with difficulty. It arises fleshy from the whole of the fossa, from the margins of the inferior costa, and from the cervix of the bone, to within an inch or so of its inferior angle.

It is inserted, tendinous and fleshy, into the outer face of the great tuberosity of the os humeri, just below the infraspinatus.

It draws the os humeri downwards and backwards, and rotates it outwards.

5. The **TERES MAJOR** is situated at the inferior edge of the teres minor. It arises fleshy from the posterior surface of the inferior angle of the scapula, and from a small part of its inferior costa; the interstice between it and the teres minor is considerable.

It is inserted, by a broad tendon, into the posterior ridge of the groove of the os humeri, along with the tendon of the latissimus dorsi. Their tendons, at first, are closely united, but afterwards there is an intermediate cavity lubricated with synovia. The tendon of the latissimus dorsi is anterior, and the lower edge of the teres extends further down the arm than that of the other.

It rolls the os humeri inwards, and draws it downwards and backwards.

6. The **SUBSCAPULARIS** occupies all the thoracic surface of the scapula, being between it and the serratus



major anticus. It arises fleshy from the whole base, superior and inferior costa, and venter of the scapula; it is divided into several columns which look somewhat like distinct muscles, but which all terminate, in a thick robust tendon, that adheres to the inferior surface of the capsular ligament.

This tendon is inserted into the lesser tuberosity of the os humeri. The subscapularis rolls the bone inwards and draws it downwards.

The Muscles of the arm are five in number, three anterior, and two posterior.

1. The BICEPS FLEXOR CUBITI is situated immediately beneath the integuments, and forms the swell so obvious in the middle front part of most arms. It arises by two heads; the first called the long, is a round tendon, which comes from the superior extremity of the glenoid cavity of the scapula, passes through the shoulder joint, and through the groove of the os humeri. The second head arises, tendinous, from the extremity of the coracoid process of the scapula, in company with the coraco-brachialis muscle. The fleshy bellies in which these tendons terminate, unite with each other, a few inches below the shoulder joint to form a common muscle. At first, they are only connected by loose cellular substance, but about half-way down the arm they are inseparably united.

The biceps terminates below in a flattened oval ten-



don, and passes in front of the elbow joint to be inserted into the posterior rough part of the tubercle of the radius. A bursa mucosa is placed between the tendon and the front of the tubercle, the surface of the latter being covered with cartilage. From the ulnar side of this tendon proceeds a fascia running into that of the fore-arm.

The relative position of the biceps is as follows: Its long head is first within the cavity of the capsular ligament, and then between the tendons of the latissimus dorsi and pectoralis major, where it is bound down by strong ligamentous fibres. The tendon below is superficial, and may be easily felt by flexing the extremity; but its insertion dips down between the pronator teres and supinator radii longus.

This muscle flexes the fore-arm.

2. The CORACO-BRACHIALIS is situated at the upper internal side of the arm, at the inner edge of the short head of the biceps muscle, with which it is connected for three or four inches. It arises tendinous and fleshy, from the middle face of the point of the coracoid process of the scapula, in common with the short head of the biceps muscle.

It is inserted, tendinous and fleshy, into the internal side of the middle of the os humeri, by a rough ridge, just below the tendons of the latissimus dorsi and teres major, and in front of the brachialis externus. From the lower end of this muscle there proceeds to the inter-



nal condyle of the os humeri an intermuscular ligament, which separates the brachialis internus from the third head of the triceps.

This muscle draws the arm upwards and forwards.

3. The **BRACHIALIS INTERNUS** is situated immediately beneath the biceps, and is concealed by it, excepting the outer edge. It has a bifurcated fleshy origin from the middle front face of the os humeri, on each side of the insertion of the deltoid, and its origin is continued fleshy from this point downwards, from the whole front of the bone to within a very small distance of its articular surface.

It is inserted, by a strong short tendon, into the rough surface at the root of the coronoid process of the ulna.

The brachialis flexes the fore-arm, and by passing in front of the elbow joint, strengthens the latter very much. Its lower part lies under the tendon of the biceps, and between the pronator teres and the supinator longus.

4. The **TRICEPS EXTENSOR CUBITI** forms the whole of the fleshy mass on the back of the arm; it therefore occupies the space between the integuments and the bone. It arises by three heads. The first, called **Longus**, comes, by a flattened tendon, from a rough ridge on the inferior edge of the cervix scapulæ. The second, called the **Brevis**, arises, by a sharp, tendinous



and fleshy beginning, from a slight ridge on the outer back part of the os humeri just below its head. The third head, called *Brachialis Externus*, arises, by an acute fleshy beginning, from the inner side of the os humeri, near the insertion of the *teres major*. This muscle, both at its external and internal edge, is separated from the muscles in front of the arm by the ligamentous septum, which arises near the middle of the os humeri, and runs to its condyles. The whole back of the os humeri, as well as the posterior surface of these intermuscular septa, is occupied by the origin of the *triceps*. The muscular fibres run in various directions according to their respective heads and places of origin.

At the inferior end of the muscle is found a broad tendon which covers its posterior face. This tendon is inserted into the base or back part of the olecranon, and into the ridge leading down the ulna on its radial side.

The *triceps* extends the fore-arm. Its bellies unite above the middle of the os humeri, but the interstices between them may be observed much lower down.

Connected with the last, is a muscle which should be dissected at the same time, as it has corresponding functions, and looks very much like an appendage of the *triceps*; it is the

5. *ANCONÆUS*. This is a small triangular muscle



just beneath the skin, at the outer posterior part of the elbow joint. It arises tendinous from the posterior lower part of the external condyle of the os humeri, adheres to the capsular ligament of the joint, and is partly covered by the tendon of the triceps.

It is inserted fleshy, and thin, into the ridge on the outer part of the head of the ulna leading from the olecranon, and fills up the triangular depression found there.

It extends the fore arm.



### SECTION III.]

#### *Of the Muscles in front of the Fore-Arm.*

THE most of these muscles arise from the inner condyle of the os humeri, and from the ridge leading to it, and are, either directly or indirectly, flexors of the fore-arm upon the arm. This fact should be impressed on the mind of the student, as it simplifies much the act of committing them to memory. The systematic treatises of anatomy describe the origin of each muscle as if it were totally distinct from the rest; the student will soon correct the error arising from this, and learn that the heads of all these muscles are connected to contiguous heads, by adhesion and by inter-



muscular ligaments, and that there would be almost as much propriety in describing them as having a common origin, as there is in considering them so insulated.

There are eight muscles situated on the front of the fore-arm, some of which are superficial and others deep-seated.

1. The **PRONATOR RADII TERES** is just beneath the fascia of the fore-arm, and forms the radial side of the muscles of the internal condyle. It arises fleshy from the anterior face of the internal condyle of the os humeri, and tendinous from the coronoid process of the ulna. It passes very obliquely across the fore-arm at the internal edge of the brachialis internus muscle and is

Inserted, tendinous and fleshy, into the external back part of the radius just below the insertion of the supinator radii brevis, occupying thereby about two inches of the middle of the bone.

It rolls the hand inwards.

2. The **FLEXOR MANUS vel CARPI RADIALIS** is placed at the ulnar side of the last muscle, and is also superficial. It arises, by a narrow tendon, from the lower front part of the internal condyle of the os humeri; fleshy from the intermuscular ligaments, fascia, and from the upper part of the ulna. It forms a thick, fleshy belly, terminating below in a tendon, which



passes under the anterior annular ligament of the wrist, and runs through a groove in the os trapezium.

It is inserted, tendinous, into the base of the metacarpal bone of the fore-finger, in front.

It bends the hand.

3. The **PALMARIS LONGUS** is at the ulnar side of the flexor carpi radialis, and is superficial. Sometimes it does not exist. It is a small short muscle terminating in a long slender tendon, and arises by a small tendon from the internal condyle, and fleshy from the intermuscular ligament on each of its sides.

It is inserted, tendinous, into the humeral margin of the ligamentum annulare anterius near the root of the thumb, and a division of its tendon passes on to the aponeurosis palmaris.

It bends the hand, and makes tense the palmar aponeurosis.

4. The **FLEXOR MANUS vel CARPI ULNARIS** occupies, among the superficial muscles, the ulnar side of the fore-arm. It arises, tendinous from the internal condyle of the os humeri, fleshy, from the upper internal side of the olecranon; and, by a tendinous expansion much connected with the fascia of the fore-arm, from the ridge at the internal side of the ulna to within three or four inches of the wrist.

It is inserted into the upper side of the os pisi-



forme by a round tendon, which begins high up at the radial margin of the muscle, and into which the muscular fibres run. Sometimes the tendon is continued over the os pisiforme, so as to be likewise inserted into the base of the metacarpal bone of the little finger.

It bends the hand.

5. The FLEXOR DIGITORUM SUBLIMIS PERFORATUS is concealed very much by the muscles just enumerated in consequence of being placed between them. To get a good view of its origin they all should be cut away from the os humeri. It arises, tendinous and fleshy, from the internal condyle of the os humeri; tendinous from the coronoid process of the ulna, and fleshy, from the tubercle of the radius; the latter part of its origin is extended tendinous obliquely, for three or four inches along that line of the radius which is at the upper margin of the pronator teres. With these origins the muscle spreads over the front of the fore-arm at its upper part, from the radial to the ulnar margin.

From the lower end of the muscle, four distinct tendons pass which commence much above the wrist, go beneath its anterior ligament, and, having got to the palm of the hand, diverge to the several fingers. To each finger, a tendon, is appropriated which passes in front of the metacarpal bone to the phalanges; and after having split into two, is inserted into the angle formed by the junction of the cylindrical and flat surfaces of the second phalanx, near the middle.



It bends the second phalanges on the first; its action may also be continued so as to clench the hand and to bend it on the arm.

6. The FLEXOR DIGITORUM PROFUNDUS PERFORANS is beneath the flexor sublimis and the flexor ulnaris. It arises fleshy from the oblong concavity of the ulna between the coronoid and the olecranon processes; fleshy from the carpal margin of the base of the coronoid process; from the ulnar portion of the interosseous ligament; and from the front of the upper two-thirds of the ulna.

The tendons of this muscle are different from those of the other; they commence in front of it, like a tendinous membrane, which is gradually divided into several fasciculi, adhering to each other by cellular membrane. The fasciculated character of the tendons is still preserved when they go under the anterior carpal ligament, and until they begin to disperse as distinct tendons to the four fingers.

Each tendon, going in front of its metacarpal bone and of the corresponding phalanges, gets through the slit in the flexor sublimis, and is inserted into the front part of the base of the third phalanx of the finger.

It bends the last joint of the fingers, and by increased action, may flex the hand like the preceding muscle.

7. The FLEXOR LONGUS POLLICIS lies in front of the radius, but beneath the flexor sublimis. It arises, by



an acute fleshy beginning, from the radius just below its tubercle; also, fleshy, from the middle two-thirds of the front of the bone, and from the radial portion of the interosseous ligament. The body of the muscle is joined by a small fleshy slip, of a tendinous origin from the internal condyle of the os humeri.

On the ulnar margin of this muscle a tendon is formed early, to which the fibres pass obliquely. This tendon goes under the annular ligament of the wrist, through the fossa formed in the short flexor muscle of the thumb, and between the sesamoid bones, to be inserted into the base of the second phalanx of the thumb.

It bends the last joint of the thumb.

While performing this dissection there are several minutiae which deserve attention. The Annular Ligament of the wrist in front, is a very strong membrane passing across the carpus, from the projection of the scaphoides and trapezium on the radial side of the wrist, to the unciform process on the ulnar side and to the cuneiform and pisiform bones. Between it and the concavity of the carpus, an oval foramen is formed for transmitting the tendons of the several flexors. These tendons, though they slide with perfect freedom upon each other, are connected by a dense and elastic cellular membrane, forming a bursa, which has the power of keeping them lubricated by a synovial secretion.



The Vaginal Ligaments of the fingers extend from the roots of the fingers to the bases of the third phalanges. They are of a ligamento-cartilaginous structure, are attached on either side to the anterior edge of the phalanges, and are much thinner as they pass over the fronts of the finger joints than elsewhere. They are inelastic, their internal surface is extremely smooth, and kept continually lubricated by synovial fluid.

Within the vaginal ligaments small tendinous fræna covered by a reflection of the synovial membrane are found to arise from the first and second phalanges, they run obliquely forwards, and terminate in the tendons of the two flexor muscles. We may also observe that in front of each joint, independently of the swelling of the articular extremities of the bones, the capsular ligament is thickened by an addition of cartilaginous matter, by which a trochlea is formed. This trochlea facilitates the sliding of the tendons by its smoothness; and the flexions of the phalanges by removing the tendons further from the axis of motion, after the same manner with the patella.

8. The PRONATOR QUADRATUS is just above the carpal surfaces of the radius and ulna, and between the other muscles and the bone. In the adult it is about two inches wide, and its fibres run across the fore-arm. It arises, fleshy and tendinous from the ridge at the inner surface of the ulna near its lower extremity, and from the front of the bone.



It is inserted into the corresponding front surface of the radius.

It rotates the radius inwards.

*Of the Muscles on the Back of the Fore-Arm.*

These muscles are ten in number. They arise for the most part from the external condyle and the ridge leading to it, and are extensors either of the fore-arm or of the fingers and hand. Their origins are less blended with each other than those of the flexor muscles, nevertheless between several of them there are intermuscular ligaments which connect them closely. They are superficial and deep seated.

1. The SUPINATOR RADII LONGUS is situated along the radial edge of the fore-arm, immediately beneath the integuments. It arises, fleshy and tendinous from the higher part of the ridge leading to the external condyle, commencing just below the insertion of the deltoid muscle, and being here placed between the brachialis internus and the short head of the triceps. It forms a thick, fleshy belly, constituting the external margin of the arm about the elbow joint, and terminates near the middle of the radius in a flat tendon.

It is inserted, by the latter, into a small rough ridge on the outer side of the radius, just above its styloid process.

It rolls the radius outwards.



2. The **EXTENSOR CARPI RADIALIS LONGIOR** is situated beneath the former muscle. It arises, tendinous, and fleshy, from the space of the external ridge of the os humeri between the supinator longus and the external condyle. It forms a short, fleshy belly, which terminates in a flat tendon above the middle of the radius.

It is inserted, by this tendon into the posterior part of the root of the metacarpal bone of the fore-finger near the thumb.

It extends the hand.

3. The **EXTENSOR CARPI RADIALIS BREVIOR** is beneath the last, but projects somewhat beyond it. It arises, tendinous, from the posterior and lower part of the external condyle, and from the external lateral ligament of the elbow joint. It forms a thick, fleshy belly, placed along the radius, and which terminates in a flat tendon about the middle of that bone.

Its tendon, becoming rounded, is inserted into the posterior part of the base of the metacarpal bone of the second finger.

It extends the hand.

4. The **EXTENSOR CARPI ULNARIS** is superficial, and placed principally parallel with the ulna. It arises, tendinous, from the external condyle, fleshy, from the intermuscular ligament and inside of the fascia. Crossing very obliquely the upper part of the radius and the



the ulna, it also arises fleshy from the back part of the latter bone. Its fibres terminate obliquely in a tendon which goes through the groove of the ulna.

It is inserted, by its tendon, into the ulnar side of the base of the metacarpal bone of the little finger.

It extends the hand.

5. The **EXTENSOR DIGITORUM COMMUNIS** is superficial, being placed between the extensor ulnaris and the extensor radialis brevis. It arises, tendinous, from the external condyle, and fleshy, from the intermuscular ligament of the contiguous muscles. As it approaches the wrist it sends off four tendons which pass together through a common groove on the back of the radius. On the back of the hand these tendons diverge, and near the roots of the fingers send cross slips to each other.

Each tendon goes to its respective finger and covers the whole posterior part of it, being spread out into a membrane, which adheres to the phalanges from the root of the first, to the root of the last.

The section of this muscle appropriated to the little finger has a distinct appearance, and sometimes its tendon goes through a distinct fossa in the radius, from which causes it has obtained the name of **Auricularis**.

This muscle extends all the joints of the fingers, being the antagonist of the flexors.



6. The *SUPINATOR RADII BREVIS* can only be well seen by detaching the origins of the aforesaid muscles; it will then be found in contact with the radius, making a close investment of its head and upper third. It arises, tendinous, from the external condyle of the os humeri, tendinous and fleshy, from the ridge on the posterior radial edge of the ulna, which descends from its coronoid process.

Its fibres surround, obliquely, the upper external part of the radius, and are inserted into its tubercle, and into the oblique rough ridge corresponding with the upper margin of the pronator teres. At the interstice between the radius and ulna, near the anterior edge of this muscle, a fleshy slip is occasionally seen, which passes from the radial side of the coronoid process to the ulnar edge of the radius.

This muscle rotates the radius outwards.

7. The *EXTENSOR OSSIS METACARPI POLLICIS MANUS* arises, fleshy, from the posterior part of the ulna immediately below the anconeus, from the interosseous ligament, and from the back part of the radius just below the insertion of the supinator brevis. It terminates in a rounded tendon, which passes over the tendons of the radial extensors, and through a groove on the styloid side of the lower end of the radius.

It is inserted, by its tendon, into the base of the metacarpal bone of the thumb, and into the external side of the trapezium.



It extends the metacarpal bone of the thumb.

8. The **EXTENSOR MINOR POLLICIS MANUS** is at the ulnar side of the last muscle. It arises, tendinous, from the back of the ulna below its middle, and fleshy from the interosseous ligament. It adheres to the radius, and terminates in a tendon which passes through a groove in the styloid side of the radius along with the last named muscle.

It is inserted into the first phalanx of the thumb by its tendon, which is extended to the root of the second phalanx.

It extends the first phalanx.

9. The **EXTENSOR MAJOR POLLICIS MANUS** arises, by a small tendinous, and extensive fleshy origin, from the back of the ulna above its middle, and from the interosseous ligament; also from the back of the radius; it terminates near the wrist in a tendon, which passes through a groove on the back of the radius near the ulna. The belly of this muscle conceals, very much, the other extensors of the thumb.

It is inserted, by its tendon, into the oblong transverse tubercle on the back of the base of the second phalanx of the thumb.

It extends the second phalanx.

The tendons of the two last muscles are much connected with each other, and are spread in the form of a



membrane on the back of the thumb, after the manner of the extensor tendons of the fingers.

10. The **INDICATOR** is a small muscle on the back of the ulna, concealed by the extensor communis and extensor ulnaris. It arises, tendinous and fleshy, from the back of the ulna, commencing near its middle, and from the contiguous part of the interosseous ligament. It terminates in a tendon which goes through the same fossa with the extensor communis; it afterwards is joined, about the head of the first phalanx, to the tendon of the common extensor belonging to the fore-finger.

With the tendon of the extensor communis it is inserted along the back of the fore-finger to the base of the third phalanx.

It extends the fore-finger.

At this stage of the dissection it is proper to notice the **Posterior Carpal Ligament**, which passes from the side of the radius to the side of the ulna. It is two inches in breadth, and seems much like a continuation of the fascia of the fore-arm. It will be found strongly attached to the different ridges of the radius and ulna, and from its want of elasticity, perfectly adapted to prevent the tendons from springing out of their respective grooves. It forms one jugum for the two first extensors of the thumb, another for the radial extensors



of the hand, a third for the tendon of the third extensor of the thumb, a fourth for the indicator and extensor communis, and a fifth for the extensor ulnaris.

*Of the Small Muscles of the Hand.*

The skin and fat being carefully removed from the palm of the hand, we bring into view the **APONEUROSIS PALMARIS**. This is a triangular tendinous membrane which covers all the hollow of the hand, and is spread over its muscles. It arises from the anterior carpal ligament somewhat narrow; it then spreads out, and dividing into four sections, is fixed to the heads of the metacarpal bones. Each section bifurcates, to allow the flexor tendons to pass to the fingers, and is united to the contiguous sections by transverse bands or fræna. The muscles of the ball of the thumb and of the little finger are covered by a thin membrane extended from the lateral margins of this aponeurosis.

The **PALMARIS BREVIS** is apt to be cut away unconsciously; it is just below the skin at the inner side of the hand. It consists of separate fasciculi unequally divided, and arises from the ligament of the wrist, and from the ulnar side of the palmar aponeurosis.

It is inserted into the skin and fat at the inner margin of the hand, and covers the muscles of the little finger.



It contracts the skin of the hand.

The APONEUROSIS being removed, a good view is obtained of the flexor tendons and many of the small muscles of the hand.

The LUMBRICALES are conspicuous; they are four in number, of the size and shape of earth worms. They arise, tendinous and fleshy, from the radial sides of the tendons of the flexor profundus, beneath the ligamentum carpi annulare, and a little beyond its anterior edge.

They terminate in little flat tendons which run along the outer or radial edges of the fingers, and are inserted into the tendinous expansion on the back of the first phalanx of each finger about its middle.

They bend the first phalanges.

Four muscles constitute the ball of the thumb.

1. The ABDUCTOR POLLICIS MANUS arises, tendinous and fleshy, from the anterior surface of the ligamentum carpi annulare and from the projecting ends of the trapezium and scaphoides.

It is inserted, tendinous, into the outer side of the base of the first phalanx of the thumb, and into the tendinous membrane derived from the extensors on its back part.

It draws the thumb from the fingers. This muscle is next to the skin.



2. The **OPPONENS POLLICIS** is beneath the abductor, and without its removal can scarcely be seen. It arises, tendinous and fleshy, from the projecting point of the os trapezium and from the adjacent part of the annular ligament.

It is inserted, tendinous and fleshy, into the radial edge of the metacarpal bone of the thumb from its base to its head.

It draws the metacarpal bone inwards.

3. The **FLEXOR BREVIS POLLICIS MANUS** is beneath the abductor pollicis and at the ulnar side of the opponens pollicis. A groove is formed in it by the tendon of the flexor longus pollicis, which divides it into two heads.

The first head arises, fleshy, from the points of the trapezium, trapezoides, and from the contiguous part of the internal surface of the annular ligament, and is inserted into the outer sesamoid bone; the sesamoid bone, like a patella, being connected to the first phalanx of the thumb by tendon.

The second or internal head arises, fleshy, from the magnum and unciforme, near their metacarpal surfaces, and from the base of the metacarpal bone of the middle finger. It is inserted into the inner sesamoid bone, which like the external, is connected, by ligament, to the first phalanx.

The short flexor, as its name implies, bends the first joint of the thumb.



4. The **ADDUCTOR POLLICIS MANUS** lies in the palm of the hand beneath the lumbricales and the tendons of the flexor sublimis and profundus. It arises, fleshy, from the ulnar edge of the metacarpal bone of the middle finger between its base and head.

It is inserted, tendinous, into the inner part of the base of the first phalanx of the thumb near the internal sesamoid bone.

It pulls the thumb towards the fingers.

The **ABDUCTOR INDICIS MANUS** is on the radial edge of the hand between the metacarpal bones of the fore-finger and thumb, and is just beneath the skin. It arises tendinous, from the trapezium, and fleshy from the ulnar edge of the metacarpal bone of the thumb between its base and head.

Being placed along the side of the metacarpal bone of the fore-finger, it is inserted, by a short tendon, into the radial side of the first phalanx.

It draws the fore-finger from the others.

There are three muscles constituting the fleshy part of the ulnar side of the hand, or the ball of the little finger.

1. The **ABDUCTOR MINIMI DIGITI MANUS** is the most superficial. It arises, fleshy from the protuberance on the internal side of the os pisiforme and from the contiguous parts of the annular ligament.



It is inserted, tendinous, into the ulnar side of the first phalanx of the little finger and into the tendinous membrane which covers its back part.

It draws the little finger from the rest.

2. The FLEXOR PARVUS MINIMI DIGITI MANUS is beneath the abductor. It arises, fleshy, from the unciform process of the os unciforme, and from the contiguous part of the annular ligament.

It is inserted, tendinous, into the ulnar side of the base of the first phalanx of the little finger, being united with the tendon of the abductor, and with the tendinous membrane expanded over the back of the finger.

It bends the little finger.

The ADDUCTOR METACARPI MINIMI DIGITI is placed beneath the Abductor and flexor, next to the metacarpal bone. It arises, fleshy, from the unciform process of the os unciforme, and from the contiguous part of the annular ligament of the wrist.

It is inserted, tendinous and fleshy, into the fore part of the metacarpal bone of the little finger, from its base to its head.

It brings the metacarpal bone of the little finger towards the others, and thereby deepens the hollow of the hand.

The Interosseous Muscles fill up the interstices of



the metacarpal bones; they are seven in number, four on the palm, and three on the back of the hand. The latter ones arise by double heads from the contiguous sides of two metacarpal bones; the inner ones have each a single head only, which comes from the metacarpal bone of the finger, which such interosseous muscle is intended to serve. As a general description they all may be said to arise, fleshy and tendinous, from the base and sides of the metacarpal bones, and to be inserted tendinous, into the sides of the first phalanges, and into the tendinous membrane on the backs of the fingers, derived from the tendons of the extensor communis. The four first are very deeply seated, but the three others rather superficially.

1. The **PRIOR INDICIS** is along the radial side of the first metacarpal bone, or that of the first finger and arises from the base and side of the same.

It is inserted, tendinous, into the radial side of the first phalanx.

It draws the fore-finger towards the thumb.

2. The **POSTERIOR INDICIS** is at the ulnar side of the first metacarpal bone. It arises from the base and ulnar side of the same bone, and is inserted, tendinous, into the ulnar side of the first phalanx of the fore-finger.

It draws the fore-finger towards the others.



3. The *PRIOR ANNULARIS* is at the radial side of the metacarpal bone of the third or ring finger, and arises from the base and radial side of the said bone.

It is inserted, tendinous, into the radial side of the first phalanx of the ring finger.

It draws that finger towards the thumb.

4. The *INTEROSSEOUS DIGITI AURICULARIS* is at the radial side of the metacarpal bone of the little finger, and arises from the radial side and base of said bone.

It is inserted, tendinous, into the radial side of the first phalanx of the same finger.

It draws the little finger towards the others.

By removing the tendons of the *extensor communis* from the back of the hand, we see the three posterior or double-headed interosseous muscles.

5. The *PRIOR MEDII* is between the metacarpal bones of the fore and middle fingers, and arises from the opposite roots and sides of these bones.

It is inserted tendinous, into the radial side of the first phalanx of the middle finger.

It draws the middle finger towards the thumb.

6. The *POSTERIOR MEDII* is between the metacarpal bones of the middle and ring fingers, and arises from the opposite sides and roots of these bones.

It is inserted, tendinous, into the ulnar side of the first phalanx of the middle finger.



It draws the middle finger towards the little.

7. The POSTERIOR ANNULARIS is between the metacarpal bones of the ring and little finger, and arises from the opposed sides and roots of these metacarpal bones.

It is inserted, tendinous, into the ulnar side of the first phalanx of the ring finger.

It draws the middle towards the little finger.



#### SECTION IV.

##### *Of the Blood-Vessels of the Upper Extremities.*

THE Arteries of the Upper Extremity are derived from the subclavian, the course of which, to the scalmi muscles, is described in the account of the neck. The subclavian passes over the middle of the first rib between the scalenus anticus and medius muscles, and afterwards goes between the first rib and the subclavius muscle to the arm-pit. Here it is called Axillary Artery, (*Arteria Axillaris*,) and its position is under the tendinous insertion of the pectoralis minor, and almost touching it; it then passes, at the internal inferior part of the head of the humerus, parallel with, and bordering on, the internal edge of the coraco brachialis mus-



cle. At the posterior fold of the arm-pit it is placed very near the tendon of the latissimus dorsi, between it and the coraco brachialis. Emerging from the axilla at this place, its name is changed into that of Brachial Artery, (*Arteria Brachialis.*)

The ARTERIA BRACHIALIS descends the arm at the internal margin of the lower part of the coraco brachialis, and afterwards at the internal margin of the biceps flexor cubiti. At the bend of the arm it is at the inner edge of the tendon of the biceps, and passes under its aponeurosis; and a little below the joint it splits into two branches of nearly equal magnitude, the Radial and the Ulnar Artery.

The relative situation of this great artery with the nerves and veins of the part, should be closely observed; between the scaleni muscles, the majority of the nerves forming afterwards the axillary plexus, is above and somewhat posterior to the subclavian artery; but when this artery becomes axillary, the nerves unite in various combinations, and surround it like so many cords of a platted whip thong. The axillary vein is below and somewhat in front of the artery, and very near it. These several parts are united by a loose, vascular, adipose and cellular membrane containing many lymphatic glands.

1. The ARTERIA DORSALIS SUPERIOR SCAPULÆ varies much in its origin; it comes sometimes from the sub-



clavian, and on other occasions from the upper part of the axillary. Not unfrequently it is a branch of the inferior thyroid. In either the first or the last case, its course is very important to the surgeon, for it runs along the posterior margin of the clavicle towards its acromial extremity, and in an operation, by being opened, might be mistaken for the subclavian artery itself. When it comes from the axillary artery it is tortuous, and has to ascend to its destination, being completely out of the way of an operation from above, upon the subclavian artery. Its final distribution is always the same, for it passes through the notch in the upper costa of the scapula, and there divides into branches supplying the supra-spinatus muscle and the shoulder-joint.

2. The ARTERIÆ MAMMARIÆ EXTERNÆ arise from the axillary just above the pectoralis minor. They consist in four principal branches, going uniformly to certain parts; but the origin of these branches varies, for sometimes they are originally distinct trunks from the axillary artery, and on other occasions blended into one or more. They are

a. Thoracica Superior, distributed to the parts of the pectoralis major muscle just below the clavicle, some branches going to the pectoralis minor.

b. Thoracica Longa, supplying the inferior parts of the great pectoral muscle, the mamma, and integuments.



*c.* Thoracica Acromialis, making for the fissure between the deltoid and great pectoral muscle, and distributed to them along the margins of this fissure upwards and downwards.

*d.* Thoracica Axillaris, very irregular in origin and size; when small it is distributed generally to the fat and glands of the axilla; when large it is a trunk, the size of a goose-quill, running on the scapular surface of the serratus major anticus, and distributed to it by branches coming off at right angles.

3. The SCAPULARIS arises from the axillary artery about the anterior margin of the subscapularis muscle. It passes downwards towards the angle of the scapula in contact with this muscle, and is distributed to the teres major and minor, subscapularis and latissimus dorsi muscles.

A little below the neck of the scapula a large trunk, the Dorsalis Inferior Scapulæ, arises from the scapularis, and winds around the bone to be distributed to the infrapinatus and the contiguous muscles, an anastomosis being formed under the neck of acromion process, between the dorsalis inferior and superior.

4. The CIRCUMFLEXA ANTERIOR is a small artery about the size of a crow-quill. It arises from the axillary just above the superior or posterior margin of the tendon of the teres major and latissimus dorsi. It surrounds half the os humeri just below its head, going



between the bone and the coraco brachialis and biceps muscle, to be distributed to the articulation and to the contiguous muscles.

5. The **CIRCUMFLEXA POSTERIOR** is much larger, and arises from the axillary about the same place with the last, but commonly a little below; sometimes they have a common trunk. It surrounds the back part of the os humeri, going between the long head of the triceps and the bone, by passing between the teres minor and major muscles in the first instance. It is distributed to the shoulder joint and the contiguous muscles, especially the deltoid.

6. The **PROFUNDA HUMERI** or **SPIRALIS** arises from the great artery of the upper extremity just below the tendon of the teres major, where the artery is called **Brachial** or **Humeral**. It passes downwards a little distance, and there enters the interstice between the first and the third head of the triceps muscle. It winds between this muscle and the bone very obliquely downwards, and appears, at last, on the outer side of the arm, between the brachialis internus and the supinator longus; it reaches to the external condyle. In this course the profunda sends many branches to the triceps and to the contiguous muscles. Its origin is sometimes from the scapular or from the posterior circumflex artery.



7. The PROFUNDA MINOR is uncertain in its origin but comes commonly from the humeral two inches below the last; sometimes it is a branch of the last. It is distributed on the internal surface of the triceps extensor, and extends to the internal condyle.

8. The NUTRITIA is a very small branch from the humeral, arising near the medullary foramen of the os humeri, which it penetrates, and is distributed to the lining membrane.

9. The ANASTOMOTICA is a small branch from the humeral, arising about the place where the os humeri begins to expand in order to form the elbow joint. It passes on the internal face of the brachialis internus muscle, and then over the ridge of the internal condyle to the groove between the condyle and the olecranon process, where it anastomoses with a recurrent branch of the ulnar artery.

Several arterioles are also sent from the humeral or brachial artery to the biceps, brachialis, triceps, and coraco-brachialis, which are too irregular and too small to deserve description.

The HUMERAL ARTERY it has been stated, is divided a little below the elbow joint into two principal trunks, Radial and Ulnar. Sometimes this division is on a line with the joint; at other times it occurs nearer the in-



section of the brachialis muscle. The division, however, does occasionally occur, in all the space between the axilla and the elbow joint, in which case the radial artery sometimes is just beneath the skin at the elbow, and continues uncommonly superficial to the wrist.

The **RADIAL ARTERY** (**ARTERIA RADIALIS**) in the early part of its course, is at the bottom of the fissure, between the pronator teres and the supinator radii longus, afterwards it crosses the insertion of the former, runs parallel with, and in front of the radius to the wrist, between the tendons of the supinator longus and of the flexor radialis. At the styloid process it gets between the carpus and the extensors of the thumb, runs a little distance on the radial side of the back of the hand, and then penetrates to the palm between the base of the metacarpal bone of the thumb and of the fore-finger. It furnishes the following branches, collateral and terminating.

1. The **RECURRENS RADIALIS** arises about the neck of the radius. It winds around the joint externally, between the external condyle and the muscles coming from it, and anastomoses with the spiralis or profunda of the humeral artery; being distributed in many collateral branches, to the joint and contiguous muscles.

2. Several small and irregular muscular branches



arise from the radial artery in its progress to the wrist; they have no appropriated names.

3. The *SUPERFICIALIS VOLÆ* arises from the radial about the inferior margin of the pronator quadratus muscle. It passes superficially over the process of the trapezium to the muscles of the ball of the thumb, and one of its terminating branches joins the *arcus sublimis*. Sometimes the *superficialis volæ* is the principal branch of the radial.

4. The *DORSALIS CARPI* arises from the radial at the carpus, runs transversely across the back of the latter and detaches the posterior interosseous arteries of the back of the hand. They anastomose with branches from the ulnar and interosseous arteries of the fore-arm.

5. The *MAGNA POLLICIS*, a terminating branch of the radial, comes from it in the palm of the hand, just at the root of the metacarpal bone of the thumb. It runs beneath the *abductor indicis*, and at the head of the metacarpal bone divides into two branches, which go along the sides of the thumb to its extremity, where they anastomose and terminate.

6. The *RADIALIS INDICIS*, arising at the same place with the latter, runs along the metacarpal bone of the



fore-finger, and along the radial side of the same finger to its extremity.

7. The *PALMARIS PROFUNDA* is the third terminating branch of the radial artery. It arises near the same place with the two last; crosses the hand between the metacarpal bones and the flexor tendons, thus forming the *Arcus Profundus*, from which branches proceed to the *interossei* muscles, and which ends on the ulnar side of the palm of the hand by a branch to the *Arcus Superficialis*.

The *Ulnar Artery*, (*Arteria Ulnaris*,) one of the forks of the brachial at the elbow, passes more in a line with it than the radial artery does. Being deeply seated, it goes, immediately after its origin, under several of the muscles of the internal condyle, and between the flexor sublimis and profundus; getting from beneath the flexor sublimis, it afterwards runs parallel with the ulna or nearly so, lying on the flexor profundus between the flexor ulnaris and the ulnar margin of the flexor sublimis, and concealed two-thirds of the way down the fore-arm by the overlapping of these muscles. At the thin part of the fore-arm, commonly called the wrist, it is superficial, and may be felt pulsating in the living body at the radial margin of the tendon of the flexor ulnaris.

The ulnar artery, at the carpus, takes a very differ-



ent course from the radial, for it passes over the anterior annular ligament of the carpus just at the radial side of the os pisiforme, to which it is held by a small ligamentous noose, and then proceeds to the palm of the hand. Between the aponeurosis palmaris and the flexor tendons it forms that curve from the ulnar to the radial side of the hand called the Arcus Sublimis. This curve commonly begins a little beyond the anterior margin of the annular ligament, and presenting its convexity forwards, terminates about the middle of the ball of the thumb at its inner margin.

The branches sent from the ulnar artery are as follow:

1. The RECURRENS ULNARIS arises from the ulnar about the lower part of the tubercle of the radius, and winding upwards is distributed in small branches to the muscles of the internal condyle. One of its ramuscles goes between the internal condyle and the olecranon process, to anastomose with the arteria anastomotica of the humeral.

2. The INTEROSSEA arises from the ulna just below the other. It is a large trunk, and proceeds but a little distance when it divides into two principal branches called anterior and posterior interosseal arteries.

- a. The Interossea Anterior is much the larger; it runs in contact with the interosseous ligament to the



upper margin of the pronator quadratus, giving off branches to the deep-seated muscles of the fore-arm in its course. Under the pronator it perforates the interosseous ligament, and distributes to the back of the carpus and of the hand, branches, which anastomose with branches of the radial and posterior interosseal.

b. The Interossea Posterior is sometimes a separate trunk, arising from the ulnar just above the former. In either case it soon perforates the interosseous ligament, to get to the back of the fore-arm. Here it sends backwards a Recurrent Branch to the back of the elbow, which anastomoses with the *recurrens ulnaris* and *radialis*. It then proceeds downwards, being deeply seated and distributed to the different muscles on the back of the fore-arm. Some of its branches, reach the wrist, and anastomose with the carpal arteries.

3. The ulnar artery, in its descent on the fore-arm, sends off many small and irregular muscular branches called by Professor Chaussier *Cubito-musculaires*; they do not require description.

4. The *DORSALIS MANUS* leaves the ulnar at the lower end of the fore-arm, and passes under the tendon of the flexor ulnaris to the back of the hand. It there meets ramuscles of the radial and interosseous, and conjointly they supply, with very small branches,



the back of the wrist, of the metacarpus and of the fingers.

5. As the *ARCUS SUPERFICIALIS* is about beginning, the ulnar artery sends superficial but small branches, to the integuments of the palm. And a little further on, a considerable branch, which dives into the bottom of the palm, through the muscles of the little finger, and joins the ulnar extremity of the *arcus profundus*; this is the *Cubitalis Manus Profunda* of Haller.

6. The *ARCUS SUPERFICIALIS* then sends a branch to the ulnar side of the little finger. Afterwards in succession three digital branches are sent off, which, arriving at the interstices between the heads of the metacarpal bones, each divides into two branches to supply the sides of the fingers which are opposite to each other; one branch is called *Digito-radial*, the other *Digito-ulnar*, according to the side of the finger on which the artery may be placed.

The *Digital Arteries*, before they divide, receive each a small branch from the *arcus profundus*. The *digito-radial* and *ulnar arteries*, pass along the front sides of the fingers to their extremities; and at the joints and extremities, anastomoses between the arteries of the two sides of the same finger occur.

The *Arcus Superficialis* terminates on the radial side



of the palm by a branch which joins the artery of the thumb coming from the radial.

The most frequent distribution of the arteries of the hand is what has been just described; anatomists are, however, not all agreed on this point. It would probably be more just to say, judging from our collection in the University, that this occurs oftener than any other single arrangement. The variety, in fact, is so great, that before a hand is opened it is not possible to know in what manner its arteries are distributed. Sometimes the radial artery furnishes one-half of the arcus sublimis, and the ulnar the other. On other occasions the interosseous artery, or the Superficialis Volæ, is continued as a large trunk over the ligament of the wrist, and across the root of the thumb to join the arcus sublimis.

#### *Of the Veins of the Upper Extremities.*

These Veins are abundantly supplied with valves, and are superficial and deep-seated; the former lying beneath the skin have original names; the latter attending the arteries on all occasions, are called after them. Anastomoses are numerous in both sets, but are particularly so in the superficial, where plexuses are formed which surround the arm.

Three principal superficial trunks are formed on the



lower part of the fore-arm, one on its radial side, another on its ulnar, and the third between the two.

1. The *VENA CEPHALICA* first arises about the root of the thumb and fore-finger on the back of the hand; a distinct trunk is formed which winds obliquely over the radius, and then runs along the external edge of the fore-arm to the elbow joint. The cephalic ascends afterwards along the external edge of the biceps flexor muscle, lies over the interstice between the pectoralis major and deltoid muscles, and ascends to within eight or ten lines of the clavicle, when it dips into the axilla to join the axillary vein. In the whole of this course it may be seen easily beneath the skin.

2. The *VENA BASILICA* arises, by several branches, from the back of the hand, principally on the ulnar side, one of which, placed between the metacarpal bone of the little finger and the ring finger, is called *Salvatella*. From this origin the basilic vein gets to the ulnar side of the fore-arm and continues so to the elbow joint, receiving on either side, anterior and posterior ulnar branches; it is then on the inner edge of the biceps muscle, and the pulsation of the brachial artery may be felt beneath it. It ascends regularly at the inner edge of the biceps, and about the middle of the arm becomes, by a junction with other veins, the *Brachial Vein*.



This vein on the fore-arm frequently consists in two trunks, of which the posterior is the largest.

3. The *VENA MEDIANA* arises, by branches, from the wrist and from the palm of the hand; it forms a trunk on the front of the fore-arm, and which three or four inches below the bend of the arm, bifurcates. One branch, the *Mediana Cephalica*, joins the cephalic vein; the second, the *Mediana Basilica*, joins the basilic vein.

The deep-seated Veins, called *Venæ Satellites* or *Comites*, are found in company with every artery of the upper extremity, there being, for the most part, one vein to each side of the artery. They anastomose frequently by branches which cross the arteries. At the elbow, the radial, ulnar and interosseous satellites unite, and form a plexus over the bifurcation of the brachial artery; from which plexus a short large branch goes outwards to join one of the superficial veins.

The trunk, formed by the union of the satellites of the fore-arm, passes upwards on the inner side of the brachial artery and receives the small veins from the different muscles. Sometimes it joins the basilic about the middle of the arm; on other occasions it joins it near or in the axilla, from which union results the axillary vein.



The *VENA AXILLARIS* receives the veins corresponding with the circumflex, scapular, and thoracic arteries, in their proper succession. It is fixed beneath the artery and very near it, in the same sheath of cellular substance. Under the clavicle it becomes *Vena Subclavia*; and as such it passes between the clavicle and the first rib at the inner side of the subclavian artery. It then leaves the artery to go in front of the *scalenus anticus*, whereas the artery goes between this muscle and the *medius*. After crossing the first rib it receives the superior dorsal vein of the scapula, the external jugular, and afterwards the internal jugular, besides several small veins from the skin and muscles of the neck.



#### SECTION V.

##### *Of the Nerves of the Upper Extremities.*

THE four inferior cervical and the first dorsal nerve, supply the upper extremity by an appropriation of nearly the whole of their anterior branches, which are of considerable magnitude, especially the three intermediate ones. They come out between the anterior and the middle *scalenus* muscle, being situated above and posterior to the subclavian artery, at various



heights according to the origin of each nerve respectively. Almost immediately after disengaging themselves from the *scaleni* muscles, they commence the formation of a plexus which surrounds the artery and continues with it to the lower part of the axilla. The fourth and fifth cervical nerves unite into a common trunk which splits into two; the seventh cervical and the first dorsal do the same; the sixth cervical also bifurcates. It is under various combinations of these different primary divisions that the axillary plexus is formed, from which proceed the different nerves of the upper extremity. This plexus, from its close connexion with the great artery, must, of course, go between the *subclavius* muscle and the first rib; and, in the upper part of the axilla, separate the axillary vein from the artery in some measure. The following branches are given off by the brachial plexus, besides the filaments from its roots to the sympathetic and phrenic in front, already mentioned in the account of the Neck.

1. The *NERVUS SCAPULARIS* is a small branch coming from the upper part of the plexus, commonly the fourth cervical nerve. It accompanies the *arteria dorsalis scapulæ* superior to the notch in the upper costa of the scapula, and is distributed to the muscles on the back of the scapula.

2. The *NERVI THORACICI* are primarily two or three



in number. They arise from the middle of the plexus and are divided into anterior and posterior branches, the former being distributed upon the pectoralis major and minor, the latter upon the serratus major anticus.

3. The *NERVI SUBSCAPULARES* of Bichat are about three in number; they come also from the central parts of the plexus, to be distributed upon the *teres major*, *latissimus dorsi*, and *subscapularis*.

4. The *NERVUS AXILLARIS*, or *CIRCUMFLEXUS*, comes from the lower part of the brachial plexus. It follows the course of the posterior circumflex artery, winding around the upper part of the *os humeri* between the *teres minor* and *major* in order to get to the internal surface of the deltoid muscle, where it terminates. In its passage it also furnishes branches to the *subscapularis*, the *teres major* and *minor*, the *infraspinatus* and to the integuments on the back of the shoulder and arm.

5. The *NERVUS CUTANEUS INTERNUS* proceeds from the lower part of the brachial plexus, and follows the course of the basilic vein to the elbow or near it. In its descent it detaches small cutaneous filaments anteriorly to the integuments of the biceps, and posteriorly to those of the triceps. A little above the bend of the elbow, commonly where the median basilic joins



the basilic vein, it divides into two terminating branches of nearly equal magnitude. The one next the internal condyle lies in front of the basilic vein just at its junction with the median basilic, and continues in front and parallel with it for some inches. It is distributed by many ramifications, to the skin of the ulnar side of the fore-arm and back of the hand, some of the branches winding around to the back part of the fore-arm. The other branch of the internal cutaneous passes beneath the median basilic vein about six lines from its junction with the basilic, and is distributed to the integuments on the middle front of the fore-arm. Before this latter branch reaches the median basilic vein, it sends off a cutaneous filament which crosses the median basilic in front, about half-way in the course of this vein.

6. The **NERVUS MUSCULO-CUTANEUS** comes from the middle of the brachial plexus. It perforates obliquely the upper part of the coraco-brachialis muscle, to which it dispenses filaments, it then passes between the biceps and brachialis internus muscles, giving also filaments to both of them. Its course being remarkably oblique under the biceps muscle, it makes its appearance superficially, only a little above the elbow joint near the external condyle. It then passes superficially between the skin and the supinator radii longus muscle, distributing filaments in its course, and near the lower part of the radius divides into two orders of



fibres, one of which is distributed on the palmar side of the hand, and the other on the dorsal, but both go to the integuments.

7. The *NERVUS RADIALIS*, or *MUSCULO-SPIRALIS*, arises from the upper portion of the brachial plexus. It is a large trunk which winds spirally around the *os humeri* between the triceps muscle and the bone, entering the fissure between the third and the first head of the triceps. It appears on the outside of the *os humeri* between the *brachialis internus* and the triceps muscle, running for some inches in contact with their intermuscular ligament. While beneath the triceps it sends several branches to its heads. There are three principal trunks afterwards to this nerve.

*a.* The *Ramus Superficialis Dorsalis* is sent from it on a line with the point of the deltoid muscle. This branch, then, goes just below the skin, parallel with and over the external ridge of the *os humeri*; it of course crosses the origin of the muscles of the external condyle. It continues superficial on the posterior external edge of the *supinator radii longus* muscle, and terminates in the integuments on the back of the hand.

The continued trunk of the muscular spiral goes in the interstice between the extensor muscles and the *brachialis internus*, and at the external condyle divides into the other two branches, from which filaments proceed to the contiguous heads of the muscles.



b. The Ramus Profundus Dorsalis perforates the supinator brevis muscle, and gets beneath the radial extensors to the back of the fore-arm; it is then distributed in numerous filaments to the muscles on the back of the fore-arm, some of its branches reaching to the wrist.

c. The Ramus Superficialis Anterior seems to be a continuation of the main trunk of the nerve, and descending at the anterior margin of the supinator radii longus muscle, it joins with the radial artery and continues in its company to a short distance below the middle of the radius. Here it crosses the bone obliquely beneath the tendon of the supinator longus, and then divides into a palmar and a dorsal ramus; the first being distributed to the muscles and integuments of the thumb, the second terminating so as to supply the back of the hand, of the thumb, fore, middle, and ring fingers, to their extremities.

8. The NERVUS MEDIANUS arises from the brachial plexus, like the other nerves. It descends the arm at the inner edge of the biceps muscle along the anterior surface of the humeral artery, adhering firmly to it and to the deep-seated veins by cellular substance. As far as the elbow it sends off no branch of importance. There, it lies at the side of the biceps tendon, crosses the lower part of the brachialis internus, and being beneath the aponeurosis of the biceps. It then perforates the pronator teres and gets between the



flexor sublimis digitorum, and the flexor longus pollicis, and enters the palm of the hand under the ligamentum carpi, at the radial edge of the tendons of the flexor sublimis. In the palm it is situated beneath the aponeurosis and the arcus sublimis.

The Median nerve dispenses the following branches: At the bend of the arm it furnishes filaments to the heads of the first layer of muscles of the fore-arm; and a little below, it detaches the nervus interosseus which supplies filaments to the flexor longus pollicis and flexor profundus. The interosseous nerve then descends with the interosseous artery in front of the interosseous ligament, and terminates in the pronator quadratus. Before the median nerve reaches the wrist it sends a branch which supplies with filaments the muscles and integuments of the ball of the thumb. In the palm of the hand it divides and subdivides, so as to furnish the two sides of the thumb, of the fore, of the middle, and one side of the ring finger with branches, which reach their extremities along with the digital arteries.

9. The NERVUS ULNARIS comes from the lowest section of the brachial plexus. It descends along the internal anterior part of the triceps muscle in a groove formed between it and the intermuscular ligament, diverging in this course gradually from the median nerve till it reaches the elbow, when it is at its greatest point of separation. At the elbow it is



behind the internal condyle, in the groove between it and the olecranon, and separates the two heads of the flexor ulnaris muscle. It then gets to the forearm between this muscle and the flexor profundus digitorum, and continues between them to within two inches of the wrist joint, when it detaches the Ramus Dorsalis.

The Ramus Dorsalis slips between the ulna and the tendon of the flexor ulnaris, runs along the internal margin of the ulna to the carpus, when it divides into ramuscles which supply the ulnar side of the integuments on the back of the hand, and the backs of the two last fingers. At the interval between the heads of the metacarpal bones of the middle and ring fingers, a considerable ramuscle joins one from the ramus superficialis anterior of the nervus radialis or musculo-spiralis.

The Ulnar Nerve, having given off this dorsal branch, descends along the radial margin of the tendon of the flexor ulnaris and of the os pisiforme above the annular ligament, to the palm of the hand. Getting beneath the aponeurosis, it there detaches first a deep seated branch, which penetrates the muscles of the little finger to supply them, the interossei, and the short flexor of the thumb. The ulnar nerve then furnishes a superficial branch, and afterwards divides into three; one for the ulnar side of the little finger, another for the opposing sides of the little and ring finger, and a third which joins the most internal digital branch of the median nerve.



To conclude; the dissector should also attend to what are called the Intercosto-Humeral Nerves. They consist of a branch from the second, and another from the third thoracic, which pass out at the fore and lateral parts of the thorax; the first from beneath the second rib, and the other from beneath the third rib.

The first intercosto-humeral, being connected with a filament from the internal cutaneous, is distributed upon the axillary glands, and the integuments of the axilla and inner side of the arm. The second, being joined by filaments from the first, is chiefly distributed to the integuments on the back of the arm, some of its branches reaching the elbow. The numbness of the inner side of the arm, in angina pectoris, is supposed to be owing to the sympathy of these nerves with the cardiac.



## PART III.

### CHAPTER II.

#### OF THE LOWER EXTREMITIES.

##### SECTION I.

##### *Of the Fascia.*

THE lower Extremity, from the pelvis to the foot, is enveloped by a strong Fascia or Tendinous Membrane lying between the skin and the muscles. This fascia consists, for the most part, of ligamentous fibres, passing in the direction of the length of the limb, secured together by transverse filaments of the same matter, but by no means so abundant. Its structure undergoes some variations; its greater part is decidedly of the character just mentioned; but at the groin it is between ligament and cellular membrane; the latter occasionally predominates so much, that the appearance



of the first is lost, particularly in corpulent subjects. On the contrary, in the lean and such as have suffered from pressure and irritation of the part by hernial protrusion, the ligamentous structure is well developed. On the Gluteus Magnus also, this fascia exists as a condensed cellular membrane, sending in its processes between the fasciculi of the muscle.

The thickness of the Fascia Femoris is not uniform. On the outer side of the thigh, knee, and hip, it is very thick and strong; on the inner side it is thin, and compared with the other, weak. It is thick on the anterior part of the leg, and somewhat thinner on the posterior, but in neither is it so thick as at the outer part of the thigh. At the ankle it is connected with the bony prominences around it, and increasing in thickness it constitutes the annular ligament of the joint for confining the tendons on its anterior part. It is also extended over the foot, and is connected at different points to its margin so as to keep itself tense.

This membrane is very closely attached to the cellular membrane at every point of its external surface, and is kept tense all over by its bony connexions. Above, it arises, from the exterior margin of the pelvis, as constituted by the pubes, Poupart's ligament, the crista of the ilium, the side of the sacrum and the ischium. At the knee it is fastened to the condyles of the os femoris, and to the head of the tibia and fibula. On the posterior part of the thigh it sends in a long process, by which it adheres to the linea aspera.



Its connexion with the knee and ankle, below, fixes it on the leg; besides which it adheres to the spine of the tibia.

Its connexion with the muscles of the lower extremity is very interesting; to some of them it adheres by its internal face, and to others it does not. To the muscles of the hip it adheres closely, and gives origin to some of the fibres of the gluteus medius. To the muscles of the exterior face of the thigh its adherence is generally loose, and indeed in some parts scarcely deserves to be considered as such, as where the internal surface of the fascia is opposed to the tendinous facing of the vastus externus muscle. On the internal semicircumference of the thigh, it adheres somewhat closely to the muscles by cellular membrane. On the leg it is in close connexion with the muscles of its anterior and fibular side, many of their fibres arising from it; but on the posterior face of the leg it is rather loosely fixed to them. From the internal face of the fascia, prolongations of cellular membrane of various densities, sometimes ligamentous, are sent in between most of the muscles. These prolongations separate the muscles from each other, form sheaths in which they repose, and preserve them in their position. As an envelope to the muscles of the leg the fascia is highly useful in supporting and sustaining their action. The knowledge of its peculiar connexion at different parts of the lower extremity, is all important in the management of abscesses of that region.



Though useful, it is not indispensable to make a complete investigation of the fascia at once, but the circumstances mentioned should be very carefully observed in extending downwards the muscular dissection.



## SECTION II.

### *Of the Muscles of the Lower Extremities.*

THE PSOAS MAGNUS, PSOAS PARVUS and ILIACUS INTERNUS are described at pages 255, 256.

The SARTORIUS arises, by a short tendon, from the anterior superior spinous process of the ilium; a body of various breadths in different subjects is then formed, whose fibres are in the direction of its length. It passes in a spiral course to the inner side of the thigh and the internal condyle, and winding under the head of the tibia, advances forwards so as to be inserted into the side of the lower part of its tubercle by a broad tendon. The lower edge of the tendon is continued into the fascia of the leg, by which this muscle is preserved in its spiral direction.

The sartorius muscle is superficial, lying in its whole course immediately beneath the fascia femoris; it cross-



es the rectus femoris, vastus internus, and triceps adductor; at the lower part of the thigh, just above the knee, it is between the tendon of the latter and that of the gracilis.

It bends the leg and draws it obliquely inwards.

The *TENSOR VAGINÆ FEMORIS* is a short muscle just on the outer side of the origin of the sartorius; it arises, tendinous, from the anterior superior spinous process of the ilium, and passes downwards and somewhat backwards between two laminæ of the fascia femoris.

It is inserted, a little below the level of the trochanter major, into the inner face of the fascia femoris. It rotates the foot inwards, and makes the fascia tense.

The *RECTUS FEMORIS* is in front of the thigh bone and just beneath the fascia femoris. It is a complete penniform muscle, fleshy in front for the most part, but faced behind with tendon. It arises, from the anterior inferior spinous process, by a round tendon, which is joined by another tendon coming from the superior margin of the acetabulum.

It is inserted into the superior surface of the patella by a strong tendon, and intermediately by the ligamentum patellæ into the tubercle of the tibia.

It extends the leg.



Under the rectus femoris, the anterior and lateral parts of the thigh bone are enveloped by a large muscular mass, considered, by most anatomists, as three distinct muscles, called Vastus Externus, Vastus Internus, and Cruræus or Cruralis. Their heads are very distinguishable from each other; but below they are inseparably united and join with the patella.

The VASTUS EXTERNUS, a very large muscle on the outside of the thigh, arises, tendinous and fleshy, from the upper part of the os femoris immediately below the trochanter major. Its origin commences in front, and passes obliquely around the bone to the linea aspera. It continues, afterwards, to arise the whole length of the linea aspera, and from the upper half of the line running from it to the external condyle.

Its fibres pass inwards and downwards, and are inserted, by a flat tendon, into the external edge of the tendon of the rectus, and also into the external upper part of the patella. This muscle has a broad tendinous surface exteriorly and above; at its lower part it has a tendinous facing on the side next to the bone.

It also extends the leg.

The VASTUS INTERNUS covers the whole inside of the os femoris. It arises, by a fleshy and pointed origin, in front of the os femoris just on a level with



the trochanter minor; tendinous and fleshy, from the whole length of the internal edge of the linea aspera and from the line leading from it to the internal condyle.

Its fibres descend obliquely, and are inserted by a flat tendon into the internal edge of the tendon of the rectus, and into the upper internal edge of the patella.

It also extends the leg.

The CRURÆUS MUSCLE is almost completely overlapped and concealed by the two vasti, and is immediately behind the rectus femoris. The edge of the vastus externus above is very distinguishable from it as it overlaps it, and is rounded off, besides being somewhat separated by vessels. But the origin of the cruræus on the side of the vastus internus is not so distinct, as the fibres of the two muscles run together; it is therefore necessary most frequently to cut through some of the fibres on the internal face of the os femoris on a level with the trochanter minor. The cruræus will then be seen to arise, fleshy, from all the fore part of the bone, and from all its outside as far as the linea aspera. Between the internal edge of this muscle and the linea aspera, the interior face of the os femoris is unoccupied, for an inch, along the whole shaft of the bone, which is very readily seen by turning off the vastus internus.

The Cruræus is inserted into the posterior face of the tendon of the rectus below, and into the upper surface of the patella. It also extends the leg.



The *Ligamentum Patellæ* is the common chord by which the action of the four last named muscles is communicated to the tibia. It is a flattened thick tendon an inch and a half wide, arising from the inferior edge of the patella, and inserted into the tubercle of the tibia. Besides this, a fascia or tendinous expansion, a continuation of the fascia of the thigh and called *Involucrum*, comes from the inferior ends of these muscles, and extends itself over the whole of the anterior and lateral parts of the knee joint, and is inserted into the head of the tibia and of the fibula. Through this it happens that even when the patella or its tendon is fractured, some motion or extension may be communicated to the leg from the thigh.\*

The *GRACILIS* is a beautiful muscle at the inner margin of the thigh, which lies immediately under the fascia, and extends from the pelvis to the leg.

It arises, by a broad thin tendon, from the front of the os pubis just at the lower part of its symphysis, and from its descending ramus; the muscle tapers to a point below, and a little above the knee terminates in a round tendon which passes behind the internal condyle of the os femoris and the head of the tibia. It then makes a curve forwards and downwards at the internal side of the latter, and is inserted at the lateral and inferior part of its tubercle.

\* A case of this kind was lately in the Philadelphia Almshouse.



The tendon at the knee is beneath the tendon of the sartorius. This muscle is a flexor of the leg.

The PECTINALIS is a short fleshy muscle at the inner edge of the psoas magnus. It arises, fleshy, from the concavity on the upper face of the pubes between its crista and the ridge above the obturator foramen; and is inserted tendinous into the linea aspera, immediately below the trochanter minor.

It draws the thigh inwards and forwards.

The TRICEPS ADDUCTOR FEMORIS is a large muscular mass consisting of three distinct portions, which are placed at the inner side of the thigh, and contribute much to fill up the vacuity between the thigh bones above. These portions are

1. The ADDUCTOR LONGUS which comes, by a rounded short tendon, from the upper front part of the pubes near its symphysis; it forms a triangular belly which increases in breadth in its descent, and is inserted into the middle third of the linea aspera at its inner edge.

This muscle, as the subject lies on its back, is uppermost of the three; its origin is between that of the pectinalis and of the gracilis; its upper edge is in contact with the lower edge of the pectinalis.

2. The ADDUCTOR BREVIS is the smallest of the three;



it is situated beneath the adductor longus and pectinalis, and on the outside of the gracilis. It arises by a rounded tendon from the middle front part of the pubes between its symphysis and the foramen thyroideum, just below the origin of the first adductor.

It is inserted into the upper third of the inner edge of the linea aspera; between the trochanter minor and the upper edge of the adductor longus, by a flat thin tendon.

3. The ADDUCTOR MAGNUS is below the other two, and is by far the largest. It arises, fleshy, from the lower part of the body of the pubes and from its descending ramus, also from the ascending ramus of the ischium as far as its tuberosity, occupying the whole bony surface between the foramen thyroideum below, and the margin of the pelvis.

It is inserted, fleshy, the whole length of the linea aspera, and on its internal margin a tendon is gradually generated, which passes downwards to be inserted into the upper part of the internal condyle of the os femoris, and by a thin edge or expansion into the line leading from the linea aspera to the internal condyle.

The adductor magnus separates the muscles on the anterior from such as are on the posterior part of the thigh, and its insertion is closely connected with the origin of the vastus internus, the two surfaces adhering by a short and compact cellular membrane.



The three adductors contribute to the same end, that of drawing the thigh inwards.

The subject should now be turned over in order to enable us to study the muscles on the back of the limb.

The **GLUTEUS MAGNUS** arises fleshy, from the posterior third of the spine of the ilium, from the side of the sacrum below it, from the side of the os coccygis, and from the posterior surface of the large sacro-sciatic ligament. The fibres of this muscle are collected into large fasciculi with deep interstices between them, and the lower edge of it is folded over the posterior sacro-sciatic ligament.

Its fibres pass obliquely forwards and downwards, and terminate in a thick broad tendon, the upper part of which goes on the outside of the trochanter major, and is very strongly inserted into the fascia femoris, and the lower part is inserted into the upper third of the linea aspera going down as far as the origin of the short head of the biceps flexor cruris.

This muscle is placed immediately under the skin, the fasciculi being separated to some depth by processes from the fascia femoris. It covers nearly all the other muscles on the back part of the pelvis, laps over its inferior margin laterally, and conceals the origins of the hamstring muscles. It draws the thigh backwards.



The **GLUTEUS MEDIUS** arises from the whole length of the spine of the ilium, except its posterior part, and from that part of the dorsum of the bone which is between its crista and the semicircular ridge extending from the anterior superior spinous process to the sciatic notch; also from the lunated edge of the os ilium between the anterior superior and anterior inferior spinous process, and from that part of the inner face of the fascia femoris which covers it.

The anterior superior part of this muscle is not covered by the gluteus magnus, but lies before it. Its fibres converge, and are inserted, by a broad thick tendon, into the upper surface of the trochanter major, and into the upper anterior part of the shaft of the bone just in front of the same trochanter.

It draws the thigh backwards and outwards.

The **GLUTEUS MINIMUS** arises from that part of the dorsum of the ilium between the semicircular ridge, just spoken of, and the margin of the capsular ligament of the hip joint. It is entirely concealed by the gluteus medius.

Its fibres converge and terminate in a round tendon, which is inserted into the anterior and superior part of the trochanter major, just within the anterior insertion of the gluteus medius.

It abducts the thigh, and can also rotate the limb inwards.

There are several small muscles about the hip joint,



the most of which can be seen by the removal of the gluteus magnus.

The **PYRIFORMIS** arises, fleshy and tendinous, within the pelvis, from the anterior face of the second, third, and fourth bones of the sacrum. It forms a conical belly which passes out of the pelvis at the upper part of the sacro-sciatic foramen, receiving a slip of fibres from the posterior inferior spinous process of the ilium.

It is inserted, by a round tendon, into the upper middle part of the trochanter major within the insertion of the gluteus medius.

It rotates the limb outwards.

The **GEMINI** are two small muscles closely connected with each other, which are situated lower down on the limb than the pyriformis. The upper one arises from the posterior part of the root of the spinous process of the ischium; the lower from the upper back part of the tuberosity of the ischium.

Being parallel to each other, and connected by their contiguous edges, they are inserted together into the posterior part of the thigh bone at the root of the trochanter major, where the rough pit is.

They also rotate the limb outwards.

The **OBTURATOR INTERNUS** muscle is principally situated within the cavity of the pelvis. It arises, fleshy,



from all the pelvic margin of the foramen thyroideum except where the obturator vessels go out, and from the internal face of the ligamentous membrane stretched across it; also from the upper part of the plane of the ischium just below the linea innominata; its fibres converge, and, forming a tendon, pass out of the pelvis over the trochlea of the ischium between the sacro-sciatic ligaments.

The tendon is placed between the gemini muscles, which form a sheath for it; and it is inserted into the pit on the back of the os femoris at the root of the trochanter major.

It rotates the limb outwards.

The **QUADRATUS FEMORIS** is below the other muscles. It arises, tendinous and fleshy, from the ridge on the outer side of the ischium which constitutes the exterior boundary of the tuberosity.

Its fibres are transverse; and are inserted, fleshy, into the rough ridge of the os femoris on its back part and which goes from one trochanter to the other.

It rotates the limb outwards.

The **OBTURATOR EXTERNUS** is concealed in front, by the pectineus and triceps adductor, and behind by the quadratus femoris; to get a satisfactory view of it, therefore, these muscles should be detached from the bone. It arises from the whole exterior circumference of the foramen thyroideum, excepting the place



where the obturator vessels come out, and from the exterior face of the ligamentous membrane stretched across it.

The fibres of this muscle converge, pass beneath the capsular ligament of the hip joint adhering to it, and terminate successively in a round tendon which is inserted into the inferior part of the cavity on the posterior surface of the os femoris, at the root of the trochanter major. The course of the tendon of this muscle is marked on the neck of the thigh bone by a superficial fossa.

It rotates the thigh outwards.

The *BICEPS FLEXOR CRURIS* constitutes the outer hamstring, and is situated on the posterior outer part of the thigh; it arises by two heads. The first, called the long head, has an origin, in common with the semitendinosus, from the upper back part of the tuberosity of the ischium by a short tendon, which in its descent, is changed into a thick fleshy belly. The other, called the short head, arises, by an acute fleshy beginning, from the linea aspera just below the insertion of the gluteus magnus, and is continued along the lower part of the linea aspera from the ridge leading to the external condyle.

A thick tendon is gradually formed on the outside of the muscle and is inserted into the upper part of the head of the fibula.

This muscle flexes the leg on the thigh.



The **SEMITENDINOSUS** is on the inside of the thigh, between the biceps and gracilis; it is superficial, being immediately under the fascia, and arises, in common with the biceps, from the back part of the tuberosity of the ischium; it also adheres, for three or four inches, to the inner edge of the tendon of this the long head of the biceps.

About four inches above the knee it terminates in a long round tendon, which passes behind the internal condyle and the head of the tibia, and is reflected forwards to be inserted into the side of the tibia, just below its tubercle and very near it, being lower down than the insertion of the tendon of the gracilis.

It flexes the leg on the thigh.

The **SEMIMEMBRANOSUS** is at the inner side of the thigh; its upper part is concealed by the semitendinosus and the origin of the long head of the biceps, and below, it projects between these two muscles. It is in contact with the posterior surface of the adductor magnus.

It arises, by a thick round tendon, from the exterior upper part of the tuberosity of the ischium, which tendon soon becomes flattened and sends off the muscular fibres obliquely from its exterior edge, to a corresponding tendon below. The latter passing behind the internal condyle and the head of the tibia, detaches a thin aponeurotic membrane under the inner head of the gastrocnemius, to cover the posterior part of the



capsule of the joint, and to be fastened to the external condyle.

It is inserted, by a round tendon, into the inner and back part of the head of the tibia just below the joint. The unfavourable insertion of this muscle is compensated by the course of its fibres, which gives it great increase of strength.

It flexes the leg on the thigh.

### *Muscles of the Leg.*

These muscles are situated anteriorly, posteriorly, and externally.

The **TIBIALIS ANTICUS** muscle is situated superficially under the fascia of the leg, at the outside of the spine of the tibia, and in front of the interosseous ligament. It arises, fleshy, from the head, outer surface, and spine of the tibia, and from the interosseous ligament, to within three or four inches of the ankle. It also arises by its front surface from the internal face of the fascia of the leg.

A rounded long tendon is formed below, which, passing through a distinct noose of the annular ligament in front of the malleolus internus, crosses the astragalus and os naviculare; and is inserted into the anterior part of the base of the cuneiforme internum, and into the adjacent part of the metatarsal bone of the great toe.



It bends the foot, and presents the sole obliquely inwards.

The **EXTENSOR LONGUS DIGITORUM PEDIS**, is also superficially placed just under the fascia of the leg and in front of the fibula, being in contact above with the tibialis anticus, and below with the extensor proprius pollicis. It arises, tendinous and fleshy, from the outer part of the head of the tibia, from the head of the fibula, and almost the whole length of its anterior angle; also from the upper part of the interosseous ligament and the internal face of the fascia of the leg.

About the middle of the leg this muscle splits into four tendons, which are confined by the annular ligament of the ankle, and then diverging, are inserted respectively into the base of each toe, except the big, and expanded over its back part as far as the last phalanx.

It extends all the joints of the small toes and flexes the foot.

The **PERONEUS TERTIUS** is rather a portion of the extensor longus; is found at its lower outer part, and cannot be naturally separated from it. It arises from the anterior angle of the fibula, between its middle and lower end.

It is inserted, by a flattened tendon, into the base of the metatarsal bone of the little toe, and assists in bending the foot.



The **EXTENSOR PROPRIUS POLLICIS PEDIS** is between the lower part of the tibialis anticus, and the extensor longus. It arises from the fibula between its anterior and internal angles, by a tendinous and fleshy origin, which commences about four inches below the head of the fibula, and continues almost to its inferior extremity. A few fibres also come from the interosseous ligament, and from the lower part of the tibia.

The muscle being half penniform, the fibres run at its fore part obliquely to a tendon, which passes under the annular ligament, and over the astragalus scaphoides and upper internal parts of the foot, to be inserted into the base of the first and second phalanx of the great toe.

On the outside of the leg, between the fibula and fascia, are the two **Peronei** muscles.

The **PERONEUS LONGUS** seu **PRIMUS** arises, tendinous and fleshy, from the fore and outside of the head of the fibula from the space on its outer side above, between the external and anterior angles, also from its external angle to within a short distance of the ankle.

A flattened thick tendon constitutes the outer face of the muscle, to which the fibres pass obliquely. This tendon is lodged in the groove at the posterior part of the malleolus externus, being confined to it by a thick ligamentous noose, and traverses the outer side of the os calcis, where its passage is marked by a superficial



sulcus. It then runs through the groove of the os cuboides, and lying deep in the sole of the foot next to the tarsal bones, is inserted into the base of the internal cuneiform bone, and into the adjacent part of the metatarsal bone of the great toe.

It extends the foot and inclines the sole obliquely outwards.

The PERONEUS BREVIS seu SECUNDUS is concealed in a great degree by the peroneus longus, being situated between the latter and the extensor longus digitorum. It arises, tendinous and fleshy, from the outer surface of the fibula, commencing about one third of the length of the bone from its head, and continuing almost to the ankle.

A tendinous facing exists externally also in this muscle, to which its fibres proceed obliquely. This tendon is continued through the fossa at the back part of the malleolus externus, being covered by the tendon of the peroneus longus, and confined by the same ligamentous noose, and passing through the superficial fossa at the outer side of the os calcis, is inserted into the external part of the base of the metatarsal bone of the little toe. It extends the foot and presents the sole obliquely downwards.

The Triceps Suræ is placed on the back of the leg, and consists of Gastrocnemius and Soleus which in fact form but one muscle.



The **GASTROCNEMIUS** is the most superficial and conceals the other in consequence of its breadth. It arises from the condyles of the os femoris by two heads. One head arises, tendinous, from the upper back part of the internal condyle, and fleshy, from the ridge leading to the linea aspera; the other head arises, by a broad tendon in the same way, from the external condyle and the ridge above it. A triangular vacancy is left between the heads of the muscle for the passage of the popliteal vessels; they then join together, but in such a way that the appearance of two bellies is distinctly preserved, of which the internal is the largest. The muscular fibres pass from a broad tendinous facing on the back to a corresponding one on the front surface of the muscle, from the latter of which comes the *Tendo Achillis*.

The heads of the gastrocnemius being detached from their origin, we then see the *Soleus* or *Gastrocnemius Internus*.

The **SOLEUS** arises, fleshy, from the posterior part of the head of the fibula and from the external angle of that bone for two-thirds of its length down, behind the *peroneus longus*. It also arises, fleshy, from the oblique ridge on the posterior surface of the tibia, just at the lower edge of the *popliteus* muscle, and from the internal angle of the tibia for four or five inches. The two heads are separated for the passage of the posterior tibial vessels.



The body of this muscle has a great intermixture of tendinous matter in it, and from its lower extremity proceeds the other origin of the tendo Achillis; about three or four inches above the heel, this tendon joins the anterior face of the tendon of the gastrocnemius, and by the union of the two is formed the Tendo Achillis, which is inserted into the posterior inferior surface of the os calcis near its tuberosities.

These two muscles extend the foot, and are all-important in walking.

The PLANTARIS is a singular little muscle concealed by the gastrocnemius, and has a short fleshy belly and a long tendon. It arises, fleshy, from the ridge of the os femoris just above the external condyle; passes across the capsular ligament of the joint, adhering to it in its course; the belly terminates somewhat below the head of the tibia in a long delicate tendon which descends between the inner head of the soleus and the gastrocnemius.

At the place where these tendons unite, the tendon of the plantaris emerges from between them, and, running at the inner edge of the tendo Achillis, is inserted into the inside of the os calcis just before the insertion of the tendo Achillis.

It extends the foot.

The POPLITEUS is a triangular muscle on the back of the knee joint. It arises from a deep depression on the



exterior face of the external condyle, by a thick round tendon, which passes through the capsular ligament, being connected with the external semilunar cartilage, and then forms a fleshy belly that passes obliquely inwards and downwards.

It is inserted, fleshy, into the oblique ridge on the back of the tibia just below its head, and into the triangular depression above it.

It bends the leg, and when bent, rotates it inwards.

By removing the soleus we expose three other muscles on the back of the leg, the Tibialis Posticus, the Flexor Longus Digitorum Pedis, and the Flexor Longus Pollicis Pedis. These muscles are covered by a thick strong fascia, from which some of their fibres originate, and which should be removed.

The FLEXOR LONGUS DIGITORUM PEDIS PERFORANS is behind the tibia, and at the inner edge of the tibialis posticus. It arises, by an acute, tendinous, and fleshy beginning, from the back of the tibia a little below the popliteus muscle, its origin being continued from the internal angle of the tibia almost to the ankle joint. It arises also, by tendinous and fleshy fibres, from the outer edge of the tibia, just above its connexion with the fibula at the ankle; and between this double order of fibres the tibialis posticus lies.

The fibres pass obliquely into a tendon at the posterior edge of the muscle, which runs in the groove of



the internal malleolus, and is confined there by a strong ligamentous sheath. The tendon then gets to the sole of the foot along the sinuosity of the os calcis, and, being joined by a considerable tendon detached from the flexor longus pollicis, it divides into four branches which are appropriated to the four small toes.

These tendons are inserted into the bases of the last phalanges of the lesser toes, are very near the tarsal bones, and, from perforating the tendons of the flexor brevis, correspond with the flexor perforans of the hand.

This muscle flexes the small toes and extends the foot.

The FLEXOR LONGUS POLLICIS PEDIS is a stout muscle formed of oblique fibres, situated on the back part of the fibula, and at the outer side of the tibialis posterior. It arises by an acute, tendinous, and fleshy beginning from the posterior flat surface of the fibula, commencing about three inches from its head, and continuing almost to the ankle.

The tendon of this muscle is large and round; it forms gradually, and constitutes a facing to the posterior edge of the muscle. It passes through a superficial fossa of the tibia at the back of the ankle, near its middle, and from thence through a notch in the back edge of the astragalus to the sole of the foot, where it crosses the tendon of the flexor longus digitorum,



giving off the branch just mentioned to join it. This tendon is deeper seated in the foot than the other.

The tendon of the flexor longus pollicis is inserted into the last joint of the great toe. It bends the great toe, and from its connexion with the others will bend them also.

The **TIBIALIS POSTICUS** is placed between, and concealed by the two last muscles. It arises, by a narrow fleshy beginning, from the front of the tibia, at the under surface of the process which joins it to the fibula, and then gets to the back of the leg, through a hole in the interosseous ligament. It continues its origin from the whole of the interosseous ligament, and from the surfaces of the tibia and fibula, bordering on the ligament, excepting one-third of the lower part of the fibula, and rather more of the lower part of the tibia.

The fleshy fibres run obliquely to a middle tendon, which passes in the groove at the back of the malleolus internus, and is inserted into the upper internal part of the os naviculare. This tendon also divides in such a way as to be inserted into the internal and external cuneiform bones, into the os cuboides, and os calcis.

It extends the foot, and presents the sole obliquely inwards.



*Of the Muscles of the Foot.*

THE EXTENSOR BREVIS DIGITORUM PEDIS is the only muscle on the superior surface of the foot. It is placed beneath the tendons of the extensor longus, and arises, tendinous and fleshy, from the fore upper part of the greater apophysis of the os calcis, being connected with the origin of the annular ligament of the ankle. It forms a short fleshy belly, which is partially divided into four parts; from these bellies proceed as many tendons, which crossing very obliquely the tendons of the extensor longus, are inserted into the great toe and the three next toes, by joining with the tendons of the extensor longus, which are spread over their backs. It extends the toes.

The Sole of the Foot is protected, in the first place, by an unusual thickness of its cuticle, which is increased in such parts as are most pressed upon, as the heel, and the ball of the great toe.

Beneath it is a thick layer of adipose matter, found in the most emaciated as well as the most corpulent subjects, which seems to be less under the influence of the causes producing a diminution or increase of fat, than the adipose matter in any other part of the body. It is collected into granulations separated from each other by processes of condensed cellular membrane resembling ligament, that pass from the interior sur-



face of the skin to the aponeurosis plantaris. It fills up completely all the fissures in this aponeurosis, and adheres very closely to it, so that it requires much trouble to get out a fair dissection of the aponeurosis.

The APONEUROSIS, or FASCIA PLANTARIS, is a ligamentous membrane, extending from the tuberosities of the os calcis, to the anterior ends of the metatarsal bones. It is triangular, and corresponds with the outline of the foot, by being narrow behind, and broad before. It is divided into three parts, according to the division of the muscles of the foot, one part lying on the muscles at the outside of the sole, another on the muscles at the inside of the sole, and the third being between the other two. The internal and external portions are thin, and reticulated; they extend from the tuberosities of the os calcis to the roots of the internal and external metatarsal bones, and are scarcely seen beyond them. But the central portion is remarkably strong near the heel, and diminishes in thickness as it spreads out. Anteriorly, it is divided into five portions, one for each metatarsal bone; each of these portions is bifurcated, and dips down to be inserted on either side of the metatarsal bone near its head and into the bases of the first phalanges of the toes. Between the prongs of each bifurcation pass the tendons nerves, &c. to the toes. The interior face of this membrane affords origin to many of the muscular fibres, and from it proceed vertical partitions, separat-



ing the muscles of the middle of the foot from such as are on each side of it.

When the Aponeurosis Plantaris is removed, we see three muscles; the middle one under the large central portion of the aponeurosis, is the Flexor Brevis Digitorum Pedis, the outer is the Abductor Minimi Digiti, and the inner the Abductor Pollicis Pedis.

The FLEXOR BREVIS DIGITORUM PEDIS arises, fleshy, from the large tuberosity of the os calcis by a narrow beginning, also from the interior surface of the aponeurosis and the tendinous septa between it and the contiguous muscles.

It forms a fleshy belly going nearly as far forwards as the middle of the metatarsal bones; there it divides into four tendons, which go to the smaller toes. These are perforated by the tendons of the flexor longus, and are inserted into the sides of the second phalanges. The tendon for the little toe is often deficient.

It bends the second joint of the toes.

By detaching this muscle from its origin and turning it down, we bring into view the tendon of the Flexor Longus Digitorum Pedis, and its attachments behind, to the tendinous slip from the Flexor Longus Pollicis, and to the Massa Carnea Jacobi Sylvii, or Flexor Accessorius, and before, to the Lumbricales muscles.



The **FLEXOR ACCESSORIUS** is at the outside of the tendon of the flexor longus. It arises, fleshy, from the inside of the sinuosity of the os calcis, and by a thin tendon, from the outside of the bone before its tuberosities.

It is inserted, fleshy, into the outside of the tendon of the flexor longus, just at its division into four tendons. Like a second hand at a rope, it assists in flexing the toes.

The **LUMBRICALES PEDIS** are four small tapering muscles which arise from the tendon of the flexor longus just after its division, or while it is in the act of dividing. One of them is appropriated to each lesser toe, and is inserted into the inside of its first phalanx, and into the tendinous expansion that is sent off from the extensor muscle to cover its back.

They increase the flexion of the toes and draw them inwards.

The **ABDUCTOR POLLICIS PEDIS** arises, tendinous and fleshy, from the internal anterior part of the large tuberosity of the os calcis, from a ligament extended from the tuberosity to the sheath of the tendon of the tibialis posticus, from the internal side of the naviculare, and from the cuneiforme internum.

It forms the internal margin of the sole of the foot, and is inserted, tendinous, into the internal sesamoid



bone and into the base of the first phalanx of the great toe.

It draws the great toe from the rest.

The FLEXOR BREVIS POLLICIS PEDIS is situated immediately at the exterior edge of the abductor pollicis. It consists of two bellies, parallel with each other, but separated by the tendon of the flexor longus pollicis; one is inseparably connected with the tendon of the abductor pollicis, and the other with the adductor pollicis.

It arises, tendinous, in common with the calcaneo-cuboid ligament from the under part of the os calcis just behind its connexion with the os cuboides, and from the under part of the external cuneiform bone.

The internal belly is inserted, tendinous, into the internal sesamoid bone along with the tendon of the abductor pollicis; and the external belly is inserted, tendinous, into the external sesamoid bone along with the tendon of the adductor pollicis. Each insertion is continued on to the base of the first phalanx of the great toe.

It flexes the great toe.

The ADDUCTOR POLLICIS PEDIS is situated at the outside of the flexor brevis, and is extended obliquely across the metatarsal bones. It arises, tendinous at the external part of the foot, from the calcaneo-cuboid ligament



and from the roots of the second, third, and fourth metatarsal bones.

It is inserted, tendinous, into the external sesamoid bone, which insertion is continued to the first phalanx of the great toe, and is closely united to the tendon of the external head of the flexor brevis pollicis.

It draws the great toe towards the others.

The ABDUCTOR MINIMI DIGITI PEDIS forms the external margin of the sole of the foot, and is immediately beneath the aponeurosis plantaris. It arises, tendinous and fleshy, from the outer tuberosity of the os calcis, and also from the exterior part of the base of the metatarsal bone of the little toe.

It is inserted, by a round tendon, into the exterior part of the base of the first phalanx of the little toe.

It draws the little toe from the other toes.

The FLEXOR BREVIS MINIMI DIGITI PEDIS is just within the tendon of the abductor minimi digiti. It arises from the ligament which is extended from the tuberosity of the cuboid bone to the heads of the metatarsal bones; also from the root of the fifth metatarsal bone.

It is inserted, by a tendon, into the lower part of the first phalanx of the little toe at its base, and into the head of the metatarsal bone of the same toe. It bends the little toe.



The **TRANSVERSALIS PEDIS** is placed beneath the tendons of the flexor muscles. It is small, and lies across the anterior extremities of the metatarsal bones. It arises, tendinous, from the capsular ligament of the first joint of the little toe; it also arises from the capsule of the first joint of the next toe.

It is inserted into the exterior face of the common tendon of the adductor and flexor brevis pollicis at the external sesamoid bone.

It approximates the heads of the metatarsal bones.

The **Interosseous Muscles** are seven in number, four of which may be seen on the upper surface of the foot. There are two to the first small toe, two to the second, two to the third, and one to the fourth or little toe. The muscles seen on the upper side of the foot are for the most part double headed, that is they arise from the contiguous surfaces of the metatarsal bones.

The **INTEROSSEUS PRIMUS DIGITI PRIMI PEDIS** or the **ABDUCTOR INDICIS PEDIS** is seen superiorly. It is placed between the metatarsal bone of the great toe and the first small toe, and arises, fleshy, by a double head, from the opposed surfaces of their roots.

It is inserted, tendinous, into the inside of the root of the first joint of the first small toe, and pulls it inwards.



The *INTEROSSEUS SECUNDUS PRIMI DIGITI*, or the *ABDUCTOR INDICIS PEDIS*, is also external or above. It is situated between the metatarsal bones of the first and second small toes, arises from the opposed surfaces of their roots by a double fleshy and tendinous head.

It is inserted into the outside of the first phalanx of the same toe by a tendon. It draws this toe outwards.

The *INTEROSSEUS PRIMUS SECUNDI DIGITI PEDIS*, or the *ABDUCTOR MEDII DIGITI*, is at the bottom of the foot, and arises from the inside of the metatarsal bone of the second small toe.

It is inserted into the inside of the first phalanx of the second toe.

It draws this toe inwards.

The *INTEROSSEUS SECUNDUS DIGITI SECUNDI*, or the *ADDUCTOR MEDII DIGITI*, is seen at the upper part of the foot, between the second and third metatarsal bones of the lesser toes, arising from the opposed surfaces of their roots.

It is inserted, tendinous, into the outside of the base of the first phalanx of the second small toe. It draws this toe outwards.

The *INTEROSSEUS PRIMUS DIGITI TERTII*, or the *ABDUCTOR TERTII DIGITI*, is in the sole of the foot. It arises from the inside of the metatarsal bone of the third toe near its root, and is



Inserted, tendinous, into the inside of the base of the first phalanx of the third toe.

It draws this toe inwards.

The INTEROSSEUS SECUNDUS DIGITI TERTII, or the ADDUCTOR TERTII DIGITI, is seen on the upper surface of the foot, occupying the interval of the metatarsal bones of the third and fourth small toes, and arises, by a double head, from the opposite surfaces of their roots.

It is inserted, tendinous, into the outside of the root of the first phalanx of the third small toe.

It draws this toe outwards.

The INTEROSSEUS DIGITI MINIMI, or the ADDUCTOR, is on the under surface of the foot. It arises from the inside of the base of the metatarsal bone of the fourth small, or the little toe, and is

Inserted, tendinous, into the inside of the first phalanx of the little toe. It draws this toe inwards.



### SECTION III.

#### *Of the Blood Vessels of the Lower Extremities.*

THE FEMORAL ARTERY, (Arteria Femoralis,) is a continuation of the external iliac. It appears first on the



thigh, half-way, or nearly so, between the symphysis pubis and the anterior superior spinous process of the ilium; emerging from beneath Poupart's ligament, it is there covered only by the skin and fascia of the part, having the femoral vein at its inside, and the trunk of the anterior crural nerve, about half an inch from it on the outside. It lies upon the psoas magnus muscle, crosses the pectinalis, and the whole of the insertion of the adductor longus muscle. About one-third of the length of the thigh bone from below, it penetrates the insertion of the adductor magnus and gets to the ham, being then behind the leg. For the upper third of its course the femoral artery is at the inner edge of the rectus femoris, and but a little distance from it; it then inclines inwards and occupies the angle formed by the contact of the vastus internus, and the adductor longus. Above, the sartorius is at its outside; but as this muscle inclines very rapidly inwards, immediately after its origin, it in a little time begins to pass along the external margin of the artery; and shortly afterwards covers the artery completely to the place where it penetrates the adductor. Where the artery lies in the angle formed by the adductor longus, and the vastus internus, it is covered by a strong interlacing of tendinous fibres from the muscles, and is also enveloped by its own cellular coat.

To cut upon the femoral artery in any part of its course, lay the subject horizontally, and turn the leg outwards, so that the external margin of the sole of



the foot will be in contact or nearly so with the table. A line drawn then from midway between the anterior superior spine of the ilium, and the symphysis pubis, to the centre of the internal condyle of the os femoris, will be precisely over it.\*

The following branches come from the Femoral Artery:

1. The first is called by Haller, *Arteria ad Cutem Abdominis*. From this a branch is sent upwards towards the umbilicus under the skin, and one more to supply the inguinal glands.

2. The EXTERNAL PUDIC (*Arteriæ Pudendæ Externæ*), two or three in number; they are sent to the integuments and lymphatic glands of the groin, also to the skin of the penis and scrotum, or to the labia externa. One of these trunks arises from the upper internal part of the femoral artery, and the other sometimes from the profunda.

The arteries as yet mentioned, anastomose freely with each other; are irregular in their number, size, and origin, but for the most part do not exceed the size of a common knitting-needle.

3. The PROFOUND ARTERY, (*Arteria Profunda Femoris*), is very happily called, by Professor Chaussier,

\* Marjolin.



La Grande Musculaire De La Cuisse, in consequence of its distribution. It is almost equal in size to the femoral itself, and arises from its posterior part on a level with the trochanter minor, but sometimes only five or six lines below Poupart's Ligament. It immediately begins to give off branches externally and internally, but the main trunk of the artery continues for several inches in contact with the femoral artery or nearly so, and beneath it. It then terminates gradually by branches which penetrate to the back of the thigh.

The profunda femoris is distributed as follows:

a. The EXTERNAL CIRCUMFLEX, (*Arteria Circumflexa Externa*,) arises from its external superior part, sometimes, however, from the femoral itself; it passes outwards under the sartorius and the rectus femoris, and divides into two secondary branches. The superior and shorter of these is distributed to the parts about the trochanter major, as the anterior edges of the gluteus medius and minimus, the capsule of the hip joint, and the heads of the extensor muscles. The second goes along the outside of the thigh to the patella, and is about the size of a crow-quill. It first passes obliquely between the rectus and the cruræus, and then vertically under the anterior margin of the vastus externus, between it and the cruræus till it terminates about the knee, by anastomosing with the articular arteries. It is principally distributed to the cruræus and vastus externus.



*b.* The INTERNAL CIRCUMFLEX, (Art. Circumflexa Interna,) arises from the inner side of the profunda, just below the external circumflex, but sometimes it also comes from the femoral. It is somewhat under the size of the other, and penetrates between the psoas magnus and pectinalis; it winds under the neck of the os femoris, and divides into two branches which supply the contiguous parts, as the heads of the muscles and the joint.

*c.* Several ramifications are also sent from the profunda to supply the anterior faces of the adductor muscles; they are irregular in number, size, and place of origin, and have no appropriate names.

*d.* The PERFORATING ARTERIES, (Rami Profundi Perforantes,) three or four in number, are given off successively, are numerically named, and all penetrate the adductor muscles near the thigh bone to get to the back of the thigh.

The first arises immediately below the little trochanter, and gets through the adductor magnus just below the quadratus femoris, to be distributed about the heads of the hamstring muscles.

The second penetrates the adductor magnus at the lower part of the insertion of the gluteus maximus into the linea aspera, to be distributed about there and to the corresponding section of the long head of the biceps flexor cruris.



The third penetrates the adductor magnus a little below the commencement of the origin of the short head of the biceps, and is distributed thereabout.

The fourth penetrates the adductor magnus about an inch and a half above the hole for the femoral artery, and is distributed to the neighbouring part of the adductor and to the hamstring muscles.

After the origin of the profunda, the femoral artery gives off three or four twigs the size of a large knitting-needle, which are disposed of, upon the sartorius, adductors, vastus internus, and integuments, but they are too irregular in number, origin, and course for systematic description.

The ANASTOMOSING ARTERY, (*Arteria Anastomotica*,) the last branch of the femoral, is sent from it just before it enters the aperture in the adductor magnus. This artery descends, in the course of the tendon of this adductor, to the knee, in front of the tendon, between it and the vastus internus muscle. It is distributed to the parts lying along its course.

The POPLITEAL ARTERY, (*Arteria Poplitæa*) is the continuation of the femoral after the latter has passed through the adductor tendon and got to the back of the lower extremity, and extends from this point to the opening in the interosseous ligament of the leg, just below the heads of the bones. Its first act is to cross obliquely the os femoris as far as its middle; it then



passes in a vertical line downwards, very nearly over the centre of the os femoris, knee joint, and head of the tibia, being only separated from these parts in consequence of a thick envelope of fat, which fills up the hollow of the ham, and protects the artery from the effects of sudden flexions of the part and of bruises. The popliteal artery sends off the following branches:

1. The Superior Internal Articular Artery, (*Articularis Superior Interna*) sometimes exists as two trunks; it arises just above the internal condyle, perforates the adductor tendon, and, going horizontally, is spent on the inner side of the joint above.

2. The Superior External Articular Artery, (*Articularis Superior Externa*) arises just above the external condyle, passes horizontally between the femur and the biceps flexor, and is distributed to the upper external parts of the joint.

3. The Middle Articular, (*Articularis Media*) sometimes comes from one of the others; it is distributed to the posterior middle parts of the knee joint.

4. The Inferior Internal Articular Artery, (*Articularis Inferior Interna*) arises on a level with the inferior part of the internal condyle. It descends obliquely, passes between the lateral ligament and the head of the tibia, and then mounts towards the patella, to be distributed in numerous branches.

5. The Inferior External Articular Artery, (*Articularis Inferior Externa*), arises near the last, and sometimes they are derived from a common trunk. It passes



between the external lateral ligament and the head of the tibia, mounts afterwards towards the patella, and is then minutely ramified on the lower external parts of the knee joint.

The upper Articular arteries anastomose with the lower, and also with the anastomotic and the long branch of the external circumflex.

Below the knee, the popliteal artery is over the popliteus muscle and between the heads of the gastrocnemius. Here it sends off a large branch to each head of the gastrocnemius muscle, and small irregular branches to the other muscles, and sometimes the nutritious artery of the tibia.

On a level with the aperture of the interosseous ligament, the popliteal artery may be considered as terminating by a division into two large branches, the Anterior Tibial, and the Posterior Tibial.

The ANTERIOR TIBIAL ARTERY, (*Arteria Tibialis Anterior*,) after getting through the interosseous foramen, passes down the leg in front of the interosseous ligament and in contact with it; it passes also over the middle of the ankle joint to the dorsum of the foot, and is continued in a straight line to the interval between the metatarsal bone of the great toe, and of the one next to it. This artery is situated under a line drawn from the middle anterior part of the head of the fibula, to the middle of the ankle joint in front, and is continued in the course of a line drawn from this



latter point to the junction of the two first metatarsal bones. Above, it is placed between the tibialis anticus and the extensor longus digitorum; below, on the leg between the extensor pollicis and the tibialis anticus; and while engaged with the tendons of the muscles under the annular ligament of the joint, it gets to the fibular side of the tendon of the extensor pollicis.

The anterior tibial artery gives off several branches.

1. The **RECURRENT TIBIAL**, (*Tibialis Recurrens*) penetrates the head of the tibialis anticus muscle, and is distributed about the exterior and anterior part of the head of the tibia, and the patella.

2. Several small arterial twigs are then sent to the muscles and periosteum on the fore part of the leg, but they have no name.

3. The **INTERNAL MALLEOLAR**, (*Malleolaris Interna*) arises from the anterior tibial near the joint, it passes under the tendon of the tibialis anticus, and is distributed to the internal ankle, and the contiguous part of the foot.

4. The **EXTERNAL MALLEOLAR**, (*Malleolaris Externa*) exists most commonly as two small branches, one arising on a level with the joint, and the other an inch or two above. They pass beneath the tendons of the



extensor longus and the peroneus tertius, to the lower part of the fibula, and inosculate with the peroneal artery.

5. The **TARSAL ARTERY**, (*Arteria Tarsea*) arises from the anterior tibial just below the ankle joint; it runs outwardly under the tendons and the belly of the extensor brevis, to be distributed to the upper outer part of the tarsus.

6. The **METATARSAL ARTERY**, (*Arteria Metatarsæ*) arises just below the last, and is distributed by many branches on the upper part of the metatarsus. A successful injection demonstrates a branch of it in each of the three outer interosseous intervals of the metatarsal bones above.

7. The **DORSAL ARTERY** of the Great Toe, (*Dorsalis Hallucis*) arises from the anterior tibial at the root of the first metatarsal bone, it runs in the superior part of the first metatarsal interval, and terminates in two branches which go to the opposed faces of the great toe, and the second toe.

After this the anterior tibial artery sinks down and joins the external plantar in the sole of the foot.

The **POSTERIOR TIBIAL ARTERY**, (*Arteria Tibialis Postica*) extends from the head of the tibia to the hollow of the os calcis; it is on the tibial side of the



leg, and is placed between the soleus posteriorly, and the flexor digitorum anteriorly, and beneath the fascia of the part. It is distributed in the following manner:

1. The PERONEAL ARTERY, (*Arteria Peronea*) arises a little below the commencement of the posterior tibial and is extended from the inferior edge of the popliteus muscle to the external ankle. It is placed at the tibial edge of the fibula, between the flexor longus pollicis muscle and the external edge of the tibialis posticus. Its situation is therefore deep and of difficult access in the living body. After descending along two-thirds of the fibula, it divides into an anterior and posterior branch. The first traverses the interosseous ligament, and descending in front of it, is ramified on the upper external part of the foot. The second descends posteriorly along the fibula, and is distributed about the peroneo-tibial articulation and the adjacent parts.

2. Several small irregular muscular and cutaneous branches afterwards arise from the posterior tibial and at its upper part most commonly, the *Arteria Nutritia Tibiæ*.

At the ankle the posterior tibial is at the internal edge of the tendo Achillis, and still confined by the fascia of the part. It passes to the sole of the foot in



the hollow of the os calcis, between the bone and the abductor muscle of the great toe. At the ankle it is on a line with the internal margin of the joint behind, and in contact with the posterior malleolus, between the tendon of the flexor longus pollicis, and that of the flexor longus digitorum. Having got to the sole of the foot it terminates by dividing into two branches, the Internal and External Plantar Arteries.

The INTERNAL PLANTAR, (*Arteria Plantaris Interna*,) is the smaller of the two; it is covered by the abductor pollicis, and passing between it and the internal inferior margin of the foot, it terminates at the anterior end of the first metatarsal bone in the internal digital artery of the great toe. In this course it sends several branches to the contiguous parts which give them a high degree of vascularity. One of the most remarkable is given off about the os scaphoides and cruizes along the internal margin of the abductor pollicis to its anterior end. Another makes its appearance superficially in the sole of the foot, in the fissure between the abductor pollicis and the flexor brevis digitorum, and goes as far forward as the other.

The EXTERNAL PLANTAR, (*Arteria Plantaris Externa*,) inclines towards the outer margin of the foot, between the flexor brevis digitorum and the flexor accessorius; it then advances at the internal edge of the abductor minimi digiti to the root of the metatarsal bone of the



fourth toe, and makes a curvature forwards and inwards between the tendons of the flexor longus and the metatarsal bones, to the first metatarsal interval, where it is joined by the anterior tibial artery from above. This sweep forms the plantar arch (*arcus plantaris*.) The distribution of the external plantar is as follows:

*a.* Half an inch from its origin it detaches backwards and outwards to the inferior and to the external parts of the heel a multifidous branch, which also sends an arteriole along the external edge of the abductor minimi digiti.

*b.* At the root of the fourth metatarsal bone a branch arises, called the External Digital Artery of the Little Toe, which goes first along the internal margin of the muscles of this organ, and afterwards at the head of its metatarsal bone, gets between them and the bone, and is distributed along the external margin of the little toe.

*c.* The Digital Arteries come next, which arise successively at the fourth, third, second, and first metatarsal intervals, or near them, from the convex side of the plantar arch. They get forward between the transversalis pedis and the interosseous muscles, and, arriving at the roots of the toes, each artery bifurcates and goes to the opposed sides of the adjacent toes, like the corresponding arteries of the hand.

The digital artery that supplies the great toe and the opposite side of the toe next to it, is derived from the united trunks of the anterior tibial and the exter-



nal plantar. At the head of the metatarsal bone it detaches a branch which runs along the inner edge of the great toe, and is united, by anastomoses, with the internal plantar artery.

*Of the Veins of the Lower Extremities.*

These veins are superficial and deep-seated. The more important of the first are the Saphena Magna and the Saphena Minor.

1. The SAPHENA MAGNA arises from the inside of the foot, about the great toe, and from its sole; it passes in front of the internal ankle, along the inside of the leg, over the internal condyle of the os femoris, along the inner front part of the thigh, and terminates in the femoral vein just below Poupart's ligament. As it ascends it collects branches from the anterior and posterior parts of the lower extremity. It may be seen very readily in the living subject beneath the skin.

2. The SAPHENA MINOR is also readily seen through the skin. It arises from the external superior parts of the foot, passes behind the external ankle and ascends on the outside of the leg to the ham, receiving contributions in its course; here it crosses the external head of the gastrocnemius muscle, and, dipping into the ham, empties into the popliteal vein.



Frequent anastomoses occur between the saphena magna and minor.

The origin and course of the deep veins of the lower extremity are so similar to the distribution and course of the arteries, that a description is needless. A venous tube always attends an arterial one, being in contact with it, enclosed in the same sheath, and called by the same name. The smaller arterial branches in the leg and thigh have each two veins called Venæ Comites.

The relative situation of the large venous trunks is important. At Poupart's ligament the femoral vein is at the inside of the artery; at the passing of the adductor tendon, the vein is nearest the thigh bone; and in the ham, the popliteal vein is behind the artery and consequently more superficial.



#### SECTION IV.

##### *Of the Nerves of the Lower Extremities.*

THE Nerves of the Lower Extremity are derived from that part of the medulla spinalis which is situated in the lower dorsal and the upper lumbar vertebræ. The



lumbar nerves form a plexus behind the *psoas magnus* muscle, from which proceeds a cluster of nerves to supply the front part of the lower extremity, including both its skin and muscles. The sacral nerves form a plexus in the pelvis at the side of the rectum, from which proceeds the largest nerve in the body, the Sciatic, appropriated to the supply of the skin and muscles on the back part of the lower extremity. The lower part of the lumbar plexus is continued into the upper of the sciatic or sacral, so that, under a more general classification than what is adopted, both of these plexuses may be considered as forming but one.

The **PLEXUS LUMBALIS** is seen by dissecting the *psoas magnus* muscle from its origin and turning it aside; the primitive nerves, constituting this plexus, sometimes pass through the substance of the muscle instead of going behind it. The plexus is formed by the four upper lumbar nerves with a filament from the last dorsal. The anterior branches only of these nerves are concerned in forming it; as the posterior branches all go to the muscles of the back.

In the distribution of this plexus to the lower extremity, it will be seen, shortly after the commencement of the dissection, that its branches may be considered under two divisions; first, such as go to the skin, and secondly, such as go to the muscles.

From the upper part of the plexus, fibrillæ pass out-



wards and downwards over the quadratus muscle; some of their ramuscles are spent on the sides of the abdominal muscles; others wind over the crista of the ilium about its middle part and are distributed to the integuments of the hip.

The SPERMATICUS EXTERNUS arises also from the upper part of this plexus; it crosses the iliacus internus muscle, shaping its course towards the anterior superior spinous process of the ilium. Here it involves itself in the edge of the abdominal muscles, and, going on the posterior face of Poupart's ligament, at the internal abdominal ring it joins the spermatic chord of the male, or the round ligament of the uterus of the female. In the first case it is distributed to the spermatic chord and scrotum; in the second to the labium externum and mons veneris.

The CUTANEUS EXTERNUS arises from the lumbar plexus below the external spermatic. It passes across the iliacus internus towards the anterior superior spinous process about an inch below the spermaticus externus, and crosses the latter nerve just at that process. Emerging from the abdomen, by penetrating the commencement of Poupart's ligament, it is distributed, in several branches, to the integuments of the vastus externus muscle and along the edge of the rectus femoris; one of the latter extends to the patella.



The CUTANEUS MEDIUS is given from the anterior crural, an inch or so above Poupart's ligament, coming from it, among the cluster of branches which arise there to be distributed to the iliacus internus muscle and to the muscles of the thigh. It appears superficially on the thigh, for the first time, by penetrating the sartorius muscle, about the internal edge of the rectus femoris; it descends then along the same edge of the latter muscle, and is distributed to its integuments. It does not descend so low as the other nerve.

The CUTANEUS ANTERIOR arises also from the crural nerve; it is on the inner side of the cutaneus medius, emerges from the fascia of the thigh, and crosses the sartorius muscle two or three inches below the cutaneus medius. It is distributed on the integuments of the vastus internus muscle, and some of its branches extend to the internal edge of the patella.

The CUTANEUS INTERNUS arises from the anterior crural nerve among the same cluster above Poupart's ligament. It divides into four or five branches of different lengths, and is distributed to the integuments of the adductor muscles and along the inner front side of the thigh. One branch observes, very much, the course of the tendon of the adductor magnus, and reaches as far down as the inner side of the knee.

The CRURALIS ANTERIOR arises from the middle of



the lumbar plexus; at first it is beneath the psoas magnus muscle; it then gets to its outside and passes from the abdomen, under Poupart's ligament, about half an inch from the exterior margin of the femoral artery. Before it reaches Poupart's ligament it gives off a cluster of nerves, several of which go to the iliacus internus muscle, others form the superficial or cutaneous nerves of the thigh, and others the deep-seated or muscular branches. The distribution of the cutaneous nerves has just been mentioned; the muscular ones supply the adductor muscles, the four extensors, the pectineus, the sartorius, and the gracilis.

One of the branches of the anterior crural nerve is seen to accompany the femoral artery, till the artery penetrates the adductor magnus; it then runs along the front margin of the tendon of the adductor magnus, in a channel formed by this tendon and the origin of the vastus internus. The nerve alluded to is the Saphenus; it passes afterwards between the internal condyle of the os femoris and the sartorius muscle, attaches itself to the saphena vein, and is distributed to the integuments of the inner side of the leg and of the upper internal parts of the foot.

The NERVUS OBTURATORIUS is derived from the middle of the lumbar plexus, also, and has very much the same position in regard to the psoas magnus as the anterior crural nerve. It descends from beneath the psoas magnus into the pelvis, near the sacro-iliac



joint, and passes forwards and downwards to the obturator foramen, having got through which, it divides into an anterior and a posterior branch. The first is distributed to the heads of the adductor longus and brevis, and to the gracilis and integuments. The second terminates in the obturator externus, and the adductor magnus.

The SCIATIC PLEXUS, (Plexus Ischiadicus) is formed by the union of the last lumbar with the four upper sacral nerves; the last lumbar before it joins the plexus receives the branch of the fourth lumbar nerve, which is left after the lumbar plexus is formed. This plexus is situated at the side of the rectum before the pyramiformis muscle.

The sacral nerves amount to six in number, sometimes only to five. They arise from the lower part of the cauda equina, and pass in a very oblique direction in order to arrive at the sacral foramina. Like the other nerves of the spine they form ganglions by the union of their anterior and posterior fasciculi, and then pass outwards from the spinal canal, each one by an anterior branch which goes through the foramen in front of the sacrum, and a posterior branch much smaller, which gets through the foramen on the back of the sacrum. The volume of the posterior branches increases till the fourth, but the fifth and the sixth are much smaller, in fact only fibrillæ. These posterior branches all communicate with each other, being dis-



tributed to the head of the sacro-lumbalis and longissimus dorsi, to the posterior edge of the glutæus magnus, to the integuments of the buttock, margin of the anus, and to the internal parts of the thigh.

The anterior branches of the sacral nerves are much larger than the posterior. The four first communicate with the sacral ganglions of the great sympathetic, besides forming the ischiatic plexus. The third and the fourth, assisted by the sympathetic, form the hypogastric plexus. The fifth, and the sixth, when it exists, are distributed to the coccygeus, sphincter and levator ani.\*

The following small branches are sent from the Sciatic plexus:†

*a.* Nervi Glutæi, one passing through the upper part of the sciatic notch along with the artery to the glutæus medius and minimus, the other below the pyriformis muscle to the glutæus magnus.

*b.* Nervus Pudendalis Longus Inferior, which passes under the tuber of the ischium to the glutæus magnus, perineal muscles, urethra and integuments of the penis,

\* This is only given as the most frequent arrangement of the sciatic plexus, and of the branches of nerves which proceed from it; other arrangements will often be met with in the cavity of the pelvis in which not so many sacral nerves are sent to the plexus, and the several branches proceeding from it, depart in a different manner.

† They sometimes come from a common trunk called the small sciatic.



and scrotum in men, and to the inferior parts of the labia externa in women.

c. *Ramus Femoralis Cutaneus Posterior.* This nerve is placed between the integuments of the thigh, and the muscles which arise from the tuberosity of the ischium. It sends many branches successively to the skin on the back of the thigh; one of its branches longer than the others goes down to the ham, and there divides into several filaments which are distributed to the integuments on the back of the leg.

The *NERVUS PUDENDALIS SUPERIOR* comes from the third and fourth sacral, occasionally receiving a contribution from the small sciatic when it exists. It goes in company with the internal pudic artery between the sacro-sciatic ligaments, and then divides into two branches; the inferior of which is distributed to the integuments and muscles of the perineum, to the urethra and scrotum; the superior passing along the ramus of the ischium and pubes with the trunk of the internal pudic artery, is distributed to the obturator internus, accelerator urinæ, urethra, and afterwards getting between the symphysis of the pubes and the penis, terminates on its integuments and the glans penis.

The *NERVUS ISCHIADICUS*, or the great Sciatic, is the common trunk formed from the sciatic plexus; it is much the largest nerve in the body, and passes from



the pelvis between the pyriformis and the geminus superior. It crosses vertically behind the small rotator muscles of the thigh; being concealed by the inferior edge of the glutæus magnus; it is there about half-way between the tuberosity of the ischium and the trochanter major. Thence it descends on the back of the adductor magnus at the outer edge of the long head of the biceps flexor cruris. About half-way down the thigh, sometimes a little lower, the Sciatic nerve divides into the Popliteal or Posterior Tibial, and Peroneal nerves. Occasionally this division takes place as high as the exit of the nerve from the pelvis, but in this case the fasciculi are parallel with each other as far as the middle of the thigh. From the trochanter minor to its usual place of division, this nerve is parallel with, and on the back of the thigh bone, but there the two branches begin to diverge. The popliteal nerve continues straight downwards to the back and middle of the knee joint, and to the insterstice between the heads of the gastrocnemius muscle, whereas the fibular nerve goes along the inner posterior edge of the biceps flexor cruris, and passes between its tendinous insertion and the external head of the gastrocnemius muscle.

In this course the following branches are sent from the sciatic: Twigs to the little rotator muscles of the thigh. The Cutaneus Internus Superior, which arises near the upper part of the thigh, and is distributed to the skin of the corresponding part. The Cutaneus



**Internus Inferior**, which arises just below the last, and descending upon the inner head of the *gastrocnemius* muscle is distributed to the integuments of the calf of the leg. A large trunk, and sometimes instead of it, distinct branches which go to the *Adductor Magnus*, *Semimembranosus*, *Biceps* and *Semitendinosus*.

The **PERONEAL NERVE**, (*Nervus Peroneus*) at the head of the fibula divides into two branches, the *Peroneus Externus* and the *Tibialis Anterior*; but before this division it sends a small branch to the external parts of the knee-joint, and two cutaneous branches called *Peroneo-Cutaneus*. The internal of the two latter descends behind the external head of the *gastrocnemius*, and at the bottom of the leg is united to a division of the posterior tibial called the *External Saphenus* or *Communicans Tibiæ*. The external branch of the *peroneo-cutaneous* is distributed to the skin along the fibula.

The **External Peroneal Nerve**, (*Peroneus Externus*) gets between the head of the *peroneus longus* and the fibula, then between the *peroneus longus* and the *extensor longus digitorum*; it descends at the outer edge of the last muscle to the inferior third of the leg, giving out, in the mean time, many muscular branches. Here it penetrates the aponeurosis and divides into subcutaneous branches, which supply the lower part of the leg and the upper surface of the foot and toes. This nerve is called, by the French, the *Musculo-Cutaneous* of the leg.



The Anterior Tibial Nerve, (*Tibialis Anterior*) gets obliquely between the fibula, the peroneus longus, and the extensor longus digitorum to the front of the interosseous ligament, where it accompanies the anterior tibial artery. It passes with the artery under the annular ligament of the ankle, and has its terminating filaments going to the muscles and integuments of the upper surface of the foot, as far as the end of the two first toes. One of its branches sinks down with the anterior tibial artery to the sole of the foot. High up in the leg it gives filaments to the knee joint, and, in its course downwards, it furnishes the muscles on the front of the leg.

The POPLITEAL NERVE, (*Nervus Popliteus*) having the direction mentioned, is placed between the skin and the popliteal vein. It gets between the heads of gastrocnemius muscle and perforates the origin of the soleus, going with the posterior tibial artery between this muscle and the flexor longus digitorum to the bottom of the leg. It gives off

a. The External Saphenus, (*Saphenus Externus* or *Communicans Tibiæ*) which arises above the knee joint, and, descending between the skin and the gastrocnemius, turns outwardly and anastomoses with the cutaneous branch alluded to of the peroneal nerve. The common trunk passes behind the external ankle, along the external margin of the foot, and terminates on the two last toes, having given off a great number of cutaneous branches.



*b.* Branches to the heads of the gastrocnemius, soleus, plantaris, and popliteus.

*c.* Branches to the flexor longus digitorum, tibialis posticus, and to the flexor longus pollicis pedis.

*d.* A branch through the interosseous ligament above to the tibialis anticus.

*e.* At the inferior part of the leg many cutaneous filaments, one of which gets to the sole of the foot.

The Posterior Tibial Nerve, having given off these branches, divides in the hollow of the os calcis into Internal and External Plantar Nerves.

The INTERNAL PLANTAR, (Plantaris Internus) proceeds along with the tendon of the flexor muscle of the great toe and the flexor longus, and gives filaments to the contiguous muscles. It then divides in such a way as to furnish the two sides of the three first toes and the internal side of the fourth.

The EXTERNAL PLANTAR, (Plantaris Externus) proceeds with the artery of the same name to the outer edge of the foot between the flexor brevis digitorum and the flexor accessorius. It is distributed to the two sides of the little toe and to the external side of the fourth toe. One branch penetrates to the interosseous muscles and to the transversalis pedis. A branch of considerable size is detached near the heel to the muscles and integuments connected with the os calcis.



## PART IV.

### LIGAMENTS.



#### CHAPTER I.

##### LIGAMENTS OF THE HEAD AND TRUNK.



##### SECTION I.

##### *Of the Ligaments of the Head and Spine.*

ARTICULATION of the Lower Jaw. The condyle of the lower jaw is invested by a capsular ligament which arises from the margin of the glenoid cavity of the temporal bone, and is inserted into the place where the condyle and neck of the lower jaw unite. There is also an accumulation of fibres internally and externally, which gives the joint the condition of lateral ligaments.



By cutting open the capsular ligament, we shall see that a moveable cartilage is interposed between the glenoid cavity and the condyle, having its upper and under surfaces accommodated to the opposite articular surfaces of these parts. There are also two distinct synovial membranes, one passing from the moveable cartilage to the glenoid cavity, and the other from the lower surface of the cartilage to the condyle. The moveable cartilage is also attached by its circumference to the internal face of the capsular ligament.

The **STYLO MAXILLARY LIGAMENT** is seen here, which runs from the styloid process, to the angle of the lower jaw, where it is inserted between the masseter and the internal pterygoid muscle. Also the small round ligament is seen, which goes from the styloid process to the appendix of the os hyoides.

### *The Ligaments of the Spine.*

There is a capsular ligament with its synovial membrane, which surrounds on either side the superior oblique process of the first vertebra, and is inserted around the root of the corresponding condyle of the os occipitis.

A circular ligament arises from the whole superior margin of the first vertebra, and is inserted into the margin of the great occipital foramen.



The Occipito-Dentate Ligament passes from the point of the processus dentatus, and is inserted into the anterior part of the margin of the occipital foramen.

The two Moderator or Oblique Ligaments, one on each side, arise from the lateral margin of the processus dentatus; and are inserted into the inner margin of the foramen magnum.

The Transverse Ligament subtends the cavity in the first vertebra for the reception of the processus dentatus. The upper edge of this ligament is fixed by an appendix to the foramen magnum, and the lower edge into the root of the processus dentatus. It keeps this process in its place.

On each side there is a loose capsular ligament with its synovial membrane, passing between the contiguous oblique processes of the first and second vertebræ.

Between the bodies of all the vertebræ except the first and second, a fibro-cartilaginous matter is placed, which is fixed to their bodies, and is a very potent means of union. This substance is more fibrous and hard externally, but near its centre it is of a pulpy consistence. A horizontal cut seems to demonstrate it as formed of concentric fibres, but there are also many others whose course is oblique, and irregular. The



central pulpy part is confined by the other, and being also in a state of compression, it makes an articulation in some degree equivalent to the ball and socket joint.

The Anterior Vertebral Ligament extends from the second vertebra to the sacrum. It consists of longitudinal white fibres, and is placed on the convex fore part of the spine. It adheres very closely to the intervertebral substance, and to the edges of the vertebræ. Where much motion is admitted, as in the neck and the loins, it is thinner than on the dorsal vertebræ.

The Posterior Vertebral Ligament is in the spinal cavity. It arises from the edge of the foramen magnum, and passes down to the sacrum and os coccygis, on the posterior surface of the bodies of all the vertebræ, adhering to them and to the intervertebral substance. It is narrower on the bodies of the vertebræ than on the intervertebral substance.

The Yellow Ligaments; there are twenty-three pairs of them. They pass between the adjoining vertebræ; one on each side, between the spinous and oblique process; and are best seen from the inside of the vertebral cavity. The first pair passes from the bony bridge of the second vertebra to that of the third, and so on successively to the sacrum. They are very elastic.



Ligamentous fibres pass also between the spinous processes, and there are others between the transverse processes.

The Ligamentum Nuchæ is a tendinous septum beginning at the spinous process of the seventh cervical vertebra, and running up to the occiput, where it is fixed into its vertical ridge. It is connected intermediately to the spinous processes of all the vertebræ above the seventh, so that it forms a partition between the muscles of the two sides of the neck.

All the Oblique Processes have their capsular and synovial membranes.



## SECTION II.

### *Ligaments of the Thorax.*

THE heads of the ribs and their tubercles are furnished with capsular and synovial membranes, uniting them with the corresponding articular surfaces of the vertebræ, and admitting of motion.

The Ligamenta Transversaria Interna arise from the inferior surface of each transverse process under its



articular face for the tubercle of the rib, and are inserted into the upper margin of the neck of the rib below; its fibres run obliquely inwards. The Ligamenta Transversaria Externa pass horizontally between the points of the transverse processes and the back of the ribs just beyond their tubercles, their fibres go outwards.

The Ligamenta Cervicum Costarum are concealed by, and pass between the back of the neck of the rib, and the front of the corresponding transverse process. To be seen the rib must be sawed through in its length.

At its anterior extremity there is a cavity in the rib into which the sternal cartilage fits and is there united. This junction is strengthened by short ligamentous fibres surrounding the part and going from the rib to the cartilage.

The cartilages of the seven true ribs run into pits in the sternum, and are there secured by the radiated ligaments which lie in front of the joints.

The Sternum is covered, both in front and behind, by a strong ligamentous expansion adhering very closely to it. From the second bone of the sternum and from the inferior margin of the seventh true rib, near it, a ligamentous fasciculus is sent to the cartilago ensiformis, and is called the Costo-xiphoid Ligament.



SECTION III.

*Of the Ligaments of the Pelvis.*

AT the posterior part of the junction of the ilium with the sacrum, several distinct ligaments are found.

The Ilio Lumbar Ligament is stretched from the transverse and inferior oblique process of the last vertebra of the loins towards the posterior superior spinous process of the ilium and is inserted into the adjoining part of the crista. It is much mixed with fat. Just below this is the Ligamentum Sacro-Spinosum, which is extended between the posterior superior spinous process and the third and fourth transverse processes of the sacrum.

The Sacro Iliac Ligament is an assemblage of very short, strong, compact fibres, which surround this articulation. It is connected to the sacrum by its transverse processes and by the rough surface just on the iliac side of it, and to the ilium by the rough edge just behind its articular surface with the sacrum. In front the articulation is covered by short, strong fibres.

The Os Coccygis is united to the sacrum by intervertebral substance and also by longitudinal ligaments on its front and back. The anterior ligament is not



very distinct; but the posterior is, as it arises from the inferior margin of the spinal canal of the sacrum, and, contributing to finish the canal or to close it up, is then distributed on the back of the os coccygis to its extremity.

The foramina, on the posterior part of the sacrum, are much diminished by ligamentous fibres which pass in every direction.

The Posterior Sacro Sciatic Ligament arises from the inferior posterior spinous process of the ilium, from the side of the sacrum which is below it, and from the side of the os coccygis. Its fibres converging it becomes thicker in the middle, and is inserted into the ridge at the inner margin of the tuberosity of the ischium, and is prolonged towards the pubes by a continued attachment along the inner margin of the ramus of the ischium.

The Anterior Sacro Sciatic ligament has its origin somewhat confounded with that of the posterior. It arises from the side of the sacrum, below its junction with the ilium, and from the side of the os coccygis. Its course is more horizontal than that of the posterior, and it is inserted into the spinous process of the ischium.

The articular surfaces of the sacrum and ilium are covered, each with its appropriate cartilage; that on



the sacrum is somewhat thicker than the one on the ilium. The contiguous surfaces of these cartilages are rough, and are separated by a yellow half-fluid tenacious substance.

The Obturator Ligament closes the obturator foramen, and arises from its margin; it is defective at the superior part where the obturator vessels go out. It is also frequently defective, or extremely thin below. The obturator muscles arise from it.

The Ossa Pubis are joined together by a ligamentocartilaginous matter which fills up the space between them. It is more fibrous externally, and is there formed of concentric lamellæ which surround the articulation. In men there is more of this fibrous matter than in women; in the latter, one frequently finds in the posterior part of the symphysis, a little flat oblong cavity occasioned by a distinct plate of cartilage on each bone. This cavity is moistened by a white or yellowish fluid.

The Sub-Pubic or Inter-pubic Ligament is a strong tendinous membrane of half an inch in breadth, occupying the very top of the arch of the pubes, and passing from one bone to the other; it is spoken of in the account of the fasciæ of the pelvis.

In front of this joint there are several other fasciculi of fibres, which get collectively the name of the Anterior Pubic Ligament.



## CHAPTER II.

### SECTION I.

#### *Of the Ligaments of the Upper Extremities.*

THE Clavicle and the Sternum are very firmly united by the breadth of their articulating surfaces, and by the thickness of their ligaments. The Radiated Ligament arises from the front of the internal end of the clavicle, and is inserted around the margin of the corresponding part of the articular surface of the sternum.

The Interclavicular Ligament lies on the posterior surface of the upper end of the sternum, and passes from one clavicle to the other.

The Capsular Ligament proceeds from around the internal end of the clavicle, and is inserted into the margin of the articular surface of the sternum. By cutting it open we find that there is a moveable cartilage interposed between the two bones, connected below with the sternum, above with the clavicle and by its margin with the internal surface of the capsular ligament, and that on each side of this cartilage there is a distinct synovial membrane.



The Costo-Clavicular, or Rhomboid Ligament, arises from the cartilage of the first rib, and is inserted into the tubercle on the under surface of the clavicle, near the sternum.

The Scapulo-Clavicular Ligaments are two in number. The first is a capsular ligament with its synovial membrane, which unites the acromial end of the clavicle to the acromion process. This ligament being thickened above and below, these parts are called the Superior and the Inferior ligaments; occasionally a moveable cartilage is found also in this joint.

The second ligament is the Conoidal; its apex arises from the tubercle at the root of the coracoid process, and its base is inserted into the tubercle near the acromial end of the clavicle. From the outer margin of the conoid, a ligamentous membrane, called the Trapezoid Ligament, is extended towards the acromial end of the clavicle. The conoidal and the trapezoid ligaments join each other behind at an angle which is near a right angle; they are both very strong and fibrous.

In front of the subclavius muscle, arising from the root of the coracoid process and going to the clavicle, and anterior end of the first rib, is the Ligamentum Bicorne.

The Triangular Ligament of the Scapula is extend-



ed over the shoulder joint. Its basis arises from the whole outer margin of the coracoid process, and its apex is fixed to the inner margin of the acromion beneath the clavicle. It is thinner in the middle than at either edge.

The Coracoid Ligament of the Scapula is stretched across its coracoid notch, and converts it into a foramen for the vessels and nerves.

### *Of the Shoulder Joint.*

The Scapulo-Humeral Articulation is formed by the the glenoid cavity of the scapula, and the head of the os humeri. A capsular ligament arises from the neck of the former, and is inserted into the neck of the latter. A fold or thickening of it, called the Accessory Ligament, passes from the coracoid process towards the great tuberosity of the os humeri.

By cutting open the joint we see the synovial membrane lining its cavity, and sending a process into the bicipital groove of the os humeri, which is afterwards reflected along the tendon of the biceps in such a way as to keep its cavity entire. This tendon is connected with the upper margin of the glenoid cavity and also with the fibrous ring called the Glenoid Ligament, which surrounds the glenoid cavity and by being attached to its edge deepens it.



*Of the Elbow Joint.*

The Elbow Joint has a capsular ligament arising from the upper margin of the articular surface of the os humeri including its sigmoid cavities, and inserted into the margin of the articular surface of the ulna, and into the coronary ligament of the radius. This capsule has additional fibres internally, and externally, called Lateral Ligaments, or Brachio-Ulnar, and Brachio-Radial. The first arises from the internal condyle, and spreads in a radiated manner to be inserted into the inner edge of the coronoid and olecranon process. The second arises from the external condyle, and is inserted into the coronary ligament of the radius.

The Coronary Ligament of the Radius arises from one side of the sigmoid cavity of the coronoid process of the ulna, and surrounding the neck of the radius it is inserted into the other side of the same cavity. Its upper margin is blended with the capsular ligament and the lower is loosely attached to the root of the neck of the radius.

On the anterior and posterior surfaces of the capsule of the elbow joint, there are small and irregular fibres termed accessory ligaments, but the capsule is particu-



larly thin under them, in order to accommodate the flexions of the joint.

By cutting open the capsule we see the extent of the synovial membrane, and the cartilaginous surfaces of the bones. At the bottom of the greater sigmoid cavity of the ulna, a small quantity of vascular adipose matter is found traversing the articular cartilage and interrupting it.

The INTEROSSEOUS LIGAMENT fills up the space between the radius and the ulna, being fixed on each side to their sharp edges. It is composed principally of oblique fibres which pass from the radius to the ulna. In it are several perforations for blood-vessels, one particularly large is just at the tubercle of the radius.

There is a small ligamentous band called the round ligament, at the upper part of the opening for the vessels, and which goes from the base of the coronoid process to the radius, just below its tubercle.

#### *Of the Joints at the Wrist.*

The articulation of the radius with the ulna below is formed into a distinct joint, by the lateral pro-



jection of the articular cartilage of the radius between the ulna and the cuneiform bone. The capsule which unites this joint is very loose and is the sacciform ligament.

The upper Wrist Joint is formed between the lower end of the radius and the three first bones of the upper row of the carpus. A capsular ligament passes from the margin of the cartilaginous surface of the radius, and from the part of the same cartilage which is continued between the ulna and the cuneiform bone, and is inserted into the margin of the articular head formed by the scaphoid, lunar, and cuneiform bones.

The External Lateral Ligament arises from the styloid process of the radius, and is inserted into the scaphoid bone, the trapezium, and anterior annular ligament. The Internal Lateral Ligament arises from the styloid process of the ulna, and is inserted into the inner side of the cuneiform bone and partly into the pisiform and the corresponding part of the anterior ligament, which confines the flexor tendons.

By cutting open this articulation we see the synovial membrane of the part, and a fold of it called the Mucous Ligament, which passes from between the scaphoides and lunare, to the radius. We also see the cartilage of the radius projecting between the cuneiform bone



and the head of the ulna, and forming with the head of the ulna, a distinct joint, as stated.

The Articulation between the first and the second row of carpal bones is formed by a capsular ligament, which goes from the first to the second row, being strengthened laterally by a multiplication of its fibres, constituting lateral ligaments internally and externally; the fibres of the capsular ligament and of the radio-carpal joint are continued into this. There are also several fasciculi of fibres which run in varied directions, some oblique and some transverse, fastening the two rows together as well as the individual bones of the same row. When this joint is opened we find but one synovial membrane for the two rows of bones where they are in contact, and this membrane sends in digital processes between the lateral surfaces of the several bones which are opposite to each other.

There are strong ligaments which go from the carpal to the bases of the metacarpal bones, but owing to the irregular surfaces of these bones but little motion is allowed, although the apparatus of articulation is complete, with its capsular ligaments and synovial membranes. The metacarpal bone of the little finger has more motion than those of the other fingers; the ring-finger is next; the middle and fore-fingers are almost stationary.



The Metacarpal Bones of the fingers are connected to each other at their bases by transverse ligamentous fasciculi; they are also connected at their heads in the same manner by the inferior palmar ligaments.

A strong capsular ligament, with its synovial membrane, is applied to the articulation between the trapezium and the thumb. This capsule is of nearly an uniform thickness, being very similar, in that respect, to the capsule of the shoulder joint, and, therefore, admits of every variety of motion.

Between the heads of the metacarpal bones and the first phalanges there is a capsule and a synovial membrane. The capsule being thickened at its sides, thus forms lateral ligaments. In front it has a cartilaginous thickening which forms a trochlea for the flexor tendon. Behind, it is imperfect, the principal strength being derived from the tendon of the extensor muscle.

The Phalanges are articulated in the same way with each other, that they are articulated with the metacarpal bones.



## CHAPTER III.

### SECTION I.

#### *Ligaments of the Inferior Extremities.*

THE Hip joint is formed by the acetabulum and the head and neck of the os femoris, which parts are enclosed in a strong capsular ligament arising on the outer circumference of the margin of the acetabulum, and inserted into the root of the neck of the os femoris. The capsular ligament varies in its thickness at different places; in front it is a fourth of an inch thick, internally it is somewhat thinner, and posteriorly where it is covered by the quadratus muscle it is thinnest. From the anterior inferior spinous process, accessory fibres arise, which give to the capsule an increased thickness above.

By cutting open the capsule, we see that its internal face, as well as the surfaces of the bones, are covered by a delicate synovial membrane which is thrown into longitudinal folds on the neck of the os femoris; and that a strong ligamentous chord passes from one side of the notch in the lower part of the acetabulum to the



other, leaving an opening below for the introduction of vessels into the cavity of the articulation.

The Ligamentum Teres arises from the pit in the head of the os femoris, and seems to be inserted into the bottom of the acetabulum, but by dissecting the synovial membrane from it, its insertion into the extremities of the notch of the acetabulum by a bifurcated termination, and into the inferior margin of the chord, subtending the notch, will be seen.

The depth of the acetabulum is increased by the Cotyloid ligament, which surrounds its margin, and is within the origin of the capsular ligament. A quantity of loose vascular, adipose matter, fills up the pit in the bottom of the acetabulum, and is covered by the synovial membrane. By some anatomists it is called the Gland of the Hip Joint.

#### *Of the Knee Joint.*

The Knee Joint is formed by the os femoris, tibia, and patella. The fascia of the lower extremity in passing from the thigh to the leg covers this joint in front as far back as the lateral ligaments and takes the place of a regular capsular ligament. It is there called Involucrum.



The External Lateral Ligament arises from the tuberosity of the external condyle, and is inserted into the head of the fibula. The Internal Lateral Ligament arises from the tuberosity of the internal condyle, and is inserted into the inner side of the head of the tibia being continued for some distance down the edge of the bone. The front of the joint is much strengthened by the tendon which passes from the point of the patella to the tubercle of the tibia. On the posterior face of the capsular ligament is found an irregular collection of fibres passing obliquely from the upper back part of the external condyle, to be inserted into the back of the head of the tibia; these constitute the Ligament of Winslow.

By opening the joint in front so as to let the patella fall upon the tibia, a good view of its internal arrangement may be obtained. The synovial membrane will be seen arising from the cartilaginous margin of the head of the tibia, and around that of the patella; but it is reflected on the front and sides of the condyles of the os femoris half an inch or more above the margin of its cartilaginous surface. On both sides of the ligament of the patella, and between it and the synovial membrane, a large mass of fat is found filling up the vacuity between the condyles and the head of the tibia. This fat projects into the cavity of the articulation, and forms on each side of the patella an oblong ridge covered by the synovial membrane. It is called, on the outside of the patella, the Ligamentum Alare Minus,



and on its inside, the *Ligamentum Alare Majus*. These ligaments terminate each in a point below the patella where they are in contact with each other; and from this place a duplicature of synovial membrane, ending on the crucial ligaments, and on the os femoris between its condyles, is extended to the posterior part of the articulation and is called the *Ligamentum Mucosum*.

At the posterior part of the joint, are fixed the Crucial ligaments, two in number, the Anterior and the Posterior. The first arises from the internal face of the external condyle, and is inserted in front of the ridge on the top of the tibia, its fibres being partially blended with those of the semilunar cartilages. The Posterior arises from the external face of the internal condyle of the os femoris, and is inserted into the head of the tibia behind the ridge on its top, some of its fibres being blended with the external semilunar cartilage. These ligaments are exterior to the synovial membrane.

The Semilunar Cartilages, two in number, are placed between the tibia and the os femoris; to see them well the last bone must be removed, leaving them on the tibia. They are thick at their exterior circumference and are brought to a thin edge internally; are fastened to the capsular and the lateral ligament by their outer margin, but the internal is loose; their upper and under



surfaces are covered by the synovial membrane. The internal is longer from before backwards than transversely and is semicircular; the external is almost circular, in each of which cases they exactly conform to the corresponding articular surface of the tibia. The posterior end of both of these cartilages is fixed to the tibia between the spine on its top, and the posterior crucial ligament; their anterior ends are inserted into the tibia before the same spine. Occasionally a transverse ligamentous band is seen to unite their anterior extremities.

The height to which the synovial membrane ascends above the patella, should be noticed by the student, as well as a large bursa just behind the tendon of the extensor muscles, which most commonly communicates with the joint.

#### *Of the Peroneo-Tibial Articulation.*

The head of the fibula, where it is united to the tibia, has all the apparatus of a moveable joint. The capsular ligament is thickened in front and behind, which occasions the names of Anterior and Posterior Ligament. But this joint is particularly strengthened by the insertion of the external lateral ligament of the knee and by the tendon of the biceps muscle.



The Interosseous Ligament fills the interstice between the two bones. It is attached to the interosseous ridges which lie on their opposing surfaces and runs the greater part of their length. It consists of oblique fibres descending from the tibia to the fibula and forming a thin strong membrane. Just below the head of the tibia it is perforated by a large foramen which transmits the tibialis posticus muscle and the anterior tibial artery and vein; lower down it has several small foramina for blood-vessels, and near the ankle joint it is perforated also by the fibular artery.

The Tibia and fibula are united at the ankle joint by triangular surfaces, concave on the part of the tibia, and convex on the part of the fibula. These surfaces are held together by intermediate ligamentous matter, as well as a ligament expanded on the front and back of the junction called the Anterior and the Posterior Ligaments. The cartilaginous crust, on the ends of the tibia and the fibula, belonging to the ankle joint, are continued for a line or two, on the opposed surfaces of the tibia and the fibula.

#### *Of the Ankle Joint.*

The Ankle Joint is formed by the tibia, fibula, and astragalus. The capsular ligament is extremely thin, and, indeed, has no very evident existence before and



behind excepting a few scattered fibres; the fatty matter which surrounds the joint, is in immediate contact with the synovial membrane, and protrudes it in some places, inwards, towards the cavity of the articulation.

There are very strong lateral ligaments on both sides. The Deltoid arises from the inferior extremity of the malleolar process of the tibia, and by radiating considerably, is inserted into the internal side of the os calcis, and astragalus. The ligament on the external side of the ankle is divided into three fasciculi. The Anterior arises from the anterior part of the end of the malleolus externus, and passes obliquely forwards to be inserted into the upper and outer part of the astragalus. The Middle Ligament, or Fasciculus, arises from the pointed extremity of the fibula, and descends perpendicularly to be inserted into the outside of the os calcis. The Posterior Ligament comes from the depression in the extremity of the malleolus externus, and passes very obliquely to be inserted into the outer back part of the astragalus.

On cutting open this joint, it will be seen that the synovial membrane is connected to the several bones at the margins of the cartilaginous articular surfaces.



*Ligaments of the foot.*

The os calcis and the astragalus are united by ligaments investing their articulating surfaces; the synovial capsule belonging to their posterior surface is insulated, but the anterior is extended into that which unites the os astragalus and the naviculare. Between the two bones there is a very strong ligament, the Interosseous, which arises from the fossa of one to be inserted into the fossa of the other; it is their best means of union.

A small ligament called the Posterior is found at the back of this joint.

The Naviculare and the Astragalus are united by a capsular ligament with its synovial membrane. This capsule is thickened by additional slips above and internally; the whole arrangement of the joint is such as to admit of much motion.

The Os Calcis and Cuboides, besides their articular cartilage and synovial membrane, form a moveable joint with a very strong ligamentous fastening called the calcaneo-cuboid ligaments. The Superior arising from the upper surface of the os calcis is inserted into the adjoining part of the cuboides. The Inferior one



is much the strongest, and consists of two laminæ, of which the superficial is the longest, some of its fibres may be traced to the basis of the outer metatarsal bone.

A very strong ligament, the Inner Calcaneo-Scaphoid, passes from the interior internal part of the os calcis by its lesser apophysis and is fixed into the inner and under surface of the scaphoides. This ligament supports the astragalus.

The External Calcaneo-Scaphoid Ligament passes from the greater apophysis of the Os Calcis below, and is fixed to the outer end of the scaphoides.

There are many other strong ligaments on the dorsal and plantar surfaces of the foot connecting the bones of the tarsus together; their course is varied and complicated.

The Ligaments of the Metatarsus and of the Phalanges correspond nearly with those of the metacarpus and the phalanges of the fingers.



## PART V.

### OF THE SKIN, HAIR, NAILS, AND SEBACEOUS ORGANS.



#### CHAPTER I.

##### OF THE SKIN.

THE Skin consists of the Cuticle, Rete Mucosum, and Cutis Vera. These parts are easily separated by maceration; also by boiling or immersion into hot water for a few minutes, and immediately afterwards throwing the section, thus heated, into cold water. Vesicatories, applied to the living body, also cause the cuticle to detach itself from the Cutis Vera.

The Cuticle is a very thin semitransparent membrane distributed over almost the whole surface of the body. In some parts, as on the palms of the hands and the soles of the feet, it is from birth much thicker than in others; and from friction and pressure in after life, it increases further in its proportionate thickness. The cuticle presents every where, but more obviously in the



hands and feet, a multitude of furrows caused by the surface of the cutis vera, and which are arranged in straight, curved, or spiral lines. It adheres to the cutis vera, and is perforated by the excretory orifices of the sebaceous organs and by the hairs, and according to some anatomists by the origin of absorbent and exhalent vessels. The perforations are best seen on the nose, ears, and external parts of generation. From the internal surface of the cuticle processes are sent in, which line the different foramina of the cutis vera. When the cuticle is raised by a blister these processes become collapsed, by which their sides are approximated, and the fluid effused beneath is prevented from escaping.

The cuticle has but little elasticity, no vascularity, and no sensibility. Its use seems to be to diminish evaporation from the surface of the body, and to shield the pulpy terminations of the nerves of the cutis vera.

The Corpus, or Rete Mucosum, is the second layer of the skin, and on it depends the great variety of colours observed in the human species. It covers every part of the cutis vera, but is not so obvious beneath the nails and at the orifices of mucous membranes. Its consistence is mucilaginous, from which its name is derived.

Mr. Gaultier states that on the soles of the feet in negroes, the rete mucosum is seen to be disposed in



the following manner: 1st. On the inequalities of the cutis vera, next to its papillæ, there is a layer, which he calls bloody pimples, (*bourgeons sanguins*) but which in the opinion of other anatomists, are only the papillæ of the cutis vera. 2d. Next to them is a layer called *Albida Profunda*, on account of its constant colour and situation. 3d. Then small points, constituting a layer, placed over the last, of a very dark brown, in negroes, which he calls *Gemmula*. And 4th, a layer adjacent to the cuticle, spread over the last, and called *Albida Superficialis*, also, from its colour and position.

In cutting through the skin, from the heel to the toes at right angles to its furrows, in negroes, this arrangement may be readily recognized. And in cases where it has been rendered indistinct from sickness it may be improved by immersing the skin for three or four days in lime water, a solution of potash or barytes, and afterwards keeping it the same length of time in a solution of corrosive sublimate.

The existence of this arrangement of the rete mucosum may be established in other parts of the body by the effects of blisters. The fluids being thus locally attracted, infiltrate the rete mucosum and separate its layers, in part; so as to form a vesicle, frequently very thick, particularly in fat persons.

The Cutis Vera gives a covering to the whole body.



It consists of fibres variously blended and running in every direction. Its blood-vessels and nerves are so numerous that the prick of the finest needle in any part will occasion pain and produce blood. Its interior surface is in close connexion with the subjacent cellular and adipose membrane, from which it may be imperfectly separated by dissection.\* The cutis vera is extremely elastic. Its thickness varies; on the back, on the soles of the feet, and on the palms of the hands it is thicker than elsewhere. On the lips and on the margin of the anus and vulva it is very thin.

The cutis vera, on its external face, is divided by numerous lines running in different directions. When the cuticle is removed, this surface is seen to be studded with small filamentous processes, the papillæ tactus, which are extremely sensitive and vascular. They are very obvious on the palms of the hands and on the soles of the feet, where they are arranged in double rows on the ridges of the cutis vera.

\* Maceration is a much more complete way of effecting this separation.



## CHAPTER II.

### OF THE HAIR.

THE Hair grows in the cellular membrane beneath the skin. It is best studied on the mustachios of the larger animals, as the horse, ox, and so on. Around the root of each hair there are two capsules, one within the other. The internal is very vascular. In the root of the hair there is a hollow canal filled with a pulpy substance.



## CHAPTER III.

### OF THE NAILS.

THE Nails are a continuation of the cuticle, but are indebted for their growth to their adhering by their roots and under surface, to the cutis vera. If they are torn off by pincers or separated by maceration, their form and origin may be readily seen.



## CHAPTER IV.

### OF THE SEBACEOUS ORGANS.

THEY consist of follicles and glands. The follicles secrete an unctuous fluid which, by inspissation, becomes of the consistence of suet. They are seated in the skin, and are more abundant in some parts, as for example, on the nose, ears, groins and external parts of generation, than in others. The follicles are placed also around the roots of the hair in the interior of the capsules.

The Sebaceous Glands are about the size of millet seeds, and are placed under the cutis vera. They are particularly numerous under the skin of the mons veneris.



# INDEX.

	PAGE		PAGE
Abdomen,	186	Appendicula of Hyoides,	152
Abdominal Aorta,	323	Appendiculæ Epiploicæ,	223
Abdominal Canal,	202	Appendicula Vermiformis,	231
Abductor Indicis Manus,	376	Aqueduct of Cotunnus,	136
Abductor Indicis Pedis,	435	Aqueduct of Fallopius,	138
Abductor Medii Digiti,	436	Aqueduct of Fontana,	120
Abductor Minimi Digiti Pedis,	434	Aqueous Humour,	123
Abductor Minimi Digiti Manus,	376	Arbor Vitæ,	63
Abductor Pollicis Pedis,	432	Arcus Superficialis,	391
Abductor Pollicis Manus,	374	Areola,	309
Abductor Tertii Digiti,	436	Arteries of Dura Mater,	53
Accelerator Urinæ muscle,	279	Arteria Anastomotica,	385
Accessory Ligament,	474	Arteria Centralis,	121
Acini of Liver,	238	Arteria ad cutem abdominis,	439
Abductor Brevis muscle,	412	Arteria Dorsalis Superior Scapulæ,	381
Abductor Digiti Minimi,	437	Arteria facialis,	31
Abductor Indicis Pedis,	436	Arteria Innominata,	321
Abductor Longus muscle,	412	Arteria Lingualis,	31
Abductor Magnus muscle,	413	Arteriæ Mammariæ Externæ,	382
Abductor Medii Digiti,	436	Arteria Maxillaris,	34
Abductor Metacarpi Minimi Digiti,	377	Arteria occipitalis,	32
Abductor Pollicis Pedis,	433	Arteria pharyngea inferior,	32
Abductor Pollicis Manus,	376	Arteria Temporalis,	33
Abductor Tertii Digiti,	437	Arteria thyroidea inferior,	36
Albida Profunda,	491	Arteria Vertebralis,	36
Albida Superficialis,	491	Articulation of Lower Jaw,	463
Alveus Communis,	136	Aryteno Epiglottideus muscle,	158
Anastomosing artery of femoral,	442	Arytenoid Cartilages,	154
Anconeus muscle,	359	Arytenoideus Obliquus muscle,	157
Annular Ligaments,	365	Arytenoideus Transversus muscle,	157
Annulus Fossæ Ovalis,	169	Attollens Auriculæ muscle,	129
Ankle Joint,	485	Axillary artery,	380
Antitragus,	127	Axillary plexus,	49
Anterior Auricular muscle,	120	Azygos Uvulæ,	148
Anterior Chamber of Eye,	123		
Anterior Ligament of Uterus,	301	Ball of Eye,	117
Anterior Ligament of Bladder,	286	Biceps Flexor Cubiti muscle,	356
Anterior Mediastinum,	164	Biceps Flexor Cruris,	418
Anterior Pubic Ligament,	471	Bladder,	280
Anterior Sacro Sciatic Ligament,	470	Bloodvessels of Brain,	75
Anterior Tibial Nerve,	461	Bloodvessels of Lower Extremities,	437
Anterior Tibial artery,	444	Bloodvessels of Head and Neck,	29
Anterior Vertebral Ligament,	466	Bloodvessels of Trunk,	320
Antitragicus muscle,	120	Blood Vessels of Upper Extremities,	380
Antithelix,	127	Brachial artery,	381
Aponeurosis or Fascia Plantaris,	430	Brachialis Externus,	359
Aponeurosis Palmaris,	373	Brachialis Internus,	358
Aponeurosis Pelvica,	285	Brachio Radial Ligament,	475



	PAGE		PAGE
Brachio Ulnar Ligament,	475	Corpus Callosum,	56
Bronchiæ,	178	Corpus Cavernosum Penis,	267
Bronchial arteries,	322	Corpus Ciliare,	119
Buccinator,	8	Corpus fimbriatum,	58
		Corpus Highmorianum,	275
Canal of Eustachius,	130	Corpus Pampiniforme,	277
Canal of Petit,	123	Corpus Spongiosum Urethræ,	268
Capsule of Glisson,	221, 239	Corpus Spongiosum Vaginæ,	299
Caput Gallinaginis,	264	Corpus Striatum,	57
Cardiac Orifice,	225	Coronary arteries,	175
Carotid Artery,	29	Coronary Ligament,	234
Carunculæ Myrtiformes,	300	Coronary Ligament of Radius,	475
Cavitas Innominata,	127	Corpusculum Aurantii,	171
Cauda equina,	74	Corrugator Supercilii,	5
Centrum Ovale,	56	Costo Clavicular Ligament,	473
Cerebrum,	55, 85	Costo-xiphoid Ligament,	468
Cerebellum,	62, 80	Cotyloid Ligament,	481
Cervicalis Anterior,	36	Couper's Glands,	271
Cervicalis Descendens muscle,	344	Cuticle,	489
Cervical ganglions,	47	Clitoris,	294
Cervical Nerves,	49	Cranium, integuments of	1
Cervicalis Posterior,	36	Cremaster muscle,	274
Chordæ Tendinæ,	170	Cribriform fascia,	212
Chorda Tympani,	138	Crico-Arytenoideus Posticus,	158
Chordæ Willisii,	52	Crico-Arytenoideus Lateralis,	157
Ciliaris,	5	Cricoid Cartilage,	153
Ciliary arteries,	124	Crico Thyroideus muscle,	156
Ciliary Ligament,	120	Crural arch,	211
Ciliary Striæ,	119	Crura of Diaphragm,	253
Circumflexa Anterior artery,	383	Crural ring,	212
Circumflexa Ilii arteria,	331	Cruralis Anterior nerve,	454
Circumflexa Posterior artery,	384	Cruræus muscle,	410
Coccygeus muscle,	282	Crucial Ligaments,	483
Cochlea,	134	Crystalline Humour,	122
Cæcum,	230	Cupola,	135
Cæliac artery,	323	Cutaneus Anterior nerve,	454
Colon,	231	Cutaneus Externus nerve,	453
Columna Nasi,	140	Cutaneus Internus nerve,	454
Columnæ Carnæ,	170	Cutaneus Medius nerve,	454
Columns of abdominal ring,	191	Cutis Vera,	491
Columns of rectum,	260	Cystic Duct,	239
Commissures of Cerebellum,	83		
Commissures of Cerebrum,	88	Dartos,	273
Complexus muscle,	345	Dorsalis Carpi artery,	387
Compressor Naris,	3	Dorsalis Manus artery,	390
Concha,	127	Dorsalis Hallucis artery,	446
Conoid Ligament,	473	Deltoid Ligament,	480
Constrictor Isthmi Faucium		Deltoid muscle,	353
muscle,	147	Depressor Anguli oris,	7
Constrictor Pharyngis inferior		Depressor Labii Inferioris,	7
muscle,	149	Depressor Labii superioris alæque	
medius,	150	nasi,	6
superior,	150	Descendens Noni,	45
Contents of Abdomen,	216	Diaphragm,	250
Coraco Brachialis muscle,	357	Digastricus,	18
Coracoid Ligament,	474	Ductus Communis Choledochus,	239
Cornea,	118	Ductus Ejaculatorius,	265
Corona Glandis,	269	Ductus ad Nasum,	141



	PAGE		PAGE
Ductus Stenonianus,	26	Female organs of generation,	292
Ductus Whartonianus,	27	Female Pelvis,	292
Ductus Wirsungii,	244	Femoral Canal,	214
Duodenum,	228	Fissure of Sylvius,	55
Dura Mater,	51	Fissura Vulvæ,	294
		Flexor Accessorius muscle,	432
Ear,	126	Flexor Brevis Digitorum Pedis,	431
Elbow Joint,	475	Flexor Brevis Minimi Digiti Pedis,	434
Eminentia Mamillares,	66	Flexor Brevis Pollicis Manus,	375
Emulgent arteries,	246, 325	Flexor Brevis Pollicis Pedis,	433
Encephalon,	50	Flexor Digitorum Profundus,	364
Epididymis,	276	Flexor Digitorum Sublimis,	363
Epigastric artery,	206, 330	Flexor Longus Pollicis,	364
Epigastric region,	186	Flexor Longus Digitorum Pedis,	426
Epiglottis Cartilage,	154	Flexor Manus vel Carpi Ulnaris,	362
Erector Penis muscle,	279	Flexor Longus Pollicis Pedis,	427
Eustachian Valve,	169	Flexor Manus vel Carpi Radialis,	361
Excretory Duct of Kidney	248	Flexor Parvus Minimi Digiti	
Extensor Brevis Digitorum Pedis,	429	Manus,	377
Extensor Carpi Radialis Brevior,	368	Foramen Cæcum of Morgagni,	145
Extensor Carpi Radialis Longior,	368	Foramen Rotundum of ear,	130
Extensor Carpi Ulnaris,	368	Foramen œsophageum,	251
Extensor Digitorum Communis,	369	quadratum,	251
Extensor Longus Digitorum Pedis,	421	Foramen ovale,	52
Extensor Major Pollicis Manus,	371	Foramen Ovale of ear,	130
Extensor Minor Pollicis Manus,	371	Foramen of Sæmmering,	121
Extensor Ossis Metacarpi Pollicis,	370	Foramina Thebesii,	169
Extensor Proprius Pollicis Pedis,	422	Foramen of Winslow,	222
External Abdominal ring,	202	Fornix,	58
External Ear,	126	Fossa Navicularis,	271
Exter. Calcaneo Scaphoid Lig.	488	Fossa Ovalis,	168
External Carotid,	30	Fourchette,	296
External Circumflex,	440		
External parts of Head and Neck,	1	Gall Bladder,	238
External Iliac artery,	330	Gall and Spurzheim, anatomy	
External Jugular,	37	of brain,	76
External Lateral Lig. of Wrist,	479	Gastric artery,	324
External Lateral Lig. of Knee,	482	Gastrocnemius muscle,	424
External Malleolar artery,	445	Gemmula,	491
External Plantar artery,	448	Gemini muscles,	416
External Plantar nerve,	462	Genio-Hyo Glossus,	20, 143
External Pudic artery,	439	Genio-Hyoideus,	20
Extremities,	351	Gimbernat's Ligament,	191
Eye,	110	Glands of Brunner,	229
		Glans Penis,	269
Falciform Ligament,	233	Glandulæ Labiales et Buccales,	145
Fallopian Tubes,	304	Glands of Meibomius,	111
Falx Major,	51	Glands of Tyson,	269
Fascia Femoris,	208	Glenoid Ligament,	474
Fascia Iliaca,	210	Glosso pharyngeal,	43, 70
Fascia of Lower Extremities,	404	Glottis,	158
Fascia Profunda Cervicalis,	184	Gluteal artery,	328
Fascia profunda colli,	14	Gluteus Magnus,	414
Fascia Superficialis,	198	Gluteus Medius,	415
Fascia Superficialis Colli,	12	Gluteus Minimus,	415
Fascia of upper extremities,	351	Gracilis.	411
Fauces,	146		
Female mammæ,	306	Hair,	493



	PAGE		PAGE
Hamulus,	135	Intertransversarii muscles,	349
Head and Neck,	1	Intestinal Canal,	227
Heart,	166	Involucrum,	481
Helix,	127	Iris,	119
Helicis Major muscle,	129	Isthmus of Fauces,	147
Helicis Minor muscle,	129	Ischiatic artery,	329
Hepatic artery,	323		
Hepatic Duct,	239	Joints at Wrist,	476
Hernia,	198		
Hey's Ligament,	210	Kidneys,	245
Hiatus aorticus,	252	Knee Joint,	481
Hippocampus,	58		
Humours of the Eye,	122	Labia Externa,	393
Hyo-Glossus,	20, 143	Labia Interna,	295
Hypoglossal nerve,	44, 71	Labyrinth,	133
Hypogastric artery,	327	Lachrymal Gland,	112
Hypogastric region,	187	Lachrymal sac and ducts,	112
Hymen,	297	Lamina Spiralis,	135
		Large Intestine,	230
Jejunum,	229	Laryngeal Nerves,	46
Ileo-Colic Valve,	232	Larynx,	152
Ileo-Colic artery,	324	Lateral Half arches of fauces,	146
Ileum,	229	Lateral Ligaments of uterus,	302
Iliacus Internus muscle,	256	Lateral Nasal Nerve,	41
Ilio Lumbar artery,	327	Lateral Sacral arteries,	327
Ilio Lumbar Ligament,	469	Lateral Ventricles,	57
Incus,	131	Latissimus Dorsi,	338
Indicator muscle,	372	Laxator Tympani muscle,	132
Infundibulum,	66, 135	Left Gastro Epiploic artery,	324
Inferior Maxillary nerve,	41	Left auricle,	172
Inferior Mesenteric artery,	325	Left Lumbar region,	186
Infra Spinatus muscle,	354	Left Ventricle,	173
Interclavicular Ligament,	472	Left Lateral Ligament,	234
Intercostals,	161	Lenticular Ganglion,	125
Intercostal arteries,	322	Left Hypochondriac region,	186
Intercosto-Humeral nerves,	403	Left Iliac region,	11, 187
Internal abdominal ring,	202	Levator Ani muscle,	288
Internal Calcaneo Scaphoid Lig.	488	Levator anguli oris,	6
Internal Carotid,	35	Levator Labii Inferioris,	8
Internal Circumflex artery,	441	Levator Labii Superioris alæque	
Internal Iliac vein,	333	Nasi,	5
Internal Jugular,	37	Levator Palati,	148
Internal Lateral Lig. of Wrist,	477	Levator Scapulæ muscle,	340
Internal Lateral Lig. of Knee,	482	Levatores Costarum muscles,	340
Internal Malleolar artery,	445	Ligamentum Alare Majus,	483
Internal Mammary vein,	332	Ligamentum Alare Minus,	482
Internal Mammary artery,	321	Ligamentum Arcuatum,	254
Internal Plantar nerve,	462	Ligamentum Bicorné,	473
Internal Plantar artery,	448	Ligamenta Cervicum Costarum,	468
Internal Pudic artery,	329	Ligaments of Foot,	487
Interossea Artery,	389	Ligaments of Head and Spine,	463
Inter Pubic Ligament,	471	Ligaments of Head and Trunk,	463
Interosseous Ligament of arm,	476	Ligamentum Nuchæ,	337, 467
Interosseous Ligament of Leg,	485	Ligaments of Inferior Extremities,	480
Interossea anterior artery,	389	Ligamentum Patellæ,	411
Interossea posterior artery,	390	Ligaments of Pelvis,	469
Interosseus Digiti Auricularis,	379	Ligament of Poupart,	189, 190
Interspinales muscles,	341	Ligamentum Pulmonis,	177



	PAGE		PAGE
Ligaments of Spine,	464	Muscles of Eye,	113
Ligamentum Suspensorium Penis,	266	Muscles of Face,	2
Ligamentum Teres,	481	Muscles of Foot,	429
Ligaments of Thorax,	467	Muscles on Back of Fore Arm,	367
Ligamenta Transversaria Inter,	467	Muscles in front of Fore Arm,	360
Ligaments of Upper Extremities,	472	Muscles of Leg,	420
Ligament of Winslow,	482	Muscles of Lower Extremities,	407
Linea Alba,	190	Muscles of the Neck,	11
Linea Semilunaris,	190	Muscles of Thorax,	159
Lineæ Transversæ,	190	Muscles of Upper Extremities,	352
Lingualis,	20,143	Musculi Accessorii,	343
Lingual Nerve,	42	Musculi Pectinati,	168
Liquor Morgagni,	122	Multifidus Spinæ muscle,	346
Liver,	233	Mylo Hyoideus,	19
Lobus,	127		
Lobulus Anonymus.	235	Nasal Nerve,	142
Lobulus Caudatus,	235	Nails,	493
Lobulus Spigellii,	235	Nervus Axillaris or Circumflexus,	397
Longissimus Dorsi muscle,	34	Nerves of basis of Brain,	66
Longus Colli,	21	Nervus Cutaneus Internus,	397
Lower Extremities,	404	Nerves, according to Gall,	101
Lower Hemorrhoidal artery,	329	Nervus Musculo Cutaneus,	398
Lumbar arteries,	326	Nerves of Head and Neck,	38
Lumbricales muscles,	374	Nervus Ischiadicus,	458
Lumbricales Pedis muscles,	432	Nerves of Lower Extremities,	451
Lungs,	176	Nervus Medianus,	400
Lymphatic Glands of Neck,	28	Nervus Motor Oculi,	67
		Nervus Obturatorius,	455
Magna Pollicis artery,	387	Nerve Olfactory,	66
Malleus,	131	Nerve Optic,	67
Male Pelvis,	258	Nerves of Orbit,	124
Masseter,	9	Nervus Pudendalis Superior,	458
Meatus Auditorius Externus,	126,27	Nervus Radialis or Musculo	
Medulla Oblongata,	64	Spiralis,	399
Mediastinum,	164	Nervus Scapularis,	396
Median Basilic vein,	394	Nervi Subscapulares,	397
Median Cephalic vein,	394	Nervi Thoracici,	396
Membrane of Jacobs or Tunica		Nervus Trigemini,	68
Jacobi,	121	Nervus Trochlearis,	68
Membrana Pupillaris,	120	Nervus Ulnaris,	401
Membranous Portion of Urethra,	270	Nerves of Upper Extremities,	395
Membrana Tympani,	129	Nerves and Vessels of Trunk,	311
Mesentery,	224	Nipple,	309
Mesocolon,	224	Nose,	139
Metatarsal artery,	446	Nutritia arteria,	385
Middle Hemorrhoidal,	328	Nymphæ,	295
Middle Thyro-hyoid Ligament,	155		
Middle Sacral artery,	326	Obliquus Capitis Superior muscle,	348
Mitral Valve,	174	Obliquus Capitis Inferior muscle,	348
Moderator Ligaments,	465	Obliquus Externus muscle,	189
Modiolus,	135	Obliquus Internus muscle,	192
Mons Veneris,	293	Obturator artery,	328
Motores Externi,	69	Obturator Externus muscle,	417
Motor Externus,	125	Obturator Internus muscle,	416
Mouth,	143	Obturator Ligament,	471
Mucous Ligament of Wrist,	477	Occipito Dentate Ligament,	465
Muscles of Abdomen,	187	Occipito Frontalis,	2
Muscles of Back,	336	Œsophagus,	151



	PAGE		PAGE
Œsophageal arteries,	322	Phrenic Nerve,	48,311
Olfactory nerves,	141	Pia Mater,	54
Omenta,	221	Pigmentum Nigrum,	119
Omentum Colicum,	223	Pineal Gland,	60
Omentum majus,	221	Pinna,	127
Omentum minus,	221	Pituitary Gland,	66
Omentum Gastro Splenicum,	223	Plantaris muscle,	425
Omo Hyoideus,	17	Platysma Myodes,	12
Ophthalmic artery,	124	Pleura,	163
Opponeus Pollicis,	375	Pleura Costalis,	164
Optic nerve,	125	Pleura Pulmonalis,	164
Orbicularis Oris,	8	Plexus Choroides,	59
Orbicularis Palpebrarum,	4	Plexus Lumbalis,	452
Orifice of Parotid Gland,	146	Pneumogastric,	70
Os Hyoides,	152	Pomum Adami,	153
Os Orbiculare,	131	Pons Varolii,	64
Os Tincæ,	302	Posterior Annularis,	380
Ostium Venosum,	169	Posterior Auris,	32
Ovaries,	305	Posterior Carpal Ligament,	372
Ovula Nabothi,	303	Posterior Chamber of Eye,	123
		Portio Dura,	39
Palatine Nerve,	44	Posterior Indicis,	378
Palmaris Brevis muscle,	373	Posterior Ligaments of Uterus,	301
Palmaris Longus,	362	Posterior Mediastinum,	164
Palmaris Profunda artery,	388	Posterior Medii,	379
Palato Pharyngeus muscle,	147	Posterior Tibial artery,	446
Palpebral Ligaments,	110	Posterior Sacro Sciatic Ligament,	470
Pancreas,	243	Posterior Vertebral Ligament,	466
Pancreatic arteries,	324	Popliteal artery,	442
Papillæ,	144	Popliteus muscle,	425
“ Capitatæ or Maximæ,	144	Popliteal nerve,	461
“ Mediæ,	144	Portio Dura,	69,138
“ Villosæ,	144	Portio Mollis,	69,137
“ Filiformes,	144	Preputium,	266
Papillæ of Kidney,	247	Primitive Iliacs,	327
Par Vagum,	45,312	Prior Annularis,	379
Parotid Gland,	25	Prior Indicis,	378
Parts concerned in Femoral		Prior Medii,	379
Hernia,	207	Processus Brevis of Incus,	131
Pectinalis muscle,	412	Processus Brevis of Malleus,	131
Pectineal Fascia,	209	Processus Gracilis of Malleus,	131
Pectoralis Major muscle,	159	Processus Longus of Incus,	131
Pectoralis Minor muscle,	160	Profound artery,	439
Penis,	266	Profunda Humeri artery,	384
Pericardium,	115	Profunda Minor artery,	385
Perforating arteries,	441	Promontory of Ear,	130
Perineum,	278	Pronator Quadratus muscle,	366
Perineal artery,	330	Pronator Radii Teres muscle,	361
Peritoneum,	219	Prostate Gland,	263
Peroneus Brevis,	423	Psoas Magnus muscle,	255
Peroneus Longus,	422	Psoas Parvus muscle,	255
Peroneus Tertius,	421	Pterygoideus Externus,	11
Peroneal artery,	447	Pterygoideus Internus,	11
Peroneal Nerve,	460	Pterygoid Nerve,	40
Peroneo Tibial Articulation,	484	Pulmonary Artery,	172
Pharyngeal Nerve,	46	Punctum Lachrymale,	111
Pharynx,	148	Pyloric Orifice of Stomach,	225
Phrenic arteries,	323	Pupil,	120



	PAGE		PAGE
Pyramid,	130	Schneiderian Membrane,	141
Pyramidalis,	194	Sciatic Plexus,	456
Pyriformis muscle,	416	Scrobiculus Cordis,	187
Quadratus Femoris,	417	Scrotum,	272
Quadratus Lumborum,	256	Sebaceous Glands,	494
		Sebaceous Organs,	494
Radial artery,	386	Semicircular Canals,	133
Radialis Indicis artery,	387	Semilunar Valves,	171
Radiated Ligaments,	472	Semilunar Cartilages,	483
Receptaculum Chyli,	334	Semimembranosus,	419
Rectum,	231, 258	Semispinalis Dorsi muscle,	346
Recurrents Radialis artery,	386	Semispinalis Colli muscle,	345
Recurrent Tibial artery,	445	Semitendinosus muscle,	419
Rectus Abdominis muscle,	193	Septum Lucidum,	58
Rectus Capitis anticus major,	21	Septum Pectiniforme,	268
Rectus Capitis anticus minor,	21	Serratus major anticus muscle,	161
Rectus Capitis Lateralis,	22	Serratus Superior Posticus,	340
Rectus Capitis Posticus major muscle,	347	Serratus Inferior Posticus muscle,	339
Rectus Capitis Posticus minor muscle,	347	Shoulder Joint,	474
Rectus Femoris muscle,	408	Skin,	489
Recurrents Ulnaris artery,	389	Sinuses of Dura Mater,	52
Regio Pubis,	187	Sinus Pulmonalis,	172
Renal Capsules,	249	Sinus of Ridley,	53
Renal Plexus,	319	Sinus of Valsalva,	171
Rete Mucosum,	490	Sinus Venosus,	168
Retina,	121	Small Muscles of Hand,	373
Retrahens Auriculæ muscle,	129	Small Intestines,	228
Rhomboid Ligament,	473	Solar Plexus,	318
Rhomboideus major muscle,	340	Soleus muscle,	424
Rhomboideus minor muscle,	339	Spermatic arteries,	325
Right Auricle,	168	Spermaticus externus nerve,	453
Right Gastro Epiploic artery,	324	Spheno palatine ganglion,	40
Right Hypochondriac region,	186	Spheno Palatine nerve,	142
Right Iliac region,	187	Sphincter Ani muscle,	281
Right Lateral,	234	Sphincter Vaginæ muscle,	299
Right Lumbar region,	186	Spinal Accessory Nerve,	43, 73
Right Ventricle,	169	Spinal Marrow,	71, 70
Rima Glottidis,	158	Spinalis Dorsi muscle,	343
Root of Lung,	177	Splanchnic nerves,	317
Round Ligaments of Bladder,	260	Spleen,	240
Round Ligaments of Liver,	234	Splenic artery,	324
		Splenius Capitis muscle,	341
Sacculus Sphericus,	136	Splenius Colli muscle,	341
Sacro Lumbalis muscle,	342	Splenius muscle,	341
Sacro Iliac Ligament,	469	Spurzheim,	101
Saphena Magna,	450	Stapedius,	133
Saphena Minor,	450	Stapes,	131
Saphena Vein,	209	Stomach,	225
Sartorial Fascia,	209	Sterno-cleido mastoideus,	13
Sartorius muscle,	407	Sterno-hyoideus,	16
Scala Tympani,	135	Sterno-thyroideus,	17
Scala Vestibuli,	135	Stylo-Glossus muscle,	19, 143
Scaleni muscles,	22	Stylo-hyoideus,	18
Scapha,	127	Stylo maxillary ligament,	16, 464
Scapularis,	383	Stylo-Pharyngeus,	19
Scapulo Clavicular Ligaments,	473	Subclavius muscle,	161
		Subclavian artery,	321
		Submaxillary Gland,	26



	PAGE		PAGE
Sublingual Gland,	27,145	Thoracica Longa,	382
Subscapularis muscle,	355	Thoracica Superior,	382
Sub Pubic Ligament,	471	Thorax,	159
Sulcus Transversalis,	235	Thyreo-Arytenoideus,	157
Sulcus Umbilicalis,	235	Thyreo-Epiglottideus muscle,	158
Superficialis Dorsi Penis,	330	Thyreo-hyoideus,	17,156
Superficialis Volæ artery,	387	Thyroid Cartilages,	153
Supra Spinatus muscle,	354	Thyroid Gland,	23
Superior Maxillary nerve,	40	Thyroidea Superior,	31
Superior Mediastinum,	164	Thyroidal Veins,	38
Superior Mesenteric artery,	324	Thymus Gland,	182
Superior Hemorrhoidal artery,	326	Tonsil Gland,	147
Superior Intercostal artery,	322	Transverse Ligament,	465
Superior Pubic Ligament,	197	Transversus Perinei muscle,	281
Supinator Radii Brevis,	370	Tricuspid Valve,	170
Supinator Radii Longus,	367	Trigeminus,	39
Sympathetic,	47,314	Trochlearis nerve,	125
		Trunk,	159
Tarsal artery,	446	Tuberculum Loweri,	168
Tarsi Cartilages,	110	Tubercula Quadrigemina,	60
Temporalis,	10	Tubuli Seminiferi,	275
Tendo Achillis,	424	Tubuli Uriniferi,	247
Tensor Palati muscle,	147	Tunica Albuginea,	274
Tensor Tarsi,	114	Tunica Arachnoidea,	54
Tensor Tympani muscle,	133	Tunica Choroidea,	118,19
Tensor Vaginæ Femoris,	408	Tunica Conjunctiva,	111
Tentorium,	51	Tunica Hyaloidea,	122
Testes,	272	Tunica Sclerotica,	117
Teres Major muscle,	355	Tunica Vaginalis communis,	200,274
Teres Minor muscle,	354	Tunica Vaginalis Testis,	274
Thigh, Artery of	437	Tympanum,	129
Tibialis Anticus,	420		
Tibialis Posticus,	428	Ulnar Artery,	388
Tongue,	143	Umbilical region,	186
Torcular Hierophili,	53	Upper Extremities,	351
Trachea,	178	Urachus,	260
Trachelo Mastoideus muscle,	344	Ureters,	248
Tragicus muscle,	129	Uterine Arteries,	328
Tragus,	127	Uterus and Appendages,	301
Transversalis Abdominis,	193	Uvula,	146
Transversalis Cervicis muscle,	344		
Transversus Auræ muscle,	129	Vagina,	297
Transversalis Linguae,	144	Vaginal Ligaments of fingers,	366
Transversalis Pedis muscle,	435	Valve of Brain,	61
Trapezoid Ligament,	473	Valve of Thebesius,	169
Trapezius muscle,	336	Valvulæ Conniventes,	229
Triangular Ligament,	473	Vasa Brevia,	324
Triangular Ligament of Urethra,	282	Vasa Efferentia,	276
Triangularis Sterni muscle,	162	Vasa Vorticosa,	119
Triceps Abductor Femoris,	412	Vas Deferens,	276
Triceps Extensor Cubiti,	358	Vastus Externus muscle,	409
Triceps Suræ,	423	Vastus Internus muscle,	409
Thalamus Nervi Optici,	57	Vena Cava Descendens,	331
Third pair or Motor Oculi,	125	Veins of Lower Extremities,	450
Third Ventricle,	60	Veins of Trunk,	331
Thoracic Duct,	184,334	Veins of Upper Extremities,	392
Thoracica Acromialis,	383	Vena Axillaris,	395
Thoracica Axillaris,	383	Vena Azygos,	184



	PAGE		PAGE
Vena Basilica,	393	Vestibulum,	296
Vena Cava Ascendens,	332	Villi,	230
Vena Cephalica,	393	Viscera of Thorax,	162
Vena Galeni,	53	Vitreous Humour,	122
Vena Mediana,	396	Vulva,	293
Vena Portarum,	234		
Venæ Satellites or Comites,	396	Yellow Ligaments,	466
Velum Pendulum Palati,	144		
Ventricles and Convolutions,	98	Zona Coriacea,	135
Ventricle of Galen or Morgagni,	154	Zona Membranacea,	135
Verticales Linguae,	144	Zona Ossea,	135
Vessels of Orbit,	124	Zona Vesicularis,	135
Vesiculæ Seminales,	264	Zygomaticus major,	6
Vesical arteries,	328	Zygomaticus minor,	6
Vestibule,	134		







# **NEW BOOKS**

RECENTLY PUBLISHED

BY

**JOSEPH G. AUNER,**

**NO. 331 MARKET STREET,**

**PHILADELPHIA.**

---

## **HORNER'S PRACTICAL ANATOMY.**

Lessons in Practical Anatomy, for the Use of Dissectors.  
By W. E. Horner, M. D., Professor of Anatomy in the University of Pennsylvania, Surgeon at the Philadelphia Hospital, *Blockley*, &c. 1 vol. 8vo. 3d edition, enlarged and improved.

---

## **HARE'S CHEMISTRY.**

A Compendium of the Course of Chemical Instruction in the Medical Department of the University of Pennsylvania. By Robert Hare, M. D., Professor of Chemistry in the University of Pennsylvania. 1 vol. 8vo.



**HOPKINSON ON THE ARTERIES.**

Engravings of the Arteries. By J. P. Hopkinson, M. D.  
1 vol. 8vo.

---

**CHASE ON HERNIA.**

A Treatise on the *Retention and Radical Cure of Hernia*, with advice to patients on the precautionary measures required to insure their safety, and an analysis of the instruments employed in the treatment of this disease, with a detailed account of numerous improvements, addressed to the profession and the public, with plates. By Heber Chase, M. D., Honorary Member of the Philadelphia Medical Society, &c. 1 vol. 12mo.

---

**HAINES'S CATECHISM ON CHEMISTRY.**

Catechism on Chemistry, adapted to the Course of Lectures delivered in the University of Pennsylvania. By Isaac S. Haines, M. D. 1 vol. 18mo.

---

**LOBSTEIN ON THE SYMPATHETIC NERVE.**

A Treatise on the Structure, Functions, and Diseases of the Human Sympathetic Nerve, illustrated with Plates. By John Frederick Lobstein, Professor of Clinical Medicine and Pathological Anatomy in the Medical Faculty of Strasburg, First Obstetrick Physician to the City Hospital, and Member of many learned Societies.—Translated from the Latin, with Notes, by Joseph Pancoast, M. D. 1 vol. 8vo.

---

**BARTON'S MATERIA MEDICA AND BOTANY.**

Outlines of Lectures on Materia Medica and Botany, delivered in Jefferson Medical College, Philadelphia. By William P. C. Barton, M. D. 2 vols. 12mo.



**MASON ON SELF KNOWLEDGE.**

A Treatise on Self Knowledge, showing the nature and benefit of that important science, and the way to attain it; intermixed with various reflections and observations on human nature. By John Mason, A. M. 1 vol. 18mo.

"The proper study of mankind is man."—*Pope.*"

---

**SANDFORD AND MERTON.**

The History of Sandford and Merton. By Thomas Day. 1 vol. 12mo.

---

**DYER'S SACRED MUSIC.**

Dyer's Selection of Sacred Music, consisting of about Three Hundred approved Psalms and Hymn Tunes; from the works of the most esteemed authors, ancient and modern, arranged for four voices, and adapted to all the metres in general use amongst the various religious denominations; and a concise Introduction to the Art of Singing, with Lessons and Examples, according to the English and Italian methods. By Samuel Dyer. 1 vol. 8vo.

---

**DYER'S ANTHEMS.**

A selection of upwards of Eighty favourite and approved Anthems, Set Pieces, Odes, and Choruses, from the works of the most approved authors; many of which have never before been published in this country, and several of them are original, and composed expressly for this work; with Biographical Sketches of the several Composers. By Samuel Dyer. 1 vol. super royal 8vo.



**DYER'S CHORUSES.**

Choruses, Solos, Duets, and Recitatives, from the works of Handel, Haydn, Mozart, Beethooven, and other composers of the first eminence, arranged in full vocal score, and interspersed with Notes and Explanatory Remarks. By Samuel Dyer. 1 vol. 4to.

---

**O'CONNOR'S GRAMMAR.**

A simplified and expeditious method of teaching English Grammar; chiefly intended as an Evening Exercise for Students. By J. O'Connor. 1 vol. 4to.

---

**CARLL'S ARITHMETIC.**

An Introduction to Arithmetic. By M. M. Carll. 1 vol. 18mo.

---

*In Press.*

**GODDARD ON THE NERVES.**

---

**PLATES OF THE NERVES,**

WITH REFERENCES,

FOR

**THE USE OF MEDICAL STUDENTS;**

INTENDED AS AN ACCOMPANIMENT TO HORNER'S ANATOMY.

BY P. B. GODDARD, M. D.,

PROSECTOR IN THE UNIVERSITY OF PENNSYLVANIA, &c.

ONE VOL. OCTAVO.

The above will comprise about twelve plates, illustrating the Nerves of the human body, as described in Horner's Special and Practical Anatomy.



# MEDICAL BOOKS

FOR SALE BY

**JOSEPH G. AUNER,**

BOOKSELLER AND STATIONER,

**NO. 331, MARKET STREET---BELOW NINTH ST.**

PHILADELPHIA.

---

## TEXT BOOKS.

COMPLETE SETS OF THE MEDICAL TEXT BOOKS.

---

In addition to the following Catalogue, all the new publications will be received as soon as published.

---

### MEDICAL, CHEMICAL, BOTANICAL, &c.

- |   |   |
|---|---|
| Abercrombie on the Stomach, &c.               | Broussais' Physiology.                                  |
| Abercrombie on the Brain.                     | Burns' Midwifery.                                       |
| Abernethy's Surgical Lectures.                | Burns on Head and Neck.                                 |
| Abernethy on Tumour.                          | Burns on Abortion.                                      |
| Accum on Culinary Poisons.                    | Burns on Inflammation.                                  |
| Accum's Chemistry, 2 vols.                    | Bell on Baths and Mineral Waters.                       |
| Accum's Mineralogy.                           | Boyer on the Bones.                                     |
| Accum's Chemical Tests.                       | Broussais on Inflammation, 2 vols.                      |
| Acupuncture, by Morand.                       | Bell on the Nerves.                                     |
| Aiken's Mineralogy.                           | Bell on the Urethra.                                    |
| Aiken on the Cow Pox.                         | Bell on Ulcers.   |
| Alibert on Fevers.                            | Bell on Wounds.   |
| Anderson's Anatomy.                           | Bell's Dissection, 2 vols.                              |
| Andral's Anatomy, 2 vols.                     | Bell's Anatomy, 2 vols.                                 |
| Armstrong on Typhus Fever.                    | Bell's Surgery, 2 vols.                                 |
| "    " Puerperal Fevers, Consumption, &c.     | Bell's Engravings of the Arteries.                      |
| Arnott's Elements of Physics, 2 vols.         | Bell's Engravings of the Bones.                         |
| Assalina on the Plague.                       | Bell's Engravings of the Nerves.                        |
| Averill's Surgery.                            | Bell's Engravings of the Muscles and Joints.            |
| Ayre on the Liver.                            | Bell on the Teeth.                                      |
| Blanden's Anatomy, 2 vols.                    | Brande's Chemistry, by Webster.                         |
| Boudeloque's Puerperal Peritonitis.           | Bateman's Synopsis of Cutaneous Diseases.               |
| Broussais' Pathology.                         | Bailey's Morbid Anatomy.                                |
| Boisseau on Fever.                            | Blackall on Dropsies.                                   |
| Broussais on Insanity.                        | Blane's Medical Logic.                                  |
| Bell and Condie on Cholera.                   | Barton's Lectures on Materia Medica and Botany, 2 vols. |
| Bichat on Pathology.                          | Bayle and Hollard's Gen. Anatomy.                       |
| Bichat on Life and Death.                     | Beck's Medical Jurisprudence, 2 vols.                   |
| Bell on Syphilis.                             | Bigelow's Materia Medica.                               |
| Bichat on the Membranes.                      | Bancroft on Fever.                                      |
| Beache's American Practice, 3 vols.           | Beddoe's Observations.                                  |
| Bache's Chemistry.                            | Bostock's Physiology, 3 vols.                           |
| Bichat's Anatomy and Physiology by Henderson. |   |



## J. G. AUNER'S CATALOGUE.

- Buchan's Domestic Medicine.  
 Bluemanback's Physiology.  
 Boyer's Surgery, 2 vols.  
 Brande's Chemistry, by M'Nevin.  
 Begin's Therapeutics.  
 Bertin on the Heart.  
 Brown's Elements of Medicine.  
 Brera on Verminous Diseases.  
 Belliol on Herpetic Affections.  
 Beddingfield's Practice.  
 Beclard's Anatomy.  
 Brea on Asthma.  
 Blake's Botany.  
 Bryant's Examinations in Anatomy and Physiology.  
 Blake on Delirium Tremens.  
 Brodie on the Joints.  
 Bell on the Nervous System.  
 Blundell's Midwifery.  
 Bougeray's Minor Surgery.  
 Carpenter's Materia Medica, new ed.  
 Calhoun on Suspended Animation.  
 Caldwell's Cullen, 2 vols.  
 Cabanis on Certainty of Medicine.  
 Caldwell's Medical Theses.  
 Calvert's Phrenology.  
 Carlisle on Old Age.  
 Cazenave on Diseases of the Skin.  
 Casey's Flora.  
 Cavallo on Electricity.  
 Chapman's Materia Medica and Therapeutics, 2 vols.  
 Chapman's Medical Journal, 14 vols.  
 Cholera, Bell and Condie on  
 Cholera, Kirk on  
 Cholera, Greenhow on  
 Cholera, Winslow on  
 Cholera, Souttetten on  
 Cholera, Torry on  
 Chisholm on Malignant Fever.  
 Cheyne on Dropsy.  
 Coxe's Medical Dictionary.  
 Coxe's American Dispensatory.  
 Coster's Manual of Surgical Operations.  
 Cook on Nervous Diseases.  
 Coxe's Orfila's Chemistry.  
 Colhoun's Prout on the Urinary Organs.  
 Comstock's Botany.  
 Combe's Phrenology.  
 Combe on Insanity.  
 Comstock's Mineralogy.  
 Castle's Manual of Surgery.  
 Cook's Morgagni, 2 vols.  
 Cooper's Lectures on Surgery, by Tyrrell.  
 Clarke's Practice.  
 Carmichael on Venereal.  
 Curry on Cold Water.  
 Cooper and Traverse's Surgical Essays.  
 Copeland on the Rectum.  
 Curry's Synopsis.  
 Cooper on Dislocation.  
 Comstock's Mineralogy.  
 Conversations on Chemistry.  
 Cooper on Dyeing.  
 Comstock's Grammar of Chemistry.  
 Cooper's (Samuel) First Lines of Surgery, 2 vols.  
 Cooper on the Joints.  
 Corvisart on the Heart.  
 Colle's Surgical Anatomy.  
 Cutbush's Observations.  
 Cullen's Practice, 2 vols.  
 Curry on Yellow Fever.  
 Cutbush's Chemistry.  
 Cheyne on Croup.  
 Crawford on Heat.  
 Coxe on Insanity.  
 Cook on White Mustard Seed.  
 Cotting's Chemistry.  
 Conversations on Natural Philosophy.  
 Cullen's Materia Medica.  
 Cloquet's Anatomy.  
 Cooper's Surgical Dictionary.  
 Coster's Physiological Practice.  
 Coxe's Refutation of Hervey's Claim.  
 Clarke on Consumption.  
 Christison on Poisons.  
 Chase on Hernia.  
 Chitty's Medical Jurisprudence.  
 Dupuytren's Surgery.  
 Dunglison's Medical Dictionary, 2 vols.  
 Dunglison's Physiology, 2 vols.  
 Darwin's Zoonomia, 2 vols.  
 Dana's Mineralogy.  
 Darwin's Life.  
 Darwin's Botanic Garden.  
 Denman's Aphorisms.  
 Dewees' System of Midwifery.  
 Dewees on Treatment of Children.  
 Dewees on Diseases of Females.  
 Dewees' Essays on various subjects connected with Midwifery.  
 Dewees' Baudeloque.  
 Dewees' Practice.  
 Desault's Surgery, 2 vols.  
 Denman's Midwifery, by Francis.  
 Duncan on Consumption.  
 Dickinson and Irving on Fever.  
 Douglas on Heat.  
 Douglas on the Muscles.  
 Ducamp on Urine.  
 Druggists' Manual.  
 Desruelles on Venereal.  
 Desault on Fractures.  
 Dunglison on Hygiene.  
 Dunglison's Therapeutics.  
 Dublin Dissector.  
 Ellis's Medical Formulary.  
 Eberle's Materia Medica and Therapeutics, 2 vols.  
 Esculapian Register.  
 Eaton's Botanical Exercises.  
 Eberle's Practice, 2 vols.



## J. G. AUNER'S CATALOGUE.

- |                                      |                                    |
|--------------------------------------|------------------------------------|
| Eberle's Notes.                      | Hildenbrand on Typhus Fever.       |
| Ewell's Letters to the Ladies.       | Hale on Spotted Fever.             |
| Ewell's Medical Companion.           | Hufeland on Scrofulous Diseases.   |
| Edinburgh Dispensatory.              | Hatin's Manual of Obstetrics.      |
| Eclectic and General Dispensatory.   | Hutin's Manual of Physiology.      |
| English Maladies.                    | Home on Ulcers.                    |
| Edward's Manual of Surgical Anatomy. | Haller on the Arteries.            |
| Ewell's Family Physician.            | Hey on Fever.                      |
| Edward's Manual of Materia Medica,   | Hennen's Military Surgery.         |
| trans. by Togno and Durand.          | Horner's Pathological Anatomy.     |
| Eaton's Manual of Botany.            | Hopkinson on the Arteries.         |
| Eberle on Children.                  | Hooper's Medical Examinations.     |
| Fordyce on Fever.                    | Haller's Physiology.               |
| Ferrier's Medical Reflections.       | Horner's Practical Anatomy for the |
| Faithorn on Liver Complaints.        | use of Dissectors.                 |
| Francis Denman's Midwifery.          | Hall on Circulation of the Blood.  |
| Fitch's Dental Surgery.              | Innes on the Muscles.              |
| Frick on the Eye.                    | James' Burnes' Midwifery.          |
| Fife's Anatomy, 2 vols.              | James' Merriman.                   |
| Formulæ Selectæ.                     | Johnson on Civic Life.             |
| Farrady's Chemical Manipulations.    | Johnson on Tropical Climates.      |
| Gibson's Surgery, 2 vols.            | Johnson on the Liver.              |
| Godman's Anatomical Investigations.  | Johnson on the Stomach.            |
| Gregory's Dissertation on Climates.  | Jaudon on Syphilis.                |
| Gregory's Practice, 2 vols.          | Jones on Hemorrhage.               |
| Good's Study of Medicine.            | Johnson on Cancer.                 |
| Good's Book of Nature.               | Johnson on Change of Air.          |
| Gardner on the Gout.                 | Kitchener on the Eye.              |
| Guthrie on Gun Shot Wounds.          | Laennec on the Chest.              |
| Gallup on Epidemics.                 | Laennec on the Stethoscope.        |
| Gale on Electricity.                 | Larry's Surgical Essays.           |
| Green's Electro Magnetism.           | Larry's Military Surgery, 2 vols.  |
| Green's Chemistry.                   | Lobstein's Practical Physician.    |
| Gervino on Children.                 | Lobstein on Phosphorus.            |
| Guthrie on Venereal.                 | London Dissector.                  |
| Gross on the Bones and Joints.       | London Practice of Midwifery.      |
| Goupil on the New Medical Doctrine.  | London Practice of Physic.         |
| Goodwin on Respiration.              | Le Gallois on Life.                |
| Graham on Indigestion.               | Lawrence's Physiology.             |
| Gooch's Midwifery.                   | Lieutaud's Practice.               |
| Gooch on Females.                    | Law on the Digestive Organs.       |
| Greenhow on Cholera.                 | Lawrence on Ruptures.              |
| General Anatomy.                     | Lincoln's Botany.                  |
| Gerhard on the Chest.                | Lobstein on the Sympathetic Nerve. |
| Goddard on the Nerves.               | Larry on Injuries of the Head.     |
| Hosack's Nosology.                   | Lawrence on the Eye.               |
| Hare's Chemistry.                    | Mackenzie on the Eye.              |
| Haine's Catechism of Chemistry.      | Mackintosh's Practice.             |
| Hall on Diagnosis.                   | Meckel's Anatomy, 3 vols.          |
| Hall on the loss of Blood.           | Majendie's Medical Formulary.      |
| Henry's Chemistry, 2 vols.           | Majendie on Prussic Acid.          |
| Hooper's Medical Dictionary.         | Morgagni, Cook's, 2 vols.          |
| Hooper's Vade Mecum.                 | Meade's Pharmacy.                  |
| Hunter on Syphilis.                  | Murray's Materia Medica.           |
| Hunter on the Blood.                 | Matthias on Mercurial Complaints.  |
| Heberden's Medical Commentaries.     | Miner and Tully on Fevers.         |
| Hamilton on Purgatives.              | Muter on Lithotomy.                |
| Hamilton on Mercury.                 | Moncriff on Waters.                |
| Horner's Special Anatomy, 2 vols.    | Moss on Infants.                   |
| Hey's Surgery.                       | Majendie's Physiology.             |
| Hall on Digestive Organs.            | M'Murtrie's Vade Mecum.            |
| Hippocrates, Aphorisms of            | Martinet's Therapeutics.           |



177h  
cent  
QM34  
836H

# J. G. AUNER'S CATALOGUE.

- Milman on Scurvy.  
Marshall on the Brain.  
Murray on the Arteries.  
Martinet's Pathology.  
Maculloch on Remittents and Intermittents.  
Maculloch on Malaria.  
Maclean on Hydrothorax.  
Mayo on the Rectum.  
Mitchell's Chemistry.  
Maygriere's Anatomy.  
Morton on Consumption.  
Maygriere's Midwifery.  
Nuttall's Botany.  
Orfila on Poisons.  
O'Bierne on Defecations.  
Parke's Chemical Catechism.  
Phrenology, Combe's  
Phrenology, Spurzheim's  
Phrenology, Calvert's  
Potts' Surgery, 2 vols.  
Prout on the Urinary Organs, by Calhoun.  
Phillips on the Laws of the Vital Functions.  
Philips on Indigestion.  
Paris' Pharmacologia.  
Paris' Chemistry.  
Parr's Medical Dictionary, 2 vols.  
Paris on Diet.  
Pemberton on the Viscera.  
Pringle on Diseases of the Army.  
Pott on Hydrocele.  
Physician's Vade Mecum.  
Philips' Mineralogy.  
Paxton's Anatomy, 2 vols.  
Philips on Diseases.  
Parson's Anatomical Preparations.  
Philips on Mercury.  
Parrish's Surgical Observations.  
Rush's Sydenham.  
Reese on Costiveness.  
Richerand's Physiology.  
Rush's Lectures.  
Rush on the Mind.  
Rush's Hillary.  
Rush's Cleghorn.  
Robinson's Catalogue of Minerals.  
Robertson's Medical Examinations, 2 vs.  
Rush on the Voice.  
Rush's Pringle.  
Ryland on the Stethascope.  
Rigby on Hæmorrhage.  
Ricketson on Health.  
Ratier's Formulary.  
Read on Consumption.  
Ryan's Medical Jurisprudence.  
Ryan's Lectures on Marriage.  
Swediur on Syphilis.  
Scudamore on Gout and Rheumatism.  
Smith on Typhus Fever.  
Shaw's Manual of Anatomy.  
Stevenson on the Eye.  
Struve on Suspended Animation.  
Smith on Contagion.  
Smith's Grammar of Botany.  
Saunders on the Ear.  
Sharpe's Surgery.  
Scotfield on Cow Pock.  
Saunders on the Liver.  
Saissey on the Ear.  
Surgeons' Vade Mecum.  
Silliman's Chemistry, 2 vols.  
Smith on Fevers.  
Sydenham's Works, 2 vols.  
Surgeon Dentist's Manual.  
Sylva's Americana.  
Syme's Surgery.  
Snell on the Teeth.  
Smith on the Arteries.  
Thomas' Practice, by Hosack.  
Thatcher's Practice.  
Teale on Neuralgia.  
Tate on Hysteria.  
Thatcher's Dispensatory.  
Thatcher on Hydrophobia.  
Trotter on Drunkenness.  
Timbrel on Ruptures.  
Traverse on the Eye.  
Traverse on Irritation.  
Thomson on Varioloid.  
Turner's Chemistry.  
Thomas' Domestic Medicine.  
Thornton's Botany.  
Thompson's Chemistry, 4 vols.  
Trotter on Nervous Temperament.  
Thomson on Inflammation.  
Tavernier's Operative Surgery.  
Torry's Botany.  
Tweedie on Fever.  
Turnbull on Veratria.  
Ure's Chemical Dictionary, 2 vols.  
Underwood on Diseases of Children.  
United States Pharmacopœia, new ed.  
Vought on Bowel Complaints.  
Velpeau's Midwifery.  
Velpeau's Anatomy, 2 vols.  
Wistar's Anatomy, with Notes by Horner, 2 vols.  
Warner's Surgery.  
Webster's Brande's Chemistry.  
Willan on the Skin.  
Williams' Jurisprudence.  
Wakefield's Botany.  
Winslow's Anatomy.  
Wilson on Spotted Fever.  
White on Pregnant Women.  
Webster's Chemistry.  
Wilson, Philip, on Fevers, 2 vols.  
Wilson, Philip, on Diseases.  
Williams on the Lungs.  
Wood and Bache's Dispensatory.  
Williams' Catechism of Medical Jurisprudence.







