

A manual of the diseases of the eye / By S. Littell, jr.

Contributors

Littell, Squire, 1803-1886.

Harvey Cushing/John Hay Whitney Medical Library

Publication/Creation

Philadelphia : J. S. Littell, 1837.

Persistent URL

<https://wellcomecollection.org/works/zuheww8b>

License and attribution

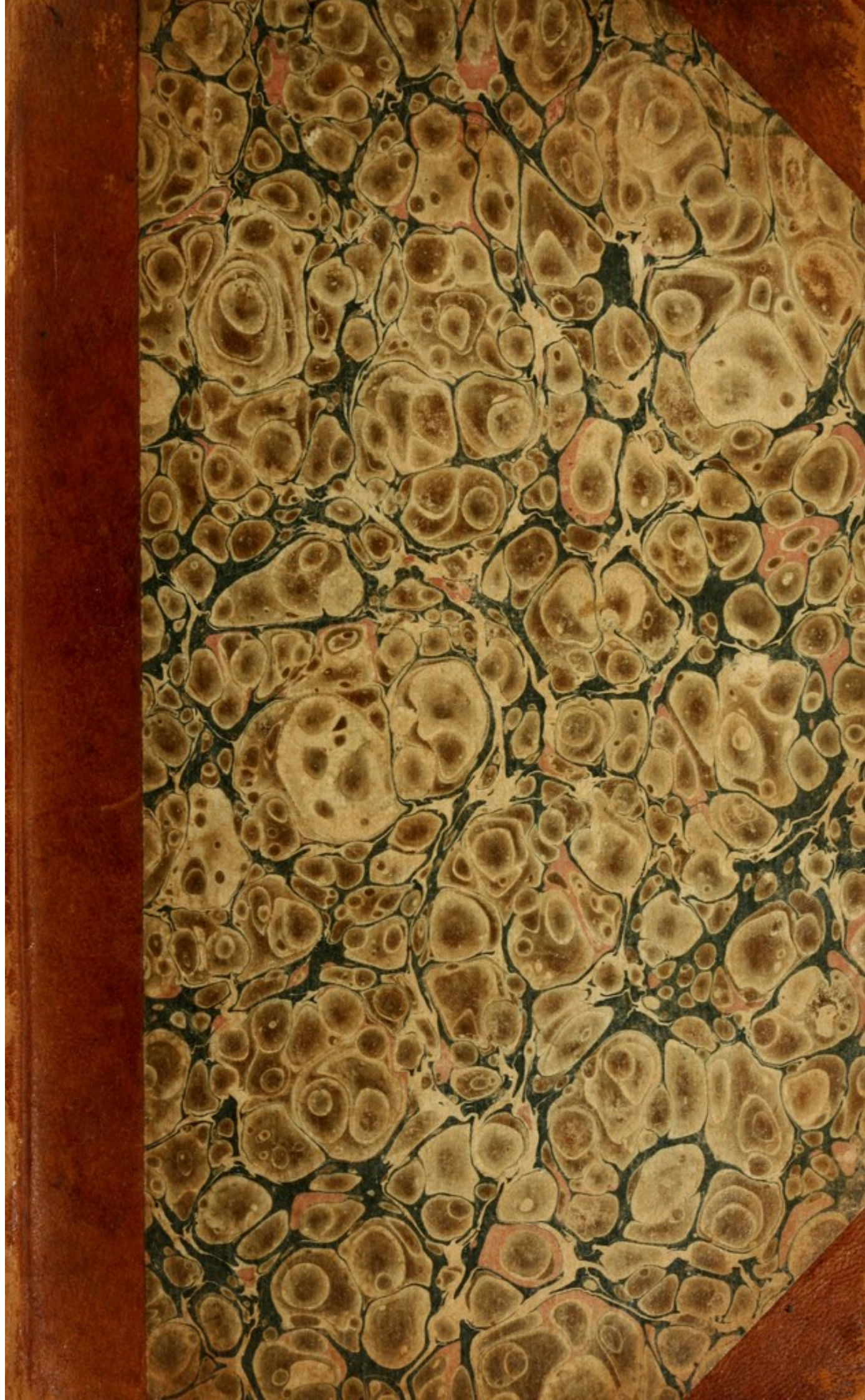
This material has been provided by This material has been provided by the Harvey Cushing/John Hay Whitney Medical Library at Yale University, through the Medical Heritage Library. The original may be consulted at the Harvey Cushing/John Hay Whitney Medical Library at Yale University. where the originals may be consulted.

This work has been identified as being free of known restrictions under copyright law, including all related and neighbouring rights and is being made available under the Creative Commons, Public Domain Mark.

You can copy, modify, distribute and perform the work, even for commercial purposes, without asking permission.



Wellcome Collection
183 Euston Road
London NW1 2BE UK
T +44 (0)20 7611 8722
E library@wellcomecollection.org
<https://wellcomecollection.org>




YALE
MEDICAL LIBRARY



HISTORICAL
LIBRARY
The Harvey Cushing Fund

Charles Jordan
Died
Maine



MANUAL

OF THE EYE

A
M A N U A L
OF THE
DISEASES OF THE EYE.

BY
S. LITTELL, JR., M. D.

ONE OF THE SURGEONS OF THE WILLS HOSPITAL FOR THE BLIND
AND LAME, FELLOW OF THE COLLEGE OF PHYSICIANS
OF PHILADELPHIA, ETC. ETC.

PUBLISHED BY
J O H N S. L I T T E L L,
PHILADELPHIA.
.....
1837.

Entered according to the Act of Congress, in the
year Eighteen Hundred and Thirty-Six, by J o h n
S. L I T T E L L, in the Clerk's Office of the District
Court for the Eastern District of Pennsylvania.



TO
GEORGE B. WOOD, M.D.,

PROFESSOR OF MATERIA MEDICA

IN THE
UNIVERSITY OF PENNSYLVANIA,

THIS LITTLE VOLUME
IS INSCRIBED BY HIS FRIEND,

THE AUTHOR.

Digitized by the Internet Archive
in 2012 with funding from
Open Knowledge Commons and Yale University, Cushing/Whitney Medical Library



ADVERTISEMENT.

THE importance of the organ of vision, and the facilities afforded by its structure for the investigation of the various morbid affections to which it is exposed, have always rendered it a favourite object of regard ; and the numerous publications which at different times have appeared, attest alike the skill and the research of those who have cultivated with especial attention this department of Surgery. Several of these productions—the late elaborate treatises of MACKENZIE, LAWRENCE, and MIDDLEMORE, in particular,—have left to the *student* little further to desire ; but a summary of modern practice which should comprise all the recent improvements, and exhibit, in a compendious form, the actual extent of our information, was still a desideratum to the *physician* engaged in the active duties of his Profession. With the exception of WELLER'S Manual, translated by the late DR. MONTEATH, and the little compilation by MR. WALKER, no attempt has hitherto been made to supply this obvious want ; and to each of these, there are objections which will ever prevent a republication in this country. The work first mentioned, though containing many excellent observations, and valuable as presenting a view of the state of Ophthalmic Surgery among our German brethren, has already become, in some measure, antiquated ; while the other, from the extreme paucity of its de-

tails, appears to have been written rather as the medium for some ingenious speculations on the Physiology of the Iris, than with a principal design to practical utility. Under these circumstances, the present volume has been composed, with the expectation, in some degree, of supplying the deficiency. It has been the object of the author, to present the points of chief importance in the symptoms, causes, and treatment of each disease, with as much brevity and perspicuity, and at the same time, with as much minuteness, as the nature of the plan would permit; he has freely availed himself of the best sources of information; and the result of his labours is submitted to the Profession, in the hope, that though a small, it may not prove an unacceptable offering.

Philadelphia, Dec. 9, 1836.

CONTENTS.

	PAGE
DISEASES OF THE ORBIT.	
Inflammation of the Cellular tissue, - -	1
Tumours, - - - - -	3
Aneurism by Anastomosis, - - - -	4
 WOUNDS OF THE EYE AND ITS APPENDAGES.	
Wounds of the Orbit, - - - - -	5
———— of the Eyelids. Ecchymosis. - -	5
———— of the Globe, - - - - -	6
———— of the Cornea, - - - - -	9
———— of the Sclerotica, - - - - -	10
———— of the Iris, - - - - -	11
———— of the Crystalline and Capsule, -	12
———— of the Retina, - - - - -	13
 DISEASES OF THE LACHRYMAL ORGANS.	
Inflammation of the Lachrymal Gland, - -	15
Scirrhus of the Lachrymal Gland, - -	16
Lachrymal Tumour, - - - - -	17
Dilatation of the Lachrymal Ducts, - -	17
Epiphora, - - - - -	18
Stillicidium, - - - - -	18
Xeroma, - - - - -	19

	PAGE
Acute Inflammation of the Lachrymal Sac, -	20
Chronic Inflammation of the Lachrymal Sac, -	22
Dropsy of the Lachrymal Sac, - - -	25
Inflammation of the Lachrymal Caruncle, -	26
Encanthis, - - - - -	26

DISEASES OF THE PALPEBRÆ.

Inflammation of the Eyelids, - - -	28
Œdema of the Eyelids, - - -	29
Erysipelatous Inflammation of the Eyelids, -	29
Inflammation of the Edges of the Eyelids, -	30
Syphilitic affections of the Eyelids, - -	34
Cancer of the Eyelids, - - - -	35
Carbuncle of the Eyelids, - - - -	38
Hordeolum, - - - - -	38
Grando. Miliun, - - - - -	39
Phlyctenula, Verruca, - - - -	40
Tumours of the Eyelids, - - - -	40
Nævi Materni, - - - - -	42
Adhesion of the Eyelids, - - - -	43
Ectropium, - - - - -	44
Entropium, - - - - -	46
Trichiasis, - - - - -	49
Distichiasis, - - - - -	49
Lagophthalmus, - - - - -	50
Ptoſis, - - - - -	51

DISEASES OF THE CONJUNCTIVA.

Simple Conjunctivitis, - - - -	53
Catarrhal Conjunctivitis, - - - -	60
Purulent Conjunctivitis, - - - -	65

	PAGE
Conjunctivitis Neonatorum, - - - -	73
Gonorrhœal Conjunctivitis, - - - -	77
Strumous Conjunctivitis, - - - -	80
Variolous Conjunctivitis, - - - -	87
Granular Conjunctiva, - - - -	90
Pannus, - - - -	93
Ulcer of the Conjunctiva, - - - -	95
Pterygium, - - - -	96
Tumours of the Conjunctiva, - - - -	98
Fungus of the Conjunctiva, - - - -	98
Relaxation of the Conjunctiva, - - - -	98
Cuticular Conjunctiva, - - - -	99

DISEASES OF THE CORNEA.

Acute Corneitis, - - - -	100
Strumous Corneitis, - - - -	102
Aquo-Capsulitis, - - - -	104
Abscess of the Cornea, - - - -	106
Ulcer of the Cornea, - - - -	107
Hernia of the Cornea, - - - -	111
Dimple of the Cornea, - - - -	111
Gangrene of the Cornea, - - - -	112
Opacity of the Cornea, - - - -	113
Staphyloma of the Cornea, - - - -	115
Conical Cornea, - - - -	118

DISEASES OF THE SCLEROTICA.

Sclerotitis, - - - -	121
Catarrho-Rheumatic Ophthalmia, - - - -	124
Staphyloma of the Sclerotica, - - - -	125

	PAGE
DISEASES OF THE CHOROID.	
Choroiditis, - - - - -	126
DISEASES OF THE RETINA.	
Acute Retinitis, - - - - -	128
Chronic Retinitis, - - - - -	130
Amaurosis, - - - - -	131
DISEASES OF THE IRIS.	
Simple Acute Iritis, - - - - -	138
Sub-Acute Iritis, - - - - -	142
Syphilitic Iritis, - - - - -	144
Rheumatic and Arthritic Iritis, - - - - -	145
Strumous Iritis, - - - - -	147
Prolapsus of the Iris, - - - - -	148
Paralysis of the Iris, - - - - -	149
Fungus excrescences of the Iris, - - - - -	149
Coloboma Iridis, - - - - -	150
Artificial Dilatation of the Pupil, - - - - -	150
Artificial Pupil, - - - - -	153
<i>Corotomia</i> , - - - - -	154
<i>Corectomia</i> , - - - - -	157
<i>Corodialysis</i> , - - - - -	158
DISEASES OF THE CRYSTALLINE AND CAPSULE.	
Capsulitis, - - - - -	160
Cataract, - - - - -	162
<i>Solution</i> , - - - - -	170
<i>Depression</i> , - - - - -	173
<i>Extraction</i> , - - - - -	176

	PAGE
DISEASES OF THE HUMOURS.	
Hydrophthalia, - - - - -	181
Glaucoma, - - - - -	183
Synchysis Oculi, - - - - -	185
DISEASES OF THE GLOBE.	
Ophthalmitis, - - - - -	187
Ophthalmitis Interna, - - - - -	190
Ophthalmitis Externa, - - - - -	193
Suppuration of the Globe, - - - - -	194
Exophthalmia, - - - - -	195
Hypoæma, - - - - -	195
Paralysis of the Eyeball, - - - - -	196
Atrophy of the Eyeball, - - - - -	197
MALIGNANT DISEASES OF THE EYE.	
Cancer of the Eye, - - - - -	198
Melanosis of the Eye, - - - - -	200
Fungus Hæmatodes, - - - - -	202
EXTIRPATION OF THE EYE. - - - - -	206
NEURALGIA OF THE EYE. - - - - -	209
VARIOUS STATES OF DEFECTIVE VISION.	
Muscæ Volitantes, - - - - -	212
Strabismus, - - - - -	214
Myopia, - - - - -	215

	PAGE
Presbyopia, - - - - -	217
Hemeralopia, - - - - -	218
Nyctalopia, - - - - -	220
FORMULÆ, - - - - -	221
VOCABULARY, - - - - -	235

ERRATA.

Page 2, line 3, for "palpebra," read palpebræ.

" 24, " 7, after "liquorice," read root.

" 30, " 21, for "have," read has.

" 34, " 12, dele "Nos."

" 58, " 11, for "gangreen," read gangrene.

" 80, " 26, for "affection," read affections.

" 104, " 25, for "laminæ," read lamina.

ERRATA.

Page 2, line 8, for "palpebra," read palpebra.

J. VAN COURT, PRINTER

48 MARKET STREET.

DISEASES OF THE EYE.

DISEASES OF THE ORBIT.

INFLAMMATION OF THE ORBIT.

INFLAMMATION of the orbit may originate either in the cellular membrane, in the periosteum, or in the bones which contribute to the formation of that cavity, and exhibits the morbid terminations peculiar to the several tissues in which it is seated, —suppuration, thickening, exostosis, caries, &c.; with a single exception, however, it will be quite unnecessary to enter into any detail on these subjects, since they can only be treated on the general principles applicable to similar affections in other parts of the body, and derive their importance from the proximity of the brain, rather than from their influence on the organ of vision.

Inflammation of the cellular tissue within the orbit is characterized by severe, deeply seated, and progressively increasing pain, headach, immobility of the globe, and a feeling of distension, arising from the swelling of the inflamed parts, which

gradually protrude the eye so as to give it an unnatural prominence. There is also more or less tumefaction of the palpebra, the patient is annoyed by intolerance of light and frequent scintillations, the lachrymal secretion is increased, the slightest motion of the eyeball is attended with acute pain, and vision is always more or less impaired—sometimes speedily lost altogether. In violent cases, the eye becomes protuberant, the lids enormously swollen, and the cornea ultimately gives way. The constitutional disturbance is proportionate to the severity of the local symptoms, and delirium is a common occurrence. Suppuration at length takes place, generally indicated by the usual symptoms, rigors, throbbing, &c., but is followed by no abatement of the pain; fluctuation may often be perceived, and the abscess approaches the surface at some point around the margin of the orbit, or between the palpebra and the eyeball.

Treatment. The urgency of the symptoms, and the danger of the inflammation extending to the brain, call for the vigorous employment of antiphlogistic measures, and render it necessary to evacuate the matter as soon as its existence is ascertained, even though it may not have made sufficient progress to be felt through the integuments, —fatal consequences having in some instances arisen from pressure upon the cranium.

The cellular tissue sometimes becomes indurated from inflammation of a more chronic charac-

ter, accompanied, however, with intense pain and chemosis. Cases are recorded in which the eye was protruded and destroyed from this cause, and it eventually became necessary to remove the disorganized and hypertrophied parts by an operation.

TUMOURS.

Morbid growths of various kinds,—osseous, sarcomatous, encysted, and hydatid,—are occasionally met with in the orbit, and as, independently of their effects upon the eye, they may produce absorption of the orbital process, and thus occasion fatal pressure upon the brain, they should be removed by an early operation. When their contents are fluid, a simple puncture may suffice; but in other cases an incision will be required, either through the integuments or conjunctiva, according to circumstances,—the former being preferable when the tumour is situated above the levator muscle, and does not extend far within the orbit. DR. MONTEATH found it necessary, in one instance, to make an incision perpendicular to the tarsal margin, through the whole breadth of the eyelid. The tumour having been exposed, is secured by means of a hook or ligature, and the dissection carefully performed with the common scalpel. When the operation is performed through the conjunctiva, it will be requisite previously to divide the external commissure of the lids; the edges of the wound

should afterwards be carefully approximated, retained in their position by suture, and the subsequent inflammation moderated by cold applications and other appropriate remedies.

The affection known under the name of ANEURISM BY ANASTOMOSIS, sometimes has its seat within the orbit, and is recognized by pain in the eye and head, accompanied with a throbbing, rushing, or thrilling sensation, humming in the ears, and protrusion of the eyeball. Its effects upon the organ of vision are often very serious,—inflammation ensues, pus is effused within the globe, and between the lamellæ of the cornea, sloughing or ulceration follows, and the humours are discharged. The application of a ligature to the carotid of the affected side, is the only remedy, and several instances are recorded in which this operation has been successfully performed.

WOUNDS OF THE EYE AND ITS APPENDAGES.

INJURIES OF THE EYELIDS.

THE parts around the eye are liable to contusions, fractures, and wounds of every description; but since they require the same treatment as similar accidents occurring elsewhere, modified only by their influence upon the brain, it is unnecessary to treat of them in detail. All extraneous substances must of course be removed, and such measures adopted as will most effectually tend to prevent the accession of inflammation. In wounds of the eyelids, the utmost care should be taken to replace and preserve the parts in accurate adjustment, and for this purpose, it may be necessary to employ one or more very fine sutures in addition to the aid derived from adhesive plaster. When the lid is extensively lacerated, the importance of the part will indicate the necessity of adopting every precaution to cherish its vitality. Ecchymosis, from contusion, is a common occurrence, and besides the usual antiphlogistic remedies, may require the employment of means to promote the absorption of the extravasated fluid; if the effusion be more considerable, and the part swollen and tense, it may be evacuated by a puncture with the lancet. Injuries of the frontal nerve are not unfrequently followed by amaurosis.

WOUNDS OF THE GLOBE.

The delicate structure of the eye and its exposed situation, renders it liable to suffer from external violence, the consequences of which are either primary,—the direct result of the accident, or secondary,—depending upon the alterations produced by the subsequent inflammation. They differ, also, according as they are occasioned by chemical or mechanical agency. The most common, are wounds of various kinds,—punctured, lacerated, or incised,—whether inflicted accidentally, or in the performance of surgical operations; contusions; and injuries from boiling water, or steam, melted metals, lime, the mineral acids, the explosion of powder, &c. &c. In all these cases, after the removal of the cause, attention should be chiefly directed, by the employment of rigid antiphlogistic measures, to the prevention and cure of inflammation. In the performance of surgical operations, when the patient has been previously prepared by a restricted diet, saline laxatives, and, in plethoric habits, by venæ-section, and where active treatment is adopted on the first appearance of inflammation, it rarely proceeds so far, in healthy constitutions, as materially to injure the eye; but under other circumstances, the best directed exertions may be unavailing. Violent blows sometimes produce rupture of the cornea, more frequently of the sclerotica, and this

may happen without lesion of the conjunctiva; or the choroid and retina may be separated from their connections, and otherwise injured, the external tunics preserving their continuity. Amaurosis is a frequent consequence of such accidents, and may likewise be occasioned by the irritation of foreign substances which have penetrated within the eye; injuries of the latter kind are sometimes followed by atrophy of the eyeball, in consequence of the destruction of its secretory powers by the subsequent inflammation, and at others by an irritable condition of the organ. Dislocation of the globe is a serious occurrence, the muscles being more or less extensively lacerated, and vision often entirely destroyed. The protruded organ should be replaced with as little delay as possible, and appropriate measures employed to obviate the consequences of so grave an injury. Its replacement may be facilitated by depressing the lower lid, and if necessary, by dividing the external commissure. Where much time has elapsed, and the swelling presents an insuperable obstacle to the reduction of the eye, it will be proper to wait until it has in some measure subsided under the application of leeches, &c. when, if the muscles have not been generally ruptured, it will often spontaneously recede. In cases of evulsion, where the globe is torn from all its natural connections, it would be preposterous to make any effort to restore it. Blood effused beneath the conjunctiva, in conse-

quence of local injury, is ordinarily absorbed as the inflammatory action disappears, but if it be deemed expedient to accelerate this process, the solution of the nitrate of silver may be employed for that purpose. Burns, arising from whatever cause, should be treated in the first instance by some tepid, bland collyrium, which, after a few days, may be exchanged for the solution just mentioned; if the injury be extensive, general and local depletion, saline laxatives, &c. will also be indicated, and the utmost care will be required to guard against inflammation of the more deeply seated tissues. When the heat has been so intense as to destroy the texture of the conjunctiva, granulations arise from the inflamed cellular membrane, and adhesions are apt to form between the palpebra and the globe. To prevent such an occurrence, it will be proper to separate any recently formed bands, and to apply the nitrate of silver in substance to the inner surface of the eyelids. When a foreign body, as a shot, or particle of metal, has actually entered the eye, it would be obviously improper to undertake any operation for its removal, unless it were so situated as to be visible; in which case, should it threaten to give rise to much irritation, it might be readily extracted through a small incision in the cornea. Such substances are generally removed through the agency of the aqueous humour when of a nature capable of being acted upon by that fluid, and where this

does not happen, it has sometimes occurred that lymph has been thrown out around them, and they have remained encysted for years without occasioning any inconvenience;—this termination, however, only takes place when the particle is small, and situated at the bottom of the anterior chamber.

WOUNDS OF THE CORNEA.

Slight injuries of the cornea in persons from any cause predisposed to inflammation, are often followed by serious consequences. WALTHER states, that in a small district in Germany, fifty or sixty eyes are annually destroyed from wounds inflicted by the beards or heads of grain; and similar accidents are not uncommon during the harvest season in our own country. Penetrating wounds of the cornea are followed by the escape of the aqueous humour, and unless the opening be very small, prolapsus of the iris is not an unfrequent consequence. The fluid is speedily reproduced after the closure of the wound, and no particular treatment is required, other than that which may be necessary to prevent or subdue inflammation. The lids should be closed, and covered with a compress moistened by some refrigerating lotion, in order to support the part, and obviate the friction between the edges of the wound, and the inner surface of the palpebra. If the iris protrude,

it will be proper to assist its retraction by friction over the closed lid, and sudden exposure to a bright light, or by gently repressing it with the blunt extremity of a probe; and also to endeavour to prevent its return by the application of belladonna to the brow. When the protrusion is large, and has the appearance of a bag containing aqueous humour, a slight puncture at the most prominent part, will in some instances enable the iris more readily to resume its position. Appropriate remedies should be adopted in all cases, to moderate the inflammatory symptoms; and if, after their removal, the protruding portion do not recede, it may be necessary to excise it with the curved scissors, and promote the cicatrization of the wound, by touching it occasionally with the nitrate of silver in substance, or strong solution. Foreign bodies are sometimes arrested in the cornea, and, in most instances, may be readily withdrawn by the forceps, or extricated with the blunted extremity of a cataract needle; if they have passed entirely within the anterior chamber, and an operation be deemed advisable, a puncture may be made near the margin of the cornea, and the offending substance extracted by a small pair of forceps.

WOUNDS OF THE SCLEROTICA

Are generally attended with serious injury to the parts which that membrane is designed to protect; it is sometimes burst by the violence of a

blow, and concussion of the retina, internal extravasation, and amaurosis, are almost invariable consequences. There is little hope of preserving vision in such cases, and suppuration can only be averted by the most active antiphlogistic treatment. By some writers, union is said never to take place after division or puncture of the sclerotica, but this statement is contrary to what we might, a priori, have anticipated, and is, moreover contradicted by the observation of others.

WOUNDS OF THE IRIS.

The iris is occasionally separated from its ciliary connections by a fall or blow, and an adventitious pupil is thus formed which may give rise to much inconvenience. The newly made opening is generally soon obliterated, but when this does not happen, and the confusion of vision is very considerable, it may be proper to divide the intervening portion of the membrane, and thus unite the two apertures. Foreign bodies which have penetrated the eye, sometimes lodge in the iris; but in general no interference is required, unless they be large and produce much irritation. Absorption of the substance of the iris, to a greater or less extent, in consequence of local injury, is not an unfrequent occurrence, and in some instances, the pupil deviates from its natural situation in the centre, and assumes a position at the circumference

of the membrane, retaining its mobility, and approaching to an oval form.

Wounds of the iris must be treated on the general principles of averting inflammation, and preventing the contraction of the circular fibres and the formation of adhesions with the crystalline capsule by the employment of belladonna. The blood which in such cases is often effused into the chambers of the eye, is generally absorbed as the inflammatory action subsides. Injuries in which the texture of the iris has been much lacerated or otherwise injured, are frequently followed by amaurosis.

WOUNDS OF THE CRYSTALLINE AND CAPSULE.

Opacity of the lens and its capsule is the usual consequence of injury, whether it consists in a puncture merely, or detachment from their vascular connections with the ciliary processes. In the latter case, they are in the situation of a foreign body, and either float loosely in the eye, or are retained in their place by the adhesion of the posterior hemisphere of the capsule to the hyaloid membrane. The symptoms attending these dislocations vary according to the nature of the injury, individual susceptibility, &c. &c. They are often followed by violent ophthalmitis, accompanied with intense pain in the organ, and hemicrania. When the capsule is also ruptured, the opaque lens,

subjected to the action of the aqueous humour, is gradually absorbed, especially in early life, and membranous cataract is the result. In those cases where the crystalline presses against the iris, or has passed into the anterior chamber, occasioning as it sometimes does great irritation, it should be removed by a small incision through the cornea. Particles penetrating the eye, are sometimes arrested in the substance of the lens; under such circumstances it will be proper to wait until all irritation has subsided, after which, if it be deemed expedient, the operation for extraction may be performed.

WOUNDS OF THE RETINA.

When the delicate structure of the retina is considered, it will not appear surprising that vision should frequently be impaired or altogether destroyed from blows and other injuries. In some instances there is no perceptible alteration in the appearance of the organ, and the amaurosis is probably occasioned by concussion, or rupture of the retina; while in others, blood is effused, with laceration of the sclerotica, and extensive disorganization of the internal parts of the eye. The prognosis will vary of course according to the circumstances of each particular case; in those last mentioned, recovery is hopeless, but slighter degrees of injury may often be successfully managed if assistance be

obtained soon after their infliction; though it sometimes happens that permanent blindness is produced by causes, which would scarcely have been deemed adequate to occasion such an effect. Depletion, both general and local, counter irritation, and mercury, should be employed with a freedom proportionate to the severity of the accident, and the importance of the affected organ. Atrophy of the globe is not an unusual sequel; and it has also been observed that where vision is thus destroyed in one eye, the other is liable to become amaurotic: by proper treatment,—cupping, rest, diet, &c.—this melancholy termination may often be averted. Punctured wounds of the retina, and pressure from a lens displaced in the operation of couching, are occasional causes of amaurosis, and indicate the expediency, in every instance, of adopting all proper precautions to prevent such a result.

DISEASES OF THE LACHRYMAL
ORGANS.

INFLAMMATION OF THE LACHRYMAL GLAND.

THIS disease is chiefly observed in children of strumous constitutions, and may arise either primarily, or by the extension of inflammation from the neighbouring parts. It commences with an increased secretion of tears, soon followed by a sensation of dryness in the eye, pain, and swelling in the situation of the gland; the globe is displaced downwards and inwards, and its mobility is gradually more and more limited. The pain increases and is felt throughout the head, but is particularly severe in the temple, and over the brow; the upper eyelid becomes swollen, tense, and extremely sensible to the touch; vision is impaired from the beginning, and in the advanced stage sometimes lost altogether. The conjunctiva participates in the inflammation; the patient is tormented by frequent flashes of light, delirium is not unfrequent, and the inflammation if not arrested, terminates in suppuration,—the opening through which the matter is discharged sometimes becoming fistulous. There is also a chronic form of the complaint, attended with enlargement of the gland, dryness, a sense of fullness rather than of pain, and more or less constraint in the motions of the eyeball;

the tumour has a lobulated appearance, and sometimes attains a considerable size; it may either remain stationary for a time, or terminate in the imperfect suppuration peculiar to scrophula.

Treatment. In the acute stage, general and local depletion, saline cathartics, and refrigerating lotions are the proper remedies. When suppuration is about to take place, it should be promoted by the usual means, and the matter discharged without unnecessary delay, by a puncture beneath the eyelid. Frictions with mercurial ointment, or with the liniment. hydrarg. comp., (R. No. 45,) may be employed to remove any induration which remains after the part has healed. The preceding measures less actively employed, together with the alterative use of mercury, the preparations of bark, and iron, and other means calculated to invigorate the constitution, constitute the appropriate treatment for the chronic form in which the inflammation sometimes appears.

In regard to the frequency of this disease, there is a wide discrepancy of opinion; by some writers, SCHMIDT, TODD, and others, it is described as of common occurrence: while MIDDLEMORE states, that it has rarely fallen under his observation, and MR. LAWRENCE has never witnessed it, either in its acute or chronic form.

A chronic enlargement of the gland, accompanied with induration and a lobulated condition of surface, has been described as a cancerous affec-

tion; but there seems reason to doubt whether it be really malignant. The tumour, when incised, displays a firm, compact and striated texture, but is said not to possess the cartilaginous hardness of scirrhus; and differs moreover, in that it does not become adherent to the surrounding parts, undergo ulceration, affect the lymphatic system, or return after extirpation: it is most frequent also, in persons of strumous diathesis. There are, however, many points of resemblance;—it rarely occurs before the middle period of life, the pain is severe and lancinating,—and since if allowed to increase, it produces serious consequences by pressure upon the surrounding parts, it may, for all practical purposes, be regarded as cancerous.

A tumour sometimes forms in the lachrymal gland, containing a clear limpid fluid enclosed in a cyst; it is readily distinguished from the preceding variety, by its uniformity of surface, and the absence of lancinating pain. It was originally described by SCHMIDT, and by him attributed to an accumulation of tears within the gland. The treatment consists in puncturing the tumour, and when this does not succeed in effecting a cure, it may be removed by an operation. It occasionally happens that one of the lachrymal ducts becomes dilated near its termination, and a swelling forms, which appears as a semi-transparent or vesicular body when the lid is everted. It is liable to be confounded with the encysted tumour of these

parts, but the error is of little moment, the treatment being in both cases the same.

EPIPHORA. STILLICIDIUM. XEROMA.

When the lachrymal fluid is secreted in undue quantity, the redundant tears flow over the cheek, constituting the complaint styled epiphora; the same effect is also produced from defective absorption, and is then termed stillicidium lachrymarum. The lachrymal secretion is increased by every chemical, or mechanical irritation of the conjunctiva, and epiphora is consequently an usual attendant on all inflammations of the eye and its appendages. It is especially common in strumous ophthalmia, and may arise also from dentition, and intestinal irritation. Imperforation of the nasal duct, or lachrymal canaliculi, contraction of the puncta, and a patulous condition of those orifices, an occasional sequel of chronic ophthalmia in old people, are the ordinary causes of stillicidium.

Treatment. As a mere symptom of ophthalmia, epiphora requires no particular attention; but when it exists as an independent affection, or arises from sympathy with some remote part, it may be removed by the employment of gentle stimuli, as the nitrate of silver, the sulphate of copper or zinc, the diluted vinum opii, and the red precipitate, or citrine ointment; together with due attention to

the state of the bowels, and the improvement of the general health. Rhubarb with magnesia or the bi-carbonate of soda, the sulphate of quinine, and the carbonate of iron, will frequently prove serviceable in the strumous constitutions in which it so often appears. If it depend, as it sometimes does, upon a morbid excitement of the lachrymal gland, it may be cured by the repeated application of leeches above the brow, assisted by the operation of a blister. The local remedies above mentioned, will be found equally useful in many cases of stillicidium. When the puncta are unduly contracted, an attempt may be made to restore the natural size of the apertures by artificial dilatation.

An opposite condition, known under the appellation of xeroma, or dryness of the eye, has been noticed as a symptom in chronic enlargement of the lachrymal gland, and will hereafter be seen accompanying the incipient stages of several diseases, ophthalmia, amaurosis, &c. It may arise also, from partial obliteration of the excretory ducts, and sometimes occurs as a nervous, or sympathetic phenomenon. The secretion from the conjunctiva takes place as usual, the surface of the membrane is clear and moist, and altogether unchanged in appearance; but the patient complains of dryness, and a sensation as of dust between the lids. When it is caused by obstruction of some of the excretory ducts, those which remain pervious, in general dilate sufficiently to supply their

place. Surgical treatment, if any be necessary, must be guided by the nature of the cause, and where this cannot be clearly ascertained, benefit will occasionally be derived from the application of blisters to the temple, and the employment of electricity.

ACUTE INFLAMMATION OF THE LACHRYMAL SAC.

Inflammation of the lachrymal sac is recognised by the appearance of a small, circumscribed, and sensitive tumour, immediately below the tendon of the orbicularis; the eyelids are slightly swollen, and the integuments somewhat red and inflamed; as the symptoms increase, the tumour acquires a bright red, or livid colour, and the redness and tumefaction extending to the surrounding parts, give to them an erysipelatous aspect. The pain, dull and lancinating in the commencement, becomes acute, tensive and throbbing; the swelling towards the nose is so considerable as almost to conceal the eye, and in the immediate neighbourhood of the inflamed sac, is exquisitely tender to the touch; the patient complains of agonizing headache, and the constitutional disturbance is much more considerable than might have been anticipated from the diminutive size of the inflamed cavity. The congestion of the membrane, is sometimes relieved by an increased secretion from its surface which

escapes through the puncta, but more generally, suppuration ensues, attended with an abatement of pain and headache; the tumour enlarges, becomes tense and shining, with evident fluctuation, and the matter is discharged through an ulcerated opening in the sac and integuments. The inflammation may now subside, the aperture heal, and the tears resume their course; or, in persons of unhealthy constitutions, becoming chronic, may terminate in permanent obstruction of the nasal duct; the secretion from the sac, mingled with the lachrymal fluid, continuing to be discharged through a fistulous orifice. The patient is also liable to a subsequent attack of acute inflammation, accompanied by a repetition of the train of symptoms which have just been enumerated. The disease generally occurs in strumous constitutions, and syphilis, variola and the other exanthemata, are the usual exciting causes; in some instances, it has been observed to supervene on an attack of influenza.

Treatment. Venæsection, the repeated application of leeches over the sac, purgatives, and the usual antiphlogistic remedies, to an extent proportionate to the severity of the symptoms, constitute the principal part of the treatment. Fomentations by a sponge wrung out of warm water, or some anodyne decoction, poultices of flaxseed meal, &c. are the best local applications. As soon as fluctuation can be perceived, an opening should be made with the point of a lancet. Some practitioners

recommend the immediate introduction of a probe, to restore the permeability of the passage; but even if this were not precluded by the extreme sensibility of the parts, it would be much more prudent to endeavour by soothing measures to allay the inflammation, and defer any attempt of this kind until the irritation had subsided. Should the discharge continue and threaten to become chronic, the wound may be dressed with lint moistened with the compound tincture of benzoin, or covered with the resinous cerate, &c. Astringent collyria, and the internal exhibition of quinine and other tonic medicines, will prove useful under such circumstances.

CHRONIC INFLAMMATION OF THE LACHRYMAL SAC.

In this affection, which may occur either as a primary disease, or as a sequel of the acute form, the inflammatory symptoms are of a much milder character; a tumour appears at the inner canthus, occasioned by the secretion from the lining membrane accumulating within, and distending the sac. It is accompanied with dryness of the nostril, and stillicidium; and may be either indolent, or painful, colourless, or red, according to the degree of the inflammation. By gentle pressure, its contents can be made to pass through the puncta, and

sometimes through the duct, into the nostril. The palpebral conjunctiva and meibomian glands are more or less inflamed, the eye becomes irritable and watery, and the patient is almost incapacitated from employing it in viewing minute objects. The inflammation is liable to occasional exacerbations, during which the sac ulcerates, and the opening either heals, or the duct having become permanently obstructed, a fistulous orifice remains. In many cases the disease disappears almost entirely during the summer months, and returns again on the approach of cold and variable weather.

Causes. It most commonly appears in young persons of strumous constitutions, and as has already been intimated, may arise either primarily, or by the extension of inflammation from other parts; as in catarrhal affections of the conjunctiva, and schneiderian membrane.

Treatment. The primary indication is the removal of inflammatory action, by the employment of leeches and other appropriate remedies. When this has been effected, if the tumour do not subside, it should be occasionally emptied by gentle pressure, and treated with stimulating applications to the conjunctiva, and edges of the eyelid; which operate either by correcting the morbid condition of that membrane and the meibomian glands, or are absorbed by the puncta, and exert their influence on the mucous lining of the sac. Solutions of the nitrate of silver, the sulphates of

zinc, copper and alumine, the ointments of the white and red precipitate, and the unguentum hydrargyri nitratis, may be beneficially employed with this view. At this period of the disease, sternutatories, as common snuff, or equal parts of the sub-sulphate of mercury and pulverized liquorice, sometimes prove serviceable: and in persons of strumous diathesis, attention to the improvement of the digestive organs, the preparations of bark and iron, the shower bath, and other invigorating measures, constitute an important part of the therapeutics.

Should the preceding plan prove ineffectual, or a fistulous orifice remain after suppuration of the sac, it will be necessary to institute measures to overcome the obstruction, which generally consists in accretion of the nasal orifice, or imperforation of the duct from stricture. The means usually adopted, is the introduction of a style through the opening already existing in the sac, or if this be not properly situated, through an aperture formed for the purpose. In the latter case, the incision must be made immediately below the tendon of the orbicularis, and a probe passed down to the floor of the nostril, to ascertain the permeability of the channel; this is then withdrawn, and a small bougie introduced, and worn for a day or two, when it is replaced by one of larger size; the passage being cleared by the injection of tepid water at each removal. After the bougie has been used

for a week or more, the nail-headed style should be substituted, and permanently worn; removing it occasionally only, in order to cleanse the instrument, and inject a little warm fluid through the opening. Under this treatment the patency of the canal is secured, the dilated sac gradually contracts around the style, and the tears, absorbed by the puncta, pass along its surface into the nostril. The cure is sometimes completed in a few months; but the obstruction is liable to recur if the style be removed too early. A small fistulous orifice sometimes remains, after the permeability of the passage has been restored, and may be healed by touching it, from time to time, with a pencil of the nitrate of silver.

When the lachrymal reservoir is distended by the accumulating fluid unaccompanied by any inflammatory symptoms, constituting the affection denominated dropsy of the sac, a cure may frequently be effected by the occasional evacuation of its contents by pressure, and the employment of some astringent solution. The instances in which fistula lachrymalis arises from the presence of a polypus excrescence within the sac, are so rare, that it is unnecessary to do more than advert to the possibility of such an occurrence.

D

INFLAMMATION OF THE LACHRYMAL CARUNCLE. ENCANTHIS.

The lachrymal caruncle and semilunar membrane, are liable to inflammation from local injury, or any accidental irritation. It is in general, easily subdued by leeches, scarifications if the vessels appear very turgid, and soothing fomentations. When suppuration is threatened, it should be promoted by the usual means, the matter evacuated by an early opening, and the cure completed by the employment of astringent collyria.

Encanthis is a term applied to a chronic enlargement of these parts, which sometimes attains to a considerable magnitude, extending along the inner margin of the lids, interposing a mechanical obstacle to their closure, and giving rise to stillicidium, and chronic ophthalmia. Two species are described; one of which is said to be malignant, and to be characterized by lividity, induration, lancinating pain, and a varicose condition of surface. In some instances, the enlargement has been owing to the irritation caused by a detached cilium, one end of which had become engaged in the punctum lachrymale.

In recent cases, the tumour will frequently subside, after the cause which produced it has been removed, under the use of soothing measures, mild astringent lotions, and if circumstances re-

quire it, the local abstraction of blood by leeches. At other times, advantage will be derived from the persevering employment of collyria, containing the nitrate of silver, or the sulphate of copper. But when this treatment does not succeed, or the excrescence assumes a cancerous disposition, excision is the proper remedy. The operation is easily performed by passing a hook or ligature through the tumour, and detaching it from its connections by means of the curved scissors. Cases however, requiring such interference, must be extremely rare, since MR. LAWRENCE states that none have occurred in his practice.

DISEASES OF THE PALPEBRÆ.

INFLAMMATION OF THE EYELIDS.

INFLAMMATION may affect the palpebræ, either primarily or by extension from the surrounding parts, and assumes a phlegmonous, erysipelatous, or chronic character, according to the tissue in which it is seated. Phlegmonous inflammation occurs more frequently in children than adults, and in the upper than the lower eyelid. It is characterized by the usual symptoms, pain, redness, and swelling; and is very prone to terminate in suppuration, which may tend to either surface. The tumefaction is generally so considerable, from effusion into the loose cellular texture, as entirely to close the eye. When pus has actually been secreted, the pain becomes pulsative, the swelling increases, and presents a livid renitent appearance. In ophthalmia, inflammation of the lachrymal sac, &c. the palpebræ frequently become oedematous in a high degree, but this is merely a temporary symptom, which disappears as the original disease subsides.

Causes. Inflammation of the eyelids may arise from various accidental injuries, as the stings of insects, contusions, &c.; it is sometimes connected with an unhealthy condition of the system, and occasionally supervenes without any assignable cause.

Treatment. Suppuration is a frequent result, and as ectropium and other unpleasant consequences may arise from the morbid changes which this termination induces, it is important to prevent its occurrence, or where this cannot be done, to limit its extent as much as possible. For this purpose, leeches, cold applications, and general remedies proportioned to the severity of the symptoms, will be proper in the first instance. If suppuration is threatened, it should be promoted by the usual means, and as soon as fluctuation can be felt, an opening must be made with the point of a lancet, parallel to the natural folds of the skin.

In simple oedema of the eyelids, a solution of the muriate of ammonia in water acidulated with vinegar, applied warm by means of a sponge, will accelerate its dispersion; and the same treatment is also useful in the ecchymosis following injuries.

Erysipelatous inflammation of the palpebræ, frequently occurs in conjunction with acute phlogosis of the lachrymal sac, and as a secondary affection caused by the extension of disease from the neighbouring parts, is of common occurrence; sometimes also, though rarely, it originates in the eyelids and is confined to them. The swelling is equally great as in the preceding variety, and presents a yellowish red, a bright scarlet, or a livid appearance; the patient complains less of pain than of a burning sensation, and vesicles frequently form on the inflamed surface. In severe cases, the inflammation

runs on to suppuration and sloughing of the cellular membrane,—an unfortunate result, the parts seldom regaining their natural pliancy and mobility. A purulent secretion takes place from the conjunctival lining, and disorganization of some of the appendages of the eye is not an unusual sequel.

The treatment must be conducted on the general principles applicable to erysipelas in other parts of the body;—emetics, cathartics, and venæsection, will be necessary to allay the constitutional disturbance, and must be employed according to circumstances, together with appropriate remedies for the relief of the local affection,—leeches, evaporating lotions, &c. &c.: when suppuration is threatened, it may sometimes be averted by an early incision through the integuments, and at a later period, the opening thus made, will afford a ready outlet to the pus, and disorganized cellular membrane. The matter in these cases evinces little disposition to approach the surface, and if the surgeon should delay interference till it have begun to acuminate, irretrievable mischief might be produced.

INFLAMMATION OF THE EDGES OF THE EYELIDS.

Inflammation of the palpebral margins, is known under the various appellations of ophthalmia tarsi, chronic inflammation of the eyelids, psorophthalmia, lippitudo, &c.; each of which is sometimes described as a distinct disease. In many instances,

the conjunctiva and meibomian glands are originally affected, and the inflammation subsequently extends to the neighbouring parts. The mucous lining is red and villous, the ciliary margins swollen, painful, and not unfrequently excoriated; there is more or less uneasiness on motion, intolerance of light, and a feeling as of some extraneous substance in the eye; a viscous puriform secretion concretes around the roots of the cilia during sleep, and agglutinates the lids, so as to render it difficult to open them in the morning; the complaint is also attended with a troublesome pruritus, and an increased secretion of tears. In some cases, the eyelids are swollen and inflamed, and the cheeks becoming excoriated by the acrid discharge, present an erysipelatous appearance; while in others, the extreme edges of the palpebræ appear to be chiefly involved; little pustules form and break, the bulbs of the cilia are at length implicated, and the inflammation is of a more indolent character, with less of swelling and redness, though the pruritus is frequently a prominent symptom. Lippitudo may be considered as the advanced stage of this affection; the ciliary margins are thickened, ulcerated, and slightly everted, so that the eye appears to be surrounded by a red circle; or else they are indurated and irregular. The eye is irritable, and subject to frequent attacks of inflammation; the patient is troubled with stillicidium; the cilia fall out, and the meibomian apertures are partially, or wholly obliterated.

ed;—when this occurs, the edges of the palpebræ becoming smooth and rounded, the complaint may be regarded as incurable; though even in this inveterate form, the situation of the patient may be rendered, by judicious treatment, much more comfortable than it would otherwise be.

Causes. This disease is generally the sequel of some other affection, measles, small pox, catarrhal ophthalmia, &c., &c.; it is more frequent in children than adults, and is very often found in connexion with the strumous diathesis. It is a common affection among the poor of our large cities, and is aggravated and protracted, by neglect of personal cleanliness.

Treatment. When the acute symptoms which are present in recent cases, have been removed by the employment of appropriate remedies,—the application of leeches where circumstances require the local abstraction of blood, warm saturnine or acetous fomentations, some mild ointment (R. No. 1,) applied along the edges of the lids at night, counter irritation, saline laxatives, &c.,—a stimulating treatment, varying in activity according to the degree of inflammation, and individual susceptibility, must be adopted. The ung. hydrargyri nitratis, the ointments of the white and red precipitate, of iodine, and of the nitras argenti; solutions of the nitrate of silver, the sulphates of copper and zinc, and the bichloride of mercury; the lunar caustic and sulphas cupri in substance, have all been employed with

greater or less advantage by different practitioners. Where the disease is of recent origin, the mildest remedies should be adopted in the first instance, and those of greater potency reserved for extreme or inveterate cases; it will likewise be proper to vary them occasionally, since otherwise the parts become habituated to their action. The best general plan, is to bathe the eyes frequently during the day with a sponge wrung out of warm vinegar and water, and to apply at night the citrine ointment, diluted according to circumstances. It should be gently rubbed into the margin of the lids, and the apertures of the meibomian ducts, care having been previously taken to remove all the encrusted matter; in very young children, the ointment may be conveniently applied during sleep, with the aid of a camels' hair pencil. Fomentations with warm milk, or with vinegar and water, will sometimes succeed in allaying the pruritus, which is often a very annoying symptom; and a piece of linen spread with the camphorated ointment (R. No. 2,) may be usefully employed during the night. In more aggravated cases, where the ciliary margins are thickened, ulcerated, and covered with encrustations, preventing the application of remedies to the immediate seat of the disease, Mr. LAWRENCE recommends the extraction of the cilia, but it can rarely be necessary to have recourse to such an operation; the indurated matter should be softened and removed by warm fomentations, or some slightly

stimulating and emollient cataplasm (R. Nos. 52, 53, 54,) and the citrine ointment applied as already indicated, or the morbid surface gently touched by a pencil of the nitrate of silver, at intervals of two or three days. The ung. hydrarg. ammoniat. (R. No. 13,) is said to be especially adapted to the disease as it appears in advanced life, and may sometimes be usefully combined with the acetate of copper, (R. No. 3.) Mr. TRAVERS speaks highly of the "golden ointment," the basis of which is the sulphuret of arsenic; and formulæ Nos. 4, 5, 6, 7, 8, and 9, may also be successfully employed in different cases.

As this affection in its chronic form, frequently occurs in debilitated constitutions, or is dependent upon a strumous diathesis, tonic remedies often constitute an important part of the treatment; and under such circumstances, the sulphate of quinine, the carbonate, or proto-sulphuret of iron, the tepid salt bath, a nutritious diet, &c., are eminently serviceable.

SYPHILITIC AFFECTIONS OF THE EYELIDS.

Syphilis sometimes attacks the palpebræ in the form of pustules, or chancre, and also of phagedenic ulceration, destroying in its progress the lids and neighbouring integuments. It generally accompanies or succeeds venereal affections in other parts of the body, and may be recognized by the

history of the case, and the peculiar appearance of the eruption, or ulcer. Instances are related, in which the chancre was confined to the conjunctiva, and occasioned so little irritation, that it was only discovered by accidentally examining the condition of that membrane. The phagedenic variety, is attended with severe pain and inflammation, and exhibits a sharp red margin, with foul, unequal surface. The same treatment is required as when the disease occurs in other situations; and in the species first mentioned, the exhibition of calomel and opium, or the blue pill, to the production of slight ptyalism, the fluid extract, or compound decoction of sarsaparilla, and in the chancreous form, the local application of the nitrate of silver, will prove serviceable. Whatever discrepancy of opinion may exist in regard to the necessity of mercury for the cure of syphilis, it is generally conceded that it is an useful auxiliary when the ulceration does not assume a phagedenic character, and in the present instance, the importance of the affected part, calls for the employment of all our resources.

CANCER OF THE EYELIDS.

Cancerous ulceration of the palpebræ is not of very frequent occurrence. It is usually seated on the lower lid, and commonly appears in the shape of a little indurated tubercle, slowly followed by

others, which unite to form a small group; the skin covering them, differing in few respects from its natural appearance. After these have existed for a period, varying in different cases, from several months to as many years, ulceration commences in the form of a slight abrasion or excoriation, accompanied by the discharge of a thin yellowish fluid, which concretes into an adherent scale upon the surface. Successive tubercles arise, and the ulceration, presenting a smooth red surface, and an irregular tuberculated margin, gradually spreads to the surrounding parts, destroying the palpebræ, and in some instances, completely denuding the eyeball. The progress of the disease is slow, and it may remain stationary for years; evincing, in some cases, a disposition to cicatrization, and even actual reparation. In its indolent stage, it is not attended with much suffering; but when the ulceration is more rapid, the pain is considerable, and is of a burning or aching character. The general health continues long unimpaired, and the lymphatic glands are not affected. When the ulceration has proceeded so far as to insulate the globe, it generally sloughs and collapses, and the patient eventually dies exhausted by the protracted irritation. The disease differs in several of the particulars above mentioned, from glandular carcinoma, and MR. LAWRENCE maintains that it is also different from lupus, to which it certainly bears a striking resemblance. MIDDLEMORE, who under the title of a "peculiar

ulceration of the eyelids," has described a disease similar to the foregoing, has also attempted to discriminate between it, and genuine cancer of that part, which according to him, originates in the sub-cutaneous cellular tissue, and is attended with lancinating pain, enlargement of the glands, and the other symptoms usually described as pathognomonic of the disease when it is situated elsewhere.

The causes of cancer are altogether unknown; it seldom occurs until after the middle period of life, and is often observed in persons whose health is otherwise unimpaired.

Treatment. In the present state of our knowledge, the early and complete removal of all the affected parts, affords the only hope of a radical cure. If this be precluded by the state of the patient, or the extent of the ulceration, all that art can do, will be to endeavour, by the internal administration of opium, the occasional application of leeches, and the employment of mild antiphlogistic and soothing remedies, to mitigate suffering which it cannot cure. Solutions of the nitrate of silver, and the chloride of soda, or the black wash, with the internal exhibition of the carbonate of iron, in some cases, seem to exert a favourable influence in retarding the progress of the malady. In performing an operation for its removal, it will be necessary, when any considerable portion of the palpebræ is destroyed, to remove the globe also.

CARBUNCLE.

Carbuncle of the eyelids is sometimes seen in persons of advanced life and impaired constitutions, and should be treated as when it occurs in other parts of the body, by an early incision, and stimulating dressings, in conjunction with appropriate general remedies. Much attention is often requisite to obviate the injurious consequences arising from the extensive destruction of the cellular membrane which it occasions.

HORDEOLUM,

Or styte, is a painful, furunculous swelling on the verge of the eyelids, slowly advancing to imperfect suppuration; it is commonly seated in the duct of a meibomian gland, but often also in the cellular membrane—a circumstance which may explain the diversity of pain exhibited in different cases. It is frequently attributable to gastric derangement, and is sometimes produced by a rich and irritating diet. The inflammation is usually attended with the formation of a slough, and as it naturally tends to suppuration, repellent applications are in general useless, if not positively injurious. The formation of matter should be promoted by fomentations, and maturing cataplasms,

(R. No. 52,) and when it has approached sufficiently near the surface, the abscess may be punctured with the point of a lancet, or, which is perhaps preferable, may be allowed to open of its own accord,—an event which, when already impending, may often be hastened by the application of the aluminous coagulum, (R. No. 55.) These little tumours sometimes form in succession for a considerable time, especially in strumous children, and persons afflicted with chronic ophthalmia of the lids or conjunctiva; and are exceedingly annoying;—the proper remedies are a spare diet, gentle aperients, and the ung. hydrarg. nitratis, or some other stimulating ointment, applied along the ciliary margins. The sulphate of quinine may be also beneficially employed under such circumstances. The styne sometimes suppurates very imperfectly, or exists as an indurated tubercle, which frequently inflames, and is productive of much inconvenience; such cases are best treated by stimulating dressings, and the repeated application of the nitrate of silver.

GRANDO. MILIUM. PHLYCTENULA. VERRUCA.

Grando is a little white, indurated tumour, and has just been adverted to, as a frequent result of an imperfectly suppurating hordeolum. Milia, which are generally seen in elderly persons, are

not dissimilar in appearance, and contain a soft caseous or adipose matter. They occasion little pain or inconvenience, and may be readily removed by means of a hook and scissors; or if preferred, the tumour may be punctured, its contents evacuated, and the nitrate of silver applied to the interior of the cyst. Phlyctenulæ are minute transparent vesicles which sometimes form along the edges of the lids; they rarely give rise to much uneasiness, and soon disappear spontaneously; if necessary, they may be punctured with the point of a needle, or excised with the scissors, and the wound afterwards touched with the lunar caustic. Verrucous excrescences are easily cured by excision, caustic, or ligature, according as they are large and sessile, or small and peduncular. When several form, they will sometimes disappear under the use of various stimulating or astringent solutions.

TUMOURS OF THE EYELIDS.

Tumours form in the cellular tissue which enters into the composition of the palpebræ, or grow from the tarsal cartilage; and are of various degrees of consistence,—solid, pulpy, melicerous, or gelatinous. The variety first mentioned, usually arises from local injury, and may often be dispersed by frictions with strong mercurial or iodine ointment. The common adipose tumour which is generally

located at some distance from the tarsal margin, the steatomatous, and the encysted tumour, for the most part, require excision; and the cyst may either be removed entire, or cut through the centre, and the divided halves withdrawn by the aid of the forceps. These morbid formations are usually situated exteriorly to the orbicularis, and where this is the case, the incision should be made through the integuments; the operation may in some instances, be facilitated by freely moving the tumour under the integuments for some days previously. The tarsal tumour is originally firm, but gradually softens to a gelatinous consistence; the integuments are moveable upon its surface, but the adventitious growth itself, is closely adherent to the cartilage, which is often absorbed to a considerable extent. Frictions with strong mercurial, or iodine ointment, or the liniment. hydrarg. comp. (R. No. 45,) may be tried during its formative stage, but if it continue to increase, it will be proper to evert the lids, and puncture the tumour, so as to permit its fluid contents to escape; in some cases, it may even be necessary to introduce the extremity of a probe, and endeavour to break down the soft vascular texture of which it occasionally consists; if fungus protrude through the wound, the morbid growth must be excised, and the part touched with the nitrate of silver. A small painful swelling, hard, round and moveable, sometimes forms on the tarsal cartilage, and is not unfre-

quently associated with a disordered condition of the digestive organs. It often subsides spontaneously when this is corrected, but its dispersion may be promoted by frictions with the liniment. hydrarg. comp. (R. No. 45,) or any other stimulating embrocation. In some cases, it may be necessary to have recourse to an operation.

NÆVI MATERNI.

Nævi materni are either venous or arterial; the latter of which, is distinguished by its elasticity, increased temperature, bright scarlet colour, and rapidity of growth. Surgical interference is, in general, unnecessary while the nævus is of small extent, since blemishes of this kind frequently either disappear spontaneously, or remain stationary through life. When however, the morbid growth is large, or evinces a disposition to increase, something must be done for its removal. In the early stage, vaccination will frequently be successful, or an eschar may be produced by the application of caustic. In other cases, the ligature or knife will be required. The tumour being raised by the fingers, a needle armed with a double ligature, is passed through its base from above downwards, and tied on either side, so as effectually to obstruct the circulation. MR. LAWRENCE states, that in one instance, the base was so large, he found

it necessary to tie it in three portions. Another method consists in introducing two needles at right angles through the tumour, and applying the ligature beneath. Where the knife is employed, it has been recommended, when the *nævus* is nourished by two or three vessels of considerable size, to take them up by a previous operation, with a view of diminishing the magnitude of the tumour.

ADHESION OF THE EYELIDS.

Of this affection there are two species—*anchyloblepharon*, or concretion of the tarsal margins, and *symbblepharon*, where the palpebræ are adherent to the globe;—they may exist either separately or combined. *Anchyloblepharon* is sometimes congenital, but both varieties are more frequently the result of inflammation following burns and other injuries; and the adhesion may be either immediate, or through the intervention of membranous bands. The first species when partial, rarely exists in such a degree as to require assistance, but should an operation be deemed necessary, the lids may be separated by an incision, care being taken not to injure the globe. When the adhesion is complete, the palpebræ should be raised in a vertical fold, a transverse opening made, sufficiently large to admit a director, and the incision continued to either angle. The utmost cau-

tion will be necessary to prevent the reunion of the divided edges. In symblepharon, when the adhesions are loose, of limited extent, and do not involve the cornea, a careful dissection will sometimes be successful; but where the patient enjoys the use of the other eye, it will be more prudent not to interfere. Reunion is still more liable to take place in this variety than in the other, and is best prevented by the frequent motion of the eye, and the occasional introduction of a little olive oil, or the end of a probe enveloped in some unctuous material,—the most persevering exertions, however, are often unsuccessful.

ECTROPIUM.

Ectropium consists in an eversion of the palpebræ, in consequence of which the lining membrane is exposed, the globe partially denuded, and great deformity produced. It is more common in the lower, than in the upper eyelid, and is not unfrequently a temporary attendant upon purulent ophthalmia, being occasioned by the excessive chemosis and swelling of the conjunctiva, which takes place in such cases. There are two varieties, one arising from thickening of the conjunctiva, and the other from cicatrices and various diseased conditions of the skin, or from abscesses situated in the cellular tissue of the lids, and the parts in

their immediate vicinity; it may also be caused by the accidental division of either canthus. The constant exposure of the eye to the action of light, and other external irritants, produces much uneasiness, and if timely measures be not adopted to remedy the evil, the cornea is rendered opaque and vascular, vision is greatly impaired,—in some instances entirely lost,—and the conjunctiva becomes changed in structure, callous, and indurated. The course of the lachrymal secretion towards the puncta, being interrupted, epiphora is an invariable attendant.

Treatment. In slight cases of ectropium, depending upon a morbid condition of the conjunctiva, the repeated application of the nitrate of silver or the sulphate of copper, with the intermediate use of the ung. hydrarg. nitrat. and some astringent solution, steadily employed for a considerable time, will generally affect a gradual improvement. If, however, these means should be insufficient, the thickened conjunctiva must be removed by excision with the curved scissors; or, if the knife be preferred, two semilunar incisions may be made, including the portion of membrane to be dissected off. After the operation, the lid, supported by a compress and bandage, resumes its natural position as the wound heals by the contraction of the granulations. In more aggravated cases, the excision of a triangular portion of the palpebral margin resembling the letter V, and the approximation of the

divided edges, has been recommended in addition to the removal of the indurated conjunctiva; and may occasionally prove useful, though the supposed elongation of the tarsal cartilage, on which it is predicated, should prove to be unfounded. In eversion from cicatrix or abscess, the cure is much more difficult, and sometimes altogether impracticable. Instances have occurred, however, in which adhesions connecting the upper eyelid with the orbit have been divided, the indurated cellular tissue removed, and the parts restored to their natural position, when success had been considered quite hopeless. If the ectropium have been caused by an accidental division of either commissure, the treatment will consist in abrading the separated edges, and retaining them in close apposition, by means of a suture.

The disease, even where it cannot be entirely cured, may be palliated by soothing applications, the use of gently stimulating ointments, and the employment of a shade to moderate the influence of external irritants,

ENTROPIUM.

Entropium is a much more formidable affection than the preceding; the constant friction of the inverted eyelid and cilia against the globe, quickly causing inflammation, and if not relieved, pan-niform opacity of the cornea, and total loss of

vision. As a mere temporary condition, it occurs in some cases of ophthalmia, the tumefied conjunctiva pressing out the orbital edge of the tarsus, while its ciliary margin is turned inwards by the action of the orbicularis, irritating the eye, and greatly aggravating the inflammation. When the disease is permanent, it sometimes arises from relaxation of the integuments, whether occurring spontaneously in advanced life, or from the injudicious employment of emollient applications. In other instances, it is seated in the tarsus, and appears as a sequel of inveterate psorophthalmia, or chronic catarrhal inflammation, ending in various morbid alterations in the texture or configuration of the palpebral margin. The upper and lower eyelid, are equally liable to be affected, and both may be inverted at the same time.

Treatment. The temporary inversion may be remedied by strips of adhesive plaster, applied perpendicularly to the lid, or by pressure properly directed to the orbital edge of the tarsus. When it depends upon relaxation of the integuments, an operation becomes necessary for the removal of the redundant portion; the quantity having been accurately determined by including with the entropium forceps, as much as may be necessary to produce the required degree of eversion, the excision is performed with the knife, or curved scissors; care being taken that the part to be removed, extend nearly the whole length of the eyelid. The

edges of the wound are afterwards brought together, and secured by two or more sutures. The actual and potential cauteries, sulphuric acid, &c., have been recommended as a substitute for the knife by English writers of high authority, but few surgeons in this country, would think of employing caustic in any of its forms, while the end could be so much better attained by other means.

If the margin of the eyelid be thickened, irregular, and permanently incurvated, the diseased part should be removed to the extent of one or two lines from its border, cautiously avoiding the punctum lachrymale; this is accomplished, by introducing a concave piece of horn beneath the lid, making an incision through the skin and orbicularis, and dissecting off the portion thus insulated, so as to include the capsules of the cilia, and leave the cartilage and mucous surface entire; or the operation may be simplified, by excising the ciliary margin with a single sweep of the knife. DR. DORSEY used to secure the eyelid by the hook or forceps, and cut away the incurvated part with the scissors or bistuory; but in many cases it is quite unnecessary to remove the tarsus. In some instances where the cartilage appears to be chiefly implicated, it may be preferable to divide it, by a perpendicular incision at each extremity, and afterwards to excise a portion of the integument as already described; or instead of the latter part of this operation, two or more ligatures might per-

haps be introduced through the skin near the edge of the lid, its margin drawn outwards, and retained in that position till the wound has nearly healed, by passing the ends beneath strips of adhesive plaster. It occasionally happens that entropium depends upon a contracted and thickened condition of the conjunctiva, and is cured by dividing the outer canthus so as to allow the complete eversion of the lid, making an incision through the conjunctiva, parallel to, and about three lines from the tarsal margin, and afterwards removing a fold of the integuments, as already mentioned.

TRICHIASIS. DISTICHIASIS.

Inversion of the cilia occasionally happens while the lid retains its natural position, and is generally partial,—a few eyelashes only, deviating from their natural position; instances however, have occurred, in which the entire series in the palpebræ of both eyes have been thus inverted. The disease is caused by the morbid changes consequent upon psorophthalmia, and injuries of various kinds; and though at first sight it may appear trivial, the constant friction of the cilia upon the globe, excites violent inflammation, and is capable of producing all the sad effects resulting from ectropium. Distichiasis rarely occurs in the form of a double row of cilia, but sometimes one or more eyelashes

grow in a wrong direction from the capsule. The erratic hairs are generally soft and white, and are liable to be overlooked on a superficial examination.

The palliative treatment consists in the eradication of the offending cilia, and it occasionally happens, that a permanent cure is thus accomplished; in some instances, it is necessary to repeat the operation every two or three weeks. When the irritation occasioned by the inverted hairs is very considerable, it may be proper to endeavour to prevent their regeneration, by puncturing the bulb, and touching the part with a pencil of the nitrate of silver. In complete trichiasis, accompanied by a morbid condition of the palpebral margin, the capsules of the cilia must be removed by the operation described under the head of ectropium.

LAGOPHTHALMUS.

When from any cause the palpebræ cannot be closed, the defect is termed lagophthalmus or hare eye. It is sometimes owing to spasmodic action of the levator muscle, and however produced, is attended with much inconvenience from the constant irritation to which the exposed organ is subjected. The worst cases of the disease, those arising from abscess of the lid, and the contraction of cicatrices, were alluded to under the head of ectro-

pium; but there is another variety depending upon paralysis of the orbicularis, induced by some affection of the facial nerve. It is accompanied with a similar condition of the other muscles of the face, and may commonly be traced to the operation of cold. Leeches, counter irritation by blister, moxa, or stimulating frictions in the neighbourhood of the stylo-mastoid foramen, and electricity, are the appropriate remedies. Measures should also be adopted to obviate the injurious consequences which may result from the constant exposure of the eye.

PTOSIS.

Ptosis may occur as an idiopathic disease, or as symptomatic of disorder of the brain, or intestinal irritation; and consists in an inability to elevate the upper eyelid, from relaxation of the integuments, weakness, or paralysis of the levator palpebræ: instances are likewise recorded in which it was congenital. When arising from relaxation and extension of the integuments, it may readily be distinguished by the circumstance that the muscle, though unequal to the task of elevating the lid with its additional weight, continues to exert its usual powers of contraction. In such cases, if the integument be thickened or enlarged, it will be proper to make trial of frictions with

iodine ointment, or the liniment. hydrarg. comp. (R. No. 45,) previously to resorting to any operation; but under other circumstances, it becomes necessary to remove a portion of the superfluous skin immediately above the orbital margin of the tarsus, as has been recommended for entropium. In ptosis from weakness or paralysis of the levator muscle, the treatment must be varied according to the cause upon which it depends. If symptoms of cerebral congestion are present, active depletion both general and local, with other appropriate remedies, will be required; but if otherwise, attention to the improvement of the general health, and of the digestive organs in particular, the shower bath, tonic medicines, stimulating embrocations before the ear, and above the eyebrow, (R. Nos. 46, 45, 48, 49, 50,) electricity, and counter irritation by blister, moxa, or seton, will prove serviceable. Paralysis of the levator muscle is occasionally seen in chlorosis, and occurs sometimes in the complicated forms of hysteria, strongly simulating organic affection of the brain; when this is the case, the treatment should be conducted with reference to the cure of the primary disease. It is not unfrequently periodical, arising probably from some derangement of the digestive organs.

DISEASES OF THE CONJUNCTIVA.

CONJUNCTIVITIS.

INFLAMMATION of the conjunctiva is a very frequent affection, both in its primary and secondary forms, for there are few inflammatory diseases of the other tissues of the eye, in which it is not also present in a greater or less degree. It occurs under several varieties, of which the principal are, acute conjunctivitis, or simple inflammation of the membrane; purulent conjunctivitis, or inflammation accompanied with the secretion of a puriform fluid; and strumous conjunctivitis, or inflammation modified by the scrophulous diathesis. There are also some other forms, to which the conjunctiva is subject from its connection with the cutaneous system.

SIMPLE ACUTE INFLAMMATION OF THE
CONJUNCTIVA.

Symptoms. Increased vascularity, pain, heat, a sensation as of sand or some extraneous substance in the eye, intolerance of light, and lachrymation, are symptoms by which, though one or more may occasionally be wanting, the disease is sufficiently characterized. The enlarged vessels

are first visible at the reflection of the conjunctiva upon the globe, and pursue a tortuous course, freely inosculating with each other, until their minute extremities finally disappear at the margin of the cornea. In some instances, the red vessels are so numerous as to impart to the eye an appearance of uniform vascularity; they even stand out in slight relief upon the surface, and may be observed to follow the motions of the conjunctiva, so that there can be little difficulty in determining the tissue in which they are seated. The pain varies in degree, in different cases, and is chiefly caused by the friction of the palpebræ upon the irregular and morbidly sensitive surface of the conjunctiva; small spots of extravasated blood are sometimes seen in the subjacent cellular tissue; there is an increased secretion of tears from sympathetic excitement of the lachrymal gland; and symptoms of constitutional disturbance are frequently present. In severe cases, other textures become involved; there may be extensive inflammation of the cellular membrane, with effusion of various kinds, constituting the phenomenon termed chemosis; or the inflammation may extend to the cornea, sclerotica and iris, accompanied by the characteristic indications of affection of those parts.

Diagnosis. Inflammation of the conjunctiva is distinguished from scleratitis, by the colour, situation, and arrangement of the injected vessels, together with the greater violence of the symp-

toms,—the pain, headache, and tension—which characterize the latter form of disease. In conjunctivitis, the redness exhibits a bright scarlet appearance, the vessels are movable and prominent, and are first visible at the angle of reflexion upon the globe; whereas in sclerotitis they have a pink, or purplish hue, are more deeply seated, and make their appearance near the margin of the cornea.

Causes. These are very numerous, and consist of chemical and mechanical irritants of every kind; exposure of the eyes to cold, intense light, or heat,—circumstances which more readily produce their effect, when favoured by the existence of any constitutional predisposition. Tumours situated near the margin of the palpebræ, sometimes give rise to an obstinate ophthalmia, when from their size and other circumstances, they might be deemed altogether inadequate to the production of such a result, not unfrequently also, the inflammation occurs without any assignable cause.

Treatment. The primary indication is the removal of the exciting cause, so far as it may be in our power; after which the inflammation will often spontaneously subside. Foreign bodies sometimes lodge beneath the upper lid, and may easily be detected by everting it over a probe, placed along the orbital margin of the tarsus. From neglect of this simple procedure, the cause is often permitted to operate undiscovered, aggravating the

inflammation, and prolonging the sufferings of the patient. Instances are recorded in which substances of considerable size, have remained for weeks, and even months, in the loose folds of the conjunctiva, producing comparatively little irritation when they are not carried over the globe by the motion of the lids. DR. MONTEATH removed a piece of wood, three quarters of an inch in length, and nearly as thick as a crow quill, from beneath the upper lid of a person who applied to him merely for the relief of a slight inflammation, induced by a fall among some bushes five months before; and similar cases are related by MR. LAWRENCE and others. A fungous condition of the conjunctiva, with more or less tumefaction of the palpebra, generally results from the protracted irritation thus occasioned, and where such a state of things exists, the part should be carefully examined with a probe. If the foreign body be small, and have penetrated entirely beneath the conjunctiva covering the globe, it may be removed by the forceps and curved scissors. Particles of iron impinging upon the anterior part of the eye, sometimes become fixed, and may be detached with the point of a cataract needle. Chemical irritants will generally have ceased to operate before assistance can be obtained, and attention must chiefly be directed to mitigate their effects. The eye should be frequently bathed in warm milk and water, and if any portion of the offending matter remain, it

may be expelled by the forcible injection of any mild fluid.

These preliminary measures having been adopted, if the inflammation do not now subside, the appropriate remedies for its reduction next require consideration. From whatever cause arising, soothing collyria, a light diet, and saline laxatives will always be proper, together with local and general depletion, as circumstances may demand. The quantity of blood drawn, must be regulated by the violence of the symptoms, and the constitution of the patient; as a general rule, it should be so considerable as to make a decided impression upon the system, and in urgent cases it may be necessary to re-open the vein after the lapse of a few hours. Local depletion is generally prescribed by the application of leeches to the lids, but the irritation which they excite, is frequently so considerable, as to render more than doubtful the propriety of this advice,—cupping from the temples or back of the neck, is at once a more expeditious, and a more effectual remedy, and may be advantageously employed instead. Emetics have also been recommended, but are indicated only when the inflammation either originates in, or is associated with, a disordered condition of the digestive organs.

Tepid fomentations are generally preferred in the commencement, and water acidulated with distilled vinegar, is one of the most useful. The mucil-

age of sassafras pith, and various anodyne decoctions, (R. Nos. 16, 17, 18,) may likewise be employed with more or less advantage,—the latter being especially adapted to cases attended with much pain and irritation. The palpebræ should be freely fomented with a soft sponge wrung out of either of these fluids, and they may also be applied to the surface of the conjunctiva by means of an eyeglass. The principal danger in all cases of conjunctivitis, arises from the chemotic swelling interrupting the circulation, and producing gangreen of the cornea, and where this occurs in any considerable degree, it will be necessary to scarify the tumefied membrane, and after the bleeding has ceased, to touch it lightly with a pencil of the nitrate of silver.

As the inflammation declines into what has been termed the sub-acute stage, some writers recommend the occasional scarification of the lid, or the application of leeches to its inner surface; but the irritation which such measures induce, generally aggravates the symptoms which they were intended to relieve. The continuance of the antiphlogistic treatment with an activity proportioned to the severity of the inflammation, is equally proper here, and will accomplish all that can be expected from the interposition of art.

When the violence of the disease has been subdued, and the inflammation, instead of disappearing, evinces a disposition to assume a chronic form,

advantage will be derived from the employment of local stimuli and astringents. A solution of two, three, or four grains of the nitrate of silver may be dropped into the eye morning and evening; and the collyrium of the bi-chloride of mercury, (R. No. 24,) or of the acetic acid, (R. No. 25,) employed in the interval. The proportion of the active ingredients in the formulæ last mentioned, may be varied according to the sensibility of the part, and the application should be made directly to the conjunctiva by means of an eyeglass. A solution of the sulphate of zinc, (R. No. 28,) copper, (R. No. 27,) alumine, (R. No. 29,) and the liquor of the sub-acetate of lead, or the vinum opii, diluted or otherwise, according to the stage of the inflammation, may be substituted for the nitrate of silver, but the latter will generally be found preferable except in trivial cases.

Counter irritation is too often indiscriminately employed at every period of conjunctivitis. Over the acute stage, it evinces little influence, and any advantage which has appeared to result from it, is more than counterbalanced by the pain and irritation which it occasions. When the complaint has assumed a chronic form, it is more generally beneficial, and a blister behind the ear, or on the back of the neck, is often an important auxiliary. In protracted cases, or where the inflammation is subject to frequent relapse, the more permanent mode of an issue or seton in the arm, may be preferable.

When the disease occurs in an individual of strumous constitution, or in an enfeebled condition of the system, after the active symptoms have been removed by the due employment of antiphlogistic remedies, tonic medicines, as the sulphate of quinine, &c. will frequently exert a favourable influence, and a similar course of treatment is also indicated in those cases, where, after the copious abstraction of blood, and the persevering employment of other debilitating measures, a congested state of the conjunctival vessels, is the only remaining symptom.

In ophthalmia of every kind, accompanied with intolerance of light, the patient should abstain from using his eyes, and keep them lightly shaded by a piece of linen or green silk.

CATARRHAL INFLAMMATION OF THE CONJUNCTIVA.

THIS form of conjunctival inflammation is marked by the same general symptoms as the preceding. In mild cases the disease is chiefly confined to the palpebræ, and circumference of the globe; but in its severer grades, the whole surface of the eye becomes highly injected, and the conjunctiva, elevated by effusion into the loose cellular tissue connecting it with the sclerotica, forms a circle around and overhanging the cornea. The

eyelids are swollen, there is more or less irritation of the tarsal margins, and a copious discharge of muco-purulent matter along with the tears. This mucous or puriform secretion, which is one of the most striking characteristics of the complaint, is at first thin and greyish, but in the progress of the disease, assumes a more decidedly purulent appearance, becoming thick, glutinous, and concretising on the edges of the palpebræ during sleep. The sensation as of the presence of some extraneous body, is frequently very distressing, but the intolerance of light is usually much less, in proportion to the vascularity, than in simple conjunctivitis. The disease is subject to exacerbations and remissions more or less strongly marked, and, not unfrequently, there is a considerable abatement of the symptoms during the night. The usual indications of catarrh are commonly present, with a degree of constitutional irritation corresponding to the severity of the local affection.

The general appearance of the inflamed organ, the catarrhal symptoms, and the mucous or puriform discharge, sufficiently distinguish this variety of inflammation from that which we have just considered. Some writers have attempted to lay down the marks which separate it from purulent ophthalmia, but the two diseases do not appear to differ in any very essential respect, and the one is probably only an aggravated form of the other.

Causes. Atmospheric vicissitudes,—whence it frequently appears as an epidemic,—exposure to the night air, and cold variously applied, are the ordinary causes of catarrhal ophthalmia. It is, consequently, most prevalent during the variable weather of autumn and spring, and is observed to spread through families and institutions, where many persons, particularly children, are congregated together. There is, also, reason to believe, that it is sometimes propagated by contagion.

Treatment. In mild cases venæsection is rarely required, and even local depletion may frequently be dispensed with. Gentle laxatives and saline diaphoretics during the day, the pediluvium and Dover's powder at night, with warm fomentations, and slightly astringent collyria, being, in general, all that is necessary. When the symptoms are more severe, and especially if there be any deeply seated or circum-orbital pain, general depletion will be demanded, and it will also be proper to abstract blood by cupping, from the temples, or back of the neck. Frequent fomentations with a sponge wrung out of hot vinegar and water, with the addition of the acetate of lead (R. No. 19,) or otherwise, and if there be much pain, one of the anodyne decoctions mentioned under the preceding head, (R. No. 16,) often exert a salutary effect. A handful of chamomile flowers enclosed in a flannel bag, steeped in hot water, and held before

the eye for a few minutes repeatedly through the day, is also a very convenient mode of applying warmth.

As soon as the purulent discharge is fairly established, a solution of two to four grains of the nitrate of silver, with the collyrium of the bi-chloride of mercury, (R. No. 24,) or of acetic acid, (R. No. 25,) may be employed as already described. When there is much pain and lachrymation, advantage will sometimes be derived from exposing the eye to the vapour arising from a mixture of camphor and laudanum, (R. No. 51,) elevated to a boiling temperature. Some mild ointment (R. Nos. 1, 10,) melted, and applied along the edges of the lids, previously well cleansed by a little warm water, is useful in preventing their adhesion during the night; after a few days the red precipitate, (R. No. 11,) or the diluted citrine ointment, (R. No. 12,) may be advantageously substituted. When the conjunctiva is swollen and elevated around the cornea, presenting the appearance termed chemosis, it must be treated as formerly directed; scarifications will be required when the danger is imminent, but in lesser degrees, it may be successfully treated, by touching the tumefied membrane with a camel's hair pencil dipped in a solution of ten grains of the nitrate of silver, or by the nitrate in substance; or the latter may be lightly drawn along the inner surface of the upper, or lower eyelid. The pain caused by this

application, is felt acutely for the moment, but it quickly subsides, and is followed, after its immediate effects are over, by a diminution of the inflammation and purulent discharge. The caustic may be again used, if necessary, after an interval of one or two days. This substance in pencil or solution, according to the indication to be fulfilled, is an invaluable remedy in many cases, and is by no means so extensively employed as its importance merits. After the fulness of the vascular system has been lessened, and the power of the circulation diminished by depletory measures, it appears to possess almost specific properties in abating the irritation of mucous membrane, and in the diseases of the conjunctiva especially, no single article is susceptible of such universal application.

The diet of the patient should be made to conform to the general indication of cure, and during the acute stage, should consist chiefly of warm diluting beverages.

The stimulating plan under various modifications, is adopted by numerous authors,—RIDGWAY, WATSON, MELIN, MACKENZIE, GUTHRIE, &c. The gentleman first mentioned, recommends a solution of the nitrate of silver, in the proportion of ten grains to the ounce, and MR. GUTHRIE an ointment of the same, (R. No. 6,) which however, is inferior to the article either in its fluid or solid form. On the other hand, it may be proper to state that MR. LAWRENCE, perhaps the highest authority in oph-

thalmic surgery, expresses his apprehensions of such powerful stimuli, and thinks that the question of their value is yet to be determined. He does not however, appear to speak from personal experience, and his observations have particular reference to the ointment of MR. GUTHRIE.

A morbid condition of the tarsal margins, and of the glandular structure of the palpebræ, sometimes remains as a sequel of catarrhal inflammation, and has been adverted to under the head of ophthalmia tarsi. In the early stage, emollient anodyne fomentations and cataplasms (R. Nos. 16, 19, 20, 21, 22, 52,) during the day, with a little red precipitate or citrine ointment applied along the edges of the lids at night, will prove very beneficial. In the advanced periods, recourse must be had to the more stimulating treatment recommended for the disease to which reference has just been made.

PURULENT OPHTHALMIA.

The extensive prevalence of this form of inflammation, its influence upon military operations in warm climates, and the dreadful ravages which it has occasionally produced, have long rendered it a prominent object of regard, and may require a separate notice of it here, though as has been already intimated, it appears to be merely an aggra-

vated form of catarrhal conjunctivitis. It is very common in warm countries, and prevailed extensively among the British and French troops employed in the Egyptian expedition. The hospitals of CHELSEA and KILMAINHAM, contained at one time two thousand three hundred and seventeen soldiers totally blind in consequence of this disease.

The symptoms vary in degree, from a slight affection of the palpebral lining, to inflammation of the most vehement character, involving the whole surface of the conjunctiva, the subjacent cellular tissue, extending to the denser textures beneath, and frequently followed by ulceration or sloughing of the cornea, and total disorganization of the eye. The disease is principally characterized by the profuse discharge of a viscous secretion, which soon becomes distinctly purulent; the eyelids are greatly swollen and distended, and when separated, exhibit an appearance of turgid and uniform vascularity. In severe cases, chemosis occurs in a high degree, the tumid conjunctiva almost burying the cornea beneath its folds, everting the lower lid, and even protruding from between the palpebræ. The pain, like the intolerance, varies according to circumstances;—when the inflammation is slight and affects principally the conjunctiva, it is inconsiderable, and the patient complains chiefly of a sensation as of particles of sand in the eye; but where the denser tissues become involved, it is often excruciating, especially around the orbit.

and has a deep, pulsative and aching character, subject to occasional exacerbations: it assumes sometimes the form of hemicrania, and is attended with an agonizing sense of tension, as though the eye would burst,—it is often very severe, immediately above the supra, or infra-orbitary foramen, and occasionally affects the whole head. The constitution early sympathizes with the local affection, fever ensues, sleep is prevented by the severity of the pain, and in many instances, the health is much impaired by the prolonged irritation. The disease evinces a strong disposition to relapse, and a granular condition of the palpebral lining, occasioned by the enlargement of the mucous glands, or some alteration in the texture of the membrane, is not an unfrequent sequel. When resolution does not take place, the inflammation may terminate in various morbid affections of the palpebræ; chronic ophthalmia, and vascular thickening of the conjunctiva; opacity, ulceration, sloughing, rupture or staphyloma of the cornea; prolapsus of the iris; or suppuration and collapse of the eyeball. Though always terrible in its aggravated form, it is much more so in persons of strumous constitutions than in others.

In regard to the prognosis, it may be stated in general terms, that when the chemosis is slight, the pain neither intense nor deeply seated, and the transparency of the cornea little impaired, there is reason to expect a favourable termination; but

where on the other hand, the tumefaction of the conjunctiva is so great as almost to conceal the cornea, and where this membrane presents a dull ashen hue, accompanied with severe, tensive and throbbing pain, the organ is in imminent danger of sloughing or suppuration.

Causes. Purulent ophthalmia is not an unfrequent occurrence in our own country, but its more extensive prevalence in warm latitudes, is owing to the greater intensity of light and heat, atmospherical vicissitudes,—which are more severely felt from the susceptible and debilitated condition of the cutaneous vessels,—and other circumstances connected with the soil or climate, inattention to cleanliness, &c., &c.; causes which induce a predisposition to disease of the dermoid and mucous tissues, and render the conjunctiva especially, liable to inflammation from accidental irritations. When once produced however, from whatever cause, there is abundant evidence that it is capable of propagating itself by contagion, and that it acquires additional virulence from a confined and vitiated atmosphere, unwholesome diet, &c. The testimony upon this point is conclusive, and is derived from direct experiment, accidental inoculation, and observation of its progress in camps, public institutions, &c.

The French slave ship *RODEUR*, affords a melancholy instance of the ravages of this ophthalmia, under circumstances propitious to its extension. The disease made its first appearance among the

slaves, one hundred and sixty in number, fifteen days after her departure from the coast of AFRICA; and subsequently spread among the crew,—one individual only escaping, and he was attacked shortly after their arrival at GUADALOUPE. Of twenty-five persons composing the crew, vision was destroyed in twelve, including the surgeon, five lost one eye, and four escaped with opacity of the cornea, and adhesion of the iris. Of the negroes who survived the voyage, thirty-nine were totally blind, twelve lost each an eye, and fourteen had corneal opacities.

Treatment. Two opposite modes of treating this disease, the antiphlogistic, and the stimulating, have been extensively practised; and opinion is still divided in regard to their relative value. This discrepancy however, is the result of a partial view of the subject, and it will be found in this case as in most others, that the exclusive advocates of each, are equally remote from the truth. The importance of the affected organ, and the rapid progress of the inflammation in its severer grades, call for all the resources of art, and experience evinces, what reason should have taught, that more is gained by a judicious combination of both methods, than from the unaided operation of either.

In robust and plethoric individuals, and generally in all cases attended with pain deeply seated or circum-orbital, headache, and a sense of tension and throbbing in the eye, venæsection will be re-

quired; and the quantity of blood abstracted, should be such as to produce a decided mitigation of the symptoms. But under other circumstances, as when the health is feeble, or the inflammation trivial and confined to the conjunctiva, bleeding, if practised at all, should be prescribed with a much more sparing hand. The treatment must be modified according to the symptoms of each particular case, and no rule can be laid down which shall supersede the exercise of a sound discretion. Repeated cupping from the temples and back of the neck, is highly useful when the occurrence of the pain just described, announces the extension of the inflammation to the fibrous tissues; and in this contingency, it will be proper to administer calomel to such an extent as slightly to affect the mouth. An active cathartic should always be given in the commencement, followed by saline laxatives through the whole course of the disease; and in severe cases, advantage may perhaps be derived from the use of colchicum, digitalis, and other remedies which appear to possess a controlling power over the circulation.

The plenitude of the vascular system having been diminished, and the urgency of the symptoms abated by these depletory measures, the local treatment becomes of primary importance. When the chemosis is so considerable as to give reason to apprehend sloughing of the cornea, it will be proper to divide the tumefied membrane by several deep

incisions; but, except under such circumstances, scarifications produce much pain and irritation, and had better be avoided. It is in this form of ophthalmia, that the nitrate of silver most remarkably displays its sanatory powers, and constitutes indeed our principal reliance. Applied in substance to the inner surface of the palpebræ, it diffuses its influence by continuous sympathy over the whole conjunctiva, while it also acts directly upon the opposing surface of the globe; and, in the severer grades of inflammation, is decidedly preferable to the forms of solution or ointment. The application may be repeated every one or two days, and a solution of the same substance employed occasionally in the interim. MR. WALKER has given an account of some cases in which it was applied to the inner surface of both lids, six or seven days in succession, and afterwards at longer intervals, until the morbid condition of the parts had disappeared; and, in a little work recently published, he states that he has since frequently employed it in all ages, and at every period of the inflammation, with the most gratifying result.

The nitrate of silver is also used by RIDGWAY, MELIN, MACKENZIE, and others. The gentleman last mentioned, prefers a solution of the strength of four grains, applied once or twice in the twenty-four hours. MR. GUTHRIE's ointment, (R. No. 6,) though so highly extolled by him, has not equalled the expectations which the present writer had been

led to entertain respecting it. It occasions more irritation than the caustic in substance or solution, is more variable in its effects, and should be restricted to chronic and torpid cases, attended with thickening of the conjunctiva and superficial opacity,—circumstances under which it often proves eminently serviceable.

DR. O'HALLORAN applies the sulphate of copper in substance to the palpebral lining, or drops into the eye, a solution of ten grains of the nitrate of silver. He has treated several hundred cases in this way, with the greatest success, and his testimony is the more valuable, inasmuch as he was induced to adopt it from the repeated failure of the antiphlogistic system.

A variety of stimulating applications have been recommended by different writers; such as the undiluted liquor plumbi sub-acetatis (VETCH,) the oleum terebinthinæ (BRIGGS,) and the undiluted sulphuric acid (MUELLER;) but any good effect which these, or similar articles, are capable of producing, is more certainly derived from the nitrate of silver.

M. SONTY states, in a recent communication to the French minister of Marine, that he has derived the greatest advantage from the aluminous coagulum (R. No. 30,) enclosed in a fine muslin bag, and a few drops of the liquid instilled into the eye repeatedly through the day—in some cases every half hour. He adopts this treatment in all stages

of the disease, and according to his statement generally accomplishes a cure in twenty-four or forty-eight hours.

Among the auxiliary remedies, including the local abstraction of blood by cupping, and counter irritation by blister to the neck, may be briefly mentioned, refrigerating lotions (R. Nos. 24, 25,) employed as recommended under the head of simple conjunctivitis, and the ung. hydrargyri nitratis (R. No. 12,) or the red precipitate ointment, (R. No. 11,) applied along the edges of the lids at night.

In protracted cases, and where the disease occurs in debilitated and strumous constitutions, tonic medicines,—quinine, iron, &c.,—may sometimes be advantageously exhibited; and the same treatment, in conjunction with the local application of the nitrate of silver, is also required in sloughing of the cornea. When suppuration of the eyeball takes place, it may be proper in some cases, to puncture the cornea, in order to relieve the agonizing pain and tension, attendant upon this unfortunate termination.

PURULENT OPHTHALMIA OF INFANTS.

THE purulent ophthalmia of infants generally makes its appearance a few days after birth, and is essentially the same with the disease just described. It arises in most instances, from the contact of

the vaginal secretion during parturition, but it may also be produced by the action of light, heat, and other irritants, upon the delicate organs of a newly born child. In its severer forms, it is attended with a copious secretion of thick, puriform matter, frequently mixed with blood, extreme vascularity of the conjunctiva, chemosis, dulness of the cornea, intolerance of light, tumefaction of the palpebræ, &c. &c. The disease generally commences in one eye, and after a few days attacks the other, but not unfrequently both are affected simultaneously.

When properly treated from the beginning, the prognosis is generally favourable, the symptoms yielding readily to appropriate remedies; but under other circumstances, or where the inflammation assumes a more aggravated character, accompanied with great tumefaction of the lids, and chemotic swelling of the conjunctiva, there is reason to apprehend loss of vision by some of the terminations already mentioned. Opacity of the cornea from thickening of its conjunctival covering, or lymphatic deposition between the proper laminae of that membrane, is not an uncommon sequel; but in many instances, owing to the comparative looseness of its texture in early life, and the recuperative energies of youth, the effused matter is absorbed before it has had time to become organized, and vision is restored in cases where, from the extent of the opacity, recovery may have appeared quite hopeless.

Treatment. In slight cases, where the inflammation is chiefly confined to the palpebræ, it will be sufficient to wash the eye frequently with tepid water, to drop into it a weak solution of the nitrate of silver, or the sulphate of alumine, once or twice a day, and to apply a little mild, (R. Nos. 1, 10,) red precipitate, (R. No. 11,) or dilute citrine, ointment, (R. No. 12,) along the edges of the lids at night. When the symptoms are more violent, the eyelids much swollen and inflamed, and the disease, having extended to the conjunctiva covering the globe, assumes a more formidable aspect, it will be proper to abstract blood by scarification, or the application of one or two leeches to the upper eyelid, or root of the nose. The former mode is perhaps preferable; one gentle stroke of the lancet along the turgid lining of the inferior palpebra, is all that is required, and the eversion should be continued for a few minutes, in order to promote the discharge from the divided vessels. When leeches are employed, care is necessary lest, from the extreme vascularity in these little patients, the punctures bleed too freely. The conjunctiva should be frequently cleansed, by injecting over its surface some mild astringent collyrium, (R. Nos. 24, 25,) or a weak solution of alum; and the solution of the nitrate of silver, in the strength of two to four grains, dropped into the eye morning and evening. Advantage will also be derived from the use of aperient medicines.

The aluminous coagulum employed as under the preceding head, will probably be found an useful addition to our remedies for this disease.

MACKENZIE prescribes the collyrium of the bichloride of mercury (R. No. 24,) three or four times in the twenty-four hours, and a solution of the nitras argenti, or sulphas cupri, in the proportion of four grains of the one and six of the other, applied by means of a camel's hair pencil, once or twice daily to the whole surface of the inflamed conjunctiva. When the puriform discharge is established, and there is reason, from the severity of the symptoms, to apprehend injury to the cornea, MR. WALKER employs the nitrate in substance, and states that he has used it as frequently, and continued it as long, in these cases as in others, and with the like beneficial result. MR. GUTHRIE recommends the same article in form of ointment (R. No. 6,) applied to the inner surface of the palpebræ.

A lotion composed of the sulphate of zinc, and sub-acetate of lead (R. No. 36,) SCHMIDT; a strong solution of the sulphate of zinc, SAUNDERS, WISHART, BLUNDELL; the undiluted liquor plumbi sub-acetatis, VETCH; the wine of opium, BENEDICT; the sulphas cupri in substance, ARMSTRONG; and the insufflation of calomel, DUPUYTREN, have also been employed in the treatment of this ophthalmia.

Messrs. LAWRENCE and MIDDLEMORE likewise

recommend astringents, but not until the violence of the inflammation has been subdued by the antiphlogistic treatment,—a result which too frequently is not attained, until vision is irretrievably destroyed. By MONTEATH and others, counter irritation on the middle and posterior part of the scalp, or behind the ears, is mentioned in terms of high commendation; but the application of blisters is not unattended with danger, and unless the necessity be urgent, had better be avoided.

If a slough unfortunately form upon the cornea, the sulphate of quinine should be exhibited in quantity of half a grain, four or five times a day; and in some cases where the inflammation has proceeded to suppuration of the eyeball, it may be proper to relieve the sufferings of the little patient, by giving exit to the matter through an artificial opening.

GONORRHŒAL OPHTHALMIA.

By most writers gonorrhœal ophthalmia is described at great length, as a distinct variety of inflammation, but the diagnostic symptoms are by no means strongly marked, and with the exception of its cause, and the extreme vehemence of its attack, it does not appear to differ very materially from the severer grades of purulent conjunctivitis. Its existence may be suspected from its

sporadic occurrence, the violence of its onset, the extraordinary rapidity of its progress, its general limitation to one eye, the tumefaction of the lids, excessive chemosis, and the profuse puriform secretion, by which it is accompanied; but the history of the case will furnish the only certain diagnosis. It seldom attacks both eyes at once, and the one last in the order of time, is probably affected by the morbid secretion from the other.

The disease arises from the direct application of gonorrhœal or leucorrhœal matter to the eye, and the consequences of the resulting inflammation are equally serious as in the most aggravated cases of purulent ophthalmia. It is singularly violent and destructive,—generally terminating, despite the most judicious measures, in ulceration sloughing or opacity of the cornea, synechia anterior, or supuration and collapse of the globe; and is so rapid in its progress, that vision is often irretrievably lost before application is made for surgical assistance. All the symptoms of vascular congestion are present in an intense degree, attended with agonizing pain and tension, hemicrania, intolerance of light, and severe constitutional disturbance. Some idea of the severity of this inflammation may be conceived, when it is stated, that of fourteen cases related by MR. LAWRENCE, vision was entirely destroyed in nine, and in three of the remaining five, there was partial opacity of the cornea, and anterior adhesion of the iris.

The treatment is the same as that recommended for purulent ophthalmia, and no time should be lost in carrying it into full operation. General and local depletion to an extent commensurate with the urgency of the symptoms, active purgatives, free scarifications of the tumefied conjunctiva, and other auxiliary remedies, are proper in every instance; but the nitrate of silver is our principal reliance, and should be applied in substance to the chemotic swelling, and to the inner surface of the palpebræ. Even MR. LAWRENCE, though he recommends the freest adoption of antiphlogistic measures, is constrained by the repeated instances of their failure, and the melancholy ravages of the disease, to assent to the employment of this remedy. MR. MIDDLEMORE objects to the use of strong local stimuli in the commencement, but when the acute symptoms have been decidedly diminished by bleeding and other means, the discharge lessened, and the florid vascularity of the conjunctiva is superseded by a pale flabby appearance of that membrane, he recommends the nitrate, either in the form of ointment or strong solution. In many cases however, such delay would be ruinous, and after one large bleeding, cupping from the back of the neck, free scarifications, and the operation of a brisk cathartic,—remedies which may be employed in rapid succession—recourse should at once be had to the caustic.

BARON DUPUYTREN strongly advises the insuffla-

tion of calomel, once or twice a day, and the liquid laudanum of SYDENHAM dropped into the eye at night.

STRUMOUS OPHTHALMIA.

Conjunctivitis modified by the scrophulous diathesis, is a very common affection in some countries; where it is even stated, that nine-tenths of the cases which occur in early life, are of this description. It is particularly prevalent in Great Britain, and the northern parts of Germany and France, but is much less frequent in the United States; though among the poorer inhabitants of our large cities it is by no means uncommon. Though often observed in maturer age, it is properly a disease of childhood, and is usually met with from the first, to the eighth or tenth year. It is said not to attack infants at the breast, and this is perhaps true under ordinary circumstances, but the statement requires some qualification, since it is not of rare occurrence in feeble unhealthy children, where the process of lactation has been prolonged beyond the customary period. Strumous ophthalmia appears under a variety of forms,—chronic conjunctivitis alone, or combined with pustules, opacity, or ulceration of the cornea; and inflammation with pustules and excoriation of the ciliary margin. It sometimes co-exists, or alternates, with scrophulous affection

in other parts of the body, and the morbid diathesis in which it appears, exerts a modifying influence over inflammation arising from any accidental cause.

Symptoms. Strumous ophthalmia is chiefly characterized by the trivial pain and redness, the extreme intolerance, profuse lachrymation, and the spasmodic contraction of the orbicularis, with which it is accompanied. The appearance of small pustules, pimples, or phlyctenulæ, on different parts of the conjunctiva, particularly around the cornea, is also a very common symptom, and is described by some writers as constituting a distinct variety. The sensibility to light is sufficiently remarkable to form a distinguishing sign of the disease; being often so intolerable, that the child will forego all his amusements, confine himself to the darkest part of the room, or bury his face in the bed clothes, in order to avoid its disagreeable impression. Any attempt to examine the eyes is attended with spasm of the orbicularis, sneezing, and a copious discharge of tears. In protracted cases, the cilia are longer and more numerous than natural, and the habitual exertion to shield the suffering organ, imparts to the patient a peculiar expression, which is almost pathognomonic of this form of ophthalmia. This excessive intolerance is sometimes absent in the pustular variety; and in many instances it exists almost alone, or is accompanied with very slight vascu-

larity: it is quite independent of any affection of the retina,—vision, except in so far as it may be affected by the opacity of the cornea, being unimpaired in the shade, and in the dusk of evening. The redness is rarely proportionate to the other symptoms, and is more frequently fascicular than diffuse; in the former case, a minute pustule or pimple, is commonly observed at the termination of each plexus of vessels. The edges of the palpebræ are often inflamed, ulcerated, and the seat of a troublesome pruritus; and excoriations about the nostrils, discharges from the nasal and auditory passages, eruptions on the head and face, glandular enlargements, &c., are likewise occasionally present. The usual indications of gastric or intestinal irritation, exist in many cases to a greater or less degree, and the disease is extremely liable to sudden change and relapse from slight causes.

Though slower in its progress, the ultimate consequences of strumous ophthalmia, are frequently not less serious than those resulting from some of the other forms of conjunctivitis; for like them it may, involve the more deeply seated tissues, and terminate in ulceration of the cornea, opacity from pustule thickening or interstitial deposition, adhesion of the iris, staphyloma, &c.

Causes. Strumous ophthalmia may be excited, in persons possessing this morbid peculiarity of constitution, by exposure to the ordinary causes of simple conjunctivitis; dentition; or by any gas-

tric, or intestinal irritation. It is especially liable to occur in debilitated states of the system, and is a frequent sequel of the various exanthemata,—small pox, measles, scarlatina, &c.

Treatment. This variety of inflammation is almost invariably connected with an atonic, or irritable condition of the system, and the constitutional treatment is therefore of paramount importance. When there is any derangement of the chylipoietic viscera, an emetic may be premised, and followed by one or more active cathartics; much attention to the condition of these organs, will be required through the whole progress of the disease, and mild aperients,—rhubarb variously combined with the bi-tartrate of potash, soda, aloes, or magnesia;—the blue mass, or the hydrargyrus cum creta; and anthelmintics, where there is reason to suspect the presence of worms, may often be usefully employed. In some instances, the occasional exhibition of more active purgatives will be necessary. A light nutritious diet, regular exercise in the open air, the tepid salt or shower bath, frictions over the body with the flesh brush or a coarse towel, diaphoretics, and whatever has a tendency to promote the cutaneous functions and invigorate the system, will also exert a beneficial influence. The sulphate of quinine is an important remedy, and often displays a striking power over the disease, allaying the morbid sensibility, and removing the inflammatory symptoms in a very remark-

able manner. It may be exhibited in any convenient form, and in quantity varying according to the age of the patient, and the urgency of the symptoms. To a child one or two years old, half a grain to a grain may be given three or four times a day. In conjunction with the sulphate of iron, the syrup of orange peel, and a few drops of sulphuric acid, it forms an elegant prescription. For persons of more advanced age, or where a treatment more decidedly tonic is demanded, it may be also advantageously combined with columbo, and the precipitated carbonate, or the proto-sulphuret of iron; and it is in this combination, that it will generally be found most serviceable. Iodine, the diluted sulphuric acid, and the liquor potassæ, have also been recommended; the article first mentioned, is occasionally employed with good effect when there are scrophulous tumours in other parts of the body, and the two last may sometimes be usefully prescribed in cases attended with anorexia, and an irritable condition of the system, but as a general remedy they are all greatly inferior to the sulphate of quinine. During the occasional exacerbations and relapses of the disease, and in all cases where any active congestion is present, cupping from the temples or back of the neck is indicated, and may be directed concurrently with the use of the other remedies, or if it be deemed expedient, these may be suspended till the acute symptoms have been subdued. Warm applications are usual-

ly most grateful to the feelings of the patient, and the acetic acid combined with the acetate of lead (R. No. 19,) or with spirits of wine (R. No. 23,) will generally answer the purpose very well. When the intolerance and spasms are severe, hot anodyne fomentations (R. Nos. 16, 17, 18, 20, 21, 22,) and the exposure of the eyes to the vapour arising from camphor mixture with laudanum, (R. No. 51,) frequently afford relief. The fomentations should be made with a sponge wrung out of the hot liquid, or with the bag of chamomile flowers, as directed under the head of catarrhal ophthalmia. In these circumstances also, PROFESSOR KOREFF recommends a saturated solution of borax, applied by means of a compress, and the utility of his suggestion is confirmed by the authority of MIDDLEMORE. BARON DUPUYTREN appears to have relied chiefly on the internal administration of belladonna, in quantity of three, eight, or twelve grains of the powder, or three or more of the extract, given in divided doses every two hours. A collyrium of two to four grains of the nitrate of silver, dropped into the eye once or twice a day, has a decided effect in mitigating the irritability and other unpleasant symptoms; and may also be usefully employed where pustules or phlyctenulæ are present. In the more indolent stage in which ulceration commonly appears, a stronger solution will be required, and should be applied by means of a camel's hair pencil; or the ulcer may be lightly touched by a

finely pointed pencil of the caustic. Under these latter circumstances, iodine is sometimes recommended, and formula No. 31, is appended on the authority of M. BERMOND. In chronic cases, where the inflammation affects also the palpebral margins, advantage will frequently be derived from the stimulating cataplasm (R. No. 52.) When vascular congestion is the prominent symptom, the vinum opii diluted or otherwise, is an excellent remedy, and the ung. hydrarg. nitratis (R. No. 12,) or the ointment of red precipitate (R. No. 11,) may likewise be beneficially applied at night to the edges of the eyelids.

Counter irritation by blister, seton, &c., is more serviceable in strumous ophthalmia, than in most other forms of conjunctivitis. In recent cases, and where the constitution is not very irritable, a blister may be applied to the back of the neck, or behind the ear; but when the complaint is protracted, or subject to frequent relapse, the more permanent form of a seton or issue in the arm, will generally be found preferable.

If, as it sometimes happens, the inflammation should continue to advance uninfluenced by the means employed to arrest its progress, threatening to penetrate the cornea and involve the deeper tissues of the eye, recourse must be had to the internal exhibition of mercury; but much caution is requisite in the employment of this article in strumous constitutions.

It has already been stated that this form of ophthalmia is extremely variable in its progress, and subject to frequent exacerbations and relapses, from atmospherical vicissitudes, irregularities in diet, &c.; the knowledge of these circumstances will prevent the too early relinquishment of remedies, and indicates the necessity of strict precautionary measures during the period of convalescence. The atony and congestion of the capillary vessels which characterize strumous conjunctivitis, are frequently mistaken for indications of increased action, and it is melancholy to witness the privation and suffering which are sometimes inflicted under this erroneous view, often aggravating the disease, and impairing still further an already enfeebled or depraved constitution. There is at no time, any necessity for confining the patient to a darkened apartment, or for having the eyes closely covered, a light shade of green silk affording quite sufficient protection.

VARIOLOUS OPHTHALMIA.

The conjunctiva, though it differs materially from the cutis in its anatomical structure, yet being continuous with that membrane, participates in its diseases, and is especially liable to become inflamed in the various exanthemata. Unpleasant consequences often follow the variolous eruption, even

when it does not extend beyond the palpebræ, but the formation of a pustule on the cornea during the prevalence of the general symptoms, is a much more unfortunate occurrence. It appears at first in the shape of a small white point surrounded by an opaque halo, which gradually spreads until it involves the whole surface of the membrane. Owing to the turgidity of the lids, and the violence of the constitutional disorder, the condition of the organ is sometimes not discovered until the mischief is irremediable; and so destructive is the inflammation, that even in cases where the most judicious measures have been employed from the commencement, vision is frequently lost or impaired by ulceration or opacity.

The treatment must be conducted, as far as practicable, on the general principles of ophthalmia, and in addition to the appropriate remedies for the constitutional affection, cupping from the temples, warm fomentations (R. No. 19,) and a weak solution of the nitrate of silver, are the remedies principally entitled to confidence. When the pustule has burst, advantage will often be derived from touching its ragged ulcerated surface by the nitrate in substance.

There is also a secondary form of this disease, which makes its attack several weeks after the eruption has disappeared, and though less dangerous than the preceding, is often extremely intractable. The lateness of the period at which

the pustule makes its appearance, may perhaps be explained on the supposition that its development has been retarded by the slight vascularity of the corneal conjunctiva. The inflammation in this variety is usually modified by the strumous diathesis, which has been called into action by the variolous affection; and as it generally occurs in debilitated states of the system, is most successfully treated by remedies which tend to invigorate the constitution. The local abstraction of blood, and the exhibition of purgatives will always be proper in the incipient stage, but after the active symptoms have been removed, the sulphate of quinine should be administered, either alone, or in combination with other tonics. The *vinum opii*, and the solution of the nitrate of silver, are the best local applications.

The inflammation which accompanies measles and scarlatina, is more commonly purulent than pustular, and requires no particular treatment; the palpebræ may be frequently bathed with warm vinegar and water, some mild ointment (R. Nos. 1, 10,) applied at night to the ciliary margins, and if the discharge be considerable, a solution of the nitrate of silver, or the sulphate of zinc instilled occasionally into the eye. The several forms in which strumous ophthalmia appears, are not unfrequent sequelæ of these eruptions.

GRANULAR CONJUNCTIVA.

A change of structure in the mucous lining of the palpebræ, is a very frequent consequence of obstinate or neglected purulent ophthalmia, and sometimes exists unsuspected, occasioning by its constant friction upon the globe, an inflammation intractable in its character, and terminating in thickening vascularity and opacity of the conjunctiva, or ulceration and staphyloma of the cornea. This morbid alteration occurs under a variety of forms, and in different degrees, from a slight inequality and thickening of the part, to the production of fungous excrescences of considerable magnitude. On everting the lids, their inner surface as far as the orbital edge of the tarsus, is sometimes observed to be thickly studded with granulations, and its continuation towards the globe presents a swollen, angry, and livid appearance. It is most strongly developed in the upper eyelid, and appears to consist in an entire change in the structure of the membrane, which exhibits an uniformly diseased surface, scabrous, irregular, and occasionally breaking into chaps or fissures. In other cases, the conjunctiva is more or less densely covered with little vascular projections, which are soft and bleed freely when lacerated, but acquire greater firmness after they have existed for some time. These various changes in the interior surfaces of

the lids, destroying their exquisite smoothness and nice adaptation to the globe, depend upon several pathological alterations;—in some instances, it consists either wholly or in part, of an enlargement of the acini of the mucous follicles, which not only exist in greatest numbers in that portion of the membrane covering the tarsal cartilage, but are also rendered more conspicuous there, by reason of the hard unyielding plane on which they are situated; and in others, of a vascular growth from the surface of the inflamed conjunctiva, or of lymphatic deposition within its texture.

Treatment. When the granulations are large, prominent, or peduncular, they may be excised by the scalpel or curved scissors, and their reproduction prevented by touching the diseased surface with the nitrate of silver or the sulphate of copper. Where however, the morbid deviation is less extensive, the cure may be readily accomplished by measures of a milder character. If the conjunctiva be tumid and loaded with blood, repeated scarifications of the lower eyelid, and the intermediate employment of some astringent collyrium, as the solutions of the nitrate of silver, the sulphates of copper, zinc, and alumine, the undiluted liquor plumbi sub-acetatis, or the albuminous solution of alum, (R. No. 30,) will frequently prove useful, and in trivial cases may be sufficient to cure the disease; but in general, it will be better to have recourse at once to the lunar caustic, or sulphas

cupri in substance. The mode of application is as follows:—the upper lid being everted over a probe, a pencil of the nitrate is lightly drawn across its surface, and the part bathed with a soft sponge wrung out of warm water, before it is allowed to resume its contact with the globe; if the sulphate of copper be preferred, a smooth crystal fixed in the end of a quill, should be gently rubbed over the membrane, in order to ensure its partial solution in the moisture by which it is covered. The operation should be repeated as soon as the irritation has subsided, and some mild astringent collyrium may be employed in the interim.

As the morbid condition of the palpebræ is removed, the ophthalmia subsides, and the conjunctiva gradually resumes its ordinary smooth and polished appearance. The disease occurs not unfrequently in connection with the strumous diathesis, and is sometimes attended with a febrile state of the system, or a disordered condition of the digestive organs; and in such cases the improvement of the general health is an indication of primary importance. A case recently came under the observation of the author, in which the irritation produced by the friction of the granulated lids upon the globe, had excited violent inflammation of a purulent character, the conjunctiva covering the cornea was vascular and opaque, resembling a mere congeries of red vessels, and so much thickened by interstitial deposition as even to pre-

sent a staphylomatous appearance; the iris and pupil were quite invisible, the health of the patient greatly impaired, and so aggravated were the symptoms, that during a period of several weeks, he was unable to distinguish light from darkness. Notwithstanding the unpromising aspect of the case, it was successfully treated, and the transparency of the parts completely restored, by scarifications, and the repeated application of the solid nitrate of silver to the inner surface of the eyelids, in conjunction with appropriate general remedies;—subsequently crystals of the sulphate of copper, and various stimulating solutions and unguents, were employed with advantage.

A similar condition of the sclerotic and corneal conjunctiva, is sometimes produced by the incurvation of the tarsal cartilage, inverted cilia, or any other source of protracted external irritation; in such cases, after the removal of the cause, by means which have been already described, the cornea, unless its texture has become consolidated through the long continuance of the inflammation, tends spontaneously to recover its transparency. The various stimulating solutions mentioned above, will prove equally useful here, and in many instances, the collyrium of the muriate of copper (R. No. 32,) used with an eyeglass, may be employed with much advantage. The ointment of the nitrate of silver, varying in strength according to the susceptibility of the part, is one of the most efficient

remedies. It should not be prescribed during the existence of any active inflammation, and the surgeon will be guided in its repetition by the effects of the previous application. Excision of a portion of the enlarged vessels may perhaps be expedient in some cases, where they are distinct and prominent, but this is at best a doubtful measure, and is not unfrequently productive of violent irritation.

Vessels circulating red blood sometimes appear on the cornea, and are generally seated either in its conjunctival covering, or in the subjacent cellular tissue. They are usually connected with ulcer, albugo, strumous corneitis, or the morbid conditions which have just been described, and frequently remain long after the original cause has ceased to operate. The treatment consists in the employment of various local stimuli, as the solutions of silver, copper, and zinc, the liquor plumbi sub-acetatis, the albuminous solution of alum, and the ointment of the nitrate of silver. Where there are only a few large vessels, and particularly when they pass to an albugo or leucoma, it may be proper to raise them with the forceps, and excise a portion of the entire tube. Vascular albugo is commonly observed in strumous unhealthy children, and is most successfully treated by the internal exhibition of the sulphate of quinine, in conjunction with local stimulants or astringents.

ULCER OF THE CONJUNCTIVA.

Ulceration of the cornea has been often mentioned as a consequence of the several varieties of inflammation, simple, strumous, &c.; it is particularly common in the mixed form of catarrho-rheumatic ophthalmia, and appears to be frequently nothing more than an abrasion or excoriation of its conjunctival covering. The ulcer is not usually followed by any considerable degree of opacity, though in a few instances a slight cloudiness may remain for some time after it has healed.

These superficial ulcerations are generally cured without difficulty, as the vascular excitement which produced them is removed by the employment of the appropriate remedies. When they are connected with an indolent condition of the vessels, a solution of the nitrate of silver, varying in strength according to the irritability of the part, and the internal exhibition of the sulphate of quinine, or some other tonic, will prove serviceable. In some instances it may be expedient to vary the application, and the solution of the sulphate of copper or zinc, may be substituted with advantage. The caustic in substance is rarely required, and much harm has been produced by its indiscriminate employment.

PTERYGIUM.

Pterygium is usually described as a vascular thickening of the conjunctiva, but according to MIDDLEMORE, it is a morbid growth or deposition in the subjacent cellular tissue, which acquires a flattened form in consequence of the pressure to which it is subjected from the action of the palpebræ; the attenuated conjunctiva being reflected over it, much in the same manner as the viscera are enclosed in the folds of the pleura or peritoneum. The edges of the adventitious production consequently remain unattached, and its connection with the globe is determined by the reflexion of the conjunctiva. It usually grows from the internal canthus, and gradually becomes narrower as it approaches the cornea, where the diminished vascularity or increased density of the conjunctiva, and its more intimate connection with the parts beneath, interpose greater resistance to its extension, and cause it to assume a triangular shape. It is loosely attached to the eyeball, and may easily be raised by the forceps—circumstances which are satisfactorily explained by the view just given of its pathology. There are several varieties,—the membranous, the fleshy, and the adipose pterygium; and occasionally it happens that two or three appear in the same eye. The disease is comparatively rapid in its growth, until it reaches the

cornea, after which its progress is more gradual; and is unattended with pain, or any inconvenience, other than what results from its size and encroachment upon the cornea, obstructing vision.

Causes. Pterygium sometimes occurs as a sequel of inflammation, but more commonly without any assignable cause; by some writers it is attributed to long continued irritation from minute particles of lime or dust, in those whose occupations expose them to the action of such irritants; it is most frequent in advanced life, but is not unusual in childhood, and has appeared even in infancy.

Treatment. So long as the disease is confined to the sclerotica, it is, in general, unnecessary to interfere further than to restrain its progress, by the use of astringent collyria,—the solutions of silver, copper, zinc, &c.; but when it evinces a disposition to encroach upon the transparent tissues, it becomes necessary to adopt more efficient measures for its removal. The membranous variety may frequently be cured by scarifications, or the excision of a small segment of the morbid growth, parallel to the margin of the cornea, by means of the curved scissors. If the pterygium be thick and fleshy, it will be better to elevate it by the forceps, pass a cataract knife beneath, and separate it from the cornea in the first instance, and afterwards from its base. When the disease has extended far upon the cornea, some degree of

opacity necessarily remains after its removal, but it is less considerable than might have been anticipated from the space which it previously occupied.

Small tumours, termed *pingueculæ* from their appearance, sometimes grow on different parts of the conjunctiva; there is also another variety, having a red, spongy and vascular texture, attached to the globe by a fine central peduncle, and presenting a slightly convex or flattened surface, in shape not unlike to a minute mushroom. They rarely occasion much inconvenience, but if desirable, on account of the deformity, may be readily excised by the forceps and scissors. Little verruculous excrescences also occur in the same situation, and are removed in like manner, or if their base be more extensive, by means of a small scalpel.

MR. WATSON describes a fungous condition of the conjunctiva, which in some instances, resists the repeated application of the nitrate of silver, and requires an operation for its removal. Three cases have fallen under his observation, in which, from an apprehension of their malignant character, it was deemed expedient to extirpate the eye. On dissection, the fibrous tunics and the internal parts of the organ were ascertained to be quite unaffected. It occasionally happens that the morbid action of the capillaries spontaneously ceases, the fungus disappears, and the eye subsides into a state of atrophy.

A relaxed or flabby condition of the conjunctiva

sometimes remains after the severer grades of purulent ophthalmia; but in general, the membrane resumes its natural state of close application to the globe, under the use of tonic medicines, and the continued employment of various stimulating and astringent collyria.

XEROSIS.

There is a singular affection described under the title of xerosis, or cuticular conjunctiva, in which that membrane loses its soft mucous texture, and becomes dry, shrivelled and almost insensible. The iris and pupil, if not altogether concealed, are dimly visible through the opaque conjunctiva, which has a dirty white, or dead appearance; and the palpebræ are often either partially everted, or adherent to the globe and to each other. It is a disease of rare occurrence, and little is known respecting its etiology. It is sometimes seen as a consequence of acute inflammation which has destroyed the secreting property of the membrane;—by MR. TRAVERS it is attributed to an obliteration of the lachrymal ducts, but this cause would scarcely be adequate to the production of such an effect.

DISEASES OF THE CORNEA.

ACUTE CORNEITIS.

ACUTE inflammation of the cornea may be produced by variolous pustules, and injuries of various kinds, chemical and mechanical; it most commonly arises from the prolonged irritation occasioned by particles of metal which have become imbedded in the substance of that membrane.

Symptoms. The redness assumes a zonular appearance around the anterior part of the sclerotic, and is either partial or complete, according to the extent of the injury, and the severity of the inflammation;—the absence of a whitish line immediately encircling the cornea, distinguishes it from a similar phenomenon accompanying iritis. When the proper substance of the cornea is inflamed, the minute vessels are scarcely visible without the aid of a magnifier, but the vascularity is much more distinct, where its conjunctival covering is principally affected. The patient complains of a deeply seated pain in, and around the orbit, intolerance of light, and in its more aggravated grades, of hemicrania. The cornea loses its transparency, acquires a turbid or bluish white appearance, and becomes opaque at the injured part, where a minute abscess appears; or ulceration may take place without previous suppuration. If the

cause have been such as to destroy its vitality, the inflammation is generally violent, the slough gradually separates, and an opening is formed through which the iris protrudes. In some instances, where the disease assumes a sub-acute character, the eye is rendered more prominent than usual, from a redundance of the aqueous humour; and the cornea, when closely inspected with a magnifying glass, is observed to be covered with an infinite number of little ulcers, which give it a roughened appearance. When pustules form on the cornea during the variolous eruption, they are often followed by suppuration and sloughing, attended with vehement inflammation of the external tunics, and its usual consequences,—evacuation of the humours, staphyloma, prolapsus iridis, &c. In secondary variolous ophthalmia, the symptoms are less urgent; one or more whitish points are observed upon the cornea, which gradually increase, and assume a yellowish hue, accompanied with pain, redness, and the usual phenomena of inflammation. Where the pustules are more numerous, the entire cornea is rendered nebulous.

Treatment. General and local depletion, mercury carried to the production of slight ptyalism, purgatives, counter irritation, refrigerating lotions, abstinence, &c., judiciously prescribed with reference to the stage and severity of the inflammation, are the appropriate remedies; and, in many instances, promptly succeed in arresting the pro-

gress, and removing the effects of the disease. It is extremely apt, however, to pass into the chronic form, and under such circumstances, where there is no contra-indication, it will be advisable to maintain a slight mercurial impression, to abstract blood by occasional cupping from the back of the neck, and also to institute some permanent mode of counter irritation.

STRUMOUS CORNEITIS.

There is another form of inflammation occurring chiefly in children and young persons of scrophulous constitution, known under the appellation of strumous corneitis. It is much slower in its progress than the preceding variety, and in many cases, appears to affect principally the corneal conjunctiva, and the cellular tissue connecting it with the parts beneath. The cornea loses its polish, becomes dull and cloudy, and sometimes presents a light diffused opacity, either partial or complete; there is more or less roughness of surface, and the eye often appears unusually prominent. Not unfrequently also, lymph is effused in considerable quantity, concealing the pupil, and in some instances, involving almost the entire superficies of the membrane. The vascularity of the cornea, though not in general very considerable, is more diffuse, and the zonular arrangement less distinctly marked

than in simple corneitis. Small vessels are sometimes observed running towards, and ramifying in the opaque portion, constituting what has been termed vascular albugo. Where the conjunctiva is chiefly affected, the intolerance is often considerable, but this is a prominent symptom when the denser structure of the cornea is implicated; traces of iritis, and of impaired vision, bordering on amaurosis, are also frequently present under such circumstances.

Treatment. The treatment of strumous corneitis must be conducted on the general principles which have been already laid down under the head of scrophulous ophthalmia; it is in general extremely unmanageable, and requires a steady perseverance in the use of remedies. In recent cases, and particularly where the proper substance of the cornea is inflamed, or symptoms of iritis are present, the blue pill, or calomel, carried to the extent of gentle ptyalism, will often exert a happy influence in arresting the progress of the disease, and promoting the absorption of the effused lymph. During the occasional exacerbations to which the disease is subject, local depletion will be proper, while any indications of active congestion are present; but under other circumstances, the various stimulating collyria—silver, copper, zinc, the vinum opii, &c.,—already so often mentioned, may be employed with advantage.

MACKENZIE prefers the vinum opii, which he drops into the eye by day, and introduces at night

the ointment of red precipitate (R. No. 11,) between the margins of the palpebræ. This latter article is also occasionally prescribed in its pulverized form, (R. No. 40,) a small quantity being blown into the eye through a quill. MR. LAWRENCE recommends the formation of an issue in the temple, as an efficient mode of employing counter irritation.

The improvement of the general health, with due attention to the proper performance of the cutaneous and digestive functions, constitutes in this, as in other manifestations of scrophulous action, a very important part of the *methodus medendi*. Tonic and alterative medicines, as the sulphate of quinine, the various chalybeate preparations, the blue pill and rhubarb, the mineral acids, iodine, and the liquor potassæ, country air and exercise, and in general, whatever tends to invigorate the constitution, may be severally employed with greater or less advantage in almost every case. The sulphate of quinine, in conjunction with the collyrium of silver or zinc, frequently evinces a remarkable controul over vascular albugo, or that form of the disease which is characterized by lymphatic deposition.

INFLAMMATION OF THE MEMBRANE OF THE AQUEOUS HUMOUR.

Inflammation of the internal laminæ of the cornea, or the membrane of the aqueous humour, is

sometimes described as an independent disease, under the title of aquo-capsulitis. It possesses however, many symptoms in common with strumous corneitis—the vascular zone, intolerance of light, the dull aching supra-orbital pain, &c.,—and for all practical purposes, might have been included under that head. It is more particularly distinguished by a pale, deeply seated opacity, which is unequally distributed, imparting to the cornea a mottled appearance, and by a turbid or cloudy state of the aqueous humour. Lymph is sometimes effused in considerable quantity, and may be observed floating in the anterior chamber, or forming a thin layer upon the surface of the inflamed membrane. The inflammation involves also the other tissues, and iritis is frequently present in a greater or less degree. It is most prevalent among children of strumous constitutions, and is often exceedingly intractable.

The treatment, which differs in no very essential particular from that prescribed for the preceding disease, consists in the employment of the antiphlogistic system to an extent proportionate to the severity of the symptoms, the exhibition of mercury, and counter irritation, during the acute stage; and the sulphate of quinine, the carbonate or proto-sulphuret of iron, the oil of turpentine, and the other remedies above mentioned, together with due attention to the hygienic indications, when the disease has assumed a chronic form.

MR. WARDROP strongly recommends the evacuation of the aqueous humour through a puncture of the cornea, and states that he has never known it fail to relieve the pain of the head, and restore the transparency of the anterior chamber. It is not a measure however, which we should, a priori, have thought likely to prove useful, and general opinion is opposed to its adoption.

ABSCCESS OF THE CORNEA.

Purulent deposition between the lamellæ of the cornea, is a frequent consequence of the several varieties of inflammation affecting that membrane, and when the effusion is situated at the inferior margin, is termed onyx, from its resemblance to the white appearance at the root of the nail. The matter is generally absorbed after the vascular excitement has subsided; but where this does not happen, it may make its way either externally, or into the anterior chamber, producing in the case last mentioned, the appearance denominated spurious hypopium.

Treatment. The appropriate remedies for the removal of the inflammation, are also those which are most effectual in limiting the extent, and promoting the absorption of the effused fluid. The system should be brought under the influence of mercury with as little delay as possible, and the antiphlo-

gistic treatment generally, carried as far as is compatible with a due regard to the constitution of the patient. The pus or lympho-purulent matter, is generally too tenacious to escape through an artificial opening, and the irritation caused by such a procedure could scarcely fail to aggravate the inflammation: but where the collection is large, and threatens to diffuse itself over the surface of the cornea, accompanied with intense pain and hemi-crania, it may be evacuated by a small puncture; care being taken that the instrument do not penetrate beyond the anterior wall of the abscess.

When the acute symptoms have been subdued, the process of absorption may be accelerated by various stimulating applications—the solution of the nitrate of silver, the vinum opii, and the unguentum argenti nitratis, particularly the latter. A slight degree of opacity frequently remains after the disappearance of these abscesses, which does not admit of removal.

ULCER OF THE CORNEA.

Ulceration may affect merely the conjunctival covering, or may implicate also the proper substance of the cornea, presenting two principal divisions, the deep and superficial;—the latter of which has already been considered. It is a common result of inflammation, and according to MR. SAUNDERS,

nearly two thirds of the cases treated at the LONDON Eye Infirmary during his time, were of this description. The texture of the cornea, which is somewhat analogous to that of cartilage, and its inferior grade of organization, render it extremely prone to the ulcerative process, when its circulation is interrupted from whatever cause; and hence it is, that in persons of advanced life, or impaired constitution, it sometimes occurs without previous inflammation. The ulceration assumes a variety of forms, presenting in some cases, a deep circumscribed excavation, with smooth glassy surface and rounded margin; and in others, an irregular cavity with ragged edges, generally preceded by effusion between the laminae of the cornea, and attended with violent irritation; there is also the crescentic ulcer, situated near the circumference of the cornea, and almost peculiar to extreme senility. The two varieties last mentioned, are generally associated with a disordered or enfeebled condition of the system, and the excessive irritability with which they are frequently accompanied, is owing to the constant friction of the palpebrae; there is, however, great diversity in regard to the severity of this symptom, depending rather on constitutional temperament, than on the size or any peculiarity of the ulcer. When the ulceration occurs in connection with the strumous diathesis, intolerance of light and lachrymation are frequently present in a high degree.

Treatment. Ulceration of the cornea occurring during the prevalence of acute inflammation, will generally cease as the inflammatory action subsides, and little more is required on the part of the surgeon, than to assist the operations of nature, and avoid the interruption of the reparative process by the use of ill-timed, or injudicious measures. While however, the ulcerative action continues, the antiphlogistic system must be employed to an extent commensurate with the urgency of the symptoms; and where there is no contra-indication, mercury should be exhibited so as to produce its constitutional impression with as little delay as possible. If the ulcer assume an indolent character, various local stimuli may be employed with advantage, and of these the best is a solution of the nitrate of silver, applied by means of a camel's hair pencil. This stationary condition sometimes arises from general debility, and demands a tonic course of treatment,—the sulphate of quinine, the various chalybeate preparations, a nutritious diet, and other means calculated to invigorate the system. If the inflammation be protracted and aggravated by the irritability of the ulcer, a stronger solution of the nitrate may be used, or it may be necessary, in order to lessen the extreme sensibility of the exposed surface, to produce a slight eschar by touching it gently with a finely pointed pencil of the caustic. The indiscriminate employment of this remedy, is frequent-

ly productive of much injury, and some skill is required to determine the proper cases for its application. MR. LAWRENCE, who evinces unusual timidity respecting stimulants in the diseases of the eye, and entertains apprehensions of the solid nitrate in particular, which must often deprive him of an useful auxiliary, is also opposed to its use in the present instance; and as a general rule, the solution, varying in strength according to the indication to be fulfilled, will be found preferable.

In strumous constitutions, or where the ulcer is connected with a disordered, or enfeebled condition of the system, mercury is improper, and depletory measures, except in so far as they may be necessary to remove any active congestion which is present in the incipient stage, are likewise inadmissible. Under such circumstances, the sulphate of quinine alone, or in combination with iron and other tonics, a nutritious diet, the collyrium of the nitrate of silver, and other invigorating measures, are imperiously demanded; the same treatment is also indicated in those cases where the ulcer assumes a sloughing disposition. If the patient be much debilitated, and the ulcer exhibit a glassy, languid appearance, with no tendency to reparation, the unguentum argenti nitratis will frequently prove extremely serviceable.

When the ulceration has penetrated through the coats of the cornea, the membrane of the aqueous

humour occasionally protrudes in the shape of a small transparent vesicle, which has been termed hernia of the cornea. The projection varies in size, according to the extent of the ulcer, and may terminate in staphyloma, or the evacuation of the humours and collapse of the eyeball. It should be touched occasionally by the nitrate of silver in substance or strong solution, the patient confined to a darkened apartment, and prolapsus of the iris prevented, when the vesicle threatens to give way, by the application of belladonna to the brow. The same treatment is equally proper in cases of slight protrusion of the iris; but where the ulcer is large, and the prolapsus more considerable, no attempt should be made to withdraw it from the aperture, since under such circumstances, it is the means instituted by nature to close the opening, and thus preserve the form of the organ. If the iris protrude so far as to become itself a source of irritation, the tumour may be lessened by a slight puncture with the cataract needle, or its retraction promoted by the occasional employment of the nitrate of silver. It sometimes happens that the ulcer not healing entirely, a fistulous orifice is left, through which the aqueous humour is discharged as it is secreted, requiring the application of the caustic in pencil or solution.

A minute depression or excavation of the cornea, denominated dimple, is sometimes seen as a sequel of phlyctenula, or ulcer. The defect is

permanent, and when situated immediately opposite the pupil, may occasion some inconvenience by the reflection of the light from its smooth and uniform surface.

Gangrene of the cornea is not an unfrequent effect of inflammation in strumous, or impaired constitutions, and is a common occurrence in the severer grades of purulent ophthalmia; it is also sometimes caused by the direct application of escharotic substances. The lifeless portion is easily recognised by its opaque, shrivelled and dirty white, or yellowish appearance; it frequently involves only the external laminæ, and the imminent danger of the organ requires the prompt adoption of appropriate remedies. If the vitality of the part have been destroyed by the action of caustic, or heated substances, the local abstraction of blood, and the antiphlogistic system generally, will be required to subdue the resulting inflammation; but in the other cases mentioned above, depletion will have already been carried to a sufficient extent, and a tonic course of treatment,—the sulphate of quinine and carbonate of ammonia, conjointly with collyria of the nitrate of silver, the sulphate of zinc, or the vinum opii—must be instituted

OPACITY OF THE CORNEA.

Opacity of the cornea is a very frequent consequence of ophthalmia, and occurs in every intermediate degree, from a slight haze or dulness, to entire loss of transparency. These several gradations are distinguished by different appellations, as nebula, macula, albugo, leucoma, &c. The first is a light diffused cloudiness, chiefly confined to the conjunctiva, and either partial or otherwise; when the opacity is distinctly circumscribed, small circular or linear, it is termed macula; albugo is produced by lymphatic deposition in the cellular tissue, or between the proper laminæ of the cornea, and in its aggravated forms, involves the entire thickness of the membrane. Leucoma is the dense white opacity resulting from the cicatrization of wounds and ulcers, and is frequently complicated with anterior adhesion of the iris. An opaque circle sometimes appears on the circumference of the cornea in advanced life, and is known under the name of arcus senilis.

Treatment. The primary indication is the removal of any existing inflammation, by the local abstraction of blood, counter irritation, and other appropriate measures. The opacity is sometimes caused by a diseased condition of the palpebral lining, incurvation of the tarsal margin, inverted cilia, &c., but the measures to be adopted for the cure

of the disease when thus produced, have already been fully considered.

Every source of irritation having been carefully investigated, and as far as practicable removed, a variety of stimulating applications are recommended with the view of promoting the absorption of the effused lymph; such as the solution of the nitrate of silver, the sulphate of copper, or zinc, the bi-chloride of mercury in the proportion of two grains to the ounce, and the *vinum opii*, pure or diluted. The sulphate of cadmium (*R. No. 34*.) has been lately introduced into practice, but is inferior to several of the articles which have just been mentioned. These solutions, gradually increased in strength according to the irritability of the eye, should be perseveringly employed; and as their effect is diminished by repetition, it will also be proper to vary them occasionally. In recent cases, the *ung. hydrargyri nitratis*, applied to the seat of the opacity by means of a camel's hair pencil, is an excellent remedy. Leucoma, and the denser forms of albugo, though they cannot be entirely removed, may often be much diminished by the absorption of the lighter deposition around their circumference. For this purpose, the ointment of the nitrate of silver, repeated at intervals of two or three days, in conjunction with the internal administration of mercury, counter irritation, &c., may frequently be employed with decided advantage. The ointment of the hydriodate of

potash is also useful under these circumstances. BARON DUPUYTREN relied chiefly on the insufflation of the red precipitate (R. No. 41,) or the oxide of zinc and sub-muriate of mercury, (R. No. 42.) The application is made twice in the twenty-four hours, and according to that eminent practitioner, recent opacities are thus removed in two or three weeks, while those which are more deeply seated and extensive, involving nearly the whole cornea, and entirely preventing the transmission of light, may be dispersed in as many months.

When the effused lymph has become organized, and has acquired a dense, shining appearance, surgical treatment is of no avail, and it is unnecessary to annoy the patient by persisting in the employment of remedies which are incompetent to the removal of the disease. In such cases, if the opacity be partial, and situated near the centre of the cornea, vision may be much improved by the daily employment of belladonna.

STAPHYLOMA OF THE CORNEA.

Staphyloma is a general term applied to a preternatural projection of the membranes of the eye, and is restricted in its signification by the tissue principally affected. Staphyloma of the cornea occurs under two varieties—the conoidal and the spherical—which are somewhat different in their

progress and termination. The first is the most common, and is generally the sequel of an ulcer, abscess, or extensive interlamellar deposition. The projection may occupy either a portion, or the whole of the membrane, and vision is lost or impaired, according as it is complete or partial, involving the pupil or otherwise. There is always more or less disorganization of the transparent tissues; and in complete staphyloma the anterior chamber is obliterated by the adhesion of the iris, and the cornea, opaque and thickened by disease, projects in the form of a whitish or pearl-coloured tumour. The spherical variety is an occasional sequel of the severer grades of purulent ophthalmia, but it may also be produced by any other cause which impairs the vitality of the cornea. In such cases, the membrane yields at every part of its circumference, and the projection frequently acquires a considerable magnitude. The cornea becomes unequally thickened in the progress of the disease; its lamellar arrangement is destroyed; the iris adheres to its inner surface, but not expanding in equal proportion, is torn into radiated fragments, so as to exhibit, when viewed from behind, a stellated appearance; and the staphyloma having arrived at this point, either remains stationary, or rupture takes place at its most prominent part, and a temporary diminution of size is thus occasioned. This termination however, is more common in the conoidal species.

Treatment. When the staphyloma projects be-

yond the eyelids, the exposure of the tumour to the action of external irritants, renders it liable to repeated attacks of inflammation attended with sympathetic irritation of the healthy organ, and an operation may be required on this account, as well as for the removal of the inconvenience and deformity occasioned by the protuberant cornea. Repeated punctures with a grooved, or cataract needle, will diminish for a time the size of the tumour, and in a few instances, may effect a radical cure; but for the attainment of this result, it is generally necessary to excise the more prominent portion of the cornea. Presuming the disease to involve the whole of that membrane, the operation is performed by introducing a cataract knife one or two lines anterior to its junction with the sclerotica, and carrying it onwards so as to make a flap of its lower division; this is then raised by the forceps, and the incision around the upper margin completed by the curved scissors. Or the operation may be performed still more expeditiously, by transfixing the cornea with a hook and removing the requisite portion by a single stroke of the knife from above downwards. It is important to avoid any undue pressure upon the globe, in order to prevent, if possible, the escape of the lens and vitreous humour, and leave a basis for an artificial eye; this, however, cannot always be done, and the operation is sometimes followed by the entire evacuation of its contents. The excision having been completed, the

lids may be closed, and secured by strips of court plaster, or merely covered with a compress moistened in some refrigerating lotion. More or less inflammation always ensues, and if it transcend the degree necessary for the reparative process, the usual remedies must be employed for its reduction. When suppuration occurs, the matter should be discharged by an early opening.

In partial staphyloma, where vision is not entirely destroyed, we are advised by BEER, MACKENZIE and others, to endeavour to arrest the further progress of the disease, by producing adhesive inflammation in the apex of the tumour; and the muriate of antimony has been recommended for this purpose. Such treatment, however, is not likely to be very successful. The irritability of the eye may be lessened by the solution of the nitrate of silver, and if circumstances require the performance of an operation, the projecting part may be removed in the manner just described.

CONICAL CORNEA.

In some instances the cornea, retaining its transparency, gradually assumes a conical or pyramidal form, and, when viewed from certain positions, reflects the light so strongly as to exhibit a peculiarly brilliant or sparkling appearance, characteristic of the disease. It generally affects both

eyes, though not in equal degree; has been observed at all periods of life, but more commonly about the age of puberty, and is said to be most prevalent among females. Conical cornea is rather a rare disease, though DEMOURS, who treats of it under the title of transparent staphyloma, states that himself and father have met with more than a hundred cases of the kind. The alteration takes place slowly, in many instances never proceeds far, and may require years for its full developement, at which point it either remains stationary—the apex of the tumour sometimes becoming opaque from its constant exposure to the action of external irritants—or ulceration takes place, and is eventually followed by staphyloma.

The pathology of this disease does not appear to be well understood; it probably depends upon some aberration in the assimilative and absorbent functions, in consequence of which the centre of the cornea becomes attenuated, and is unable to resist the pressure of the redundant aqueous humour. The patient is always myopic, and the unnatural refraction renders vision confused and imperfect; the surface of the projection is sometimes slightly irregular, and objects appear as if multiplied.

Treatment. Little can be done to arrest the progress of this affection, but in its early stage, advantage may be derived from the use of a double concave lens, so arranged in the frame as greatly to contract the sphere of vision. MR. TRAVERS

prefers a piece of black wood, three or four lines in thickness, with an aperture in the centre about the size of the pupil. The patient should abstain from all close exertion of the eye, and vision may be temporarily improved by the employment of belladonna. The incipient opacity of the projection, may be diminished by the use of a solution of the nitrate of silver;—when the disease is attended with pain and tension of the eyeball, it has been recommended to evacuate the aqueous humour.

DISEASES OF THE SCLEROTICA.

SCLEROTITIS.

INFLAMMATION of the sclerotica is characterized by the peculiar appearance and distribution of its minute vessels, which exhibit a pale red, or pinkish colour, and run in a radiated direction to the margin of the cornea, around which they form a wreath or plexus, more or less distinct—in some cases slightly encroaching upon its surface. The pupil is contracted, and less active than usual, indicating the presence of iritis; and when this complication exists in any considerable degree, the zonular arrangement is more strongly marked. The pain is dull, aching and tensive, often less severe in the globe than in the surrounding parts, and is greatly aggravated at night, the patient being comparatively free from uneasiness during the day; headache and hemicrania are also occasional symptoms. The vascularity of the conjunctiva is, in general, inconsiderable, a few dilated vessels only being perceptible; and there is usually little intolerance, or lachrymation, but in severe cases, these symptoms are present in a high degree, accompanied with fever, and other manifestations of constitutional suffering. The inflammation is often limited to one eye, and frequently alternates with rheumatic affections in other parts of the body, or

makes its attack as they subside. It is tedious in its progress, less decidedly influenced by remedies than disease of the other tissues, and leaves an irritable condition of the organ which renders it liable to relapse from slight causes.

Sclerotitis is most common about the middle period of life, and is generally caused by exposure to cold. Allusion has been made to its connection with inflammation of the fibrous textures, and it may now be stated that it is also occasionally seen in conjunction with gonorrhœa. Iritis, glaucoma, attenuation and staphyloma of the sclerotica, are among its morbid terminations.

Treatment. When the pain and other symptoms are severe, and especially if there be any febrile excitement, venæsection will be required; due regard being had in every case, to the violence of the inflammation, the period of the disease, and the constitution of the patient. Local depletion by cupping from the back of the neck, to the extent of four or five ounces every third or fourth day, with active purgatives, saline laxatives, and the tincture of colchicum, will usually exert a very happy influence. Mercury exhibited with a view to its constitutional impression, is particularly proper when the iris and deeper seated tissues are implicated, but under other circumstances, it is rarely necessary to continue it so long as to produce ptyalism. It may be given at night, in combination with opium, or in smaller quantities during

the day; the bi-chloride is sometimes preferred to the other preparations, and may be appropriately administered in the compound syrup of sarsaparilla. Warm anodyne fomentations (R. Nos. 16, 19,) are the best local applications, and a tepid collyrium, containing acetic acid, (R. No. 25,) may likewise be employed with advantage. Frictions over the brow with belladonna and cantharides (R. No. 50,) mercurial ointment blended with opium, or the compound soap liniment, (R. No. 46,) will sometimes prevent the accession, or lessen the severity of the nocturnal paroxysms; counter irritation by blister, may be also beneficially employed. When the acute stage has passed away, and a state of vascular congestion alone exists, a solution of the nitrate of silver, or the vinum opii may be dropped into the eye once or twice a day. In chronic cases, and especially where there is reason to suspect the presence of any strumous disposition, the sulphate of quinine, alone, or combined with the preparations of iron, will frequently prove extremely serviceable. MACKENZIE states that in old mal-treated cases, the liquor arsenicalis, in the quantity of eight or ten drops thrice a day, sometimes afford great relief. The iris ought to be kept under the influence of belladonna throughout the progress of this ophthalmia, and attention should also be directed to the proper performance of the renal and cutaneous functions, and to the measures necessary to guard against relapse.

CATARRHO-RHEUMATIC OPHTHALMIA.

After what has been said of the separate affection of the several tissues, it will be unnecessary to describe particularly their combination in the present instance. The usual symptoms of conjunctivitis are present in a greater or less degree, and may occasionally mask some of those peculiar to inflammation of the sclerotica. The latter, however, is sufficiently denoted by the character of the pain, which is subject to nocturnal exacerbations, and is situated chiefly in the eyebrow and temple. The cornea is extremely liable to suffer in this variety from ulceration, abscess, or interstitial deposition. The ulcer is generally superficial, and cicatrizes without opacity, but often leaves behind a slight irregularity of surface. Lymphatic deposition between the laminae of the cornea, is a much more urgent symptom, the ulceration which follows not unfrequently penetrating the anterior chamber. The inflammation may extend also to the iris, terminating in the effusion of lymph, and in some instances the obliteration of the pupil.

The treatment does not differ from that already laid down for simple scleratitis, except in the addition of the local remedies for catarrhal ophthalmia. It is, however, much more dangerous than the preceding disease, and should be treated with corresponding activity. When the antiphlogistic plan

has been carried sufficiently far, the tincture of colchicum, alone, or combined with other diuretics, may often be prescribed with much advantage.

STAPHYLOMA OF THE SCLEROTICA.

The sclerotica is much less liable to become staphylomatous than the cornea, as well from its different organization, the strength and firmness of its texture, and its inaptitude to inflammation, as its exemption from interstitial deposition, comparative security from accidental injury, and disinclination to assume the ulcerative process. Staphyloma of this membrane does, however, sometimes occur as a consequence of inflammation, lesion from external violence, or pressure caused by a varicose enlargement of the choroidal vessels; and is attended with impairment, or total loss of vision, according to the extent of the morbid alterations. Under such circumstances, the sclerotica loses its resisting power, becomes attenuated, and projects in the form of one or more bluish or lead-coloured tumours, covered with varicose vessels. They rarely attain sufficient magnitude to require an operation, but if much irritation and deformity be produced, the same treatment will be necessary as in the kindred affection of the cornea.

DISEASES OF THE CHOROID.

CHOROIDITIS.

THOUGH inflammation of the choroid, has long been known as a complication of iritis and other internal ophthalmiæ, it is only of late years that pathologists have admitted its independent existence. The disease is usually confined to one eye, and is attended with a slight enlargement of the sclerotic vessels, which exhibit a faint and imperfect zonular arrangement around the cornea; the pain is deeply seated and tensive, the pupil generally dilated, its mobility impaired, and its circular outline not unfrequently destroyed. The globe is tense and hard to the touch; the sclerotica presents a leaden or dark brown discolouration, and in the progress of the case, becomes attenuated, and projects at one or more points, covered with varicose vessels. Intolerance of light and lachrymation, are generally present in a greater or less degree, and vision always greatly impaired, is not unfrequently lost altogether. The protrusion of the sclerotica may be occasioned by a varicose distension of the choroidal vessels, or by serous effusion between the membranes;—in some instances the whole eyeball is enlarged to such an extent as to be with difficulty covered by the palpebræ.

The attenuation, livid discolouration, and in-

equality of the sclerotica, the peculiar irregularity of the pupil—which is drawn towards the side most affected,—and the absence of the symptoms diagnostic of those affections, sufficiently distinguish choroiditis from inflammation of the iris, retinitis, or glaucoma. It frequently happens, however, particularly in its latter stages, that general internal ophthalmia supervenes, and the several diseases are so blended together that it is quite impossible to unravel them.

Treatment. General and local depletion, purgatives, mercury, counter irritation, &c., judiciously employed, are the appropriate remedies in this, as in the other varieties of internal ophthalmia. The extreme vascularity of the choroid, however, occasions some difference in their operation,—inflammation of that tissue being more decidedly influenced by the abstraction of blood, and less under the controul of mercury. MR. MACKENZIE has administered the arseniate of potash, in the thirteenth part of a grain, with considerable benefit in the advanced stage;—the morbid appearances disappearing under its use, and health and vision simultaneously improving. The sulphate of quinine, the preparations of iron, and medicines of a similar character, would probably be found still more effectual under such circumstances, as the disease usually occurs in persons of strumous constitution. When the globe is very tense and painful, relief may sometimes be afforded by an artificial opening.

DISEASES OF THE RETINA.

ACUTE RETINITIS.

ONE of the earliest and most prominent symptoms of acute inflammation of the retina, is the aggravated and distracting pain by which it is accompanied. It either makes its attack suddenly, or is preceded for a brief period by an uneasy, or tensive sensation in the globe; the pain is deeply seated, throbbing and agonizing, darting through the head, increased by the slightest motion of the organ, and attended with giddiness,—occasionally even with delirium. The intolerance of light is excessive, the lachrymation profuse, and there is an appearance as of scintillations or luminous bodies passing before the eye. The external vascularity is inconsiderable, but the patient complains of a sense of fulness or tension in the ball, and vision is greatly impaired from the commencement,—total blindness sometimes supervening in a few hours. The constitutional disturbance is frequently so severe, that on a superficial examination, the disease might even be mistaken for phrenitis. After a while the intolerance subsides, and the pupil, which was before rather contracted, acquires a turbid hue, and becomes dilated and motionless. The inflammation is rarely confined to the retina, but in its progress involves also the

other tissues, and iritis, glaucoma, and external ophthalmia are usually present in different degrees, producing a correspondent modification of the symptoms. Extensive disorganization of the internal structures is a common result, or suppuration may take place, followed by collapse of the globe.

Inflammation of the retina sometimes occurs without any very obvious cause, but in other cases it can be directly traced to flashes of lightning, exposure to intense light and heat, or undue exertion of the eye in viewing minute and brilliant objects.

Treatment. Though extremely dangerous, retinitis is not always destructive to vision, if the appropriate remedies are vigorously employed before the sight is wholly extinguished. The most active antiphlogistic treatment is demanded, and no time should be lost in carrying it to its fullest extent. The patient should be bled ad deliquium, and the vein must be re-opened if a decided impression have not been produced by the first operation; cupping from the temples and back of the neck, active cathartics, &c., should be prescribed in quick succession. Mercury is an invaluable remedy in this form of ophthalmia, and should be exhibited in such manner as to produce its constitutional impression with the least possible delay. Counter irritation will also be useful, the light must be carefully excluded, and every part of the anti-

phlogistic system rigidly enforced. In the management of this formidable affection, the surgeon should bear in mind the suddenness of its onset, and the rapidity of its progress; irreparable mischief is sometimes produced in a very few hours; and although the extent of the depletion must be regulated by the constitution and state of the patient, it ought in every instance, to be carried as far as can be done consistently with a due regard to these circumstances.

CHRONIC RETINITIS. AMAUROSIS.

Acute retinitis, whether owing to the vehemence of the attack, neglect, or insufficient treatment, is extremely liable to terminate in loss of sight; but there is a chronic inflammation more frequent in its occurrence, which may be equally destructive to vision, and as it is perhaps the most common cause of amaurosis, may be properly included in the description of that disease.

When amaurosis occurs as a consequence of chronic inflammation of the retina, the usual indications of vascular excitement are present, though in a much slighter degree than in the acute form; the patient complains of pain or uneasiness in the eye, accompanied with a sense of heat, dryness, and a morbid sensibility to the impression of light, which, however, may not amount to actual intolerance. He

evinces an aversion to use the organ, and is often annoyed by *muscæ volitantes* and ocular spectra of different kinds. The sensibility of the membrane is gradually lessened by interstitial deposition, and vision is impaired in every intermediate grade, from slight dimness to total loss of sight; objects at first appear obscure, as if enveloped in mist or smoke, are confusedly blended together, and in some instances are only partially discerned; while in others their shape is variously distorted, or there is an erroneous perception of colour. Strabismus and double vision are frequent symptoms, and it may happen that where the central portion of the retina is quite insensible, the patient is still capable of seeing objects situated laterally with tolerable distinctness. The ocular spectra assume various forms; exhibiting an appearance as of net-work or gauze, dark motes, or pellucid serpentine tubules or *striæ*, and not unfrequently flashes of light, sparks, and other luminous bodies. They may be either fugitive and occasional, or fixed and permanent; and are an unfavourable symptom, inasmuch as they usually indicate alteration in the texture of the retina. The pain, likewise, differs in degree, nature and situation; it is often accompanied with giddiness, and is frequently a prominent subject of complaint, though in many cases it is rather an uneasy sensation of fulness and distension, than a feeling of positive suffering. It may be either constant or otherwise, assumes sometimes the form of general

headache or hemicrania, and is frequently confined to the brow and neighbouring parts. The pupil is usually dilated and immovable, or if the iris still preserve any degree of activity, its motions are sluggish and limited in extent; instances, however, of regular contraction and dilatation are not very uncommon. If one eye only be amaurotic, the pupil may often be observed to dilate when the other is closed, and vice versa; it is very frequently irregular, and instead of its natural pure black colour, exhibits a dull, turbid, or horny appearance. When the amaurosis arises from general debility, or is symptomatic of irritation in other parts of the body, the pain and other indications of increased action, are much less apparent, and in many instances, there is, from the beginning, a diminished sensibility to light, the patient requiring a brilliant illumination of objects for the purposes of vision. Imaginary sensations about the eyes are not unusual, and the disease is sometimes complicated with paralysis of the levator palpebræ. In every instance where the amaurosis is complete and inveterate, the countenance loses its expression, and acquires a vacant unmeaning stare, which at once betrays the nature of the malady. Under such circumstances also, the globe frequently has a tremulous, vacillating, or rolling motion.

The progress of amaurosis is extremely variable; it may be produced suddenly, or as is more frequently the case, may require months or even

years for its full development. It is most common in the middle period of life, usually commences in one eye, and does not attack the other, until vision in that first affected, is either much impaired or totally destroyed; and may be either complete or partial, permanent, temporary, or periodical.

The causes of this affection are very numerous, and include whatever has a tendency to excite inflammation, or disordered circulation in the nervous apparatus of vision,—excessive exertion of the organ, exposure to intense light and heat, external injuries, febrile diseases, violent passion, intoxication, insolation, plethora, and determination to the head from any cause; various forms of gastric and intestinal disorder; certain states of the uterine system, particularly pregnancy and amenorrhœa; suppression of habitual evacuations; pressure upon the brain, retina or optic nerve; different pathological states of these parts; irritation produced by the growth and decay of the teeth, inverted cilia, tumours on the palpebræ, &c.; the depressing emotions; general debility from profuse discharges—the loss of blood, diarrhœa, lactation, menorrhagia—venereal excesses, and extreme senility; a torpid condition of the nervous system; injuries of the supra and infra-orbitary nerves, &c. &c. It is sometimes congenital, and not unfrequently hereditary. Many of the causes above enumerated, operate through the medium of the Trigemini, and experience and observation prove

that amaurosis is more frequently connected with lesion of some of the branches of that nerve, than is perhaps generally imagined.*

Amaurosis is liable to be confounded with glaucoma, and also with cataract in its incipient stage; a mistake the more likely to happen, inasmuch as it sometimes supervenes on a turbid condition of the humours, and these several diseases frequently exist in various degrees of combination. A correct diagnosis can only be formed by an intelligent consideration of the symptoms characteristic of each affection, which will be detailed under their respective heads.

If the amaurosis have originated in inflammation which has long subsided, it probably depends on some organic change in the retina, or a varicose enlargement of the arteria centralis, and is not likely to be removed by any measures which may be adopted. The prognosis is more favourable

* A curious case, instructive in several respects, recently occurred at the WILLS HOSPITAL. A patient was admitted, with rheumatic ophthalmia of the right eye, who, twenty years before, had lost the sight of the left, from a wound inflicted by a particle of metal. The iris had been injured by the accident, and the pupil, approaching to an oval form, had deviated from the centre to its circumference. Previously to his admission, he was barely able with this eye to distinguish light from darkness, but during the inflammation of the other, its vision gradually improved, and was entirely restored by a metastasis of the ophthalmia, which occurred without any obvious cause. When discharged from the house, he was able to see equally well with both eyes.

when it arises from plethora, profuse evacuations, protracted suckling, lesion of the Fifth Pair, or sympathy with irritation in other parts of the body. In its incipient stage, and where, though complete, the disease is of recent occurrence, we may sometimes succeed in arresting its progress, and restoring vision; but if confirmed, or complicated with other affections, it may generally be regarded as incurable, and under such circumstances, it is worse than useless to harass the patient, and perhaps injure his constitution, by perseverance in the employment of means which can lead to no beneficial result.

The treatment of a disease, or more properly, a symptom, depending upon so many and such opposite causes, must of course vary exceedingly in different cases. A strict inquiry should in every instance be instituted into the origin of the complaint, and the practice regulated accordingly; otherwise the surgeon will be guided by no rational aim, and his prescriptions must necessarily be tentative and empirical. If the patient be robust and plethoric, and symptoms of cerebral congestion are present, or if there be any indication of vascular excitement in the retina, depletion both general and local, will be required; cupping from the back of the neck, to the extent of six or eight ounces every two or three days, is an efficient remedy, and after a few repetitions may be exchanged for counter irritation by blister or seton.

Active cathartics, and the strict observance of the antiphlogistic regimen, will likewise be necessary under such circumstances. Mercury often evinces a striking control over disease of the retina, and its alterative action is therefore proper in every instance, while if there be no contra-indication, the system should be early brought more decidedly under its influence, and its constitutional impression continued for a considerable time. Where the amaurosis has arisen from sympathy with irritation in other parts of the body, the cause should be carefully investigated, and if possible, removed; particular attention should be given to the correction of any existing visceral derangement, and the remedies directed with this view,—the blue pill, rhubarb, aloetic aperients, vermifuges, emmenagogues, &c.,—perseveringly employed. When, on the other hand, it has been caused by vascular exhaustion, or nervous hebetude or debility, the preparations of bark and iron, valerian, the shower bath, a nutritious diet, exercise in the open air, together with local stimulants—electricity, frictions with ammoniacal liniment (R. No. 47,) and other rubefacients, sternutatories, as common snuff, or equal parts of the sub-sulphate of mercury and pulverized liquorice root, the vapour of ammonia and ether,—and whatever has a tendency to invigorate the system, and awaken the susceptibility of the part, may be usefully called into requisition. The result of the case to which allusion was made on a previous page, gives

reason to hope that advantage may, in some instances, result from imitating the operations of nature, and exciting an artificial inflammation of the organ.

Strychnia promises to prove an useful acquisition to our therapeutical agents in some forms of amaurosis. It is employed in the endermic method; the cuticle having been removed from a space above the brow by the previous application of a blister, one-fourth of a grain is sprinkled on the abraded surface. The quantity is gradually increased to two grains, and if it occasion much pain or irritation, it may be mixed with a little pulverized opium, or any simple substance. MIDDLEMORE and others speak of this article in terms of high commendation, but the effects which occasionally follow its employment, depend probably less upon its general impression, than its action as a local irritant.

When the amaurosis is produced by injury of the branches of the Fifth Pair above mentioned, it may possibly be removed by the complete division of the nerve, or the excision of the cicatrix. Pressure upon the retina has been enumerated among the occasional causes; it may arise from extravasation between that membrane and the choroid, or from an undue secretion of the vitreous or aqueous humour, and after the morbid action has been subdued by mercury, local depletion, &c., the effused matter may be evacuated through a puncture,—little hope, however, can be entertained of restoring vision by such an operation.

DISEASES OF THE IRIS.

IRITIS.

THE structure of the iris, its exposure to external injury, and its sympathies with various morbid conditions of the system, render it extremely prone to inflammation, which may be either simple, or complicated with syphilis, rheumatism, gout, scrophula, &c. The general symptoms however, are so much alike in all these cases, that it would be difficult without reference to the constitutional predisposition of the patient, or other circumstances connected with its history, to determine the real character of the complaint, in any particular instance.

SIMPLE ACUTE IRITIS.

One of the most obvious symptoms of inflammation of the iris, is the appearance of a radiated zone or wreath, formed by the minute ramifications of the anterior ciliary arteries, which advance in separate trunks upon the sclerotica, and at the distance of a few lines from the cornea, subdivide into numerous branches, before they penetrate the external coats to pass to their ultimate distribution. This vascular plexus may be either partial or

complete, and is more or less distinct, according to the extent, degree, and stage of the inflammation. The vessels terminate abruptly at the circumference of the cornea, and in some instances, an interior whitish line may be observed immediately encircling that membrane. The iris is thickened and prominent anteriorly, loses its brilliant fibrous appearance, becomes dull, corrugated and uneven, and acquires a green or reddish hue, according as it was previously light or dark coloured. These changes commence at its inner circle, gradually extend to the ciliary margin, and are chiefly caused by lymph deposited interstitially, or effused upon its surface. In the progress of the inflammation red vessels, and spots of extravasated blood, are occasionally seen on the iris, and in some instances, small abscesses form, and discharge their contents into the anterior chamber. The aqueous humour is more or less turbid; the pupil has a clouded or hazy appearance, and is contracted, irregular and motionless,—the irregularity frequently assuming an angular direction. The contraction is occasionally so considerable, that it is almost entirely obliterated; or the aperture is obstructed by lymphatic deposition, which produces effects according to its quantity, from a slight confinement of the pupillary margin at one or more points, to complete closure of the opening, and adhesion to the capsule of the lens. The effused lymph assumes various appearances,—occupying the pupil in a dense mass,

constituting what has been called lymphatic cataract, exhibiting a reticulated mesh work, or hanging in fringes from its circumference. Intolerance of light, lachrymation, and pain, deeply seated, circum-orbital, and generally aggravated at night, are present in different degrees, according to the severity of the inflammation; and the disease, if not arrested, progressively involves the other tissues,—the choroid, retina, membrane of the aqueous humour, and the external tunics. The constitutional disturbance is often considerable, and the advance of the symptoms in their severer forms, is sometimes so rapid that vision is irretrievably lost in a few days.

Causes. Direct mechanical irritation, whether from injuries inflicted accidentally, or in the performance of surgical operations; extension of inflammation from the neighbouring parts; exposure of the iris from wounds or ulcers of the cornea; the combined influence of light and heat; any undue or prolonged effort on the part of the eye, especially in viewing minute and brilliant objects; cold; and other less appreciable agencies, are the ordinary causes of iritic ophthalmia.

Prognosis. In recent cases, previously to the occurrence of any structural derangement, the prognosis is generally favourable; and even where the inflammation, though accompanied with contraction of the pupil and extravasation of lymph, is still confined to the iris, the patient often regains

an useful degree of vision; but when the disease has been of long duration, and has involved the investing membranes and internal parts of the eye, producing change of colour, thickening and corrugation of the iris, closure, or obstruction of the pupil, recovery is hopeless.

Treatment. The principal danger in iritis, arises from the effusion of coagulable lymph,—an occurrence which can only be prevented by the adoption of prompt and judicious measures. Venæsection should never be omitted when the state of the constitution will permit its employment, and the repeated abstraction of blood by cupping from the temples, and back of the neck, with an active cathartic in the beginning, and the rigid observance of the antiphlogistic system, will always be proper. It is in this disease that mercury most conspicuously displays its remedial powers, in preventing the deposition, and promoting the absorption of lymph; it should be early administered in such quantity as will place the system fully under its influence with the least possible delay, and it is sometimes necessary to continue its impression during a period of several weeks. Salivation is not absolutely required in every instance, but it generally produces a more decided effect upon the symptoms, and is therefore advisable whenever they assume a threatening aspect. Frictions over the brow and temples with belladonna and cantharides, (R. No. 50,) or the liniment hydrarg. comp. (R. No.

45,) blended with opium, are often useful in allaying the severity of the pain; anodyne fomentations (R. Nos. 16, 19, 21,) may also be prescribed with the same view, and particular attention should be directed to obviate the contraction of the pupil by means of belladonna, though it unfortunately happens that this narcotic exerts comparatively little influence over the membrane in its inflamed state. Counter irritation is inadmissible during the existence of the acute symptoms, but is an useful auxiliary after the active stage has subsided. MR. CARMICHAEL warmly recommends the oil of turpentine (R. No. 56,) when from any cause a substitute for mercury is desired, and its utility in such cases, has been confirmed by the testimony of others. Where the iritis has assumed a chronic form, and the patient has been much debilitated by the previous treatment, the sulphate of quinine is sometimes eminently serviceable; and if under these circumstances, there should be a congested condition of the external vessels, some gentle astringent or stimulating collyrium may be employed with advantage.

SUB-ACUTE IRITIS

Is sometimes merely the second stage of the preceding variety, but it may also occur as a primary affection, and where this is the case, the al-

teration in the colour and brilliancy of the iris, is usually first perceptible in its ciliary margin. The disease is tardy in its development, and commonly very insidious in its progress. There is often little redness or pain, and the patient complains chiefly of dimness of vision, which is sometimes so gradually and imperceptibly impaired, that, where the inflammation affected only one eye, the sight has been lost, before he was aware of his misfortune. When first consulted, the various morbid changes peculiar to iritis, can generally be detected in the iris and pupil, and lymphatic deposition may have already commenced, even at this early period. Sub-acute iritis is frequently complicated with inflammation of the membrane of the aqueous humour, evinces a strong disposition to relapse, and its terminations, when it has been permitted to continue long, are the same as those of the acute species.

The treatment consists in the employment of the remedies already designated for iritic inflammation—local depletion, mercury to the production of slight ptyalism, counter irritation, saline laxatives, colchicum, &c., &c.—to an extent commensurate with the urgency of the symptoms. The complaint in its present form is often extremely unmanageable, and as it is frequently associated with depraved states of the constitution, it is important to ascertain the particular diathesis

in which it appears, in order that the means to be instituted for its cure, may be regulated accordingly.

SYPHILITIC IRITIS.

Inflammation of the iris is not an uncommon occurrence among the secondary symptoms of syphilis, and is also observed in connection with the various syphiloid eruptions; in the former case, it may either precede the other constitutional affections, or make its appearance simultaneously. It is said to be more frequently observed after chancre which has been cured without mercury, than under opposite circumstances. Writers have attempted to discriminate between this, and the other varieties of iritis, but the local symptoms are not sufficiently distinctive to afford any very certain ground of diagnosis. It is supposed to be more particularly characterized by the insidiousness of its approach, the brownish hue of the vascular zone around the cornea, the greater severity of the nocturnal paroxysms, and the peculiar irregularity of the pupil, which is frequently drawn in an angular direction towards the nose. The deposition of minute globular or convex masses of lymph, of a reddish brown or cinnamon colour, is another sign which is described as pathognomonic

of this form of iritis; these little globules are usually observed around the pupillary margin, but may also be situated beneath the serous covering of the iris; in the latter case, they assume more or less of a hemispherical shape, and consequently encroach upon the anterior chamber. In numerous instances, however, no such tubercles appear at any period, and they are never seen in the earlier stages of the inflammation.

In the progress of the disease, the lesser circle of the iris becomes thickened, corrugated, and inverted, and the membrane of the aqueous humour being inflamed to a greater extent than in simple iritis, its secretion becomes turbid, and the cornea also sooner grows nebulous. The symptoms above enumerated, may excite a well founded suspicion of the nature of the complaint, but the history of the case will afford the surest diagnosis; any difficulty, however, which may arise in establishing this point is the less to be regretted, inasmuch as the treatment differs in no respect from that prescribed for idiopathic iritis.

RHEUMATIC AND ARTHRITIC IRITIS.

By some authors, the several varieties of iritis are described with great minuteness of detail, but, as has just been intimated, the distinguishing features are not very strongly marked, and for the

most part, it is only from our knowledge of the constitutional predisposition of the patient, or other circumstances connected with his history, that an opinion can be formed of the nature of any particular case. When iritis occurs in rheumatic, or arthritic subjects, the vessels of the conjunctiva, especially after the disease has continued for some time, become enlarged and varicose, and the corneal wreath has a deep livid hue, almost approaching to a purple; there is also greater liability to inflammation of the posterior tunics, and the irregularity of the pupil is said more frequently to assume an oblong deviation. With these exceptions, it does not appear to differ from the preceding forms, unless it be in its greater tendency to relapse, which renders the prognosis in the arthritic variety—fortunately less frequent in its occurrence—more unfavourable than in any other.

Treatment. The antiphlogistic plan is equally proper here, as in the other forms of iritis, regard being had to the constitutional origin of the disease, and the enfeebled condition of the system with which it is frequently associated. Mercury is less decidedly useful in arthritic iritis, but much advantage is, nevertheless, derived from its employment as an alterative, in conjunction with remedies which tend to improve the vitiated condition of the chylipoietic viscera. In the rheumatic variety, which rarely occurs as an idiopathic affection, it displays its wonted influence; but more than ordinary care

is required to guard against relapse. Medicines which promote the renal secretion are more particularly indicated in these cases; and the tincture of colchicum, variously compounded with articles of similar tendency, may frequently be prescribed with much advantage. In persons of irritable or impaired constitutions, an invigorating treatment is demanded, and the sulphate of quinine, the preparations of iron, the oil of turpentine, the volatile tincture of guiacum, &c., according as circumstances may lead to the preference of either, are often serviceable. Counter irritation also is an important auxiliary.

STRUMOUS IRITIS.

Inflammation of the iris, like the same process in other parts of the body, is not unfrequently modified by the scrophulous diathesis; and this modification is the form under which the disease most commonly appears in childhood. It is usually caused by the extension of morbid action in strumous corneitis, and when this is the case, the opacity of the cornea may be so considerable as to obscure the iris, and much mischief produced before the implication of that membrane is discovered;—this is the more likely to happen from the circumstance that some of the symptoms,—the zonular redness, pain, and impaired vision—

are common to both affections. The condition of the iris should therefore be carefully inspected in every instance, and local depletion, purgatives, mercury exhibited with a view to its alterative action, and the external employment of belladonna, early resorted to, in conjunction with counter irritation, and the appropriate remedies for strumous ophthalmia. The sulphate of quinine, the preparations of iron, &c., are equally proper here, as in inflammation similarly modified affecting the other tissues; and often produce the happiest results.

PROLAPSUS OF THE IRIS.

Prolapsus of the iris is a common occurrence after wounds, ulcers, rupture, or sloughing of the cornea, and is generally attended with severe pain from the constant irritation to which the exposed membrane is subjected. When the protrusion takes place as a consequence of the two causes last mentioned, the opening which they occasion is generally large, and the iris assumes the form of a convex, dark coloured tumour, which sometimes attains a considerable magnitude. The treatment consists in the application of belladonna to the eyebrow, and the occasional employment of the nitrate of silver in substance or strong solution, with the view of allaying the extreme

sensibility of the part, and promoting its retraction.

The palpebræ should be covered by a compress moistened with some refrigerating lotion, rest procured by the preparations of morphia, and appropriate measures instituted in all cases, to moderate the inflammation. If the iris protrude through the edges of a recent wound, it may be gently replaced with the blunt extremity of a probe, but where there has been any considerable loss of substance, as from ulceration, any attempt of this kind would be improper; since under such circumstances, it effectually closes the aperture, and is the means adopted by nature to preserve the form of the organ. In staphyloma iridis, an operation may become necessary in order to relieve the sympathetic irritation in the sound eye, and is performed as in the kindred affection of the cornea.

There are several other diseases of the iris, of which the limits assigned to the present work will permit only a very cursory notice. Paralysis occurs from various circumstances affecting the ciliary nerves, and fungous excrescences sometimes grow from its surface without any assignable cause; they evince no malignancy of character, are unattended with any appreciable degree of inflammation, and frequently yield to the influence of mercury. There are also congenital deficiencies or aberrations in its colour, and in the appearance of its pupillary margin. Occasionally it is entirely

absent, and the cordiform division denominated coloboma iridis, is a common occurrence. The fissure is usually situated at its inferior portion, and there is reason to believe that in some instances it is continued through the choroid and retina.

ARTIFICIAL DILATATION OF THE PUPIL.

The artificial dilatation of the pupil by the local application of narcotics, is a practice of comparatively recent origin, and may justly be ranked among the modern improvements in this department of surgery. The credit of the discovery is due to DR. SAMUEL COOPER, by whom it was announced to the Profession, in an inaugural dissertation on the properties and effects of the *datura stramonium*, presented to the Medical Faculty of the University of Pennsylvania in 1797. DR. COOPER's experiments were limited to the article just mentioned, but subsequent investigation has proved that the same property is possessed by the *atropa belladonna*, the *hyosciamus niger*, and the *lauro-cerasus*. It constitutes a resource of great practical utility under a variety of circumstances,—in the internal ophthalmiæ frequently enabling the surgeon to preserve vision which would otherwise have been lost; supplying a palliative remedy—the more valuable that its effects are not diminished by repetition—in many cases of cataract,

contraction of the pupil, and central opacity of the cornea; while it is of scarcely inferior importance in facilitating operations on the eye, and assisting the diagnosis in a multitude of diseases. The belladonna is most frequently employed, the extract being softened with water, and applied to the upper lid, and over the brow for the space of one or two hours. A filtered solution, in the proportion of a scruple to an ounce of distilled water, dropped into the eye, is more powerful in its operation, but is also more liable to excite irritation. According to REISINGER, atropine and hyosciamine, the active principles of two of these plants, evince still greater power,—a single drop of a solution containing one grain of the latter, producing extreme dilatation, which in one instance continued for seven days. An ingenious explanation of the *modus operandi* of these substances is given by MR. WALKER. He supposes that the branches of the third and fifth pair of nerves which unite to form the lenticular ganglion, preside respectively over the dilatation and contraction of the iris; the former being appropriated to the radiated, and the latter to the circular or orbicular fibres. Filaments from the same division of the Fifth, are also distributed to the palpebræ and forehead, and through this nervous communication the narcotic influence is propagated to the sphincter fibres of the iris, which, by their extreme delicacy of structure, and the absence of any fixed attachment, are rendered lia-

ble to paralysis from a degree of narcotism which would not otherwise be perceptible. The contraction of the orbicular fibres being thus temporarily suspended, while those supplied by the Third Pair preserve their vitality unimpaired, the antagonism is destroyed, and dilatation is of course the result.

It is generally believed that the action of the iris is dependent upon the retina, though there are several well known phenomena—its frequent mobility in amaurosis, the opposite condition of fixed and dilated pupil without loss of vision, its invariable activity in uncomplicated cataract, however densely opaque, and its state of contraction during sleep, when the functions of the retina are suspended,—which are quite inexplicable upon this supposition. From these circumstances, together with the absence of any nervous communication, and other considerations drawn from pathology and comparative anatomy, evincing an analogy and mutual relation between the iris and palpebræ, and proving the sensibility of the anterior part of the eye to the impression of light, MR. WALKER infers that the iris performs the part of an internal eyelid, and that sensibility to light, and vision, are two distinct attributes, possessed by different portions of the organ; the former being derived from the Trigemini, and residing in the iris and exterior of the eye, while the latter is the peculiar function of the retina through the optic nerve.

ARTIFICIAL PUPIL.

When vision is destroyed by partial opacity and staphyloma of the cornea, or by permanent contraction of the iris, whether simple, or complicated with adhesion to the cornea or capsule of the lens, cataract, or obstruction of the pupil from extravasated lymph, the unfortunate patient may still be permitted to entertain a hope of its restoration from the formation of an artificial pupil, provided the condition of the several structures be such as to warrant the performance of an operation for this purpose. In recent cases of closure or obstruction of the pupil, the persevering application of belladonna, in conjunction with the internal exhibition of mercury, and the steady employment of the appropriate remedies for opacity of the cornea when the defect arises from this cause, will often produce a considerable improvement, though the morbid changes may be so extensive as to have appeared beyond the reach of art. In some instances also, of central opacity and partial synechia anterior, where there is no longer any prospect of amendment from such treatment, an useful degree of vision may be obtained by the daily use of the narcotics above mentioned. But where these measures are either inapplicable, or have been tried without effect, an operation is the only resource. As conditions indispensable to its success, the pa-

tient should be able to distinguish light from darkness, the globe free from any general disease, the iris not materially altered from its healthy structure, and all traces of inflammatory action must have disappeared. It is improper for obvious reasons, if one eye only is lost; and when useful vision is destroyed in both, that which is most perfect should be selected for the operation.

The situation of the proposed aperture will also require consideration. When the operator has the power of selection, the centre of the iris is the most eligible position, and the nasal, is generally preferred to the temporal division, though the latter is recommended by MR. GIBSON as being the most convenient for the surgeon; in many cases, however, there is no alternative, and the opening must be formed behind the transparent part of the cornea wherever that may be.

The numerous operations for artificial pupil, which have at different times been invented, may all be referred to three principal classes;—corotomia, or the simple incision of the iris; corectomia, or the excision of a portion of that membrane; and corodialysis, or separation from its ciliary attachment.

Corotomia. This operation appears to have been first introduced by CHESELDEN; but though successfully performed by him in several instances, it has not realized the expectations which others had been thereby induced to entertain of its general utility.

It is predicated upon the contractility of the radiated fibres of the iris, and where this property has been destroyed, by inaction from long continued closure of the pupil, interstitial deposition, or other effects of inflammation, no separation will follow its division. It is, therefore, not improbable that disappointment may have often arisen from inattention to this circumstance, and the consequent indiscriminate performance of the operation in all states of that membrane.* It should not be adopted when either of the above mentioned conditions are present, or where there is any considerable departure from the healthy structure of the iris, but in recent cases of closure of the pupil, and in partial synechia anterior, the greater portion of the cornea being transparent, and the iris apparently stretched between the points of attachment and adhesion, it is perhaps preferable to any other mode. It is performed by introducing the iris knife through the sclerotica, near its junction with the cornea, and piercing the iris at the distance of a line from its ciliary margin; the point of the instrument is then carried across the anterior chamber in front of the iris, penetrates the corresponding point on the opposite side, and the division of the intervening part is effected by a compound

* Vide a report by M. M. CHAUSSIER, DUMERIL, and BOYER, a committee of the Academie Royale de Medecine, on DR. FAURE'S Memoirs on Artificial Pupil.—*Jour. of For. Med.* 1828.

motion in withdrawing the instrument. The chief difficulty arises from the facility with which the iris yields before the pressure necessary to divide its texture, and caution is also required to avoid separating it from its ciliary connections. The scalpel of SIR WILLIAM ADAMS is not well adapted for this purpose, and in some late operations at the WILLS HOSPITAL, an instrument, narrower in its blade, and resembling a sharp pointed bistuory, was advantageously employed instead.

When the case is complicated with cataract, the capsule and lens may be divided at the same time; or if these parts should become opaque in consequence of the injury unavoidably inflicted during the operation, they must be removed at a subsequent period.

CHESELDEN's operation was subsequently modified by MAUNOIR in the following manner: a puncture having been previously made in the cornea, involving about one-fourth of its circumference, the operator introduces a pair of fine scissors, perforates the centre of the iris with the pointed blade, and passes it along the posterior surface, until the other reaches the junction of the cornea with the sclerotica; the membrane is then divided in its transverse diameter, and another incision is immediately made, diverging from the first so as to include a triangular portion, the apex of which terminates in the centre of the iris. The part thus insulated retracts towards the ciliary border, and

leaves an opening which admits sufficient light for the purposes of vision. This operation is alike applicable to closure of the pupil, and central opacity of the cornea, and possesses an advantage over some others, in that the newly formed aperture is not situated directly opposite the incision in the cornea.

Corectomia. In MR. GIBSON'S operation, which is perhaps the best that has been devised, an incision three or four lines in length, is made in the cornea, immediately in front of its junction with the sclerotic; the aqueous humour escapes, and is usually followed by a slight protrusion of the iris, which should be increased by gentle pressure on the upper and inner part of the globe, until the prolapsus attains the size of a pin's head; when it must be removed by means of the curved scissors. It may happen, however, that the iris does not readily protrude; and where this is the case, a hook should be introduced, the membrane drawn forward, and a sufficient portion excised as before. If adhesions have formed, as in synechia anterior, they must be separated, as far as practicable, with the point of the knife employed to puncture the cornea; but when they are extensive, it will be preferable to perform a previous operation for that purpose. In some instances, it may be expedient to introduce the scissors through the incision in the cornea, and excise a portion of the iris while it remains in situ; the part thus detached to be afterwards removed by

the forceps. This operation is especially applicable to those complications, in which closure of the pupil is combined with cataract and synechia posterior; and in such cases the lens should be previously removed by absorption or depression.

Another method, first practised by WENZEL, consists in making an incision through the cornea, as in the operation for cataract by extraction, the knife being simultaneously passed through the iris so as to form a flap of smaller dimensions in that membrane, which must be subsequently excised by the scissors introduced for the purpose; or two incisions may be made in the iris by the scissors, including a triangle, as in MAUNOIR's operation, except that in this instance, the base is reversed, and corresponds to the division made by the knife. The operation by excision is adapted to closure of the pupil, whether uncombined, or complicated with opacity of the cornea.

Corodialysis. The formation of an artificial pupil at the circumference of the iris, was originally suggested by the accidental separation of that membrane from its connections with the ciliary ligament. The operation is performed, by introducing a curved cataract needle through the sclerotica at the external canthus, and carrying it with its convexity forward across the posterior chamber, till it reaches the upper and inner part of the iris; which it perforates about the fourth of a line from its ciliary

border, and the separation is effected by pressing the point, thus entangled, in a direction downwards and outwards. Subsequent experience having shown that the opening formed in this way soon became obliterated, it was proposed by REISINGER to draw the detached portion of the iris through a puncture in the cornea, and either leave it there to contract adhesions with the edges of the wound, or remove it by excision. The operation is performed in the following manner: an incision one or two lines in length, having been made near the centre of the cornea, a hook is introduced by which the iris is engaged near its ciliary border, detached from its connections, and cautiously drawn out, until a pupil of sufficient magnitude is produced.

Corodialysis may be appropriately performed where only a small segment of the cornea remains transparent, the incision being made through the opaque portion. Its combination with corectomia occasions less irritation than with iridencleisis or strangulation, and is exclusively applicable to cases of synechia anterior, or staphyloma, where only a third part of the iris remains unadherent.

Blood is generally effused in considerable quantity, and more or less inflammation always occurs after these operations. A strict observance of the antiphlogistic regimen should therefore be enjoined, and inflammation averted, or arrested by the prompt employment of the appropriate remedies.

DISEASES OF THE CRYSTALLINE AND CAPSULE.

CAPSULITIS.

INFLAMMATION of these parts is described with great minuteness of detail by the German writers, who even pretend to discriminate between the affection of the lens and either hemisphere of its membranous envelope. The symptoms, however, are generally so obscure, that the actual presence of the disease is seldom recognised, and for the most part, it is known only by its effect in destroying the transparency of the tissue in which it is seated. It is commonly associated with some degree of iritis, and according to WALTHER, usually occurs about the middle period of life, and in persons of cachectic constitution. In its complicated form, capsulitis is accompanied with slight intolerance, and dimness of vision; the pupil is contracted, approaches more or less to an oval outline, its motions are sluggish and limited in extent, the iris loses its brilliancy, and a dark or reddish brown tinge, is perceptible around its interior circle. When the pupil is dilated by belladonna, red vessels may be observed running upon the capsule, and with the aid of a magnifier, a much greater degree of vascularity can be discovered. The minute arteries are arranged in a beautiful manner; forming

a wreath composed of a series of vascular arches, from which vessels pass towards the centre of the membrane, where they again ramify so as to constitute a plexus of similar character.

When the disease is more strongly developed, the vascularity is sometimes so considerable as to exhibit an uniform redness, and in such cases, the capsule occasionally presents a flocculent grey, or brownish appearance, from the deposition of lymph. The inflammation is tardy in its progress, the pain trivial and felt chiefly above the brow, objects appear as if seen through a fine gauze, and vision, impaired from the beginning, gradually becomes more indistinct and confused. Lenticular cataract, thickening and opacity of the capsule, or effusion within its cavity, may be enumerated among the consequences of capsulitis.

As might be anticipated, the inflammation of a part thus isolated in its relations, is little influenced by any remedies we may employ; when it is detected sufficiently early, the local abstraction of blood, mercury, counter irritation, belladonna, &c., constitute the appropriate treatment; it rarely happens, however, that they are followed by any beneficial result, and the resources of art are principally displayed in the removal of its ordinary consequences,—opacity of the capsule and lens.

CATARACT.

An opaque condition of the crystalline, and its capsule is denominated cataract. When the opacity is seated in the lens, it is called lenticular cataract; capsular, when the membrane only is opaque; and capsulo-lenticular, when both are combined. The several varieties of these principal divisions, are still further distinguished by names descriptive of their appearance, or some other circumstance connected with them.

The principal symptom in the incipient stage, is indistinctness of vision, which gradually increases from a dimness, apparently caused by a mist or smoke enveloping every object, to a state of almost total blindness. On examination, the lens is observed to be more or less opaque, and the opacity augments in proportion as the sight is impaired. It is most considerable in the centre, and when fully formed, presents a densely white, grey, or amber hue, which is sometimes strongly contrasted with an appearance as of a black ring encircling its circumference. This phenomenon is caused by the shadow of the iris, and varies in breadth and distinctness, according to the distance, colour, and consistence of the cataract. Vision is always more perfect when the pupil is dilated, as in the shade, or at the approach of evening; and the patient is generally able, even in the worst cases, to

distinguish light from darkness. When the disease is uncomplicated with any other affection, and the size of the lens does not interpose a mechanical obstacle, the iris preserves its activity unimpaired, contracting or dilating according to the intensity of the light. The opacity is generally slow in its progress, requiring months and sometimes years for its full development; instances, however, are occasionally met with, in which it is produced in a much shorter period, and such is always the case where it originates in local injury. When it occurs in one eye, the other usually becomes affected soon afterwards.

Cataracts vary in consistence from bony hardness to entire fluidity. Hard lenticular cataract is seen principally in advanced life, and may be recognised by its brownish or amber tint; the opacity commences in the centre of the lens, which is rather smaller than natural, and is situated at some distance from the pupil, leaving the iris free and unimpeded in its action; the annular appearance caused by the shadow of the uvea, is quite perceptible, and in the dusk of evening, or when the pupil is dilated by belladonna, the patient can discern objects pretty distinctly. The soft or fluid cataract is large, prominent, and more completely fills the pupil, being either in actual contact with, or in close proximity to the iris; it is the form in which cataract usually appears before the middle period of life, and is readily distinguished by its

greyish, bluish-white, or milky colour, which presents a striking contrast with the darker hue of the iris. In the more fluid species, small dots, streaks, or inequalities, are occasionally observed, which vary their shape and position at different times. All the varieties of lenticular cataract commence with dimness of vision, and inability to distinguish objects unless viewed obliquely, or brought close to the eye; their outline first becomes confused, and the cloudiness increasing as the disease advances, the patient, in many cases, is merely sensible of the impression of a strong light.

In anterior capsular cataract, the opacity is convex, and presents a pearly or silvery whiteness; it is situated nearly on a level with the pupil, and is often striated, marbled or otherwise variegated. It begins at different parts of the capsule, and not unfrequently towards its circumference; vision is less impaired than in the lenticular variety, and the dark ring encircling its periphery is almost always visible. If the posterior hemisphere is affected—an occurrence which rarely happens while the lens preserves its transparency—the opacity is concave and deeply seated, and has a dull yellowish hue, instead of the glistening white, which characterizes the affection of the anterior portion. When the capsule is generally opaque, the lens is always involved, and this complication usually exhibits the same pearly and striated appearance, which has just been mentioned as distinctive of anterior cap-

sular cataract; the duller and more equable opacity of the crystalline may sometimes be perceived through the interstices of the striæ, and in early life the cataract is occasionally so large as to press forward the lens, and encroach upon the cavity of the anterior chamber. Under such circumstances, the pupil is immoveable, and the dark shadow entirely wanting. At a more advanced age, the consistence of the lens is greater; it does not lie so closely in contact with the iris, the pupil is somewhat dilated, and its mobility unimpaired, but the annular appearance is rarely very distinct. Differences more or less apparent, distinguish also the other forms of cataract, but in a work like the present, allusion can only be made to a few of the peculiarities which mark some of the chief divisions.

The disease is not unfrequently complicated with other affections, such as amaurosis, synechia anterior, closure of the pupil, glaucoma, and a disorganized condition of the vitreous humour. For some of these—amaurosis and glaucoma especially—it is liable to be mistaken during its formative period, and the error is the more unfortunate, inasmuch as it prevents the adoption of the appropriate treatment for those diseases, when alone it could be successfully employed. In amaurosis, the opacity, or rather the paleness, is more deeply seated, and has a turbid or horny appearance; it bears no proportion to the decline of vision, the patient being almost or quite blind, though the obscuration

is hardly perceptible. The pupil is generally dilated, not unfrequently somewhat irregular, and the iris scarcely, if at all movable. It is more usually accompanied by an appearance as of *muscæ volitantes* or dark spots before the eye, than of a mist or gauze, which attends the formation of cataract. In the latter affection, vision is always more perfect when the pupil is dilated, either artificially, or on the approach of evening; while in amaurosis, the temporary increase or diminution of sight, depends upon causes which excite or depress the system, and is not influenced by the state of the pupil; amaurosis, moreover, is accompanied by other symptoms—vertigo, headach, scintillations, &c.—which are seldom observed in conjunction with cataract. It is only, however, in the incipient stage of these diseases, or when they exist in combination, that there can be any difficulty in establishing the diagnosis, for when fully developed the characteristics of each are sufficiently apparent. In glaucoma also, the opacity is more deeply seated, has a concave appearance, is more extensively diffused, and exhibits a dull, dingy green, or dirty yellowish discolouration. The patient can see better in a strong light, and vision, as in amaurosis, bears no correspondence with the degree of opacity, being often nearly destroyed, though the cloudiness of the pupil is scarcely present to an appreciable extent. There is generally more or less pain and uneasiness, the globe is tense and firm

to the touch, and frequently has an unhealthy aspect. The mobility of the iris is either greatly impaired, or altogether destroyed, and this membrane is frequently pressed towards the cornea, so as to exhibit an arched appearance on its anterior surface. In all these cases, the diagnosis may be greatly assisted by the artificial dilatation of the pupil, and by concentrating upon it the rays of light by means of a double convex lens.

Causes. In common with other parts of the body, the crystalline undergoes alterations as life advances, which renders it less fitted for the proper performance of its functions; its convexity diminishes, and its colourless transparency gradually verges to a yellow or amber tint. This deviation alone, may be sufficient in some cases, to impair vision, but the opacity which constitutes cataract, is more commonly owing, when it occurs under such circumstances, to defective nutrition from the changes which are going on in the vascular system, and which are early manifested in the delicate organization of the lens and its capsule. Injury of these parts, however slight, is a very common cause, and the crystalline may even become opaque from the mere contact of the aqueous humour. In many instances the opacity is wholly unconnected with inflammation, but that the reverse also frequently happens, is evident from the affections with which it is complicated, and the circumstances which are said to engender a predisposition to the

complaint; thus it arises from wounds, exposure to intense light and heat, determination to the head, and general plethora, whether from habitual indulgence, or the suppression of customary evacuations. In some cases, its formation is attended with aversion to light, a sense of heat, and other indications of vascular excitement. PETIT states, that of three hundred cases of cataract which came under his observation, two-thirds occurred in persons who had been accustomed to much exercise of their eyes in a strong light. The disease is very frequently congenital, and numerous examples are also recorded of its hereditary origin.

Treatment. The expectation of arresting the progress of cataract, or, after opacity has taken place, of restoring the transparency of the tissues by medical treatment, having been, in this country at least, altogether abandoned, the only remedy consists in the removal of the opaque body from the axis of vision, by means of a surgical operation.

Previously, however, to resorting to such a measure, there are several preliminary questions which require consideration, and of these one of the most important, is the frequent complication with amaurosis and other affections, which often exists to such a degree as to render the operation entirely nugatory. The surgeon should therefore be extremely guarded in his prognosis, for the state of the parts posterior to the opaque crystalline, cannot be accurately determined, and the

disappointment is always proportionate to the importance of the object, and the strength of previous expectation. The patient should be exempt from the actual presence of any constitutional disorder, such as gout, rheumatism, and scrophula; and also from any disease of the eyelids which might exert an injurious influence. No operation should be undertaken during the existence of ophthalmia, and prudence will dictate the propriety of correcting any gastric derangement, and of adopting preparatory measures to avert, or moderate inflammation; a restricted diet, saline laxatives, and, if there be any undue plenitude of the vascular system, venæ-section, may often be advantageously employed with this view. It is, in general, improper to interfere while there is any degree of useful vision, and it is also deemed inexpedient to do so, when one eye only is affected. In the case last mentioned, however, when the removal of the cataract is particularly desirable, on account of the deformity which it occasions, there can be no valid objection to the performance of an operation; and if symptoms are present, indicative of its incipient formation in the healthy organ, their further progress may possibly be thereby arrested. It is customary to operate upon one eye only at a time, and this caution is especially applicable to cases of extraction.

The operation is performed in three different modes,—extraction, depression, and division or

solution,—each of which possesses advantages which may render it eligible under certain circumstances. In this country, the operation by solution is generally preferred; it is well adapted to the removal of soft or fluid cataract, the usual form in which the disease appears in early or middle life, requires little manual dexterity, is attended with less danger to the eye than either of the others, and may be employed in a multitude of cases where extraction is inapplicable. The principle on which it is founded, is the solution of the lens in the aqueous humour, admitted through an opening in the capsule. The pupil having been previously dilated by the agency of belladonna, and the patient placed in a supine position supported by pillows, an assistant retracts one of the lids, while the surgeon takes charge of the other, and introduces a sharp-edged needle—slightly curved at the point, and considerably shorter than that recommended by SCARPA—through the sclerotica, a little above its transverse diameter, and about a line from the cornea. The point of the instrument having been directed towards the centre of the eye while piercing the sclerotica, is now brought forward, and carried across the posterior chamber, beyond the middle of the iris, when its cutting edge is turned towards the opacity, and the capsule with the crystalline, gently divided into several pieces; in performing this part of the operation, it is advisable to raise the needle repeatedly

clear of the cataract, and re-enter it again in a different direction. If the lens happen to be fluid, it escapes immediately on the division of the capsule, and is diffused through the aqueous humour; and where it is of firmer consistence, small fragments are often observed floating through the chambers. In some instances, a single operation may suffice, but more commonly it is necessary to repeat it once and again, after the lapse of a proper interval; on these subsequent occasions, the crystalline should be more completely comminuted, and the fragments passed into the anterior chamber, where their solution takes place more rapidly; care being taken to avoid, if possible, the posterior hemisphere of the capsule.

Keratomyxis, or the introduction of the needle through the cornea near its margin, is also frequently practised, and as it is easily performed, occasions little pain, and is fully adequate to the cure of the disease, it is particularly applicable to cataract as it occurs in childhood; in very early infancy, the thickness of the cornea, and the consequent proximity of the iris, may, perhaps, constitute valid objections to its employment. Less injury is thus inflicted upon the organ, and keratomyxis is, therefore, sometimes resorted to, on the first occasion in adults; but the surgeon has not such entire command over the needle as when it is introduced through the sclerotica, and the diffi-

culty of breaking up the lens, renders it less adapted to the performance of the subsequent operations.

When it is desirable to avoid the delay attendant upon the slow process of absorption, or when the irritation caused by the broken fragments of the lens, gives rise to chronic ophthalmia; it has been recommended to puncture the cornea near its temporal margin, and remove the cataract, softened by the contact of the aqueous humour, with the aid of the curette. This operation is extensively practised by MR. GIBSON at the MANCHESTER Infirmary; and is adopted also by MR. TRAVERS, who dispenses, however, with the previous employment of the needle.

The operation for congenital cataract, differs in no very material respect from that just described. It is important that the obstruction should be removed without unnecessary delay, as the sensibility of the retina is weakened by disuse, and the patient early loses his control over the motions of the eye; perhaps the age of six or eight months, before dentition has fully commenced, may be assumed as the most eligible period,—many surgeons, however, prefer operating during the second year. As the lens in these cases possesses comparatively little consistence, its fragments are less liable to excite irritation, and may be, therefore, at once brought forward into the anterior chamber.

An opaque capsule frequently remains after the

absorption of the crystalline, whether this occurs spontaneously or otherwise, obstructing the pupil, and requiring an operation for its removal. Congenital cataract often exists in this form, the lens having been either partially, or entirely removed. The best operation under these circumstances, is extraction through a small incision in the cornea; or the needle being introduced through the sclerotic, an attempt may be made to detach the capsule from its ciliary connections throughout the upper and greater part of its circumference, and afterwards depress it below the level of the pupil; in some instances it may be sufficient to cut it into pieces with the point of the instrument, but this manœuvre is rarely successful.

DEPRESSION.

Depression of the crystalline into the vitreous humour below the axis of vision, is another mode resorted to for the removal of cataract, and like the operation by solution, has the advantage of being easily performed. The pupil having been previously dilated by belladonna, a bandage applied over the sound eye, and the patient placed in the posture already described, the needle is introduced through the sclerotic as before, with its convexity upwards, and carried onward through the posterior chamber, until the point is just concealed

behind the superior and nasal portion of the pupillary margin; the instrument is then turned upon its axis, so that its concavity is applied to the upper border of the lens, and pressed upon that body in such manner, as gradually to remove it, in a direction obliquely downwards and outwards, till it is no longer visible through the pupil; which will have been accomplished, when the handle of the instrument is brought into a direction parallel with the transverse diameter of the eye. The needle being held for a moment in contact with the lens, the more certainly to retain it in its new situation, is then to be brought into the anterior chamber, and gently moved around, so as freely to lacerate the capsule, if it have not previously been ruptured; otherwise it may be withdrawn immediately. When this operation is properly performed, the crystalline and capsule are depressed together, or the lens alone escapes through a fissure in the posterior hemisphere of its envelope; but it happens also, not unfrequently, that the cataract, preserving its relations with the vitreous humour, merely revolves with that body, detaching it from its connections with the ciliary processes, rupturing the minute vessels by which it is nourished, and being moreover, extremely liable to resume its position when the depressing force is discontinued. To obviate this, MR. WATSON directs a breach to be made, as a preliminary measure, in the posterior portion of the capsule and in the vitreous humour, for the

escape and reception of the lens; the point of the needle is then to be carried over its upper edge, the anterior hemisphere lacerated, and the crystalline depressed below the axis of vision.

Reclination is merely a modification of this operation, and is preferred by many surgeons, inasmuch as the lens thus depressed, is less likely to injure the retina, or to re-appear behind the pupil. The needle is introduced as before, but instead of being elevated to the summit of the lens, is merely raised above its transverse diameter; the operation is completed by bringing the handle of the instrument in an oblique direction forward, and so displacing the crystalline, that its superior margin is turned backwards into the vitreous humour; its anterior surface looking upwards, and being on a level with the inferior edge of the pupil.

In false cataract caused by lymphatic deposition, an attempt may be made to destroy its adhesions with the iris, and afterwards recline or depress the lens; or, if the pupil can be sufficiently dilated, it may be removed by extraction.

The operation of depression has been superseded in a great measure by that of solution, which has been found much more extensively applicable than was anticipated at the period of its introduction. It is still, however, not unfrequently employed, and particularly in the hard amber-coloured cataract of advanced life, which resists the action of the needle, and does not readily dissolve in the

aqueous humour. The chief dangers to be apprehended from it, are chronic inflammation, amaurosis from pressure upon the retina, and disorganization of the vitreous humour;—evils which have probably been exaggerated by the exclusive advocates of extraction, since a comparison of the results afforded by the two methods, is by no means unfavorable to the operation by depression.

EXTRACTION.

Though the advantages of extraction have been vividly portrayed by its friends, there are reasons which will ever prevent it from being practised by the great body of the Profession. It is both complicated and difficult, requiring more than an ordinary degree of resolution and steadiness on the part of the patient, and greater experience and manual dexterity than can be expected from the generality of surgeons, who have few opportunities of witnessing, or performing such operations. It is adapted to hard lenticular, or thickened capsular cataract, and demands, as conditions favourable to its success, a prominent eye, large anterior chamber, a cornea of ample dimensions, and a due degree of constitutional or reparative power. The pupil having been previously dilated, the patient so placed in a recumbent position that the light may fall upon the eye from a convenient

direction, and the upper eyelid properly elevated by an assistant, the surgeon steadies the globe with the index and middle fingers of one hand, while with the other—holding the instrument with the fingers contracted, so as to admit its propulsion without requiring the movement of the whole hand—he introduces the point of the knife perpendicularly to the cornea, about one fourth of a line from its circumference, and a little above its transverse diameter; having fairly penetrated the membrane, he depresses the handle towards the temple of the patient, and carries the blade horizontally across the anterior chamber, until it reaches the corresponding point on the opposite side, through which it is to be steadily passed, and the section of the cornea completed by the progressive motion of the instrument. This stage of the operation being finished, the lids are closed for a brief period, in order to lessen the contraction of the pupil, and quiet the irritability of the organ. The next object is to open the anterior hemisphere of the capsule; with this view, the superior palpebra is raised as before, and the surgeon depresses the lower lid, pressing it gently against the globe to favour the advancement of the cataract, and also that he may the more readily introduce the sharp extremity of the curette through the incision in the cornea. The capsule having been sufficiently divided by repeated crucial incisions, this instrument is carefully withdrawn, and the palpebræ again allowed to close for

a few minutes. If its envelope have been sufficiently lacerated, the crystalline sometimes follows immediately, but when this does not happen, the eye must be again uncovered, and the pressure renewed through the medium of the lower lid, until the lens is observed to enter the pupil, from which moment to the complete exit of the cataract, it must be gradually diminished. If the crystalline should be arrested between the divided edges of the cornea, in consequence of too small an incision in that membrane, its escape may be facilitated by means of the curette; but in this part of the operation, the utmost caution is required to prevent the loss of the vitreous humour. The opaque lens having been removed, the patient is requested to close his eyes as if about to sleep, and the operator having subsequently ascertained that the edges of the incision are in accurate adjustment, the lids may be secured by a strip of court plaster, or simply covered by a fold of linen moistened with cold water, and left undisturbed for two or three days. Very considerable inflammation generally follows the operation, and must be subdued by the prompt employment of the appropriate remedies. The patient should be confined to bed in a darkened room for the first week, and carefully watched by an experienced assistant.

When the lens has been absorbed, and the opaque and thickened capsule alone remains, a much smaller incision may be made in the cornea, the

hook or forceps introduced, and the membrane in general, easily removed.

A comparison of the results furnished by the different modes of operating for cataract, leaves no doubt as to their relative value. Of three hundred and six cases of extraction at LA CHARITE, the cures were in the proportion of two and a half to one; while of an equal number depressed by DUPUYTREN at the HOTEL DIEU, they were more than five to one. Of seventy operations by extraction, forty-three by displacement, and twenty-one by keratonyxis, performed at the institution last mentioned between the years 1806 and 1810, the successful cases were respectively nineteen, twenty-four, and seventeen. The native Hindoos practice a rude method of depression, through a puncture previously made with a lancet, and of seventy-seven operations thus performed, the cures were as two and a half to one.

As in all the operations for the removal of cataract, inflammation is the principal consequence to be dreaded, precautionary measures are proper in every instance, and attention should likewise be directed to prevent the contraction or adhesion of the iris, by the occasional application of belladonna. In the internal ophthalmia, termed by DUPUYTREN inflammation of the retina, which not unfrequently follows the operations of depression and solution; that gentleman was accustomed to employ, in addition to the usual antiphlogistic remedies, the pow-

der, or extract of belladonna; to the extent of three, eight, or twelve grains of the one, and three or more of the other, given in divided doses every two hours. He bears testimony to the efficacy of this treatment after an experience of ten years.

The refractive power of the eye being necessarily diminished by the loss of the crystalline, it becomes necessary to supply its place by artificial means, and glasses are usually required, both for near and distant vision, with foci respectively, of two and a half, and four and a half inches. They should never be employed while any degree of inflammation remains, generally not within two months after the operation, and then only occasionally.

DISEASES OF THE HUMOURS.

HYDROPTHALMIA.

Dropsy of the eye may be caused by an increased secretion either of the aqueous, or vitreous humour. When it arises from the former, the cornea appears rather prominent in the beginning, but soon becomes flattened, and increases in diameter, so as to form a much larger segment of a circle. The iris acquires a darker hue, and its mobility is either greatly impaired, or it is quite paralytic and tremulous. The pupil is generally dilated, and the patient is either myopic, far-sighted or amaurotic, according to the state of the cornea, and the sensibility of the retina. A sense of fulness and tension in the eye, and some degree of headache or hemicrania, are also present in most cases. In the progress of the disease, the cornea becomes nebulous, and rupture eventually takes place, followed by collapse of the organ. It occasionally happens that the complaint is congenital, accompanied with opacity of the cornea, and disappears after the lapse of one or two years. JUENCKIN mentions a Swedish family, seven brothers of which had congenital dropsy of the anterior chamber.

Where there is a redundant secretion of the vitreous humour,—by far the most frequent form of the disease—the eyeball is enlarged in every di-

mension, and particularly in its antero-posterior diameter; the cornea projects in a conical shape, and for a time retains its transparency, but as the symptoms advance, it becomes expanded, flattened and opaque; the iris is motionless, and arched on its anterior surface; the sclerotica is attenuated, and has a bluish, or dark brown appearance; the patient is myopic in the beginning, but vision is soon lost altogether; the pain is severe, deeply seated, and attended with an agonizing feeling of distension; the globe, enlarged tense and immovable, protrudes between the lids, and being constantly exposed to the action of external irritants, inflames and ulcerates; the constitution sympathizes with the local affection, and the disorganized vitreous humour finally escapes through a rupture in the most prominent and attenuated part of the sclerotica.

The causes of hydrophthalmia are not very certainly known; the disease is strictly local in its origin, and has been attributed to a preternatural weakness of the fibrous envelopes, or to any cause by which their resisting power is impaired. It occurs also, as a sequel of acute inflammation of the eye; and in many instances, is probably dependent upon increased action of a more chronic character. In such cases, advantage may be occasionally derived from the local abstraction of blood, counter-irritation, and the internal exhibition of mercury;—more commonly, however, the disease continues

to advance, and produces much uneasiness by the pressure of the globe upon the surrounding parts, and the repeated attacks of inflammation to which the organ is exposed. Under such circumstances, the evacuation of the fluid by an incision of the lower part of the cornea, or by a puncture through the sclerotica, will prove a palliative measure; but to accomplish a radical cure, a segment of the cornea must be removed, as in staphyloma.

GLAUCOMA.

Glaucoma is an affection resembling amaurosis in many of its symptoms, and principally characterized by a green, or yellowish discolouration of the vitreous humour, and impairment, or total loss of vision. It is attended with pain, slight in the commencement but progressively increasing, and a sense of fulness or tension in the globe, which is preternaturally hard to the touch. The vitreous humour is increased in quantity, loses its transparency, and acquires a dirty yellowish, or greenish hue, which at first presents a concave appearance; but gradually becomes more equably diffused throughout the interior of the eyeball. Frequently also, the lens becomes opaque, constituting what has been called *cataracta viridis* or *glaucomatosa*; the pupil is dilated, tardy in its motions, and often irregular; the iris, convex in front,

encroaches upon the cavity of the anterior chamber, and vision, greatly impaired from the beginning, is finally extinguished altogether. The septa of the hyaloid membrane, and the pigmentum nigrum are absorbed to a greater or less degree; and to this circumstance, in conjunction with the pressure upon the retina, and the alteration in the transparency of the humours, the loss of sight is attributable. In the progress of the disease, other tissues become involved, and an assemblage of symptoms is presented, which will be more fully described, when treating of ophthalmitis interna.

There is another form of the complaint, occurring in advanced life, and apparently unconnected with inflammation. The greenish discolouration of the vitreous humour is more or less perceptible, and vision is impaired from this cause, as also by the diminished susceptibility of the retina.

Little is known respecting the causes of glaucoma; it is said to be more prevalent in some countries than in others, and by MR. LAWRENCE, in common with most of the German writers, it is attributed to chronic inflammation of an arthritic character, affecting chiefly the membrane of the vitreous humour. Absence of the pigmentum nigrum, and absorption of the septa of the hyaloid membrane, together with a fluent condition of its contents, are the principal pathological alterations which have been hitherto observed.

Owing to the insidiousness of its approach, it of-

ten happens that this affection has made considerable progress before its existence is discovered, and the prognosis,—unfavourable under any circumstances—is consequently very discouraging. In the incipient stage, advantage may sometimes be derived from the employment of antiphlogistic remedies,—cupping from the back of the neck, active cathartics, colchicum, counter-irritation, and the alterative use of mercury; but when the disease is completely formed, it may be regarded as incurable. In the variety which has been mentioned as sometimes occurring in advanced age, vision may be temporarily improved by the employment of belladonna.

SYNCHISIS OCULI.

The secretory functions of the hyaloid membrane are sometimes destroyed, and the vitreous humour partially absorbed in consequence of long continued internal ophthalmia; a condition to which the term synchisis has been applied. Under such circumstances, the globe loses its tension, becomes flaccid, and the iris, no longer equably supported, acquires an undulating or tremulous motion; the mobility of the pupil is nearly or quite destroyed, and vision is impaired or lost, according to the degree of disorganization,—in the former case, the patient is usually presbyopic. Not unfrequently, the lens

becomes opaque, the septa of the hyaloid membrane are absorbed, and the vitreous humour exhibits a brownish discolouration. As the state of things now described, is merely the sequel of some preceding disease which has subverted the healthy structure of the organ, it is beyond the reach of any surgical treatment. The oscillatory motion of the iris is sometimes produced by falls, blows, and other accidents by which the eyeball is injured; and is also occasionally seen after the operation for cataract,—the patient continuing to enjoy perfect vision.

The tunica hyaloidea is a serous membrane, and consequently liable to the diseases which affect similar tissues in other parts of the body. Its septa are sometimes thickened and rendered opaque by inflammation, and instances are recorded, in which it has even been found ossified; its secretion also, may be deranged from the same cause, pus or lymph is effused, and the vitreous humour undergoes various changes in colour and consistence; to some of which, allusion has already been made.

DISEASES OF THE GLOBE.

THOUGH obliged, for the sake of perspicuity, to describe the lesions of the several tissues as so many separate and independent affections, we rarely find the lines of demarcation as strongly drawn in practice. Inflammation is seldom strictly limited to the part in which it originates, and where it is thus undefined, derives its distinctive appellation from the structure primarily, or most prominently affected. When we consider the number and variety of the tissues which are brought together in the eye, exhibiting an epitome of the whole frame, supplied in part by the same vessels and nerves, and concurring in the performance of one common function, it is even surprising that complications do not exist to a still greater extent, in the affections of that organ.

OPHTHALMITIS.

In this formidable disease, which happily is not of very frequent occurrence, the inflammation attacks several of the tissues which enter into the composition of the eye, either simultaneously, or in such rapid succession, that it is quite impossible to determine the order in which they respectively become involved. The symptoms vary of course

according to the greater or less predominance of the affection of any particular texture, but the same general character may be recognized in every instance. The pain, owing to the unyielding nature of the investing membranes, is always severe,—acute and lancinating, or dull, aching, and throbbing—extending to the parts around the orbit, accompanied with severe headache or hemicrania, and an agonizing feeling of distension; the sensibility to light is extreme, and there is an appearance as of luminous bodies darting before the eyes, indicating the extension of the inflammation to the retina. The pupil is contracted, the palpebræ spasmodically closed, and all motion of the organ exquisitely painful. The external redness is at first inconsiderable, and the pink-coloured vessels of the sclerotica may be observed beneath the conjunctiva, but they are soon concealed by the increasing vascularity of this membrane, which gradually acquires a deep scarlet colour, and is elevated around the cornea in the form of deep chemosis. As the disease advances, various morbid changes are perceptible in the internal parts; the pupil is contracted and immovable, the cornea turbid and finally opaque; and in some instances, the globe, everting the lids, protrudes in the shape of a red fleshy mass, presenting a most unsightly spectacle. If the inflammation be not speedily arrested, suppuration ensues, the cornea ruptures, and the eyeball collapses from the evacuation of its

contents. As might be anticipated, the constitutional disturbance is very severe, and delirium is not an unusual occurrence.

Amaurosis, in a greater or less degree, is a common sequel of this disease, even in its mildest form, and in more aggravated cases, the inflammation not unfrequently terminates in complete destruction of the organ of vision. Opacity, ulceration, and staphyloma of the cornea; disorganization of the iris; synechia anterior or posterior; permanent contraction of the pupil, or closure from effused lymph; cataract; &c. &c., are among its ordinary consequences.

The danger of ophthalmitis is chiefly to be estimated by the vehemence of the pain, the intolerance of light, constitutional disturbance, and the degree in which the transparent tissues, and internal parts are affected. It is said to occur with greatest frequency in the right eye, and the severity of the symptoms sufficiently distinguish it from inflammation of any separate structure.

Causes. Gout, rheumatism, scrophula, and other morbid conditions of the system, may be enumerated among the predisposing causes; and in such cases, the disease will be more readily excited by external violence, neglected inflammation of any of the tissues, intense light, especially when combined with heat, and the usual agents which give rise to the ordinary forms of ophthalmia.

Treatment. The sad consequences of ophthal-

mitis can only be averted by the most prompt and energetic measures, in the very origin of the complaint; general and local depletion, active cathartics, nauseating doses of tartarised antimony, colchicum, mercury, and counter-irritation, should always be employed, with a freedom proportioned to the urgency of the symptoms, and the importance of the diseased organ. Suppuration is, however, very liable to occur, notwithstanding all our efforts; and under such circumstances, it may be proper to relieve the sufferings of the patient, by evacuating the matter through a puncture of the cornea. In some instances, a sufficient portion of the globe is preserved, to form the basis for an artificial eye, but it happens also, not unfrequently, that the humours escape, and the organ degenerates into a mere tubercle.

OPHTHALMITIS INTERNA.

Examples are not unfrequent, in which the inflammation attacks chiefly the internal parts of the eye—the retina, choroid, and iris,—and presents a combination of the symptoms peculiar to the several tissues; differing, however, in some of its features, according as one, or the other, is more prominently affected. It is attended with a dull, aching, and deeply seated pain, extending to the brow and upper part of the head, intolerance of

light, and a sense of fulness or distension in the globe. The external vascularity is slight at first, but gradually increases, and assumes a zonular arrangement around the cornea. Vision is impaired from the beginning, and in aggravated cases is soon destroyed. The frequent scintillations or flashes of light, are often a source of much annoyance, and the usual indications of iritis are also present to a greater or less extent. The pupil is dull and hazy from effused lymph, which is sometimes thrown out in such quantity as entirely to close the aperture; it is generally contracted, and in the progress of the disease not unfrequently quite obliterated. The external tunics eventually become involved, the cornea loses its transparency, and suppuration is not an uncommon occurrence,—the matter making its appearance at the lower part of the anterior chamber, constituting the phenomenon termed hypopium.

There is a species of internal ophthalmia, usually observed in persons of arthritic constitution, which presents an assemblage of symptoms somewhat different from those just described; the pain, lachrymation, intolerance, &c., are equally or more severe—the first indeed is often excruciating, and is described as piercing or lacerating in its character,—but with these are associated many of the manifestations of choroiditis and glaucoma, indicating extensive disease of the internal structures. The conjunctival vessels have a varicose appearance,

and the zonular redness of the sclerotica verges to a leaden hue; nodulated projections arise on different parts of the globe; the iris changes its colour, becomes motionless, and is often drawn towards the lens; the pupil is either contracted and slightly irregular, or it is dilated, and approaches more or less to an oval form; it is sometimes cloudy from lymphatic deposition, and not unfrequently exhibits a greenish tinge. The crystalline may be either implicated or otherwise—in the former case, the opacity assumes a sea green colour; it is often propelled against the iris, encroaching upon the anterior chamber, and in some cases, even lying in close contact with the cornea. Vision is generally soon destroyed, but the occasional coruscations still induce the unfortunate patient to cling to the fallacious hope of its eventual restoration.

The treatment of the variety first mentioned, differs in no respect from that of iritis, and the judicious employment of the usual antiphlogistic measures,—venæsection, purgatives, cupping, &c.—together with the free administration of mercury, will often be followed by the happiest results. In the arthritic species, local depletion, saline laxatives, colchicum, and the alterative exhibition of mercury, afford the greatest probability of success, but the prognosis in this form of disease is extremely unfavourable.

In those cases of internal ophthalmia consequent

upon fever, cholera, parturition, and other enfeebled or depraved conditions of the system, the treatment must be regulated by the state of the patient, and the urgency of the symptoms;—as a general rule, tonic medicines, the sulphate of quinine, the preparations of iron, &c., are indicated under these circumstances, and may be exhibited conjointly with the alterative use of mercury, counter-irritation, and the occasional local abstraction of blood. The oil of turpentine, which has been found useful in certain forms of iritis, would probably be equally serviceable in these more extensive inflammations.

OPHTHALMITIS EXTERNA.

The investing membranes of the eye—the conjunctiva, cornea, and the sclerotica,—are sometimes, in like manner, simultaneously, and almost exclusively affected. A common example of this, has already been noticed under the head of catarrho-rheumatic inflammation; and a similar state of things is not unfrequently witnessed in purulent ophthalmia, and as a consequence of wounds, or the application of morbid secretions.

S

SUPPURATION OF THE GLOBE.

Suppuration is a common termination of the severer forms of ophthalmia which have just been considered, and is indicated by the occurrence of rigors, intense frontal or circum-orbital pain, headache, throbbing, and an intolerable feeling of distension in the eyeball. The conjunctiva is extremely vascular and tumid; the chambers are filled with purulent fluid, and the lens is pushed forward against the cornea, which becomes opaque and prominent. The globe is evidently increased in size, the palpebræ also are greatly swollen, and the symptoms having obtained their highest point of aggravation, the vitality of the cornea is destroyed, rupture takes place, and the eyeball collapses.

The treatment best adapted to avert this melancholy result, has been fully described under the head of ophthalmitis, and need not be repeated on the present occasion. When it has proved unavailing, and suppuration has actually occurred, the sufferings of the patient may be greatly mitigated by making a puncture through the cornea with a cataract knife, and the subsequent employment of warm anodyne fomentations.

It occasionally happens that suppuration of the eyeball is produced by injury or disease of the fifth pair of nerves, the application of a ligature

to the carotid artery, and phlebitis following parturition, or extensive surgical operations.

EXOPHTHALMIA.

Protrusion of the eyeball occurs as a symptom in ophthalmitis, hydrophthalmia, disease of the parietes, and suppuration of the cellular membrane, of the orbit. It is also occasioned by adventitious growths within that cavity, and by various affections of the organ itself. When it arises from inflammation or congestion of the globe, or the surrounding parts, general and local depletion, purgatives, and the usual antiphlogistic treatment will be proper, but enough has already been said of the causes which may produce such a result.

HYPOÆMA.

Effusion of blood into the chambers of the eye, is a frequent consequence of local injury, whether inflicted accidentally, or in the performance of surgical operations, and sometimes occurs to a small extent in the severer grades of iritis. The blood is not diffused through the aqueous humour, but gravitates to the lower part of the chamber, and when extravasated behind the iris, occasionally imparts to the pupil a red appearance. The hemorrhage sometimes takes place into the cellules of the vitreous

humour, and instances are recorded in which it was apparently vicarious of the menstrual secretion. In some of these cases, the effusion recurred at irregular intervals, accompanied with throbbing pain, and a sense of distension in the eye; vision becoming still further impaired after each repetition, in consequence of the accumulating coagulum.

Considered in itself alone, the extravasation is an occurrence of little moment, for the blood is usually soon again absorbed; but when it has arisen from external violence, it indicates great injury of the organ, and requires the adoption of active remedies to guard against inflammation.

PARALYSIS OF THE EYEBALL.

Paralysis of the muscles of the globe may arise from a variety of causes affecting the brain or nerves. The Third Pair, which is more extensively distributed, supplying either wholly or in part, the recti muscles, the inferior oblique, and the levator palpebræ, is most commonly affected; but the trochleares and abducentes may likewise be involved. It is not unfrequently attended with gastric derangement, headache, vertigo, and double vision; the local symptoms, however, will of course vary according to the extent of the paralysis. The prognosis is most favourable when it is confined to the Third Pair.

The treatment must be regulated by the nature of the cause. When there is reason to suspect the existence of any cerebral affection, general depletion, purgatives, mercury, and other appropriate remedies, will be required; under other circumstances, advantage may be derived from counter-irritation by blister, or stimulating embrocations, electricity, and the endermic employment of strychnia.

ATROPHY OF THE EYEBALL.

It sometimes happens that the secretory functions of the eye are destroyed in consequence of long continued ophthalmia, wounds, lesion of the fifth pair of nerves, and other less evident causes. When this occurs, the humours are absorbed, the membranes contract, the globe loses its tension, becomes flaccid, and gradually shrinks to the bottom of the orbit, where it appears in the form of a small yellowish tubercle;—the parts, though greatly reduced in size, still preserving their relative proportions. It rarely happens that surgical assistance, except in so far as it may be required for the adaptation of an artificial eye, is of any avail in the treatment of this affection.

MALIGNANT DISEASES OF THE EYE.

CANCER OF THE EYE.

SCIRRHOUS induration, and cancerous ulceration of the eye, are very particularly described by the older writers, but there is reason to believe that this peculiar degeneration is much less frequent than was formerly supposed. It is only of late years, that the malignant affections of this organ have been accurately discriminated, and several diseases which were once confounded under the general name of carcinoma, are now ascertained to differ in almost every thing except their fatality. MR. WARDROP has never met with an instance where the coats or contents of the eyeball, were the primary seat of cancer, and intimates a doubt whether it ever originates there; MR. TRAVERS expresses his conviction that it is confined to the lachrymal gland, conjunctiva, and eyelids; and MR. WATSON states, that though he has witnessed many cases of cancer of the orbit, he has never known it to affect any of the coats of the eye, except the conjunctiva.

What these writers affirm, might have been, a priori, anticipated, from the structure of the organ; it could hardly be imagined that the fibrous textures of the cornea and sclerotica were susceptible of such a change; and the internal parts of the eye,

—the choroid and retina,—are more liable to other malignant alterations. MR. LAWRENCE, however, whose general experience coincides with the authorities above mentioned, relates a solitary instance, in which the globe was converted into an apparently scirrhus mass, presenting an irregular varicose surface, and exhibiting no traces of its original organization; the complaint was of long standing, and ulceration had taken place, but there was no offensive discharge, and the general health continued unimpaired. MR. MIDDLEMORE also, appears to have met with several cases of scirrhus in advanced life, consequent upon repeated attacks of inflammation, and characterized by the severity of the pain, shrinking and induration of the organ, and other symptoms indicative of their cancerous nature. On dissection, the sclerotica was ascertained to be thickened, its proper texture interlaced by bands of a firm white substance, and the contents of the eyeball converted into a solid yellowish mass, permeated by fibrous matter, resembling the dense white cellular striæ of a scirrhus mamma.

Treatment. As in carcinoma of other organs, extirpation is the only remedy; and in the commencement of the complaint, while the globe is freely movable, the cellular membrane and neighbouring parts being yet uninvolved, there is reason to hope that a permanent cure may be thus effected. Under opposite circumstances, the prognosis is

much more unfavourable; but inasmuch as the operation affords the only chance of escape, it should still be proposed, provided the extent of the disease does not preclude the possibility of removing it entirely. In the incipient stage, while there is any doubt as to its real nature, advantage will be derived from the repeated application of leeches, and the use of tonic remedies, as the sulphate of quinine and the carbonate of iron, mild aperients, and small doses of the blue pill in combination with the extract of cicuta. When the disease has unfortunately been suffered to advance until extirpation is no longer deemed advisable, the resources of art can only be employed in mitigating the sufferings of the patient, and smoothing his rugged passage to the grave. Attention to the state of the digestive organs, the internal exhibition of opium and other narcotics, and warm fomentations containing laudanum or the vinous tincture of opium, are the means most conducive to this end.

MELANOSIS OF THE EYE.

Melanosis is a rare disease, and has only recently begun to attract attention. Like carcinoma, it occurs towards the middle period of life, and generally makes its appearance simultaneously in other parts of the body. It has been confounded with fungus

hæmatodes, with which it certainly possesses many features in common, but differs from that affection in the period of its attack, its dark or black colour, and the inorganic character of the deposition. It commences with an irritable state of the eye, a turbid condition of the humours, and impairment of vision, which is speedily destroyed altogether; and is attended in its progress, with distension and irregular enlargement of the globe, attenuation and dark brown discolouration of the sclerotica, and opacity of the lens. The pupil is dilated, the iris convex anteriorly, and a dark slate-coloured substance may be observed at the bottom of the eye, which gradually advances, in the form of a black dingy mass, until it is arrested by the cornea. The eyeball enlarges, the unequal prominences increase and are covered with varicose vessels, sloughing or ulceration follows, the surrounding parts become contaminated, and the whole is converted into a dark fungus, accompanied with frequent hæmorrhage, or the discharge of a thick, black and grumous fluid. The disease extends along the optic nerve to the brain, and often shows itself also in other situations. The morbid secretion sometimes occupies the place of the vitreous humour, but is more generally deposited between the choroid and retina. To the symptoms above enumerated as distinguishing melanosis from fungus hæmatodes, may be added the absence of any metallic appearance, the peculiar discolouration of the sclerotica, its more gradual

progress, and the inferior degree of pain with which it is accompanied.

Very little is known of this formidable affection beyond the malignancy of its nature. Extirpation presents the only chance of recovery, and the hope thus afforded, is scarcely strong enough to hold out any encouragement to the operation; unless it be undertaken in its earliest stages, while the disease is still confined to the interior of the eye, and the general health unimpaired. When performed under other circumstances, it has commonly returned, either in the orbit, or some other part of the body.

FUNGUS HÆMATODES OF THE EYE.

Fungus hæmatodes is a much more frequent disease than either of those which have just been described, and is commonly observed in childhood; though instances of its occurrence in more advanced life, have also been recorded. In its incipient stage, it may be recognised by a peculiar lustrous or metallic appearance in the bottom of the eye; and the vessels of the conjunctiva are loaded with blood, the pupil dilated and motionless, and vision usually lost, even at this early period: there is also more or less pain, and the sympathetic irritation of the constitution early betrays the severity of the local disorder. As the disease advances, a yellowish spongy body, par-

tially covered with vascular ramifications from the arteria centralis, may be seen approaching towards the pupil; the humours become turbid, the globe tense, the pain increases, and the lens is pushed forward by the fungus. The cornea now becomes prominent and opaque, the sclerotica is attenuated and presents a livid hue, the superficial vessels exhibit a varicose appearance, the globe is enlarged and irregularly tuberculated from the partial bulging of its investing membranes, and the morbid growth eventually makes its way externally, protruding in the form of a soft bleeding fungus, portions of which occasionally slough, attended with a foetid sanious discharge, and profuse hæmorrhage. The subsequent progress is much more rapid, and the patient worn out by constitutional irritation, and exhausted by repeated loss of blood, finds release from his sufferings only in death.

When the eye has been removed, before the progress of the disease has confounded all traces of its original organization, the retina and optic nerve have appeared to be the primary seat of this destructive malady; the lymphatic glands eventually become affected, not unfrequently also, the bones of the orbit are involved, and medullary formations exist simultaneously in the brain and other parts of the body.

The metallic appearance at the bottom of the eye, is not peculiar to this affection, having been

likewise observed in cases which never evinced any malignancy of disposition. It may be produced by some change in the vitreous humour or hyaloid membrane, and is occasionally seen after penetrating wounds of the eye; in these latter cases, it is attributed to lymphatic deposition between the choroid and retina,—a state of things usually followed by atrophy of the globe.

Treatment. Fungus hæmatodes is a constitutional and fatal disease, from which even the knife of the surgeon affords no hope of escape; the malady having invariably re-appeared after extirpation, though the operation was performed in the earliest stage, and under circumstances the best calculated to ensure success. It may sometimes be resorted to, in order to alleviate suffering and protract existence, but where the character of the disease is unequivocally ascertained, it offers no prospect of permanent relief. A mild antiphlogistic treatment, during the occasional attacks of inflammation which accompany its formative period; and subsequently, the employment of narcotics, the use of anodyne fomentations, and lotions of the chloruret of soda, constitute the whole of our present resources in the management of this dreadful disorder.

There are other forms of malignant disease which do not exactly correspond to either of those which have just been described, but appear to consist in an assemblage of morbid productions,—fungous, mela

noid, sarcomatous, cartilaginous, osseous, and fluid. Such hybrid cases probably depend upon the changes which inflammation and other less appreciable agencies, superinduce in the action of the organizing vessels, and are said to justify a more favorable prognosis than where the affection preserves its perfect purity of type.

T

EXTIRPATION OF THE EYE.

To a certain extent increased action is essential to the reparative process, but the tendency usually is, to transcend the required limits, and it is therefore highly conducive to the successful issue of every considerable operation, that the constitution of the patient should be in such a state, as will most effectually avert the occurrence, or moderate the accession of inflammation. To accomplish this, a preparatory treatment is frequently indicated, and is especially required when an operation is to be performed in the immediate vicinity of any vital organ; or where, as in the eye, the functions of the part may be speedily annihilated by the morbid changes produced by inflammation. The nature and activity of the means employed for this purpose, must be regulated by the circumstances of each particular case, for it would manifestly be preposterous to prescribe the same treatment when the system was exhausted by the pain and irritation of a protracted disease, as would be proper while the general health continued still unimpaired. The preceding remarks apply in all their force to the formidable operation about to be described. All due precautions, therefore, having been sedulously adopted, the patient should be placed in a supine position, and the palpebræ divided at their external commissure, so that they may be everted to an

extent sufficient to expose the margin of the orbit. A strong ligature is now passed through the globe, and being drawn upwards by an assistant, the conjunctiva is divided along its lower portion, by means of a small straight scalpel, cutting through the fibres of the inferior oblique muscle, and detaching the eyeball from the floor on which it rests. The incision is then continued along the upper surface, separating the conjunctiva from the lid, and dividing the tendon of the obliquus superior, —a part of the operation, during which much caution is requisite to avoid injuring the brain. The diseased mass having been thus detached around its circumference, the next step is to sever its connection with the optic nerve by the curved scissors or scalpel, introduced at the external canthus. The interior of the orbit should afterwards be carefully explored, with a view to the removal of any indurated part which may remain, and it will be proper also, to include the lachrymal gland, if it have not been previously taken away. The hæmorrhage from the ophthalmic artery is sometimes considerable, but generally ceases spontaneously; if otherwise, it may be necessary to apply pressure by means of a roll of lint. The subsequent treatment consists in replacing the palpebræ, uniting the divided commissure by one or more sutures, and covering the whole by a fold of linen moistened with cold water, and supported by a roller. The patient should be treated as for a wound of

equal magnitude elsewhere, with the additional caution rendered necessary, in the present instance, by the proximity of the brain. Quietude, laxatives, confinement to a darkened room, and a restricted diet, will of course be required in every case. On the succeeding day, any foreign substance which may have been introduced to arrest the bleeding must be carefully removed; and if inflammation supervene, general and local depletion, purgatives, warm anodyne injections, and fomentations, will be proper.

NEURALGIA OF THE EYE.

THE nerves distributed to the eye and its appendages, like those which animate the other parts of the body, are not unfrequently the seat of neuralgia. The disease is most commonly seated in the ophthalmic division of the Fifth Pair, to which anatomists agree in attributing the common sensibility of the organ, and the twigs from the nasal branches of which, according to the ingenious hypothesis of MR. WALKER, endow the iris with sensibility to light; a property he considers quite distinct from that of vision. It is characterized by paroxysms of excruciating agony, momentary in their duration, and accompanied with spasmodic contractions of the muscles, by which the globe is suddenly thrown into different directions. There is intolerance of light, profuse lachrymation, and generally a contracted state of the pupil. In many cases, the eyeball preserves its integrity under repeated attacks of this disease, but more frequently it shrinks upon itself, and eventually degenerates into a mere tubercle. When this happens, the pain, which may have previously been so intolerable, as to induce the unfortunate patient to insist upon the extirpation of the organ, ceases entirely.

There is another form of neuralgia, manifesting itself chiefly in a morbid sensibility to the impression of light, which may exist for years, without

producing the slightest change in any of the tissues. It affords an argument in favor of the theory to which allusion has just been made, for vision continues unimpaired in the shade, though the patient cannot endure any considerable degree of light, and is consequently incapacitated from employing the eyes in viewing minute objects. The disease is likewise subject to occasional exacerbations, during which even the reflection from a carpet is intolerable. This variety is usually observed among females, and is probably dependent upon some uterine or intestinal irritation. In one instance, that of a lady who had long suffered from hepatalgia, its exciting cause was merely a slight imprudence in reading by twilight. Persons unacquainted with the nature of this complaint, are apt to attribute it to inflammation of the retina, and apprehensions are entertained lest it should be prelude of amaurosis. Under this erroneous impression, it is sometimes attacked by the whole array of antiphlogistic measures—general and local depletion, counter irritation by blister and seton, rigid seclusion in a darkened apartment for months together, &c., &c.,—without any other result than that of enfeebling the general health, and increasing the severity of the disease.

The removal of the exciting cause, when it can be ascertained, and the steady employment of measures calculated to invigorate the constitution, and allay the irritability of the system, constitute the

appropriate treatment in both species of neuralgia. Aloetic aperients,—in some instances more active purgatives,—the shower bath, exercise in the open air, the preparations of iron, particularly the carbonate and proto-sulphuret, the sulphate of quinine, the vegetable bitters,—columbo, serpentaria,—valerian, and medicines of similar character, in various states of combination, may be employed with more or less advantage in almost every case. Belladonna, internally administered, has also been highly recommended. Frictions around the eye with ether, the compound liniment (R. No. 46,) and other stimulating embrocations, afford temporary relief; and in some cases, benefit has also been derived from moxas, setons, and other modes of counter-irritation.

VARIOUS STATES OF DEFECTIVE
VISION.

MUSCÆ VOLITANTES.

THE appearance of minute objects floating before the eyes has already been noticed as a common symptom in the incipient stage of amaurosis; it occurs also as an independent affection, is sometimes congenital, and may continue through life without seriously impairing vision. If there be only a single black spot, it is termed scotoma, but when more numerous, they have received the fanciful appellation of *muscæ volitantes*. These appearances assume a variety of forms, sizes, and colours, are most perceptible when the eye reposes on a white ground, and frequently occasion much uneasiness from the dread of impending cataract, or amaurosis. The pathology of this complaint is still open to investigation. In many cases it is evidently symptomatic of gastric derangement, which is increased by any temporary aggravation, as when the patient is suffering under an attack of *cephalea nauseosa*, or sick headache. In others, it is caused by a plethoric condition of the system, undue exertion of the visual organs, or any cause capable of modifying the circulation of the retina. It may arise also, from insensibility of certain portions of this membrane, and is perhaps, not unfre-

quently owing to a varicose enlargement of the arteria centralis, or some of the choroidal vessels; particularly when it supervenes upon a state of chronic inflammation of the deeply seated textures.

So long as muscæ volitantes are unattended with pain, and the other symptoms enumerated under the head of amaurosis, the pupil preserves its clear black colour, the iris its accustomed mobility, and the patient retains unimpaired the power of distinguishing minute objects, he may be assured that his forebodings of approaching evil are entirely groundless.

Treatment. When the disease depends upon a varicose condition of the retinal or choroidal vessels, it is generally uninfluenced, except in a very small degree, by any remedies we may employ; but when it is produced by plethora, nervous exhaustion, an atonic state of the system, or is symptomatic of irritation in the alimentary canal, or other organs, relief may often be afforded by measures adapted to the removal of these several causes. A light unirritating diet, regular exercise, gentle aperients of rhubarb and aloes, and the preparations of bark and iron, may be advantageously employed in the circumstances last mentioned; but when it is occasioned by undue plenitude of the vascular system, general and local depletion, abstinence, saline laxatives, and the avoidance of whatever may induce a determination to the head, constitute the appropriate remedies. If the defect have existed

many years, the spots do not increase, and the individual continue to enjoy perfect vision, no treatment of any kind is required.

STRABISMUS.

Strabismus consists in some aberration from the uniform direction of the optic axes, in consequence of which the consent or harmonious agreement between the visual organs is destroyed. Generally one eye only is affected, and the deviation is towards the nose. This variety is attributed to paralysis of the abductor muscle, from affection of the sixth pair of nerves or abducentes; which, owing to their extreme delicacy of structure, and their connection with the sympathetic, are extremely liable to suffer from irritation of the brain, and other parts of the body. In other instances, the eye is turned outwards, indicating lesion of the third pair, or *motores oculorum*. The defect in some cases, appears to depend upon an inequality of power between the retinae, which though it now and then accompanies incipient amaurosis, is more commonly congenital. Strabismus is also frequently observed in cataract, and central opacity of the cornea, and is sometimes attributed to improper training, imitation, the temporary seclusion of an inflamed eye, &c., &c. The vision of the diseased organ is always more or less defective, and when both eyes are involved, the patient is usually near sighted.

The treatment of this complaint must be regulated, in some measure, by the cause which has produced it. When congenital, it rarely happens that surgical assistance is of any avail; but under other circumstances, as where it is dependent upon gastric or intestinal irritation, advantage may be derived from the employment of the appropriate remedies,—aperients, vermifuges, tonics, &c. In other cases, we are directed to tie up the sound eye several hours during the day, and endeavour to call into action the weaker organ. With a view, likewise, to the accomplishment of this object, means have been contrived, to intercept the light in the direction of the deviation. In strabismus divergens, WELLER recommends a pasteboard funnel, having an oval base, and an aperture at its small extremity, to be so applied as to include both eyes, and thus oblige the patient to look straight forward; little benefit, however, can be expected from this, or similar inventions.

MYOPIA.

Myopia is generally attributed to some defect in the organization of the eye, the situation of the lens, or the density of the transparent media; or to an excess of the vitreous humour, and other causes, by which it has been supposed the refractive power of the organ might be increased, or the

retina removed beyond the focal distance of the crystalline. That the complaint is sometimes produced in this way, there can be no question, as when, for example, it occurs in the incipient stage of hydrophthalmia, and in those cases also, in which it is congenital, or affects many members of the same family. More commonly, however, it depends upon the state of the pupil, which having been long contracted, whether from internal ophthalmia, irritability of the iris, or habitual exercise in viewing minute objects, loses its adjusting power, and is restricted within a narrower range of action; so that when the field of vision is extended, it does not dilate to admit a pencil of rays, of sufficient magnitude for distinct vision. A multitude of facts might be adduced in support of the opinion, that the power of adapting the eye to the variations of distance, resides chiefly in the iris.—Thus, it has been observed, that individuals with permanent contraction of the pupil are always very near sighted; that when the mobility of the iris is destroyed, the eye loses the capacity of adapting itself to the perception of objects at different distances; and that when the pupil is dilated by belladonna, proximate objects cannot be distinguished while those which are more remote are plainly visible. The imperfection is, consequently, most prevalent in cities, among literary persons, and those whose occupations require the close exercise of their eyes; while it is comparatively rare in the

country, and is seldom observed in sailors, soldiers and others, whose sphere of vision is more extensive, and who are constantly intent upon the discovery of distant objects. It is commonly believed also, that it diminishes with the advance of years, and that those whose vision is thus defective in their youth, see better than other persons in the evening of life; the reverse, however, is generally true, the individual becoming more near sighted, as he grows older.

Myopia can only be remedied, while the causes which produced it continue to operate, by the use of concave glasses; and the lowest number through which objects can be seen of their natural magnitude without fatiguing the eye, should be selected. They should be worn only when the assistance which they afford is particularly required, and ought not to be hastily exchanged for others of higher power. In the treatment of this complaint, a country residence is desirable, and the patient should abstain from much exercise of the eyes in reading or writing.

PRESBYOPIA.

As life advances, the eye is supposed to undergo certain alterations which impair its refractive power; in consequence of which, the focal distance of the lens is removed beyond the retina, the percep-

tion of near objects is rendered indistinct, and the individual becomes far-sighted or presbyopic. Some of these alterations, however, are counter-balanced by others; the flattening of the cornea for example, and the diminished secretion of the aqueous or vitreous humour, if such changes really occur, might be supposed to be compensated by the increased density of the crystalline. It has been observed that persons who have naturally a large pupil, are usually far-sighted, and it seems probable that this defect, like myopia, is dependent upon the condition of the iris, the delicate fibres of which—the first to feel the impress of approaching age—lose their power of active contractility, and the pupil consequently does not readily accommodate itself to the perception of objects which are near. This view of the subject, is strengthened by the fact, that the complaint usually occurs under circumstances the reverse of those which have been mentioned as favourable to the production of myopia. The only remedy is a convex glass, which corrects the divergence, and concentrates the rays along the visual axis.

HEMERALOPIA.

Hemeralopia is sometimes described as a periodical amaurosis, which makes its attack by day, and disappears on the approach of night, endemic in some countries, and epidemic at certain seasons

in others. There appears to be some reason, notwithstanding the testimony on which it reposes, to doubt the accuracy of this description; and for the most part, it is a mere attendant upon some other affection. Its occasional sporadic occurrence as an independent disease, may not, however, be denied without throwing off all deference to authority, since BOYER records his personal knowledge of an individual, who was thus regularly attacked every spring, for a long period of time. Albinos are hemeralopic, and intolerance of light to a greater or less degree, is a common complaint in most inflammatory affections of the eye; it is also not unfrequently symptomatic of uterine and intestinal irritation in females, and children of delicate or strumous constitutions. In some cases, hemeralopia depends upon a morbid irritability of the iris, produced by excessive employment of the eye on minute objects, or by exposure to a bright light, particularly when reflected from a snowy surface; in consequence of which, the iris contracts so greatly, as to prevent the entrance of luminous rays in sufficient quantity for distinct vision. Persons in whose eyes there is some impediment to the transmission of light along the visual axis, as from opacity, cataract, &c., see less distinctly by day, when the pupil is contracted, than towards evening; but these are not the conditions usually comprehended under the term of hemeralopia. When the disease makes its attack in an intermit-

tent form, the sulphate of quinine, or the liquor arsenicalis, may perhaps be usefully employed.

NYCTALOPIA.

A defect, the reverse of that just described, in which vision, unaffected during the day, becomes impaired, or is altogether lost as the light of the sun is withdrawn; is not of very rare occurrence. It is especially common among seamen, and the inhabitants of warm countries, where the eyes are exposed to the reflected glare of the sea, or the burning rays of a vertical sun; and may arise either from impaired sensibility of the retina, or permanent contraction of the pupil, induced by the powerful stimulus to which the organ is constantly subjected. The prognosis is favourable, but if the complaint be neglected or improperly treated, it is said to terminate occasionally in incurable amaurosis.

Local depletion may be necessary in some cases, counter-irritation will be useful in all, and it will likewise be proper, to enjoin, as far as practicable, the avoidance of the exciting cause.

FORMULÆ.

I. UNGUENTA.....	223
II. FOMENTA.....	226
III. COLLYRIA.....	228
IV. PULVERES.....	231
V. RUBEFACIENTIA	232
VI. CATAPLASMATA.....	233
VII. MEDICAMENTA INTERNE ADHIBITA.....	234

FORMULÆ MEDICAMENTORUM.

I. UNGUENTA.

No. 1.

R.	Zinci Oxid.	3j.
	Adipis ppt.	3j.
	Liquor. Plumb. Sub-Acetat.	3fs.

No. 2.

R.	Adipis ppt.						
	Cetacei, a a,	3ij.
	Ceræ Flavæ	3iij.
	Melt, and add,						
	Camphoræ						
	Zinci Oxid. a a,	gr. iij.

This ointment, spread upon a piece of fine linen, is sometimes applied over the eyelids to prevent them from becoming agglutinated during the night.

No. 3.

R.	Hydrarg. Ammoniat.	gr. xv.
	Cupri Acetat.	gr. viij.
	Zinci Oxid. Imp. ppt.						
	Bol. Armen. a a,	ʒj.
	Adipis ppt.	3j.

No. 4.

R.	Ung. Hydrarg. Fort.	
	Cerat. Plumb. Sub-Acetat. a a,	3j.
	Ung. Hydrarg. Nitrat.	3ij.

No. 5.

R.	Hydrarg. Oxid. Rub.	gr. x.
	Zinci, Sulphat.	gr. xx.
	Adipis ppt.	3ij.
		DUPUYTREN.

No. 6.

R.	Argent. Nitrat.	gr. ii—x.
	Liquor. Plumb. Sub-Acetat.	gr. xv.
	Adipis ppt.	3ij.
		GUTHRIE.

No. 7.

R.	Hydrarg. Ammoniat.	gr. xij.
	Camphoræ	gr. viij.
	Zinci Oxid. Imp. ppt.	gr. xv.
	Adipis ppt.	3iifs.
		JADELOT.

No. 8.

R.	Cupri. Sulphat.	gr. x.
	Camphoræ	gr. iv.
	Zinci. Oxid. Imp. ppt.	gr. vj.
	Adipis ppt.	3fs.
		WELLER.

No. 9.

R.	Zinci Oxid. Imp. ppt.	.	.	.	gr. xv.
	Zinci Sulphat	.	.	.	gr. ifs.
	Hydrarg. Oxid. Rub.	.	.	.	gr. vj.
	Adipis ppt.	.	.	.	3ij.
					WELLER.

No. 10.

R.	Liquor. Plumb. Sub-Acetat.	.	.	.	3fs.
	Ung. Cetacei -	.	.	.	3j.

No. 11.

R.	Hydrarg Oxid. Rub.	.	.	gr. xij—xx.
	Adipis ppt.	.	.	3j.

No. 12.

R.	Ung. Hydrarg. Nitrat.	.	.	.	3j.
	Adipis ppt.	.	.	.	3iij.

No. 13.

R.	Hydrarg. Ammoniat.	.	.	.	3j.
	Adipis ppt.	.	.	.	3ifs.

No. 14.

R.	Oxid. Zinci Imp. ppt.				
	Bol. Armen. a a,	.	.	.	3ij.
	Hydrarg. Ammoniat.	.	.	.	3j.
	Adipis ppt.	.	.	.	3fs.
					JANIN.

No. 15.

R.	Hydrarg. Oxid. Rub.				
	Zinci Carbonat. Imp. ppt. a a,	.	.	.	3fs.
	Plumb. Oxid. Semivit.	.	.	.	3j.
	Zinci Oxid. Imp. ppt.	.	.	.	3fs.
	Hydrarg. Sulphuret.	.	.	.	℥j.
	Balsam. Peruv.	.	.	.	gtt. xv.
	Adipis ppt.	.	.	.	3ij.

The preceding formula is given on the authority of PELLIER, by whom it was much employed in opacities of the cornea.

II. FOMENTA.

No. 16.

R.	Capsul. Papav. Alb.	.	.	.	3j.
	Chamæmel.	.	.	.	3ij.
	Semin. Lini.	.	.	.	3fs.
	Aquæ	.	.	.	oij.

No. 17.

R.	Fol. Cicutæ vel Belladon.				
	Capsul. Papav. a a,	.	.	.	3j.
	Aquæ	.	.	.	oij.

No. 18.

R.	Fol. Stramon. Recent.	.	.	.	3ij.
	Aquæ	.	.	.	oij.

Evaporate, in each of the above prescriptions, one third of the fluid, and strain.

No. 19.

R.	Plumb. Acetat.	℥j.
	Acet. Distillat.	℥j.
	Vin. Opii	℥ij.
	Aquæ	oj.

No. 20.

R.	Decoct. Papav. Capsul.	.	.	.	℥iv.
	Aquæ Rosæ.				
	Mist. Camphor. a a,	.	.	.	℥ij.

No. 21.

R.	Liquor. Ammon. Acetat.	.	.	.	℥ij.
	Aquæ Fervent.	.	.	.	℥vi.
	Ext. Opii.	.	.	.	gr. x.

Dissolve the opium in the water, strain, and add the acetate of ammonia.

No. 22.

R.	Extract. Opii.	gr. x.
	Camphoræ	gr. vj.
	Aquæ Fervent.	℥xij.

To the opium and camphor, previously well triturated, add the water, and strain. A simple solution of one drachm of the extract of opium in a pint of water, may also be usefully employed.

No. 23.

R.	Acet. Distillat.					
	Alcohol. Dilut. a a,	℥j.
	Aquæ	oj.

III. COLLYRIA.

No. 24.

R.	Hydrarg. Chlorid. Corrosiv.	.	.	gr. j.
	Vin. Opii	.	.	3fs.
	Aquæ Rosæ.	.	.	3viii.

No. 25.

R.	Acet. Distillat.	.	.	3fs.
	Vin. Opii	.	.	3j.
	Aquæ Rosæ.	.	.	3viiij.

No. 26.

R.	Argent. Nitrat.	.	.	gr. ij—x.
	Aquæ Rosæ.	.	.	3j.

No. 27.

R.	Cupri Sulphat.	.	.	gr. ij—vi.
	Aquæ Rosæ.	.	.	3j.

No. 28.

R.	Zinci Sulphat.	.	.	gr. ij—iv.
	Aquæ Rosæ.	.	.	3j.

No. 29.

R.	Aluminis.	.	.	gr. ij—x.
	Aquæ Rosæ.	.	.	3j.

No. 30.

R.	Albumin. Ovi.	.	.	q. s.
----	---------------	---	---	-------

Triturate the albumen on a plate with a crystal of the sulphate of alumine, until it forms a coagulum.

No. 31.

R.	Tinct. Iodin.	gtt. xxx.
	Tinct Opii	gtt. xxxvj.
	Aquæ Distillat.	℥iv.
						BERMOND.

No. 32.

R.	Ammon. Muriat.	℥ij
	Cupri Acetat.	gr. iv.
	Aquæ Calcis	℥viij.
						SCARPA.

Digest for twenty-four hours, and filter. It is an useful application in some forms of opacity of the cornea, especially that arising from pannus, or vascular thickening of the conjunctiva; and may be used with an eyeglass, diluted or otherwise, according to circumstances.

No. 33.

R.	Sodæ Borat.	℥ss.
	Aquæ	℥ij.

No. 34.

R.	Cadmii Sulphat.	gr. j.
	Aq. Distillat.	℥ij.

No. 35.

R.	Liquor Plumb. Sub-Acetat.	℥ss.
	Vin. Opii	℥j.
	Aquæ Rosæ.	℥viij.

No. 36.

R.	Zinci Sulphat.	gr. ij.
	Liq. Plumb. Sub-Acetat.	gtt. iij.
	Tinct. Camphor.	gtt. xij.
	Aq. Distillat.	℥j.

No. 37.

R.	Plumb. Acetat.	gr. v.
	Zinci Sulphat.	gr. iij.
	Vin. Opii.	℥ij.
	Acet. Distillat. a a,	℥ij.
	Aquæ	℥vj.

No. 38.

R.	Cupri Sulphat.	gr. vj.
	Camphoræ	℥j.
	Aq. Fervent.	℥viij.

BATES.

No. 39.

R.	Lapid. Divin.	gr. ij—iv.
	Aquæ Rosæ.	℥j.

The Lapis Divinus was introduced into practice by *St. Yves*, and may, perhaps, form an useful collyrium in some cases, though it probably possesses no superiority over the simple salts above mentioned. It is prepared, by fusing together in a crucible, three ounces each, of the nitrate of potash, and the sulphates of copper and alumine, and adding towards the close of the process, half an ounce of pulverized camphor.

IV. PULVERES.

No. 40.

R. Hydrarg. Oxid. Rub. . . gr. iv—viij.
 Sacch. Alb. 3j.

No. 41.

R. Hydrarg. Oxid. Rub. . . . gr. x.
 Zinci Oxid. Imp. ppt. . . . gr. xx.
 Sacch. Alb. 3ij.

DUPUYTREN.

No. 42.

R. Zinci Oxid.
 Sacch. Alb. a a, partes æquales.

No. 43.

R. Zinci Oxid.
 Hydrarg. Chlorid. Mitis
 Sacch. Alb. a a, partes æquales.

DUPUYTREN.

No. 44.

R. Pulv. Opii gr. iv.
 Hydrarg. Chlorid. Mitis
 Sacch. Alb. a a, ʒj.

The preceding formulæ, very finely levigated, are employed in corneal opacities, being blown through a quill, or dropped on the eye by the fingers.

V. RUBEFACIENTIA.

No. 45.

R.	Ung. Hydrarg. Fort.	
	Adipis, a a,	3j.
	Camphoræ,	
	Alcohol, a a,	3ij.
	Aquæ Ammon.	3i.

To the camphor dissolved in the spirits of wine, add the aqua ammoniæ, and the ointment previously blended with the lard.

No. 46.

R.	Liniment. Sapon.	3ij.
	Camphoræ	3ij.
	Ol. Monard.	
	Aq. Ammon.	
	Tinct. Opii, a a,	3ij.
	Tinct. Cantharid.	3fs.

No. 47.

R.	Ol. Olivæ	
	Aq. Ammon. a a, partes æquales.	

No. 48.

R.	Ol. Laur.	3ij.
	Ol. Mac. Exprim.	3ifs.
	Ol. Caryophyl.	℥j.
	Balsam. Peruv.	3ij.

Recommended by REIL as a stimulating application in ptosis.

No. 49.

- R. Æther. Sulphur.
 Alcohol Ammoniat. Aromat. a a, . 3j.
 Tinct. Camphor. . . . 3ij.

No. 50.

- R. Tinct. Belladon.
 Tinct. Cantharid. a a, partes æquales.

No. 51.

- R. Mist. Camphor. . . . 3ij.
 Tinct. Opii. . . . 3fs.
 Liq. Ammon. Acetat. . . . 3ij.
 Aq. Rosæ. . . . 3iv.

—

VI. CATAPLASMATA.

No. 52.

- R. Cataplas. Farin. Lini. . . 3iv.
 Cerat. Resinos. . . . 3j—3fs.

No. 53.

- R. Pulv. Fol. Cicutæ.
 Pulv. Fol. Hyosciam.
 Farin. Sem, Lini, a a, partes æquales.

Boil in water to the consistence of a cataplasm; a quantity of camphor may also be usefully added. Recommended by GRAEFE, as an application in tylosis, and other indurated conditions of the palpebral margins, to prepare the way for the employment of other remedies.

No. 54.

R.	Capsul. Papav. Alb.	.	.	.	No. iv.
	Fol. Cicutæ.				
	Fol. Belladon.				
	Fol. Hyosciam. a a,	.	.	.	℥j.
	Aquæ	.	.	.	oij.

Evaporate to oifs, strain, add Farin. Sem. Lini, ℥iv. and boil to a suitable consistence.

No. 55.

R.	Lact. Vaccin.	.	.	.	℥ss.
	Pulv. Alumin.	.	.	.	q. s.

Coagulate in a spoon by means of heat.

VII. MEDICAMENTA INTERNE ADHIBITA.

R.	Ol. Terebinth. Rect.	.	.	.	℥j.
	Vitel. Unius Ovi.				
	Tere simul, et adde gradatim.				
	Emuls. Amygdal.	.	.	.	℥iv.
	Syr. Cort. Aurant,	.	.	.	℥ii.
	Tinct. Lavend. Comp.	.	.	.	℥iv.
	Ol. Cinnam.	.	.	.	gtt. iv.

Dose, ℥i three times a day.

CARMICHAEL.

VOCABULARY.

VOCABULARY.

THE HISTORY OF THE UNITED STATES OF AMERICA, FROM THE FIRST SETTLEMENTS TO THE PRESENT TIME. BY JAMES M. SMITH. VOL. I. PART I. CHRONOLOGY. FROM THE FIRST SETTLEMENTS TO THE END OF THE SEVENTEENTH CENTURY.

Part I.

THE FIRST SETTLEMENTS	1
THE DISCOVERY OF AMERICA	15
THE FIRST VOYAGE TO AMERICA	35
THE FIRST SETTLEMENTS IN AMERICA	55
THE FIRST VOYAGE TO AMERICA	75

THE HISTORY OF THE UNITED STATES OF AMERICA, FROM THE FIRST SETTLEMENTS TO THE PRESENT TIME. BY JAMES M. SMITH. VOL. I. PART II. CHRONOLOGY. FROM THE BEGINNING OF THE EIGHTEENTH CENTURY TO THE END OF THE SEVENTEENTH CENTURY.

Part II.

THE FIRST SETTLEMENTS	1
THE DISCOVERY OF AMERICA	15
THE FIRST VOYAGE TO AMERICA	35
THE FIRST SETTLEMENTS IN AMERICA	55
THE FIRST VOYAGE TO AMERICA	75

Part III.

THE FIRST SETTLEMENTS	1
THE DISCOVERY OF AMERICA	15
THE FIRST VOYAGE TO AMERICA	35
THE FIRST SETTLEMENTS IN AMERICA	55
THE FIRST VOYAGE TO AMERICA	75

THE HISTORY OF THE UNITED STATES OF AMERICA, FROM THE FIRST SETTLEMENTS TO THE PRESENT TIME. BY JAMES M. SMITH. VOL. I. PART IV. CHRONOLOGY. FROM THE BEGINNING OF THE EIGHTEENTH CENTURY TO THE END OF THE SEVENTEENTH CENTURY.

VOCABULARY.

ADENITIS CONTAGIOSA PALPEBRARUM. (*αδην, glandula.*)

Purulent ophthalmia. Supposed by some of the German writers to have its seat in the glands of the eyelids.

ADNATA. The tunica conjunctiva. So named from its close adherence to the anterior part of the eyeball.

ÆGILOPS. (*αἴξ, a goat; ὠφ, the eye.*) An ulcer at the inner canthus of the eye, believed by the ancients to be common to the animal from which the appellation is derived.

ALBINO. (*albus, white.*) A person in whose eyes the pigmentum nigrum is deficient, or altogether wanting.

ABDUCENTES. The sixth pair of nerves, or motores externi.

ALBUGO. Opacity of the cornea from interstitial deposition.

ALBUGINEA. The tunica sclerotica,—so named from its white appearance.

AMAUROSIS. (*αμαυρω, to obscure.*) Diminution, or total loss of sight, existing independently of alteration in the natural transparency of the parts anterior to the retina, or of any morbid condition of the eyeball. It is a disease, or rather a symptom, depending on various pathological states of the retina, optic nerve, brain, and other parts of the system.

AMBLYOPIA. (*αμβλυσ, dull; ὠφ, the eye.*) Impairment of vision. Incomplete amaurosis.

ANCHYLOPS. (*αγχι, near; ὠφ, the eye.*) See Ægilops.

- ANCHYLOBLEPHARON.** (*αγκυλος, crooked; βλεφαρον, the eyelid.*) Cohesion of the eyelids at their ciliary border.
- ANTERIOR CHAMBER.** The space between the cornea and the iris, occupied by the aqueous humour.
- AQUA MORGAGNI.** The appellation given to a minute quantity of fluid, supposed by MORGAGNI to be contained within the capsule of the lens.
- AQUEOUS HUMOUR.** The fluid occupying the anterior and posterior chambers of the eye.
- AQUO-CAPSULITIS.** Inflammation of the capsule of the aqueous humour, or lining membrane of the cornea.
- ARCUS SENILIS.** An opaque circle on the circumference of the cornea, occasionally seen in advanced life.
- ATONIA PALPEBRARUM. ATONIATON BLEPHARON.** (*α, priv, and τωος, tone.*) Relaxation of the eyelids.
- ATRESIA IRIDIS.** (*α, priv, and τιτραω, to perforate.*) Closure, or imperforation of the pupil.
- ATROPHY.** (*α, priv; τροφη, nourishment.*) Shrinking of the eyeball.
- BLENNHORRHŒA. BLENORRHAGIA.** (*βλεννα, mucus; ρω, to flow.*) Purulent, or gonorrhœal ophthalmia.
- BLEPHARA.** (*βλεφαριν; βλεπω, to see.*) The eyelids.
- BLEPHARIDES.** (*βλεφαρις, eyelash.*) The cilia.
- BLEPHARITIS.** Purulent ophthalmia. Inflammation of the eyelids.
- BLEPHAR-OPHTHALMITIS. BLEPHARITIS IDIOPATHICA.** Inflammation of the eyelids.
- BLEPHARO-BLENNORRHŒA. BLEPHAR-OPHTHALMIA.** Purulent or gonorrhœal ophthalmia.
- BLEPHAROPHTHALMITIS GLANDULOSA.** Inflammation of the glands of the eyelids. Purulent ophthalmia.
- BLEPHAROPLEGIA.** (*βλεφαρον, eyelid; πληγη, stroke or blow.*) Paralysis of the eyelid.
- BLEPHAROPTOSIS.** (*βλεφαρον; πτωσις, a falling down.*) In-

ability to raise the upper eyelid, from relaxation of the integuments, or paralysis of the levator palpebræ.

BLEPHAROSPASMOS. Spasm of the eyelids.

BUPHTHALMOS. (*βυς, taurus; Οφθαλμος, the eye.*) Dropsy of the eye.

CANAL OF PETIT. A cavity around the circumference of the lens, formed by the membrana vasculosa retinæ.

CANTHUS. (*κανθος, angle of the eye.*) The commissure of the eyelids.

CAPSULE. The membrane which contains the crystalline.

CAPSULITIS. Inflammation of the capsule of the lens.

CARUNCULA LACHRYMALIS. A small glandular body situated in the inner angle of the eye.

CATARACTA. (*καταρρασσα, to break or disturb, because the disease confounds, or destroys vision.*) Opacity of the crystalline or its capsule.

————— *Capsularis.* Opacity of the capsule of the lens.

————— *Capsulo-lenticularis.* Opacity of the capsule and crystalline.

————— *Centralis.* Opacity of the central portion of the lens or capsule.

————— *Dura, Caseosa, Gelatinosa, Fluida, &c.* Distinctions founded on the consistence of cataract.

————— *Fluida-Dura.* Hard opaque nucleus with fluid circumference of the lens.

————— *Gypsea.* Conversion of the capsule into a chalky or bony substance.

————— *Immatura.* Incomplete or unripe cataract.

————— *Lactea.* Milky cataract.

————— *Lenticularis.* Simple opacity of the lens.

————— *Lymphatica.* False cataract from effusion of lymph into the pupil.

CATARACTA. *Marmoracea, Fenestrata, Punctata, Stellata, Stricta, Variegata, Dimidiata, &c.* Distinctions drawn from the different appearances of cataract.

————— *Membranacea.* False cataract from effusion of lymph into the pupil, obstructing the aperture as though it were closed by a membrane.

————— *Pyramidalis.* False cataract, in which the effused lymph projects through the pupil into the anterior chamber.

————— *Siliquosa.* Cataract with a shrivelled and opaque capsule.

————— *Trabecularis.* Trabecular fibrinous cataract; formed by a bar of coagulable lymph extended across the pupil.

————— *Pigmentosa.* False cataract from the deposition of the colouring matter of the uvea upon the capsule of the lens.

CATARRHAL OPHTHALMIA. Conjunctivitis accompanied with a mucous or puriform secretion, and arising from atmospheric vicissitudes.

CATARRHO-RHEUMATIC OPHTHALMIA. Inflammation caused as above, affecting simultaneously the conjunctiva and sclerotica.

CERATATIS. (*κερας, a horn.*) Inflammation of the cornea.

CERATOCELE. (*κερας, and κηλη, tumour.*) Hernia of the cornea, caused by the protrusion of the membrane of the aqueous humour through an opening in that tunic.

CERATOTOME. (*κερας, and τομη, sectio.*) A knife for the incision of the cornea.

CHALAZION. (*χαλαζα, grando, hail.*) A little tumour on the border of the eyelid, so called from its supposed resemblance to a hail stone.

CHEMOSIS. (*χαίω, to gape.*) An inflammatory swelling of the conjunctiva, accompanied with serous effusion into the subjacent cellular tissue; the tumid membrane forms a ring encircling and overlapping the cornea, and in some cases, even protruding from between the eyelids.

CHOROID. (*χόριον, chorion, and ὁμοίς, likeness.*) The dark coloured and highly vascular membrane which secretes the pigmentum nigrum, situated between the sclerotica and retina.

CHOROIDITIS. Inflammation of the tunica choroidea or vasculosa.

CHRUPSIA. (*χρῶς, colour, and ὁψις, vision.*) Cases in which objects appear of a different colour from that which they naturally possess.

CILIA (*cileo, to move about.*) The eyelashes.

CILIARY DUCTS. The excretory ducts of the meibomian glands, opening on the inner edge of the eyelids.

CILIARY MARGIN. The free extremity of the eyelids, at the junction of its mucous lining with the skin.

CILIARY PROCESSES. The reflected portion of the choroid surrounding the lens, and consisting of numerous little folds or plicæ, arranged in a radiated direction.

CIRSOPHTHALMIA. (*κίρσις, varix; ὀφθαλμος, the eye.*) A general varicose state of the blood vessels of the eye.

CLAVUS. (*The head of a nail.*) Protrusion of the iris through an opening in the cornea, in the form of a large and dark-coloured tumour.

COLLYRIUM. (*κόλλα, glue, and ῥεω, to flow.*) A lotion for the eye, so termed because these preparations were formerly of a glutinous nature.

COLOBOMA IRIDIS. (*κολοβω, to mutilate.*) A congenital fissure, generally situated in the inferior portion of the iris.

———— *Palpebrarum.* A defect in the eyelids similar to the above, resembling hare-lip.

CONICAL CORNEA. *Staphyloma Pellucidum.* A disease in which the cornea, retaining its transparency, projects in a conical or sugar-loaf form.

CONJUNCTIVA. (*Conjungo, to join together.*) The mucous membrane which lines the eyelids, and covers the anterior portion of the globe. The adnata.

CONJUNCTIVITIS CATARRHALIS. Catarrhal ophthalmia.

CONJUNCTIVITIS CONTAGIOSA. Purulent ophthalmia.

CONSIDENTIA, OR SUBSIDENTIA PUPILLÆ. Closure of the pupil.

COREDIALYSIS. (*κορη, pupil; διαλυσis, separation.*) An operation for artificial pupil, in which a portion of the iris is separated from its ciliary connections.

COREMORPHOSIS. (*κορη, pupil; μορφωσις, formation.*) The formation of an artificial pupil.

CORETOMIA. (*κορη; τομη, sectio.*) The formation of an artificial pupil by incision.

CORECTOMIA. (*κορη; εκτομη, excision.*) The formation of an artificial pupil by excision.

CORNEA. (*Cornu, horn.*) The anterior transparent portion of the globe.

CORNEITIS. Inflammation of the cornea.

CORONA, OR ZONA CILIARIS. The indented circle on the vitreous humour, caused by the ciliary processes.

CORPUS CILIARE. The radiated wreath or circle, formed by the ciliary processes.

COUCHING. An operation for the cure of cataract, in which the lens is depressed below the axis of vision.

CRYSTALLINE HUMOUR, OR LENS. The convex transparent body, usually of the consistence of wax, situated immediately behind the pupil.

CURETTE. An instrument shaped like a minute spoon or scoop, sometimes used in the extraction of cataract.

CYSTITOME. (*κυστις, vesica; τομη, sectio.*) An instrument or opening the capsule of the lens.

- DACRYOADENITIS.** (*δακρυω, to weep, and αδην, glandula.*) Inflammation of the lachrymal gland.
- DACRYOCYSTITIS.** †(*δακρυω, and κυστις, vesica.*) Acute inflammation of the lachrymal sac.
- DACRYOCYSTALGIA CACHOCHYMIA.** (*δακρυω, to weep; αλγος, pain; κακοχυμια, a redundancy of vitiated humours.*) Inflammation of the lachrymal sac, occurring most commonly in persons of strumous diathesis.
- DACRYOBLENNORRHOEA.** (*δακρυω, and βλεννη, mucus.*) A discharge of mucus from the lachrymal sac.
- DACRYOMA.** (*δακρυω, to weep.*) An impervious state of the puncta lachrymalia.
- DACRYOPŒOS.** (*δακρυ, a tear, and ποιω, to make.*) An appellation given to substances which excite a flow of tears.
- DACRYORHYSIS.** (*δακρυ, and ρυτις, fluctio.*) A preternatural secretion of tears.
- DACRYOSTAGON.** (*δακρυ, and σταγων, a drop.*) Stillicidium lachrymarum.
- DACRYOPS.** (*δακρυ, and ωψ, the eye.*) Swelling of the lachrymal sac.
- DIPLOPSIA.** (*διπλος, double, and οψις, vision.*) Double vision.
- DISTICHIASIS.** (*δισ, twice; στικος, a row.*) A double row of cilia.
- DYSOPSIA.** (*δυσ, difficulter; οψις, vision.*) Impaired vision. Hemeralopia.
- ECCHYMOSES.** (*εξ, out; χυμος, juice.*) Extravasation of blood beneath the conjunctiva.
- ECTROPIUM.** (*εκτρεπω, to divert, to turn out.*) Eversion of the eyelids.
- EGYPTIAN OPHTHALMIA.** Purulent ophthalmia, so called from its ravages among the troops composing the English and French expeditions to that country.
- EMPYESIS OCULI.** (*εν, within; πυσ, pus.*) Suppuration of the eyeball.

ENCANTHIS. (*εν, in; κανθος, angle of the eye.*) Enlargement of the caruncula lachrymalis.

ENTROPIUM. (*εν, and τρεπω.*) Inversion of the eyelids.

EPICANTHIS. (*επι, upon; κανθος, angle of the eye.*) A fold of skin projecting over the internal canthus.

EPIPHORA. (*επι; φερω, to bring.*) An undue secretion of the lachrymal fluid.

EXOPHTHALMIA. (*εξ, out; οφθαλμος, the eye.*) Protrusion of the globe from between the lids.

EXTRACTION. An operation for cataract, in which the opaque lens is removed through an incision of the cornea.

FISTULA LACHRYMALIS. An ulcerated opening, sometimes remaining after suppuration of the lachrymal sac.

FOSSA HYALOIDEA. (*υαλος, crystal, and εidos, likeness.*) The depression on the anterior surface of the vitreous humour, occupied by the lens.

FUNGUS HÆMATODES. (*αιμα, blood, and εidos.*) A malignant and fatal disease of the eye.

GRANDO. An imperfectly suppurating sty.

GRANULAR CONJUNCTIVA. A morbid condition of the mucous lining of the palpebræ, consisting in an enlargement of the minute glands, or some other alteration in the structure of the part, the consequence of inflammation, and generally seen after purulent ophthalmia.

GLAUCOMA. (*γλαυκος, a sea green colour.*) An affection of the eye, resembling amaurosis in many of its symptoms, and characterized by a green or yellowish discolouration of the vitreous humour, and impairment or loss of vision.

GERONTOXON. (*γερων, old; τοξον, a bow.*) Arcus senilis.

GONORRHOËAL OPHTHALMIA. Conjunctivitis caused by the application of gonorrhœal matter to the eye.

GUTTA SERENA. Complete amaurosis. A name given to this disease by the Arabians, in contradistinction to cataract or gutta obscura.

HÆMOPHTHALMIA. (*αιμα, blood; οφθαλμος, the eye.*) See Hypoæma.

HEMERALOPIA. (*ημερα, day; αλας, blind; ωφ, the eye.*) Day blindness. Sometimes described as an intermittent amaurosis.

HEMIOPSIA. (*ημι, half; οφ, vision.*) An affection of the sight, in which the patient sees only half of an object.

HERNIA CORNEÆ. Protrusion of the capsule of the aqueous humour, through an ulcer of the cornea.

HORDEOLUM. (*hordeum, barley.*) A small furunculous tumour on the margin of the palpebra.

HYALITIS. (*υαλος, glass.*) Inflammation of the hyaloid membrane.

HYDROPHTHALMIA. HYDROPHTHALMOS. HYDROPS OCULI. (*υδωρ, water; οφθαλμος, the eye.*) Dropsy of the eye.

HYDROPS SACCI LACHRYMALIS. Enlargement of the lachrymal sac, from the accumulating secretion.

HYPOBLEPHARON. (*υπο, under; βλεφαρον, the eyelid.*) An artificial eye.

HYPOÆMA. (*υπο, under; αιμα, blood.*) An effusion of blood within the eye.

HYPOCHYMA. (*υπο, and χυμα, effusio.*) Cataract.

HYPOGALA. (*υπο, and γαλα, milk.*) Effusion of a milky fluid into the eye.

HYPOLYMPHA. Extravasation of lymph into the anterior chamber.

HYPOPION. (*υπο, and πυν, pus.*) Effusion of pus into the anterior chamber.

IMPERFORATIO PUPILLÆ. Closure of the pupil by the continuance after birth, of the membrana pupillaris.

IRIS. (*ειρω, to show.*) The perforated membrane which extends across the globe, dividing it into two chambers. So called from its varied colour.

IRIDECTOMEDIALYSIS. (*ιρις, iris; εκτομη, excision; διαλυσις, sepa-*

ration.) An operation for artificial pupil, performed by detaching the iris from its ciliary connections, and excising the portion thus separated.

IRIDENCELEISIS. (*ιρις*, and *εγκλειω*, *to enclose*.) An operation for artificial pupil, differing from the above, in that the separated portion of the iris, instead of being excised, is strangulated between the edges of an incision made in the cornea.

IRIDODIALYSIS. (*ιρις*, and *διαλυσις*.) Formation of an artificial pupil, by the simple separation of the iris from the ciliary margin.

IRIDOTOMIA. (*ιρις*, *ιδος*; and *τομη*, *sectio*.) Formation of an artificial pupil by incision.

IRITIS. Inflammation of the iris.

KERATITIS. (*κερας*, *a horn*.) Inflammation of the cornea.

KERATO-IRITIS. Inflammation of the capsule of the aqueous humour. *Aquo-Capsulitis*.

KERATONYXIS. (*κερας*, and *νυξις*, *a puncture*.) An operation for removing cataract by solution, in which the needle is introduced through the cornea.

KORETOMIA. (*κορη*, *pupil*; *τομη*, *sectio*.) Formation of an artificial pupil by incision.

LACHRYMAL CANALS. The ducts, or canaliculi which convey the tears into the lachrymal sac.

LACHRYMAL DUCTS. The excretory ducts of the lachrymal gland.

LACHRYMAL GLAND. The gland which secretes the tears, situated in the external and upper part of the orbit.

LACHRYMAL SAC. The receptacle for the tears, situated near the internal angle of the eye, and communicating with the nose through the nasal duct.

LAGOPHTHALMOS. (*λαγως*, *a hare*; *οφθαλμος*, *the eye*.) A

disease in which from inability to close the eyelids, the globe is left uncovered.

LE MOSITAS. (*λημνη, lippientes oculi.*) Inflammation of the angles of the eye.

LENTITIS. Inflammation of the crystalline lens.

LEUCOMA. (*λευκος, white.*) The dense white opacity of the cornea, following wounds or ulcers.

LEUCOPHLEGMATIA PALPEBRARUM. Serous effusion into the cellular tissue of the eyelids.

LIPPITUDO. The advanced stage of ophthalmia tarsi, in which the palpebral margins become thickened, indurated, and partially everted, so that the eye appears as if surrounded by a red circle.

LUSCITAS. Immovable distortion of the eyeball.

LYTHIASIS. (*λυθος, a stone.*) An imperfectly suppurating sty.

MACULA. A small opaque speck on the cornea.

MARMARYGAL. (*μαρμαριζω, resplendo.*) An appearance as of sparks or coruscations passing before the eyes.

MADAROSIS. (*μαδαρσω, to make bald.*) A falling out of the cilia.

MEIBOMIAN GLANDS. So named from their discoverer, Meibomius; minute glands secreting an unctuous matter, situated beneath the mucous membrane of the eyelids.

MELANOSIS. (*μελανισα, to blacken.*) A malignant and constitutional disease, attended with the deposition of a black grumous matter; sometimes making its appearance in the eye.

MEMBRANA HYALOIDEA. (*υαλος, crystal; εidos, likeness.*) The membrane which secretes, and contains the vitreous humour.

METAMORPHOPSIA. (*μεταμορφω, to transform; οψις, vision.*) Confused or distorted appearances, sometimes seen by persons affected with amaurosis.

MILIUM. A small white tumour, resembling a millet seed, situated on the border of the eyelid.

MILPHOSIS. (*μιλφωση*, *defluvium pilorum palpebræ*.) A baldness of the eyebrows.

MONOCULUS. (*μονος*, *one*.) A bandage for the eyes.

MOTORES OCULORUM. The third pair of nerves.

MUSCÆ VOLITANTES. (*musca*, *a fly*.) A fanciful appellation given to an appearance as of particles moving before the eyes; frequently accompanying the formative stage of amaurosis, but often existing unconnected with that affection.

MYOCEPHALON. (*μυια*, *a fly*, and *κεφαλη*, *the head*.) A small protrusion of the iris through a wound or ulcer of the cornea, supposed to resemble the head of a fly.

MYDRIASIS. (*μυδρω*, *to abound in moisture*.) Preternatural dilatation of the pupil, formerly supposed to be caused by an undue secretion of the humours.

MYODESOPIA. (*μυς*, *a mouse*; *ωδως*, *likeness*; and *ωφ*, *the eye*.)
See *muscæ volitantes*.

MYOPIA. (*μυω*, *to shut*, and *ωφ*, *the eye*.) Near sightedness.

MYOSIS. (*μυω*.) Unnatural contraction of the pupil.

NASAL DUCT. The passage leading from the lachrymal sac into the nose.

NEBULA. A light superficial opacity of the cornea.

NICTITATION. An involuntary twinkling of the eyelids.

NYSTAGMUS. (*νυσταγμος*, *dormitatio*.) Oscillation of the eyeball.

NYCTALOPIA. (*νυξ*, *night*; *αλαως*, *blind*; *ωφ*, *the eye*.) Night blindness.

OBLIQUI. The obliquus superior and inferior muscles of the eye.

OCULUS. The eye.

OCULUS BOVINUS. (*bos*, *an ox*.) An enlargement of the eye caused by disease. *Hydrophthalmus*.

OCULUS LEPORINUS. (*lepus*, *a hare*.) See *lagophthalmus*.

ONYX. (*ονυξ*, *a nail*.) A purulent deposition between the

laminæ of the cornea, resembling the white appearance at the root of the nails.

OPHTHALMIA. (*οφθαλμος*, *the eye*.) A general term for inflammation of the eye.

————— *Contagiosa or Purulenta*. Purulent ophthalmia.

————— *Catarrhalis or Mucosa*. Catarrhal ophthalmia.

————— *Gonorrhœica*. Gonorrhœal ophthalmia.

————— *Morbillosa*. Ophthalmia consequent upon measles.

————— *Neonatorum*. (*νεος*, *juvenis*.) Purulent ophthalmia of infants.

————— *Scarlatinosa*. Ophthalmia following scarlatina.

————— *Erysipelatosa or Serosa*. Erysipelatous ophthalmia.

————— *Tarsi*. Inflammation of the borders of the eyelids.

————— *Variolosa*. Ophthalmia following small pox.

OPHTHALMIC. Relating to the eye.

OPHTHALMITIS. Inflammation of the globe.

OPHTHALMITIS INTERNA OR EXTERNA. Inflammation affecting more particularly the internal or external tissues of the eye.

OPHTHALMO-BLENNORRHOEA. Purulent ophthalmia.

OPHTHALMODYNIA. (*οφθαλμος*; *δυνη*, *pain*.) Violent pain in the eyeball. Neuralgia.

OPHTHALMOLOGY. (*λογος*, *a discourse*.) The science of medicine in relation to the eye.

OPHTHALMOPLEGIA. (*πληγη*, *a blow or stroke*.) Paralysis of the muscles of the eyeball.

OPHTHALMOPONIA. (*πονωω*, *to labour*.) Intense pain in the eye.

OPHTHALMOPTOSIS. (*πτωσις*, *a falling down*.) Displacement of the eyeball.

OPHTHALMORRHAGIA. (*εἶω, to flow.*) Hemorrhage from the eye or palpebræ.

OPHTHALMOS. (*ὀπτομαι, to see.*) The eye.

OPTOMETER. An instrument for measuring the limits of distinct vision.

ORBITA. The bony cavity which contains and protects the eyeball.

OXYOPIA. (*ὀξύς, sharp; ὠψ, the eye.*) Acuteness of vision.

PACHEABLEPHARA. PACHYTES. (*παχὺς, thick; βλεφαρον, the eyelid.*) Enlargement and thickening of the eyelid.

PALPEBRÆ. (*a palpitando, from their frequent motion.*) The eyelids.

PANNUS. (*pannus, cloth.*) A thickened vascular condition of the conjunctiva, covering the cornea.

PATHETICI. The fourth pair of nerves or trochleares.

PHALANGOSIS. (*φάλαγξ, a row of soldiers.*) Inversion of the cilia.

PERIORBITA. The fibrous membrane lining the orbit.

PERIBROSIS. (*περί, about; βρῶσις, erosion.*) Inflammation of the canthi, attended with excoriation.

PINGUECULA. (*Pinguis, fat.*) A little tumour apparently adipose, sometimes growing on the conjunctiva.

PHTHISIS OCULI. Collapse or shrinking of the eyeball.

PROPHYSIS. (*πρὸς; φύσις, natura.*) Adhesion of the globe to the eyelid.

PHLYCTENULÆ. (*φλυκταίναι, small bladders; from φλυζω, to be hot.*) Vesicles containing a watery fluid.

PHOTOPHOBIA. (*φῶς, light; φοβέω, to dread.*) Intolerance or dread of light.

PHOTOPSIA. (*φῶς, light; ὥψις, vision.*) Luminous appearances sometimes seen in amaurosis, and other affections.

PIGMENTUM NIGRUM. The dark colouring matter secreted by the vessels of the choroid membrane.

- POSTERIOR CHAMBER.** The part of the eyeball immediately behind the iris, occupied by the aqueous humour.
- PRESBYOPIA.** (*πρεσβυς, old; ὤψ, the eye.*) Far-sightedness.
- PROLAPSUS IRIDIS.** Protrusion of the iris through an ulcer or wound of the cornea.
- PROTOPSIS.** (*πρῶς, before; πίπτω, to fall.*) Protrusion of the globe between the palpebræ.
- PSOROPHTHALMIA.** (*ψώρα, scabies; ὀφθαλμος.*) Inflammation of the margin of the palpebræ, frequently attended with a troublesome pruritus, and therefore supposed to be of psoric origin.
- PTERYGIUM.** (*πτέρυξ, a wing.*) A morbid production of a triangular shape, usually growing from the internal angle of the eye, and supposed to have its seat in the subconjunctival cellular tissue.
- PHTHEIRIASIS.** (*φθαιριαισις, pedicularis morbus.*) Pediculi attached to the eyelashes.
- PTILOSIS.** (*πτίλος, bald.*) Loss of the cilia.
- PTOSIS.** (*πίπτω, to fall.*) Paralysis of the upper eyelid.
- PUNCTA LACHRYMALIA.** The orifices of the lachrymal canaliculi at the inner canthus of the eye.
- PUPIL.** (*pupilla.*) The aperture in the centre of the iris for the passage of light to the retina.
- PURULENT OPHTHALMIA.** Conjunctivitis, accompanied with the secretion of a purulent matter.
- PUSTULAR OPHTHALMIA.** Conjunctivitis attended with pustules, generally of a strumous character.
- RECLINATION.** A mode of operating for cataract in which the lens is turned backwards into the vitreous humour, on a line with the inferior margin of the pupil.
- RETINA.** (*rete, a net.*) The nervous expansion on the inner surface of the eye, for receiving the impression of light.
- RETINITIS.** Inflammation of the retina.

RHEUMATIC OPHTHALMIA. Inflammation of the sclerotica, produced by atmospherical vicissitudes.

RHEXIS, OR RHEGMA OCULI. (*ρηγμα, a rupture.*) Rupture of the eyeball.

RHOCAS. (*ροκος, qui fluxtione laborat.*) See epiphora.

RHYTIDOSIS. (*ρυτις, a wrinkle; ερπω, to draw.*) Collapse of the cornea.

SCHEROMA. Dryness of the eye, from a defect of the secretion of tears.

SCLEROTICA. (*σκληρος, hard.*) The firm white fibrous membrane, which invests the eye, and preserves the form of the organ.

SCOTOMATA. (*σκοτιω, to darken.*) Dark spots sometimes seen in amaurosis.

SCROPHULOUS OR STRUMOUS OPHTHALMIA. Inflammation of any of the tissues of the eye, modified by the strumous diathesis.

SECONDARY CATARACT. An opaque capsule remaining after the absorption of the crystalline.

STAPHYLOMA. (*σταφυλη, a grape.*) Projection of the cornea in the form of a whitish or pearl coloured tumour.

————— *Racemosum.* (*racemus, a bunch of grapes.*) Protrusion of the iris through several ulcers in the cornea, exhibiting an appearance not unlike a cluster of berries.

STAPHYLOSIS. A protrusion or protuberance of the choroid from attenuation of the sclerotica.

STILICIDIUM. (*stillo, to drop; cado, to fall.*) Redundancy of tears, from some obstruction in the excretory portion of the lachrymal organs.

STRABISMUS. (*στραβιζω, to squint.*) Squinting, a disease which consists in some deviation of the optic axes from their uniform directions.

STYE. A little furunculous tumour on the margin of the eyelid.

SYMBLEPHARON. (*συν, together, and βλεφαρον, eyelid.*) Adhesion of the eyelids to the globe.

SYNCHISIS. (*συχνω, to confound.*) Dissolution of the vitreous humour, from absorption of the septa of the membrana hyaloidea.

SYNECHIA ANTERIOR. (*συνεχεια, continuity.*) Adhesion of the iris to the cornea.

———— **POSTERIOR.** Adhesion of the uvea to the capsule of the lens.

SYNIZESIS. (*συνιζις, a flowing together.*) Closure of the pupil.

TARSORAPHIA. (*ταρσος, tarsus; ραφη, a suture.*) Excision of the tarsal margins; sometimes practised for the cure of ectropium.

TARSUS. The firm elastic cartilage which forms the border of each eyelid, and preserves their even expansion, and accurate adjustment to the globe.

TARAXIS. (*ταρασσω, to disturb.*) A slight degree of conjunctivitis.

TRAUMATIC CATARACT. (*τραυμα, a wound.*) Opacity of the lens, produced by injury.

TRACHOMA. (*τραχος, rough.*) See psorophthalmia.

TRICHIASIS. (*τριξ, a hair.*) Inversion of the cilia.

TUNICA ARANEÆ. (*αρανης, a spider.*) The capsule of the lens.

TUNICA JACOBI. A thin delicate membrane between the choroid and retina, so called from its discoverer.

TUNICA RUSCHIANA. The internal lamina of the choroid, seen only in animals.

TYLOSIS. (*τυλος, callosity.*) Thickening and induration of the ciliary margins.

UVEA. (*uva, an unripe grape.*) The posterior surface of the iris, supposed in animals, to bear some resemblance to an unripe grape.

UNGUIS. A collection of matter between the laminæ of the cornea.

VISUS COLORATUS. A defect of vision in which objects appear surrounded by various colours; occasionally observed in amaurosis.

—— *Defiguratus.* Vision attended with a confused or distorted appearance of objects.

—— *Dimidiatus.* Vision attended with the perception of only one half of an object.

—— *Duplicatus.* Double vision.

—— *Lucidus.* An appearance as of flashes of light before the eyes. Photopsia.

—— *Muscarum.* An appearance as of flies, or minute insects passing before the eyes.

—— *Nebulosus.* Vision in which objects appear as if enveloped in a cloud or mist.

—— *Reticulatus.* Objects appearing as if seen through a net-work or gauze.


VITREOUS HUMOUR. The transparent fluid secreted by the hyaloid membrane, and occupying the posterior portion of the eye.


XEROMA. (*ξηρος, dry.*) An affection in which the conjunctiva, though unchanged in appearance, imparts to the patient a sensation of unnatural dryness. In such cases, it is supposed to arise from obstruction of some of the lachrymal ducts. When it occurs as a symptom in the early stage of ophthalmia, it is owing to deficient secretion on the part of the lachrymal gland. Xerophthalmia.


XEROSIS. A term applied to a peculiar dry and shrivelled condition of the conjunctiva.

XEROPHTHALMIA. Inflammation, with dryness of the conjunctiva ; a frequent symptom in the early stage of ophthalmia.

THE END.







Accession no. 29901

Author Littell, S.
Manual of diseases
...eye

19th cent

Call no. RE46
L58
1837

